# LOW-GRADE NEUROENDOCRINE TUMOUR OF THE CERVIX: REPORT OF 2 CASES OF AN EXTREMELY UNUSUAL NEOPLASM

Belfast Health and Social Care Trust

Pallavi Vijay Borkar[1], Shatrughan Sah[1], Catherine Wight[1], Paul Kelly[2], W Glenn McCluggage[2]
[1]Department of Histopathology, University Hospitals Coventry & Warwickshire NHS Trust, Coventry, UK
[2]Department of Pathology, Belfast Health and Social Care Trust, Belfast, UK

NHS University Hospitals Coventry and Warwickshire NHS Trust

## INTRODUCTION

The neuroendocrine neoplasms (NENs) of female genital tract account for <2% of gynaecological neoplasms.[1] Of these uterine cervix NENs are uncommon with almost all representing neuroendocrine carcinomas (NECs), either small cell or large cell type. Low-grade neuroendocrine tumours (NETs) are vanishingly rare with few reports in the recent literature.[1-4] We present 2 cases of primary cervical NET with unusual features.

## CASE HISTORY

| | Case 1 | Case 2 |
|---|---|---|
| **Age** | 57 years | 53 years |
| **Clinical presentation** | Postmenopausal bleeding for 6 months, cervical polyp on ultrasound scan | Cervical smear: ?Glandular neoplasia of endocervical type, friable tumour in cervix |
| **Biopsy diagnosis** | Low grade NET | High grade (small cell) NEC |
| **Scan findings** | CT, MRI, PET and octreotide scans: No primary tumour elsewhere | Bilateral pelvic avid lymph nodes |
| **Management** | Radical hysterectomy with pelvic lymphadenectomy followed by chemoradiotherapy | Radical chemoradiotherapy followed by salvage hysterectomy |
| **Final diagnosis on hysterectomy** | Primary cervical well differentiated (Grade 2) NET with lymph node metastasis. FIGO stage IIIC1 | Residual tumour with features of a NET (Ki67 1.3%). FIGO stage IIIC1 |
| **Follow up** | Remains disease free after 2 years | Remains disease free after 2 years |
| **Unusual feature** | Low grade NET, lymphovascular invasion, lymph node metastasis | "maturation" phenomenon secondary to chemotherapy, from high grade NEC to low grade NET |
| **Molecular tests** | No HPV detected | High risk HPV 18 and 51 detected on biopsy and resection |

## HISTOPATHOLOGY

### Case 1

**Biopsy**- Low grade neuroendocrine tumour with sparse mitotic figures and no necrosis seen. Tumour cells diffusely positive for chromogranin, synaptophysin and CD56. Ki67 proliferation index 9-10%.
p16 was negative and no HPV was detected on molecular tests.

**Resection specimen**- No tumour was seen on macroscopic examination. Histology showed a 17.4 mm cervical low grade NET with sparse mitosis (1 per 10/ HPF) and no necrosis. Immunohistochemical profile was similar to that seen on biopsy. There was extensive lymphovascular involvement with single metastatic lymph node. FIGO stage IIIC1.

### Case 2

**Biopsy**- High grade (small cell) neuroendocrine carcinoma with small foci of necrosis and high mitotic activity. Tumour cells diffusely positive for chromogranin, synaptophysin,CD56, TTF1 and diffuse block type with p16. Ki67 proliferation index was more than 90%.

**Resection specimen**- Macroscopic examination of cervix showed no tumour. Microscopy revealed a 33 mm residual NET with low grade nuclear features, only scattered mitotic figures (1/ 10 HPF), no necrosis and lymphovascular invasion. Immunohistochemical profile similar to that seen on biopsy. Ki67 proliferation index 1.3%. p16 exhibited block-type immunoreactivity and molecular tests revealed high risk HPV 18 and 51 on biopsy and resection.
FIGO stage IIIC1 (involved bilateral pelvic lymph nodes on PET scan).

## MICROPHOTOGRAPHS

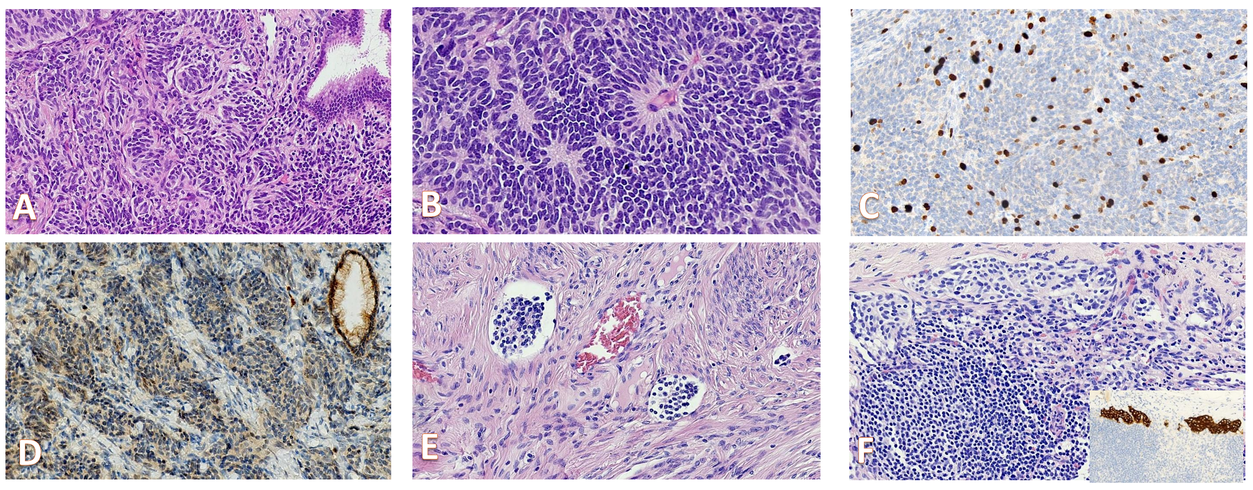


**Figure 1 (Case 1): Biopsy**- (A) solid nests of bland epithelioid & spindle cells within stroma. (B) with pseudoresettes. (C) Ki67 index 9-10%. (D) negative p16 staining. (E) **Resection specimen**- lymphovascular invasion. (F) a lymph node with small focus of metastatic tumour, positive staining with synaptophysin (inset).

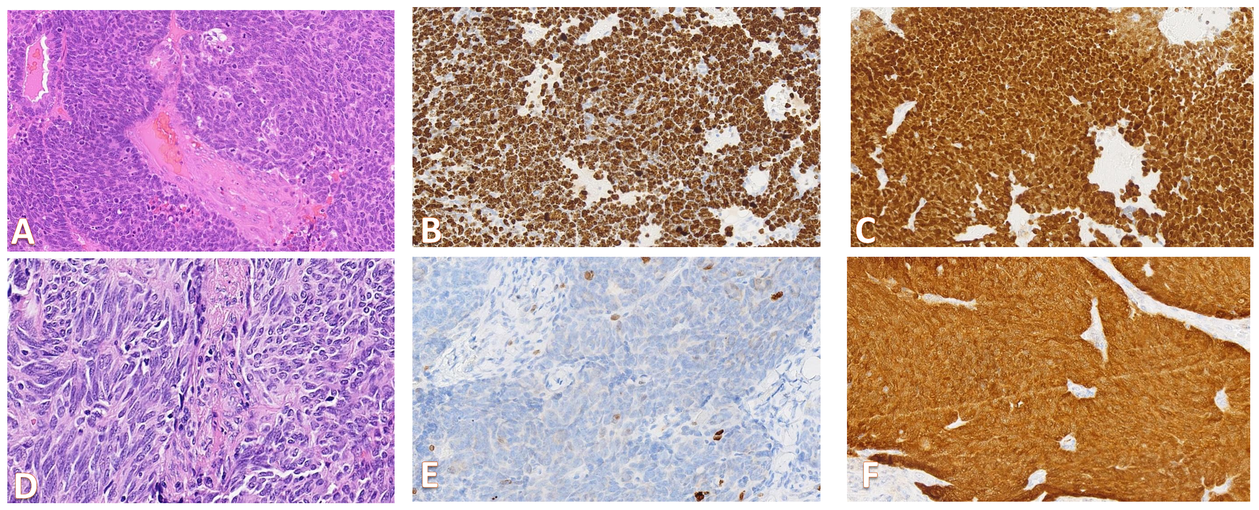


**Figure 2 (Case 2): Biopsy-** (A) monotonous population of cells with high nuclear grade and high mitotic activity. (B) Ki67 index >90%. (C) diffuse block type p16 immunoreactivity. **Resection specimen-** (D) bland spindle cells with low nuclear grade. (E) Ki67 index 1.3%. (F) diffuse block type p16 positivity.

## DISCUSSION

**Neuroendocrine neoplasm (NEN) 2018 WHO proposed classification[5]**

| Site | Category | Family | Type | Grade | Prior terminology |
|---|---|---|---|---|---|
| **Uterus (corpus and cervix)** | Neuroendocrine neoplasm (NEN) | Neuroendocrine tumor (NET) | Uterine neuroendocrine tumor (NET) | G1 | Carcinoid |
| | | | | G2 | Atypical carcinoid |
| | | | | G3 | Atypical carcinoid |
| | | Neuroendocrine carcinoma (NEC) | NEC, small cell-type | | Small cell carcinoma |
| | | | NEC, large cell-type | | Large cell NE carcinoma |

Diagnosis of neuroendocrine neoplasm on histopathology is relatively straightforward with immunohistochemistry. At the same time, it is particularly important to classify them accurately. Uterine cervix NEC usually have aggressive clinical course and managed accordingly with combined approach of surgery and chemoradiation. Clinical outcomes of NET in cervix is unpredictable with limited data available in literature.[1-4, 6] Our first case even though was low grade NET behaved in aggressive manner with lymph node metastasis. A combination of NET and NEC is extremely rare at all sites since they are thought to have a different pathogenesis. We speculate that in the second case, the NET developed out of the NEC as a "maturation" phenomenon secondary to chemotherapy rather that this representing a combined tumour. This is highly unusual and has not been reported in literature yet.

## CONCLUSION

These cases highlight importance of identifying neuroendocrine neoplasm accurately and a multimodality treatment approach for better patient outcomes. And actively seek specialist pathologist opinion in cases with unusual features.

## REFERENCES

1.Chun YK. Neuroendocrine Tumors of the Female Reproductive Tract: A Literature Review. Journal of Pathology and Translational Medicine. 2015; 49, 450–461. https://doi.org/10.4132/jptm.2015.09.20
2.Peng P, Ming W, Jiaxin Y, & Keng S. Neuroendocrine tumor of the uterine cervix: a clinicopathologic study of 14 cases. Archives of Gynecology and Obstetrics. 2012; 286, 1247–1253. https://doi.org/10.1007/s00404-012-2407-2
3.Yoshida Y et al. Atypical metastatic carcinoid of the uterine cervix and review of the literature. Journal of Obstetrics and Gynaecology Research. 2011; 37, 636–640. https://doi.org/10.1111/j.1447-0756.2010.01402.x
4.Ishikawa M et al. A multi-center retrospective study of neuroendocrine tumors of the uterine cervix: Prognosis according to the new 2018 staging system, comparing outcomes for different chemotherapeutic regimens and histopathological subtypes. Gynecologic Oncology. 2019; 155, 444–451. https://doi.org/10.1016/j.ygyno.2019.09.018
5. Rindi G et al (2018). A common classification framework for neuroendocrine neoplasms: an International Agency for Research on Cancer (IARC) and World Health Organization (WHO) expert consensus proposal. Modern Patholoigy. 31: 1770-1786. https://doi.org/10.1038/s41379-018-0110-y
6. Howitt BE, Kelly P, McCluggage WG. Pathology of Neuroendocrine Tumours of the Female Genital Tract. Current Oncology Reports. 2017; 19, 59. doi: 10.1007/s11912-017-0617-2