The British Association of Gynaecological Pathologists

Synchronous endometrioid carcinomas of the endometrium and the ovaries

X. Matias-Guiu, M.D.
Hospital Universitari Arnau de Vilanova, University of Lleida, IRBLLEIDA
Hospital Universitari de Bellvitge, IDIBELL.

Simultaneous endometrioid carcinomas of the endometrium and the ovaries

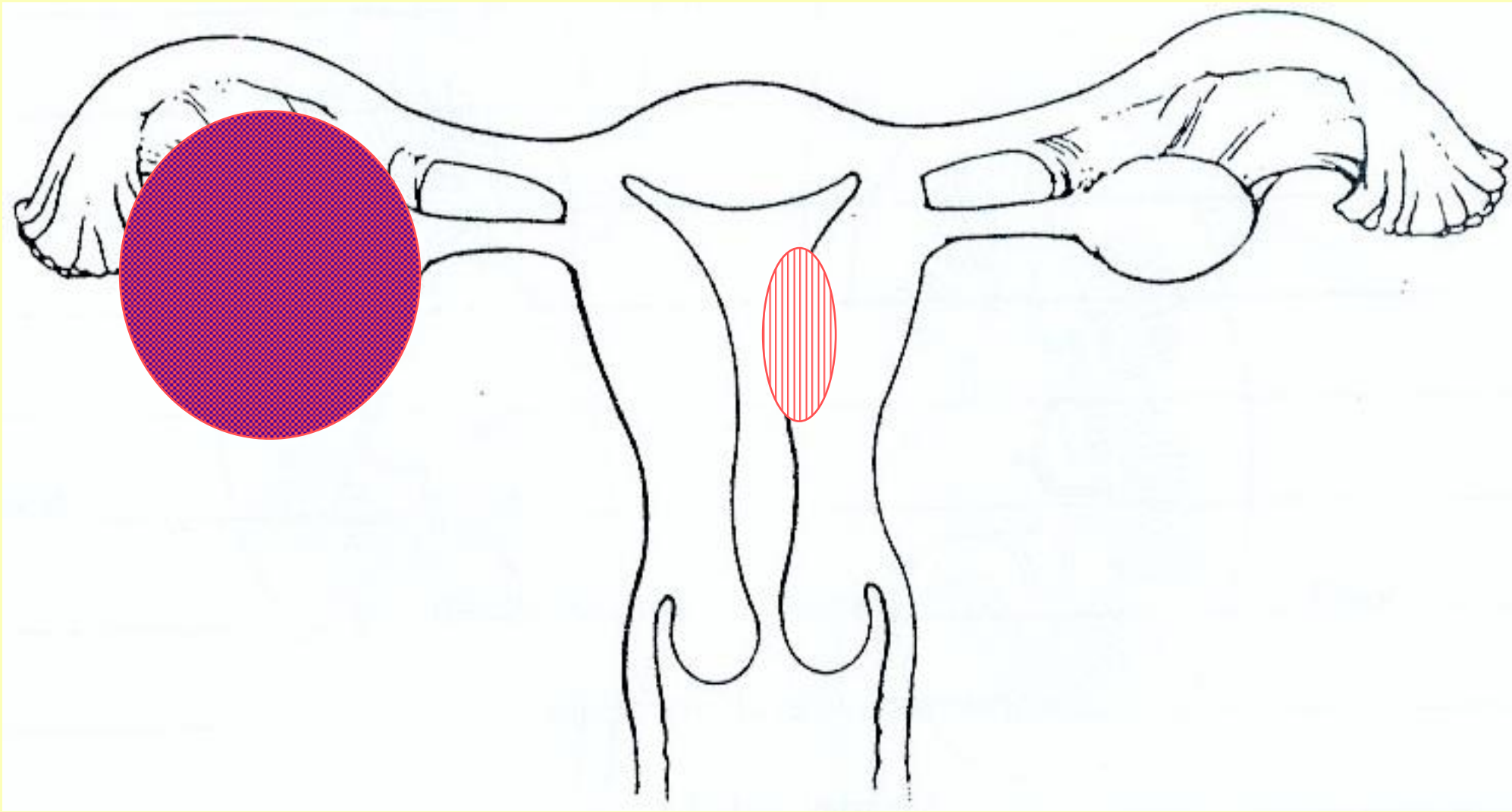

Simultaneous endometrioid carcinomas of the endometrium and the ovaries

- 15-20% ovarian endometrioid carcinomas, and 5% of endometrial carcinomas
- Usually favourable outcome suggest independent origin, but may be metastatic or uncertain

Simultaneous endometrioid carcinomas of the endometrium and the ovaries (Criteria)

- Tumor sizes
- Histological grades
- Bilaterality
- Pattern of tumor growth
- Tubal, myometrial, vascular invasion
- Presence of endometriosis

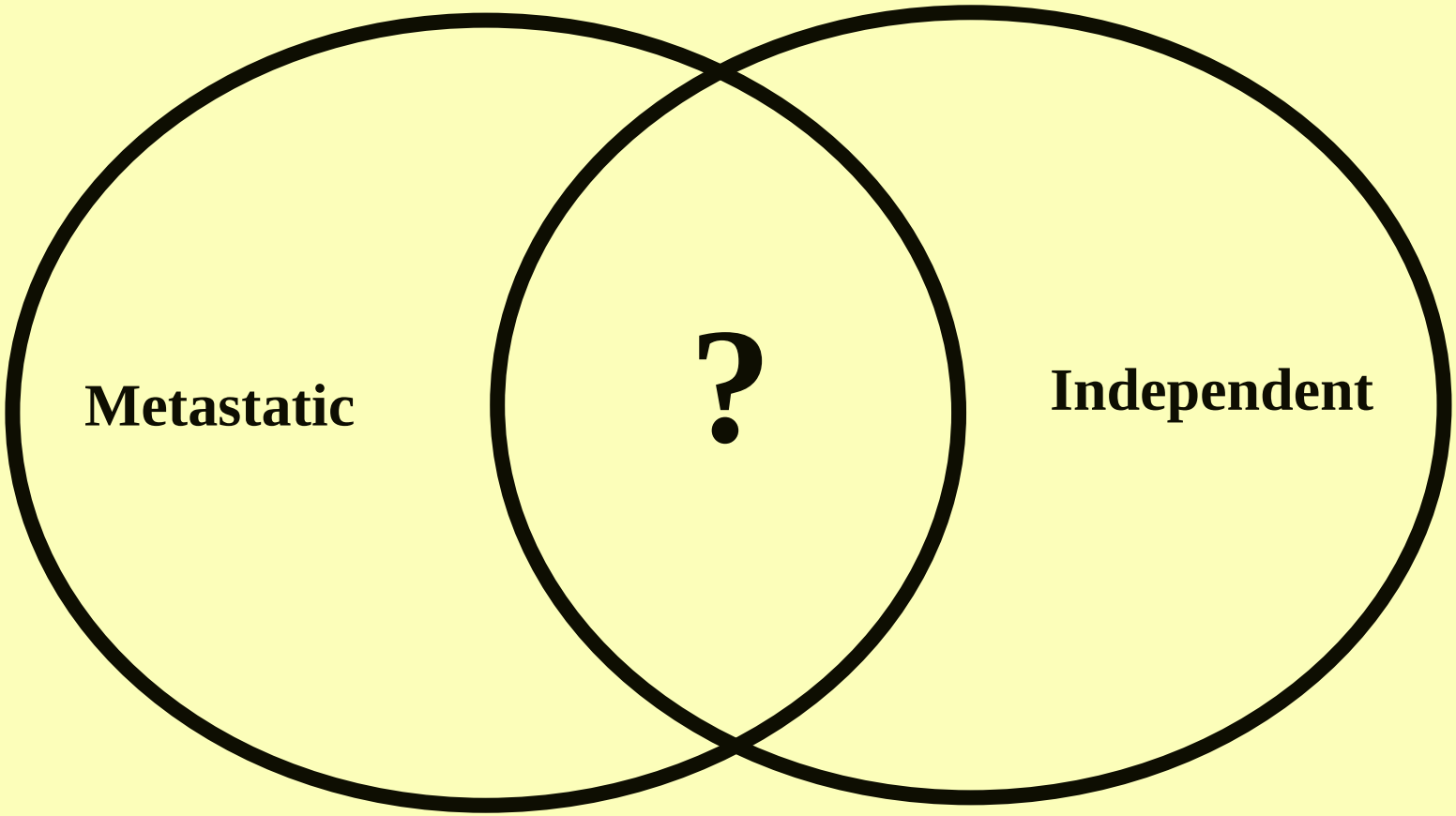
Metastatic
?
Independent

Simultaneous endometrioid carcinomas of the endometrium and the ovaries (Techniques)

- Immunohistochemistry
- Flow Cytometry
- LOH analysis
- Single gene approaches
- High throughput genomic approaches (cDNA, aSNP)

Prat J, Matias-Guiu X, Barreto J: Simultaneous carcinoma involving the endometrium and the ovaries. Cancer 1991 68:2455-9

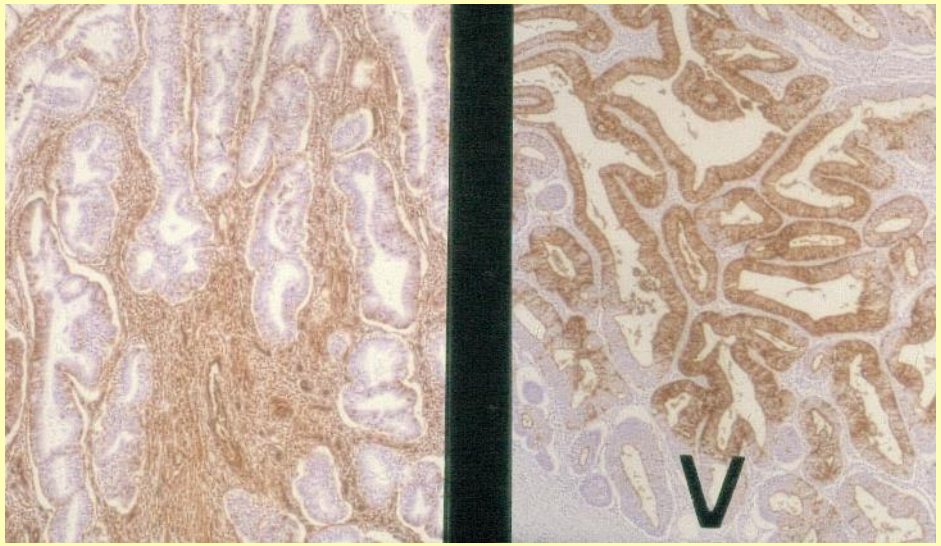

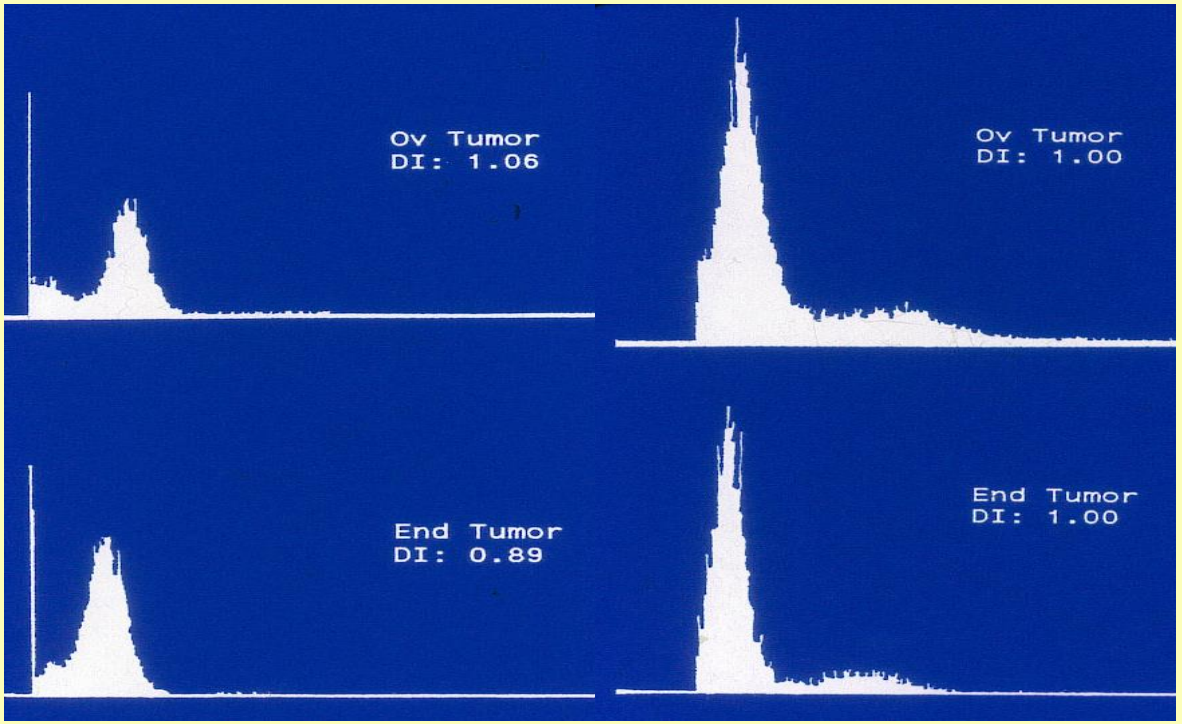

Use of gene expression profiles to stage concurrent endometrioid tumors of the endometrium and ovary

Alfred Guirguis [a], Esther Elishaev [b], Sung-Hee Oh [c], George C. Tseng [c], Kristin Zorn [a], Julie A. DeLoia [a,*]

[a] *Department of Obstetrics, Gynecology and Reproductive Sciences, University of Pittsburgh, PA, USA*
[b] *Department of Pathology, University of Pittsburgh, PA, USA*
[c] *Department of Biostatistics, University of Pittsburgh, PA, USA*

Received 5 July 2007

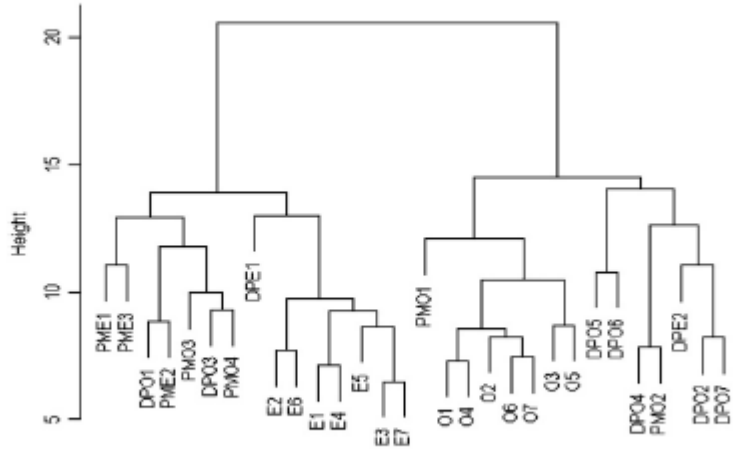

Fig. 3. Hierarchical unsupervised clustering of all samples in both the training and test sets using the SAM-generated 163 gene list. E = primary endometrial cancer, O = primary ovarian cancer, PME = primary metastatic endometrial cancer, PMO = primary metastasis to the ovary, DPO = dual primary ovarian cancer, DPE = dual primary endometrial cancer.

Human Pathology (2005) **36**, 605–619



ELSEVIER

Human
PATHOLOGY

www.elsevier.com/locate/humpath

Original contributions

Synchronous endometrioid carcinomas of the uterine corpus and ovary: alterations in the β-catenin (*CTNNB1*) pathway are associated with independent primary tumors and favorable prognosis☆

Julie A. Irving MD, FRCPC[1], Lluis Catasús PhD, Alberto Gallardo MD, Elena Bussaglia PhD, Marisa Romero BSc[2], Xavier Matias-Guiu MD[3], Jaime Prat MD, FRCPath*

MOLECULAR FEATURES OF ENDOMETRIOID CARCINOMA

ENDOMETRIUM

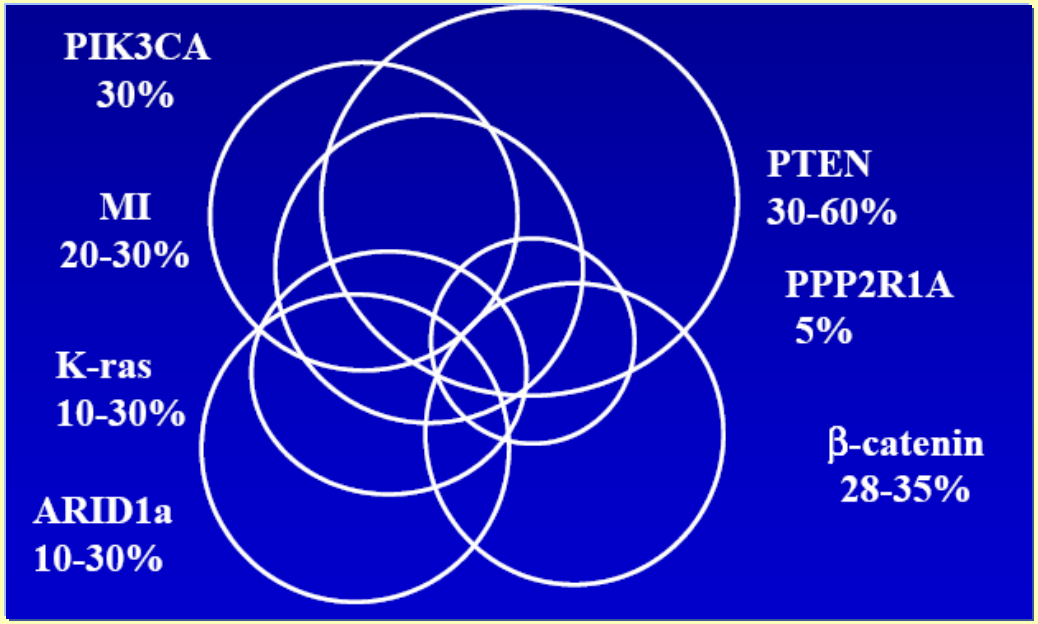

OVARY

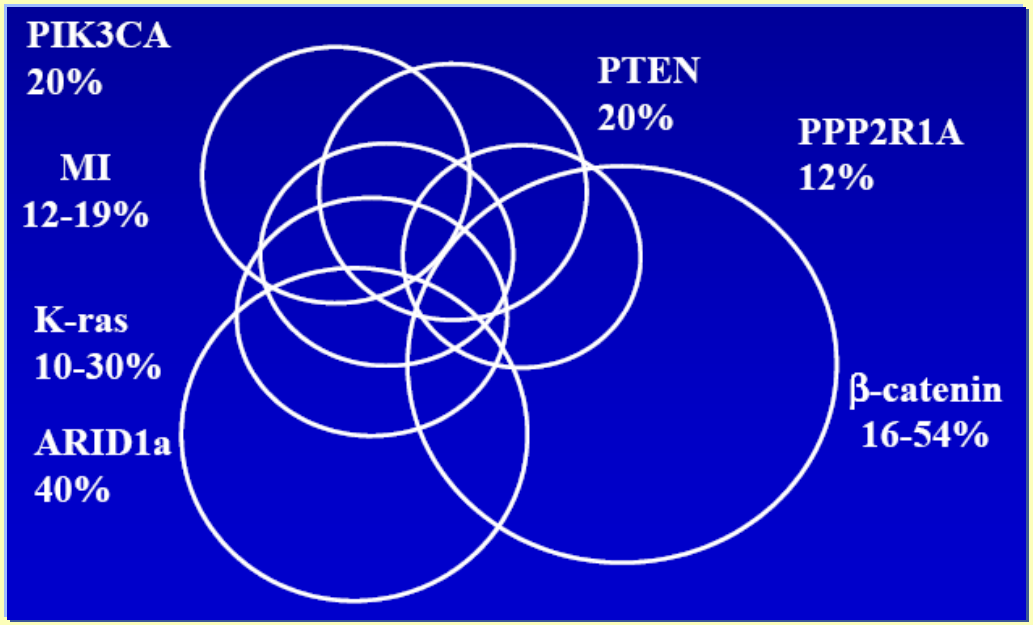

Independent Primary Endometrioid Carcinomas of Uterus and Ovary

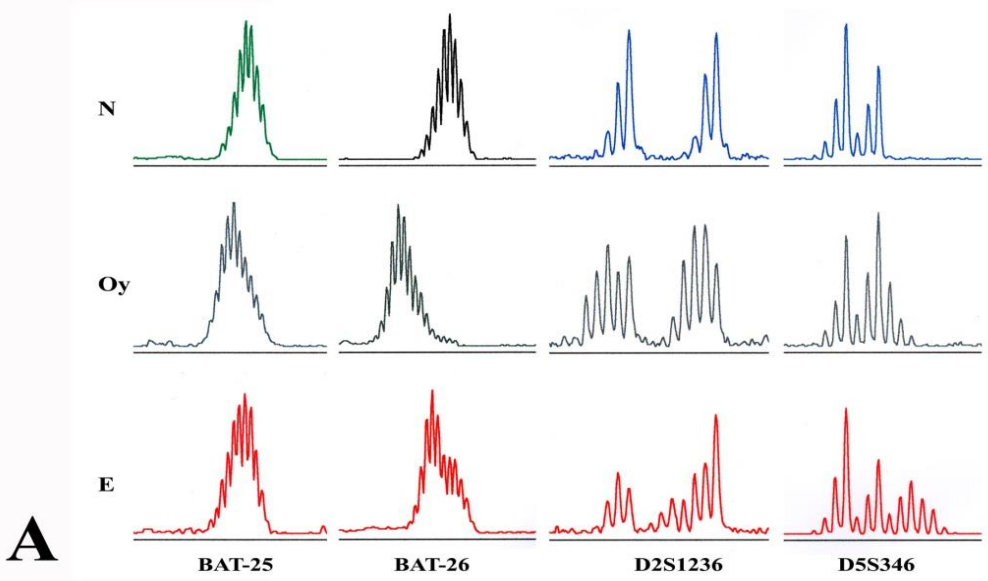

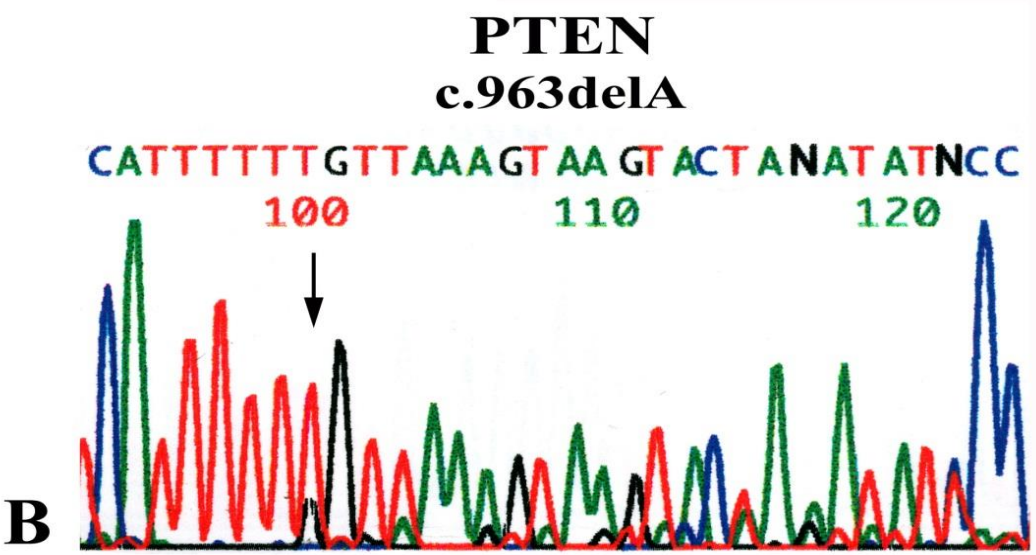

Different MI pattern

Identical PTEN mutation

Irving J et al
Hum Pathol 2005

Metastatic Carcinoma

(Identical MI pattern - AWT at 3 y)

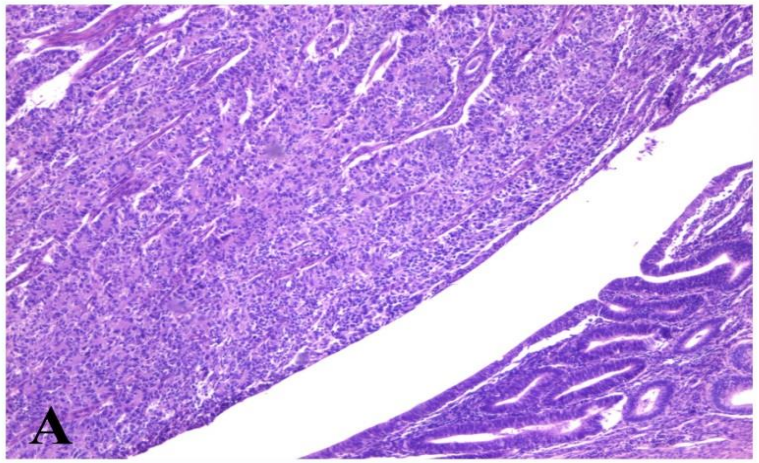

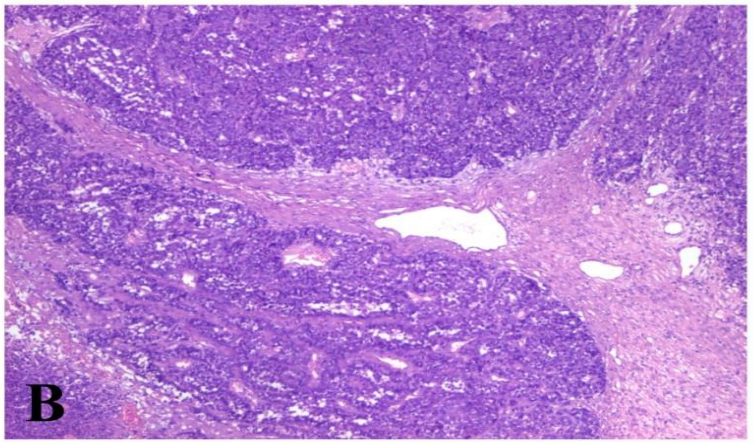

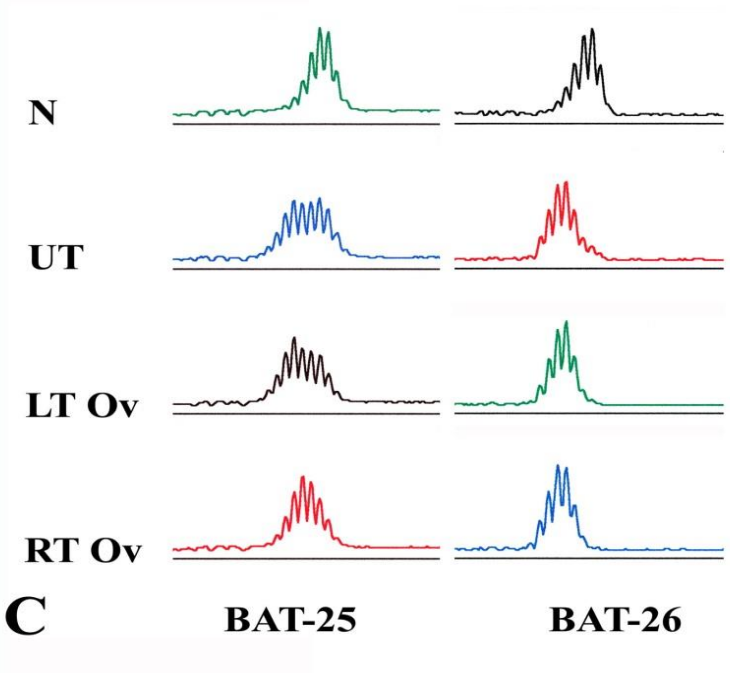

Irving J et al Hum Pathol 2005

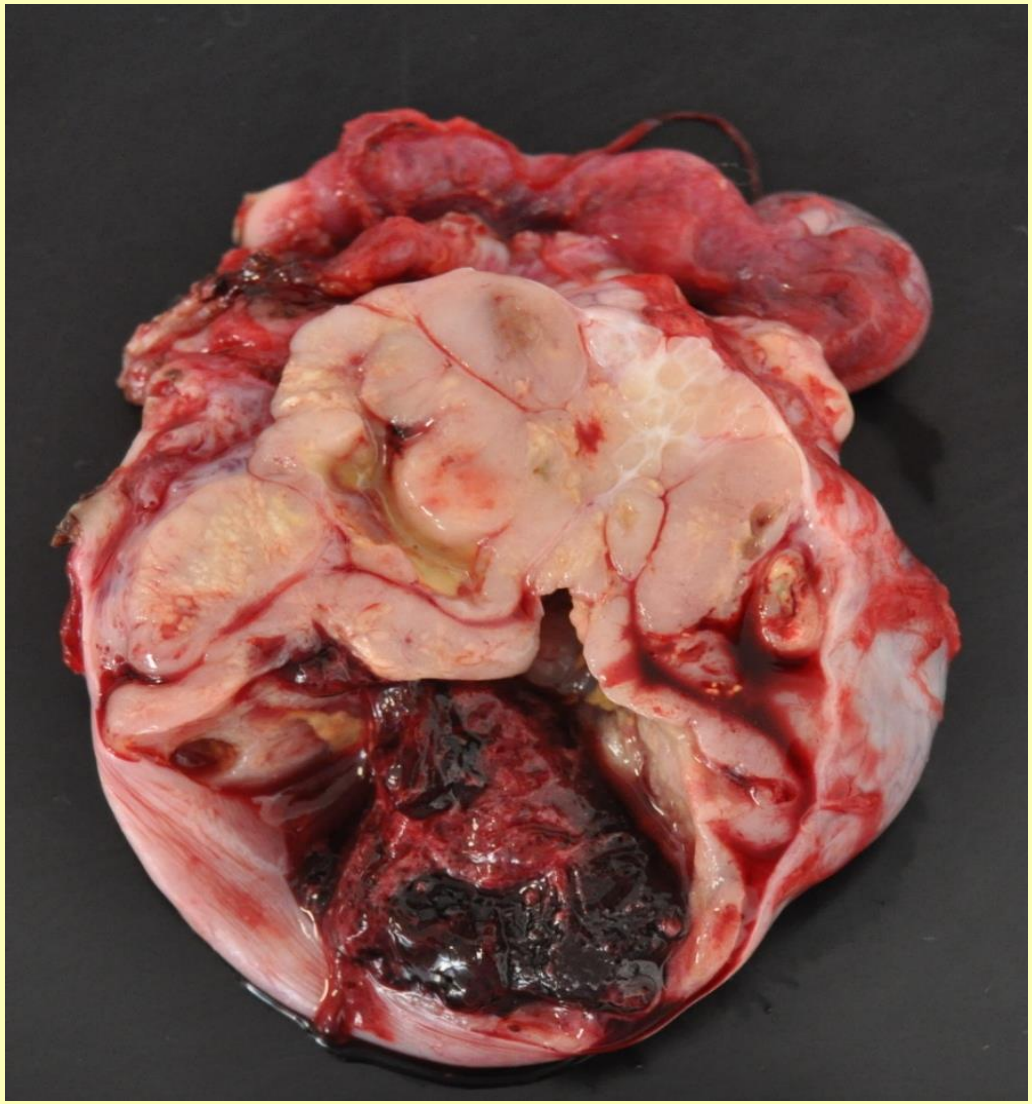

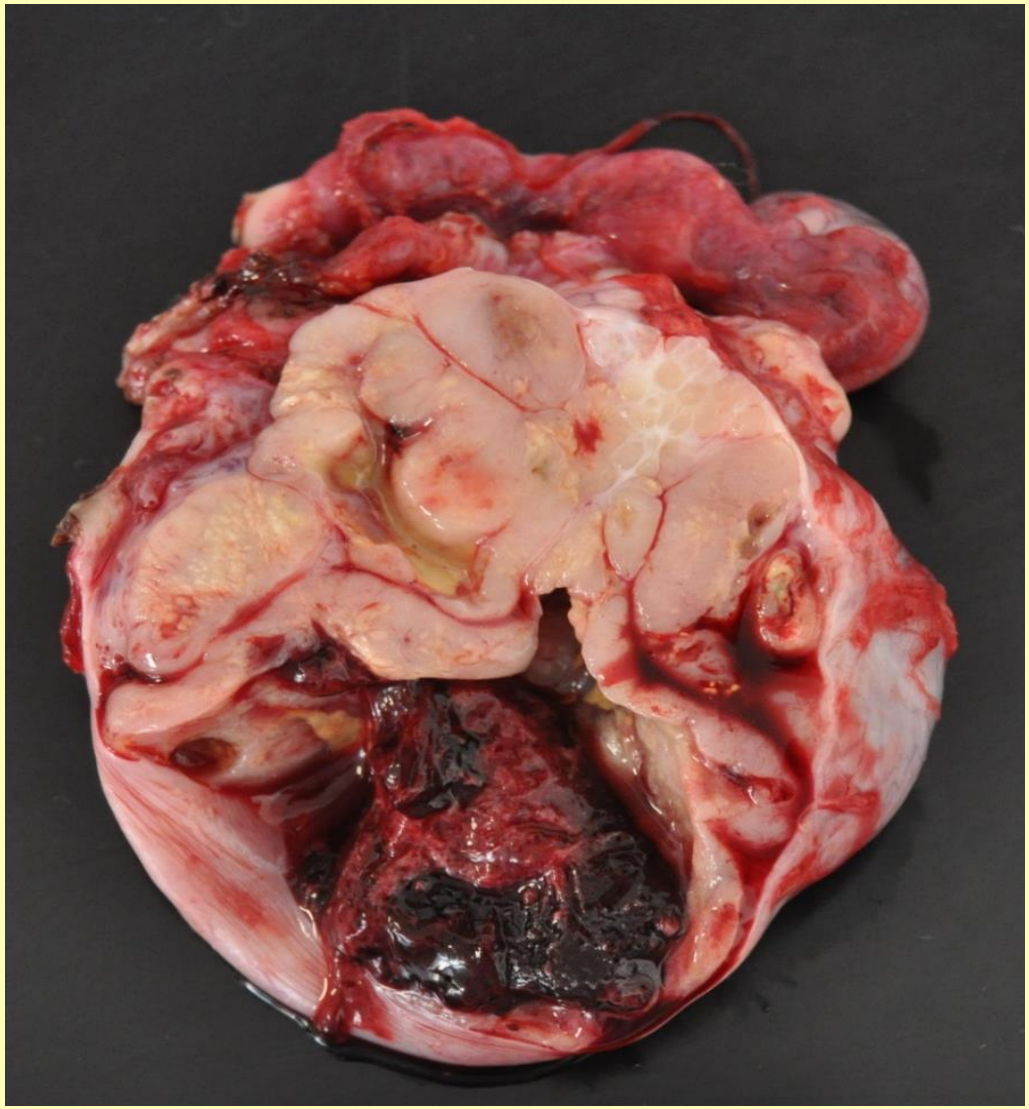



CTNNB1 S33Y
TCT-TAT

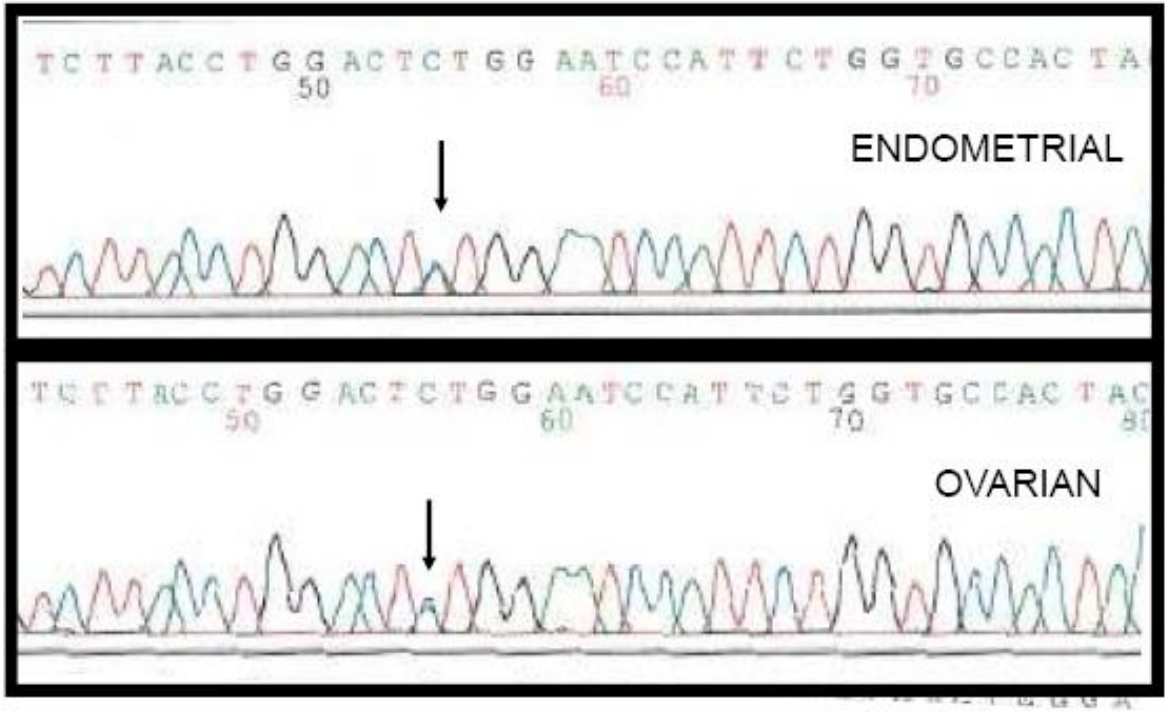

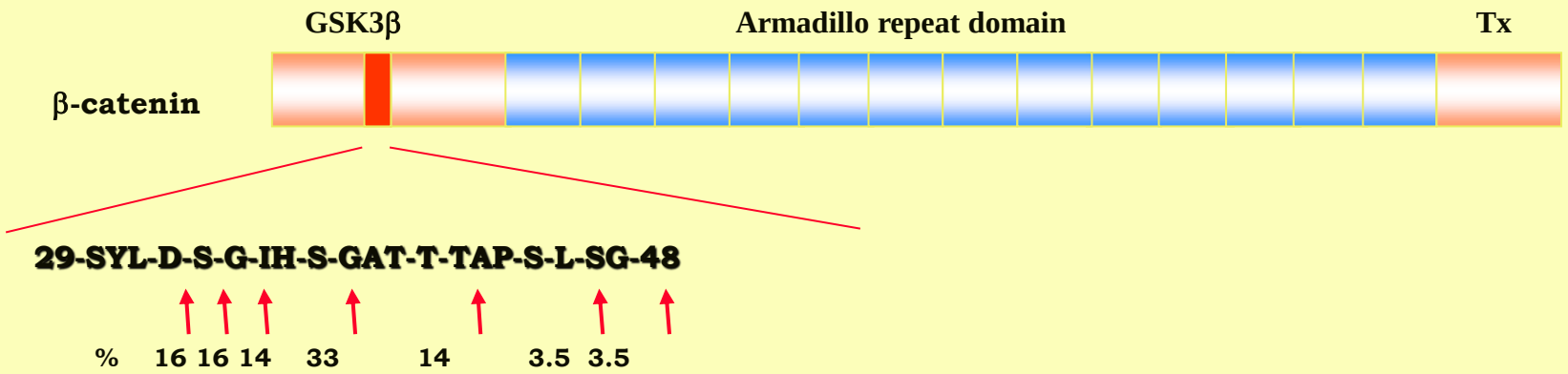





Independent carcinomas
NED @ 18 yrs

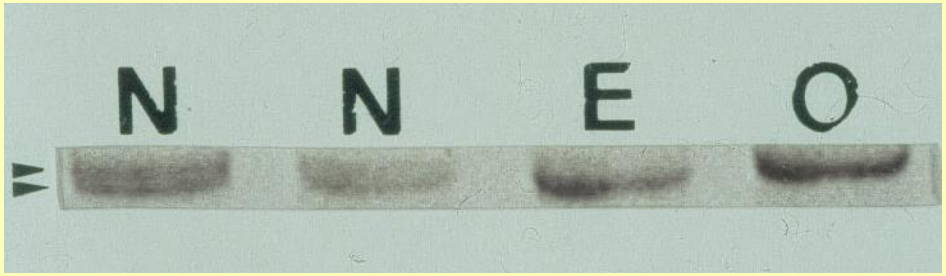
N
N
E
O


BAT-26
N
E
O

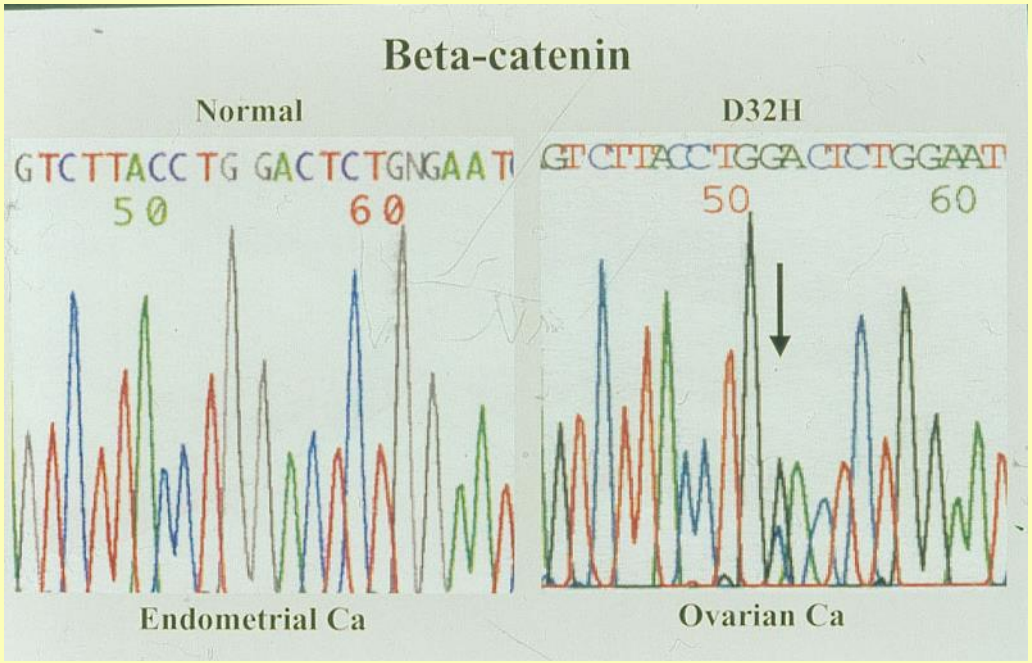
Beta-catenin
Normal
D32H
GTCTTACCTG GACTCTGNGAAT
50
60
GTCTTACCTGGACTCTGGAAT
50
60
Endometrial Ca
Ovarian Ca

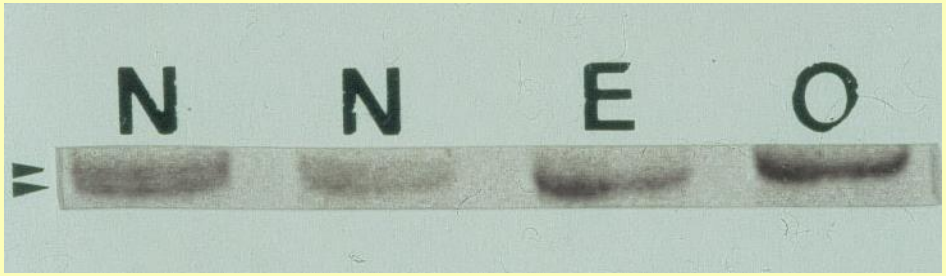
N
N
E
O

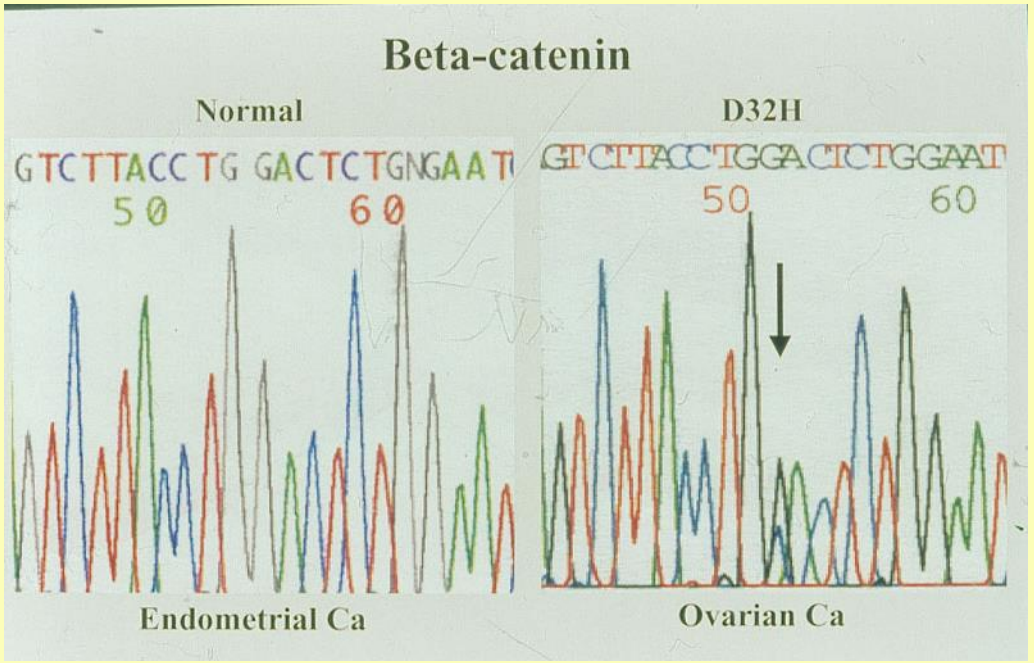
Beta-catenin
Normal
D32H
GTCTTACCTG GACTCTGNGAAT
50
60
GTCTTACCTGGACTCTGGAAT
50
60
Endometrial Ca
Ovarian Ca


BAT-26
N
E
O

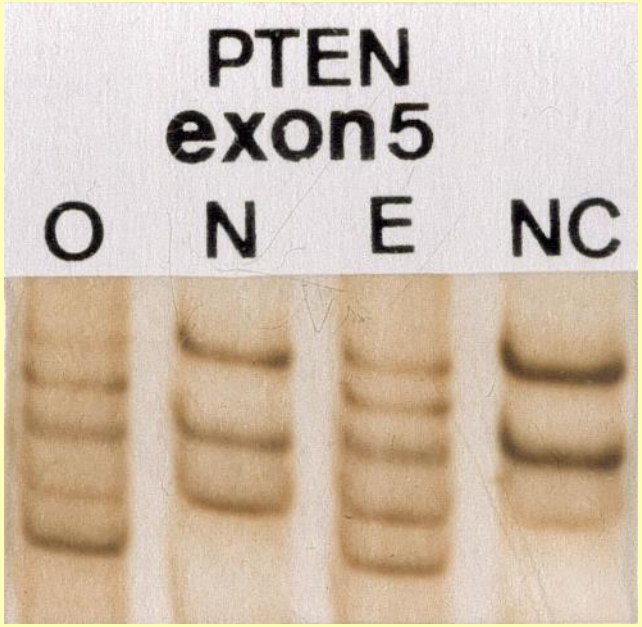
PTEN
exon5
O
N
E
NC

Simultaneous endometrioid carcinomas of the endometrium and the ovaries

Is it possible for two independent tumors to exhibit identical molecular alterations in some genes ?

Stem Cells and the Pathogenesis of Endometriosis

ISAAC E. SASSON[a] AND HUGH S. TAYLOR[a,b]

International Journal of Gynecological Pathology
30:317–327, Lippincott Williams & Wilkins, Baltimore
© 2011 International Society of Gynecological Pathologists

Review

Stem Cells in Human Endometrium and Endometrial Carcinoma

Irene Cervelló, Ph.D., Cristina Mirantes, M.Sc., Xavier Santamaria, M.D., Xavier Dolcet, Ph.D., Xavier Matias-Guiu, M.D., Ph.D., and Carlos Simón, M.D., Ph.D.

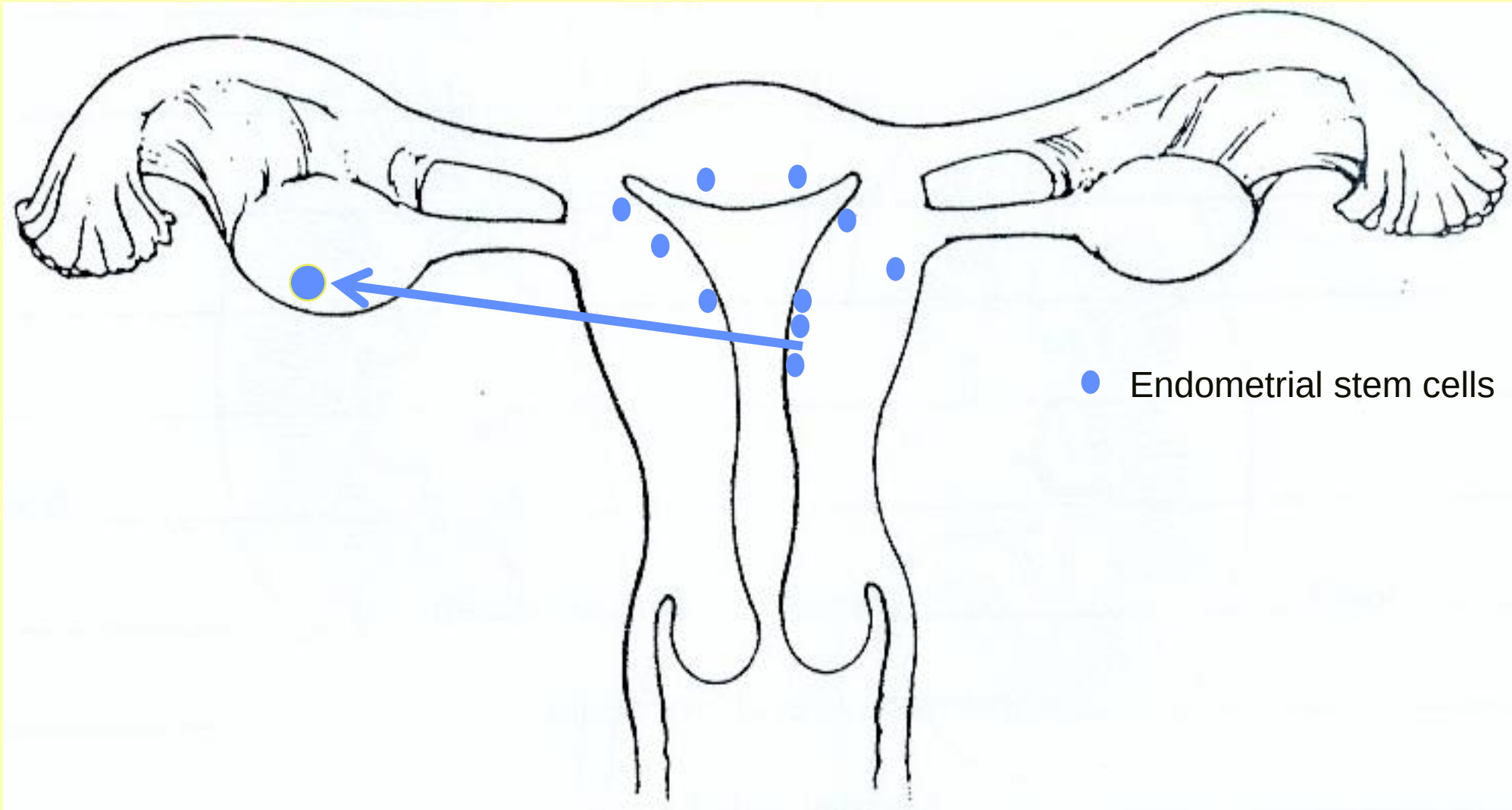

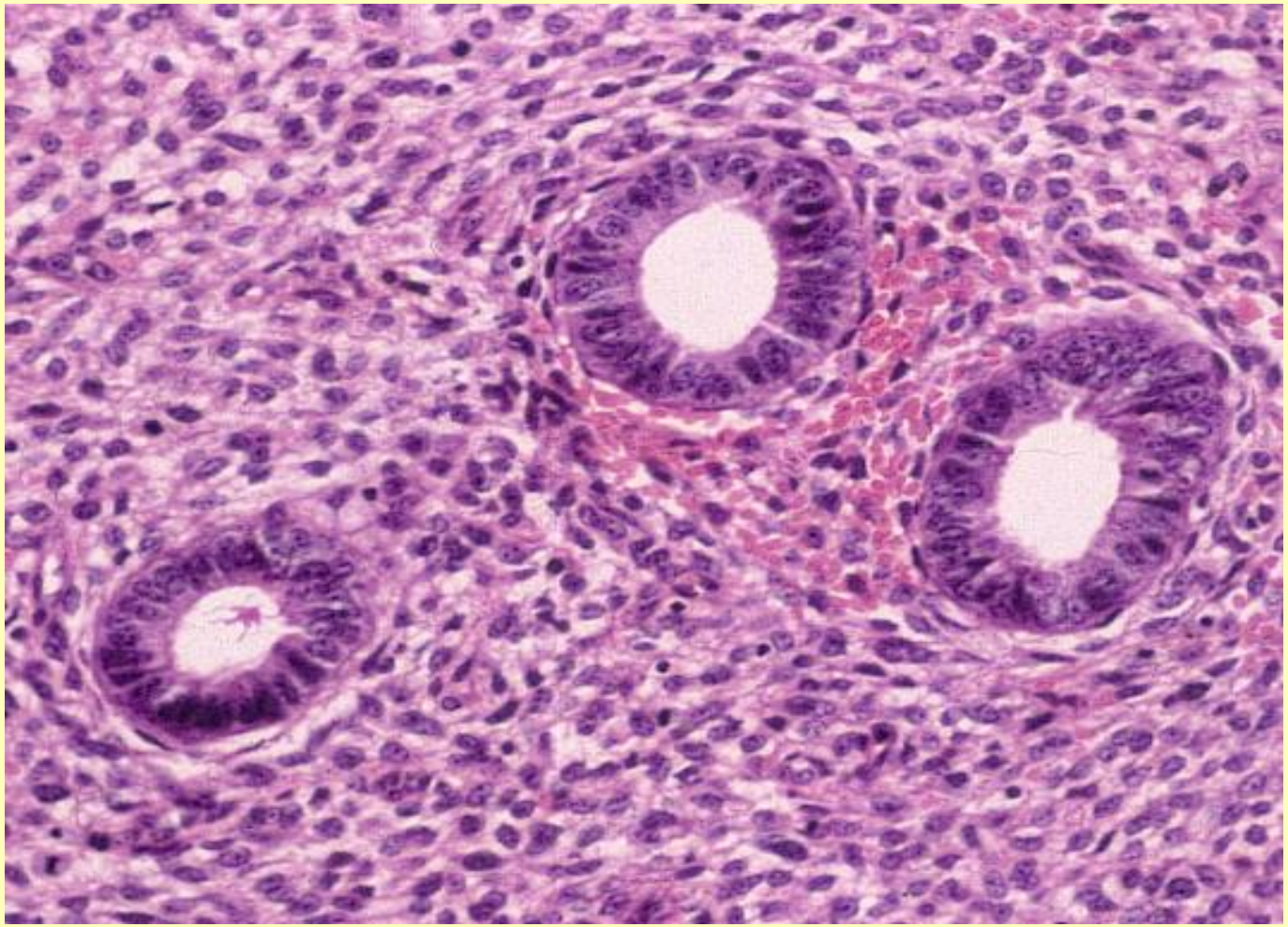

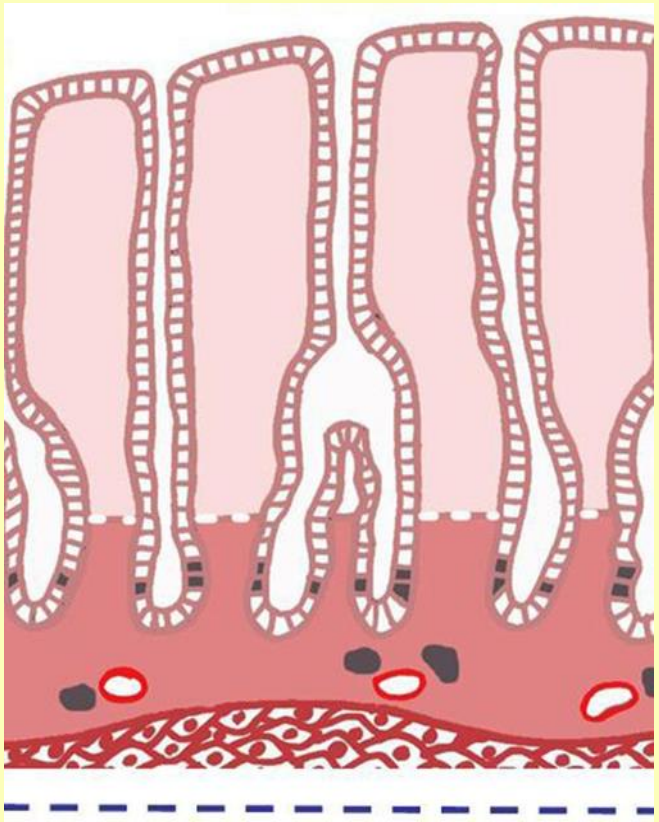

Article

The mutational landscape of normal human endometrial epithelium

https://doi.org/10.1038/s41586-020-2214-z

Received: 19 December 2018

Accepted: 20 March 2020

Published online: 22 April 2020


Check for updates

Luiza Moore[1,2], Daniel Leongamornlert[1], Tim H. H. Coorens[1], Mathijs A. Sanders[1,3], Peter Ellis[1,4], Stefan C. Dentro[1,5], Kevin J. Dawson[1], Tim Butler[1], Raheleh Rahbari[1], Thomas J. Mitchell[1], Francesco Maura[1,6], Jyoti Nangalia[1], Patrick S. Tarpey[1], Simon F. Brunner[1], Henry Lee-Six[1], Yvette Hooks[1], Sarah Moody[1], Krishnaa T. Mahbubani[7,8,9], Mercedes Jimenez-Linan[2], Jan J. Brosens[10], Christine A. Iacobuzio-Donahue[11,12], Inigo Martincorena[1], Kourosh Saeb-Parsy[7,8], Peter J. Campbell[1] & Michael R. Stratton[1]✉

Nature | Vol 580 | 30 April 2020

Altered PTEN Expression as a Diagnostic Marker for the Earliest Endometrial Precancers

George L. Mutter, Ming-Chieh Lin, Jeffrey T. Fitzgerald, Jennifer B. Kum, Jan P. A. Baak, Jacqueline A. Lees, Liang-Ping Weng, Charis Eng

Journal of the National Cancer Institute, Vol. 92, No. 11, June 7, 2000

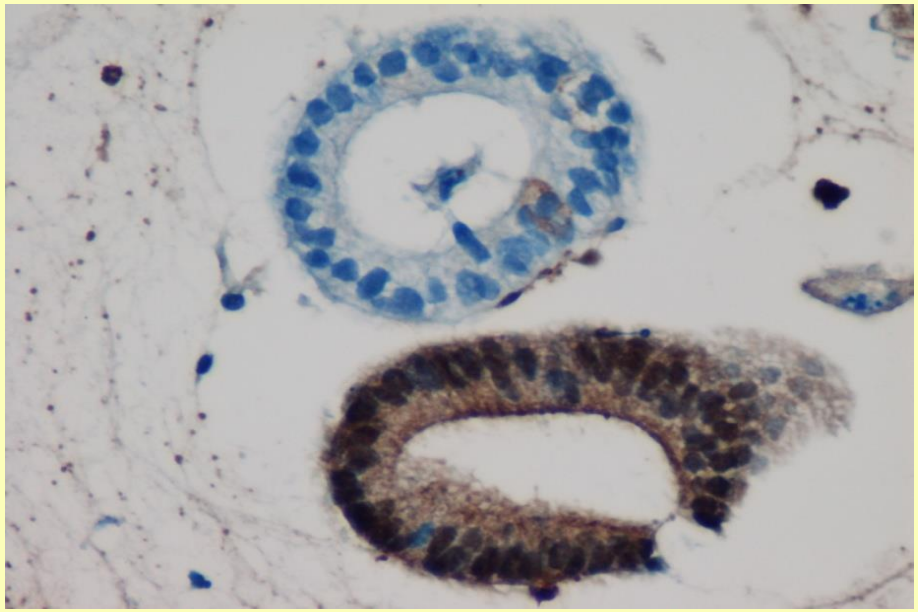

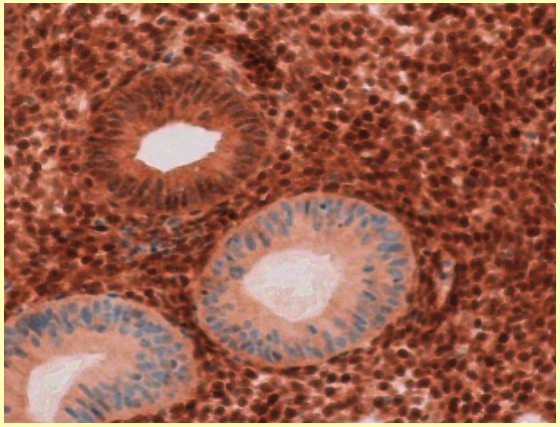

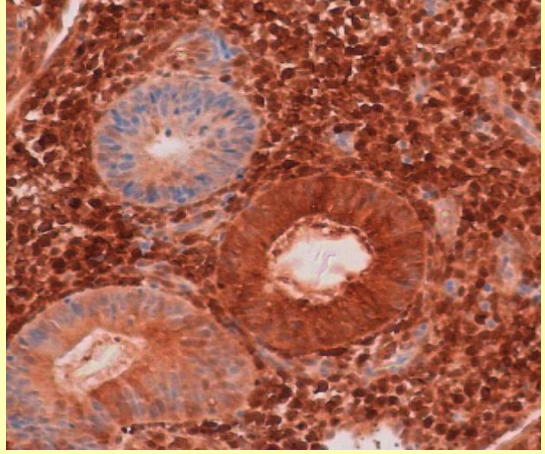

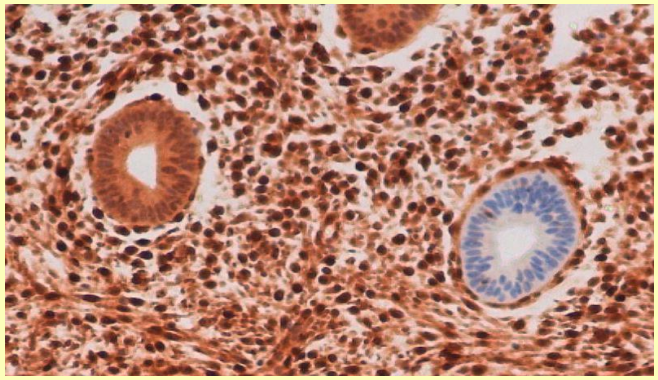

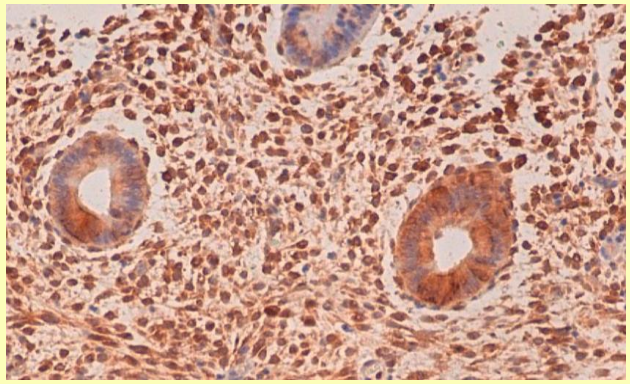

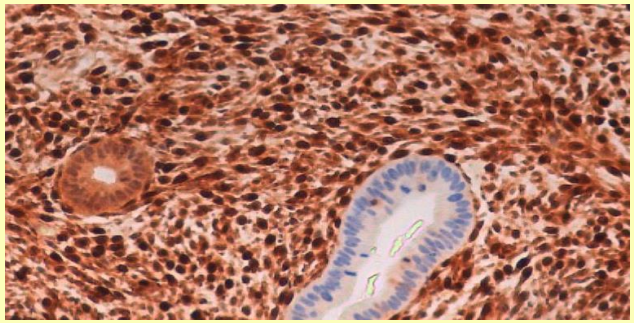

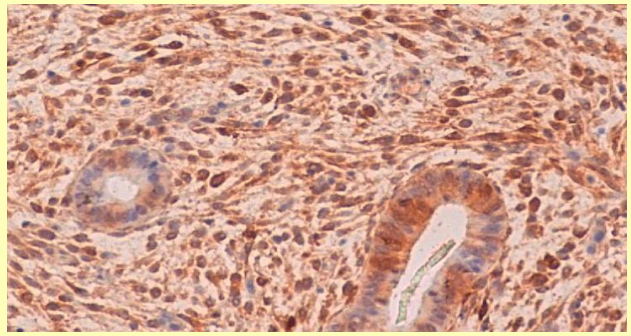

PTEN

ALDH 1

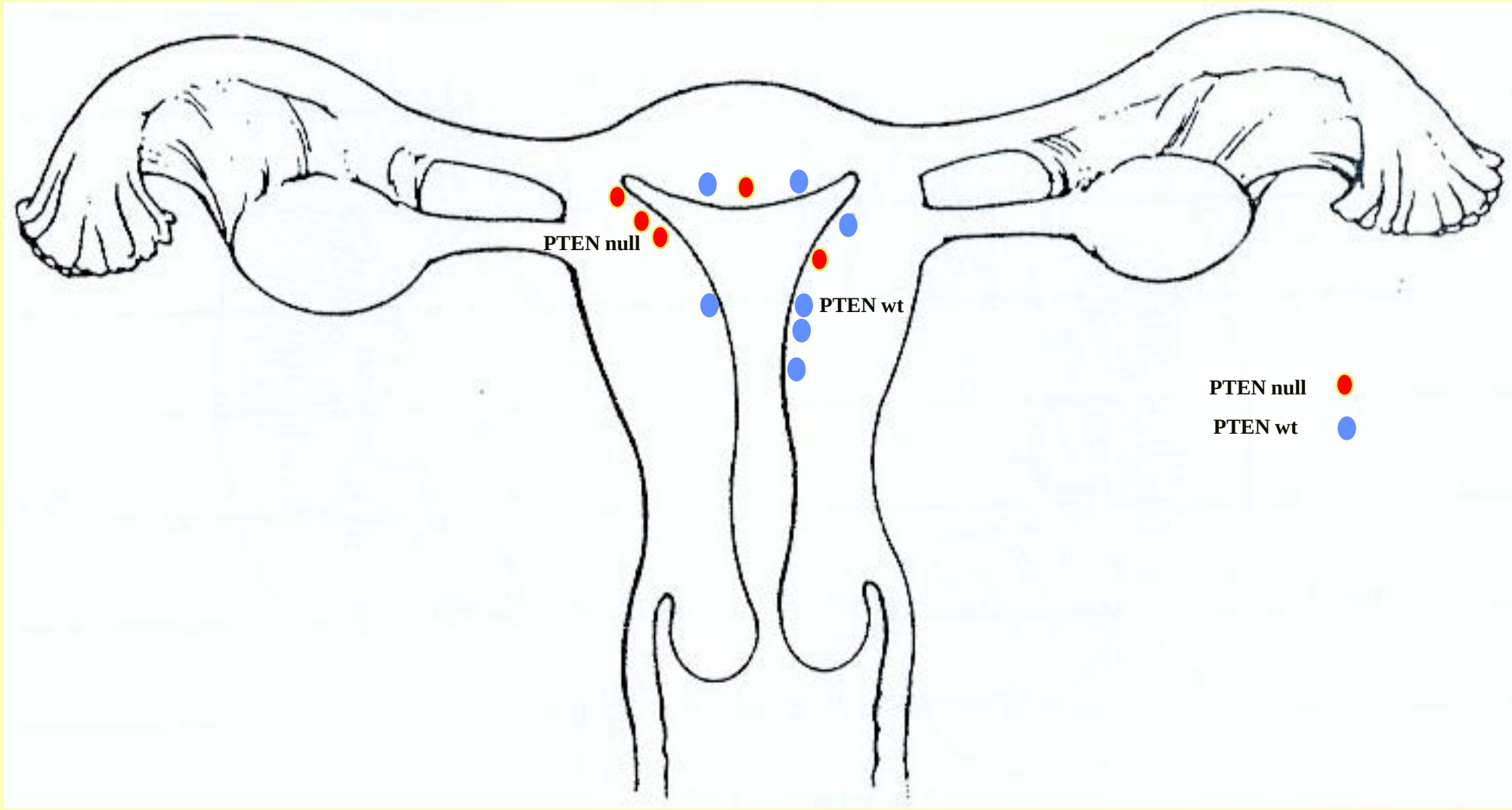
PTEN null
PTEN wt
PTEN null
PTEN wt

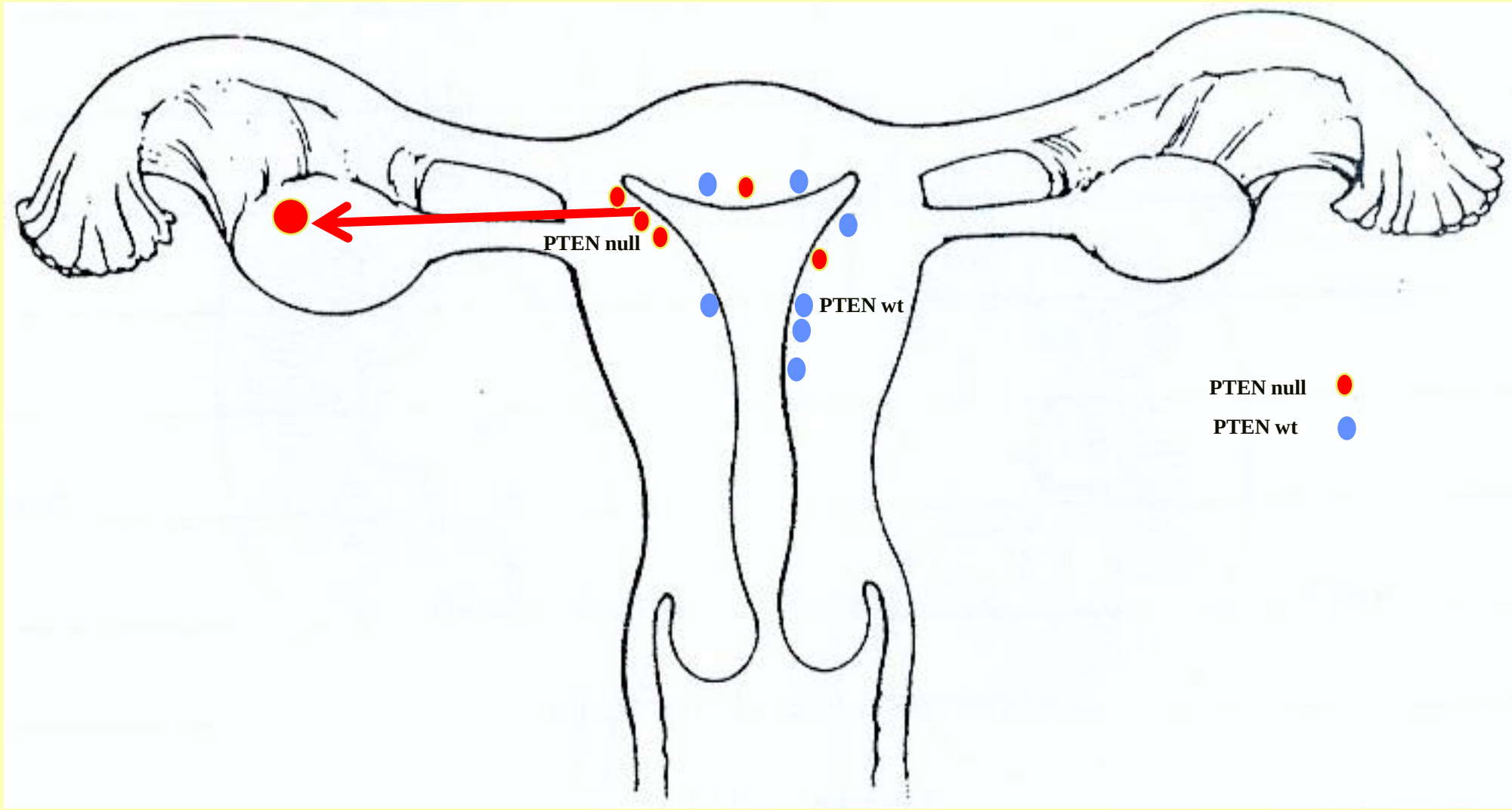
PTEN null
PTEN wt
PTEN null
PTEN wt

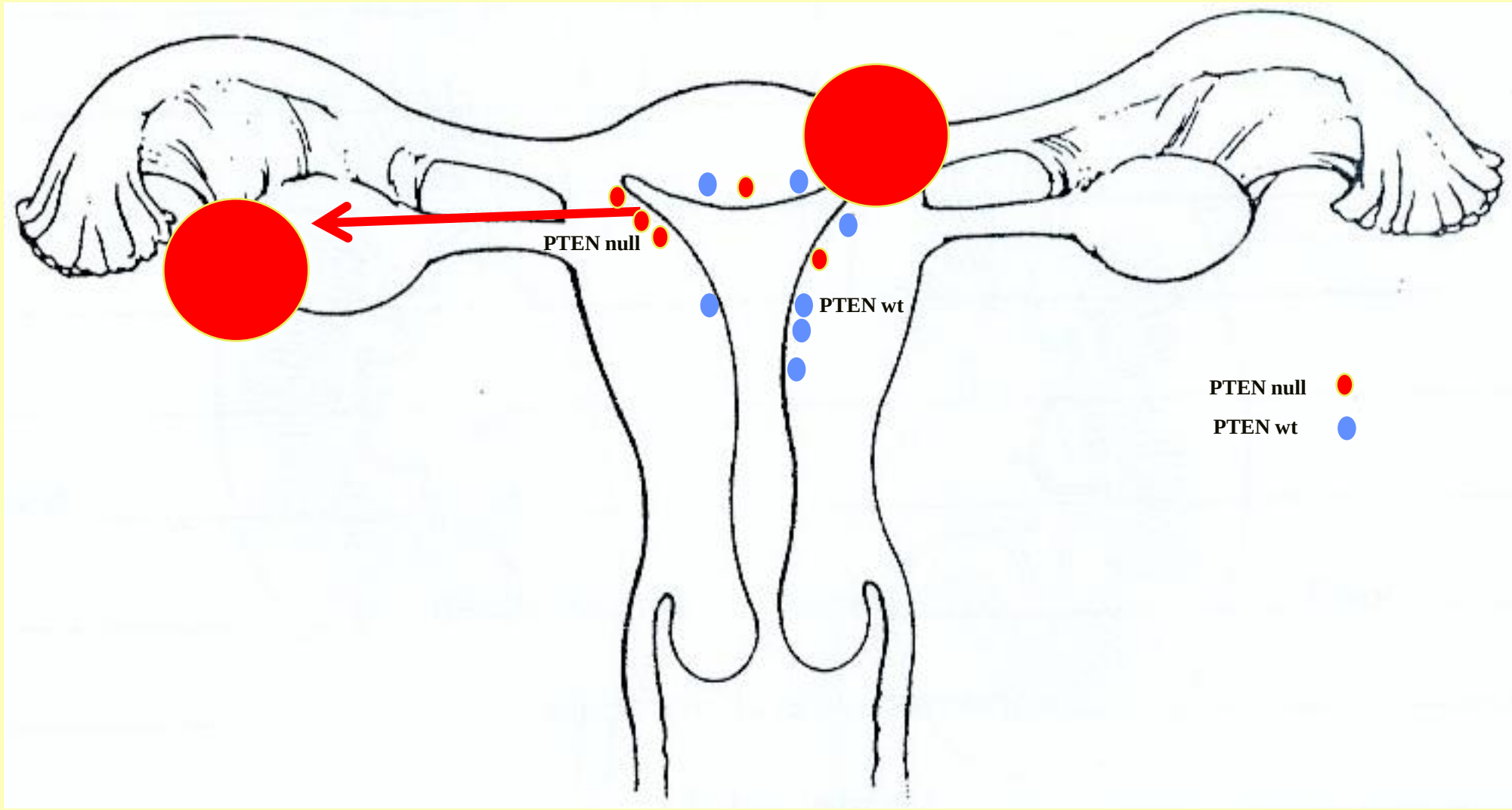
PTEN null
PTEN wt
PTEN null
PTEN wt

Simultaneous endometrioid carcinomas of the endometrium and the ovaries

Independent tumors may occasionally show similar genetic alterations as their common precursor stem cells may carry such alterations.

BRIEF COMMUNICATION

Massively Parallel Sequencing-Based Clonality Analysis of Synchronous Endometrioid Endometrial and Ovarian Carcinomas

Anne M. Schultheis*, Charlotte K. Y. Ng*, Maria R. De Filippo, Salvatore Piscuoglio, Gabriel S. Macedo, Sonia Gatius, Belen Perez Mies, Robert A. Soslow, Raymond S. Lim, Agnes Viale, Kety H. Huberman, Jose C. Palacios, Jorge S. Reis-Filho, Xavier Matias-Guiu, Britta Weigelt

JNCI J Natl Cancer Inst, 2016, Vol. 108, No. 6

. We subjected sporadic synchronous EECs/EOCs from five patients to whole-exome massively parallel sequencing, which revealed that the EEC and EOC of each case displayed strikingly similar repertoires of somatic mutations and gene copy number alterations. Despite the presence of mutations restricted to the EEC or EOC in each case, we observed that the mutational processes that shaped their respective genomes were consistent. High-depth targeted massively parallel sequencing of sporadic synchronous EECs/EOCs from 17 additional patients confirmed that these lesions are clonally related. In an additional Lynch Syndrome case, however, the EEC and EOC were found to constitute independent cancers lacking somatic mutations in common. Taken together, sporadic synchronous EECs/EOCs are clonally related and likely constitute dissemination from one site to the other.

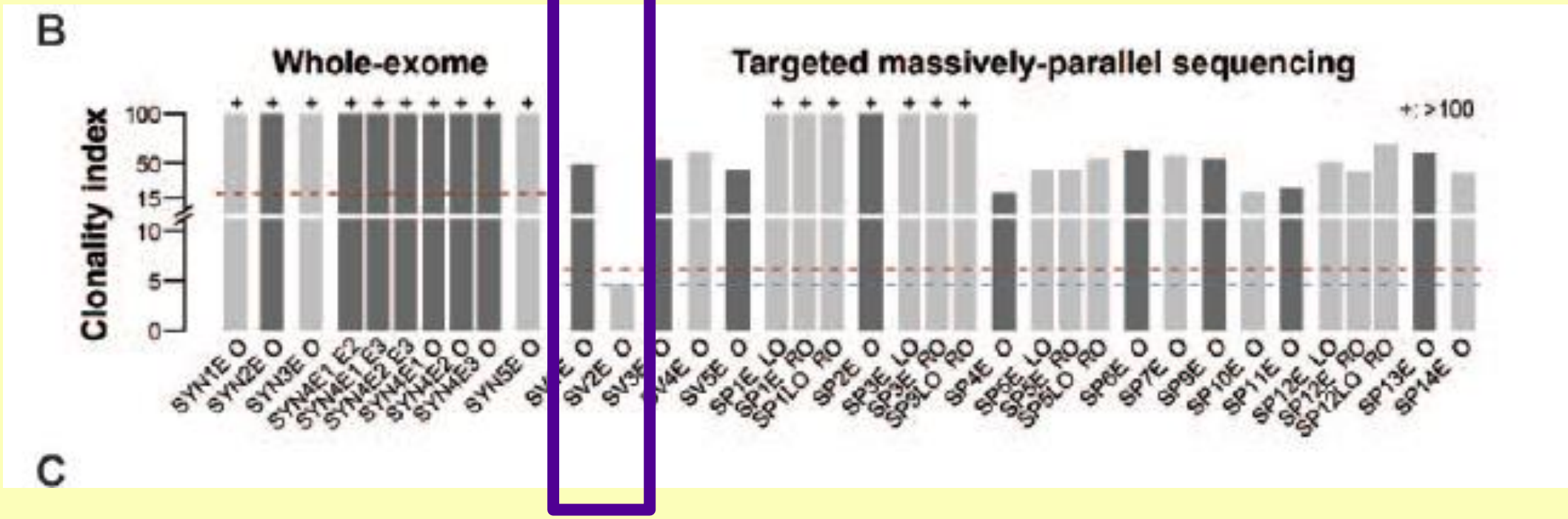
B
Whole-exome
Targeted massively-parallel sequencing
Clonality index
100
50
15
10
5
0
+: >100
SYN1E O
SYN2E O
SYN3E O
SYN4E1 E2
SYN4E1 E3
SYN4E2 E3
SYN4E1 O
SYN4E2 O
SYN4E3 O
SYN5E O
SV2E O
SV3E O
SV5E O
SP1E LO
SP1E RO
SP1LO RO
SP2E O
SP3E LO
SP3E RO
SP3LO RO
SP4E O
SP6E O
SP7E O
SP9E O
SP10E O
SP11E O
SP12E LO
SP12E RO
SP12LO RO
SP13E O
SP14E O
C

Case 1. Endometrioid Carcinoma of Uterus Metastatic to the Ovary

EEC grade 3, 80% myometrium and cervix (II), LVI, 8 cm in diameter.
EOC, grade 3, ruptured capsule (12 cm in diameter)
No follow-up



		Non-synonymous Mutations	
Case 1		Total	Passenger
Shared		23	3
Private	endometrial	137	46
	ovarian	24	5
Total		184	54

Case 2. Independent Primary Endometrioid Carcinomas of Uterus and Ovary

EEC 2, restricted to the endometrium (IA), 1.8 cm in diameter.
EOC, grade 2, intact capsule (IA) (14 cm in diameter)
No evidence of recurrence after 6 years, without treatment





Case 2		Non-synonymous Mutations	
		Total	Passenger
Shared		35	3
Private	endometrial	24	3
	ovarian	21	7
Total		80	13

Case 3. Independent Primary Endometrioid Carcinomas of Uterus and Ovary

EEC 2, 5% myometrium (IA), 2 cm in diameter.
EOC 2, intact capsule (IA) (10 cm in diameter)
No evidence of recurrence after 3 years



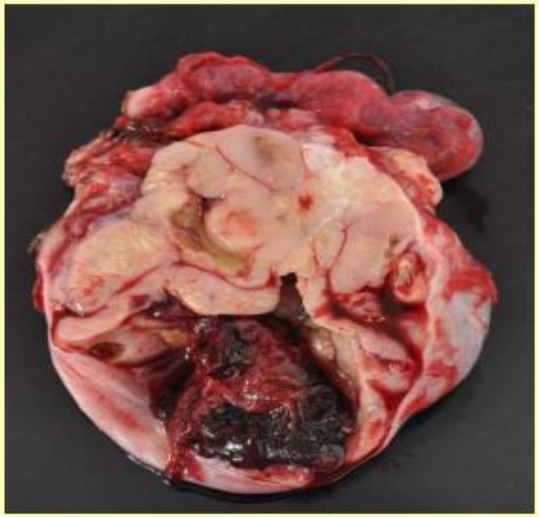

		Non-synonymous Mutations	
Case 3		Total	Passenger
Shared		20	5
Private	endometrial	27	10
	ovarian	27	13
Total		74	28

Case 4. Questionable Simultaneous Endometrioid Carcinoma of Uterus and the Ovary

EEC grade 3, 75% myometrium (IB), LVI, 8 cm in diameter.
EOC, grade 1 mucinous, intact capsule (20 cm in diameter)
Alive with disease (retroperitoneal LN, after 4 years)





		Non-synonymous Mutations	
Case 4		Total	Passenger
Shared		110	20
Private	endometrial1	270	53
	endometrial2	113	28
	endometrial3	152	28
	ovarian	232	44
Total		877	173

Case 5. Endometrioid Carcinomas of Uterus Metastatic to the Ovary

EEC grade 2, 75% myometrium and cervix (II), LVI, 4 cm in diameter.
EOC, grade 3, ruptured capsule (12 cm in diameter)
Alive with disease (retroperitoneal LN, one year after surgery)





		Non-synonymous Mutations	
Case 1		Total	Passenger
Shared		23	3
Private	endometrial	137	46
	ovarian	24	5
Total		184	54

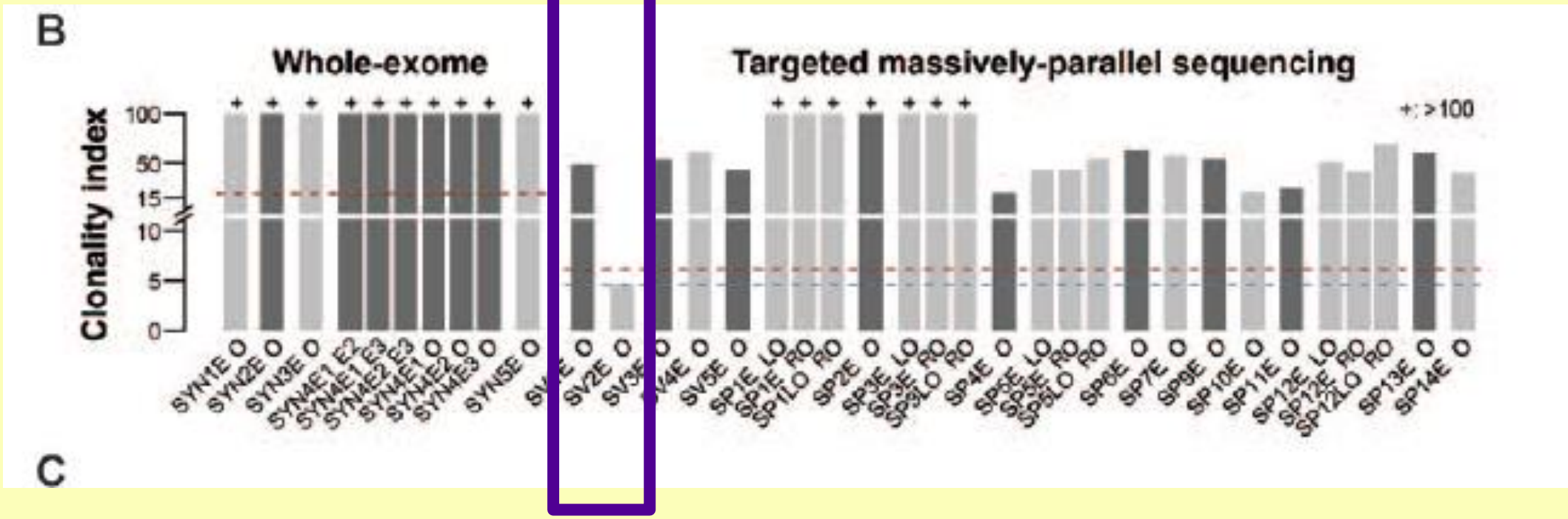
B
Whole-exome
Targeted massively-parallel sequencing
Clonality index
100
50
15
10
5
0
+: >100
SYN1E O
SYN2E O
SYN3E O
SYN4E1 E2
SYN4E1 E3
SYN4E2 E3
SYN4E1 O
SYN4E2 O
SYN4E3 O
SYN5E O
SV2E O
SV3E O
SV5E O
SP1E LO
SP1E RO
SP1LO RO
SP2E O
SP3E LO
SP3E RO
SP3LO RO
SP4E O
SP6E O
SP7E O
SP9E O
SP10E O
SP11E O
SP12E LO
SP12E RO
SP12LO RO
SP13E O
SP14E O
C

Clonal relationship and directionality of progression of synchronous endometrial and ovarian carcinomas in patients with Lynch syndrome

Lea A Moukarzel[1*], Arnaud Da Cruz Paula[1*], Lorenzo Ferrando[2,3], Timothy Hoang[2], Ana Paula Martins Sebastiao[2], Fresia Pareja[2], Kay J Park[2], Achim A Jungbluth[2], Gabriel Capella[4], Marta Pineda[4], Jeffrey D Levin[5], Nadeem R Abu-Rustum[1], August Vidal Bel[6], Jorge S Reis-Filho[2], Xavier Matias-Guiu[7], Karen Cadoo[5], Zsofia K Stadler[5] and Britta Weigelt[2]

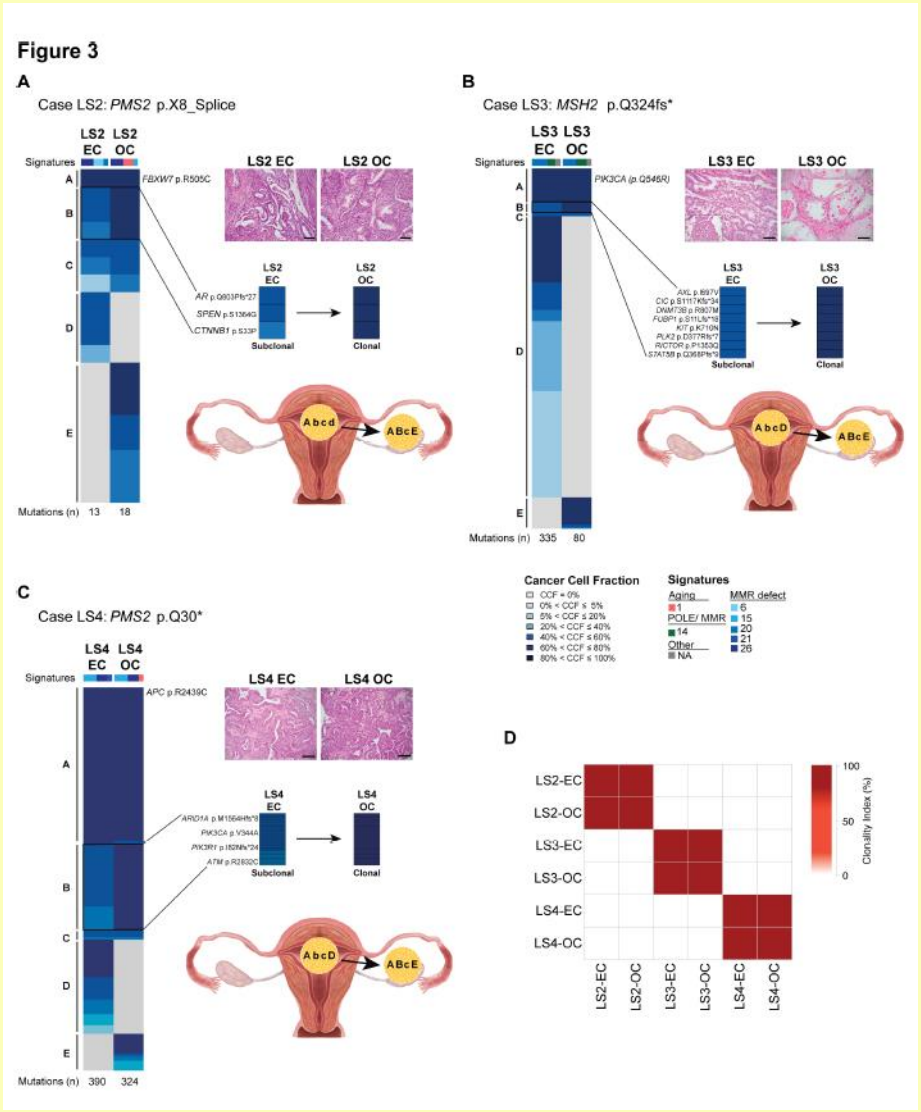
Figure 3
A
Case LS2: PMS2 p.X8_Splice
LS2 EC
LS2 OC
Signatures
FBXW7 p.R505C
AR p.Q803Pfs*27
SPEN p.S1364G
CTNNB1 p.S33P
Subclonal
Clonal
Mutations (n) 13 18
B
Case LS3: MSH2 p.Q324fs*
LS3 EC
LS3 OC
PIK3CA (p.Q546R)
Mutations (n) 335 80
C
Case LS4: PMS2 p.Q30*
LS4 EC
LS4 OC
APC p.R2439C
Mutations (n) 390 324
Cancer Cell Fraction
CCF = 0%
0% < CCF ≤ 5%
5% < CCF ≤ 20%
20% < CCF ≤ 40%
40% < CCF ≤ 60%
60% < CCF ≤ 80%
80% < CCF ≤ 100%
Signatures
Aging
1
POLE/ MMR
14
Other
NA
MMR defect
6
15
20
21
26
D
LS2-EC
LS2-OC
LS3-EC
LS3-OC
LS4-EC
LS4-OC
Clonality Index (%)
100
50
0

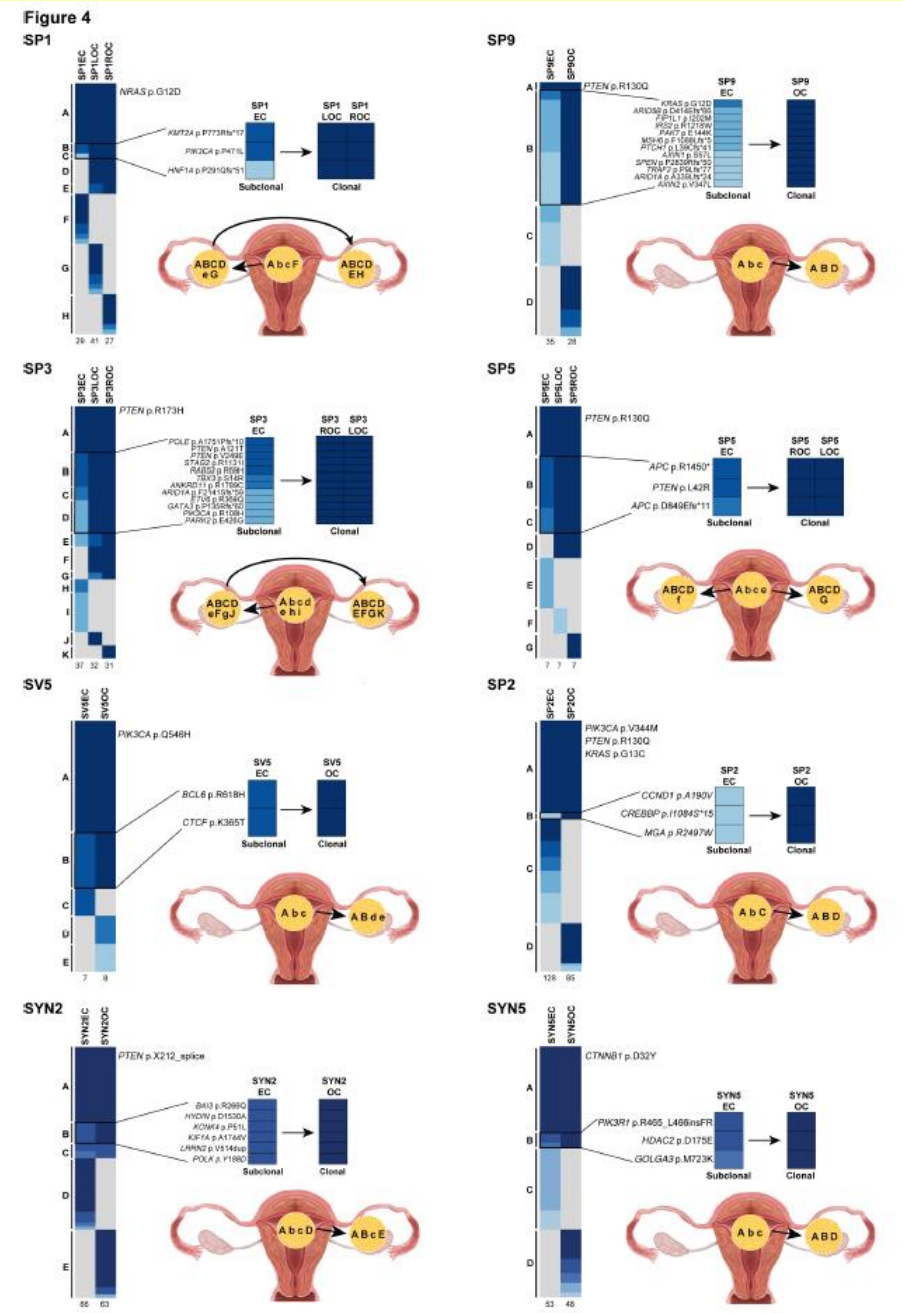
Figure 4
SP1
NRAS p.G12D
SP9
PTEN p.R130Q
SP3
PTEN p.R173H
SP5
PTEN p.R130Q
SV5
PIK3CA p.Q546H
SP2
PIK3CA p.V344M
PTEN p.R130Q
KRAS p.G13C
SYN2
PTEN p.X212_splice
SYN5
CTNNB1 p.D32Y
Subclonal
Clonal

Simultaneous endometrioid carcinomas of the endometrium and the ovaries

- Mutational profile of both tumors is identical in vast majority of cases suggesting common origin.

- True simultaneous tumors seem to be restricted to Lynch syndrome.

BRIEF COMMUNICATION

Synchronous Endometrial and Ovarian Carcinomas: Evidence of Clonality

Michael S. Anglesio, Yi Kan Wang, Madlen Maassen, Hugo M. Horlings, Ali Bashashati, Janine Senz, Robertson Mackenzie, Diljot S. Grewal, Hector Li-Chang, Anthony N. Karnezis, Brandon S. Sheffield, Melissa K. McConechy, Friedrich Kommoss, Florin A. Taran, Annette Staebler, Sohrab P. Shah, Diethelm Wallwiener, Sara Brucker, C. Blake Gilks, Stefan Kommoss, David G. Huntsman

JNCI J Natl Cancer Inst, 2016, Vol. 108, No. 6

We used 18 SEOs to investigate the ancestral relationship between the endometrial and ovarian components. Based on both targeted and exome sequencing, 17 of 18 patient cases of simultaneous cancer of the endometrium and ovary from our series showed evidence of a clonal relationship, ie, primary tumor and metastasis. Eleven patient cases fulfilled clinicopathological criteria that would lead to classification as independent endometrial and ovarian primary carcinomas, including being of FIGO stage T1a/1A, with organ-restricted growth and without surface involvement; 10 of 11 of these cases showed evidence of clonality.

Implication of genomic characterization in synchronous endometrial and ovarian cancers of endometrioid histology

Angel Chao [a,1], Ren-Chin Wu [b,1], Shih-Ming Jung [b,1], Yun-Shien Lee [c,d], Shu-Jen Chen [e], Yen-Lung Lu [e], Chia-Lung Tsai [c], Chiao-Yun Lin [a], Yun-Hsin Tang [a], Ming-Yu Chen [a], Huei-Jean Huang [a], Hung-Hsueh Chou [a], Kuan-Gen Huang [a], Ting-Chang Chang [a], Tzu-Hao Wang [a,c,*], Chyong-Huey Lai [a,**]

Gynecologic Oncology

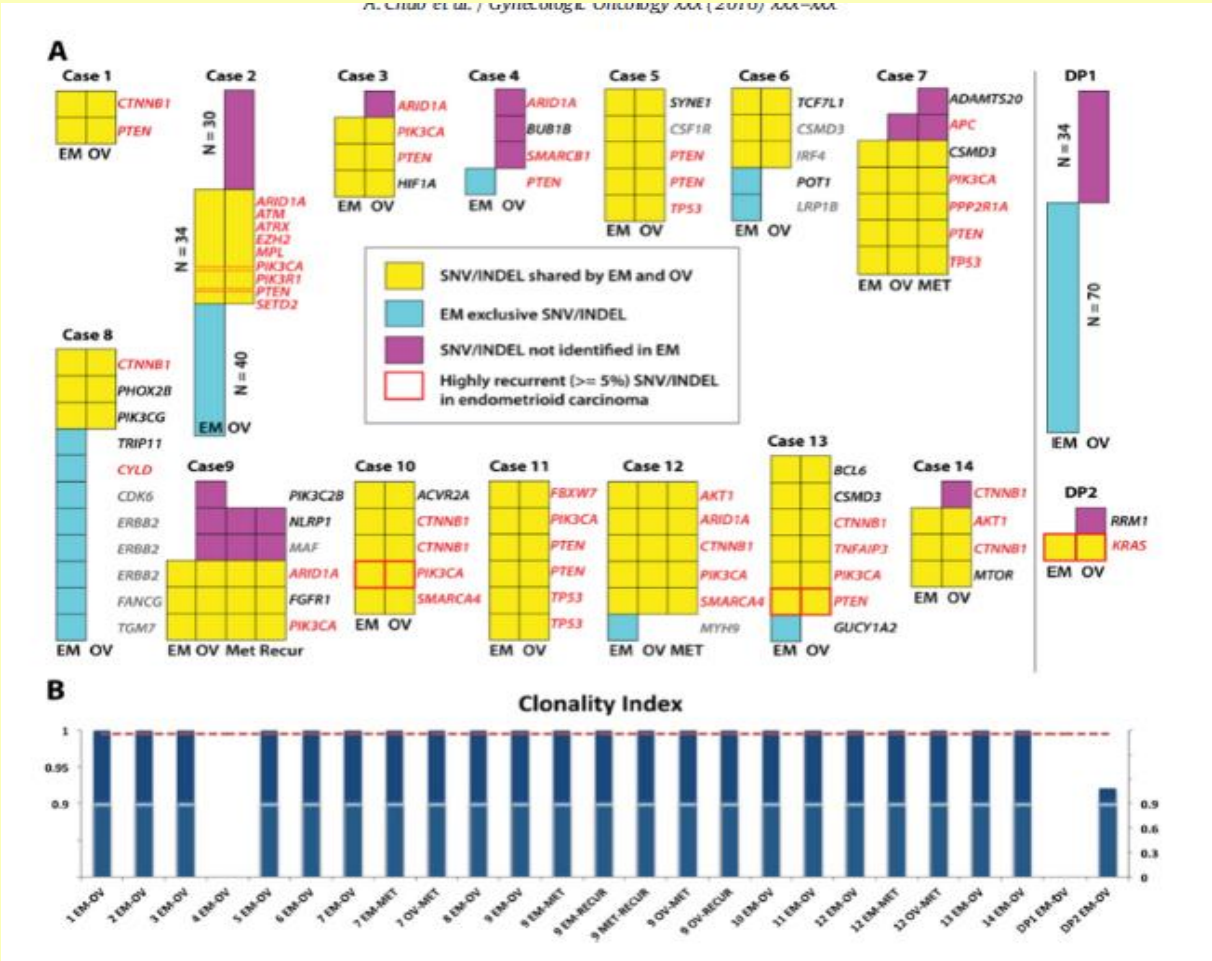

Simultaneous endometrioid carcinomas of the endometrium and the ovaries (unsolved issues)

- Why some ovarian metastasis are associated with bad prognosis and others are associated with indolent behaviour ?

Synchronous and Metachronous Endocervical and Ovarian Neoplasms

Evidence Supporting Interpretation of the Ovarian Neoplasms as Metastatic Endocervical Adenocarcinomas Simulating Primary Ovarian Surface Epithelial Neoplasms

Esther Elishaev, MD, C. Blake Gilks, MD,† Dianne Miller, MD,‡ Monica Srodon, MD,* Robert J. Kurman, MD,*§ and Brigitte M. Ronnett, MD*§*

Finally, it is interesting to note that 8 of the patients appear to have had isolated ovarian metastases of endocervical adenocarcinoma without documented metastatic disease elsewhere, and 7 of these patients with available follow-up data had not experienced disease recurrence during follow-up intervals ranging from 7 to 45 months. These findings suggest that isolated metastases may not necessarily indicate a poor prognosis, as would be expected for advanced-stage disease, and that resection of isolated metastases may have therapeutic and survival benefits. Additional follow-up will be required to determine the long-term prognosis for these patients.

Endocervical Adenocarcinomas With Ovarian Metastases

Analysis of 29 Cases With Emphasis on Minimally Invasive Cervical Tumors and the Ability of the Metastases to Simulate Primary Ovarian Neoplasms

Brigitte M. Ronnett, MD,† Anna V. Yemelyanova, MD,* Russell Vang, MD,*†*
C. Blake Gilks, MD,‡ Dianne Miller, MD,§ Patti E. Gravitt, PhD,‖ and Robert J. Kurman, MD†*

Endocervical adenocarcinomas, including microinvasive forms and some not recognizably invasive, have the potential to metastasize to the ovaries; extension into the lower uterine segment/corpus endometrium may be a risk factor, with retrograde uterine/transtubal spread as a possible mechanism.

Simultaneous endometrioid carcinomas of the endometrium and the ovaries (unsolved issues)

Aggressiveness may be related to :

- The precise step of endometrial tumorigenesis in which the ovarian metastasis develops.

- The metastatic pathway used (hematogenous versus transtubal)

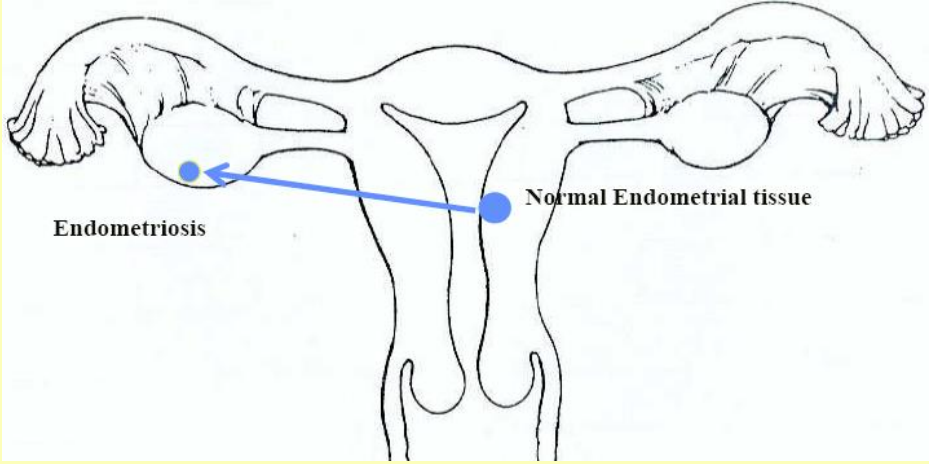
Endometriosis
Normal Endometrial tissue

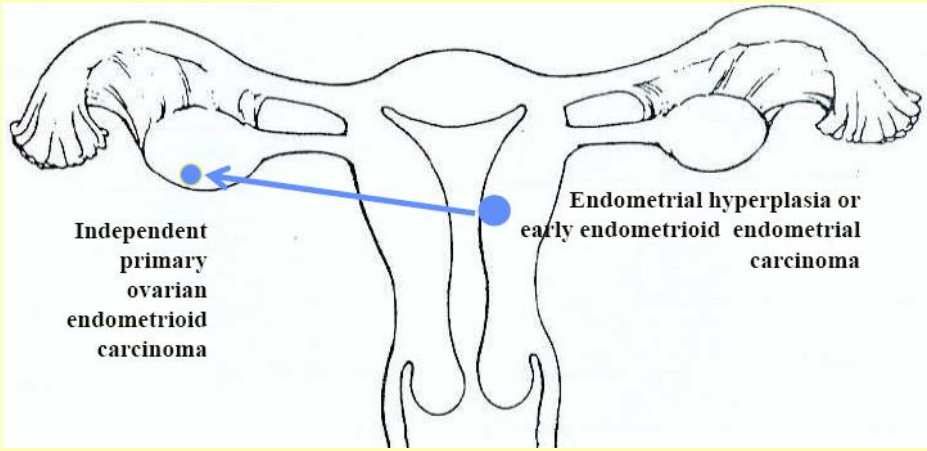
Independent primary ovarian endometrioid carcinoma
Endometrial hyperplasia or early endometrioid endometrial carcinoma

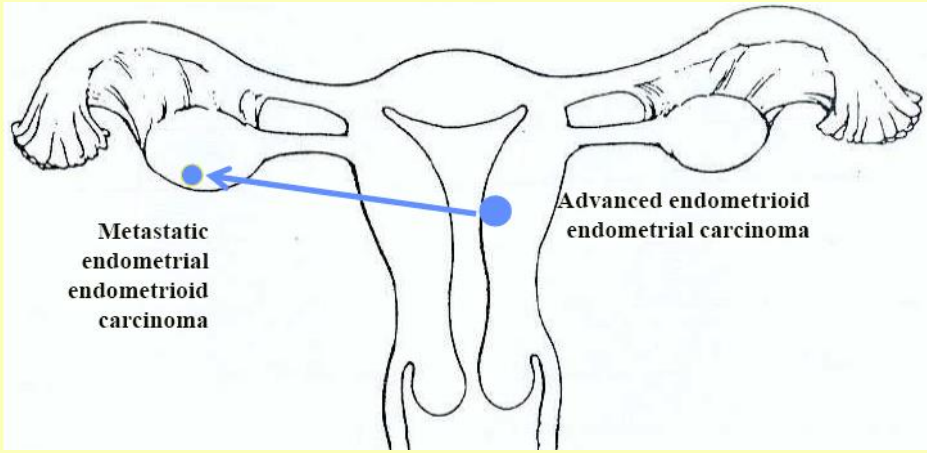
Metastatic endometrial endometrioid carcinoma
Advanced endometrioid endometrial carcinoma

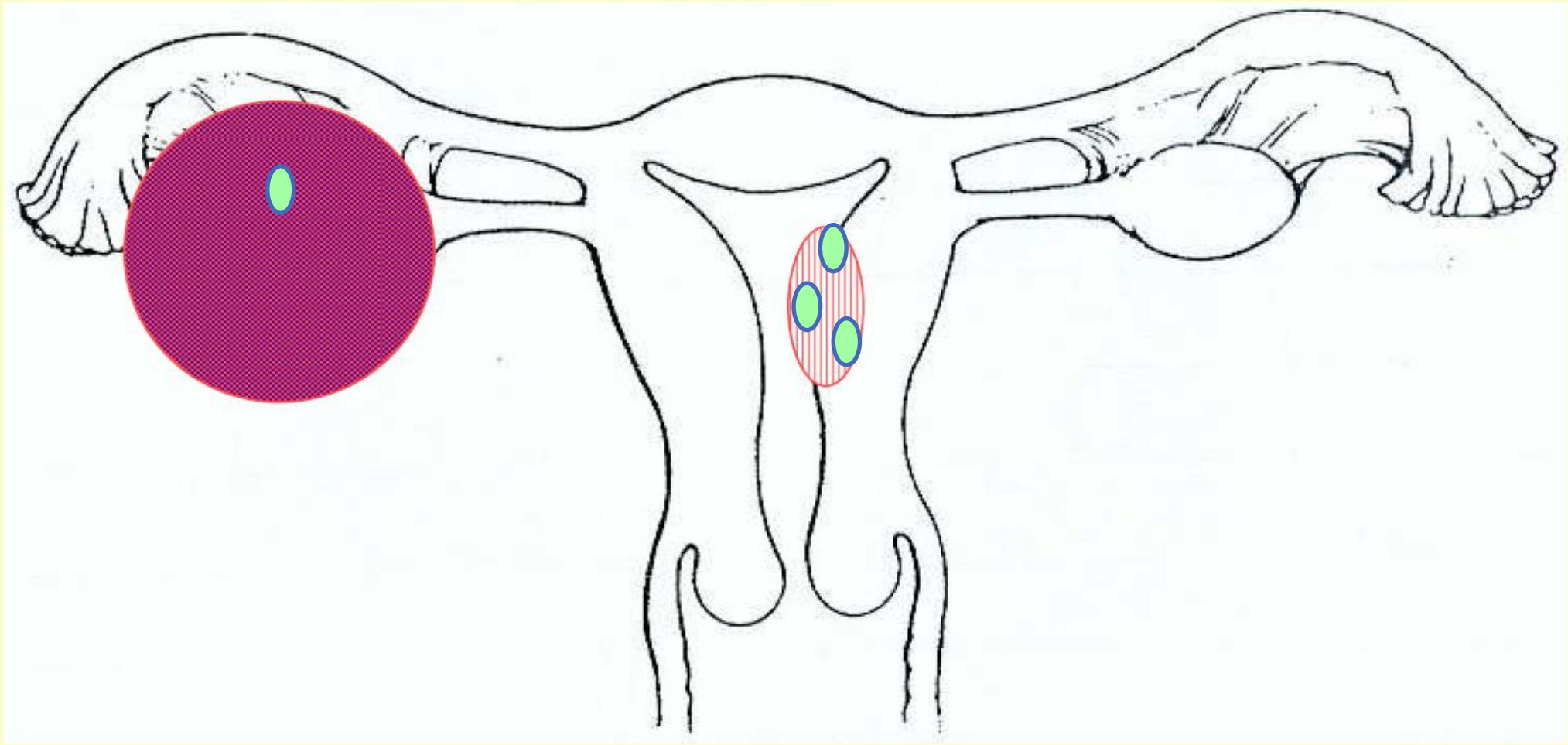

		Non-synonymous Mutations	
Case 4		Total	Passenger
Shared		110	20
Private	endometrial1	270	53
	endometrial2	113	28
	endometrial3	152	28
	ovarian	232	44
Total		877	173

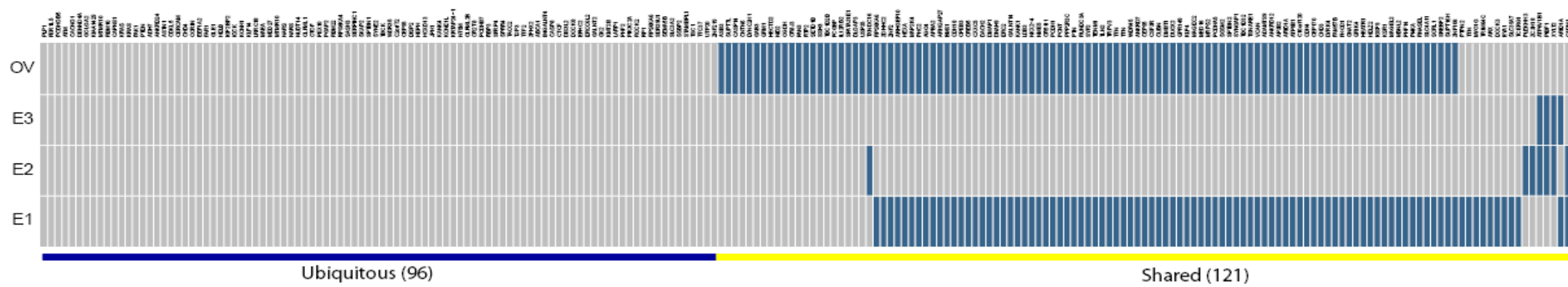
OV
E3
E2
E1
Ubiquitous (96)
Shared (121)

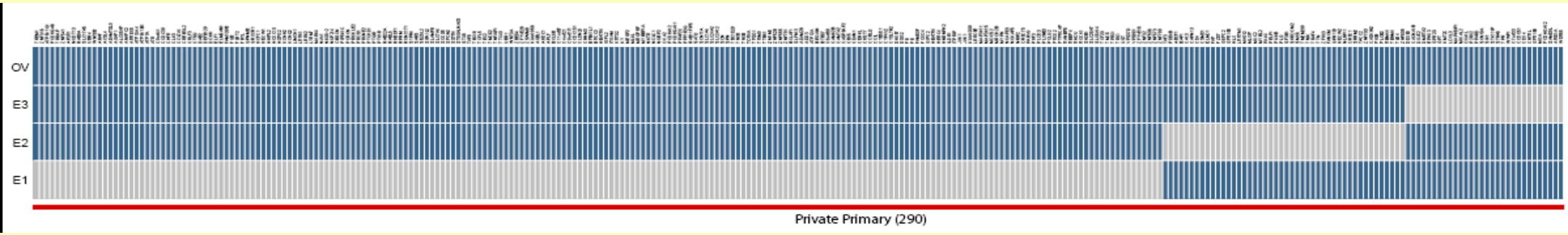
OV
E3
E2
E1
Private Primary (290)

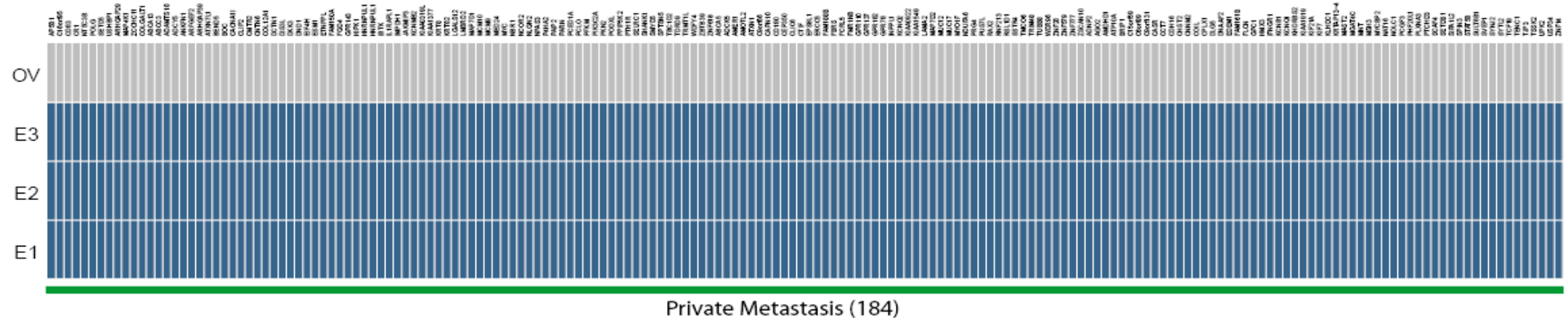
OV
E3
E2
E1
Private Metastasis (184)

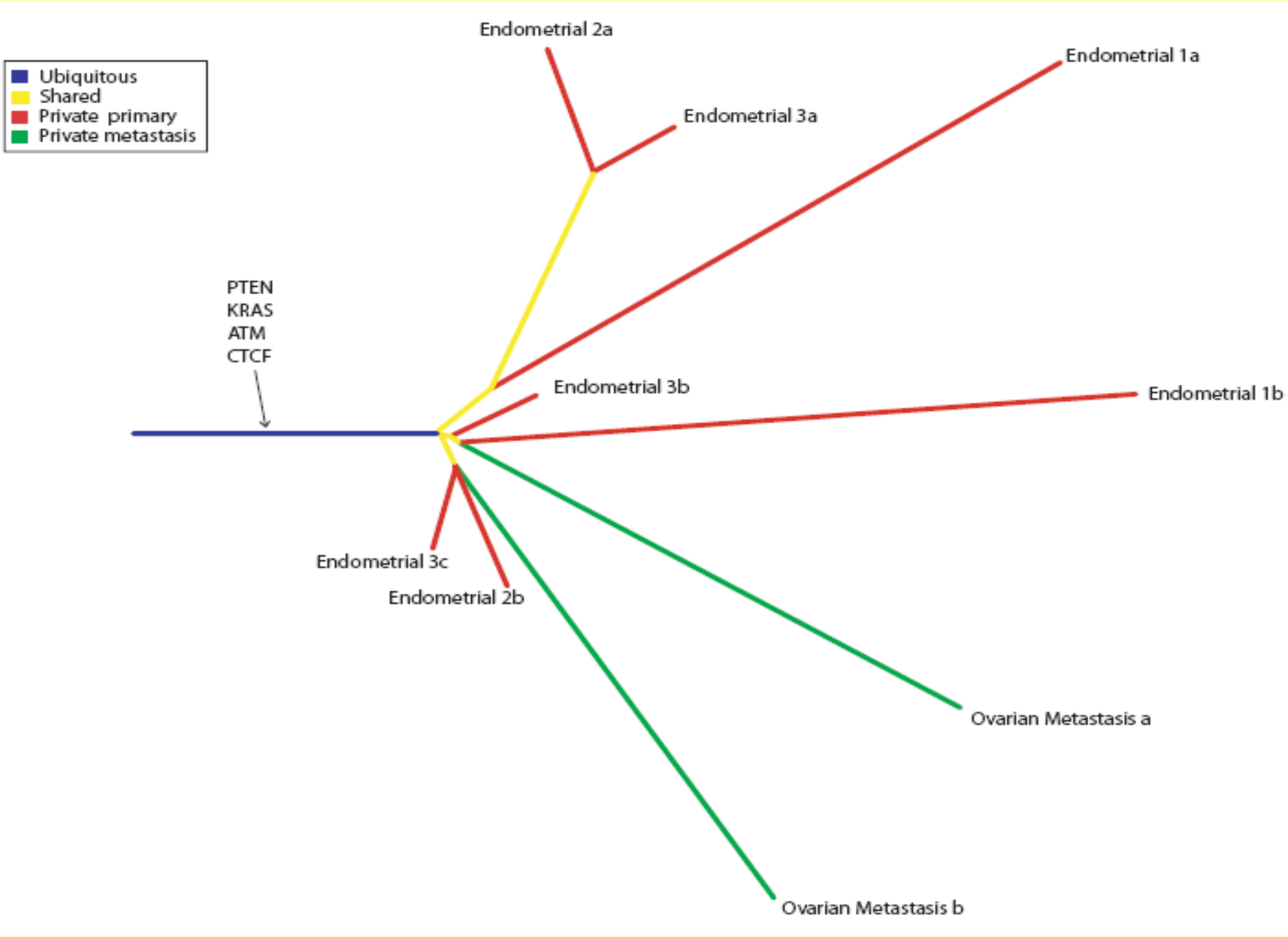
Ubiquitous
Shared
Private primary
Private metastasis
Endometrial 2a
Endometrial 1a
Endometrial 3a
PTEN
KRAS
ATM
CTCF
Endometrial 3b
Endometrial 1b
Endometrial 3c
Endometrial 2b
Ovarian Metastasis a
Ovarian Metastasis b

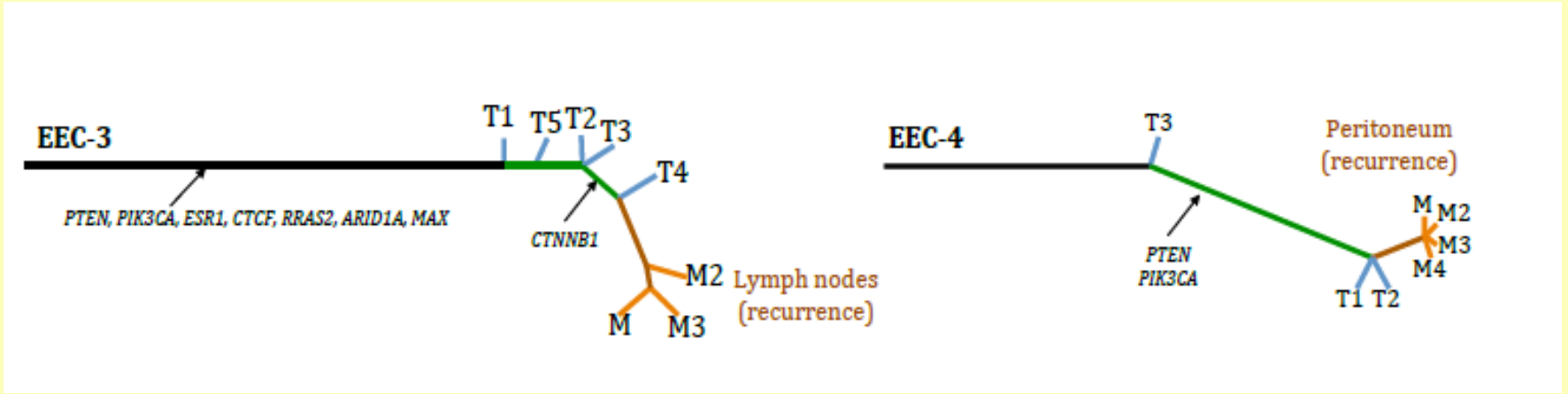
EEC-3
T1
T5
T2
T3
T4
PTEN, PIK3CA, ESR1, CTCF, RRAS2, ARID1A, MAX
CTNNB1
M2
Lymph nodes
(recurrence)
M
M3
EEC-4
T3
Peritoneum
(recurrence)
PTEN
PIK3CA
M
M2
M3
M4
T1
T2

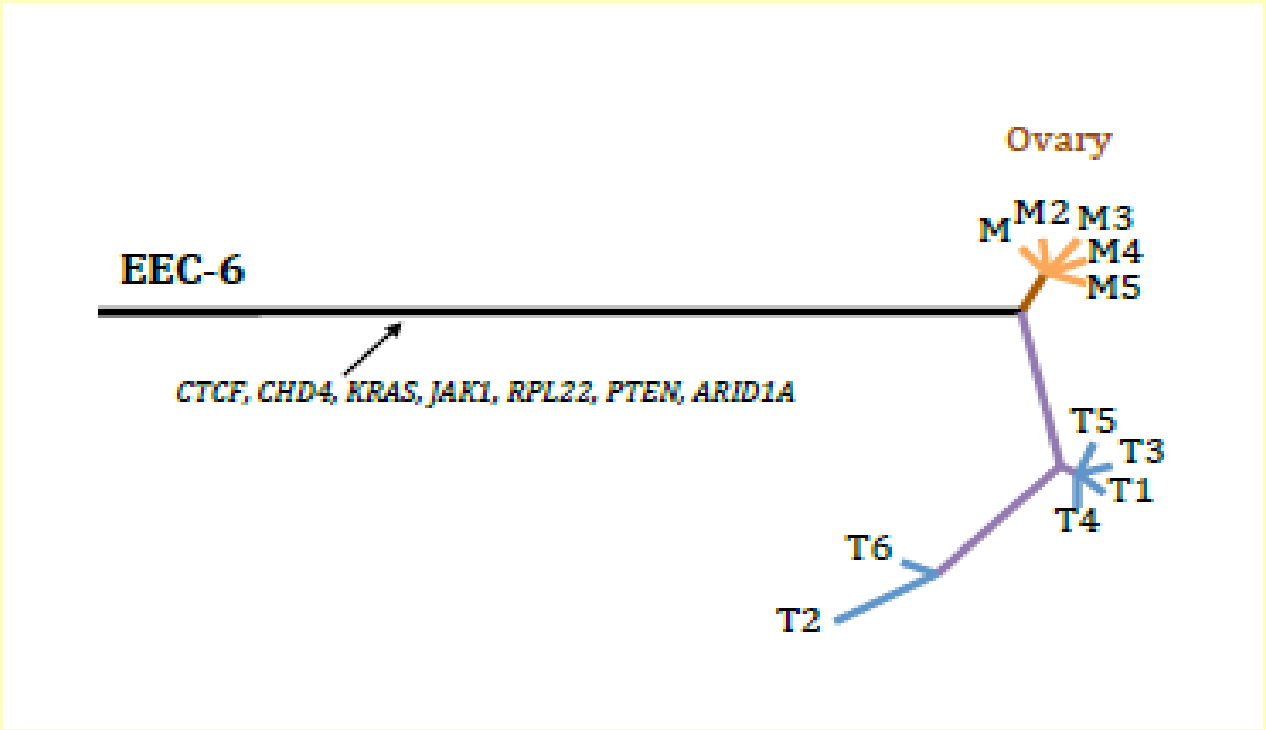
Ovary
EEC-6
M
M2
M3
M4
M5
CTCF, CHD4, KRAS, JAK1, RPL22, PTEN, ARID1A
T5
T3
T1
T4
T6
T2

Simultaneous endometrioid carcinomas of the endometrium and the ovaries (unsolved issues)

- If vast majority of them are metastatic, why they arise at the vicinity of endometriosis?

Simultaneous endometrioid carcinomas of the endometrium and the ovaries (unsolved issues)

- Metastatic mucinous tumors to the ovary frequently look benign, why not for endometriosis?

- Self-seeding metastasis ?

Clinical implications of cancer self-seeding

Elizabeth Comen, Larry Norton and Joan Massagué

Abstract | Most metastatic cancers are incurable—a fact that underscores the limitations of our existing paradigms for understanding metastasis. In this Review, we use breast cancer to explore many of the enigmas revealed by these existing paradigms. Traditionally, metastatic models describe metastasis as a unidirectional process, whereby cancer cells leave a primary tumor and unidirectionally seed metastasis in regional lymph nodes or distant sites. By contrast, recent data indicate that metastasis is a multidirectional process whereby cancer cells can seed distant sites as well as the primary tumor itself. This later process, known as 'self-seeding,' has been validated in diverse experimental models. Here, we show that the self-seeding model may answer many of the mysteries inherent to cancer metastasis. Indeed, reframing our understanding of metastasis within the self-seeding model offers new opportunities for prevention and cure of metastatic cancer.

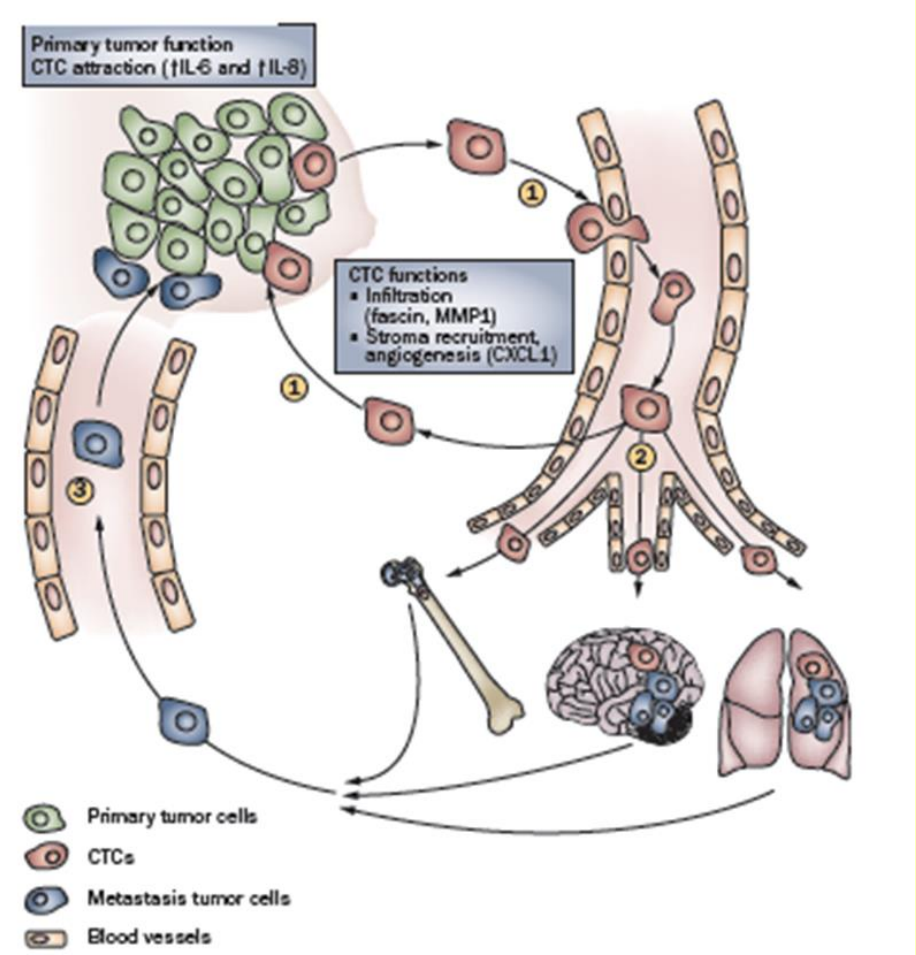

Simultaneous endometrioid carcinomas of the endometrium and the ovaries, How to report them?

- All of them as metastatic?
- Use Scully criteria, regardless of molecular data?
- Risk stratification ?

Risk-based stratification of carcinomas concurrently involving the endometrium and ovary

Gulisa Turashvili [a], Natalia R. Gómez-Hidalgo [b], Jessica Flynn [c], Mithat Gonen [c], Mario M. Leitao Jr [b,d], Robert A. Soslow [a], Rajmohan Murali [a,*]

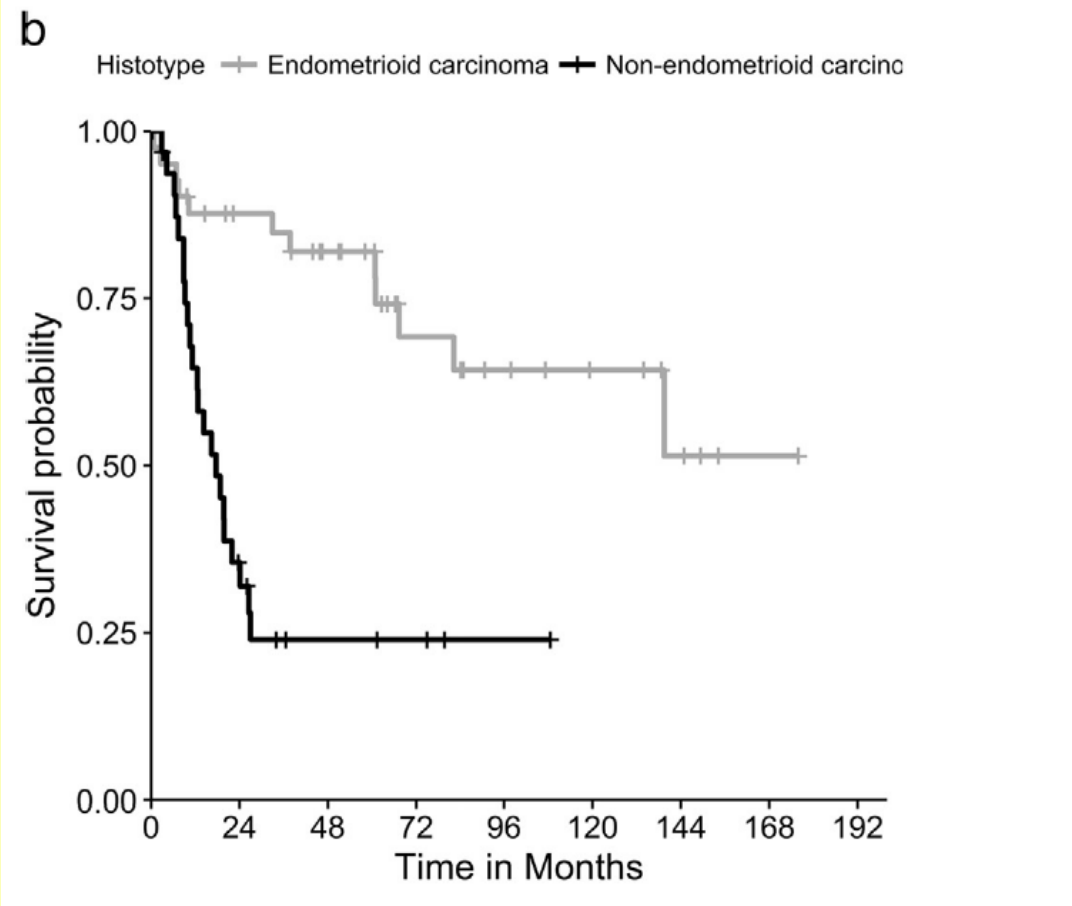

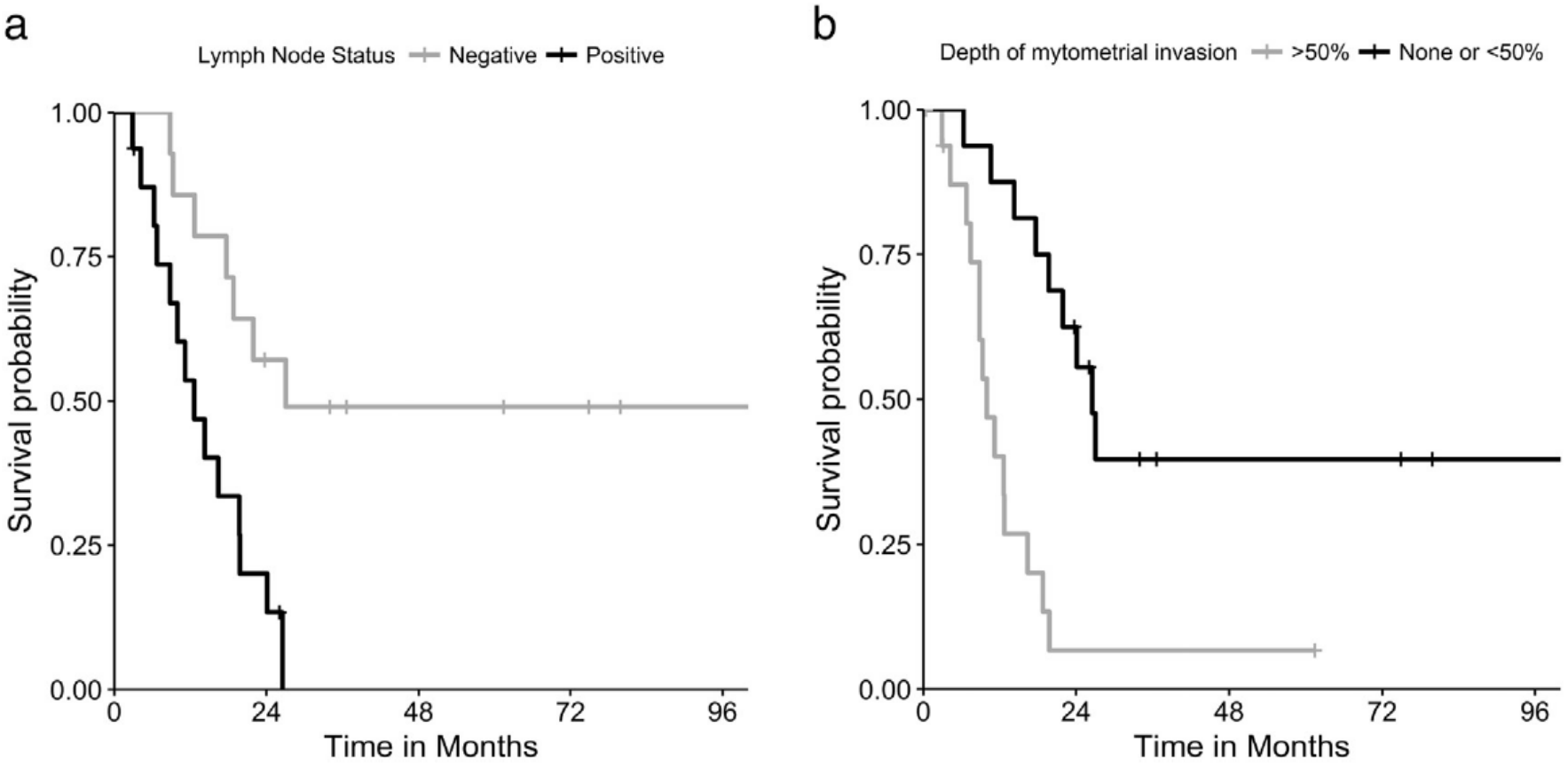
a
Lymph Node Status
Negative
Positive
1.00
0.75
0.50
0.25
0.00
Survival probability
0
24
48
72
96
Time in Months
b
Depth of mytometrial invasion
>50%
None or <50%
1.00
0.75
0.50
0.25
0.00
Survival probability
0
24
48
72
96
Time in Months

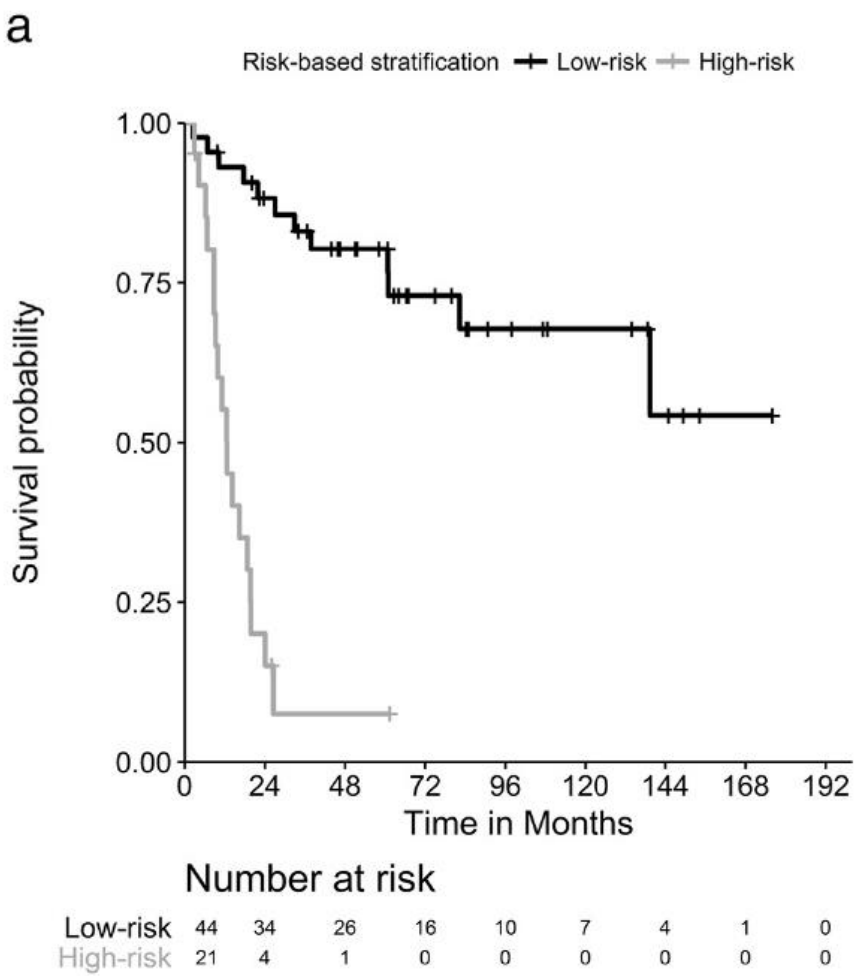
a
Risk-based stratification
Low-risk
High-risk
Survival probability
1.00
0.75
0.50
0.25
0.00
0
24
48
72
96
120
144
168
192
Time in Months
Number at risk
Low-risk 44 34 26 16 10 7 4 1 0
High-risk 21 4 1 0 0 0 0 0 0

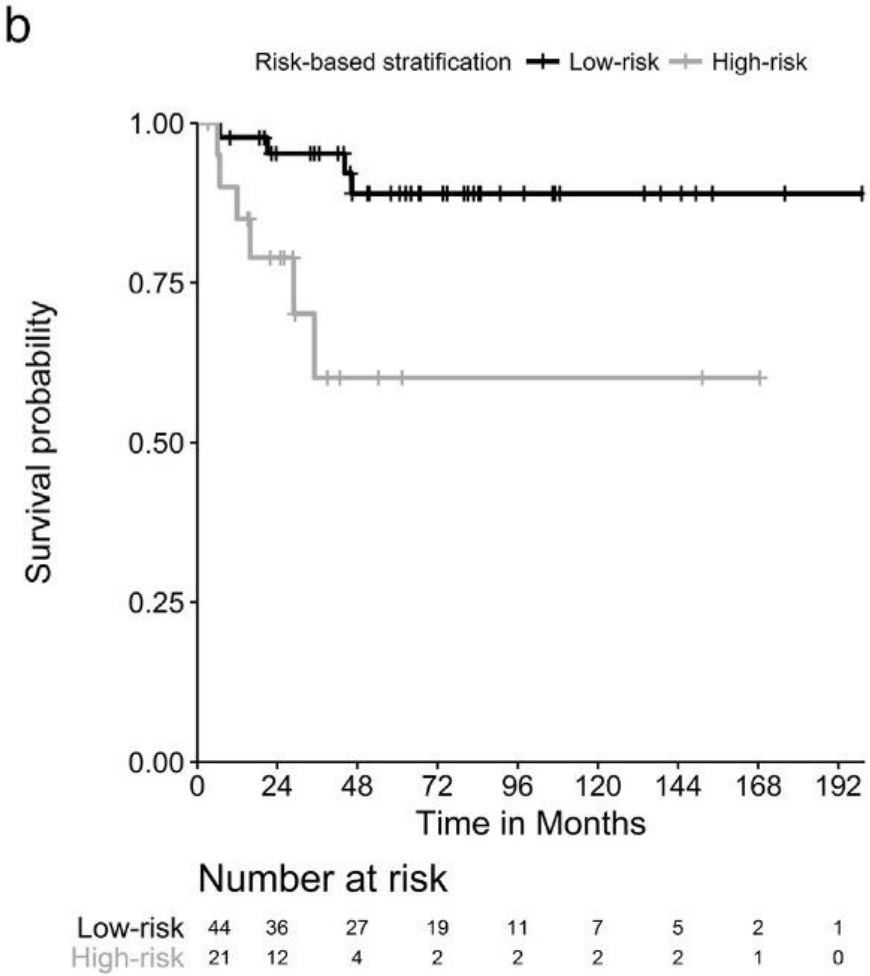
b
Risk-based stratification
Low-risk
High-risk
Survival probability
1.00
0.75
0.50
0.25
0.00
0
24
48
72
96
120
144
168
192
Time in Months
Number at risk
Low-risk 44 36 27 19 11 7 5 2 1
High-risk 21 12 4 2 2 2 2 1 0

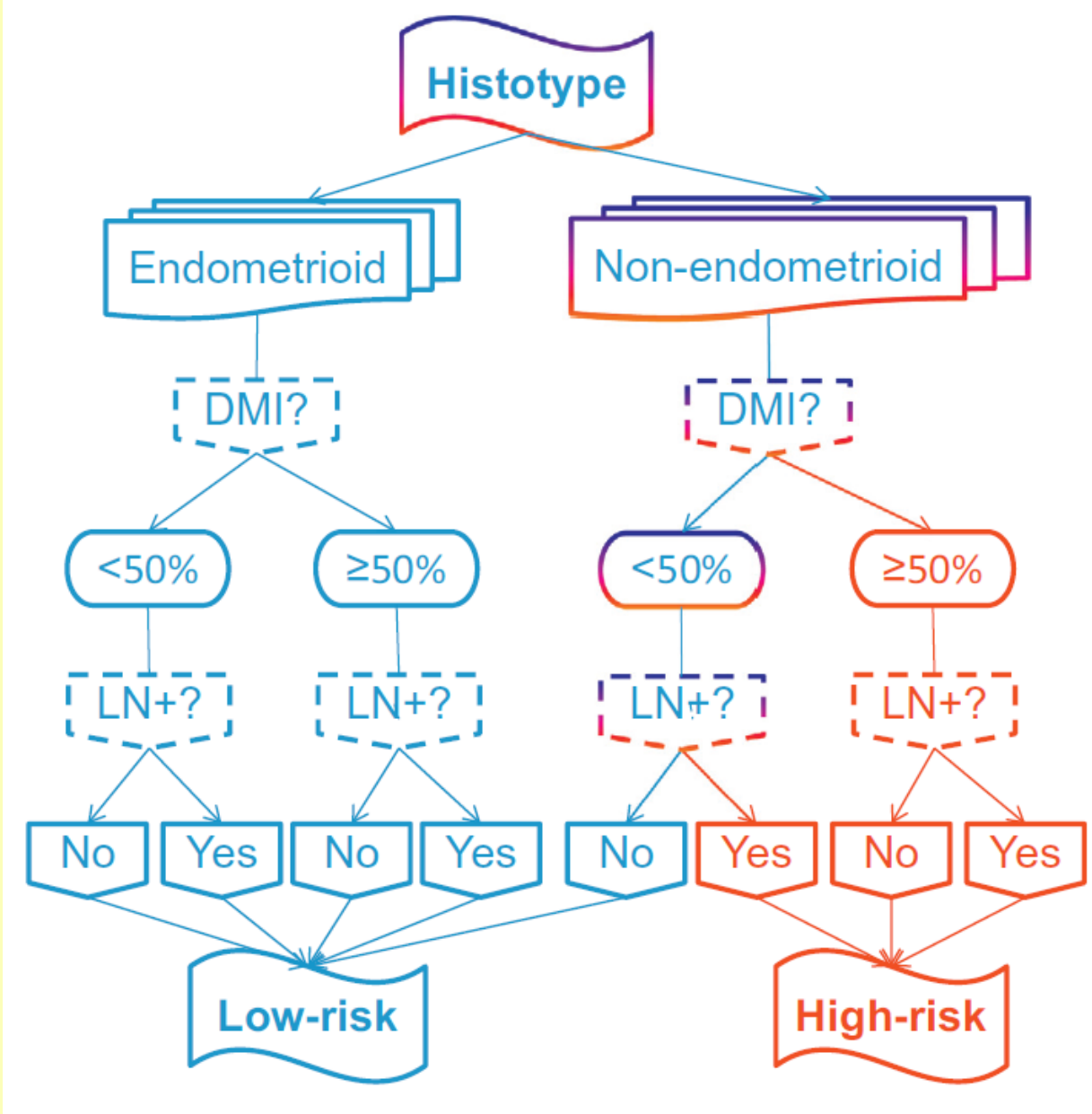
Histotype
Endometrioid
Non-endometrioid
DMI?
DMI?
<50%
≥50%
<50%
≥50%
LN+?
LN+?
LN+?
LN+?
No
Yes
No
Yes
No
Yes
No
Yes
Low-risk
High-risk

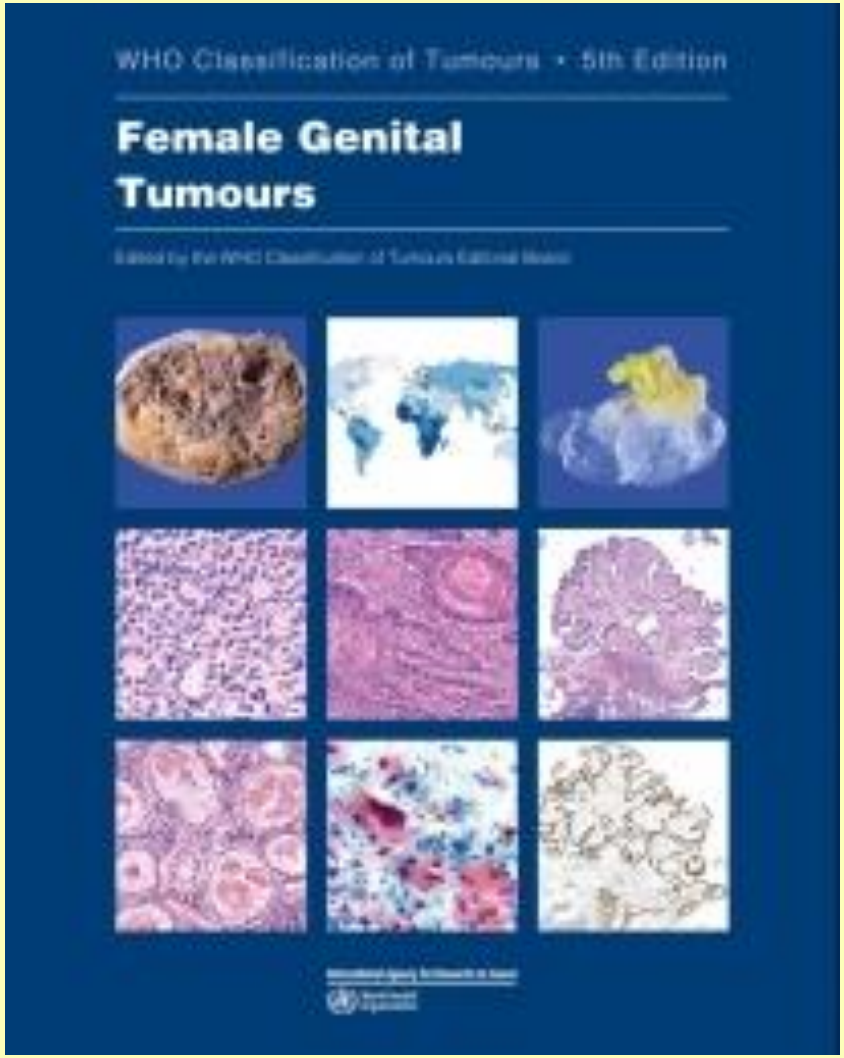
WHO Classification of Tumours • 5th Edition
Female Genital Tumours


WHO Classification of Tumours 5th Edition: Female Genital Organs Tumours
1st Editorial Board meeting: 9 May 2019, IARC, Lyon FRANCE

Simultaneous endometrioid carcinomas of the endometrium and the ovaries, WHO, 2020

- Most of them are clonally related ("metastatic")
- A subset with good prognosis, and should be managed as two independent primaries:
  - Unilaterality
  - Absence of vascular invasion
  - Low grade endometrioid morphology
  - Absence of metastasis in other places

Staging them as Stage III can give rise to overtreatment

The British Association of Gynaecological Pathologists

Synchronous endometrioid carcinomas of the endometrium and the ovaries

X. Matias-Guiu, M.D.
Hospital Universitari Arnau de Vilanova, University of Lleida, IRBLLEIDA
Hospital Universitari de Bellvitge, IDIBELL.