Clinical implications resulting from the new WHO classification, and a new era in vulvar cancer



Jessica N McAlpine-University of British Columbia and BC Cancer



Learning Objectives

- To understand how change in standard pathology reporting for vulvar precancer and cancer impacts clinical care (surgical goals, adjuvant therapy, surveillance)
- To understand/be aware of how further molecular stratification might refine these practice changes and other technologies that may be implemented to further inform clinical care

No COI to declare…but all ‘changes’ suggested within this presentation still need to be validated and represent informal recommendations/considerations only

Gynecologic Cancer Initiative

OVCARE BC'S OVARIAN CANCER RESEARCH TEAM

Vulvar Cancer –how has it been staged and what is still relevant?



Staging

→Historical key parameters in pathological reporting from staging (and per examination)

- Histology
- Depth of invasion
- Size of tumour
- Margins
- Involvement of inguino-femoral lymph node(s)
- (Proximity to midline)
- (Proximity to other structures)

New WHO classification-2020

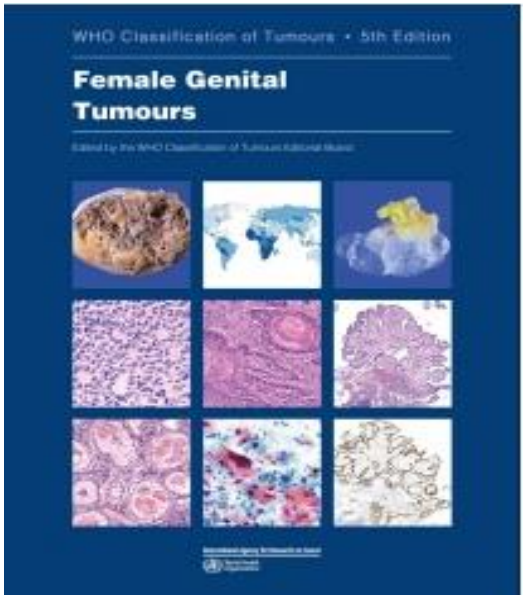

Vulvar squamous cell carcinoma

10.1.2: Squamous cell tumours and precursors

- 10.1.2.1: Squamous intraepithelial lesions, HPV-associated
- 10.1.2.2: Vulvar intraepithelial neoplasia, HPV-independent
- 10.1.2.3: Squamous cell carcinoma, HPV-associated
- 10.1.2.4: Squamous cell carcinoma, HPV-independent
- 10.1.2.6: Squamous cell carcinoma NOS

New WHO classification

- The term "**HPV-independent vulvar intraepithelial neoplasia (VIN)"** is recommended for the HPV-independent precursors. Most lesions included in this category are morphologically classified as **differentiated VIN**, but there is some morphological overlap between differentiated VIN and **high-grade SIL** {29505429; 19730361}. Recently, two other precursors of HPV-independent SCC have been described: **differentiated exophytic vulvar intraepithelial lesion** and **vulvar acanthosis with altered differentiation** {15105653; 27834349; 29470358; 31097103}. These precursors have been included as subtypes of HPV-independent VIN {27834349}.

- This edition of the WHO classification differs from previous editions by **dividing SCCs on the basis of their association with HPV infection** {23190170}. Approximately two thirds of vulvar SCCs arise via an HPV-independent pathway {23886586}; they behave more aggressively than HPV-associated carcinomas {28899974}. ….p16 is a reliable (although not perfect) surrogate of HPV-associated SCCs and can be assessed in most laboratories {26630231}…..
- A morphological diagnosis of **SCC NOS is an acceptable alternative where p16 immunohistochemistry or HPV testing is not available.**

- Although there are currently no differences in treatment between the two distinct etiopathogenic types, it is recommended that the type of SCC **(HPV-associated or HPV-independent) be documented** on the pathology report.

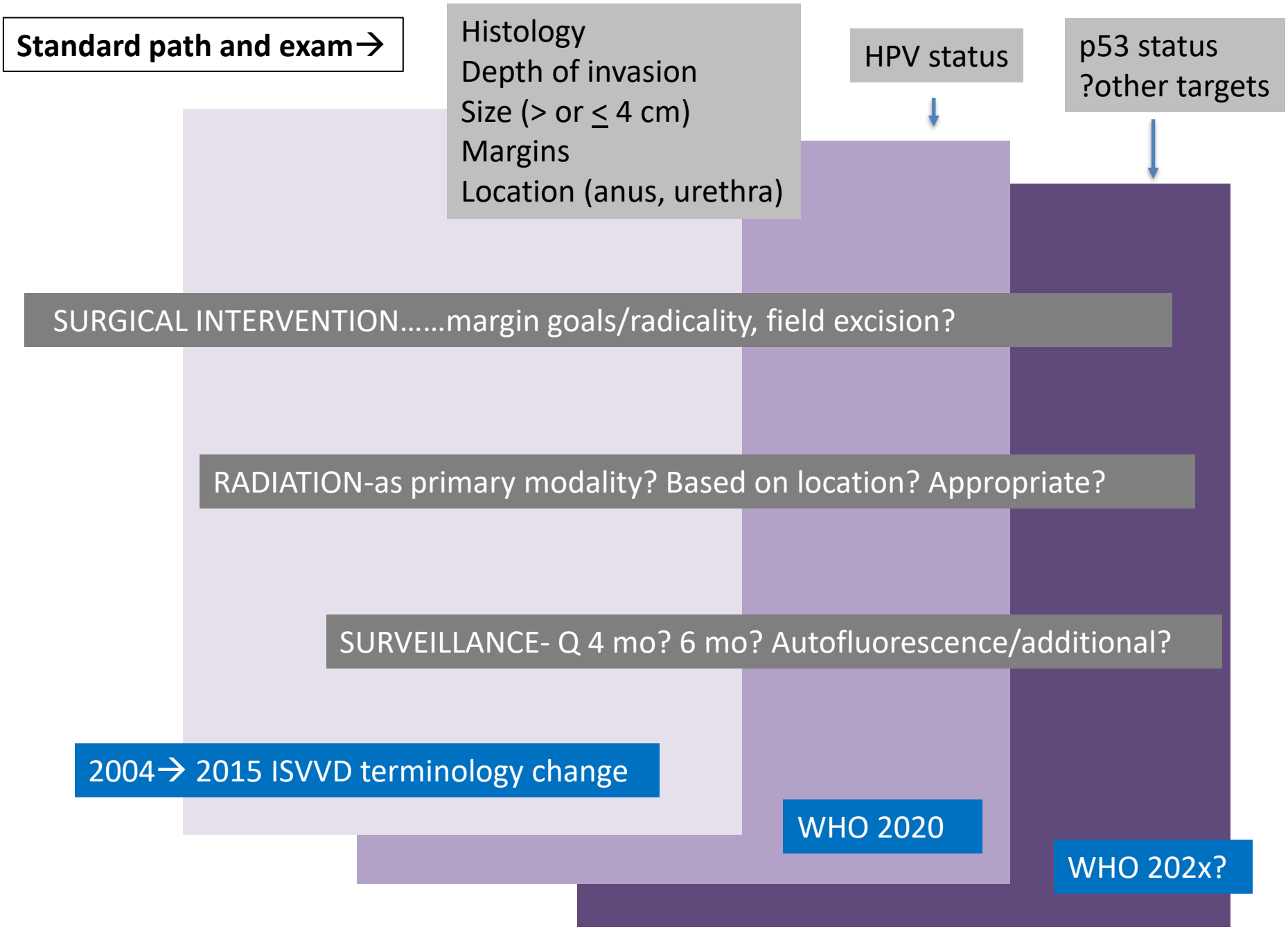
Standard path and exam→
Histology
Depth of invasion
Size (> or ≤ 4 cm)
Margins
Location (anus, urethra)
HPV status
p53 status
?other targets
SURGICAL INTERVENTION……margin goals/radicality, field excision?
RADIATION-as primary modality? Based on location? Appropriate?
SURVEILLANCE- Q 4 mo? 6 mo? Autofluorescence/additional?
2004→ 2015 ISVVD terminology change
WHO 2020
WHO 202x?

TREATMENT
Preinvasive: Vulvar intraepithelial neoplasia (VIN)

- Wide local excision (WLE)/skinning vulvectomy with 3 mm margin goals for all (in practice ~ 0mm tolerated)
- Margin assessment = visual and pathological
- Imiquimod – considered for any preinvasive lesion
- Laser –considered for any preinvasive lesion

-multisite and anatomic locations may direct to laser….



SURVEILLANCE
Preinvasive: Vulvar intraepithelial neoplasia (VIN)

- Q 4 mo or Q 6 mo for all…often followed for years

Preinvasive squamous cell lesions of the vulva

Two distinct pathways: for precursors (uVIN or HG SIL vs. dVIN) and progression to cancer. Often **two different phenotypes** walking in to office…





HPV-associated

- Younger women
- Smokers
- Prior abnormal paps/lower genital tract disease/HPV field effect
- Multisite
- Non-keratinizing (basal, warty)
- Less aggressive

HPV-independent

- Older
- +/- tobacco use…
- Often prior lichen sclerosis/vulvar dermatoses
- Unifocal?
- Precursor brief, misdiagnosed, + margins
- Differentiated, keratinized SCC
- More aggressive





dVIN vs HG SIL -outcomes

- Mean age dVIN and dVIN/VSCC 75 yo
- HPV-independent lesions were all unifocal
- Positive margins in 60-75% for dVIN and 35% for SCC
- Recurrence/progression of dVIN to SCC 30-92% across series within median time of 13-23 months. High proportion e.g., 22/25 dead of disease.
- In contrast…..progression of uVIN/HG SIL to cancer ~8-9% and with some series having no progression events at median 5 years f/u…other series time to VSCC 50-72 mo (Cochrane median 71.5 mo)

dVIN-only (without adjacent VSCC) is rare….what does that tell us?

van de Nieuwenhof et al Eur J Cancer 2009
Bigby et al, Int J Gyne Path 2016
Cochrane Systematic Review, 2016
McAlpine,..Gilks Int J Gyne Cancer 2017

Dramatic differences in outcomes: HPV-associated uVIN(red) and HPV-independent dVIN (blue)

Progression-free Survival

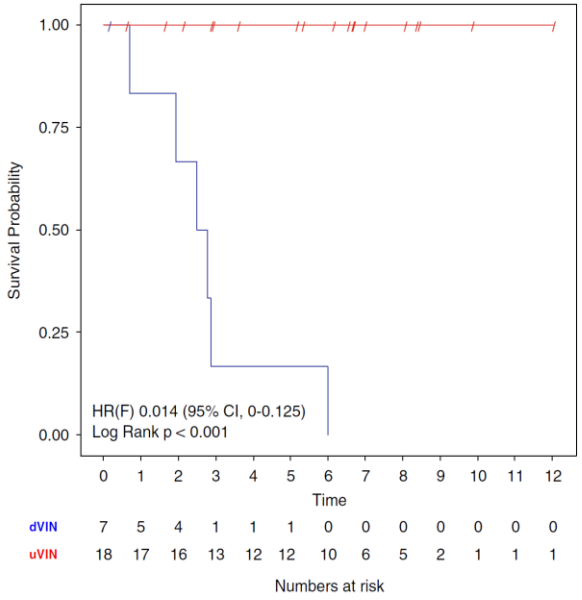

Disease-specific Survival

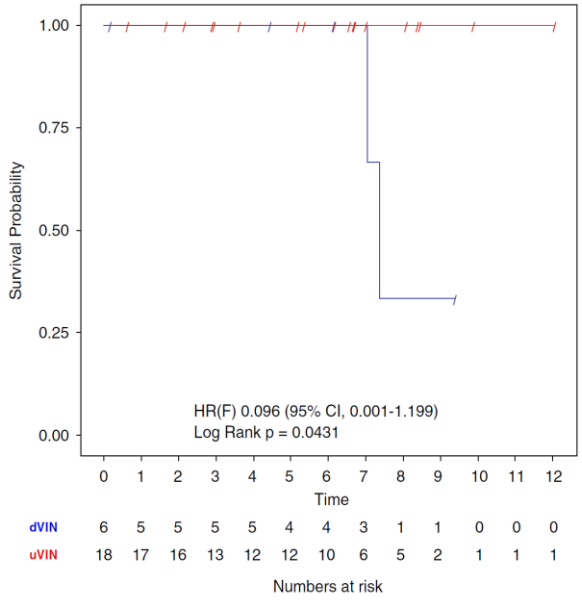

Overall Survival

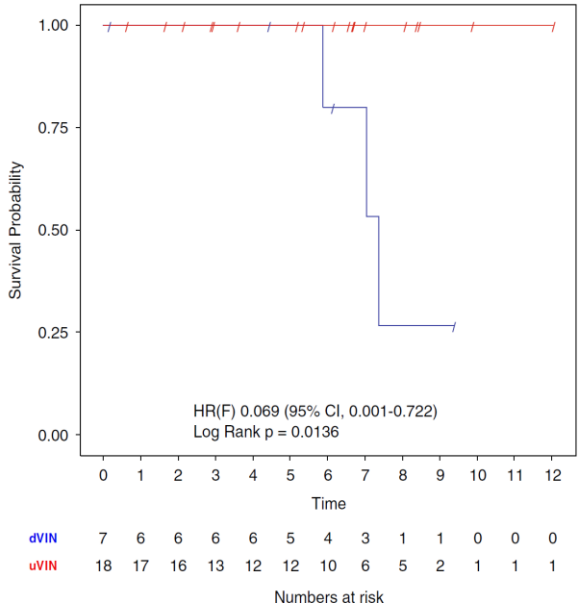

McAlpine, Kim, Gilks- Int J Gyne Ca, 2017

What about surveillance intervals for HPV-associated vs -independent?

May 2017, Biopsy LS

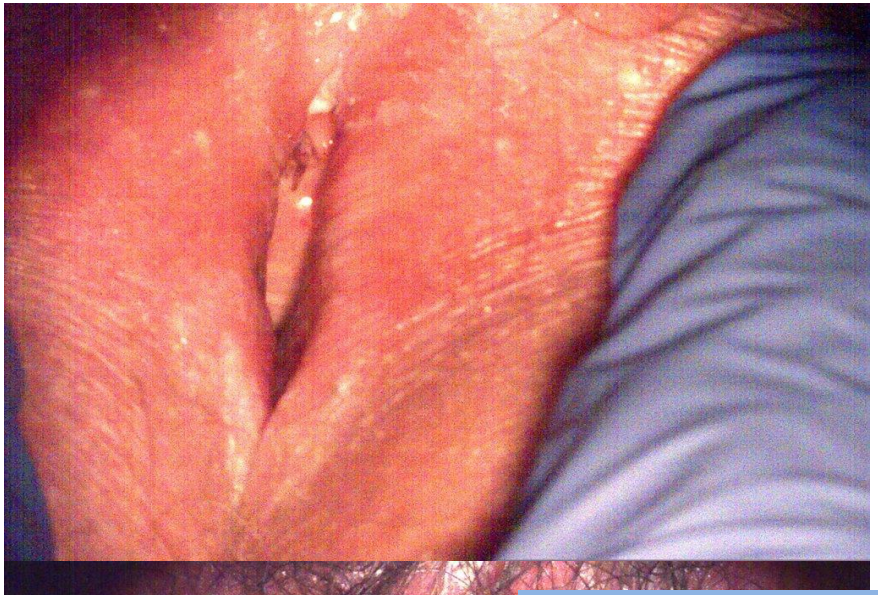

June 2017, after Clobetasol Rx



October 2017, no biopsies taken





What about surveillance intervals for HPV-associated vs -independent?

Jan 2018 (3 mo since last seen), VSCC

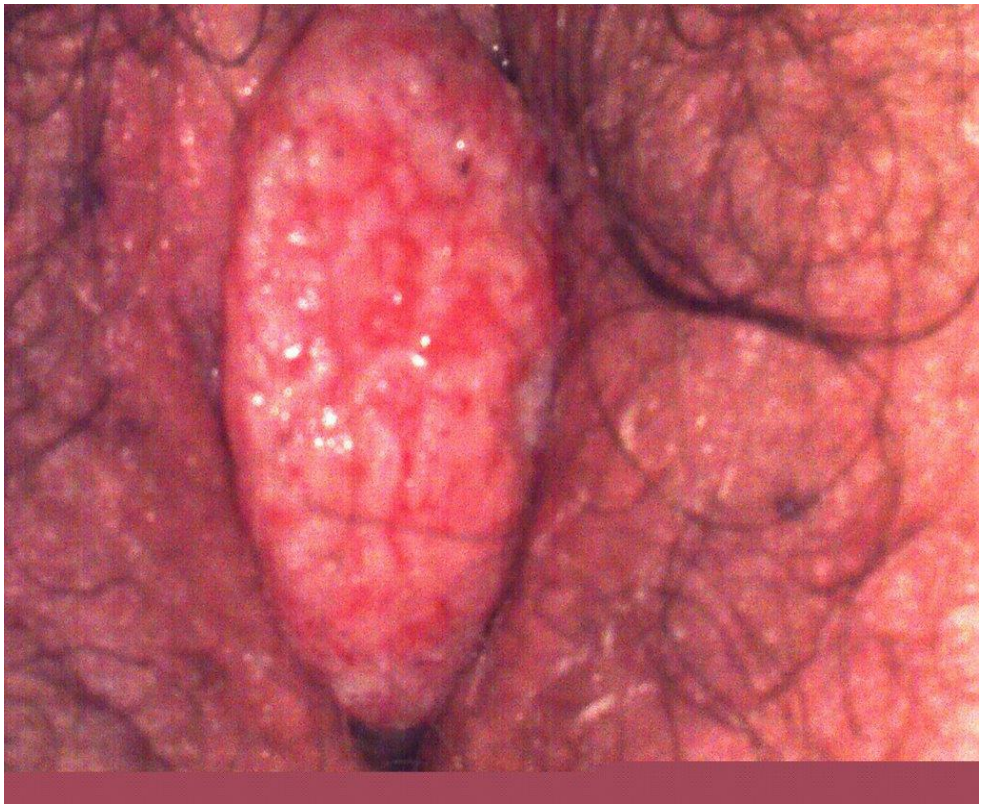

Challenges vulvar squamous lesions…continued

- Lack of refinement in risk stratification
- Margin status
- Tissue integrity
- Patient health/immunosuppression
- Anatomic location
- Multi-site
- Misdiagnosis
- Loss to follow-up

Singh et al, Am J Surg Path, 2015
Cheng et al, Int J Gyne Ca, 2016

Challenges vulvar squamous: Margin status

TABLE 1. Study Cases: Status of Specimen Resection Margins

Patient	Age (y)	Specimen No.	Invasive Component?	Blocks for p53	Original dx of Margins	p53-assisted Diagnosis of Margins
A	90	1	Y	8	All margins neg	All margins neg
		2	Y	6	All margins neg	Focal positive margin
		3	Y	6	All margins neg	Focal positive margin
B	33	4	Y	6	VIN at ant and post margins	VIN at ant and post margins
		5	Y	4	All margins neg	All margins neg
C	70	6	Y	9	All margins neg	All margins neg
D	92	7	Y	15	All margins neg	No dVIN
E	72	8	N	4	All margins neg	All margins neg
		9	N	13	All margins neg	Focal positive margin
F	77	10	N	15	All margins neg	Focal positive margin
G	51	11	N	17	All margins neg	All margins neg
H	49	12	Y	5	VIN at margin	More extensive margin involvement
I	50	13	Y	9	VIN focally at margin	More extensive margin involvement
J	97	14	Y	18	VIN at margin	More extensive margin involvement

Blocks for p53 = number of tissue blocks showing specimen resection margin that were immunostained for p53.

p53 IHC can assist

Singh et al, Am J Surg Path, 2015
Cheng et al, Int J Gyne Ca, 2016

Challenges vulvar squamous lesions…continued

- Lack of refinement in risk stratification
- Margin status
- Tissue integrity
- Patient health/immunosuppression
- Anatomic location
- Multi-site
- Misdiagnosis
- Loss to follow-up

Singh et al, Am J Surg Path, 2015
Cheng et al, Int J Gyne Ca, 2016

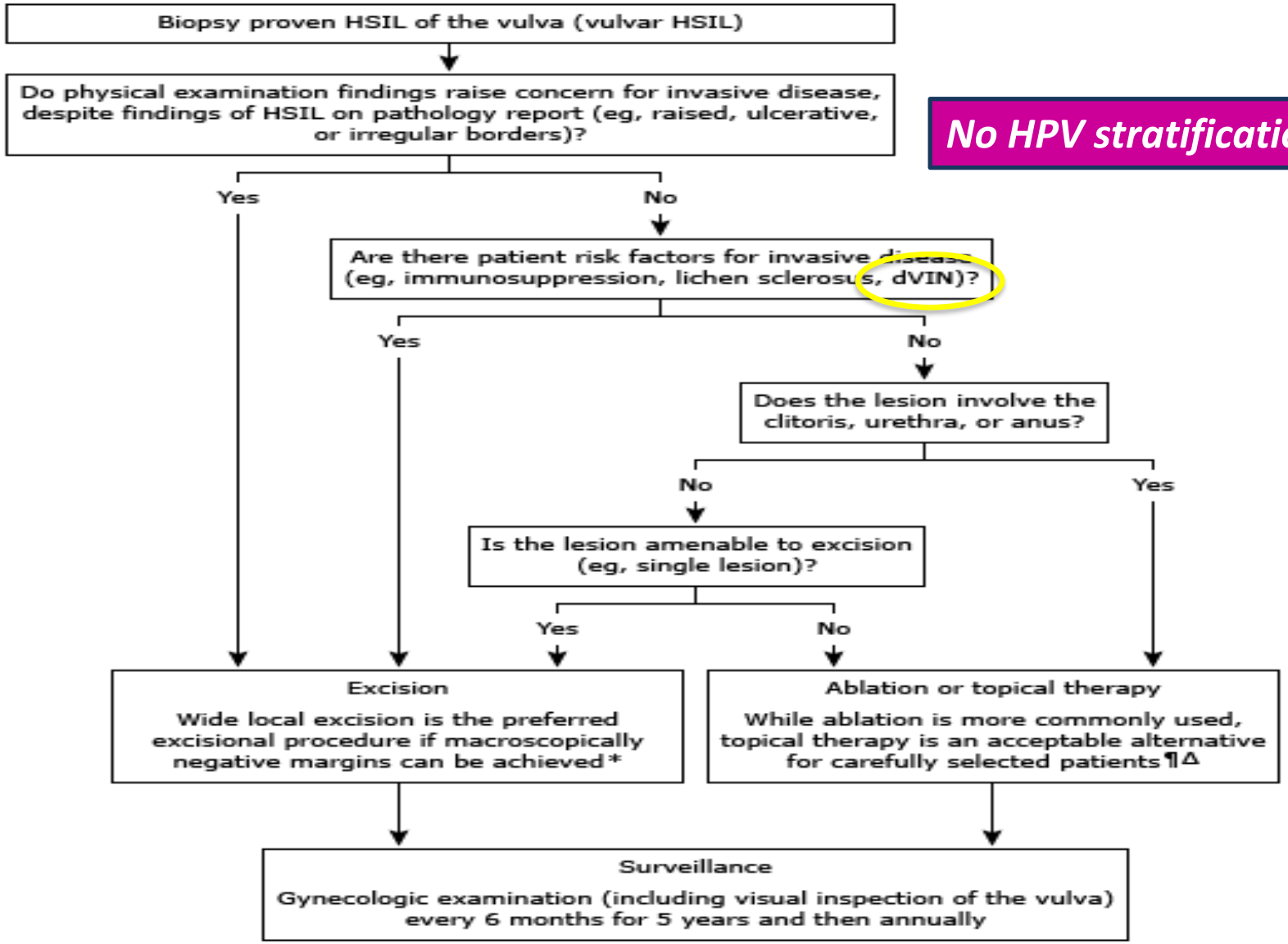

No HPV stratification

UpToDate

Hoelschneider et al, UpToDate 2020

TREATMENT CHANGES PROPOSED/IN ACTION for PREINVASIVE DISEASE

HPV-associated vs.HPV-independent



- Imiquimod – ? Impact decision based on HPV status?
- Laser –option for HPV- associated but should not be for HPV-independent
- Margin goals- >>> for HPV-independent
- Margin determination – better tools to assess ‘neg’ margin?
- High- potency steroids e.g. clobetasol. Role in HPV-independent and decrease risk of recurrence w Rx?

Tristram et al, Lancet Oncology 2014
Crabtree, Tyler JAMA Dermatology 2020

SURVEILLANCE CHANGES PROPOSED FOR PREINVASIVE
HPV-associated vs.HPV-independent



→Q 4 mo for HPV-independent…based on prior clinical course, date of most recent occurrence/recurrence and LONG TERM/? LIFETIME follow-up

→Q 6 mo for HPV- associated- CONSIDER EARLIER DISCHARGE

INVASIVE VSCC - Surgical Management

Invasive lesion: goal 1.4-1.5 cm surgical margin, 0.8 mm after fixation, 'radical' vulvectomy

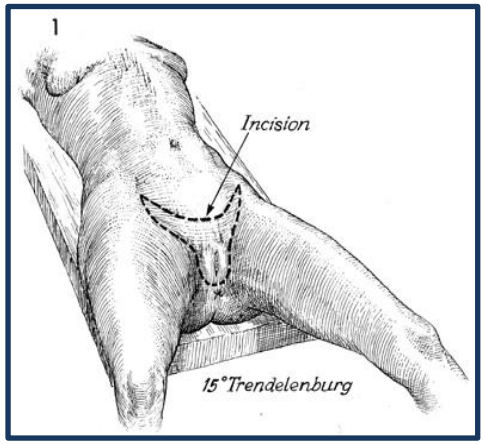

Surgical trend >1980's/90's to decrease morbidity…
1) AGGRESSIVE en bloc resection→ localized……
2) Full groin dissection→ sentinels

Decreased morbidity but is there a cost?
Are we seeing higher recurrence rates?

Currently no differences in surgical treatment algorithms based on HPV status

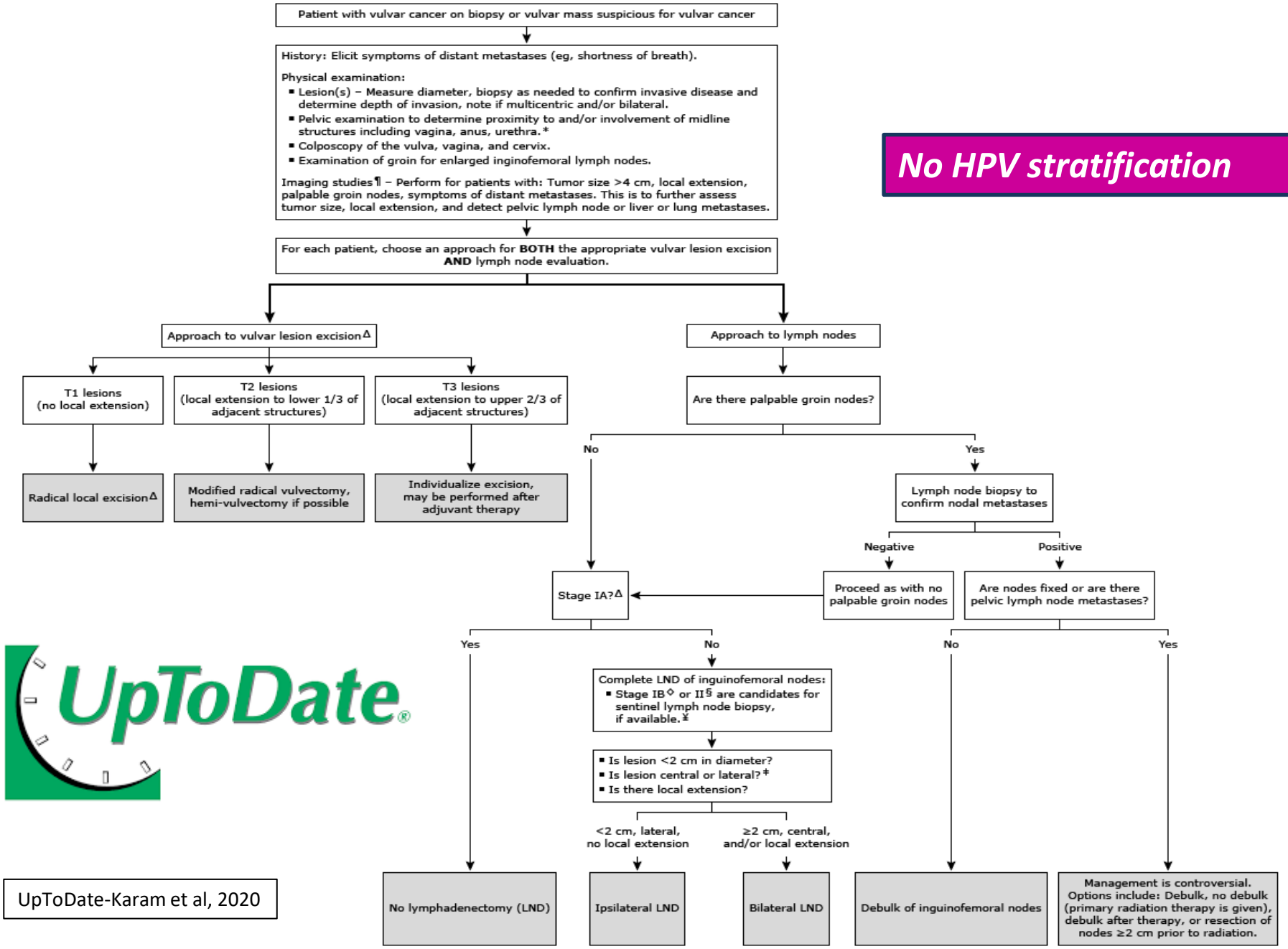

No HPV stratification

UpToDate®

UpToDate-Karam et al, 2020

VSCC –prognosis and HPV status

- **Prognostic: worse prognosis for HPV-negative tumours**
  - Ansink *Gynecol Oncol* 1994
  - Monk *Obstet Gynecol* 1995
  - van de Nieuwenhof *Cancer Epidemiol Biomarkers Prev* 2005
  - Lindell *Gynecol Oncol* 2010
  - Dong *AJSP* 2015
  - *Lee *Gynecol Oncol* 2016
  - Hay *J Low Genit Tract Dis* 2016
  - *Allo, Clarke, unpublished
  - McAlpine *Histopathol* 2017, in press
- **Not prognostic**
  - Pinto *Gynecol Oncol* 2004
  - Santos *AJSP* 2006
  - Alonso *Gynecol Oncol* 2011

Histopathology 2017 DOI: 10.1111/his.13205

Human papillomavirus (HPV)-independent vulvar squamous cell carcinoma has a worse prognosis than HPV-associated disease: a retrospective cohort study

- Identification of all patients with invasive VSCC from 1985-2005
- Patient demographics, clinicopathologic parameters (grade, histology, sites of metastasis, LVSI, margins), surgery performed, adjuvant therapy, cytology records, disease free survival, overall survival
- Pathology and IHC (p16) paraffin blocks

British Columbia Retrospective VSCC Project

- Identification of all patients with invasive VSCC from 1985-2005
- Patient demographics, clinicopathologic parameters, surgery performed, adjuvant Rx, cytology records, disease free survival, overall survival
- Pathology and IHC (p16) paraffin blocks

- Median age of HPV-independent and HPV-associated VSCC was 75 and 58 years respectively ($p<.001$)
- Tumor size, stage, LVI and adjuvant treatments were similar in both groups
- HPV-independent cases more commonly + positive margins ~40% vs 14%
- dVIN: not associated with prior abnormal cytology
- Factors associated with outcomes in ***univariable*** analysis included HPV status, age, tumor size, any positive node, and adjuvant treatment
- HPV status showed the strongest association with outcomes on ***multivariable*** analysis.

McAlpine, Karnezis- Histopathology, 2017

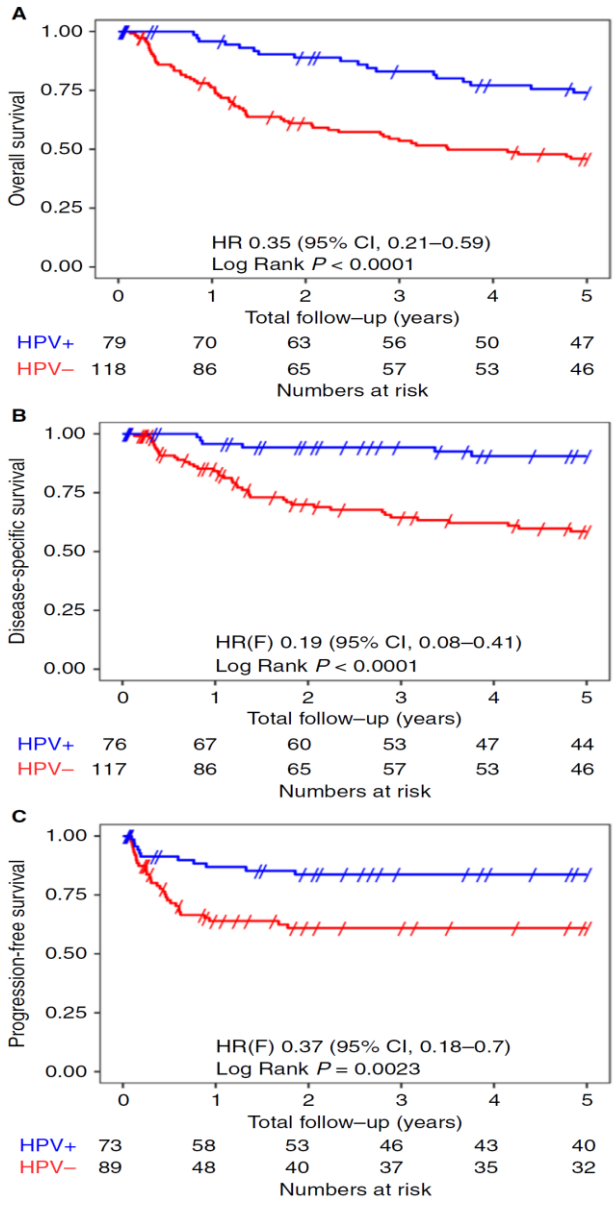

HPV-status impacted outcomes, yes….
but were there differences in outcomes across eras where surgical practice changed?

1985-1995 more radical, en bloc resections
1995-2005 shift to less radical/local radical

McAlpine, Karnezis -Histopathology, 2017

VSCC outcomes- practice pattern dependent?

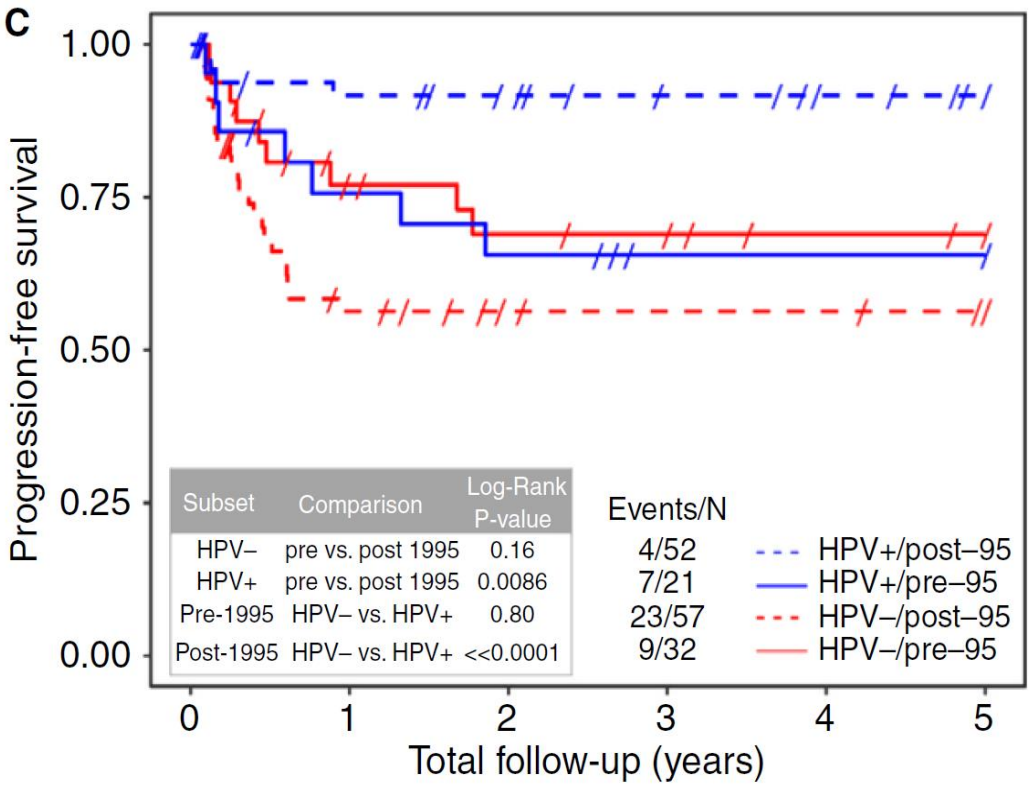

Less radical current practice-p16 pos

Radical *en bloc* era

Less radical current practice-p16 neg

Role for surgery appears to be different in HPV+ vs HPV- disease ….

Higher rate recurrences in HPV-independent disease and changing composition of pelvic exenterations

McAlpine, Karnezis -Histopathology, 2017

Further stratification- will it change management?

A, Kaplan–Meier curves for local recurrence rate.

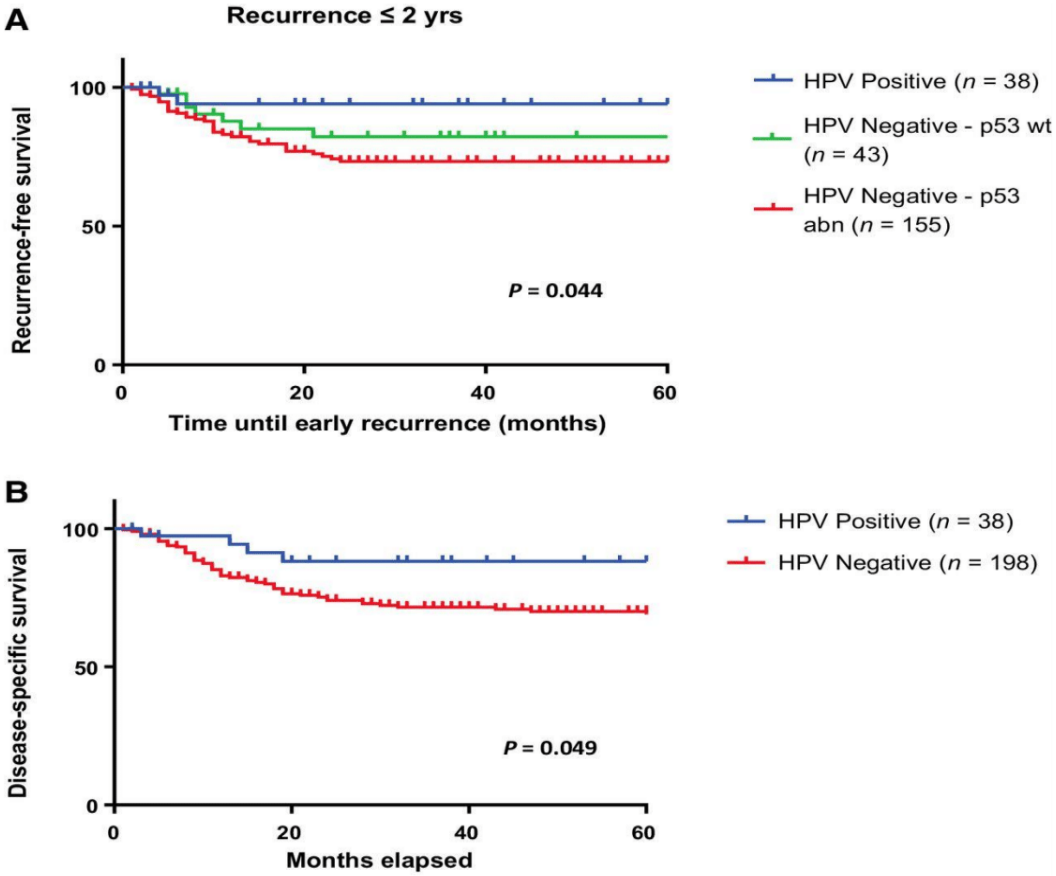

Linda S. Nooij et al. Clin Cancer Res 2017;23:6781-6789

©2017 by American Association for Cancer Research

Clinical Cancer Research
AACR American Association for Cancer Research

Contents lists available at ScienceDirect

Gynecologic Oncology

journal homepage: www.elsevier.com/locate/ygyno

Review Article

The prognostic value of p16 and p53 expression for survival after vulvar cancer: A systematic review and meta-analysis

Freja Lærke Sand [a,1], Ditte Maria Bjerno Nielsen [a,1], Marie Hoffmann Frederiksen [b], Christina Louise Rasmussen [a], Susanne K. Kjaer [a,c,*]

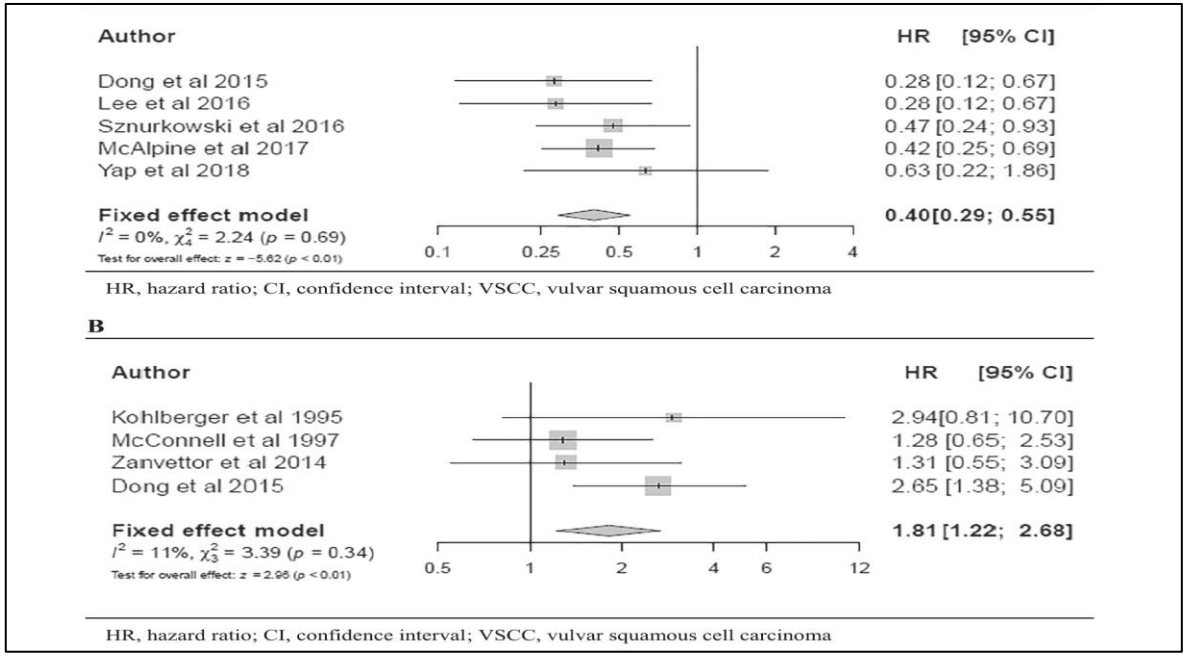

p53positive ….HR 1.81
p16 Positive…. HR 0.4

Sand et al, Gynecol Oncol 2017

“Clinically relevant third subgroup of VSCC …. p53-/p16”

- p53 abnormal denotes a worse outcomes subgroup of VSCC
- ‘Pattern based’ p53 IHC is a good surrogate for TP53 mutations
- Cases with TP53 and PIK3CA co-mutations had the worst clinical outcomes ($p < 0.001$).

→ *“recommend testing for p53 in all HPV-independent lesions suspicious for dVIN, even in the presence of marked inflammation or non-acanthotic skin, particularly when close to a margins…”*

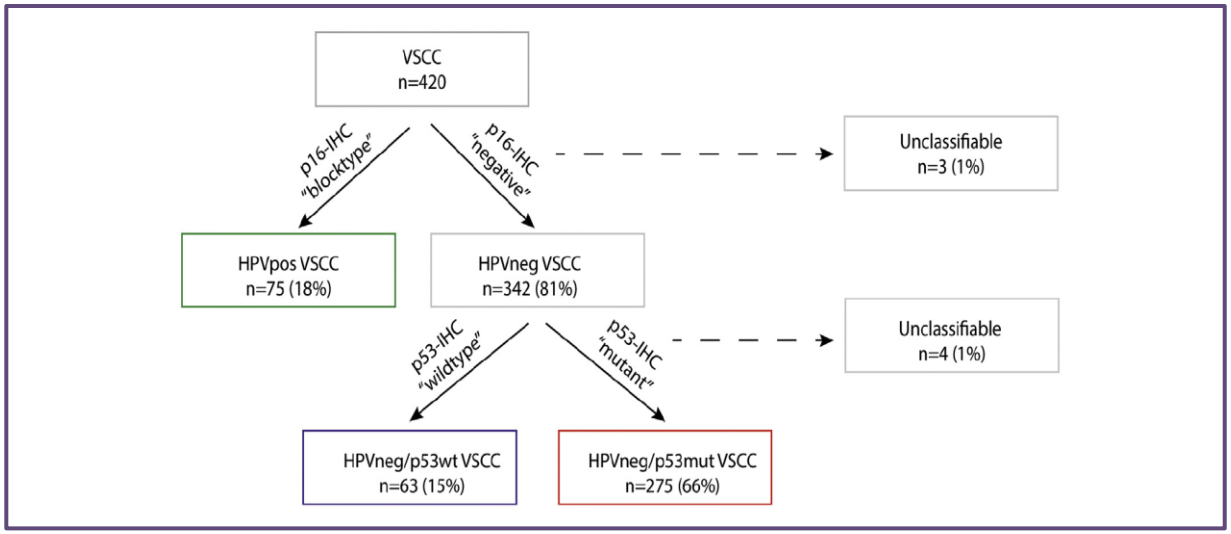

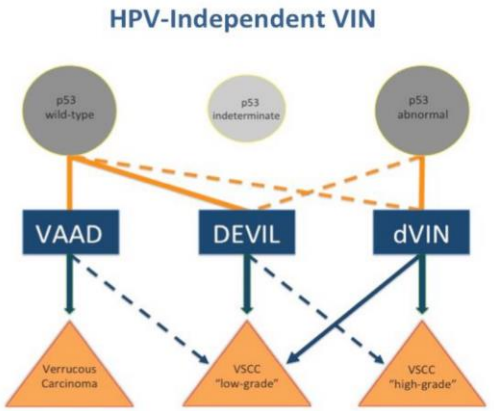

Hoang, Pathology 2016; Tessier-Cloutier, Mod Path, 2020 and 2021; Kortekaas, Histopath 2020;Gilks and Singh, Histopathology 2021, Nooj et al, CCR 2017
Kortekaas et al Gyn Onc 2020, Woelber et al AJOG 2021

What about margins then? If greater surgical effort needed for HPV-independent disease how great/radical is needed?

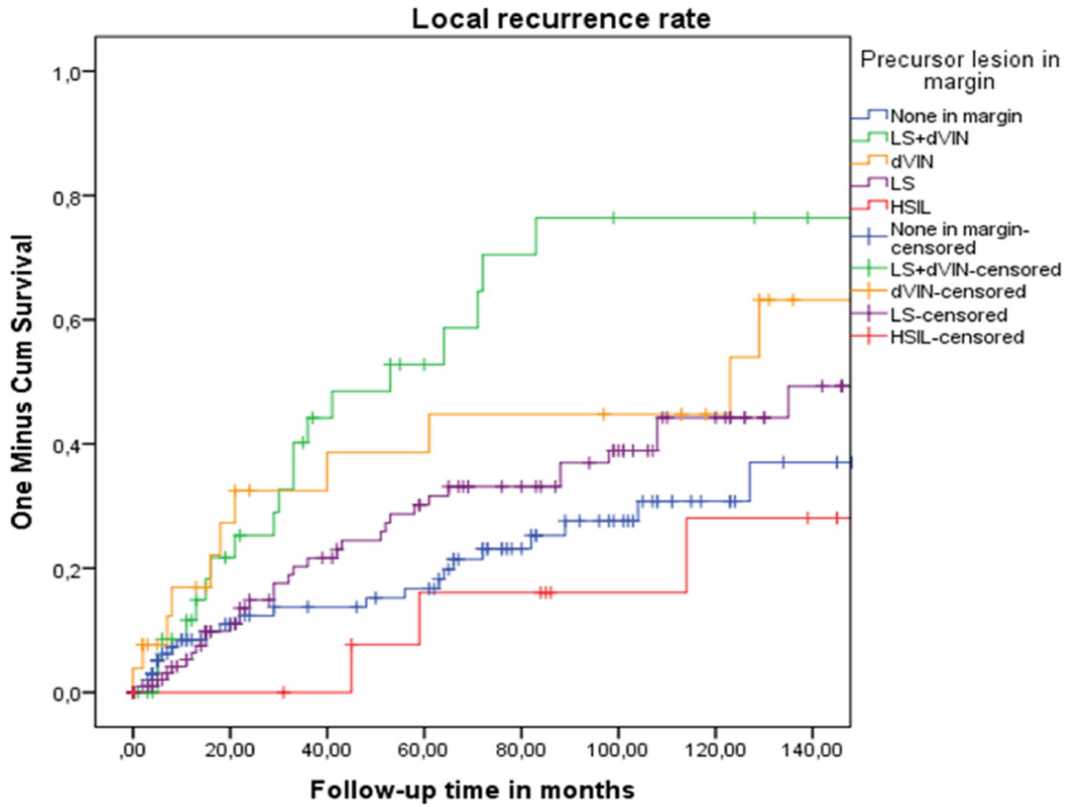

Months		0	24	60	120	144	**Univariable Cox-regression** HR (95% CI)
Number at risk							
-	None in margin	103	64	56	14	9	1.0
-	LS and dVIN	39	20	9	3	1	3.32 (1.79-6.16), p<0.001
-	dVIN	26	12	10	6	1	2.28 (1.10-4.71), p=0.042
-	LS	104	66	47	19	9	1.45 (0.84-2.49), p=0.183
-	HSIL	15	15	10	6	5	0.83 (0.28-2.41), p=0.728

Margins-Local recurrence rate impacted by presence of dVIN in the margin (vs. adjacent to). LS and HSIL margins not matter...

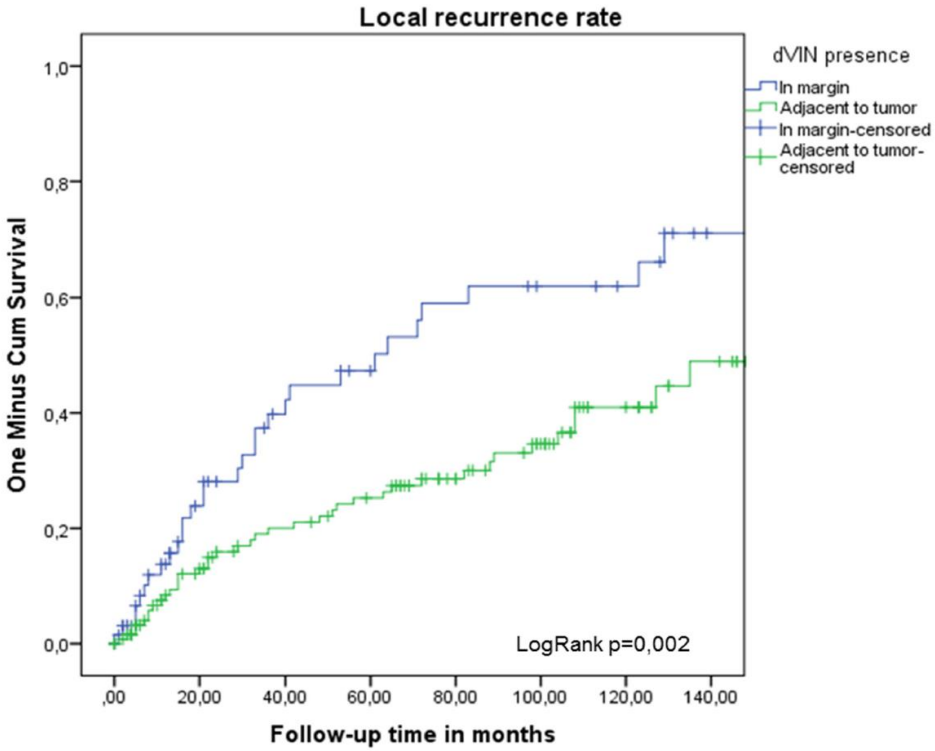

Months	0	24	60	120	144
Number at risk					
- dVIN in margin	65	32	19	9	2
- dVIN adjacent to the tumor	132	86	70	22	11



→Need to return to OR when dVIN positive margin
→ Consider toleration of lesser margins with all other pathology? E.g., HSIL?

Grootenhuis et al, Gynecol Oncol 2019

Chemoradiation in Vulvar Cancer- is it a good option? Discordant results in historical series→ why?

- Assessed primary RT for nonsurgical advanced VSCC
- Worse outcomes/recurrence in older individuals….why?

Cochrane Review 2011
Natesan et al, Int J Gyne Cancer, 2016

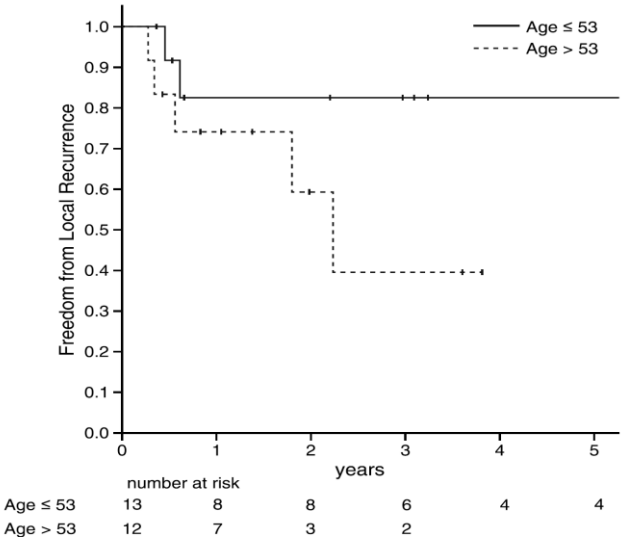



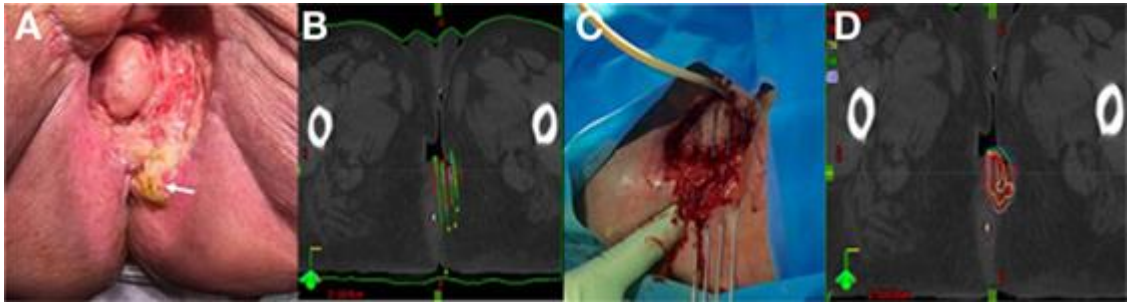

Chemoradiation in Vulvar Cancer
-discordant results in historical series→ why?

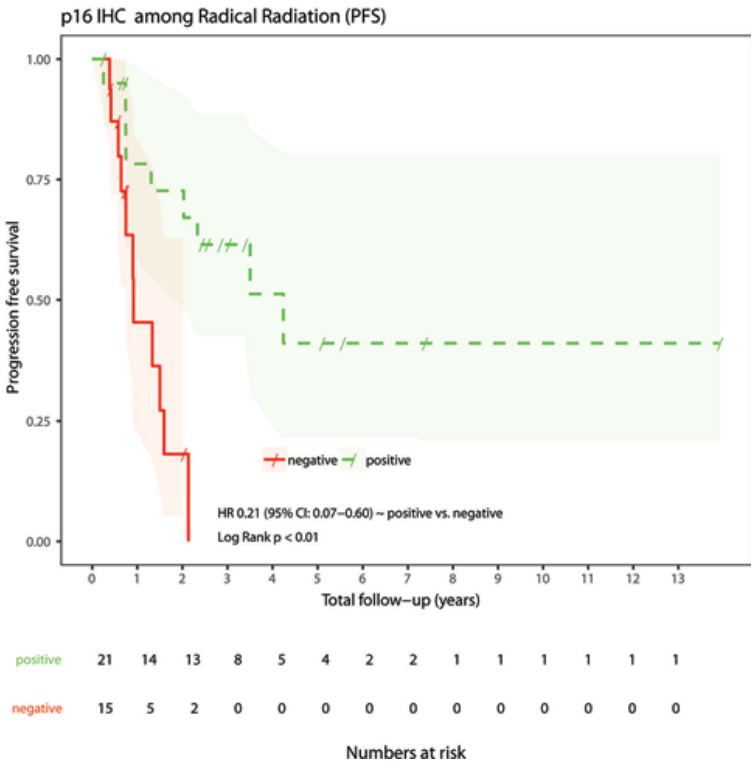

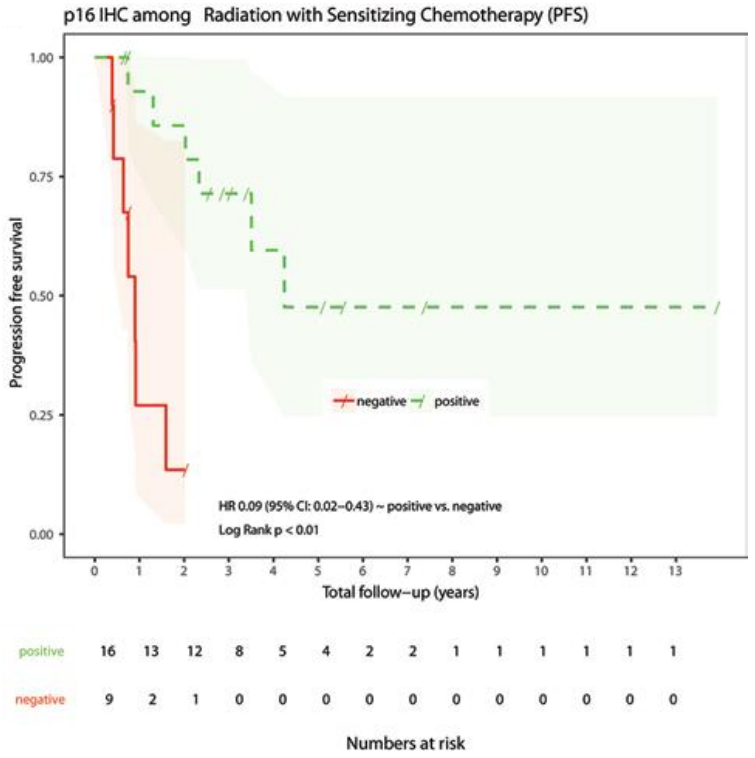

- Outcomes (PFS and OS) in women who received definitive radiation or chemoradiation differed markedly by HPV status

=Predictive implications

→Rethink primary ChemoRT in HPV-independent VSCCs?

→Possible de-escalation in the more radiosensitive HPV-associated VSCCs??

Proctor et al, Gyn Onc 2020; Lee et al, Gyn Onc 2016; Yap, Clin Oncol 2018

Radiation- side effects!
Particularly hard to bear if RT not curative/as effective!

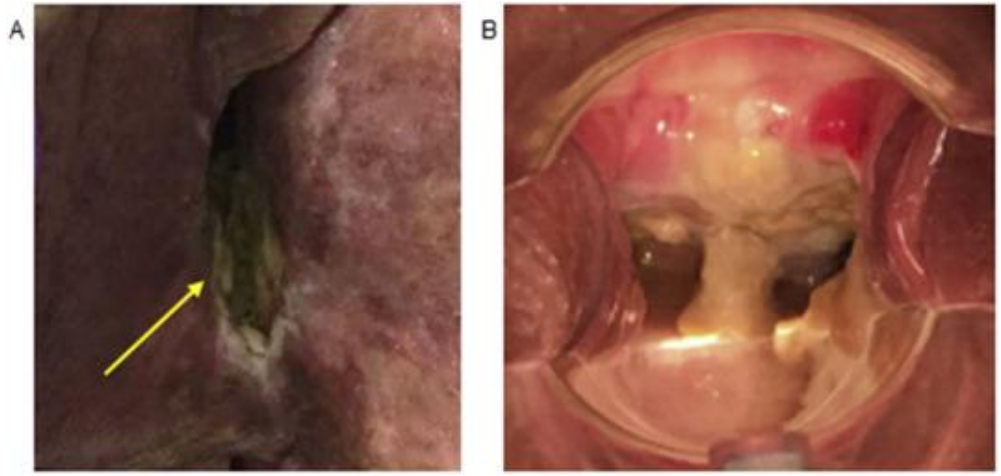



Do we need to change our mindset?

…primary surgery to ‘spare’ colostomy–is it really enabling an improved quality of life? Should primary RT be offered in HPV-independent tumor or is radical upfront surgery better?

→More radical again? Vulvar Field Resection

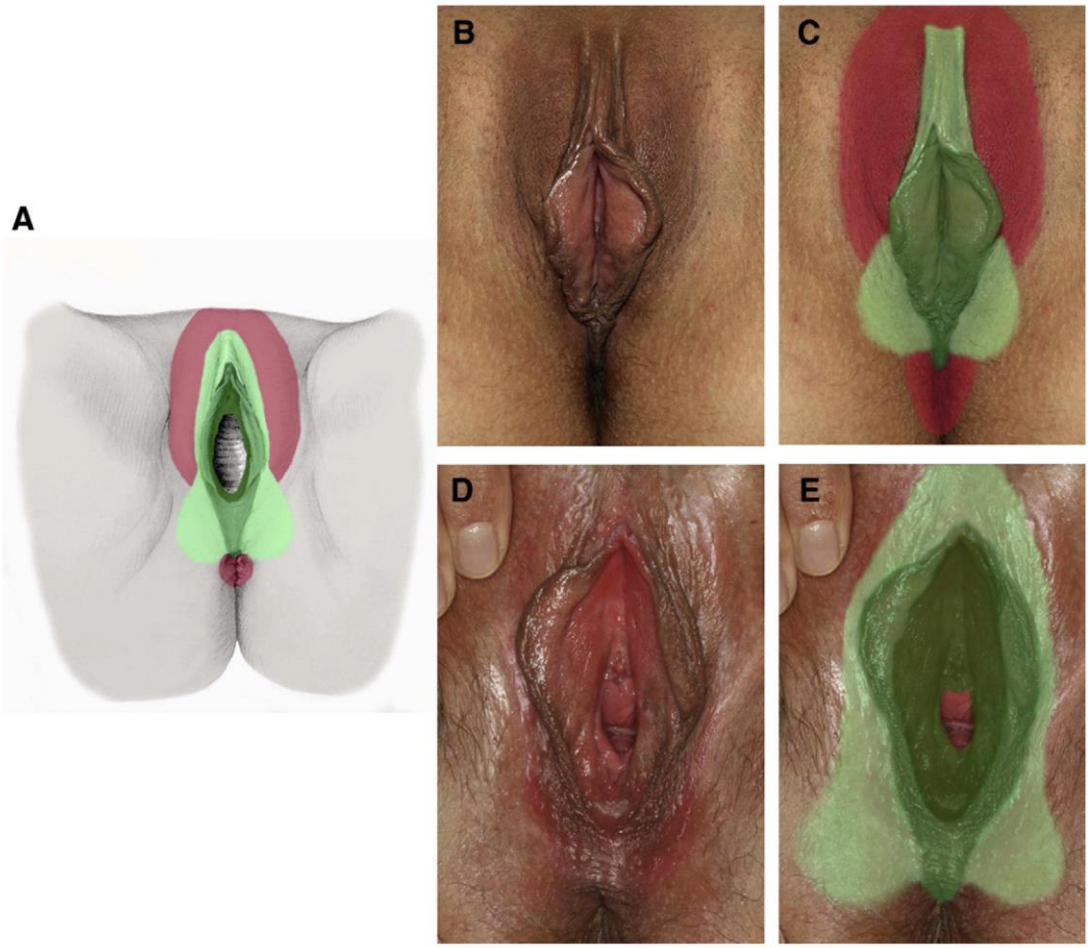

- Ultra radical surgery proposed= Vulvar Field/complete resection!
- Ontogenetic vulvar anatomy colored to demonstrate site of origin/derivation from different precursor tissues.
- Three subcompartments shown

HÖckel et al, Gyn Onc 2020
Hockel et al, Lancet Oncology 2018

→More radical again? Vulvar Field Resection



- Have we come a full circle?
- Morbidity
- Resources (OR time, plastics consultation, extended hospital stay)

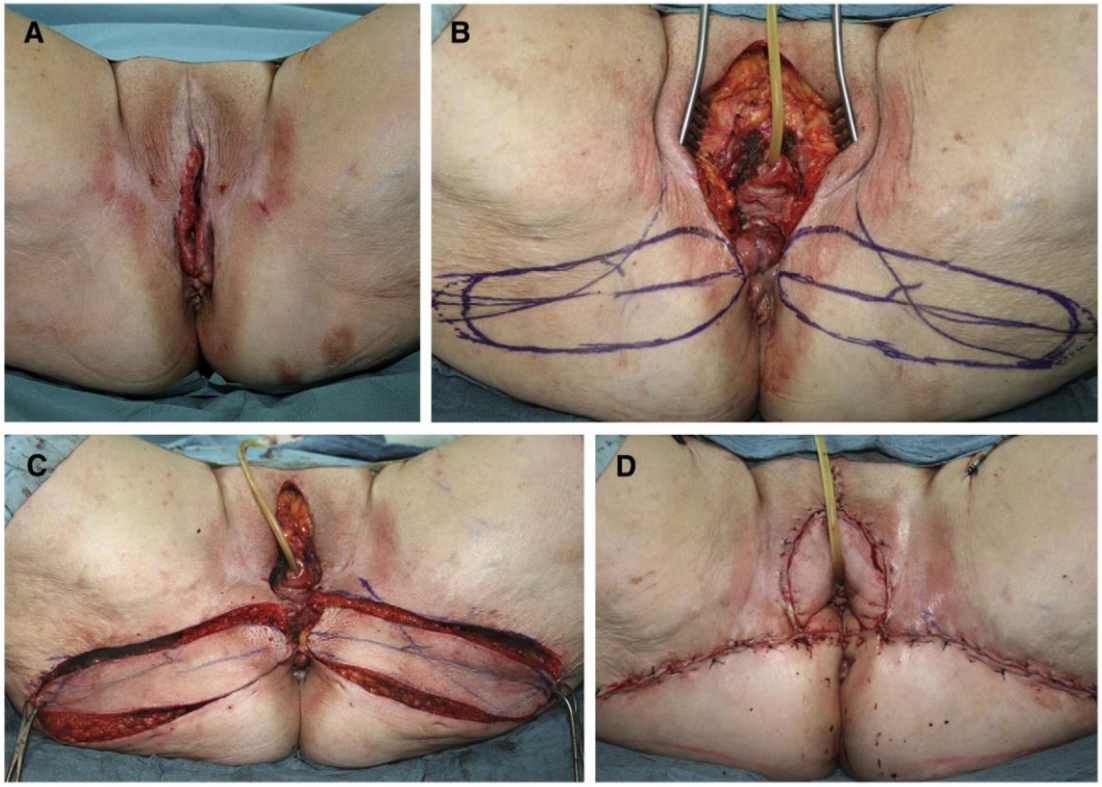

And…
no HPV stratification!

Summary:

- Traditional pathology reporting still essential (histotype, nodes)
- Molecular features define diverse diseases-prognostic and predictive implications
- Algorithms for preinvasive + invasive disease based on HPV status
- Margins will be an evolving story- but clearly dVIN at the margin is impactful→ consider re-resection
- The 'best' surgery still to be determined but clearly a more aggressive surgical effort for HPV-independent preinvasive and invasive squamous lesions
- Radiation: HPV- associated lesions are more sensitive to RT/chemoRT = better option to use (and possible de-escalation?) Upfront surgical effort may be a better option than primary RT/chemoRT for HPV-independent disease

New trials, new directions..

- HPV and p53- specific algorithms
- HPV and p53-specific clinical trials
- Imaging technologies to help determine margin status
- Molecular markers to help determine margin status



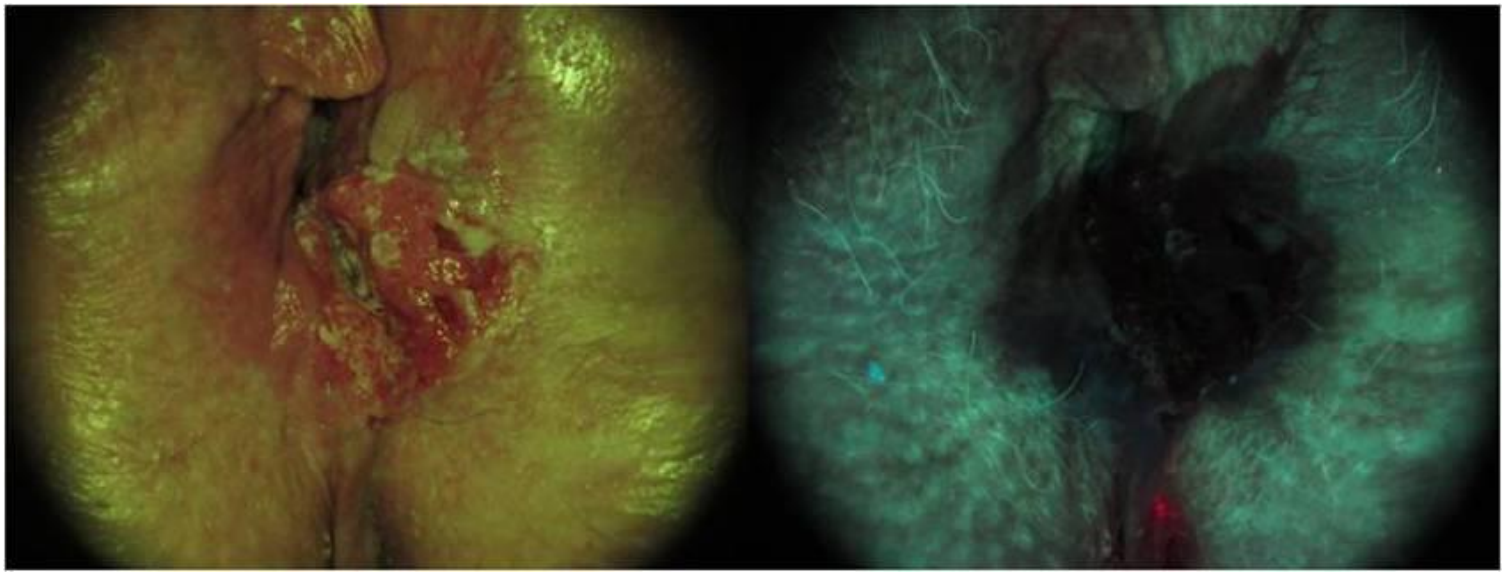

Acknowledgements

UBC:
Blake Gilks
Lien Hoang
Emily Thompson
Lily Proctor
Amy Jamieson
Dianne Miller
Tony Karnezis
Rachel Kim
Ardalan Akbari
Sima Eshragh
Samuel Leung
Angela Cheng
C Chow

UK-Barts and the London NHS:
Susanne Jordan
Naveena Singh



Questions?