The British Association of Gynaecological Pathologists

# 21st Annual Meeting in Collaboration with ISGyP

# 5th and 6th June 2025

## Vaginal Epithelial Lesions. An Update.

Dr Karen Talia
The Royal Women's and the Royal Children's Hospital
Melbourne
Australia

6th June 2025

The British Association of Gynaecological Pathologists

# Speaker disclosures

- ❑ I have no financial conflicts of interest to disclose

# Vaginal epithelial neoplasia

Primary vaginal carcinoma is RARE

Less common than other FGT sites

**80% of vaginal carcinoma is metastatic – endometrium, cervix, vulva, colorectum**

Most primary carcinomas are squamous, **most HPVA**

90% SCC vs.10% adenocarcinoma

*IJGO 2021;155:19-27*

| HPVA | squamous | HPVI |
| --- | --- | --- |
| HPVA precursors: SIL (VaIN) | | HPVI: None established |
| HPVA-associated SCC *Majority* | | HPV-independent SCC |

| HPVA | glandular | HPVI |
| --- | --- | --- |
| | | **Proposed precursors:** Villous adenoma<br>Atypical adenosis |
| **HPV-associated adenocarcinoma** | | **HPV-independent adenocarcinoma**<br>• Endometrioid adenocarcinoma<br>• Clear cell carcinoma<br>• Mucinous carcinoma, gastric type<br>• Mucinous carcinoma, intestinal type<br>• Mesonephric adenocarcinoma<br>• Adenocarcinoma of Skene's gland origin<br>*Majority* |
| | | Secondary carcinoma |

# WHO 5 – 1° vaginal squamous lesions

| BENIGN | MALIGNANT |
| --- | --- |
| Squamous papilloma of the vagina | HPV-associated SCC |
| Atrophy of the vagina | HPV-independent SCC |
| Tubulosquamous polyp | Squamous cell carcinoma NOS |
| Squamous intraepithelial lesions | |

# Vaginal squamous cell carcinoma

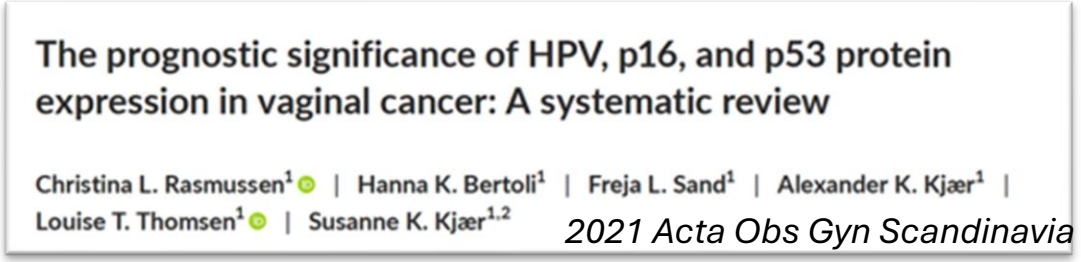
The prognostic significance of HPV, p16, and p53 protein expression in vaginal cancer: A systematic review

Christina L. Rasmussen[1] | Hanna K. Bertoli[1] | Freja L. Sand[1] | Alexander K. Kjær[1] | Louise T. Thomsen[1] | Susanne K. Kjær[1,2]

*2021 Acta Obs Gyn Scandinavia*


Human papillomavirus and p16 in squamous cell carcinoma and intraepithelial neoplasia of the vagina

Hanna Kristina Bertoli[1], Christina Louise Rasmussen[1], Freja Lærke Sand[1], Vanna Albieri[2], Bodil Norrild[3], Freija Verdoodt[1] and Susanne K. Kjaer[1,4]

*Int J Cancer 2018*

70-80% HPVA, mostly HPV 16

HPVA vaginal cancer incidence rising globally

Morphology as in cervix; HPVI more likely keratinising, p53abn in 59%

**Diagnosis requires no concurrent or recent (5 yrs) vulval/cervical SCC**

Based on published studies:

- **p16 unpredictable** – p16 ”overexpression” in HPVI cases
- **Improved survival in HPVA** vaginal SCC compared with HPVI
- p53 prognostic impact: No firm conclusions; mixed findings (small numbers)

*Alonso Gynecol Oncol 2012, Adams Int J Gynecol Obstets 2021*

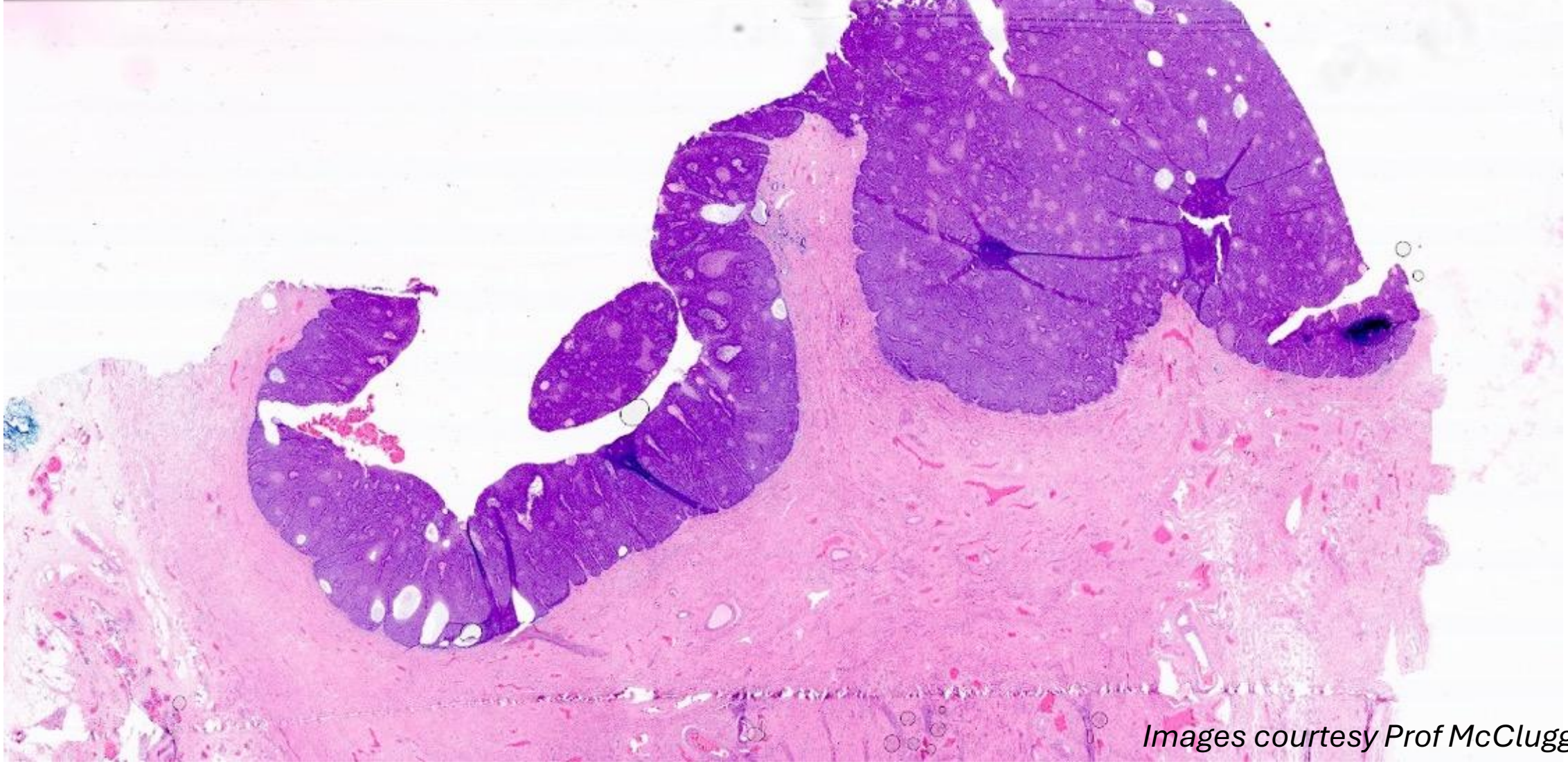

*Images courtesy Prof McCluggage*

# Case 1

51yo

At hysterectomy for other reasons - partial resection of vaginal wall

Known vaginal lesion, biopsy: VaIN

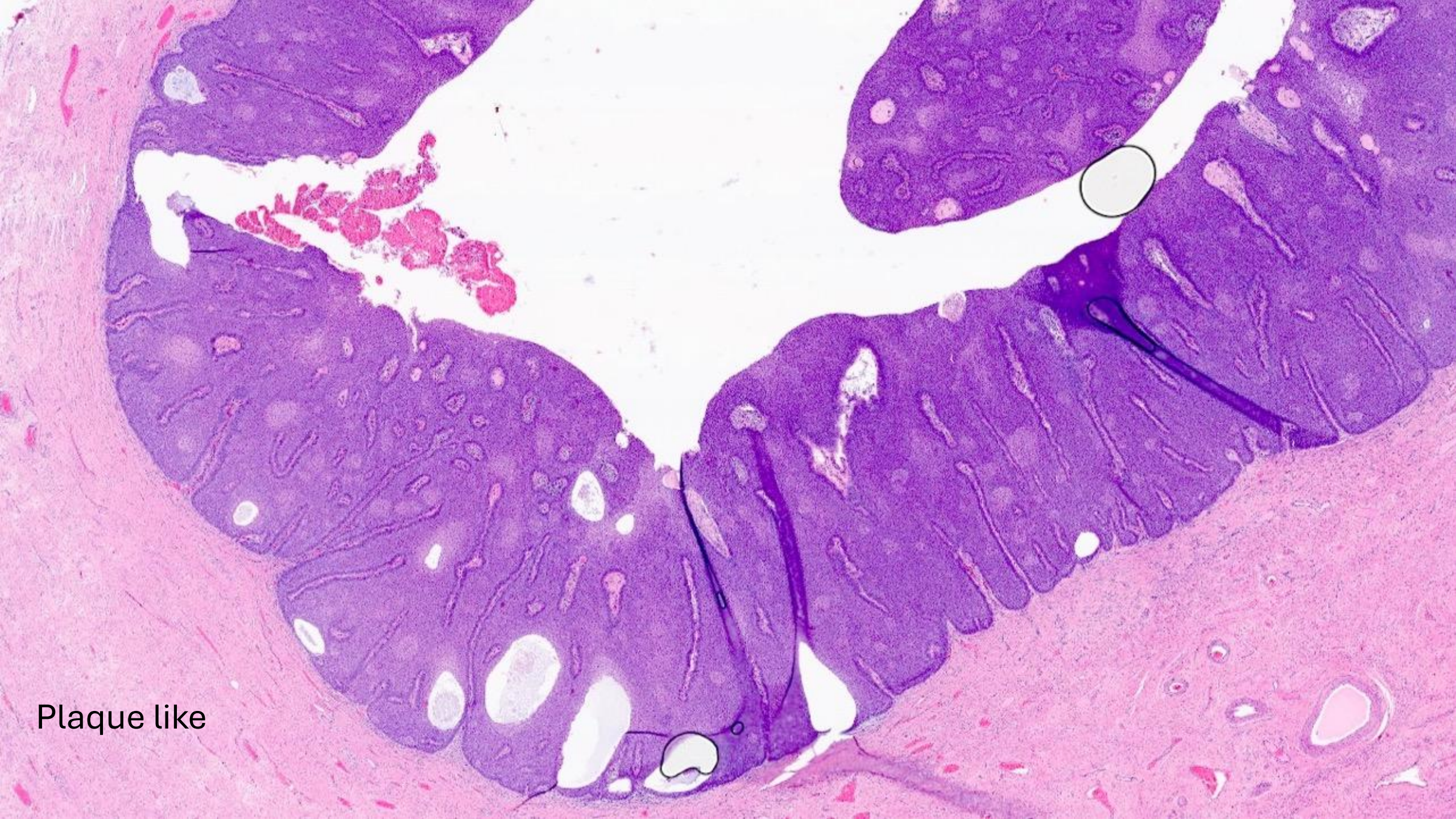
Plaque like

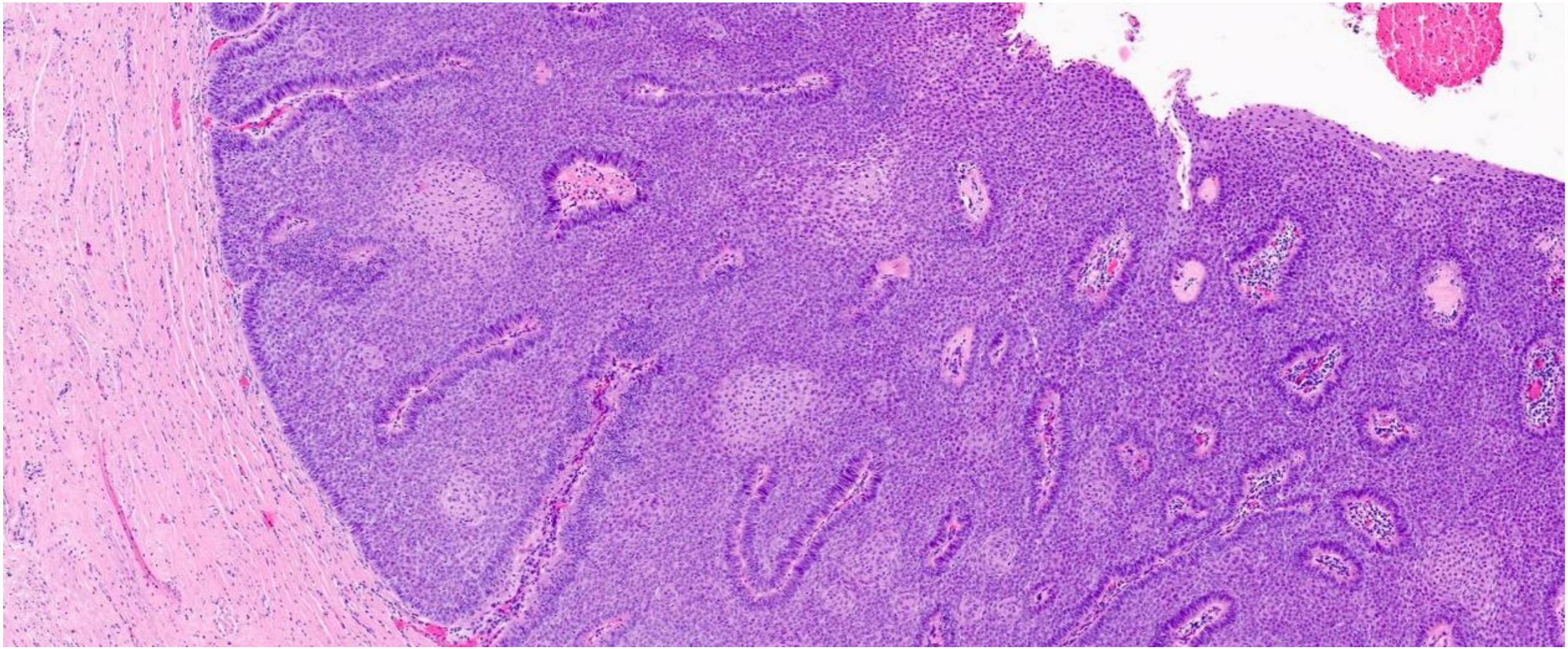

Basaloid cells, basal palisading, squamous eddies

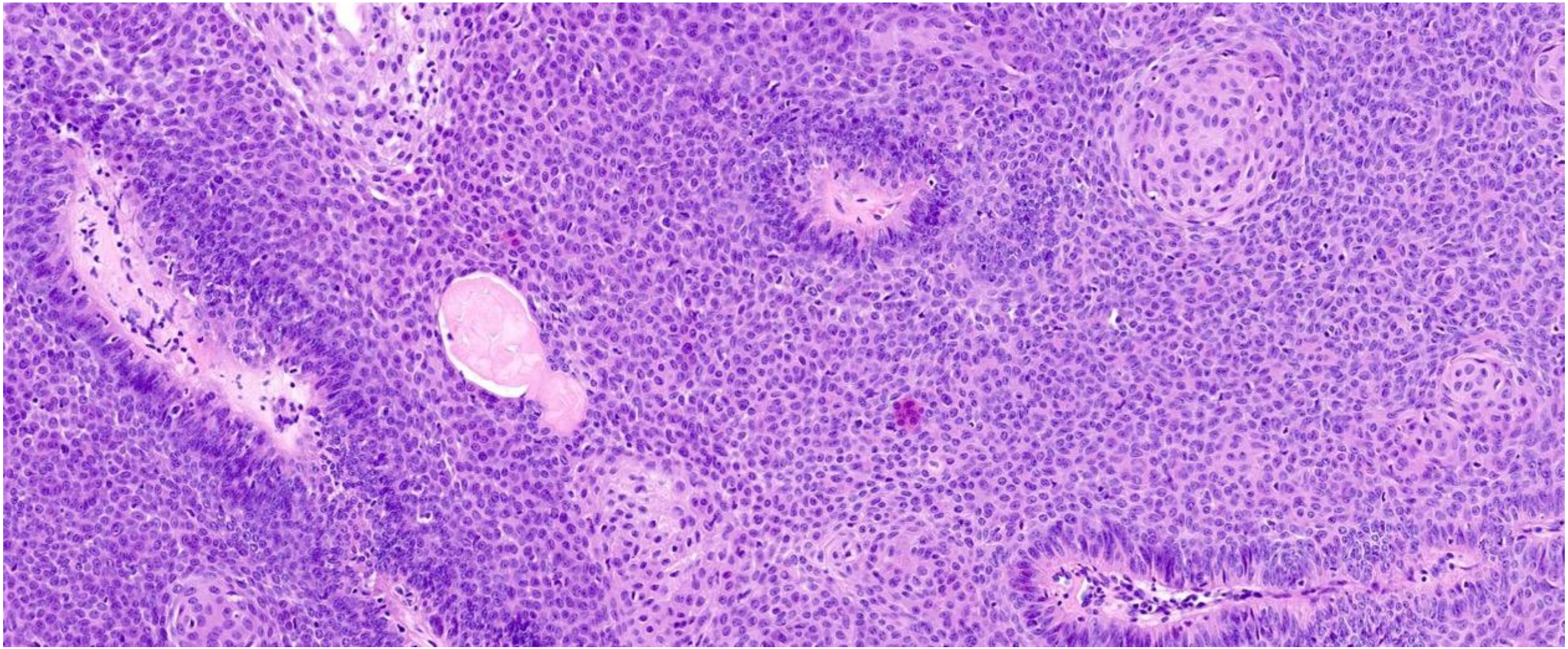

Cellular streaming, hyalinised stroma, eddies

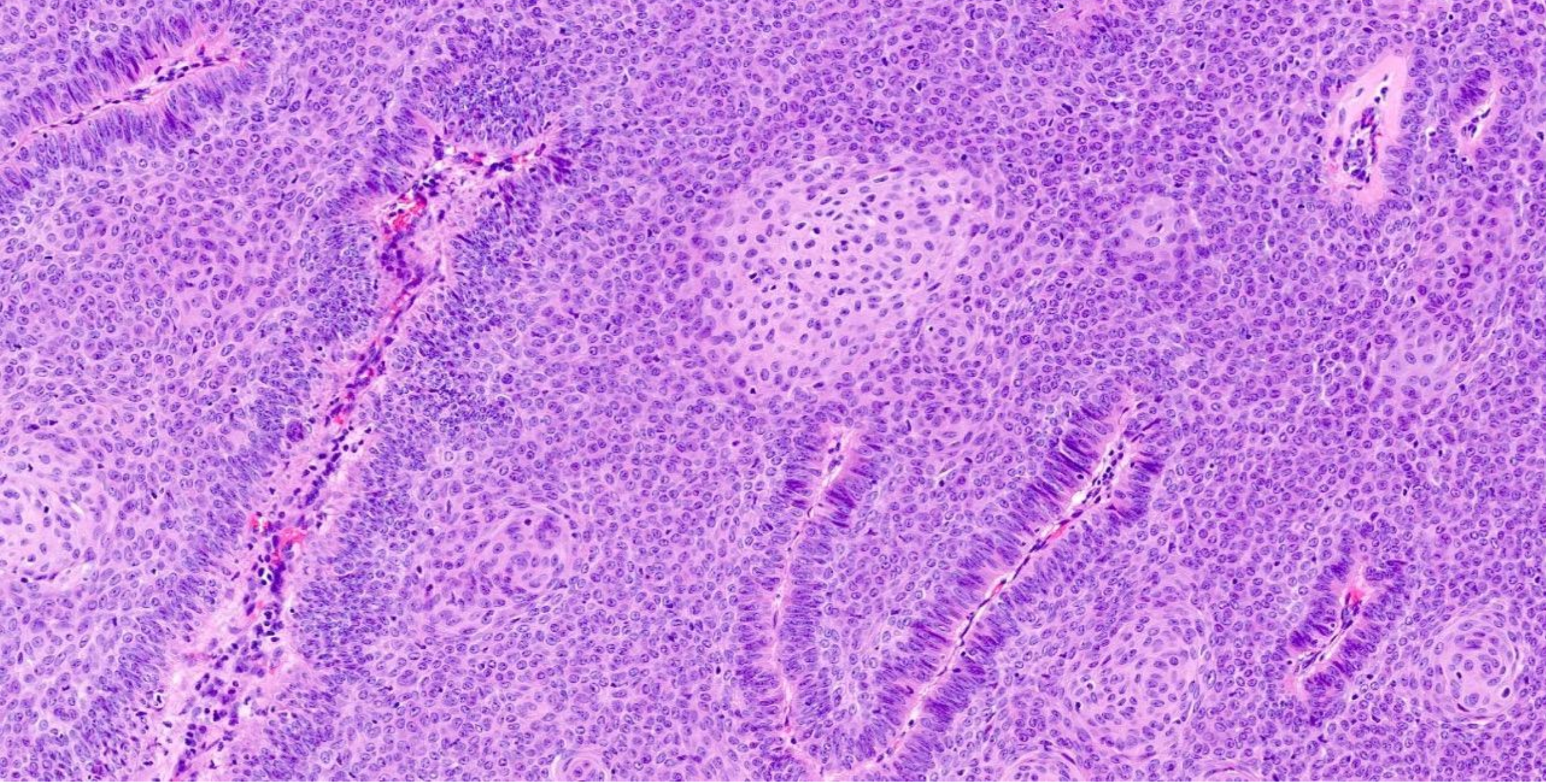

Uniform ovoid nuclei, basaloid appearance

p16

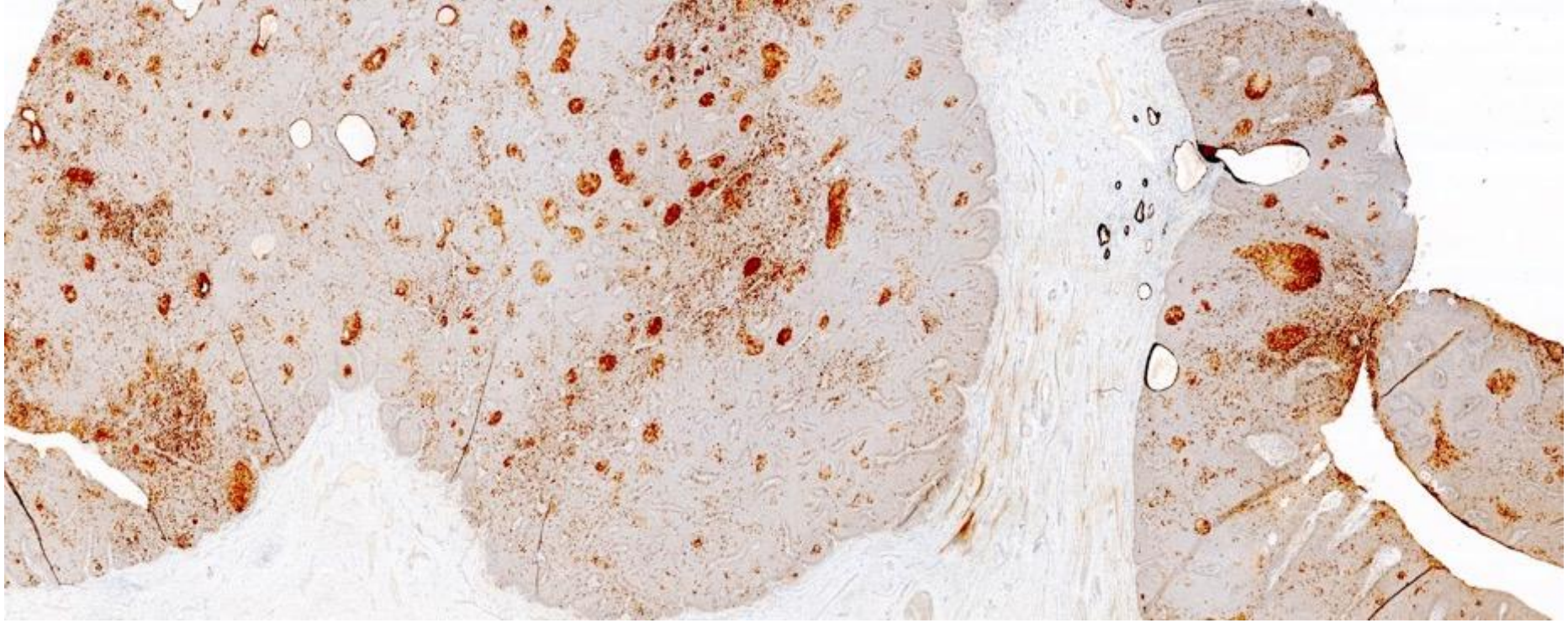

p16

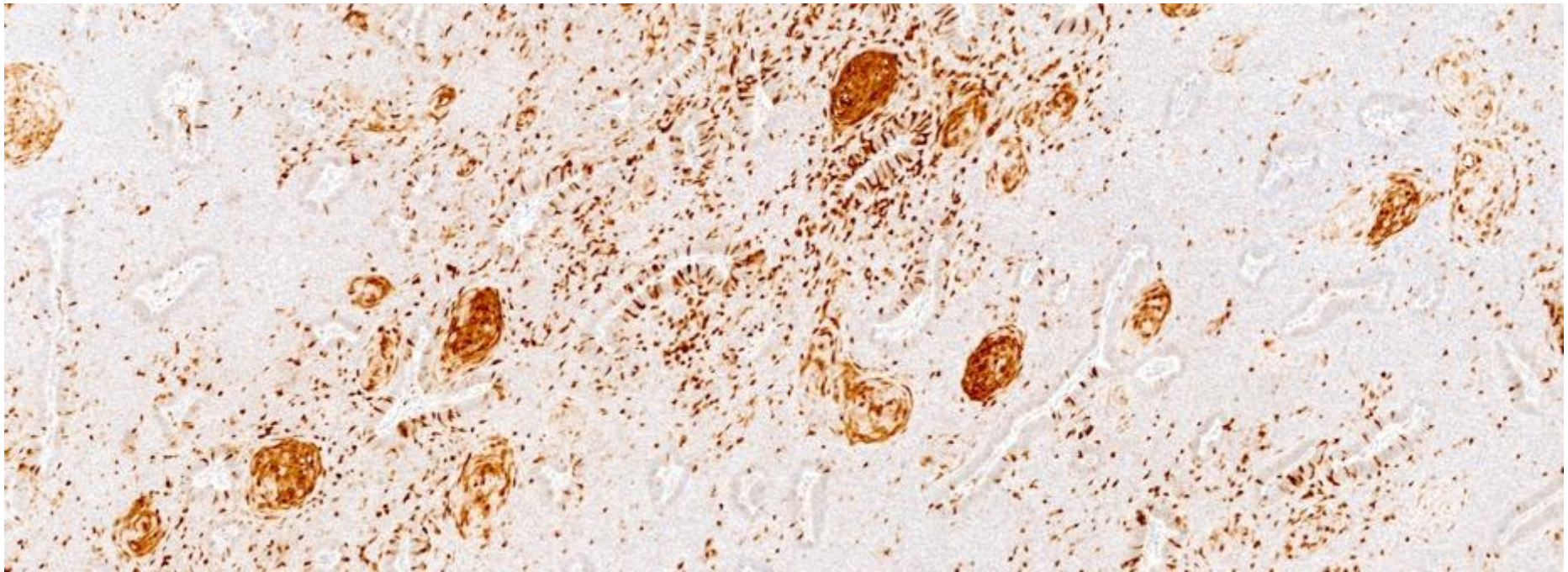

HPV typing:
HPV42
detected

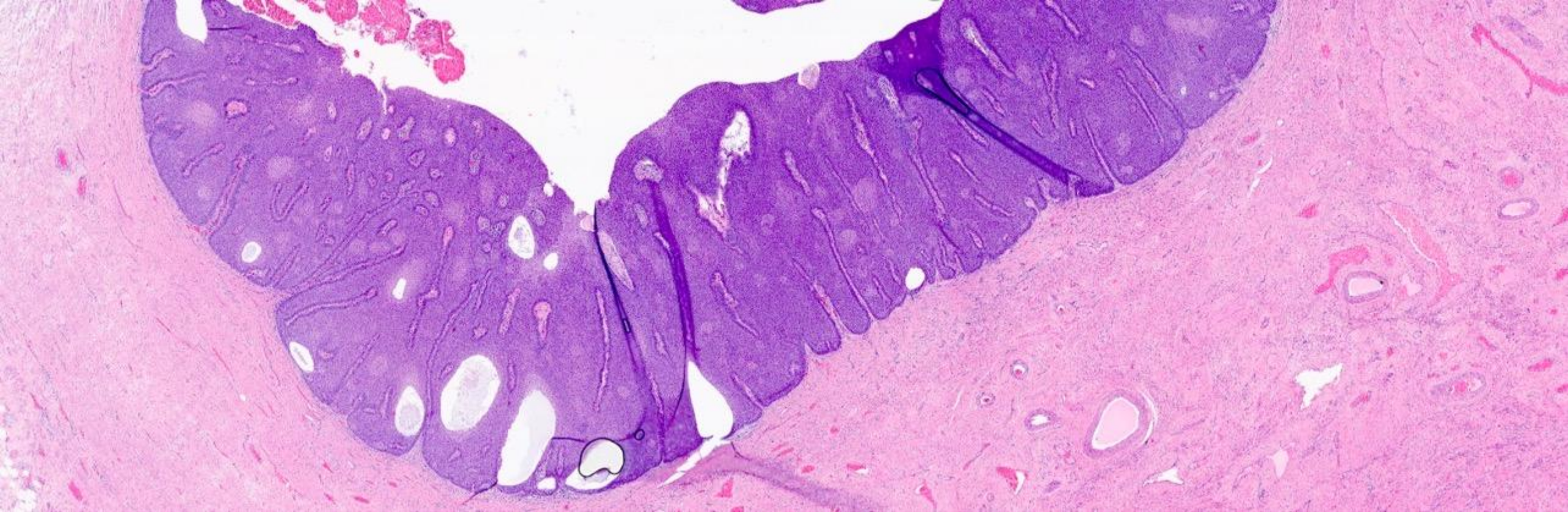

# Seborrheic-keratosis like lesion

- Extremely uncommon; 18 cases (17 reported)
- Cervix and vagina. Unique morphology
- Resembles cutaneous seborrheic keratosis
- Plaque-like / stuck on, well demarcated edge
- Lacks koilocytosis
- HPV42 (**LRHPV**) detected in most cases: 14 of 18

WHO 6

*AJSP 2017, AJSP 2025, IJGP 2022, Acta Cytol 2021*

# Clinical

- Mean age 60.9 years (**33 – 83**)
- Clinically: PV bleeding, **suspicious cervical lesion; polypoid, friable, readily removed/ exfoliated on biopsy**
- Mean size 2 cm (range 10 - 31 mm)

10 cases with follow-up (mean 26.8 months):

- **2 cases of local recurrence**
- No malignant transformation reported

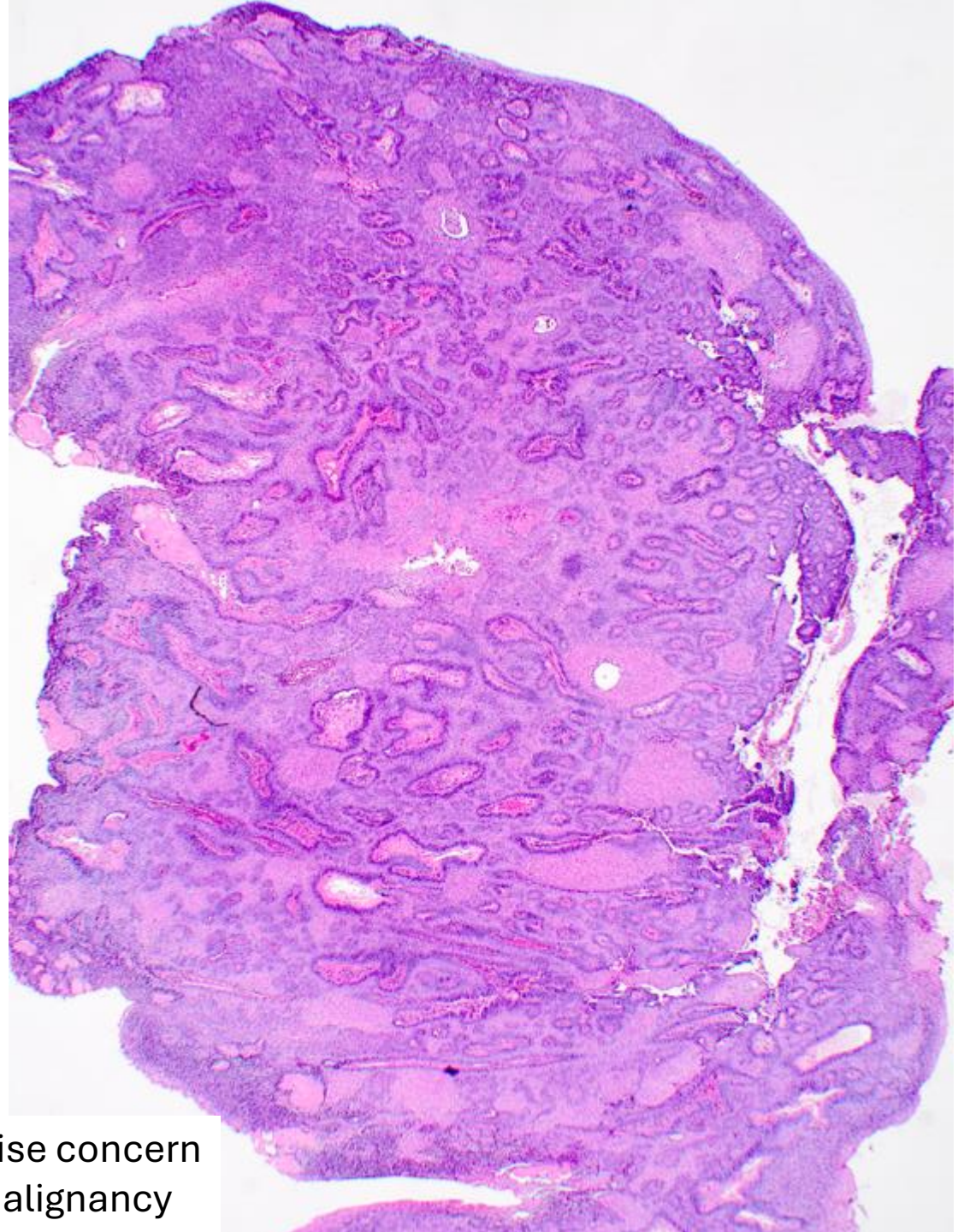

May raise concern for malignancy

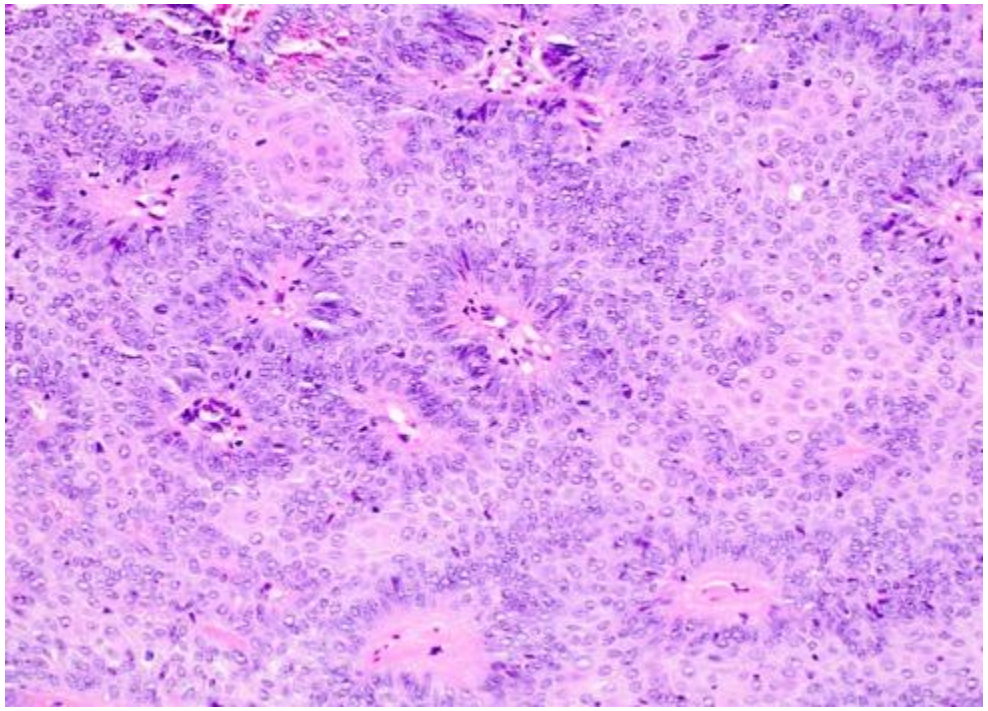

Palisading

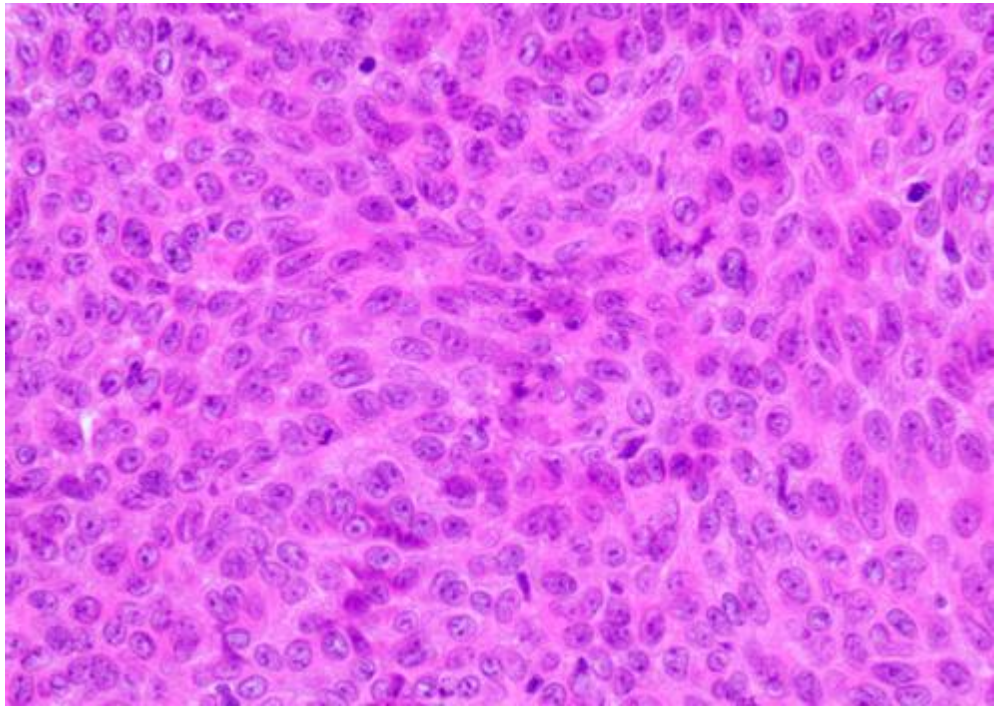

Bland basaloid cells

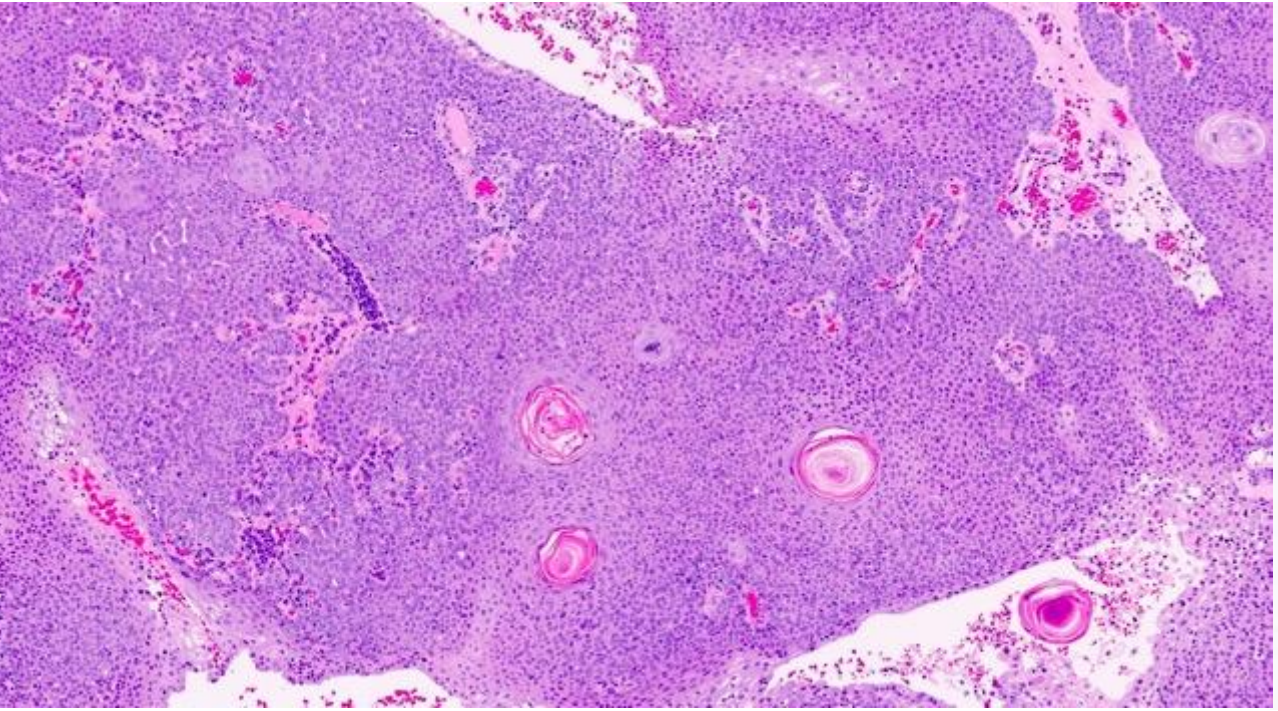

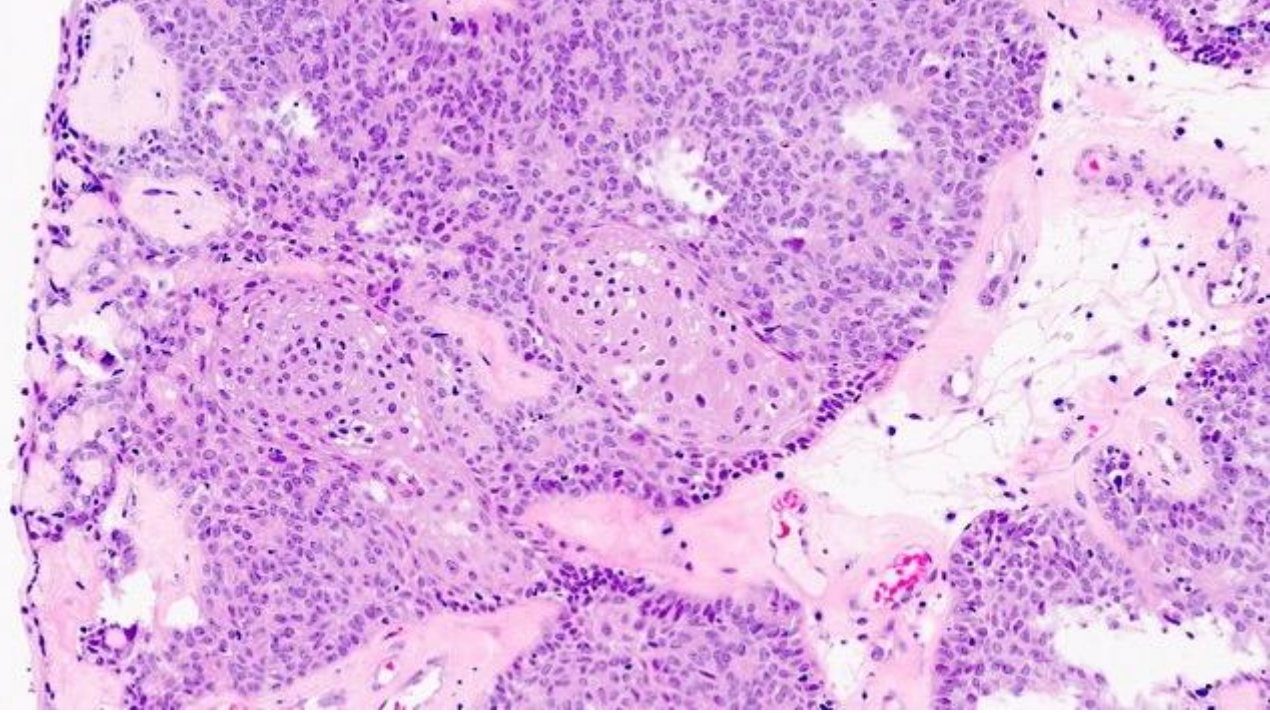



Hyalinisation, occasional “horn cysts”

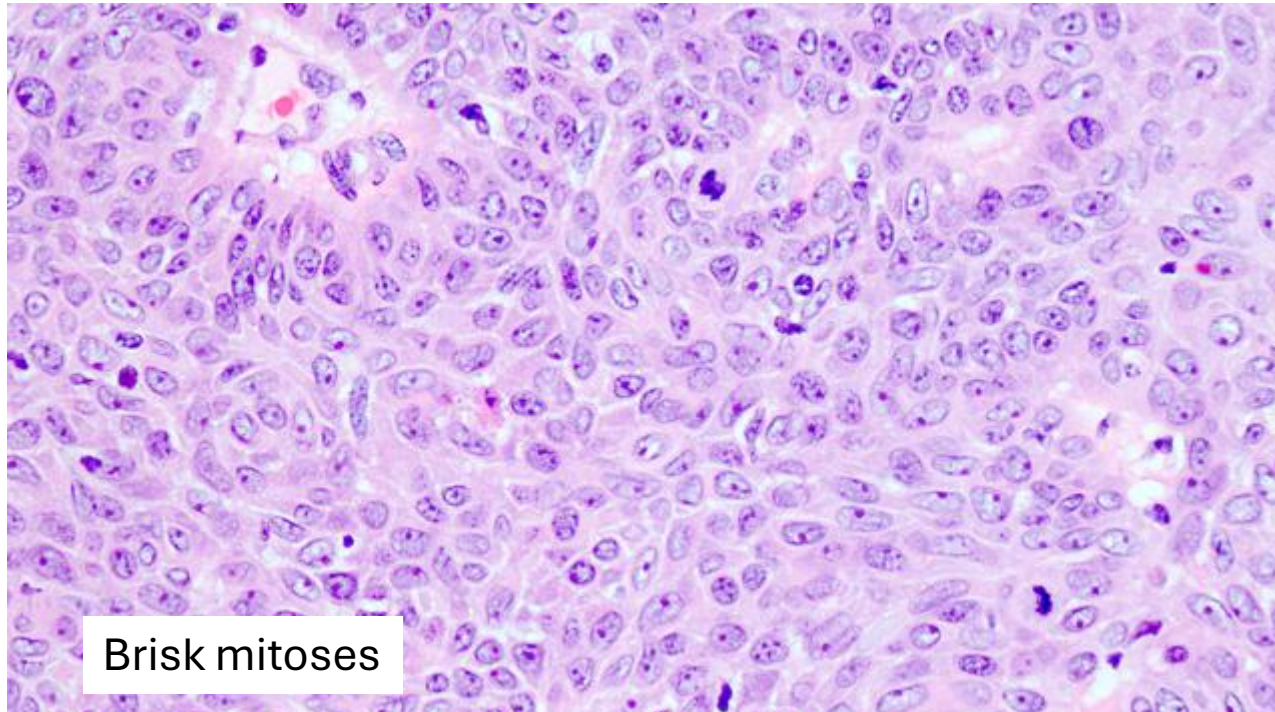

Brisk mitoses

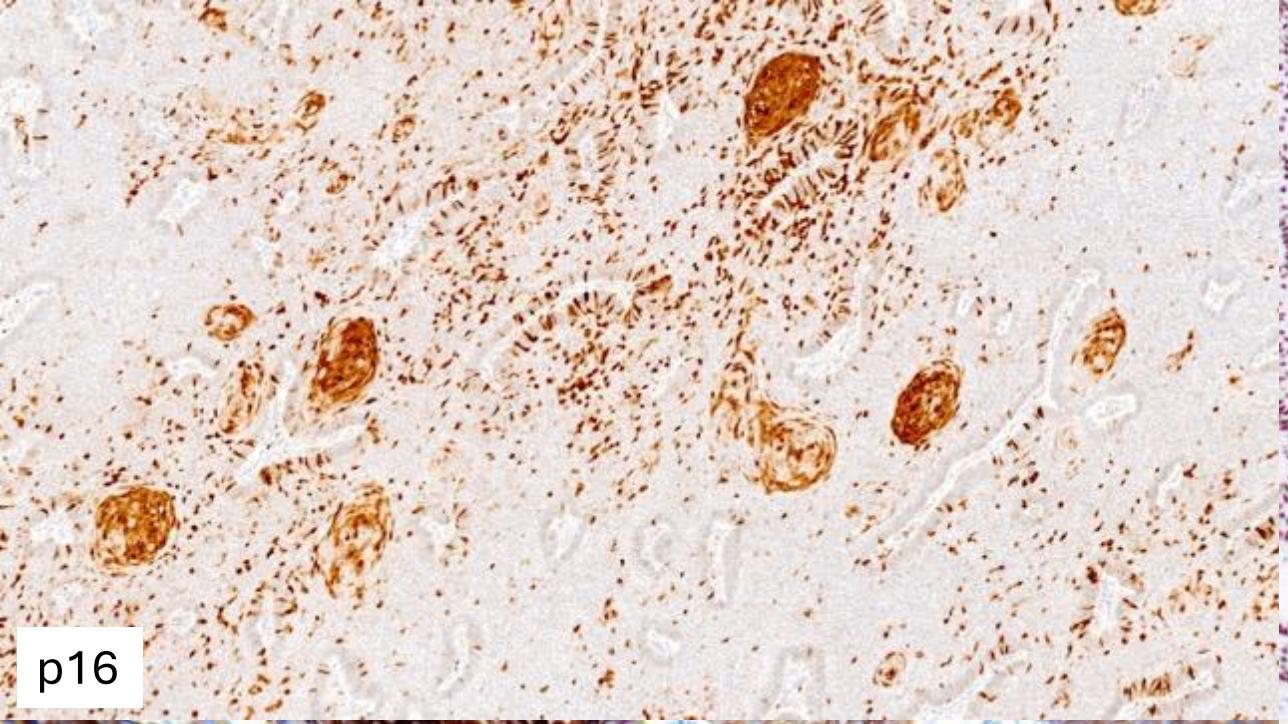
p16

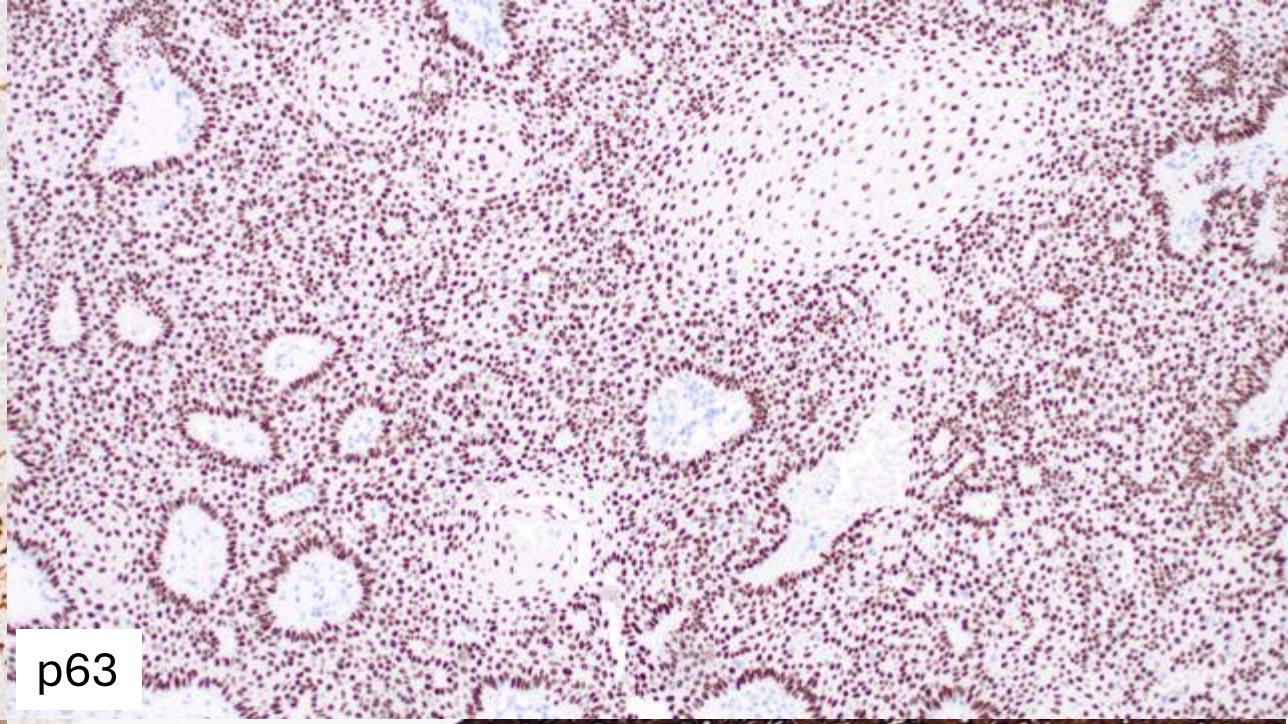
p63

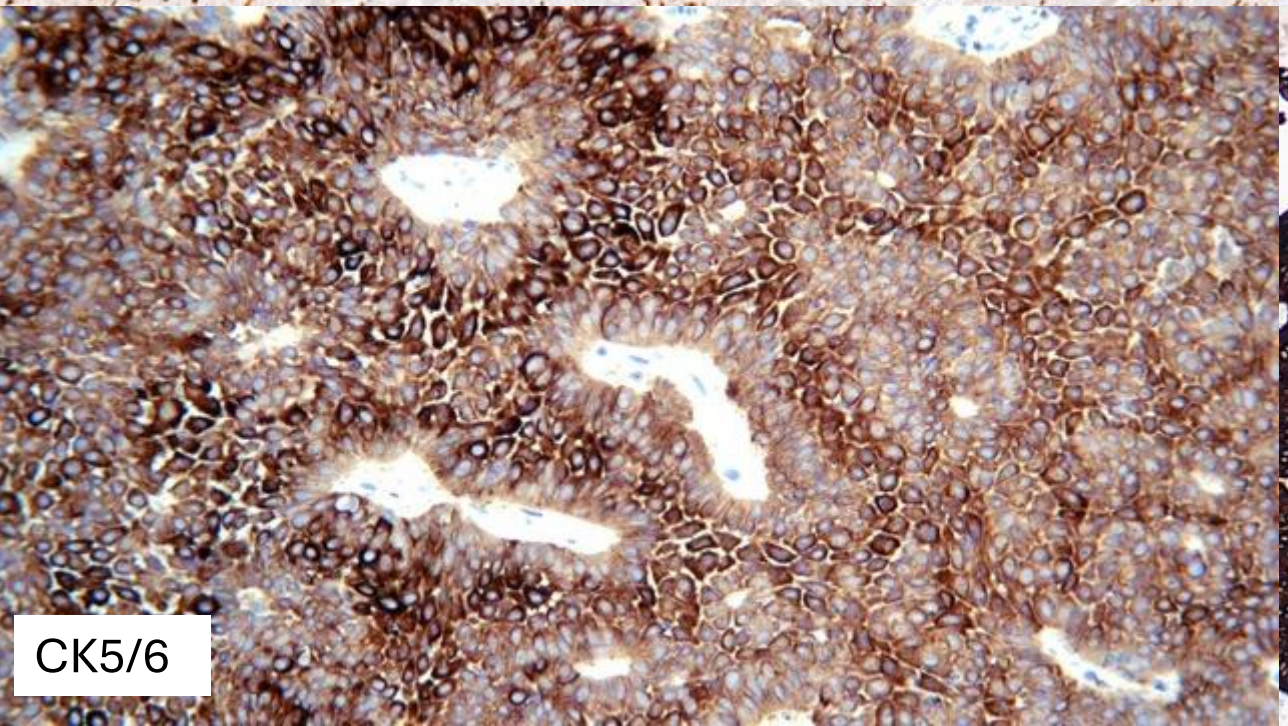
CK5/6

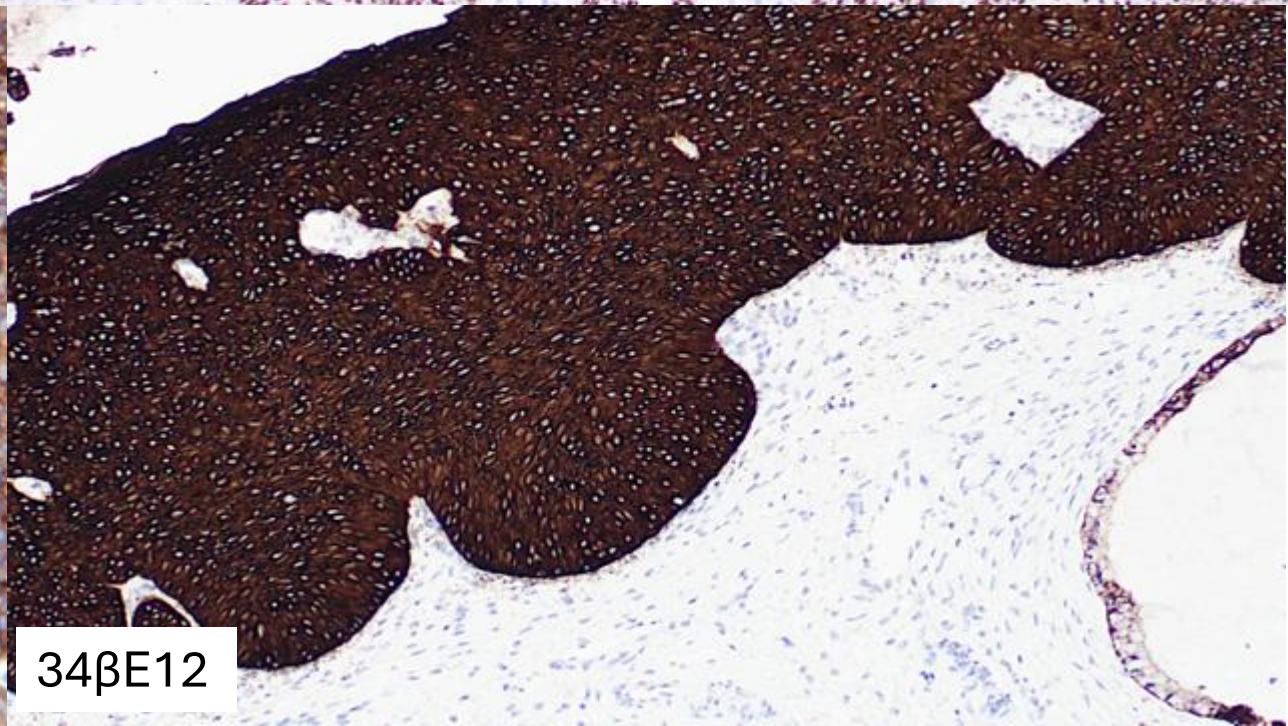
34βE12

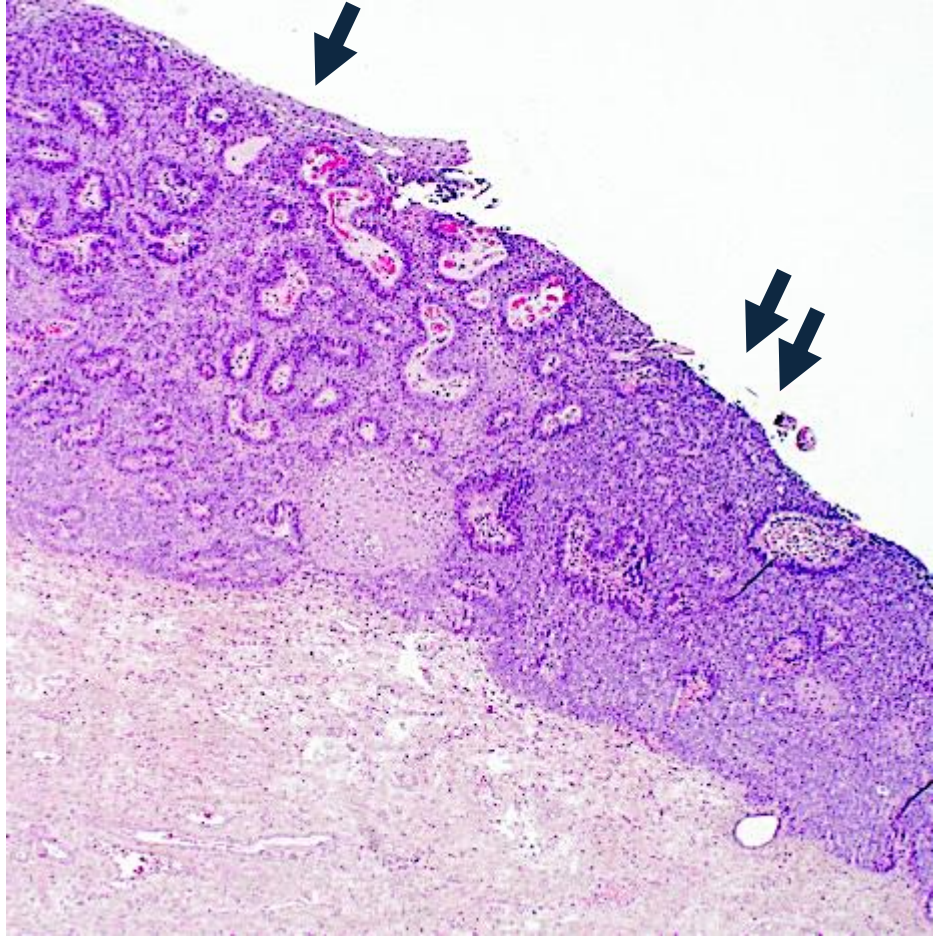

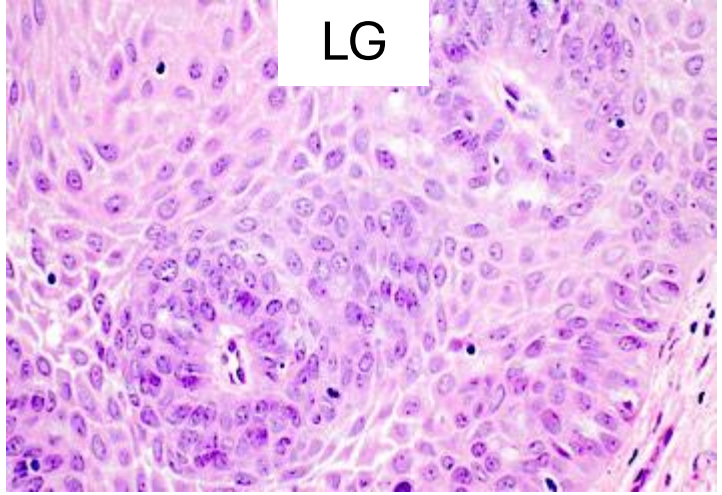
LG

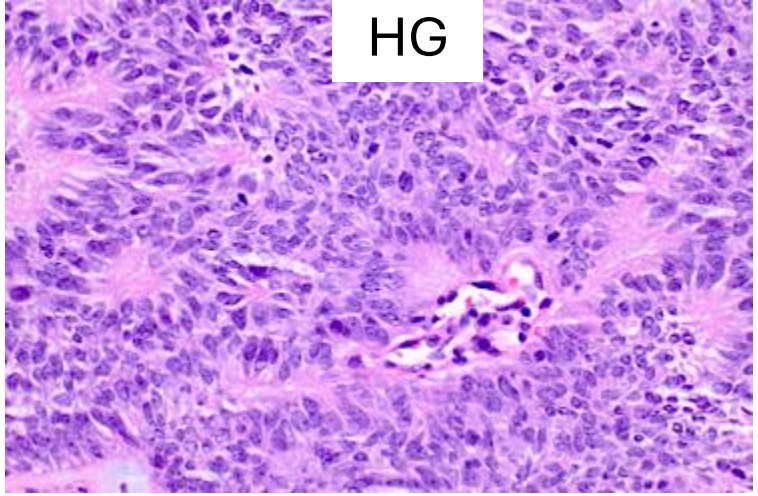
HG

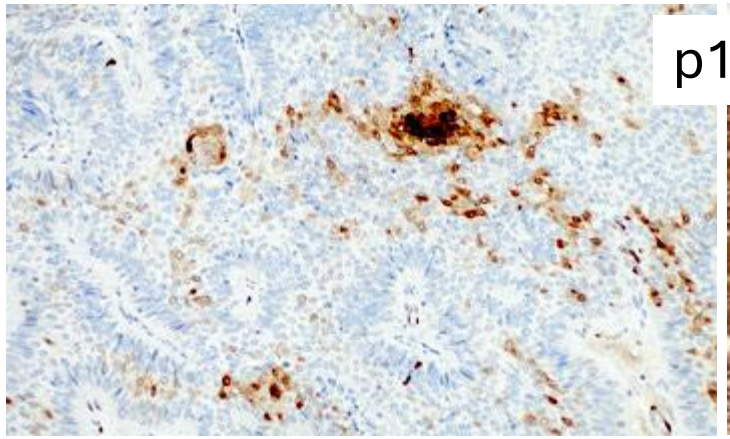
p16

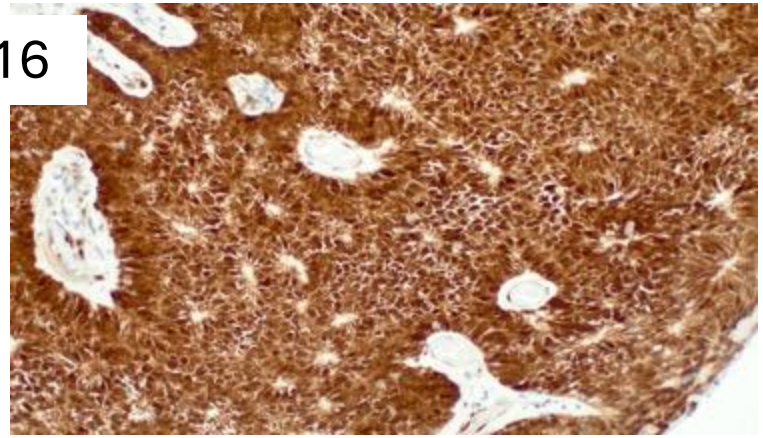

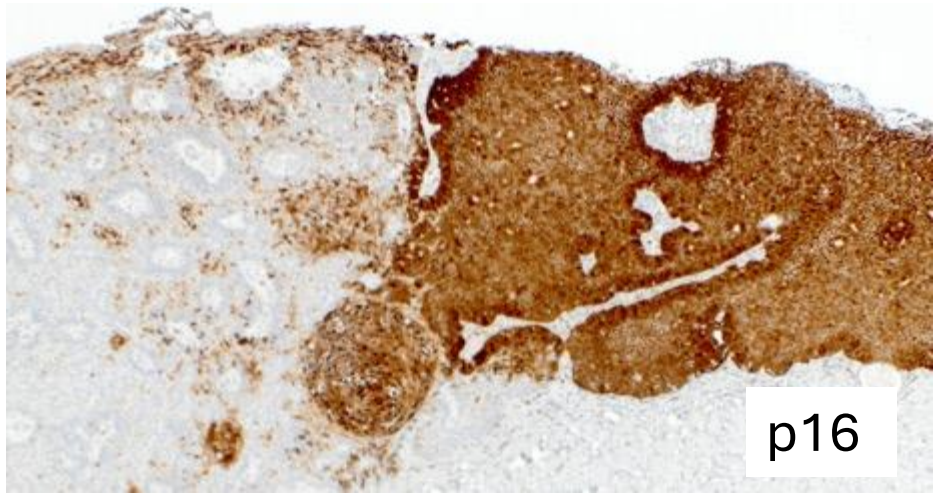
p16

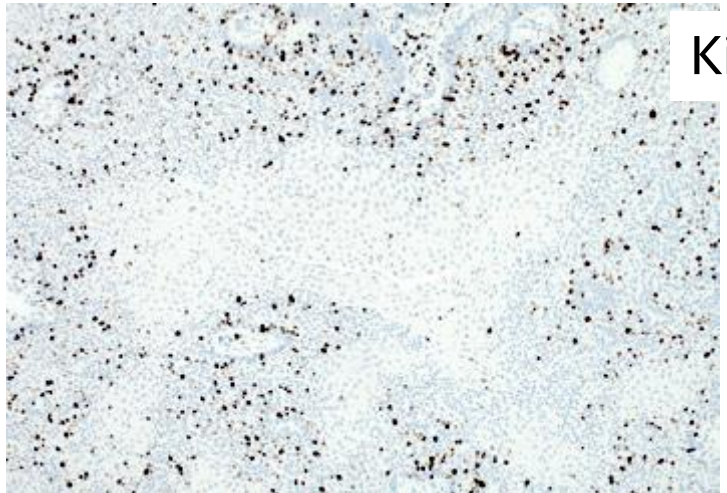
Ki67

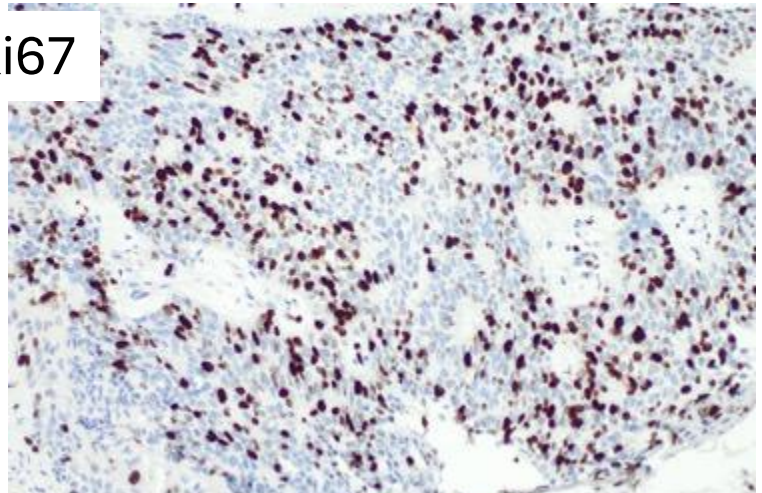

HPV42

*A Common Low-Risk HPV Type Associated With Distinctive Cervicovaginal and Cutaneous Neoplasia*

*Karen L. Talia,* David Hawkes, PhD,†‡§ Gloria Zhang, MD,‖ Jackie Jamison, DRCPath,¶ Jennifer Shanks, MSc,¶ Bin Yang, MD, PhD,‖ Robert Soslow, MD,‖ and W. Glenn McCluggage#*

# Observations, questions

**HPV42 associated morphologically distinct lesion**

→Unique HPV genotype – phenotype association

**Occasional high-grade, p16 block-type lesions associated with a LRHPV**

→Reconsider the oncogenic potential of HPV42?

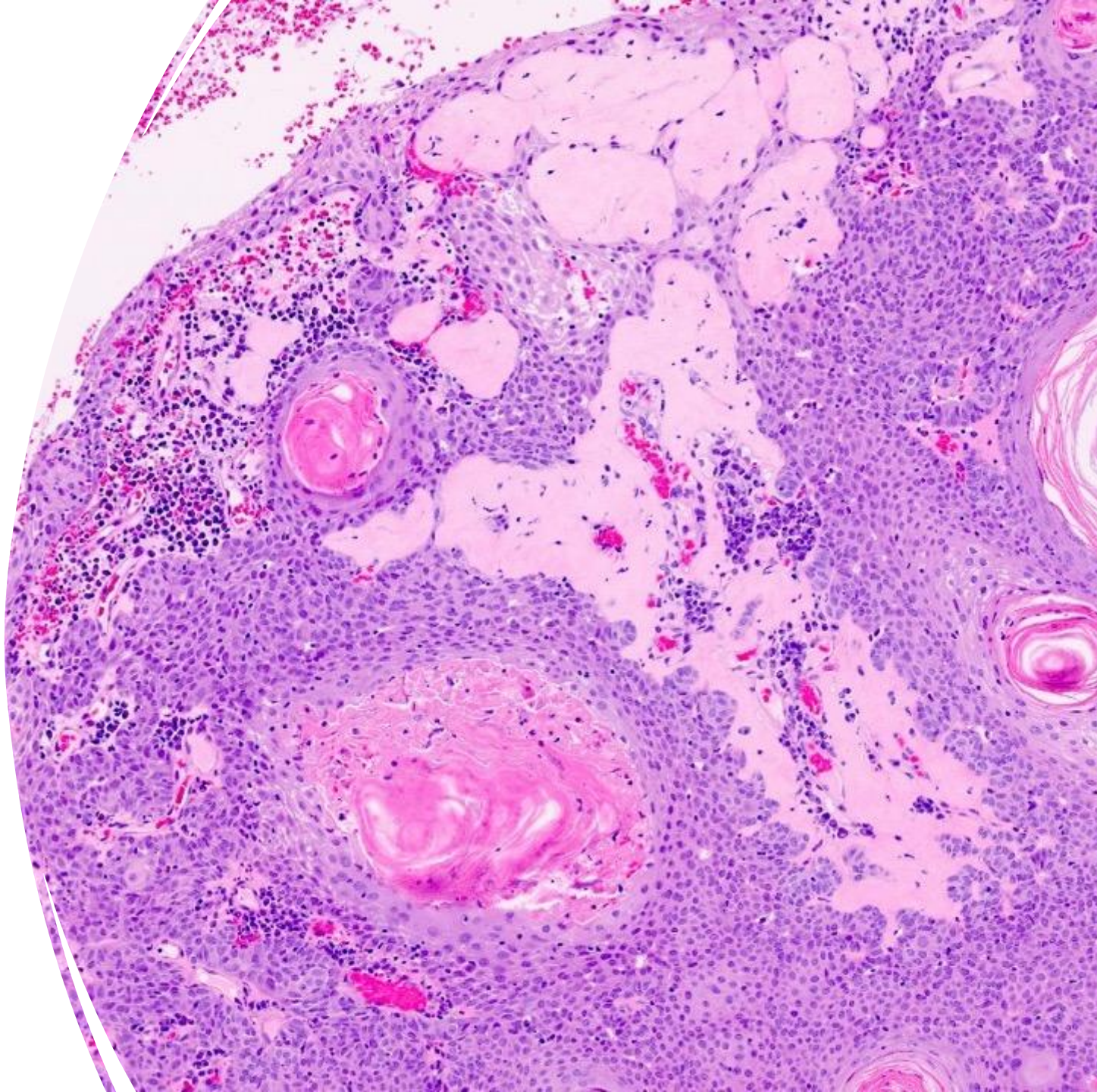

# Most cervicovaginal cancer HPV associated

# 12 HPV types cause almost all HPVA disease

**IARC classification:** % of cancer caused by that HPV type (attributable fraction)

## "Carcinogenic" HPV

(aka HRHPV)

**Group 1:**
Carcinogenic to humans
Dominated by HPV16,18

**Group 2a, 2b:**
Probably, possibly carcinogenic
Low prevalence in cx cancer

*WHO Target product profiles for HPV screening tests*

| | |
|---|---|
| **Group 1a:** | HPV16 is singularly carcinogenic and causes about 60% of cases of squamous cell carcinoma (SCC). |
| **Group 1b:** | HPV18 and HPV45 cause 15% and 5% of SCC cases, respectively. |
| **Group 1c:** | Other closely related HPV types – HPV31, HPV33, HPV35, HPV52 and HPV58 – together account for 15% of SCC cases. |
| **Group 1d:** | The remaining carcinogenic types – HPV39, HPV51, HPV56 and HPV59 – are much less carcinogenic and together cause about 5% of SCC cases. |

**Non carcinogenic:** LRHPV; eg HPV6 (most prevalent pre-vaccine) *Walboomers J Pathol* 1999

**LRHPV** is episomal
Transient productive infection, produce and release virus
No deregulated E6/E7 gene expression
**LSIL**

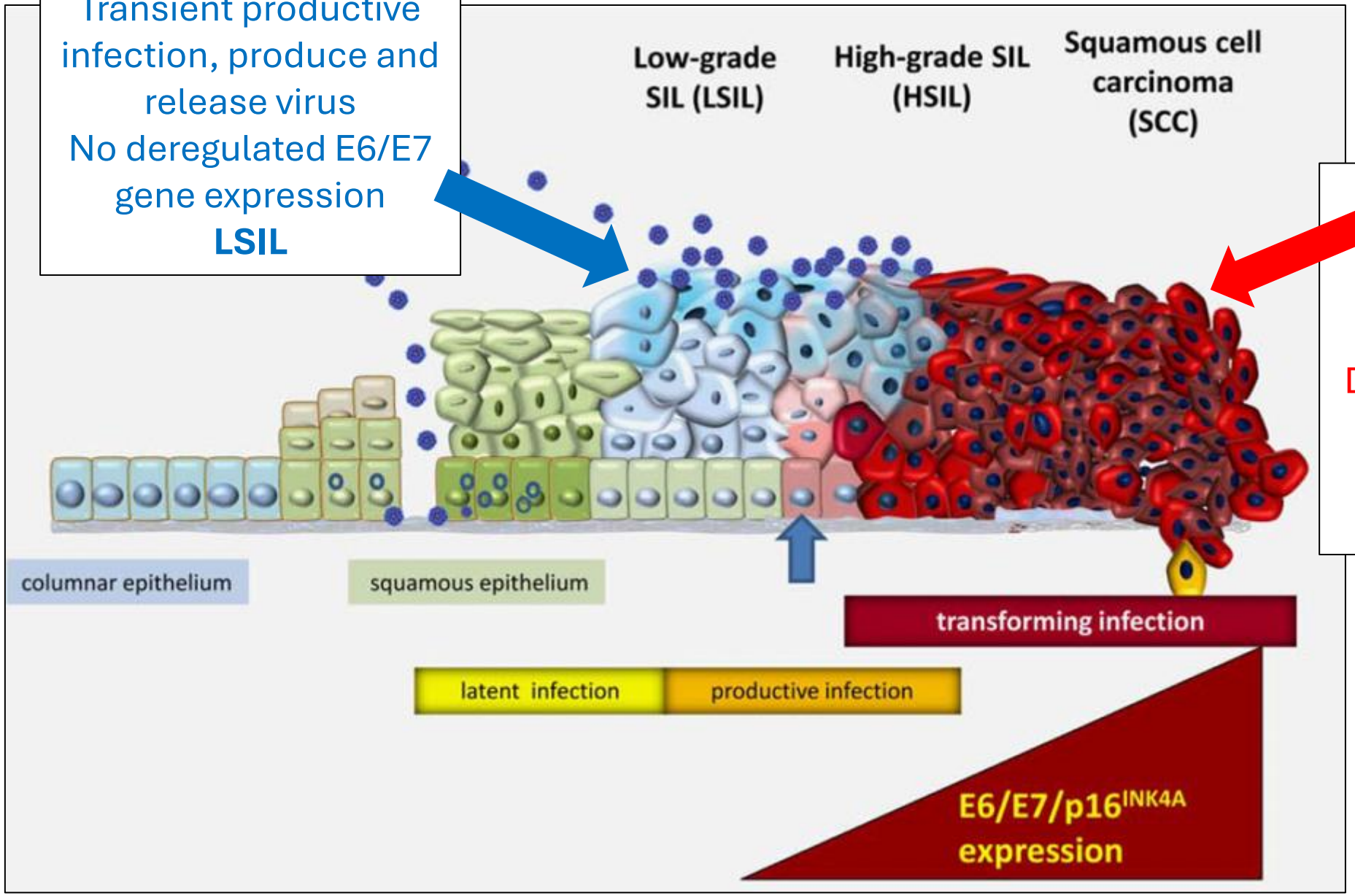


Persistent **HRHPV**
Viral integration
Viral E6/E7 gene expression
Disrupt cell cycle control (deregulate p53, pRb)
Transforming infection
**HSIL, SCC**

*Bergeron et al Int J Cancer 2014*

# HPV42

**Isolated from vulval papillomas**; phylogenetically **similar to HPV6**

**Prevalence varies geographically**; higher in Africa, HIV positive men, Polish, German and Australian women; 2nd most prevalent overall and **most prevalent LRHPV in Australian women aged 16-24***

- Rare vulval seborrheic keratoses, vulvovaginal condyloma
- 1 vaginal HSIL, extremely rare HPV42-associated anogenital SCC

**Highly prevalent but only rare reported disease manifestations**

*Cancer Control 2022, Journal of Medical Virology 2010, BMC Infect Dis 2019, *Vaccine 2020, Histol Histopathol 2021, AJSP 2007, Am J Surg Pathol 2013, The Lancet Oncology 2010*

**Defining Novel DNA Virus-Tumor Associations and Genomic Correlates Using Prospective Clinical Tumor/Normal Matched Sequencing Data** *J Molec Diagn 2022*

Chad M. Vanderbilt,* Anita S. Bowman,* Sumit Middha,* Kseniya Petrova-Drus,* Yi-Wei Tang,* Xin Chen,† Youxiang Wang,† Jason Chang,* Natasha Rekhtman,* Klaus J. Busam,* Sounak Gupta,*‡ Meera Hameed,* Maria E. Arcila,* Marc Ladanyi,* Michael F. Berger,* Snjezana Dogan,* and Ahmet Zehir*

ARTICLE

**Association of HPV42 with digital papillary adenocarcinoma and the use of in situ hybridization for its distinction from acral hidradenoma and diagnosis at non-acral sites** *Mod Path 2022*

Chad Vanderbilt[1], Thomas Brenn[2], Andrea P. Moy[1], Gordon Harloe[3], Charlotte Ariyan[4], Edward Athanasian[4] and Klaus J. Busam[1,5]

*AJSP 2023*

**Digital Papillary Adenocarcinoma in Nonacral Skin**
*Clinicopathologic and Genetic Characterization of 5 Cases*

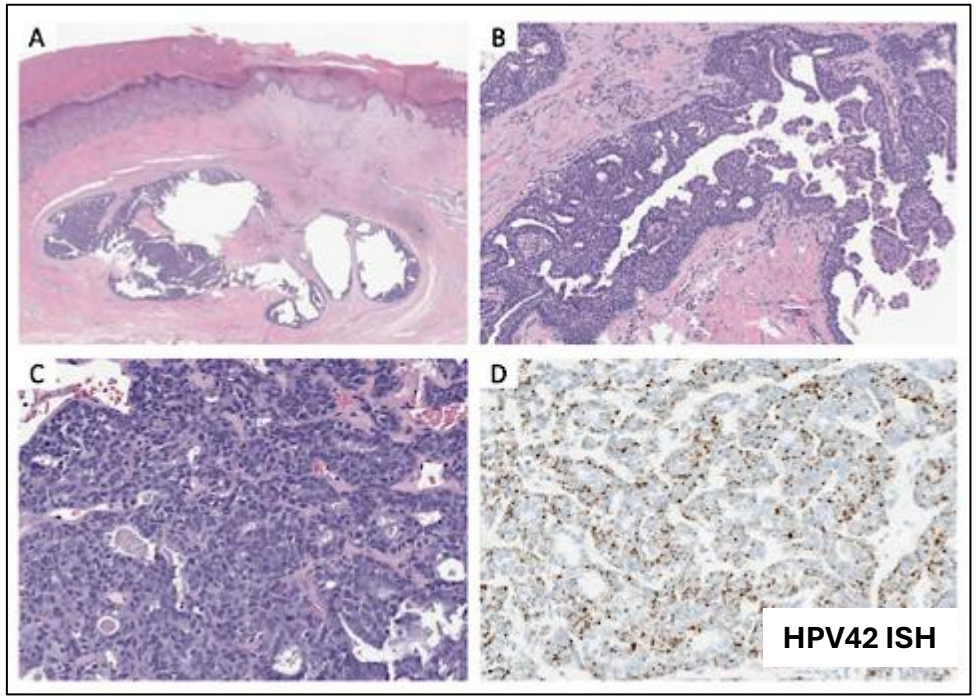


*Vanderbilt Mod Path 2022*

# HPV 42 and Digital Papillary Adenocarcinoma (DPA)

Recent aetiological link:

HPV42 as a cause of DPA - rare aggressive malignant sweat gland tumour, fingers/toes

Genomic study, 48000 solid tumours, investigating DNA virus-cancer associations

**HPV42 in all 4 cases of DPA**

Follow-up studies:

- 10 DPA HPV42 ISH+; 2 in **scrotal skin**
- 45 of 47 DPA tested HPV42+ *Cancer Discov* 2023
- 5 non-acral DPA, 4 female **anogenital skin**

# ?Oncogenic potential of HPV42

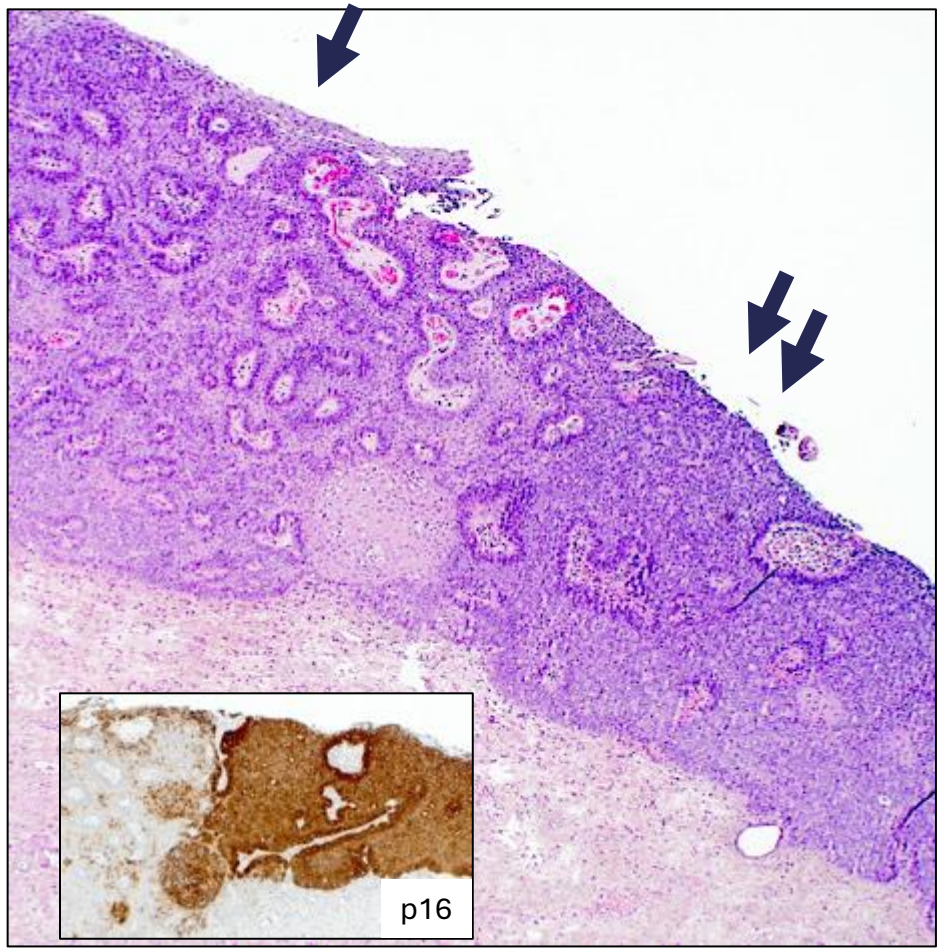


SKLL with HG/p16 block positive component

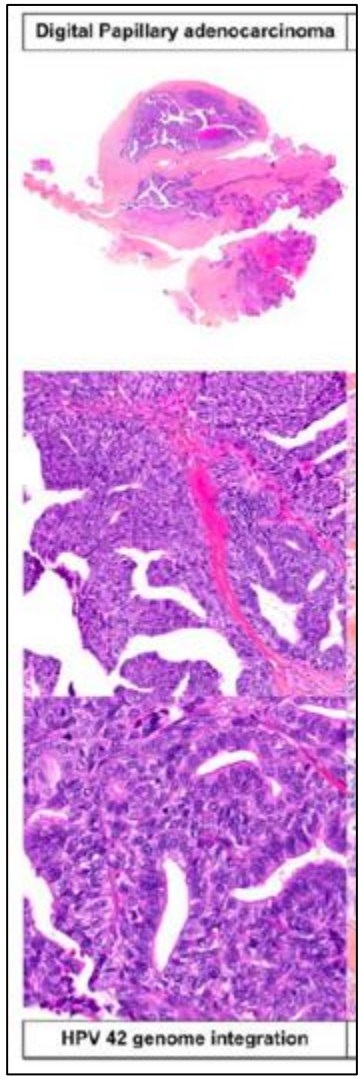


The Occasional Role of Low-risk Human Papillomaviruses 6, 11, 42, 44, and 70 in Anogenital Carcinoma Defined by Laser Capture Microdissection/PCR Methodology

*Results From a Global Study* *AJSP 2013*

*Núria Guimerà, BSc,*† Belén Lloveras, MD, PhD,*‡ Jan Lindeman, MD, PhD,†*

Limited evidence (DPA studies, experimental *in vitro* data):
**HPV42 can integrate into host genome and initiate transforming infection, hallmark of carcinogenic HPV** – offers some explanation for these findings

Relatively high prevalence + very rare associated malignancy → **most often non-carcinogenic in the lower FGT**

*AJSP 2013, AJSP 2023, Cancer Discov 2023*

# Glandular lesions

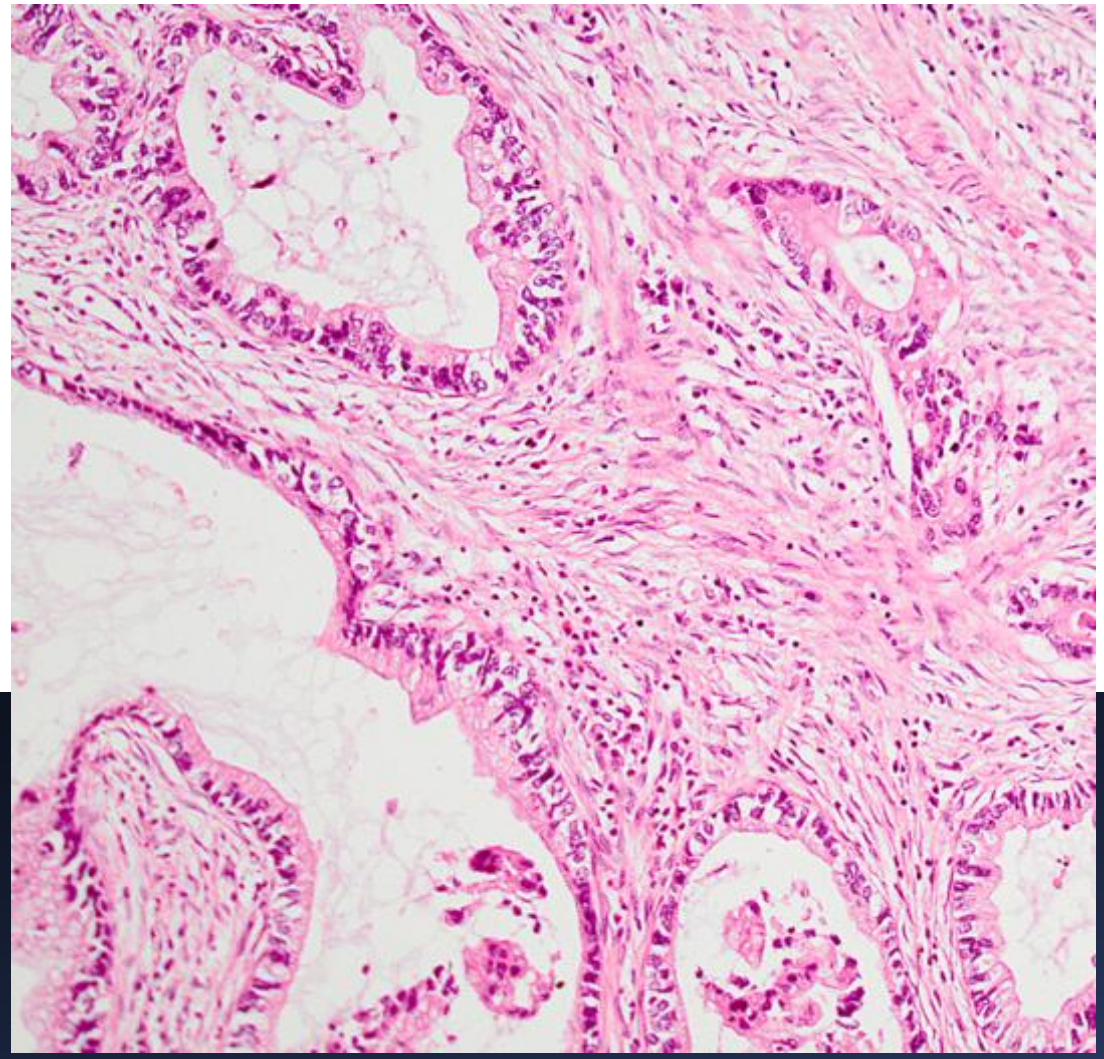

# Normal vaginal histology

Non-keratinising squamous epithelium

Wall composed of fibromuscular tissue

## NO GLANDS

Require a glandular precursor

- embryological remnant - cloacal remnant
- surface epithelial metaplasia
- adenosis, endometriosis, endocervicosis
- extension via a rectovaginal fistula

*Source: slideshare.net*

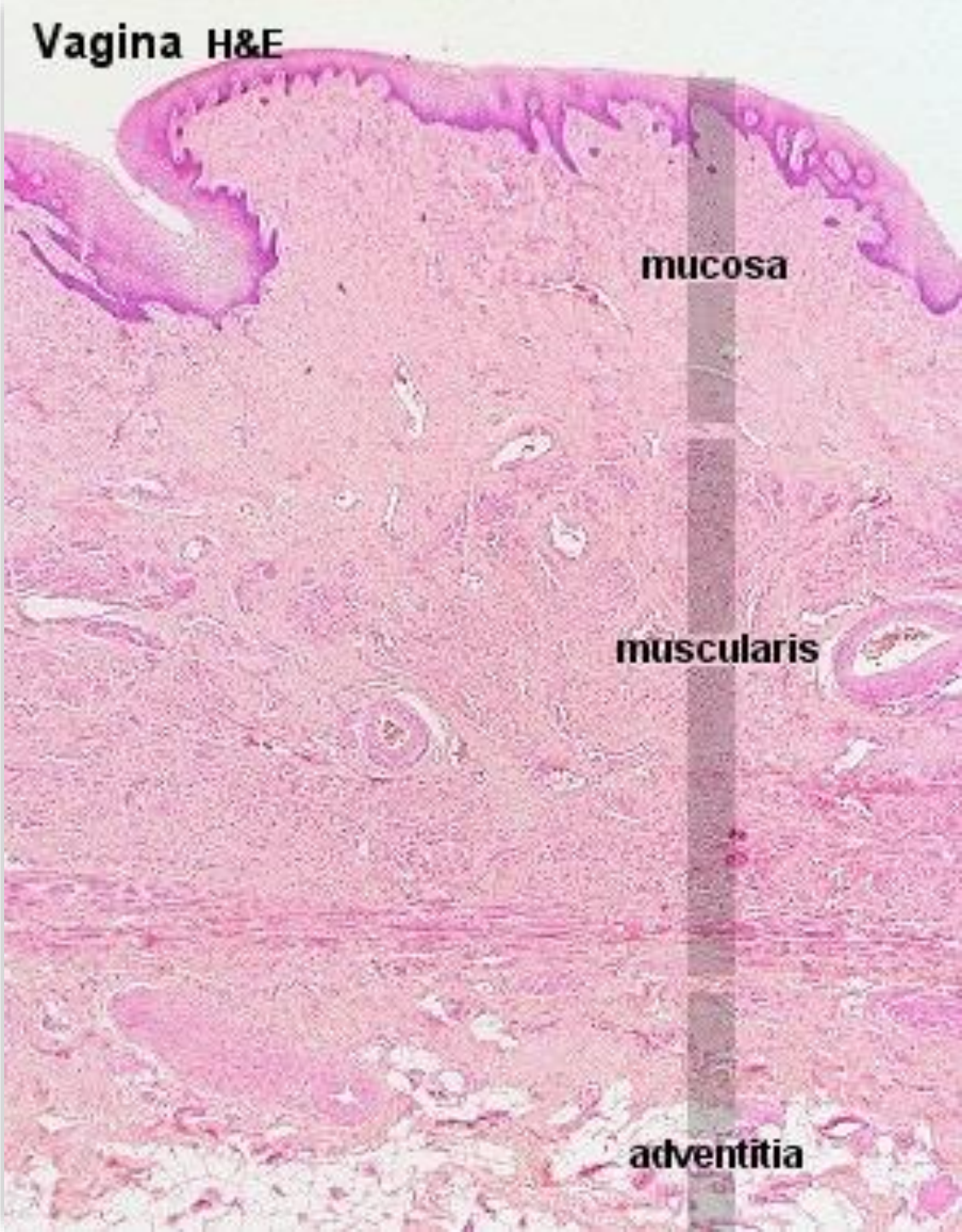

# WHO 5 – 1° vaginal glandular lesions

| BENIGN | MALIGNANT |
| --- | --- |
| Villous adenoma<br>Mullerian papilloma<br>Adenosis<br>Endocervicosis<br>Cysts | HPV-associated adenocarcinoma<br>HPV-independent adenocarcinoma<br>• Endometrioid endometriosis<br>• Clear cell carcinoma<br>• Mucinous carcinoma, gastric type<br>• Mucinous carcinoma, intestinal type<br>• Mesonephric adenocarcinoma<br>• Carcinosarcoma<br>• Mixed tumour<br>• Adenocarcinoma of Skene's origin |
| | Secondary carcinoma |

# Case 2

35 y.o. Prior LLETZ for CIN 3

Red area posterior vagina: Biopsy

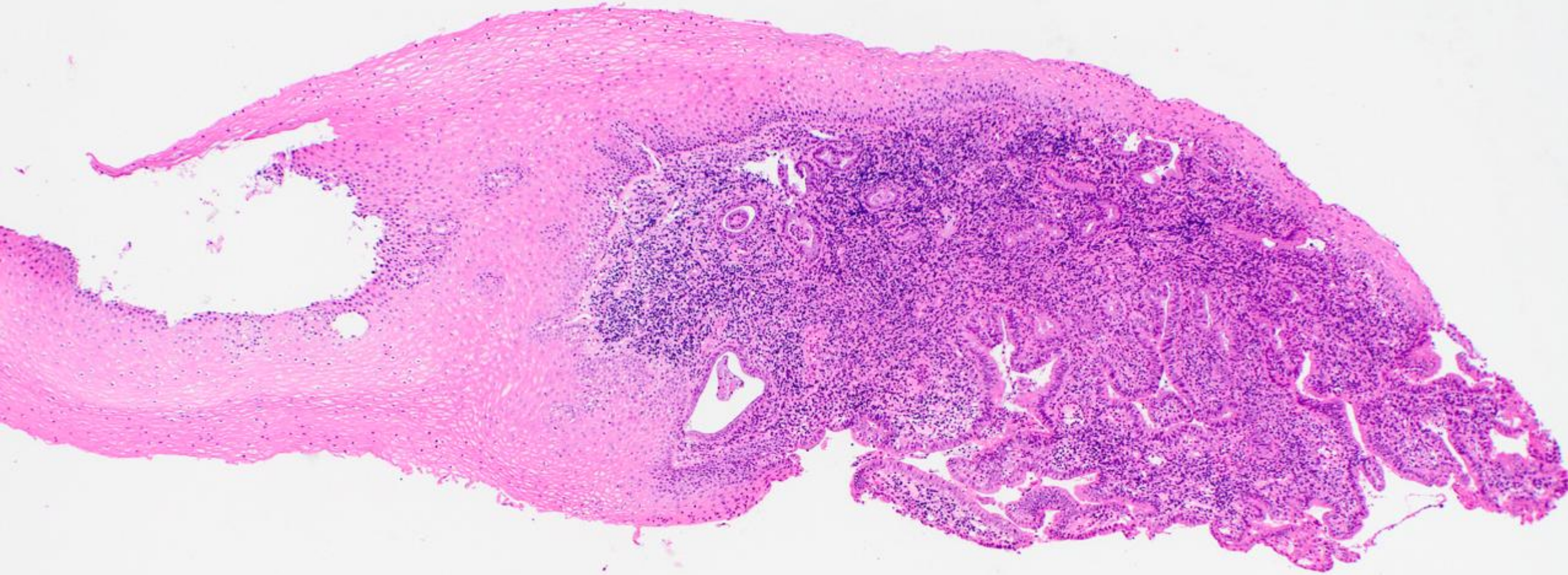

Vaginal biopsy

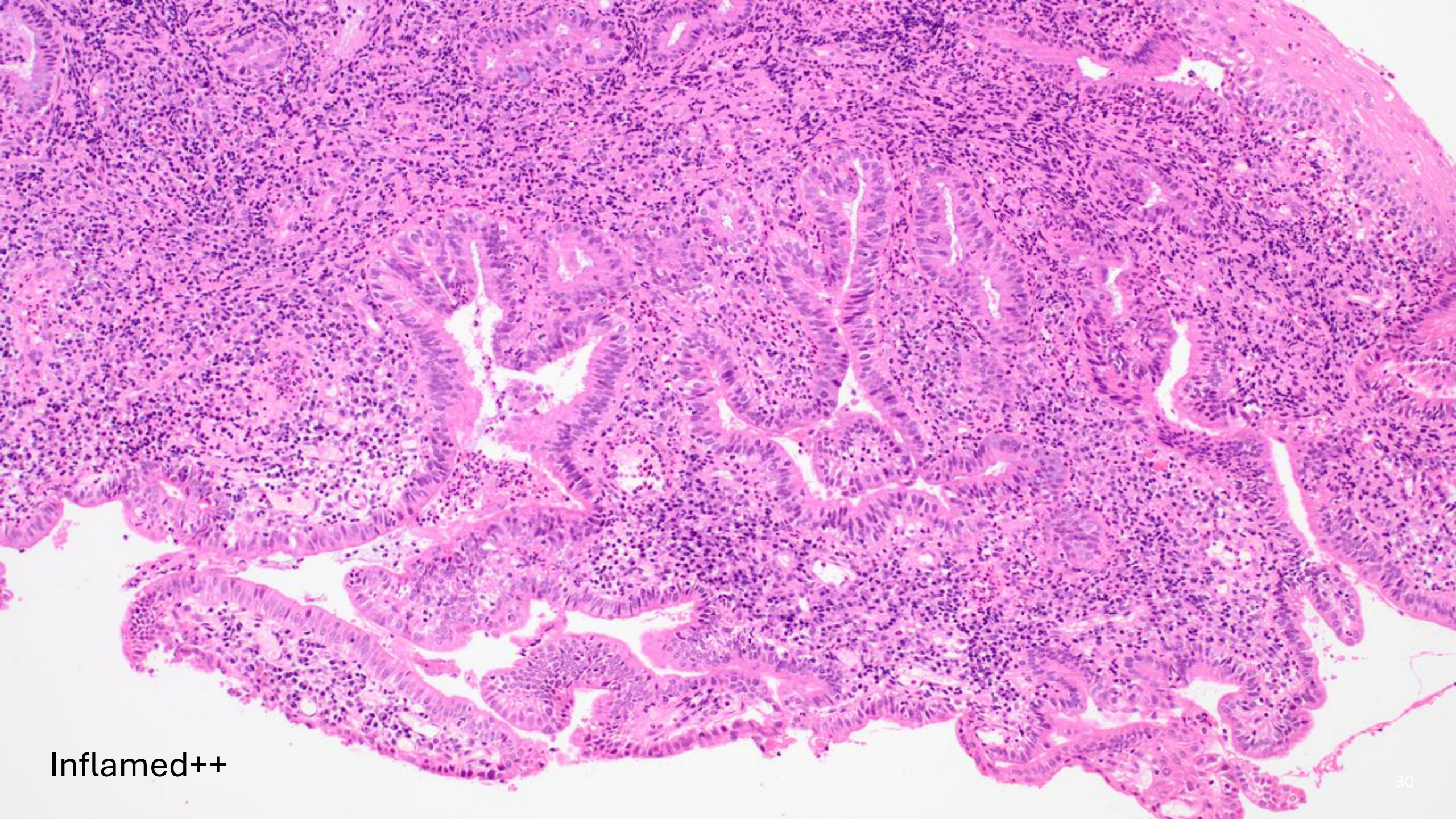

Inflamed++

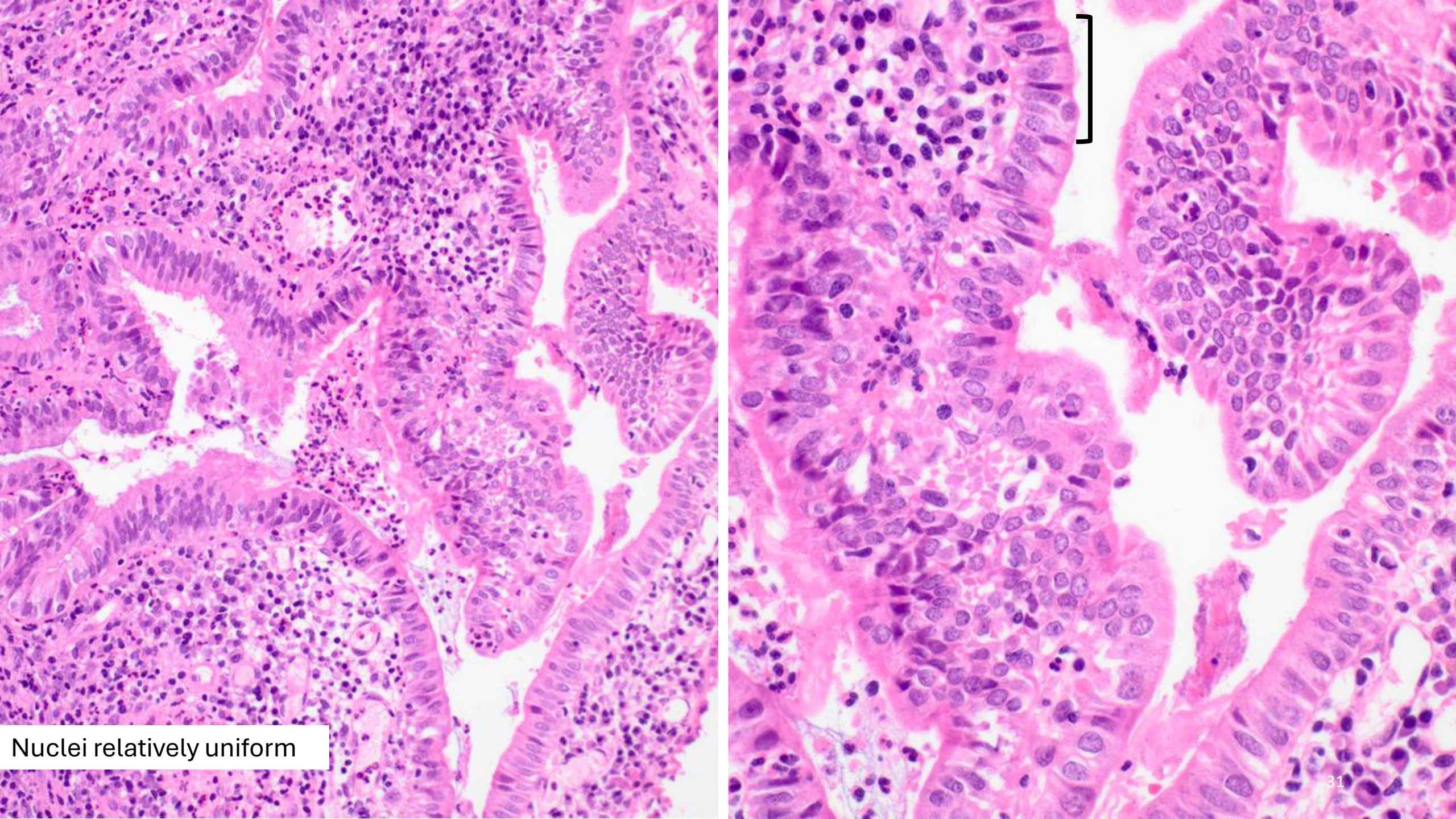
Nuclei relatively uniform

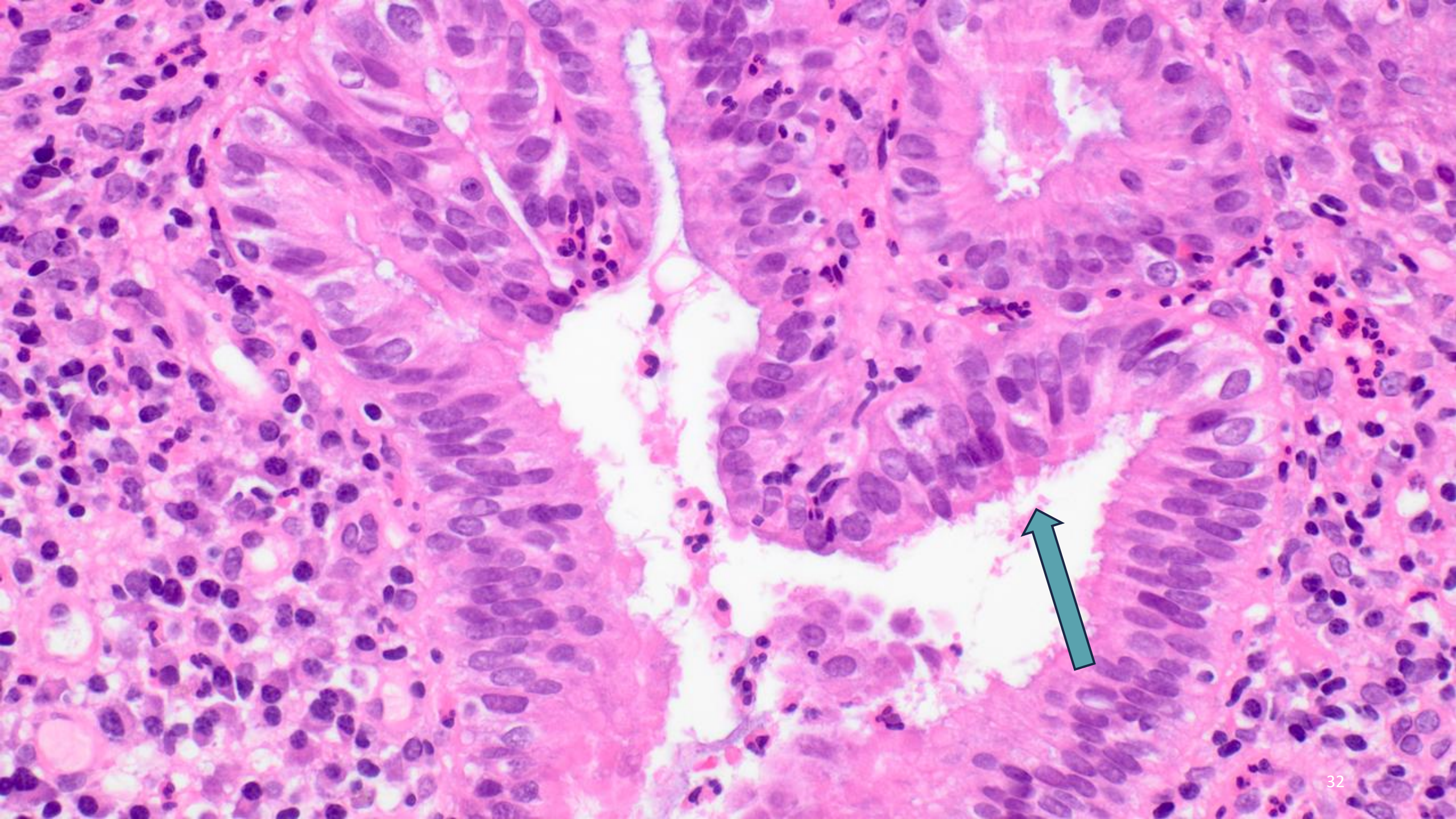

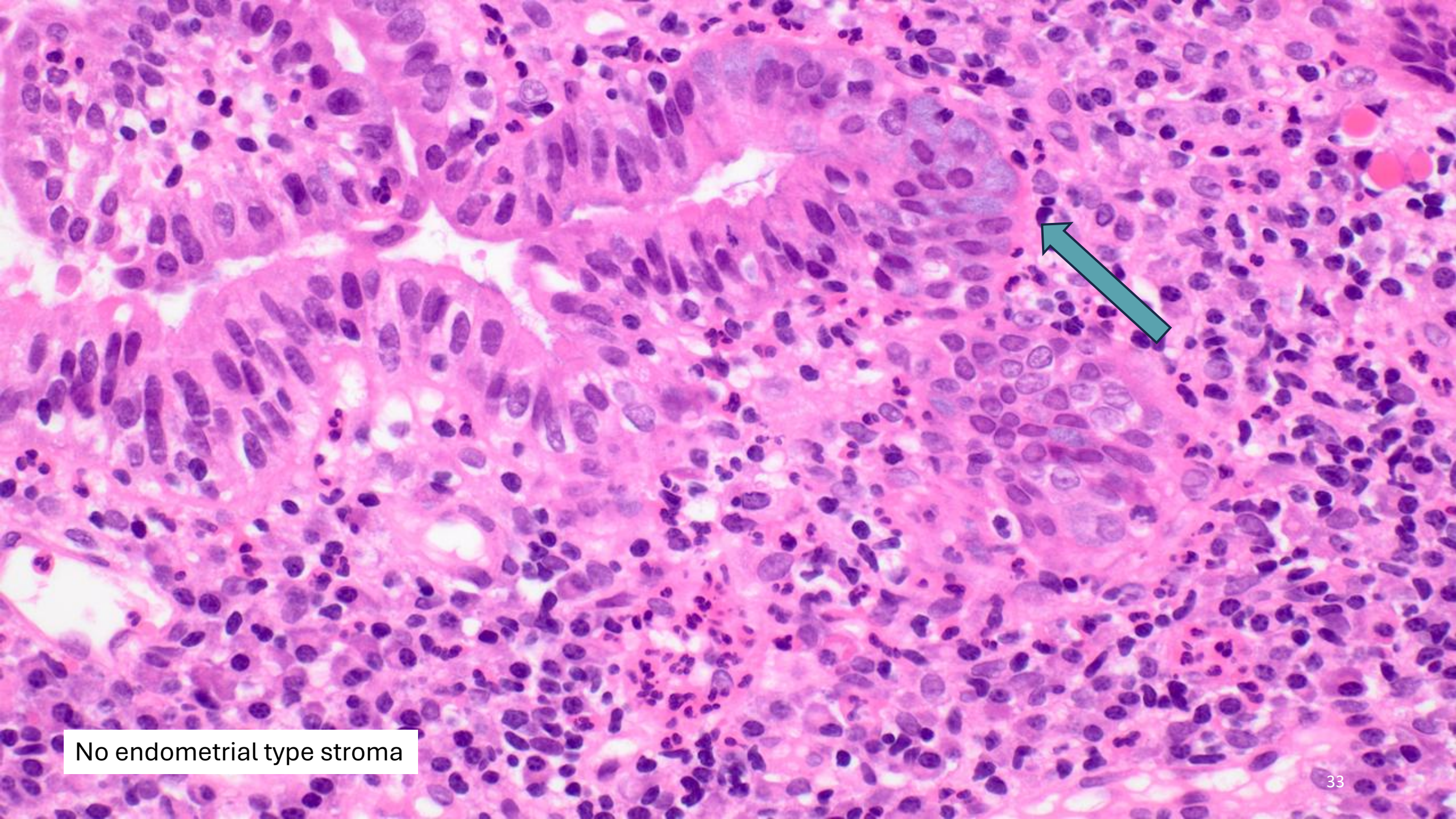
No endometrial type stroma

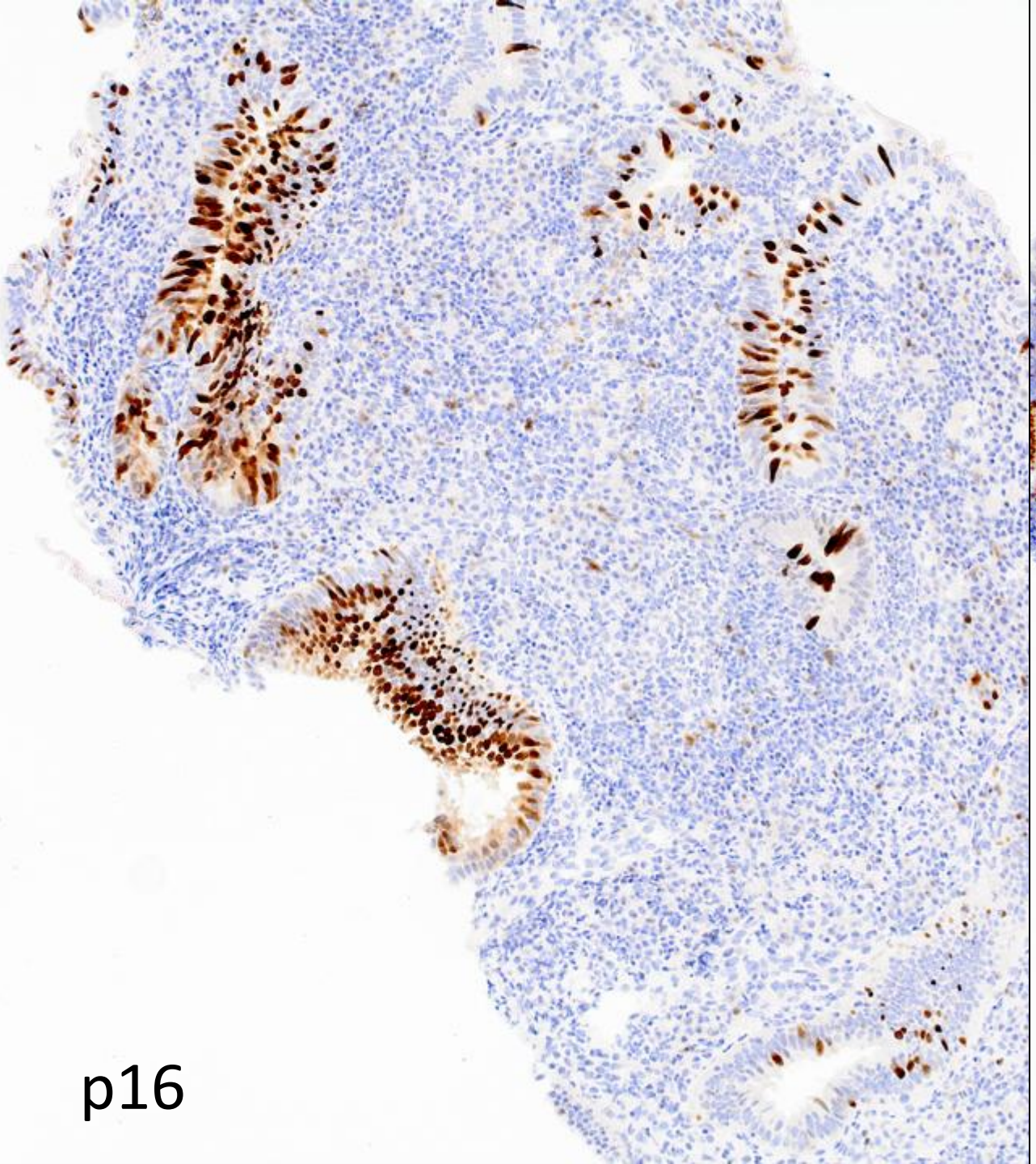

p16

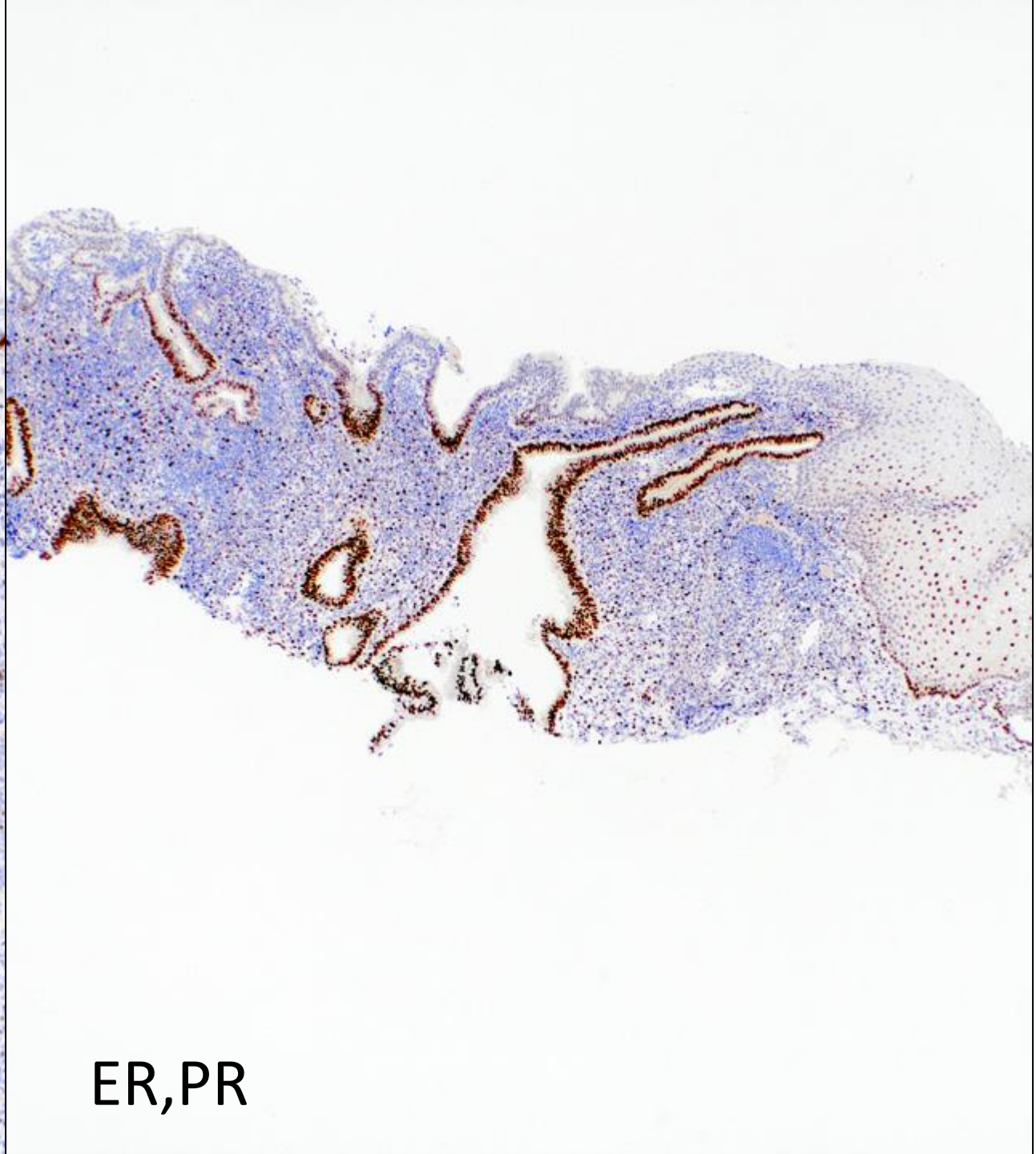

ER,PR

# Diagnosis?

## Vaginal adenosis, tubo-endometrioid & endocervical type

**Definition:**
Benign glandular epithelium involving superficial lamina propria or surface epithelium of the vagina

**Clinical:**
Usually asymptomatic
or discharge, dyspareunia, PCB
DES-exposed upper 2/3 vagina
Sporadic variable location
Red granular patches or cysts



*Source: J Natl Med Assoc 2007;99:166–167*

# Diethylstilboestrol (DES)

**Synthetic estrogen**, first manufactured 1938
1947: US FDA approved use in pregnancy – prevention of miscarriage, premature delivery

**Despite evidence showing no benefit in pregnancy** use continued until 1971

Prenatal exposure to estrogenic chemical during organogenesis
→TERATOGEN, CARCINOGEN




*Differentiation 2012;84:252-260*
*APMIS 2000;108:793-804*

# 1971: Linked to clear cell carcinoma

**DES in utero** (**DES daughter**):

- **Up to 90% congenital adenosis**, cx ectropion
- **1-2/1000 risk**: **Clear cell carcinoma** vagina, cervix; mean age 19 years (40 x normal risk)
- **Increased risk breast cancer**, cervical dysplasia
- 1/3rd structural abnormality reproductive tract
- Greater risk adverse pregnancy outcome miscarriage, ectopic, infertility, prematurity

**DES son: Increased risk testicular cancer**

**DES grandchildren:** Suspected continued epigenetic impact; no established increased cancer risk, studies ongoing as these patients still young




*Cancers(Basel) 2024;16:2575*
*Differentiation 2012;84:252-260*
*N Engl J Med 1971;284:878-881*
*Am J Clin Pathol 1979;71:715-721*
*Cancer 1979;25:745-757*

*APMIS 2000;108:793-804*
*Obstet Gynecol Annu 1982;11:187*
*N Engl J Med 1975;292;334*
*Cancer 1984;54:869-875*

# DES: Adenosis as precursor lesion

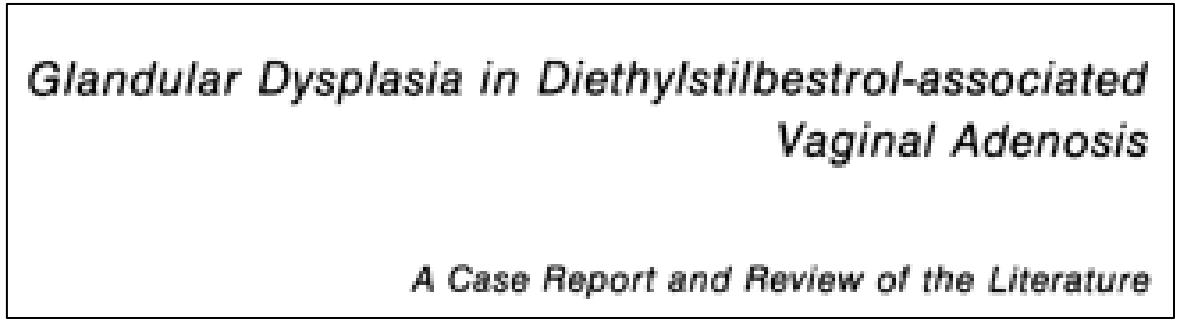

Glandular Dysplasia in Diethylstilbestrol-associated Vaginal Adenosis

A Case Report and Review of the Literature

*Antonioli Am J Clin Pathol 1979*

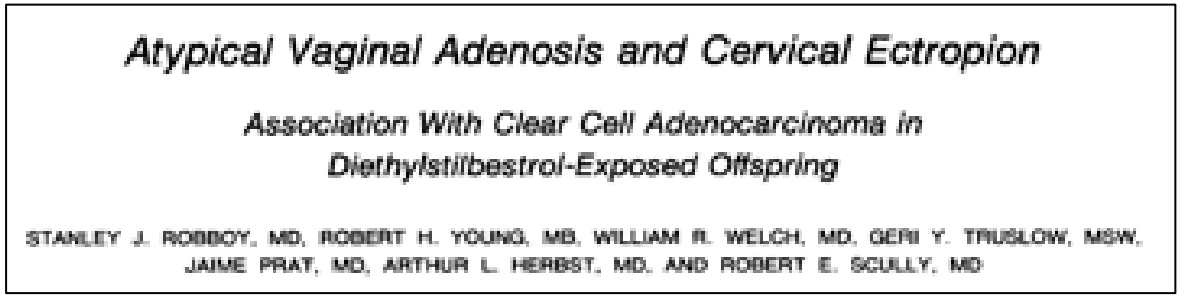

Atypical Vaginal Adenosis and Cervical Ectropion

Association With Clear Cell Adenocarcinoma in Diethylstilbestrol-Exposed Offspring

STANLEY J. ROBBOY, MD, ROBERT H. YOUNG, MB, WILLIAM R. WELCH, MD, GERI Y. TRUSLOW, MSW, JAIME PRAT, MD, ARTHUR L. HERBST, MD, AND ROBERT E. SCULLY, MD

*Robboy Cancer 1984, Natl Cancer Inst Monogr 1979*

**Observations in DES-exposed:**

High prevalence of tuboendometrial vaginal adenosis and cervical ectropion (cervical analogue of adenosis) in close proximity to clear cell carcinoma

Atypical adenosis described, directly adjacent to tumour

→**Hypothesis**: DES induces abnormal vaginal epithelialisation and adenosis

→Progression to “atypical adenosis” as a tumour precursor then carcinoma

# Adenosis post 1970

**Uncommon, up to 10% incidence;** usually idiopathic

**Trauma:** Laser, radiation, chemotherapy (topical 5FU), inflammation e.g. Stevens-Johnson syndrome

**Endocrine disruption**: Hormone/drug/chemical exposure

**Congenital:** ?Association with genitourinary malformation

*Eur J Gynaecol Oncol 2001;22:260-2002*
*Rev Obstet Gynecol 2011;4:81*
*J Natl Med Assoc 2007 Feb; 99(2): 166–167*

# Adenosis – what's new?

Mucinous: Commonest

- Endocervical
- Gastric type (WHO 2020)

Tubo-endometrioid

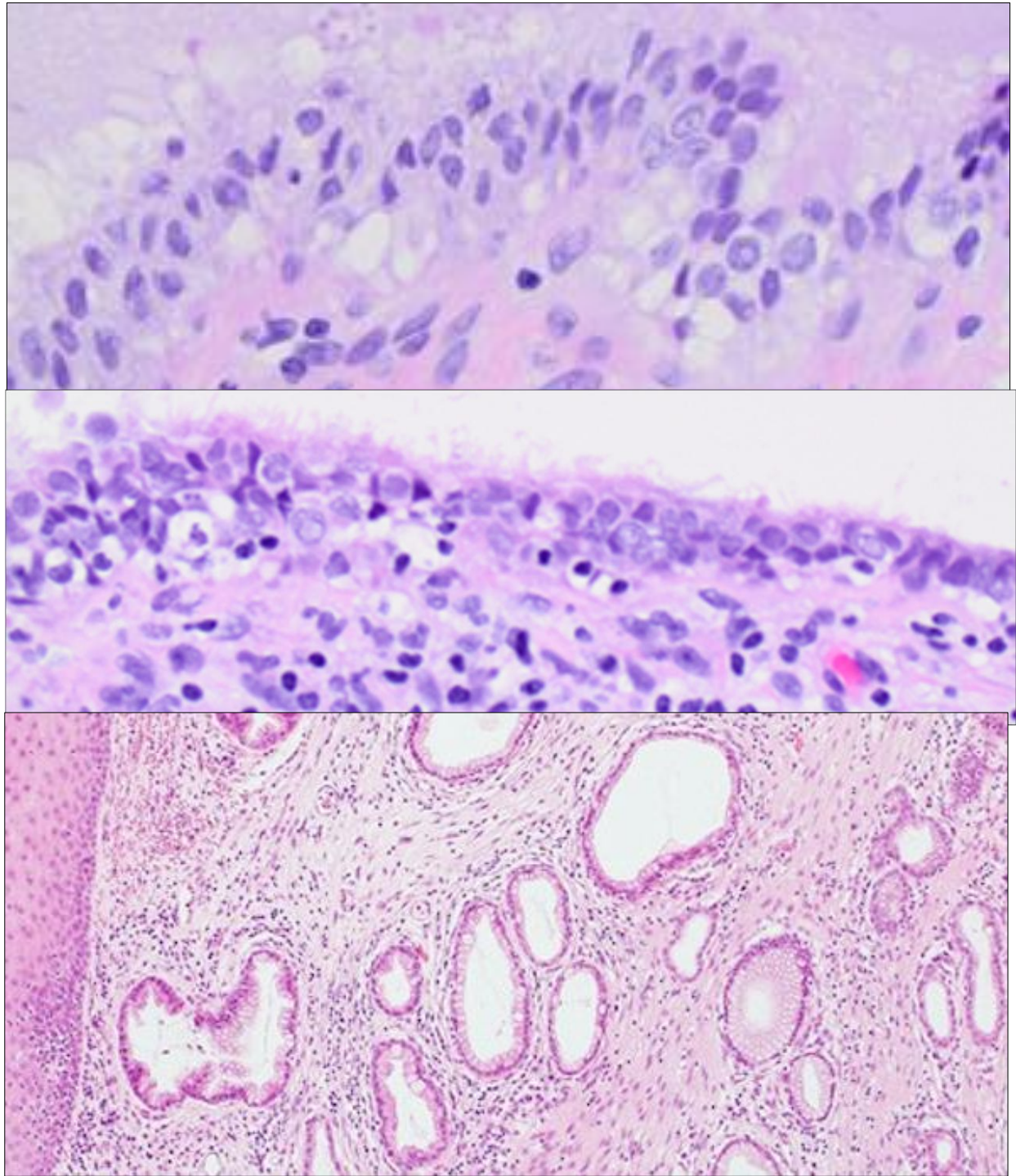

*AJSP 2018;42:958-970*

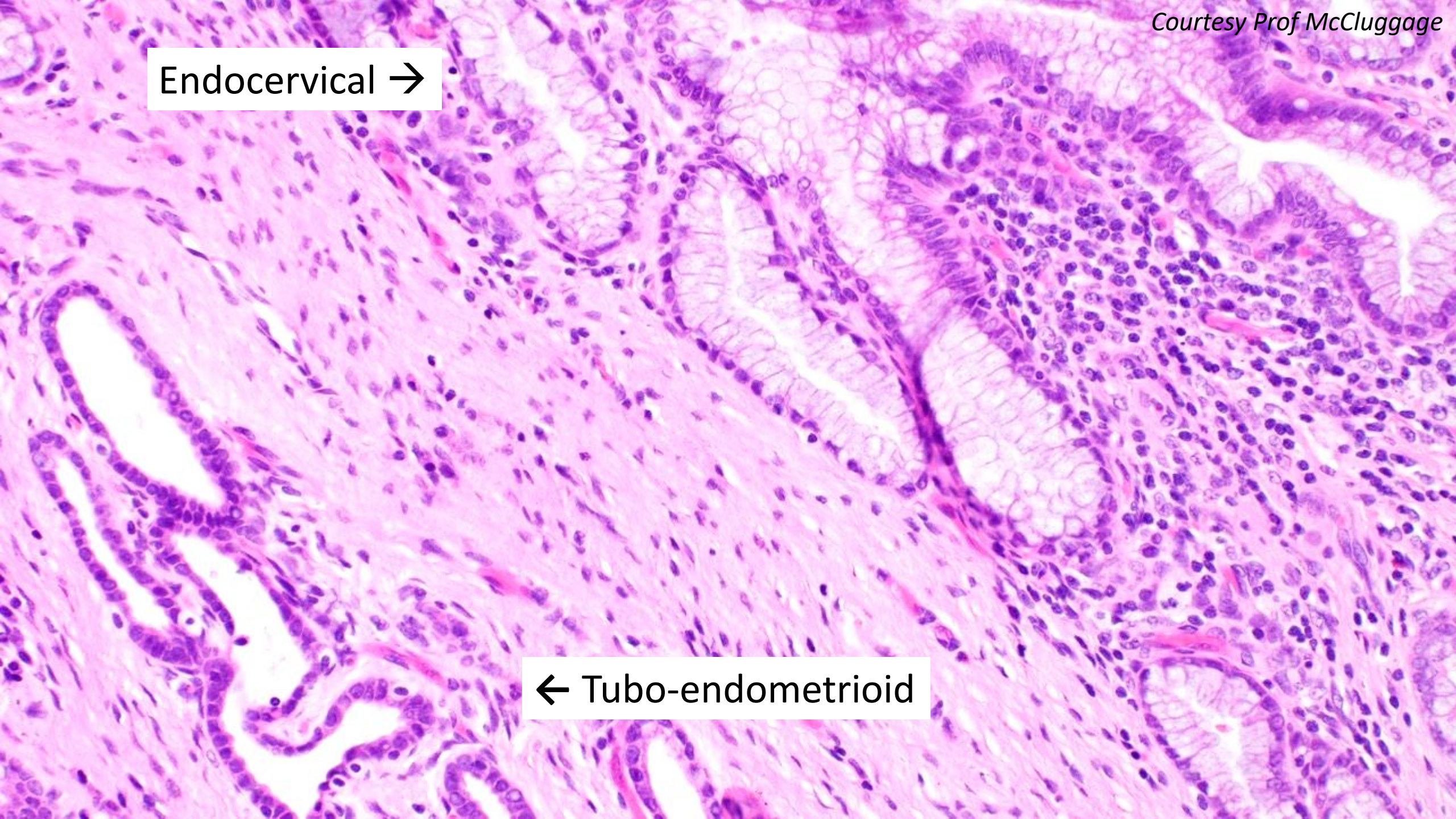
Courtesy Prof McCluggage
Endocervical →
← Tubo-endometrioid

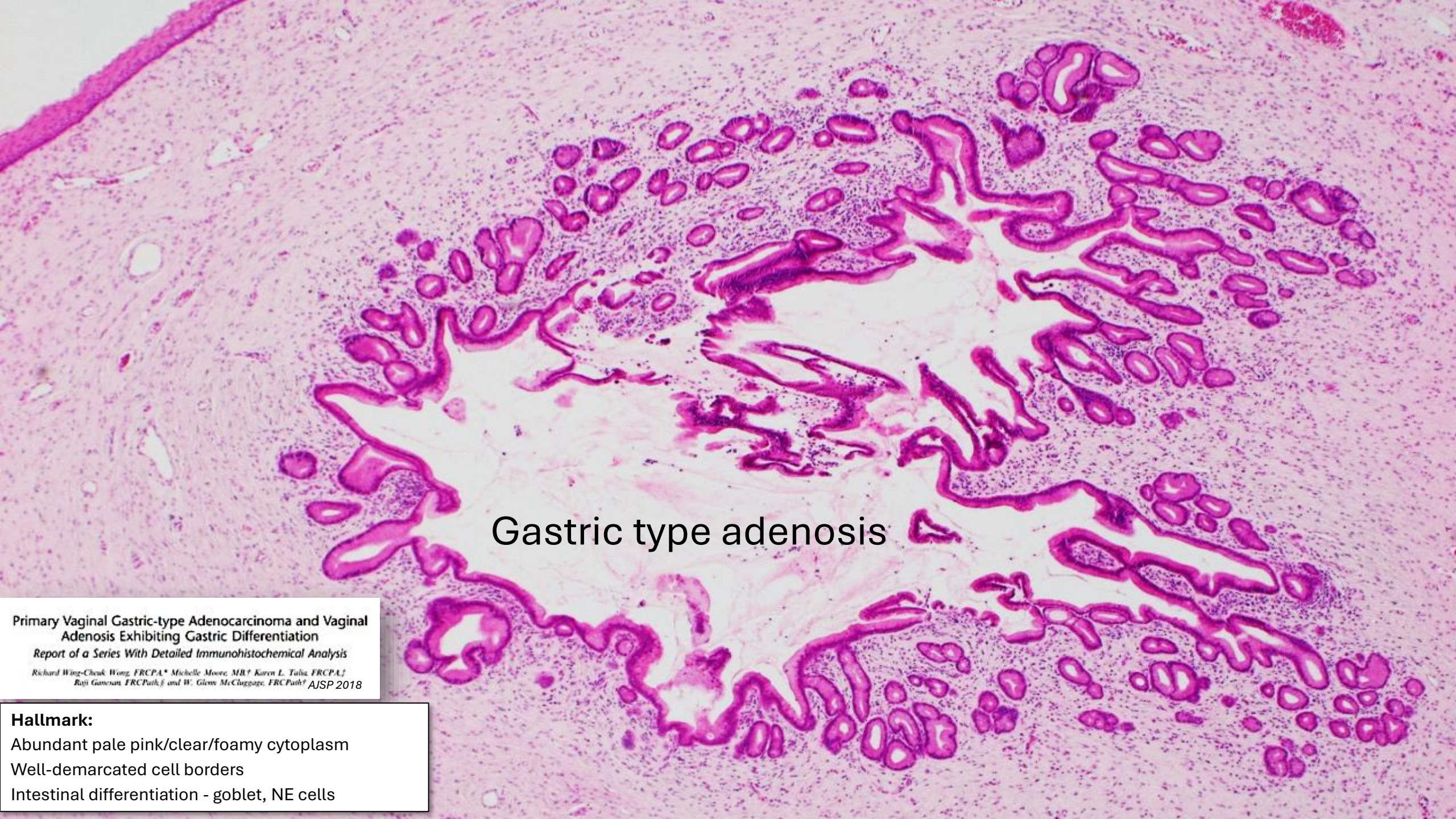

Gastric type adenosis

Primary Vaginal Gastric-type Adenocarcinoma and Vaginal Adenosis Exhibiting Gastric Differentiation

*Report of a Series With Detailed Immunohistochemical Analysis*

*Richard Wing-Cheuk Wong, FRCPA,* Michelle Moore, MB,† Karen L. Talia, FRCPA,‡ Raji Ganesan, FRCPath,§ and W. Glenn McCluggage, FRCPath†*

*AJSP 2018*

**Hallmark:**

Abundant pale pink/clear/foamy cytoplasm

Well-demarcated cell borders

Intestinal differentiation - goblet, NE cells

Adenosis, gastric type
- goblet cells



*Courtesy Prof McCluggage*

# Vaginal gastric type glandular lesions

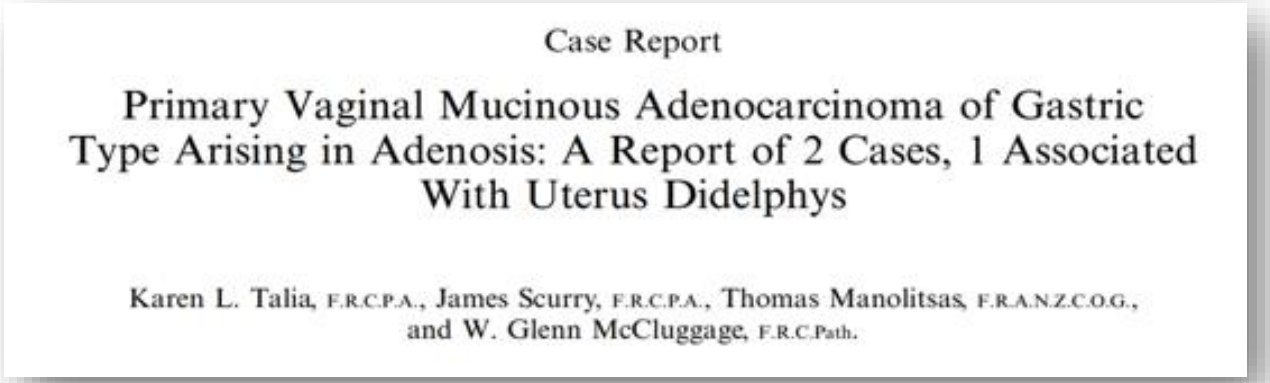

Case Report

Primary Vaginal Mucinous Adenocarcinoma of Gastric Type Arising in Adenosis: A Report of 2 Cases, 1 Associated With Uterus Didelphys

Karen L. Talia, F.R.C.P.A., James Scurry, F.R.C.P.A., Thomas Manolitsas, F.R.A.N.Z.C.O.G., and W. Glenn McCluggage, F.R.C.Path.

*IJGP 2012;31:192-199*



ORIGINAL ARTICLE

Primary Vaginal Gastric-type Adenocarcinoma and Vaginal Adenosis Exhibiting Gastric Differentiation

*Report of a Series With Detailed Immunohistochemical Analysis*

*Richard Wing-Cheuk Wong, FRCPA,* Michelle Moore, MB,† Karen L. Talia, FRCPA,‡ Raji Ganesan, FRCPath,§ and W. Glenn McCluggage, FRCPath†*

*AJSP 2018;42:958-970*

**5 adenocarcinomas**

- Adenosis in all; atypia in 4

**6 pure adenosis, gastric type**

Atypia in 4

# Pure gastric-type vaginal adenosis (no cancer)

**6 cases:**

Atypia in 4/6; cytologic and architectural

Overlap with cervical gastric-type lesions - foci resembling LEGH, gAIS

Focal goblet cells in all

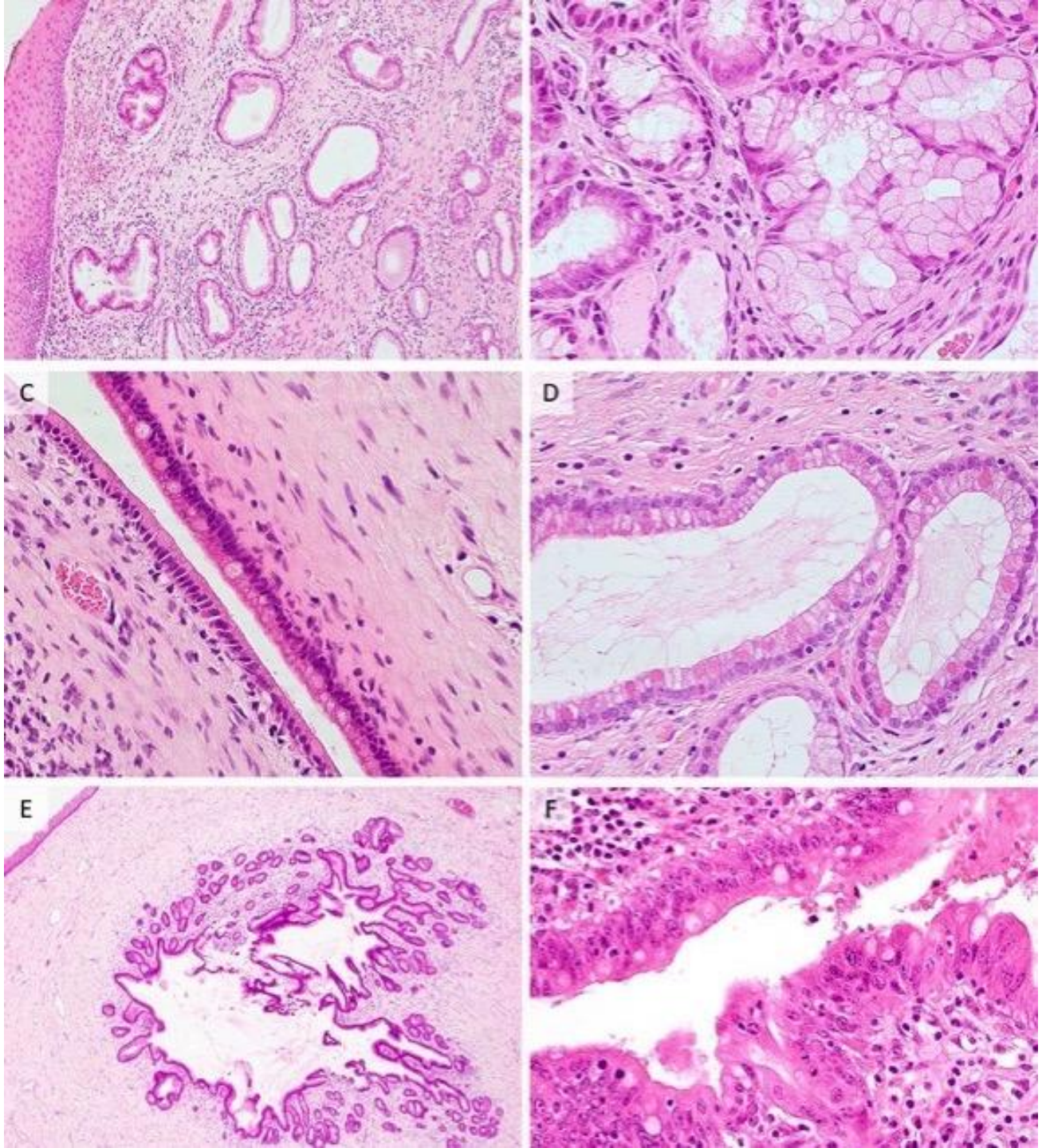

# Vaginal gastric-type adenocarcinoma

**5 cases:**

Identical to gastric-type cancer cervix

- Mix of gastric and intestinal type epithelium with prominent cell membranes; some morphologic heterogeneity – solid, basaloid, sarcomatoid components
- Same immunophenotype
- Aggressive clinical course

Adenosis in all cases, some with atypical features - ? tumour precursor

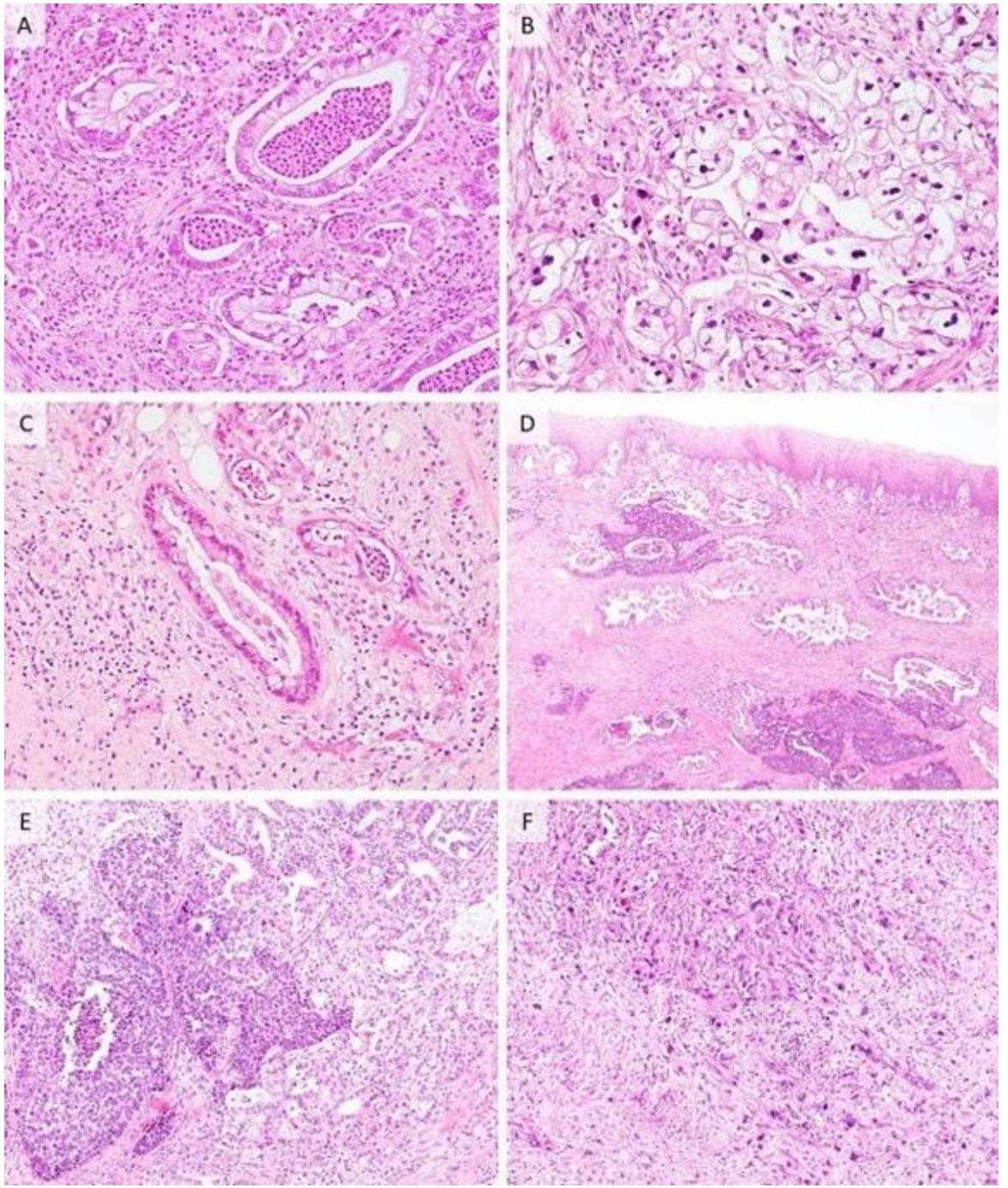


*AJSP 2018;42:958-970*

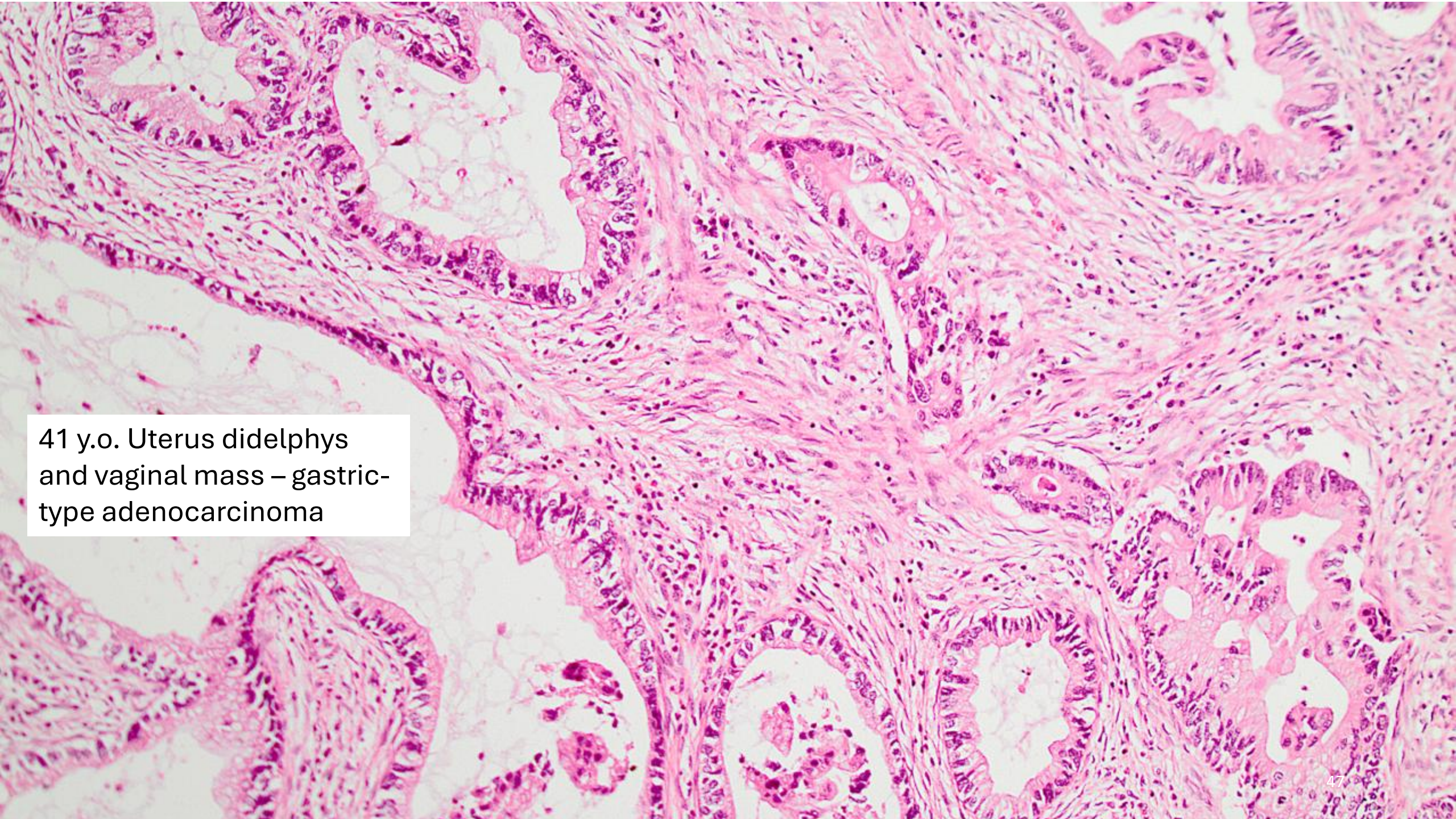
41 y.o. Uterus didelphys and vaginal mass – gastric-type adenocarcinoma

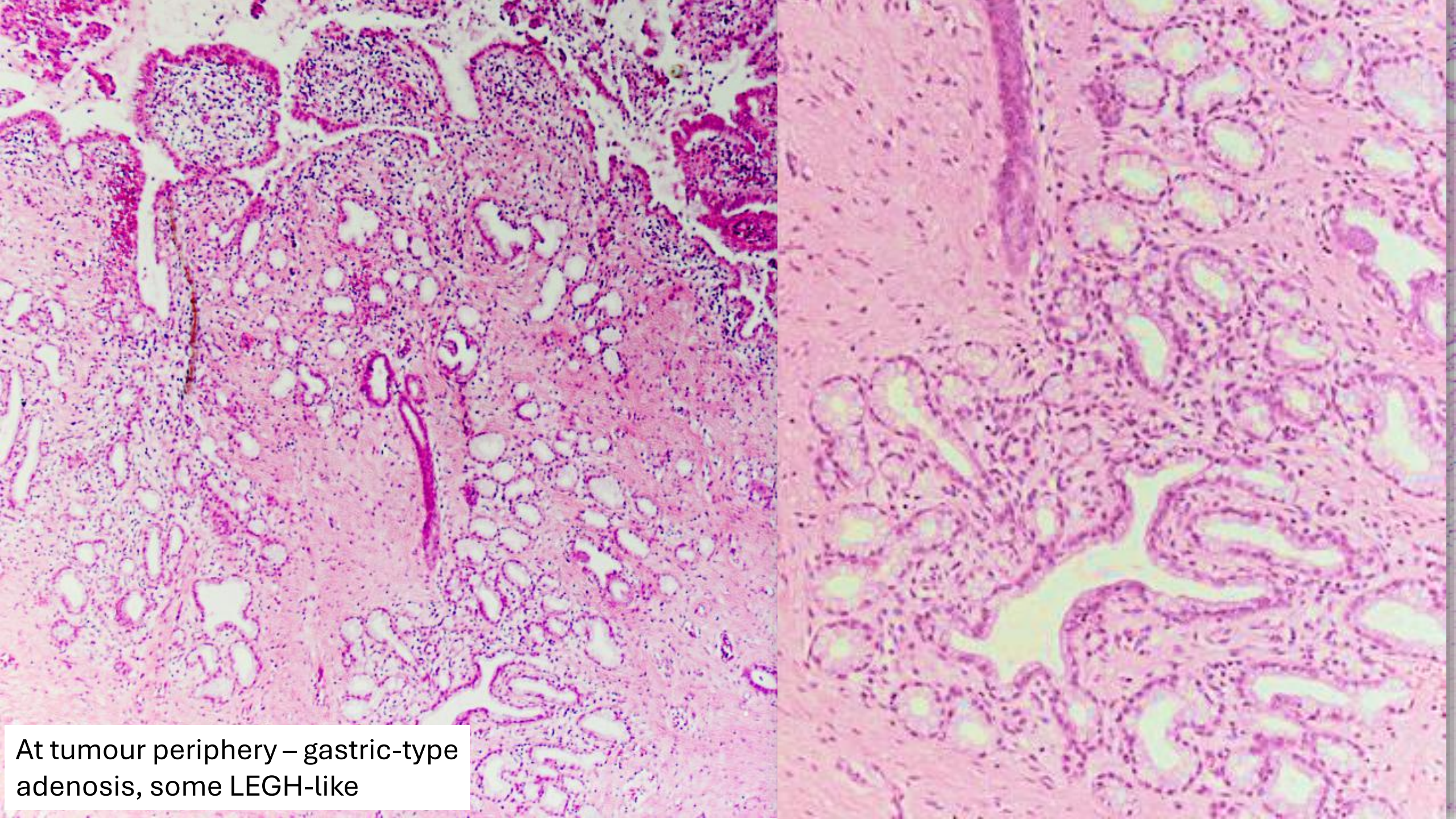

At tumour periphery – gastric-type adenosis, some LEGH-like

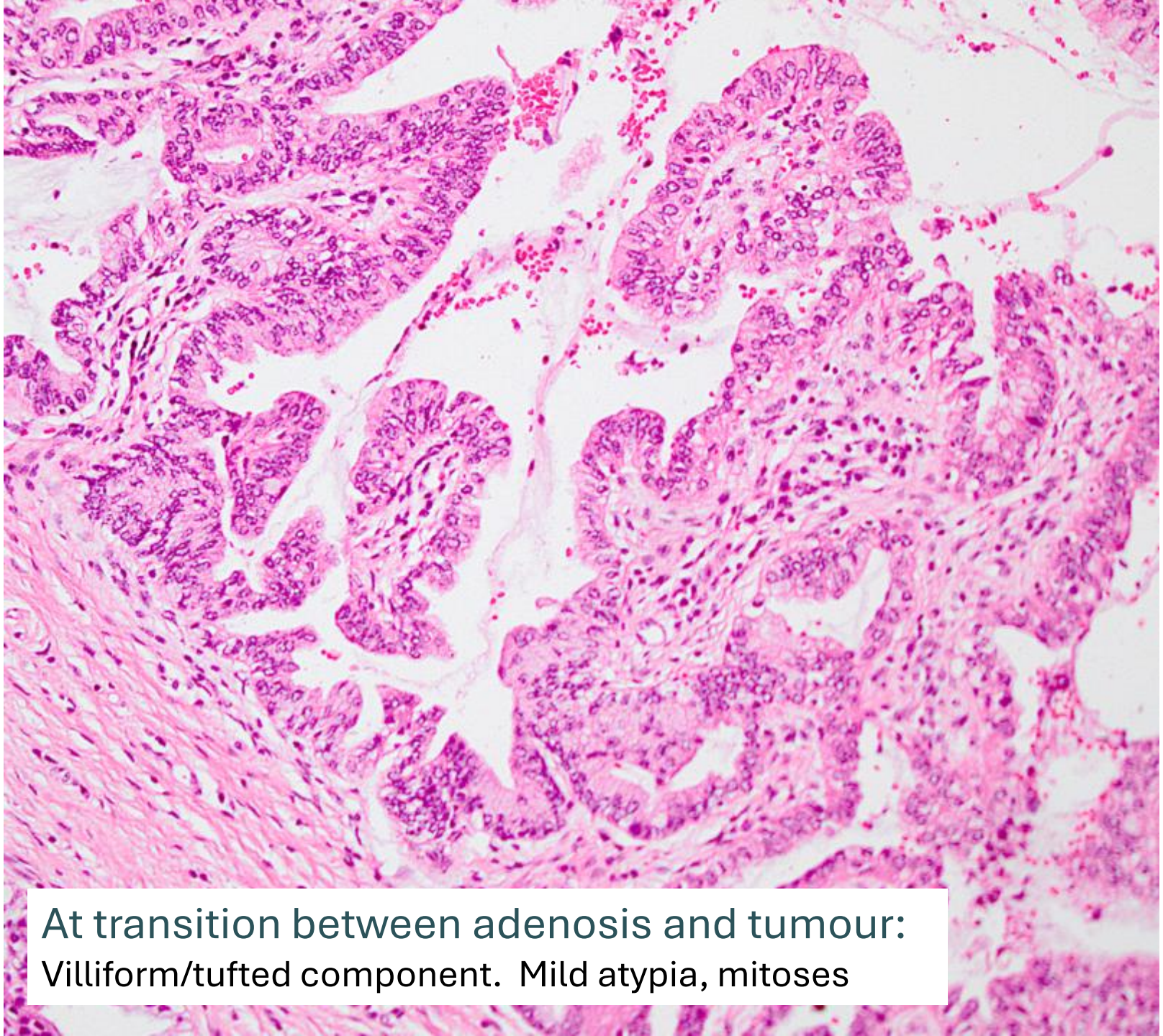

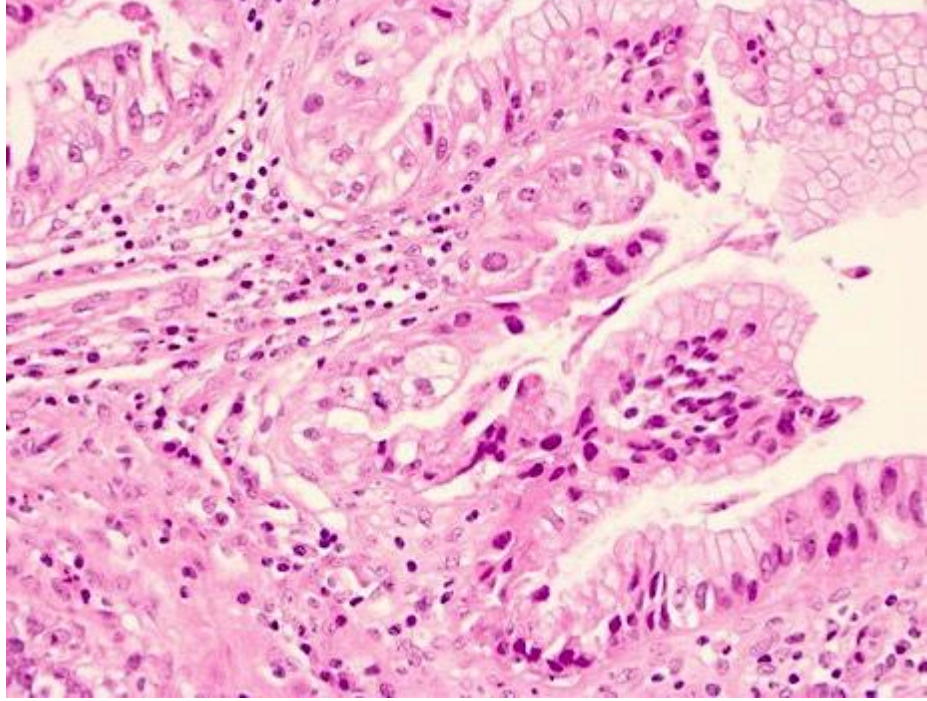

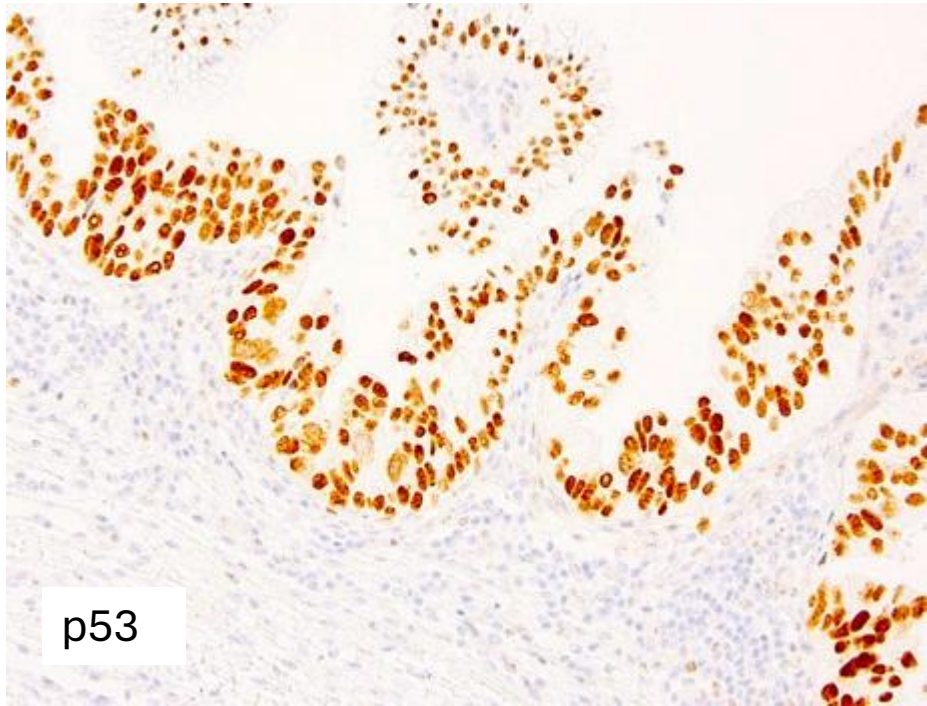

p53

At transition between adenosis and tumour:

Villiform/tufted component.  Mild atypia, mitoses

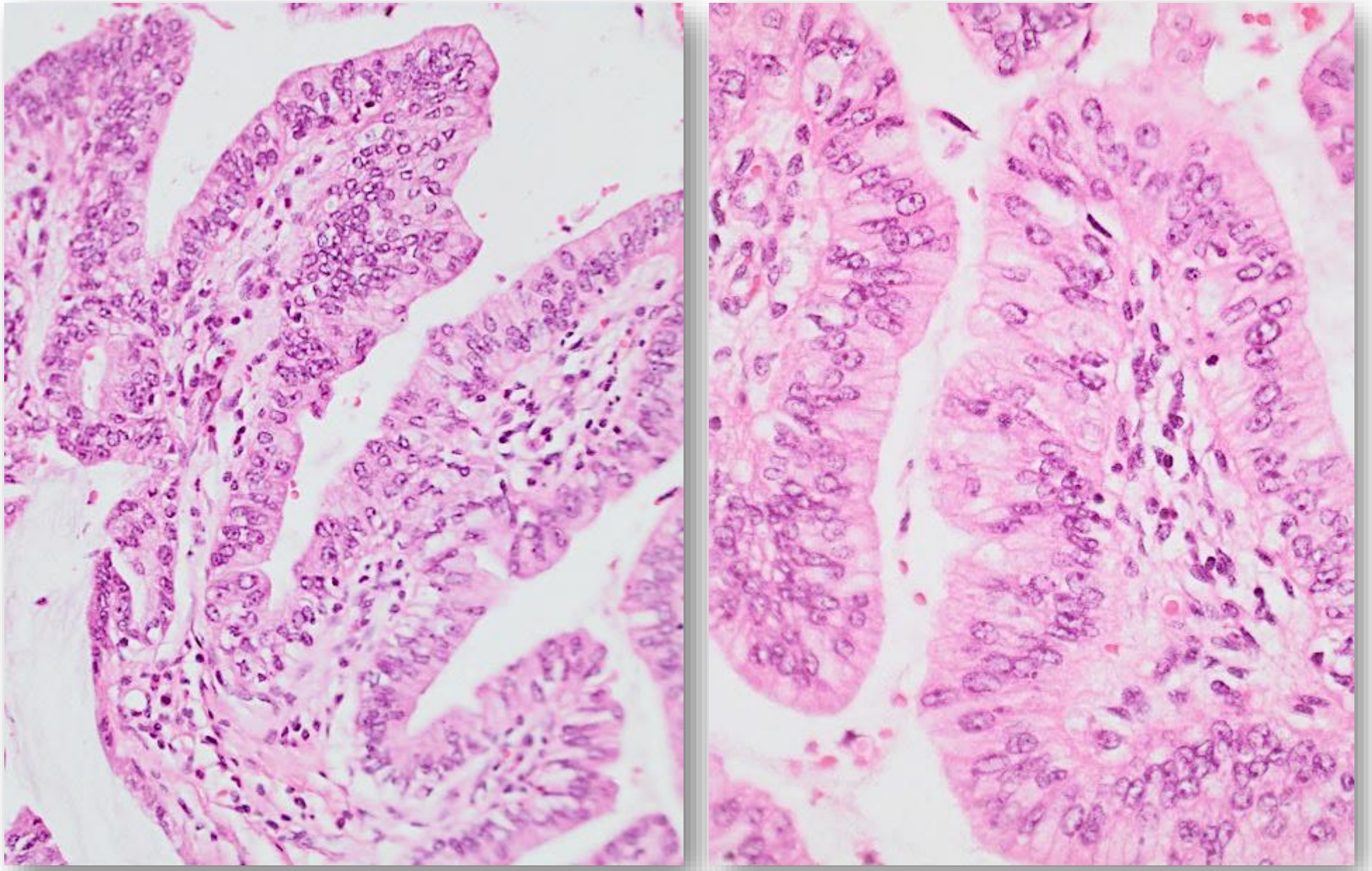

Proposed atypical adenosis, gastrointestinal type

# Possible tumorigenesis

*Am J Clin Pathol 1979*
*Cancer 1984*
*Natl Cancer Inst Monogr 1979*
*Am J Surg Pathol 2018*

**Adenosis**

Tubo-endometrial

Gastric

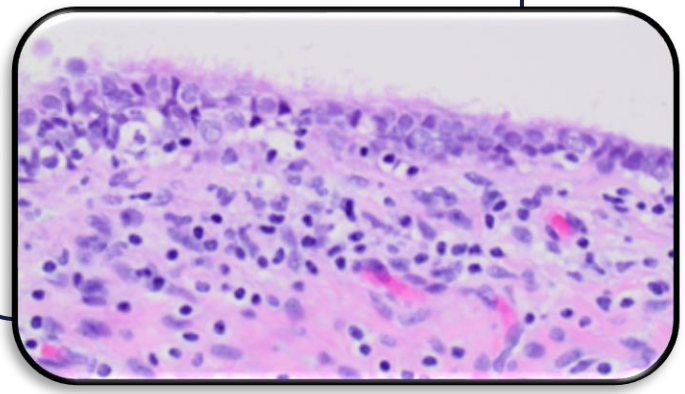

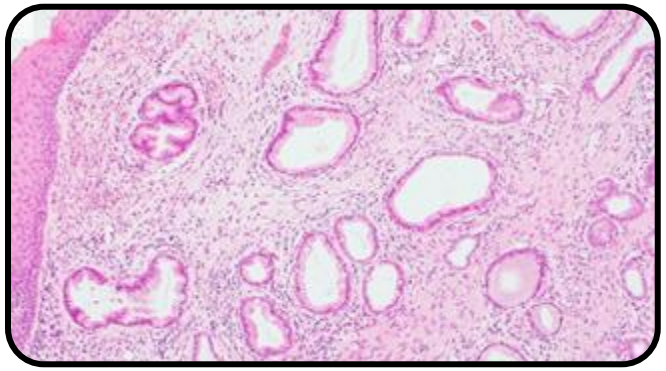

**Atypical adenosis**

*- Putative transitional lesion*

- **Tuboendometrial**
- **Gastric**

**Carcinoma**

- **Clear cell carcinoma**
- **Gastric type adenocarcinoma**

*Does congenital Müllerian duct anomaly predispose to malignancy?*

- 2 malformed uteri - reports of cervicovaginal adenocarcinoma with malformation, some with adenosis; no DES

*Cancer 1976, Arch Pathol Lab Med 1983, Gynecol Oncol 1994, Virchows Arch 1998, Virchows Arch 2000, Obstet Gynecol 2000, J Pak Med Assoc 2009; J Obstet Gynecol Res 2010, J Kyoto Pref Univ Med 1990*

# Gastric-type adenocarcinoma – what's new?

## Markers of pyloric mucin help confirm gastric differentiation but not essential for diagnosis

Traditional: **MUC6** sensitive but poorly specific – normal glands, HPVA & endometrial ca

**HIK1083** specific but poorly sensitive, not widely available

**Claudin 18** emerging as highly sensitive and specific

**Claudin 18.2** isoform (expressed in gastric/oesoph/pancreatic cancers)

**Therapeutic significance:** Claudin 18.2-directed cytolytic antibody – zolbetuximab

Claudin 18.2 as a biomarker to direct therapy

*Wong AJSP 2020, Wong AJSP 2018, Kaur AJSP 2025, Mikami Mod Path 2004, Nara Gynecol Oncol 2007, Kawauchi AJSP 2008, Matsubara AJSP 2014, Yang Mod Path 2024, Lin AJSP 2025, Kamijo AJSP 2025, Lin AJSP 2025*

# Claudin-18 and Mutation Surrogate Immunohistochemistry in Gastric-type Endocervical Lesions and their Differential Diagnoses

*Lawrence Hsu Lin, MD, PhD,*† Harsimar Kaur, MBBS,* David L. Kolin, MD, PhD,* Marisa R. Nucci, MD,* and Carlos Parra-Herran, MD**

*AJSP 2025*

12 benign gastric
46 gastric type adenoca/AIS
54 benign Mullerian
11 HPVA adenoca/AIS

**Claudin 18**, **PR** + mutation surrogate markers: **p53** (*TP53*), **STK11/LKB1** (*STK11*), **MTAP** (*CDKN2A*), **SMAD4**/DPC4 (*SMAD4*)

Claudin 18 a highly specific marker of benign and malignant gastric type lesions
Once gastric phenotype established, mutation surrogate marker helps confirm malignancy

**Claud**

se

Confirm

**PR:**

rmal)

**Mutation surrogates:**

Confirm malignant

63% aberrant staining; p53>STK11>MTAP>SMAD4
Most benign gastric negative
More p53 abnormal in poorly differentiated gastric type carcinoma

Extensive Pathologic Invasion and Prognostic Implication of Gastric-Type Cervical Adenocarcinoma

*A Comparative Analysis With Human Papillomavirus-Associated Adenocarcinoma*

Kyosuke Kamija, MD,*† Tsutomu Miyamoto, MD, PhD,* Shiori Oshima, MD,‡§ Shiho Asaka, MD, PhD,§‖ Manaka Shinagawa, MD,* Yoshinori Sato, MD,§ Hirofumi Ando, MD, PhD,* Ryoichi Asaka, MD, PhD,* Marina Fujioka, MD,* Natsuki Uchiyama, MD,* Yusuke Yokokawa, MD,* Yasuhiro Tanaka, MD,* Yukiko Kusama, MD,¶ Uehara Takeshi, MD, PhD,# Yaeko Kobayashi, MD, PhD,** and Tanri Shiozawa, MD, PhD*

AJSP 2025

33 gastric type, 70 HPVA adenoca
Compared macroscopy, clinical, histology; performed image analysis

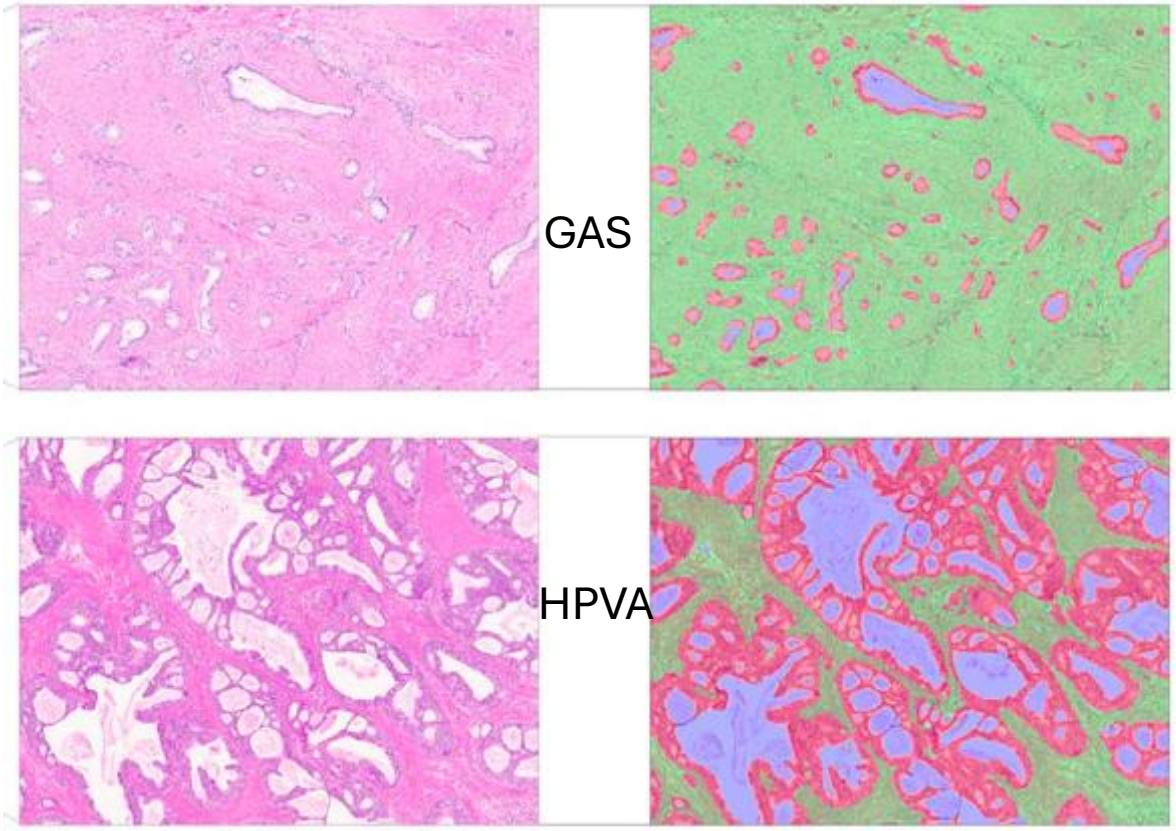


# Compared to HPVA: Unique "stealth" pattern of invasion

**Gastric type cancer:** Lower cell density, diffuse pattern of invasion
→ unclear tumour boundaries, positive surgical margins
→ 70% upstaged post-op

## Independent risk factors for OS/PFS:
## Advanced stage, positive peritoneal cytology, positive margins

More perineural infiltration than HPVA (70 vs.10%); PNI = significantly worse survival

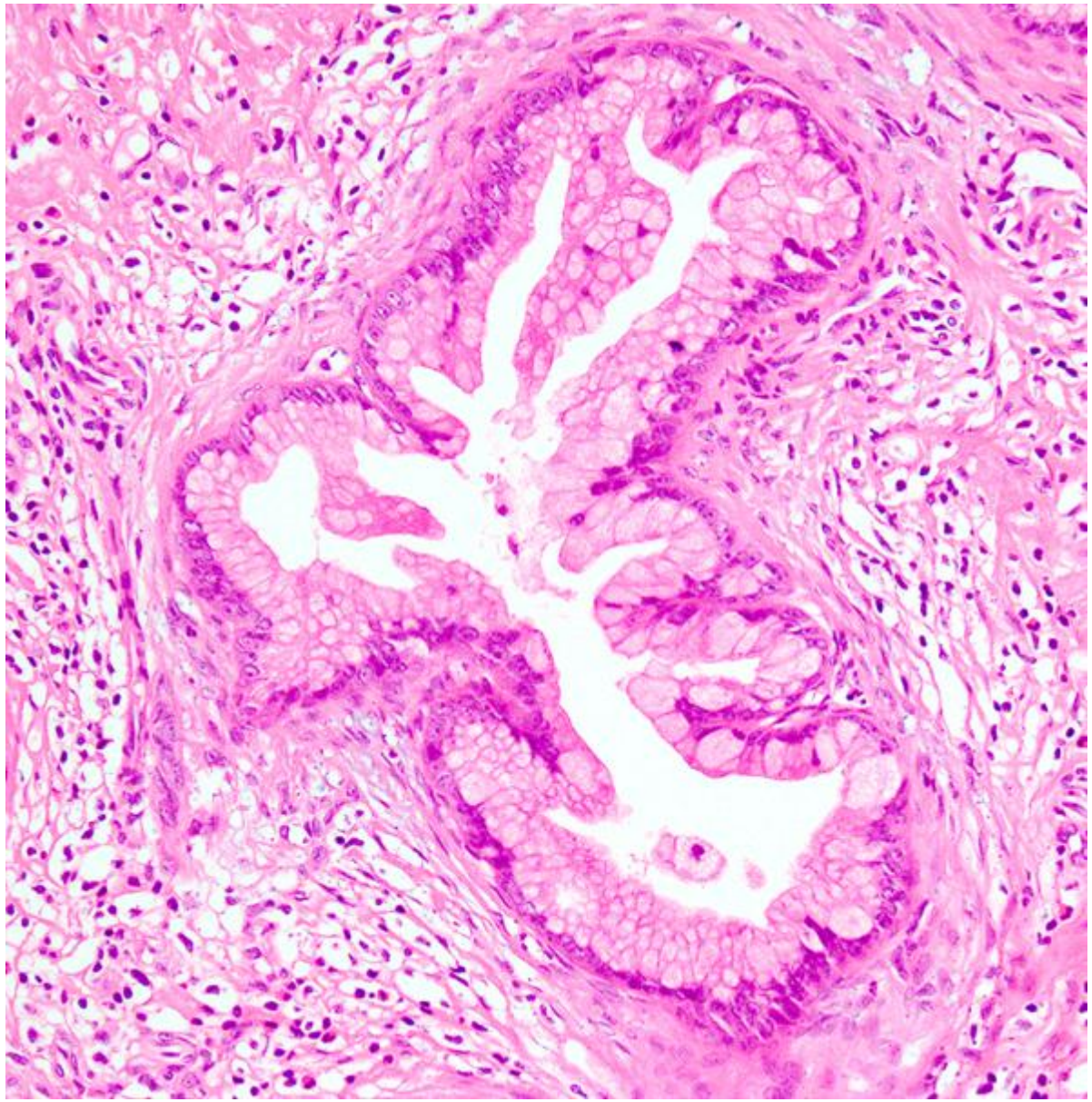

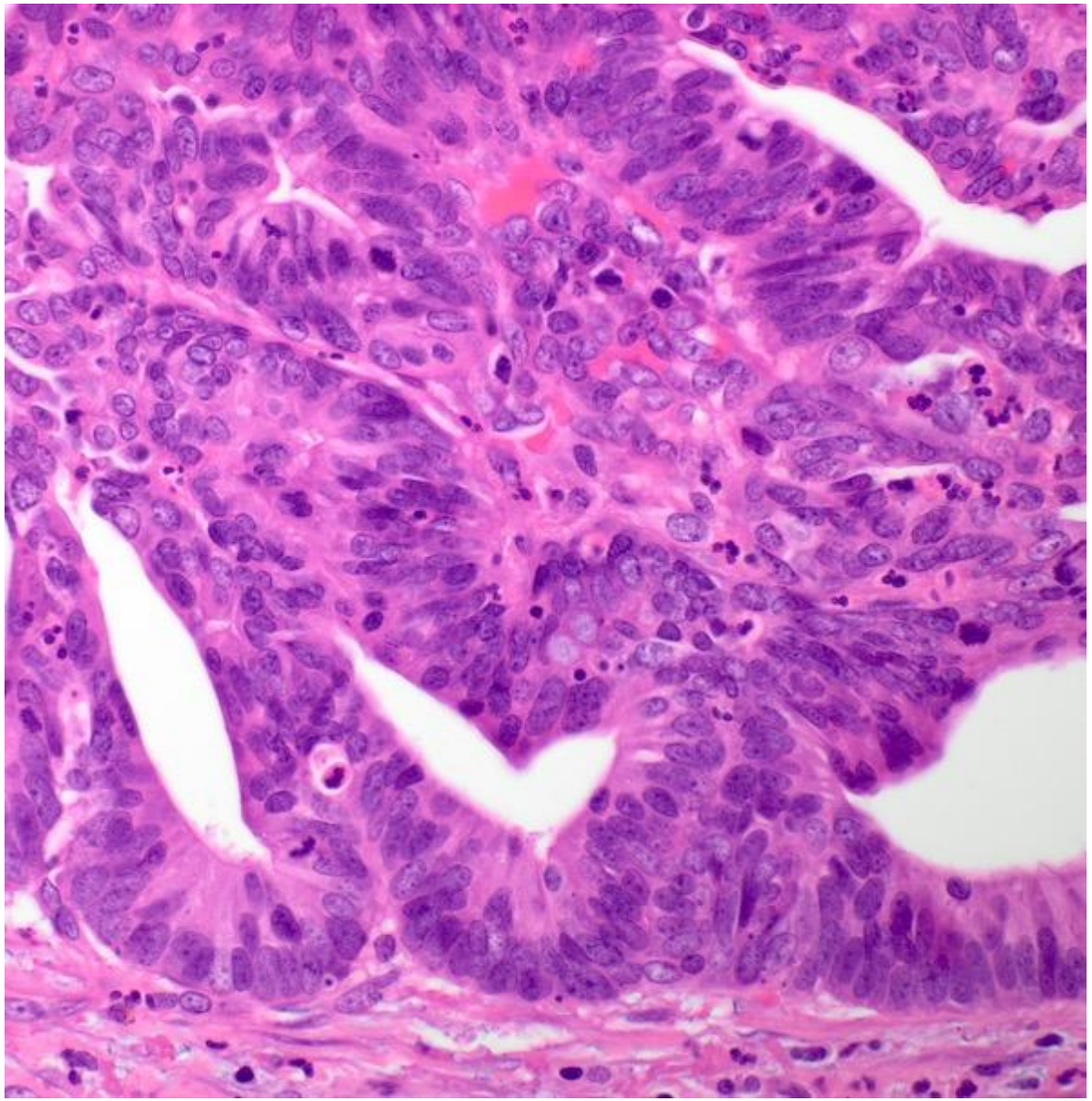

Gastric type vs. Intestinal type adenocarcinoma

# Adenocarcinoma, intestinal type – vulva and vagina

Primary Intestinal-type Glandular Lesions of the Vagina

*Clinical, Pathologic, and Immunohistochemical Features of 14 Cases Ranging From Benign Polyp to Adenoma to Adenocarcinoma*

*Paul N. Staats, MD,* W. Glenn McCluggage, FRCPath,† Philip B. Clement, MD,‡ and Robert H. Young, MD§*

*AJSP 2014*

In the vagina, usually polypoid, small, superficial, **posterior/lower vagina**

**Some associated with adenoma** (identical to colorectal)

**No DES,** endometriosis

## Identical to colorectal carcinoma

- Intestinal differentiation - goblet cells, NE cells
- Tubulovillous/glandular/solid architecture
- Occasionally serrated, mucin extravasation, signet ring cells, dirty necrosis
- Diffuse **CK20, CDX2, CEA,** CK7± ER/PR negative, p16 negative

WHO

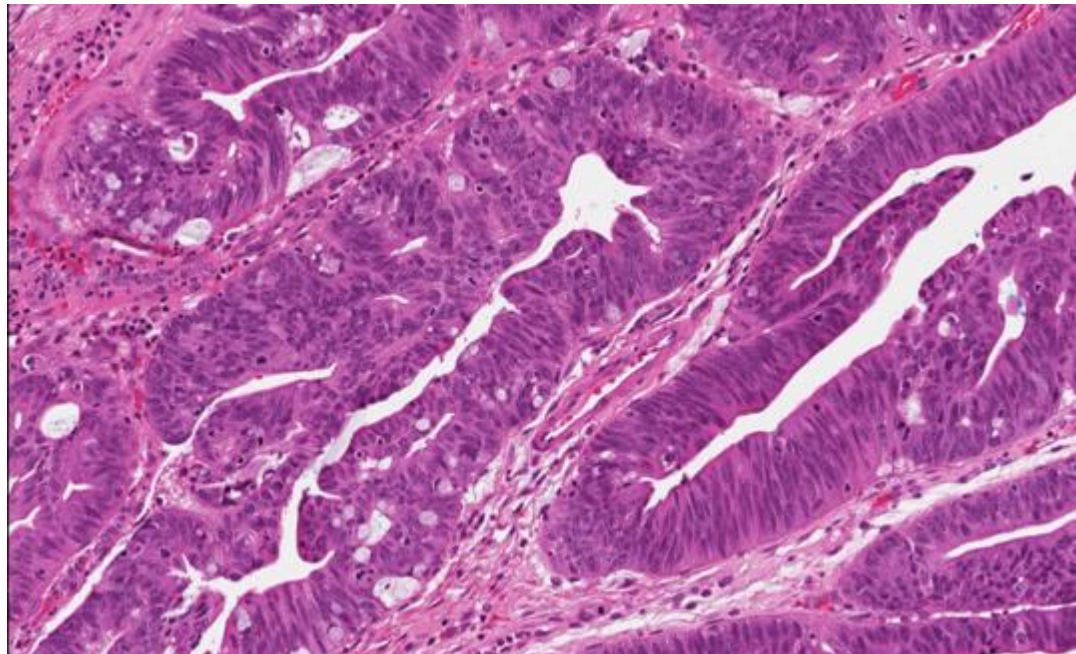

# Cell of origin and histogenesis unresolved ? Adenoma-carcinoma sequence

Adenocarcinomas arise in association with colorectal-type adenomas

Pure adenomas reported, lower vagina, vulval vestibule

Small numbers but identical to those in colon; tubular/ villous/ tubulovillous

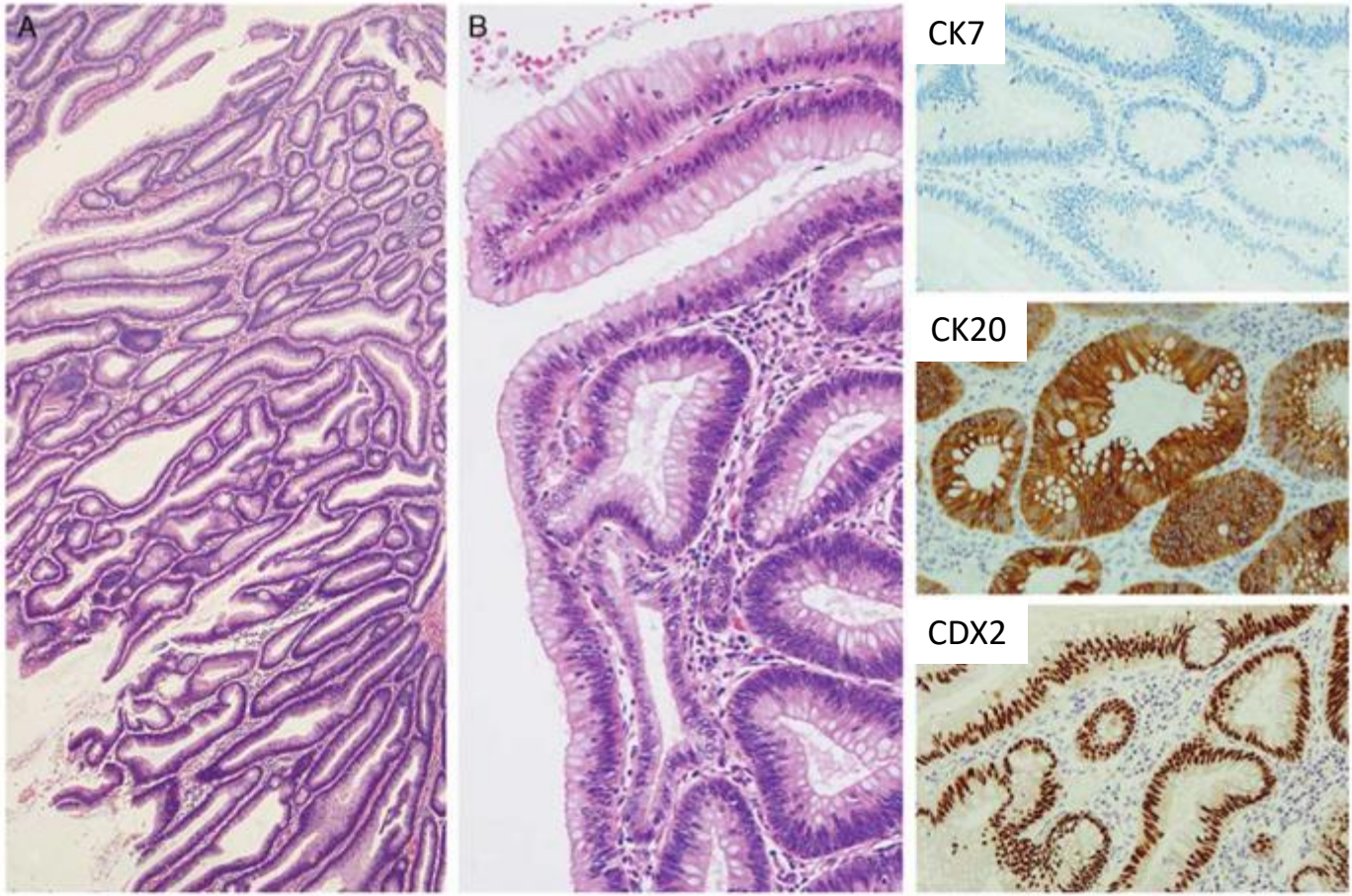


Vaginal tubulovillous adenoma with *KRAS* and *APC* mutations

*Staats AJSP 3014*

*Shuangshoti IJGP 2019*

Primary Vulvar and Vaginal Adenocarcinomas of Intestinal Type Are Closer To Colorectal Adenocarcinomas Than To Carcinomas of Müllerian Origin

Alexis Trecourt[a,b], Isabelle Treilleux[c], Daniel Pissaloux[c], Marie Donzel[a,d], Brice Thamphya[c], Franck Thirode[c], Aurélie Houlier[c], Sandrine Paindavoine[c], Tatiana Franceschi[c], Aline Baltrès[c], Witold Gertych[e], Pierre-Adrien Bolze[e], Pierre Antoine Chaix[f], Charlotte Roux-Terrier[g], Françoise Descotes[h], Isabelle Ray-Coquard[i,j], Jonathan Lopez[h,i], Mojgan Devouassoux-Shisheboran[a,b,i,*]

*Mod Pathol 2025*

4 vulval, 4 vaginal intestinal type adenocarcinoma
IHC, HPV ISH, DNA and RNA sequencing, clustering analysis

**AIM:** Clarify histogenesis

IHC and molecular analysis of 8 tumours, 4 vulval and 4 vaginal

**CK20** 100%, **CDX2** 100%, **SATB2** 62.5%, **CK7** 82.5%, CK20 >> CK7 (some focal)

**PAX8, ER, PR, p16, SOX17:** ALL negative

**p53** abn in 75%, **MMR** ALL proficient, **HRHPV ISH:** ALL negative

Pathogenic variants: ***TP53*** (5/7) > ***KRAS*** (3/7), *ATM / STK11 / RAD51D / PTEN* (1 case each)

Clustering analysis whole RNA sequencing **- Vulvovaginal intestinal adenocarcinoma** (pink) **clusters with colorectal carcinoma** (brown)

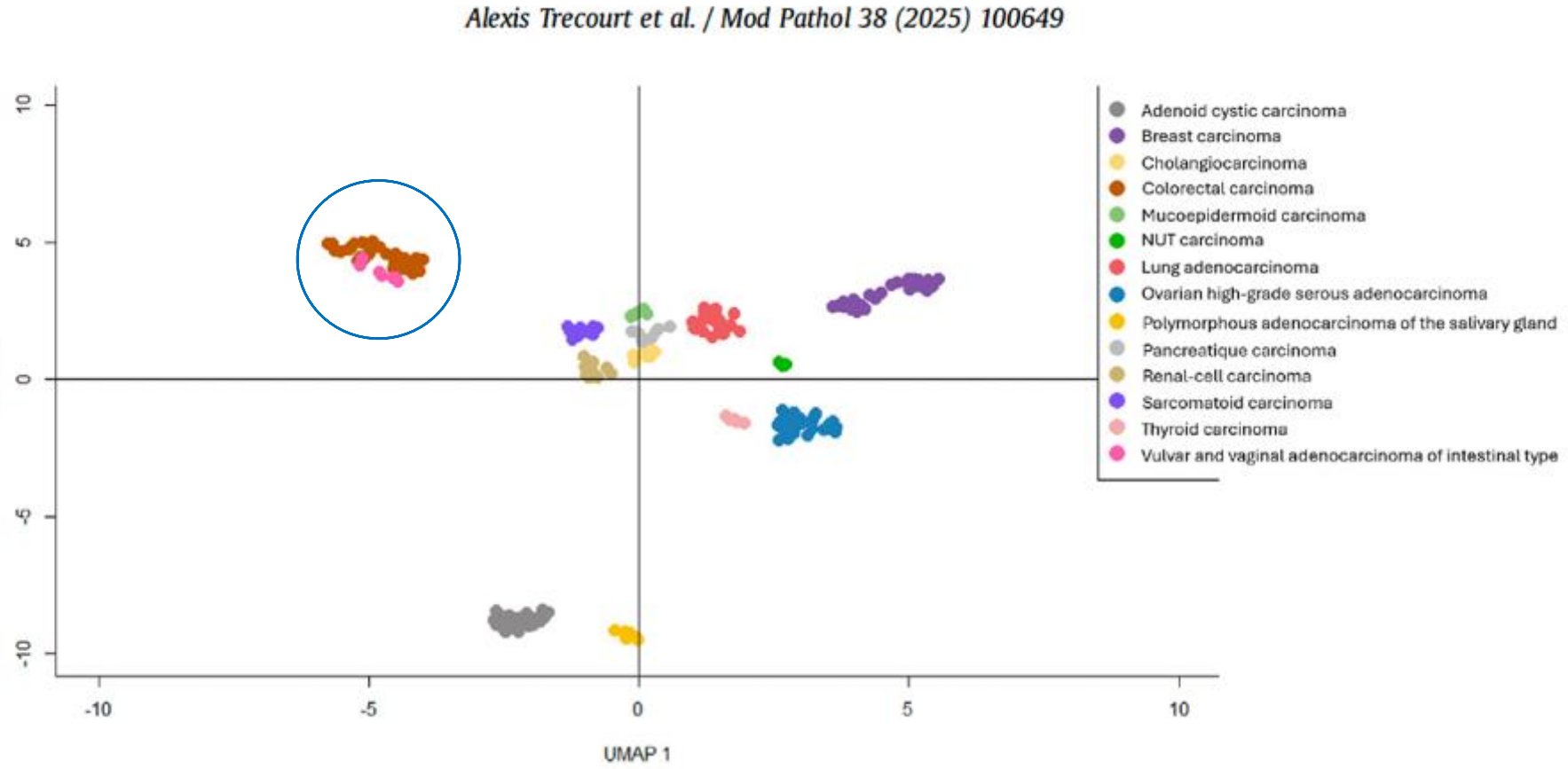


NanoString analysis: **Clusters with colorectal carcinomas and not with mimics such as cervical adenocarcinoma** including HPVA usual & intestinal type, HPVI gastric type

Primary Vulvar and Vaginal Adenocarcinomas of Intestinal Type Are Closer To Colorectal Adenocarcinomas Than To Carcinomas of Müllerian Origin

Alexis Trecourt[a,b], Isabelle Treilleux[c], Daniel Pissaloux[c], Marie Donzel[a,d], Brice Thamphya[c], Franck Thirode[c], Aurélie Houlier[c], Sandrine Paindavoine[c], Tatiana Franceschi[c], Aline Baltrès[c], Witold Gertych[e], Pierre-Adrien Bolze[e], Pierre Antoine Chaix[f], Charlotte Roux-Terrier[g], Françoise Descotes[h], Isabelle Ray-Coquard[i,j], Jonathan Lopez[h,i], Mojgan Devouassoux-Shisheboran[a,b,i,*]

*Mod Pathol 2025*

4 vulval, 4 vaginal intestinal type adenocarcinoma
IHC, HPV ISH, DNA and RNA sequencing, clustering analysis

# Conclusions

**Closer to colonic than Müllerian adenocarcinoma**

Morphology, immunophenotype identical

Similar gene alterations *TP53* and *KRAS* although no MMRd

**Vulval/vaginal likely a single entity, should be grouped together**

**Must exclude a colorectal primary –** colonoscopy, imaging

Mostly indolent behaviour in reported cases

*Staats AJSP 2014, Dellino Cancers 2022, He EJGO 2015*

*Courtesy R Wong*
*Prof McCluggage*

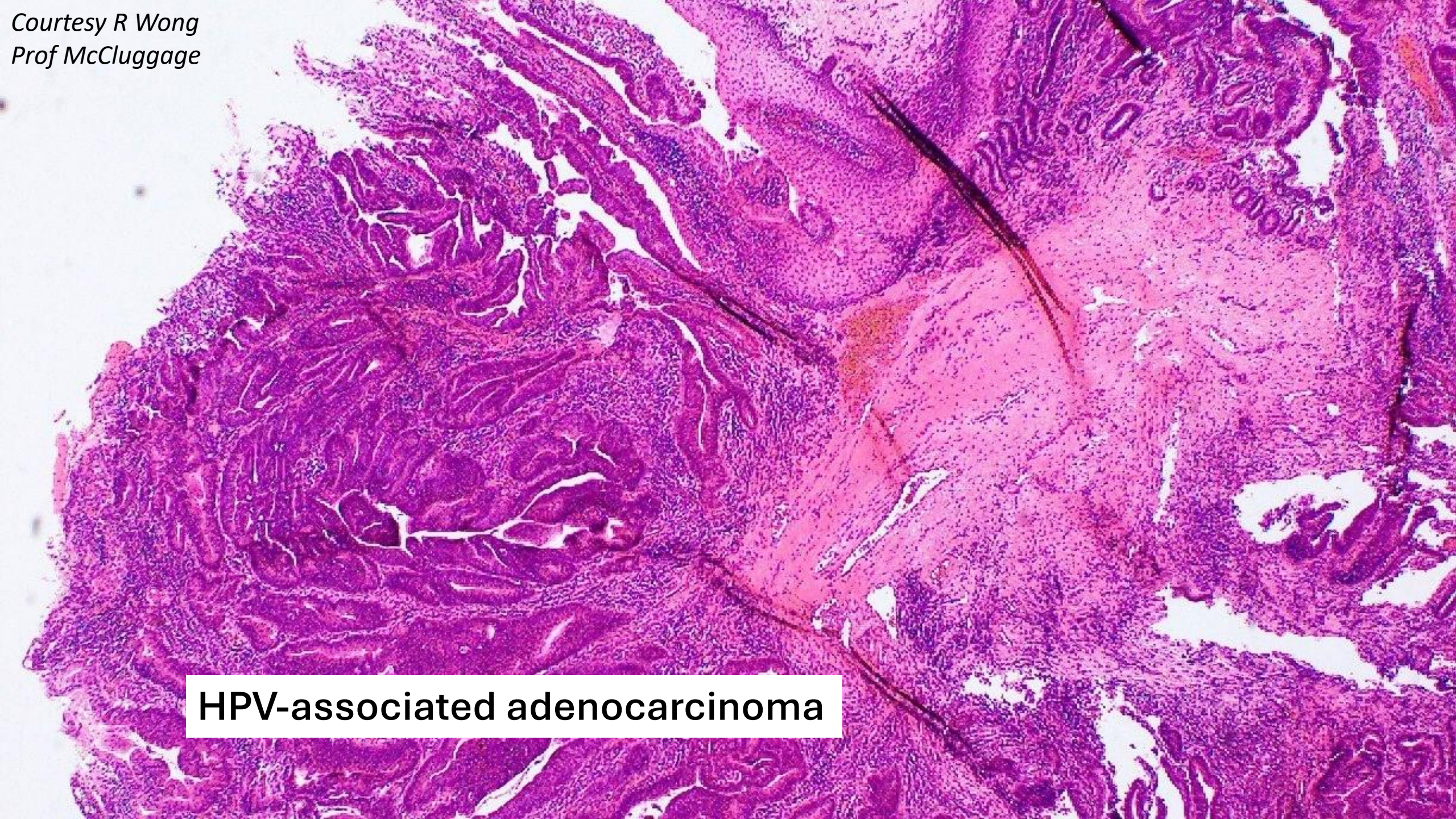

HPV-associated adenocarcinoma

*Courtesy R Wong, Prof McCluggage*

**A novel group of HPV-related adenocarcinomas of the lower anogenital tract (vagina, vulva, and anorectum) in women and men resembling HPV-related endocervical adenocarcinomas**

Lysandra Voltaggio[1] · W. Glenn McCluggage[2] · Jeffrey S. Iding[3] · Brock Martin[4] · Teri A. Longacre[4] · Brigitte M. Ronnett[1]

*Mod Path 2020*

**Rare ++;** 4 vaginal cases this series
plus 2 vulva, 3 anorectal

**Resembles endocervical HPVA adenocarcinoma**

Often papillary/villiform architecture

Mucin-deplete pseudoendometrioid, apical mitoses, apoptoses

**p16 diffuse, HRHPV ISH +**

**Origin in adenosis speculated**

– present in 2 of 4 cases

**Must exclude spread from cervix**

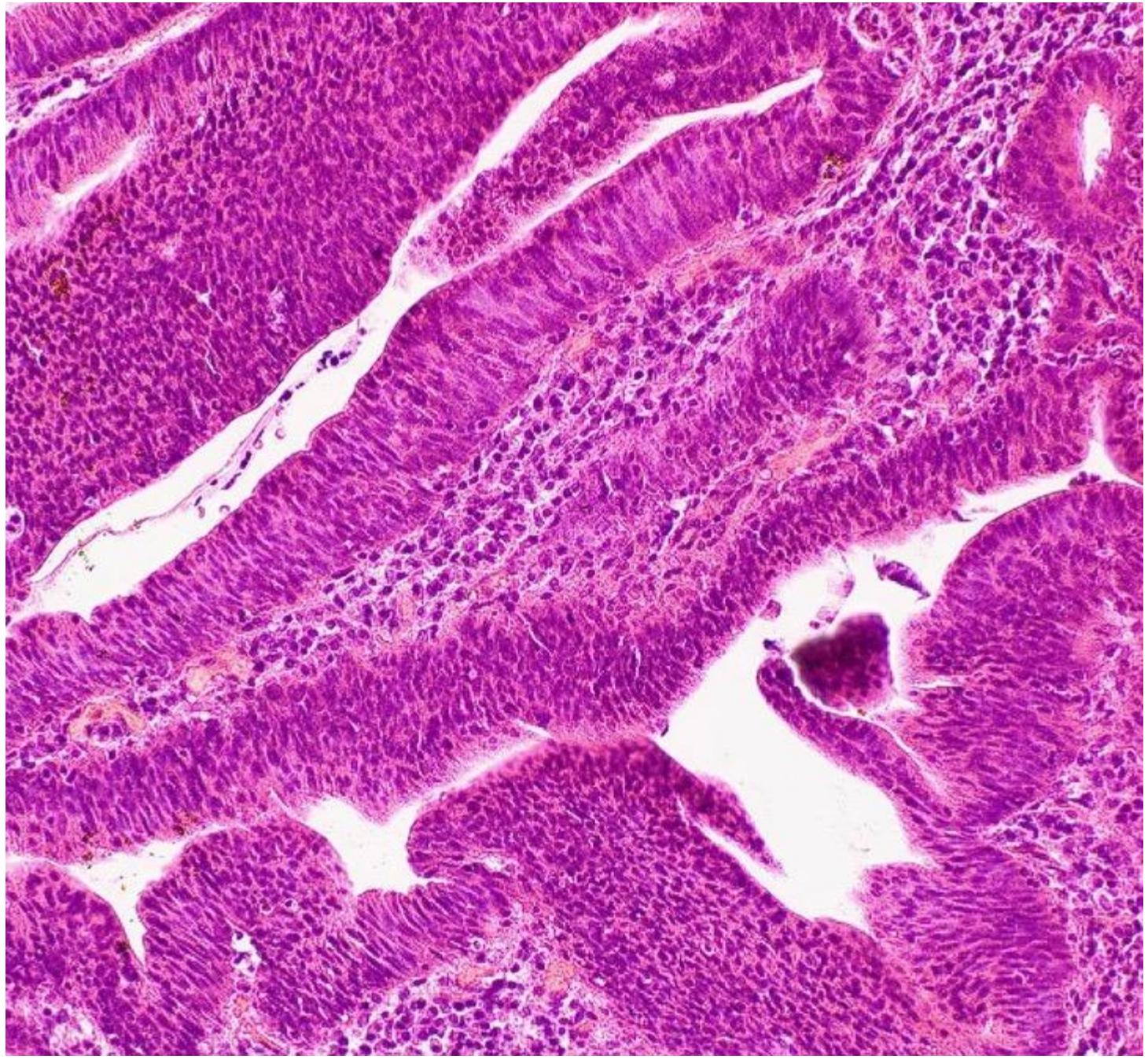

# Reproductive Organ Pathology of Individuals Undergoing Gender-Affirming Surgery

Justin T. Kelley, MD, MPH[a,1], Emily R. McMullen-Tabry, MD[b], Stephanie L. Skala, MD[a,*]

## Benign lesions – what's new?

## Androgen-induced Hyperplastic Prostatic Glands in the Uterine Cervix

Case Report

## Testosterone-induced "Virilization" of Mesonephric Duct Remnants and Cervical Squamous Epithelium in Female-to-Male Transgenders: A Report of 3 Cases

Kamaljeet Singh, M.D., C. James Sung, M.D., W. Dwayne Lawrence, M.D., M.Sc. (Path), and M. Ruhul Quddus, M.D., M.Phil. (Path)

Original Article

## Histologic Features of Hysterectomy Specimens From Female-Male Transgender Individuals

Mahmoud A. Khalifa, M.D., Ph.D., Aimi Toyama, M.D., Molly E. Klein, M.D., and Victor Santiago, M.D.

## Prostatic Metaplasia of the Vagina and Uterine Cervix

*An Androgen-associated Glandular Lesion of Surface Squamous Epithelium*

*William J. Anderson, MBChB,*† David L. Kolin, MD, PhD,† Grace Neville, MB BCh,† David A. Diamond, MD,‡ Christopher P. Crum, MD,† Michelle S. Hirsch, MD, PhD,† and Sara O. Vargas, MD*†*

Histopathology

Histopathology 2022, 80, 946–953. DOI: 10.1111/his.14587

## Surface prostatic metaplasia, transitional cell metaplasia and superficial clusters of small basophilic cells in the uterine cervix: prevalence in gender-affirming hysterectomies and comparison with benign hysterectomies from cisgender women

Emily R McMullen-Tabry,[1] Andrew P Sciallis[2] & Stephanie L Skala[2,3]

[1]*Grand Traverse Pathology, PLLC, Traverse City, MI, USA,* [2]*Department of Pathology, and* [3]*Rogel Cancer Center, University of Michigan, Ann Arbor, MI, USA*

## Histologic Findings in Gynecologic Tissue From Transmasculine Individuals Undergoing Gender-Affirming Surgery

*Lawrence Hsu Lin, MD, PhD; Andrea Hernandez, DO; Alan Marcus, MD; Fang-Ming Deng, MD, PhD; Esther Adler, MD*

# Androgen associated prostatic metaplasia vagina

Prostatic Metaplasia of the Vagina and Uterine Cervix

*An Androgen-associated Glandular Lesion of Surface Squamous Epithelium*

William J. Anderson, MBChB,*† David L. Kolin, MD, PhD,† Grace Neville, MB BCh,† David A. Diamond, MD,‡ Christopher P. Crum, MD,† Michelle S. Hirsch, MD, PhD,† and Sara O. Vargas, MD*†

*AJSP 2020*

Histologic Findings in Gynecologic Tissue From Transmasculine Individuals Undergoing Gender-Affirming Surgery

*Arch Path Lab Med 2022*

Lawrence Hsu Lin, MD, PhD; Andrea Hernandez, DO; Alan Marcus, MD; Fang-Ming Deng, MD, PhD; Esther Adler, MD

Transgender, female to male, n=23;
Gender reassignment surgery following long-term testosterone; median 26-27 yrs

**Prostatic glands basal squamous epithelium, 74%**
**Squamous cells AR and NKX3.1 positive supporting androgen-driven metaplasia**
**Most also had "transitional metaplasia"**

**NKX3.1 & AR** 100%, **PSA** 69%
**ER/PAX8** neg
AR+ in squamous and stromal cells

Benign clinical course

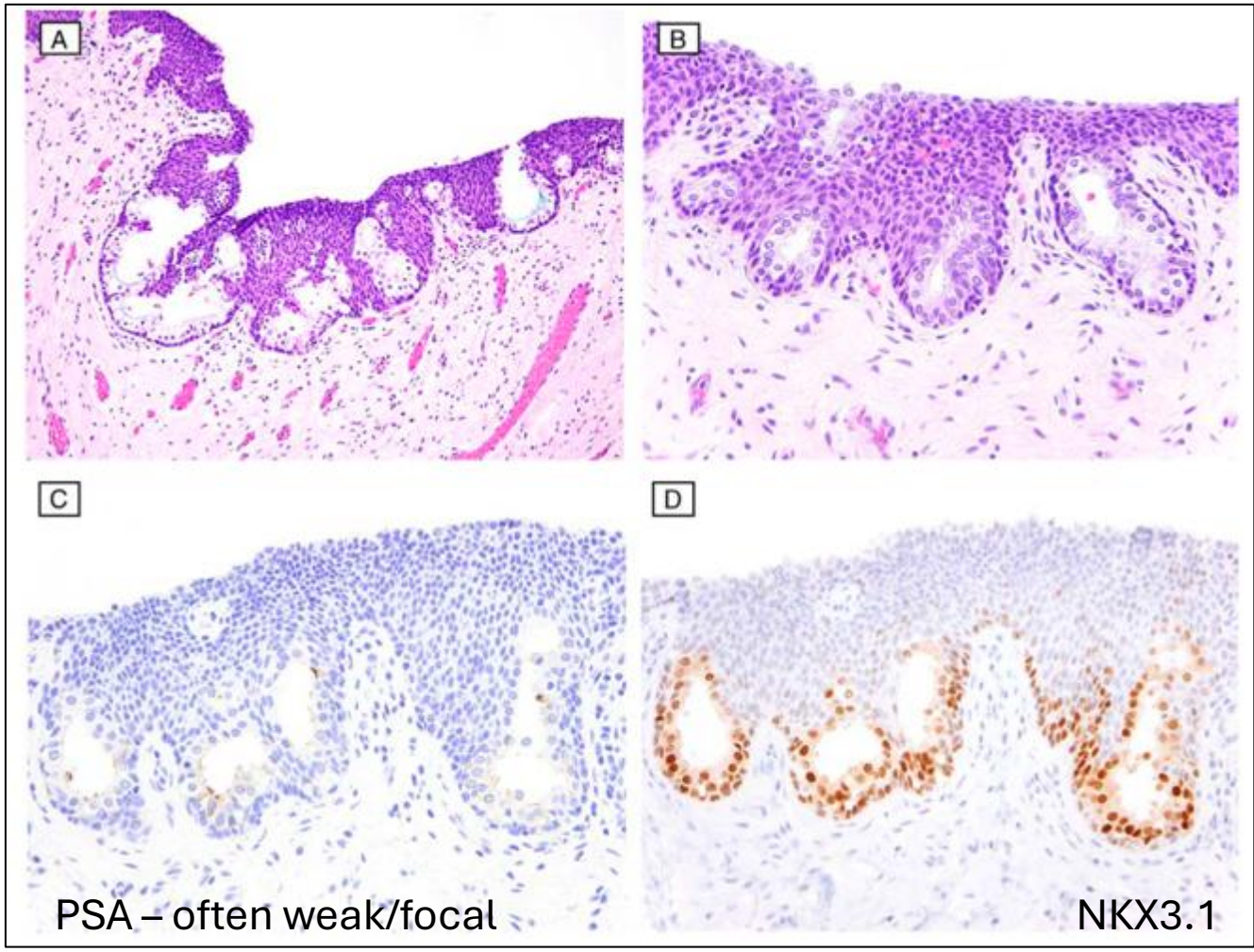

# Prostatic-type tissue in FGT
## (without androgen therapy/excess)

**Skene's glands:** Hyperplasia, cyst, rare adenoca

**Ectopic prostate tissue cervix**

**Tubulosquamous polyp vagina**

Similar morphology

- Glands and squamous elements - may predominate
- Double cell layer (at least focally)

Explanations proposed:
- Embryologically misplaced periurethral Skene's glands?
- Metaplasia of endocervical glands??




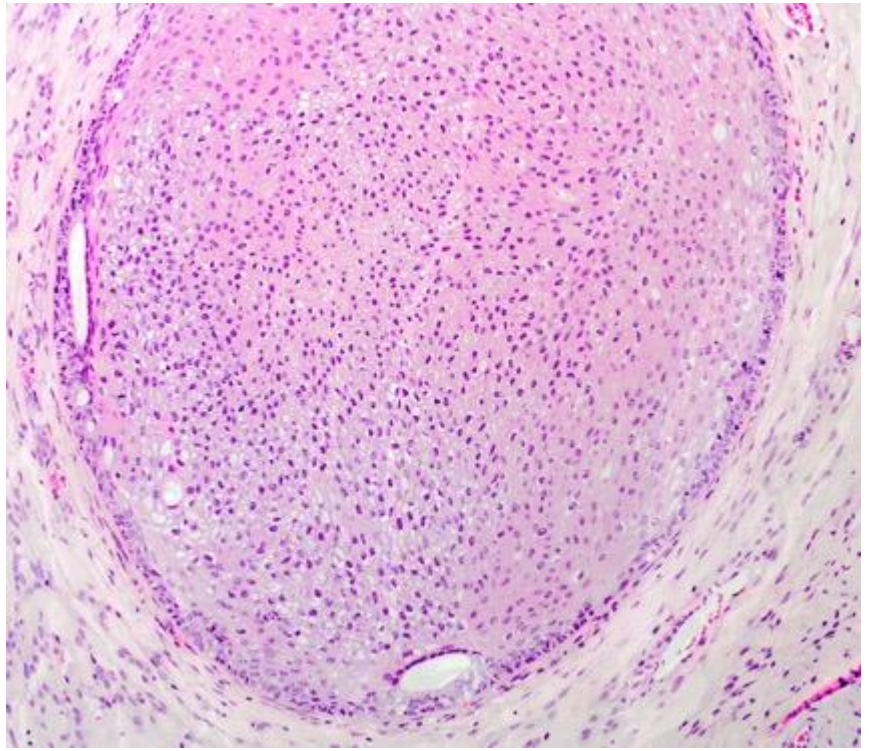

*Kelly IJGP 2011, Stewart Pathol 2021;53:193-198; Roma Ann Diagn Pathol 2016;, Hawari IJGP 2021, McMullen-Tabry Histopathol 2022*

# Tubulosquamous polyp

Upper vagina, usually post-menopause
First described 2007 by Glenn McCluggage

- Polypoid, surface squamous epithelium
- Stromal squamous nests with tubular prostatic-type glands, often a minor component at the periphery of squamous lobules
- Rare: Sebaceous glands, basaloid hair follicle-like structures

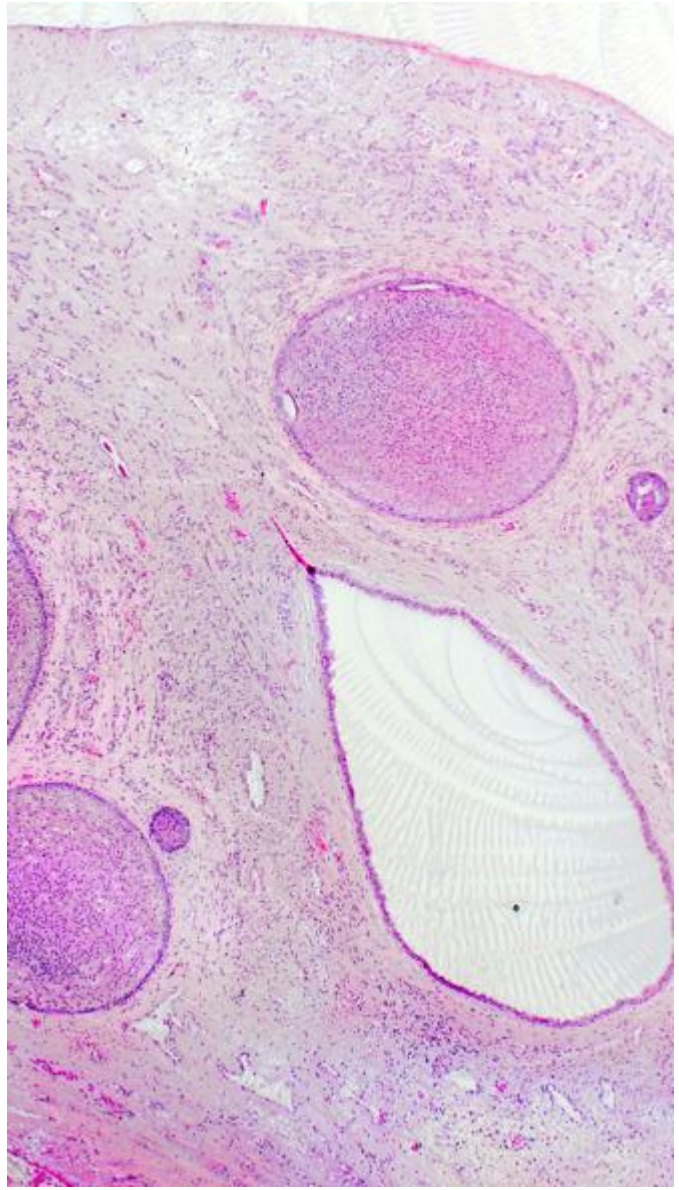

*McCluggage Am J Surg Pathol 2007;31:1013–1019; Stewart Pathol 2021;53:193-198; Roma Ann Diagn Pathol 2016;22:63-66; Harwari IJGP 2021;40:400-407*

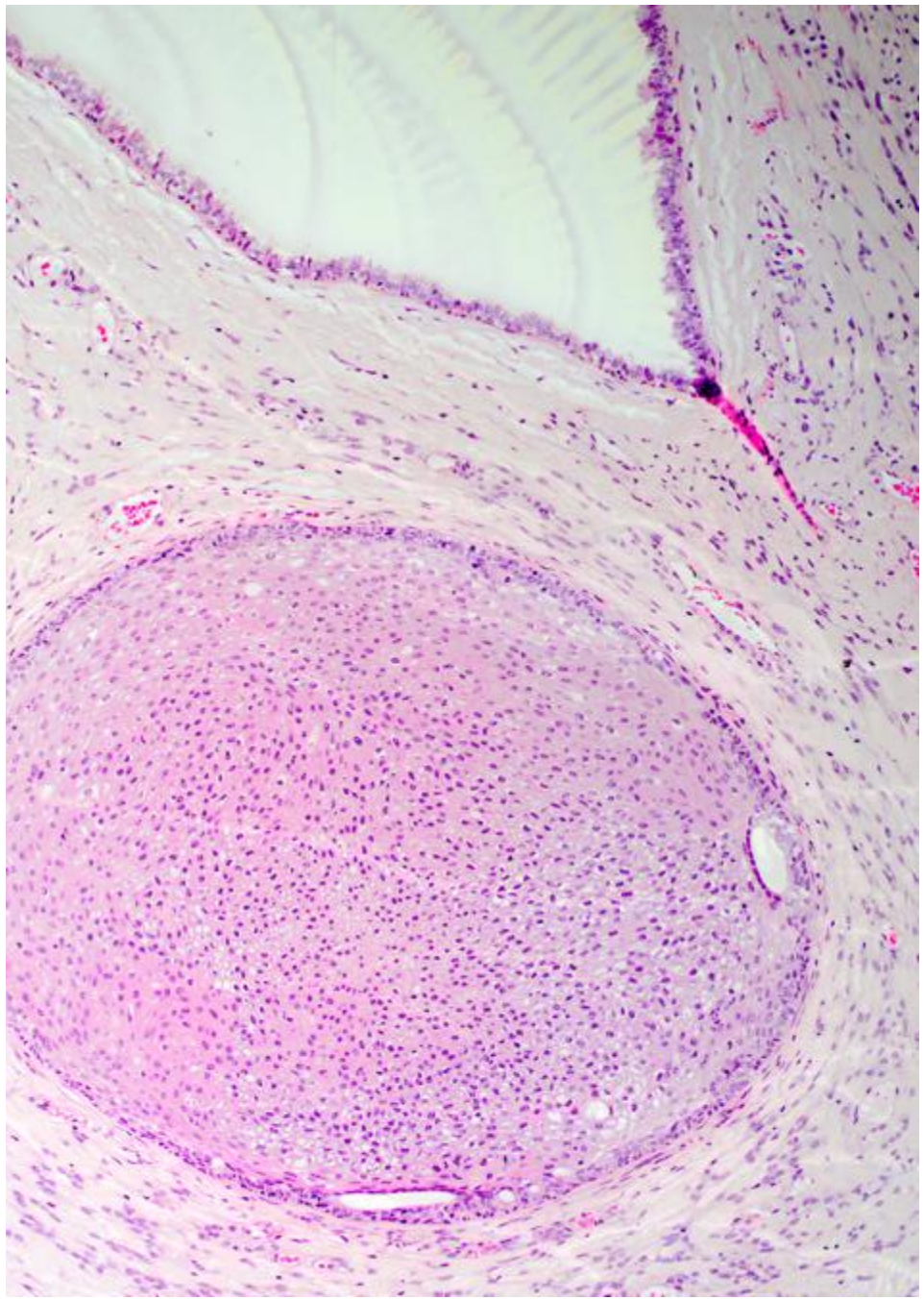

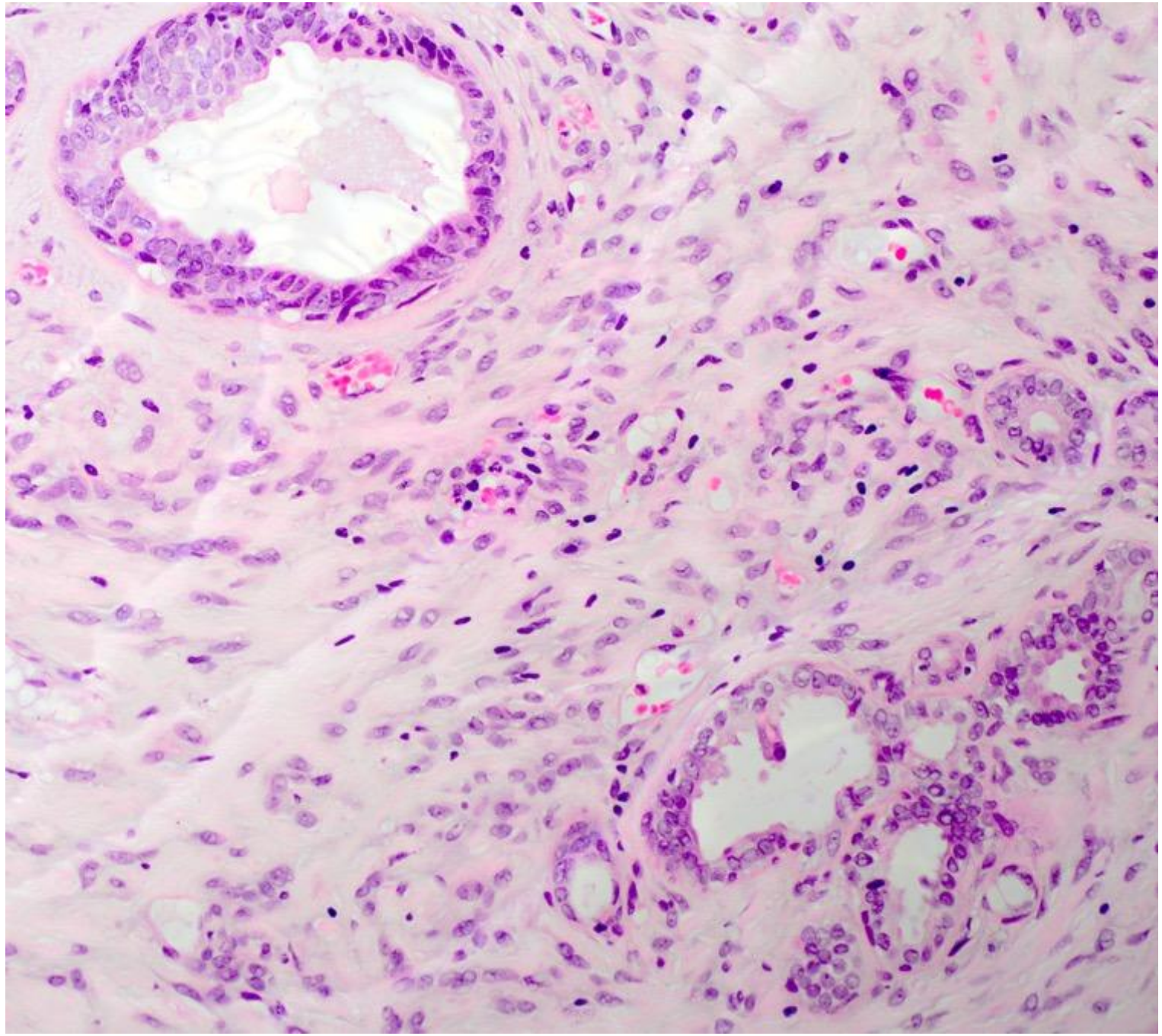

# Summary

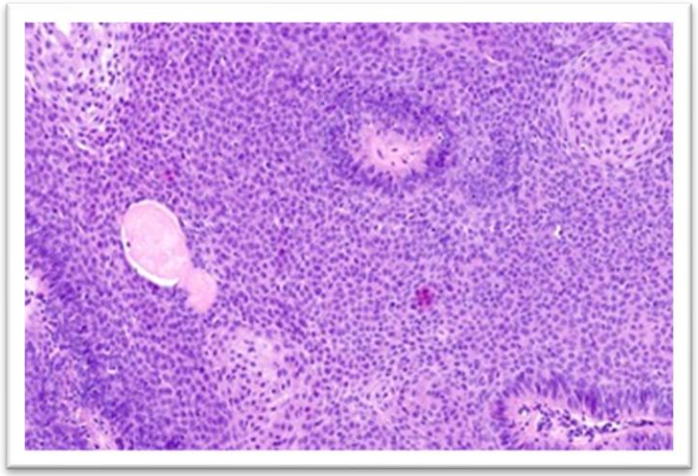

- HPV genotype-phenotype associations are still incompletely understood; perform HPV testing on novel lesions
- LRHPV is occasionally associated with pre/neoplasia

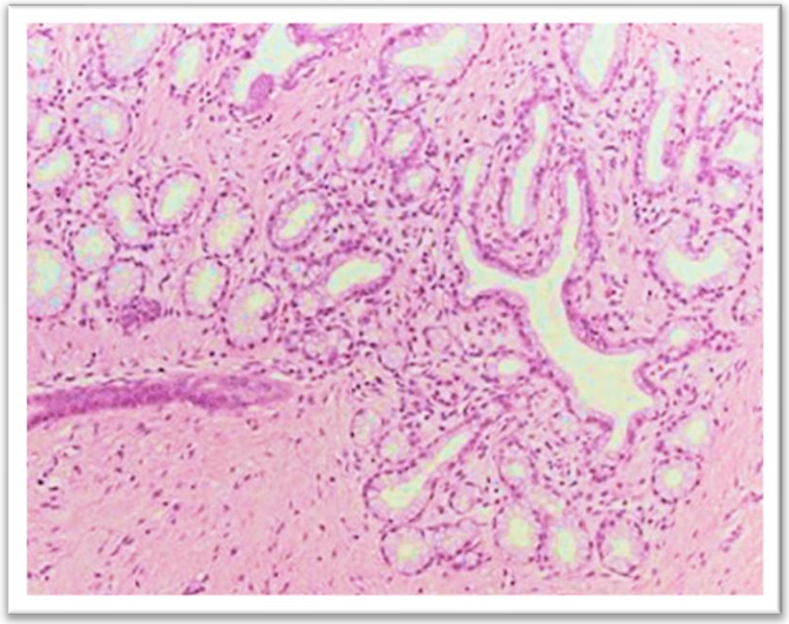

- Vaginal gastric type adenosis and carcinoma is now recognised
- Diagnosis requires a combination of morphology and IHC; gastric type markers are not essential
- Must exclude a cervical primary before make this diagnosis

# Summary

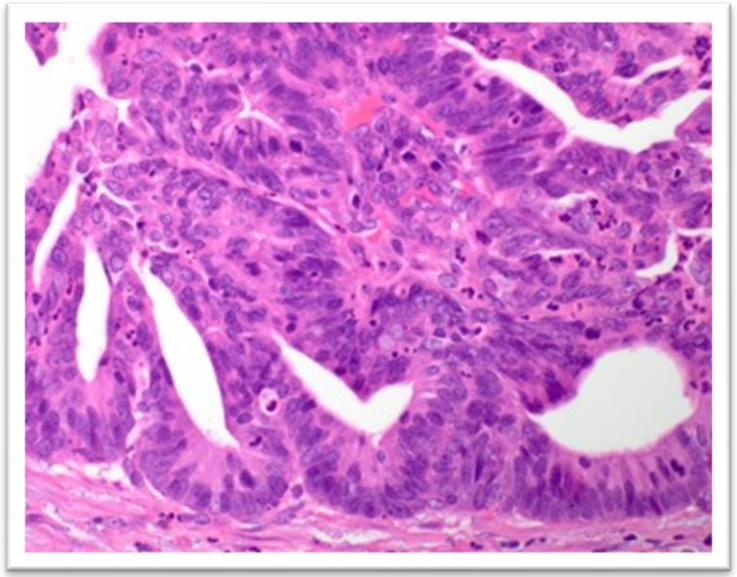

Most adenocarcinoma in the vagina is metastatic

Must exclude metastasis before diagnose 1° vaginal adenocarcinoma

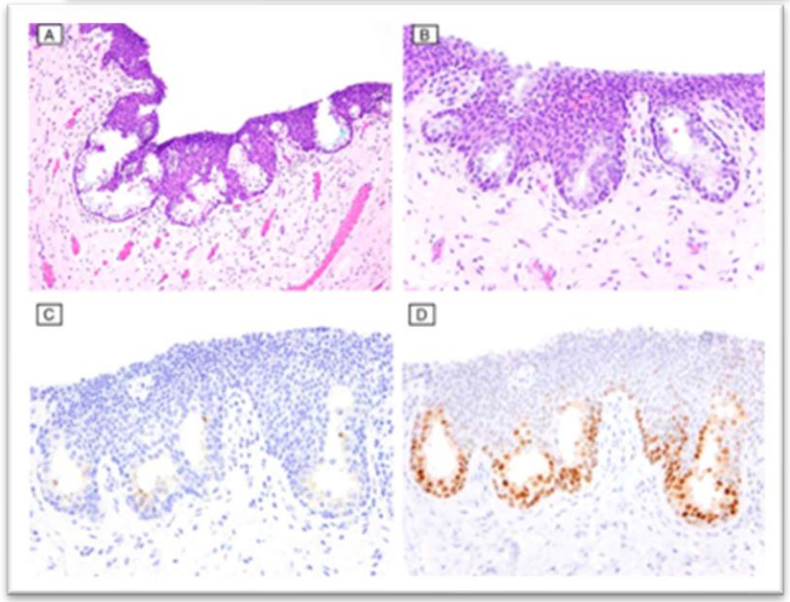


Androgen-induced changes in female-male transgender patients are now well characterised

# Thank you!

Acknowledgements
Glenn McCluggage
Richard Wong

