The British Association of Gynaecological Pathologists



Lecturer – L. Hoang

Consultant Pathologist, Vancouver General Hospital

Clinical Assistant Professor, University of British Columbia, Canada

The British Association of Gynaecological Pathologists

Everyday Dilemmas in Gynaecological Pathology

- Tubal pathology – STIC, STIL and p53 signature
- L. Hoang
- Consultant Pathologist, Vancouver General Hospital
- March 7, 2025

The British Association of Gynaecological Pathologists

Speaker disclosures

Choose one

I have no financial conflicts of interest to disclose

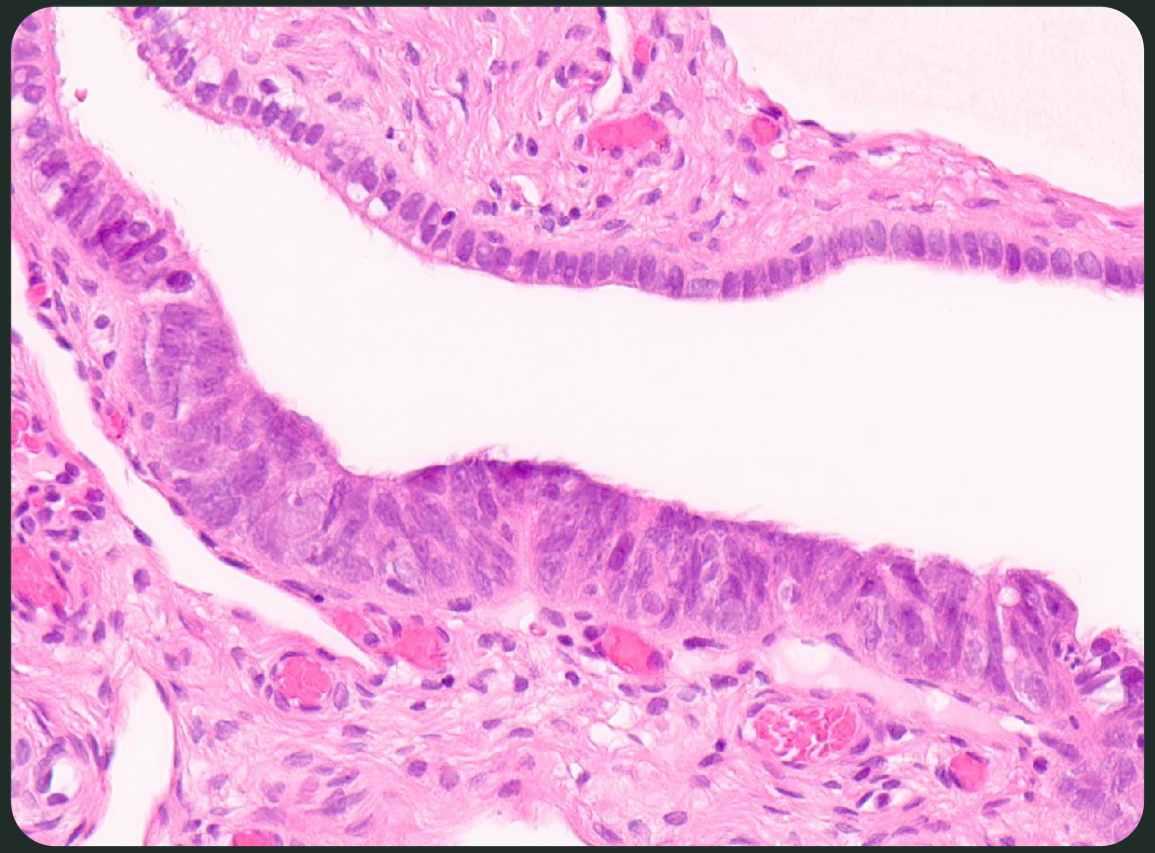

TUBAL PATHOLOGY

STIC, STIL and p53 signatures

L. Hoang

BAGP, March 2025

Overview

Review STIC cases

Diagnostic Criteria | ❶
Treatment | ❷
Prosectioning | ❸
Pathogenesis | ❹
Staging | ❺
STIL and related lesions | ❻

Overview

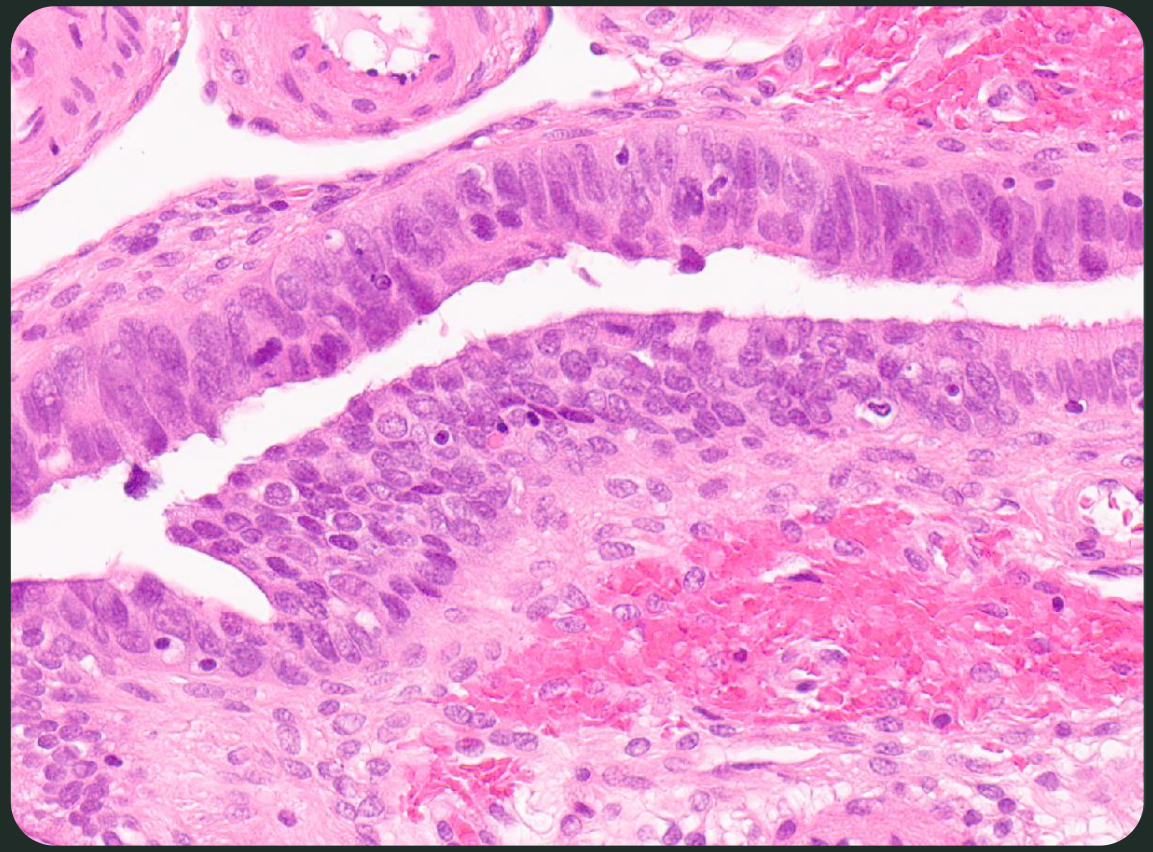

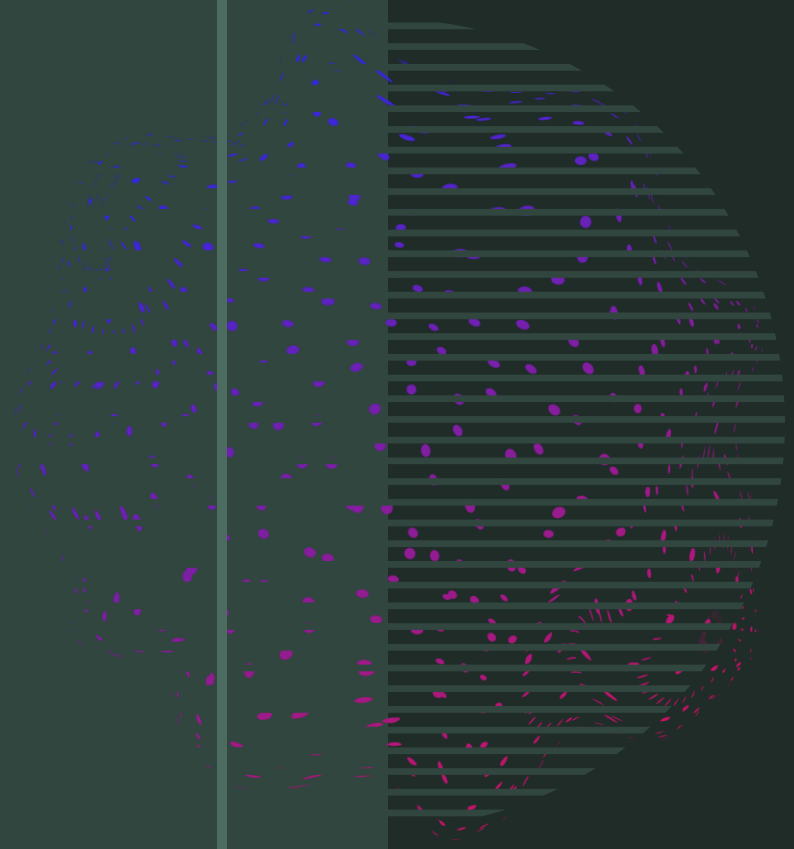

Case 1

50yo known *BRCA2* mutation carrier

FHx of breast, ovarian, colon cancers, melanoma

Risk-reducing bilateral salpingo-oophorectomy

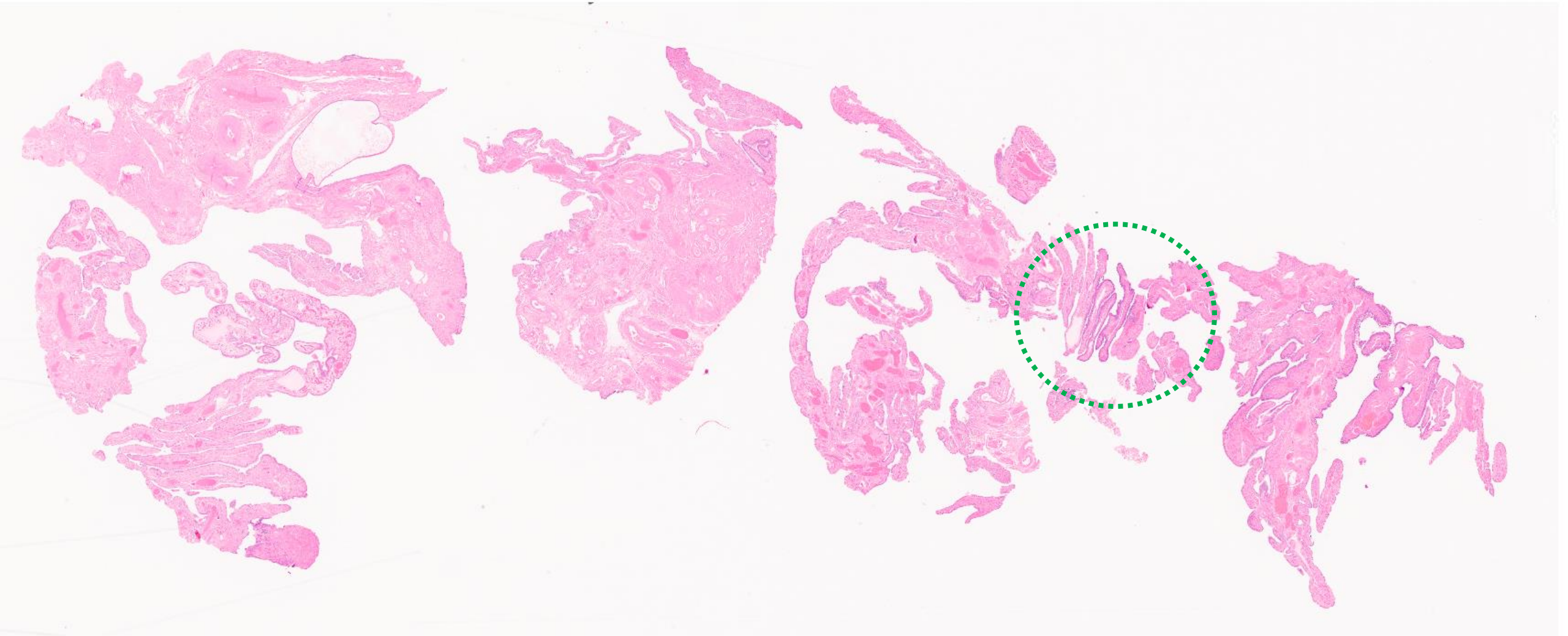

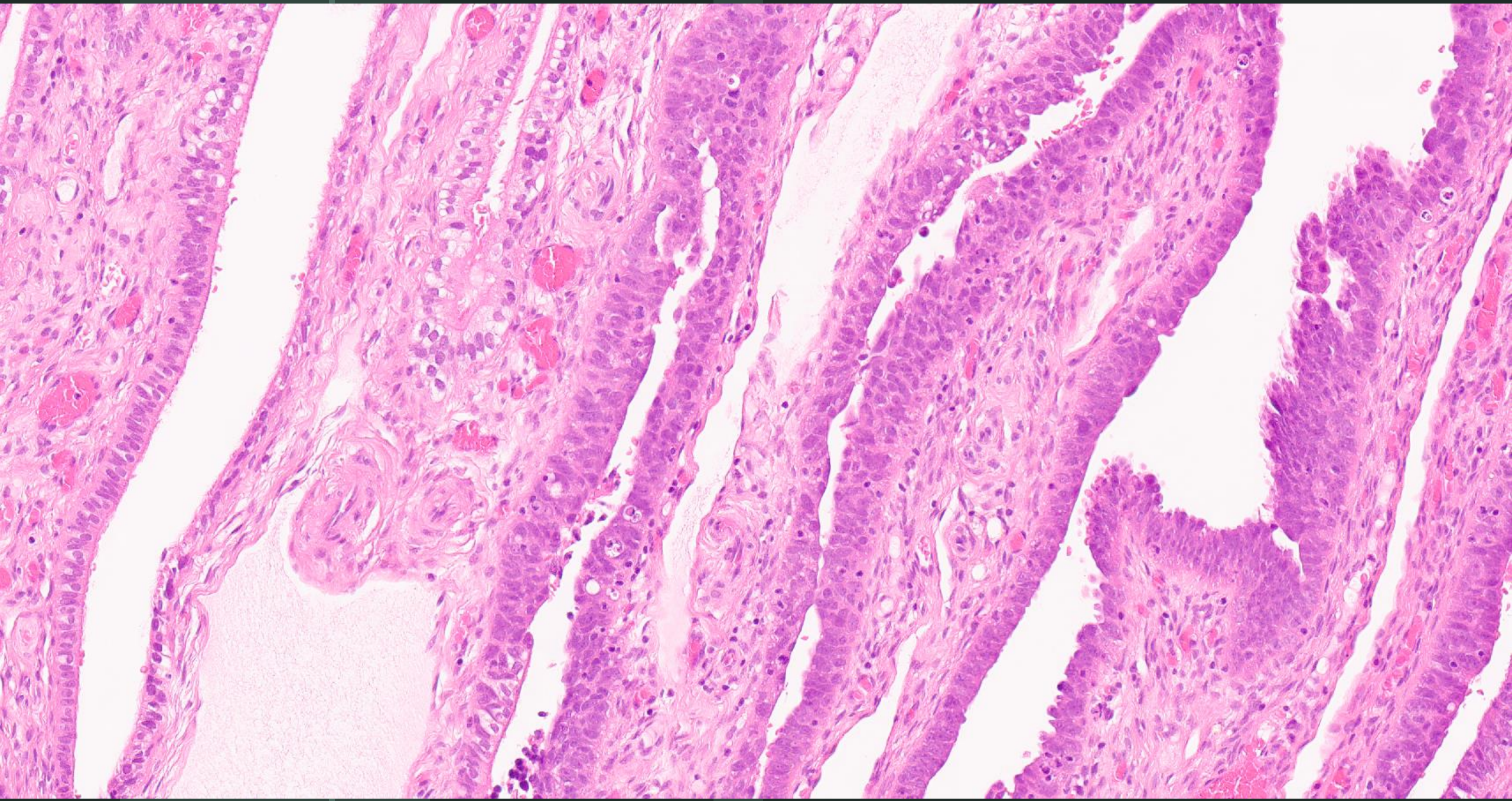

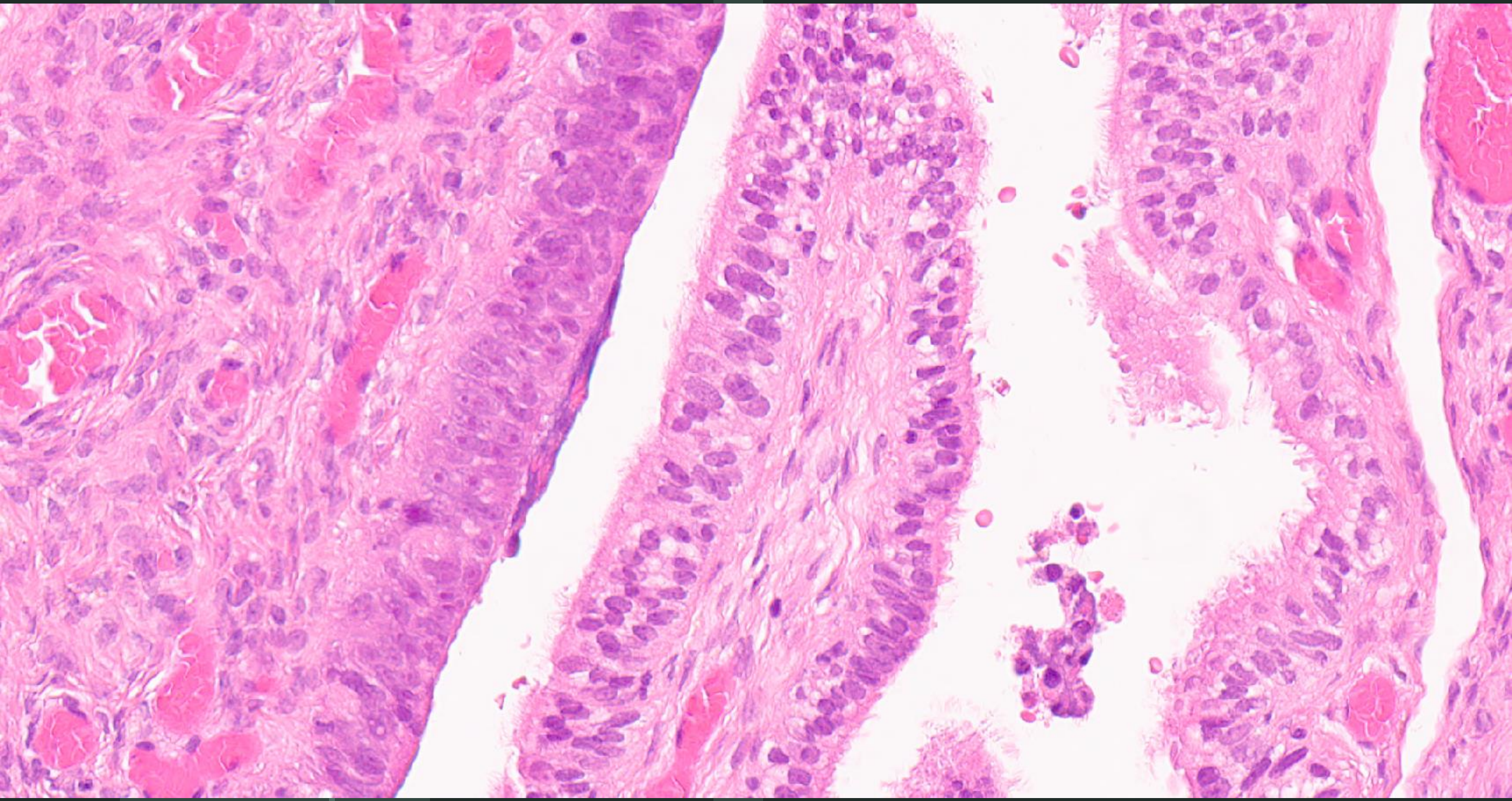

p53



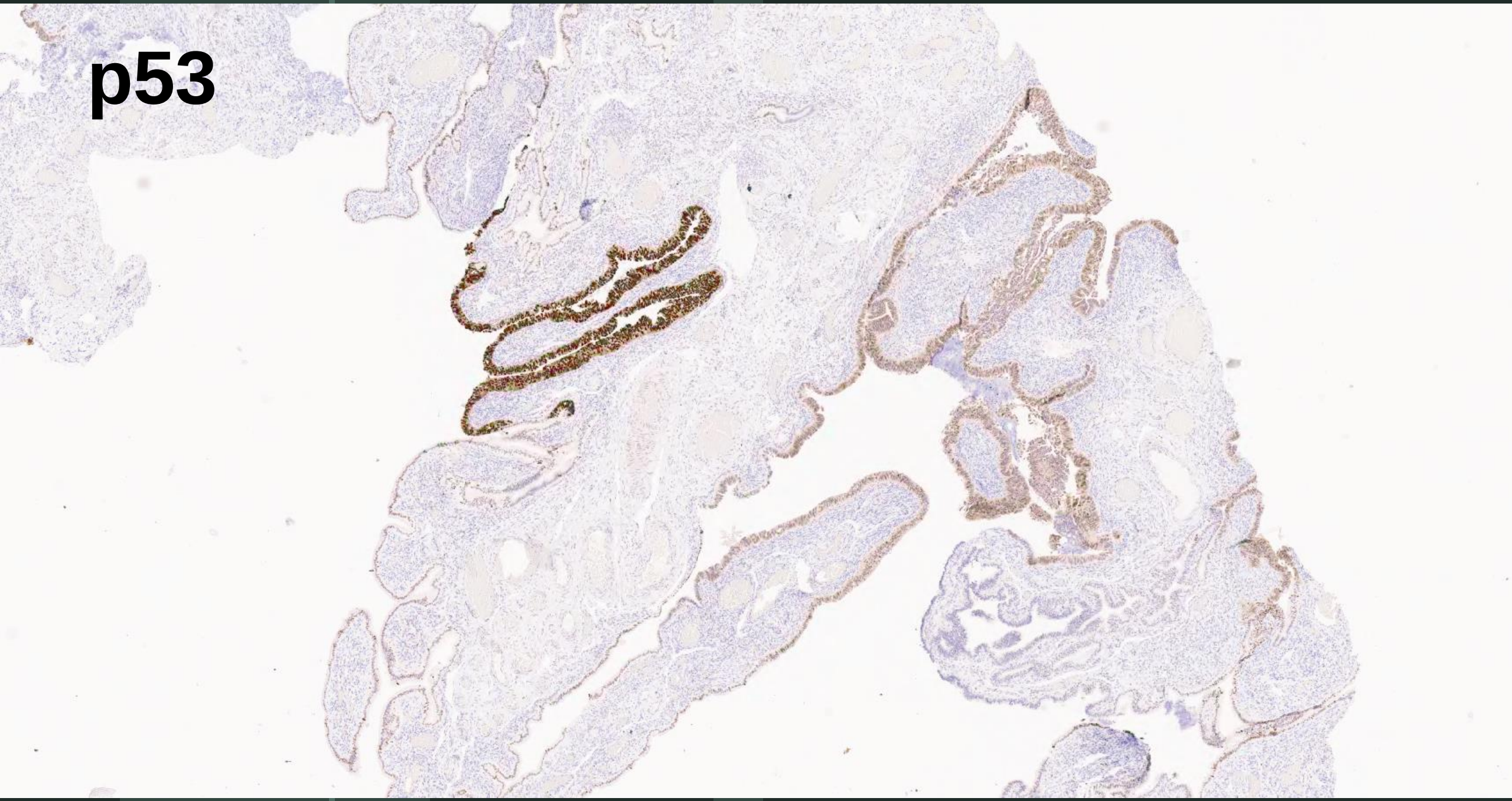
p53

p53

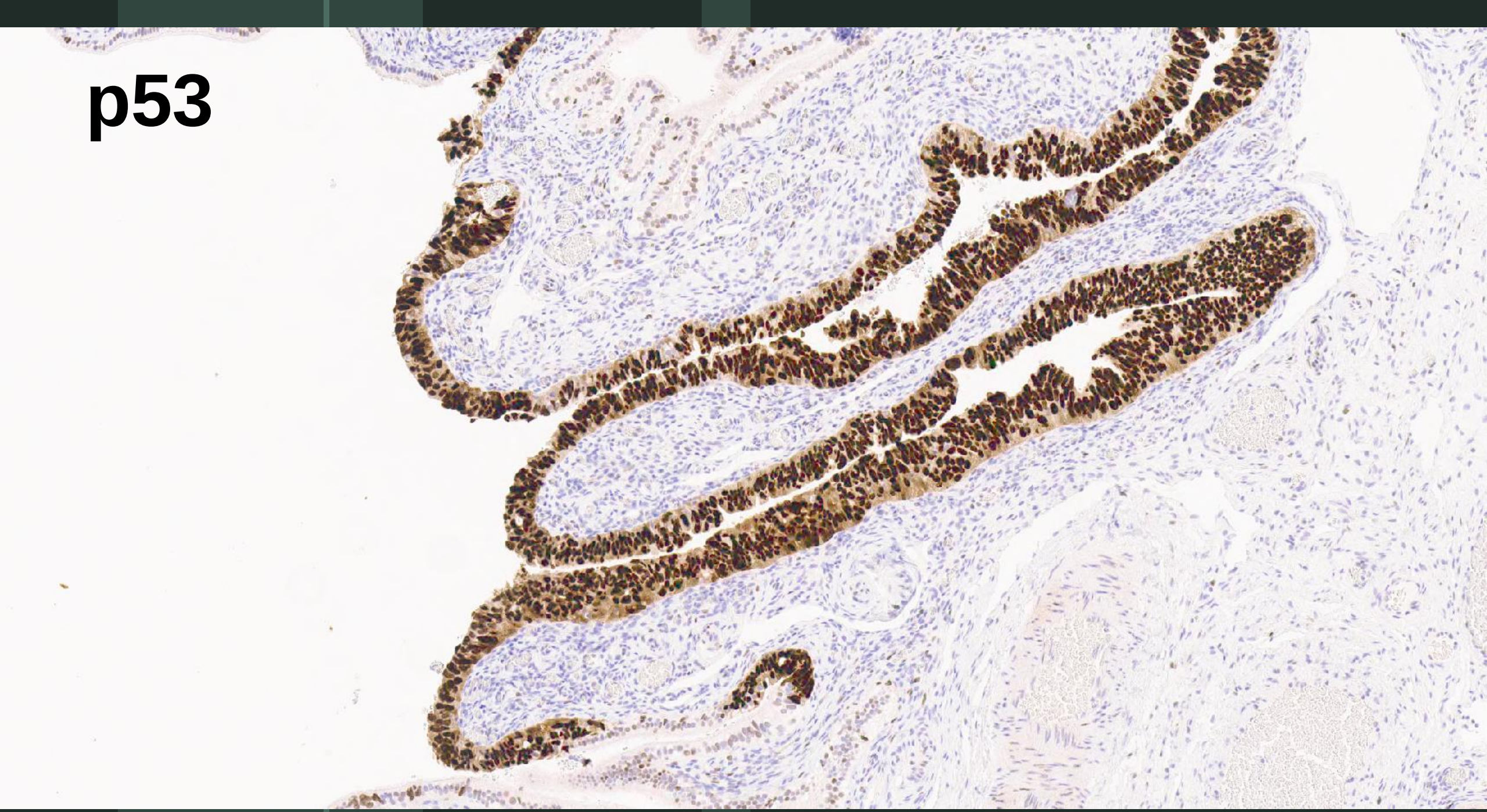

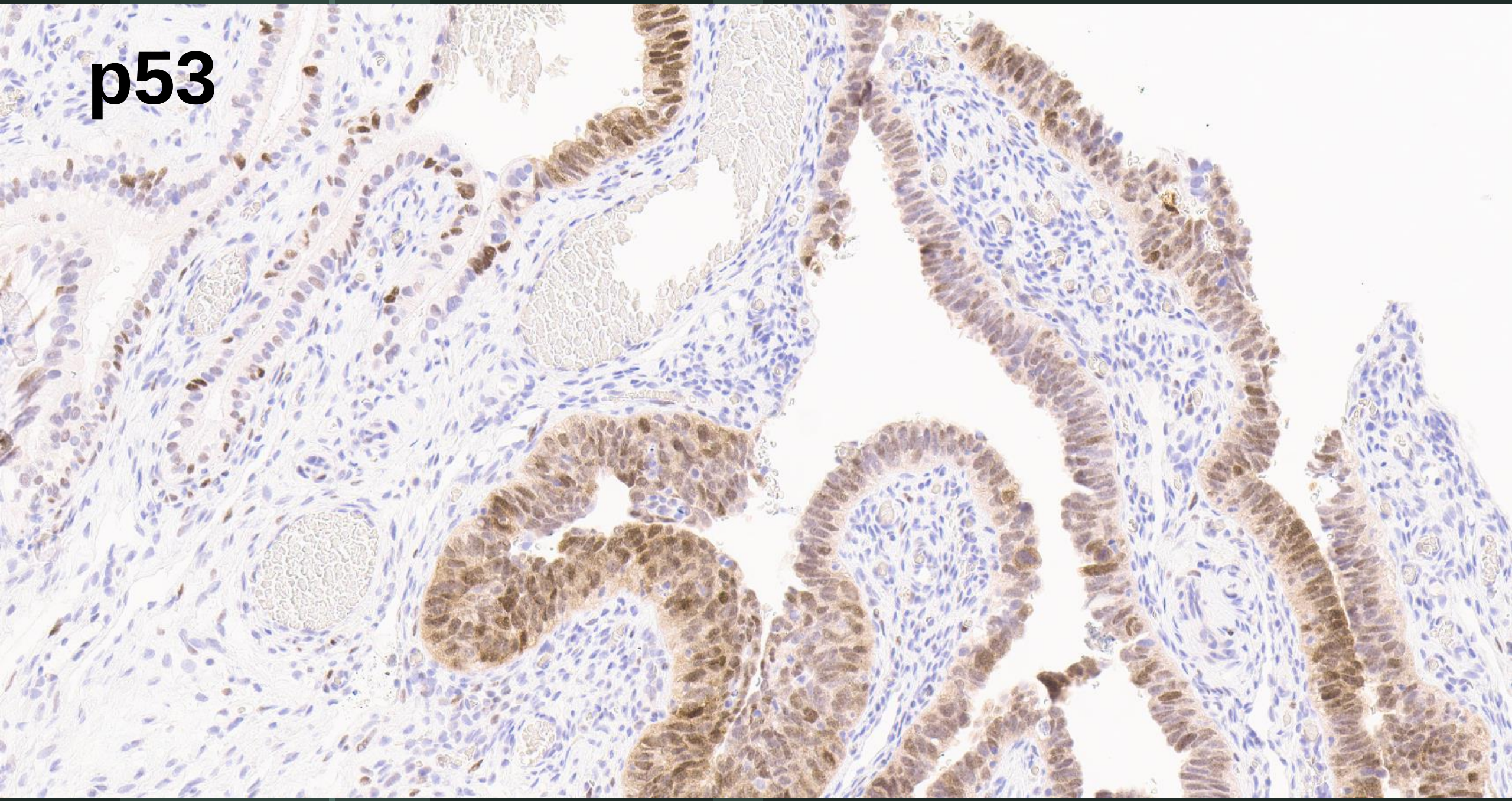
p53

Ki67

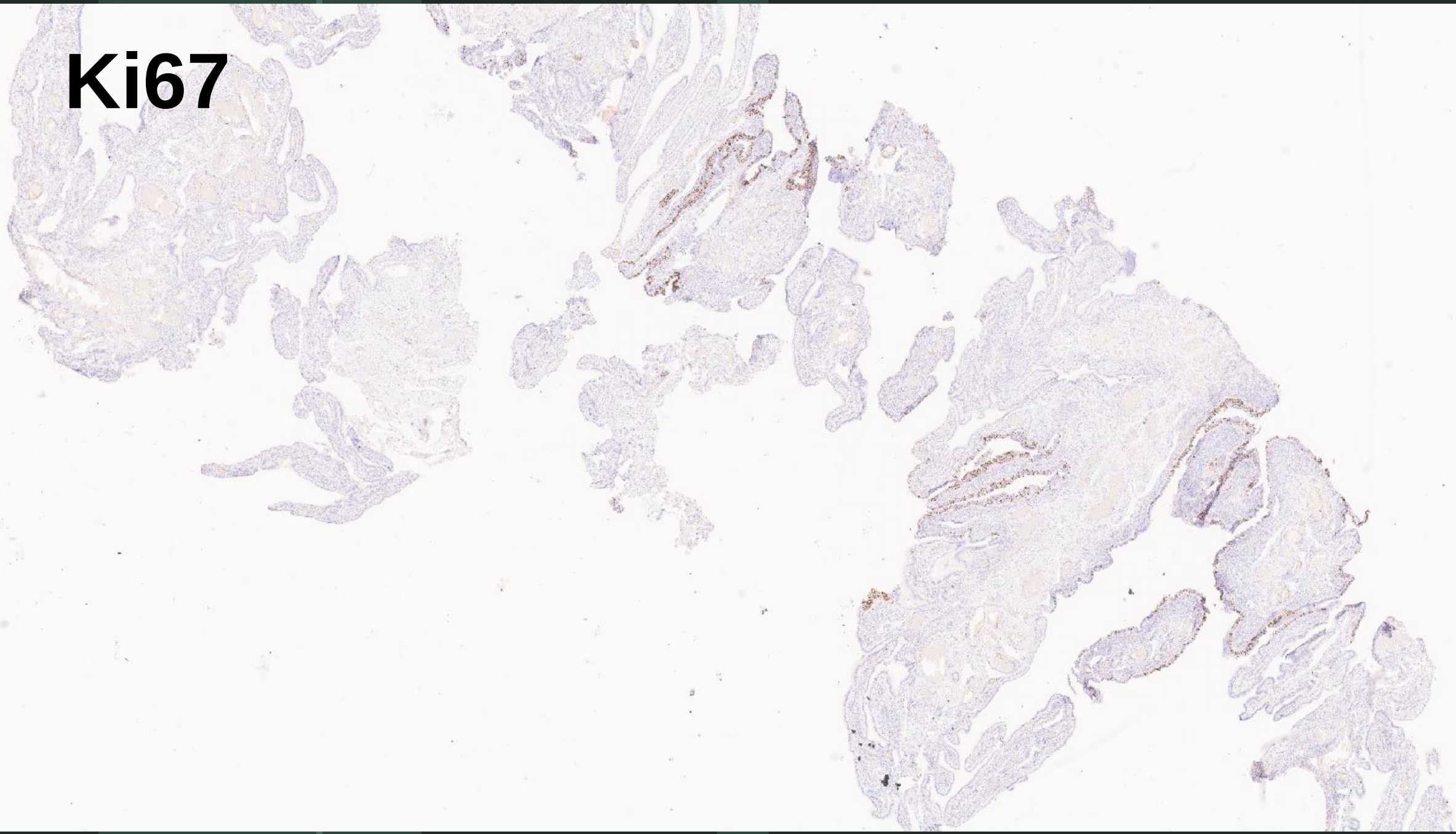

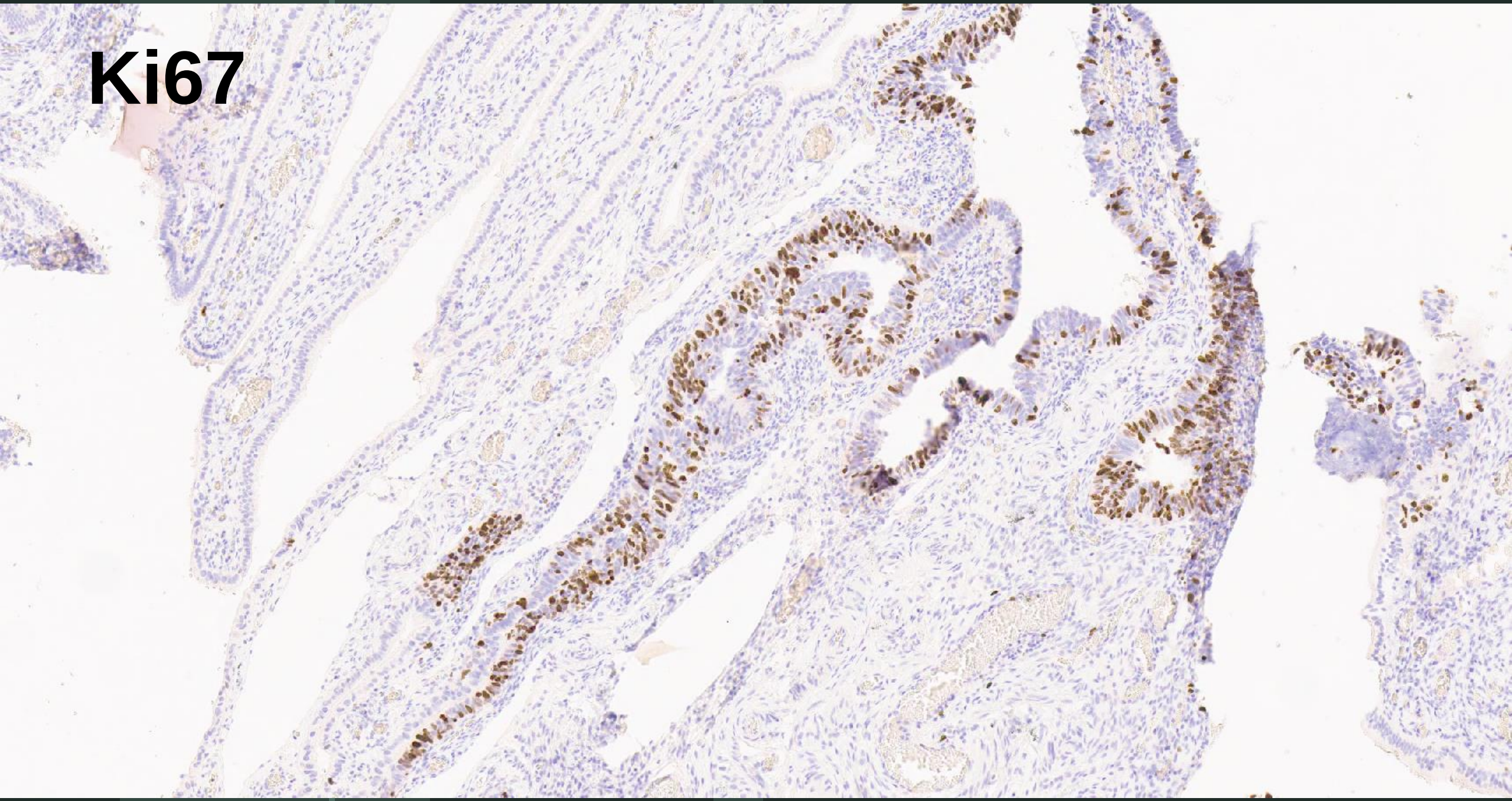
Ki67

What is STIC?

and

What are the minimum diagnostic criteria for STIC?

Dx: STIC

Has surgical staging (hysterectomy, omental biopsy, pelvic washings)
→ All negative

Undergoes surveillance

7 years later, develops breast cancer

Definition

- STIC = Serous tubal intraepithelial carcinoma
  - Precursor to tubo-ovarian high-grade serous carcinoma

Prevalence

- STIC is a rare finding
  - <0.1% of the general population
  - ~2-10% of women at high risk of HGSC (e.g. BRCA carriers)
  - ~50% of HGSC

Ruel-Laliberte 2022; PMID: 36099965; Colombi 2024; PMID: 39274288

Diagnostic Criteria

- WHO 5th Criteria:
  1) Abnormal morphologic features
  2) Aberrant p53 expression (>75% strong or moderate to complete absence)
  3) Increased Ki67 immunostaining (>10%)
  4) In at least 12 cells

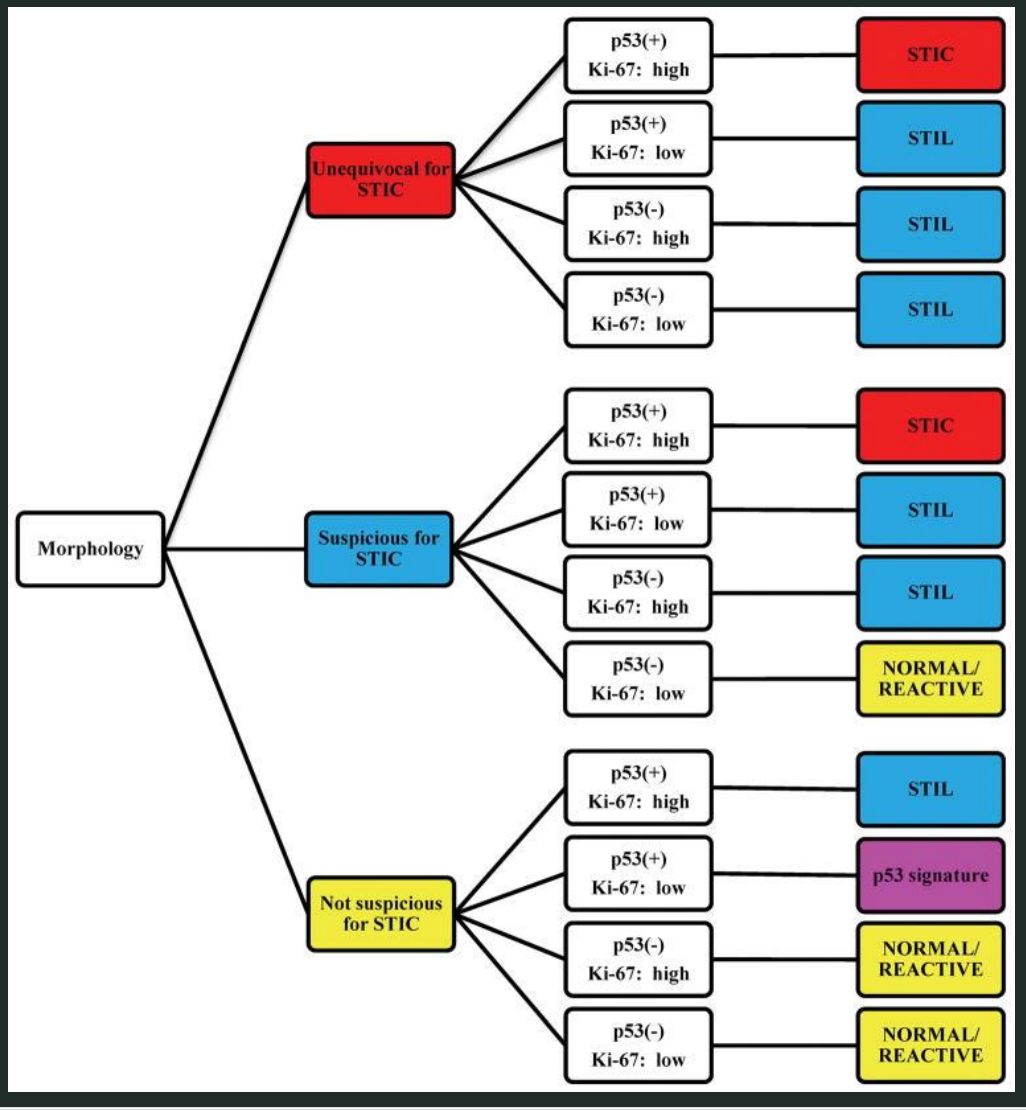

Vang/Kurman 2012; PMID: 22498942

Diagnostic Criteria

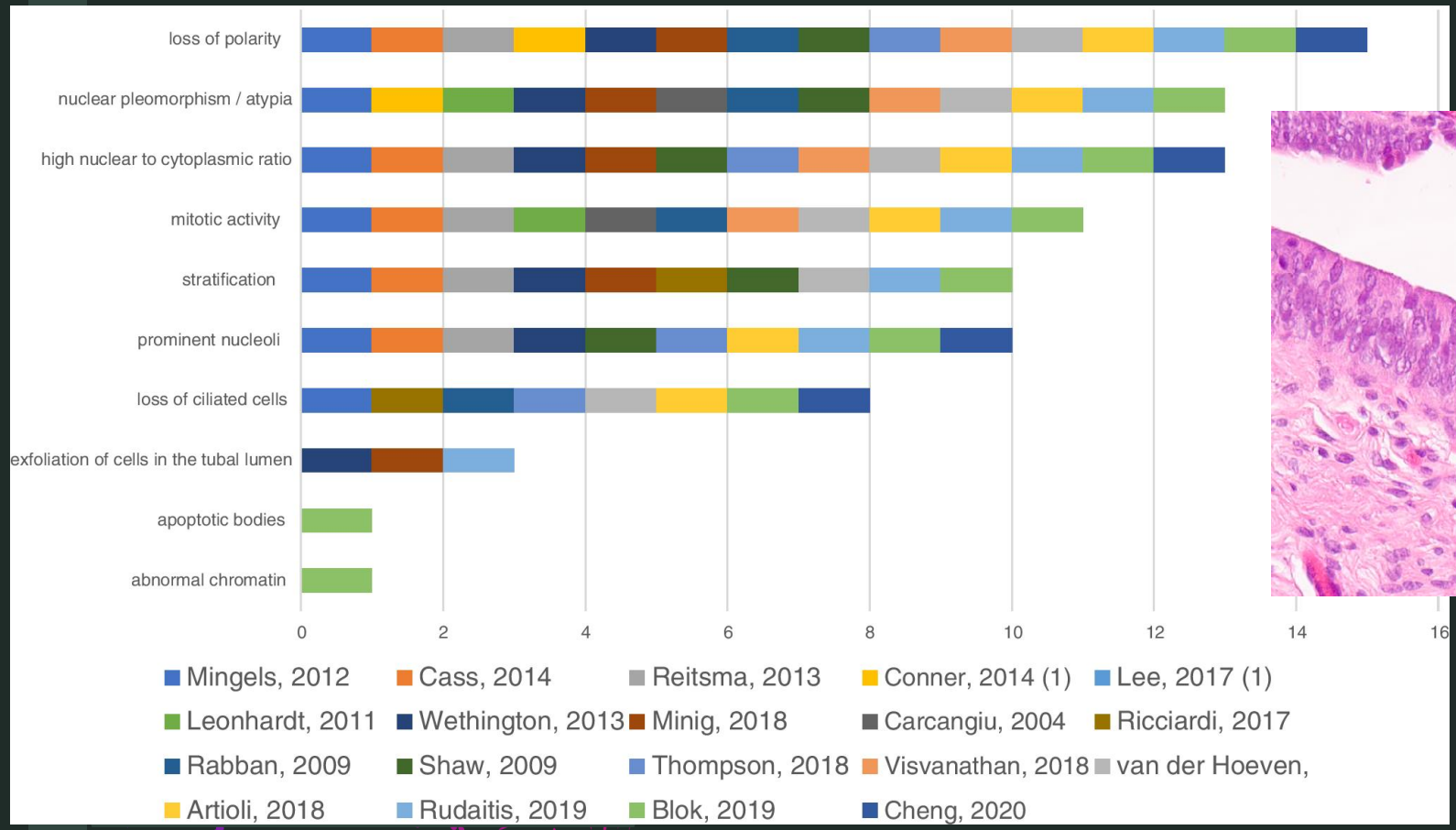

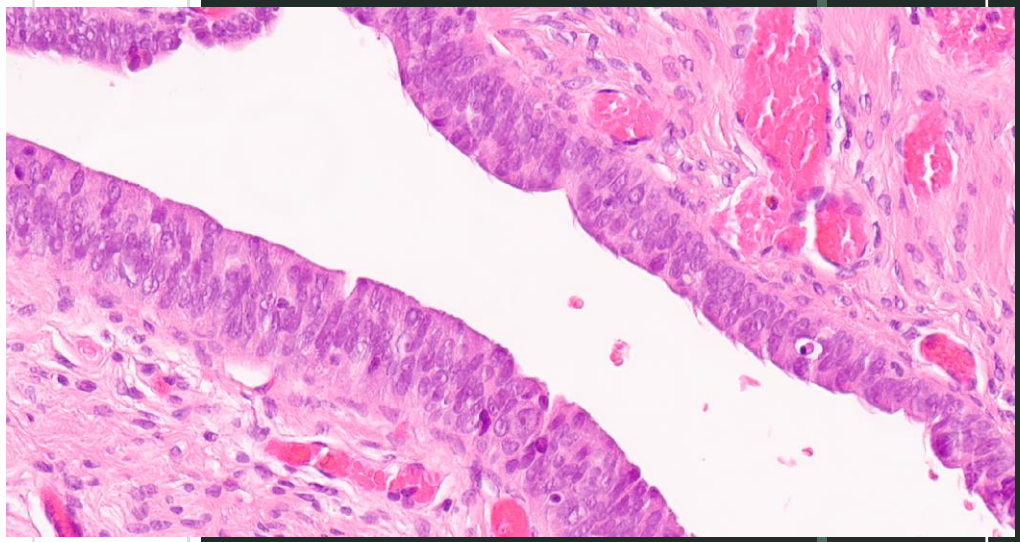

Bogaerts PMID: 34850262

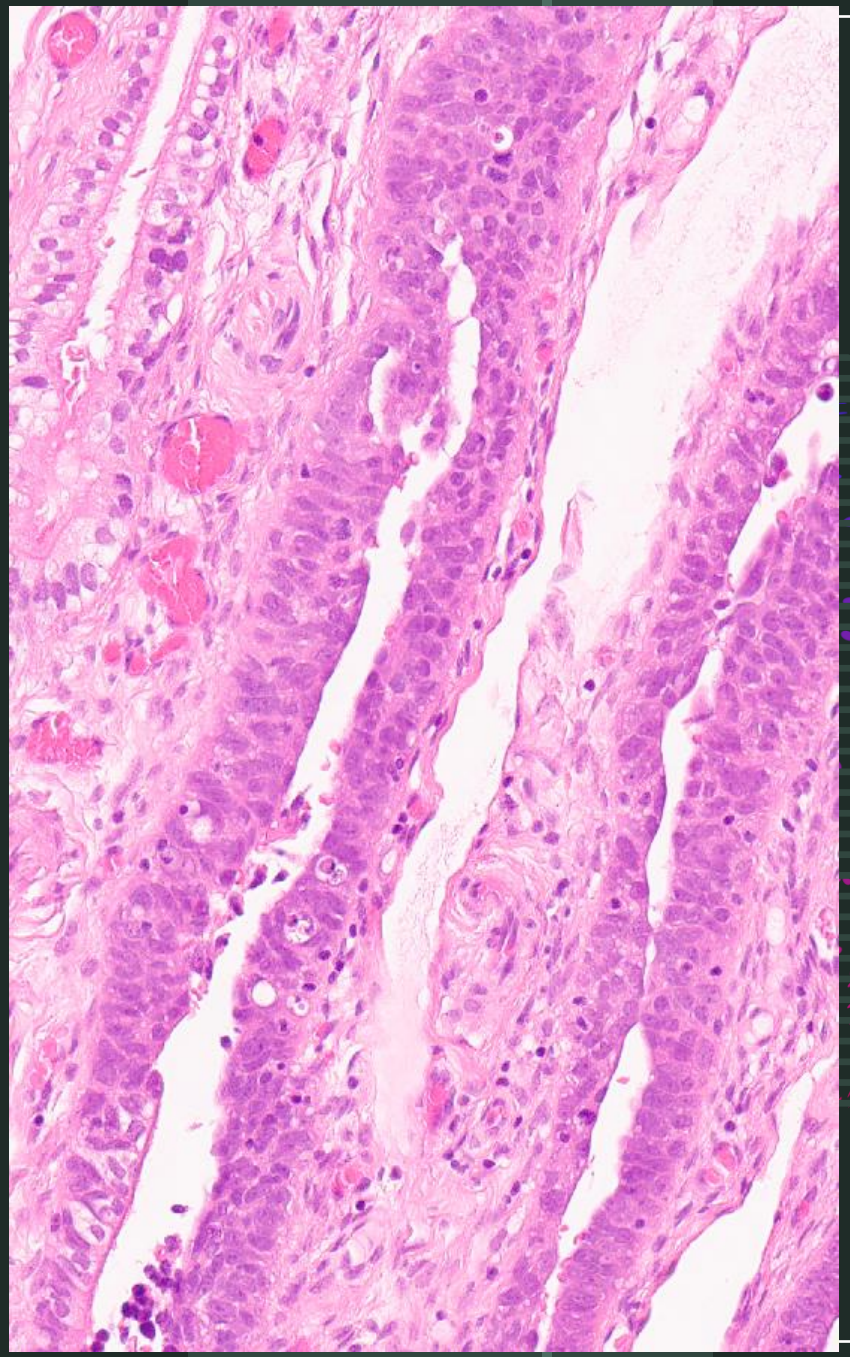

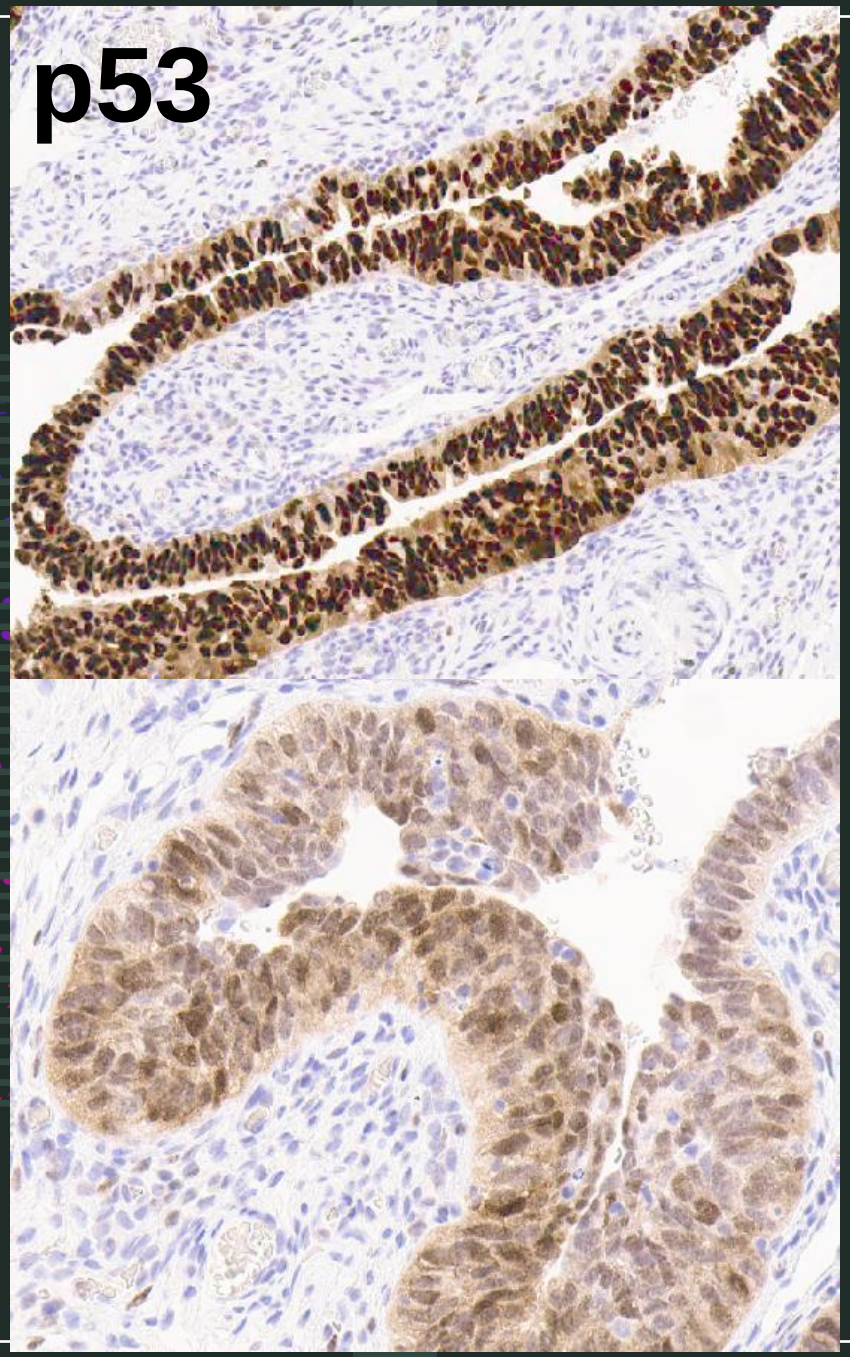
p53

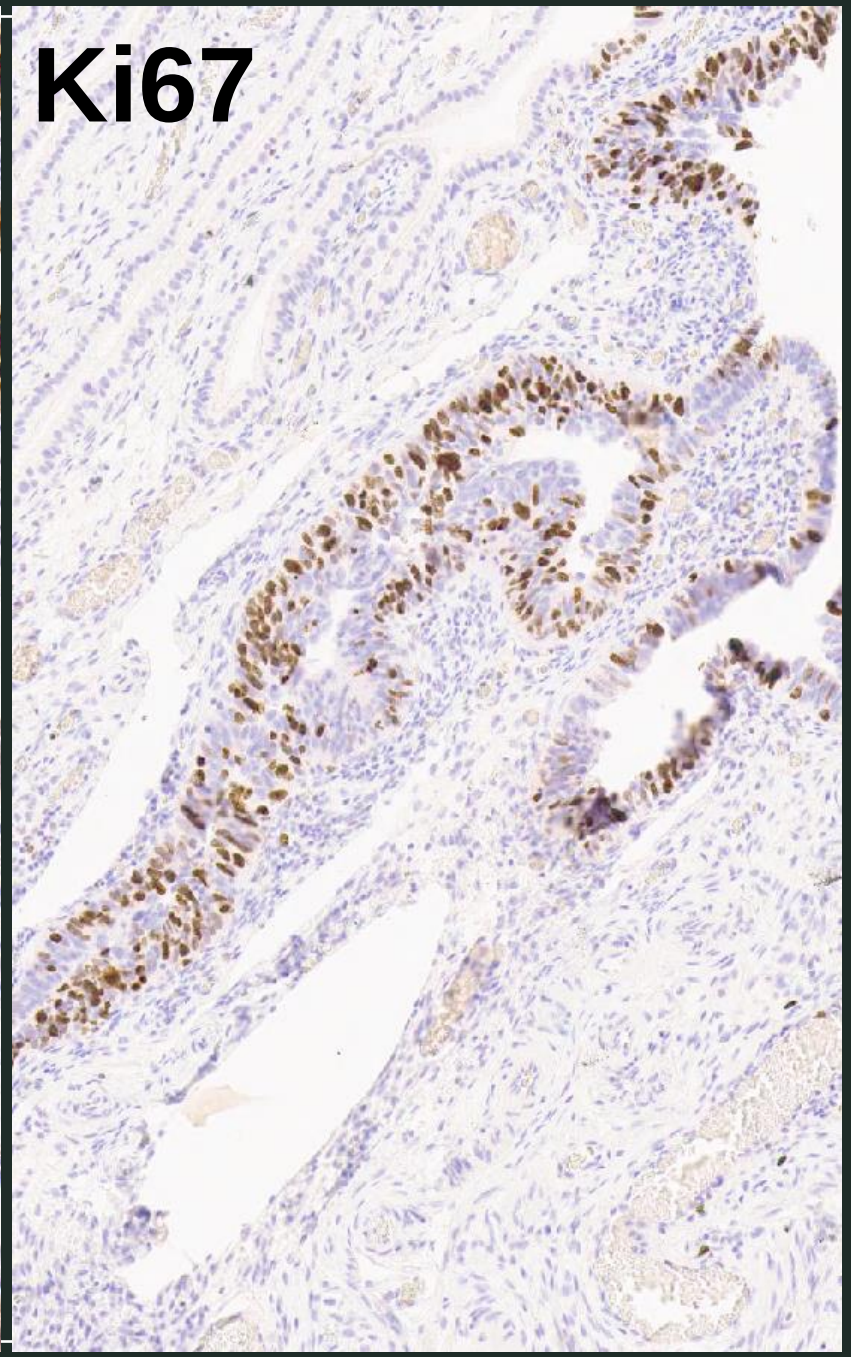
Ki67

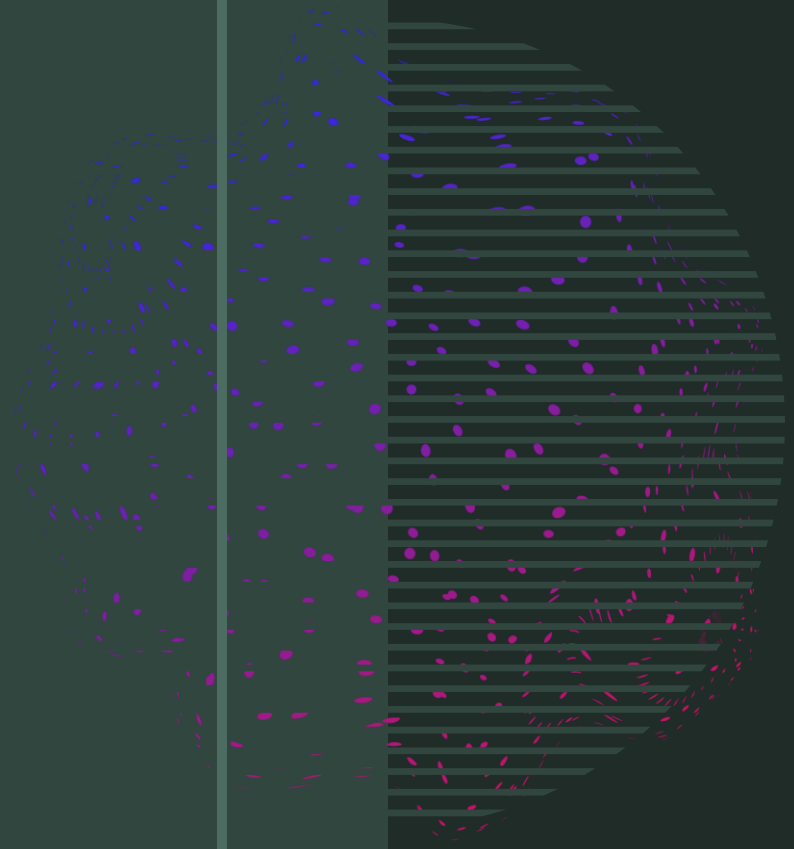

Case 2

39 yo has a C-section

Opportunistic salpingectomy for permanent contraception

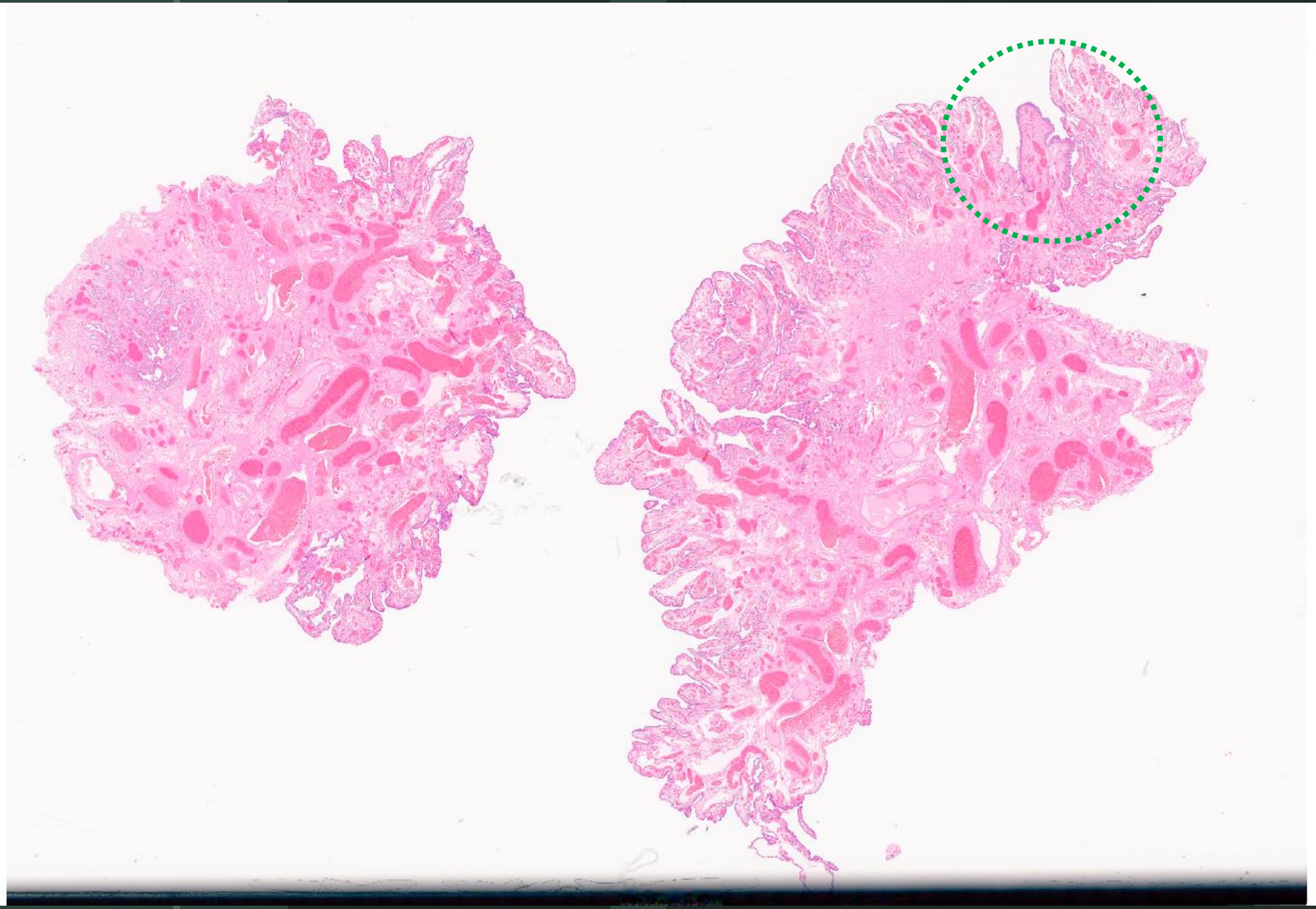

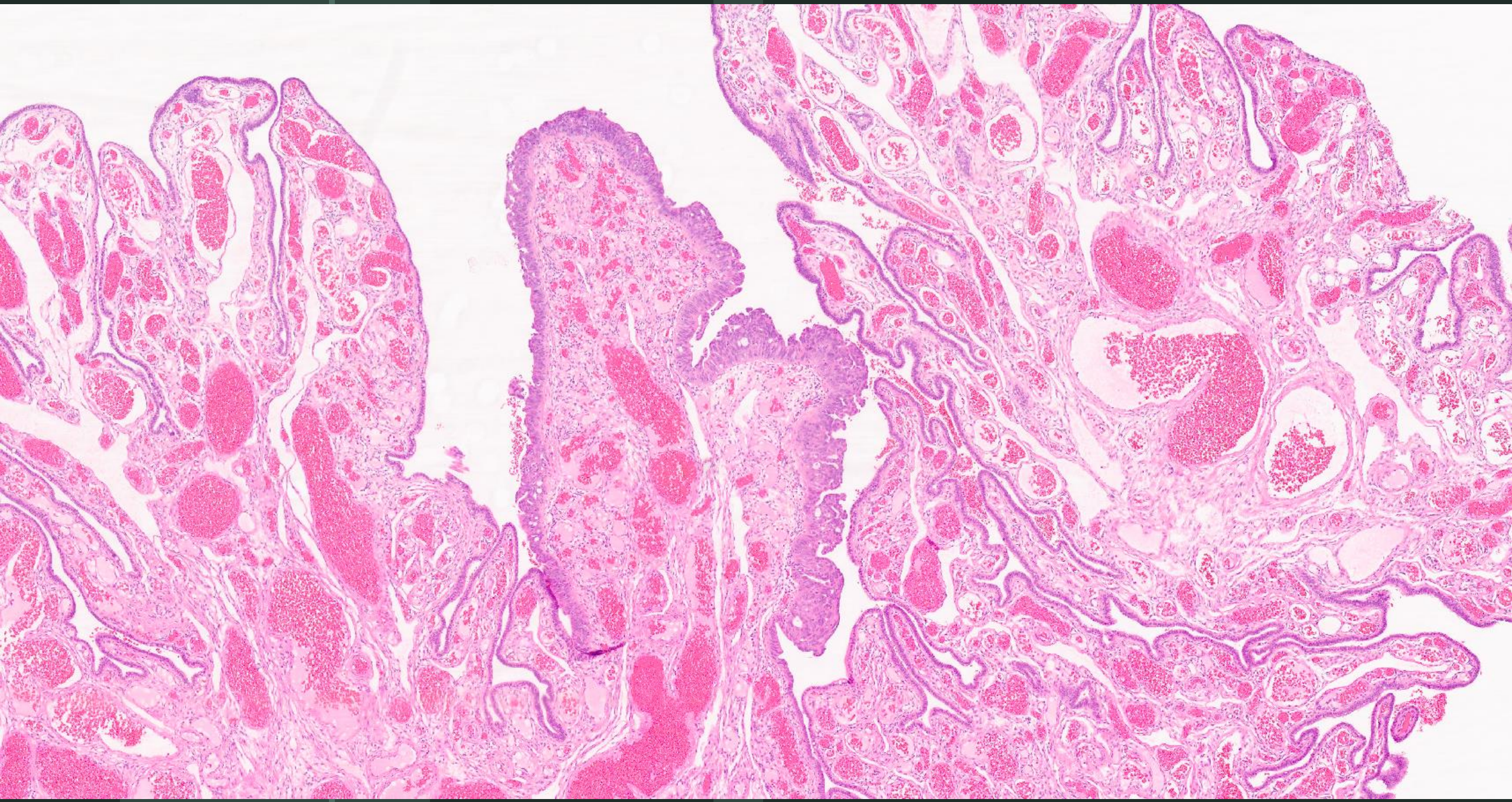

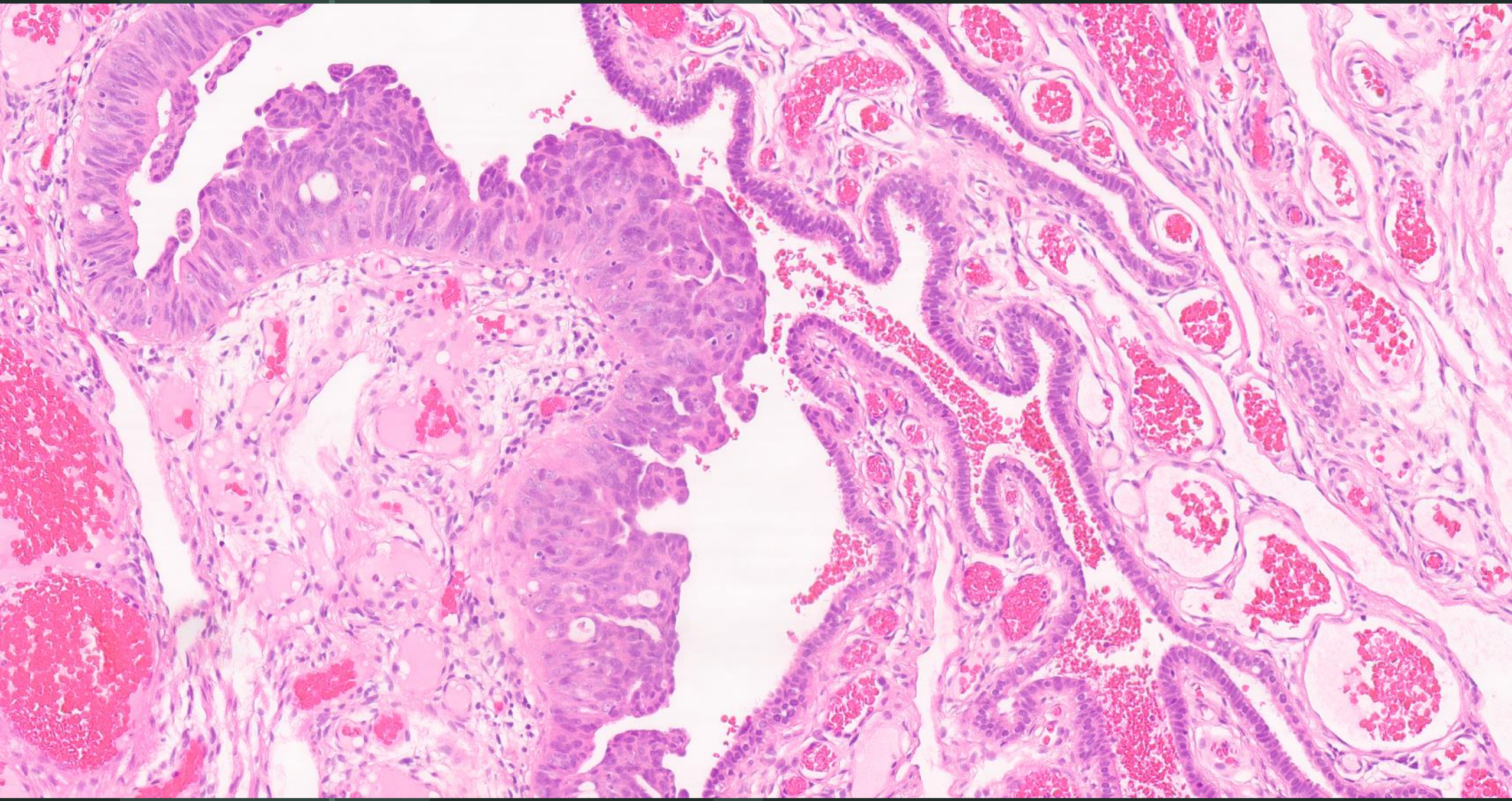

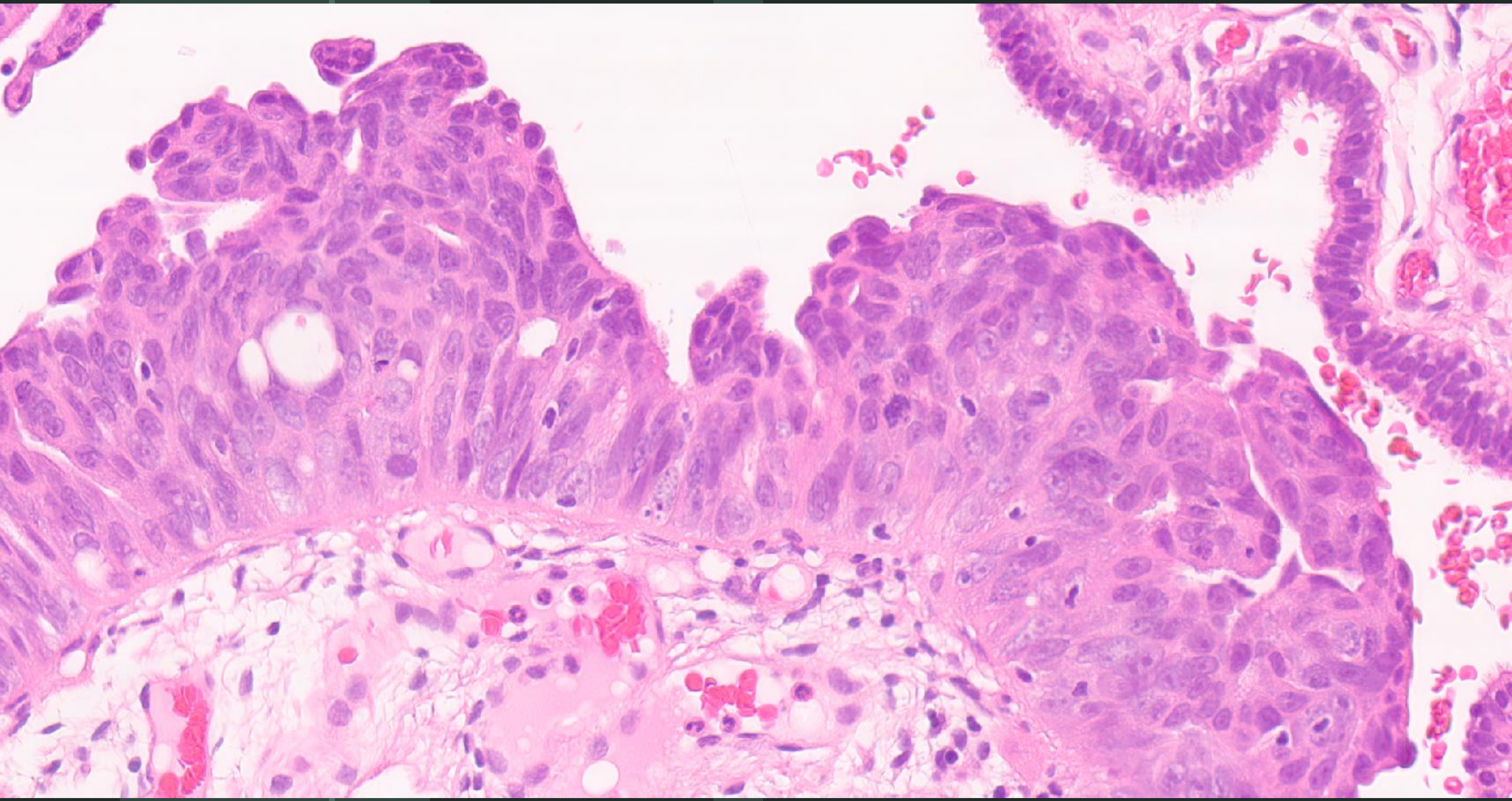

p53

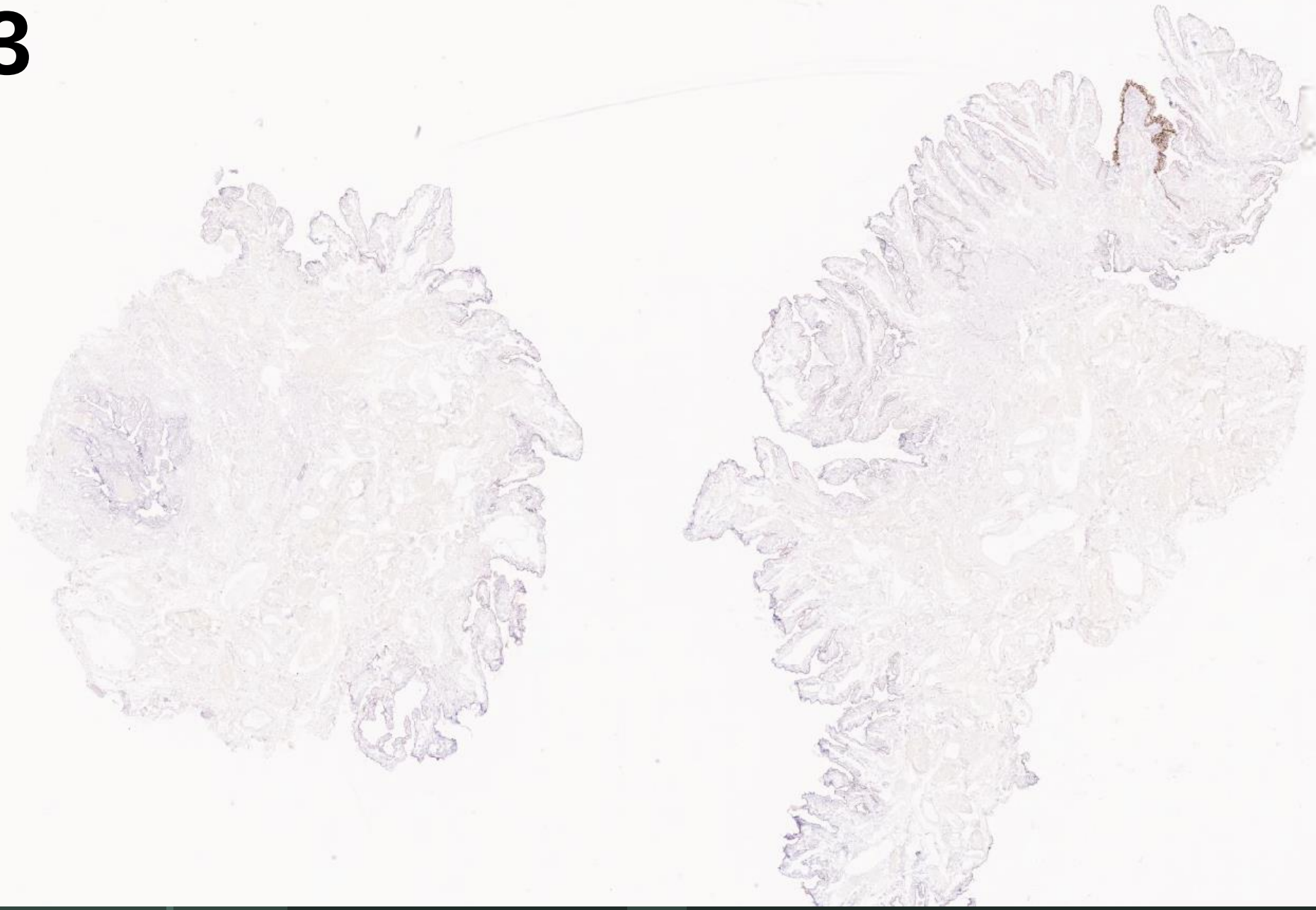

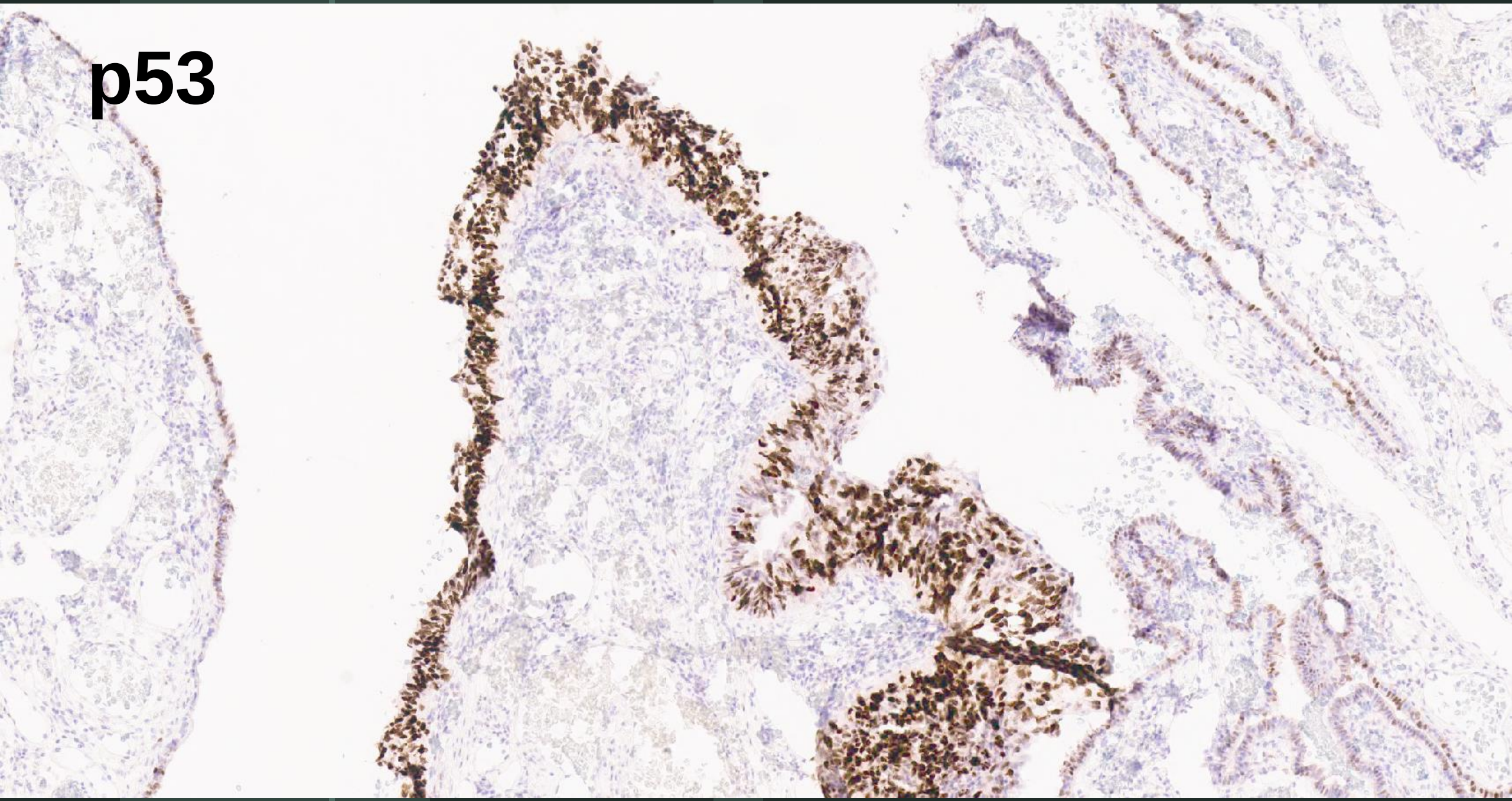
p53

Ki67

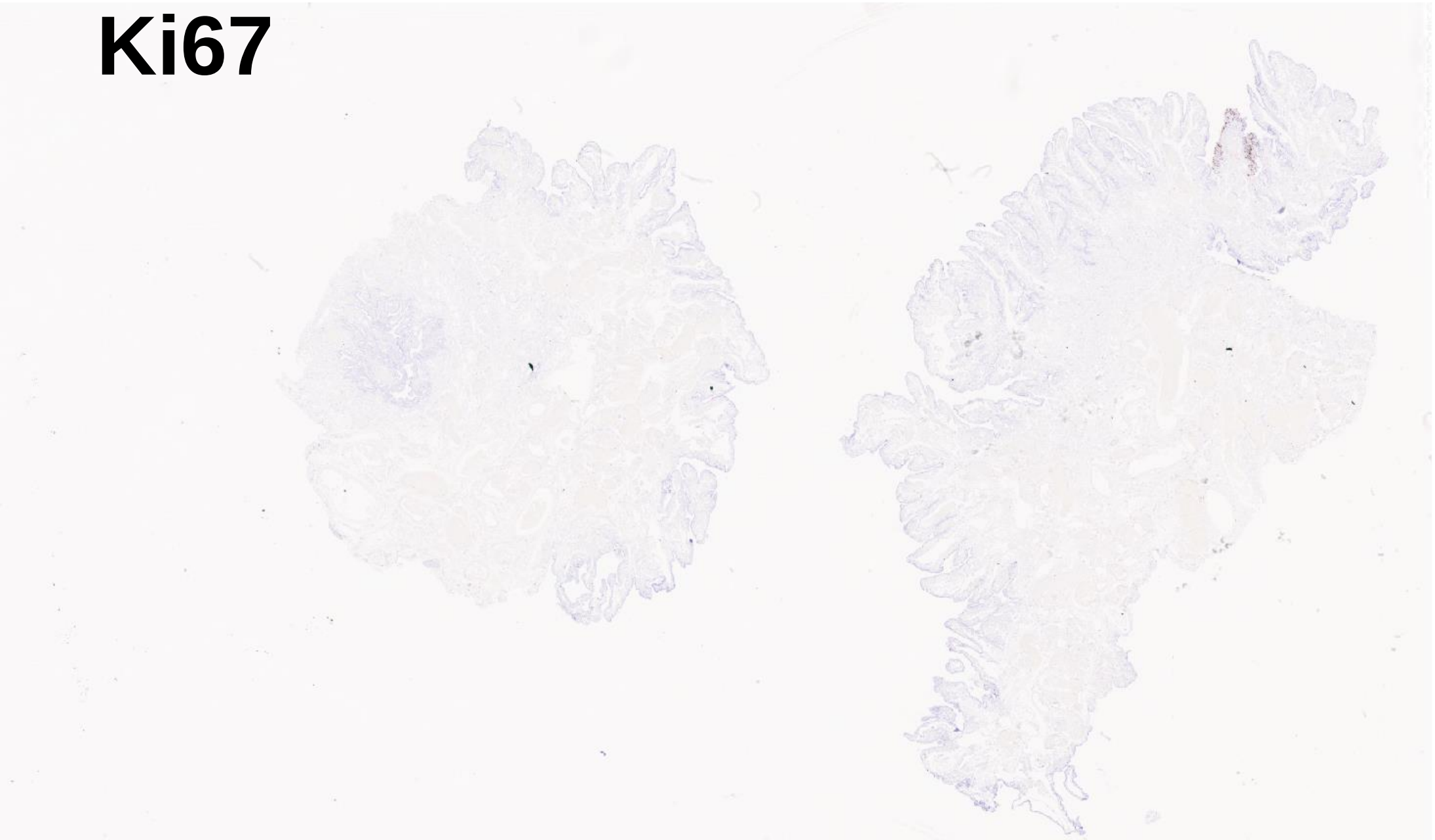

Ki67

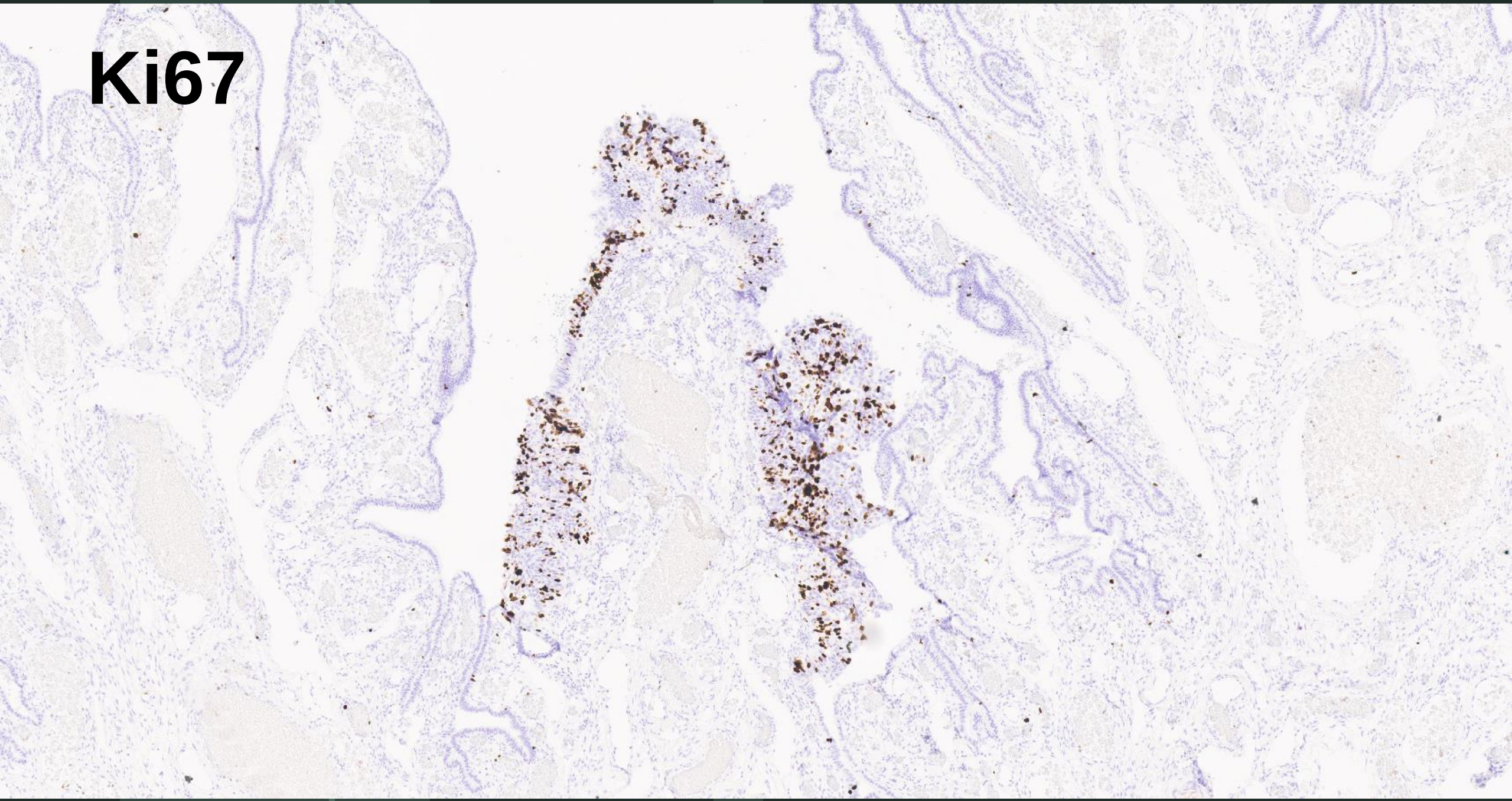

What is too much for STIC?

~~

What are the maximum diagnostic criteria for STIC?

Dx: STIC

Has surgical staging (laparoscopy, omental biopsy, pelvic washings)
→ All negative

Offered BRCA testing
→ Negative (no germline mutation)

Wants to preserve fertility and avoid early menopause

Ovarian mass found by imaging 3 years later → pT1C2


• Epithelial stratification
• Clefting
• Tufts of detached cells
? Too much

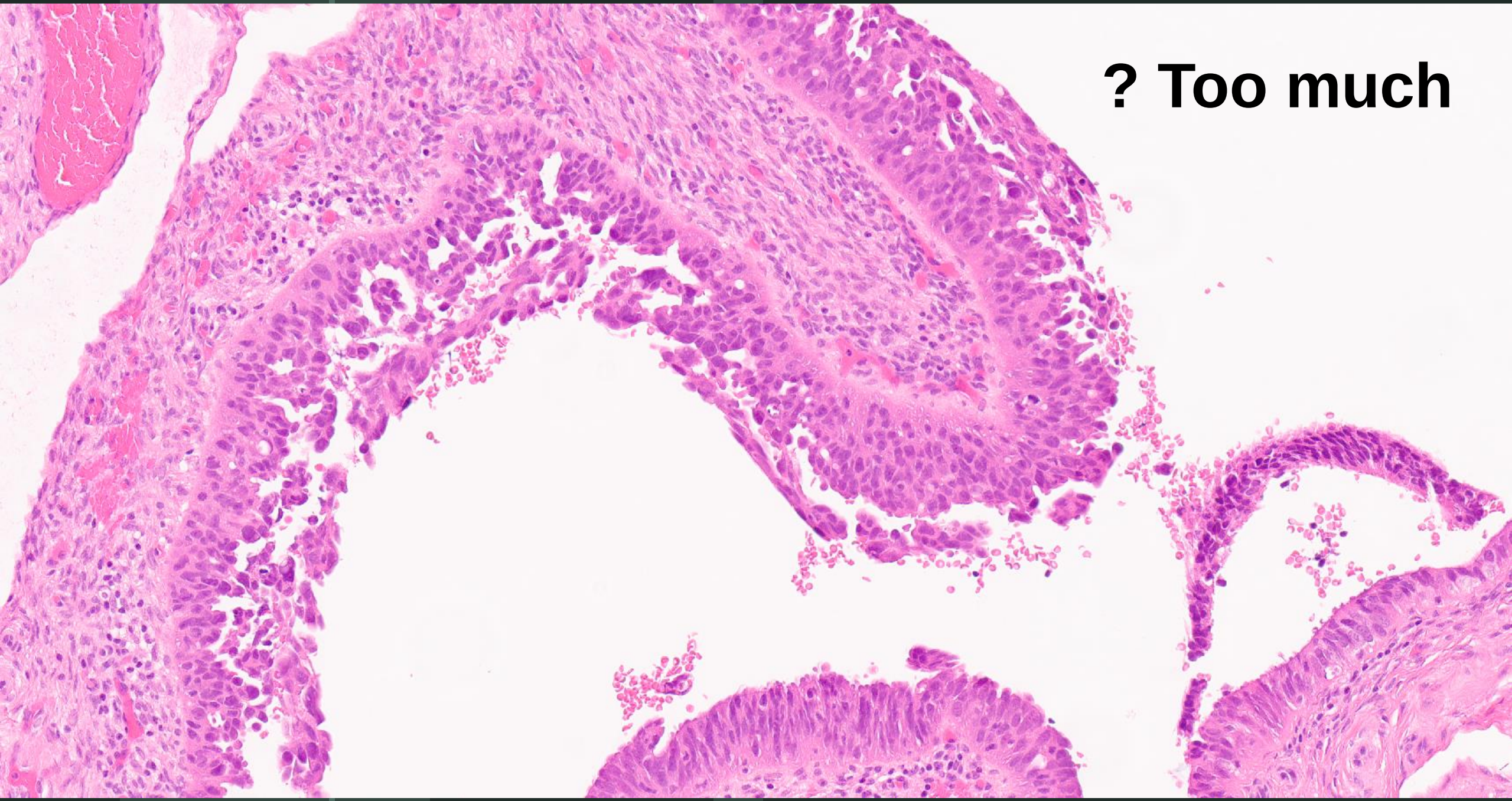
? Too much

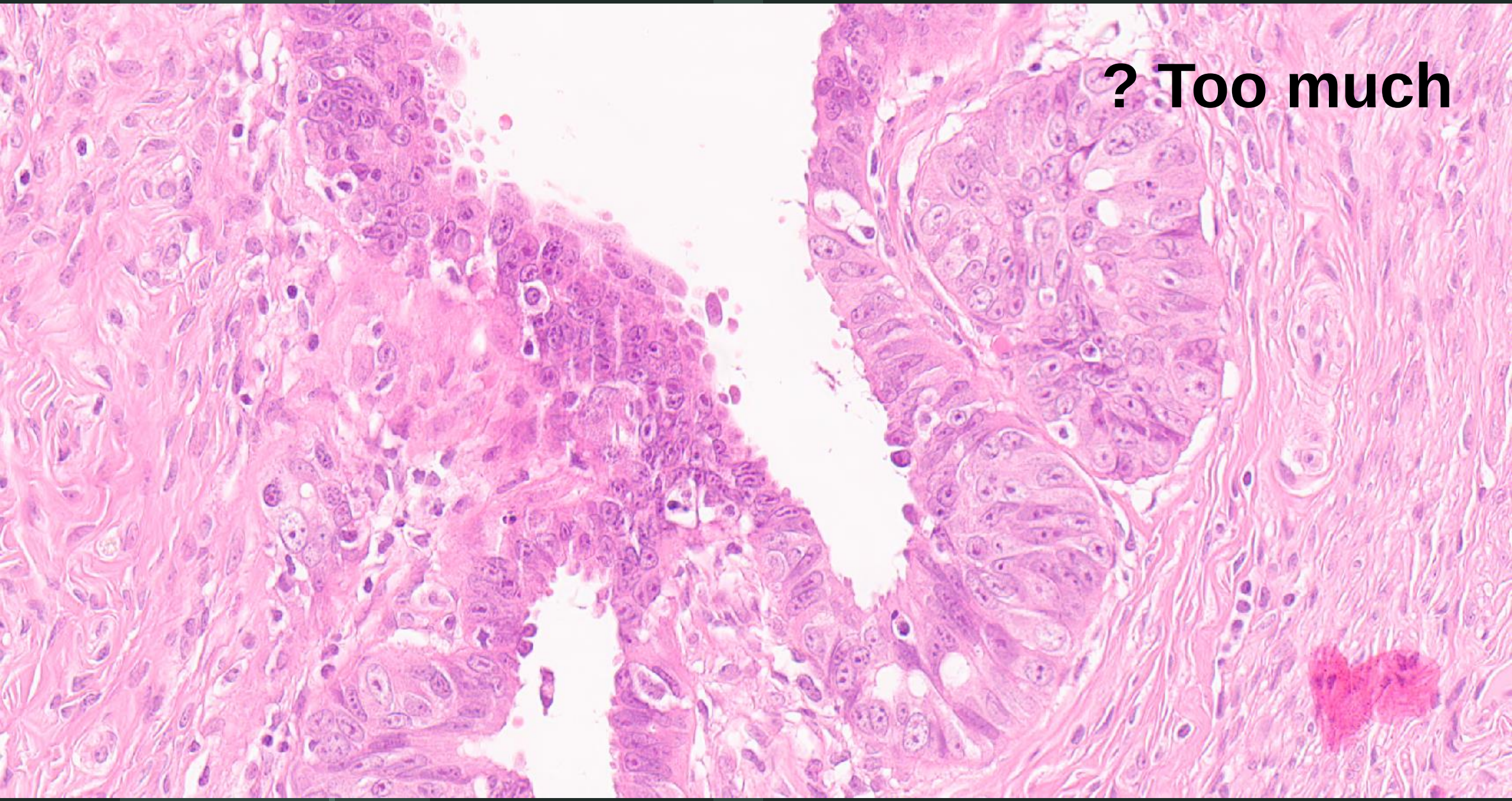
? Too much

?High-risk STIC

- Flat vs BLAD (budding, loose adherent, detached) STIC
  - BLAD more frequently found concurrently with HGSC, higher Ki67, more frequent DNA copy number gains at CCNE1 or CMYC

- Worth a comment in the pathology report



Chien/Shih 2024; PMID: 38298022; CanSTIC [unpublished]

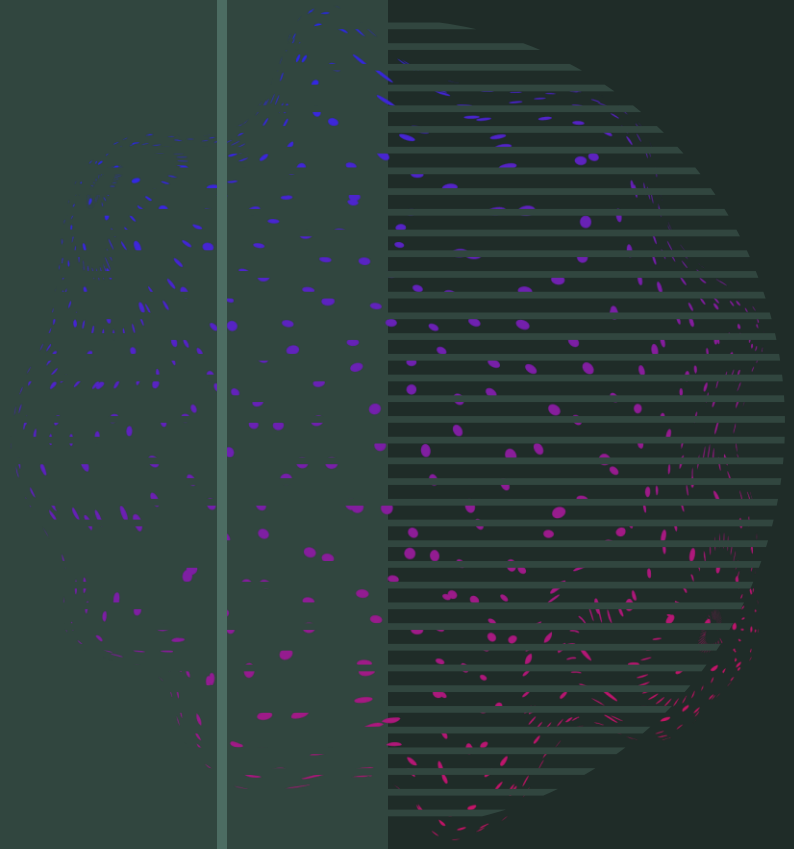

Case 3

39 yo has an opportunistic salpingectomy for family planning

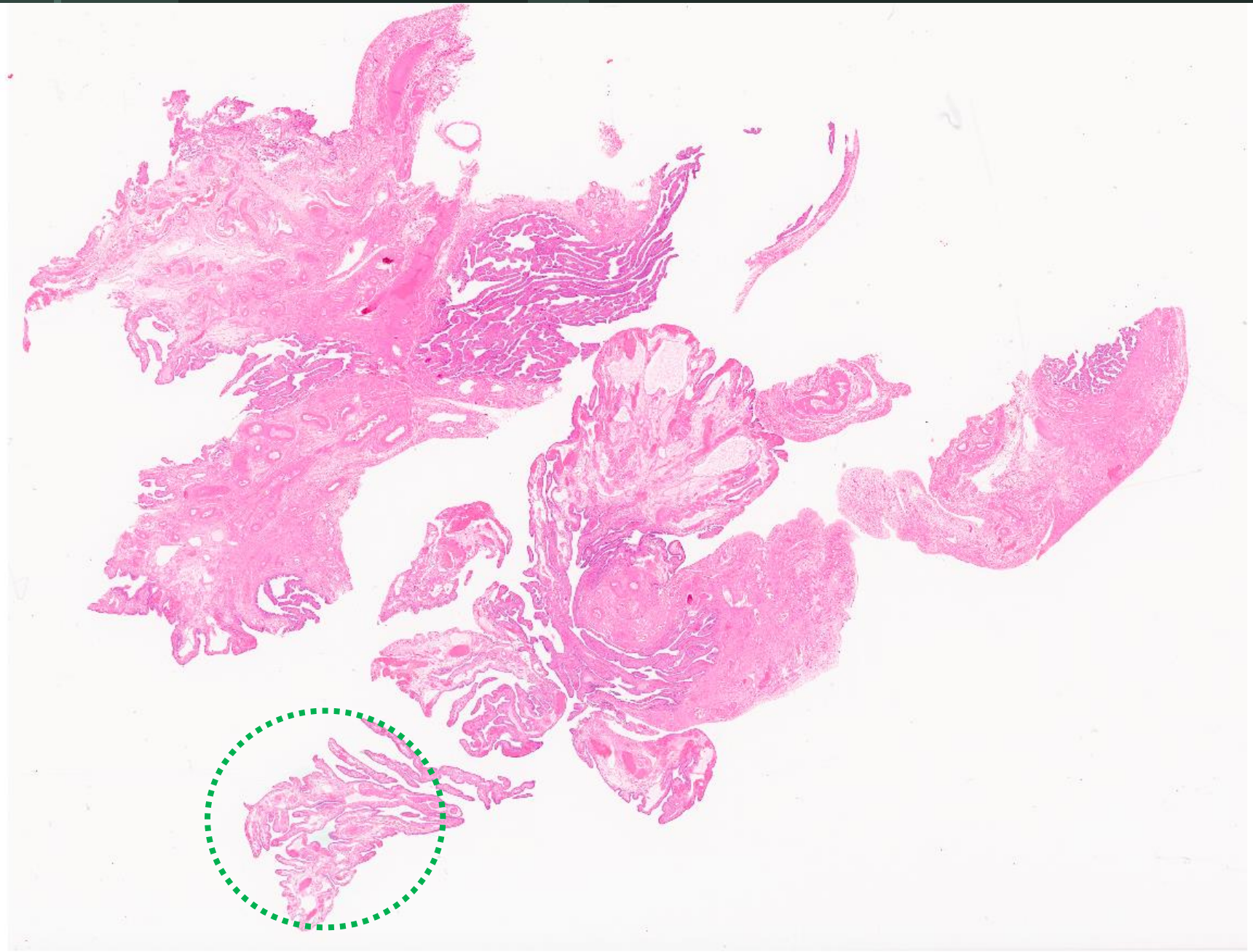

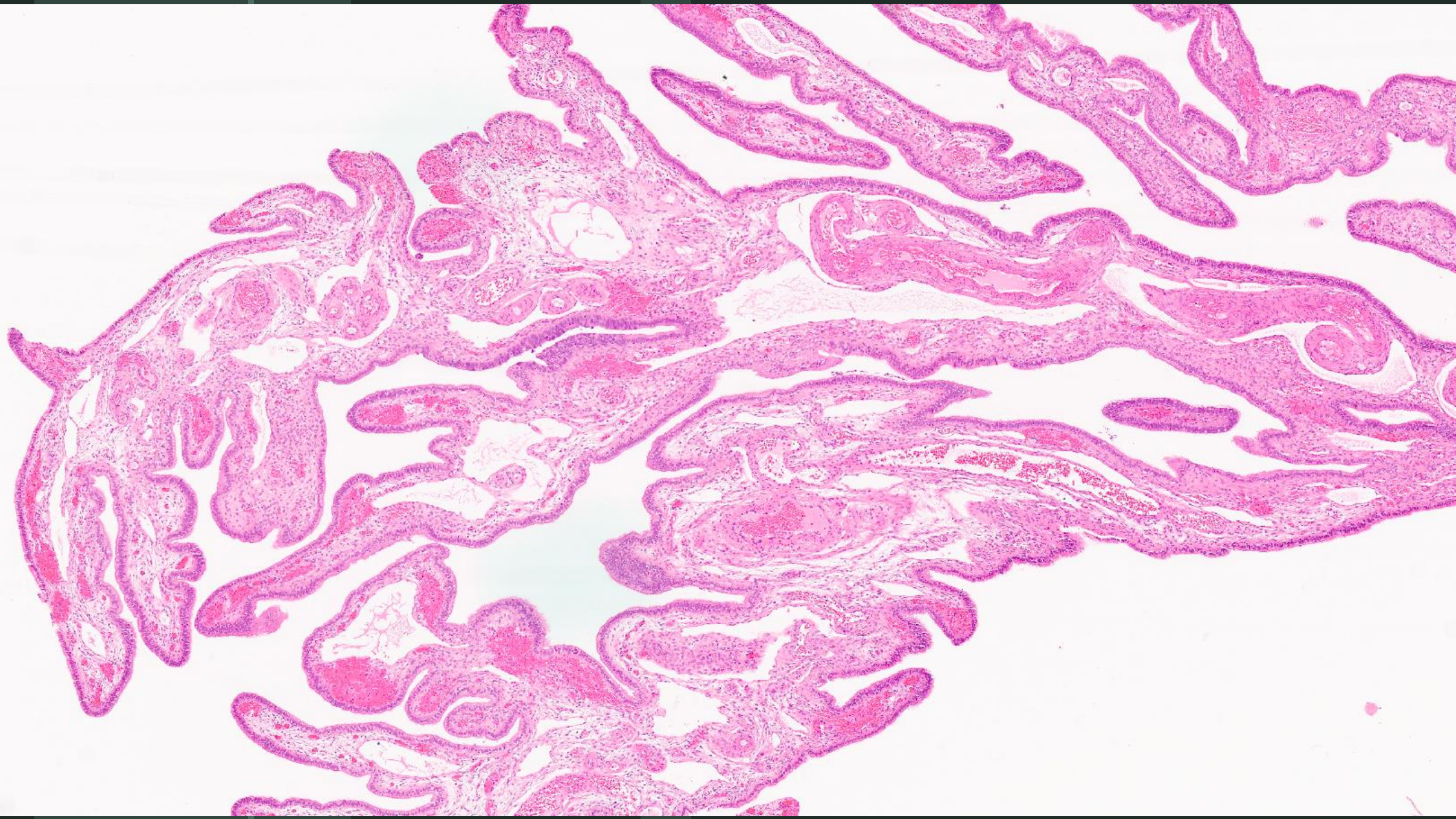

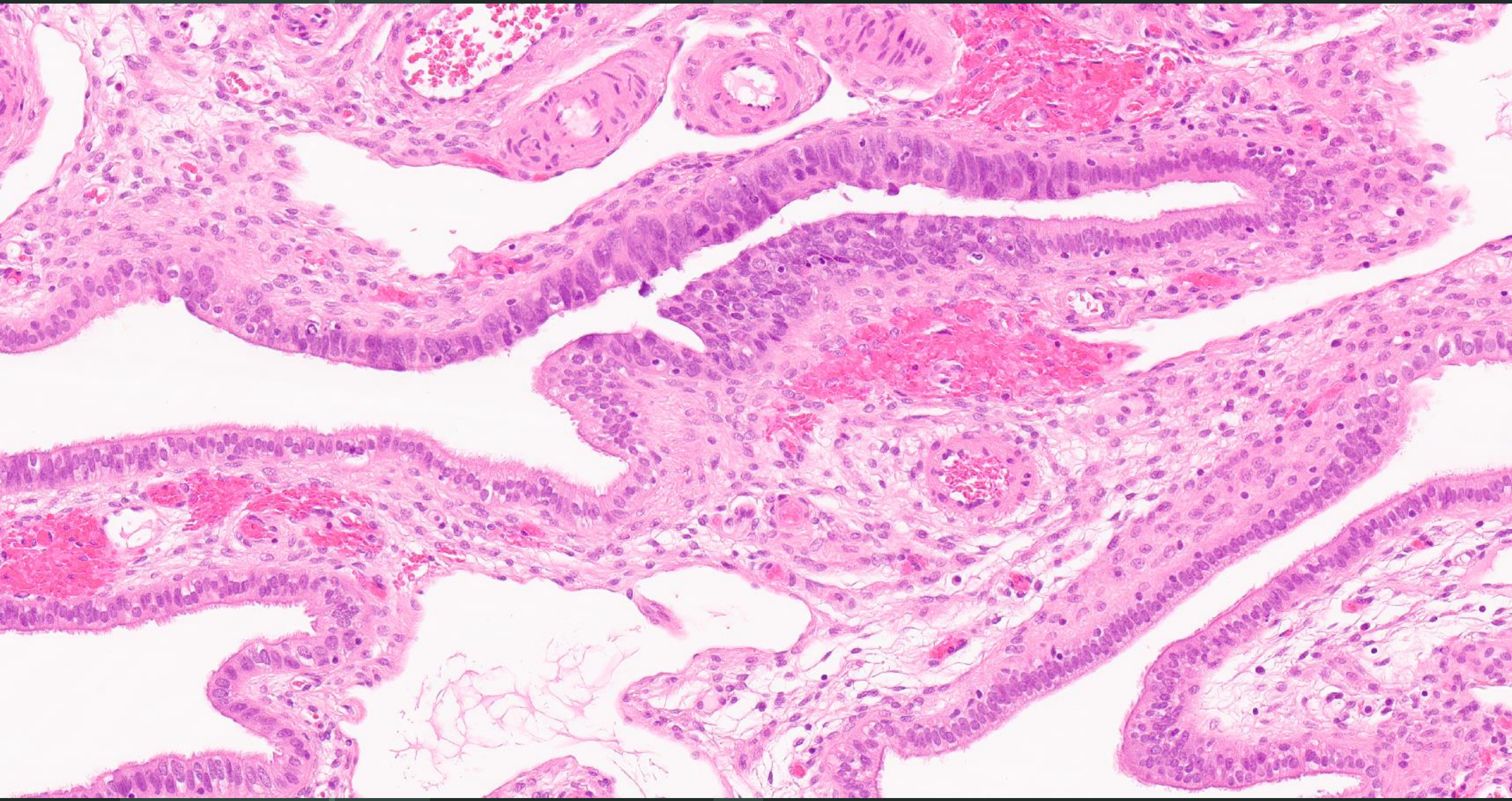

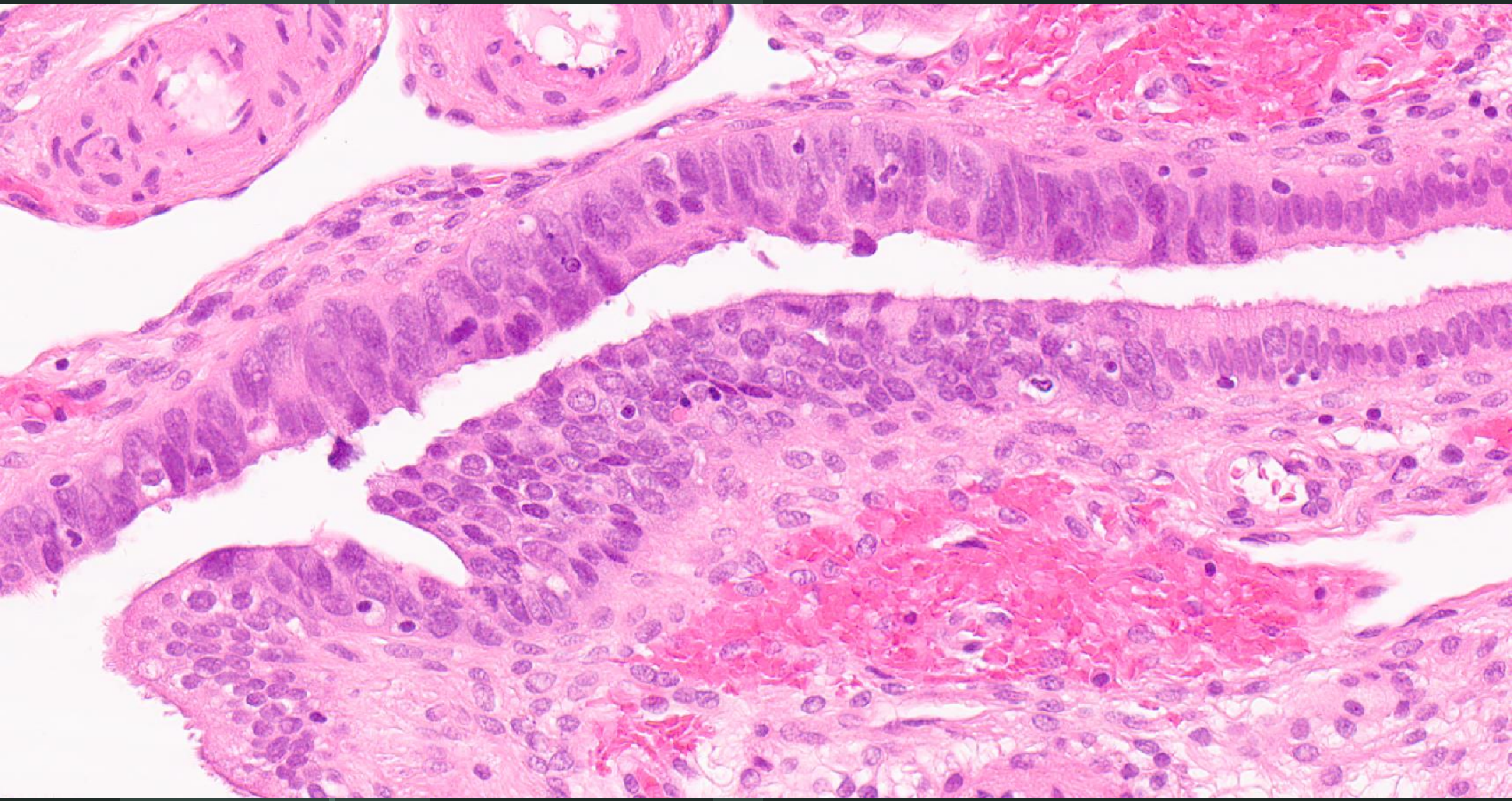

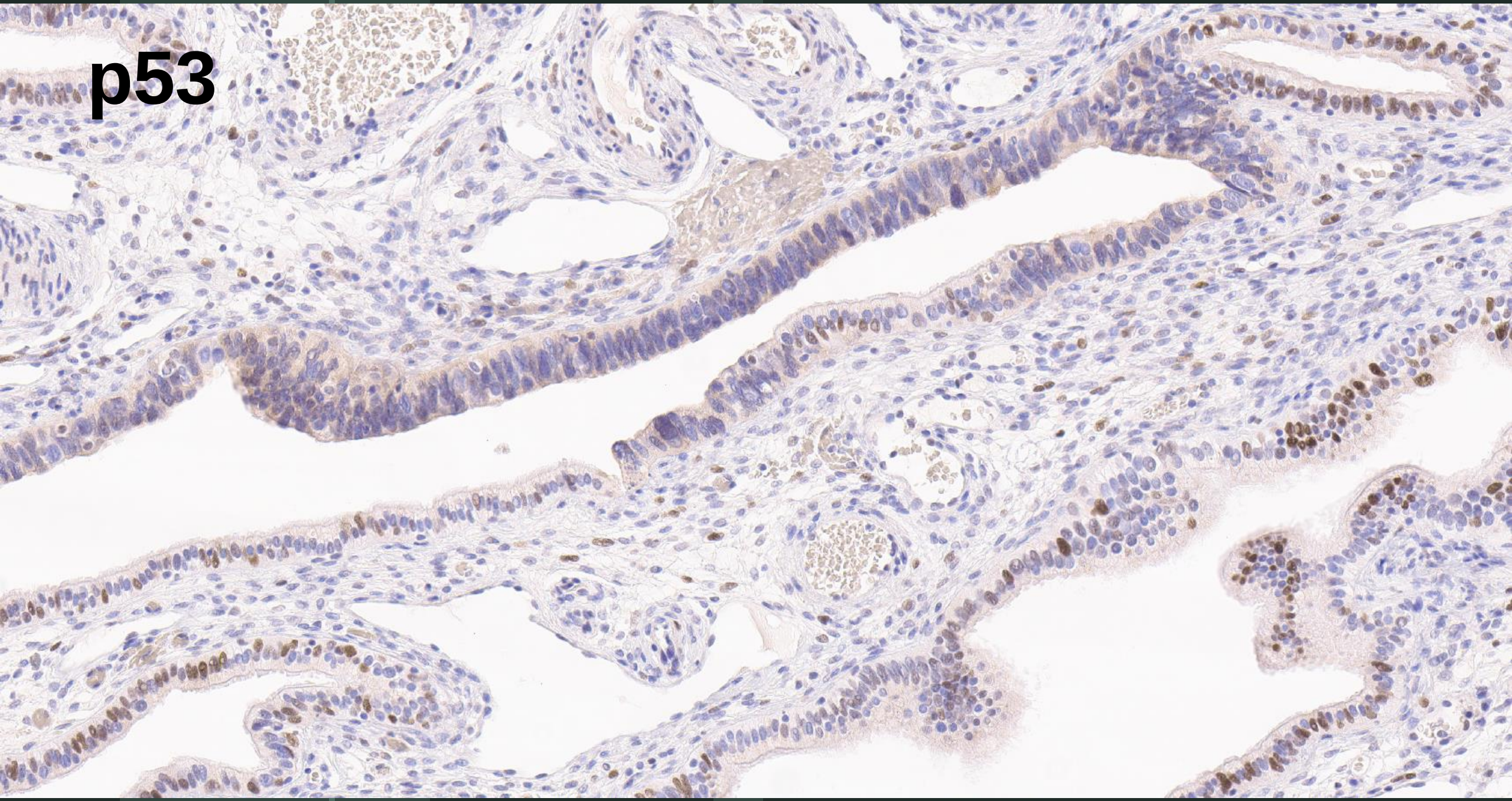
p53

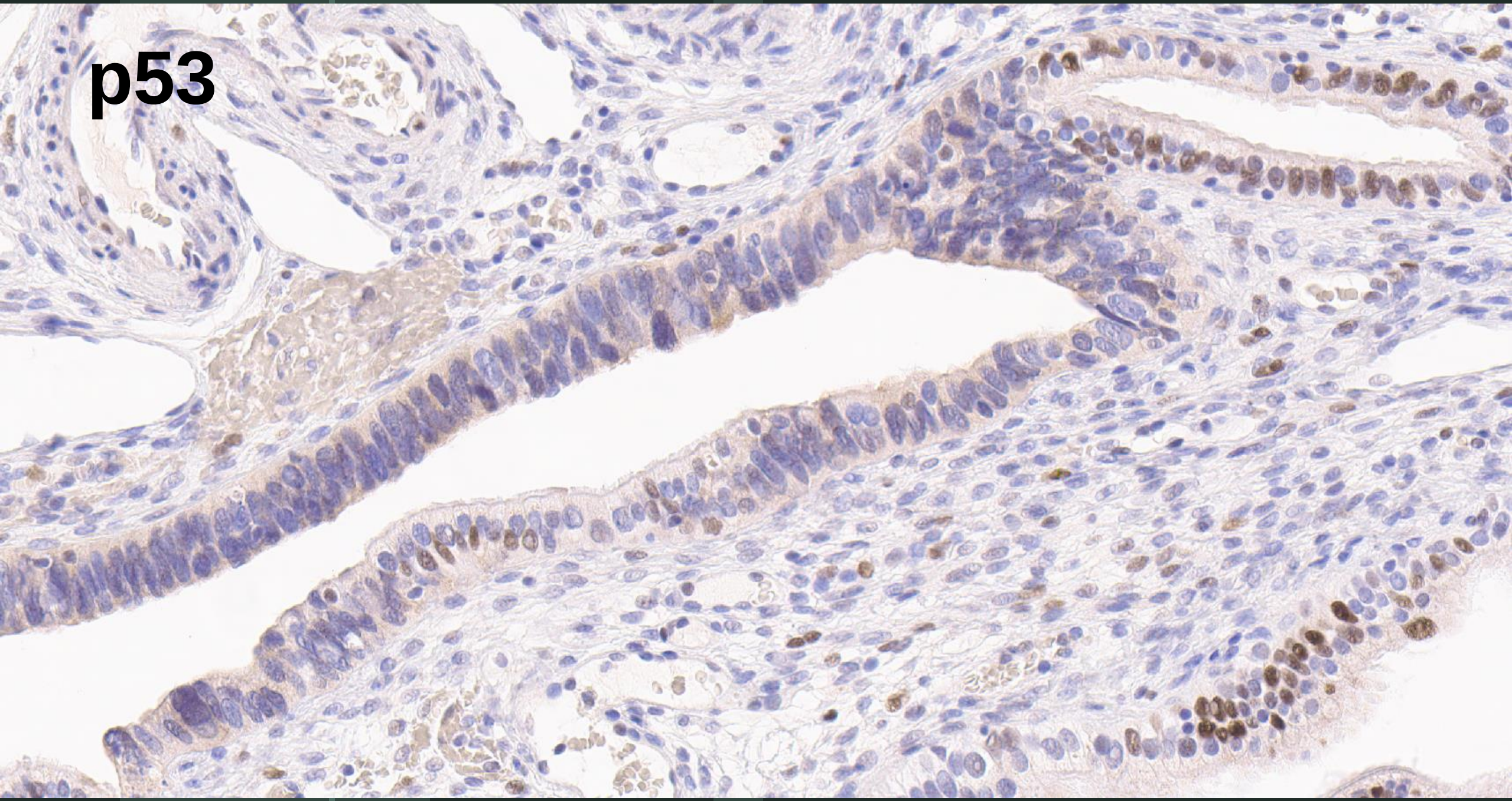
p53

Ki67

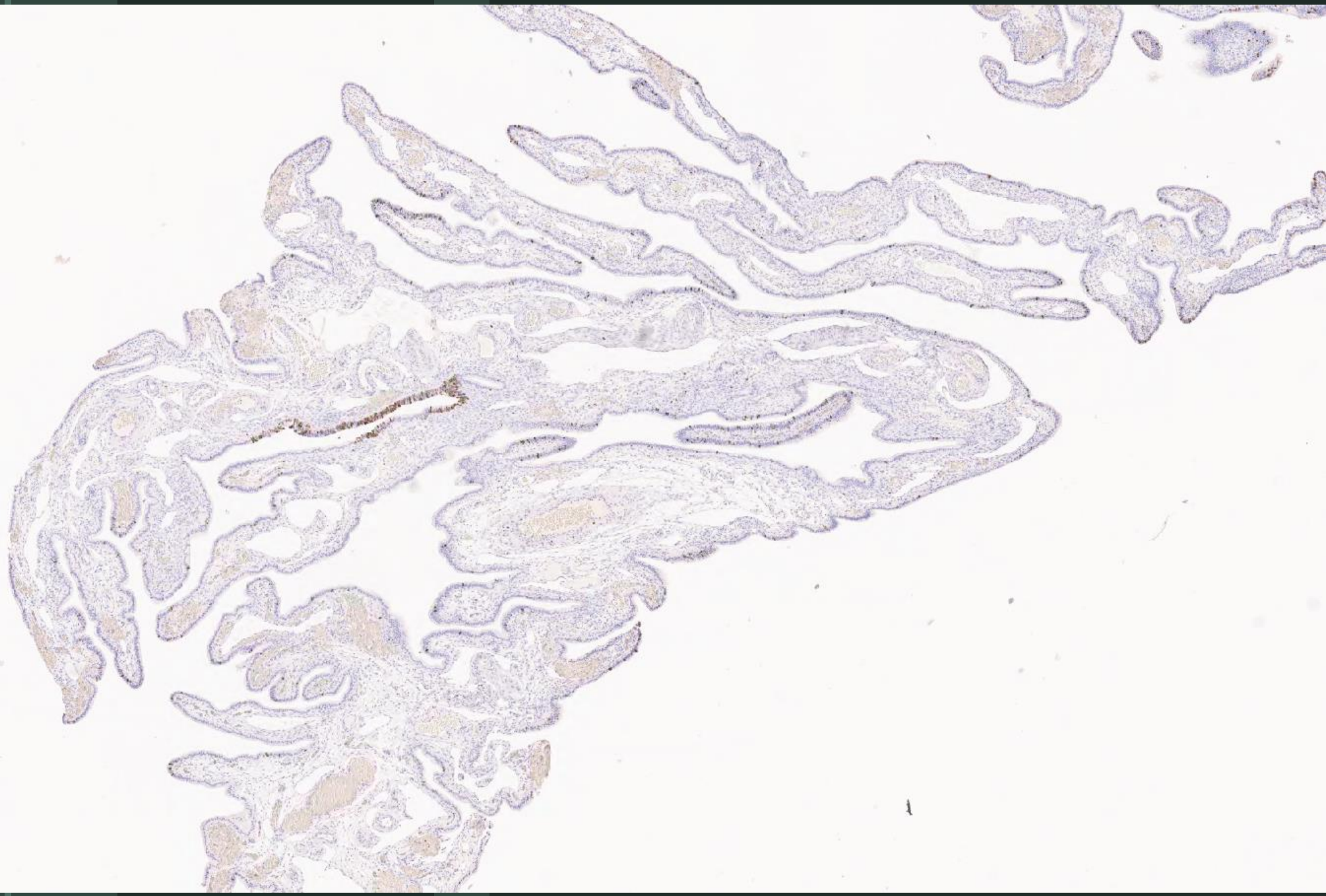

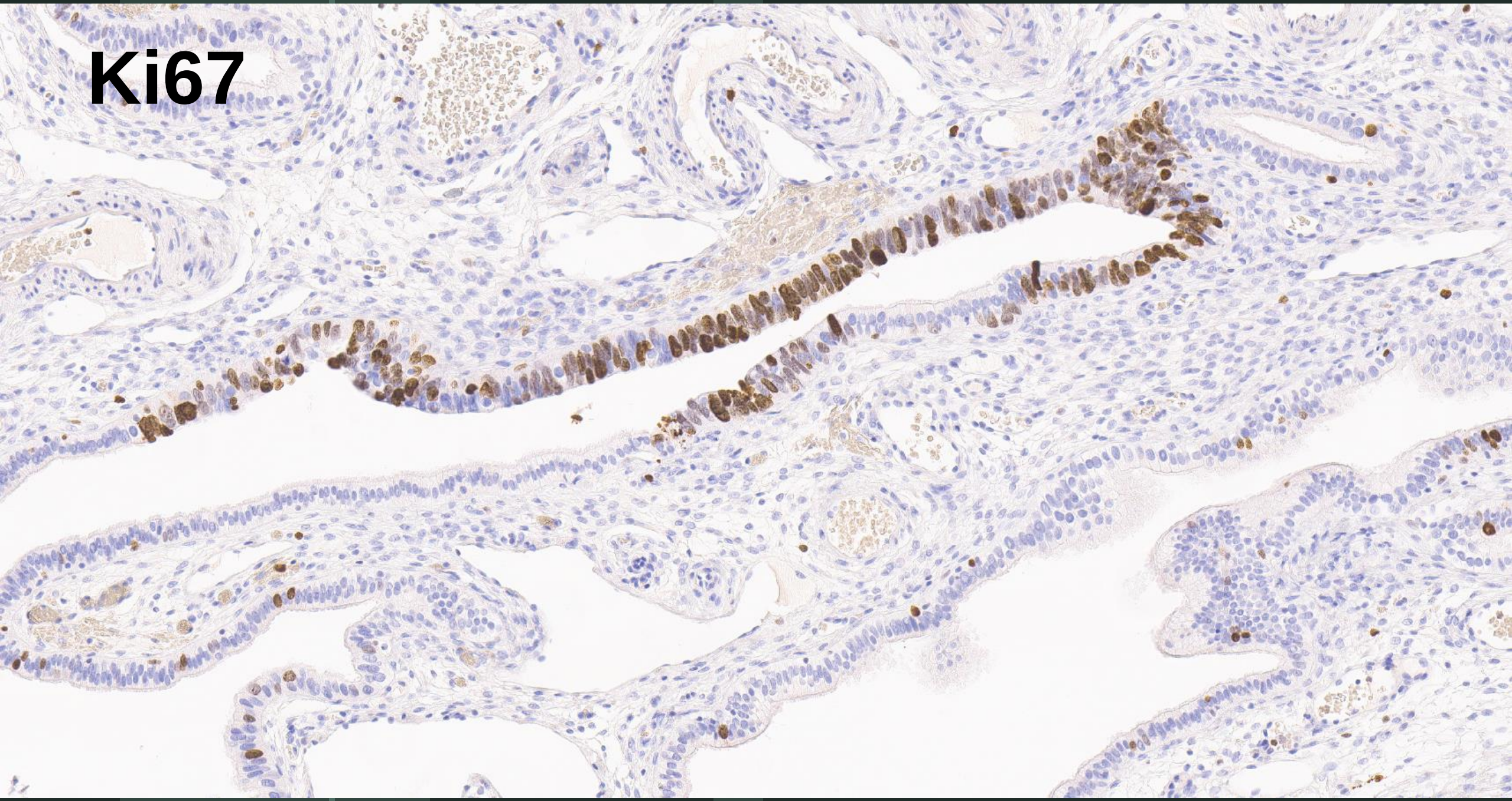
Ki67

How should STIC be treated?

Dx: STIC

Has surgical staging (hysterectomy, bilateral oophorectomy, omental biopsy, pelvic washings)
→ All negative

Offered BRCA testing
→ Declined

Chooses surveillance

Lives disease free for 10 years and passes from other causes

No consensus – Wide Options

- Surveillance
  - Annual transvaginal ultrasound, serum CA125
- Surgical Staging
  - Look, TH-BSO
- Adjuvant chemotherapy
- Prophylactic Surgery
  - Prophylactic BSO
  - Opportunistic Salpingectomy
- Referral for Genetic Counselling

NCCN OC/FT/PP v3.2024;

Observation / Surveillance

- 10% risk of having concurrent HGSC at the time of STIC diagnosis
- Risk of developing HGSC after 5 and 10 years:
  - 0.3% and 0.9% in non-BRCA patients
  - 10% and 30% in BRCA patients
- Average time from STIC to HGSC is 6 years

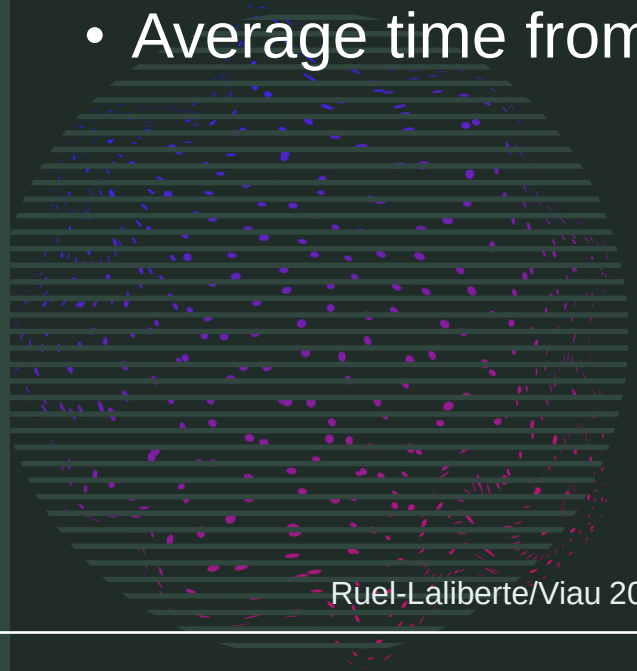

Ruel-Laliberte/Viau 2022, PMID: 36099965; Linz/Battista 2022, PMID: 36119503; Steenbeek/de Hullu 2022, PMID: 35302882

Prophylactic Surgeries

- RRSO reduces ovarian cancer risk by 80–96%
  - RRSO after completed childbearing
  - RRSO at ages 35-40 years for *BRCA1*, 40-45 years for *BRCA2*, 45-50 years for *BRIP1*, *RAD51C*, *RAD51D* mutation carriers
  - Iatrogenic menopause
- Salpingectomy followed by delayed oophorectomy (TUBA WISP)

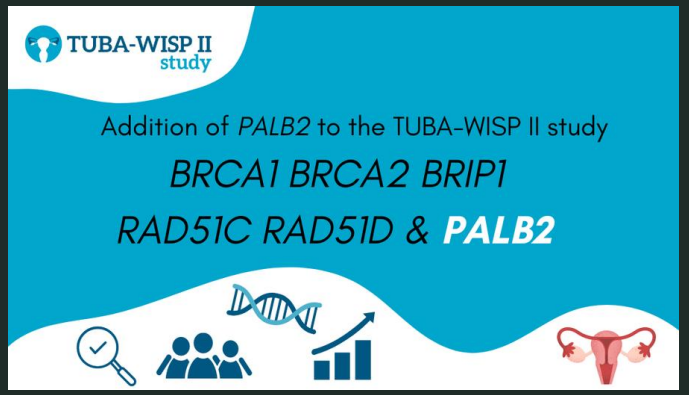

Labidi-Galy/Velculescu 2017; PMID: 29061967; Narod 2006, PMID 16835424; Vermeulen/Kenter 2017, PMID: 28509627.

Opportunistic Salpingectomy











Opportunistic Salpingectomy

- Removal of the fallopian tubes to prevent HGSC
  - Done in (average-risk) women undergoing gynecologic (or other) surgery for other indications, or instead of tubal ligation
  - Supported by most major bodies, ACOG, SGO, ACS, NCCN, RCOG, ESGO
- Not associated with:
  - Early menopause
  - Surgical complications (infections, hospital readmissions, pain Rx prescriptions, lab/imaging orders post-op)
- Reduces ovarian cancer risk by 40-70%

Labidi-Galy/Velculescu 2017; PMID: 29061967; Narod 2006, PMID 16835424; Vermeulen/Kenter 2017, PMID: 28509627. Hanley/Miller 2022, PMID: 35138400; Rufin/Hanley 2024; PMID: 38043843; Hanley/McAlpine 2018, PMID: 29852159; Hanley/Miller 2020, PMID: 32067967.

Chemotherapy for STIC

- Most professionals/bodies do not recommend chemotherapy or PARP inhibitors; reserved for clinical trials

- Preliminary Canadian data
  - Those that received adjuvant chemotherapy did not develop HGSC
  - Meta-analysis, 11 of 115 STIC received chemotherapy and none developed HGSC during 96.0 months (25.0-245.9) follow-up.

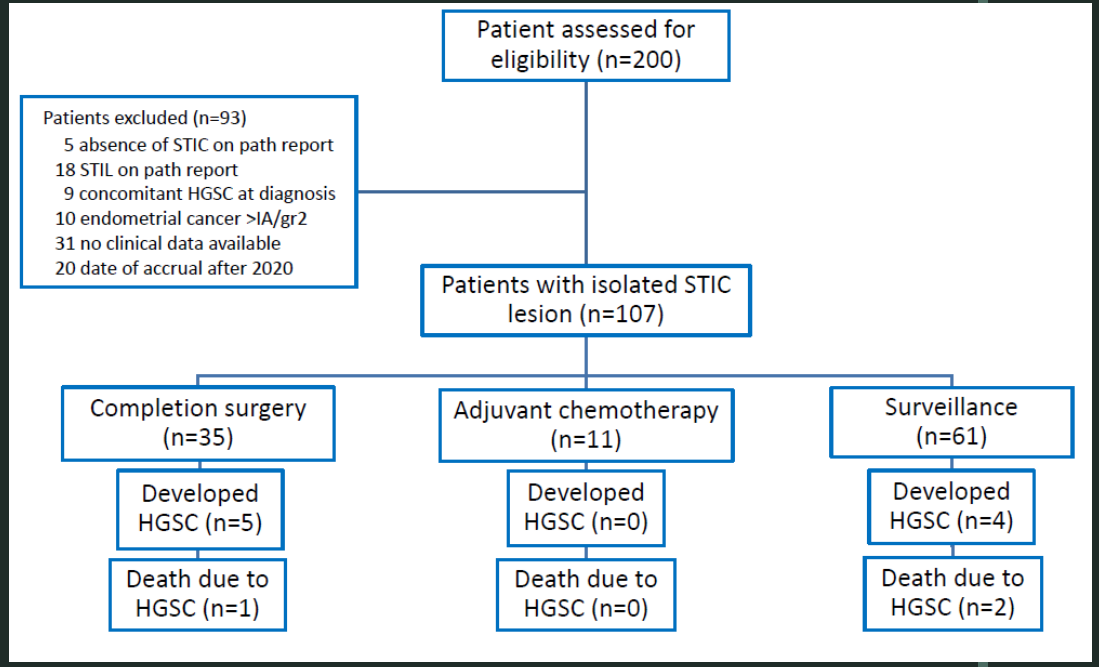

Canadian management of Serous Tubal Intraepithelial Carcinoma (Can-STIC) Spenard/Bernardini 2024; Gynecol Oncol 2024;S1(190):S304.

Negri/Steenbeek 2024; PMID 39054407, Steenbeek/DeHullu 2022 PMID: 35302882

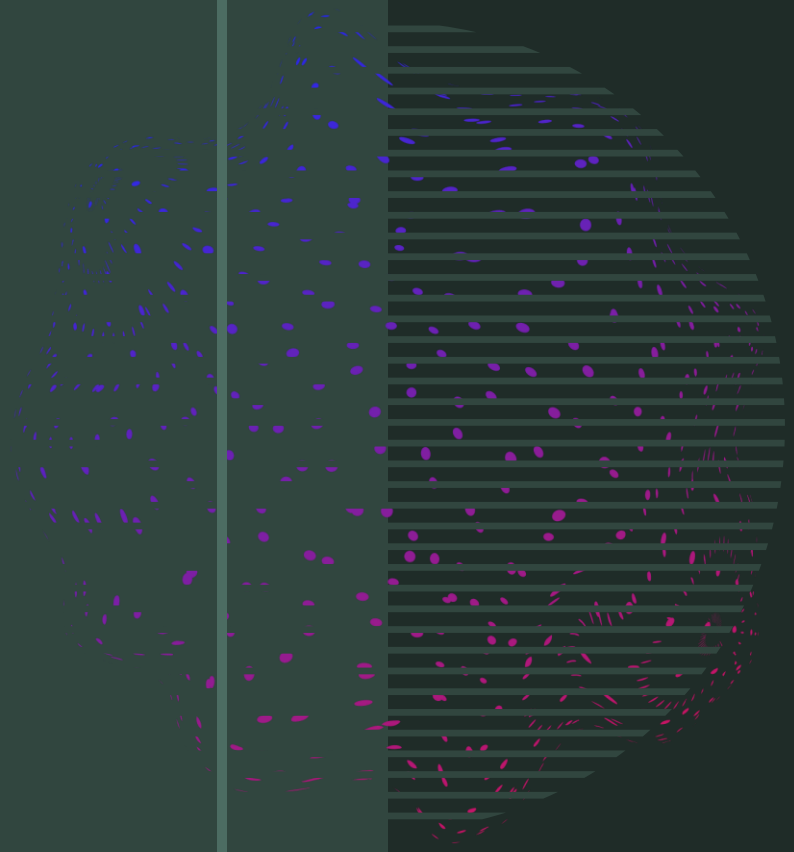

Case 4

A 47-year-old female with FIGO grade 2 endometrioid endometrial carcinoma

Undergoes TH-BSO and staging

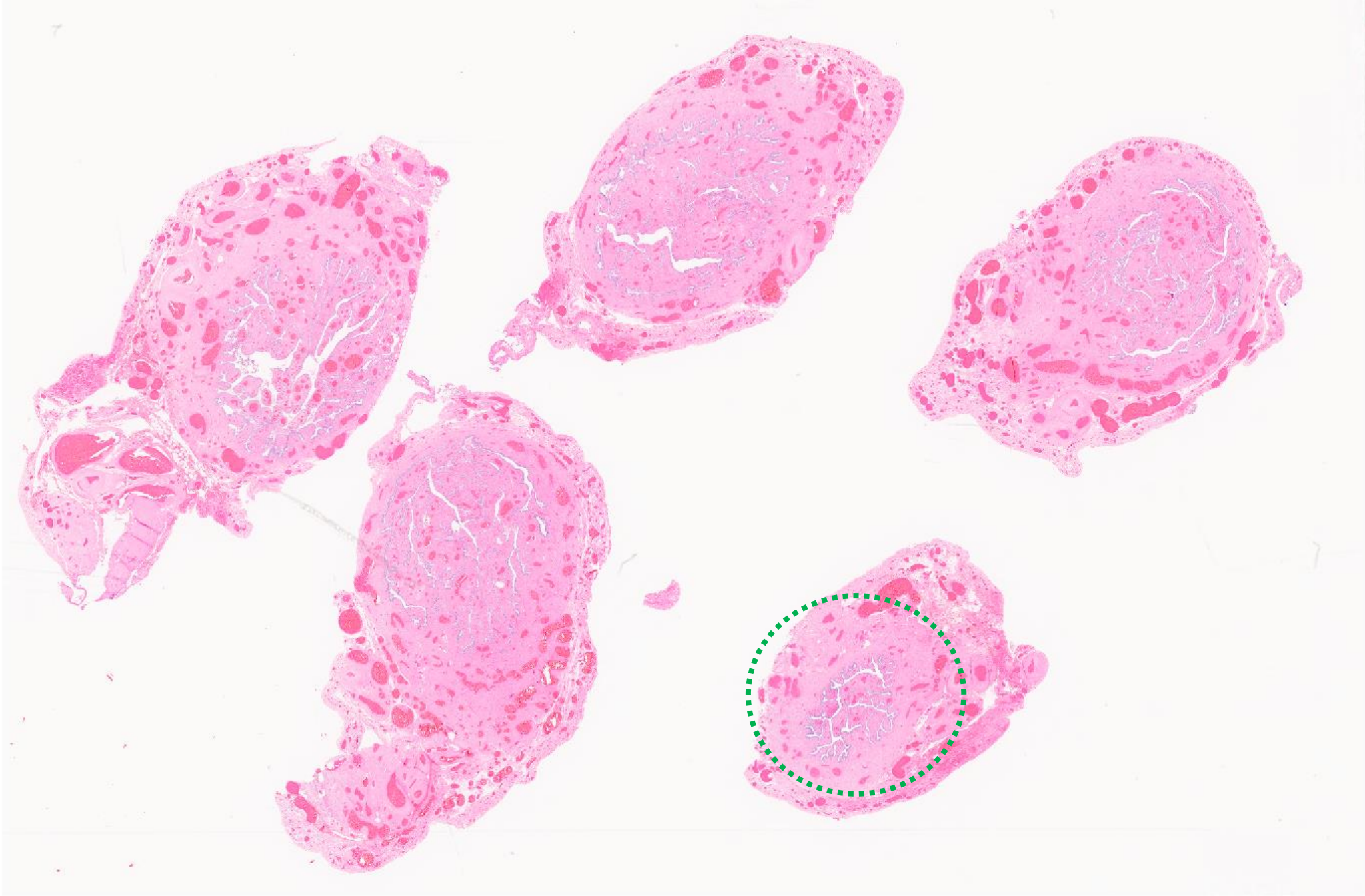

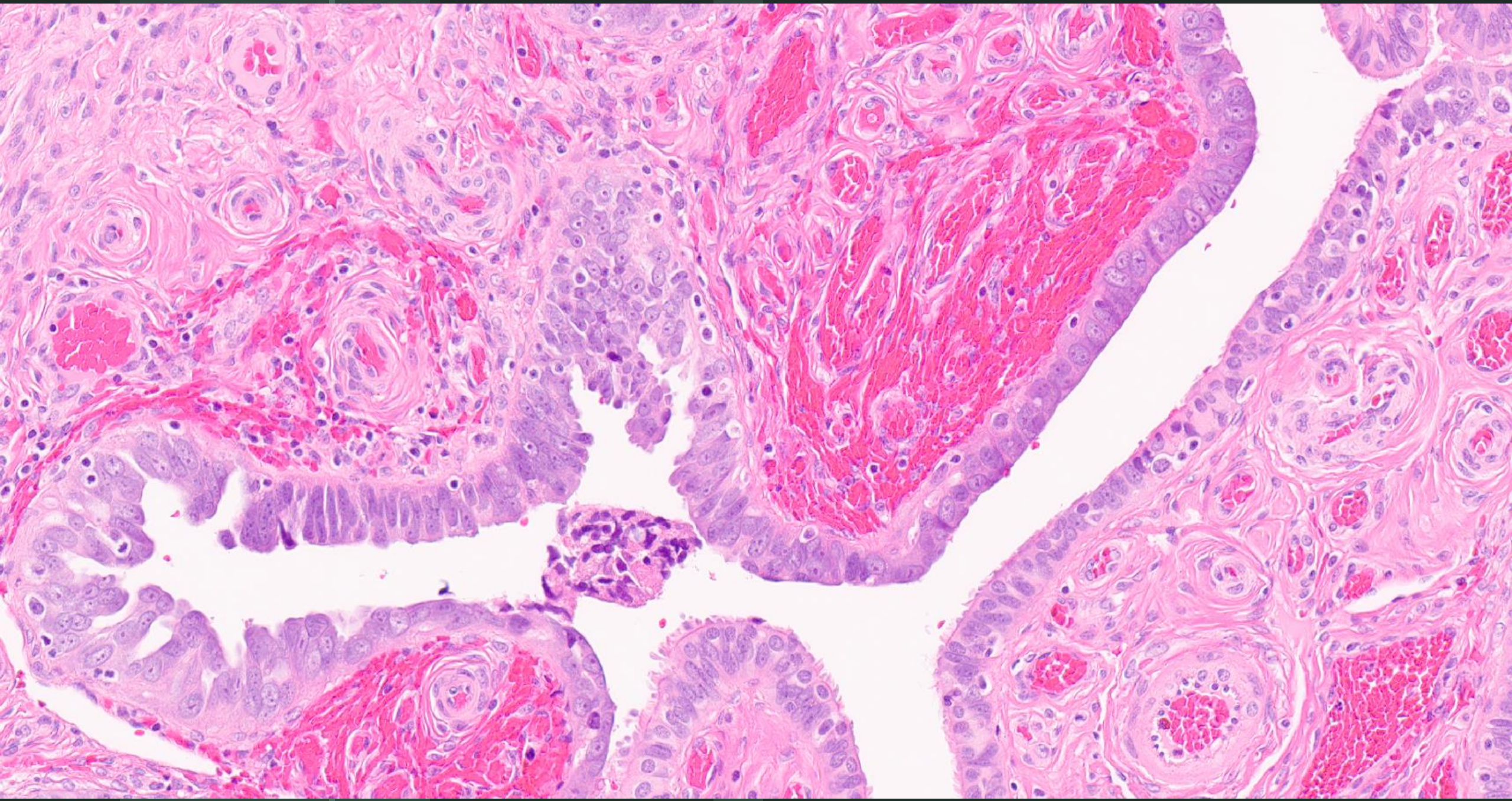

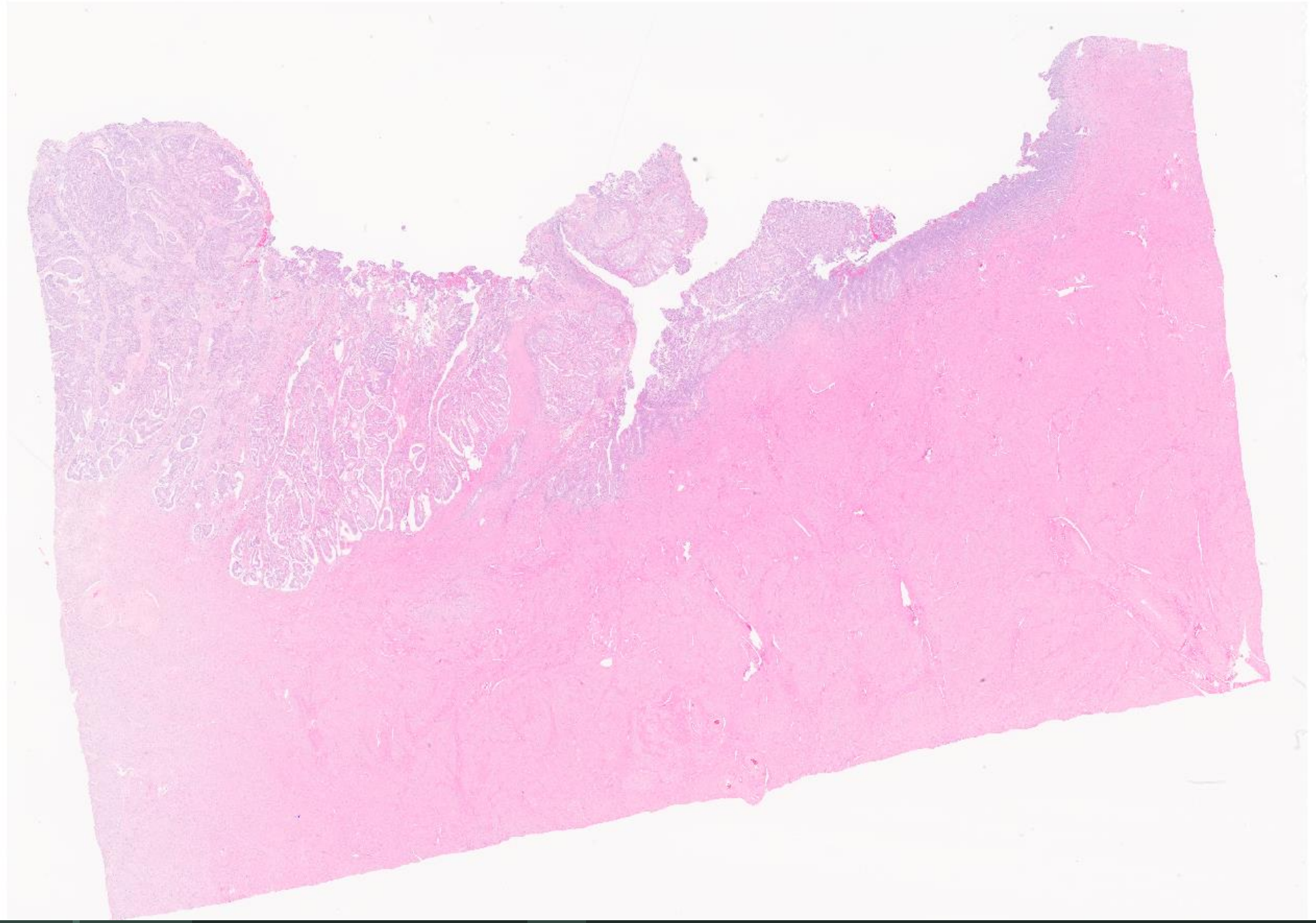

p53

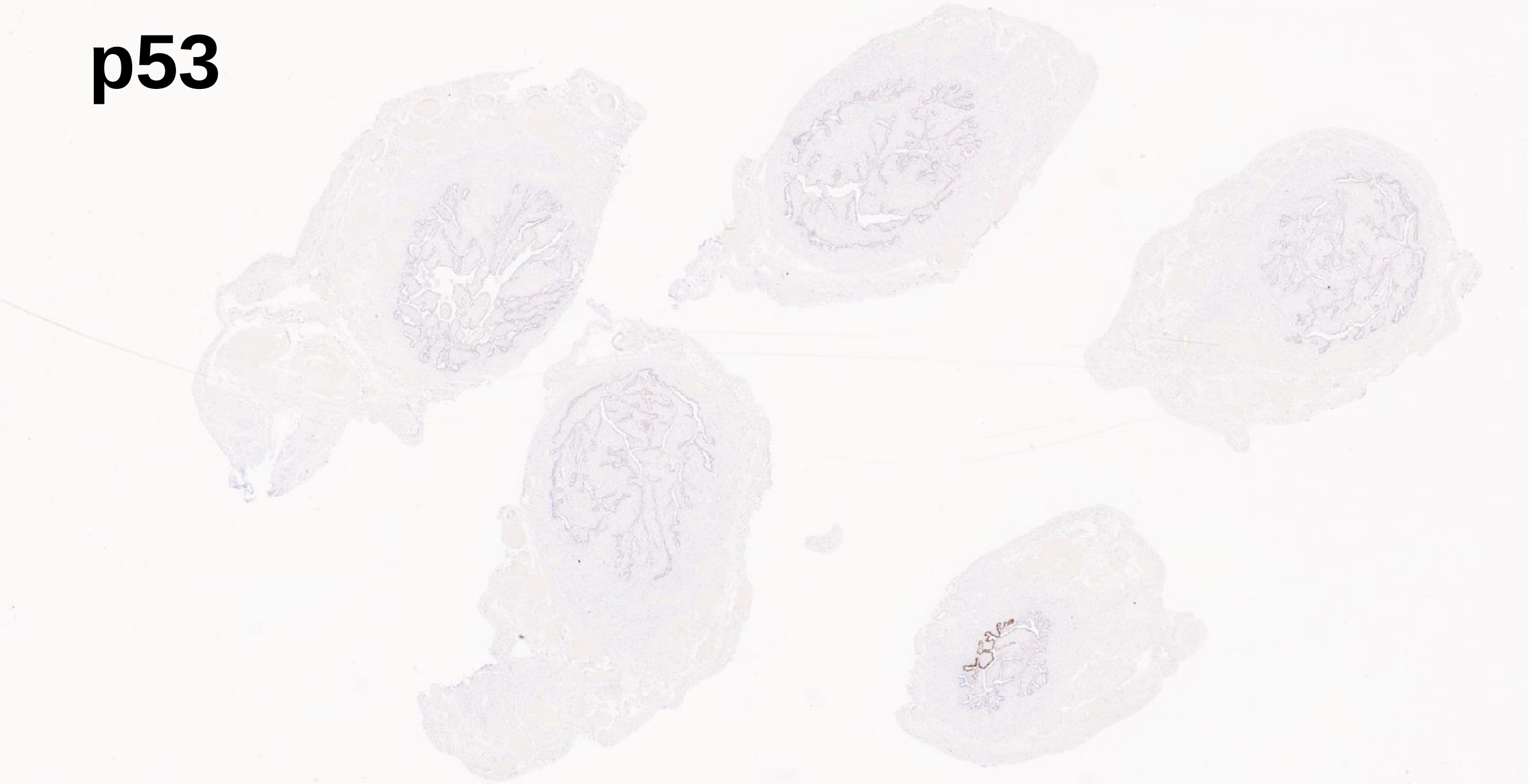


p53

Ki67

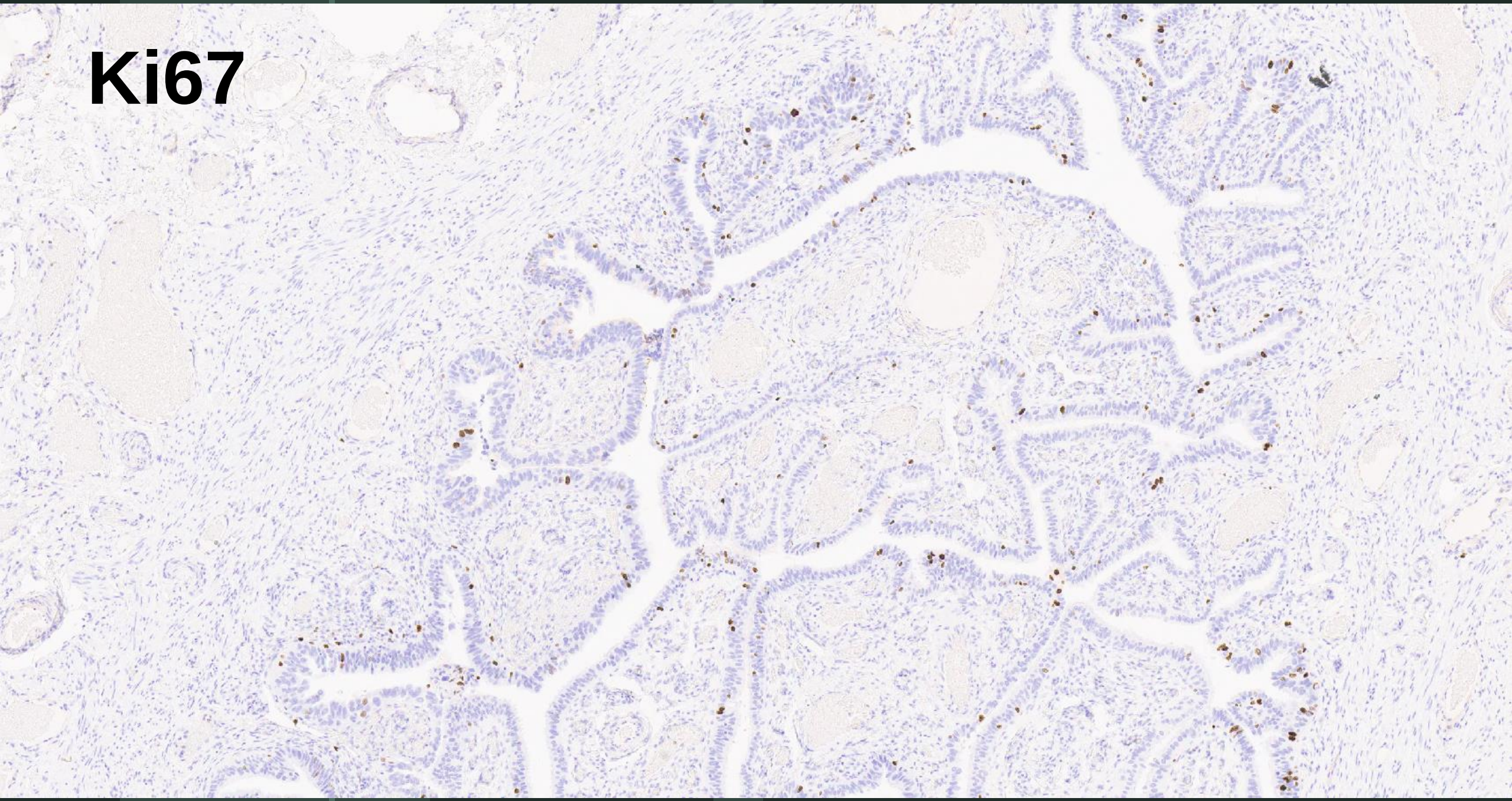

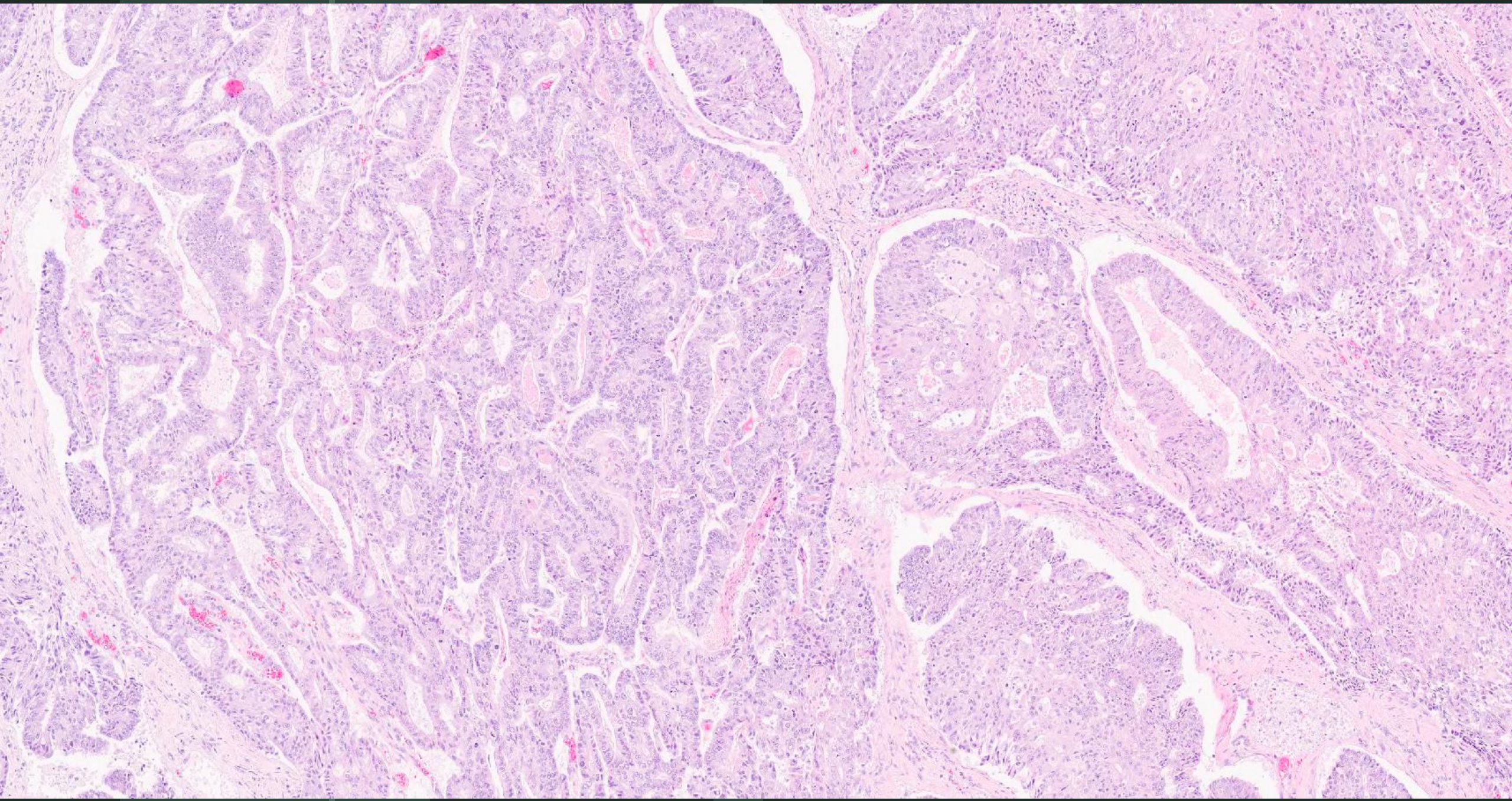

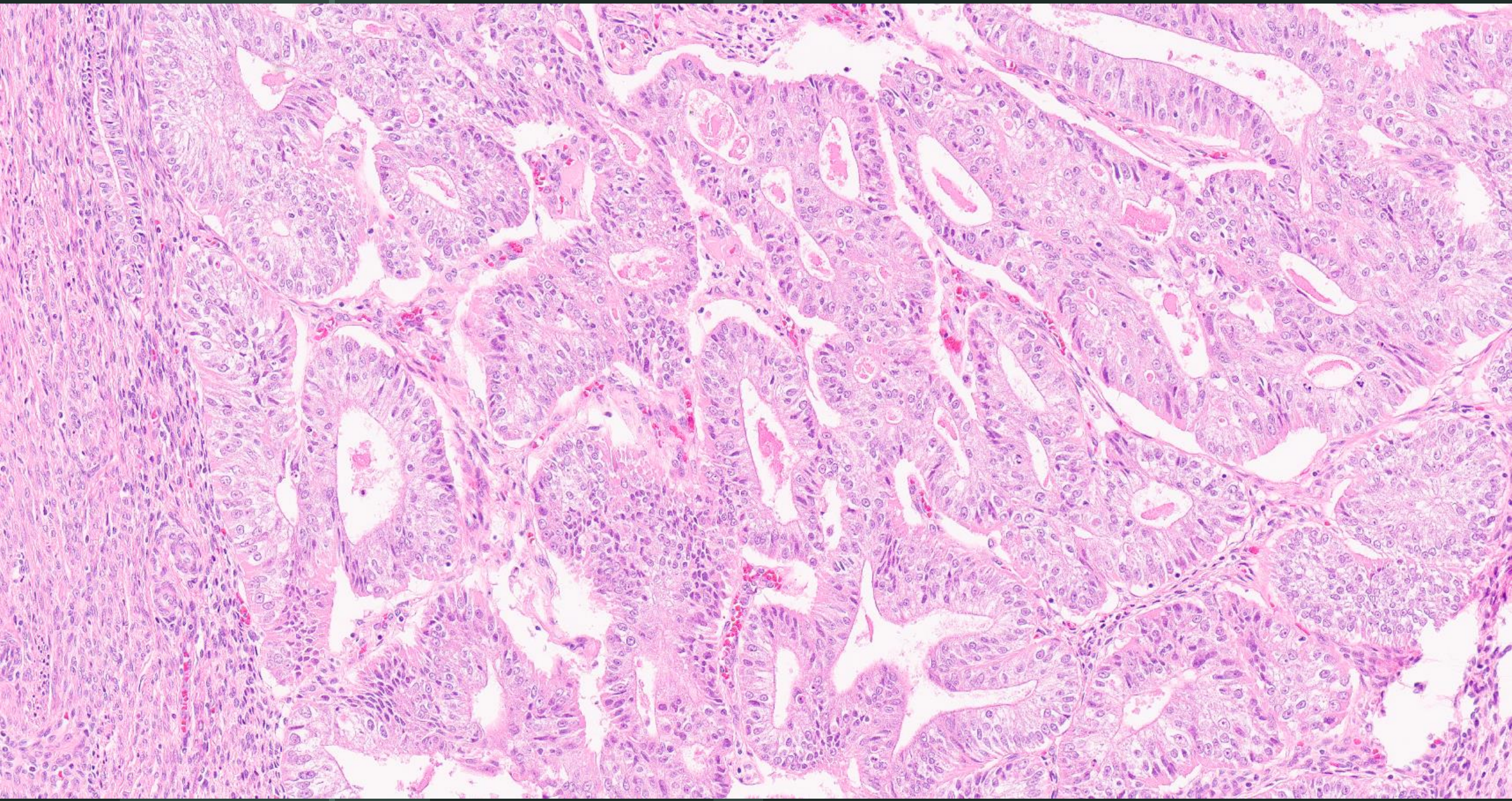

p53

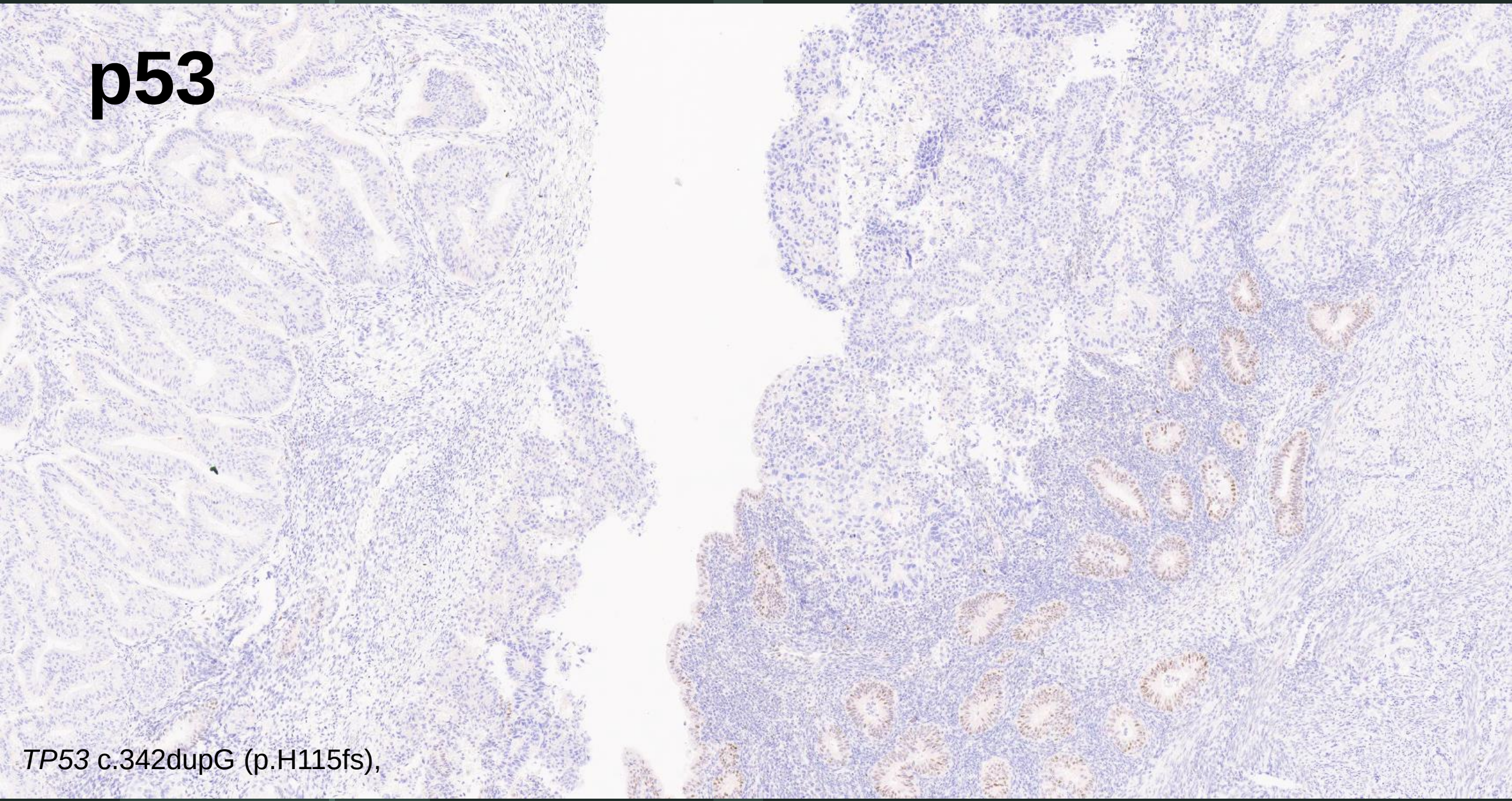

TP53 c.342dupG (p.H115fs),

How should you prosection fallopian tubes?

Dx: STIC

EEC2, stage IA, *TP53* mutant

Incidental STIC

2nd staging procedure with exploratory laparoscopy, washings and omental biopsy. No residual disease. Germ line BRCA negative.

Moved back to other country

SEE-FIM

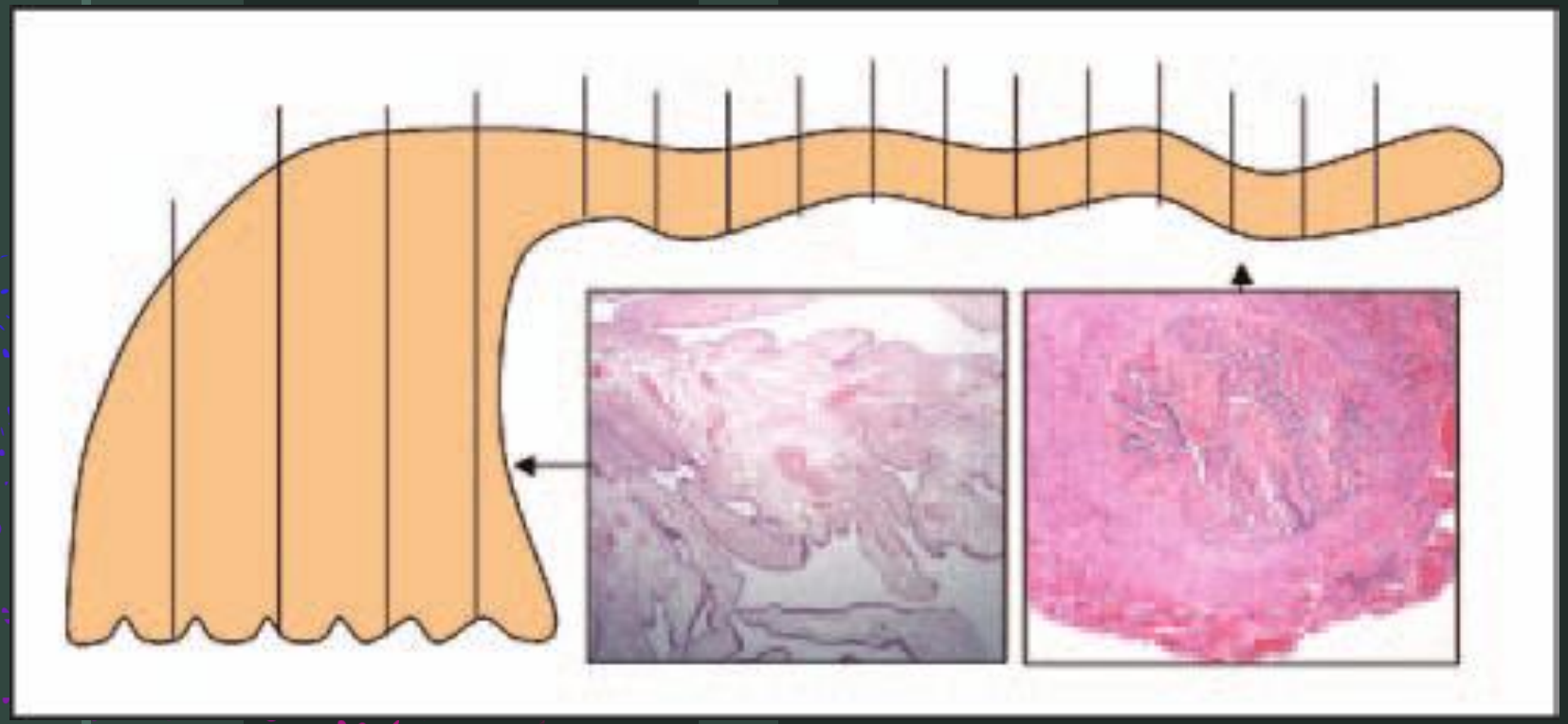

Sectioning and Extensively Examining the Fimbriated End Fallopian Tube.

→ amputation and longitudinal sectioning of the infundibulum and fimbriated end (distal 2 cm) to allow maximal exposure of the tubal plicae

→ isthmus and ampulla are cut transversely at 2- to 3-mm intervals

From Crum et al. Curr Opin Obstet Gynecol. 2007;19(1):3-9.

Prosectioning

- Incidence of STIC
  - Total embedding: 3.2% vs Not total embedding: 1.7%
- Koc et al. HGSC cases
  - 39 SEE-FIM, found 15 STIC vs 113 representative, found 1 STIC

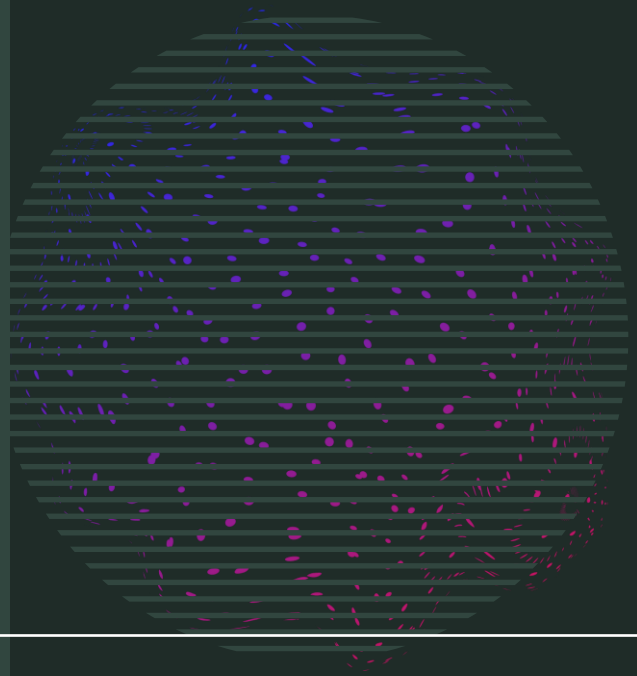

Bogaerts/Simons 2022, PMID: 34850262; Koc/Arinkan 2018, PMID: 27539290

Prosectioning – When to SEE-FIM?

- Low probability of finding STIC in general population
- Little clinical consequence if found adjacent to HGSC
- Reserved to selected cases, at high risk of HGSC
    - BRCA1/2, or other HRD carriers
    - Strong family history



Bogaerts/Simons 2022, PMID: 34850262; Koc/Arinkan 2018, PMID: 27539290

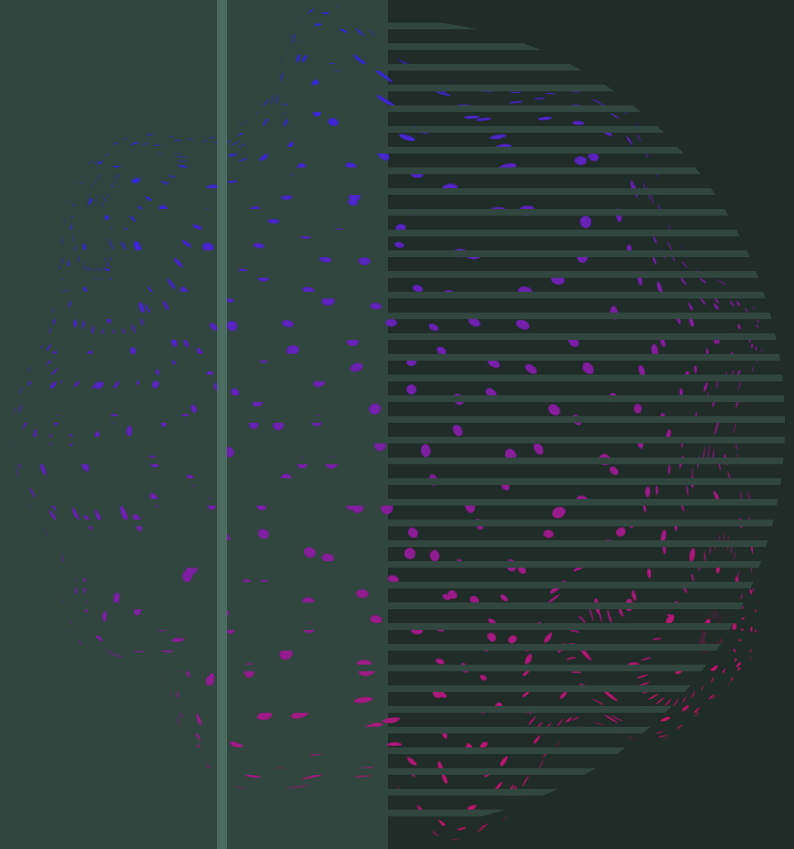

Case 5

A 39-year-old female undergoes TH-BS for menorrhagia and dysmenorrhea

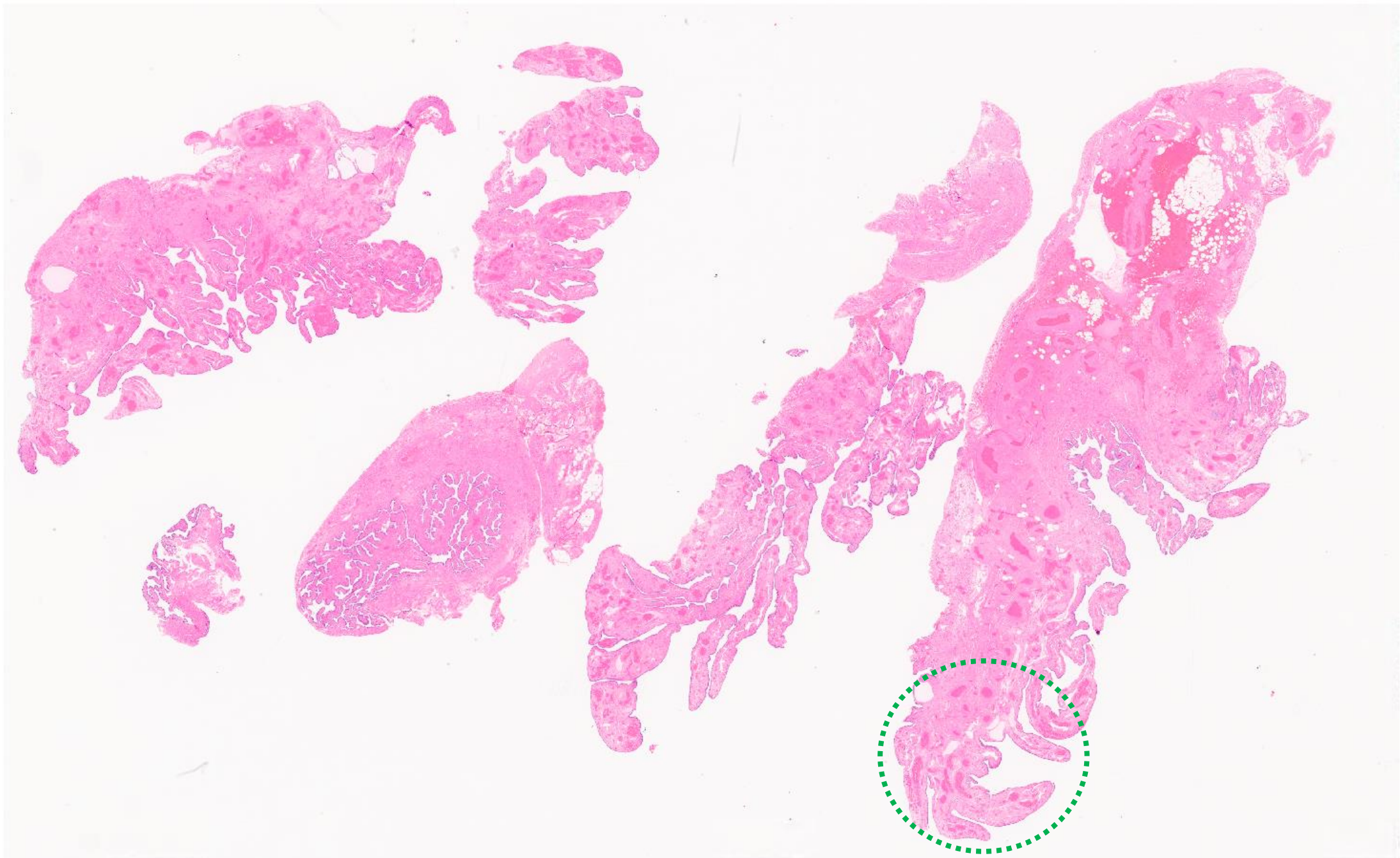

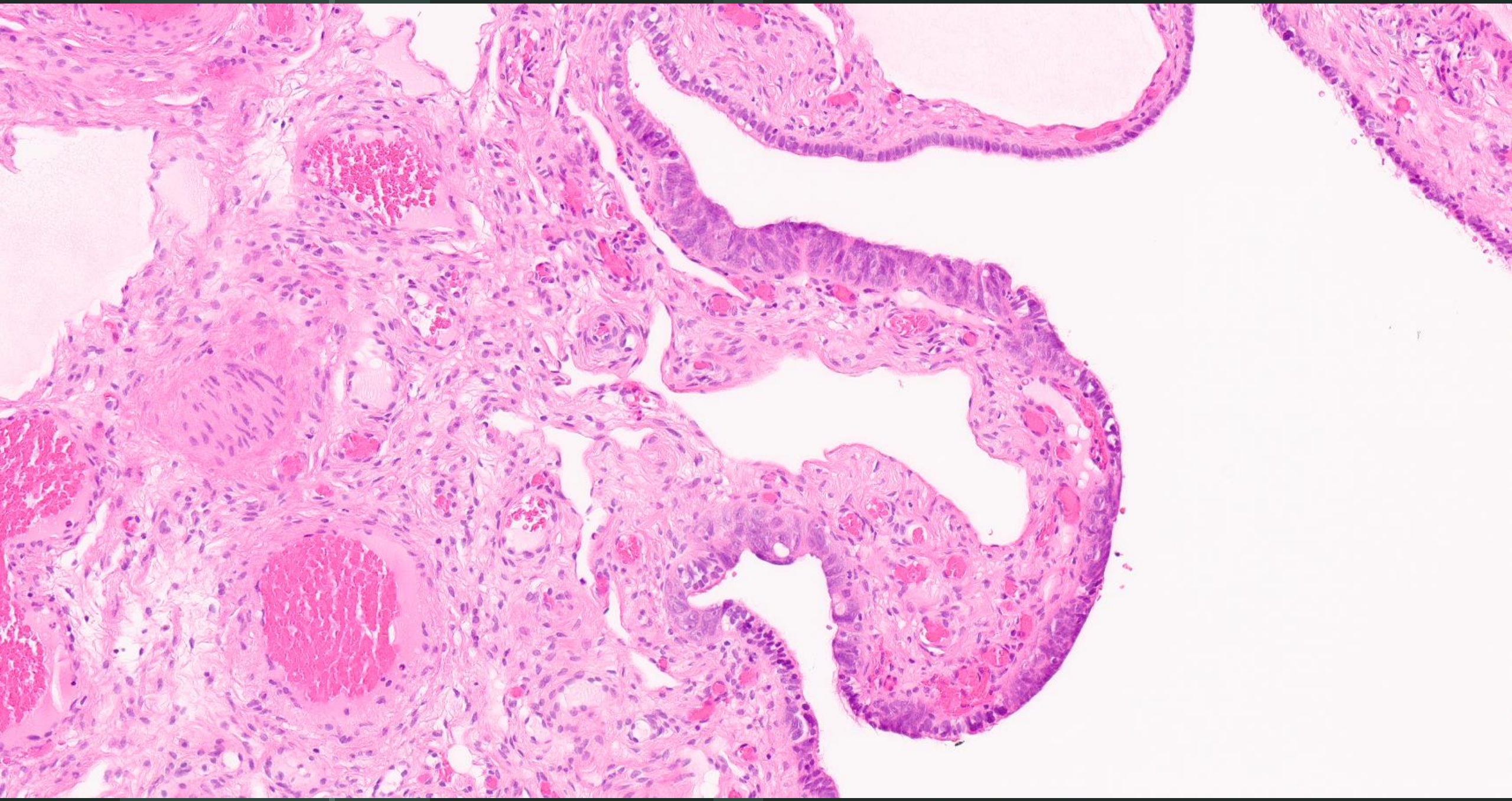

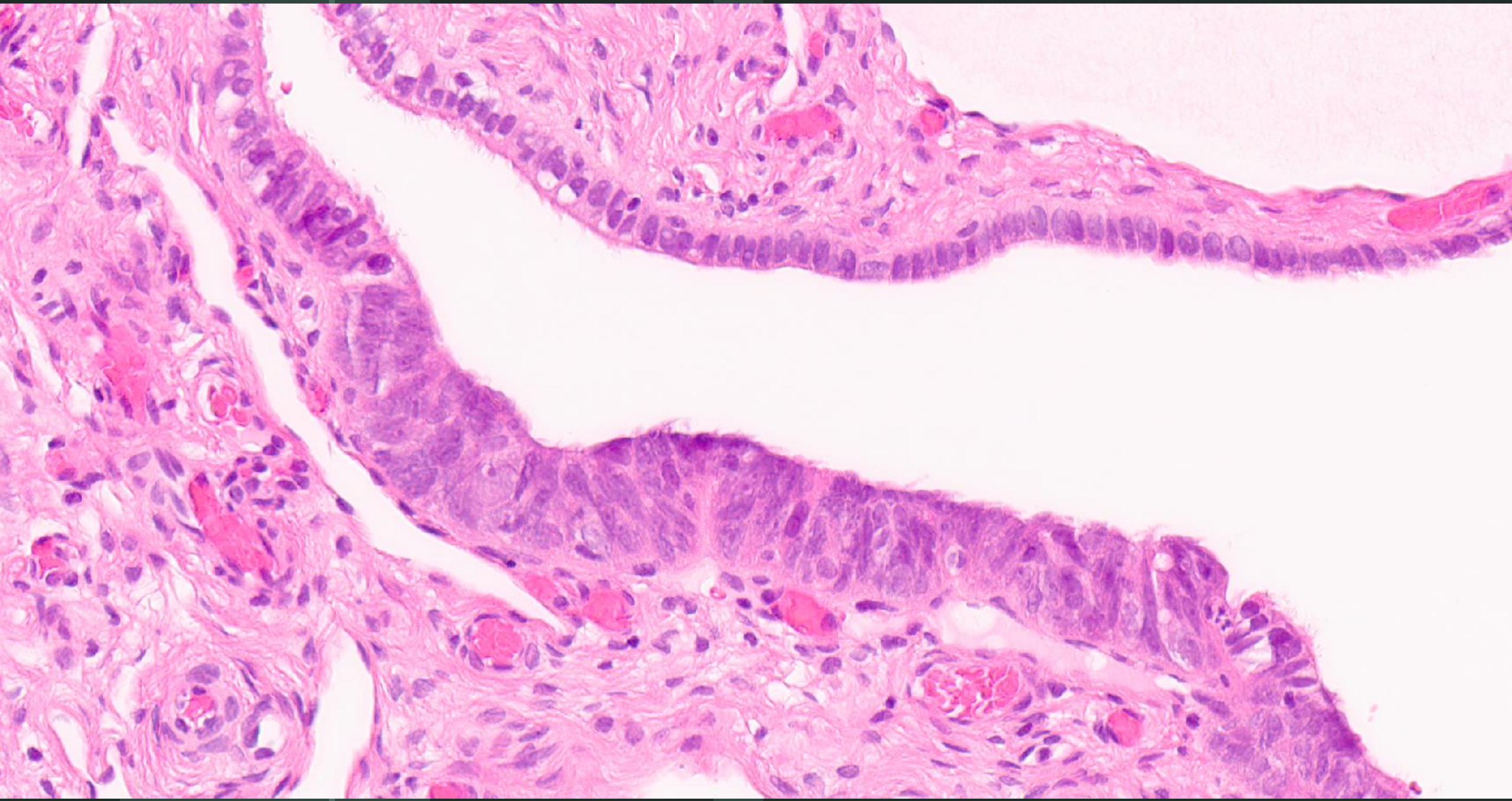

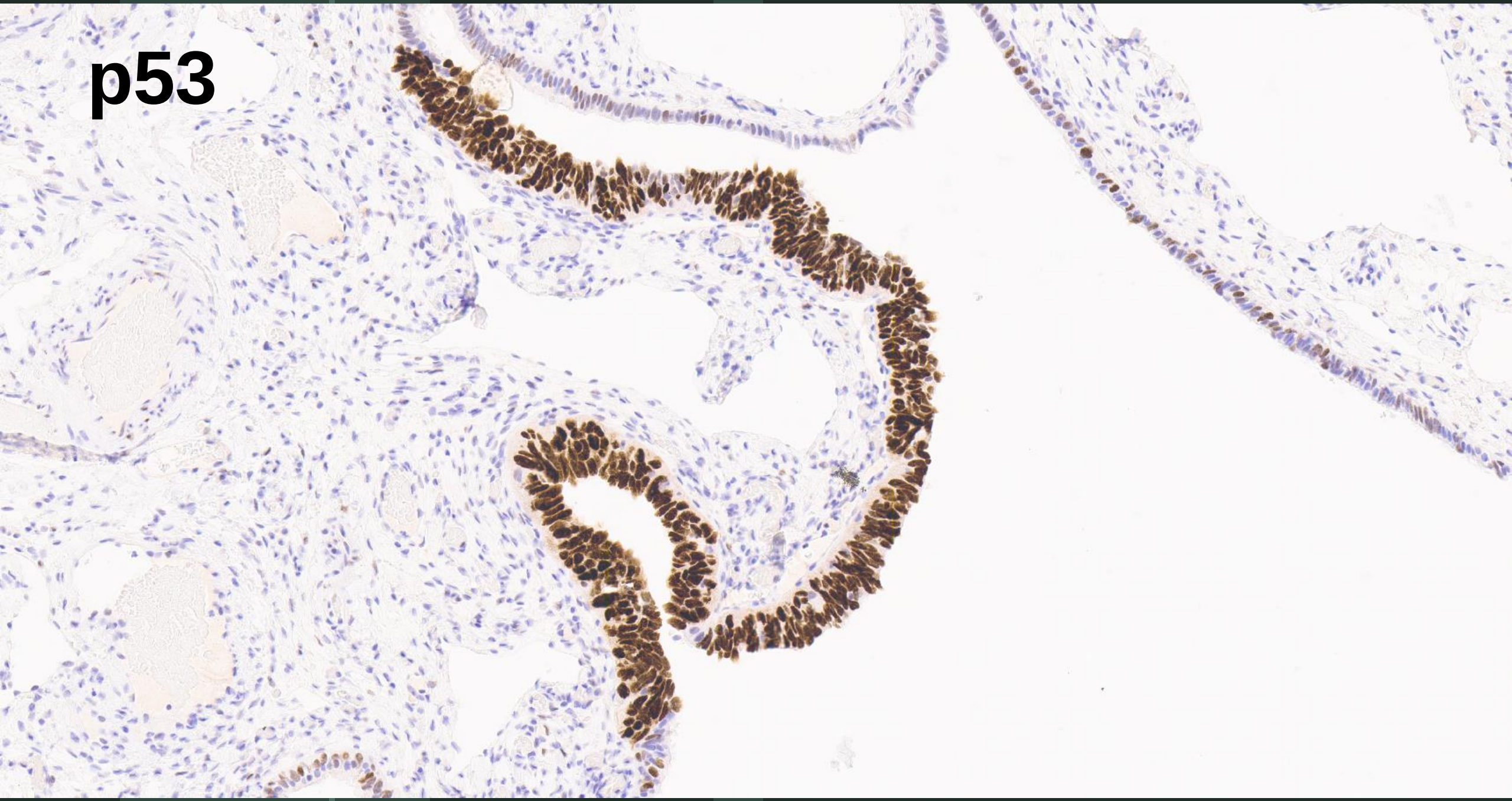
p53

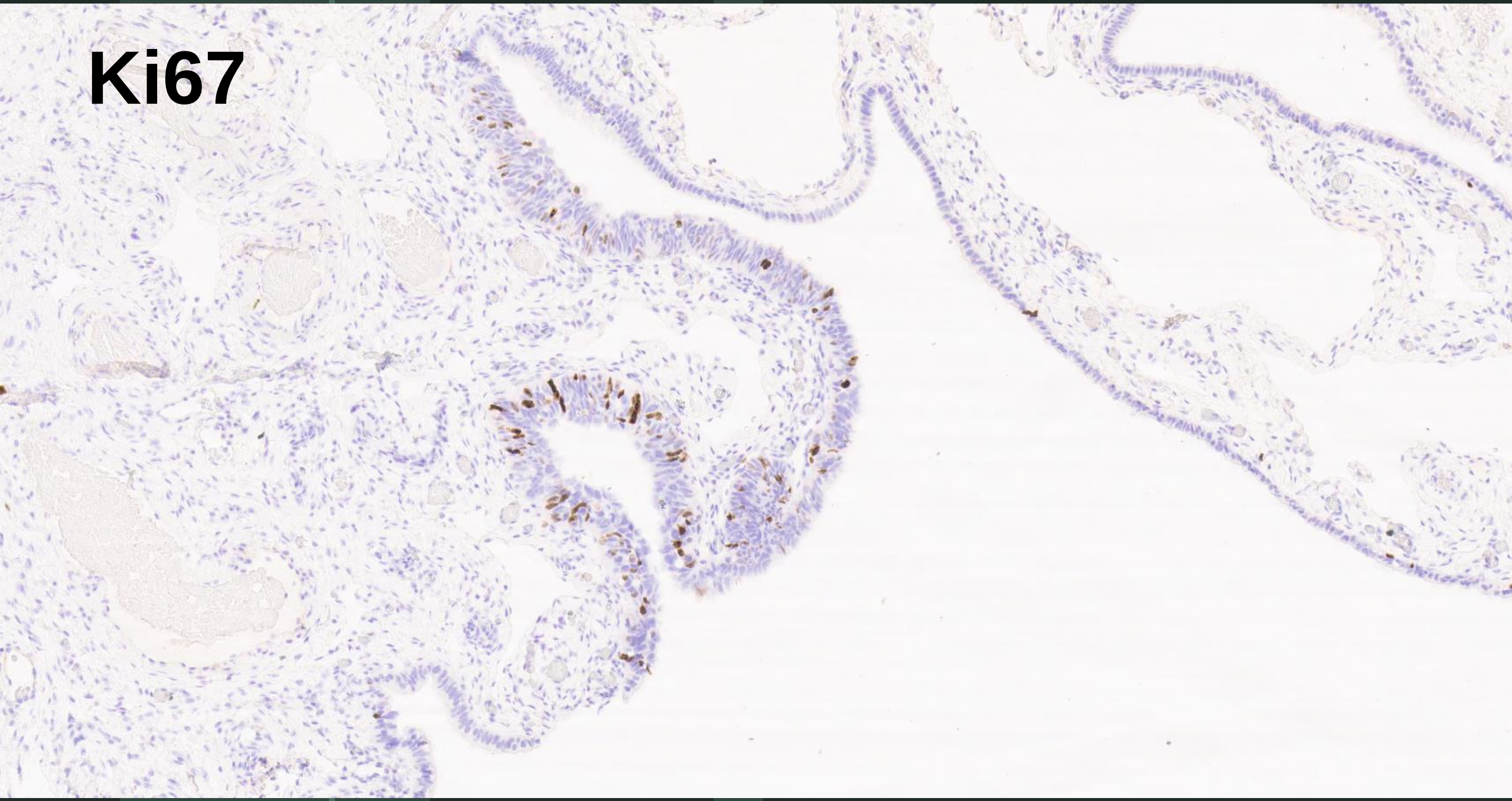
Ki67

How is STIC staged?

Dx: STIC

Completion staging surgery, consisting of BSO, omental biopsy, and washings → all negative

Offered BRCA testing
→ Declined

Undergoes surveillance

No recurrence/transformation but dealing with symptoms of surgical menopause

Staging

- AJCC 8th Edition:
  - co-existing STIC should be classified as a primary stage IA carcinoma of the ovary (does not alter staging)
- CAP and ICCR:
  - STIC without invasion or extratubal spread may be staged as IA
  - STIC or invasive carcinoma involving tubal mucosa or inseparable tubo-ovarian mass should be designated a primary fallopian tube carcinoma
- ESMO and ESGO:
  - HGSC involving the ovary with a STIC should be classified as a stage IIA fallopian tube primary

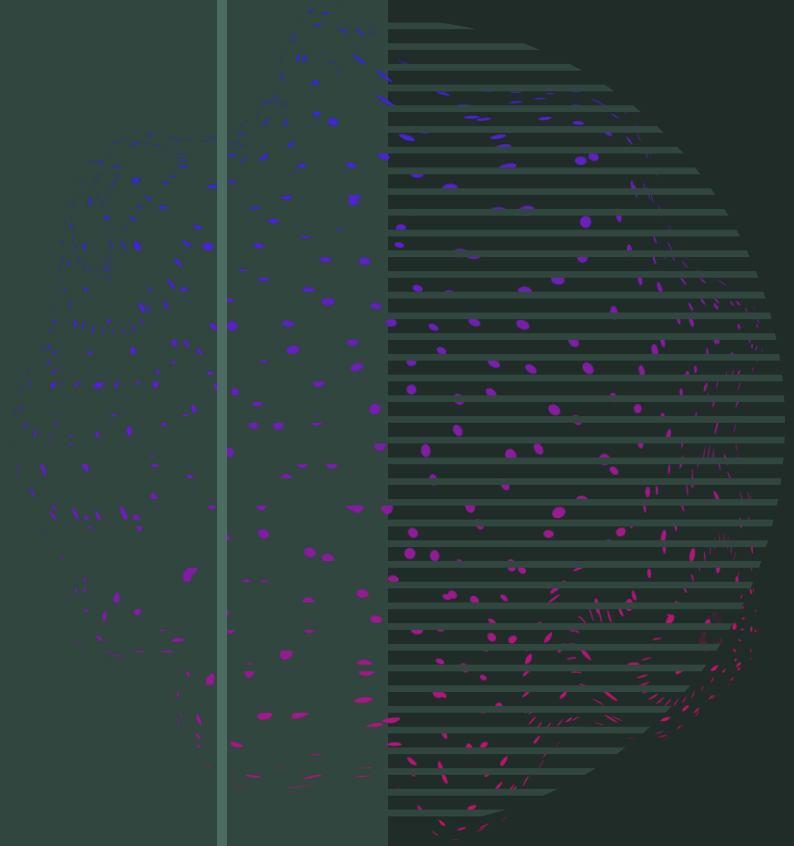

STIL and related lesions…

What are we supposed to do with them?

STIL: Serous Tubal Intraepithelial Lesion

- A “transitional” lesion between normal epithelium and STIC
- WHO: “STIL is a related lesion that shows variable morphology, p53 expression and Ki67 immunostaining, falling short of the full criteria for STIC”

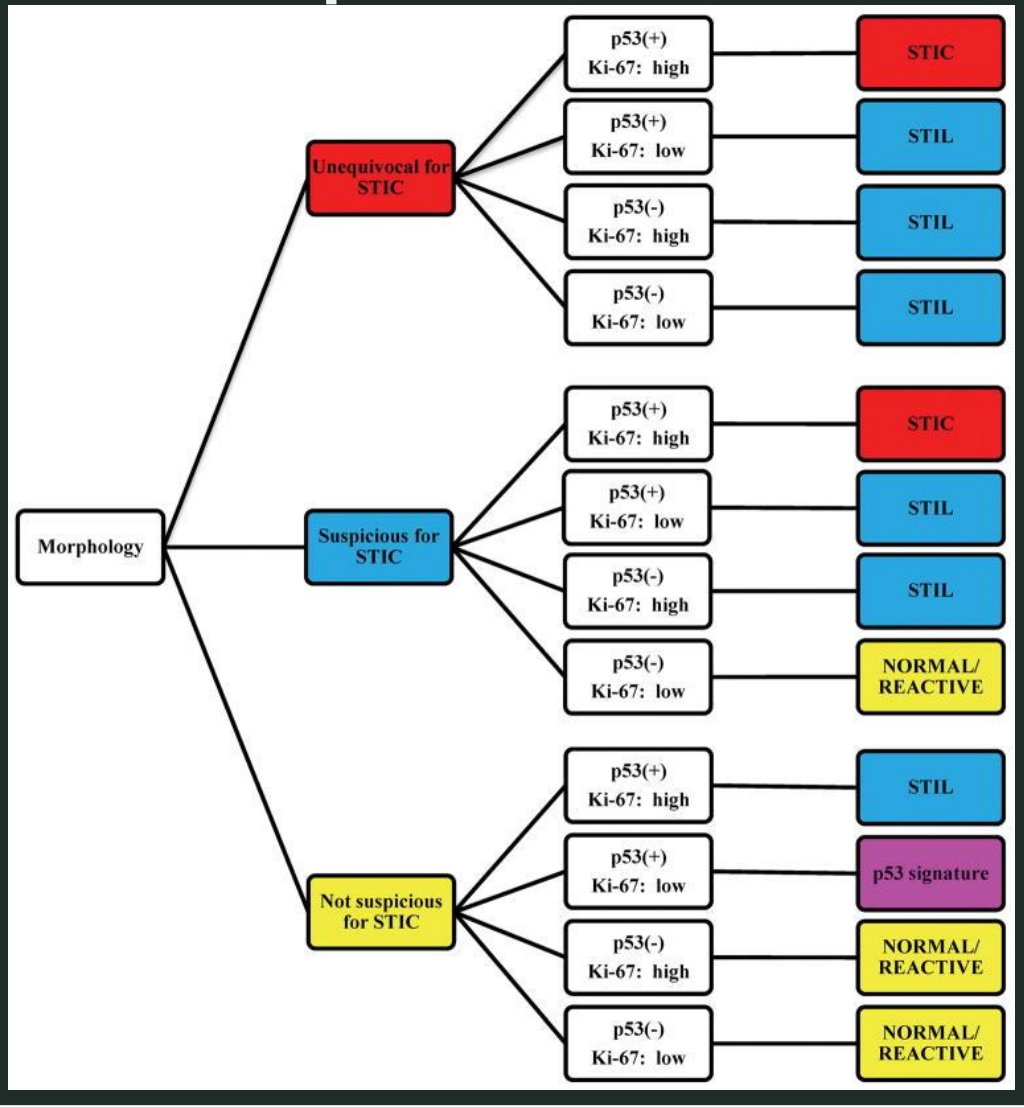

Vang/Kurman 2012; PMID: 22498942

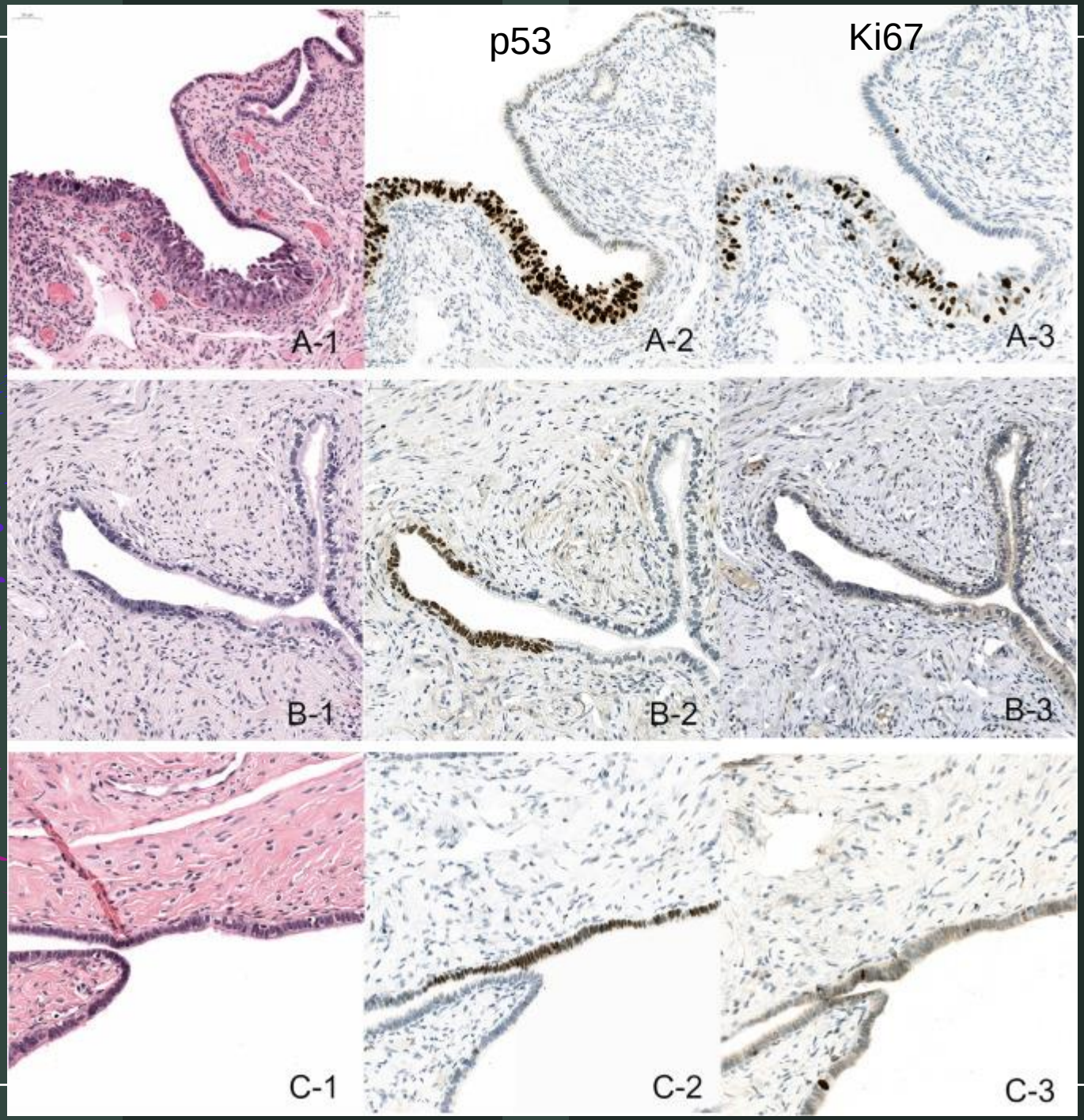

STIC

STIL

p53 signature

Bogaerts PMID: 34850262

STIL: Serous Tubal Intraepithelial Lesion

- Variety of names:
  - Tubal intra-epithelial lesion in transition [TILT]
  - Tubal dysplasia
  - Dormant STIC [atypia + p53abn, low Ki67]
- Pathogenesis:
  - Intermediate # of somatic mutations by WES
- Seen in ~9% of fallopian tubes
- Designation should be restricted to research purposes (not for pathology reports)

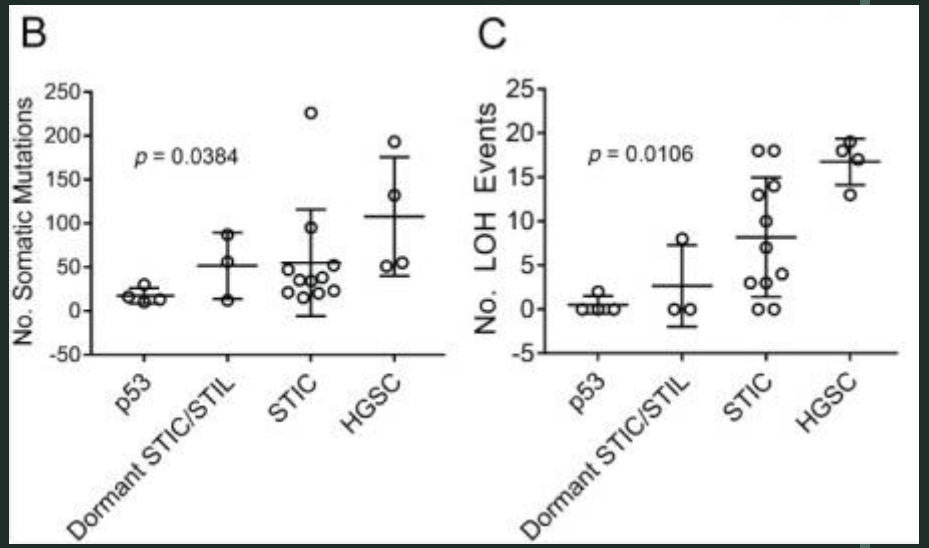

•Vang/Shih 2022; PMID: 35859323, Wu/Wang 2019 PMID: 30560554

p53 Signatures

- Morphologically normal exhibiting strong staining for p53
  - ≥ 12 consecutive secretory cells
- Pathogenesis:
  - Show immunostaining for γ-H2AX, marker of DNA damage
  - Show telomere shortening
- Thought to be an early event in the pathway to HGSC
- Wide reported frequencies
  - 2% of salpingectomies; 10-71% in BRCA mutations, 17-50% in background population
  - Higher frequency and more often multifocal when co-existing STIC
- Designation should be restricted to research purposes (not for pathology reports)

•Vang/Shih 2022; PMID: 35859323

SCOUT: Secretory (or stem) Cell Outgrowth

- ≥ 30 secretory cells without intervening ciliated cells
- Benign, but may represent a ‘transitional’ lesion to STIC
- Do not have p53 abnormalities or elevated Ki67; reduced PAX2
- Found in 45% of fallopian tubes; More common in patients with HGSC

- Type I: have conspicuous ciliated differentiation
- Type II: “endometrioid” in appearance, limited ciliated cells, pseudostratified growth

- Designation should be restricted to research purposes (not for pathology reports)

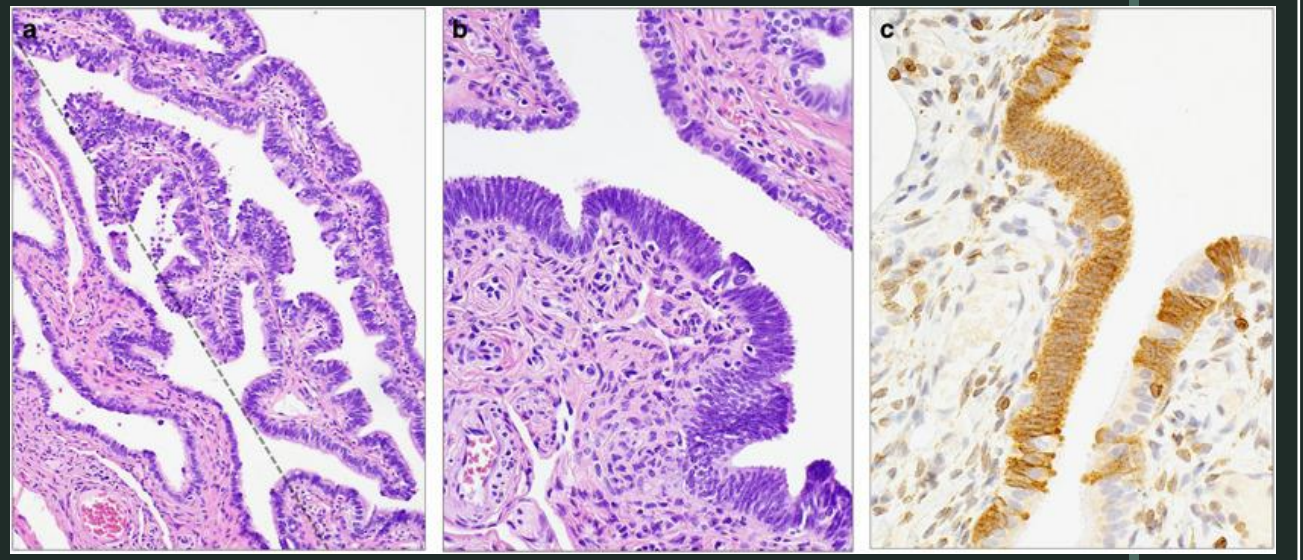

•Vang/Shih 2022; PMID: 35859323; Meserve/Crum 2017 PMID: 28106106

Metastatic tumor can mimic STIC

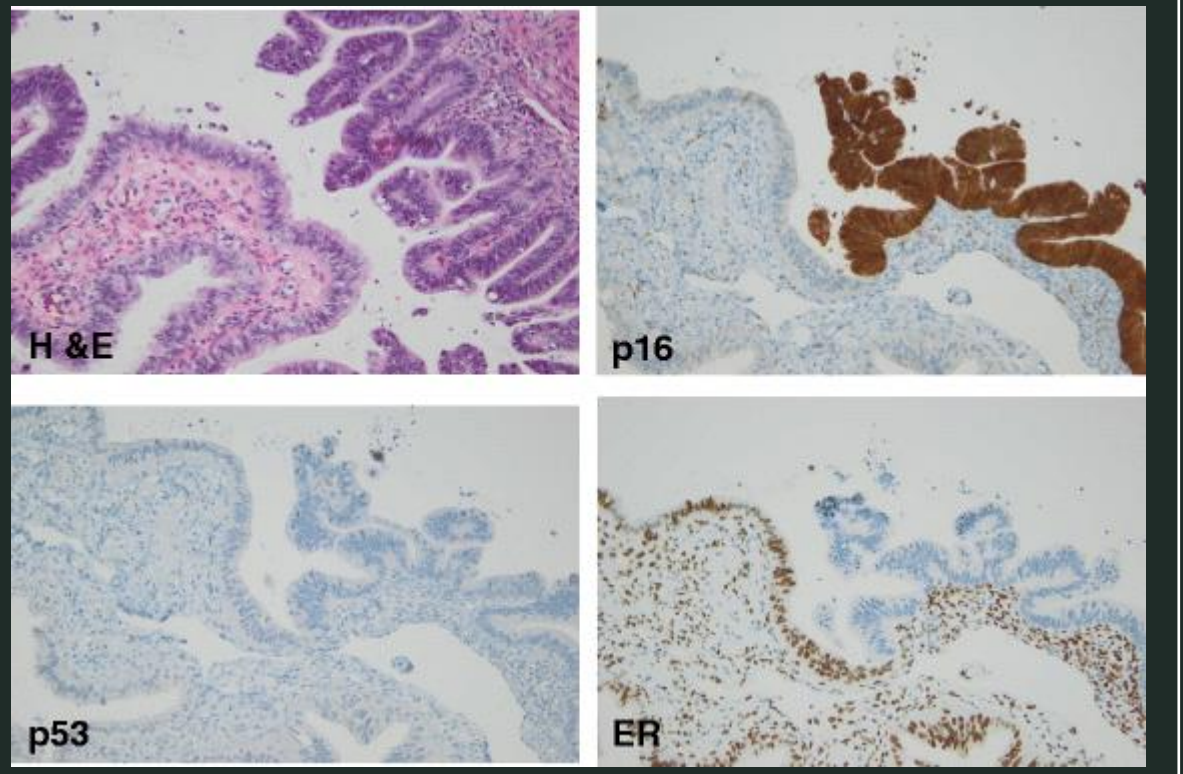

Metastatic Endocervical Adenocarcinoma to Fallopian Tube

Deel/Zuna 2016; PMID: 27530463

Thank you~



Precursor: Chicken or the Egg?

- Finding of STIC in asymptomatic BRCA+ women
- Pre-invasive HGSC are more likely to be in fallopian tube (than ovary)
- Share identical mutations with HGSC
- Comparison of telomere length and centrosome amplification in matched STIC and ovarian HGSC support STIC as precursor (rather than metastatic deposit)
- Fallopian tube secretory cells can be transformed, producing serous carcinomas.

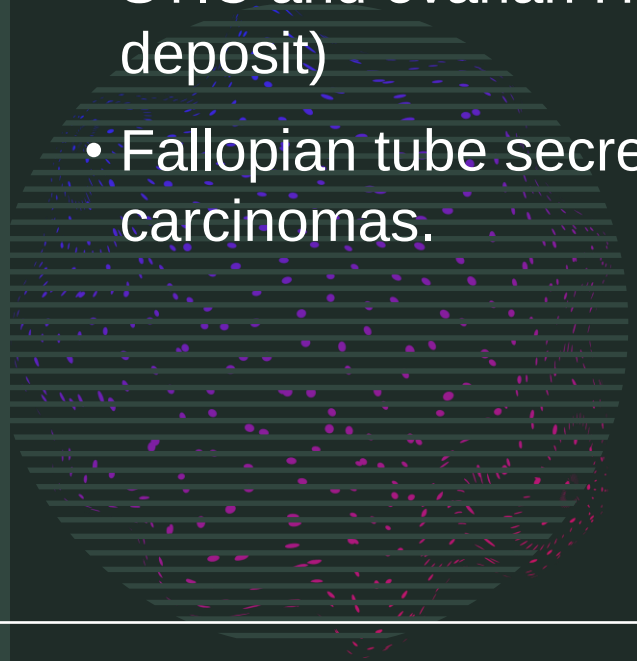

Kuhn/Shih 2010, PMID:20431479; Kuhn/Shih 2012, PMID: 21990067; Chien/Shih, PMID: 38298022; Pisanic II/Shih 2019, PMID: 30553834; Meserve/Crum 2017 PMID: 28106106

Uptake of Opportunistic Salpingectomy in Canada

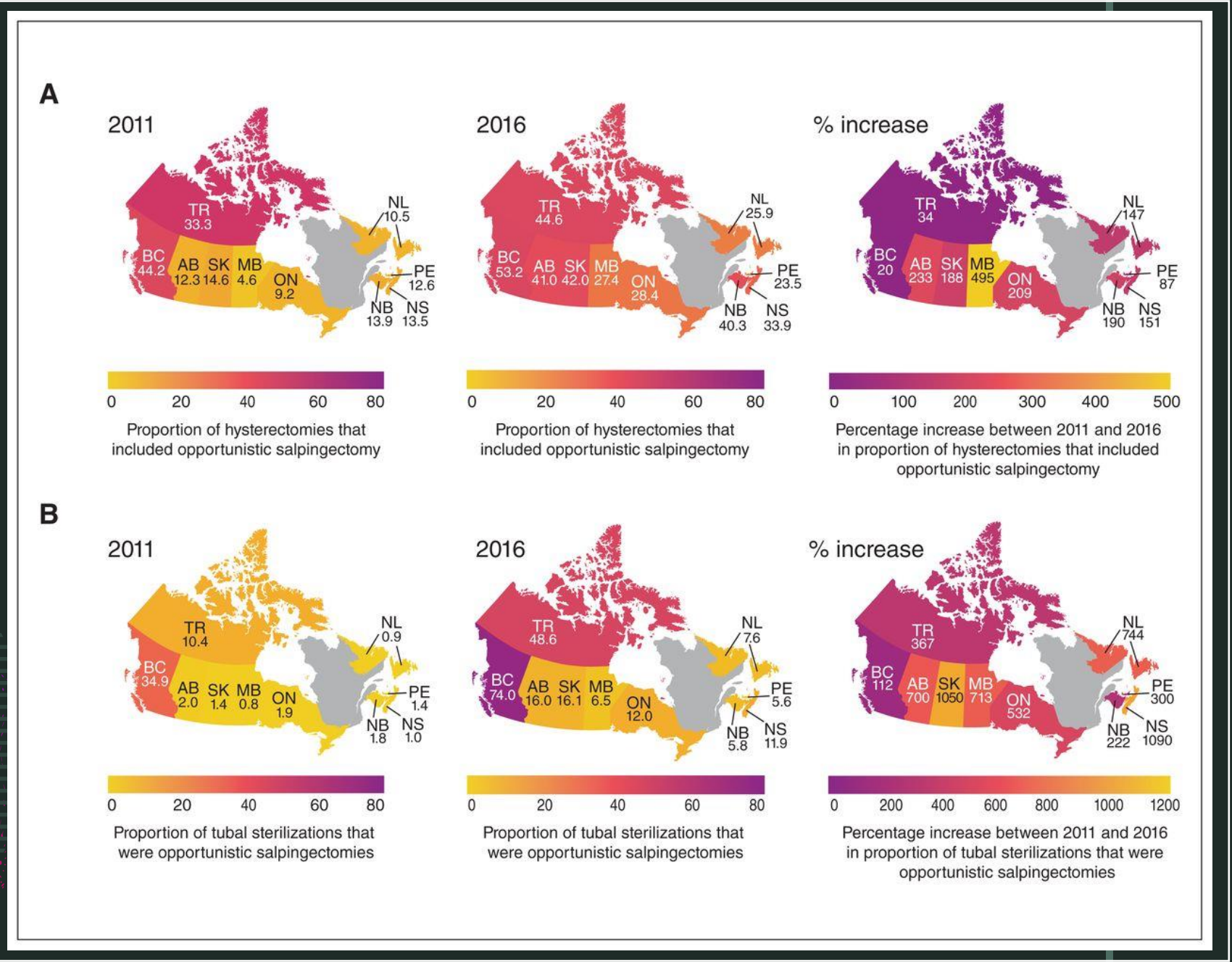

Hanley/Earle 2022; DOI: https://doi.org/10.9778/cmajo.20210219