The British Association of Gynaecological Pathologists

Lecturer – Professor Xavier Matias Guiu



Xavier Matias-Guiu (XM) obtained his PhD in 1987 in Barcelona. In 1991-92, XM was Research Fellow in Pathology at the New England Medical Centre/Tufts University in Boston. From 1986 to 2002, XM worked in Hospital Sant Pau, Barcelona. XM was Director of the Lleida Institute of Biomedical Research (IRBLLEIDA) from 2004 to 2015. Over the last nine years he has combined the position of Chairman of Pathology at Hospital Universitari Bellvitge in Barcelona, Chairman of Pathology at Hospital Universitari Arnau de Vilanova in Lleida, Professor of Pathology at University of Lleida and University of Barcelona, and the direction of research groups in IRBLLEIDA and IDIBELL, with especial focus in integrating molecular features of gynecological cancers in the appropriate microscopic context. XM has participated in guidelines in medical management of patients with gynecological cancer (ESMO-ESGO-ESTRO, ESMO-ESGO-ESP, ESGO-ESTRO-ESP guidelines, ISGYP guidelines, FIGO, and WHO classification of tumors of the female genital tract). He is currently Past President of the the International Society of Gynecological Pathology (ISGYP), and President Elect of the European Society of Pathology (ESP)

The British Association of Gynaecological Pathologists

Everyday Dilemmas in Gynaecological Pathology

- Synchronous endometrial and ovarian carcinoma
- Xavier Matias-Guiu
- Hospital Universitari Arnau de Vilanova
- March 08/03, 2025

The British Association of Gynaecological Pathologists

Speaker disclosures

Choose one

X I have no financial conflicts of interest to disclose

❑ I have the following to disclose

The British Association of Gynaecological Pathologists

Synchronous endometrioid carcinomas of the endometrium and the ovaries

X. Matias-Guiu, M.D.
Hospital Universitari Arnau de Vilanova, University of Lleida, IRBLLEIDA

Simultaneous endometrioid carcinomas of the endometrium and the ovaries

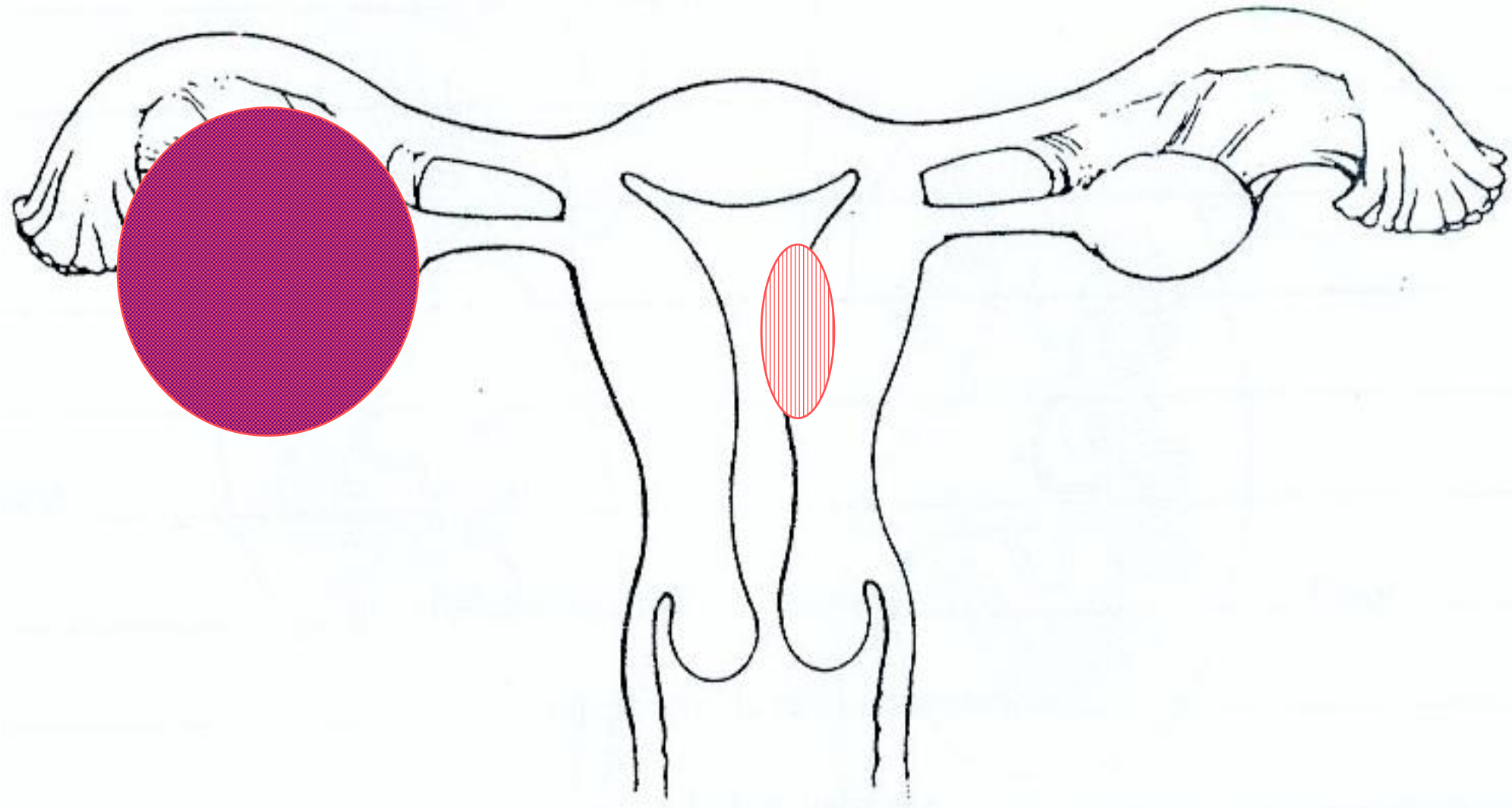

Simultaneous endometrioid carcinomas of the endometrium and the ovaries

- 15-20% ovarian endometrioid carcinomas, and 5% of endometrial carcinomas
- Usually favourable outcome suggest independent origin, but may be metastatic or uncertain

For non-endometrioid carcinomas, ovarian tumors should be also considered metastatic, unless histologic type is different between both tumors

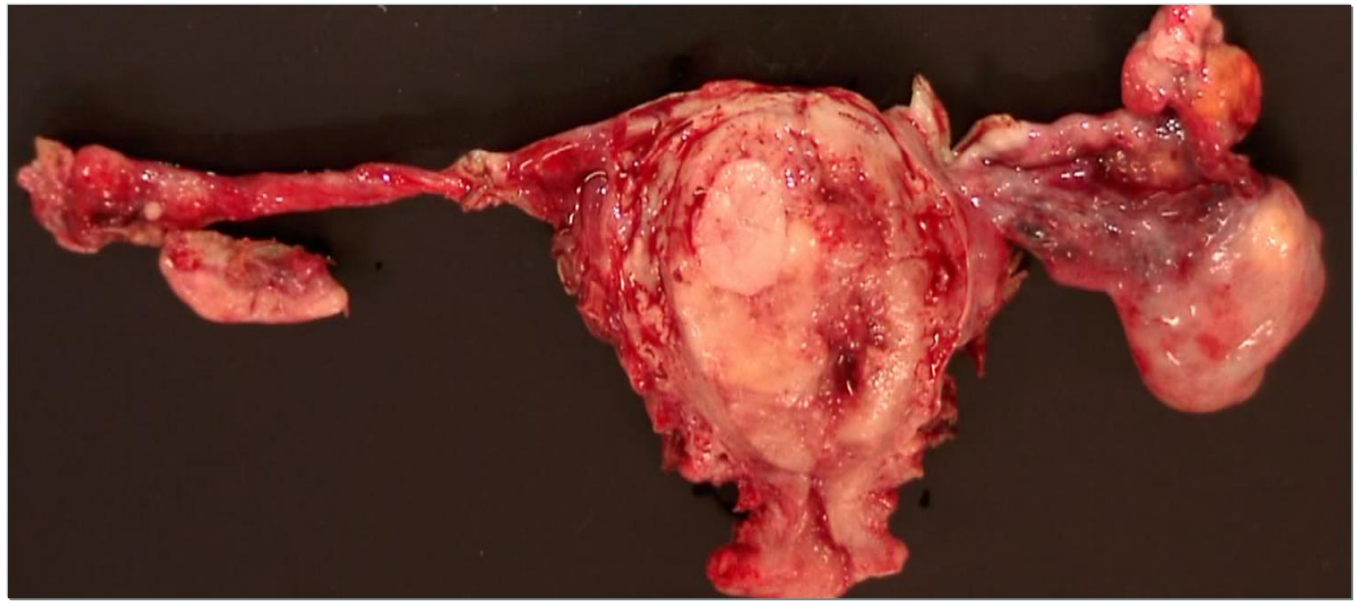

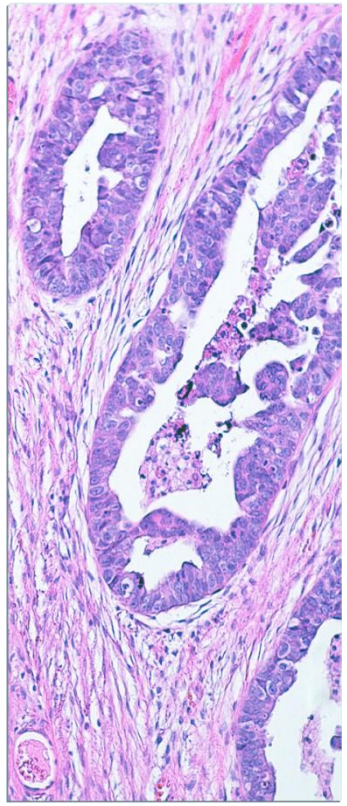

Simultaneous endometrioid carcinomas of the endometrium and the ovaries (Criteria)

- Tumor sizes
- Histological grades
- Bilaterality
- Pattern of tumor growth
- Tubal, myometrial, vascular invasion
- Presence of endometriosis

Simultaneous endometrioid carcinomas of the endometrium and the ovaries (Scully Criteria)



Atlas
of
Tumor Pathology

Tumors of the Ovary, Maldeveloped Gonads, Fallopian Tube, and Broad Ligament

by
Robert E. Scully, M.D.,
Robert H. Young, M.D., FRCPath,
and Philip B. Clement, M.D.

UNIVERSITAT DE LLEIDA
Biblioteca
1600215464

AFIP

Table 5-1

ENDOMETRIOID TUMORS OF OVARY AND ENDOMETRIUM

**Endometrial Primary
Ovarian Secondary**

1. Histologic similarity of the tumors
2. Large endometrial tumor - small ovarian tumor(s)
3. Atypical endometrial hyperplasia additionally present
4. Deep myometrial invasion
   a. Direct extension into adnexa
   b. Vascular space invasion in myometrium
5. Spread elsewhere in typical pattern of endometrial carcinoma
6. Ovarian tumors bilateral and/or multinodular
7. Hilar location, vascular space invasion, surface implants, or combination in ovary
8. Ovarian endometriosis absent
9. Aneuploidy with similar DNA indices or diploidy of both tumors*
10. Similar molecular genetic or karyotypic abnormalities in both tumors

*The possibility of tumor heterogeneity must be taken into account in the evaluation of the ploidy findings.

Table 5-3

ENDOMETRIOID TUMORS OF OVARY AND ENDOMETRIUM

Independent Primary Tumors

1. Histologic dissimilarity of the tumors
2. No or only superficial myometrial invasion of endometrial tumor
3. No vascular space invasion of endometrial tumor
4. Atypical endometrial hyperplasia additionally present
5. Absence of other evidence of spread of endometrial tumor
6. Ovarian tumor unilateral (80 to 90 percent of cases)
7. Ovarian tumor located in parenchyma
8. No vascular space invasion, surface implants, or predominant hilar location in ovary
9. Absence of other evidence of spread of ovarian tumor
10. Ovarian endometriosis present
11. Different ploidy or DNA indices, if aneuploid, of the tumors*
12. Dissimilar molecular genetic or karyotypic abnormalities in the tumors

SYNCHRONOUS **METASTATIC**

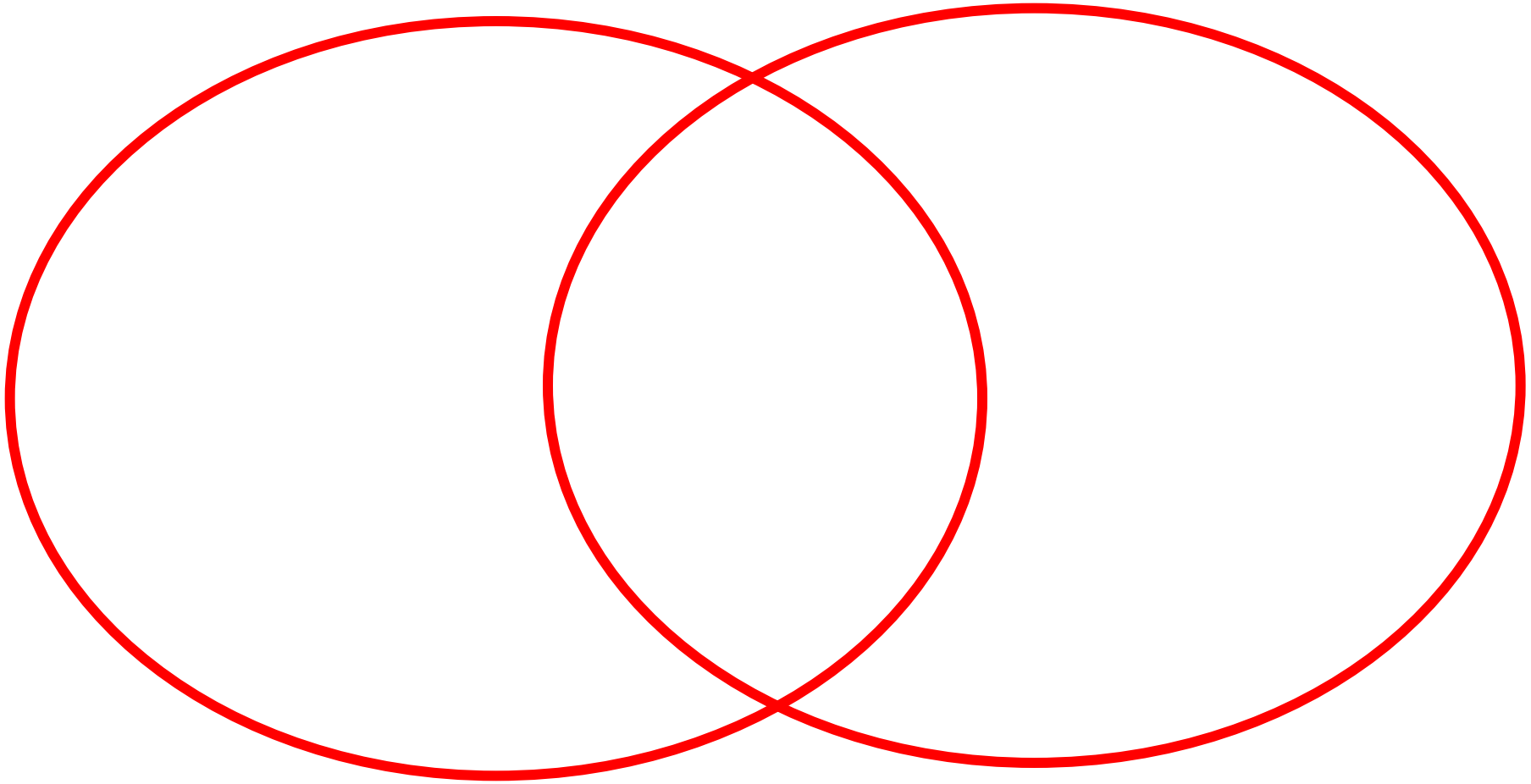

Prat J, Matias-Guiu X, Barreto J: Simultaneous carcinoma involving the endometrium and the ovaries. Cancer 1991 68:2455-9

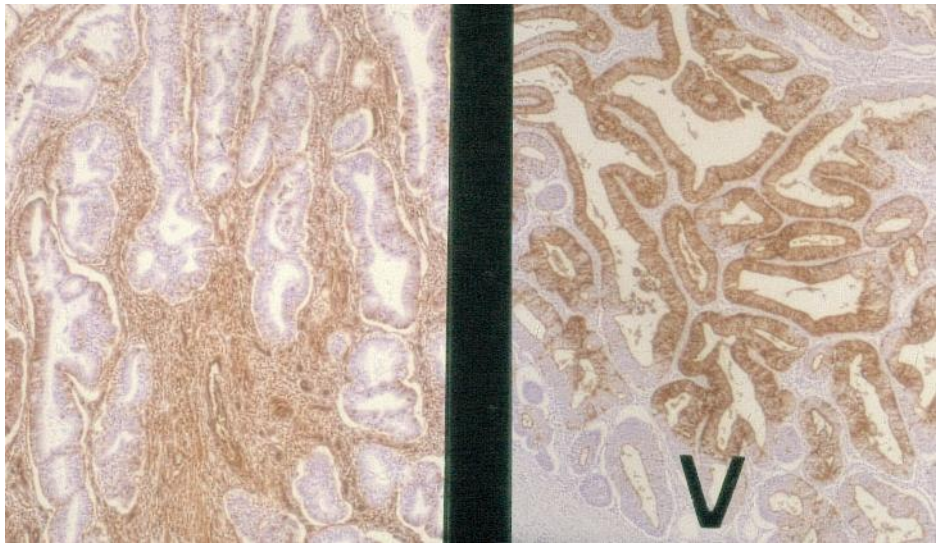

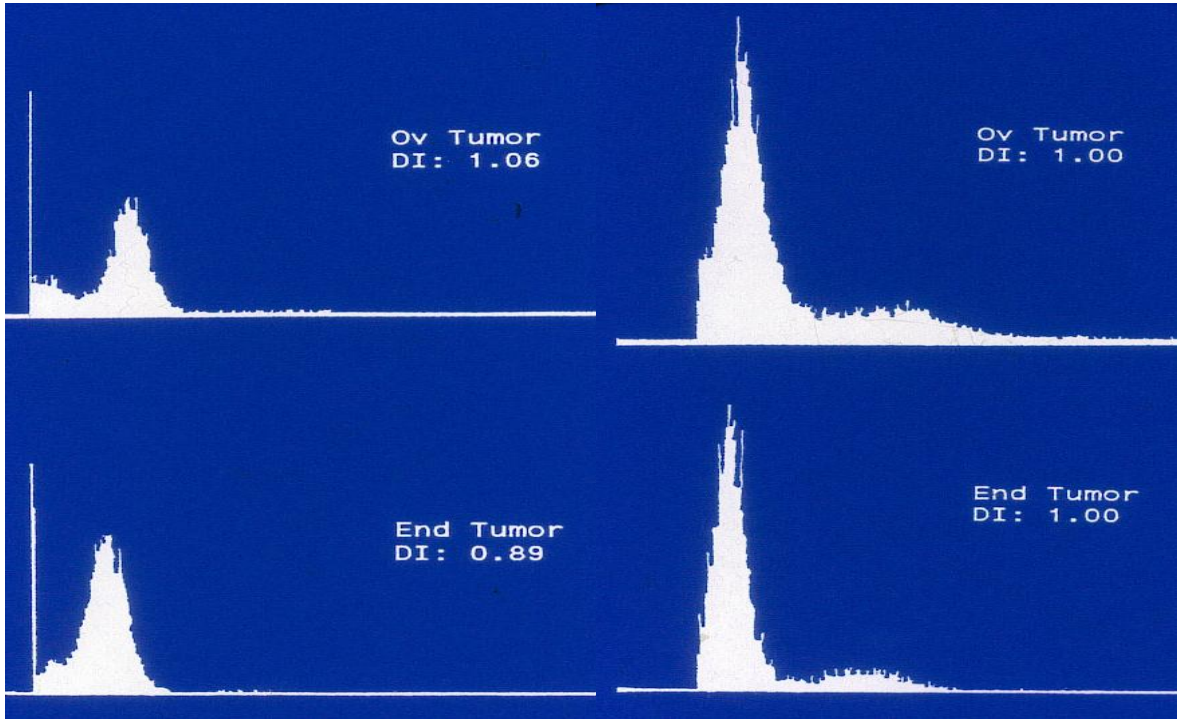

Human Pathology (2005) 36, 605–619

ELSEVIER

Human
PATHOLOGY

www.elsevier.com/locate/humpath

Original contributions

Synchronous endometrioid carcinomas of the uterine corpus and ovary: alterations in the β-catenin (*CTNNB1*) pathway are associated with independent primary tumors and favorable prognosis☆

Julie A. Irving MD, FRCPC[1], Lluis Catasús PhD, Alberto Gallardo MD, Elena Bussaglia PhD, Marisa Romero BSc[2], Xavier Matias-Guiu MD[3], Jaime Prat MD, FRCPath*

ENDOMETRIUM

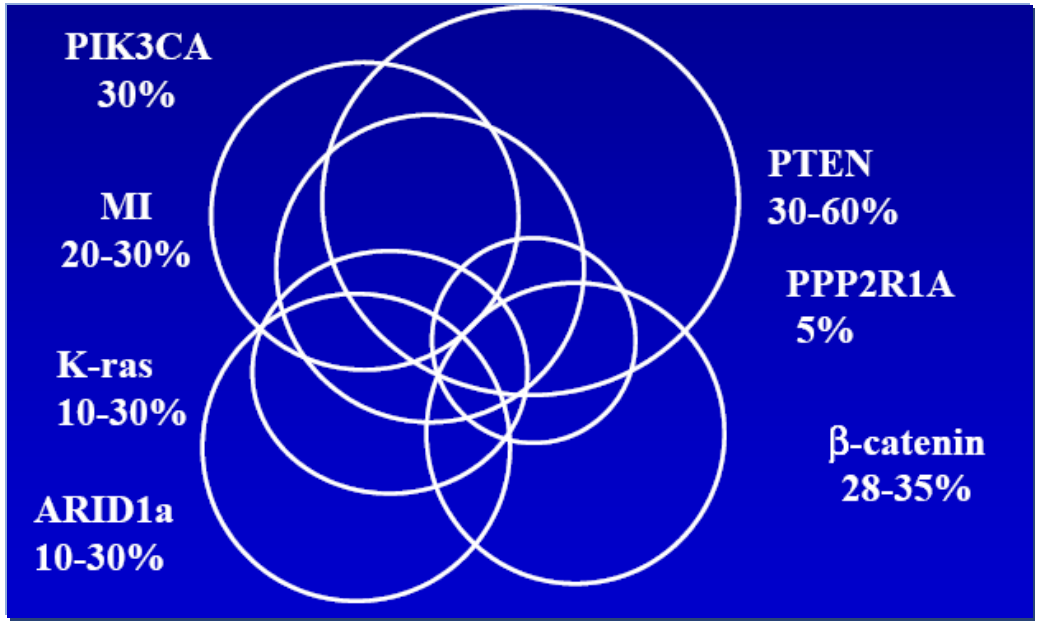

OVARY

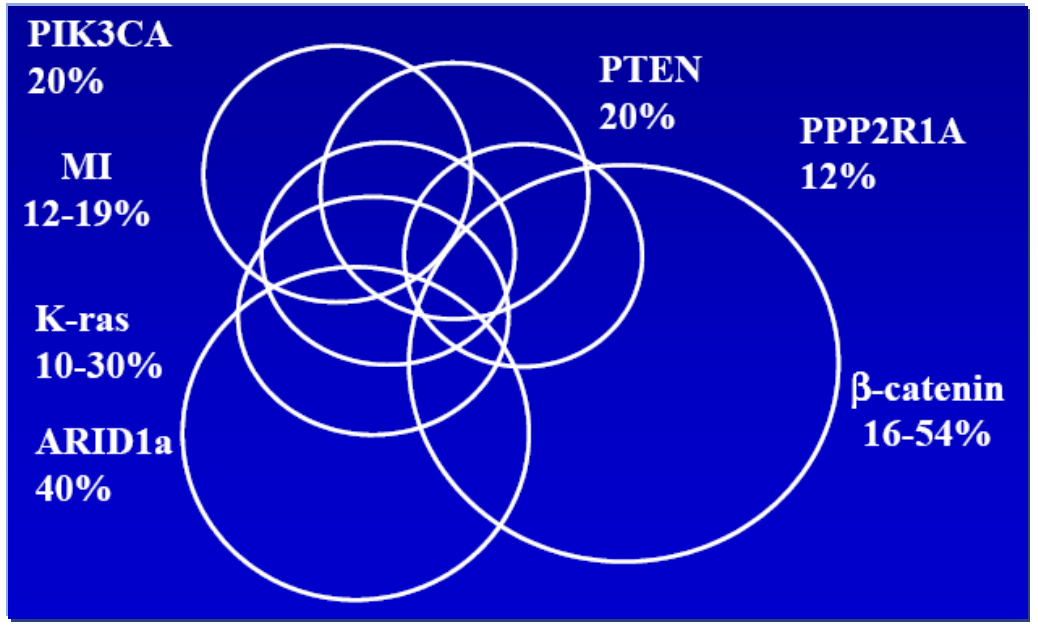

Metastatic Carcinoma

(Identical MI pattern - AWT at 3 y)

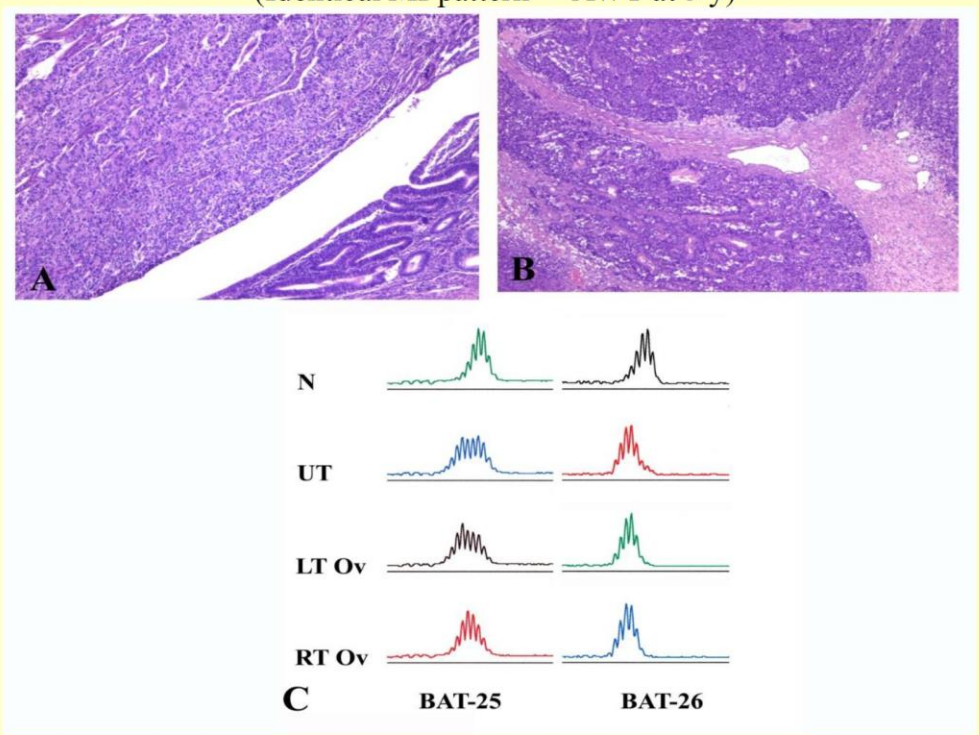

Irving J et al Hum Pathol 2005

Independent Primary Endometrioid Carcinomas of Uterus and Ovary

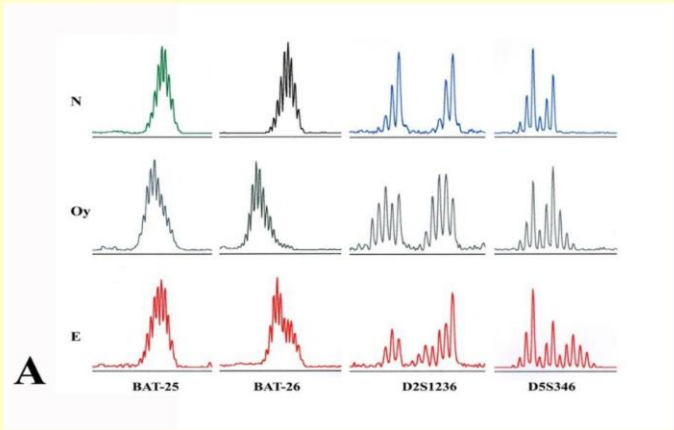

Different MI pattern

Simultaneous endometrioid carcinomas of the endometrium and the ovaries

Sometimes in some “clinically independent tumors” some molecular alterations are shared by both tumors

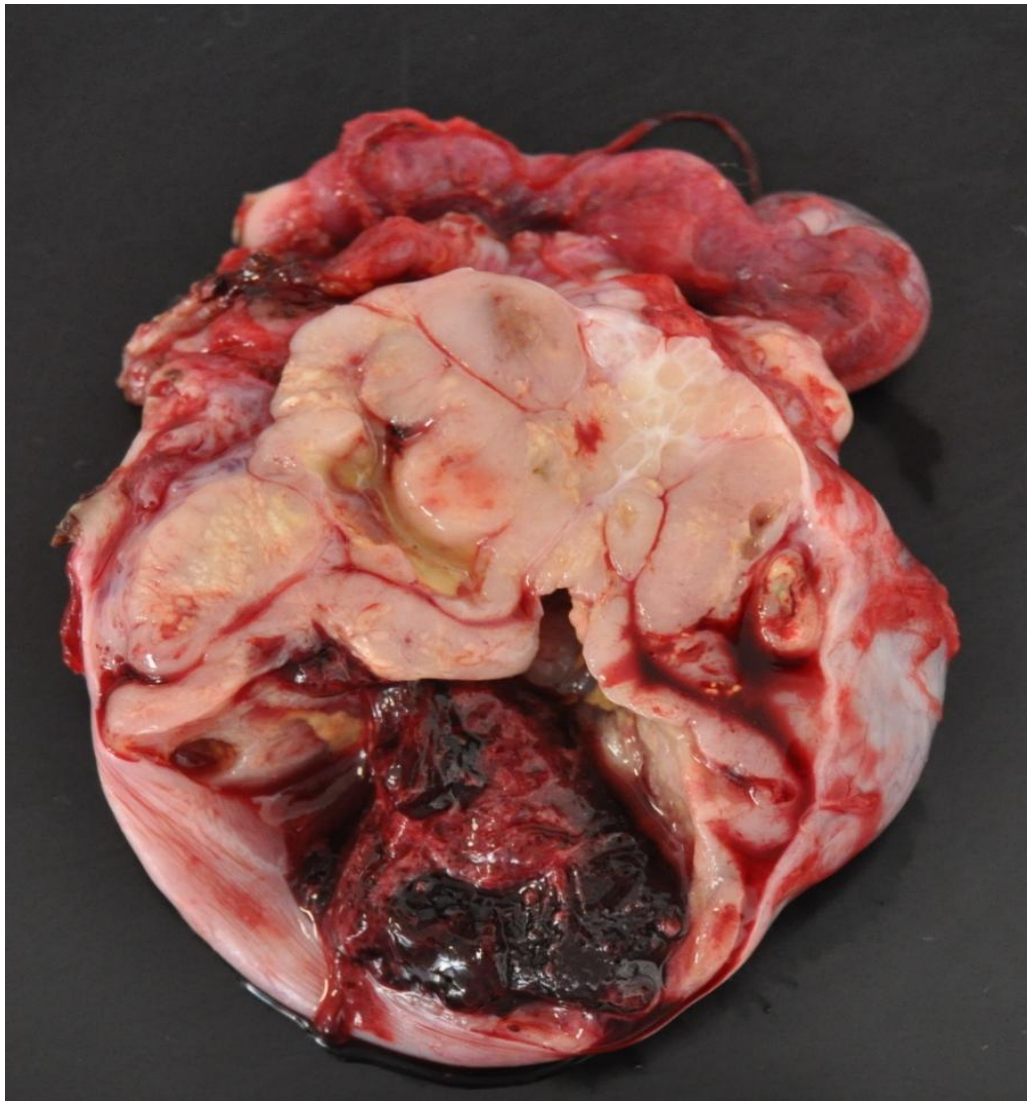

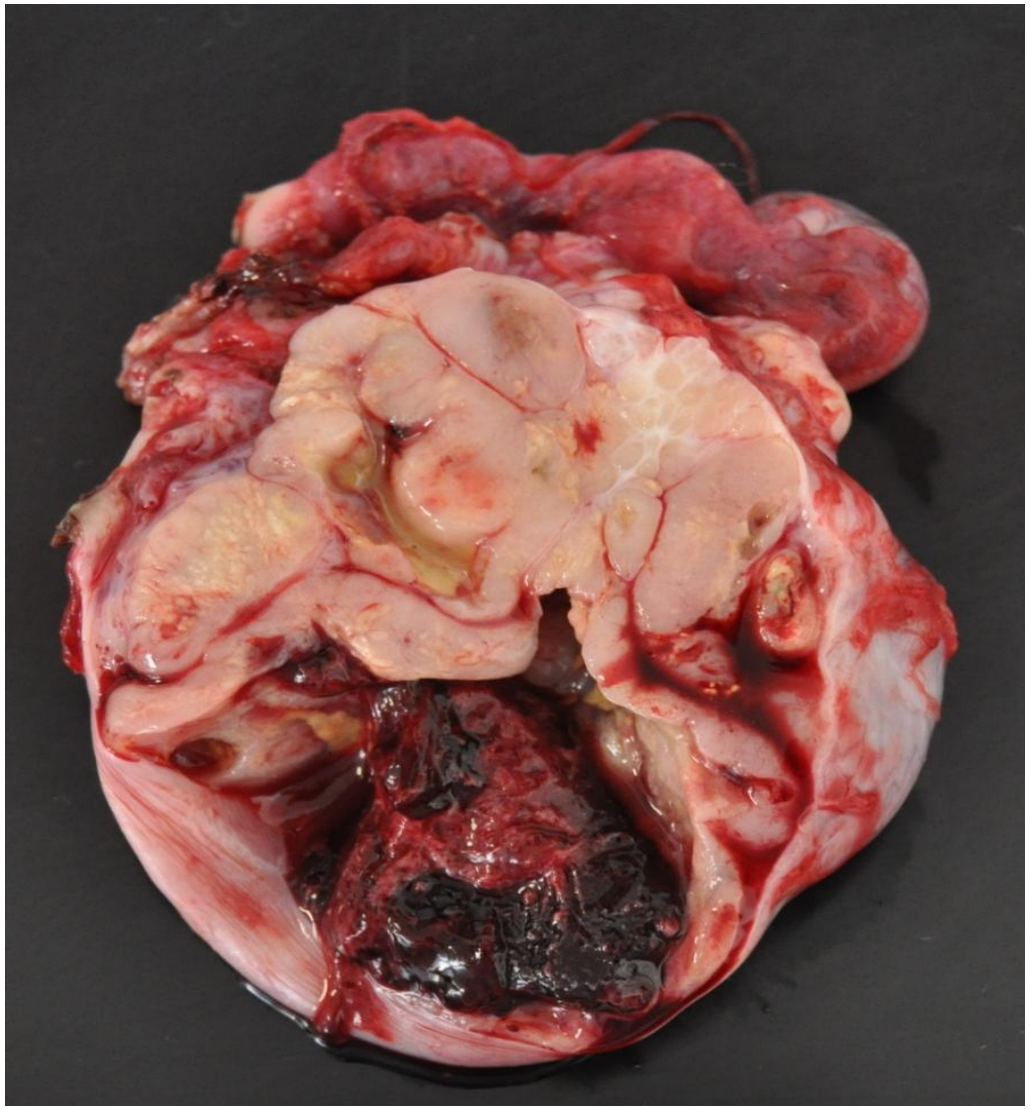



CTNNB1 S33Y
TCT-TAT

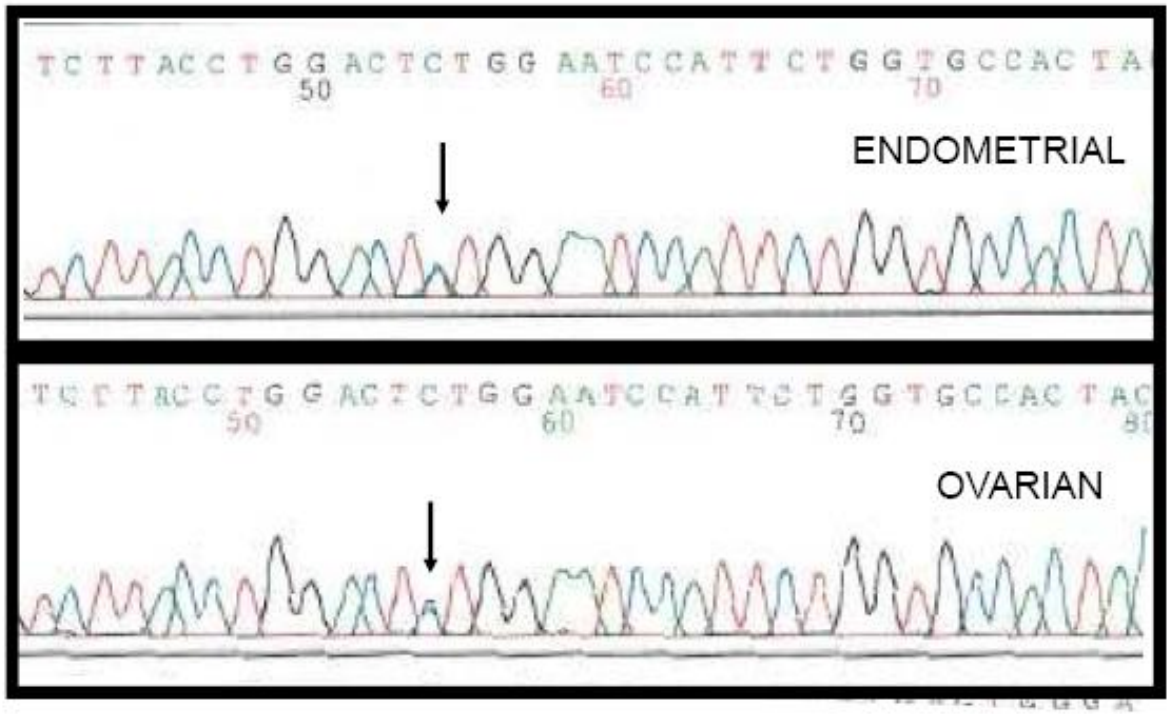

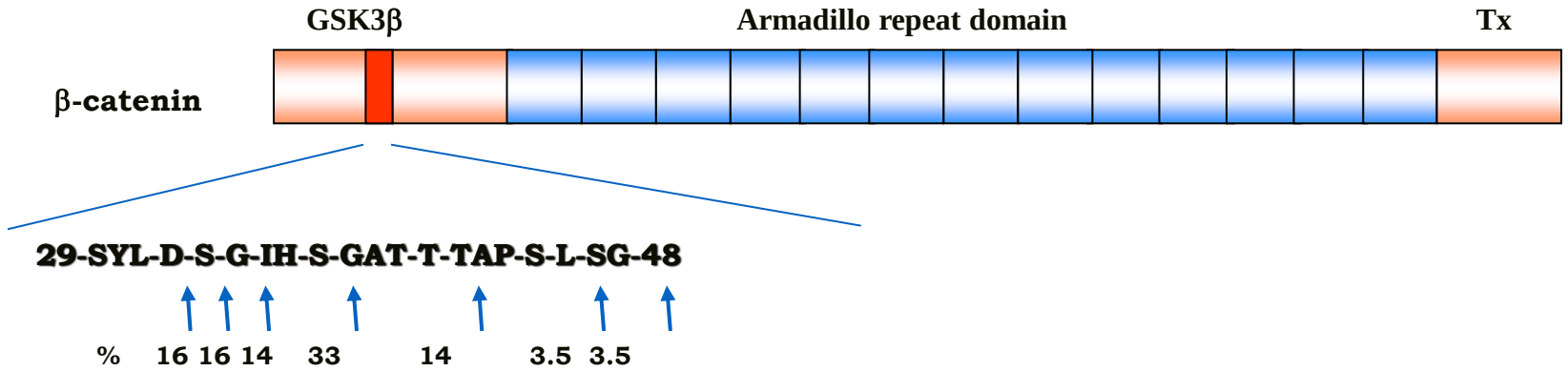





Independent carcinomas
NED @ 18 yrs

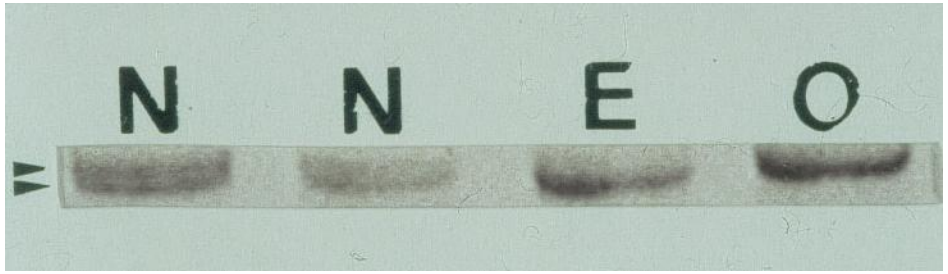
N
N
E
O


BAT-26
N
E
O

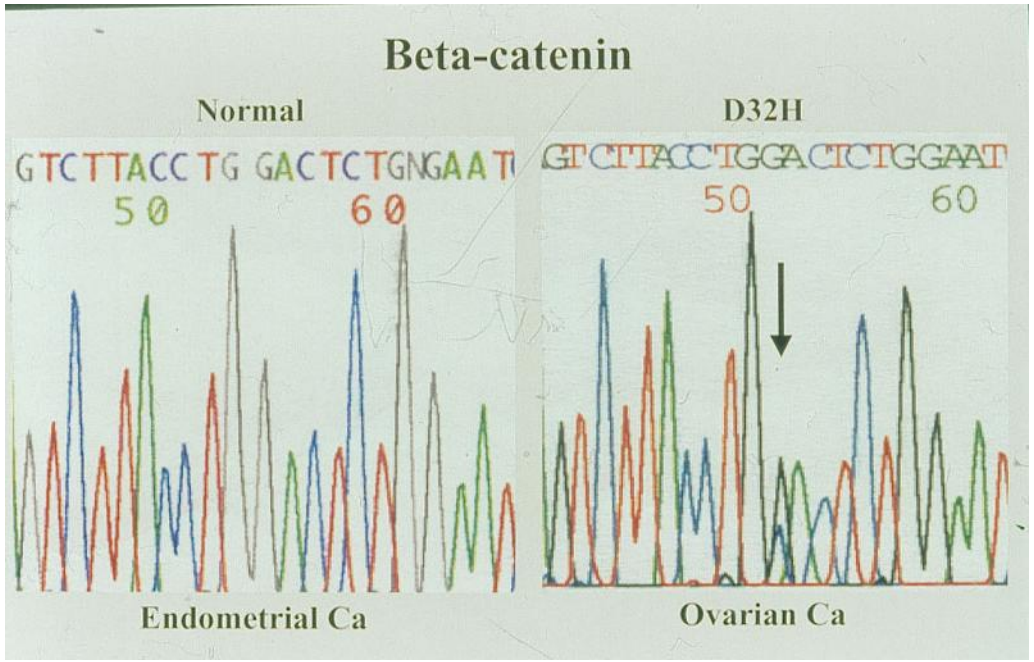
Beta-catenin
Normal
D32H
GTCTTACCTG GACTCTGNGAAT
50
60
GTCTTACCTGGACTCTGGAAT
50
60
Endometrial Ca
Ovarian Ca

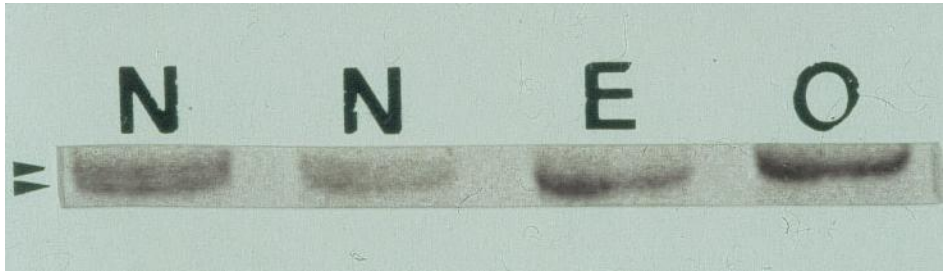
N
N
E
O

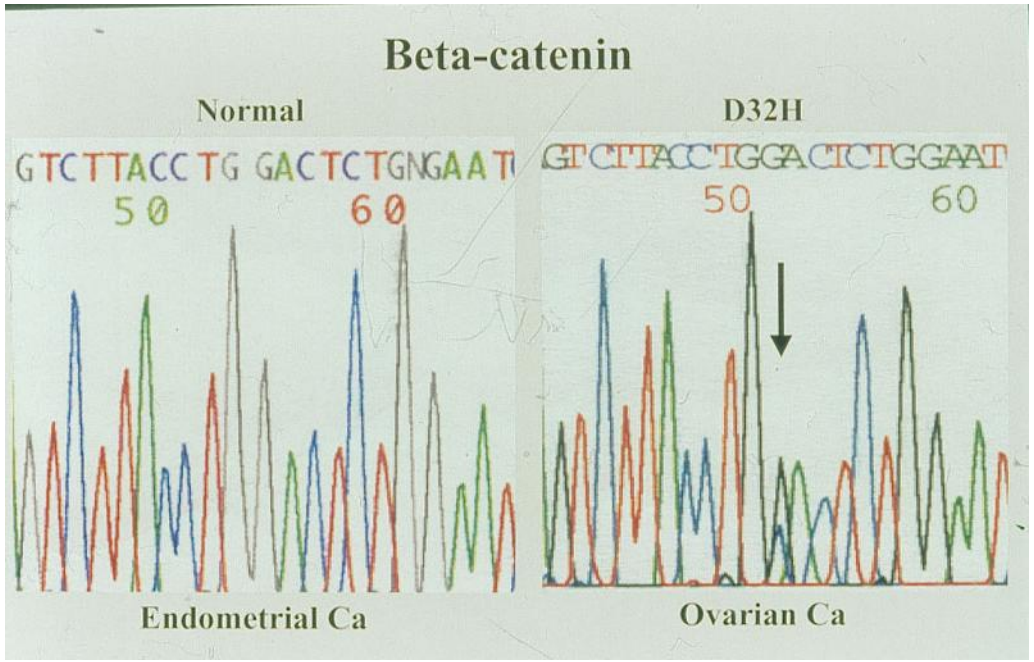
Beta-catenin
Normal
D32H
GTCTTACCTG GACTCTGNGAAT
50
60
GTCTTACCTGGACTCTGGAAT
50
60
Endometrial Ca
Ovarian Ca


BAT-26
N
E
O

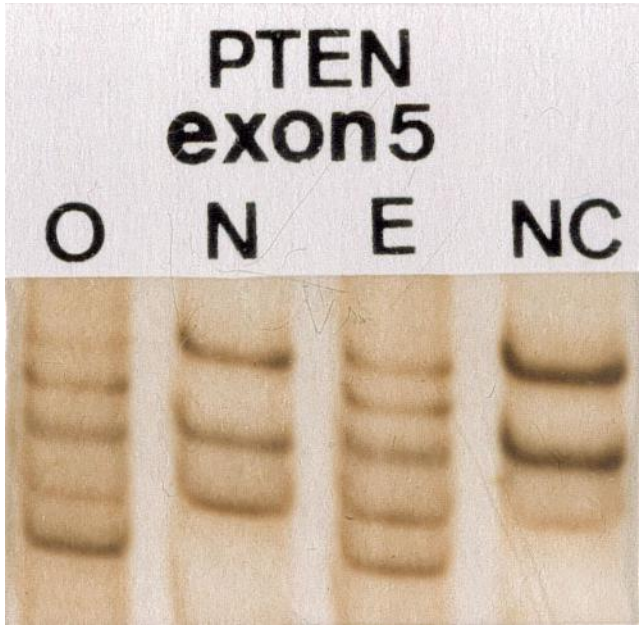
PTEN
exon5
O
N
E
NC

Simultaneous endometrioid carcinomas of the endometrium and the ovaries

Is it possible for two independent tumors to exhibit identical molecular alterations in some genes ?

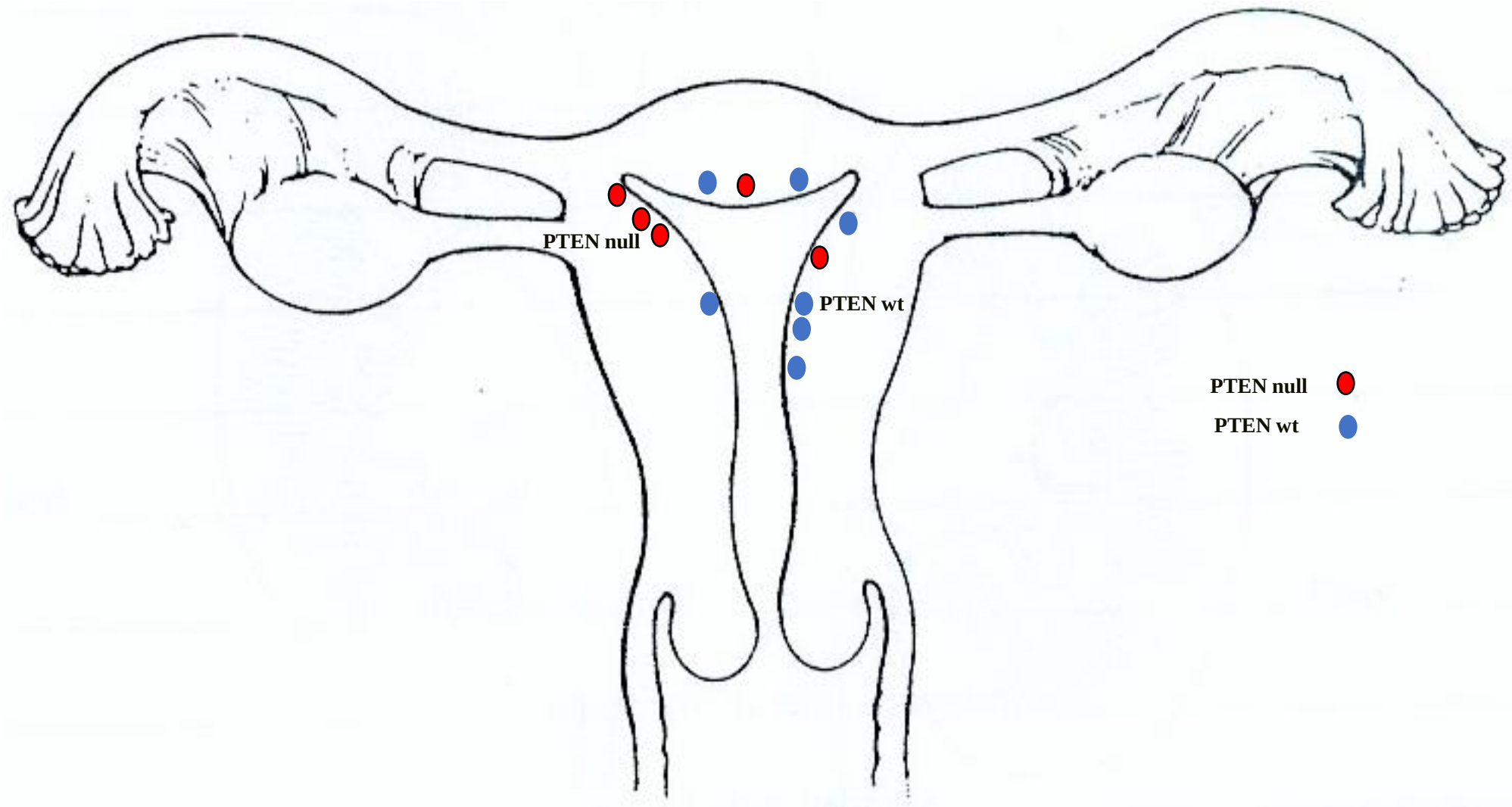
PTEN null
PTEN wt
PTEN null
PTEN wt

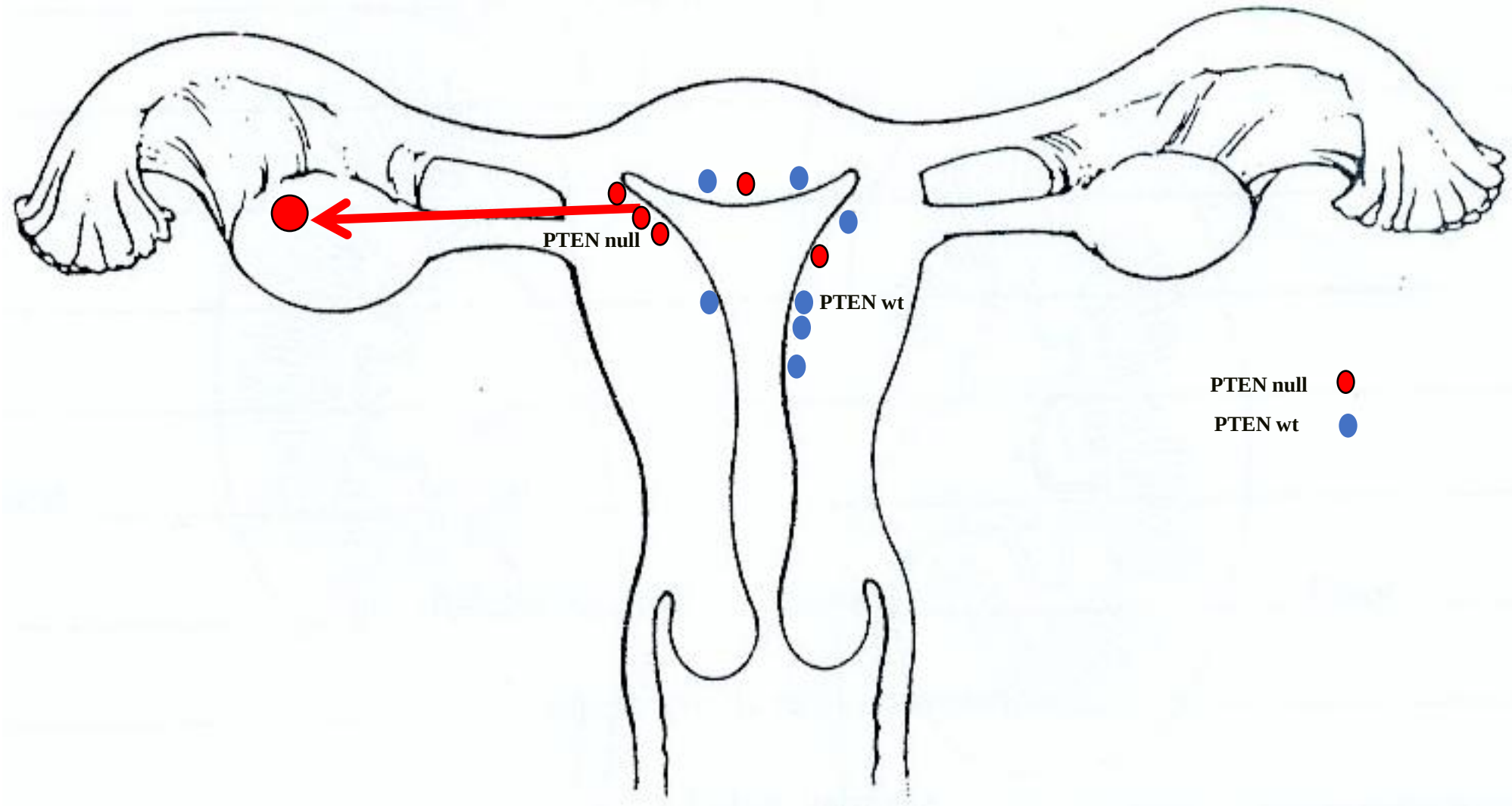
PTEN null
PTEN wt
PTEN null
PTEN wt

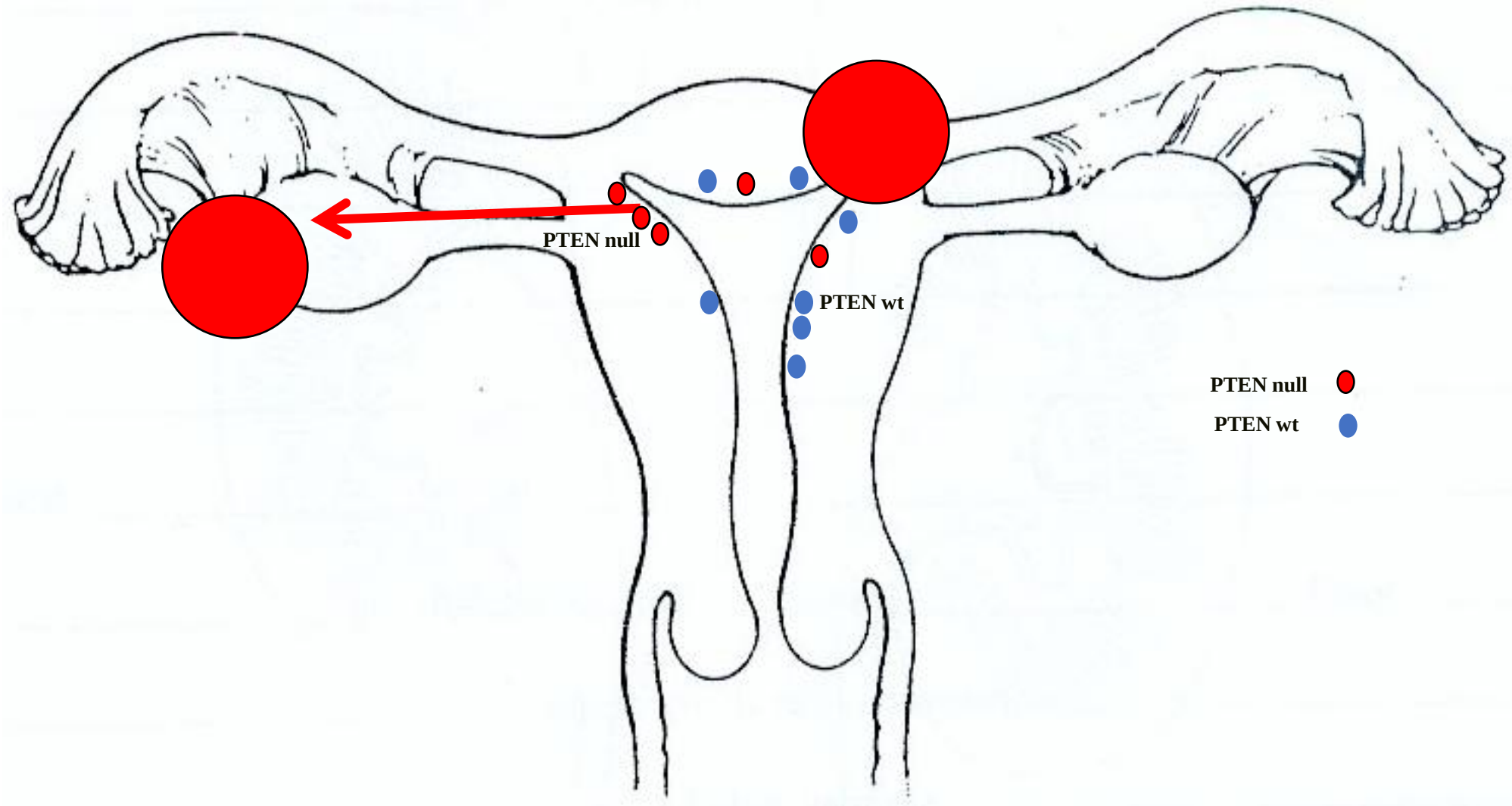
PTEN null
PTEN wt
PTEN null
PTEN wt

Simultaneous endometrioid carcinomas of the endometrium and the ovaries

Independent tumors may occasionally show similar genetic alterations as their common precursor stem cells may carry such alterations.

BRIEF COMMUNICATION

Massively Parallel Sequencing-Based Clonality Analysis of Synchronous Endometrioid Endometrial and Ovarian Carcinomas

Anne M. Schultheis*, Charlotte K. Y. Ng*, Maria R. De Filippo, Salvatore Piscuoglio, Gabriel S. Macedo, Sonia Gatius, Belen Perez Mies, Robert A. Soslow, Raymond S. Lim, Agnes Viale, Kety H. Huberman, Jose C. Palacios, Jorge S. Reis-Filho, Xavier Matias-Guiu, Britta Weigelt

JNCI J Natl Cancer Inst, 2016, Vol. 108, No. 6

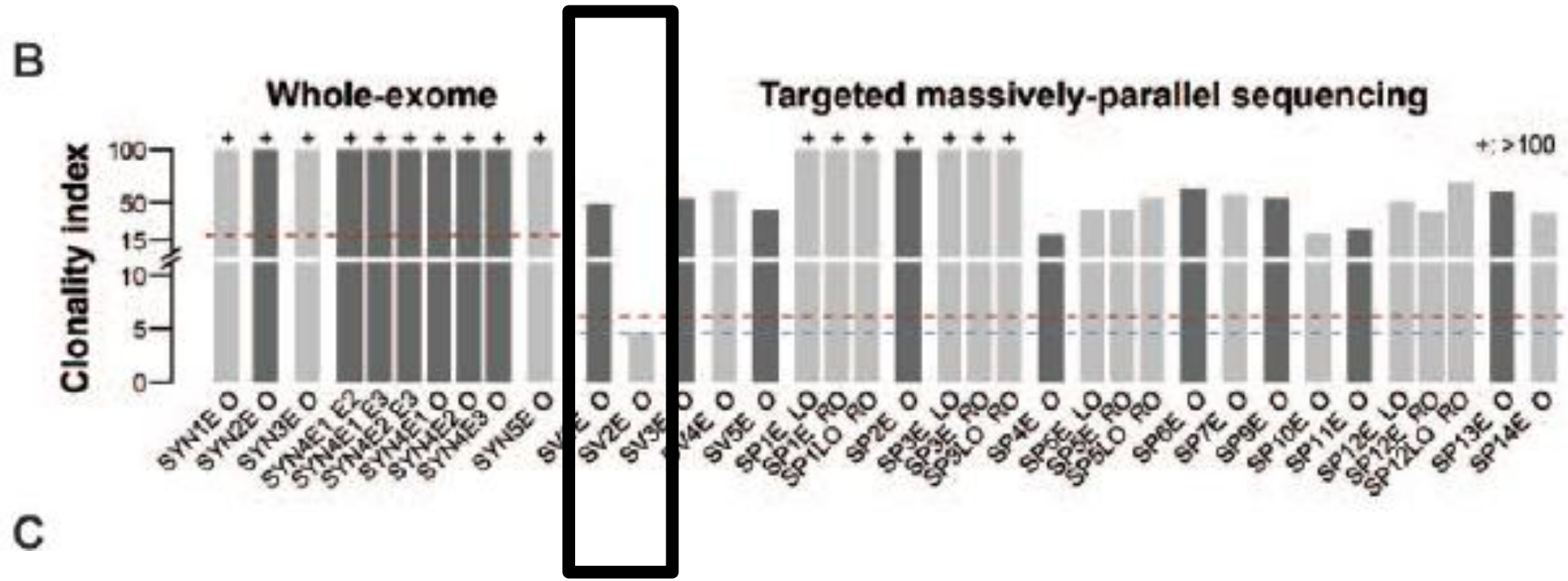

Independent Primary Endometrioid Carcinomas of Uterus and Ovary

EEC 2, 5% myometrium (IA), 2 cm in diameter.
EOC 2, intact capsule (IA) (10 cm in diameter)
No evidence of recurrence after 3 years



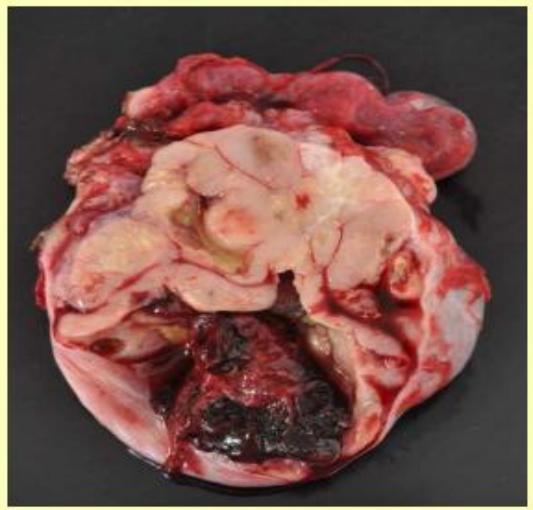



Independent Primary Endometrioid Carcinomas of Uterus and Ovary

EEC 2, restricted to the endometrium (IA), 1.8 cm in diameter.
EOC, grade 2, intact capsule (IA) (14 cm in diameter)
No evidence of recurrence after 6 years, without treatment

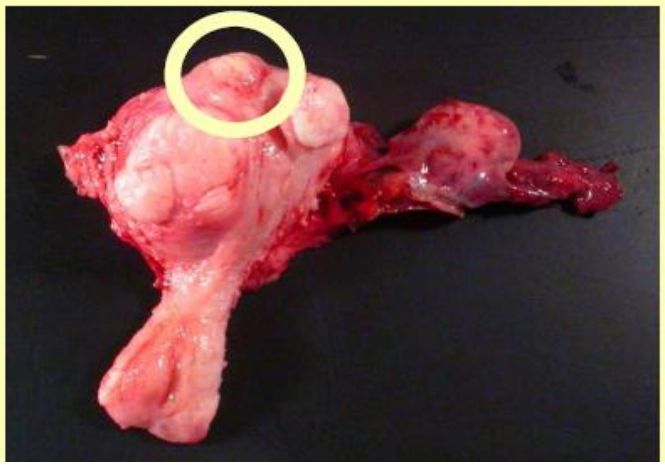

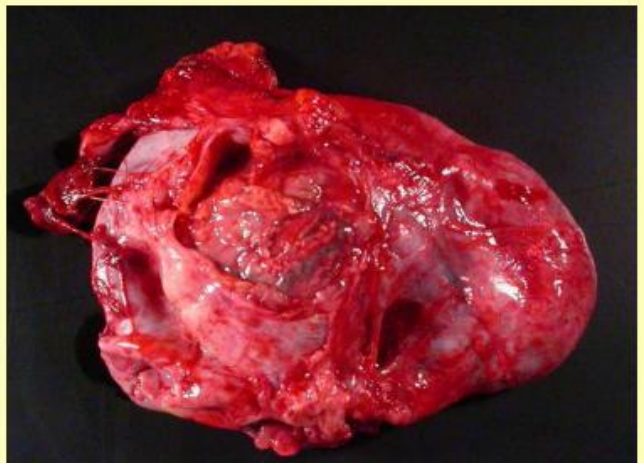



BRIEF COMMUNICATION

Synchronous Endometrial and Ovarian Carcinomas: Evidence of Clonality

Michael S. Anglesio, Yi Kan Wang, Madlen Maassen, Hugo M. Horlings, Ali Bashashati, Janine Senz, Robertson Mackenzie, Diljot S. Grewal, Hector Li-Chang, Anthony N. Karnezis, Brandon S. Sheffield, Melissa K. McConechy, Friedrich Kommoss, Florin A. Taran, Annette Staebler, Sohrab P. Shah, Diethelm Wallwiener, Sara Brucker, C. Blake Gilks, Stefan Kommoss, David G. Huntsman

ONCOLOGY LETTERS 17: 2207-2214, 2019

Synchronous endometrioid endometrial and ovarian carcinomas are biologically related: A clinico-pathological and molecular (next generation sequencing) study of 22 cases

NIKOLA HÁJKOVÁ[1], IVANA TICHÁ[1], JAN HOJNÝ[1], KRISTÝNA NĚMEJCOVÁ[1], MICHAELA BÁRTŮ[1], ROMANA MICHÁLKOVÁ[1], MICHAL ZIKÁN[2], DAVID CIBULA[3], JAN LACO[4], TOMÁŠ GERYK[4], GÁBOR MÉHES[5] and PAVEL DUNDR[1]

Implication of genomic characterization in synchronous endometrial and ovarian cancers of endometrioid histology

Angel Chao [a,1], Ren-Chin Wu [b,1], Shih-Ming Jung [b,1], Yun-Shien Lee [c,d], Shu-Jen Chen [e], Yen-Lung Lu [e], Chia-Lung Tsai [c], Chiao-Yun Lin [a], Yun-Hsin Tang [a], Ming-Yu Chen [a], Huei-Jean Huang [a], Hung-Hsueh Chou [a], Kuan-Gen Huang [a], Ting-Chang Chang [a], Tzu-Hao Wang [a,c,*], Chyong-Huey Lai [a,**]

Molecular profiling identifies synchronous endometrial and ovarian cancers as metastatic endometrial cancer with favorable clinical outcome

Casper Reijnen [1,2], Heidi V.N. Küsters-Vandevelde[3], Marjolijn J.L. Ligtenberg[4,5], Johan Bulten[4], Marloes Oosterwegel[1], Marc P.L.M. Snijders[2], Sanne Sweegers[4], Joanne A. de Hullu[1], Maria C. Vos[6], Anneke A.M. van der Wurff[7], Anne M. van Altena[1], Astrid Eijkelenboom[4] and Johanna M.A. Pijnenborg [1]

Mitochondrial DNA genotyping efficiently reveals clonality of synchronous endometrial and ovarian cancers

Flora Guerra[1,8], Giulia Girolimetti[1,8], Anna Myriam Perrone[2], Martina Procaccini[2], Ivana Kurelac[1], Claudio Ceccarelli[3], Dario De Biase[4], Giacomo Caprara[5], Claudio Zamagni[6], Pierandrea De Iaco[2], Donatella Santini[7] and Giuseppe Gasparre[1]

Simultaneous endometrioid carcinomas of the endometrium and the ovaries (unsolved issues)

- Why some ovarian metastasis are associated with bad prognosis and others are associated with indolent behaviour ?

Simultaneous endometrioid carcinomas of the endometrium and the ovaries (unsolved issues)

Aggressiveness may be related to :

- The precise step of endometrial tumorigenesis in which the ovarian metastasis develops.
- The metastatic pathway used (hematogenous versus transtubal)

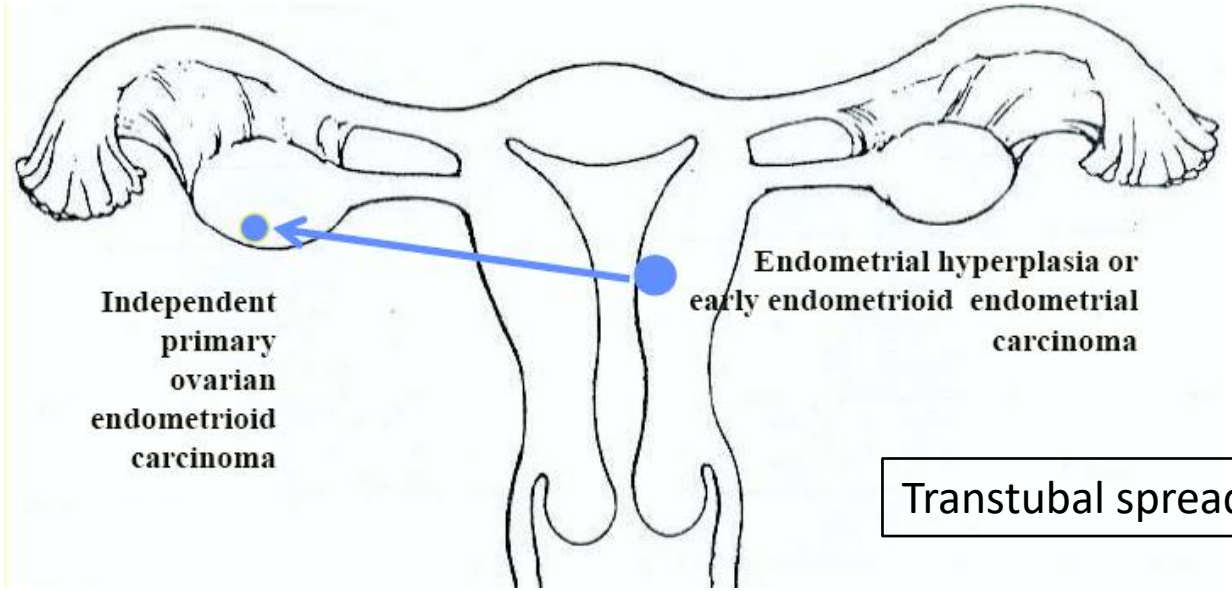

Transtubal spread

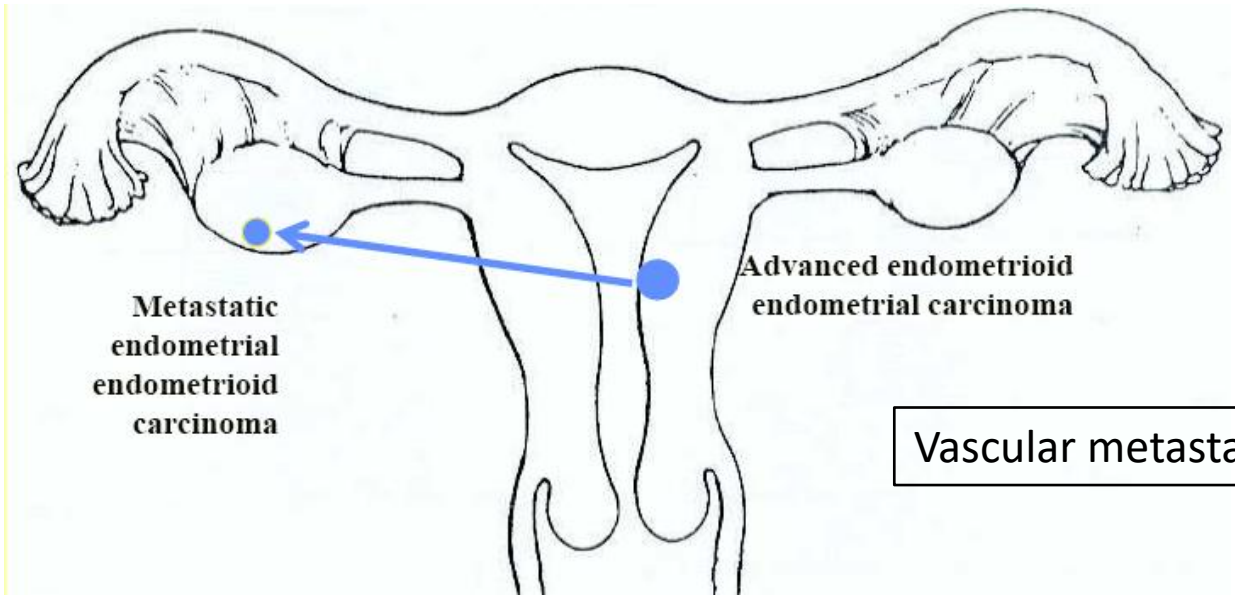

Vascular metastasis

Simultaneous endometrioid carcinomas of the endometrium and the ovaries (circumstantial evidences)

- Similar situations (endocervical adenocarcinoma)
- Epidemiological data (impact of tubal ligation).
- Tumor phylogeny

Synchronous and Metachronous Endocervical and Ovarian Neoplasms

Evidence Supporting Interpretation of the Ovarian Neoplasms as Metastatic Endocervical Adenocarcinomas Simulating Primary Ovarian Surface Epithelial Neoplasms

Esther Elishaev, MD, C. Blake Gilks, MD,† Dianne Miller, MD,‡ Monica Srodon, MD,* Robert J. Kurman, MD,*§ and Brigitte M. Ronnett, MD*§*

Finally, it is interesting to note that 8 of the patients appear to have had isolated ovarian metastases of endocervical adenocarcinoma without documented metastatic disease elsewhere, and 7 of these patients with available follow-up data had not experienced disease recurrence during follow-up intervals ranging from 7 to 45 months. These findings suggest that isolated metastases may not necessarily indicate a poor prognosis, as would be expected for advanced-stage disease, and that resection of isolated metastases may have therapeutic and survival benefits. Additional follow-up will be required to determine the long-term prognosis for these patients.

Endocervical Adenocarcinomas With Ovarian Metastases

Analysis of 29 Cases With Emphasis on Minimally Invasive Cervical Tumors and the Ability of the Metastases to Simulate Primary Ovarian Neoplasms

Brigitte M. Ronnett, MD,† Anna V. Yemelyanova, MD,* Russell Vang, MD,*†*
C. Blake Gilks, MD,‡ Dianne Miller, MD,§ Patti E. Gravitt, PhD,‖ and Robert J. Kurman, MD†*

Endocervical adenocarcinomas, including microinvasive forms and some not recognizably invasive, have the potential to metastasize to the ovaries; extension into the lower uterine segment/corpus endometrium may be a risk factor, with retrograde uterine/transtubal spread as a possible mechanism.

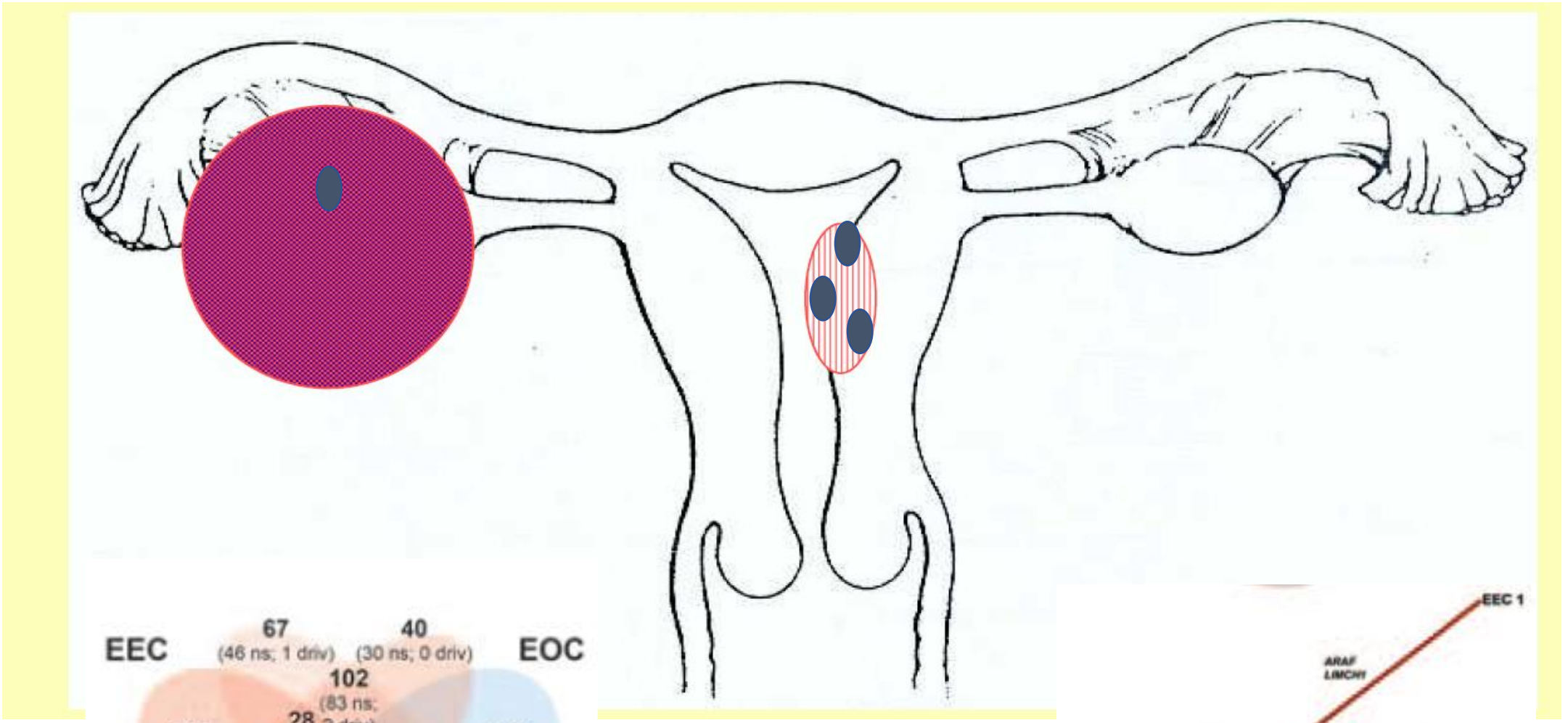

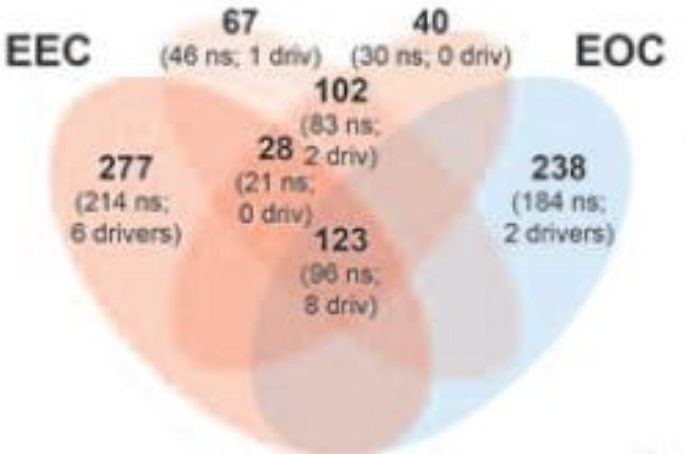
EEC
EOC
67
(46 ns; 1 driv)
40
(30 ns; 0 driv)
102
(83 ns;
2 driv)
28
(21 ns;
0 driv)
277
(214 ns;
6 drivers)
123
(96 ns;
8 driv)
238
(184 ns;
2 drivers)

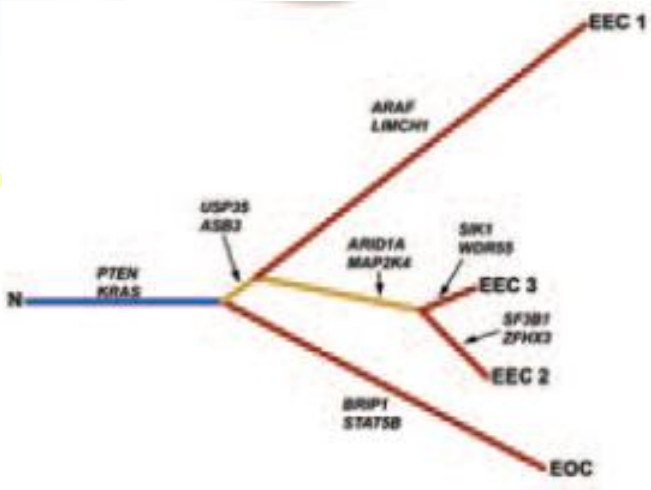
EEC 1
ARAF
LIMCH1
USP35
ASB3
ARID1A
MAP2K4
SIK1
WDR55
N
PTEN
KRAS
EEC 3
SF3B1
ZFHX3
EEC 2
BRIP1
STAT5B
EOC

Intratumor genetic heterogeneity and clonal evolution to decode endometrial cancer progression

Alba Mota[1,2,14], Sara S. Oltra[1,2,3,14], Pier Selenica[4], Cristian P. Moiola[3,5], Carlos Casas-Arozamena[6], Carlos López-Gil[5], Eva Diaz[1], Sonia Gatius[7], María Ruiz-Miro[8], Ana Calvo[9], Alejandro Rojo-Sebastián[3,5,10], Pablo Hurtado[11], Roberto Piñeiro[11], Eva Colas[3,5], Antonio Gil-Moreno[3,5,12], Jorge S. Reis-Filho[4], Laura Muinelo-Romay[3,6], Miguel Abal[3,6], Xavier Matias-Guiu[3,7,13], Britta Weigelt[4] and Gema Moreno-Bueno[1,2,3] ✉

Oncogene; https://doi.org/10.1038/s41388-022-02221-0

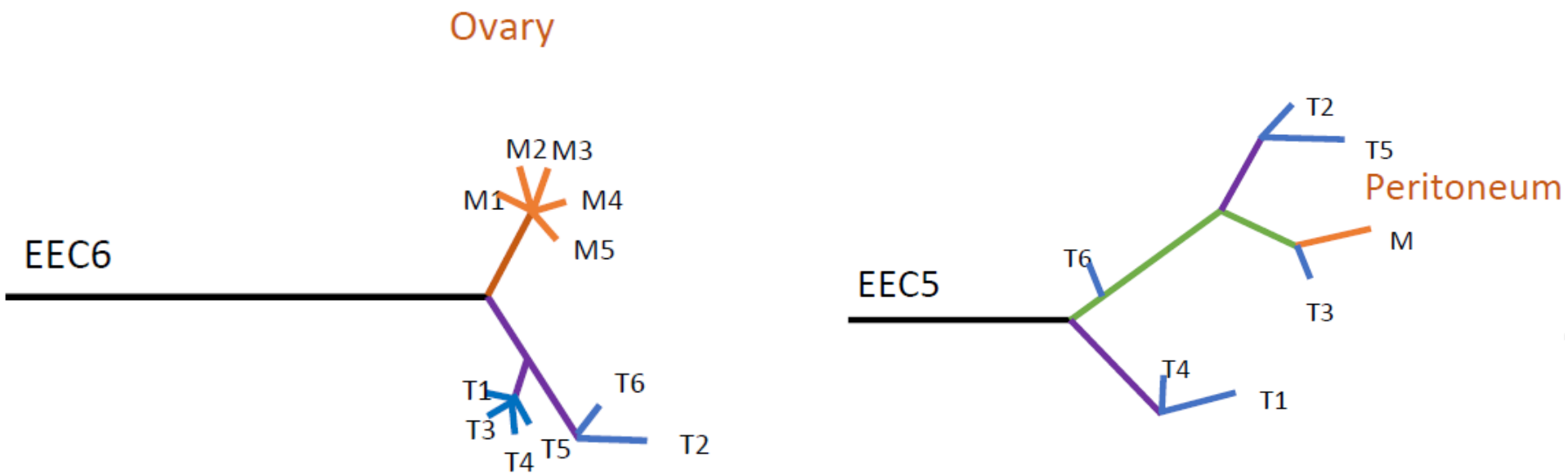

Simultaneous endometrioid carcinomas of the endometrium and the ovaries, How to report them?

- All of them as metastatic?
- Use Scully criteria, regardless of molecular data?
- Risk stratification ?

Simultaneous endometrioid carcinomas of the endometrium and the ovaries, How to report them?

- All of them as metastatic?
- Use Scully criteria, regardless of molecular data?
- Risk stratification ?

Archives of Gynecology and Obstetrics (2019) 300:1045–1052
https://doi.org/10.1007/s00404-019-05288-5

GYNECOLOGIC ONCOLOGY

The prognosis of stage IA synchronous endometrial endometrioid and ovarian carcinomas

Xiangbo Zhan[1,2] · Lei Li[1] · Ming Wu[1] · Jinghe Lang[1]

In patients with stage IA endometrioid endometrial carcinoma, the appearance of synchronous stage IA ovarian carcinoma is very low and has no significant effects on survival outcomes. Adjuvant therapy does not influence the survival outcomes of this population.

Prognostic factors of synchronous endometrial and ovarian endometrioid carcinoma

Yutaka Yoneoka,[1,2] Hiroshi Yoshida,[3] Mitsuya Ishikawa,[1] Hanako Shimizu,[1] Takashi Uehara,[1] Takashi Murakami,[2] Tomoyasu Kato[1]

J Gynecol Oncol. 2019 Jan;30(1):e7

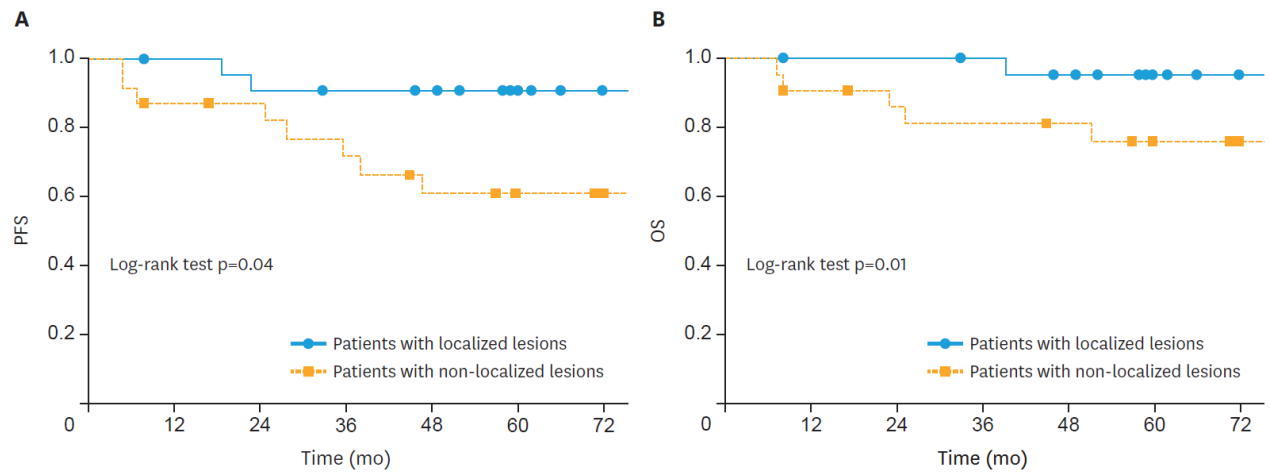

Risk-based stratification of carcinomas concurrently involving the endometrium and ovary

Gulisa Turashvili [a], Natalia R. Gómez-Hidalgo [b], Jessica Flynn [c], Mithat Gonen [c], Mario M. Leitao Jr [b,d], Robert A. Soslow [a], Rajmohan Murali [a,*]

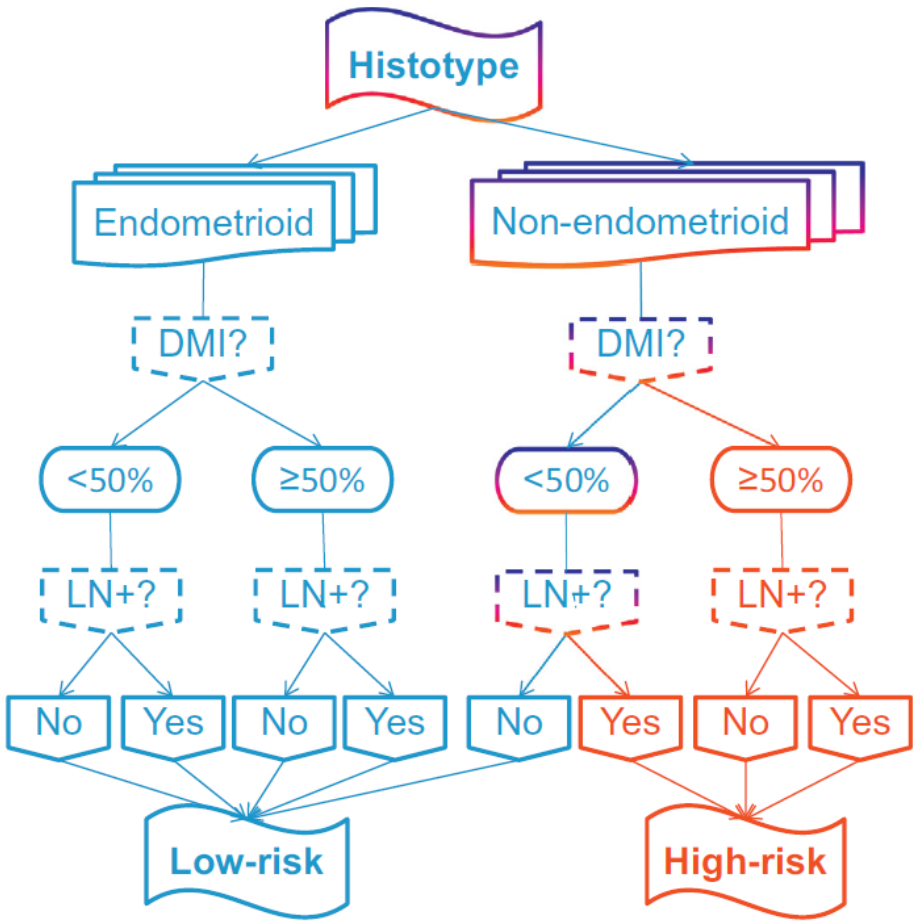

Simultaneous endometrioid carcinomas of the endometrium and the ovaries, WHO 2021, ESGO-ESTRO-ESP 2021, FIGO 2023

- Most of them are clonally related (“metastatic”)
- A subset with good prognosis, and should be managed as two independent primaries:
  - Limited myometrial invasion
  - Absence of vascular invasion
  - Low grade endometrioid morphology
  - Absence of metastasis in other places
  - Both tumors should be limited to the organ (“IA”)

Validation of the 2023 FIGO staging schema for advanced endometrial cancer

Koji Matsuo [a,b,*,1], Maximilian Klar [c], Bonnie B. Song [a], Lynda D. Roman [a,b], Jason D. Wright [d]

European Journal of Cancer

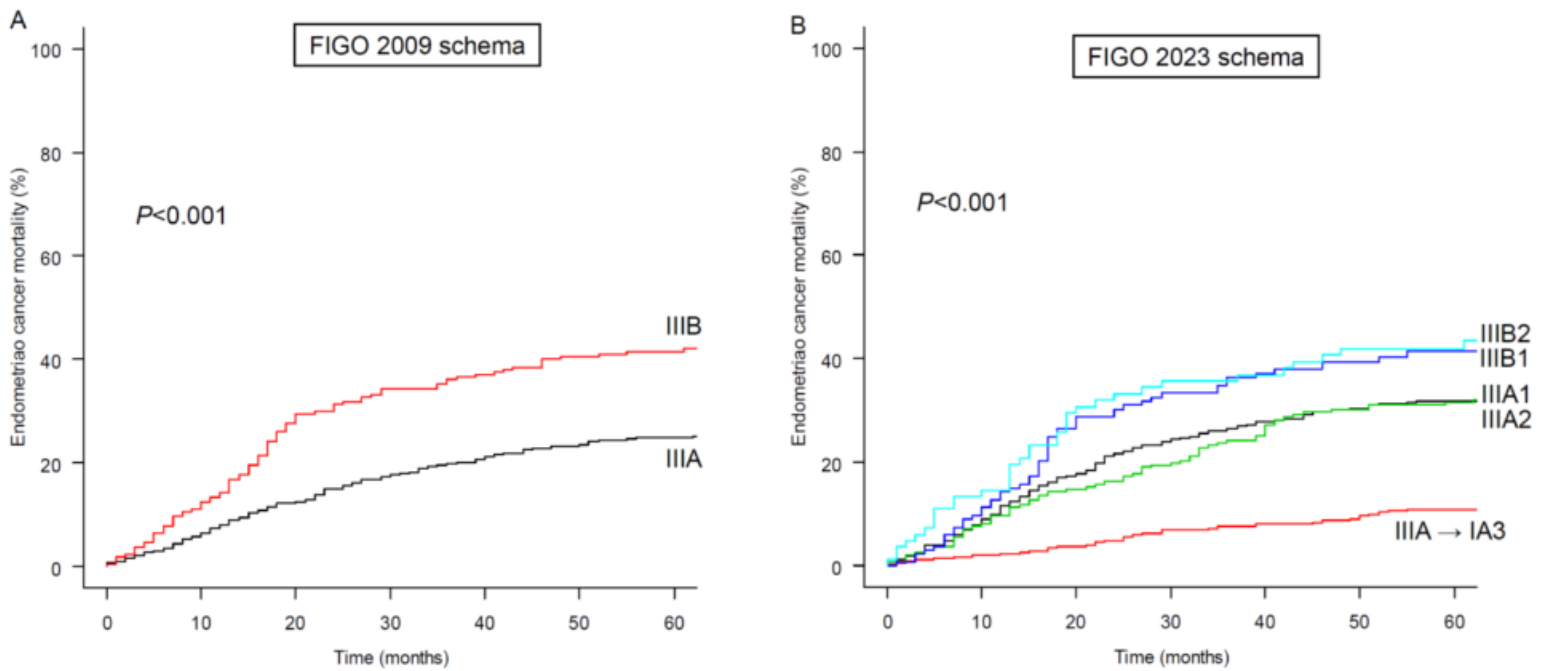

IA3 Low-grade endometrioid carcinomas limited to the uterus and ovary[c]

Low-grade endometrioid endometrial cancer with adnexal only metastasis: Evaluation of de-escalation of adjuvant therapy

Koji Matsuo [a,b,*,1,2], Ling Chen [c,1], Monica K. Neuman [a], Maximilian Klar [d], Lynda D. Roman [a,b], Jason D. Wright [c,**]

European Journal of Cancer 200 (2024) 113533

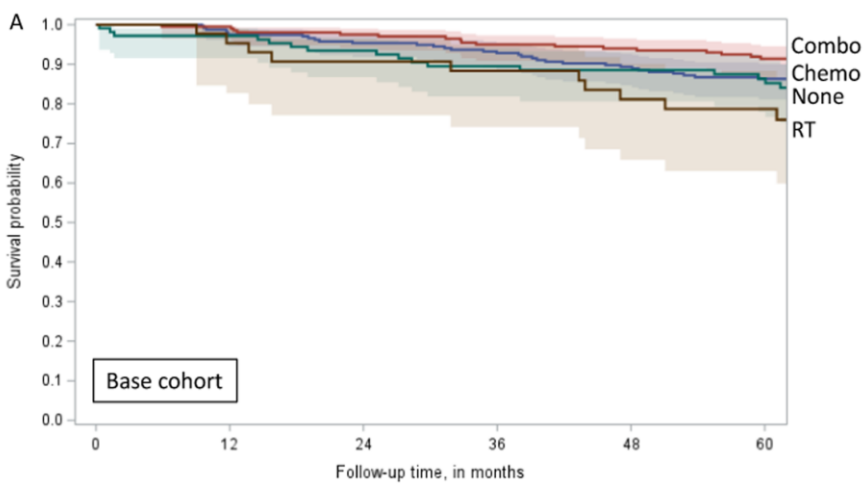

stage IA3 disease.

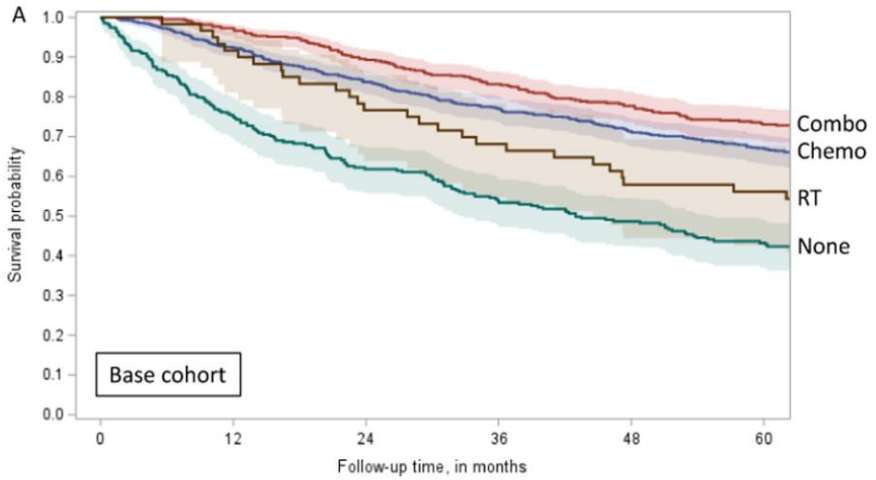

stage IIIA1 disease.

Independent Primary Endometrioid Carcinomas of Uterus and Ovary

EEC 2, restricted to the endometrium (IA), 1.8 cm in diameter.
EOC, grade 2, intact capsule (IA) (14 cm in diameter)
No evidence of recurrence after 6 years, without treatment

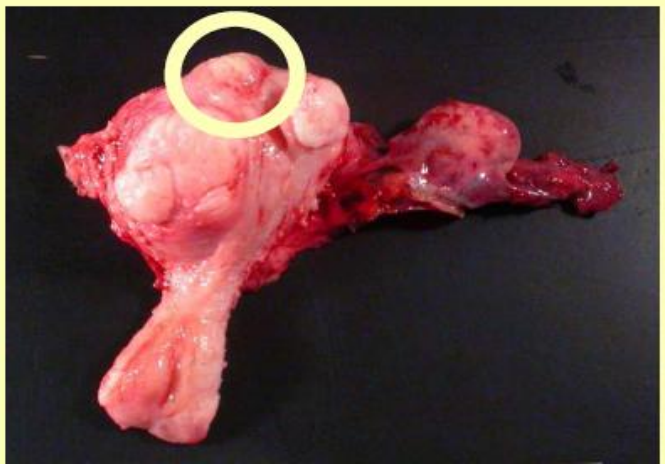

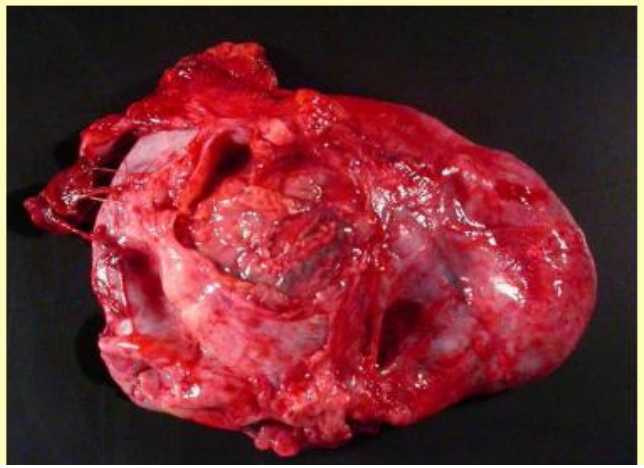



Can IHC and molecular pathology analysis be helpful ?.....

....or maybe misleading ?

49 year-old woman with a 6,5 cm large endometrial tumor and a 4 cm large right ovarian mass



Low grade Endometrioid carcinoma of the endometrium invading less than 50% of myometrial wall, No LVI

ovarian metastasis

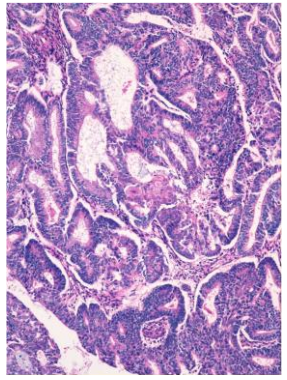

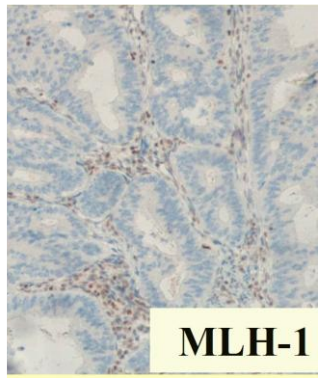

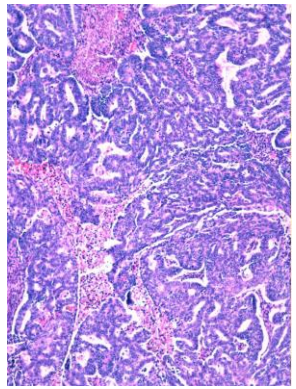

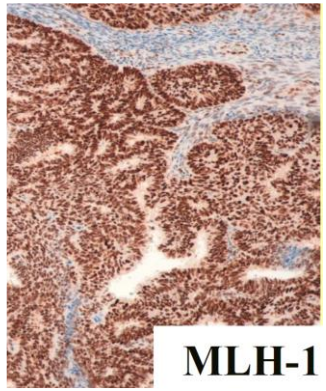

ADDITIONAL STAINS IN THE ENDOMETRIAL TUMOR.

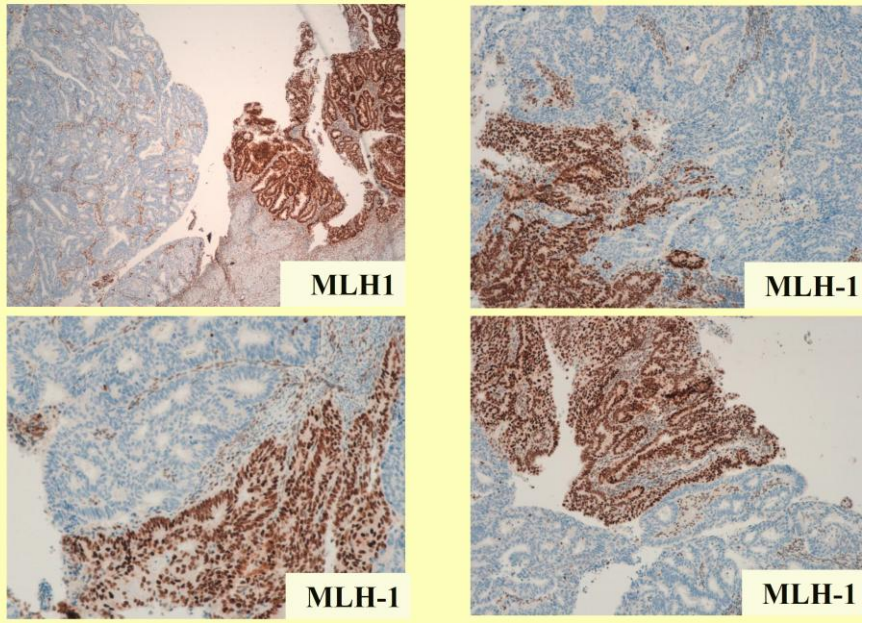

- MLH-1 promoter hypermethylation (with MLH-1 loss of expression) was a subclonal event in the endometrial carcinoma, with intact MLH-1 in a certain proportion of the tumor.
- The MLH-1 proficient component of the primary tumor progresses, and metastasize to the ovary.

1. Speaker experience (Prof. Xavier Matias-Guiu, University of Lleida, Spain).

55 year-old woman with a 8 cm large endometrial tumor and a 9 cm large right ovarian mass

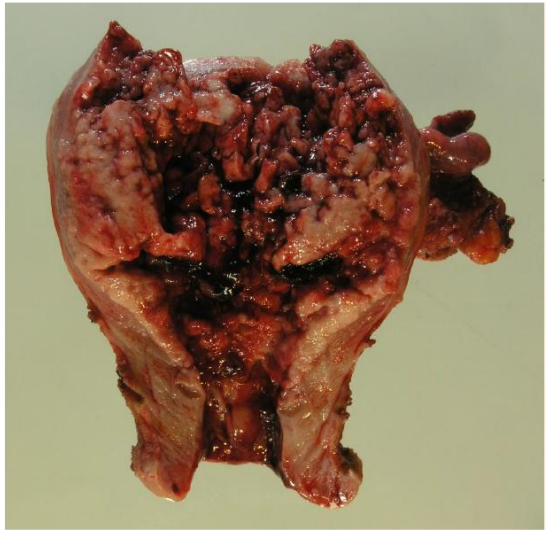

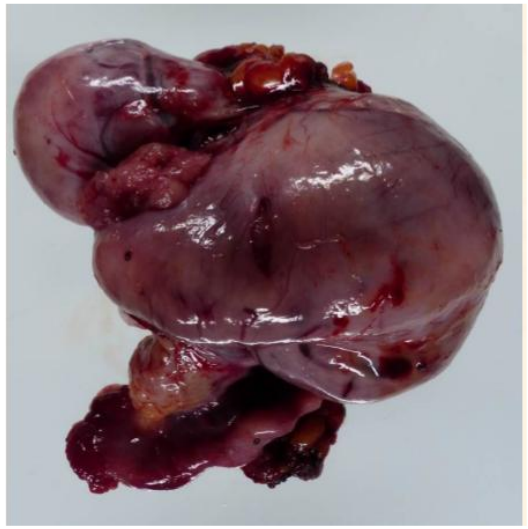

Low grade Endometrioid carcinoma of the endometrium

ovarian metastasis

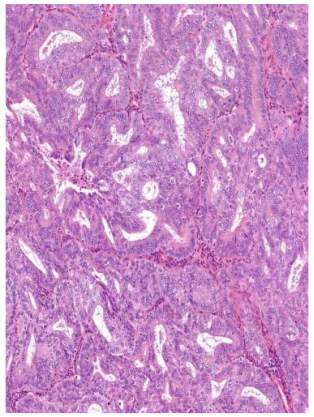

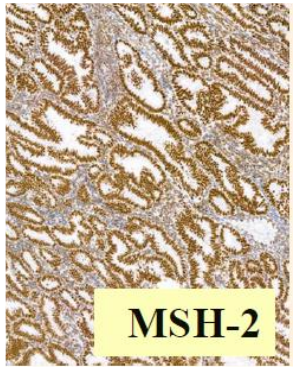

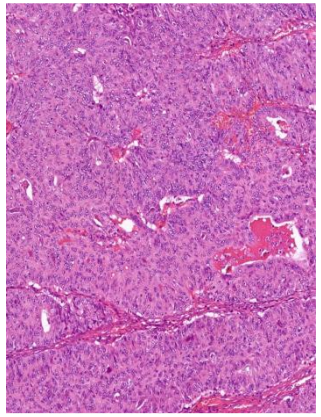

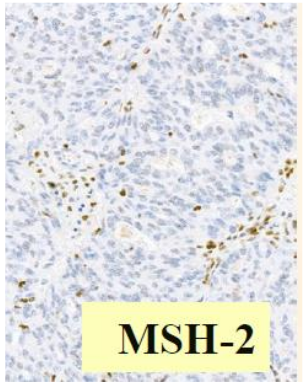

A common POLE mutation (S297F) in both tumors

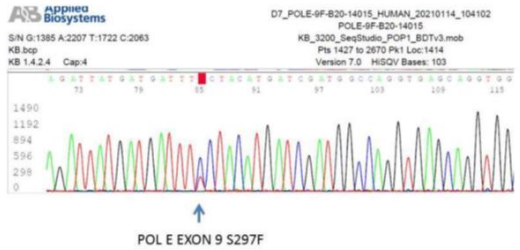

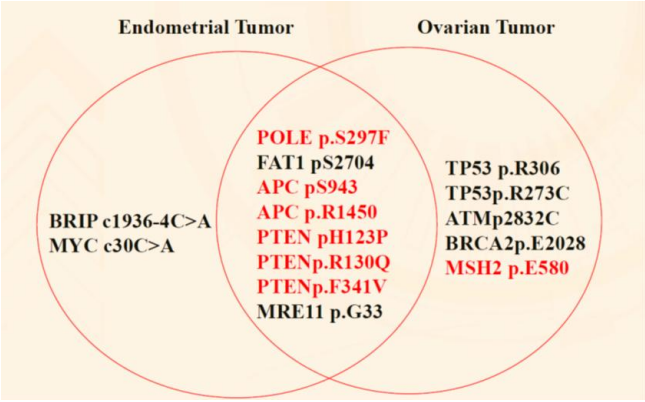

- POLE mutated endometrial carcinoma with an ovarian metastasis with secondary MHS2 mutation (FIGO stage III).

1. Speaker experience (Prof. Xavier Matias-Guiu, University of Lleida, Spain).

Take home messages

- Vast majority of endometrioid ovarian carcinomas that coexist with endometrioid endometrial carcinomas are metastatic
- Use WHO criteria to identify the cases most likely to be associated with better prognosis
- We need more scientific evidence to get solid criteria for risk stratification

The British Association of Gynaecological Pathologists

Synchronous endometrioid carcinomas of the endometrium and the ovaries

X. Matias-Guiu, M.D.
Hospital Universitari Arnau de Vilanova, University of Lleida, IRBLLEIDA