The British Association of Gynaecological Pathologists

bsccp | The British Society for Colposcopy and Cervical Pathology

Lecturer – Dr Sarah Bell

Dr Bell is a Consultant Gynaecological Pathologist in NHS Greater Glasgow and Clyde (GGC) with clinical and research interests in gynaecological cancer and molecular pathology testing. Dr Bell is council member and co-meetings secretary of the British Association of Gynaecological Pathologists. Dr Bell is a member of the Scottish Gyn Oncology Trials Group. Dr Bell is also Molecular Pathology and Genomics Integration Lead in West of Scotland Genomics centre and represents pathology for the Scottish Genomics network and New Test Acquisition groups.



The British Association of Gynaecological Pathologists

BAGP-BSCCP Basic Cervical Histopathology Course

- Title *Squamous cell carcinoma including measurements*
- Speaker Dr Sarah Bell
- Affiliation NHS Greater Glasgow and Clyde
- Date 26/02/25

The British Association of Gynaecological Pathologists

Speaker disclosures

- ❑ I have no financial conflicts of interest to disclose

Squamous cell carcinoma, including measurements

Dr Sarah Bell

Consultant Gyn Pathologist, Queen Elizabeth University Hospital, Glasgow, UK.

Talk outline

- SCC – features & classification
- HPV typing
- Common issues in diagnosing invasion
- Histological reporting guidelines to be used
- Basics of how to measure tumours
- Common issues with measurements/staging

Squamous cell carcinoma (SCC)

- 4th most common ca in female
- Represents 80-90% of all cervical cancers
- Majority – high risk HPV driven
  - HPV 16 & 18 commonest

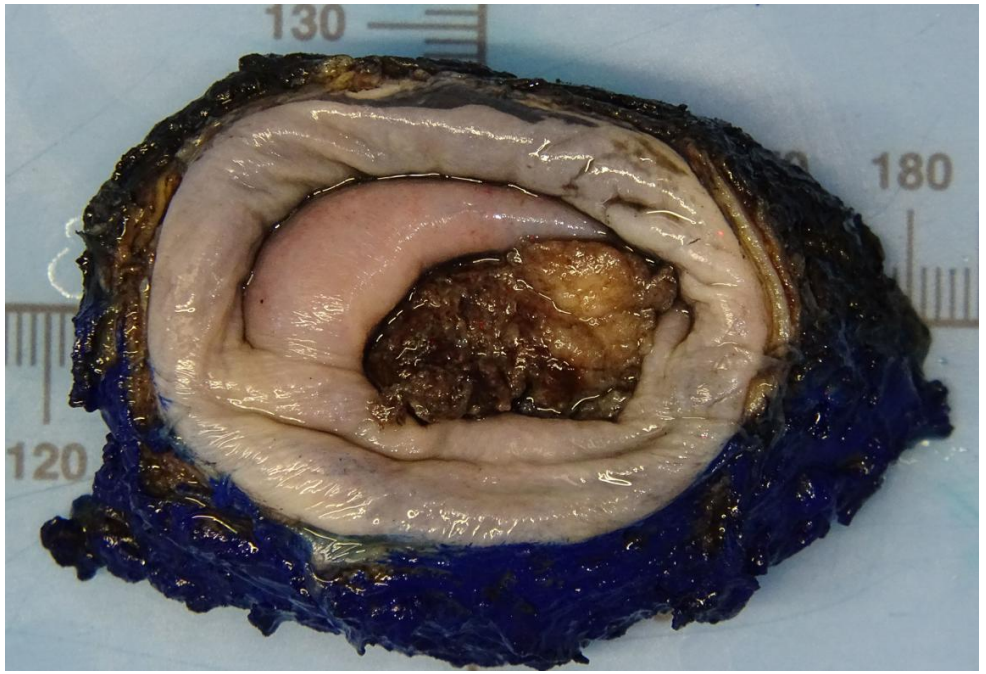

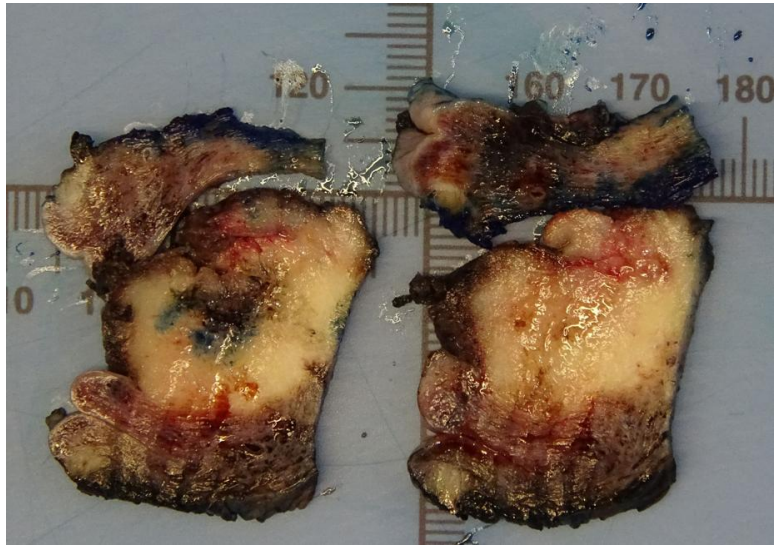

SCC- definitions

- WHO (2020) – *infiltrating, angulated irregular nests, anastomosing cords and solid sheets separated by an intervening desmoplastic or inflammatory stroma*

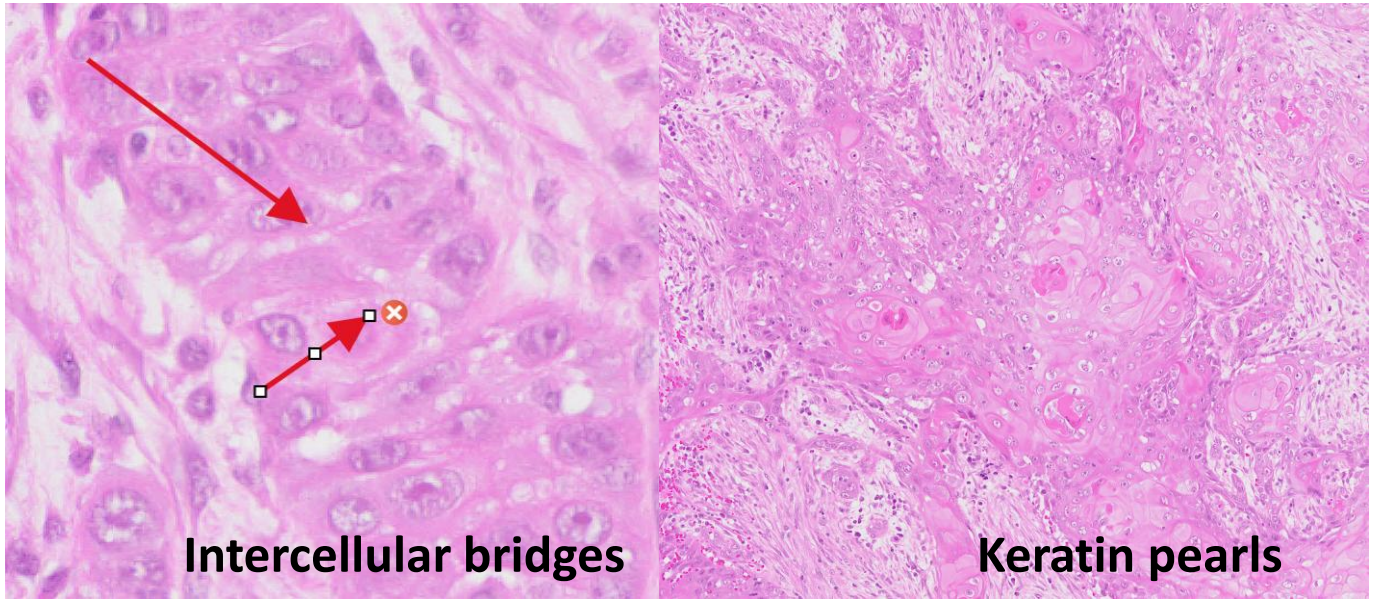

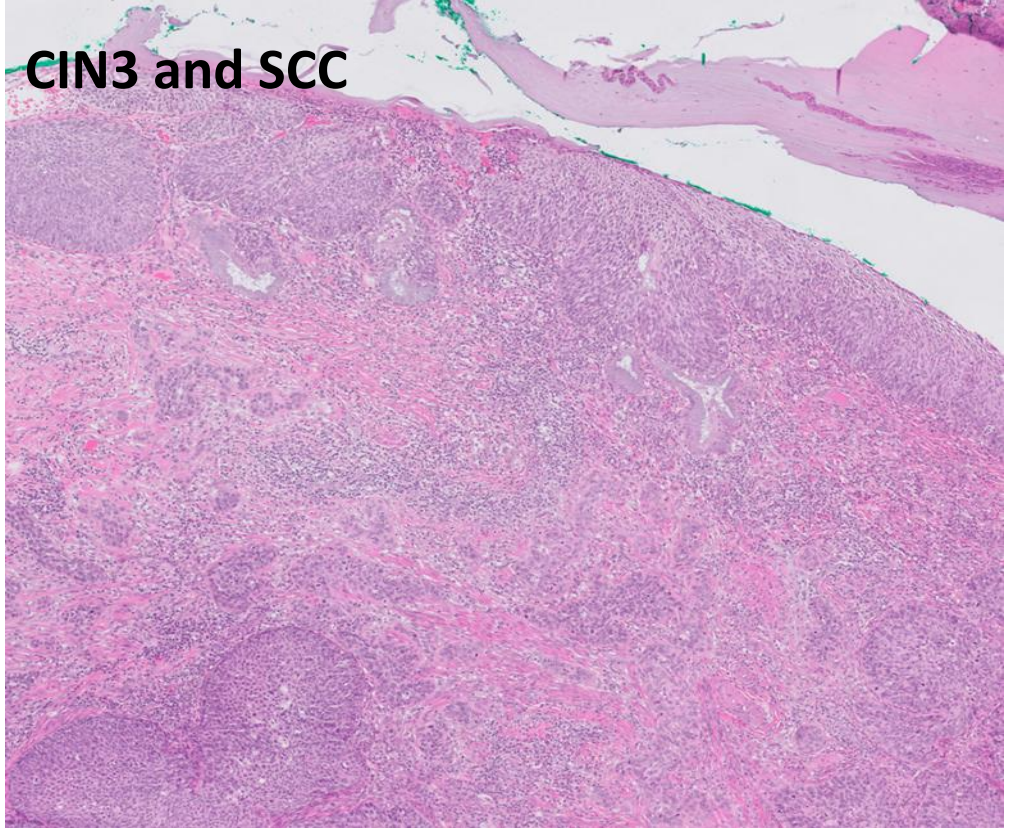

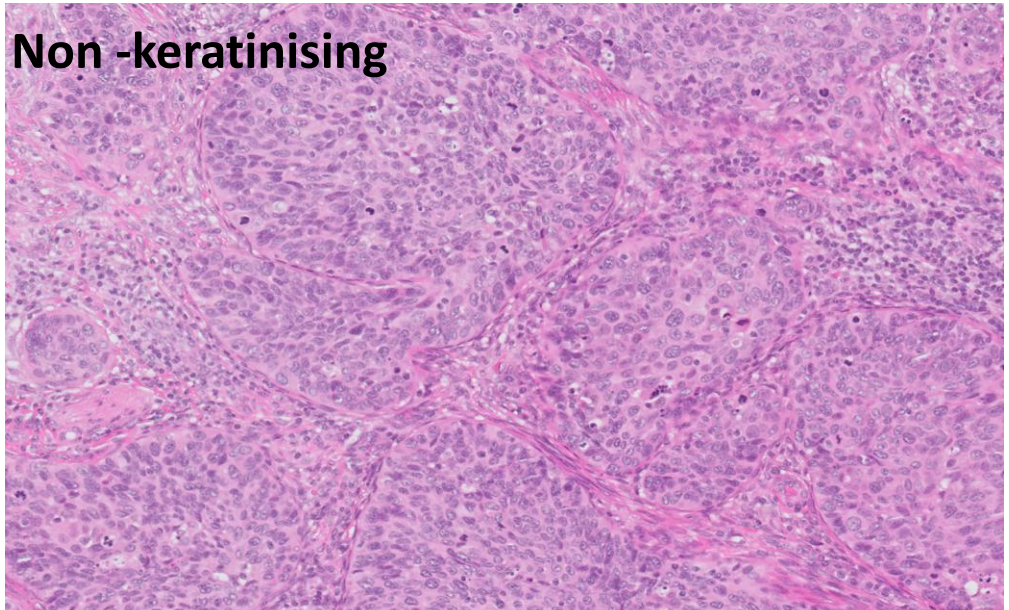

SCC - Patterns

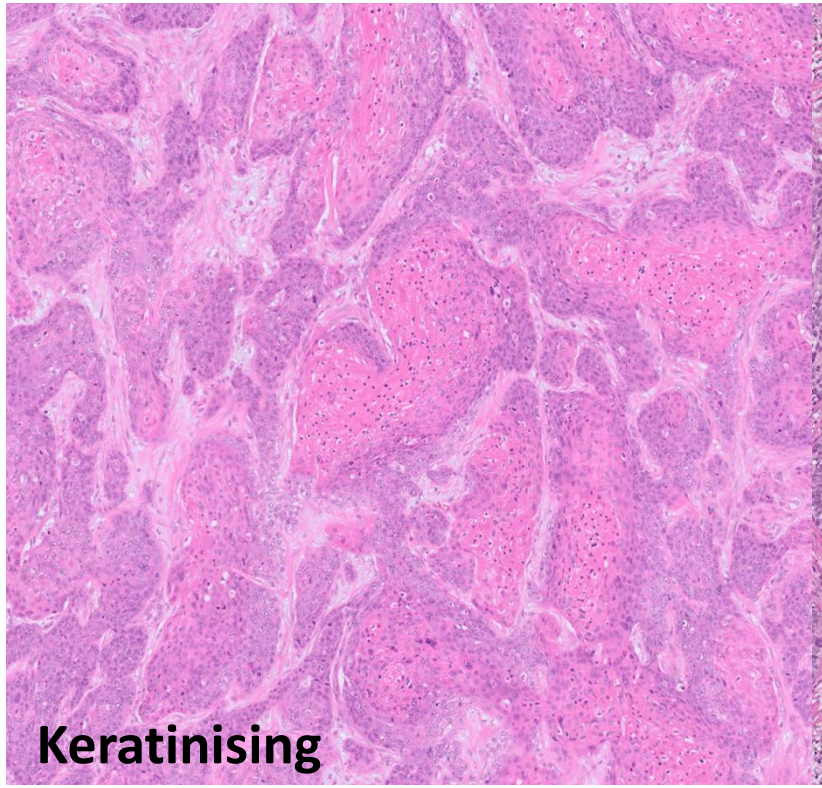

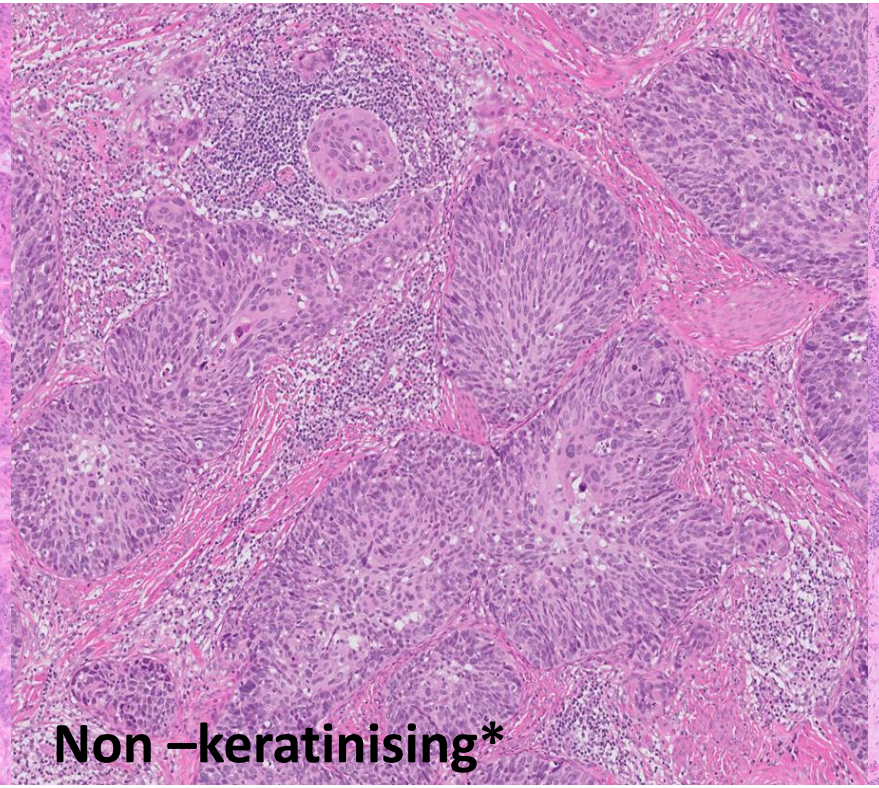

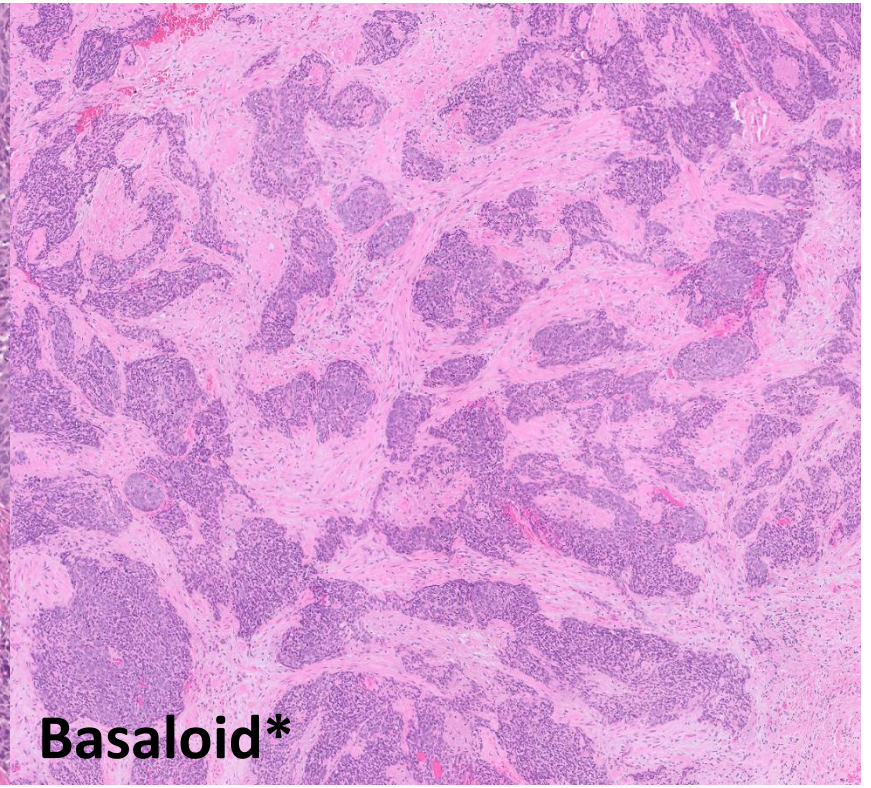

- Warty (condylomatous), papillary, squamotransitional, lymphoepithelioma like
- Spectrum of patterns encountered – NOT PROGNOSTIC

Cannot reliably distinguish HPV association on morphology alone….

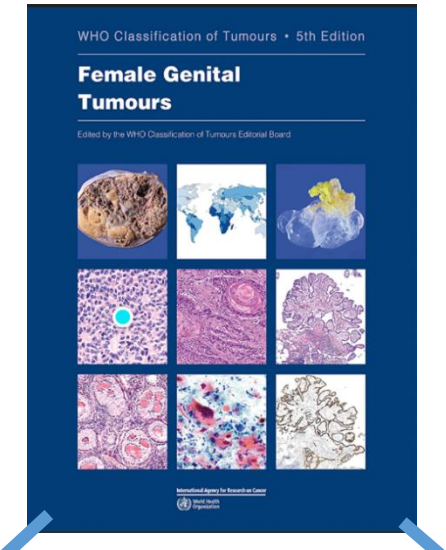

HPV associated

HPV independent

WHO 2020

- HPV classification across FGT
- Help to assess vaccination/screening programmes
- Prognostic information

How should we test for HPV?

- WHO (2020) – p16 testing and/or molecular HPV typing recommended
  - Overexpression of p16 is an acceptable surrogate marker of HPV association '*essential*'
  - HPV testing - '*desirable*'

Method	Pros	Cons
P16INK4a immunohistochemistry	•Rapid •Used routinely in pathology depts •Good ***surrogate*** of deregulated E6 expression (upregulation of p16 expression) •Widely available in path labs	•Does not provide type specific resolution •***p16 may be upregulated in absence of HPV*** (FALSE POSITIVES)
PCR-DNA genotyping	•Can ***identify presence/type of HPV*** •Broad spectrum of HR-types •Sensitive •Specialist/mol path services	Presence does not necessarily mean oncogenic responsibility Less specific (FALSE POSITIVES)
Quantitative PCR-mRNA (E6/E7 expression)	Direct marker of deregulated oncogenic expression	Specimen quality – *FFPE is challenging*
In-Situ Hybridisation (ISH)	Offers 'localisation' in cell Specific	Usually type specific Lower sensitivity
Next Gen Sequencing	Super sensitive and (analytically) specific	Cost Laboratory availability

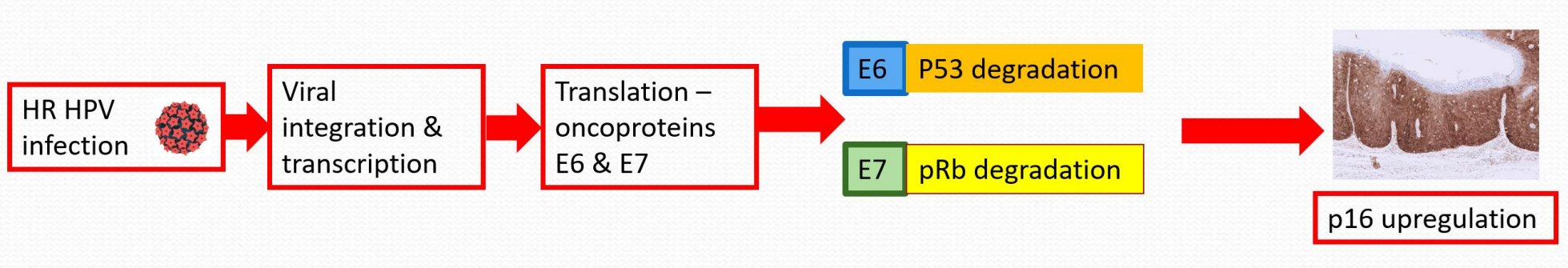

THE BRITISH ASSOCIATION OF GYNAECOLOGICAL PATHOLOGISTS

Interpretation of p16 Immunohistochemistry In Lower Anogenital Tract Neoplasia

Authors: Naveena Singh[1], C Blake Gilks[2], Richard Wing-Cheuk Wong[3], W Glenn McCluggage[4], C Simon Herrington[5]

Abnormal expression in squamous epithelial lesions fulfils ALL of the following (this pattern has been described as BLOCK POSITIVE staining):

- Strong and continuous nuclear OR more typically nuclear and cytoplasmic expression in all epithelial cells in the basal and parabasal layers with upward extension
- Upward extension must involve at least the lower one-third of the epithelial thickness
- Abnormal expression must extend for at least 6 cells across
- It is acknowledged that the criteria defining the horizontal and upward extent are arbitrary but these serve to improve specificity

- Use of the word 'positive' is not recommended in pathology reports owing to potential for confusion.
- Report as
  - PRESENCE vs ABSENCE OF ABNORMAL (DIFFUSE/BLOCK POSITIVE) EXPRESSION

    OR
  - ABNORMAL (DIFFUSE/BLOCK POSITIVE EXPRESSION) vs NEGATIVE/NORMAL expression

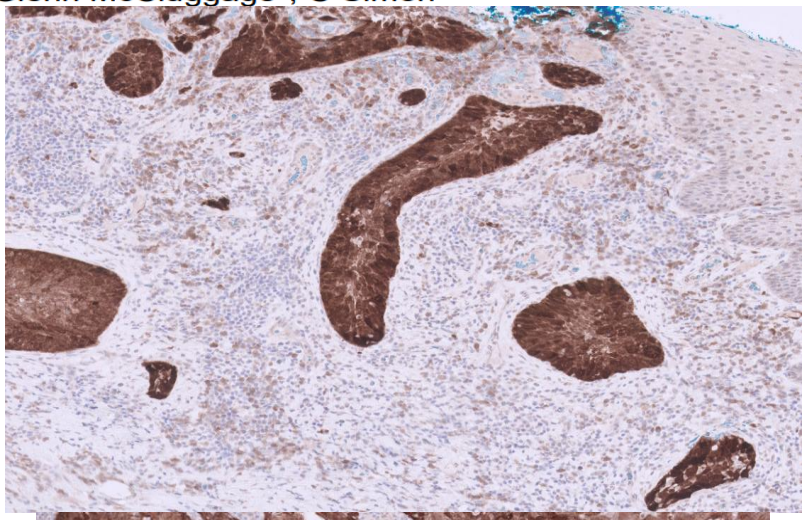

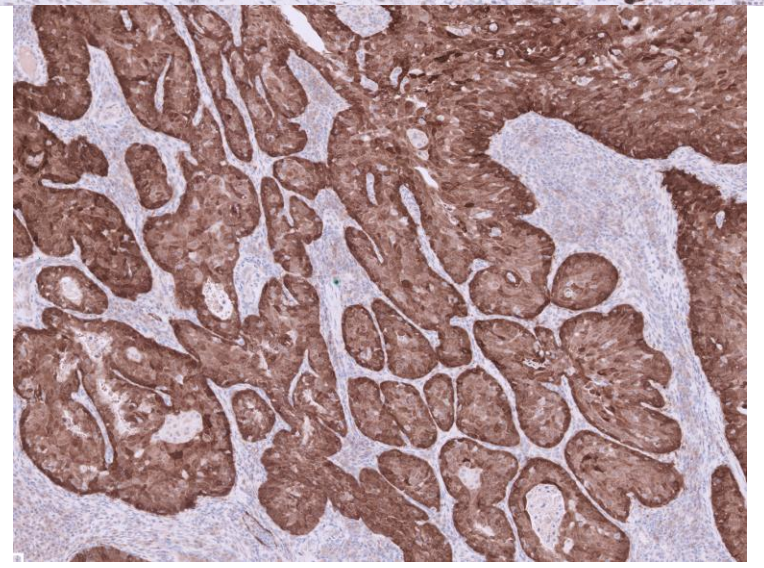

Scottish Human Papillomavirus Reference Laboratory

- **Since 2022 SHPVRL** has offered an HPV genotyping service for all new diagnoses of cervical cancer to all the Scottish health boards
- PCR based detection (qualitative) - type specific resolution of all established high-risk and common low risk types

No spatial information – generates type specific "yes/no" result



FFPE block



10 um section



Nucleic acid extraction & purification

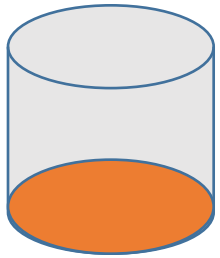

Total Nucleic acid

Amplification of HPV sequences
RT PCR



Genotype specific detection of up to 24 HR-HPV types using Anyplex HPV 28 assay

HPV Genotyping - classification

- Type specific detection of 24 HPV types including all 13 established high-risk types (as per table below) and common low risk types

Group (IARC)	HPV types	Comments
1 (Carcinogenic)	16	Most potent type, risk order of magnitude higher than any other type
1 (Carcinogenic)	18,31,33,35,39,45,51,52,56,58,59	Sufficient Evidence for Cervical Cancer
2A (Probably Carcinogenic)	68	Limited evidence in humans but mechanistic evidence for cervical cancer
2B (Possibly Carcinogenic)	26,53,66,67,70,73,82, 30, 34,69,85,97	Limited evidence in humans for cervical cancer

Low-risk types: 6, 11, 40, 42, 43, 44, 54, 61

Infographic: Milestones of the HPV vaccination and surveillance programme

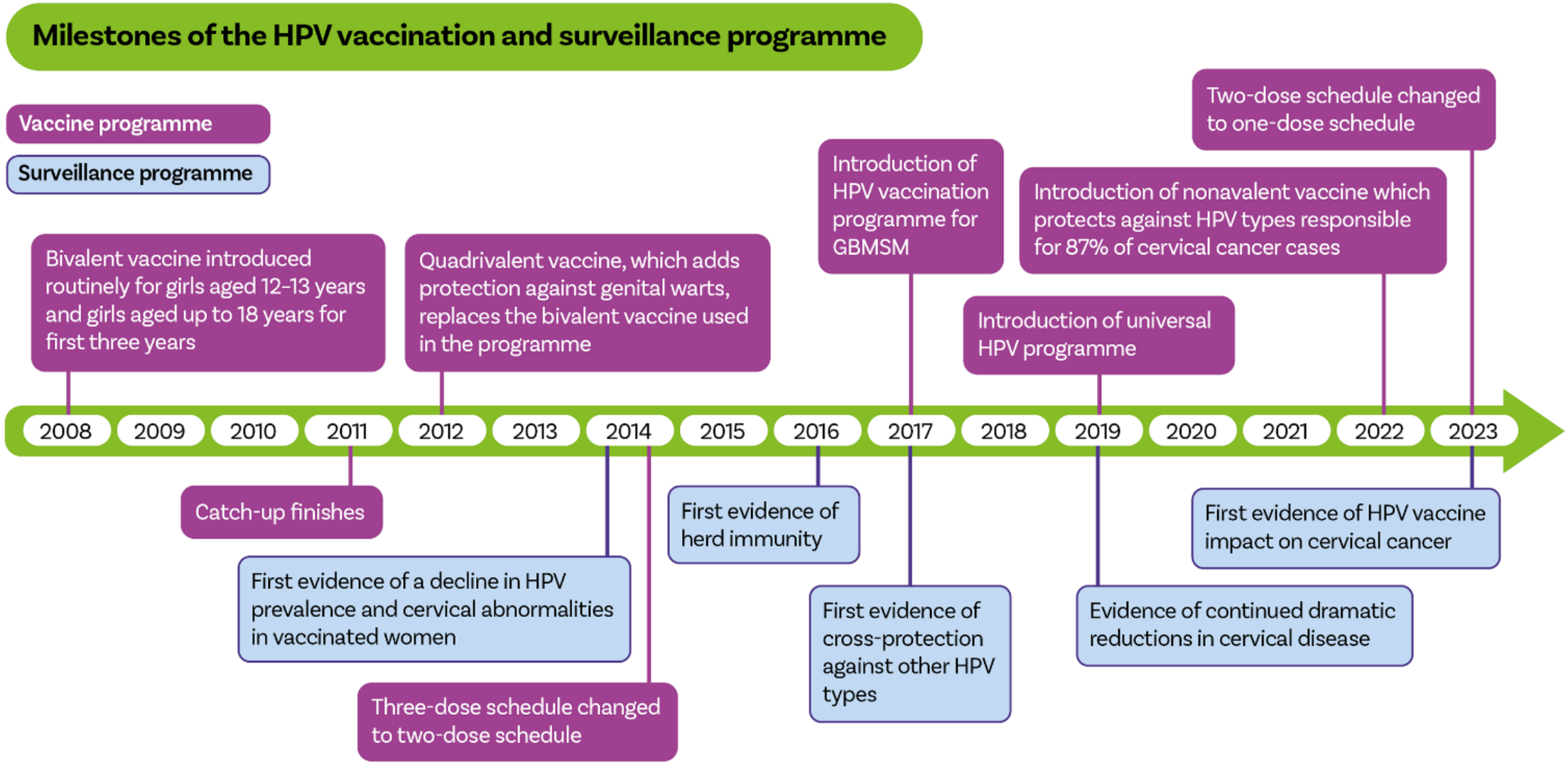

https://publichealthscotland.scot/news/2024/january/no-cervical-cancer-cases-detected-in-vaccinated-women-following-hpv-immunisation/

OXFORD

JNCI: Journal of the National Cancer Institute, 2024, **116(6)**, 857–865
https://doi.org/10.1093/jnci/djad263
Advance Access Publication Date: January 22, 2024
Article

Invasive cervical cancer incidence following bivalent human papillomavirus vaccination: a population-based observational study of age at immunization, dose, and deprivation

Tim J. Palmer, FRCPath[1,2,*], Kimberley Kavanagh, PhD[1,3], Kate Cuschieri, PhD[4], Ross Cameron, MPH[1], Catriona Graham, MSc[5], Allan Wilson, FIBMS[6], Kirsty Roy, PhD[1]

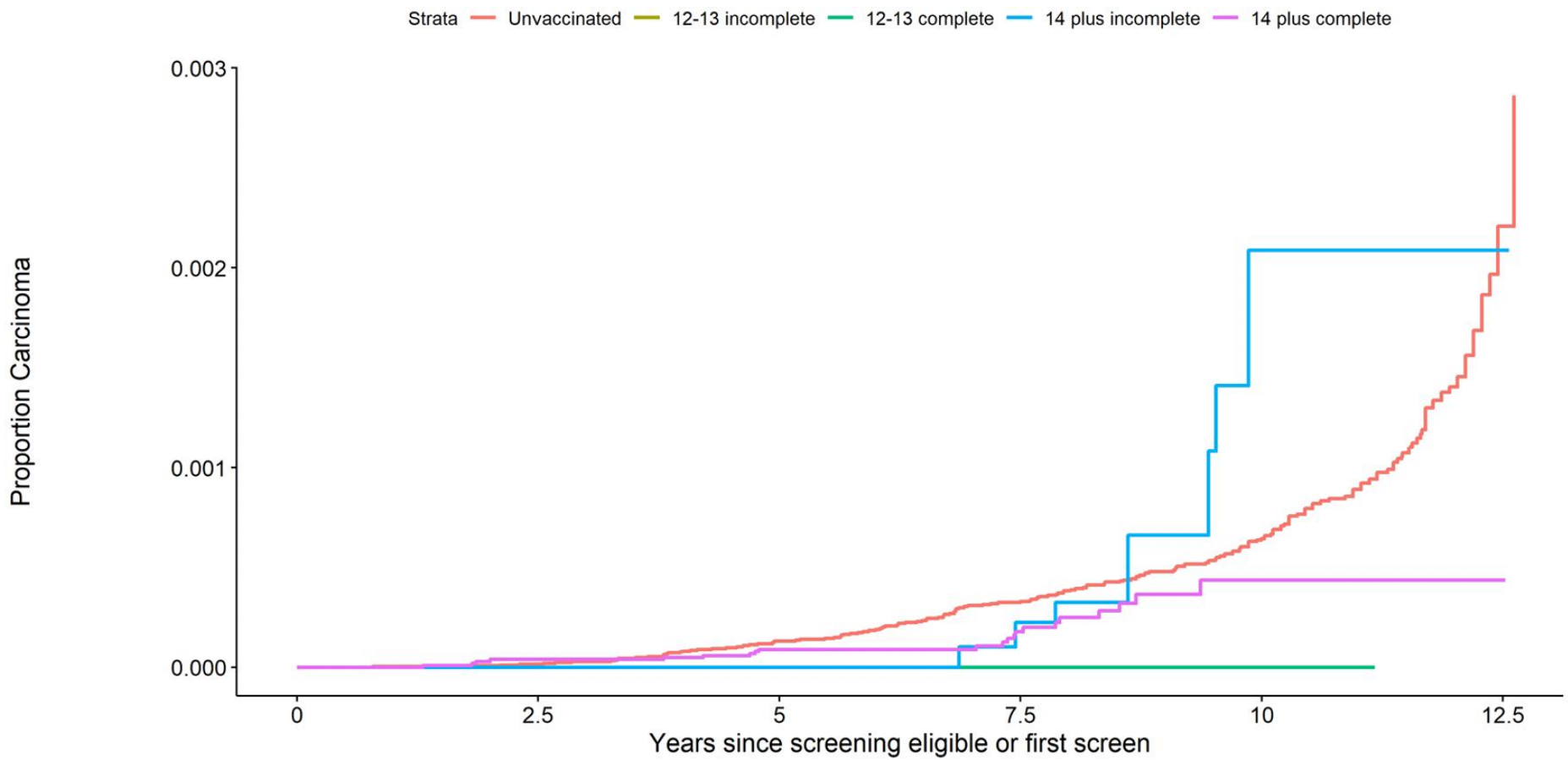

HPV independent SCC



Review

Human papillomavirus-independent cervical cancer

Andreina Fernandes [1], David Viveros-Carreño [2], Jorge Hoegl [3], Maira Ávila,[1] Rene Pareja [2,4]

- ‘True’ HPV negative

But could also be:

- Loss of HPV genome during integration
- HPV types not detected by current molecular tests
- Failed test
- Metastases from other sites

Invasive Squamous Cell Carcinoma of the Cervix: A Review of Morphological Appearances Encountered in Human Papillomavirus-associated and Papillomavirus-independent Tumors and Precursor Lesions

(*Adv Anat Pathol* 2024;31:1–14)

Simona Stolnicu, MD, PhD, Douglas Allison, MD,† Andrei Patrichi, MD,* Jessica Flynn, MS,‡ Alexia Iasonos, PhD,‡ and Robert A. Soslow, MD†*

- 5-7% SCC are HPV independent
- HPV-I SCC – older age, often advanced at presentation, worse prognosis
- Spectrum of morphologies
- Precursor lesions poorly characterised at present (small case series)

Human Papilloma Virus–Independent/p53abnormal Keratinizing Squamous Cell Carcinoma of the Uterine Cervix Associated With Uterine Prolapse

Lars-Christian Horn, MD, PhD, Christine E. Brambs, PhD,† Bahriye Aktas, PhD,‡ Astrid Dannenmann, MD,§ Jens Einenkel, PhD,§ Michael Höckel, PhD,‡ Irene Krücken, MD,*‖ Sabine Taubenheim, MD,¶ Gero Teichmann, MD,# Ulrike Obeck, MD,‖ Mathias Stiller, MD,‖ and Anne Kathrin Höhn, MD**

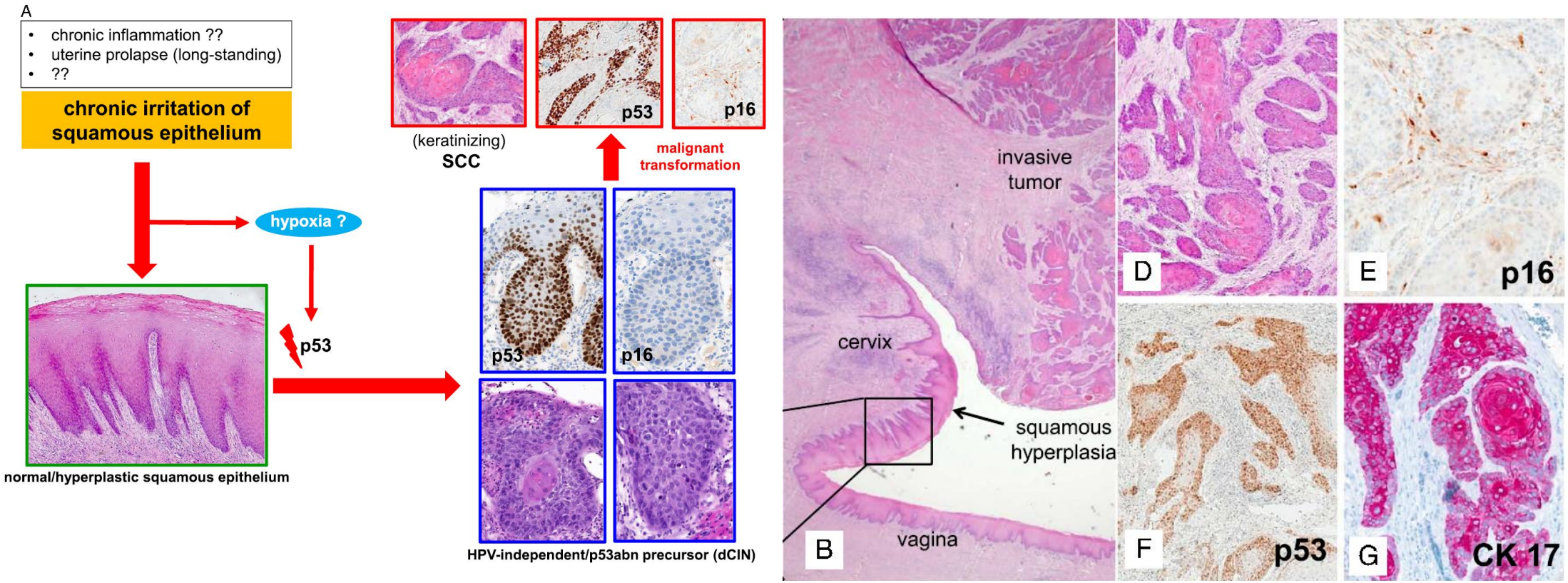

(*Int J Gynecol Pathol* 2025;44:2–14)

SCC ‘NOS’

- WHO (2020) - Acceptable alternative where p16 IHC or HPV molecular testing not available
- ***Every effort should be made to classify where possible***

- ***ICCR – presence of background typical CIN3 or HR-HPV detected in smear sufficient for HPV-a***

Reporting guidelines

NHS England

Guidance

Cervical Screening Programme: histopathology reporting handbook

Updated 27 September 2024

Contents

Cervical screening: histopathology guidance for the NHS cervical screening programme

https://www.gov.uk/government/publications/cervical-screening-histopathology-reporting-handbook/cervical-screening-programme-histopathology-reporting-guidance

The Royal College of Pathologists

Pathology: the science behind the cure

Standards and datasets for reporting cancers

Dataset for histopathological reporting of cervical neoplasia

March 2021

Authors: Dr Raji Ganesan, Birmingham Women's and Children's NHS Foundation Trust, Birmingham
Dr Naveena Singh, Barts Health NHS Trust, London
Dr Anthony T Williams, Birmingham Women's and Children's NHS Foundation Trust



Common issues in diagnosing invasion

Expansile CIN3

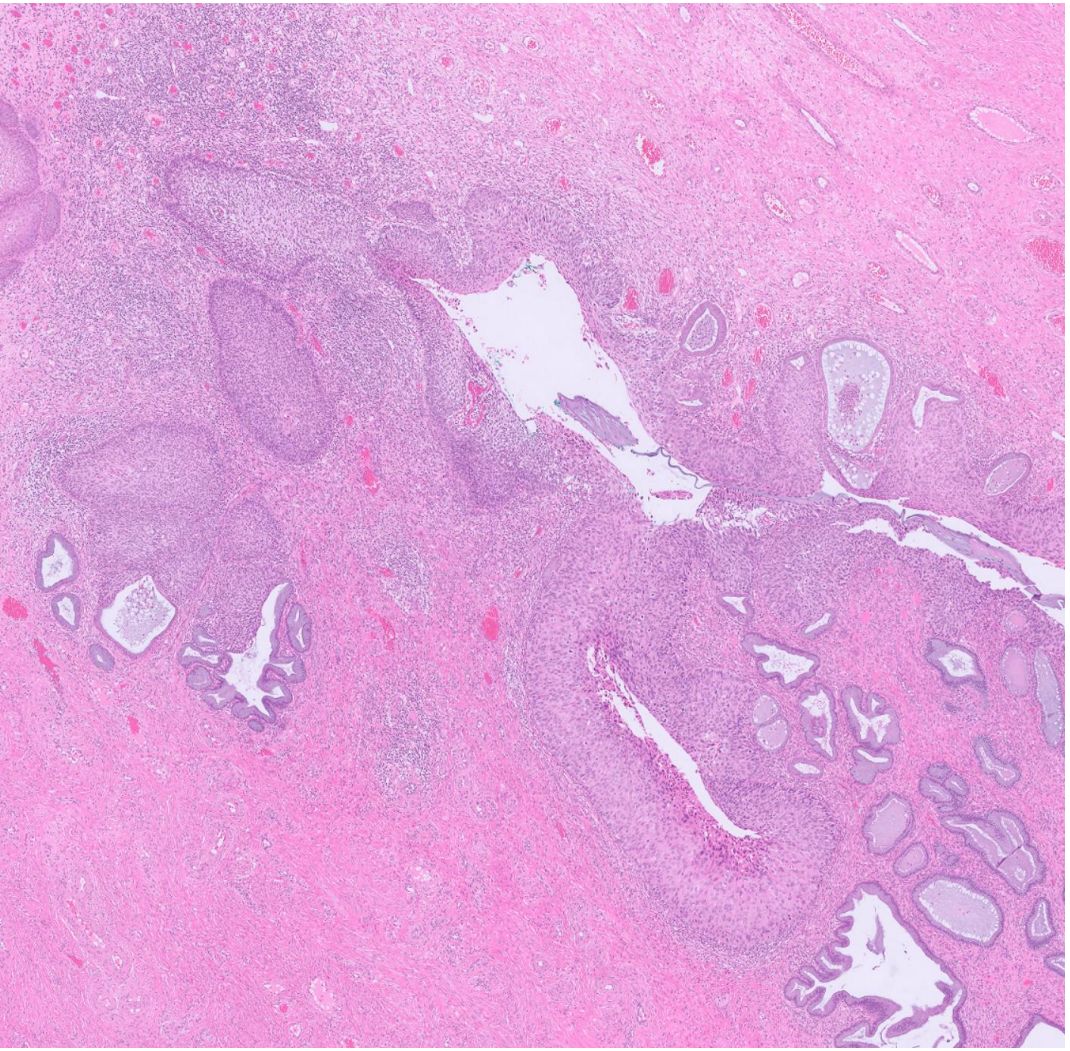

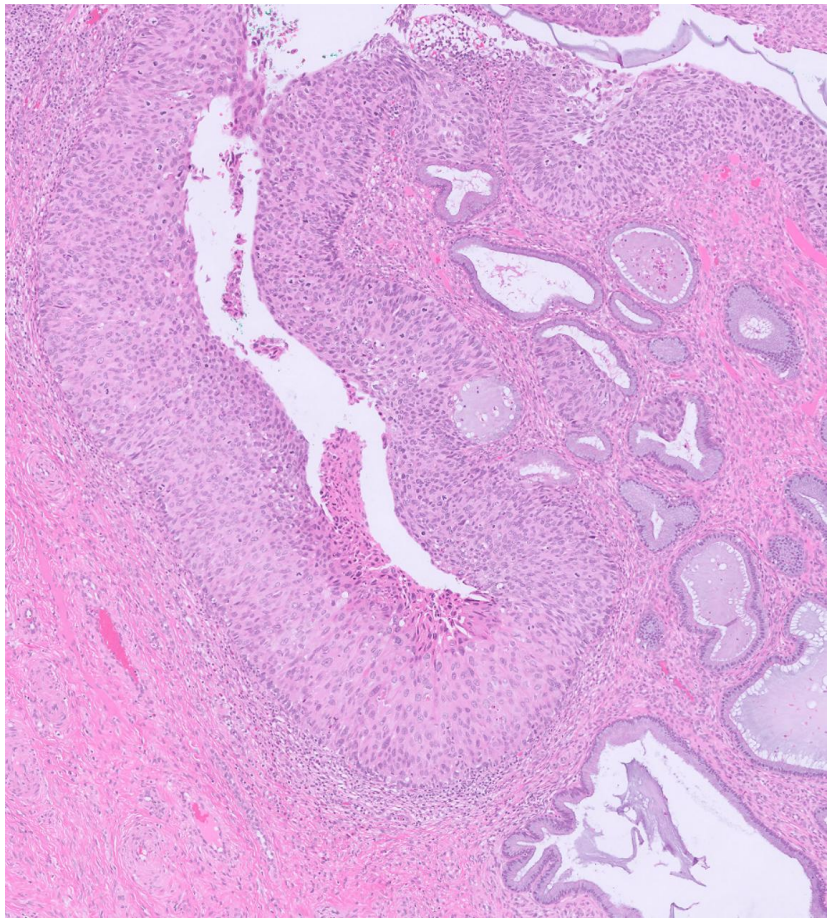

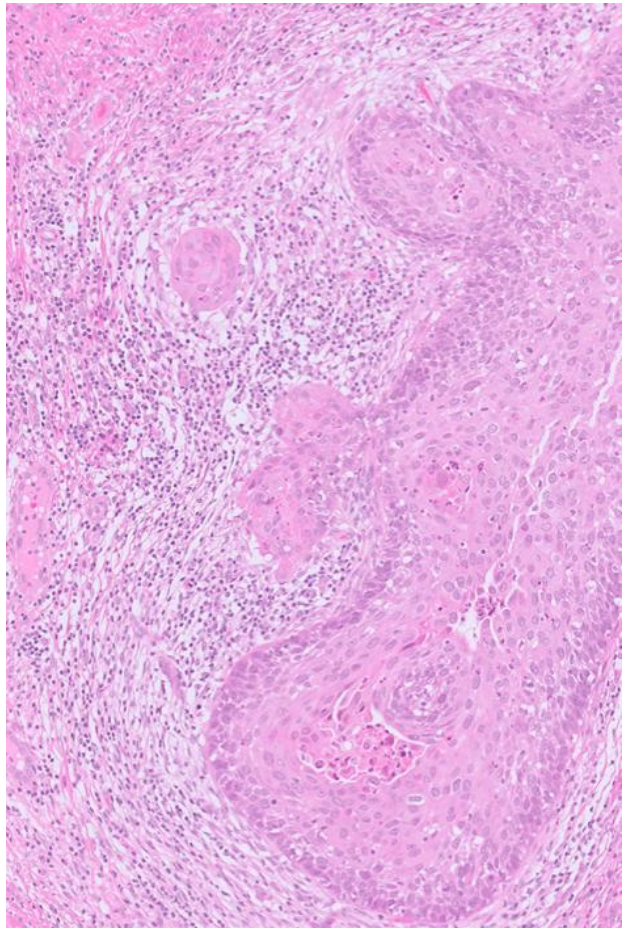

‘Early’ invasion

Budding/ irregular stromal junction
Eosinophilia – ‘paradoxical maturation’
Stromal reaction
Inflammatory ‘flare’

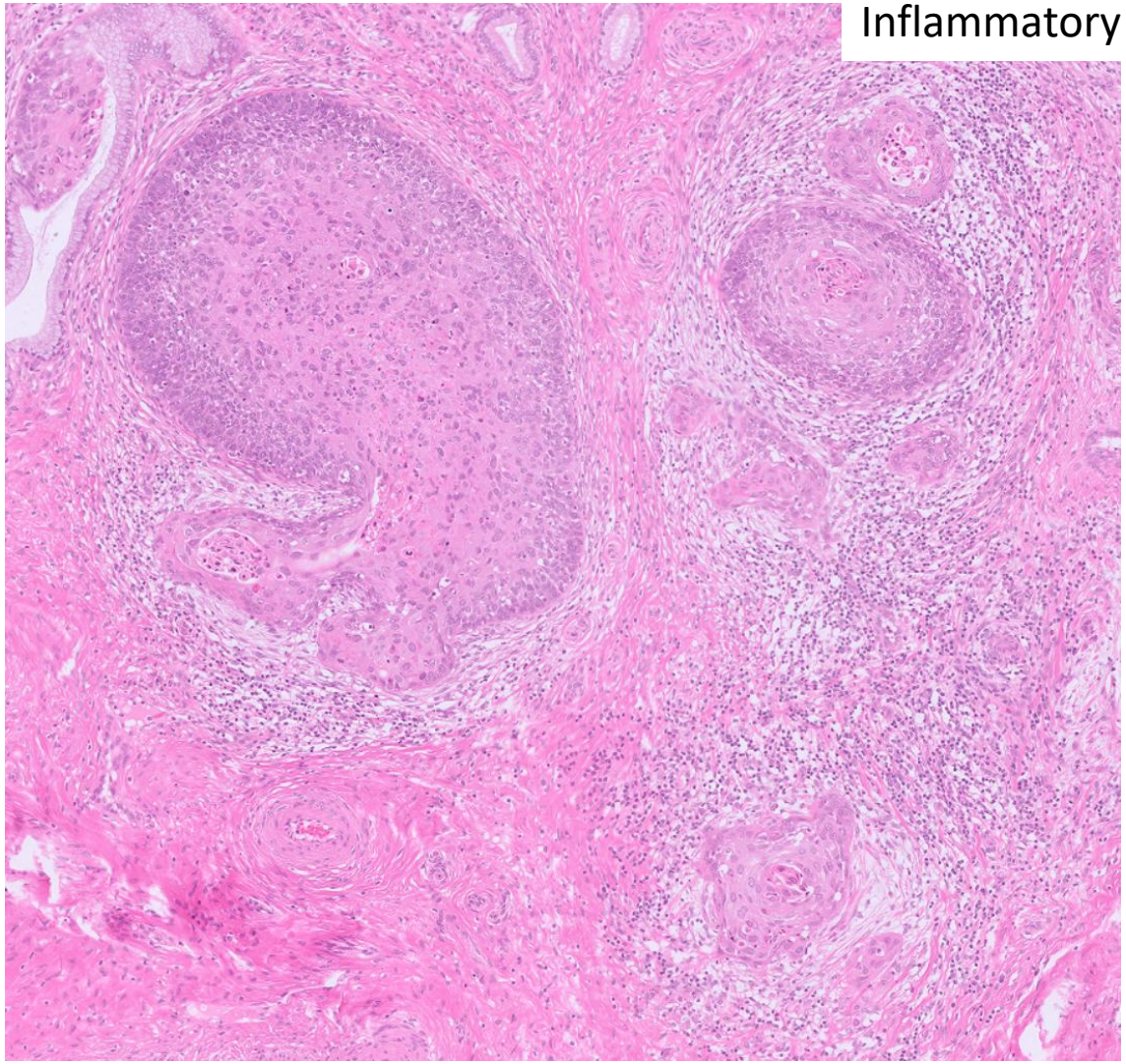

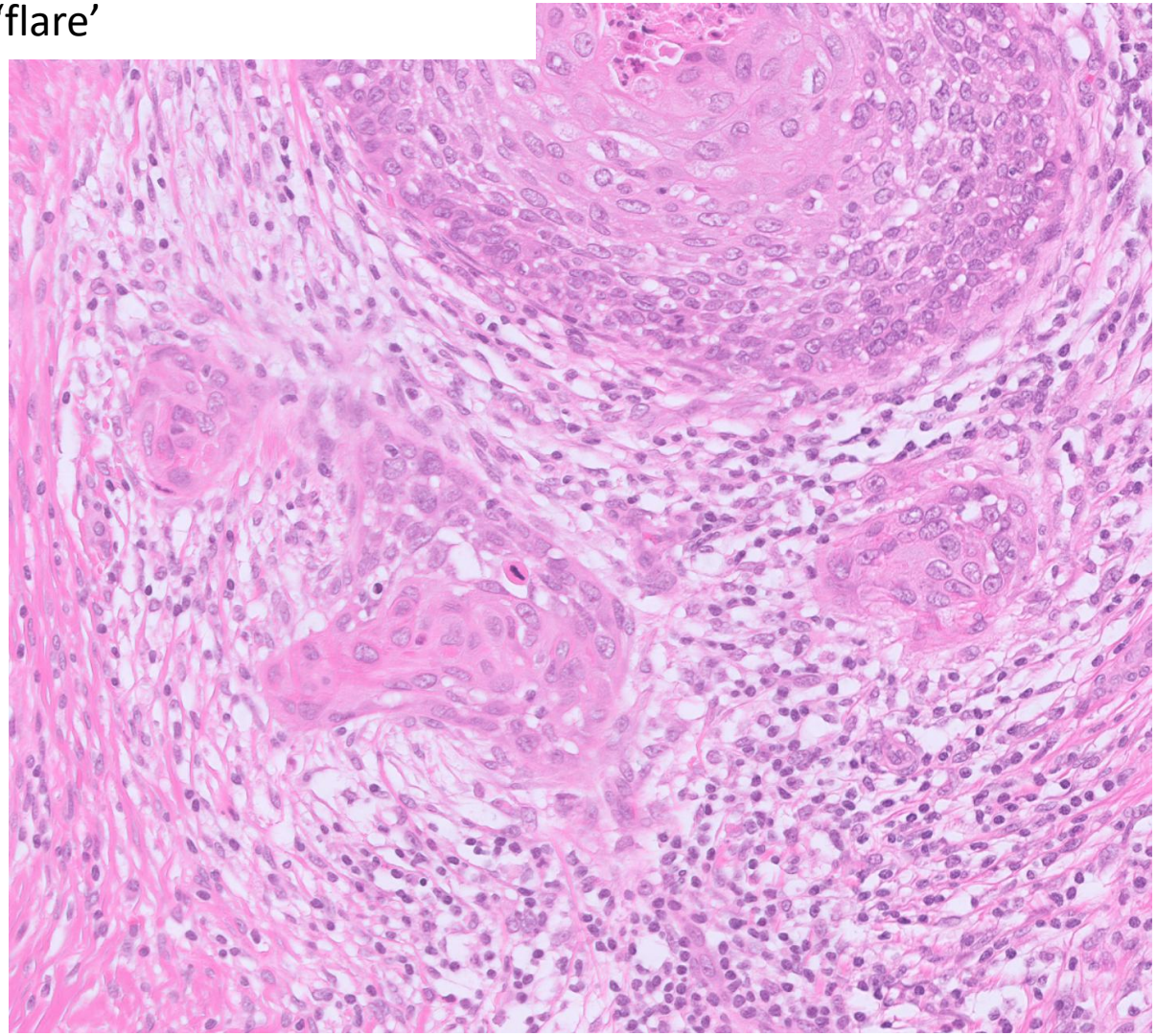

Papillary S

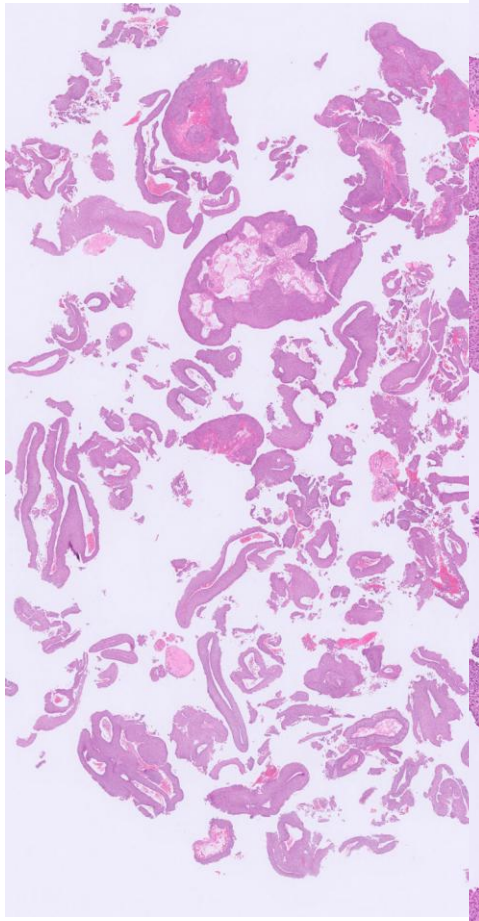

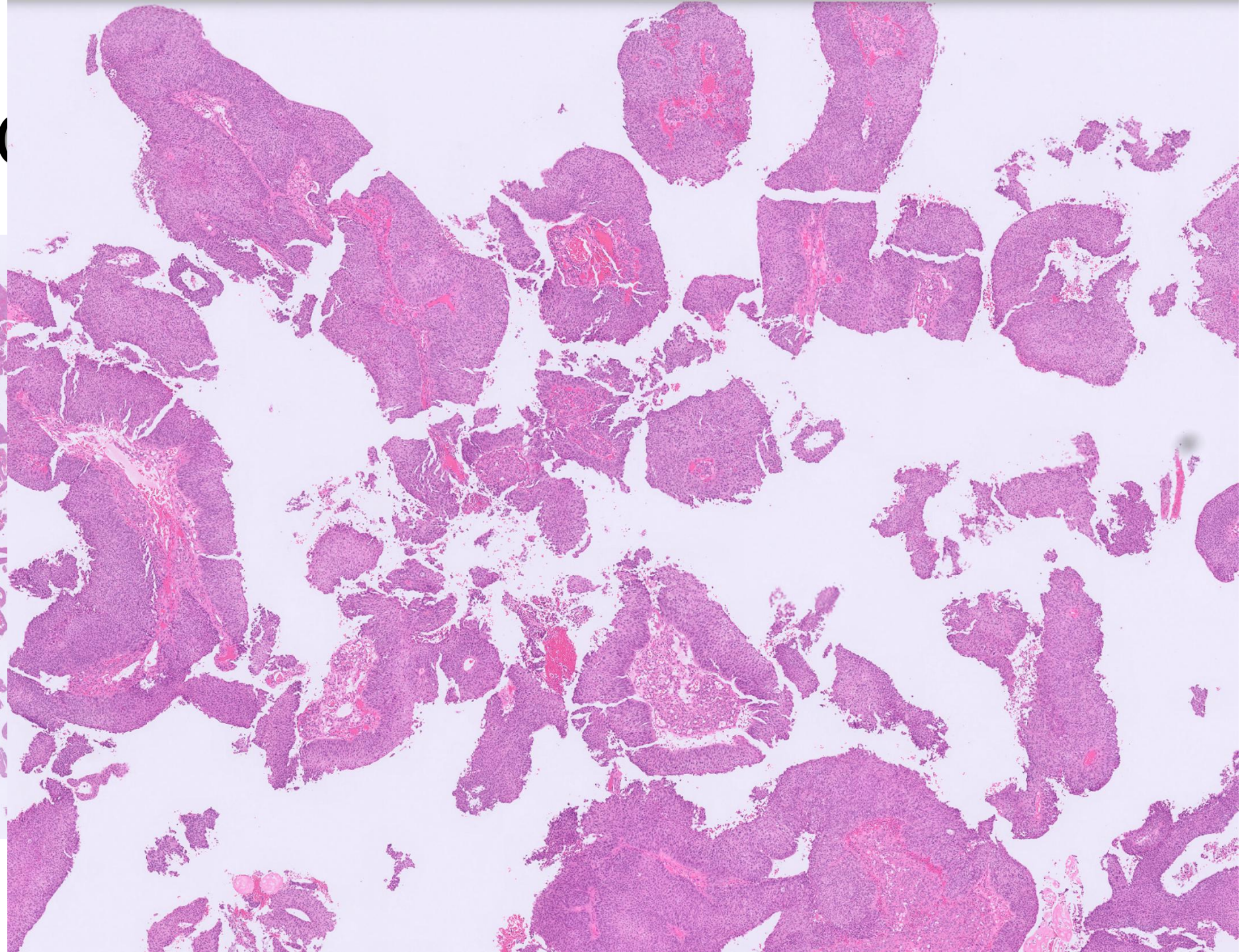

CIN3 like SCC

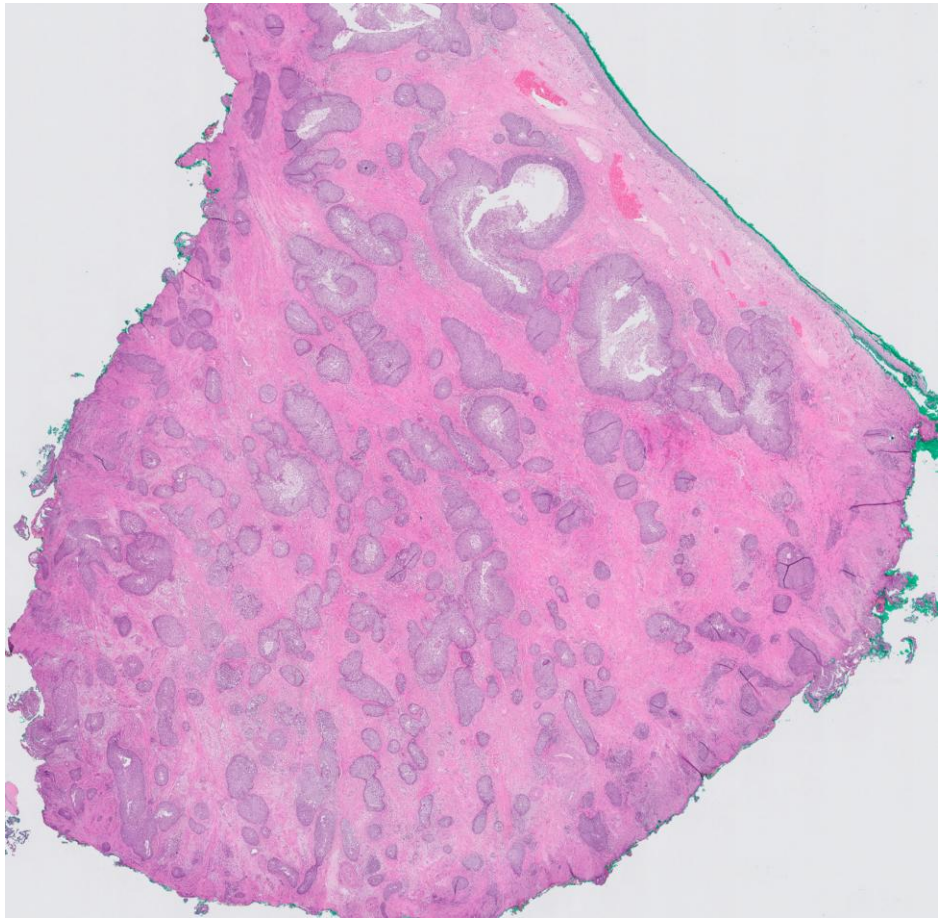

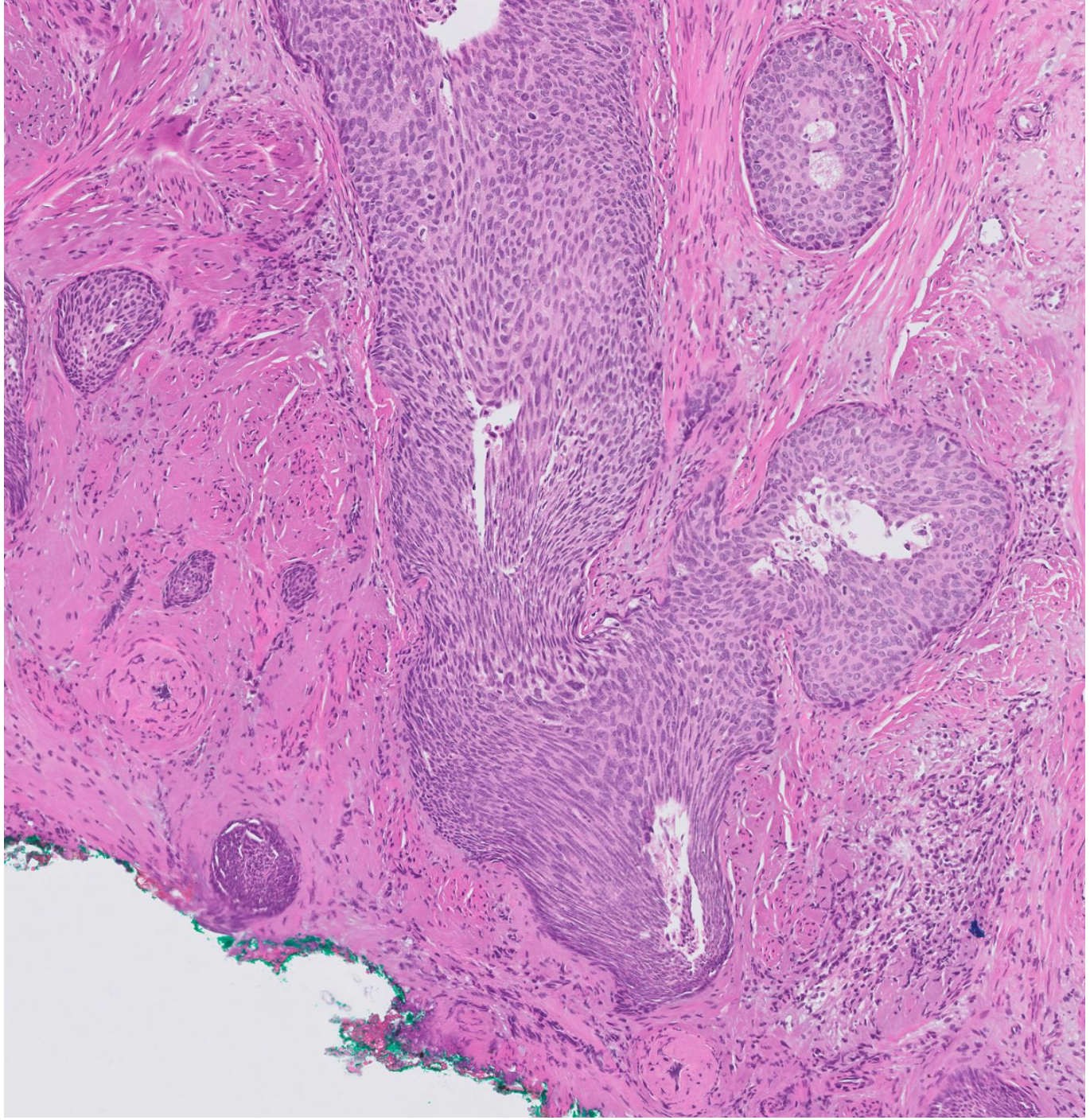

Subtle invasion

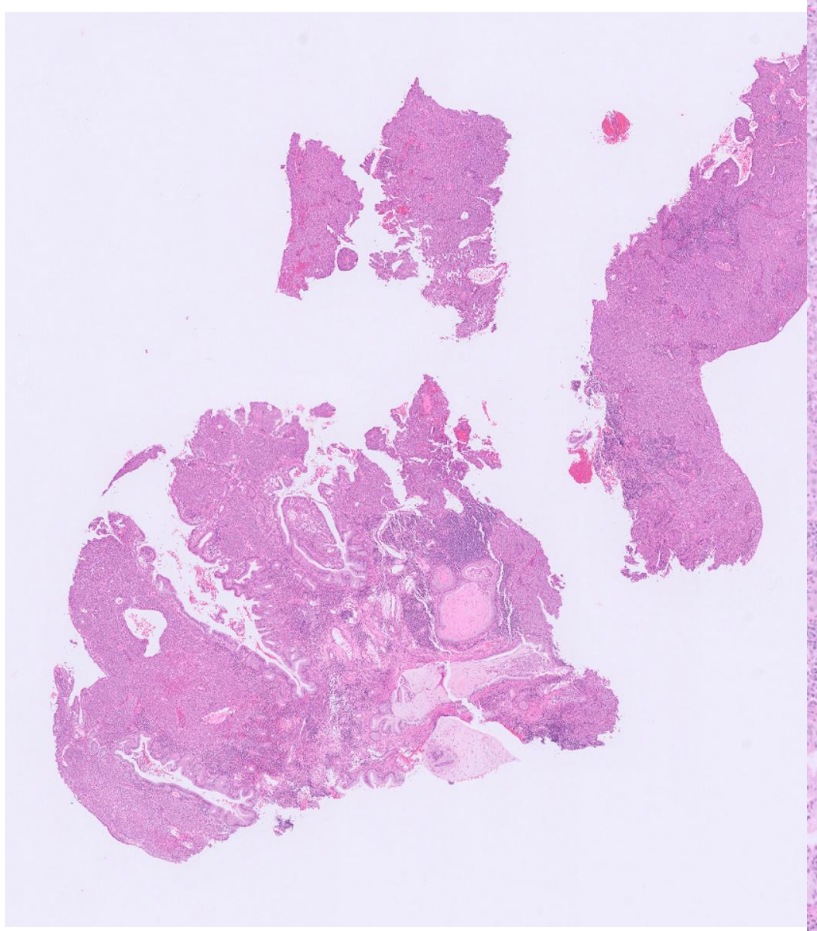

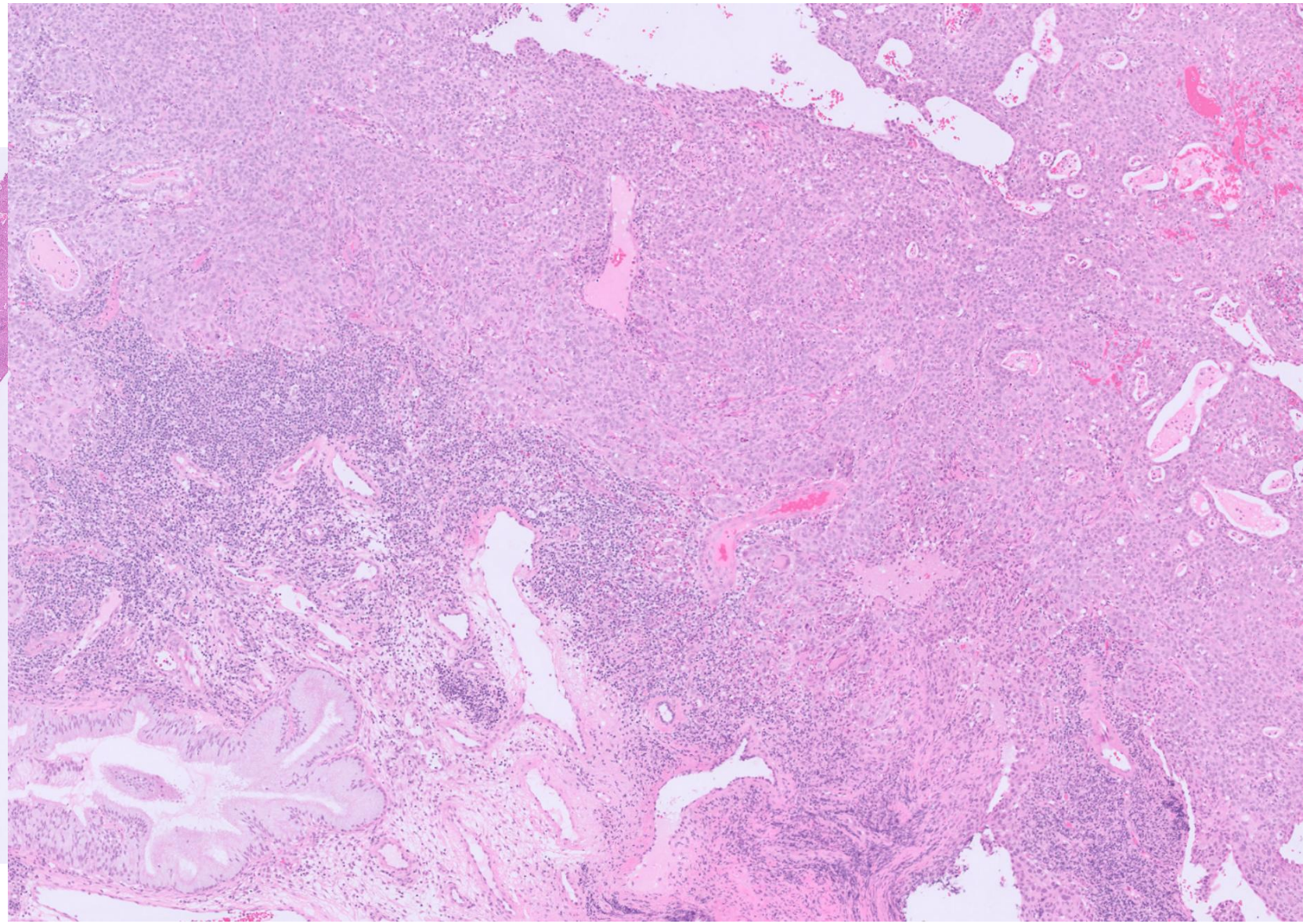

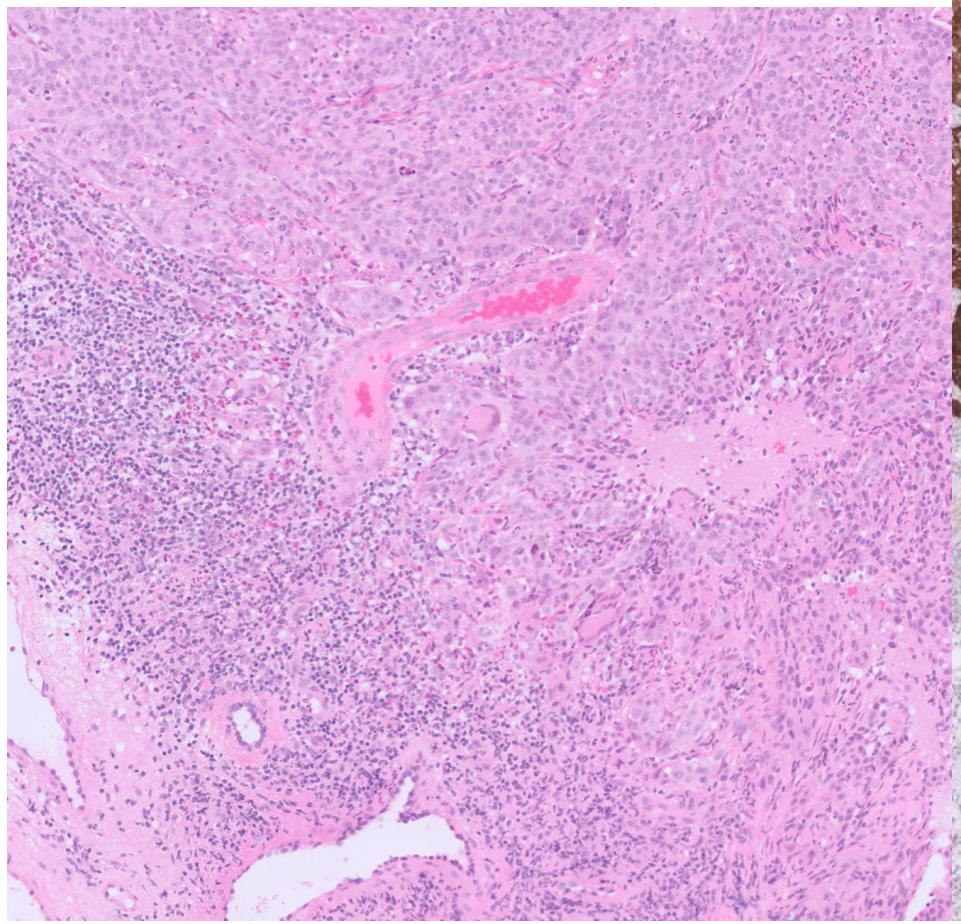

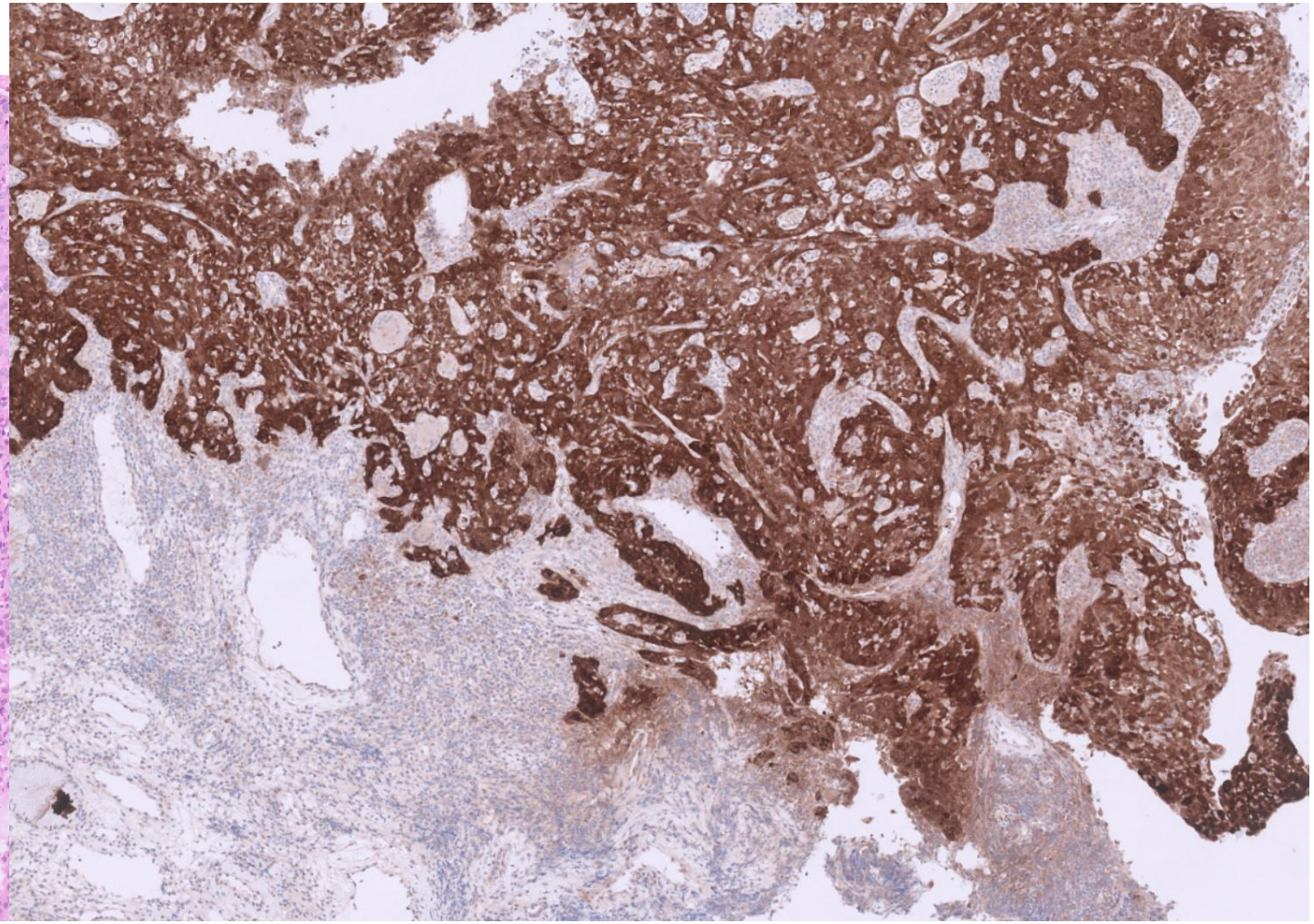

Biopsy sampling

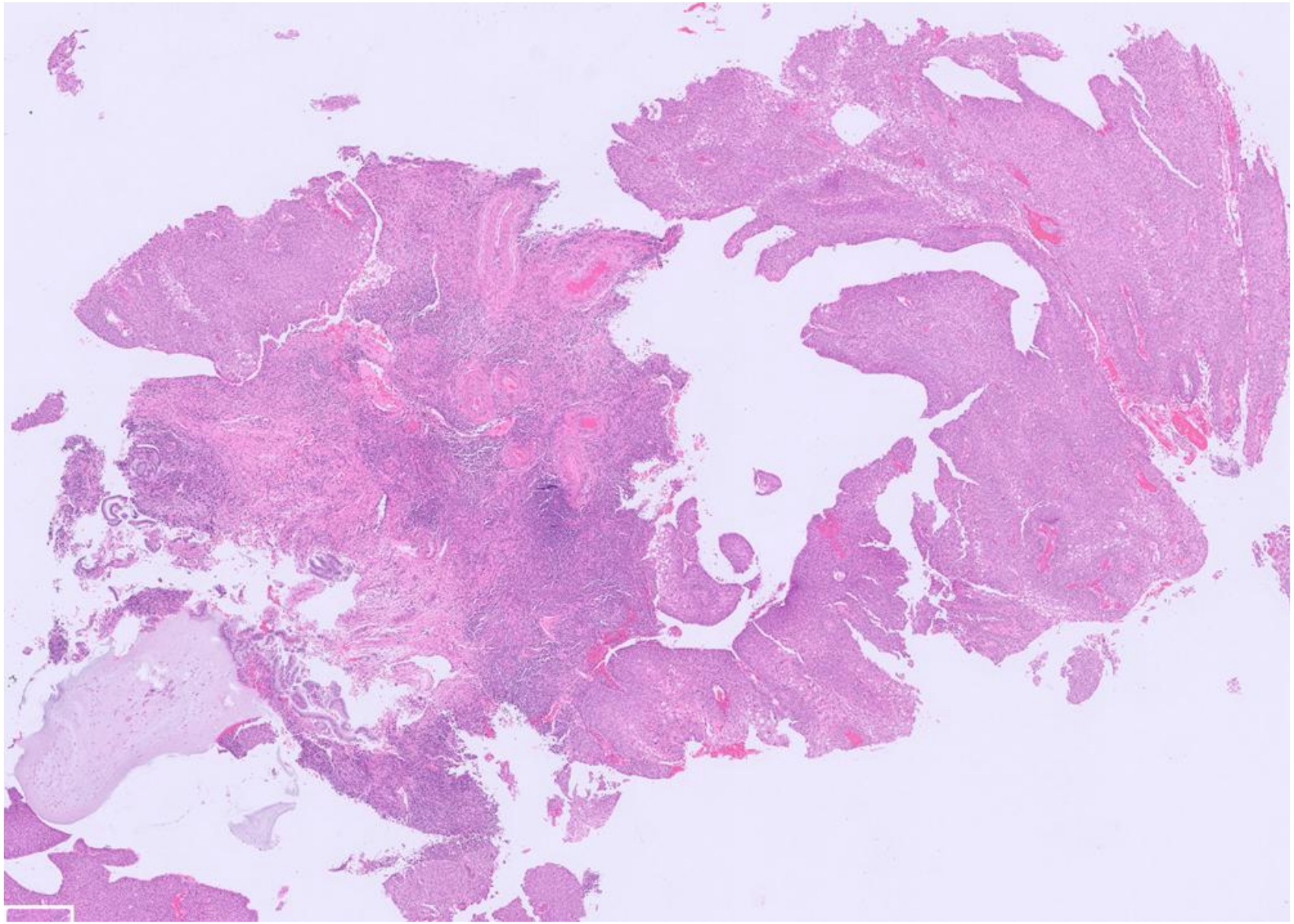

Subsequent LLETZ.....

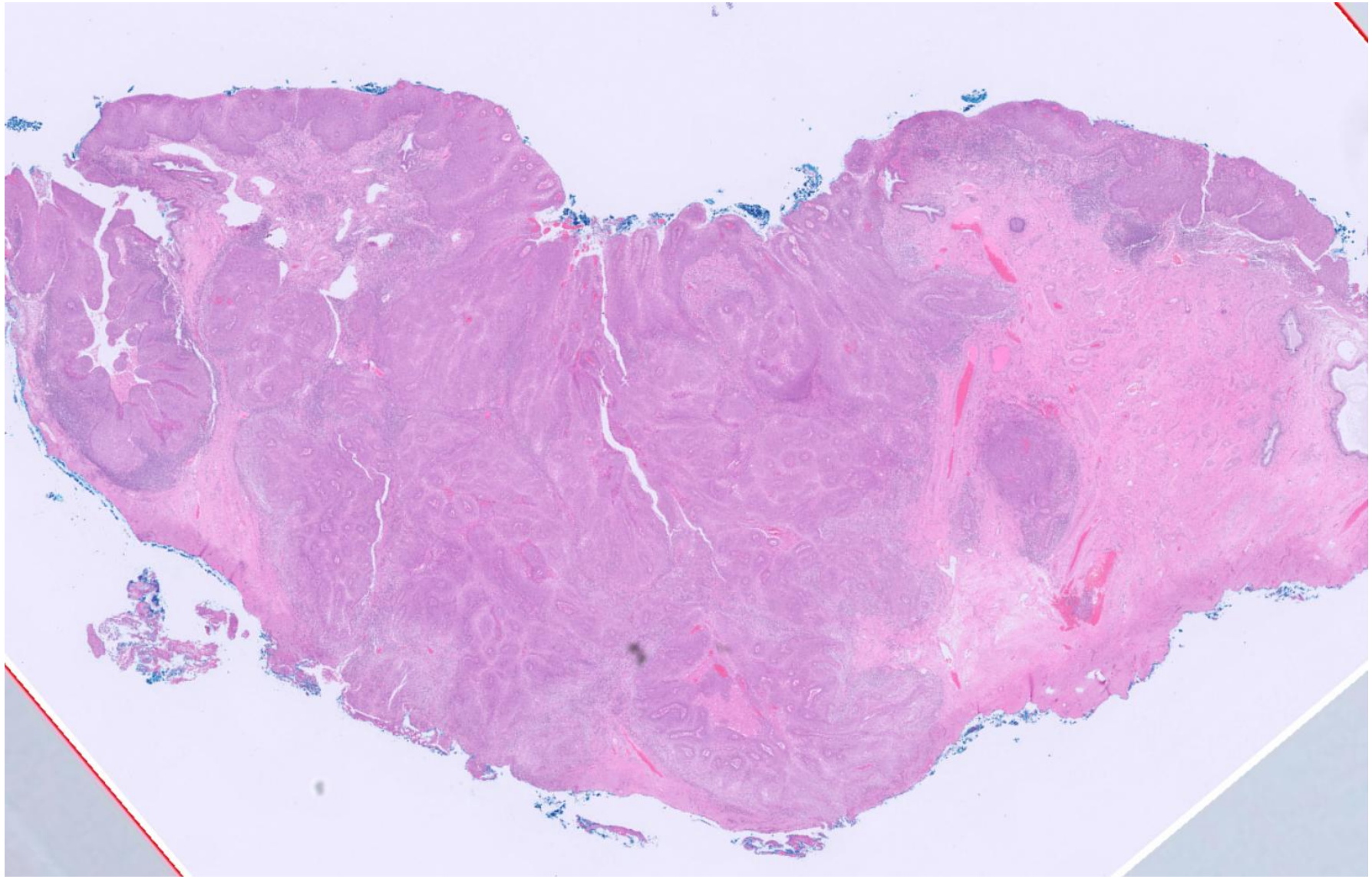

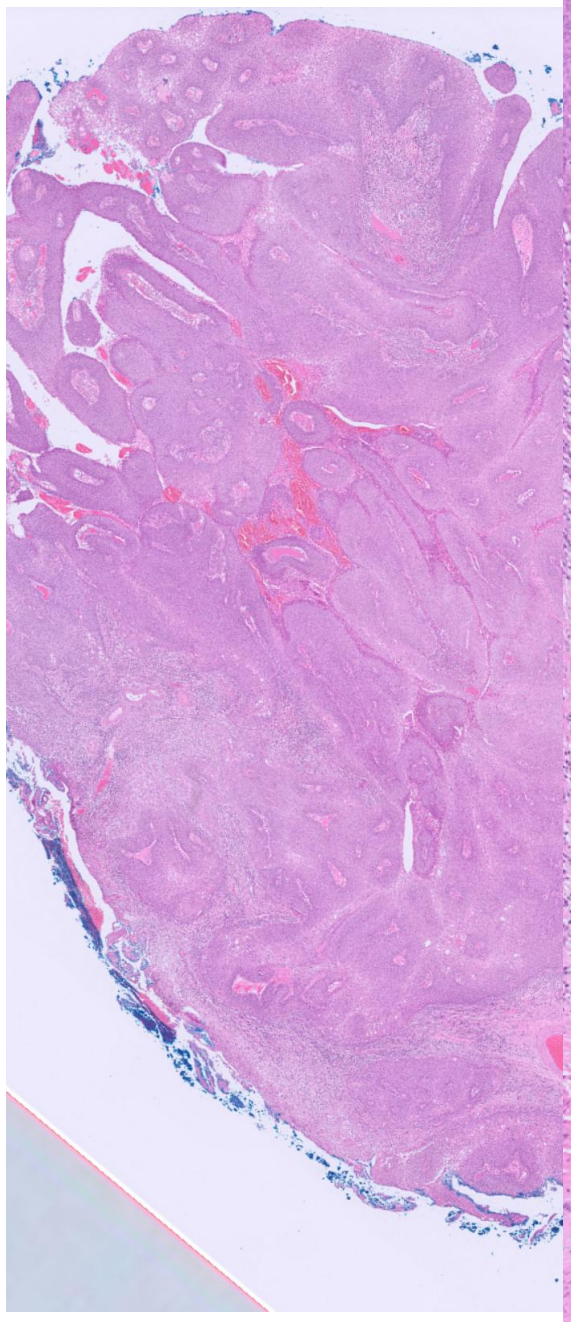

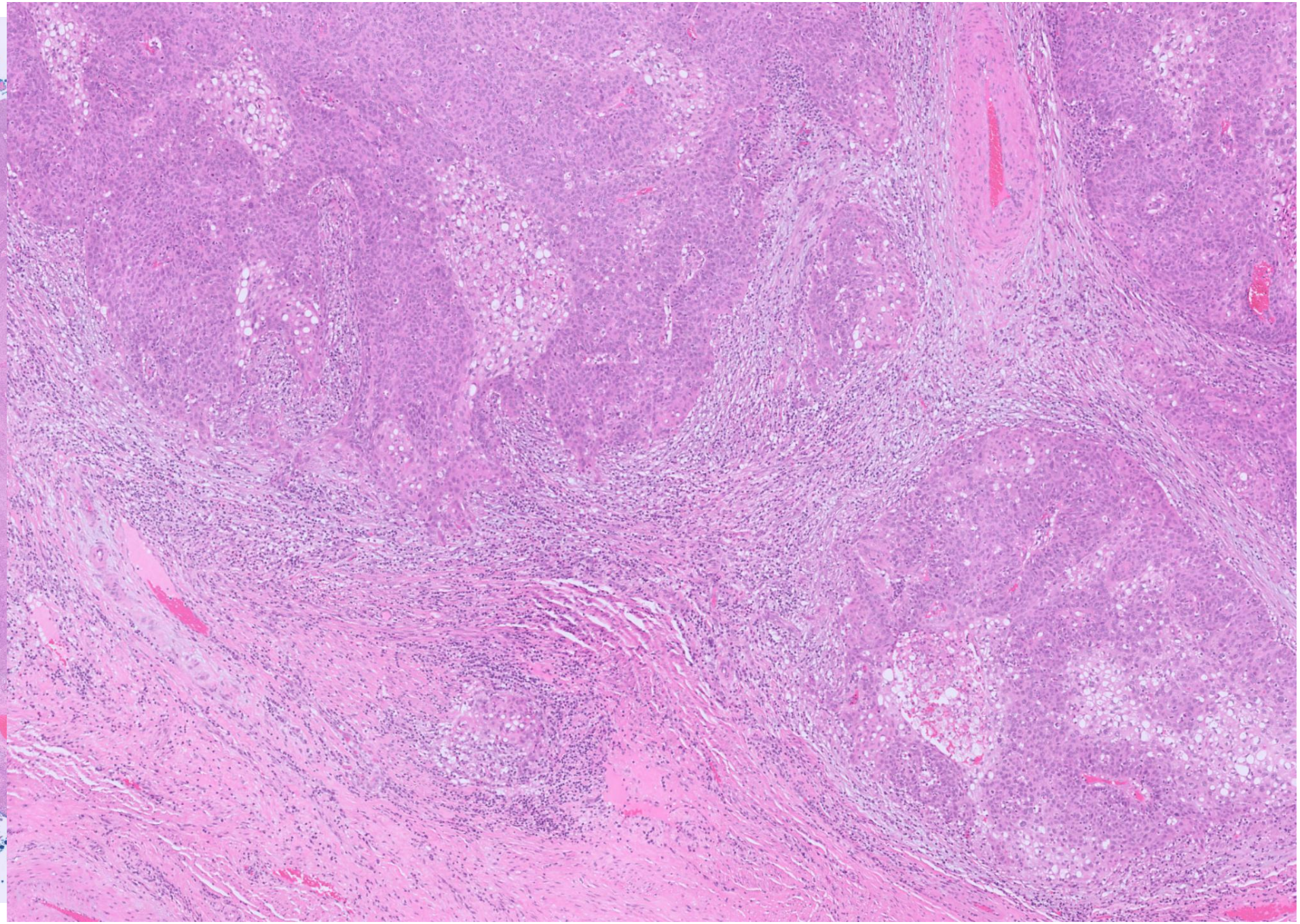

A note on grading SCC's

- Clinicians usually expect a grade however….
- No universally agreed grading system for SCC
  - Modified Broder's based on keratinisation
  - Many CSCC are non keratinising/basaloid
  - Early invasive SCC often look 'poorly' dx
- Uncertain clinical/prognostic value
- ICCR – recommend not to grade SCC

Importance of measurements:

- FIGO staging in IA1/IA2 and 1B categories
- Determines management
  - *1A1 – repeat LLETZ/simple hyst*
  - *1A2/1B1 – radical hysterectomy*
  - *Need for adjuvant with other factors*
- Standardised/consistent trimming CRUCIAL
- Large ca – biopsy only size based on imaging/clinical
- *Provisional stage offered but needs clinical/radiology and correlation with ALL specimens*

The NEW ENGLAND JOURNAL of MEDICINE

ORIGINAL ARTICLE

Simple versus Radical Hysterectomy in Women with Low-Risk Cervical Cancer

Authors: Marie Plante, M.D., Janice S. Kwon, M.D., Sarah Ferguson, M.D., Vanessa Samouëlian, M.D., Gwenael Ferron, M.D., Amandine Maulard, M.D., Cor de Kroon, M.D., +13, for the CX.5 SHAPE investigators* Author Info & Affiliations

Published February 28, 2024 | N Engl J Med 2024;390:819-829 | DOI: 10.1056/NEJMoa2308900 | VOL. 390 NO. 9

Copyright © 2024

- FIGO 2009 stage 1A2 or 1B1
- </= 2cm
- DOI <10mm LEEP or MRI <50% stromal involvement
- No nodal mets on imaging

Received: 24 July 2018 | Revised: 5 November 2018 | Accepted: 20 December 2018 | First published online: 17 January 2019
DOI: 10.1002/ijgo.12749

FIGO COMMITTEE REPORT

WILEY
International Journal of Gynecology & Obstetrics FIGO

Revised FIGO staging for carcinoma of the cervix uteri ☆

Neerja Bhatla[1,*] | Jonathan S. Berek[2] | Mauricio Cuello Fredes[3] | Lynette A. Denny[4] | Seija Grenman[5] | Kanishka Karunaratne[6] | Sean T. Kehoe[7] | Ikuo Konishi[8] | Alexander B. Olawaiye[9] | Jaime Prat[10] | Rengaswamy Sankaranarayanan[11,12]

Box 1 FIGO staging of carcinoma of the cervix uteri (2018).

Stage I:

The carcinoma is strictly confined to the cervix uteri (extension to the corpus should be disregarded)

- IA Invasive carcinoma that can be diagnosed only by microscopy, with maximum depth of invasion <5 mm[a]
  - IA1 Measured stromal invasion <3 mm in depth
  - IA2 Measured stromal invasion ≥3 mm and <5 mm in depth
- IB Invasive carcinoma with measured deepest invasion ≥5 mm (greater than stage IA), lesion limited to the cervix ut
  - IB1 Invasive carcinoma ≥5 mm depth of stromal invasion and <2 cm in greatest dimension
  - IB2 Invasive carcinoma ≥2 cm and <4 cm in greatest dimension
  - IB3 Invasive carcinoma ≥4 cm in greatest dimension

Stage II:

The carcinoma invades beyond the uterus, but has not extended onto the lower third of the vagina or to the pelvic wall

- IIA Involvement limited to the upper two-thirds of the vagina without parametrial involvement
  - IIA1 Invasive carcinoma <4 cm in greatest dimension
  - IIA2 Invasive carcinoma ≥4 cm in greatest dimension
- IIB With parametrial involvement but not up to the pelvic wall

Stage III:

The carcinoma involves the lower third of the vagina and/or extends to the pelvic wall and/or causes hydronephrosis or non-functioning kidney and/or involves pelvic and/or paraaortic lymph nodes[c]

- IIIA Carcinoma involves the lower third of the vagina, with no extension to the pelvic wall
- IIIB Extension to the pelvic wall and/or hydronephrosis or non-functioning kidney (unless known to be due to another cause)
- IIIC Involvement of pelvic and/or paraaortic lymph nodes, irrespective of tumor size and extent (with r and p notations)[c]
  - IIIC1 Pelvic lymph node metastasis only
  - IIIC2 Paraaortic lymph node metastasis

Stage IV:

The carcinoma has extended beyond the true pelvis or has involved (biopsy proven) the mucosa of the bladder or rectum. A bullous edema, as such, does not permit a case to be allotted to stage IV

- IVA Spread of the growth to adjacent organs
- IVB Spread to distant organs

Measurements on Path report

- All specimens taken into account
- DEPTH OF INVASION – deepest measurement in any one specimen
- Largest HORIZONTAL dimension – not needed for FIGO 2018 but should still report
  - Horizontal measurement in one slice
  - Number of consecutive blocks involved

DO NOT use term microinvasive carcinoma

Depth of invasion (DOI)

Base of epithelium where ca arises to deepest focus of invasion (whether continuous (B) or discontinuous (A & C)

D) If no obvious surface involvement - deepest focus to base of nearest non neoplastic epithelium

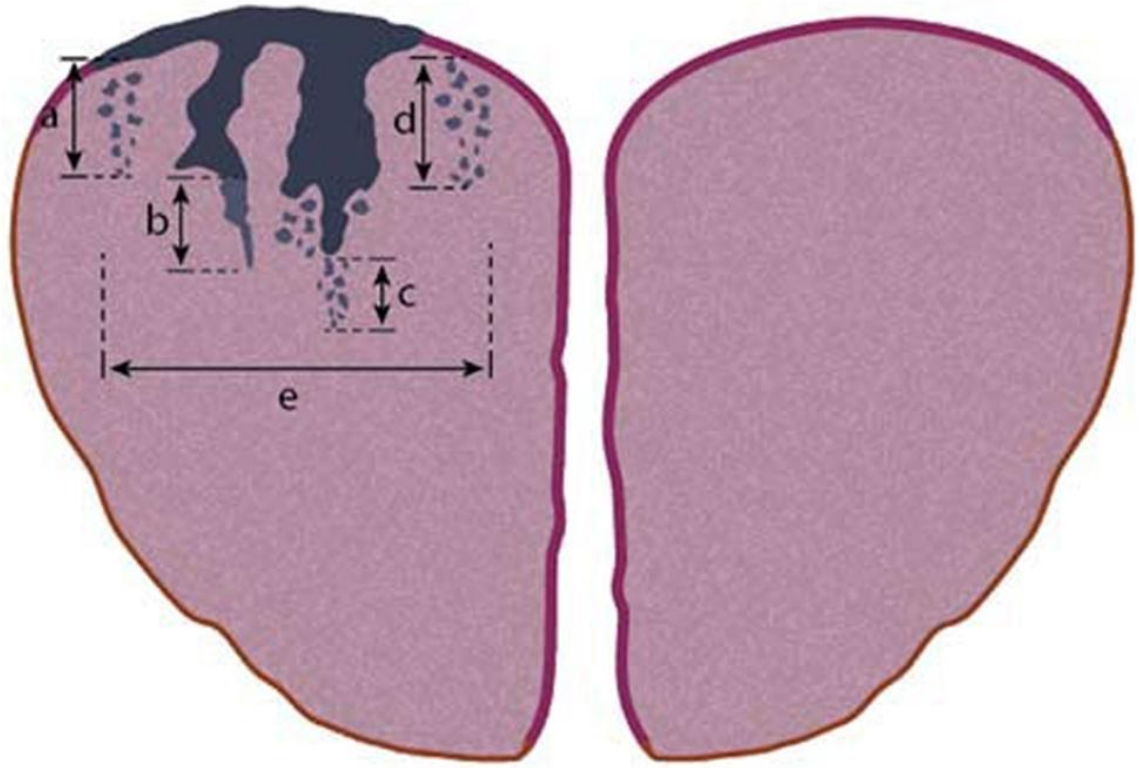

McCluggage WG, Judge MJ, Alvarado-Cabrero I, Duggan MA, Horn LC, Hui P et al. Data set for the reporting of carcinomas of the cervix: recommendations from the International Collaboration on Cancer Reporting (ICCR). Int J Gynecol Pathol 2018;37:205–228.

Example A

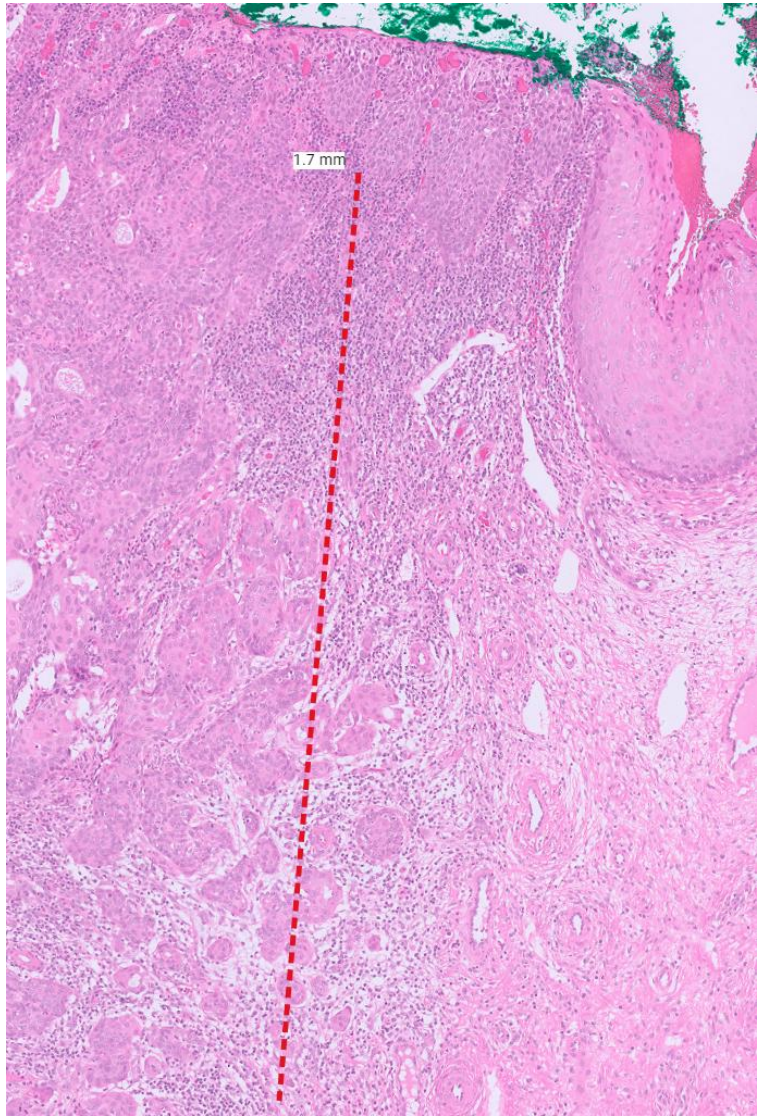

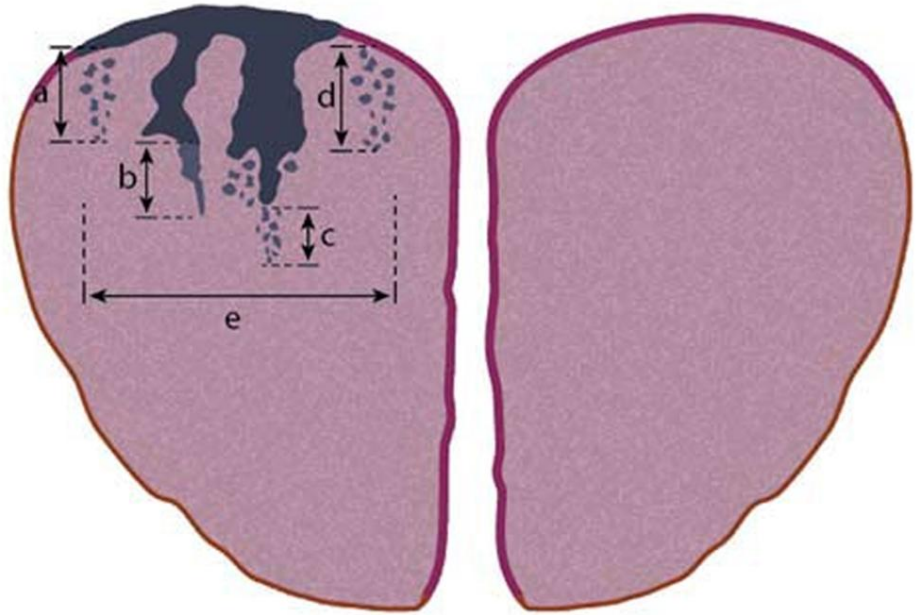

McCluggage WG, Judge MJ, Alvarado-Cabrero I, Duggan MA, Horn LC, Hui P et al. Data set for the reporting of carcinomas of the cervix: recommendations from the International Collaboration on Cancer Reporting (ICCR). Int J Gynecol Pathol 2018;37:205–228.

Example B

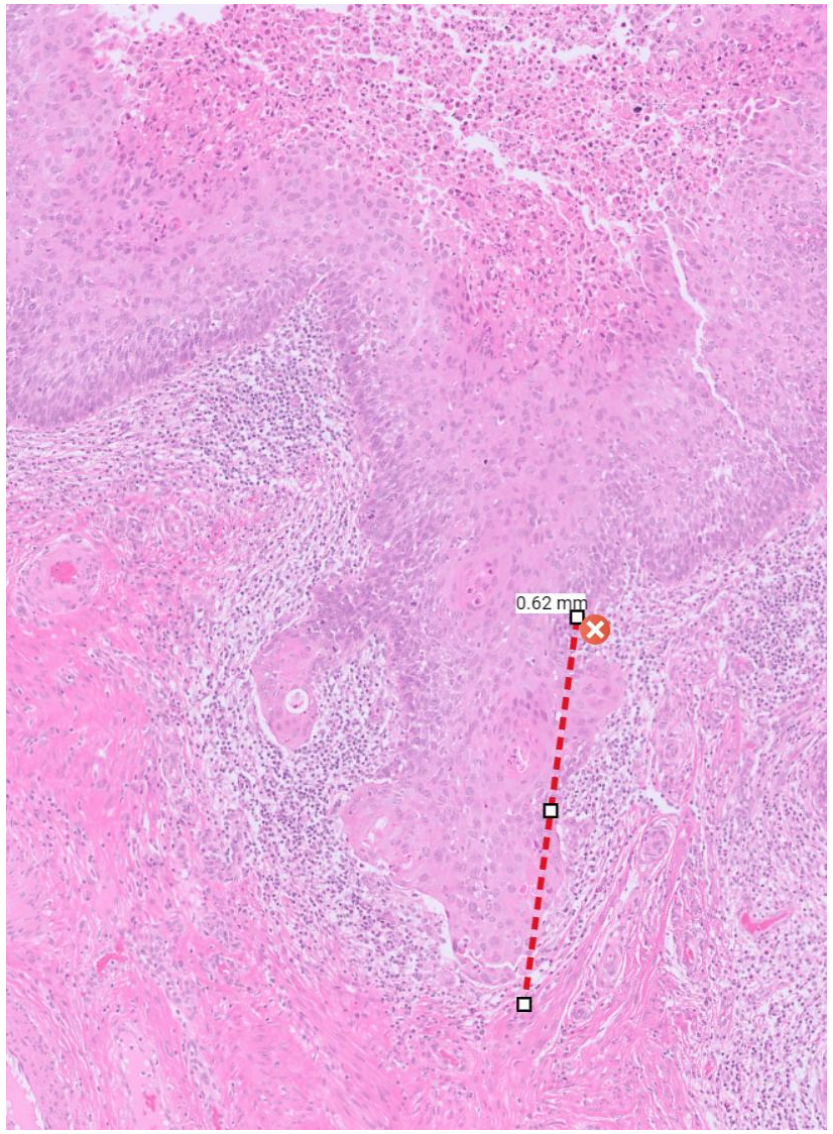

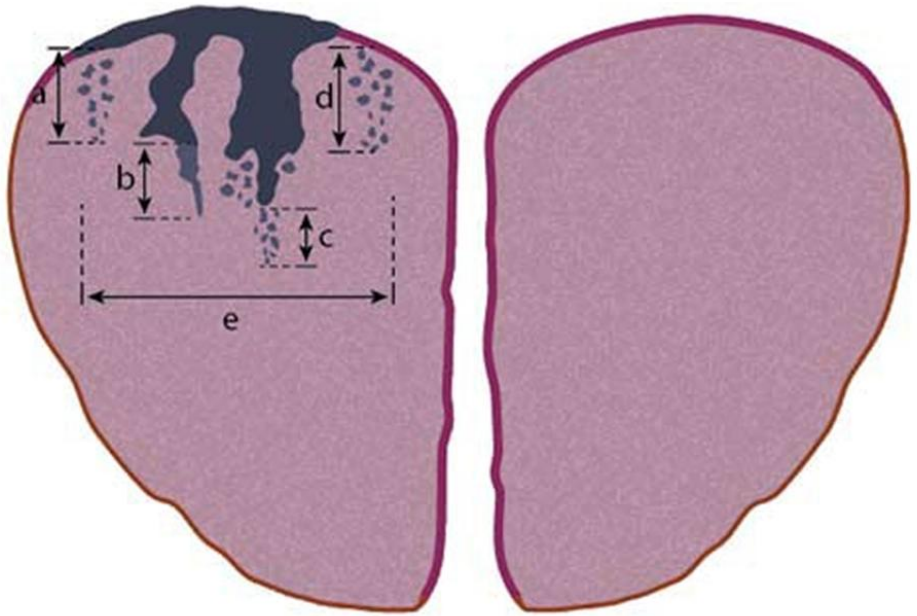

McCluggage WG, Judge MJ, Alvarado-Cabrero I, Duggan MA, Horn LC, Hui P et al. Data set for the reporting of carcinomas of the cervix: recommendations from the International Collaboration on Cancer Reporting (ICCR). Int J Gynecol Pathol 2018;37:205–228.

Example C

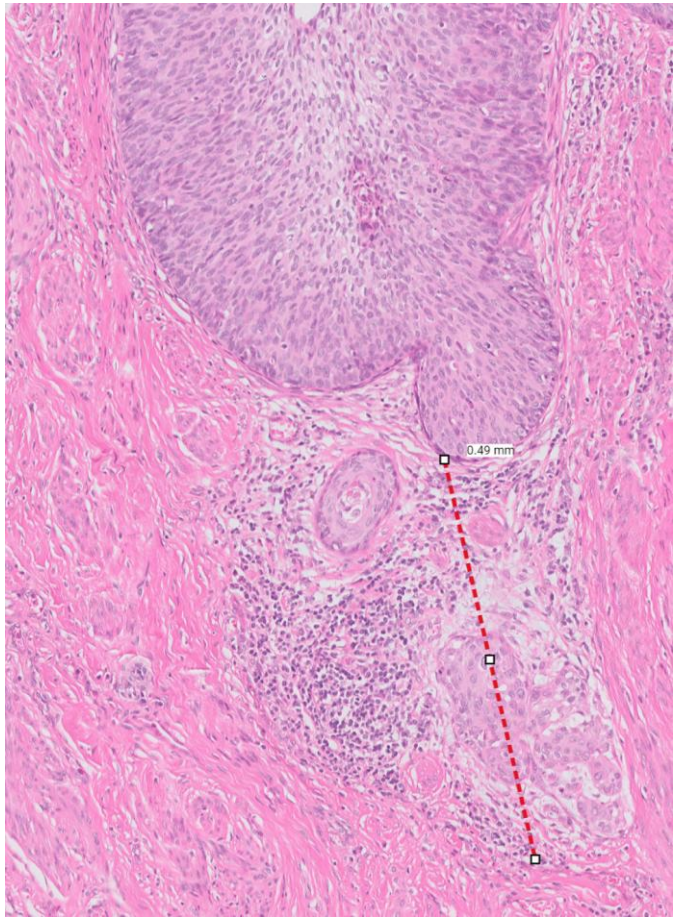

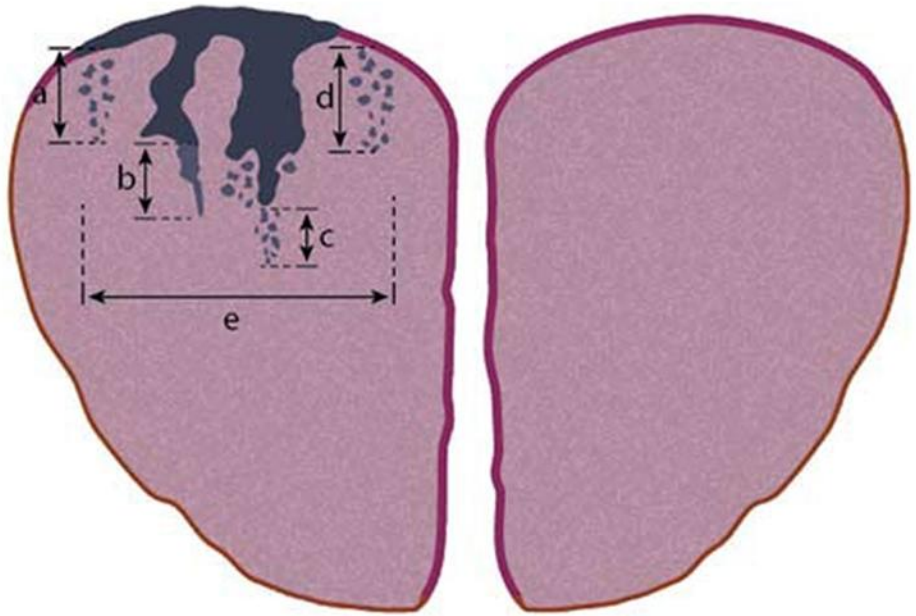

McCluggage WG, Judge MJ, Alvarado-Cabrero I, Duggan MA, Horn LC, Hui P et al. Data set for the reporting of carcinomas of the cervix: recommendations from the International Collaboration on Cancer Reporting (ICCR). Int J Gynecol Pathol 2018;37:205–228.

Example E – horizontal

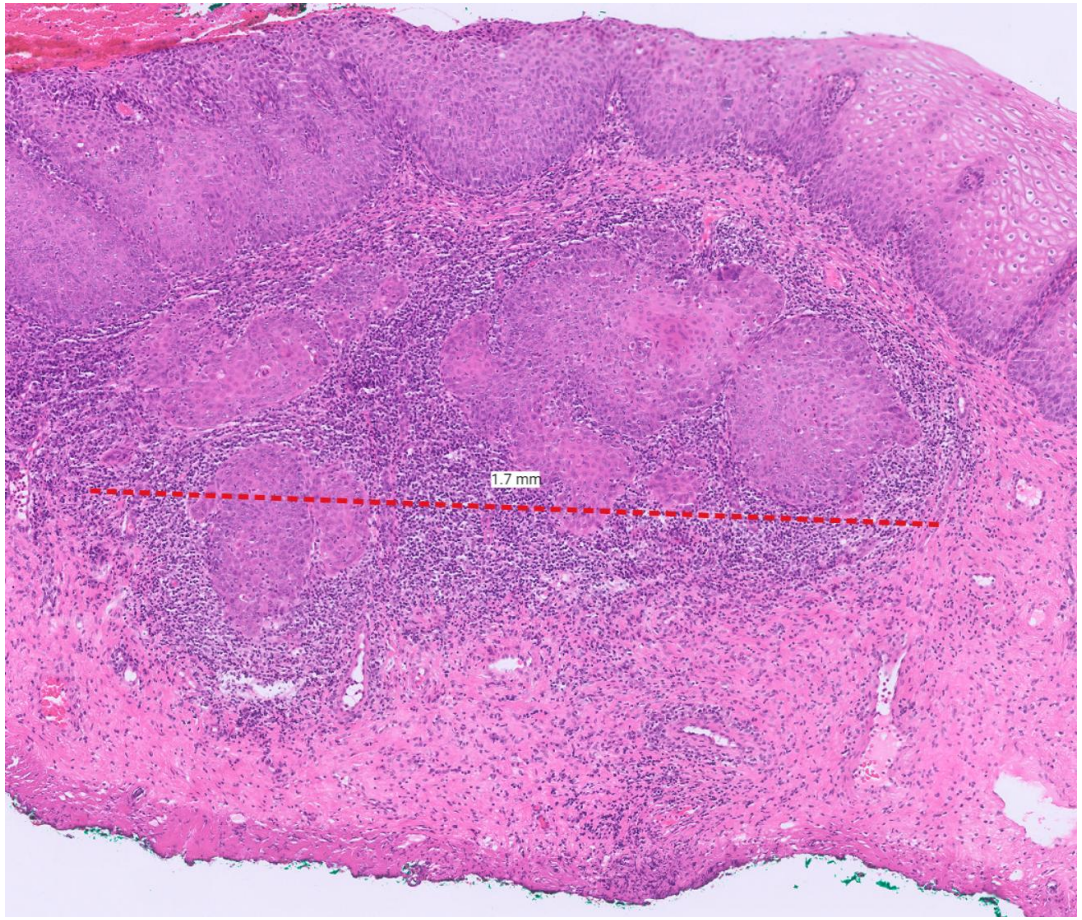

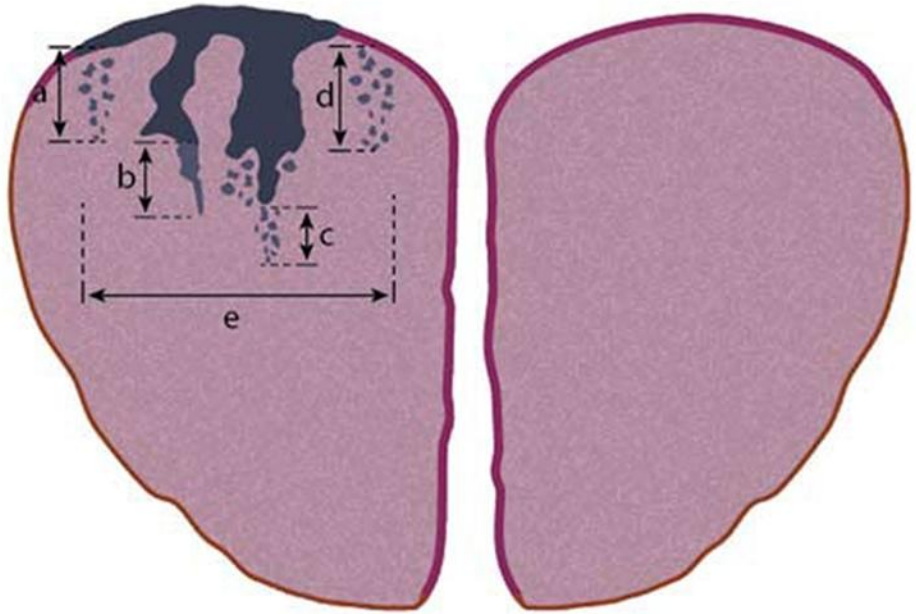

McCluggage WG, Judge MJ, Alvarado-Cabrero I, Duggan MA, Horn LC, Hui P et al. Data set for the reporting of carcinomas of the cervix: recommendations from the International Collaboration on Cancer Reporting (ICCR). Int J Gynecol Pathol 2018;37:205–228.

Example E horizontal

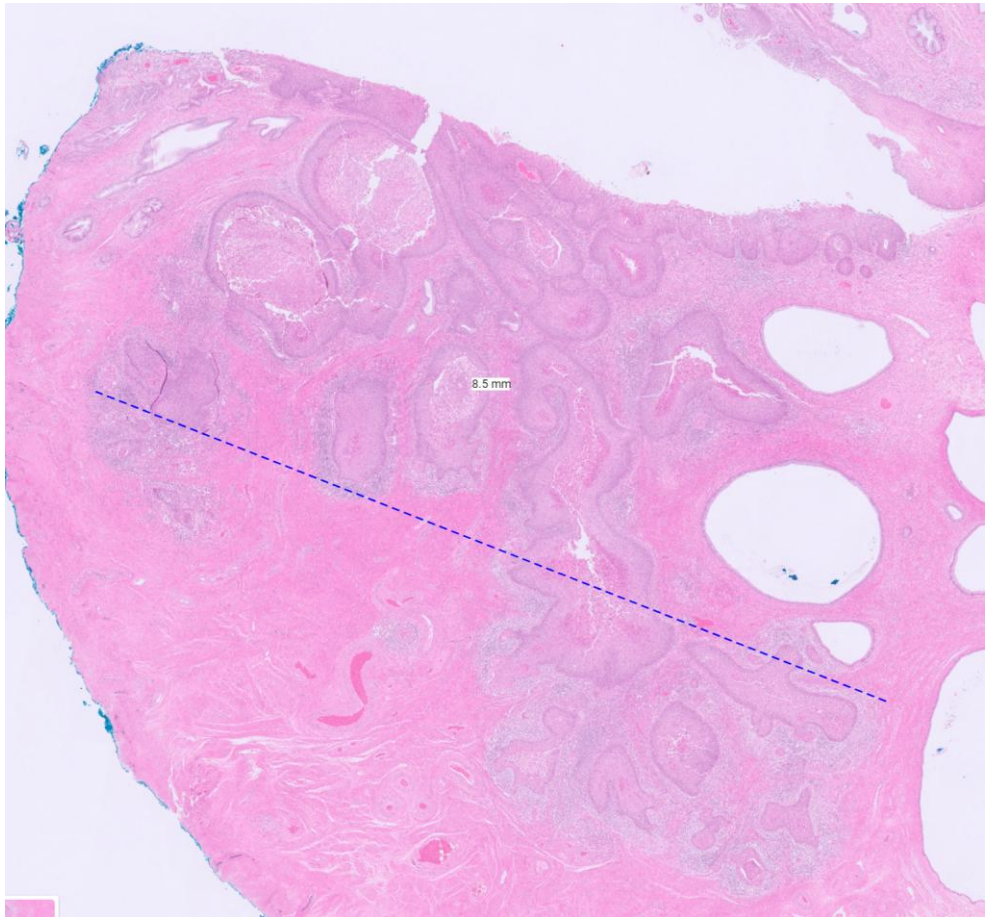

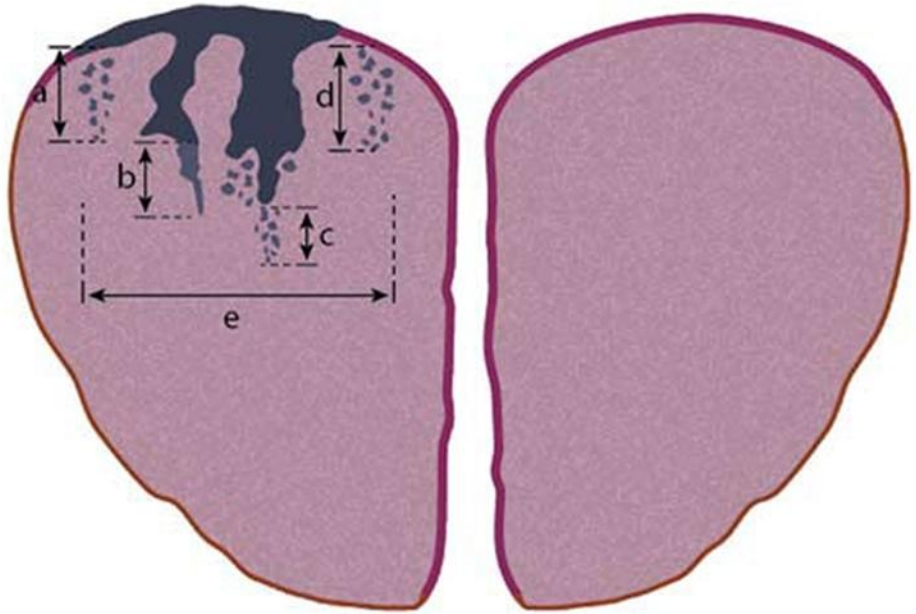

McCluggage WG, Judge MJ, Alvarado-Cabrero I, Duggan MA, Horn LC, Hui P et al. Data set for the reporting of carcinomas of the cervix: recommendations from the International Collaboration on Cancer Reporting (ICCR). Int J Gynecol Pathol 2018;37:205–228.

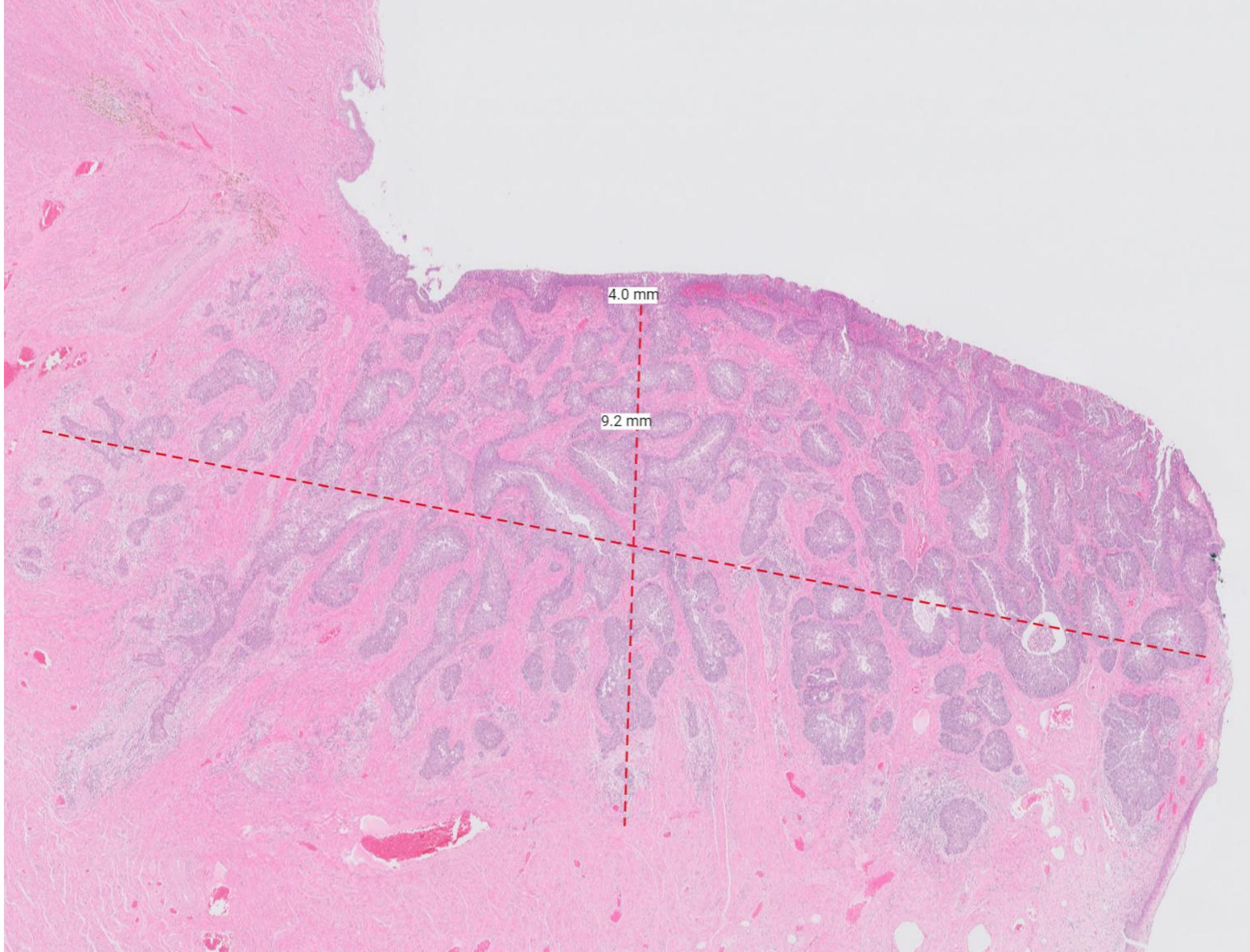
4.0 mm
9.2 mm

Tumour thickness

- Polypoid/exophytic
- Glandular lesions
- Ulceration
- Explanation in report – management based on largest dimension

Horizontal size

- In one block - measure across all foci of invasion from edge to edge (even if some small areas where no invasion)
- No of sequential blocks involved (2.5-3mm depending on trim)

Figure 3: Measurement of cervical tumours in three dimensions.

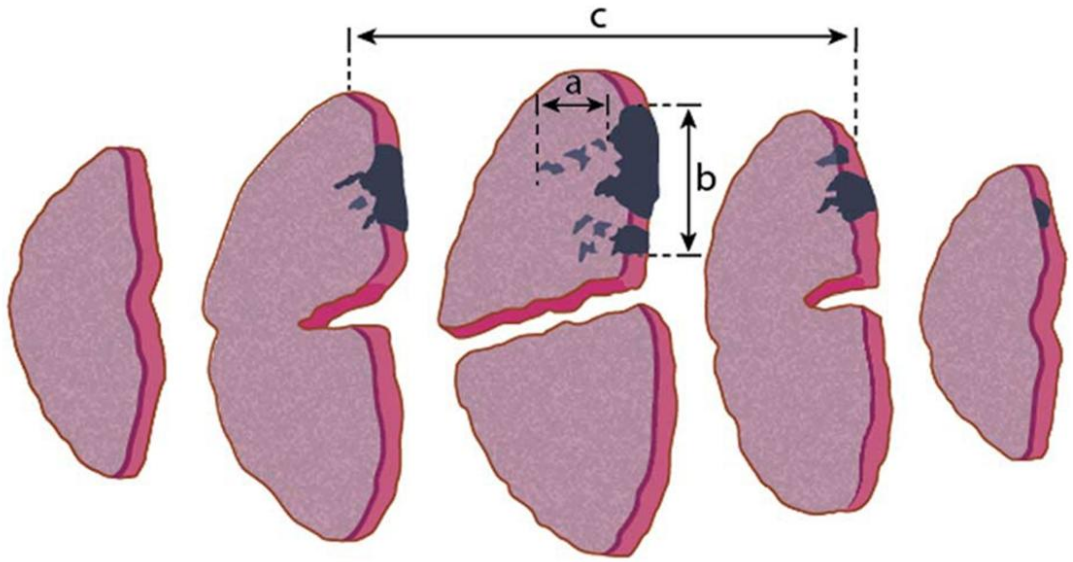

McCluggage WG, Judge MJ, Alvarado-Cabrero I, Duggan MA, Horn LC, Hui P et al. Data set for the reporting of carcinomas of the cervix: recommendations from the International Collaboration on Cancer Reporting (ICCR). Int J Gynecol Pathol 2018;37:205–228.

Multifocality

- Up to 25% of cases
- Now less of an issue with FIGO 2018
  - Often superficial tumours
- Criteria
  - Blocks of uninvolved cervical tissue between foci
  - Separate cervical lips
  - Far apart in same section (arbitrary 2mm)
  - Levels may be required to check definitely multifocal

PATHOLOGY OF THE LOWER GENITAL TRACT: ORIGINAL ARTICLES

Multifocal FIGO Stage IA1 Squamous Carcinoma of the Cervix: Criteria for Identification, Staging, and its Good Clinical Outcome

Day, Elizabeth M.B., B.Chir., Ph.D.; Duffy, Siobhan B.Sc., M.B.Ch.B.; Bryson, Gareth B.Sc., M.B.Ch.B., F.R.C.Path.; Syed, Sheeba M.B.B.S., M.D., M.R.C.Path.; Shanbhag, Smruta M.B.B.S., M.R.C.O.G.; Burton, Kevin M.B.C.H.B., M.D., M.R.C.O.G.; Lindsay, Rhona B.Sc., M.B.Ch.B., M.R.C.O.G.; Siddiqui, Nadeem F.R.C.O.G., Ph.D.; Millan, David B.Sc., M.B., Ch.B., F.R.C.Path.

Author Information

International Journal of Gynecological Pathology 35(5):p 467-474, September 2016. | *DOI:* 10.1097/PGP.0000000000000269

Consistency of measurement

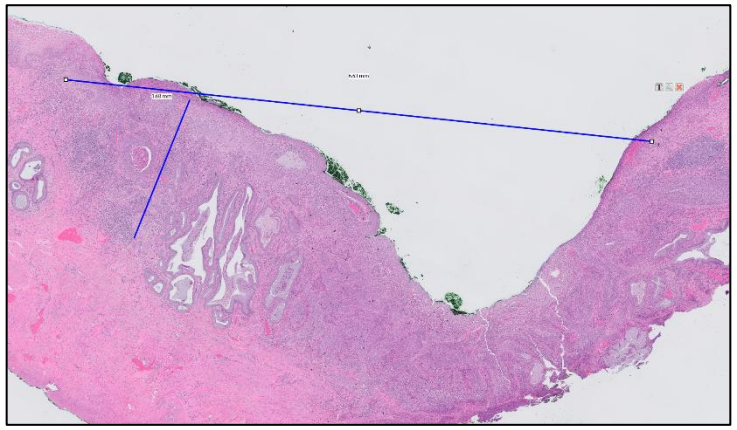

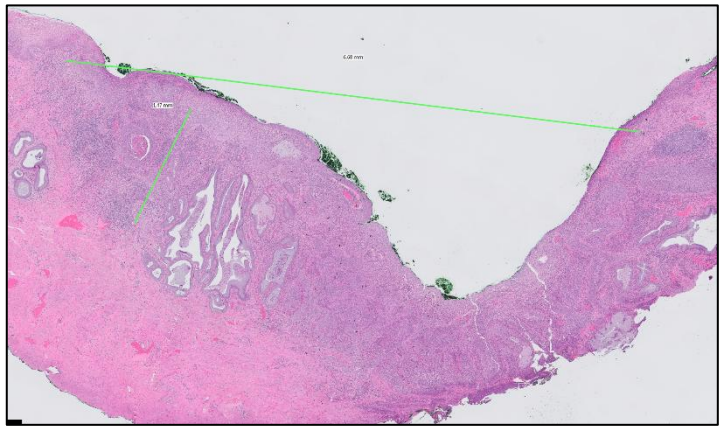

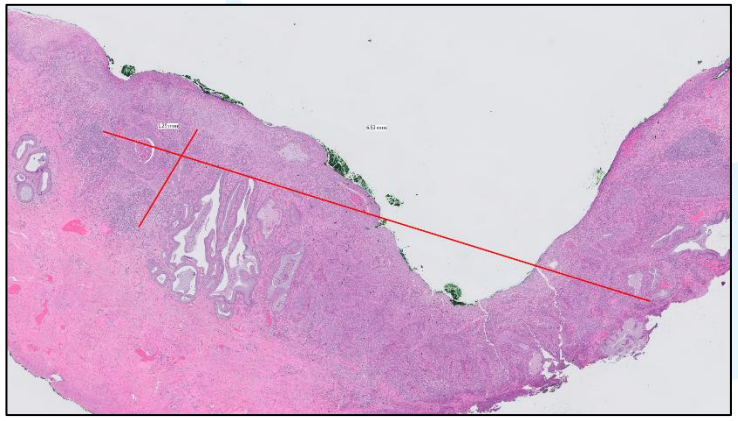

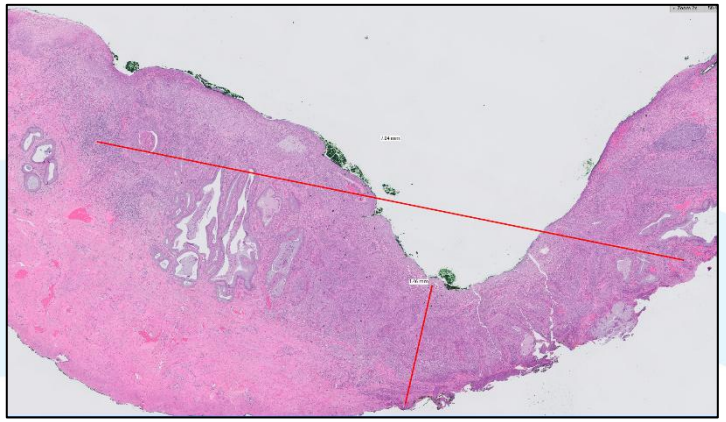

Pathologist	Horizontal	Depth of invasion
Pathologist 1	6.63	**1.68**
Pathologist 2	6.53	**1.29**
Pathologist 3	6.68	**1.47**
Pathologist 4	7.04	**1.46**

Source of variation

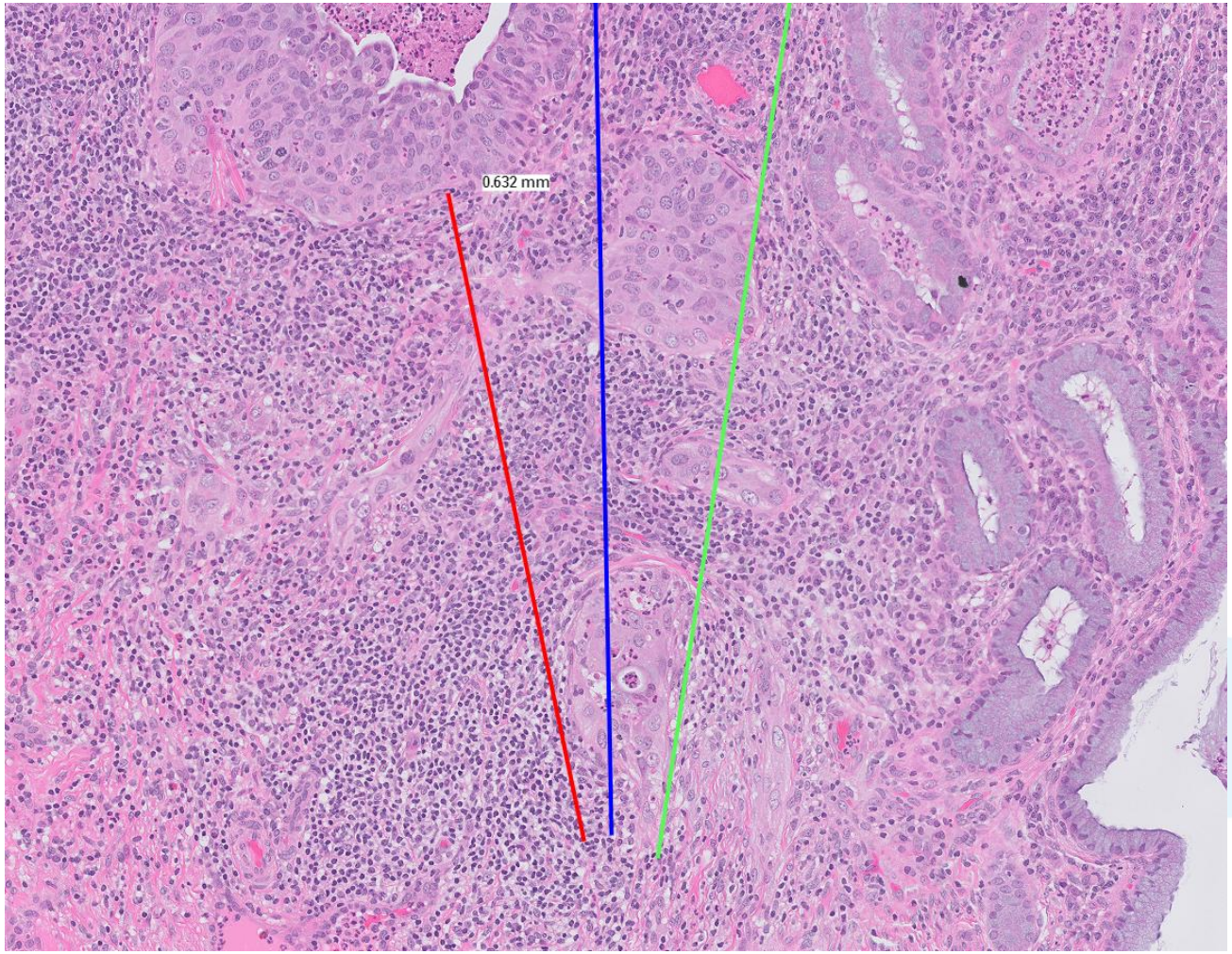

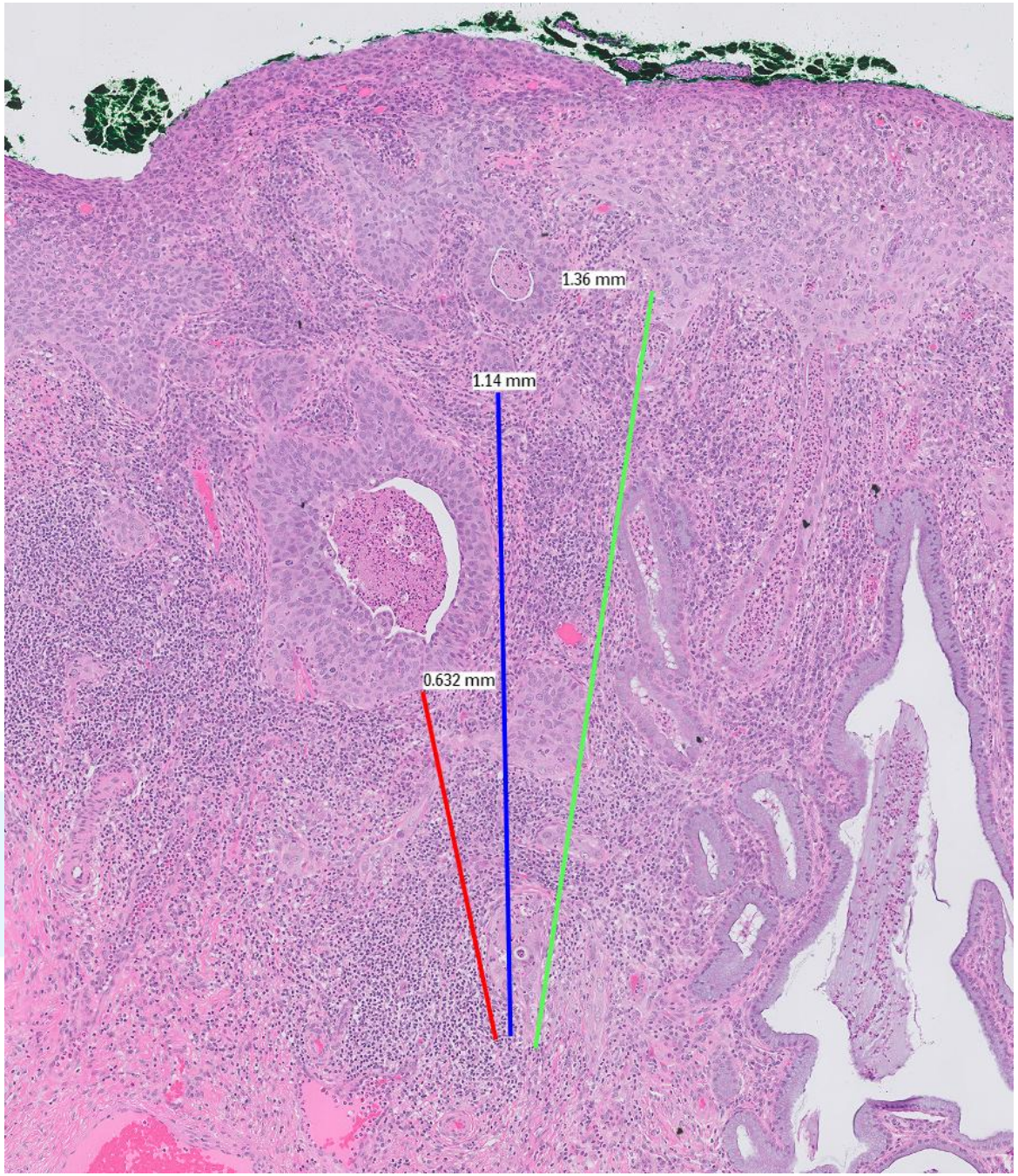

Digital Pathology

- *Digital tools allow for better capture/recording of measurements and areas*
- *Pseudo-volumetric assessment is possible from the aggregation of area from multiple involved sections*

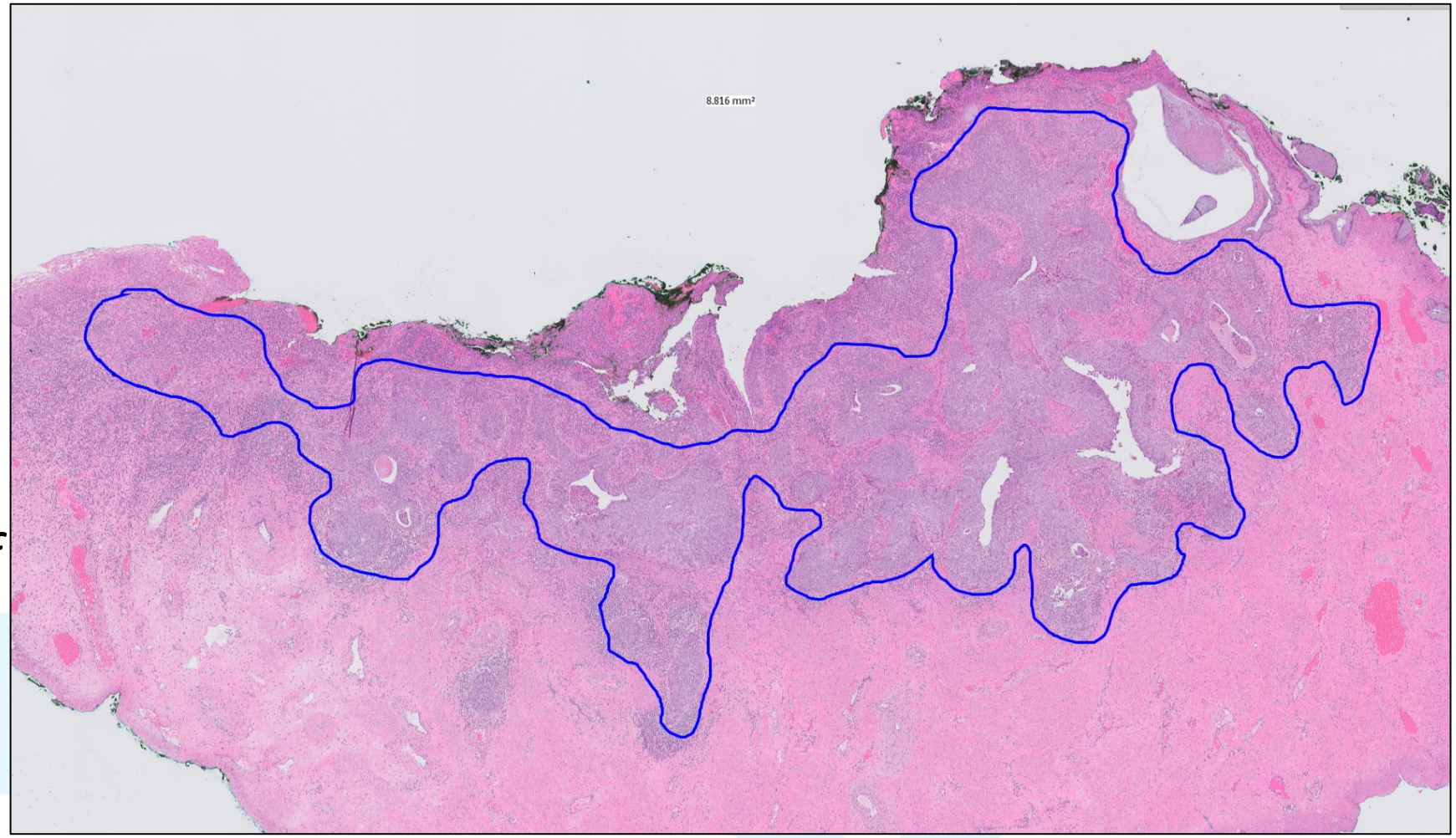

Multiple specimens - how to add together

- DOI – take the maximum in any one specimen (i.e. don’t add together!)
- Horizontal – add together (but may overestimate)
- MDT discussion/agreement

LLETZ

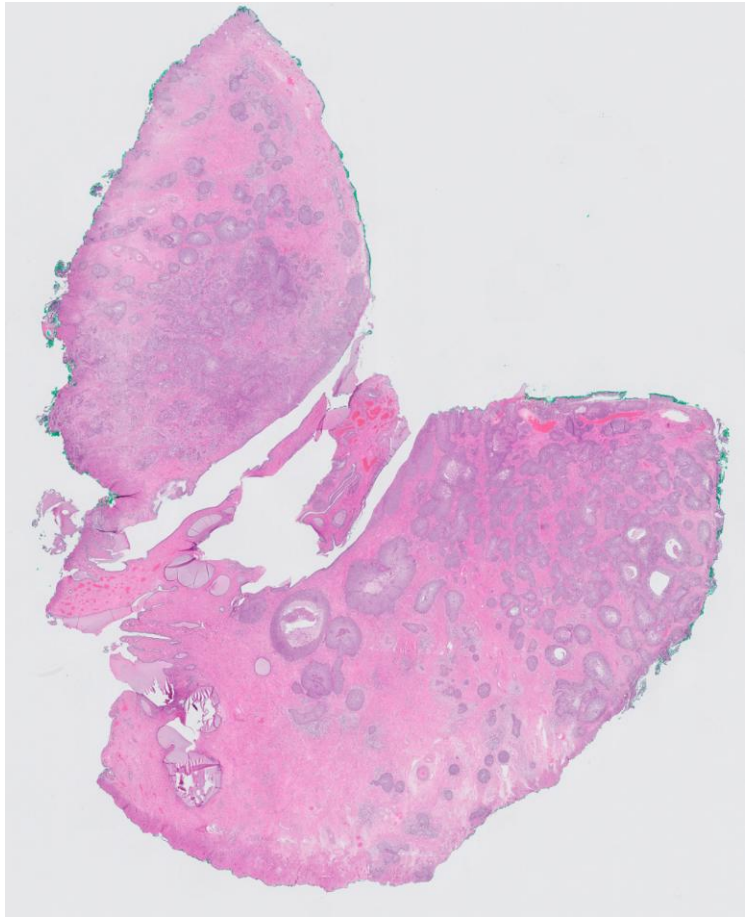

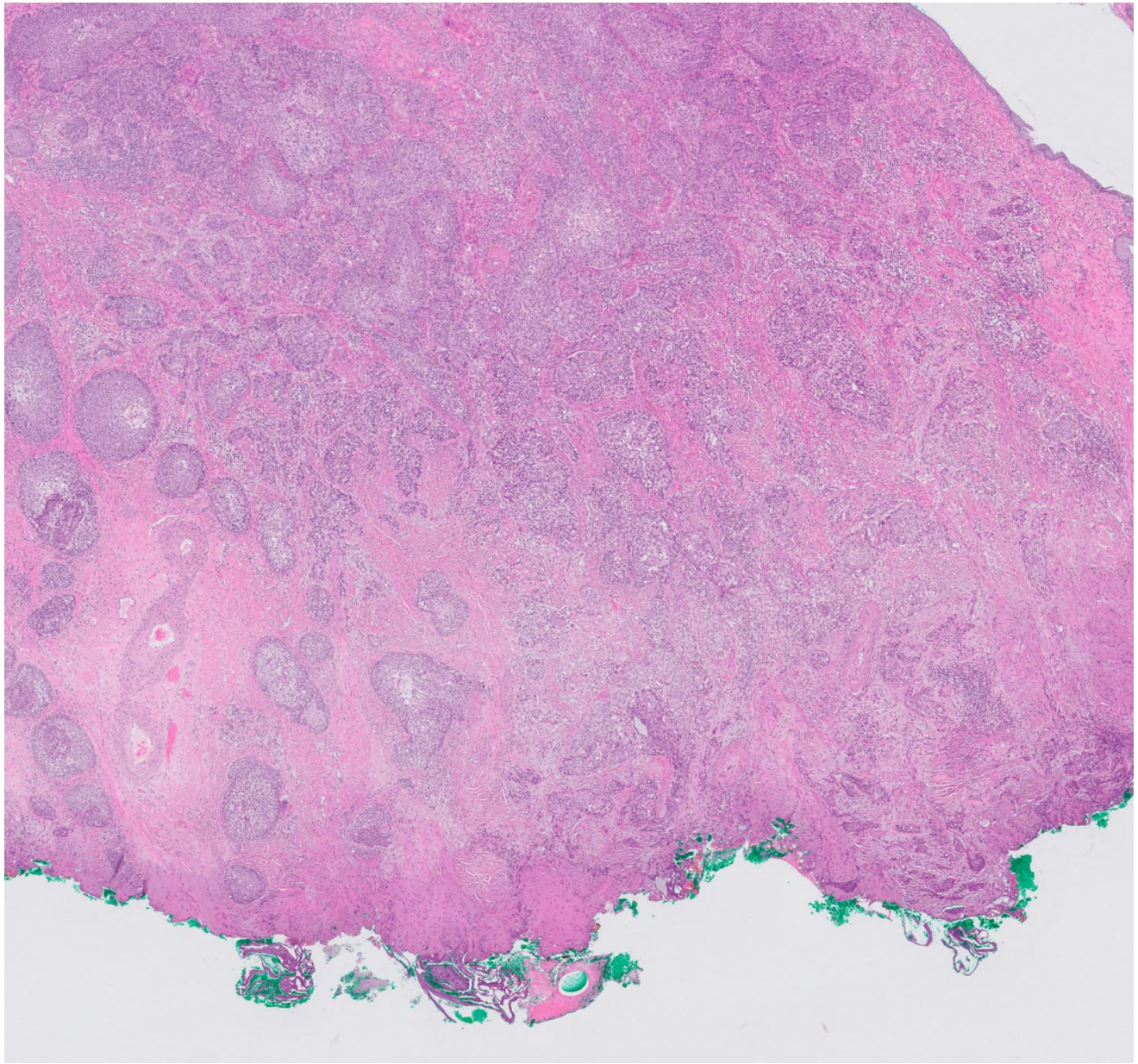

Completion hysterectomy

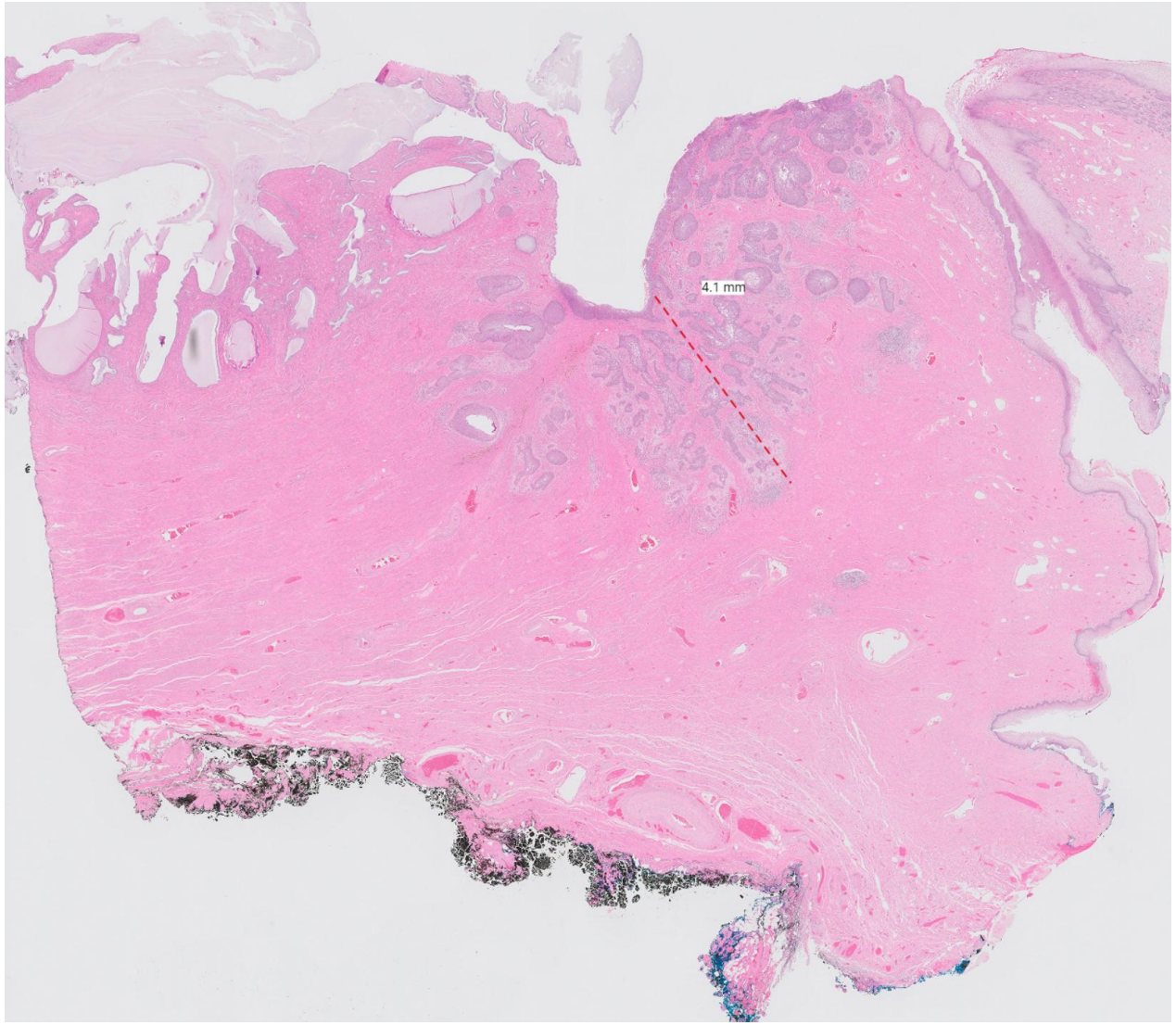

Margin involvement - LLETZ

- FIGO (2018) – 1B1 but not given in tabulated criteria

PRACTICAL APPROACH:

- ‘at least’ measurements
- Provisional stage (at least)
- Correlate all specimens/imaging/clinical where possible

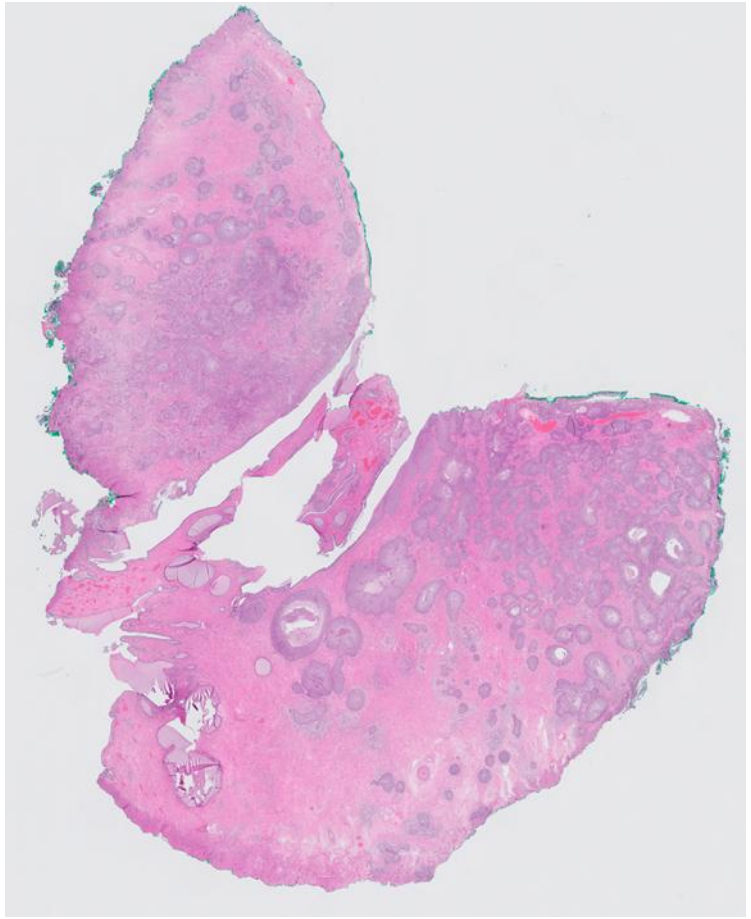

The British Association of Gynaecological Pathologists

2018 FIGO Staging System for Cervical cancer
Summary and comparison with 2009 FIGO Staging System

Authors: Naveena Singh[1], Brian Rous[2], Raji Ganesan[3]
[1]Barts Health NHS Trust, [2]Cambridge University Hospitals NHS Trust, [3]Birmingham Women's Hospital, UK

Updated by: Raji Ganesan[3], Glenn McCluggage[4]
[4]Belfast Health and Social Care Trust, Belfast, UK

- ***Although it is stated in the FIGO document that if the margins of the cone biopsy are positive for invasive cancer with a tumour with dimensions of a IA carcinoma, the patient is assigned to IB1, in practice in the event that the margins of a cone/ loop biopsy are positive for disease, a repeat cone/ loop biopsy is required to stage the patient.***

Summary

- SCC – classify as HPV associated or independent
- Levels, levels, levels
- DOI for FIGO 2018 (but still give horizontal measurements)
- Margin involvement in LLETZ