The British Association of Gynaecological Pathologists

Lecturer – Dr Kat Vroobel

Kat Vroobel is a consultant histopathologist specialising in gynaecological pathology and haematopathology at the Royal Marsden Hospital. She reports almost exclusively oncological specimens and experiences a high proportion of complex cases as a result. Her interests include uterine mesenchymal tumours and high grade/ambiguous endometrial carcinomas. She has published on a range of topics and contributed to the RCPath Dataset for carcinomas of the ovaries, fallopian tubes and peritoneum. She enjoys teaching at a local and national level and is Educational Lead for the department.



The British Association of Gynaecological Pathologists

Everyday Dilemmas in Gynaecological Pathology

- When smooth muscle tumours don’t read the books…
- Katherine Vroobel
- The Royal Marsden NHS Foundation Trust
- 7th March 2025

The British Association of Gynaecological Pathologists

Speaker disclosures

I have no financial conflicts of interest to disclose

Case 1

- 40F
- Open myomectomy for suspicious looking intramural and subserosal degenerating fibroid, omentum and bladder attachment.
- Pedunculated fibroid increasing in size on imaging, arising from uterine fundus.

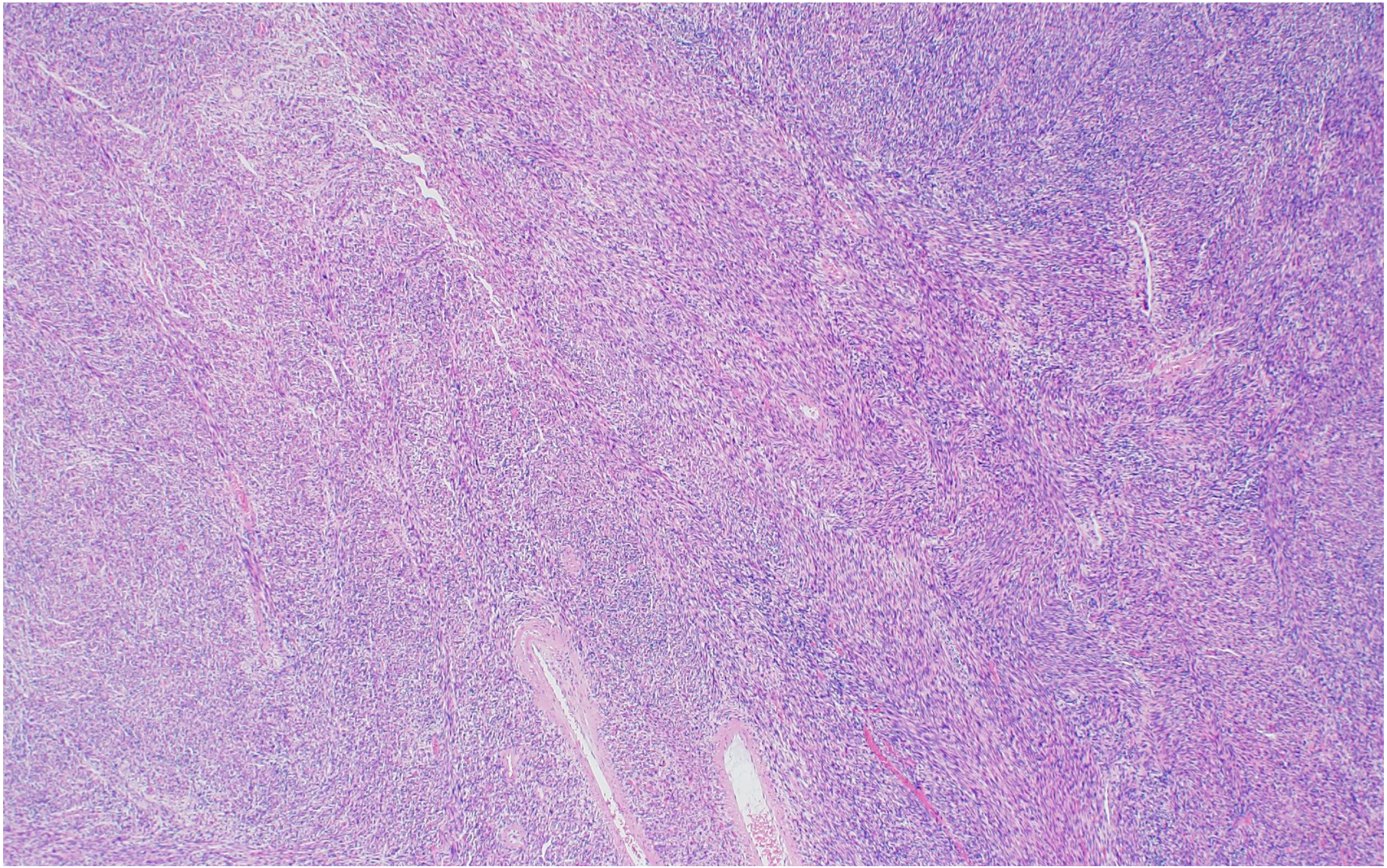

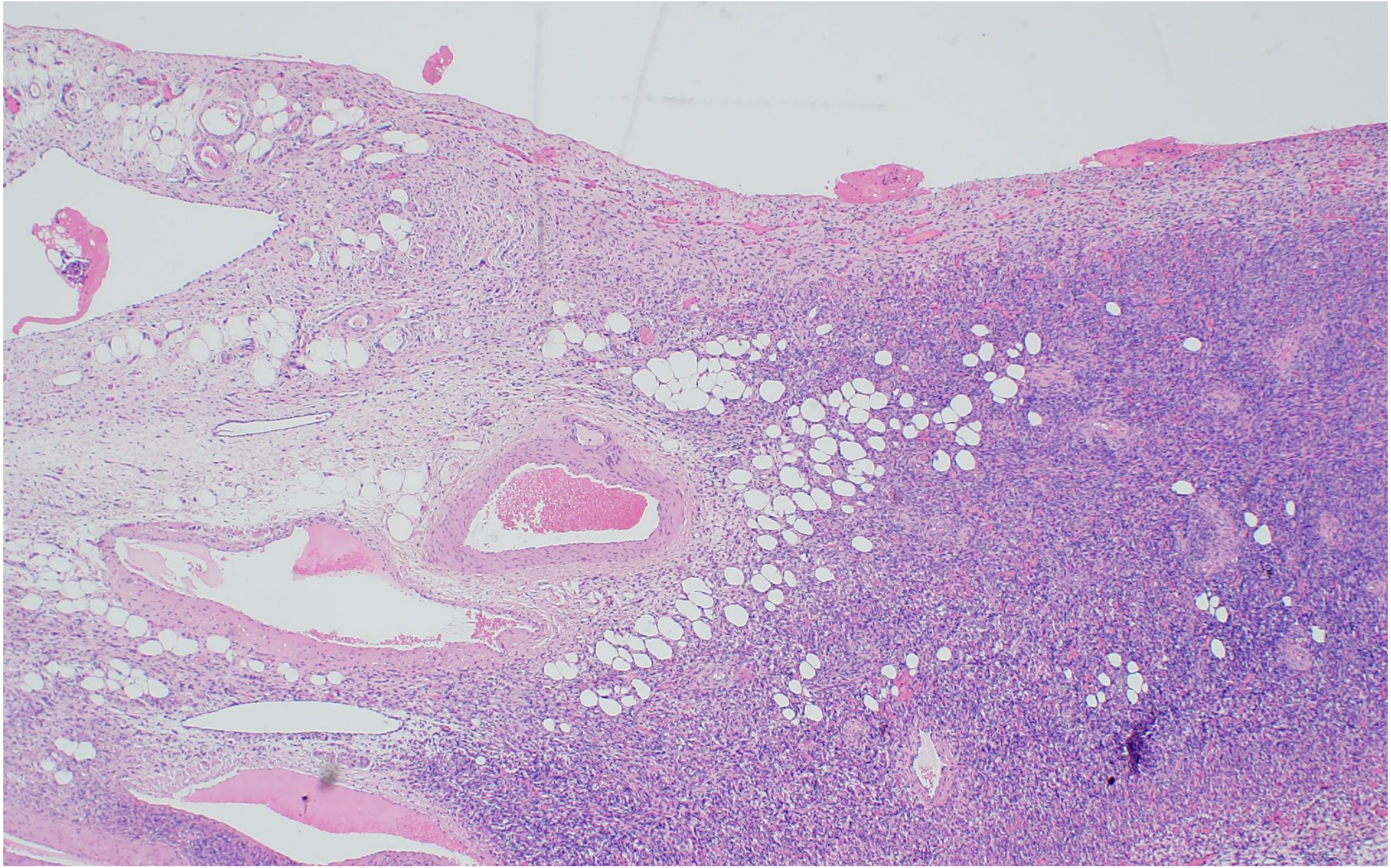

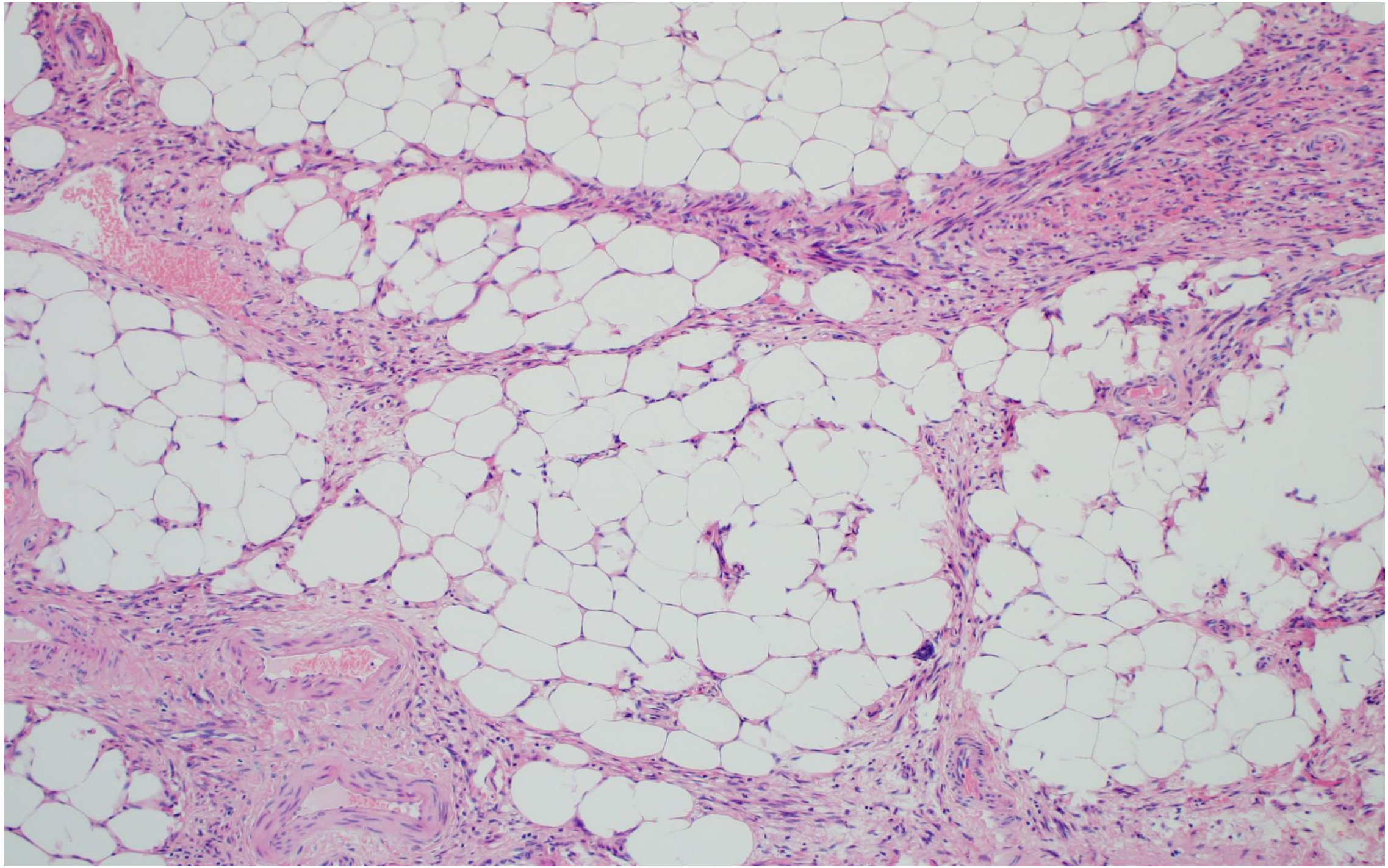

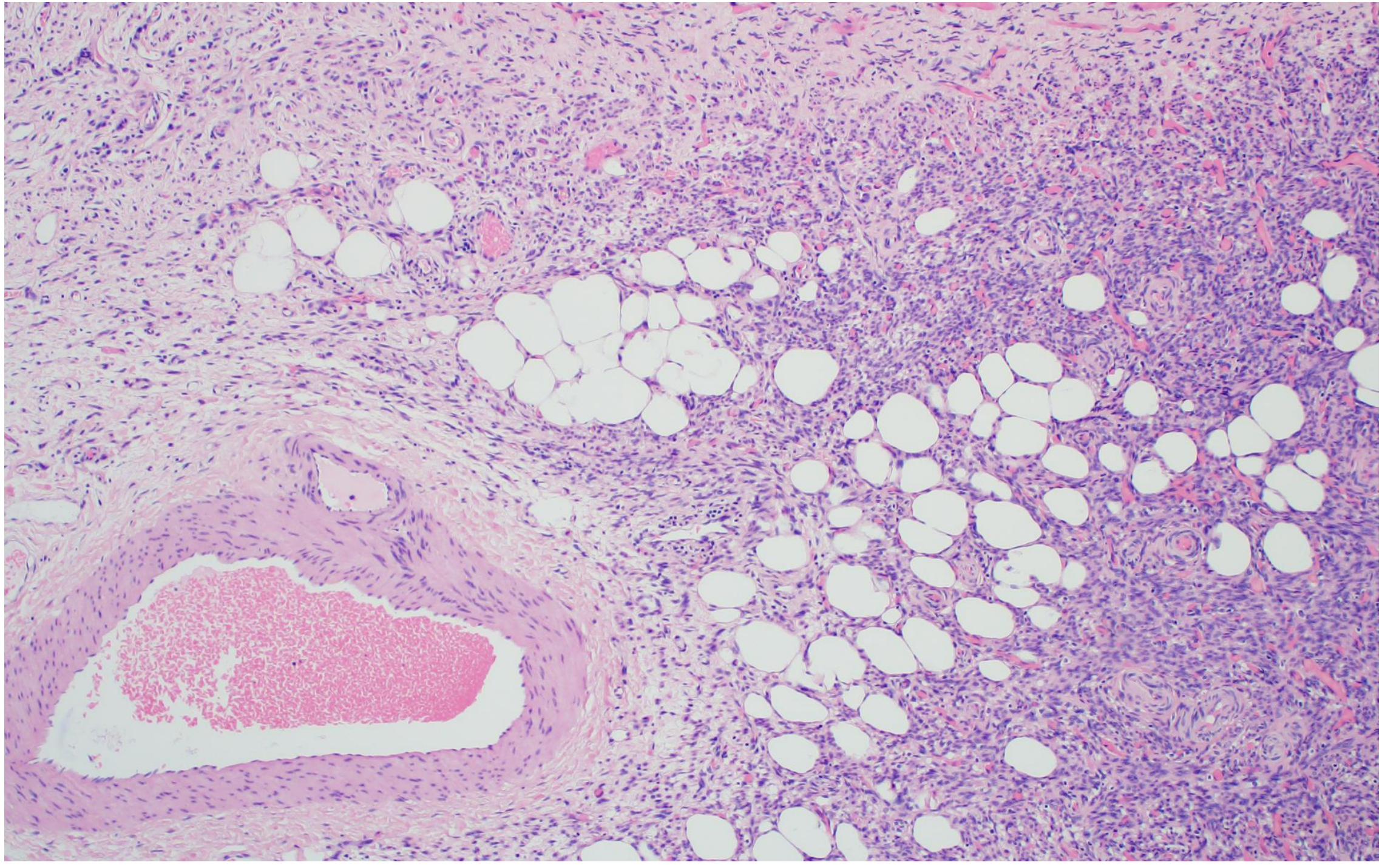

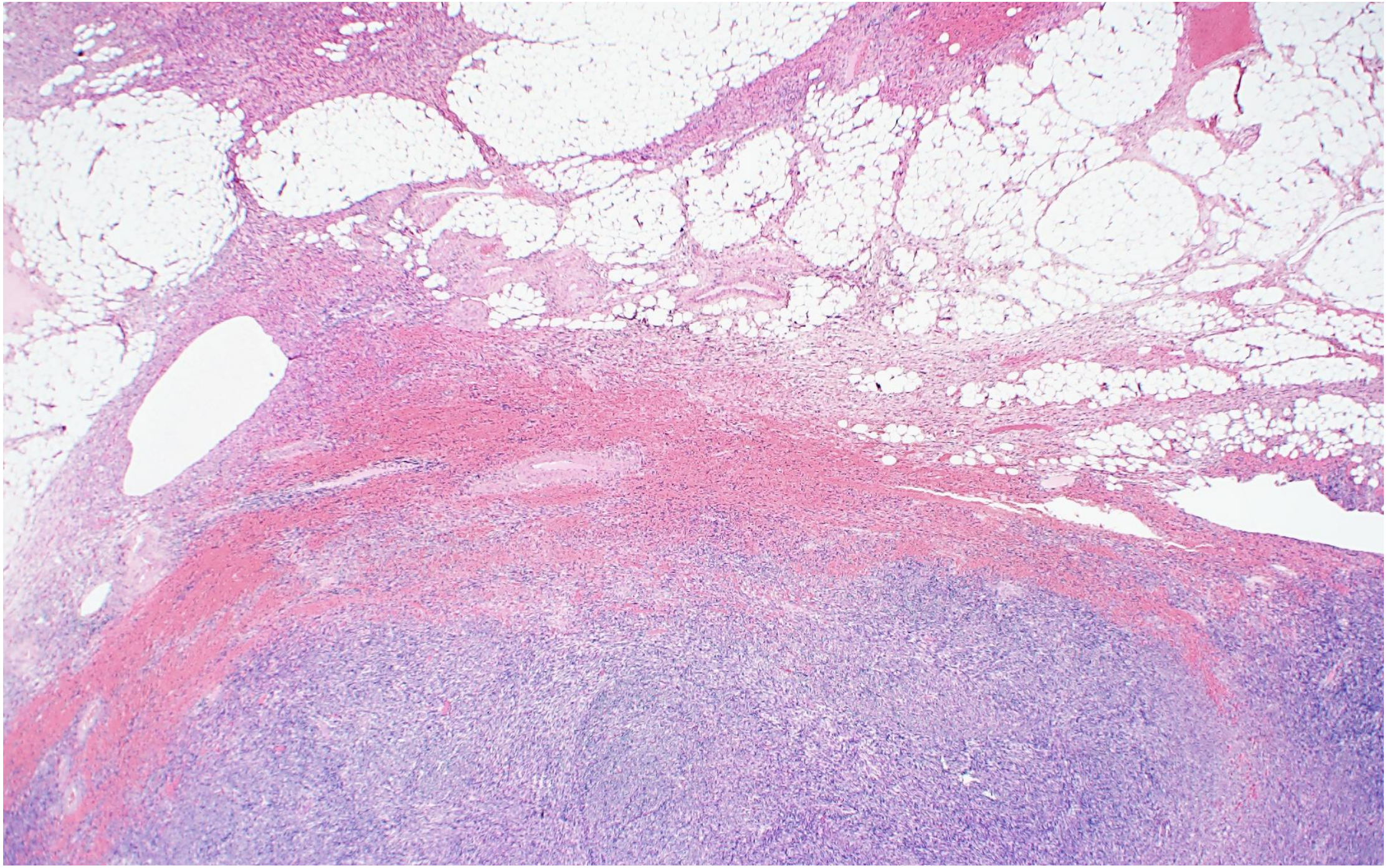

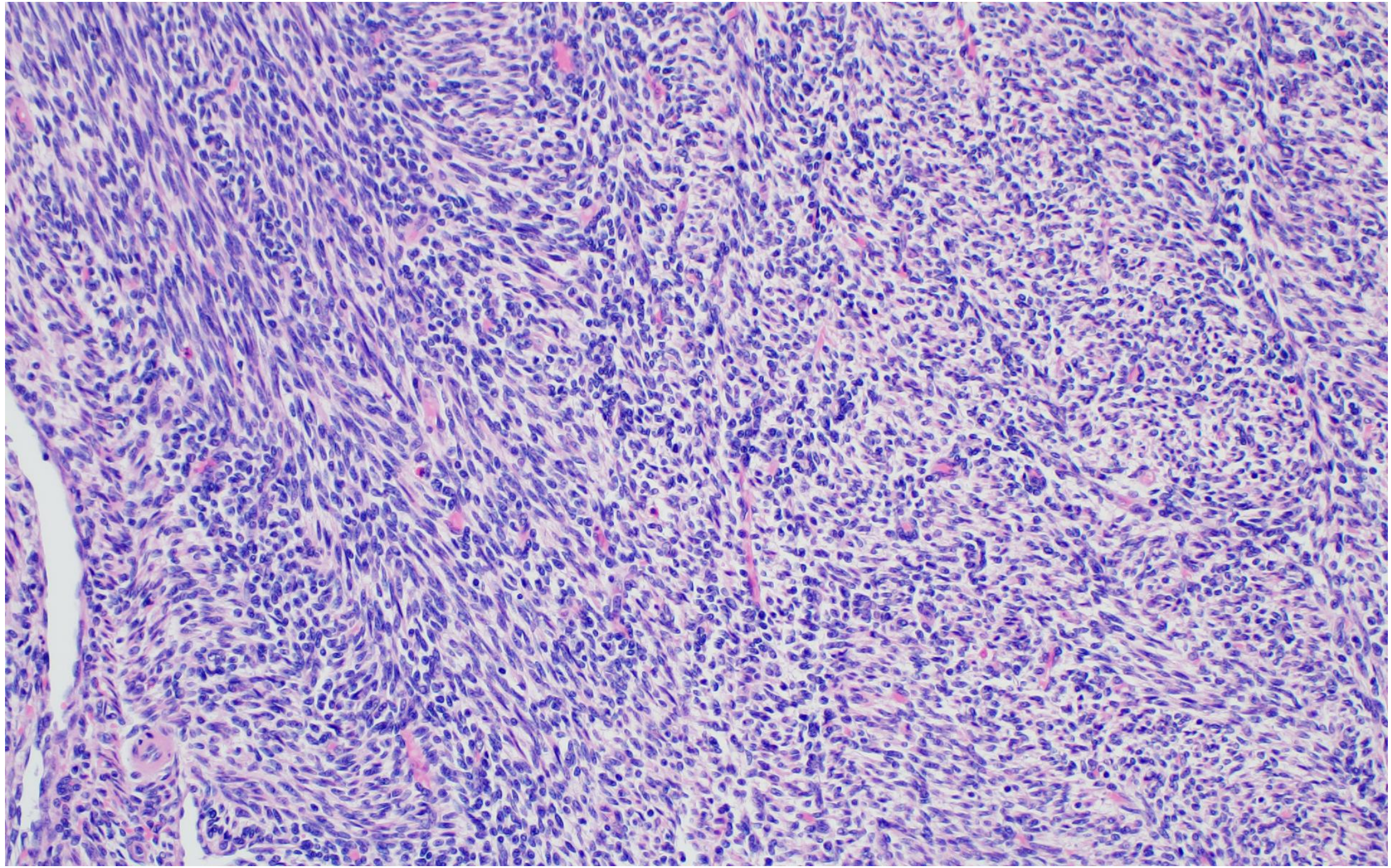

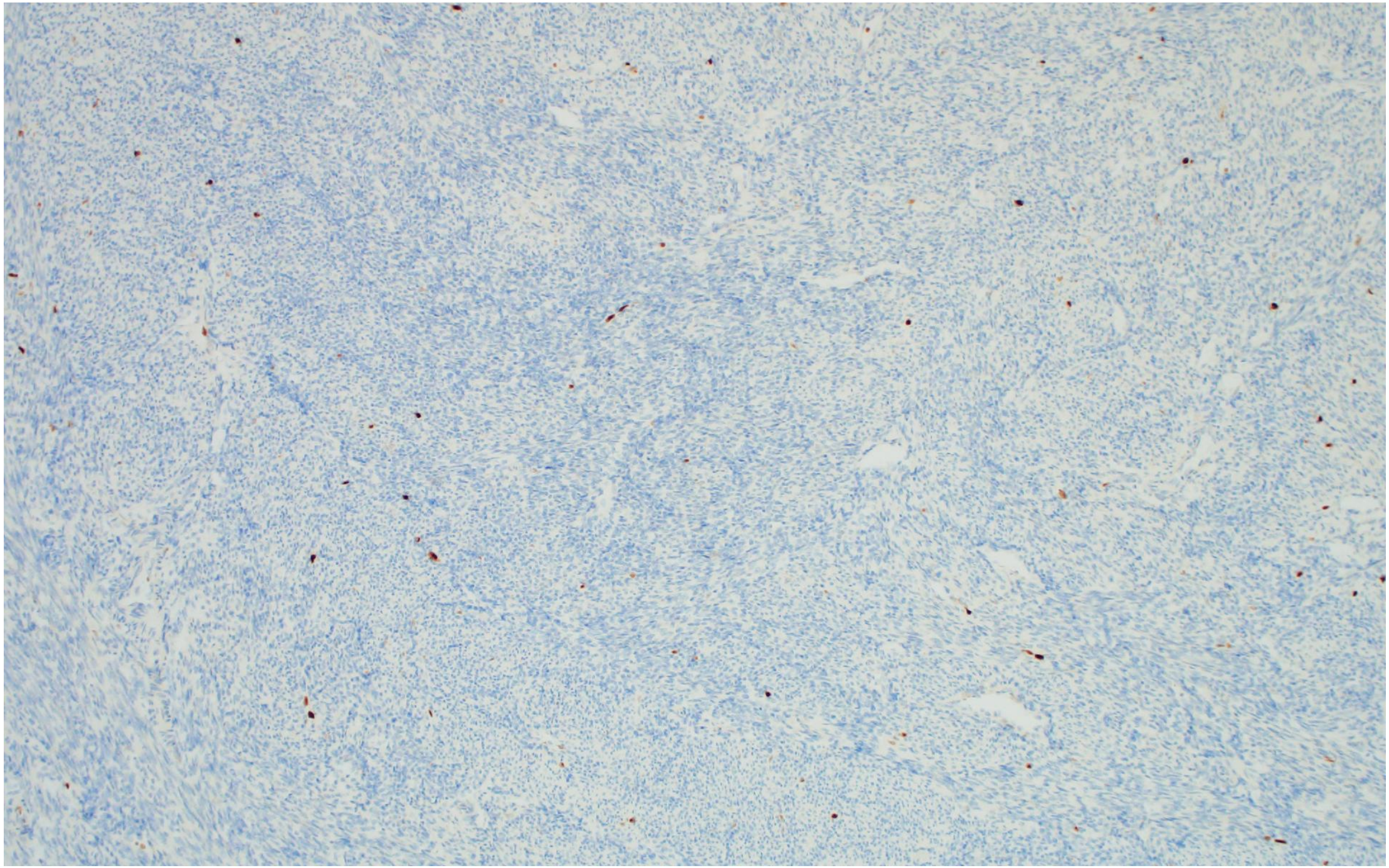

Case 2

- 58F
- Large pelvic mass, biopsy leiomyoma
- At operation, vaginal and rectosigmoid involvement, worrying for malignancy
- History of subtotal hysterectomy in 2017 for ?benign fibroids

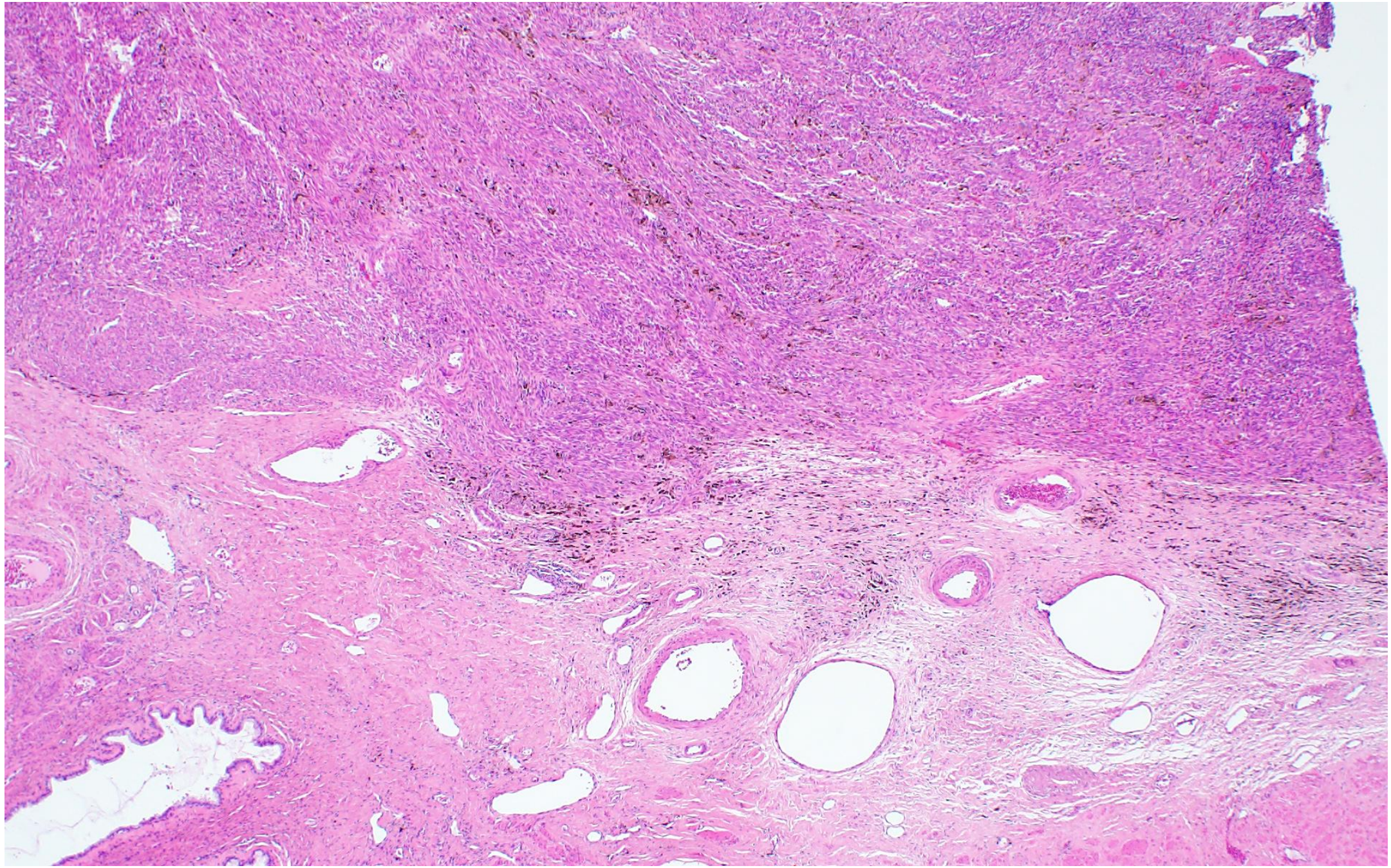

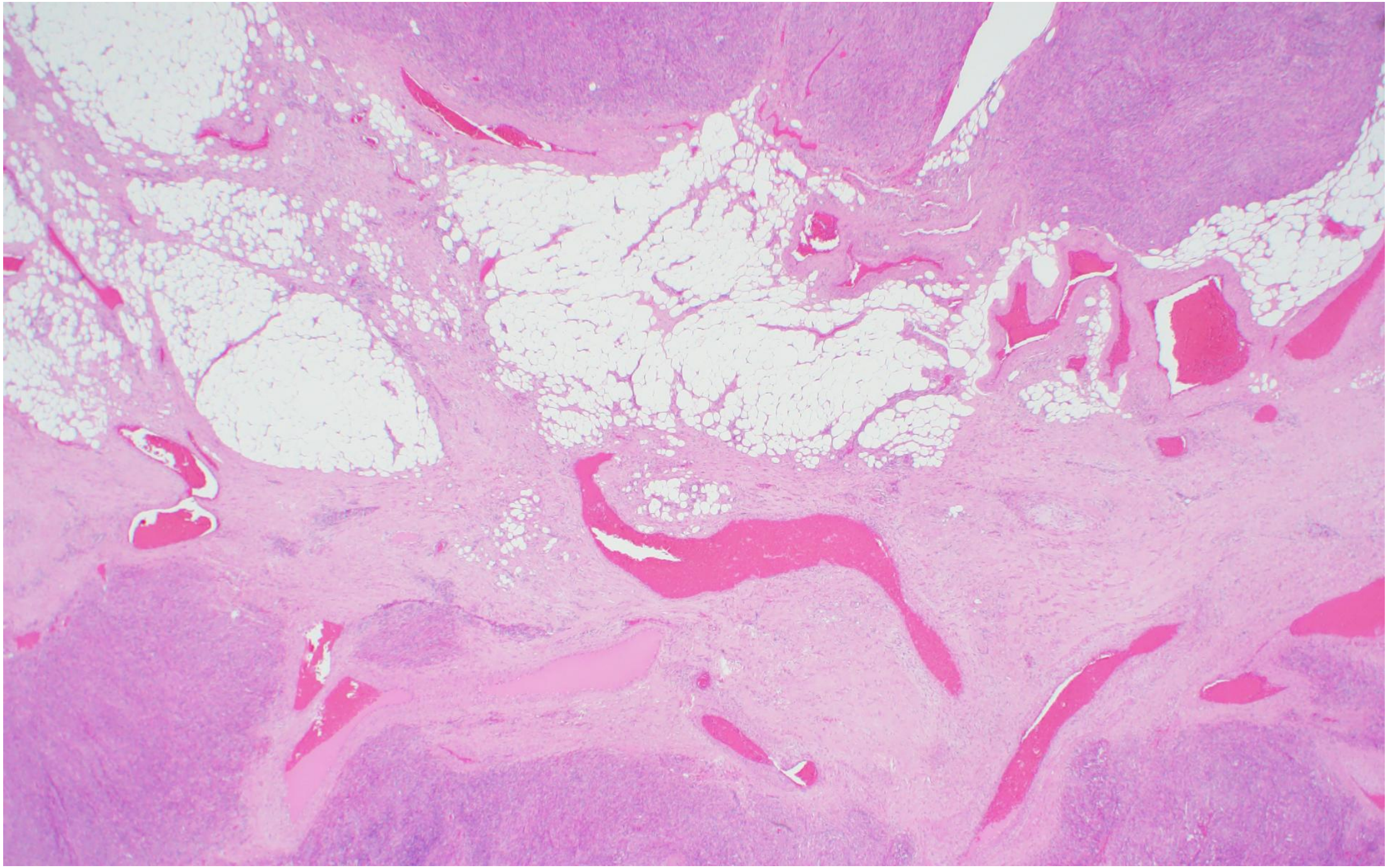

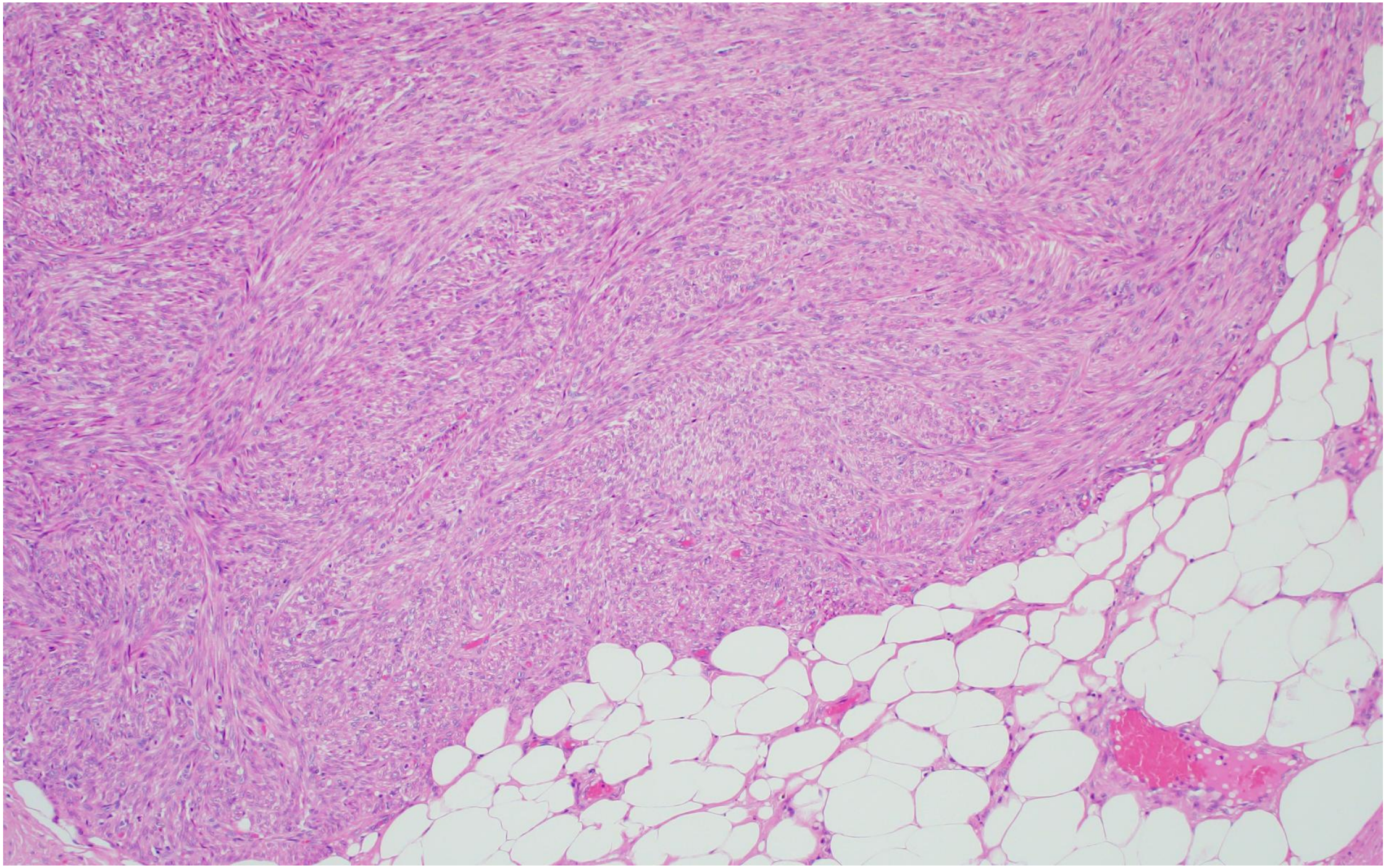

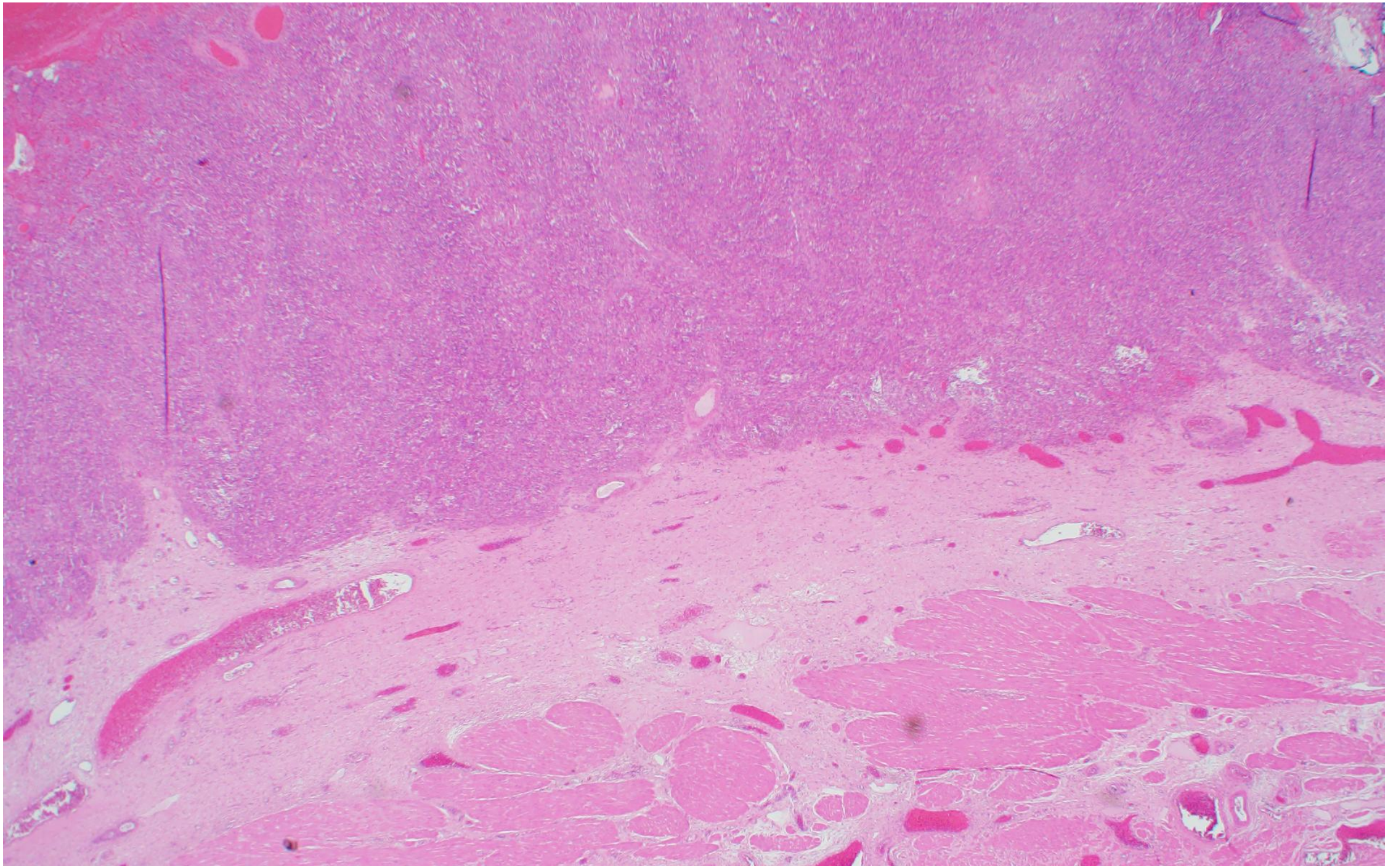

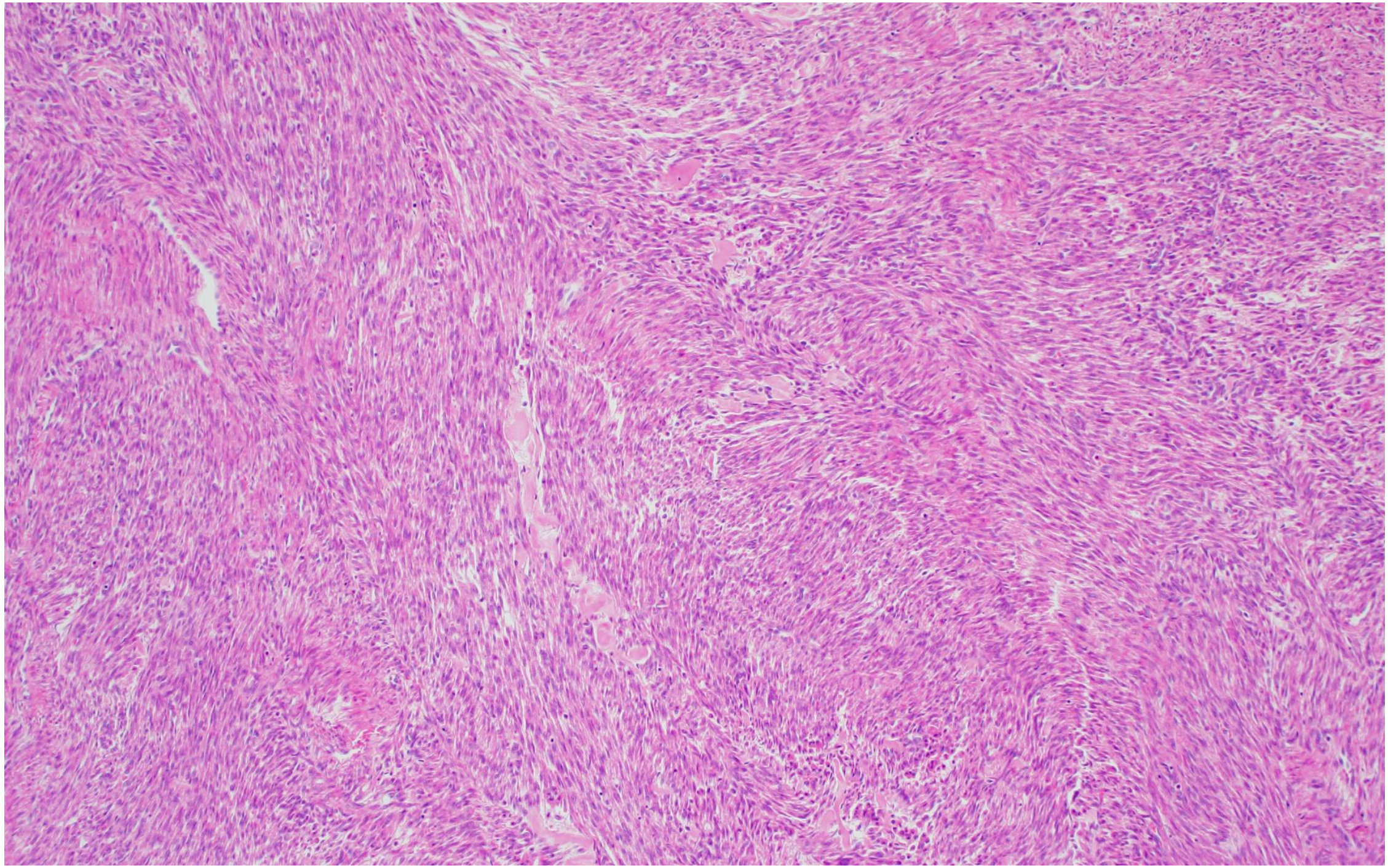

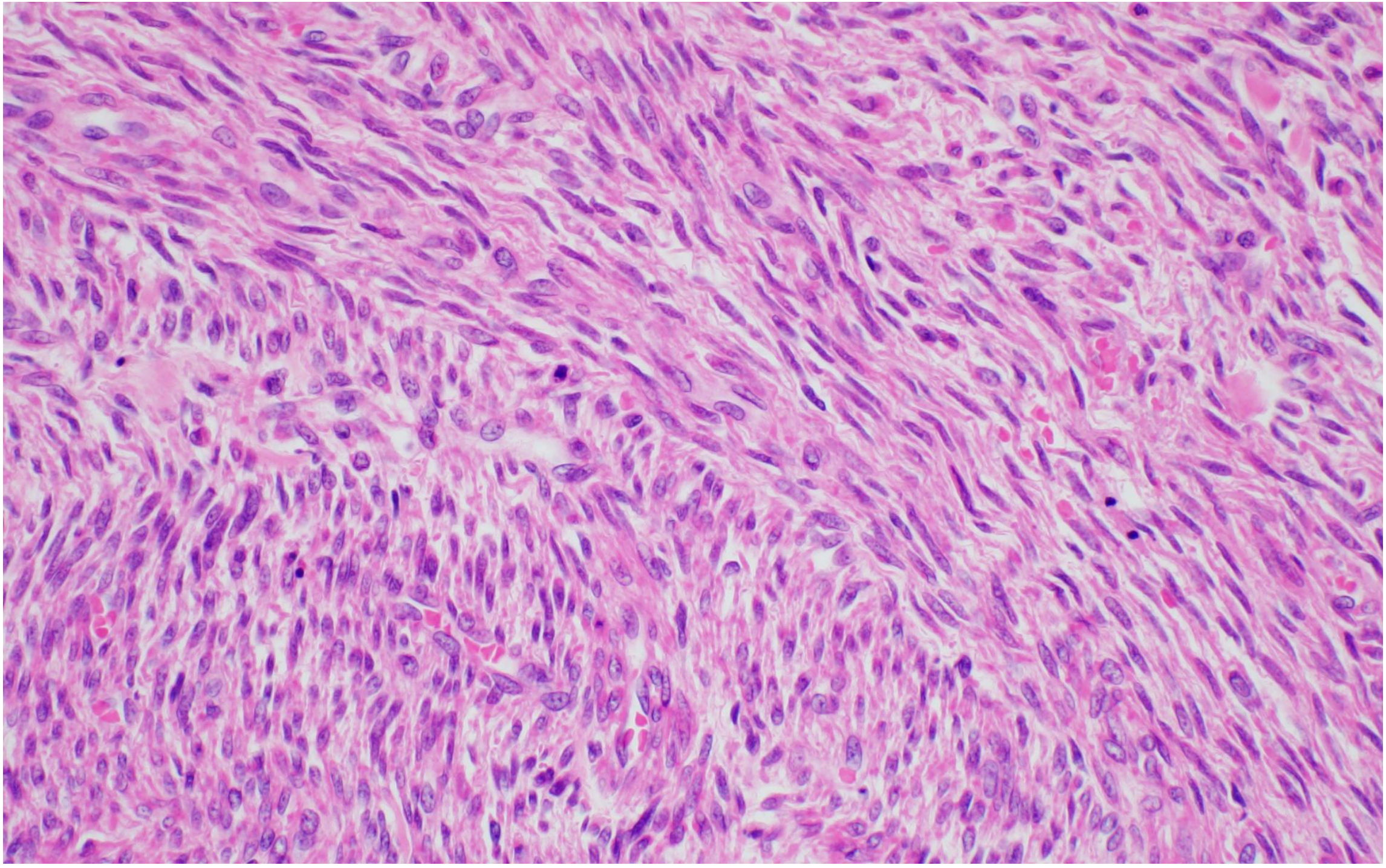

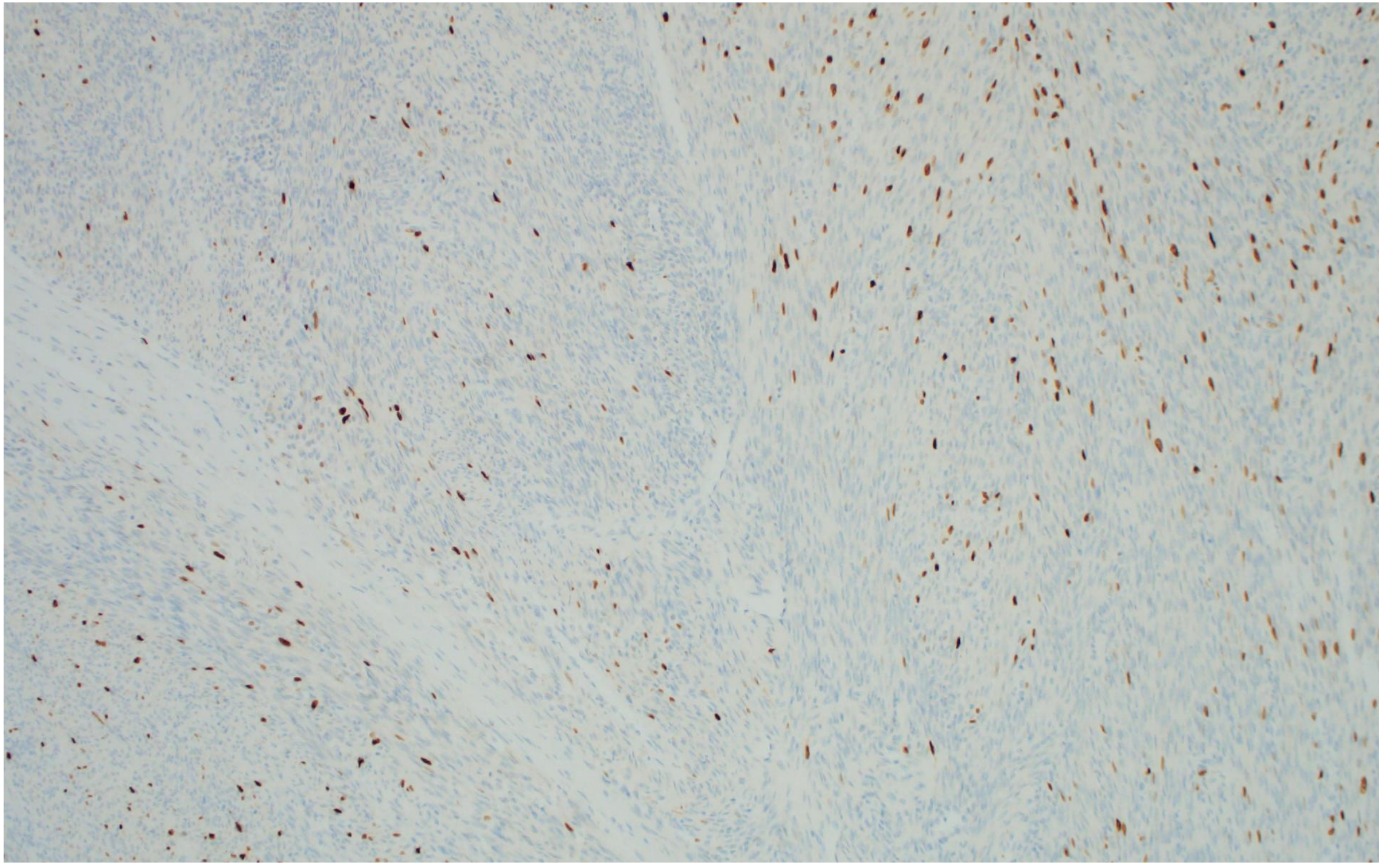

WHO diagnostic criteria

Leiomyosarcoma (spindle cell)

Two or more of:

- Marked cytological atypia (2+/3+
- Tumour cell necrosis
- 4 or more mitoses/mm2 (10+/10hpf)

Smooth muscle tumour of uncertain malignant potential (STUMP) – guidelines, not prescriptive

- Focal/multifocal or diffuse atypia + 6-9 mitoses/10hpf
- Tumour cell necrosis but no other concerning features
- >15 mitoses/10hpf but no other concerning features
- Diffuse nuclear atypia and uncertain mitotic counts

WHO diagnostic criteria

No inclusion of circumscribed vs infiltrative edge

(only for myxoid LMS)

ooth muscle tumour of uncertain malignant
ential (STUMP) – guidelines, not prescriptive

/multifocal or diffuse atypia + 6-9
ses/10hpf

- Marked cyt
- Tumour cel
- 4 or more mitoses/mm2 (10+/10hpf)

our cell necrosis but no other concerning
res

mitoses/10hpf but no other concerning features

- Diffuse nuclear atypia and uncertain mitotic counts

WHO diagnostic criteria

No inclusion of circumscribed vs infiltr… edge

(only for myxoid LMS)

[based on criteria]

should we call these cases benign leiomyomata?

L… lignant
…criptive

- Marked cyt… …ning
- Tumour cel… …g features
- 4 or more mitoses/mm2 (10+/10hpf) …tic counts

Sparse literature

"Furthermore, sampling may show an infiltrative growth, lymphovascular invasion, or presence of conventional and/or epithelioid components, which will facilitate the diagnosis of malignancy."

Esther Oliva, *Modern Pathology* 2016

STUMP?

- Gupta *et al.*, Histopathology 2018

- Brigham and Women's Hospital detailed their criteria for STUMP:

  - Necrosis which is difficult to classify
  - Diffuse and multifocal atypia and mitotic counts near threshold for LMS
  - Bland but >15 mitoses/10hpf
  - Bland but tumour cell necrosis present
  - Epithelioid or myxoid areas with atypia/necrosis between leiomyoma and LMS
  - Myometrial invasion with no other canonical criteria of malignancy
  - Atypical mitotic figures with no other canonical criteria of malignancy

- 9/22 cases were infiltrative

- Infiltrative margins were present in 5/8 cases which recurred – not significant, p=0.205

- 9/22 cases were infiltrative

- Infiltrative margins were present in 5/8 cases which recurred – not significant, p=0.205

BUT

What about extension **beyond** the uterus?

Options

1. Leiomyoma
   - Technically correct as per diagnostic criteria
   - Does not capture the worrying feature of infiltrative margins
   - Outcome: No follow-up

Options

1. Leiomyoma
   - Technically correct as per diagnostic criteria
   - Does not capture the worrying feature of infiltrative margins
   - Outcome: No follow-up

2. STUMP
   - Patient will have follow-up
   - Is it of uncertain malignant potential if it’s already spread locally?

Options

1. Leiomyoma
   - Technically correct as per diagnostic criteria
   - Does not capture the worrying feature of infiltrative margins
   - Outcome: No follow-up

2. STUMP
   - Patient will have follow-up
   - Is it of uncertain malignant potential if it’s already spread locally?

3. Leiomyosarcoma
   - Does not fulfil diagnostic criteria

Follow-up

Case 1:

- Patient wanted to conserve fertility as was planning to conceive
- Short interval imaging follow-up
- No current evidence of disease
- Plan for completion surgery once family complete

Case 2:

- Within 8 months developed peritoneal nodules
- Currently has multifocal peritoneal disease throughout abdomen and pelvis

Case 2 recurrence

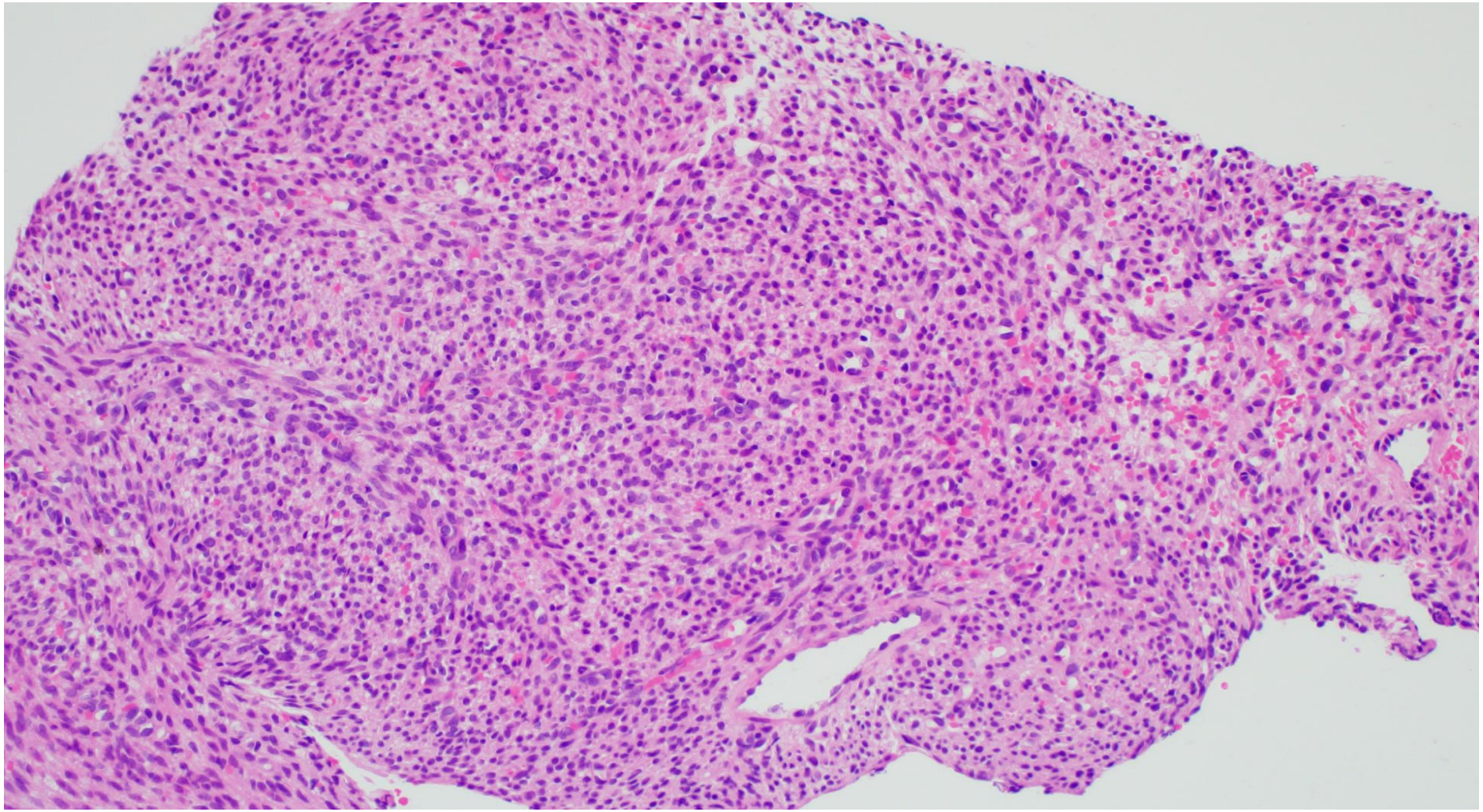

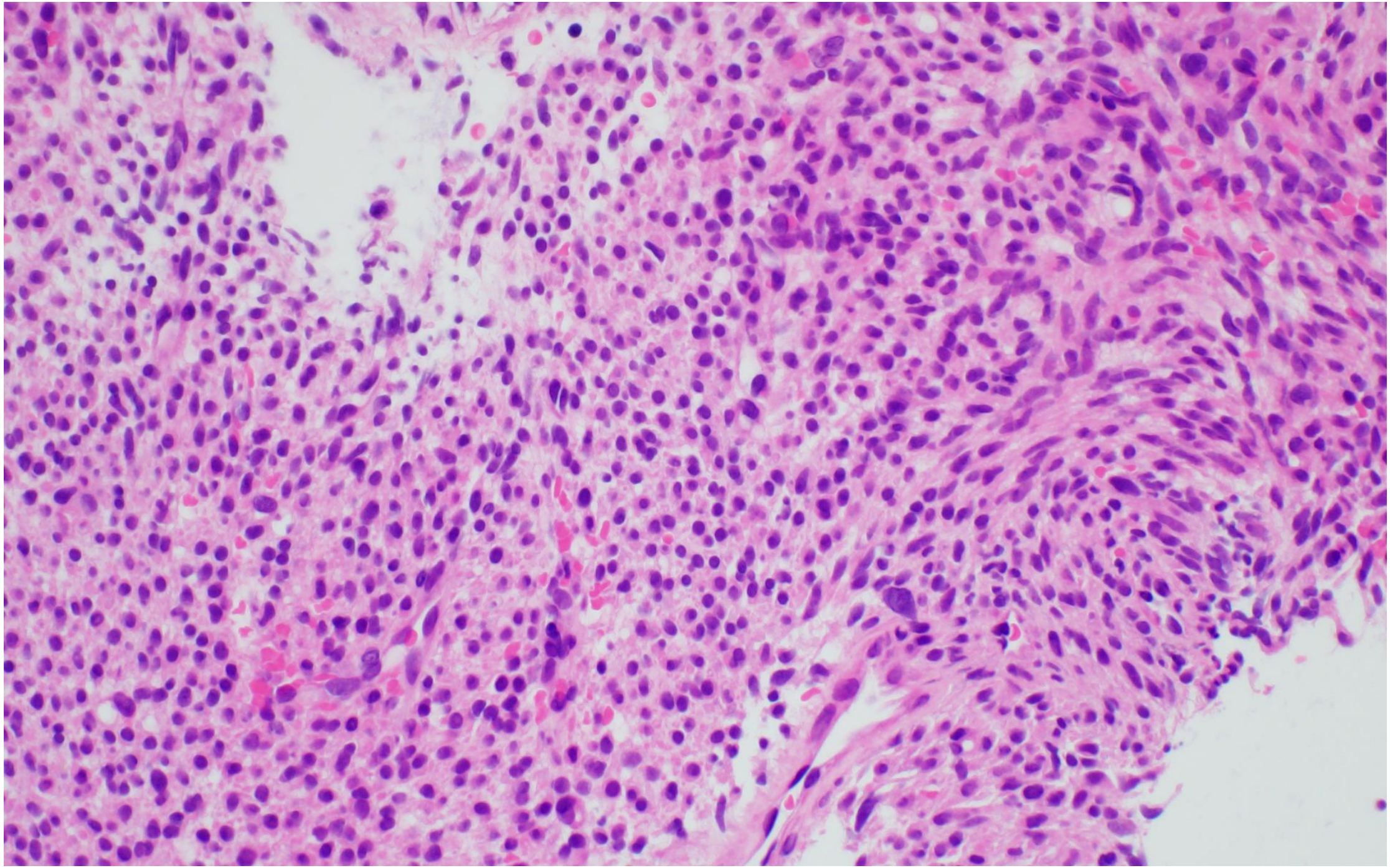

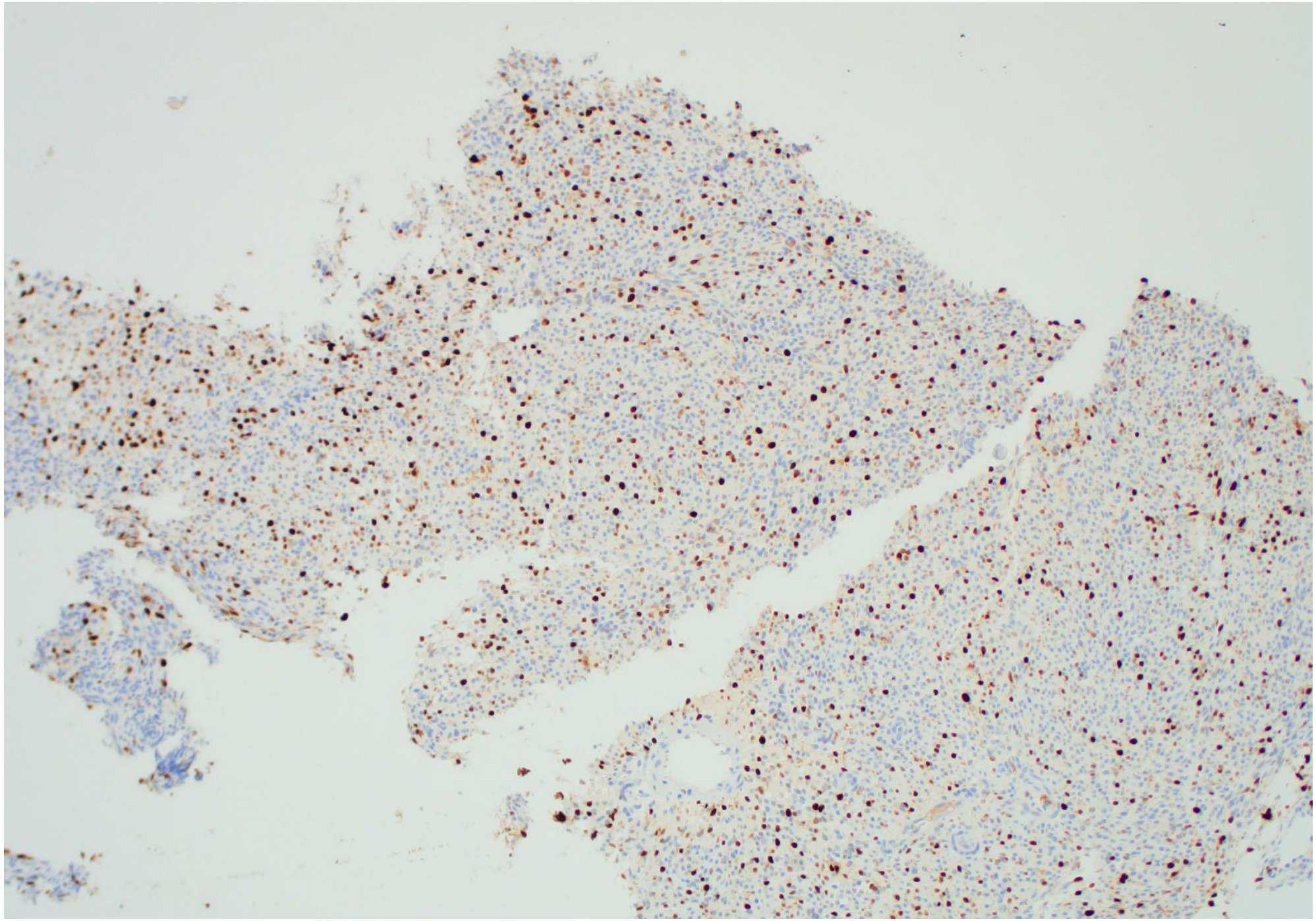

How did I report?

Case 1:

"While diagnostic criteria of leiomyosarcoma are not met, this lesion should be regarded as having a risk of local recurrence/a potentially locally aggressive behaviour. Repeat imaging and rediscussion at a Central MDT is recommended."

Case 2:

"Despite the lack of typical diagnostic features for leiomyosarcoma (necrosis/atypia/mitotic activity), the infiltrative pattern and presence of separate metastatic nodule in rectosigmoid mesentery implies locally aggressive/malignant behaviour.

NGS in progress for further characterisation but based on current findings for management purposes overall best regarded as leiomyosarcoma with unusual features."

Take home messages

- Despite good criteria for classification of smooth muscle tumours, some cases cannot be definitively categorised
- Exclude mimics
- Sometimes a descriptive report is better than pushing a tumour into a diagnosis that it does not quite “fit”
- More molecular in the future?