# Case One

45-year-old female with a tan-yellow bulky mass involving the uterus;
“worm-like” plugs are noted involving parametrial vessels

# Diagnosis Case One:
# Low Grade Endometrial Stromal Sarcoma


- Dessources K, Miller KM, Kertowidjojo E et al (2022). ESR1 hotspot mutations in endometrial stromal sarcoma with high-grade transformation and endocrine treatment. Mod Pathol 35(7):972-978.
- Zou Y, Turashvilli G, Soslow RA et al. (2020) High-grade transformation of low-grade endometrial stromal sarcomas lacking YWHAE and BCOR genetic abnormalities. Mod Pathol 33: 1861-1870.
- Moore M, McCluggage WG. (2020) Uterine Endometrial Stromal Tumors With Limited Infiltration: First Report of a Case Series Indicating Potential for Malignant Behavior. Int J Gynecol Pathol.
- Nucci MR, Harburger D, Koontz J, Dal Cin P, Sklar J. (2007) Molecular analysis of the JAZF1-JJAZ1 gene fusion by RT-PCR and fluorescence in situ hybridization in endometrial stromal neoplasms. Am J Surg Pathol. Jan;31(1):65-70
- Oliva E, de Leval L, Soslow RA, Herens C. (2007) High frequency of JAZF1-JJAZ1 gene fusion in endometrial stromal tumors with smooth muscle differentiation by interphase FISH detection. Am J Surg Pathol. 2007 Aug;31(8):1277-84
- Huang HY, Ladanyi M and Soslow RA (2004). Molecular detection of JAZF1-JJAZ1 gene fusion in endometrial stromal neoplasms with classic and variant histology: evidence for genetic heterogeneity. *Am J Surg Pathol* 28(2):224-232.
- Dionigi A, Oliva E, Clement PB, Young RH. (2002) Endometrial stromal nodules and endometrial stromal tumors with limited infiltration: a clinicopathologic study of 50 cases. Am J Surg Pathol. May;26(5):567-81
- Koontz JI, Soreng AL, Nucci M, Kuo FC, Pauwels P, van Den Berghe H, Dal Cin P, Fletcher JA and Sklar J (2001). Frequent fusion of the JAZF1 and JJAZ1 genes in endometrial stromal tumors. *Proc Natl Acad Sci U S A* 98(11):6348-6353.
- Chang KL, Crabtree GS, Lim-Tan SK, Kempson RL and Hendrickson MR (1990). Primary uterine endometrial stromal neoplasms. A clinicopathologic study of 117 cases. *Am J Surg Pathol* 14(5):415-438.

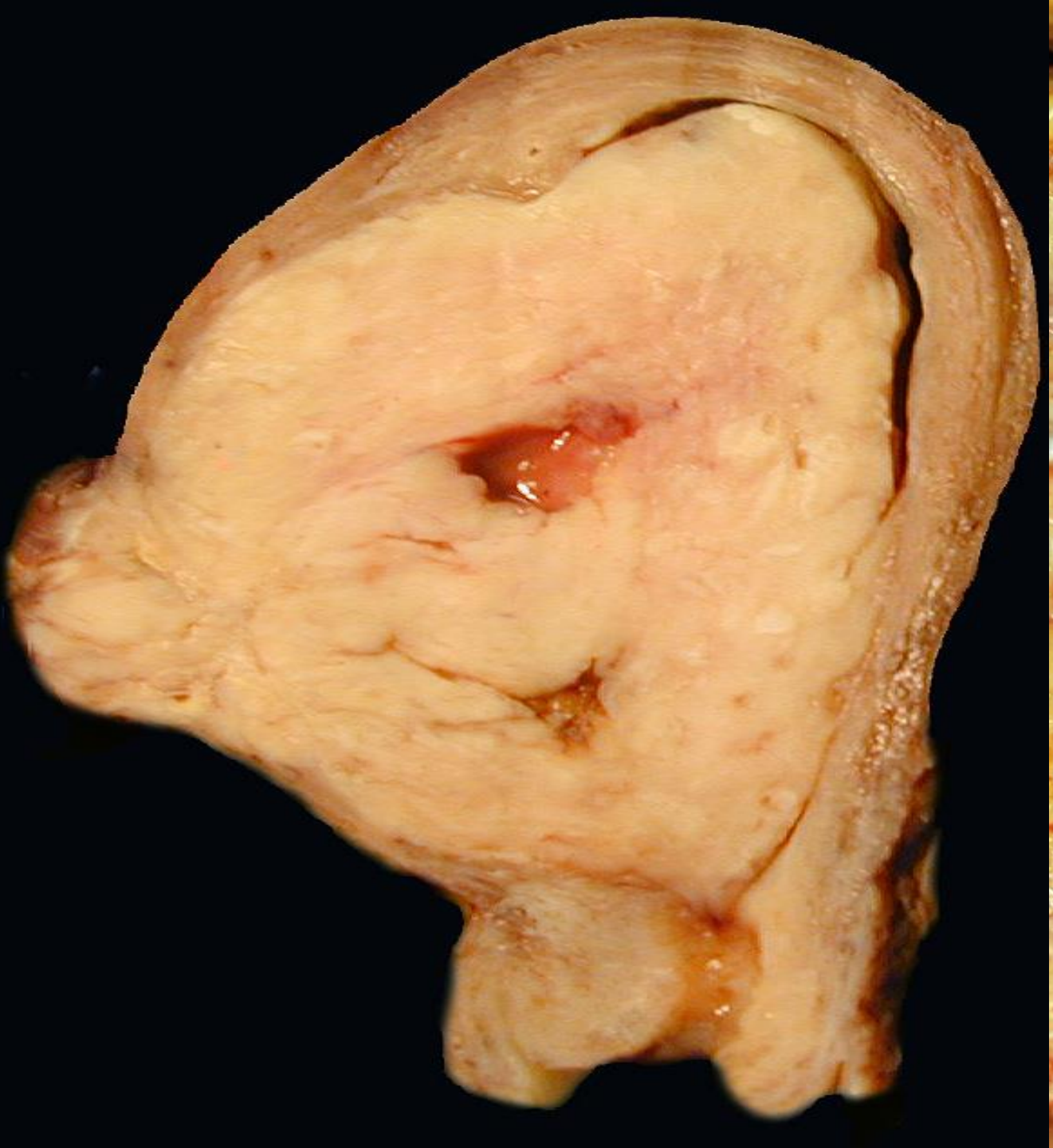




Low-Grade Endometrial Stromal Sarcoma With Apparently Well-Circumscribed Margins

↓

Must sample extensively!!

# Case Two

30-year-old female with a bulky tan white fleshy myometrial mass that transmurally involved the uterine wall and extended to involve the serosal surface.

# Diagnosis Case Two:
# High Grade Endometrial Stromal Sarcoma (YWHAE)


- Alkanat NE, Uner A, Usubutun A (2022). High-grade endometrial stromal sarcoma: Morphologic and clinical features, the role of immunohistochemistry and fluorescence in situ hybridization in diagnosis. Int J Surg Pathol (on line ahead of print).
- Mohammad N, Stewart CJR, Chiang S, Turashvili G, Dickson BC, Ng TL, Köbel M, McCluggage WG, Croce S, Lee CH. (2021) p53 immunohistochemical analysis of fusion-positive uterine sarcomas. Histopathology. May;78(6):805-813
- McCluggage WG, Lee CH. (2019) YWHAE-NUTM2A/B Translocated High-grade Endometrial Stromal Sarcoma Commonly Expresses CD56 and CD99. Int J Gynecol Pathol. Nov;38(6):528-532.
- Hemming ML, Wagner AJ, Nucci MR, Chiang S, Wang L, Hensley ML, George S. (2017) YWHAE-rearranged high-grade endometrial stromal sarcoma: Two-center case series and response to chemotherapy. Gynecol Oncol. Jun;145(3):531-535
- Lee C-H, Hoang LN, Yip S et al. (2014). Frequent expression of KIT in endometrial stromal sarcoma with YWHAE genetic rearrangement. 27(5):751-7.
- Kruse AJ, Croce S, Kruitwagen RF, Riedl RG, Slangen BF, Van Gorp T, Van de Vijver KK. (2014) Aggressive behavior and poor prognosis of endometrial stromal sarcomas with YWHAE-FAM22 rearrangement indicate the clinical importance to recognize this subset. Int J Gynecol Cancer.Nov;24(9):1616-22
- Lee CH, Ali RH, Rouzbahman M, Marino-Enriquez A, Zhu M, Guo X, Brunner AL, Chiang S, Leung S, Nelnyk N, Huntsman DG, Blake Gilks C, Nielsen TO, Dal Cin P, van de Rijn M, Oliva E, Fletcher JA, Nucci MR. (2012) Cyclin D1 as a diagnostic immunomarker for endometrial stromal sarcoma with YWHAE-FAM22 rearrangement. Am J Surg Pathol. Oct;36(10):1562-70
- Lee CH, Mariño-Enriquez A, Ou W, Zhu M, Ali RH, Chiang S, Amant F, Gilks CB, van de Rijn M, Oliva E, Debiec-Rychter M, Dal Cin P, Fletcher JA, Nucci MR. (2012) The clinicopathologic features of YWHAE-FAM22 endometrial stromal sarcomas: a histologically high-grade and clinically aggressive tumor. Am J Surg Pathol. May;36(5):641-53

# Often advanced stage

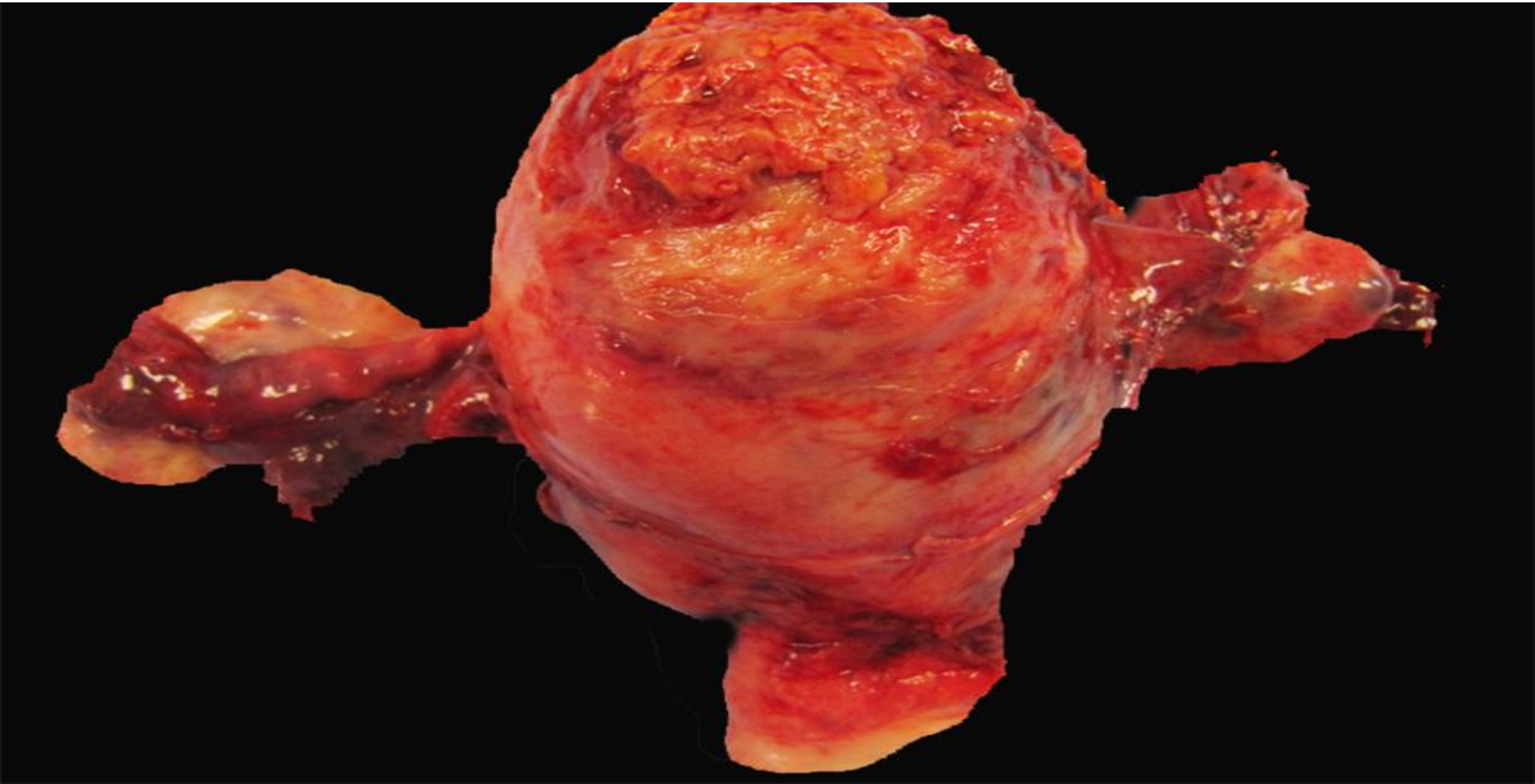

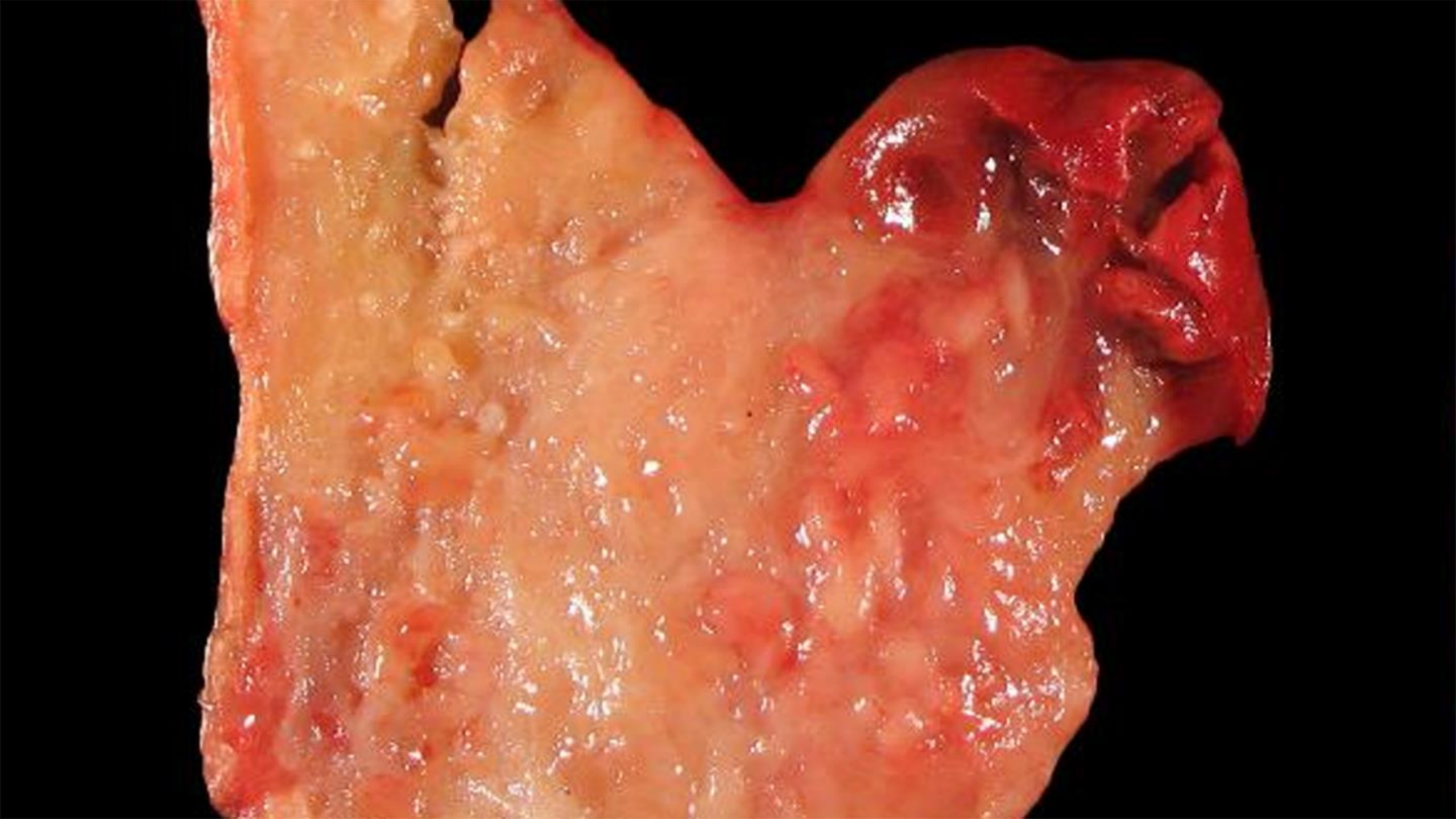

# Case Three

33 year old female with a fleshy gray-white myometrial mass

# Diagnosis Case Three:
# High Grade Endometrial Stromal Sarcoma (BCOR)


- Kommoss FKF, Chiang S, Kobel M et al (2022). Endometrial stromal sarcomas with BCOR internal tandem duplication and variant BCOR/BCORL1 rearrangements resemble high grade endometrial stromal sarcomas with recurrent CDK4 pathway alterations and MDM2 amplifications. Am J Surg Pathol 46(8):1142-1152.
- Lewis N, Soslow RA, Delair DF, Park KJ, Murali R, Hollmann TJ, Davidson B, Micci F, Panagopoulos I, Hoang LN, Arias-Stella JA, 3rd, Oliva E, Young RH, Hensley ML, Leitao MM, Jr., Hameed M, Benayed R, Ladanyi M, Frosina D, Jungbluth AA, Antonescu CR and Chiang S (2018). ZC3H7B-BCOR high-grade endometrial stromal sarcomas: a report of 17 cases of a newly defined entity. *Mod Pathol* 31(4):674-684.
- Mariño-Enriquez A, Lauria A, Przybyl J, Ng TL, Kowalewska M, Debiec-Rychter M, Ganesan R, Sumathi V, George S, McCluggage WG, Nucci MR, Lee CH and Fletcher JA (2018). BCOR Internal Tandem Duplication in High-grade Uterine Sarcomas. *Am J Surg Pathol* 42(3):335-341.
- Hoang LN, Aneja A, Conlon N, Delair DF, Middha S, Benayed R, Hensley ML, Park KJ, Hollmann TJ, Hameed MR, Antonescu CR, Soslow RA and Chiang S (2017). Novel High-grade Endometrial Stromal Sarcoma: A Morphologic Mimicker of Myxoid Leiomyosarcoma. *Am J Surg Pathol* 41(1):12-24.

# *BCOR*-associated HGESS: Gross Appearance

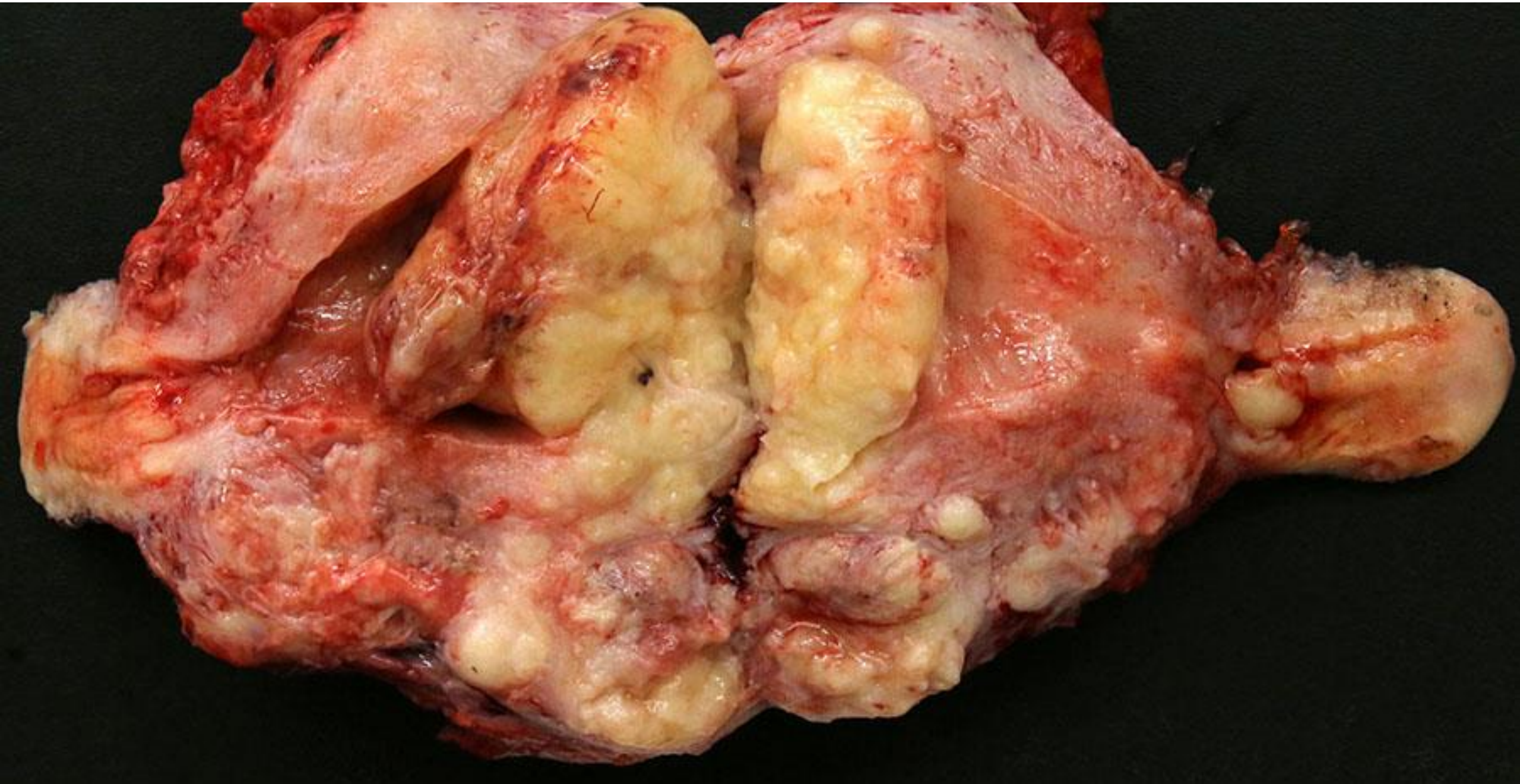

# Case Four

38-year-old with a soft, tan-white myometrial mass with a partially whorled cut surface and foci of myxoid change

# Diagnosis Case Four: Inflammatory Myofibroblastic Tumor


- Bennett JA, Wang P, Wanjari P, Diaz L, Oliva E (2021). Uterine inflammatory myofibroblastic tumor: First report of a *ROS1* fusion. Genes Chromosomes Cancer 60 (12): 822-826.
- Bennett JA, Croce S, Pesci A, Niu N, Van de Vijver K, Burks EJ, Burandt E, Zannoni GF, Rabban JT and Oliva E (2020). Inflammatory Myofibroblastic Tumor of the Uterus: An Immunohistochemical Study of 23 Cases. *Am J Surg Pathol* 44(11):1441-1449.
- Haimes JD, Stewart CJR, Kudlow BA, Culver BP, Meng B, Koay E, Whitehouse A, Cope N, Lee JC, Ng T, McCluggage WG and Lee CH (2017). Uterine Inflammatory Myofibroblastic Tumors Frequently Harbor ALK Fusions With IGFBP5 and THBS1. *Am J Surg Pathol* 41(6):773-780.
- Parra-Herran C, Quick CM, Howitt BE, Dal Cin P, Quade BJ and Nucci MR (2015). Inflammatory myofibroblastic tumor of the uterus: clinical and pathologic review of 10 cases including a subset with aggressive clinical course. *Am J Surg Pathol* 39(2):157-168.
- Rabban JT, Zaloudek CJ, Shekitka KM and Tavassoli FA (2005). Inflammatory myofibroblastic tumor of the uterus: a clinicopathologic study of 6 cases emphasizing distinction from aggressive mesenchymal tumors. *Am J Surg Pathol* 29(10):1348-1355.

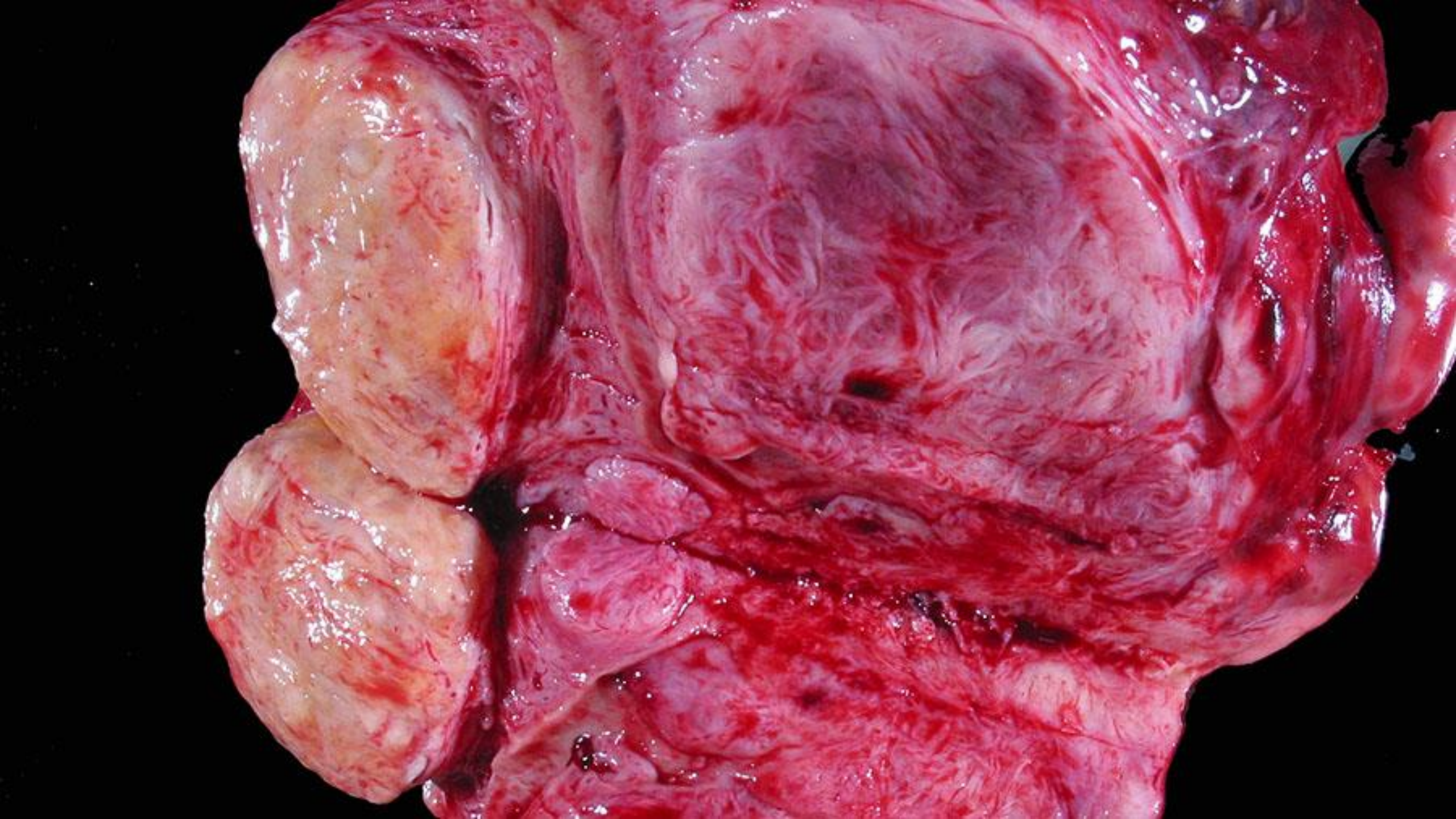

# Case Five

38-year-old female with an 8 cm well circumscribed tan-white myometrial mass with whorled cut surface.

# Diagnosis Case Five: FH-Deficient Leiomyoma


- Rabban JT, Chan E, Mak J, Zaloudek C, Garg K. (2019) Prospective Detection of Germline Mutation of Fumarate Hydratase in Women With Uterine Smooth Muscle Tumors Using Pathology-based Screening to Trigger Genetic Counseling for Hereditary Leiomyomatosis Renal Cell Carcinoma Syndrome: A 5-Year Single Institutional Experience. Am J Surg Pathol. May;43(5):639-655
- Miettinen M, Felisiak-Golabek A, Wasag B, Chmara M, Wang Z, Butzow R and Lasota J (2016). Fumarase-deficient Uterine Leiomyomas: An Immunohistochemical, Molecular Genetic, and Clinicopathologic Study of 86 Cases. *Am J Surg Pathol* 40(12):1661-1669.
- Joseph NM, Solomon DA, Frizzell N, Rabban JT, Zaloudek C and Garg K (2015). Morphology and Immunohistochemistry for 2SC and FH Aid in Detection of Fumarate Hydratase Gene Aberrations in Uterine Leiomyomas From Young Patients. *Am J Surg Pathol* 39(11):1529-1539.
- Reyes C, Karamurzin Y, Frizzell N, Garg K, Nonaka D, Chen YB and Soslow RA (2014). Uterine smooth muscle tumors with features suggesting fumarate hydratase aberration: detailed morphologic analysis and correlation with S-(2-succino)-cysteine immunohistochemistry. *Mod Pathol* 27(7):1020-1027.
- Sanz-Ortega J, Vocke C, Stratton P, Linehan WM and Merino MJ (2013). Morphologic and molecular characteristics of uterine leiomyomas in hereditary leiomyomatosis and renal cancer (HLRCC) syndrome. *Am J Surg Pathol* 37(1):74-80.

# Case Six

25 year old woman with a polypoid lesion of cervix

# Diagnosis Case Six: NTRK-rearranged Sarcoma


- Costigan DC, Nucci MR, Dickson BC et al. (2022). NTRK-rearranged uterine sarcomas: Clinicopathologic features of 15 cases, literature review, and risk stratification. Am J Surg Pathol 46(10): 1415-1429.
- Hodgson A, Pun C, Djordjevic B, Turashvili G. (2021) NTRK-rearranged Cervical Sarcoma: Expanding the Clinicopathologic Spectrum. Int J Gynecol Pathol. Jan;40(1):73-77
- Rabban JT, Devine WP, Sangoi AR, Poder L, Alvarez E, Davis JL, Rudzinski E, Garg K, Bean GR. (2020) NTRK fusion cervical sarcoma: a report of three cases, emphasising morphological and immunohistochemical distinction from other uterine sarcomas, including adenosarcoma. Histopathology. Jul;77(1):100-111
- Croce S, Hostein I, Longacre TA, Mills AM, Pérot G, Devouassoux-Shisheboran M, Velasco V, Floquet A, Guyon F, Chakiba C, Querleu D, Khalifa E, Mayeur L, Rebier F, Leguellec S, Soubeyran I, McCluggage WG. (2019) Uterine and vaginal sarcomas resembling fibrosarcoma: a clinicopathological and molecular analysis of 13 cases showing common NTRK-rearrangements and the description of a COL1A1-PDGFB fusion novel to uterine neoplasms. Mod Pathol. Jul;32(7):1008-1022.
- Chiang S, Cotzia P, Hyman DM, Drilon A, Tap WD, Zhang L, Hechtman JF, Frosina D, Jungbluth AA, Murali R, Park KJ, Soslow RA, Oliva E, Iafrate AJ, Benayed R, Ladanyi M, Antonescu CR. (2018) NTRK Fusions Define a Novel Uterine Sarcoma Subtype With Features of Fibrosarcoma. Am J Surg Pathol. 2018 Jun;42(6):791-798



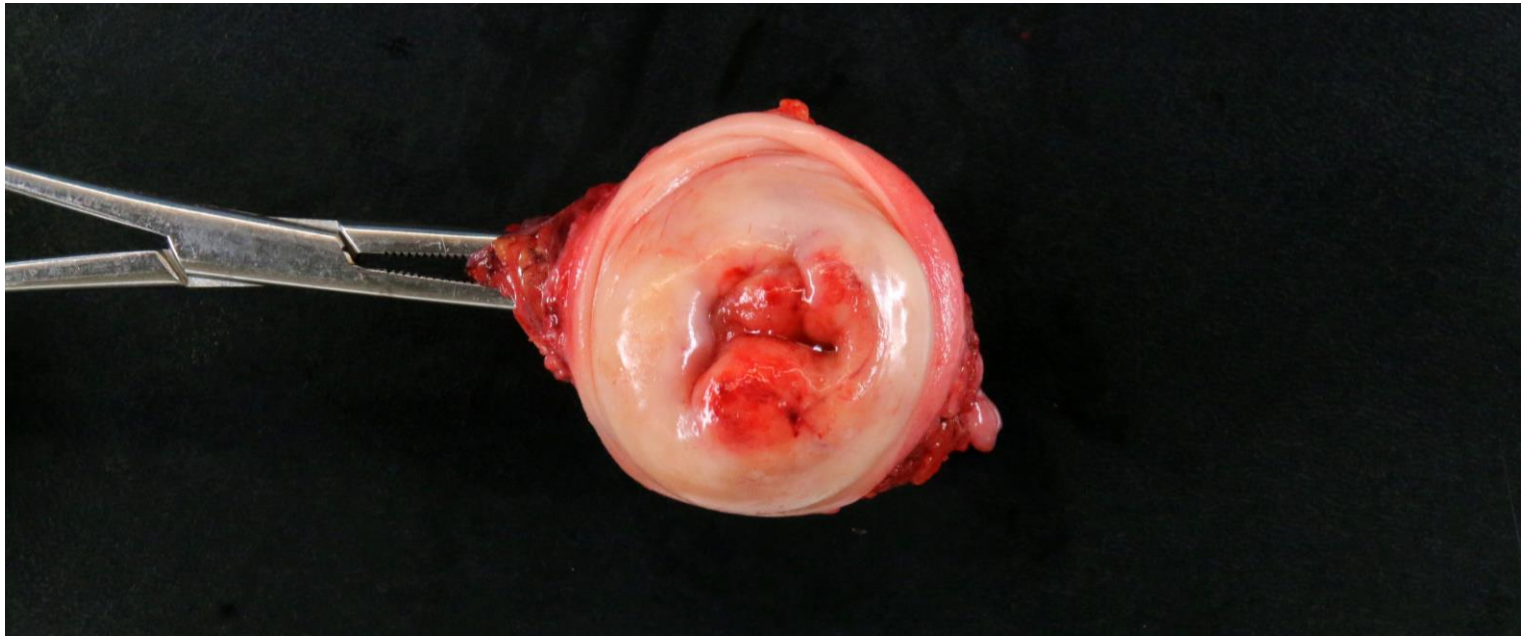

# NTRK Sarcoma


A
0
1
2
CM
3
4

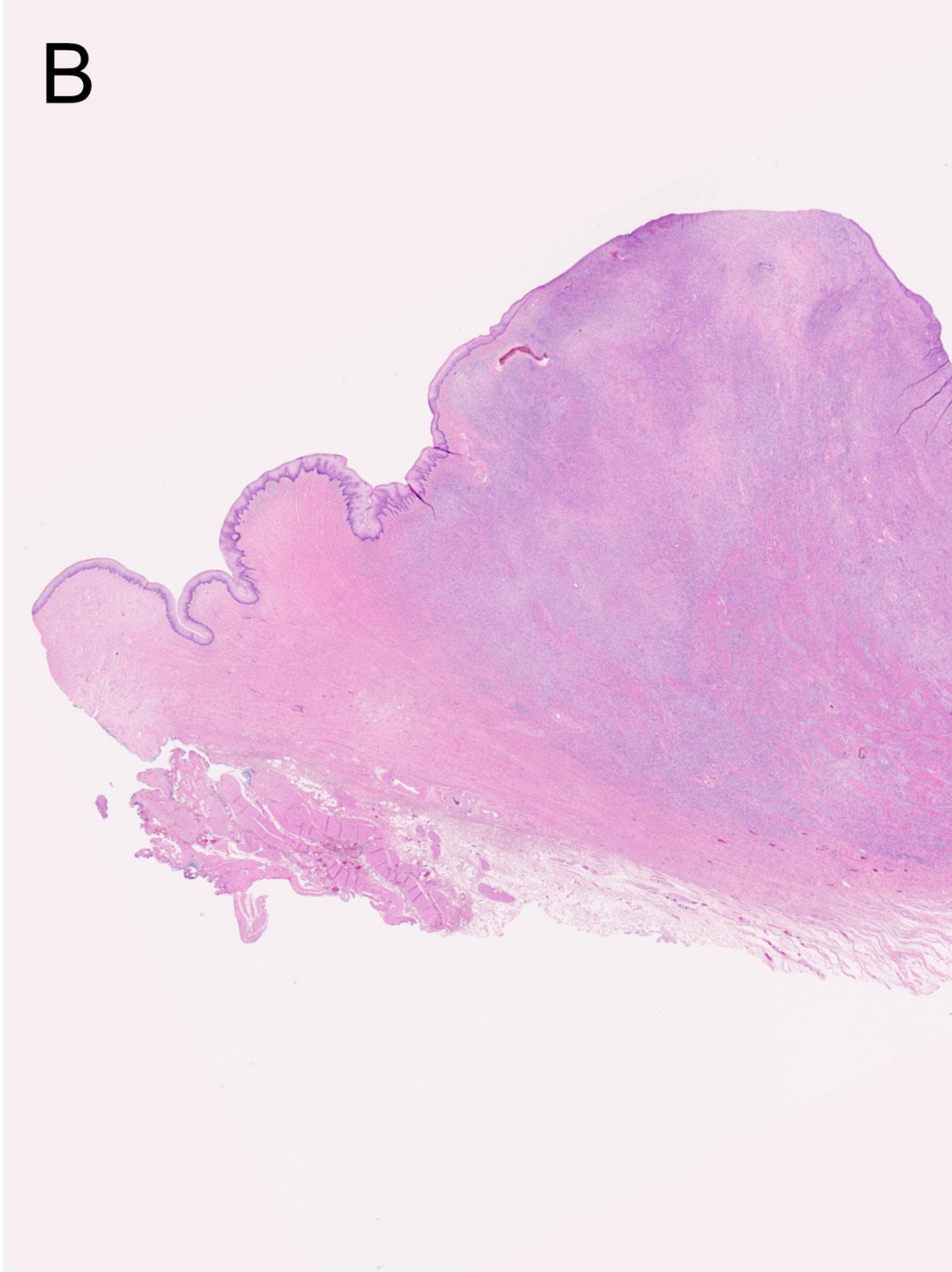
B

# Case Seven

50-year-old female with a large, fleshy tan-white uterine mass.

# Diagnosis Case Seven: COL1A1-rearranged Sarcoma


- Grindstaff SL, DiSilvestro J, Hansen K, DiSilvestro P, Sung CJ and Quddus MR (2020). COL1A1-PDGFB fusion uterine fibrosarcoma: A case report with treatment implication. Gynecol Oncol Rep 31:100523.
- Croce S, Hostein I, Longacre TA, Mills AM, Pérot G, Devouassoux-Shisheboran M, Velasco V, Floquet A, Guyon F, Chakiba C, Querleu D, Khalifa E, Mayeur L, Rebier F, Leguellec S, Soubeyran I and McCluggage WG (2019). Uterine and vaginal sarcomas resembling fibrosarcoma: a clinicopathological and molecular analysis of 13 cases showing common NTRK-rearrangements and the description of a COL1A1-PDGFB fusion novel to uterine neoplasms. Mod Pathol 32(7):1008-1022

# Case Eight

70 year old female with removal of an endometrial polyp

# Diagnosis Case Eight: Mullerian Adenosarcoma


- Hodgson A, Amemiya Y, Seth A, Djordjevic B and Parra-Herran C (2017). High-grade Müllerian Adenosarcoma: Genomic and Clinicopathologic Characterization of a Distinct Neoplasm With Prevalent TP53 Pathway Alterations and Aggressive Behavior. Am J Surg Pathol 41(11):1513-1522.
- Stolnicu S, Molnar C, Barsan I, Boros M, Nogales FF and Soslow RA (2016). The Impact on Survival of an Extensive Sex Cord-like Component in Mullerian Adenosarcomas: A Study Comprising 6 Cases. Int J Gynecol Pathol 35(2):147-152.
- Blom R and Guerrieri C (1999). Adenosarcoma of the uterus: a clinicopathologic, DNA flow cytometric, p53 and mdm-2 analysis of 11 cases. Int J Gynecol Cancer 9(1):37-43.
- Clement PB and Scully RE (1990). Mullerian adenosarcoma of the uterus: a clinicopathologic analysis of 100 cases with a review of the literature. Hum Pathol 21(4):363-381.
- Clement PB (1989). Müllerian adenosarcomas of the uterus with sarcomatous overgrowth. A clinicopathological analysis of 10 cases. Am J Surg Pathol 13(1):28-38.
- Clement PB and Scully RE (1989). Müllerian adenosarcomas of the uterus with sex cord-like elements. A clinicopathologic analysis of eight cases. Am J Clin Pathol 91(6):664-672.

# Benign Polyp vs. Mullerian Adenosarcoma

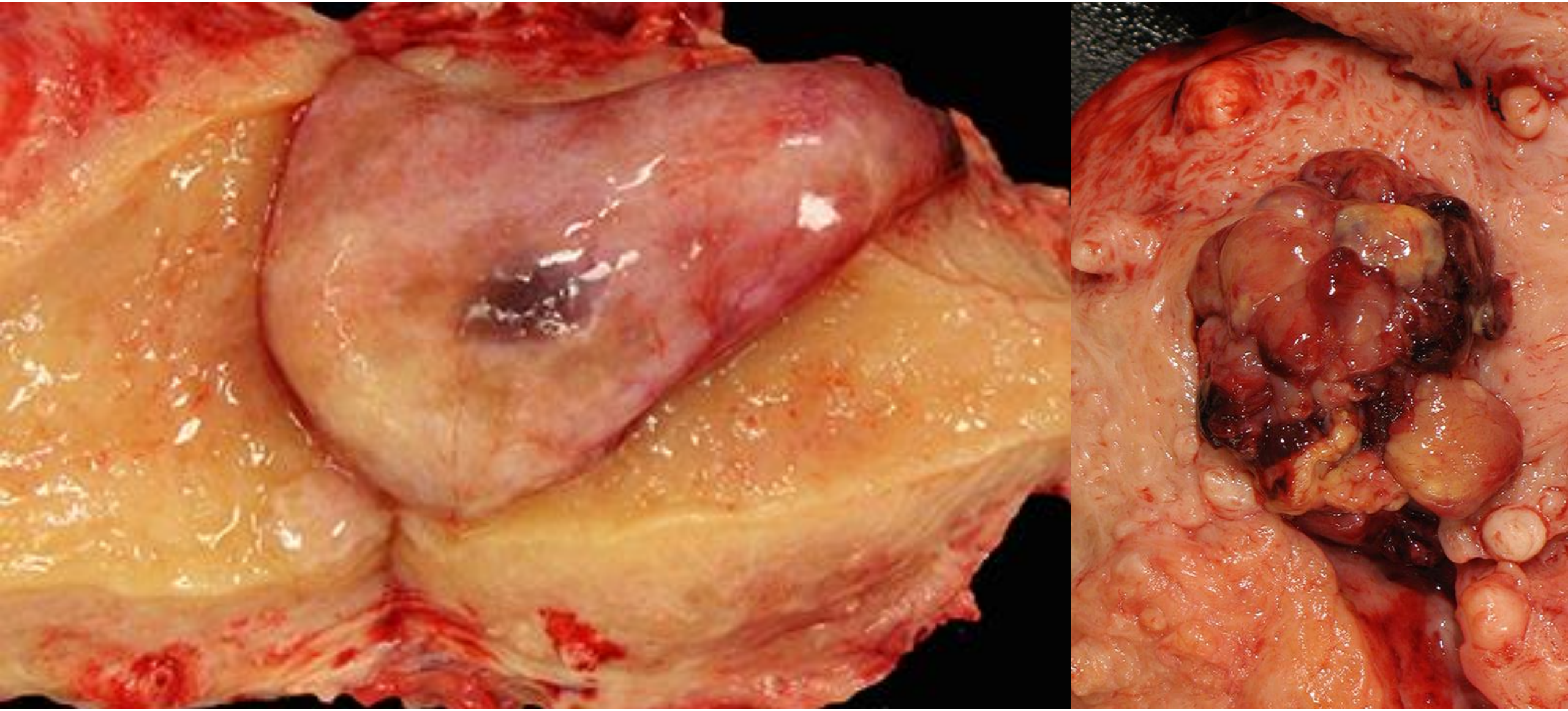

Clues on gross examination; not helpul in biopsy material

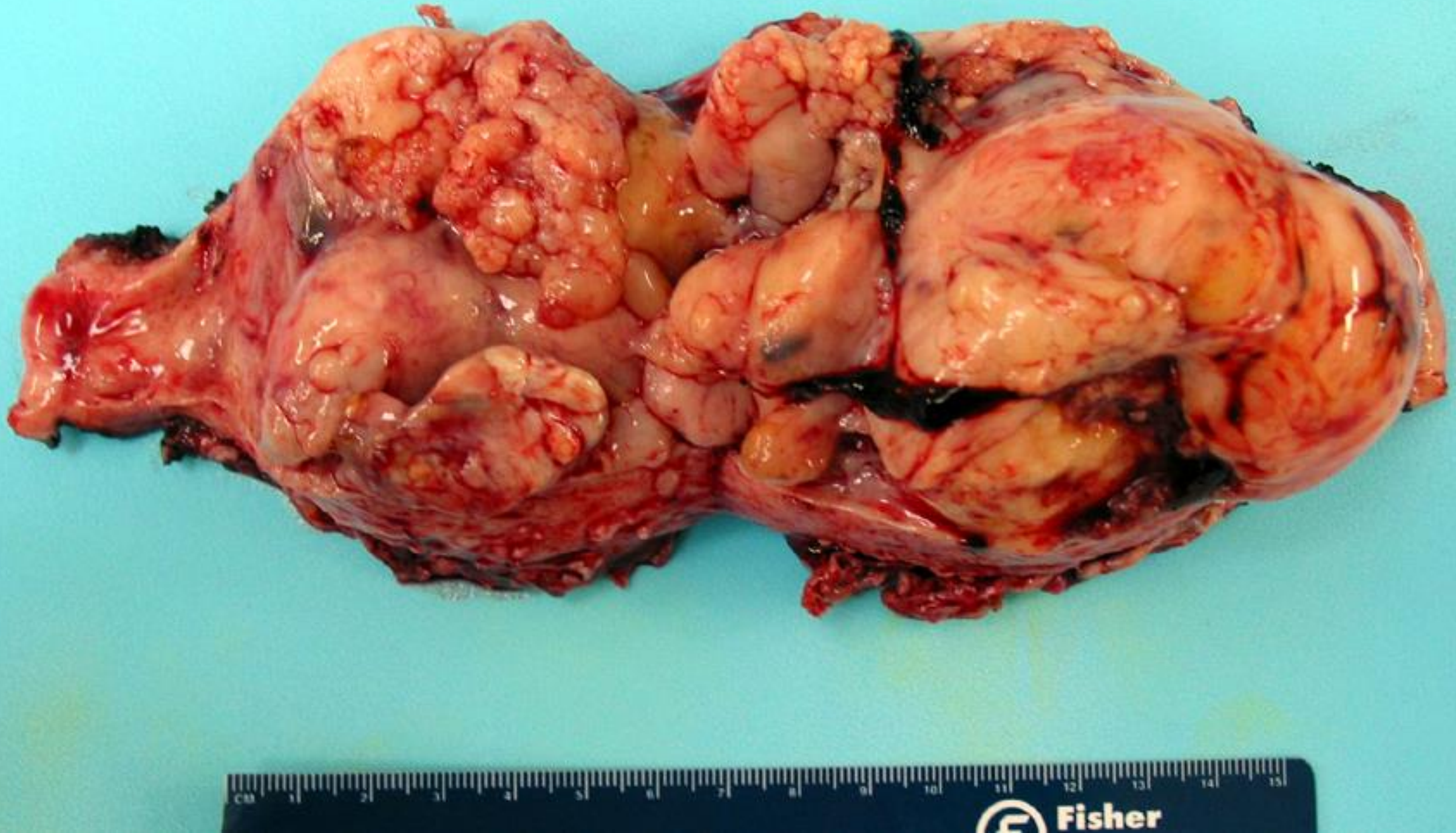
Fisher

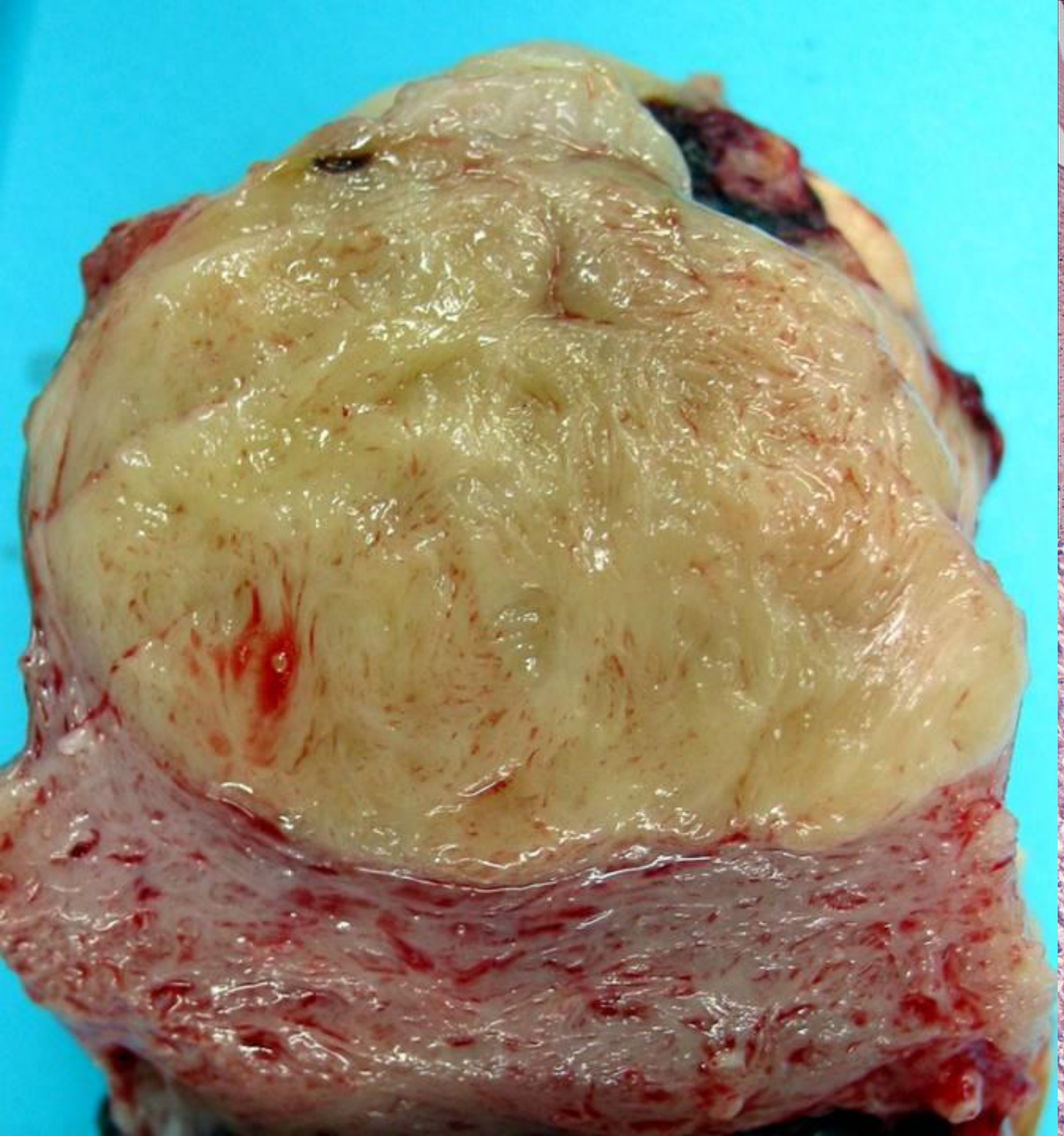

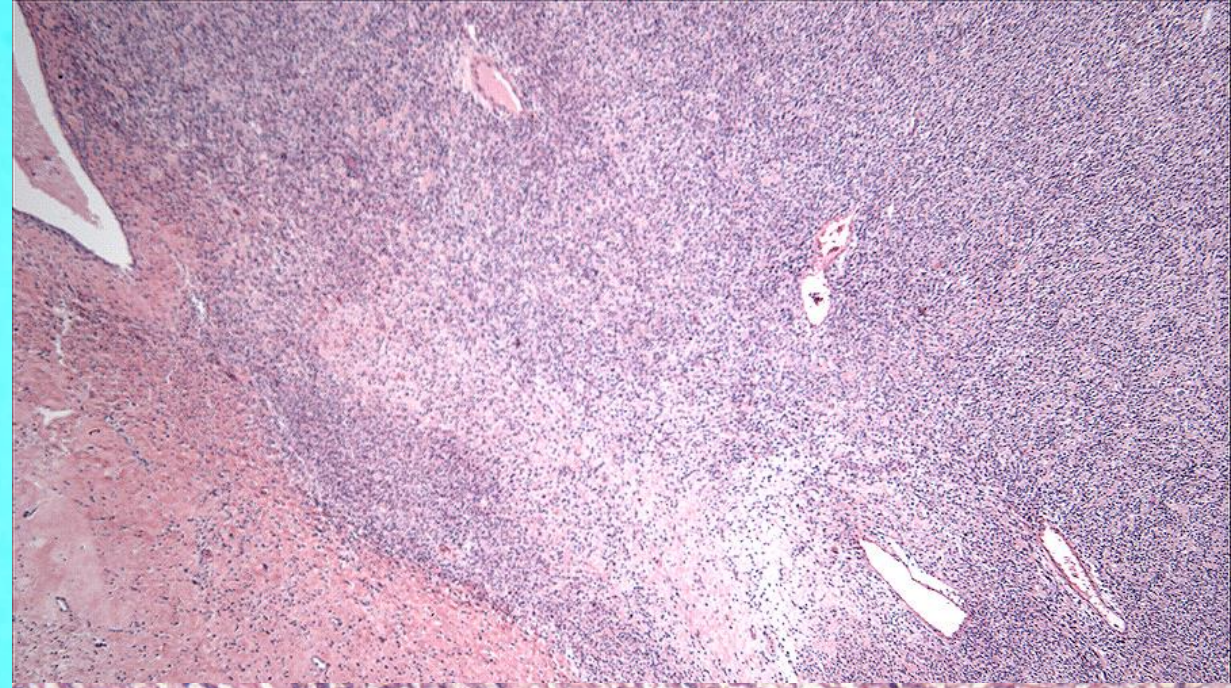

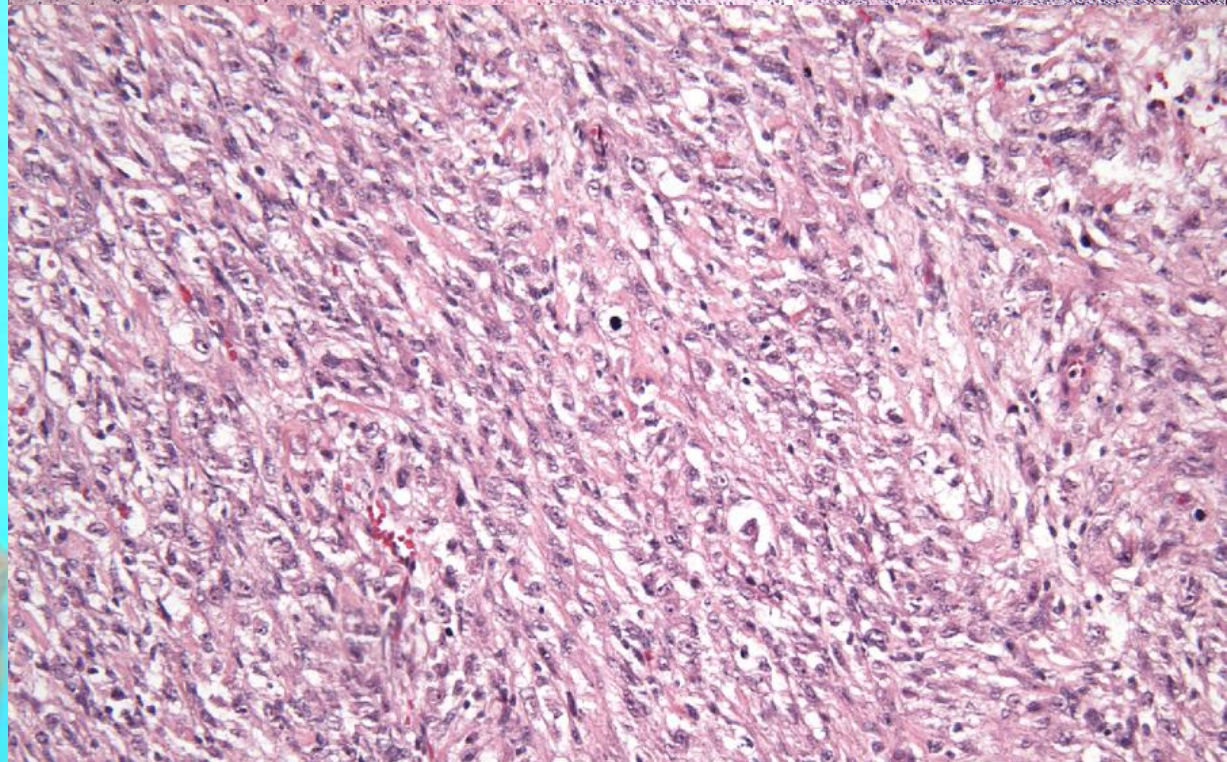

# Case Nine

64-year-old female with a 12 cm tan-white firm intramural mass.

# Diagnosis Case Nine:
# Solitary Fibrous Tumor


- Yang EJ, Howitt BE, Fletcher CDM, Nucci MR. (2018) Solitary fibrous tumour of the female genital tract: a clinicopathological analysis of 25 cases. Histopathology. Apr;72(5):749-759

# Case Ten

39-year-old female with a 2 cm intramural tan-white mass

# Diagnosis Case 10: LAM-like PEComa


- Selenica P, Conlon N, Gonzalez C, Frosina D, Jungbluth AA, Beets-Tan RGH, Rao MK, Zhang Y, Benayed R, Ladanyi M, Solit DB, Chiang S, Hyman DM, Hensley ML, Soslow RA, Weigelt B and Murali R (2021). Genomic Profiling Aids Classification of Diagnostically Challenging Uterine Mesenchymal Tumors With Myomelanocytic Differentiation. Am J Surg Pathol 45(1):77-92.
- Schoolmeester JK, Dao LN, Sukov WR, Wang L, Park KJ, Murali R, Hameed MR and Soslow RA (2015). TFE3 translocation-associated perivascular epithelioid cell neoplasm (PEComa) of the gynecologic tract: morphology, immunophenotype, differential diagnosis. Am J Surg Pathol 39(3):394-404.
- Folpe AL, Mentzel T, Lehr HA, Fisher C, Balzer BL and Weiss SW (2005). Perivascular epithelioid cell neoplasms of soft tissue and gynecologic origin: a clinicopathologic study of 26 cases and review of the literature. Am J Surg Pathol 29(12):1558-1575.
- Vang R and Kempson RL (2002). Perivascular epithelioid cell tumor ('PEComa') of the uterus: a subset of HMB-45-positive epithelioid mesenchymal neoplasms with an uncertain relationship to pure smooth muscle tumors. Am J Surg Pathol 26(1):1-13.



# Case Eleven

40 year old woman with hysterectomy for abnormal uterine bleeding

# Diagnosis Case 11: Lymphangioleiomyomatosis