The British Association of Gynaecological Pathologists

CERVICAL CASES- BAGP TRAINEE MEETING

- W Glenn McCluggage
- Department of Pathology, Belfast Health and Social Care Trust, Belfast, UK

- 7 June 2023

CASE 1

- F 35
- On progestogens
- Presented with postcoital bleeding
- Cervical erosion seen and biopsied

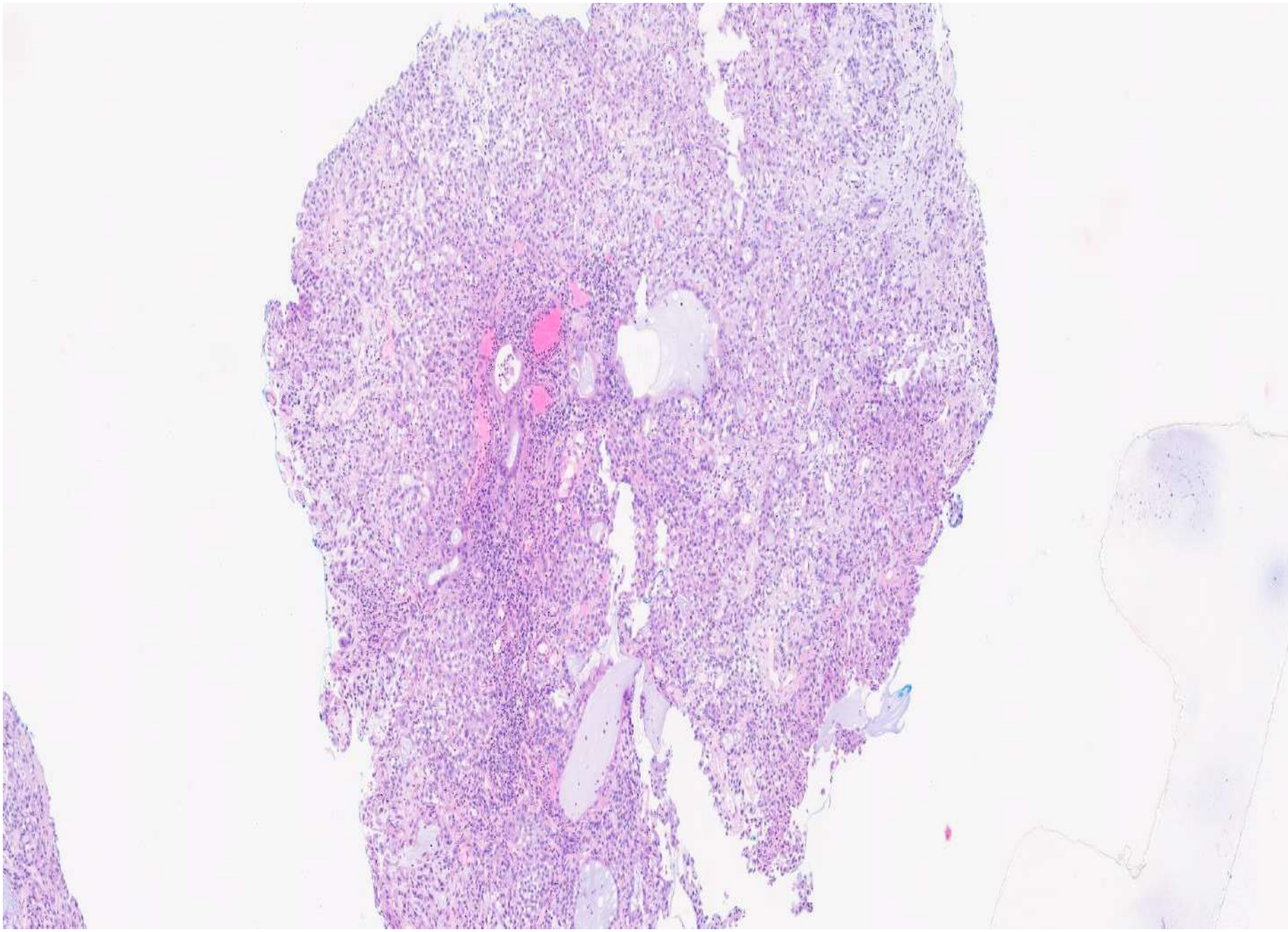

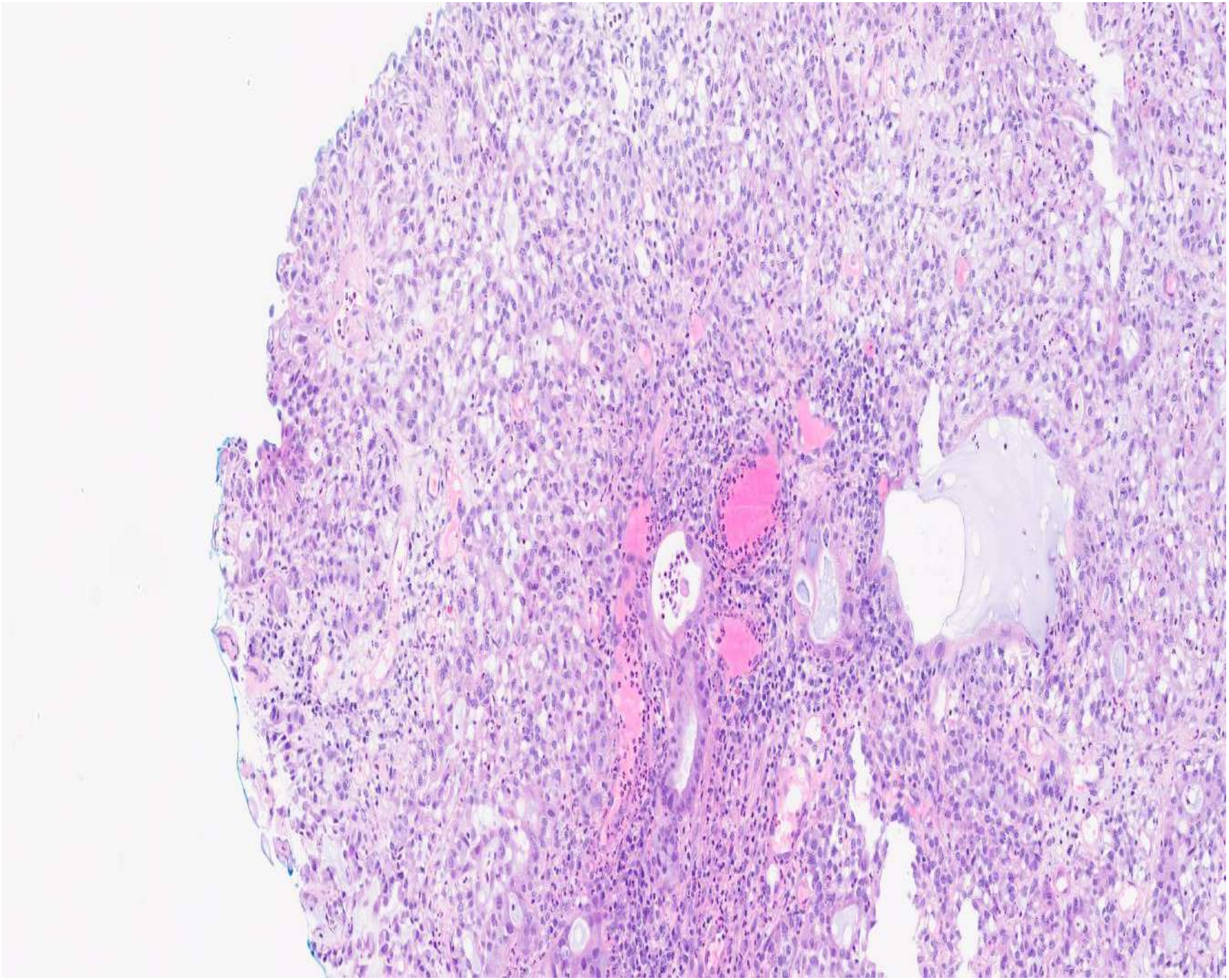

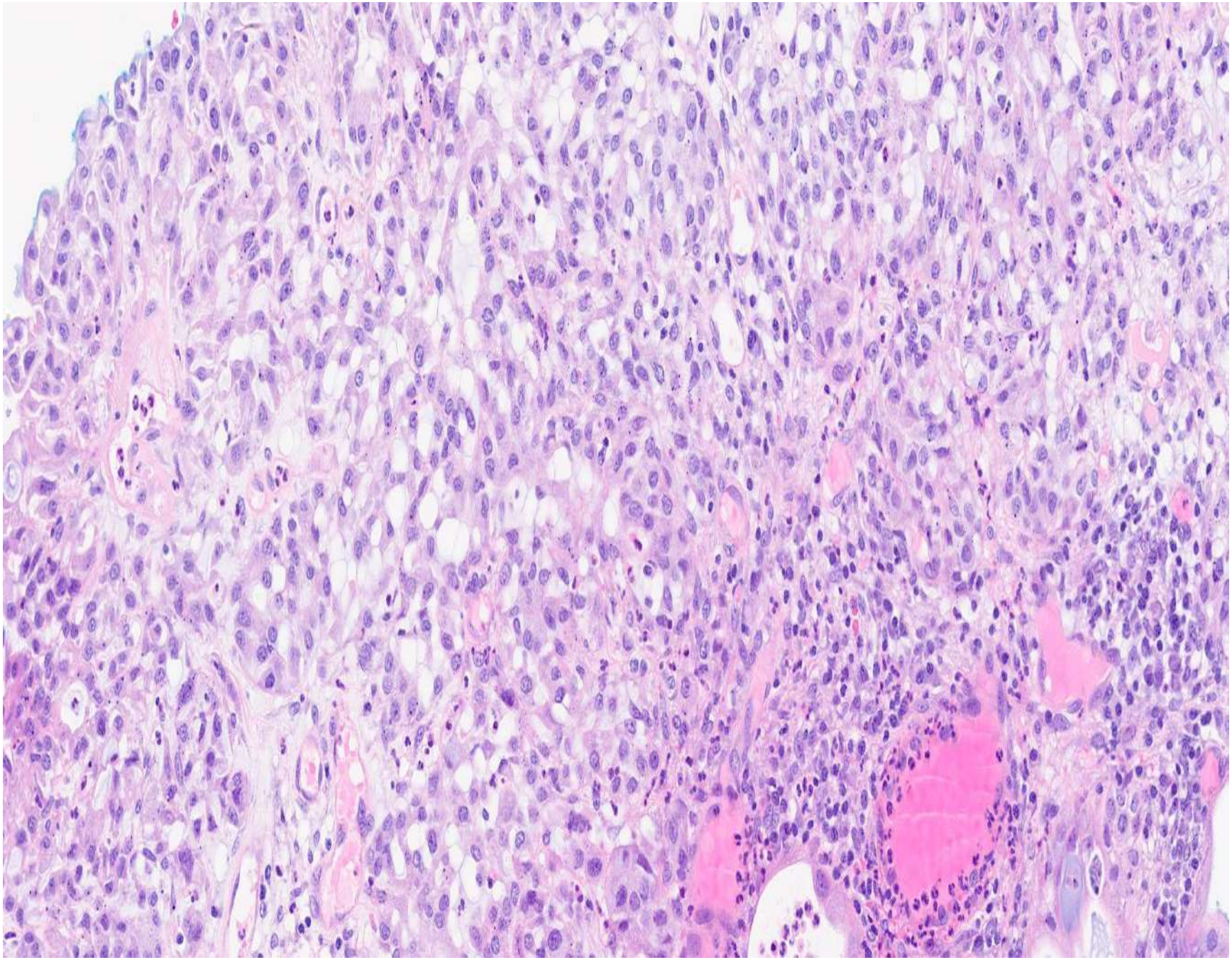

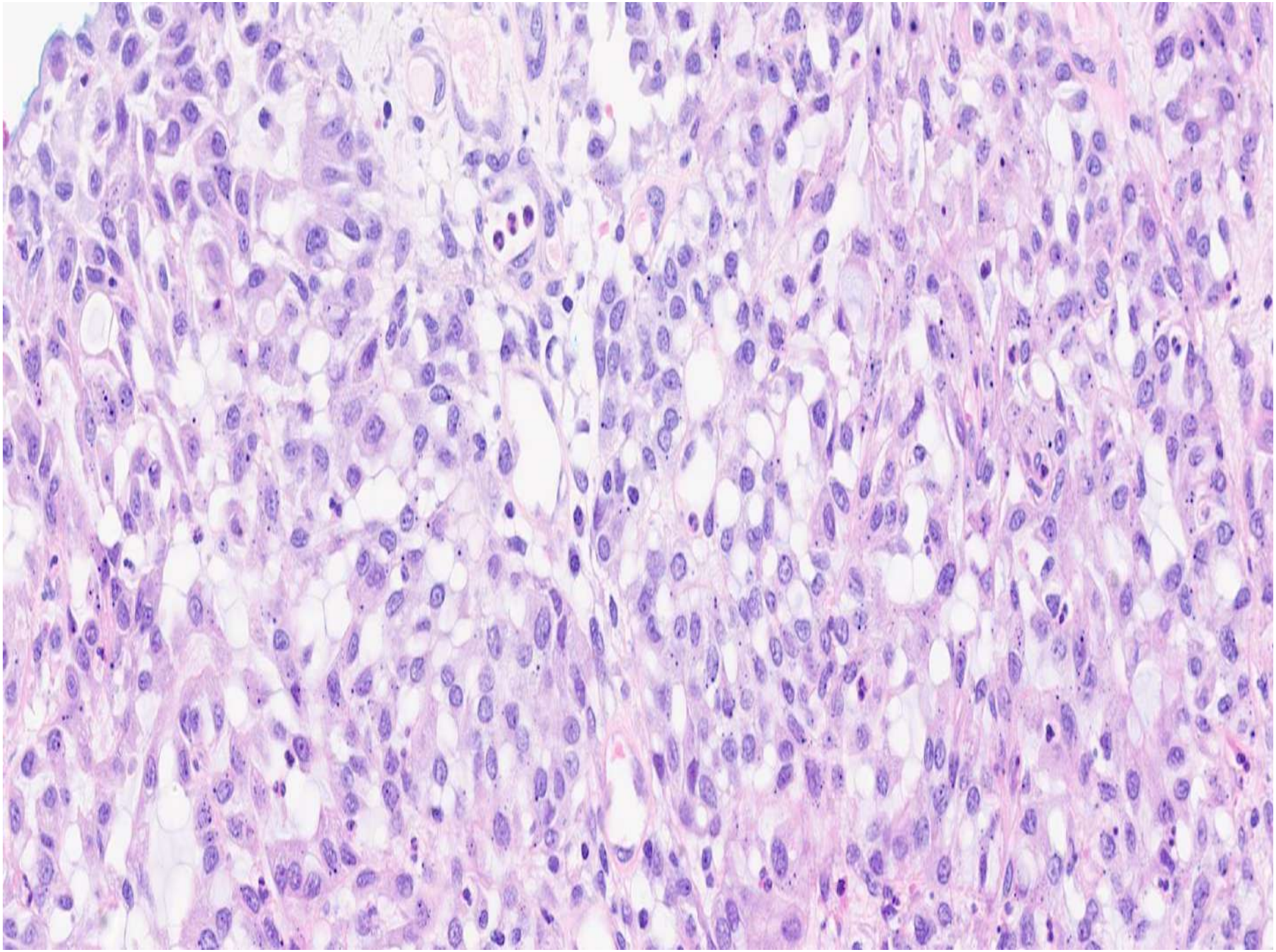

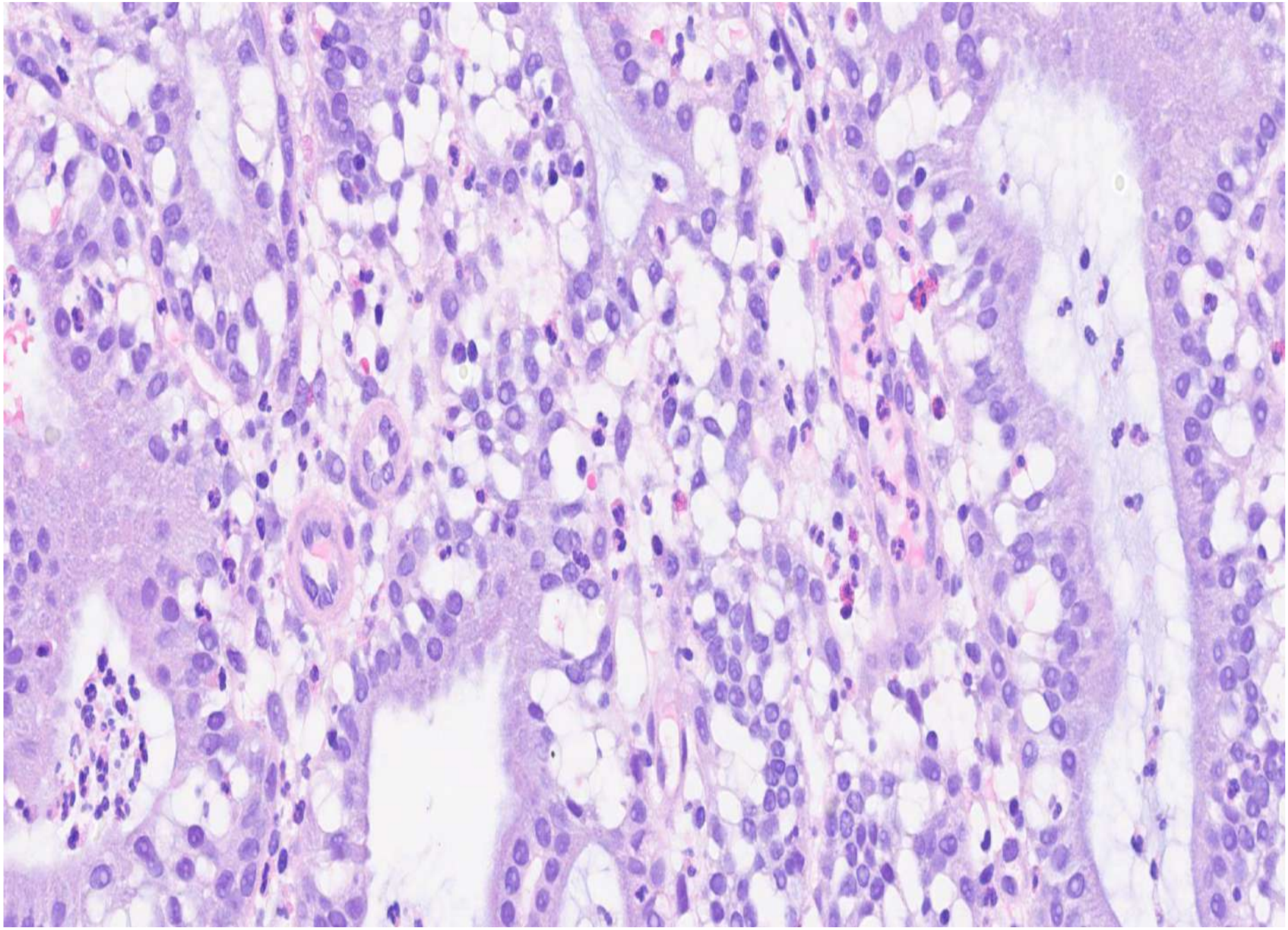

? DIAGNOSIS

DIAGNOSIS- CERVICAL MICROGLANDULAR HYPERPLASIA

- common
- usually, but not invariably, young
- usually, but not invariably, associated with hormonal preparations
- unusual findings- SOLID, STROMAL HYALINISATION, SIGNET-RING CELLS- look for more typical areas as clue to diagnosis
- may mimic endometrioid carcinoma or clear cell carcinoma

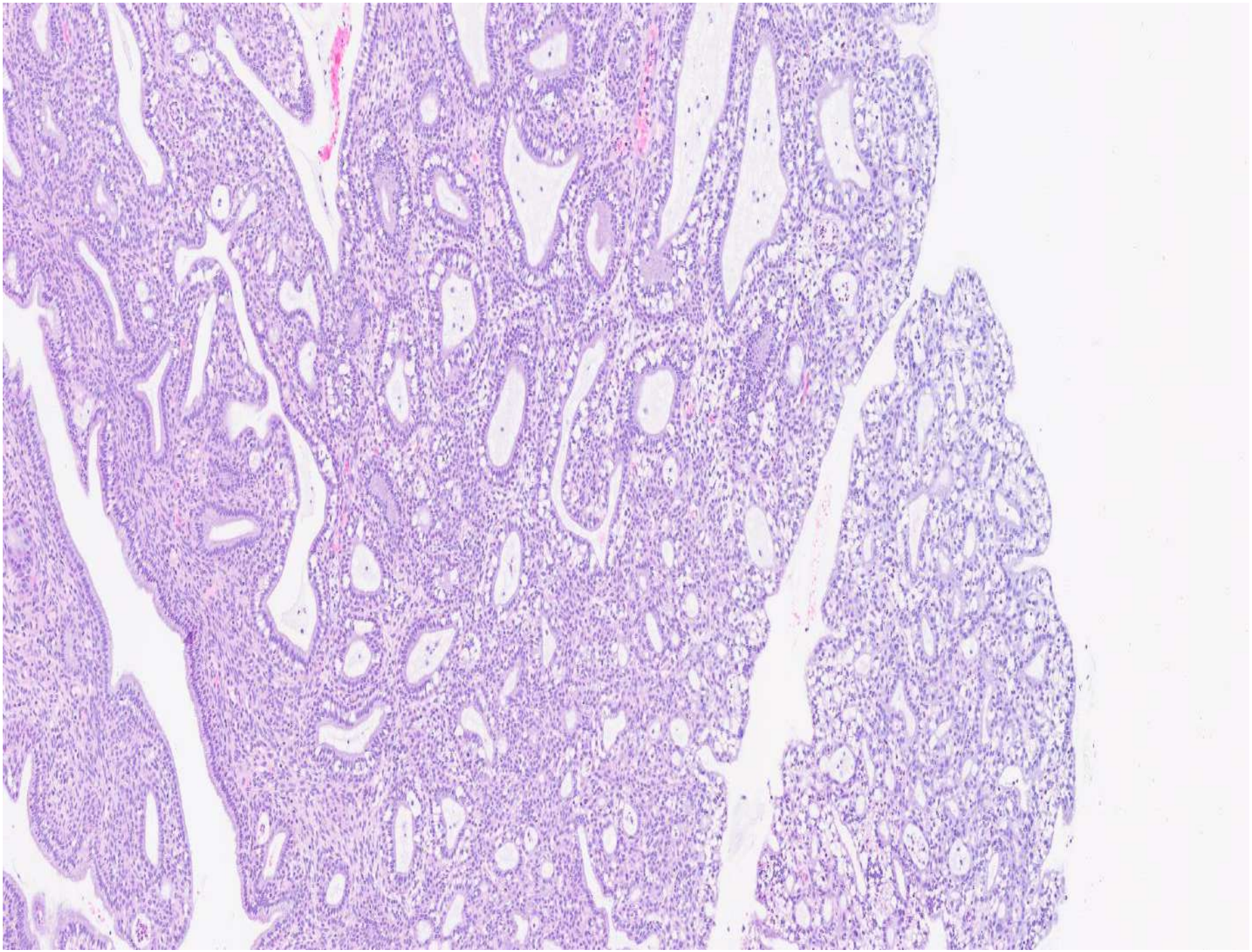

MICROGLANDULAR HYPERPLASIA

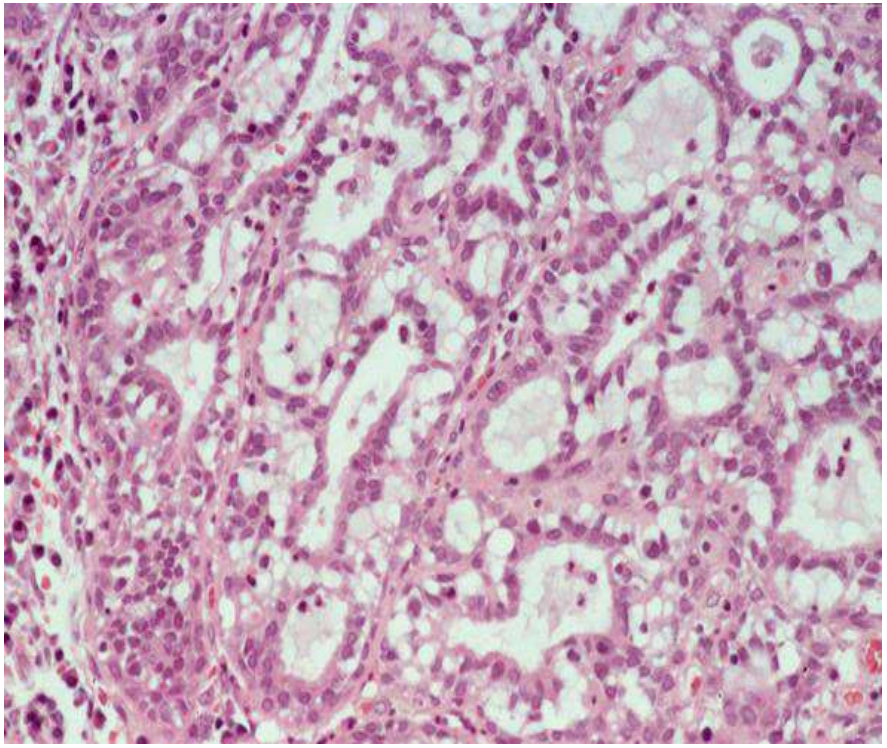

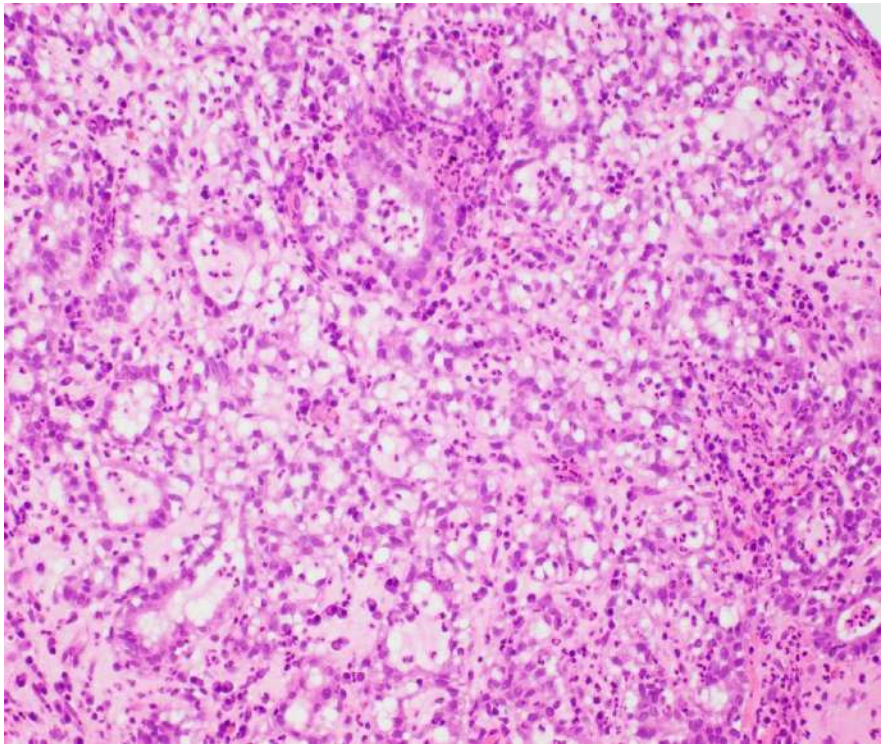

MGH CERVIX- SOLID

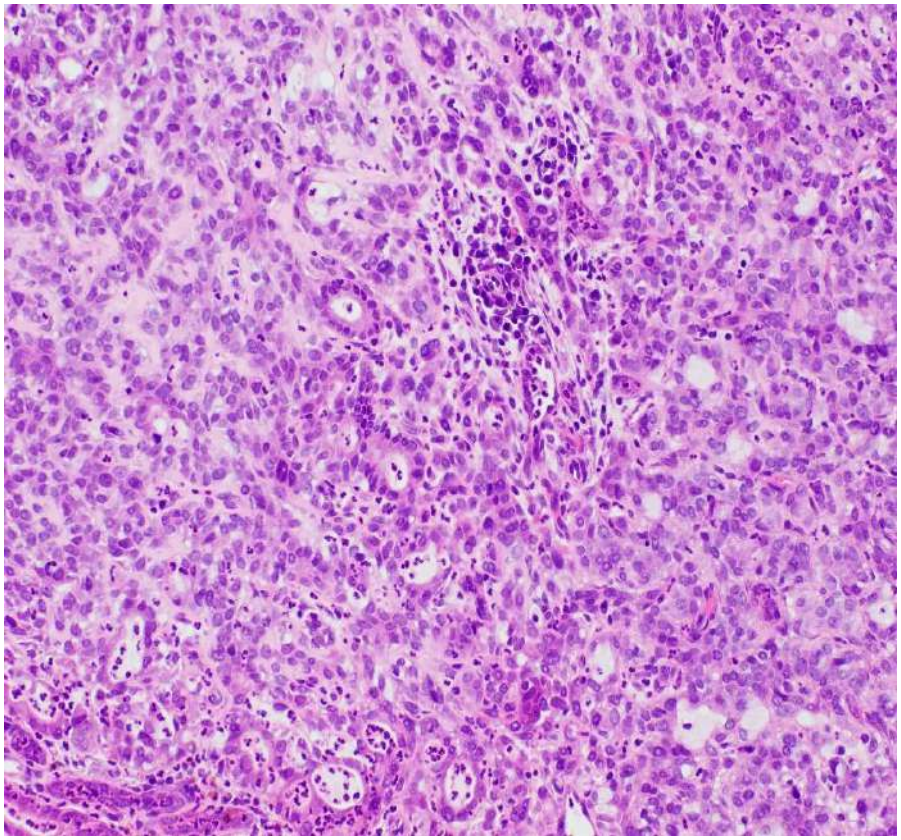

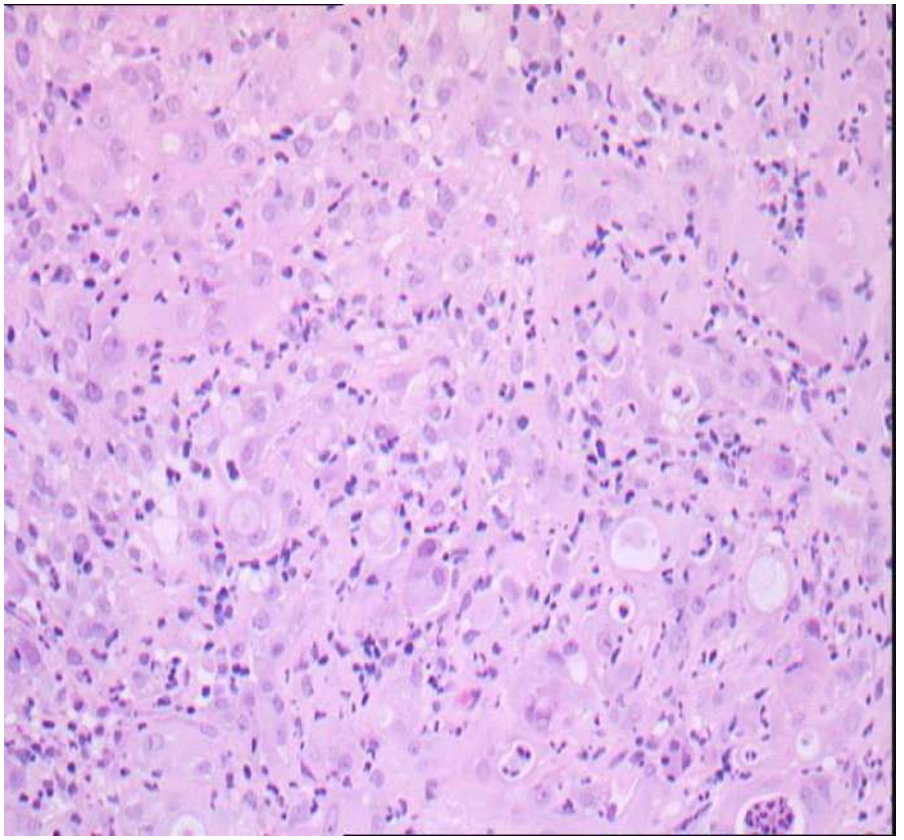

MGH CERVIX- STROMAL HYALINISATION MIMICKING CLEAR CELL CARCINOMA

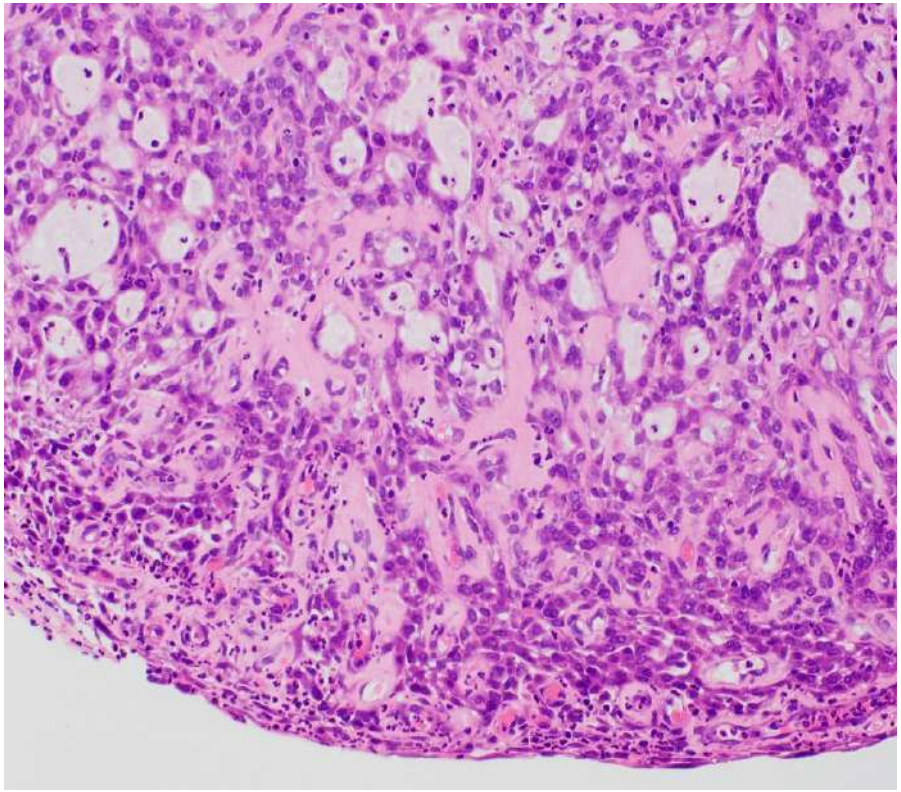

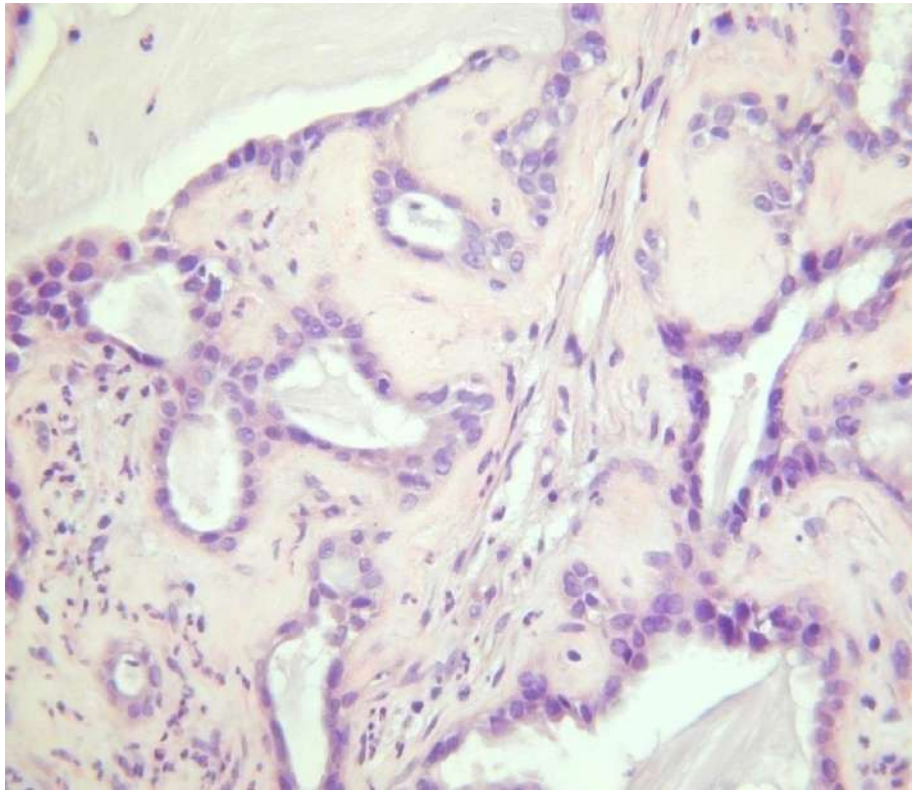

SIGNET RING CELLS

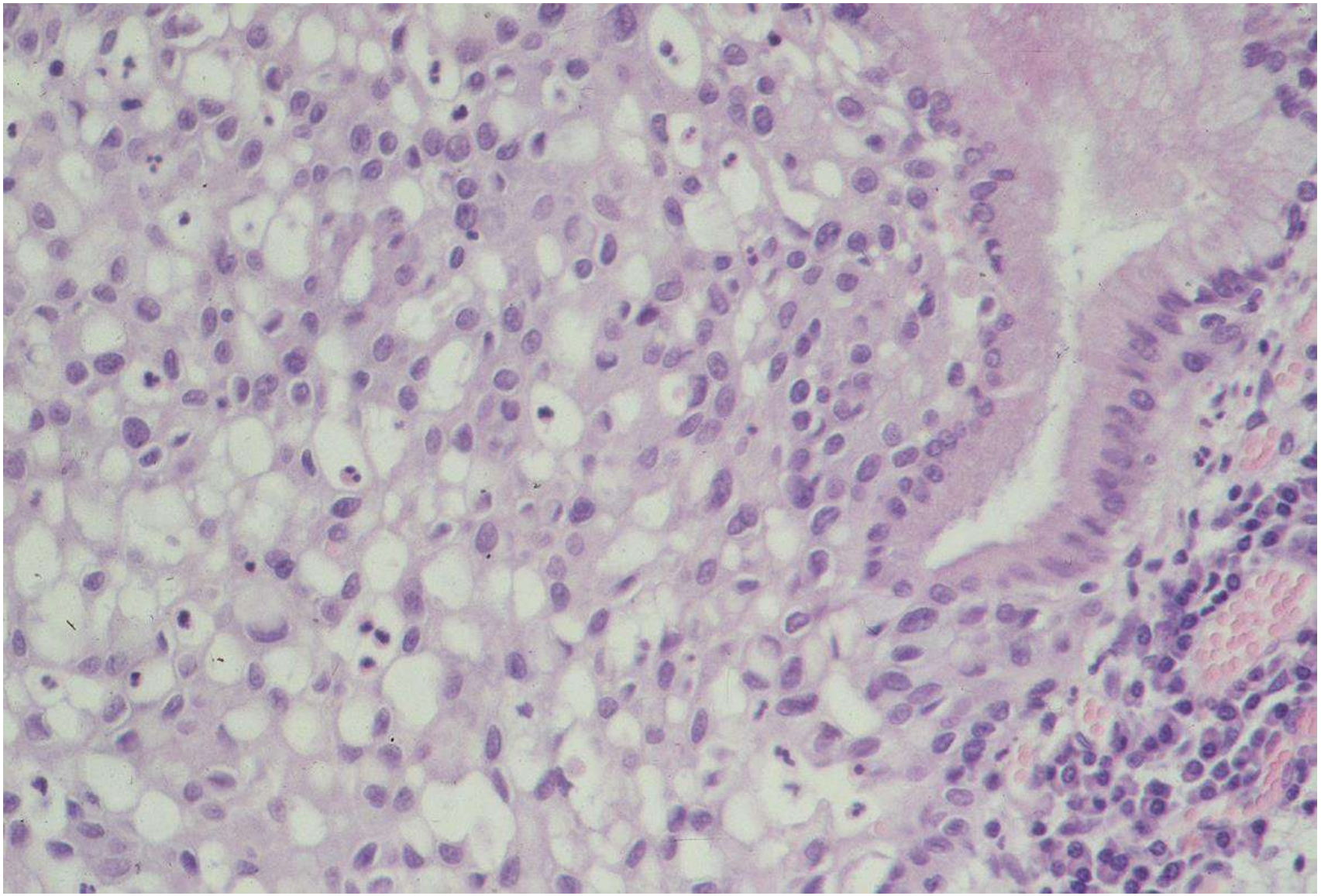

MICROGLANDULAR VARIANT OF ENDOMETRIOID CARCINOMA OF ENDOMETRIUM MIMICKING CERVICAL MGH

- usually on surface of endometrioid or mucinous adenocarcinoma but may be more widespread
- especially likely to be sampled on biopsy
- microglandular architecture
- may closely mimic cervical microglandular hyperplasia
- IMMUNOHISTOCHEMISTRY OF LIMITED VALUE- MANY STUDIES SHOW TOO MUCH OVERLAP (in my opinion, most useful marker is **p16**)
- Recent study (PMID 35347751)- **p63** may also be of value (many more p63 positive cells in MGH, often with linear arrangement)

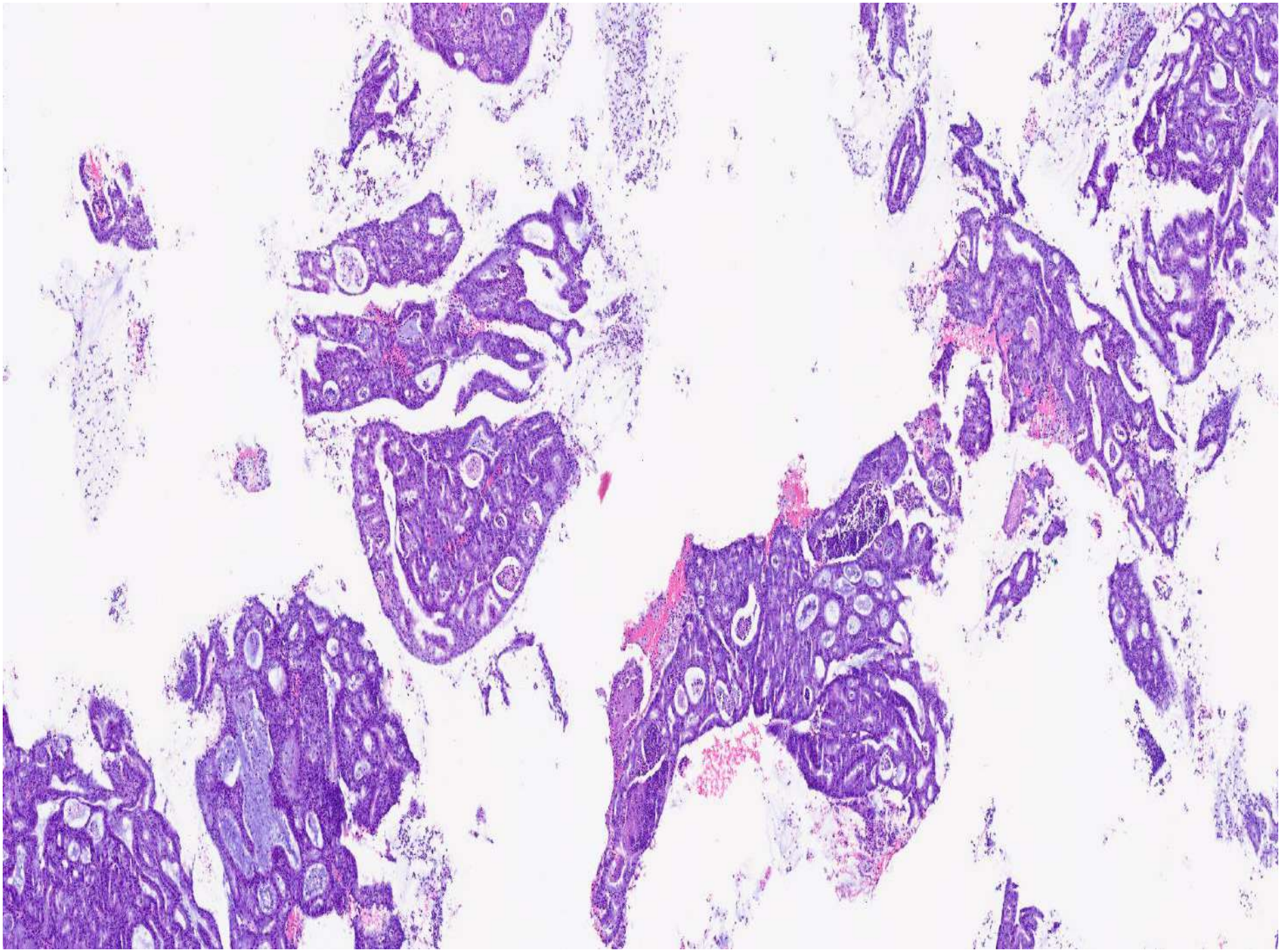

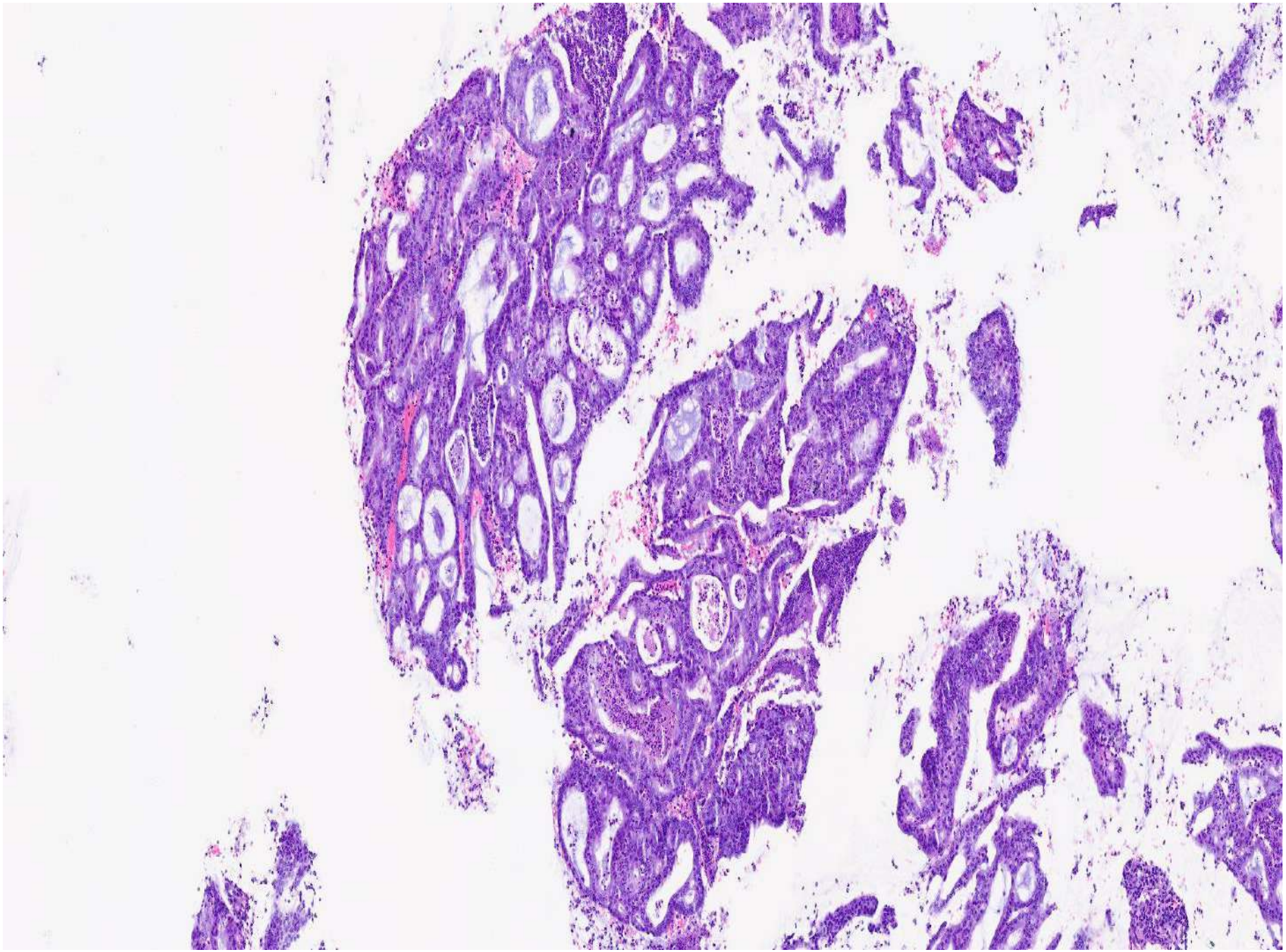

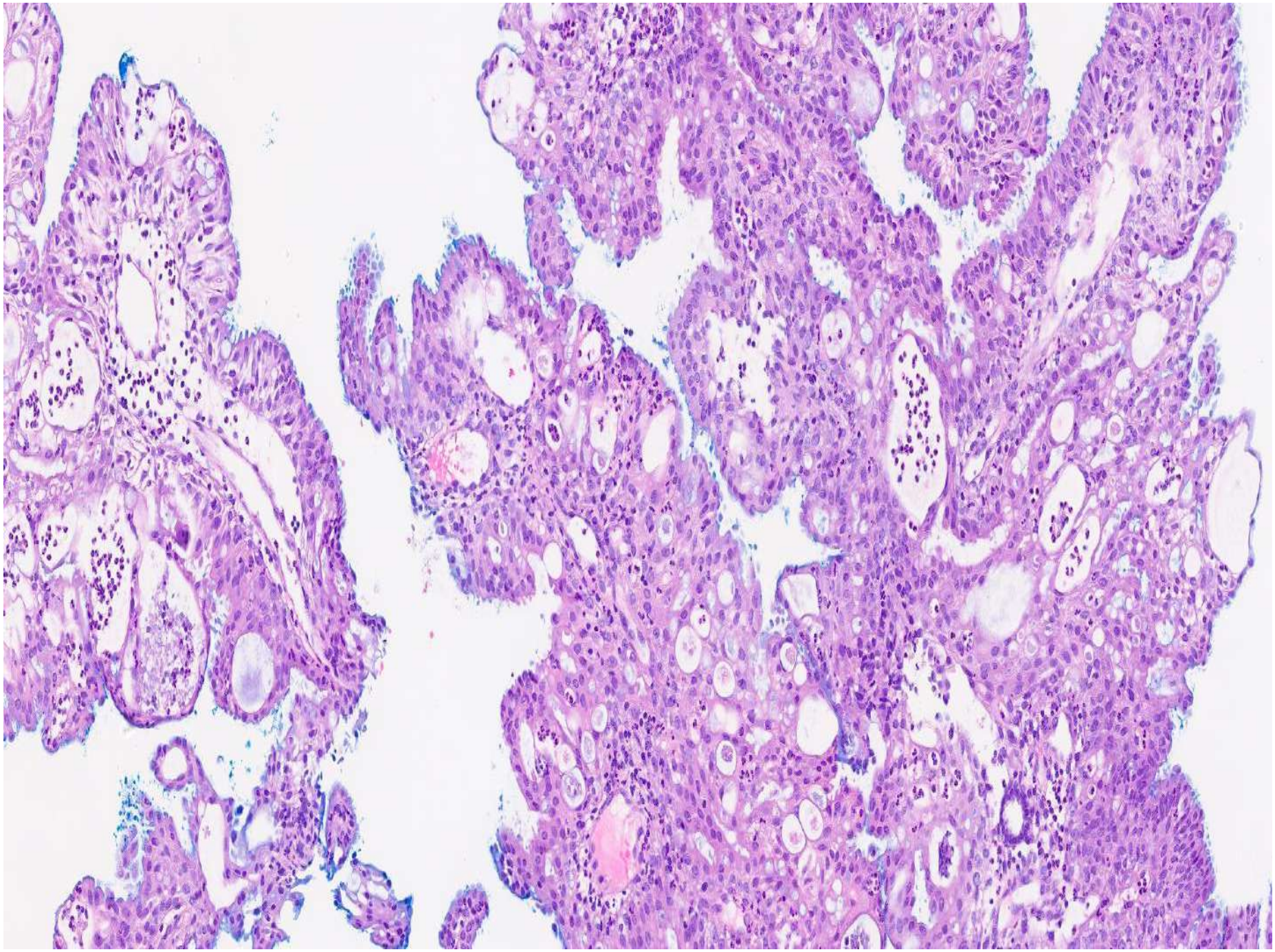

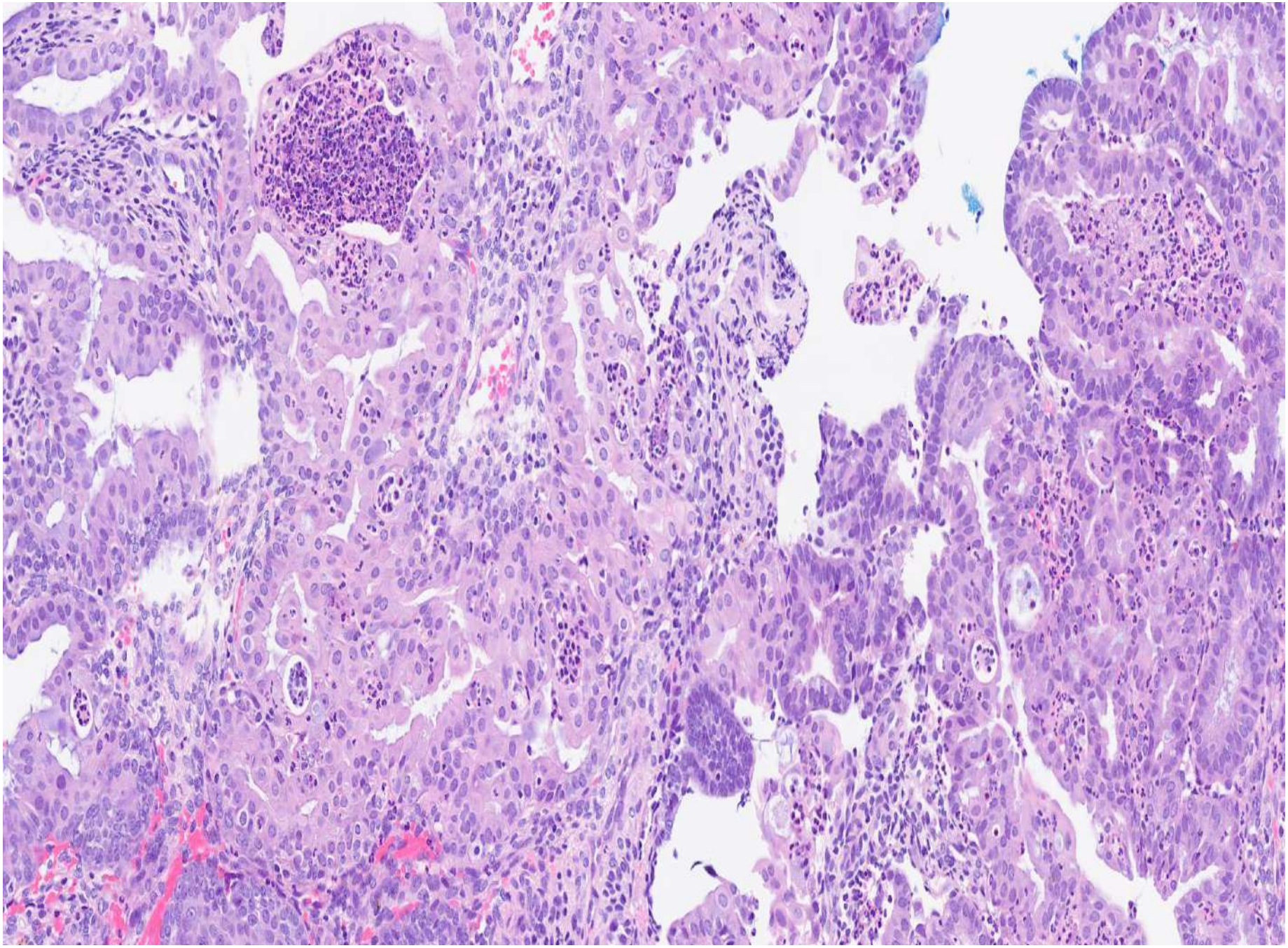

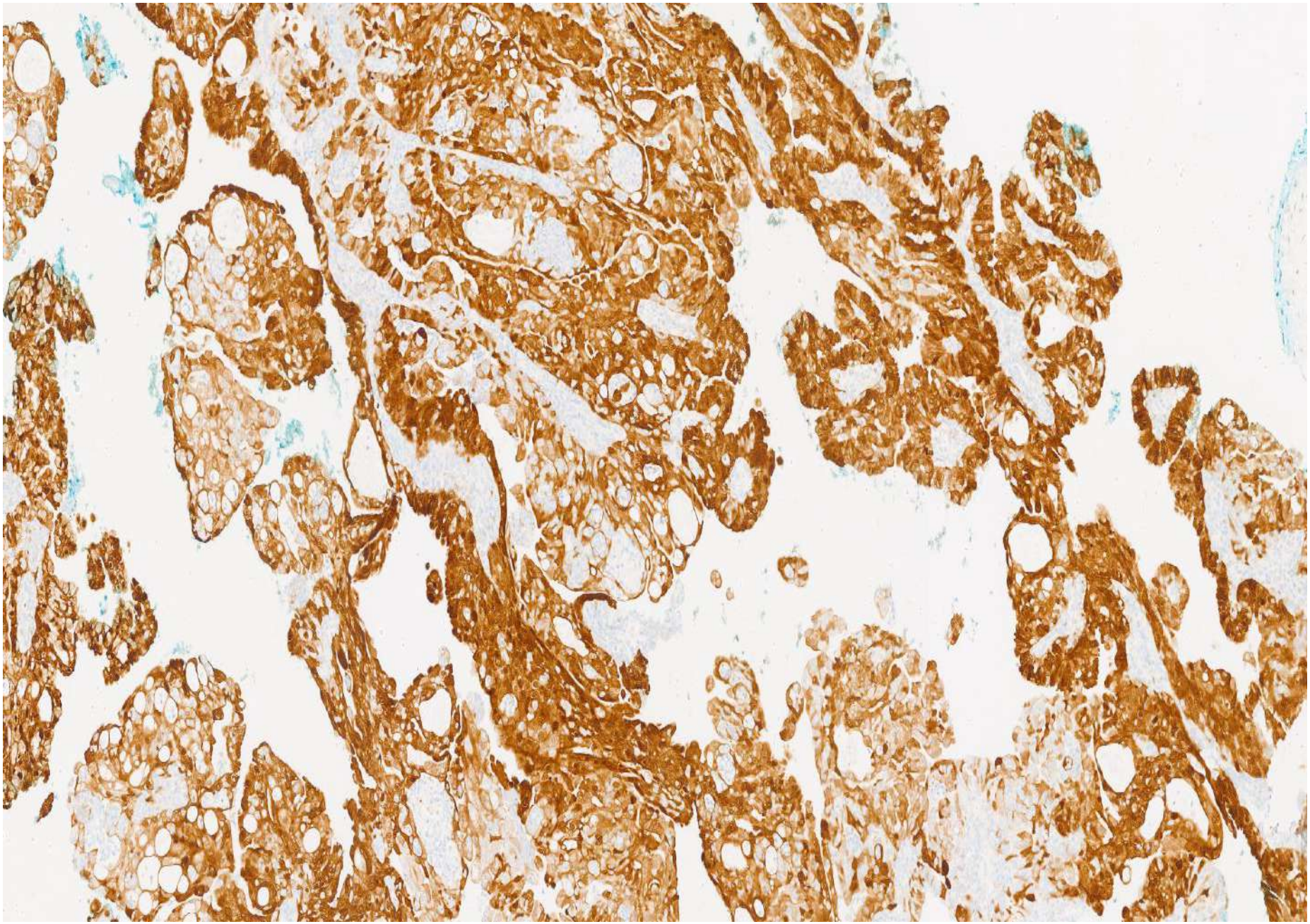

p16

p16 IN 2 MORE CASES OF MICROGLANDULAR FOCI ON SURFACE OF ENDOMETRIOID CARCINOMA

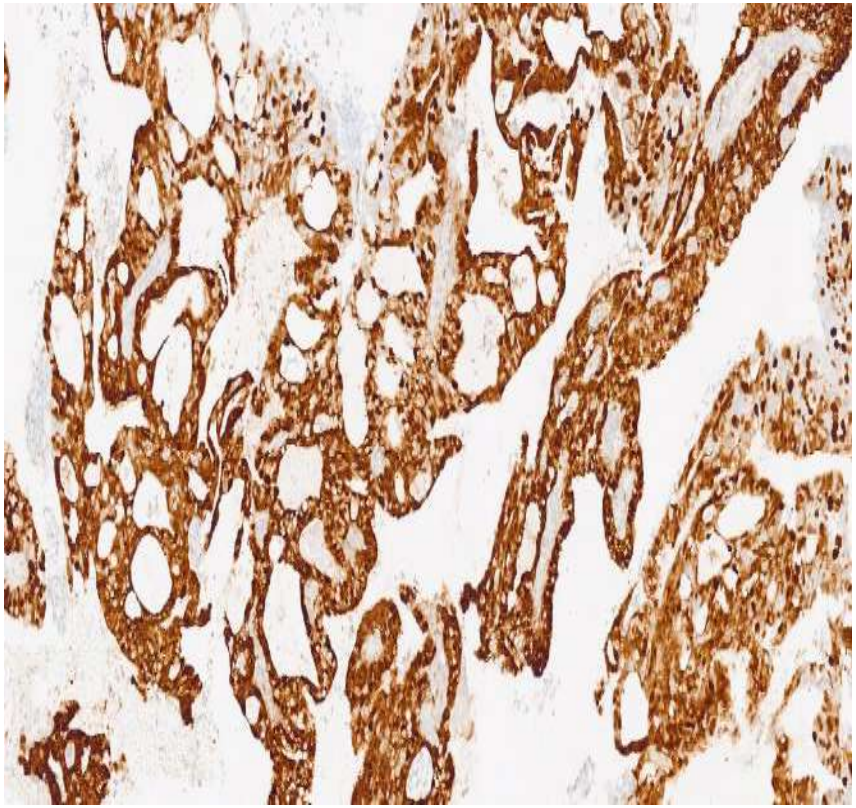

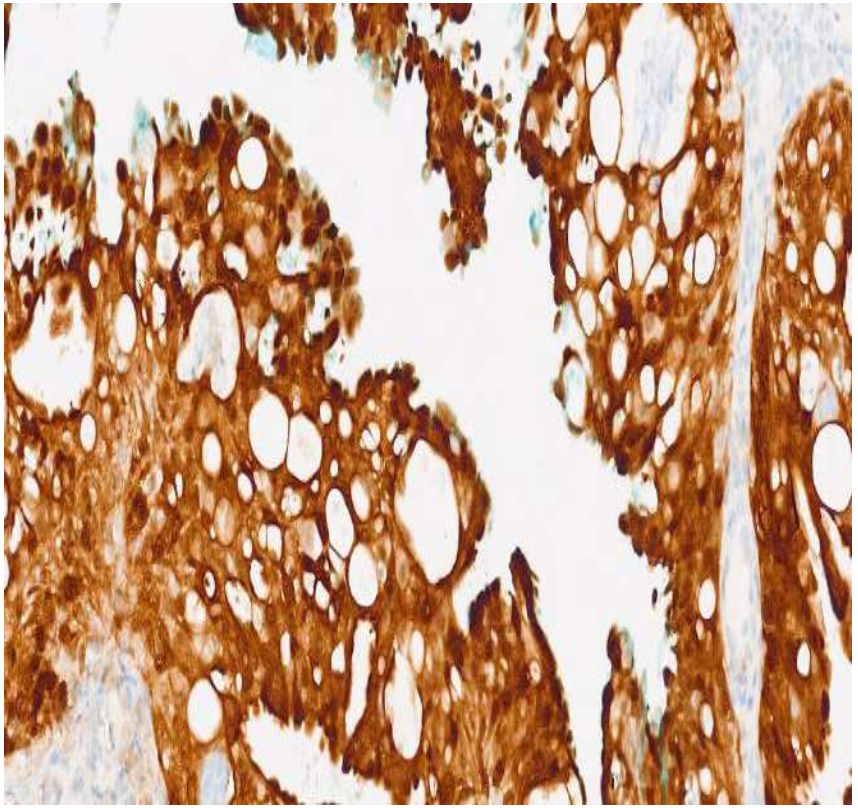

MGH- p63

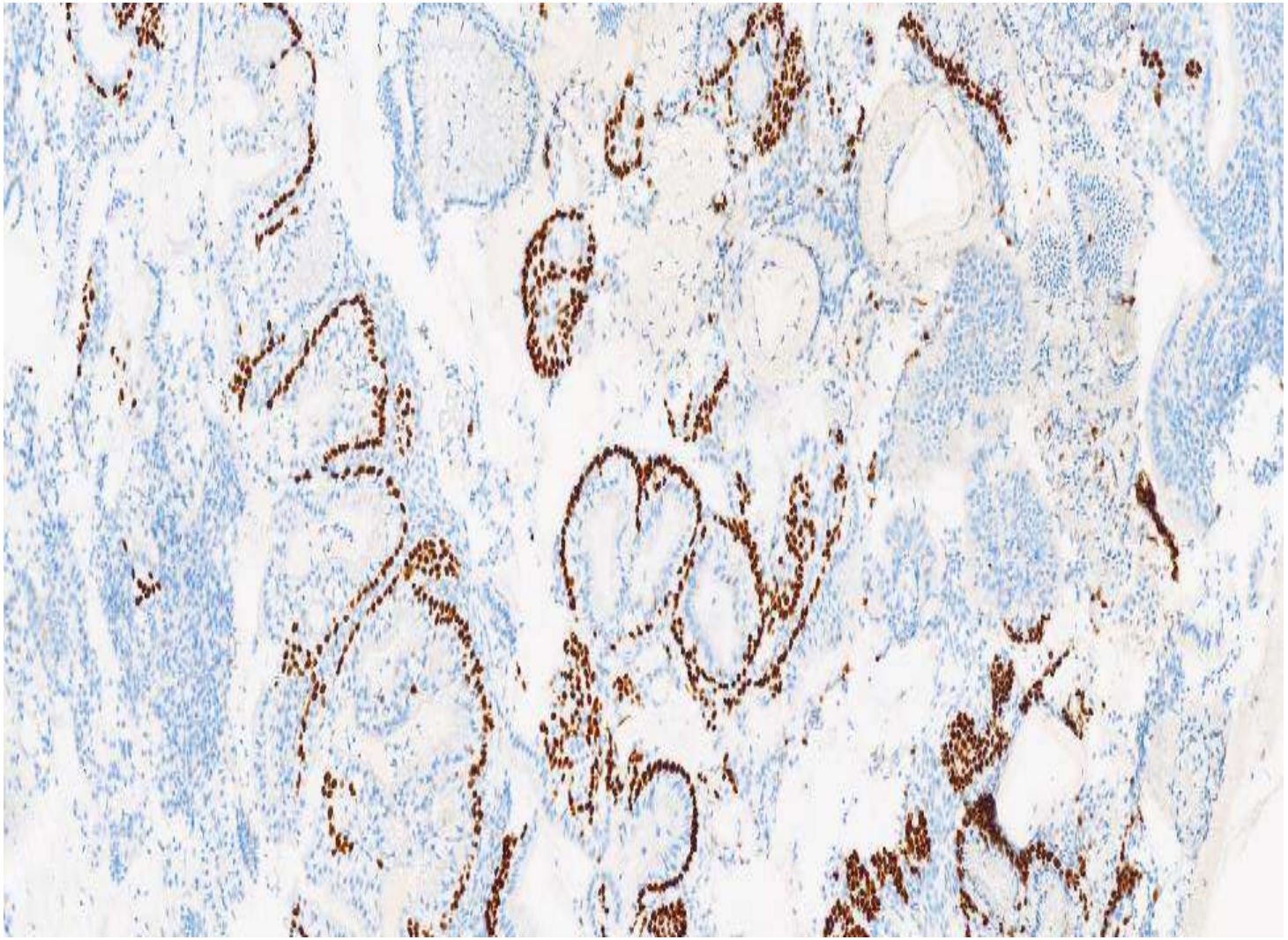

CASE 2

- F 35
- LLETZ for CIN III



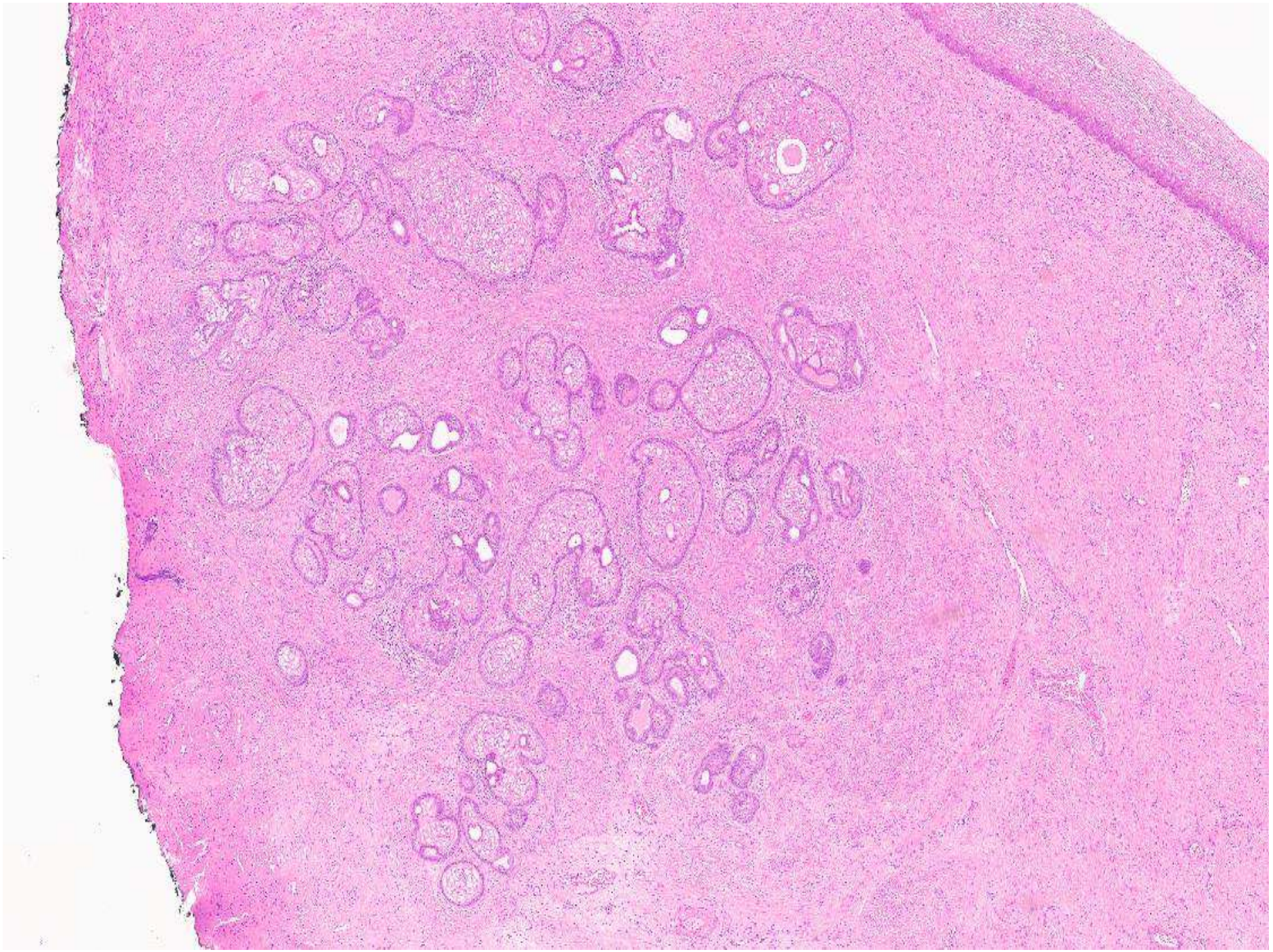

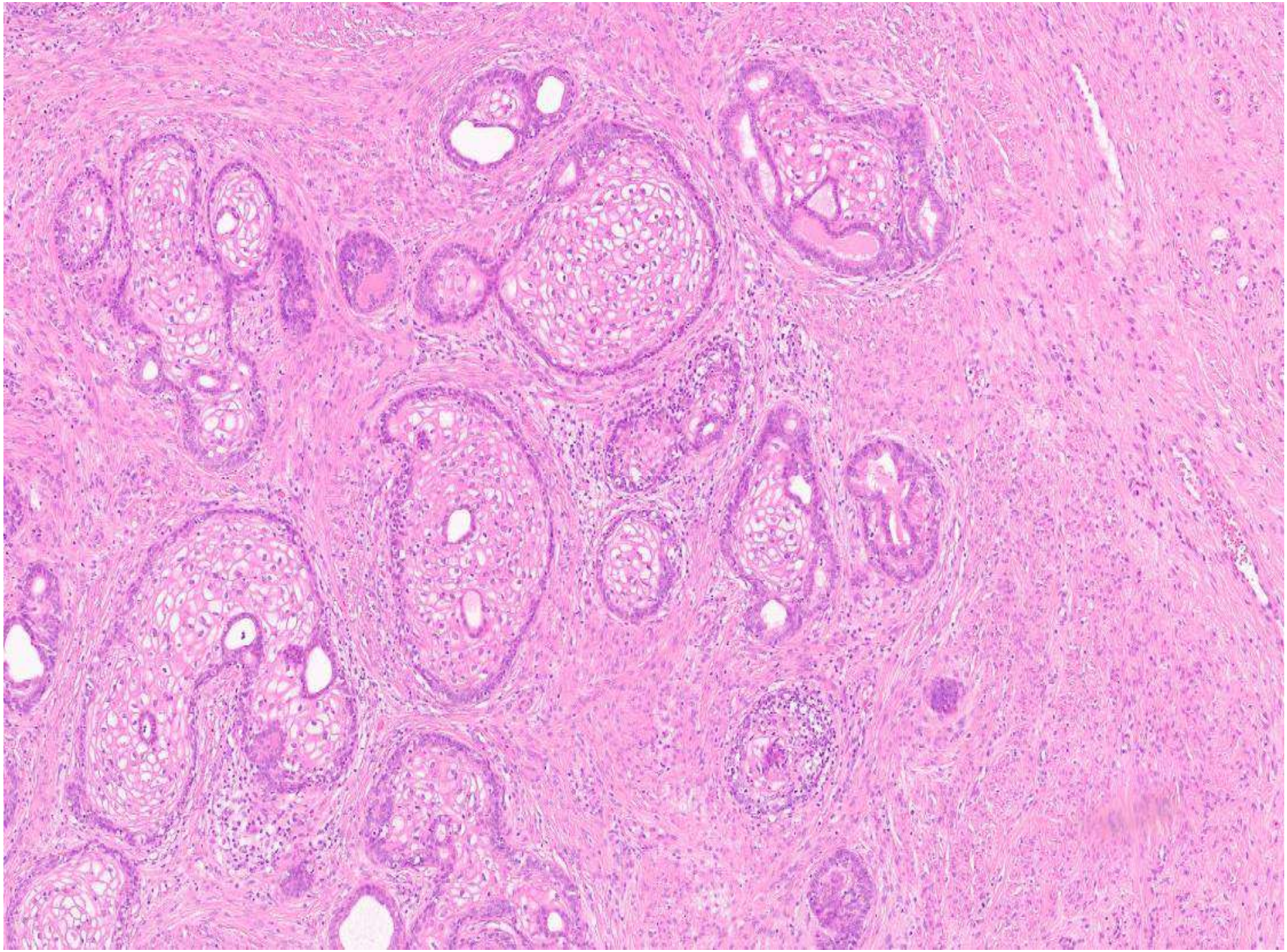

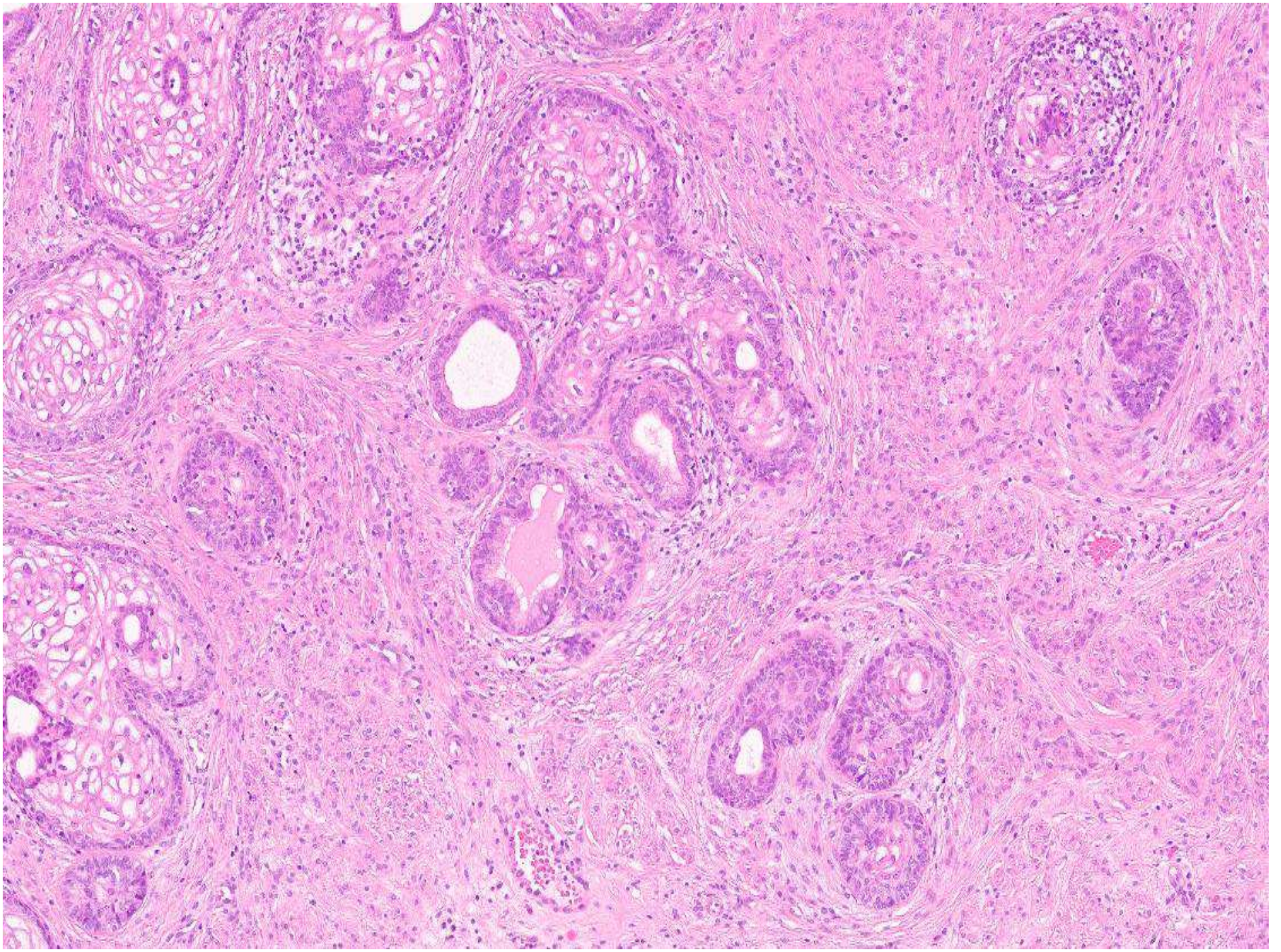

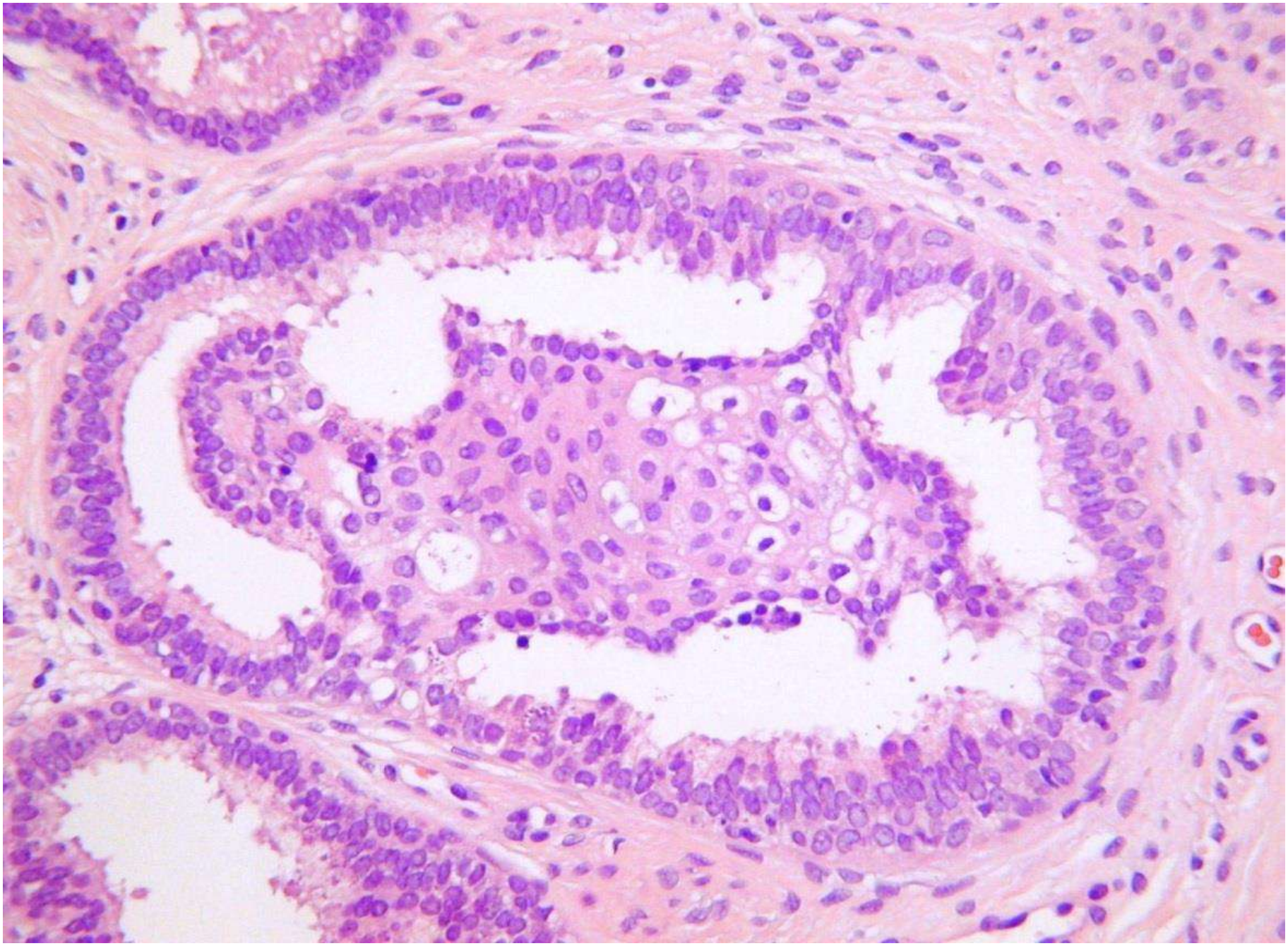

? DIAGNOSIS

IMMUNOHISTOCHEMISTRY

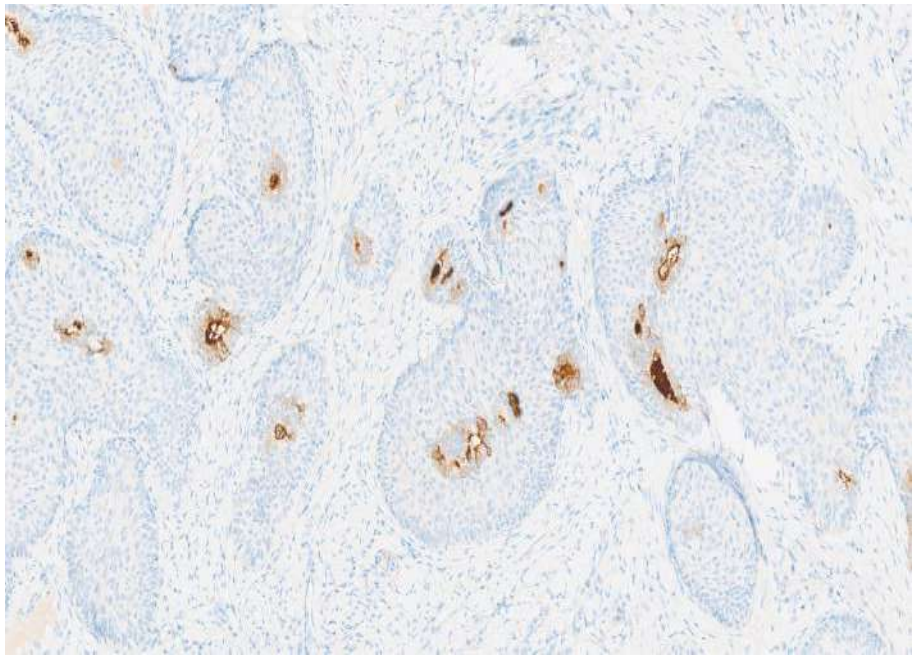

PSAP

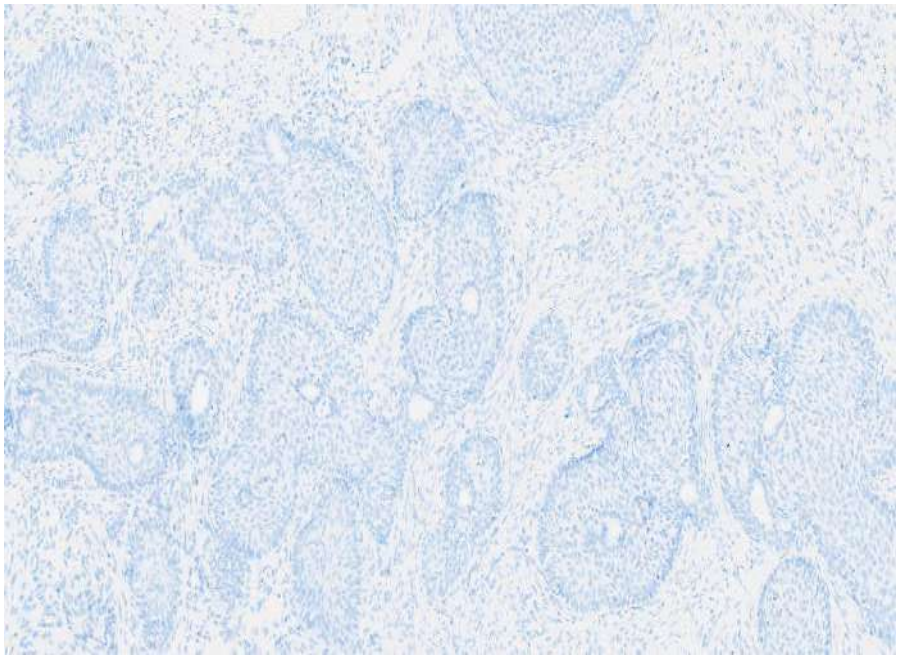

PSA

NKX3.1

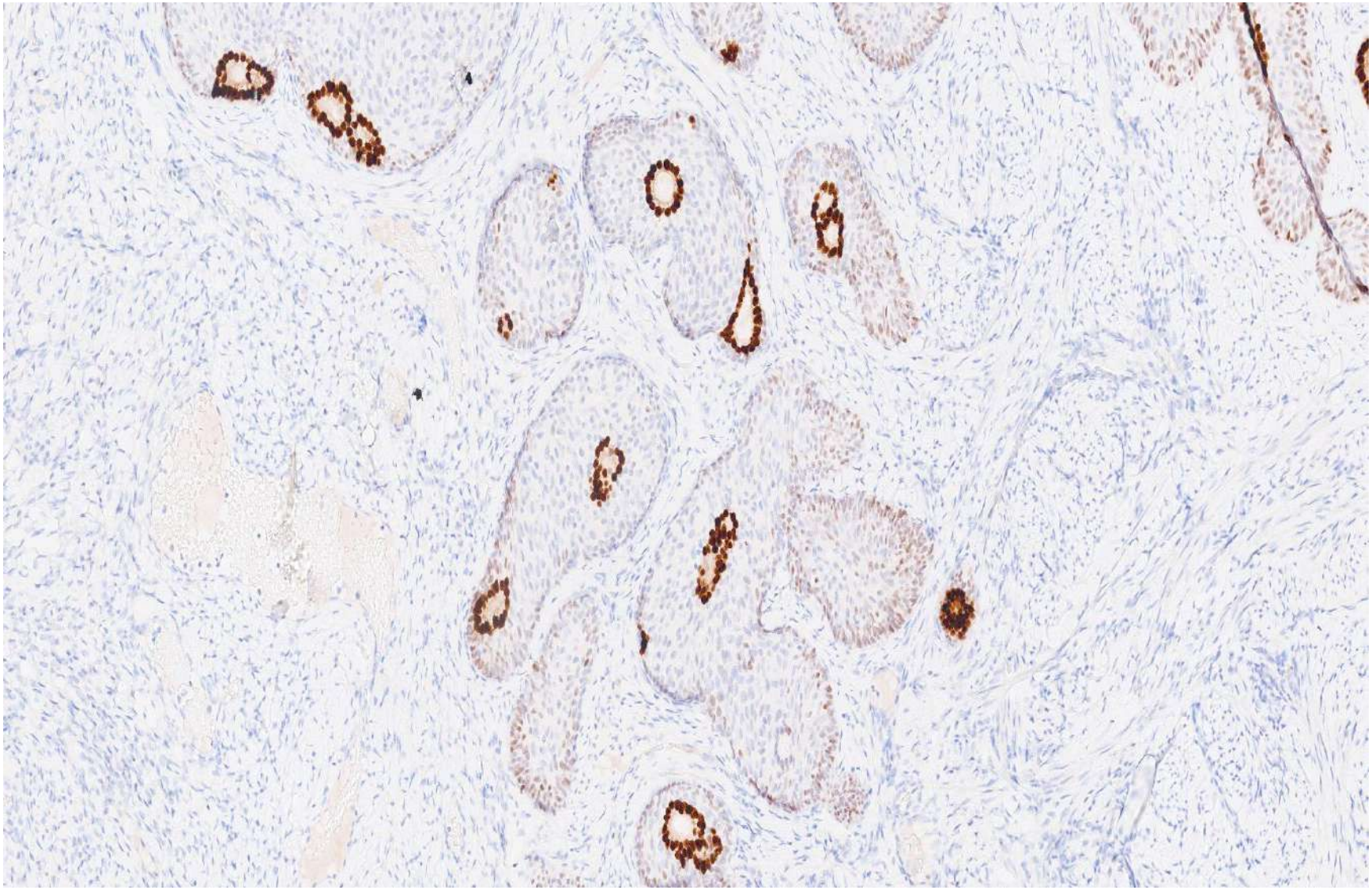

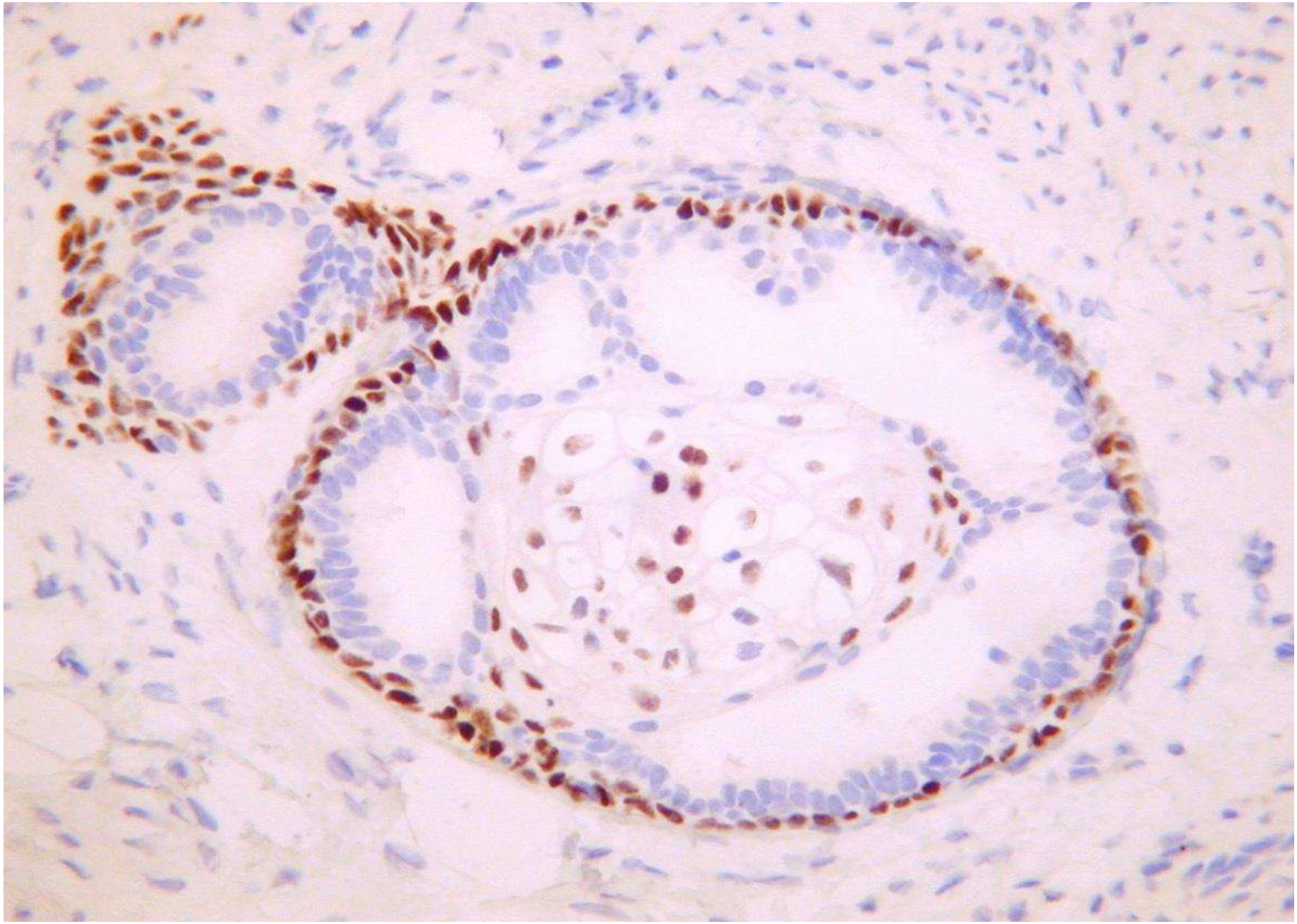

p63

DIAGNOSIS- “ECTOPIC” PROSTATIC TISSUE IN CERVIX

- AJSP 2006;30;209-215
- usually incidental microscopic finding
- ? developmental anomaly, ? metaplasia of endocervical glands (but usually in ectocervical stroma)
- positive with PSA and PSAP (often focal; can be negative; PSAP more likely to be positive than PSA)
- positive with NKX3.1

ECTOPIC PROSTATIC TISSUE CERVIX

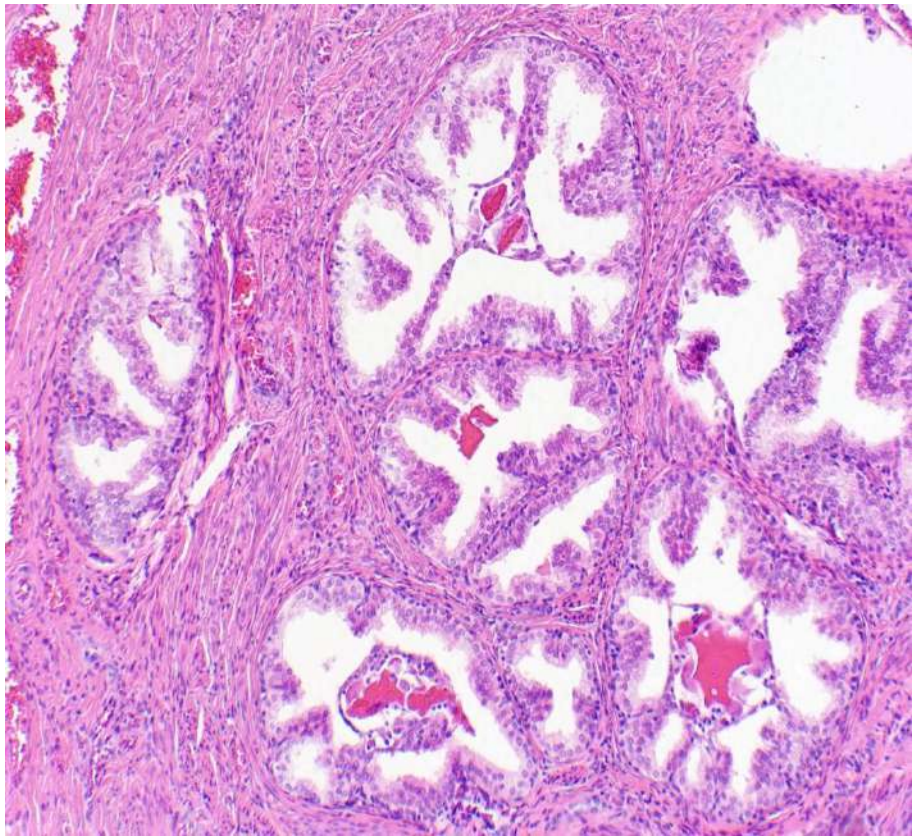

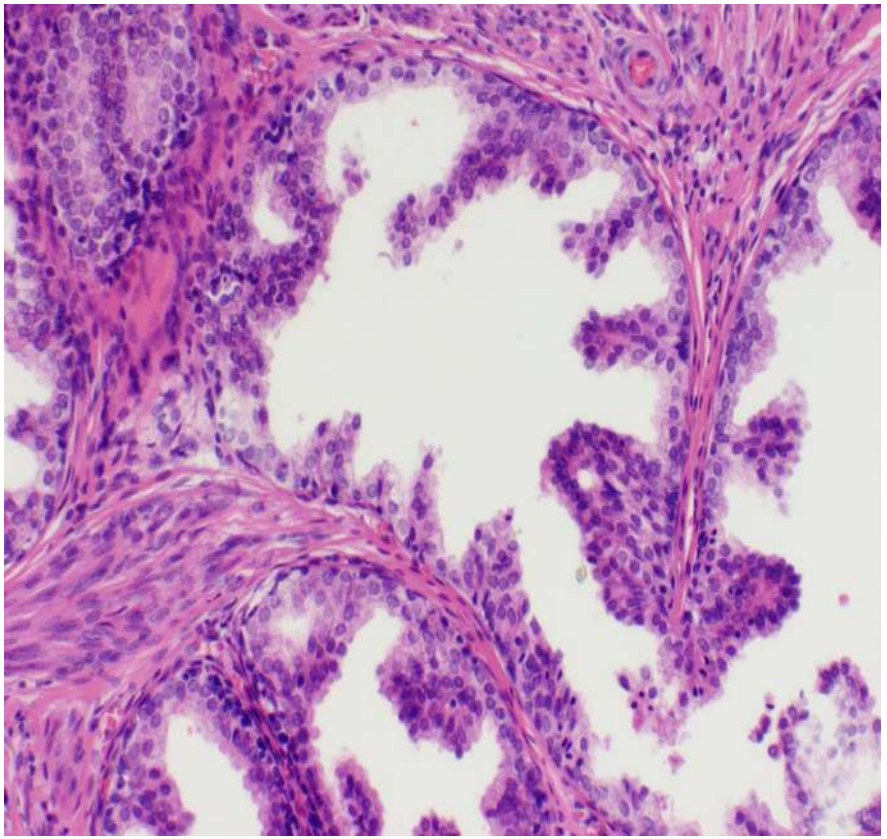

PMID: 17592267

ORIGINAL ARTICLE

Tubulo-squamous Polyp

A Report of Ten Cases of a Distinctive Hitherto Uncharacterized Vaginal Polyp

W. Glenn McCluggage, FRCPath and Robert H. Young, MD†*

Abstract: We report 10 cases of a morphologically distinct vaginal polyp which has hitherto not been characterized. The polyps occurred in women aged 39 to 78 years (most were postmenopausal) and were from 1.0 to 3.0 cm. Most of whose

Key Words: vagina, polyp, immunohistochemistry, prostatic acid phosphatase, prostate-specific antigen, differential diagnosis

(*Am J Surg Pathol* 2007;31:1013–1019)

TUBULOSQUAMOUS POLYP OF VAGINA (AJSP 2007;31;1013-1019)

- characteristic vaginal polyp
- mostly in upper vagina

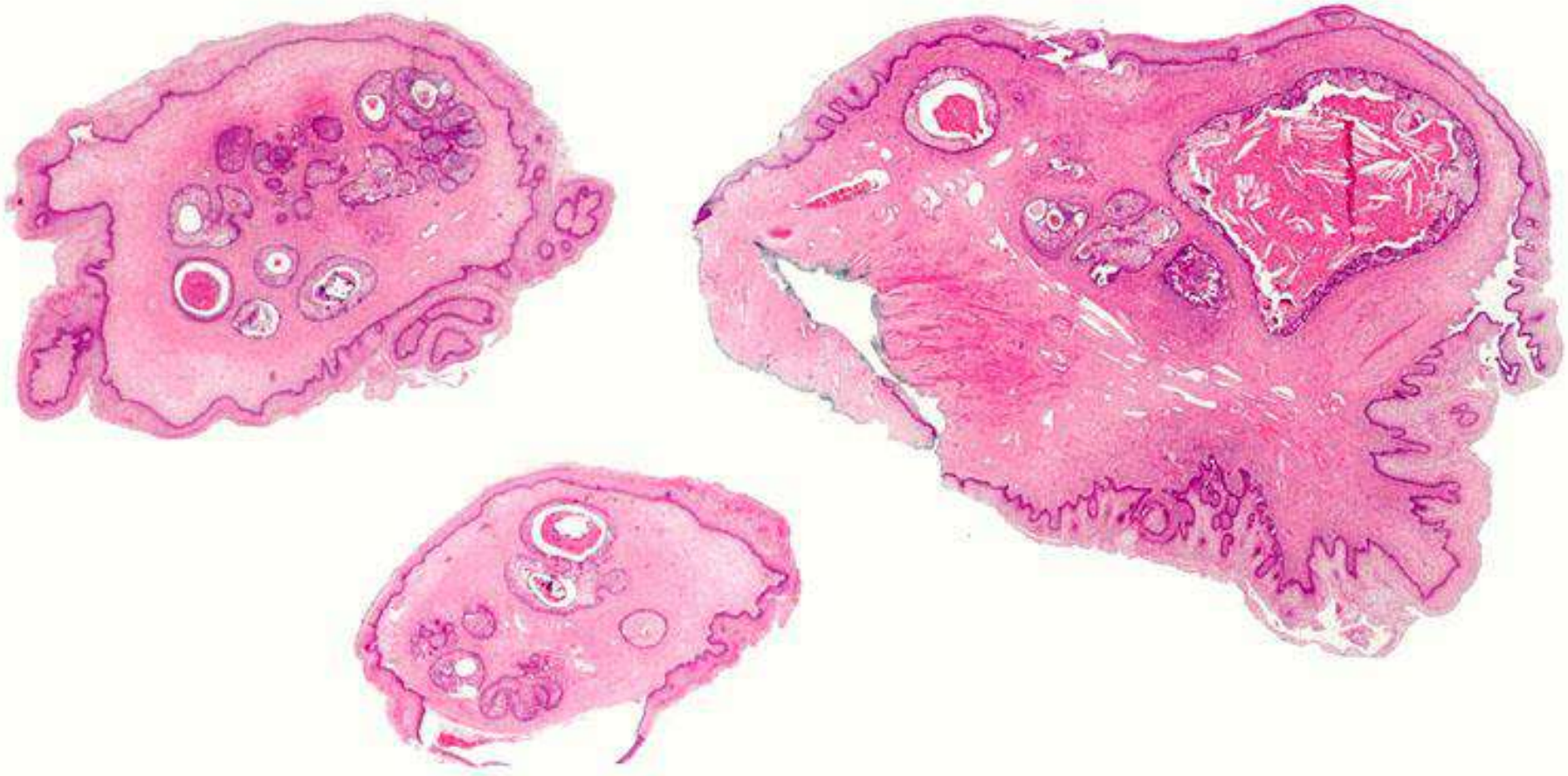



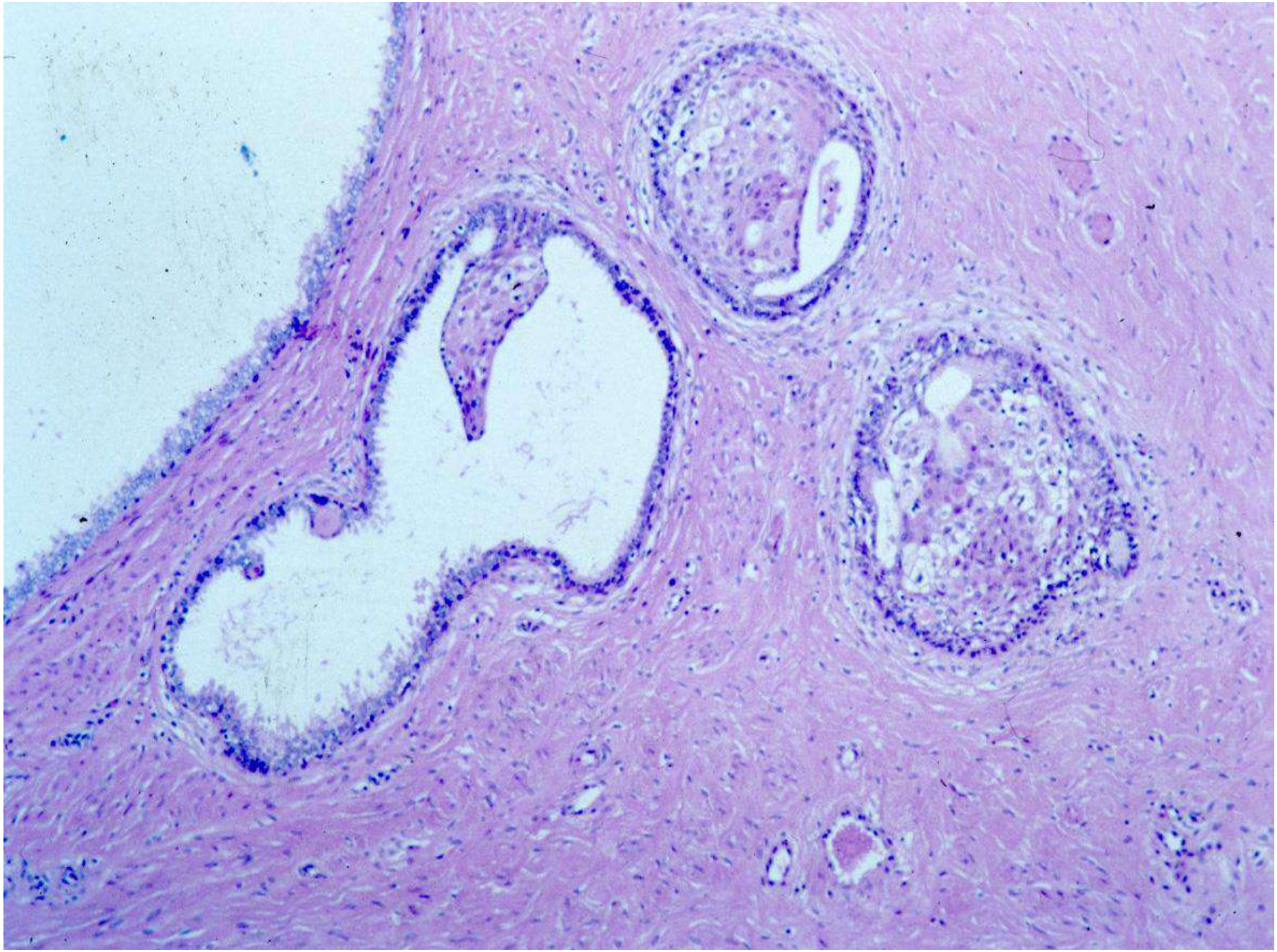

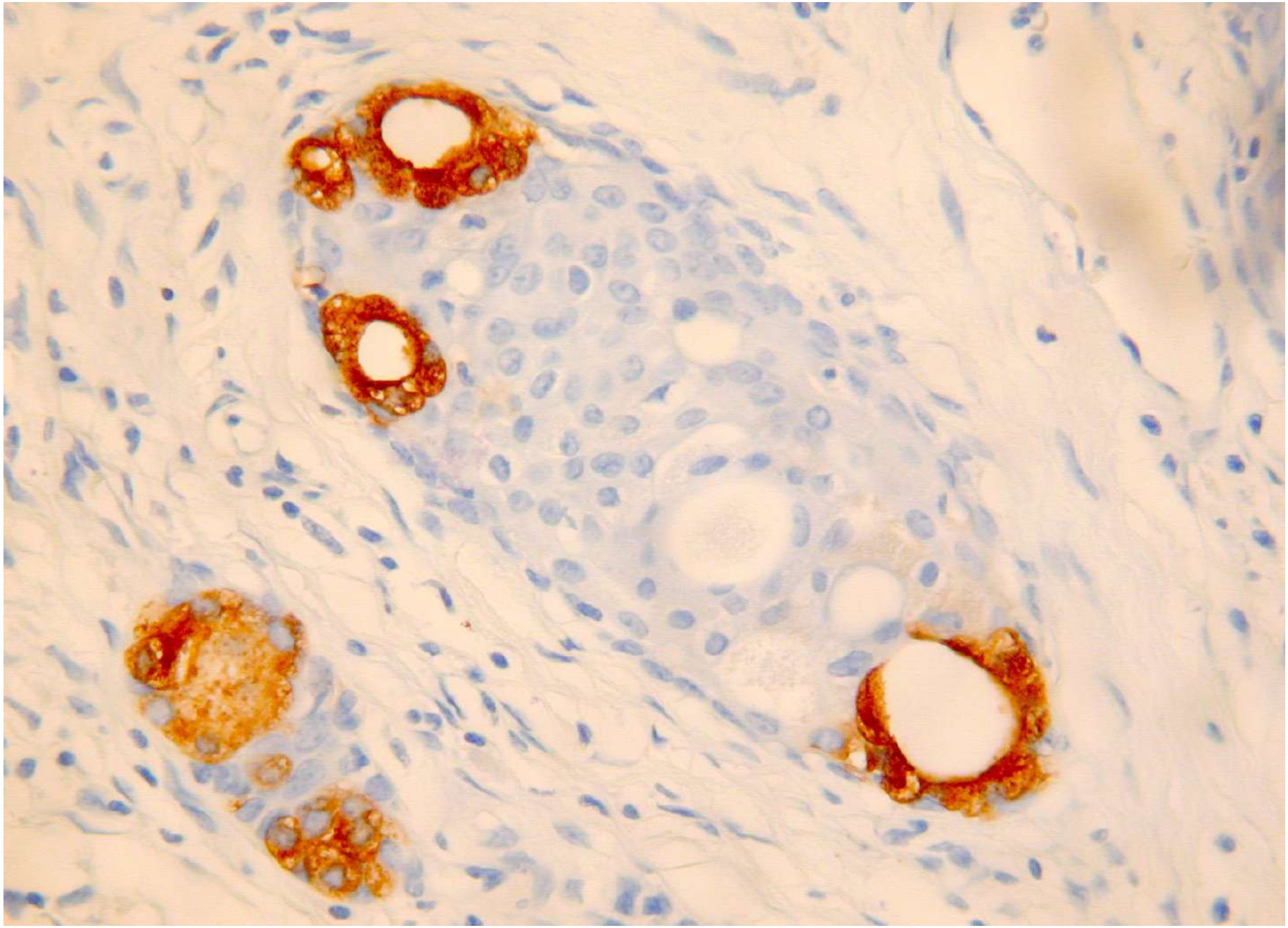

PSAP

NKX3.1 IN TUBULOSQUAMOUS POLYP

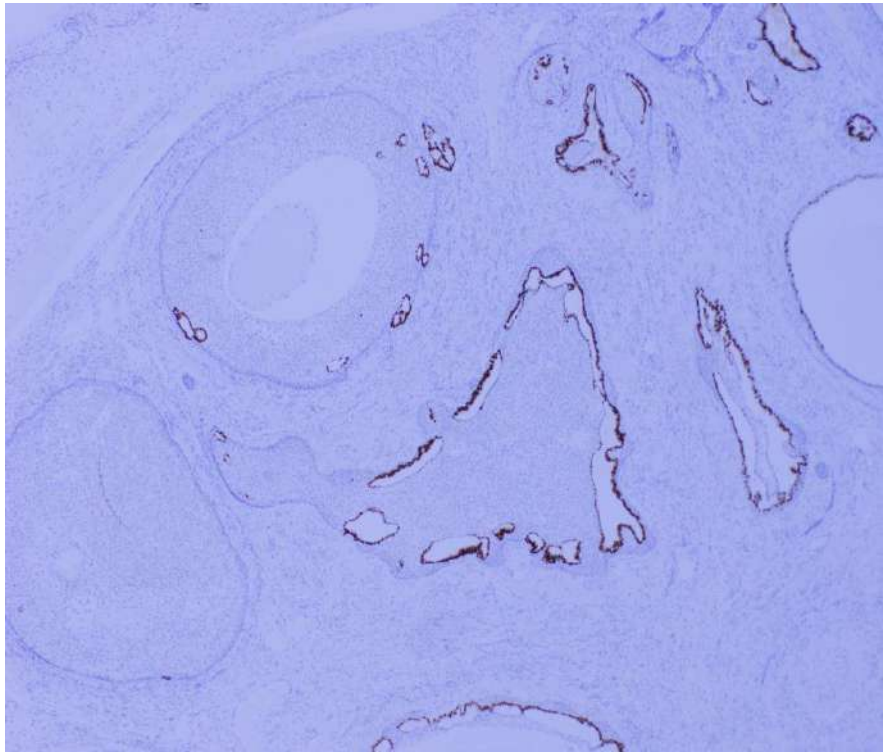

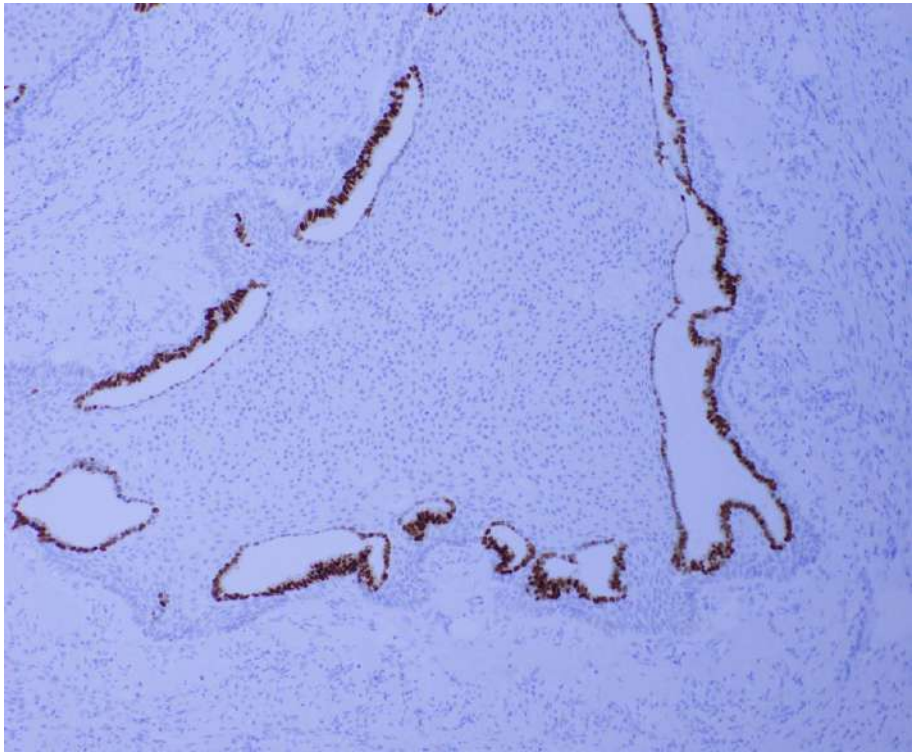

PMID 21979599

International Journal of Gynecological Pathology
30:605–612, Lippincott Williams & Wilkins, Baltimore
© 2011 International Society of Gynecological Pathologists

Original Article

Misplaced Skene's Glands: Glandular Elements in the Lower Female Genital Tract That Are Variably Immunoreactive With Prostate Markers and That Encompass Vaginal Tubulosquamous Polyp and Cervical Ectopic Prostatic Tissue

Paul Kelly, F.R.C.Path., Hilary A. McBride, F.I.B.M.S., Kathryn Kennedy, F.I.B.M.S., Lynette E. Connolly, F.I.B.M.S., and W.Glenn McCluggage, F.R.C.Path.

UNIFYING THEORY

- IJGP 2011;30;605-612 (PMID 21979599)
- vaginal tubulosquamous polyp and ectopic prostatic tissue in cervix are same lesion
- probably derived from paraurethral Skene's glands (female equivalent of prostatic glands in male); however, new evidence regarding the histogenesis
- occasionally also see in vulva

PMID: 32282346

ORIGINAL ARTICLE

Prostatic Metaplasia of the Vagina and Uterine Cervix

An Androgen-associated Glandular Lesion of Surface Squamous Epithelium

William J. Anderson, MBChB,† David L. Kolin, MD, PhD,† Grace Neville, MB BCh,† David A. Diamond, MD,‡ Christopher P. Crum, MD,† Michelle S. Hirsch, MD, PhD,† and Sara O. Vargas, MD*†*

PMID: 32282346

- Patients with androgen excess; mainly male to female transgender patients receiving exogenous testosterone; also various congenital disorders associated with androgen excess
- May involve cervix or vagina
- Proposed term “androgen associated prostatic metaplasia”
- In many cases, glands involve basal layer of squamous epithelium suggesting that they arise in-situ here

PMID: 34664289

Histopathology

Histopathology 2022, 80, 946–953. DOI: 10.1111/his.14587

Surface prostatic metaplasia, transitional cell metaplasia and superficial clusters of small basophilic cells in the uterine cervix: prevalence in gender-affirming hysterectomies and comparison with benign hysterectomies from cisgender women

Emily R McMullen-Tabry,[1] Andrew P Sciallis[2] & Stephanie L Skala[2,3]

[1]*Grand Traverse Pathology, PLLC, Traverse City, MI, USA,* [2]*Department of Pathology, and* [3]*Rogel Cancer Center, University of Michigan, Ann Arbor, MI, USA*

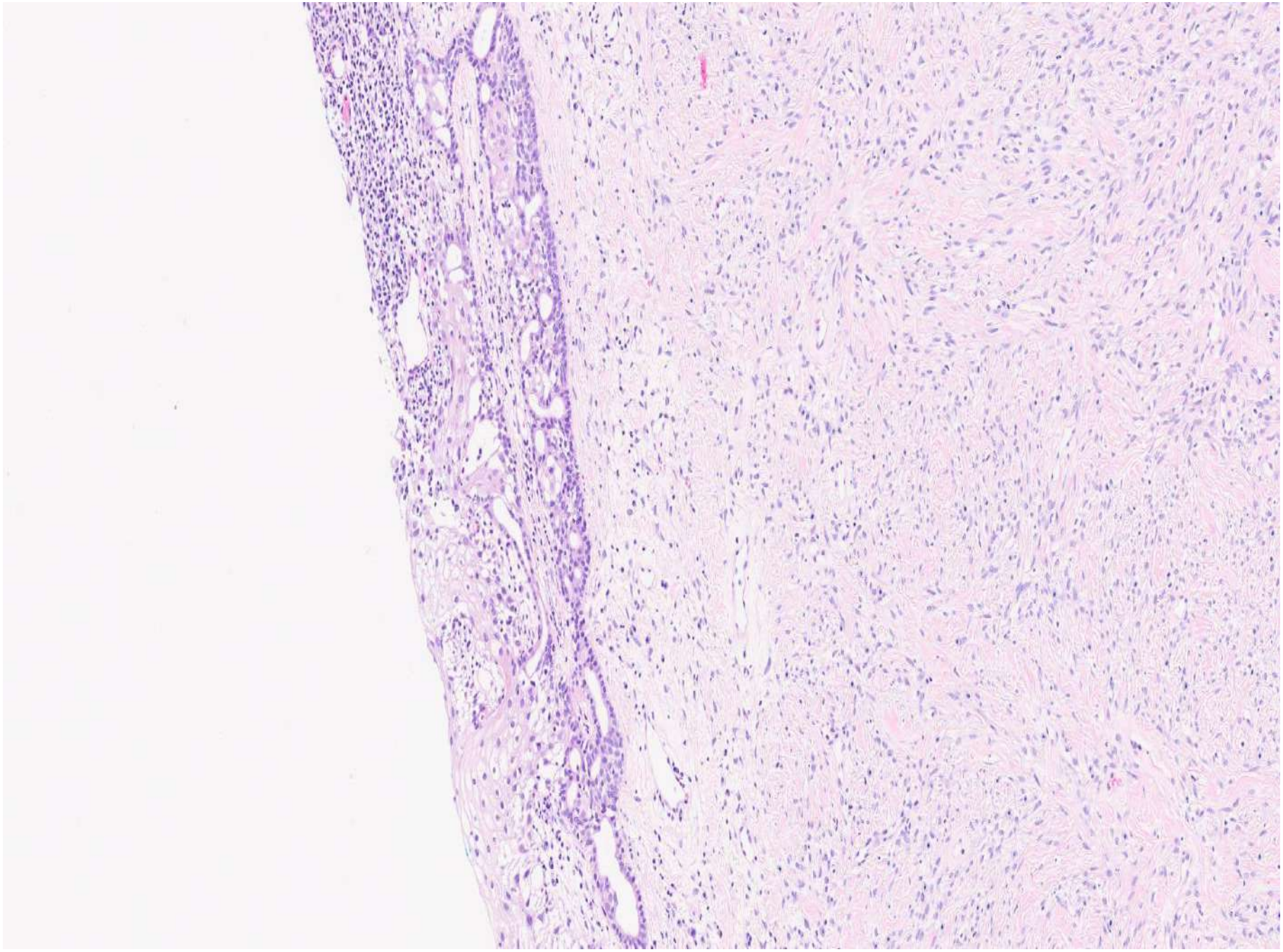

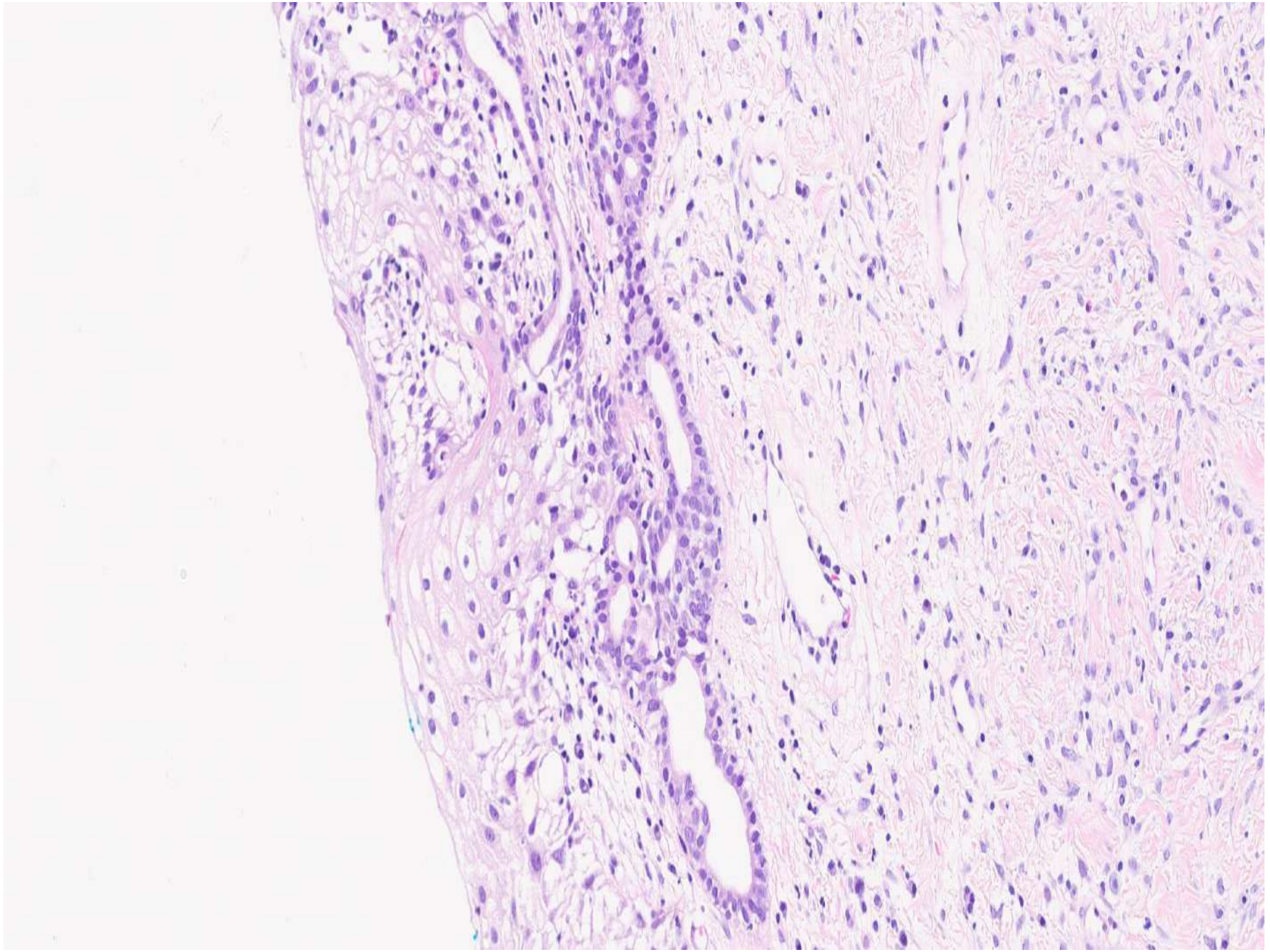

NKX3.1

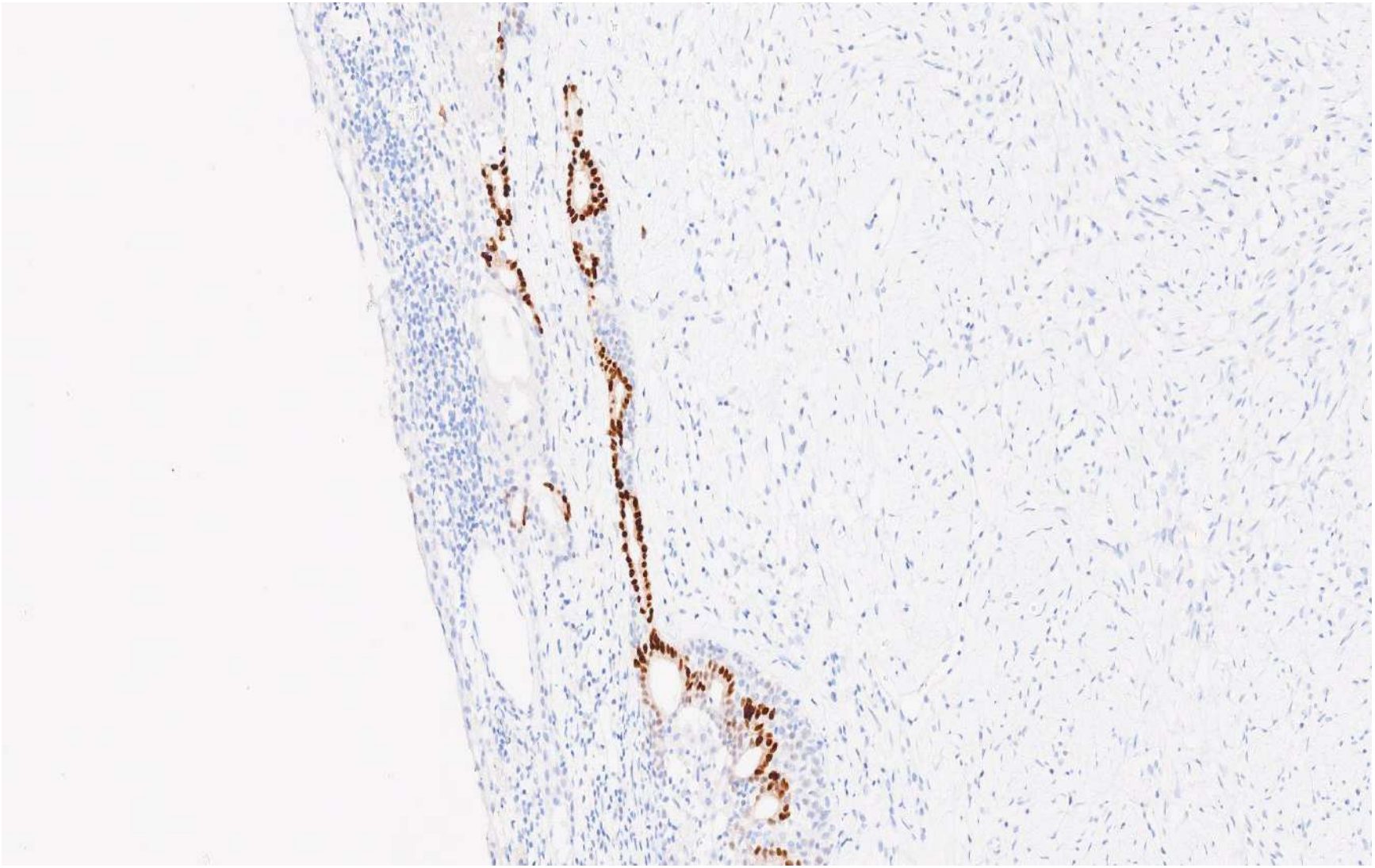

PMID 33021555

International Journal of Gynecological Pathology
00:1–8, Lippincott Williams & Wilkins, Baltimore
Copyright © 2020 by the International Society of Gynecological Pathologists

Original Article

Skene's Gland Derivatives in the Female Genital Tract and Cervical Adenoid Basal Carcinoma are Consistently Positive With Prostatic Marker NKX3.1

Rand Hawari, F.R.C.Path., Larissa Fernandes, F.I.B.M.S., Kay J. Park, M.D., and W. Glenn McCluggage, F.R.C.Path.

PMID 33021555

- Cervical ectopic prostatic tissue (all 11 cases NKX3.1 positive)
- Vaginal tubulosquamous polyp (all 3 cases NKX3.1 positive)
- Cervical adenoid basal carcinoma (all 6 cases NKX3.1 positive); 3 of 5 cases positive (focal) with PSAP (all PSA negative)
- NKX3.1 is a better marker of ectopic prostatic tissue and tubulosquamous polyp than traditional prostatic markers which may be negative

CERVIX ADENOID BASAL CARCINOMA

- Rare (< 1% of cervical malignancies)
- Associated with high-risk HPV (especially HPV 16)
- Often associated with HSIL or other carcinoma (especially squamous carcinoma); report as mixed carcinoma
- Indolent and has never been shown to metastasise in “pure” form; alternative names proposed “adenoid basal epithelioma” or “low-grade adenoid basal tumour”
- Term adenoid basal carcinoma retained in WHO 2020

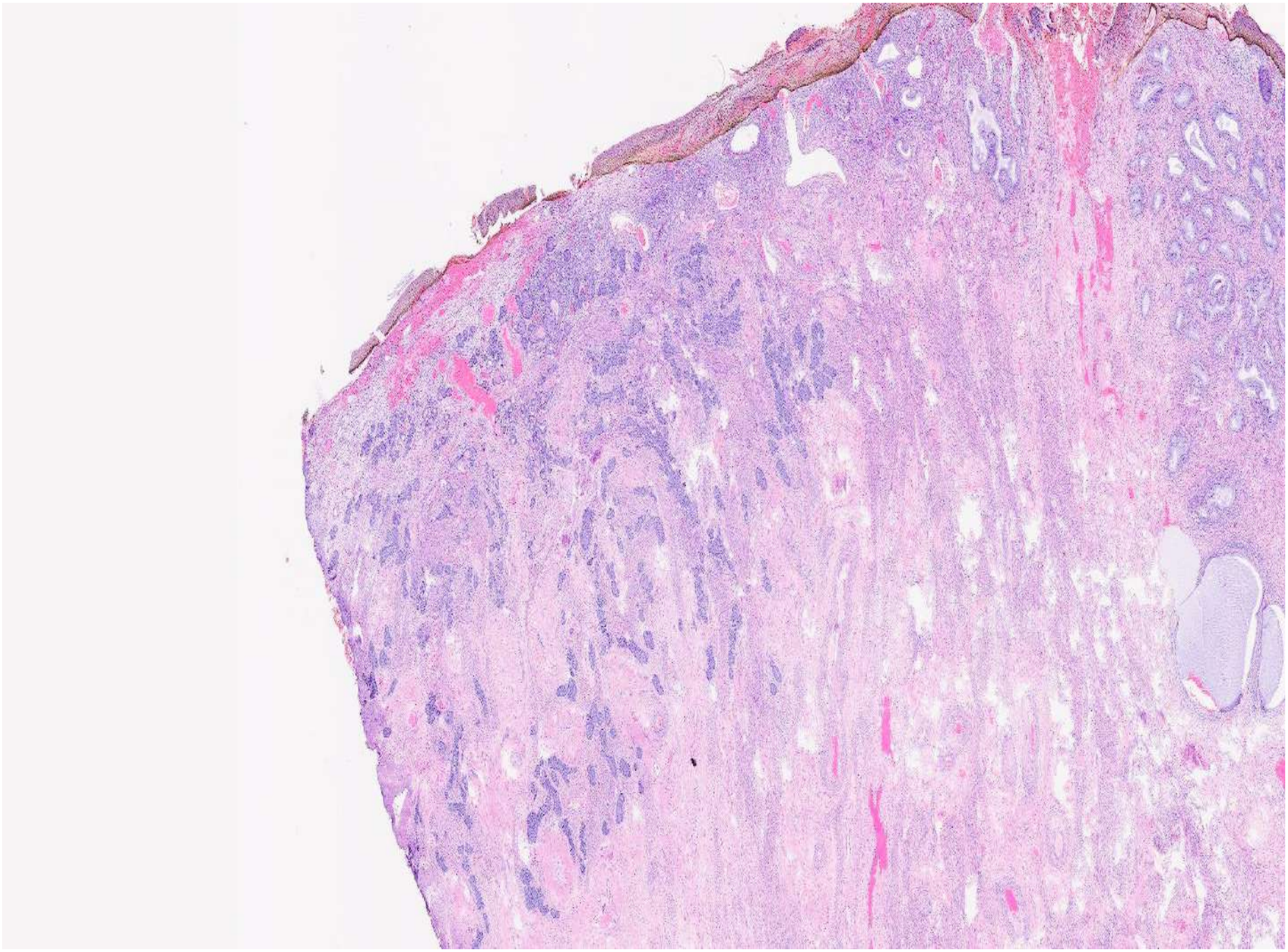

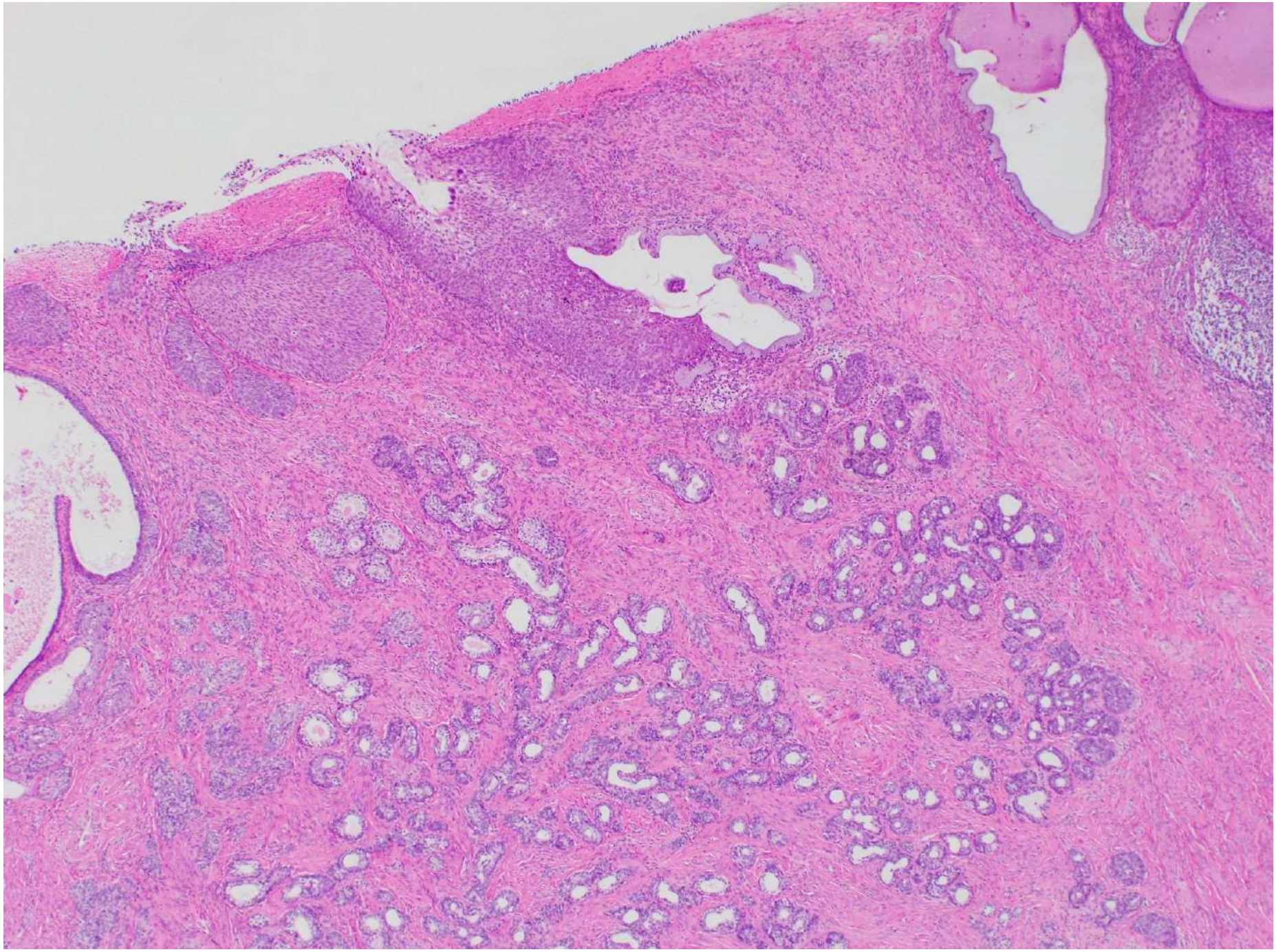

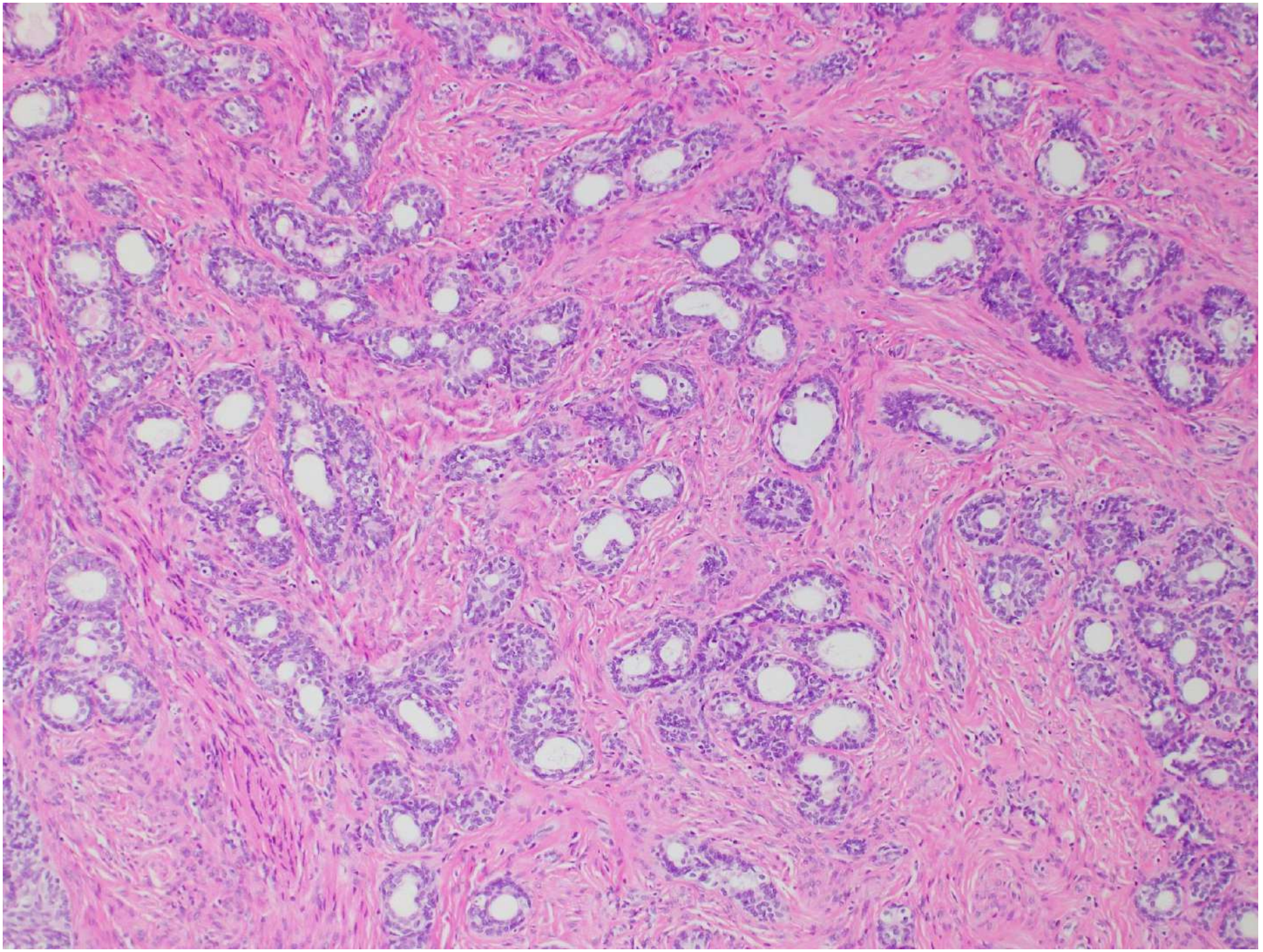

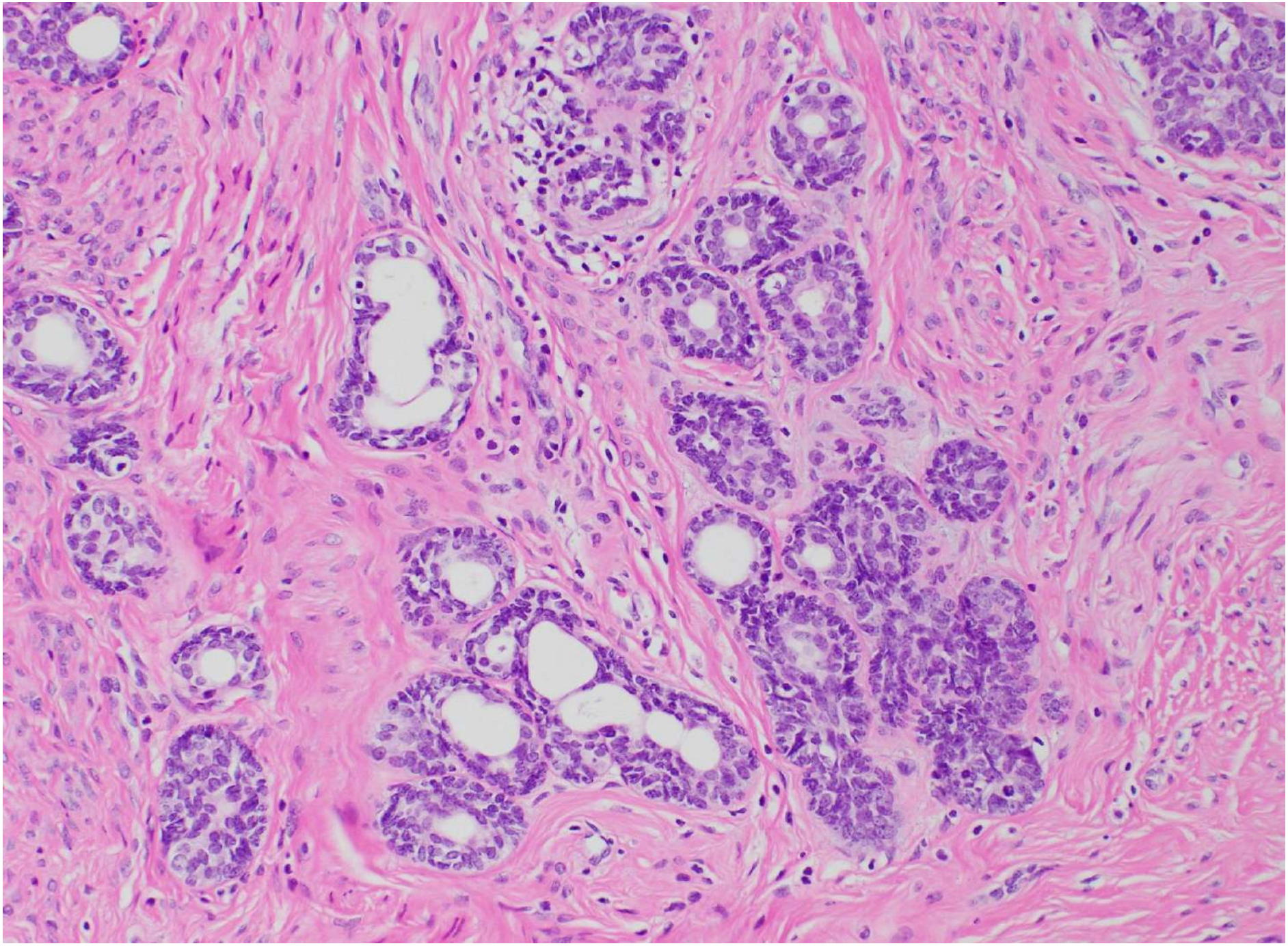

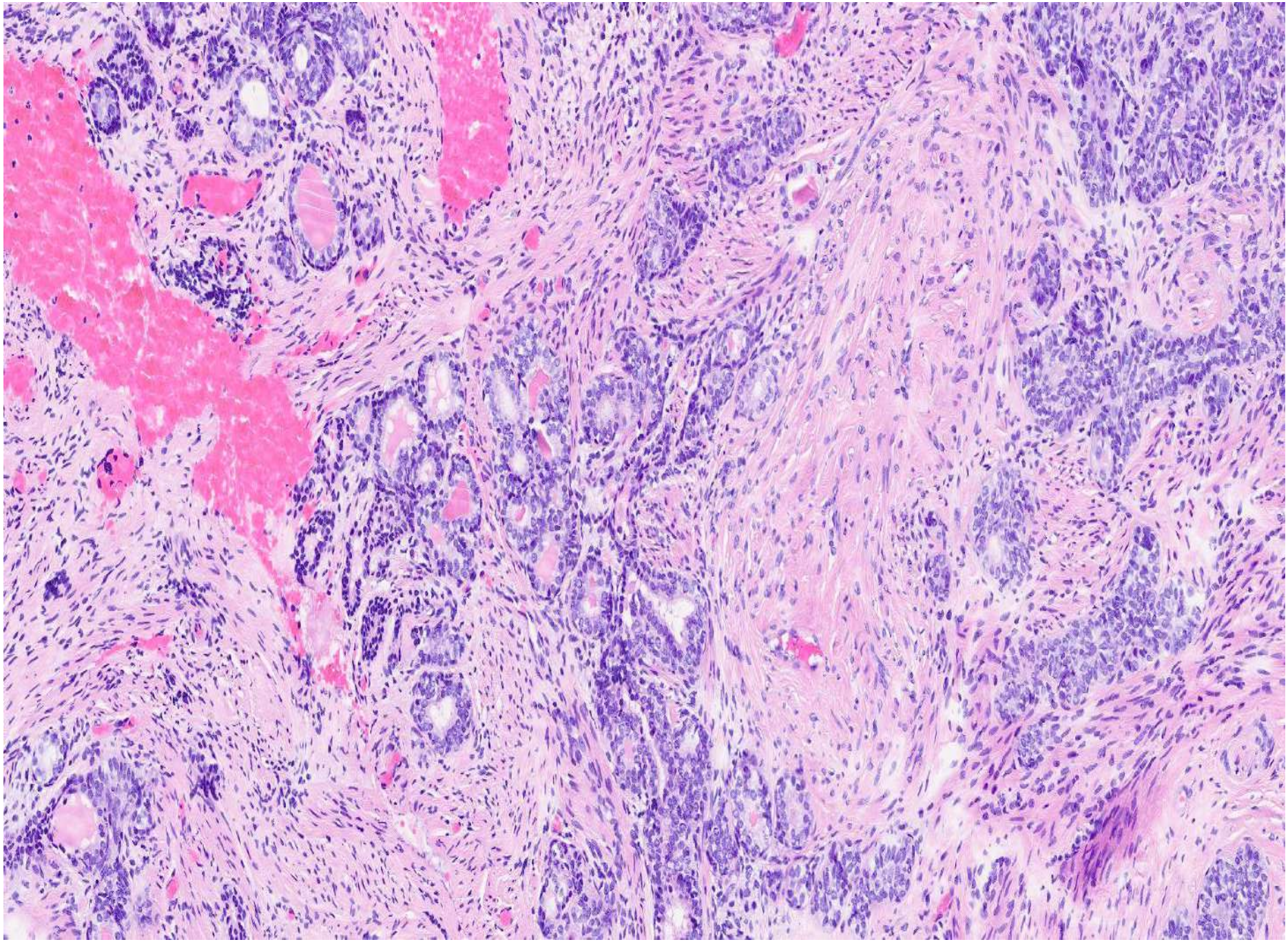

CERVIX ADENOID BASAL CARCINOMA ADMIXED WITH CIN III

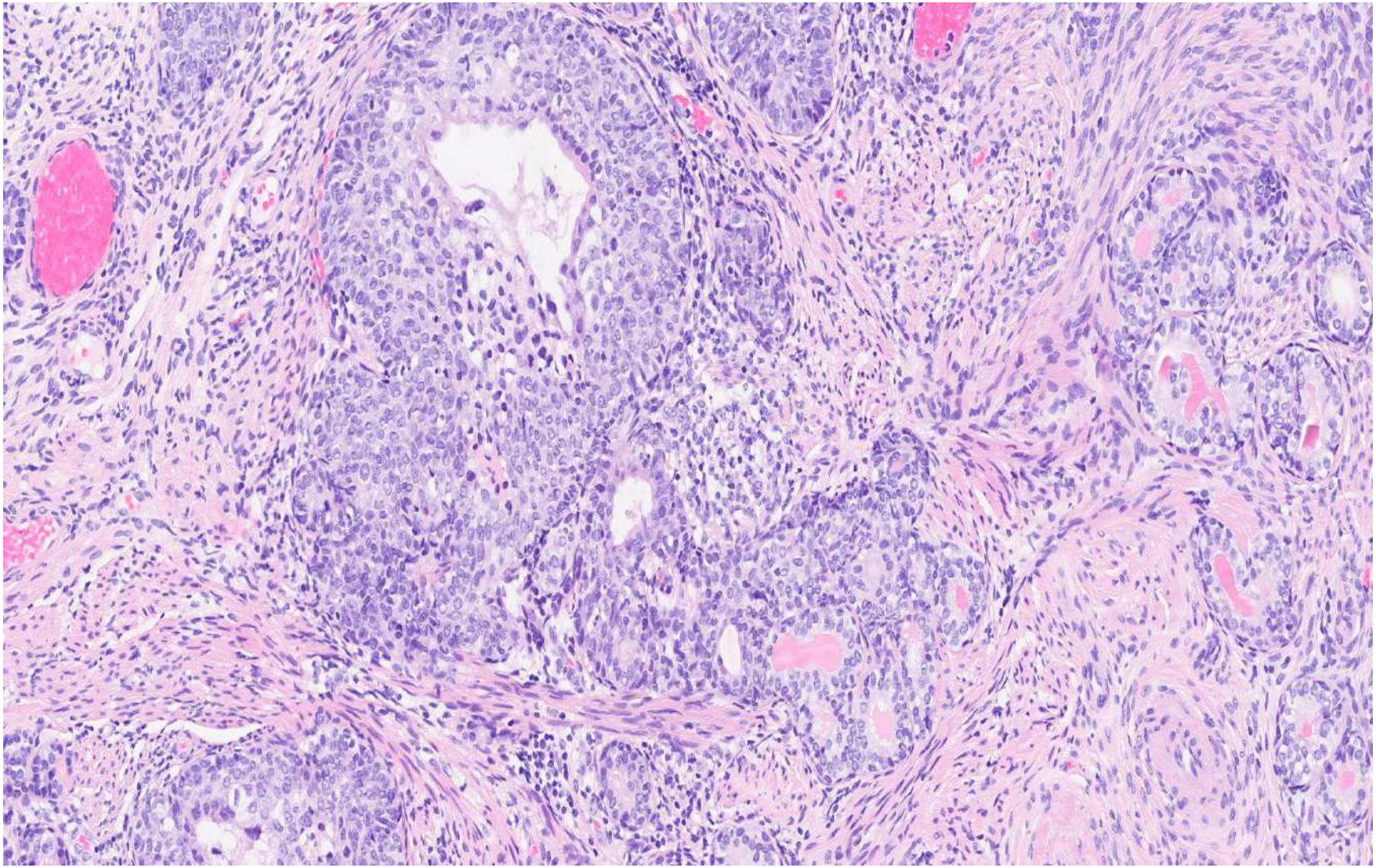

CERVIX ADENOID BASAL CARCINOMA ADMIXED WITH SCC

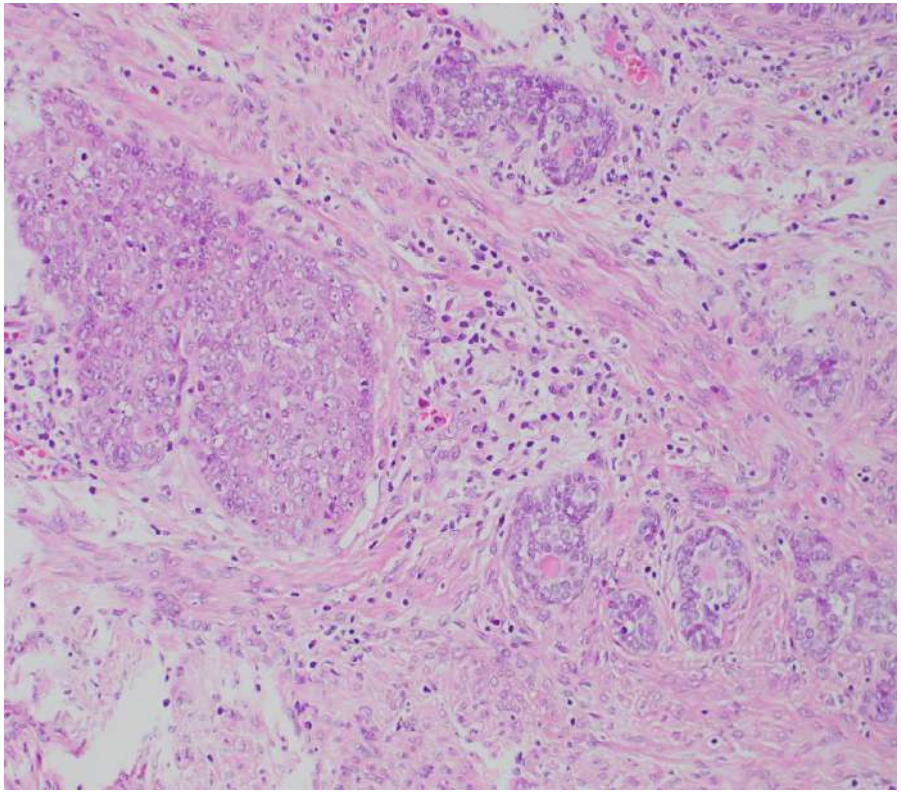

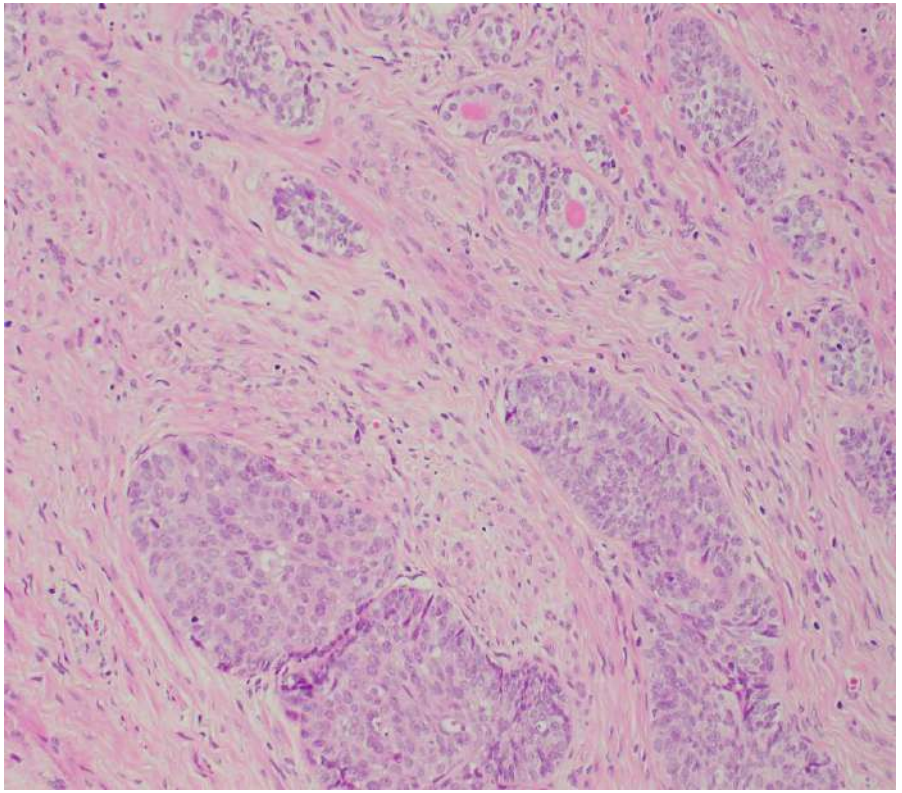

IMMUNOHISTOCHEMISTRY

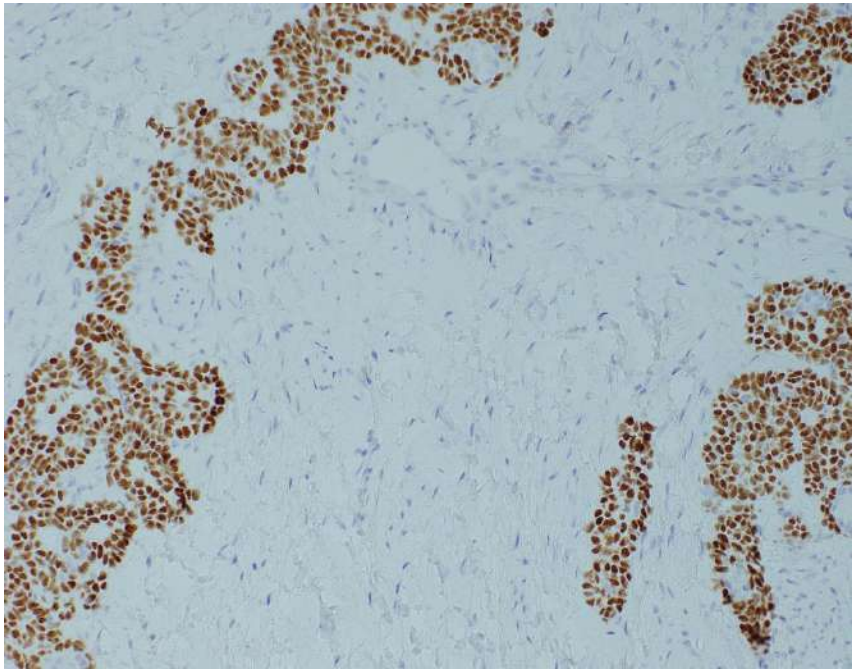

p63

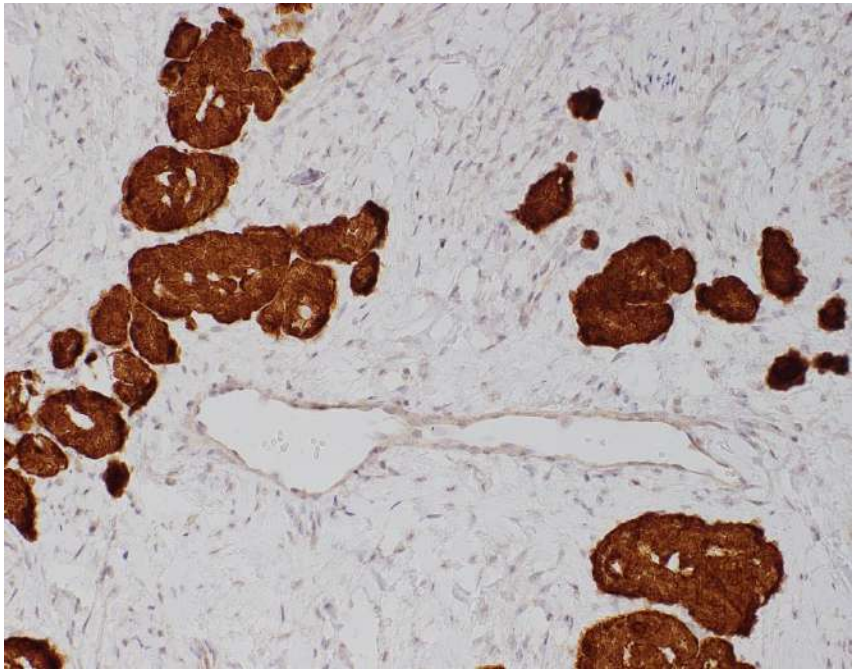

p16

CERVIX ADENOID BASAL CARCINOMA-NKX3.1

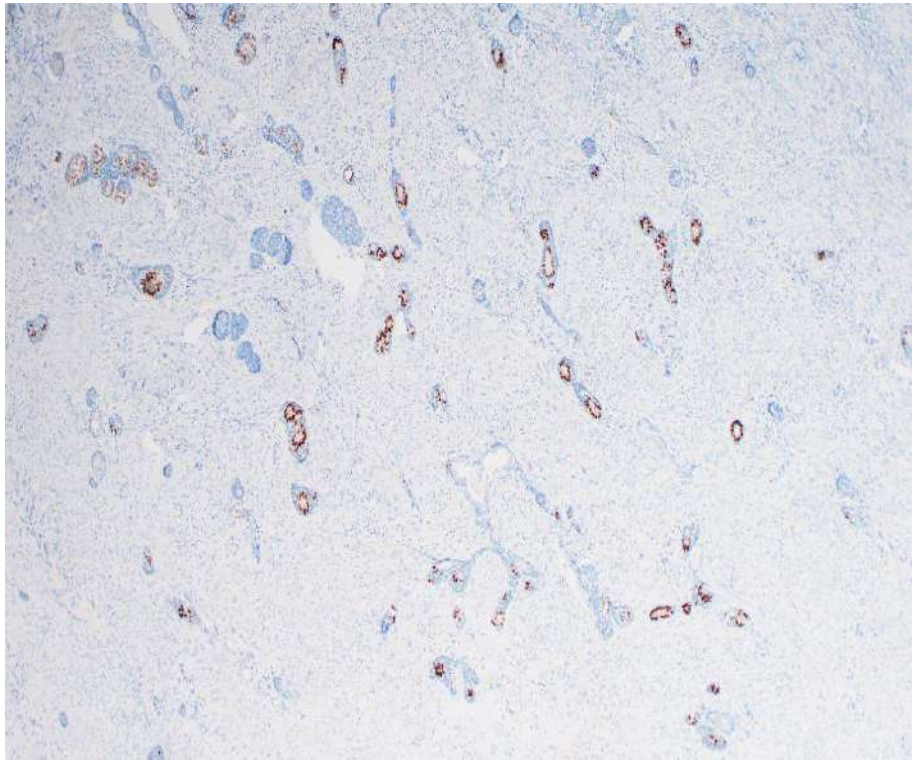

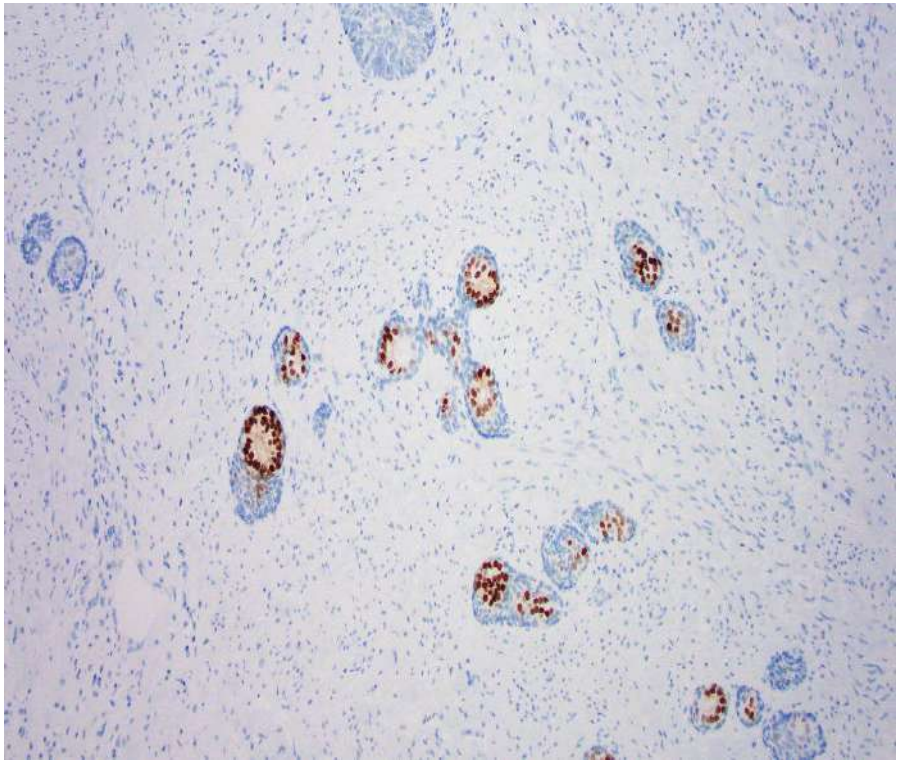

CERVIX ADENOID BASAL CARCINOMA

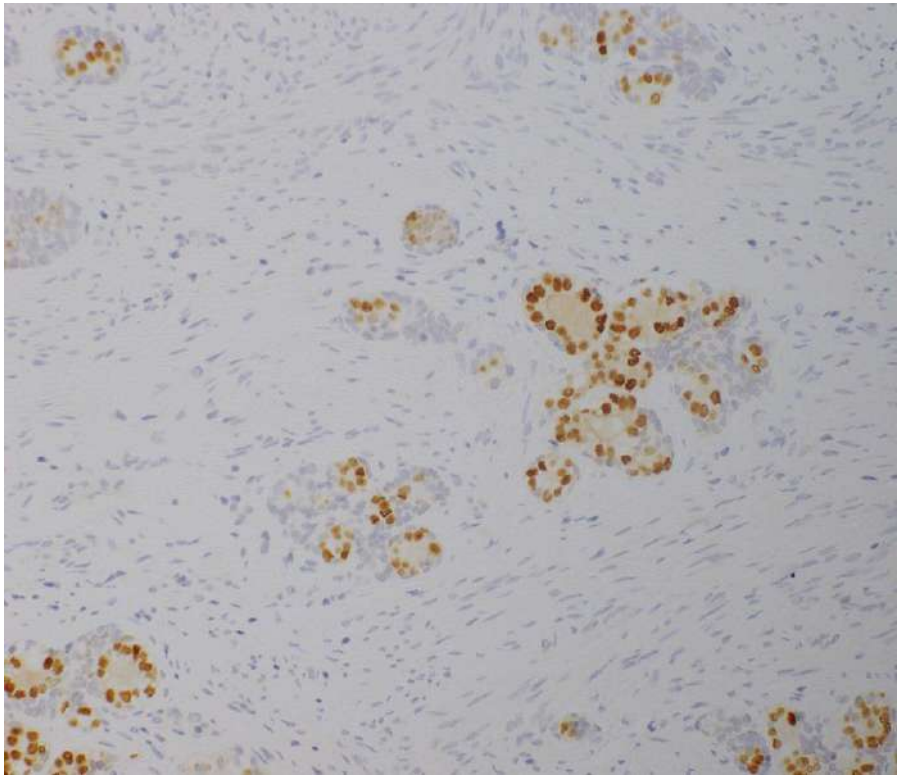

NKX3.1

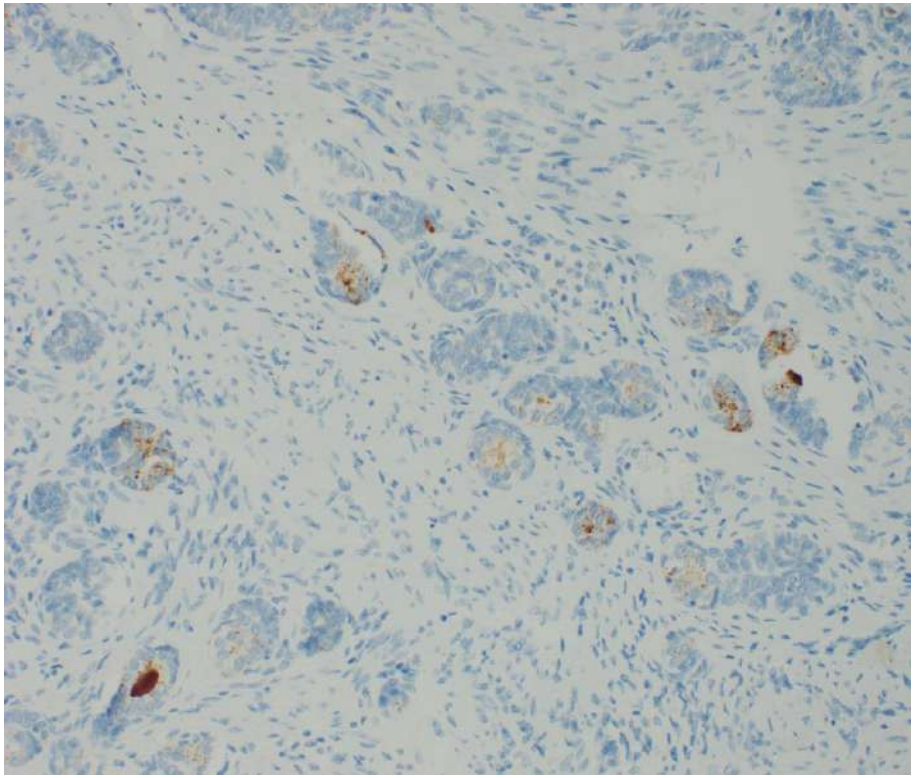

PSAP

PATHOLOGY : PMID 33032811

ANATOMICAL PATHOLOGY

NKX3.1 expression in cervical 'adenoid basal cell carcinoma': another gynaecological lesion with prostatic differentiation?

COLIN J. R. STEWART[1,2], JOANNE MOSES[3]

[1]Department of Pathology, King Edward Memorial Hospital, Perth, WA, Australia; [2]School of Women's and Infants' Health, University of Western Australia, WA, Australia; [3]LabPlus, Auckland City Hospital, Auckland, New Zealand

? IS ADENOID BASAL CARCINOMA RELATED TO ECTOPIC PROSTATIC TISSUE- PROS

- “similar” morphology (bland morphology, no stromal response)
- NKX3.1 and PSAP often positive
- Coexistence in occasional cases (1 case in our study)
- Could adenoid basal carcinoma be secondary to persistent high-risk HPV infection of ectopic prostatic tissue- PMID 33021555

? IS ADENOID BASAL CARCINOMA RELATED TO ECTOPIC PROSTATIC TISSUE- CONS

- Some “differences” in morphology
- Ectopic prostatic tissue usually at ectocervix; adenoid basal carcinoma usually at transformation zone
- Adenoid basal carcinoma is HPV-associated lesion

CASE 3

- F40
- LLETZ for persistent low-grade smears

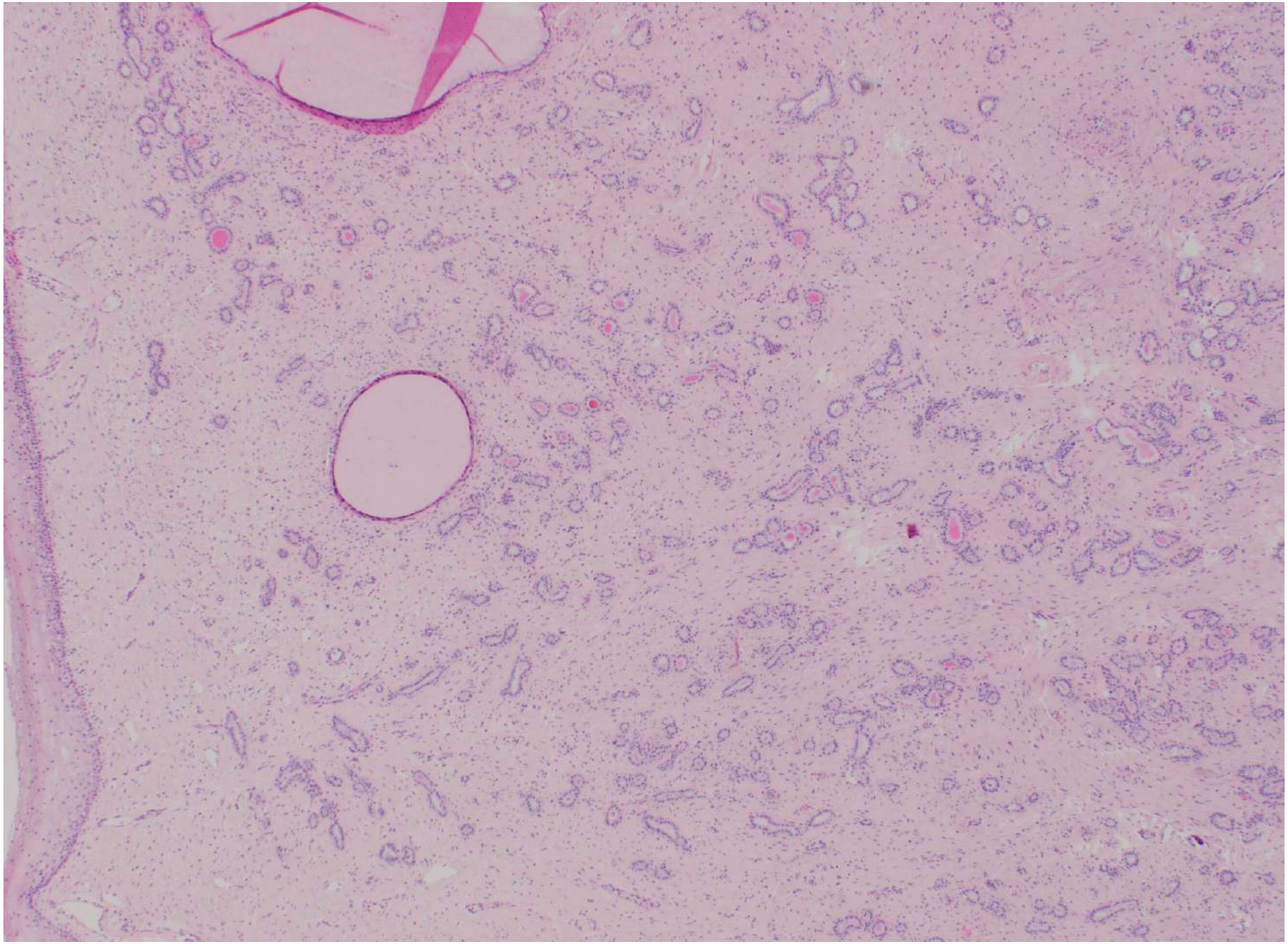

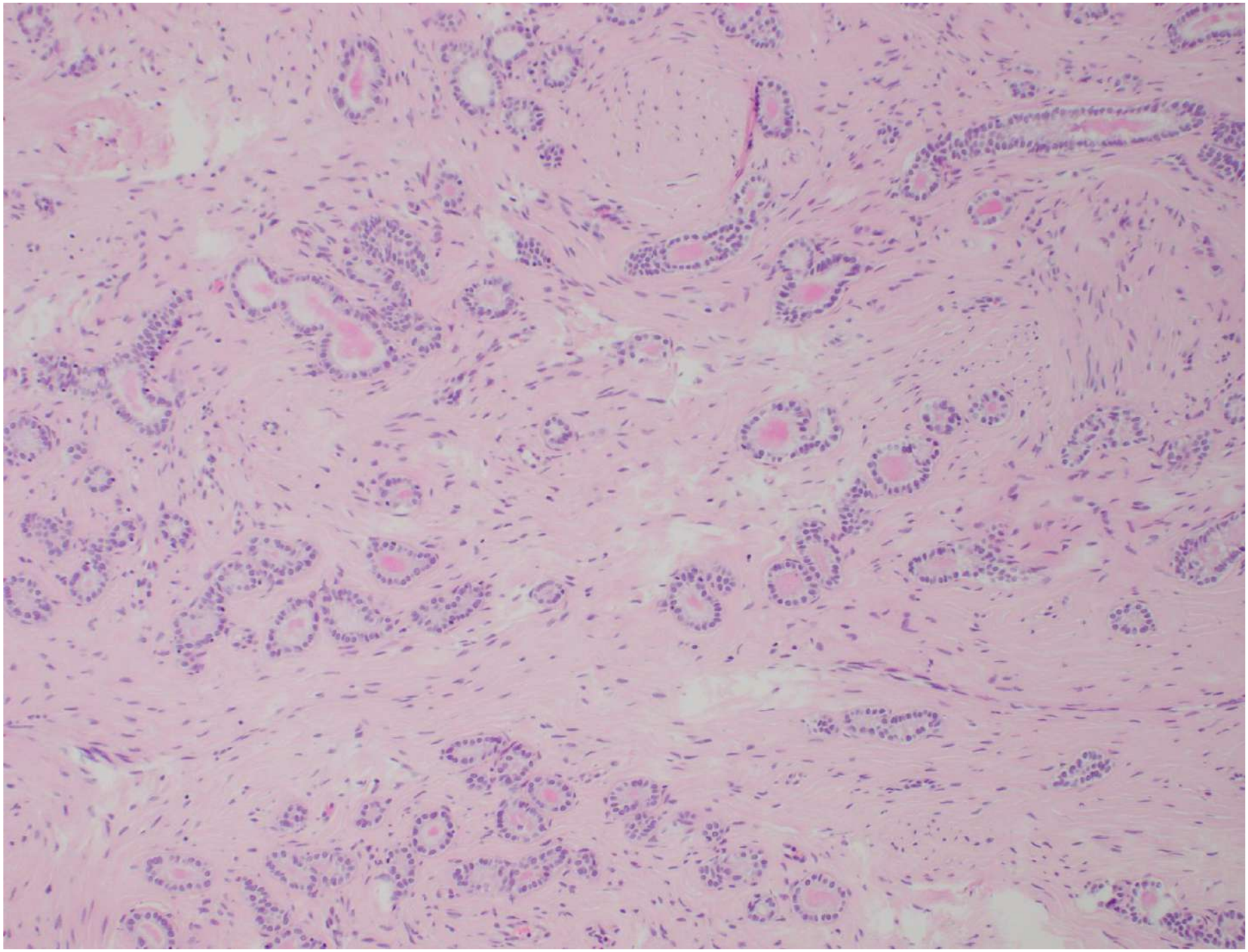

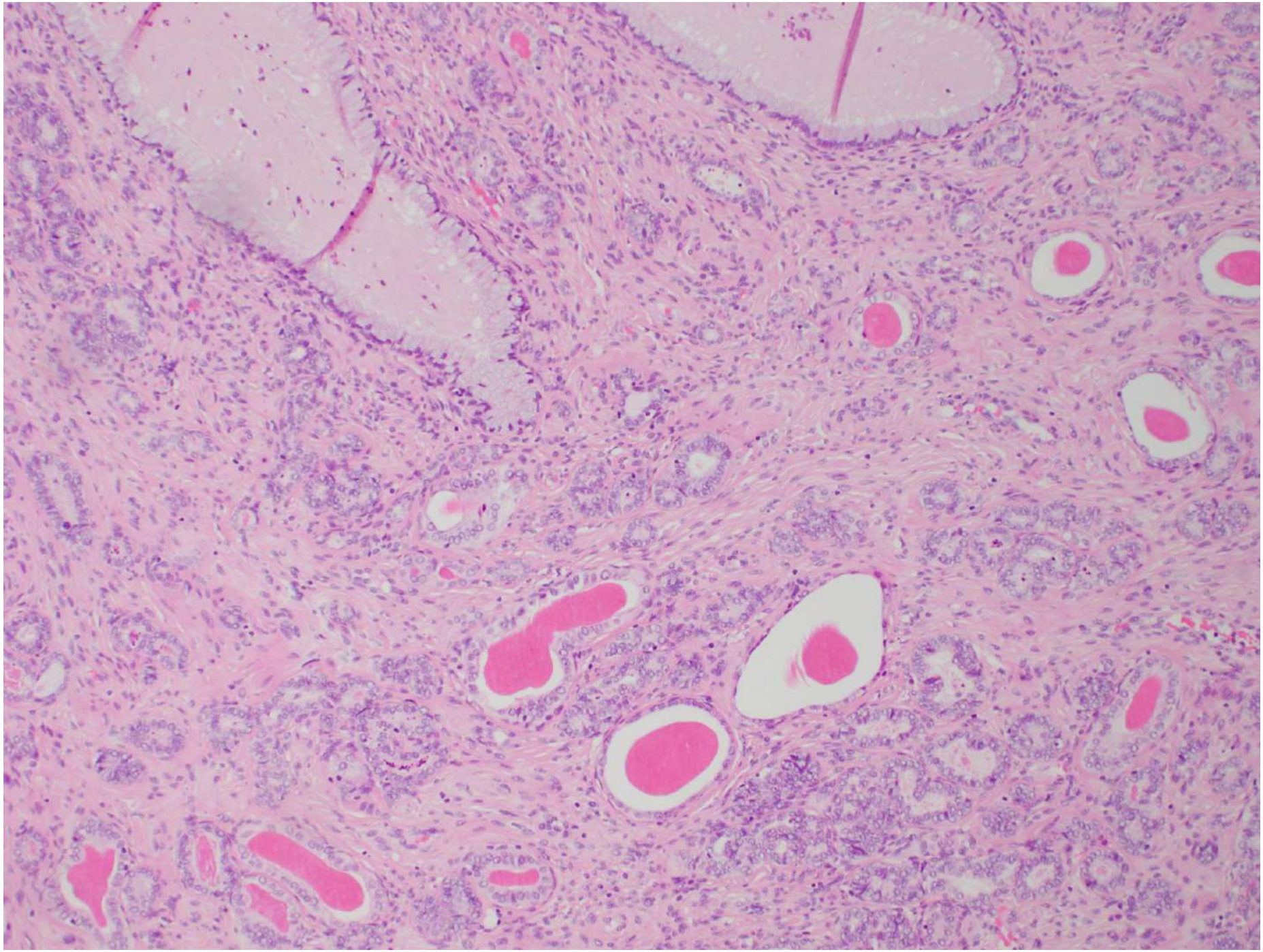

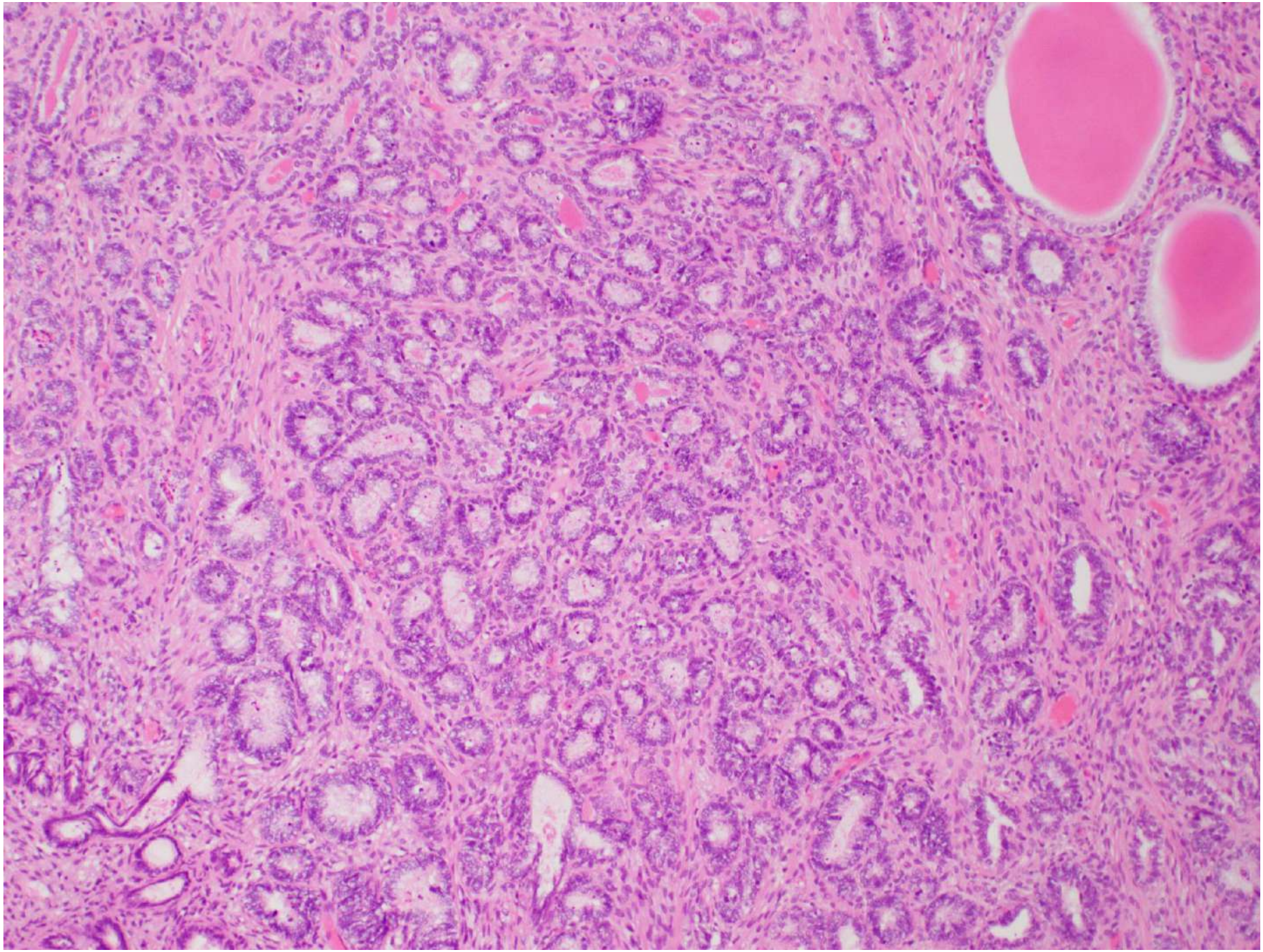

GATA3

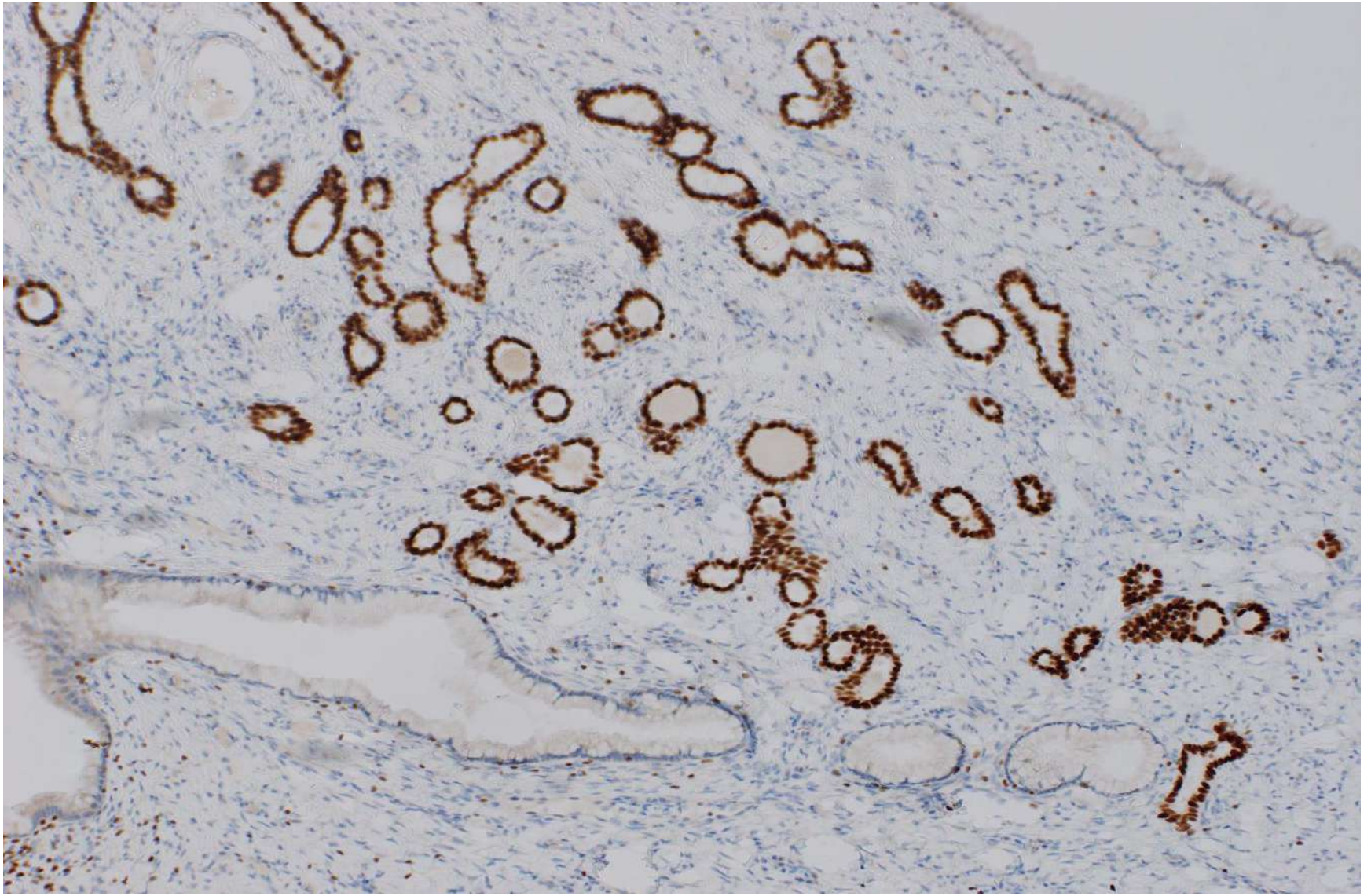

? DIAGNOSIS

DIAGNOSIS

- Florid mesonephric hyperplasia cervix

CERVIX- MESONEPHRIC REMNANTS AND HYPERPLASIA

- Relatively common (lateral walls); usually lobular architecture and often “linear” pattern
- Arbitrary distinction between “normal” and “hyperplasia” (6mm)
- Hyperplasia- lobular, diffuse or ductal patterns described
- Usually beneath normal endocervical glands but diffuse hyperplasia can involve entire cervix
- Diffuse mesonephric hyperplasia may be very difficult to distinguish from mesonephric adenocarcinoma

MESONEPHRIC REMNANTS

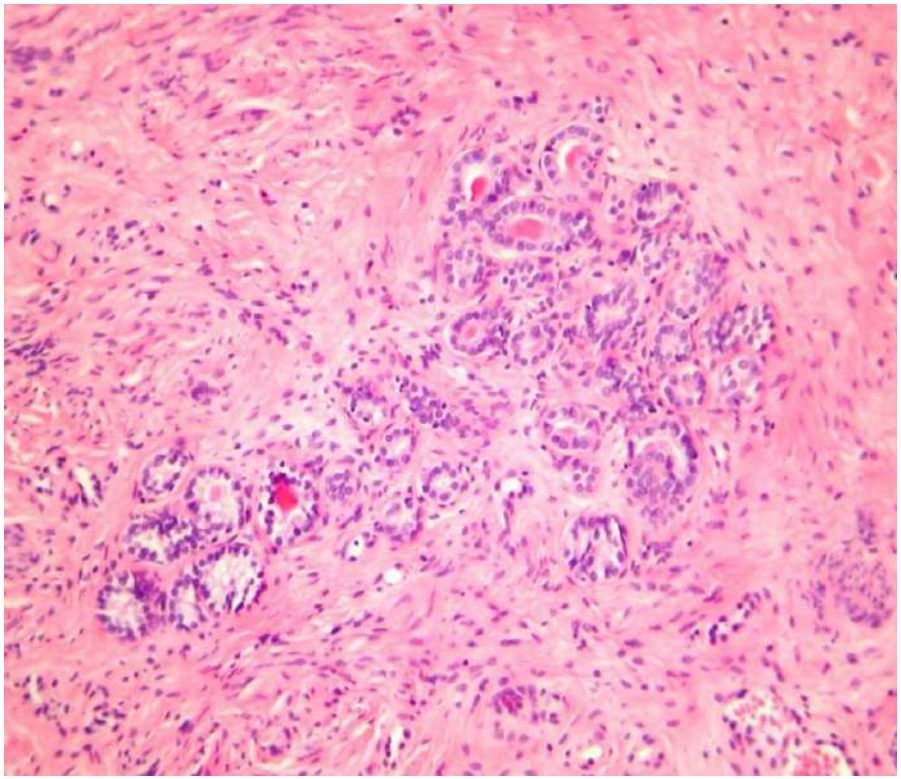

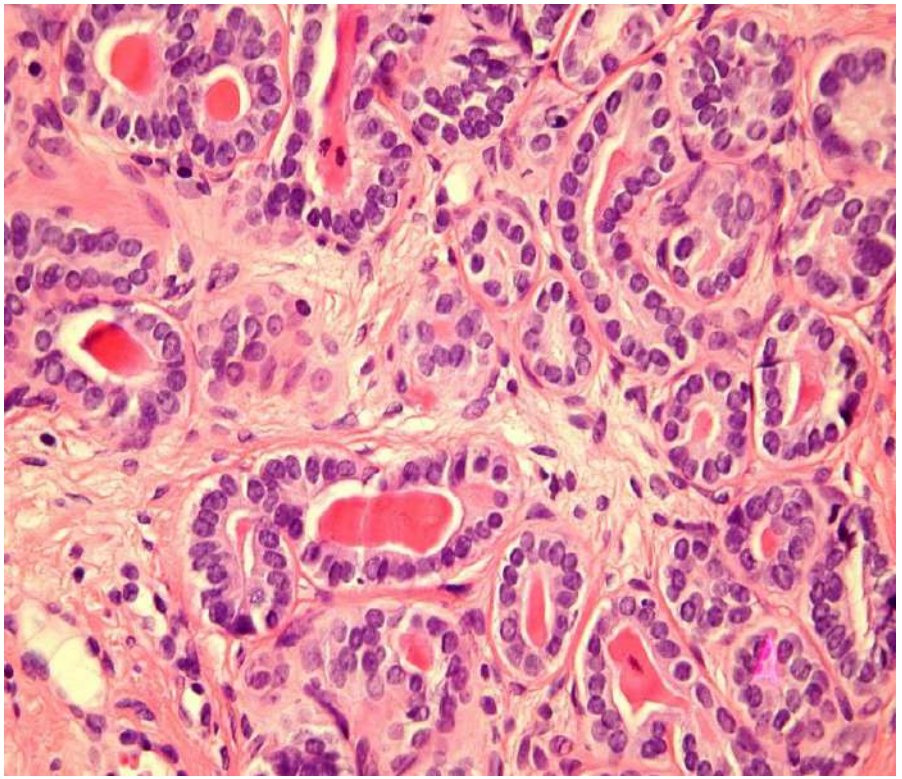

UNUSUAL FEATURES

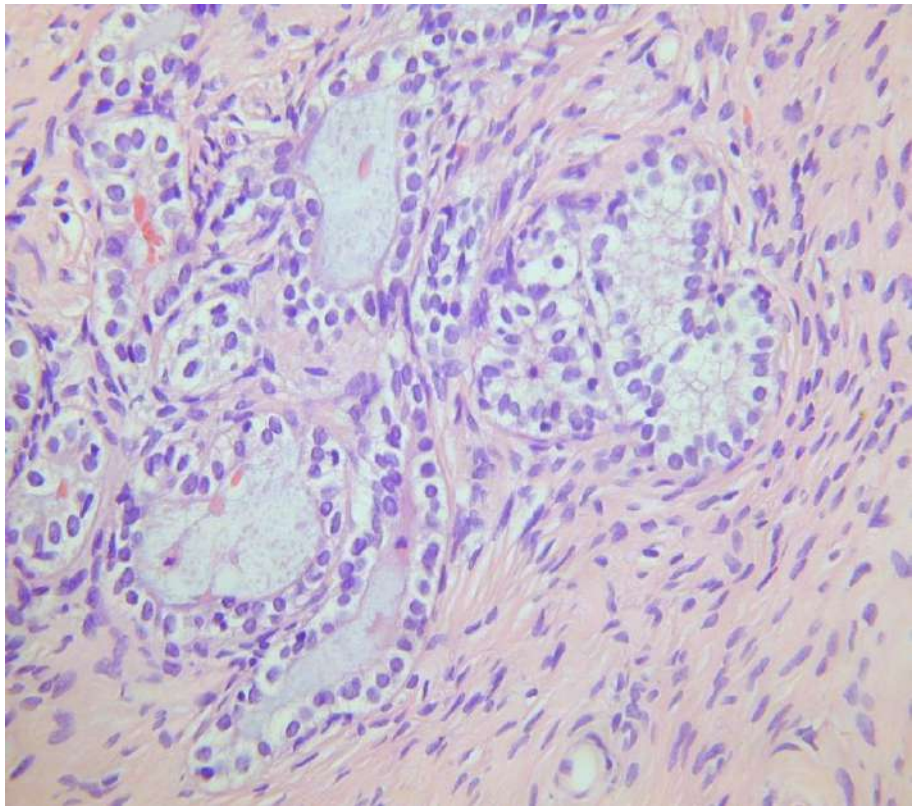

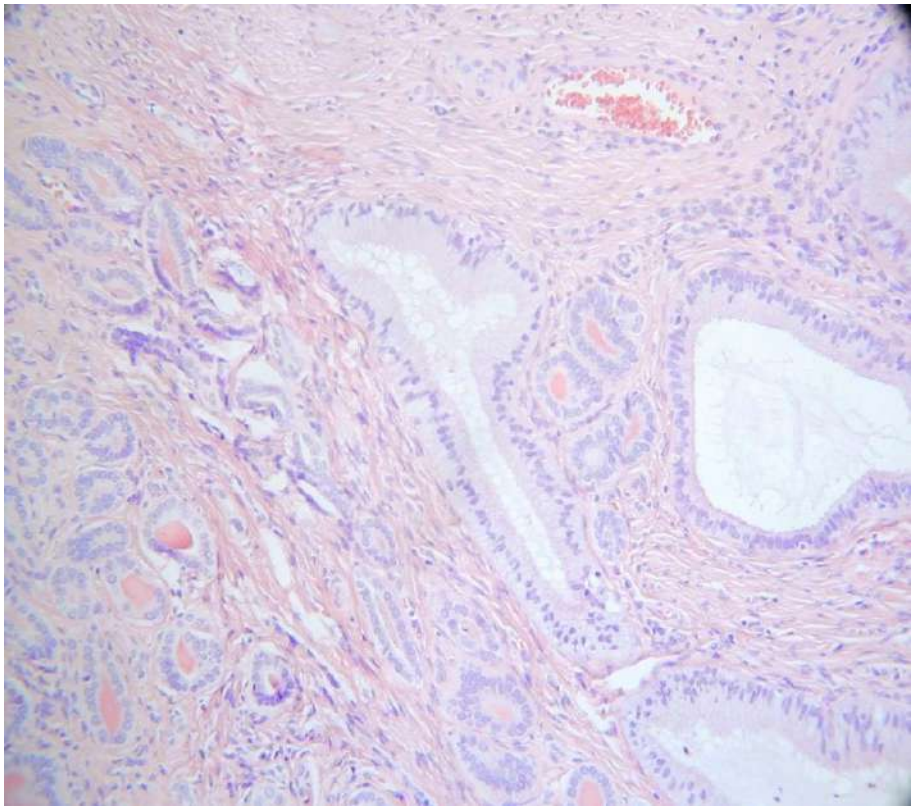

LOBULAR MESONEPHRIC HYPERPLASIA

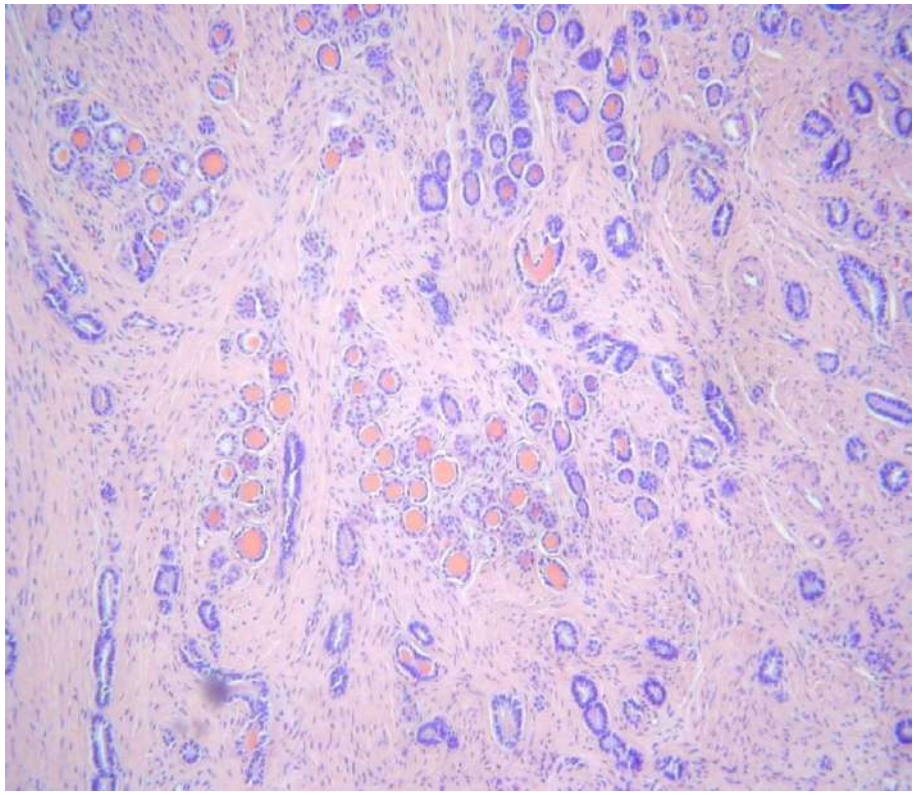

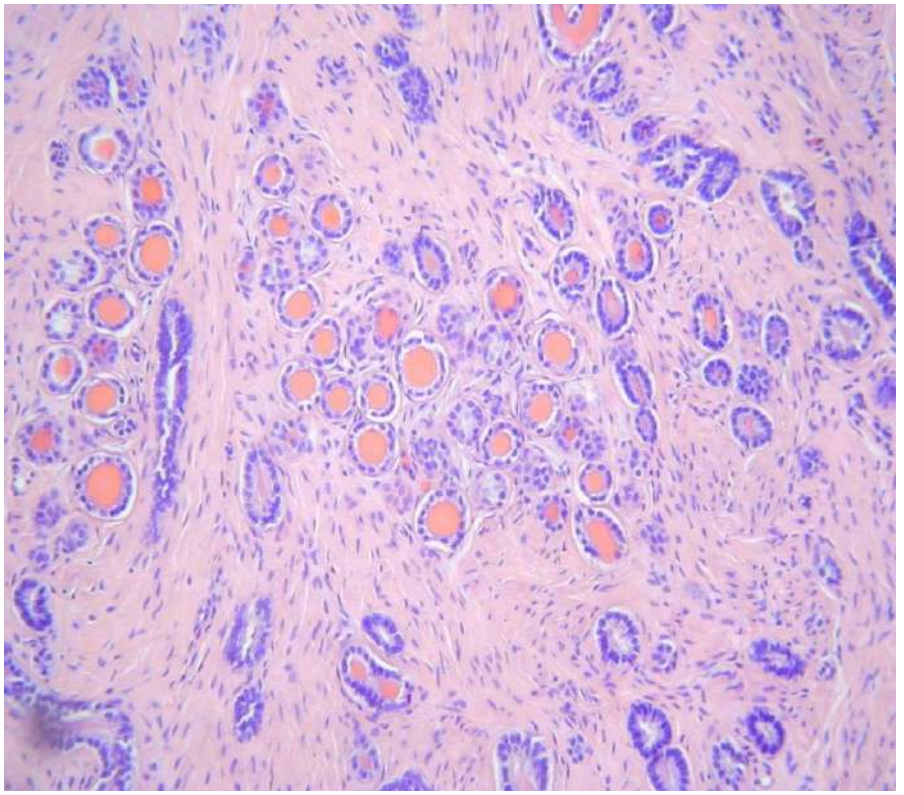

FLORID DIFFUSE MESONEPHRIC HYPERPLASIA

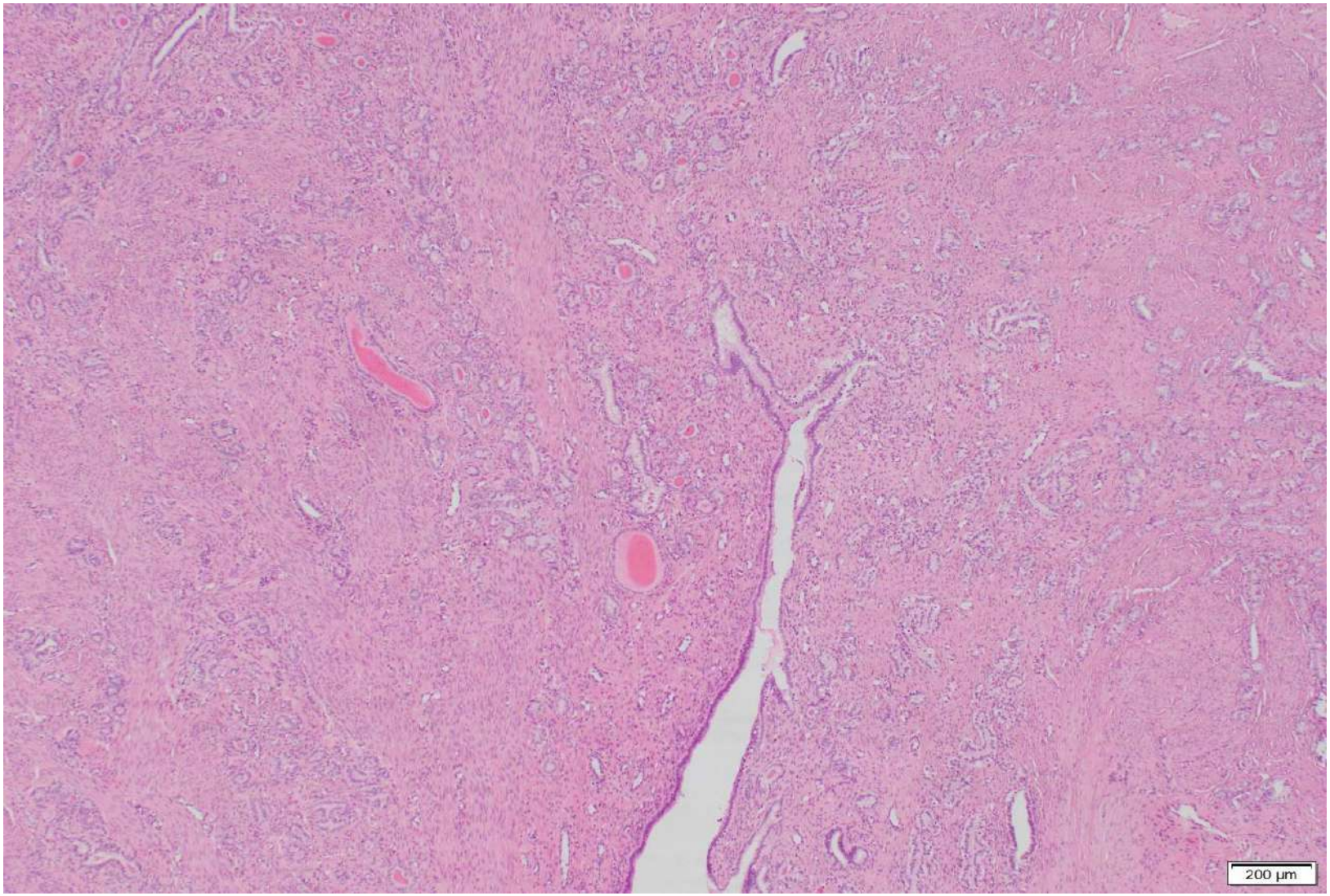

FLORID DIFFUSE MESONEPHRIC HYPERPLASIA

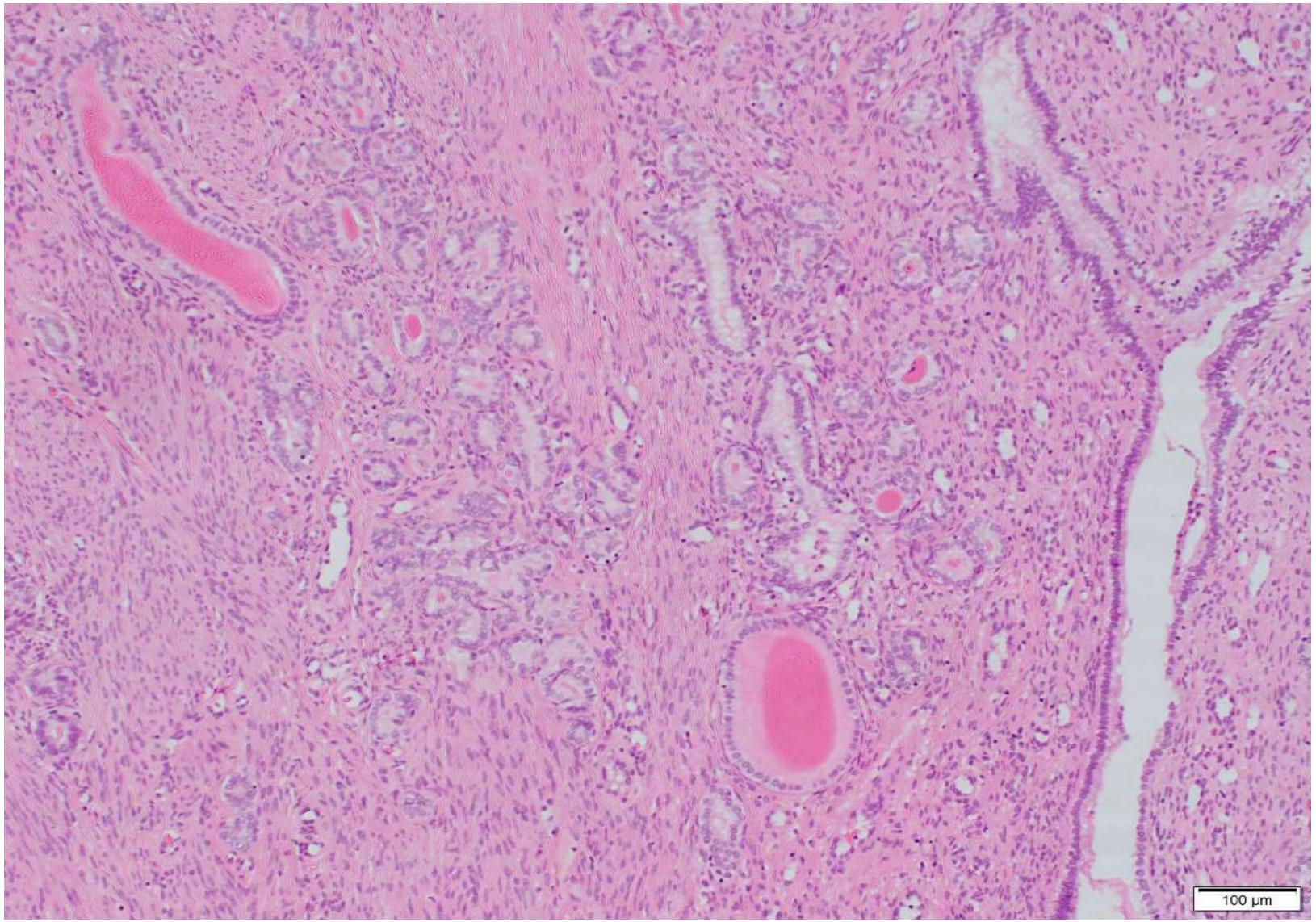

DUCTAL MESONEPHRIC REMNANTS

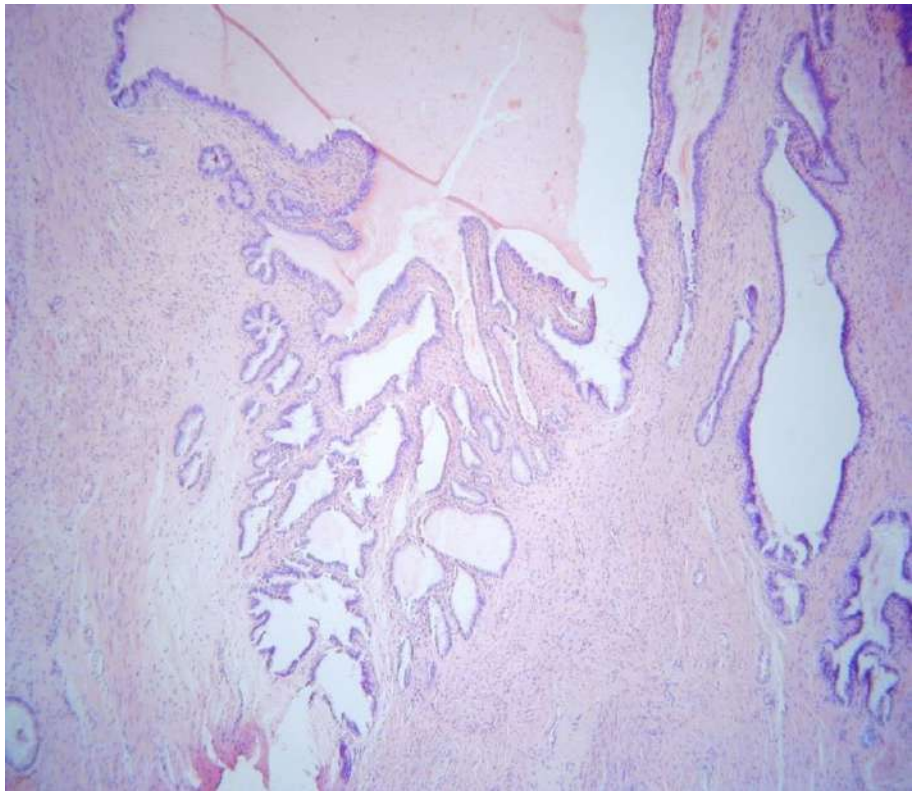

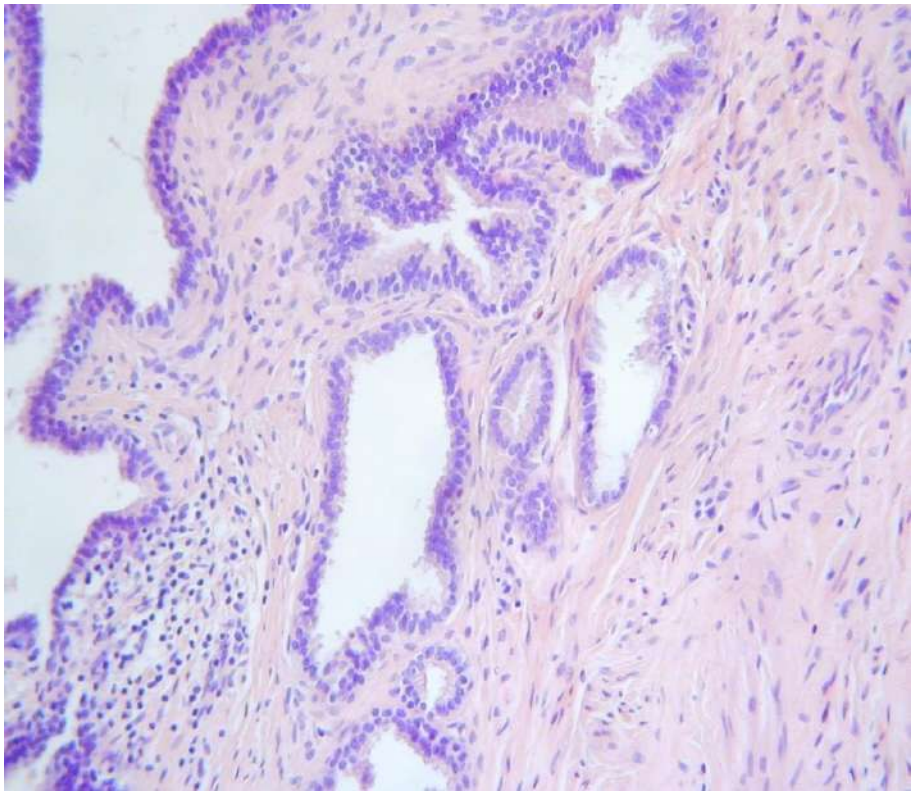

IMMUNOHISTOCHEMISTRY OF CERVICAL MESONEPHRIC REMNANTS

- Often luminal CD10 positive (not reliable)
- Vimentin positive
- GATA3 positive (RELIABLE MARKER OF BENIGN MESONEPHRIC PROLIFERATIONS)
- ER and PR “flat” negative (may be useful)
- PAX8 positive (not useful in distinction from Mullerian lesions)
- PAX2 usually positive (sometimes lost in mesonephric adenocarcinomas, although very few cases studied)

IMMUNOHISTOCHEMISTRY OF MESONEPHRIC REMNANTS

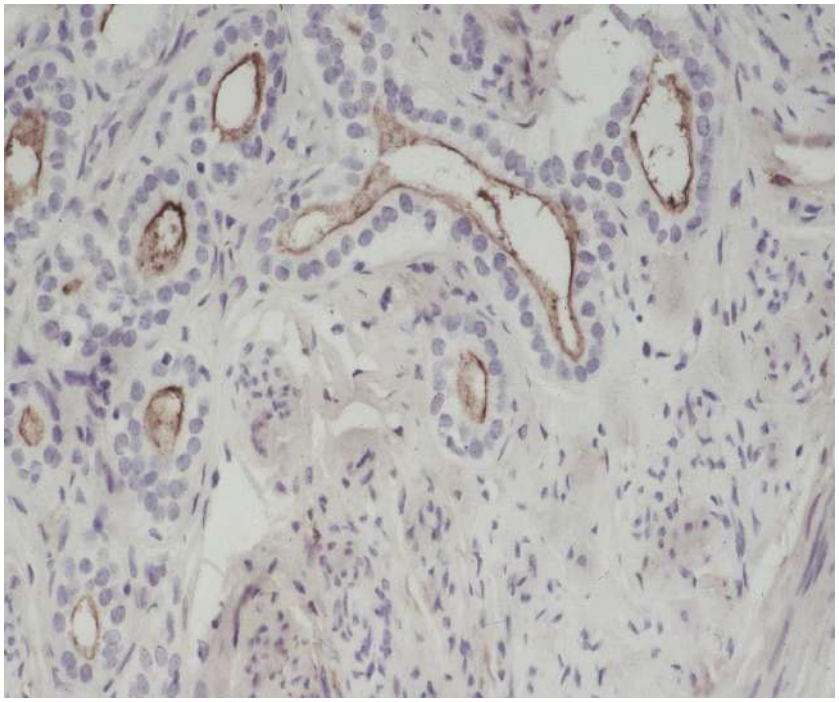

CD10

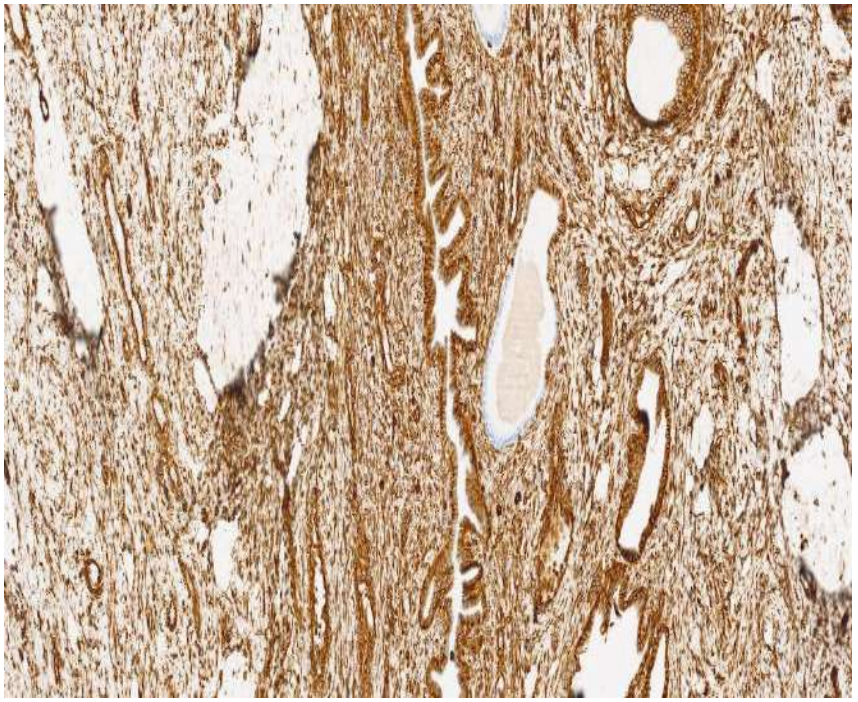

vimentin

GATA3 – MESONEPHRIC HYPERPLASIA

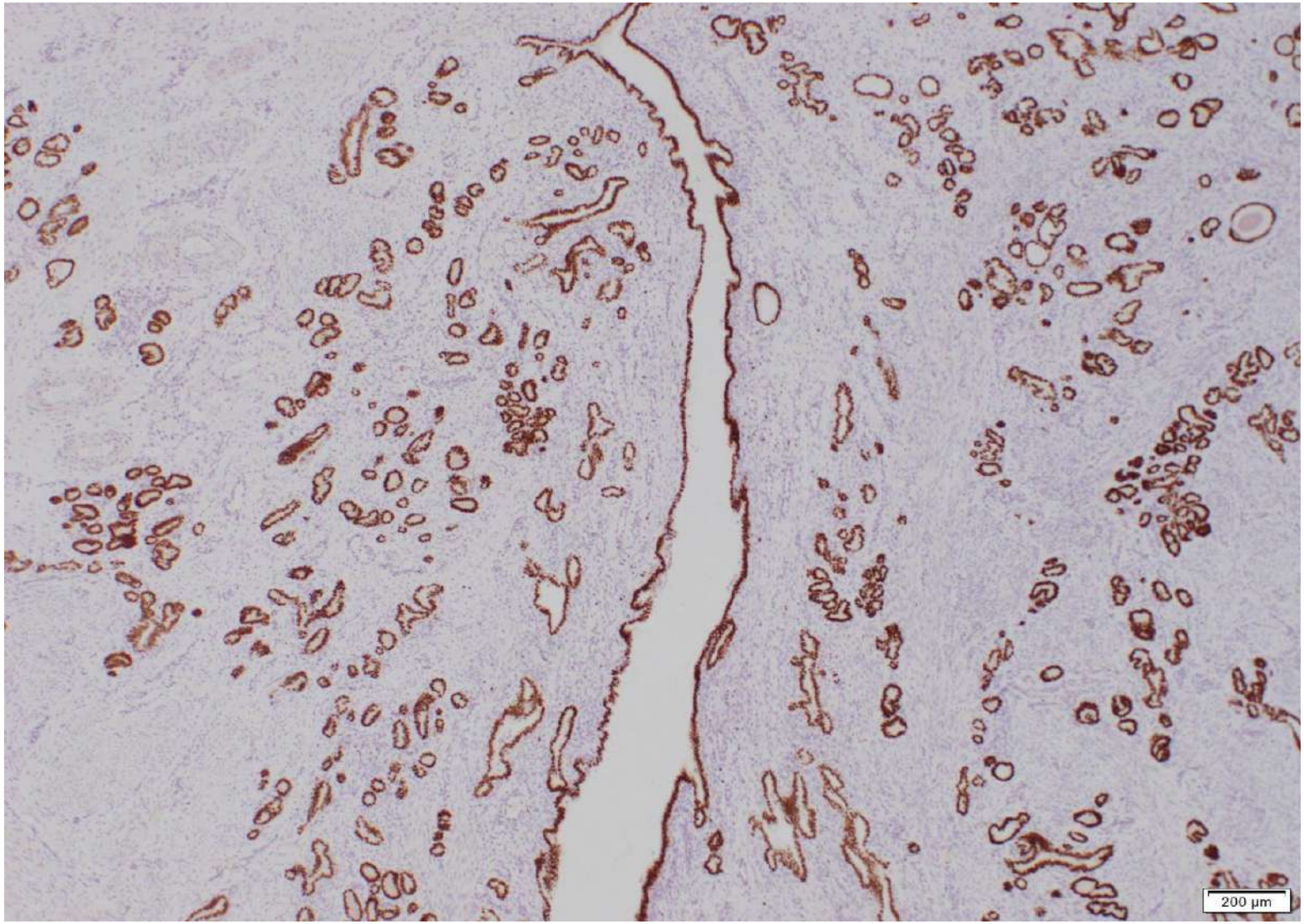

DUCTAL MESONEPHRIC REMNANTS

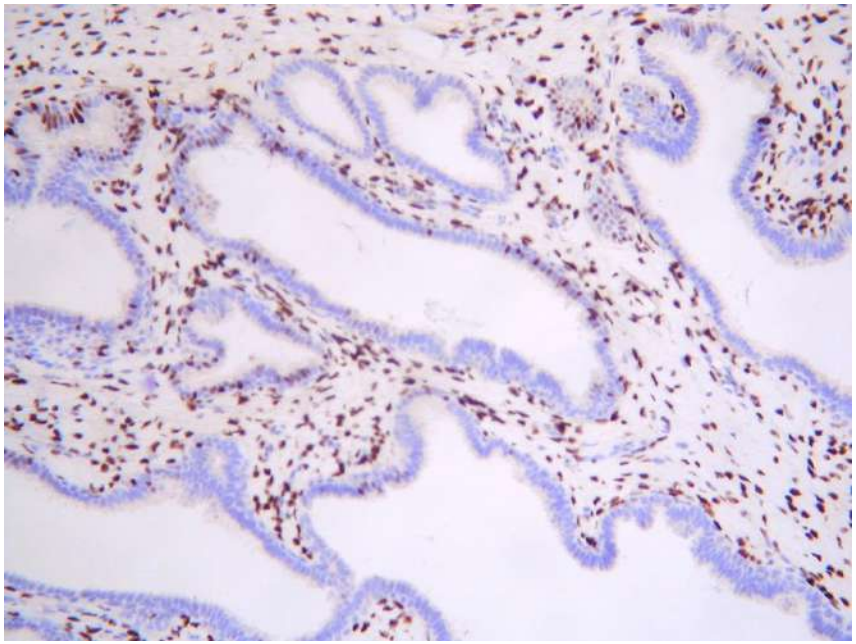

ER

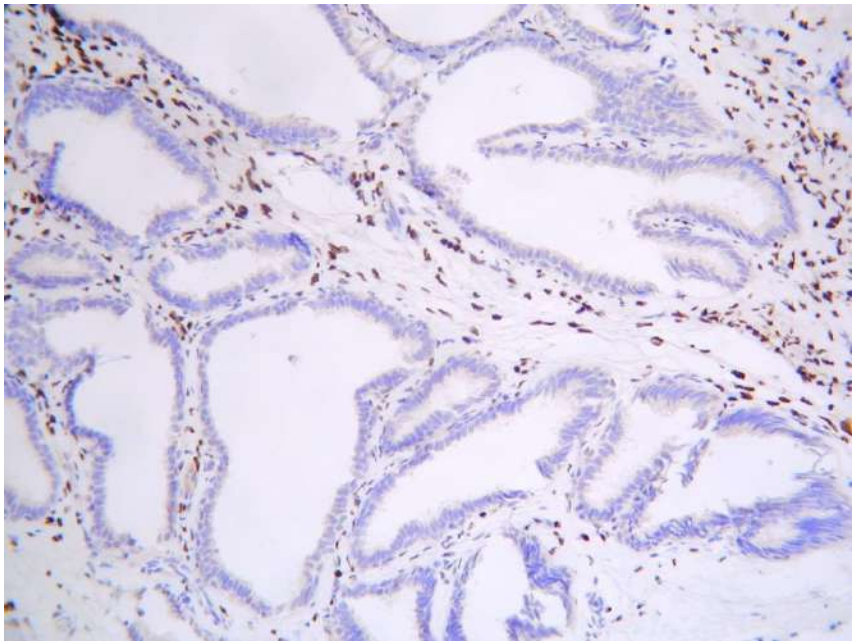

PR

MESONEPHRIC ADENOCARCINOMA

- uncommon
- most common in cervix; rarely in vagina and uterine body (uterine corpus cases may not be true mesonephric adenocarcinomas)
- admixture of morphological patterns is characteristic but my result in diagnostic problems
- may get spindle cell component (usually morphologically bland and best not to call carcinosarcoma unless heterologous elements)
- HPV-independent neoplasm
- may be associated with and arise from hyperplastic mesonephric remnants
- immunohistochemistry of some value (lots of markers suggested to be of value) but diagnosis predominantly morphological and supported by immunohistochemistry

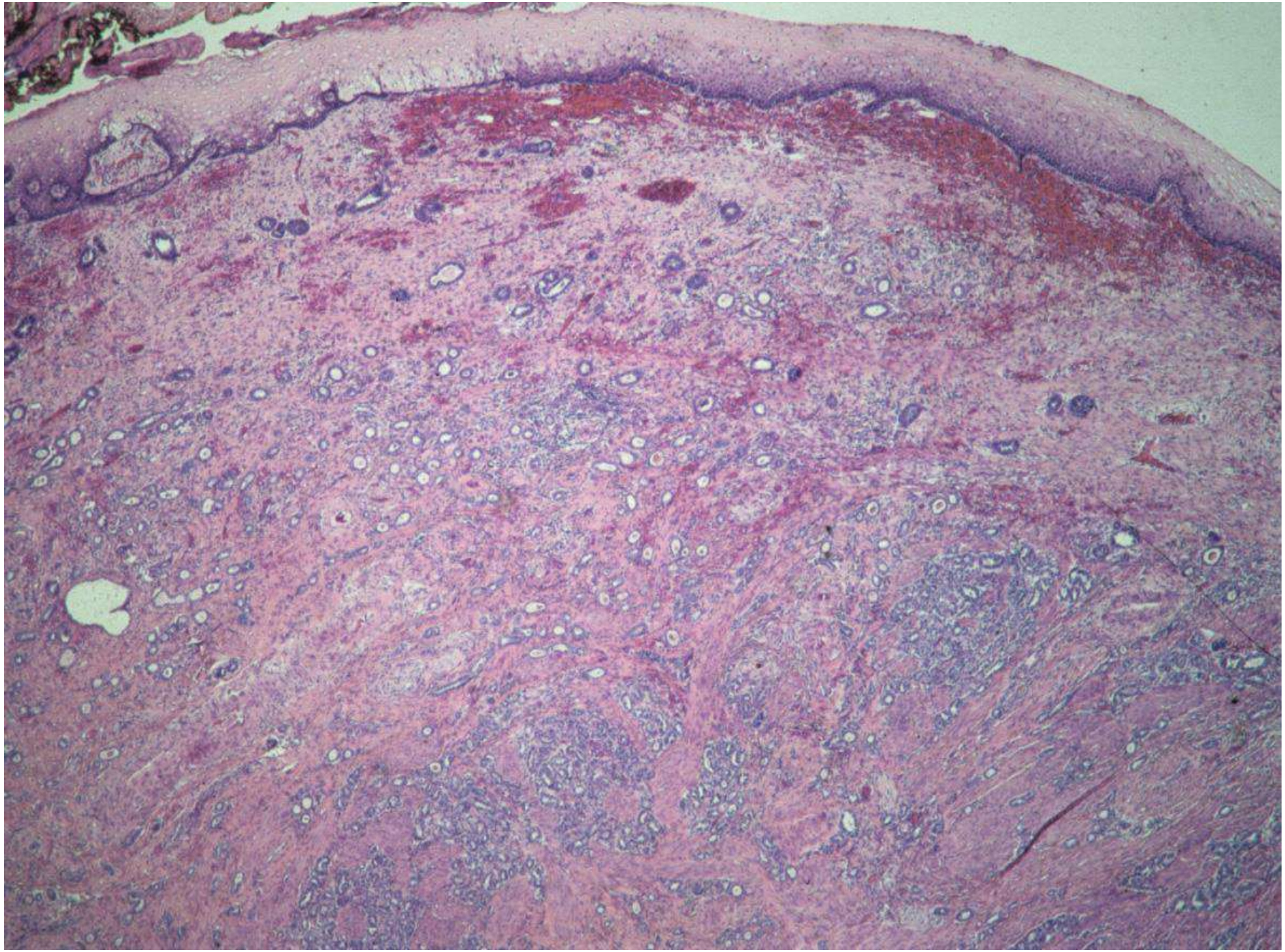

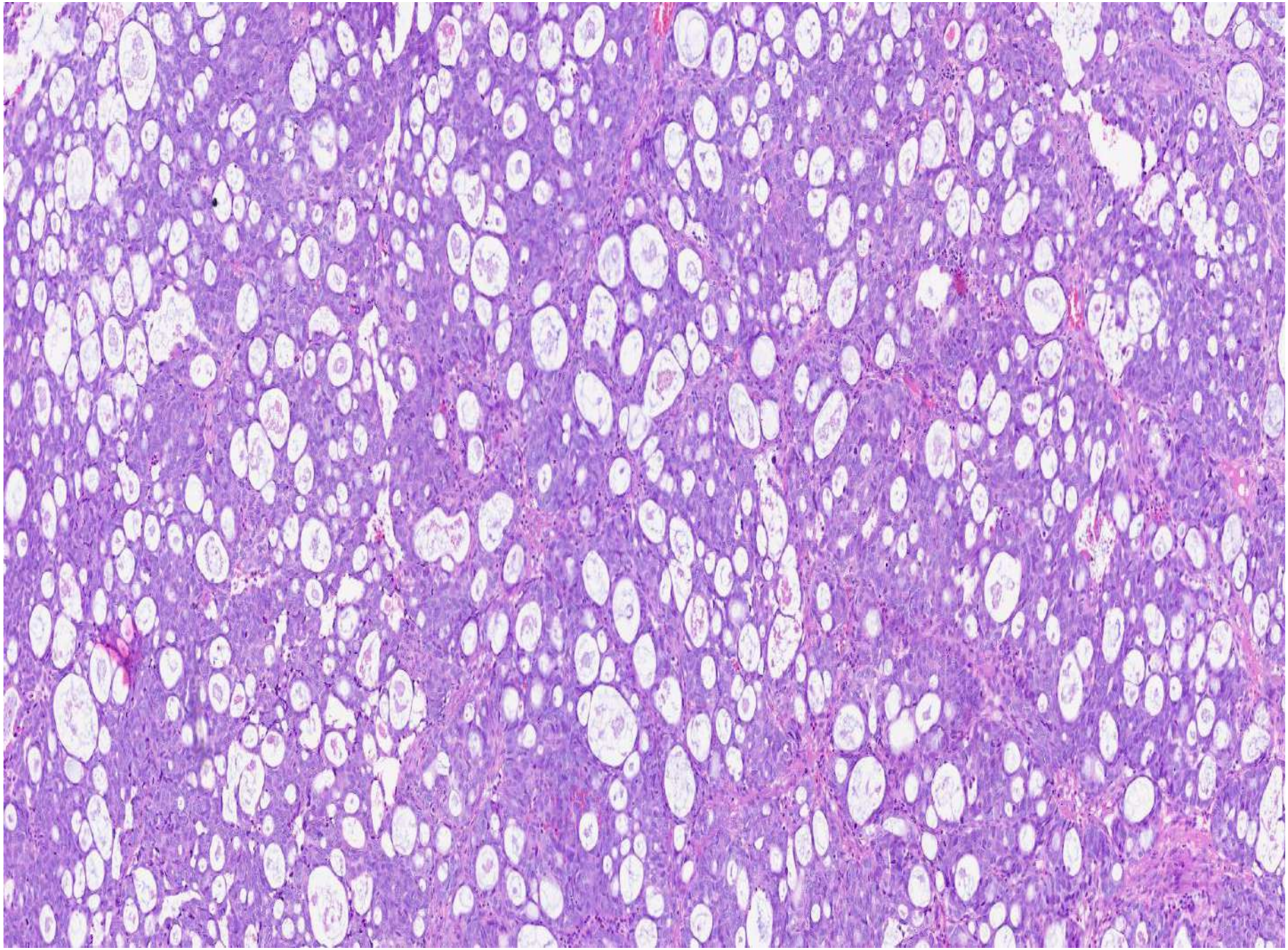

DIFFERENT PATTERNS- TUBULES

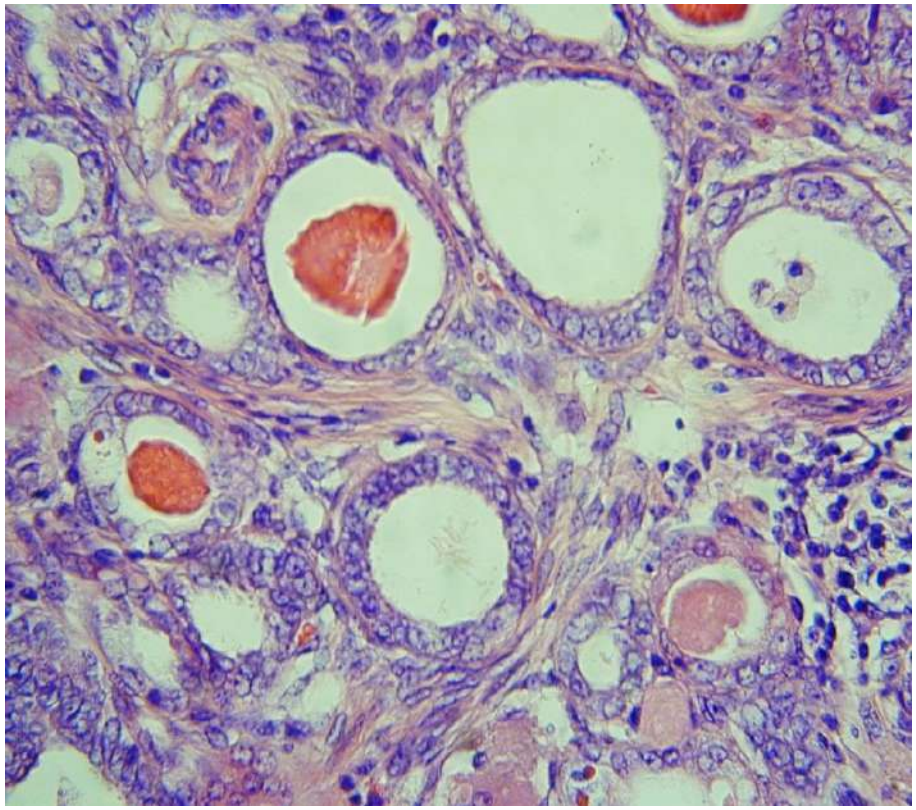

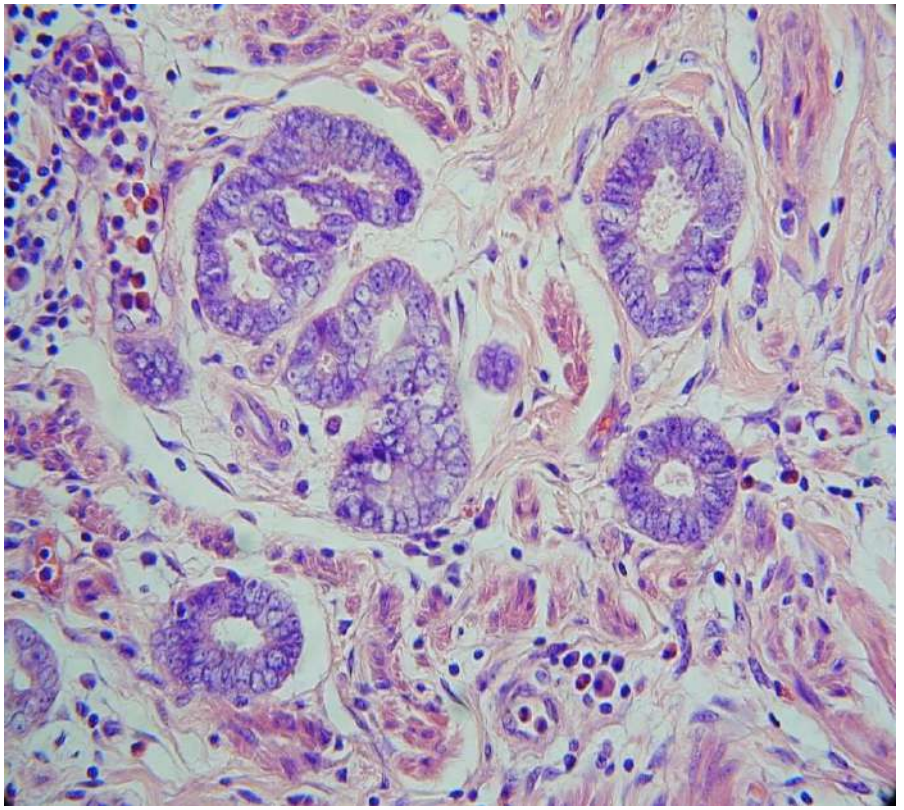

DILATED TUBULES

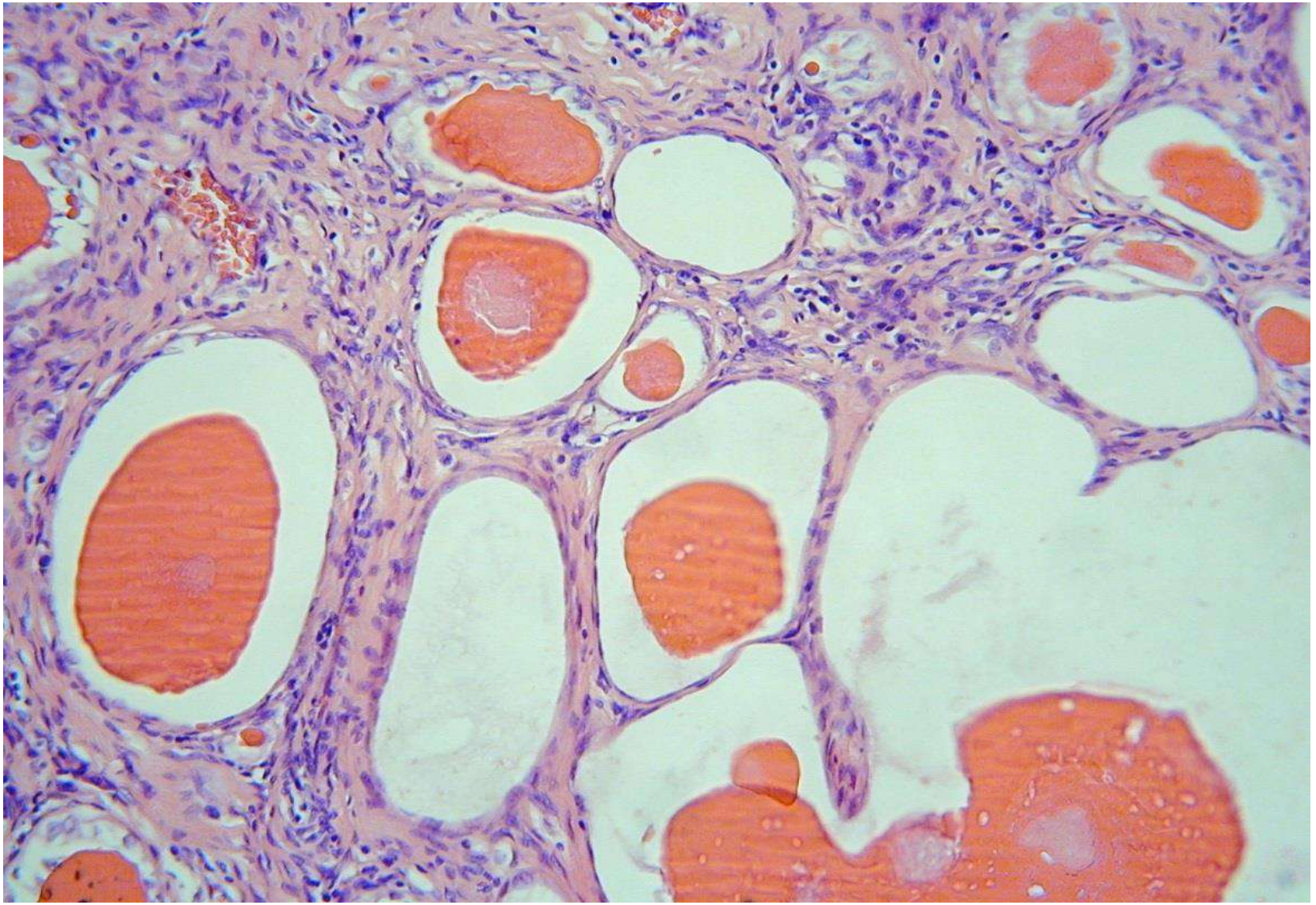

DIFFERENT PATTERNS

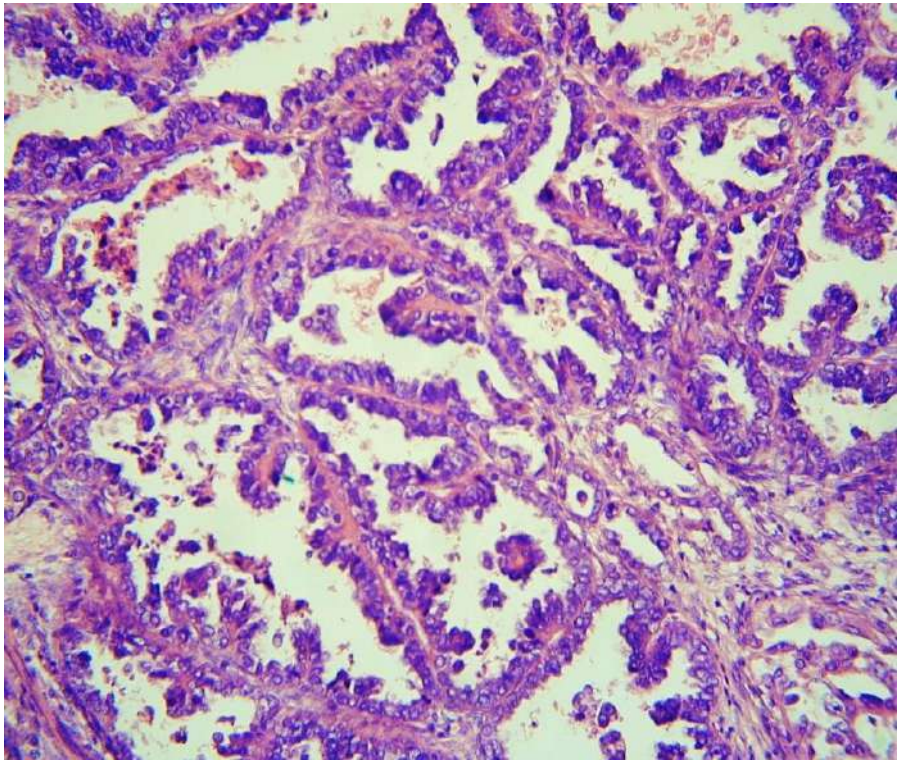

Serous-like

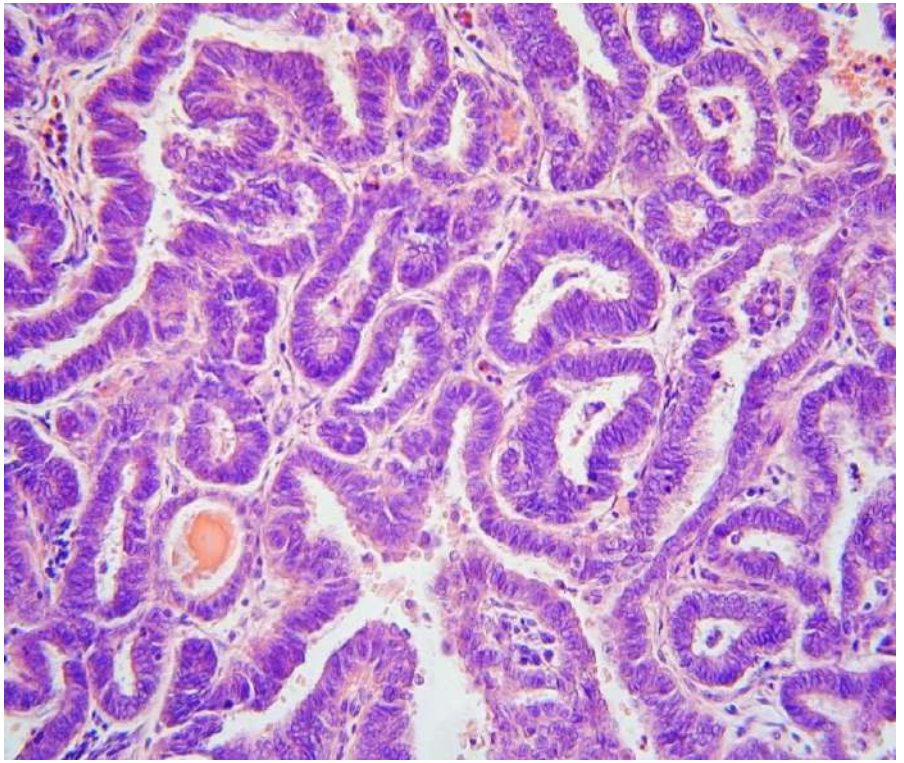

Ductal-like

DIFFERENT PATTERNS

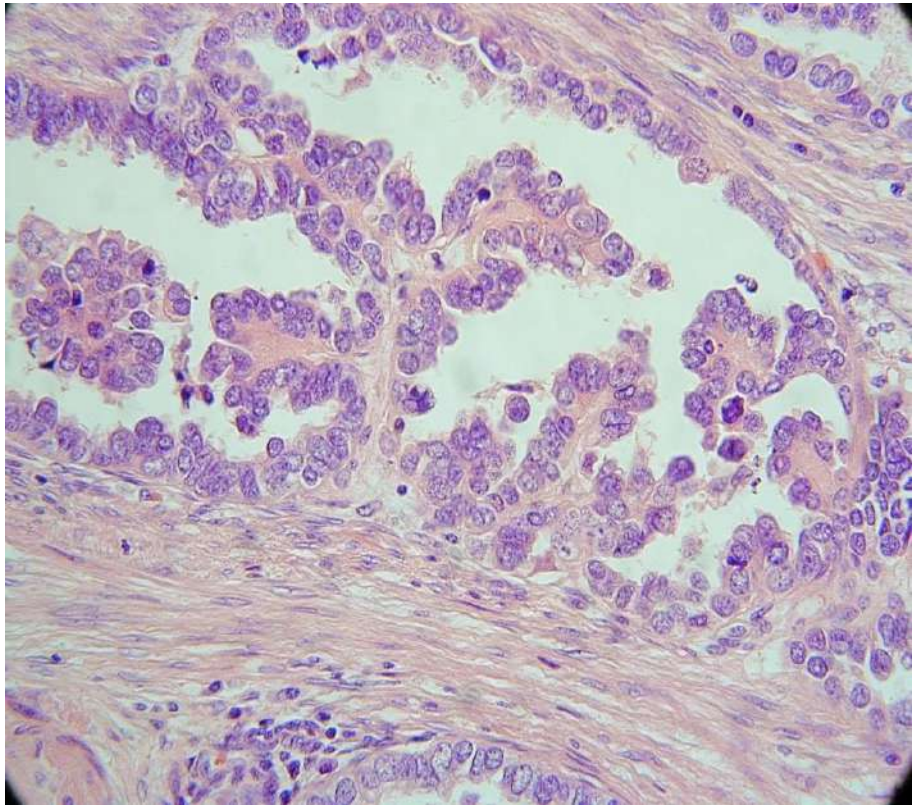

Clear cell-like

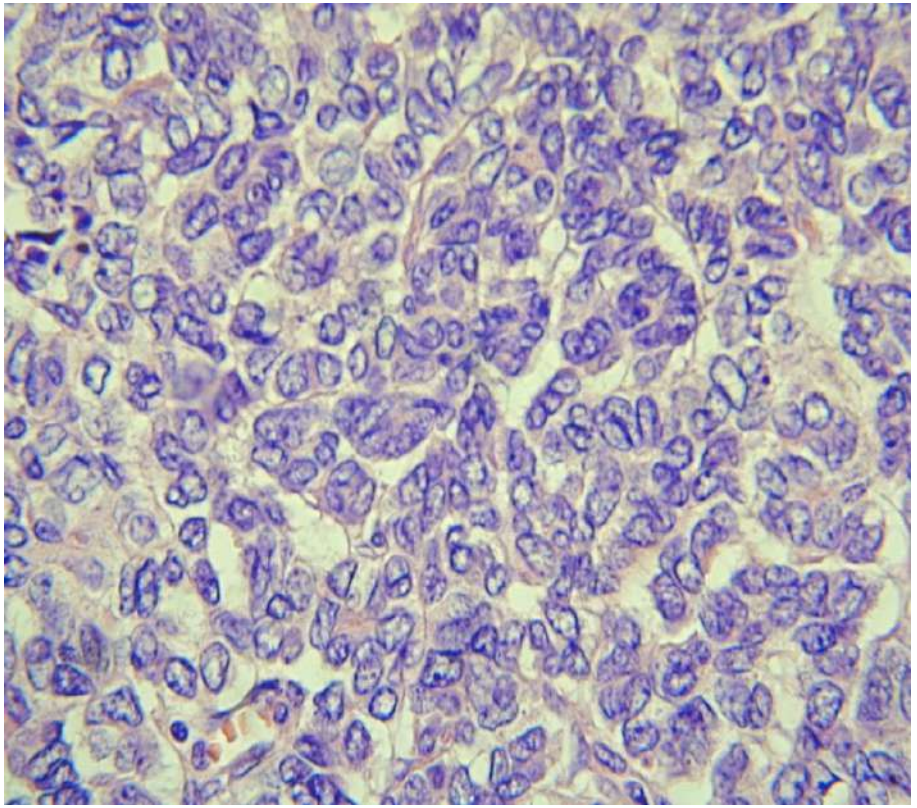

Solid/ spindled

SPINDLED AREAS

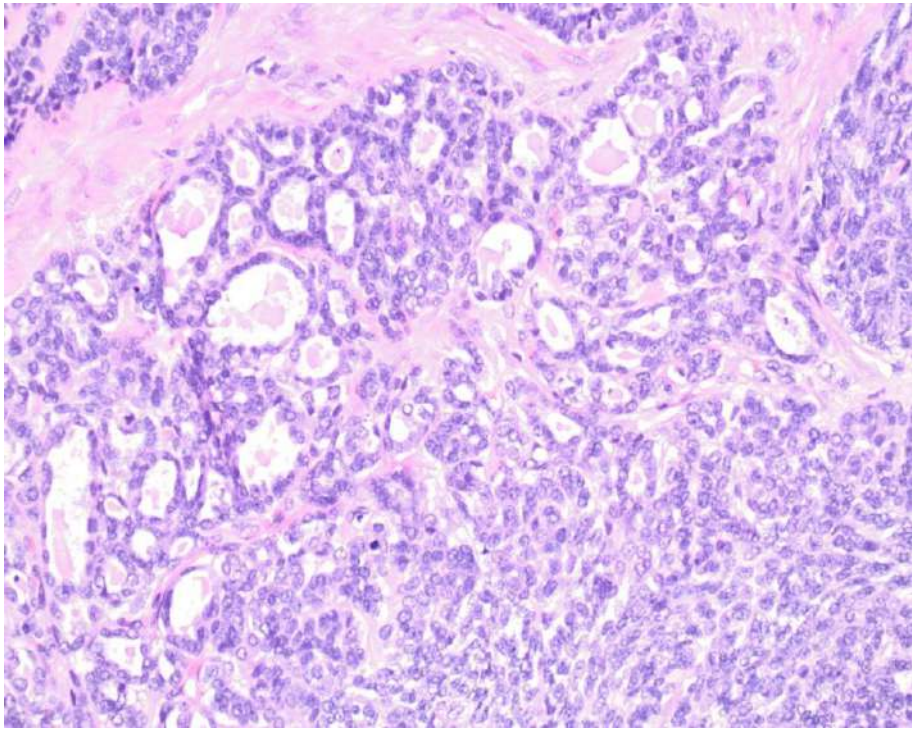

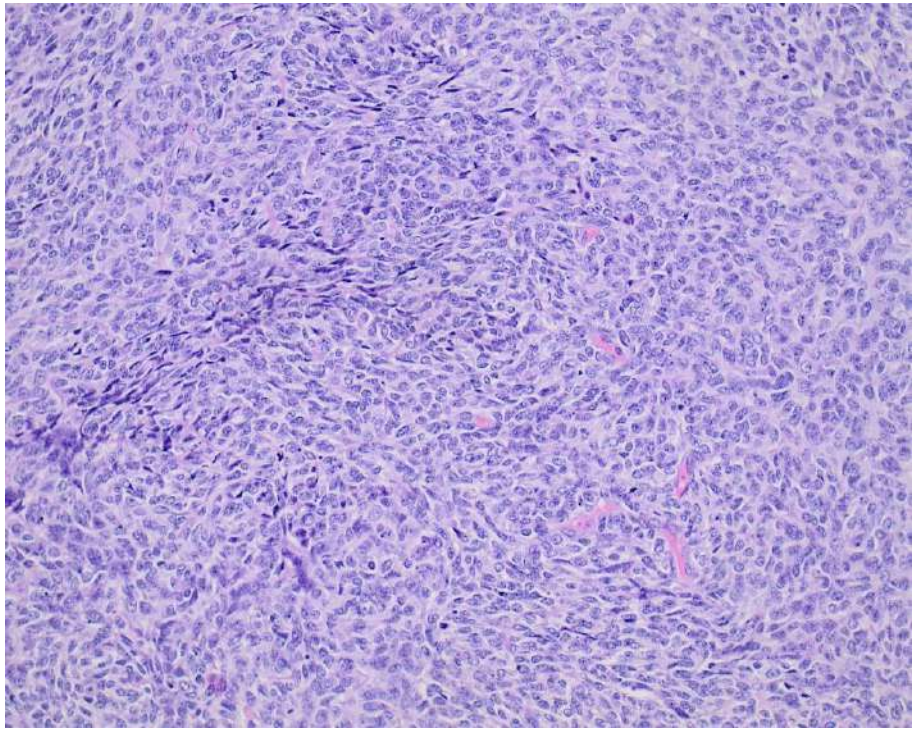

IMMUNOHISTOCHEMISTRY OF MESONEPHRIC ADENOCARCINOMA- AJSP PMID 22456609

- diagnosis largely based on morphology (no pathognomonic markers)
- inhibin, calretinin, vimentin may be positive (but variable and not reliable)
- PAX8 positive
- **CD10, GATA 3, TTF1** may be positive (but not always and not always diffuse)
- ER, PR characteristically totally/ flat negative
- p16- negative/ focal
- p53- wild-type

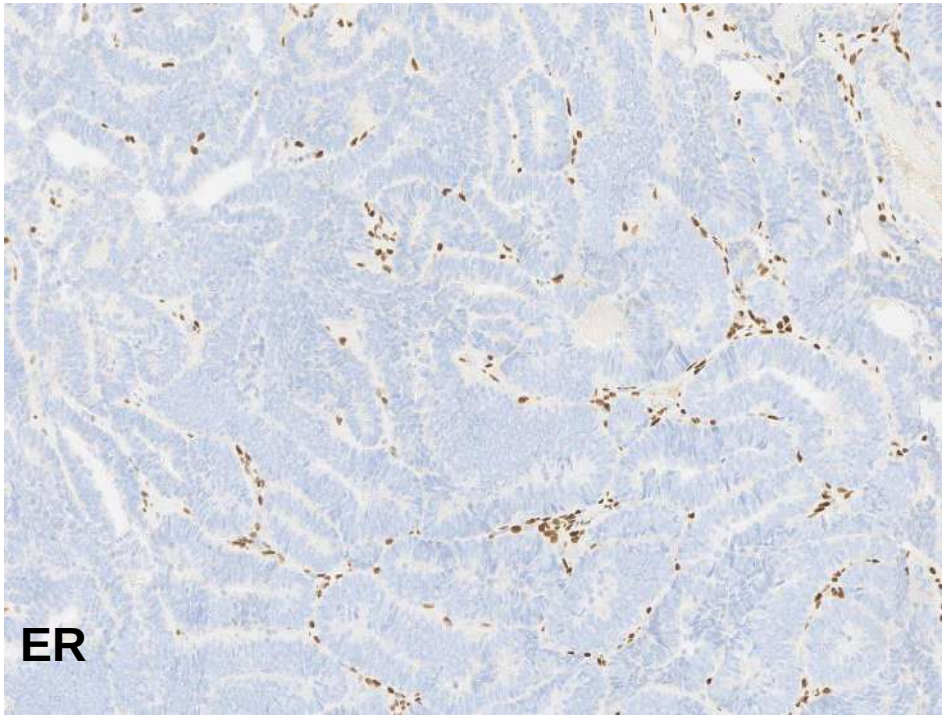
ER

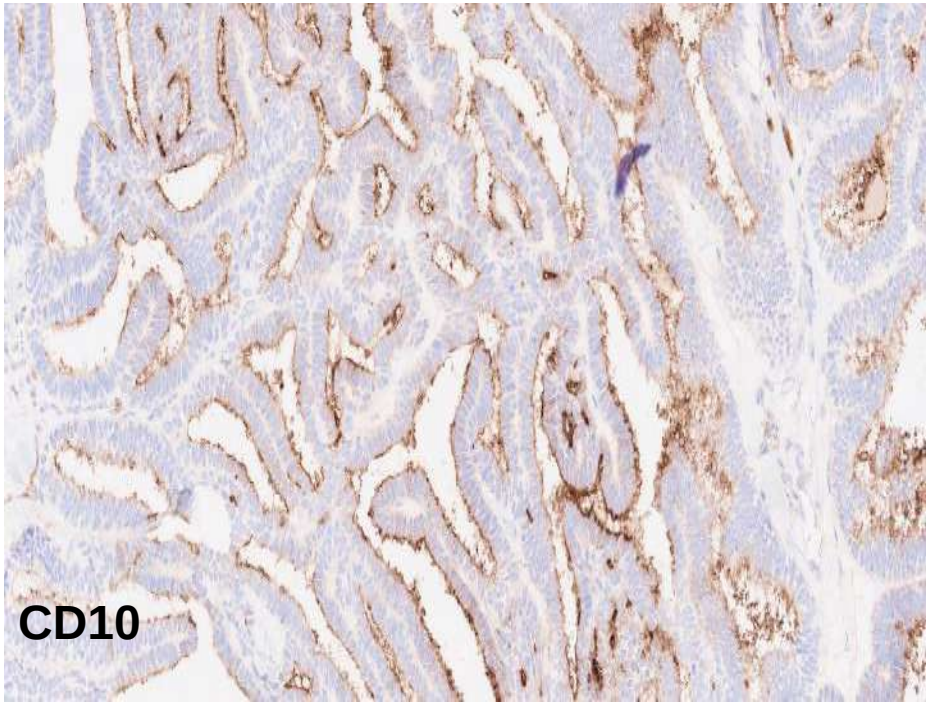
CD10

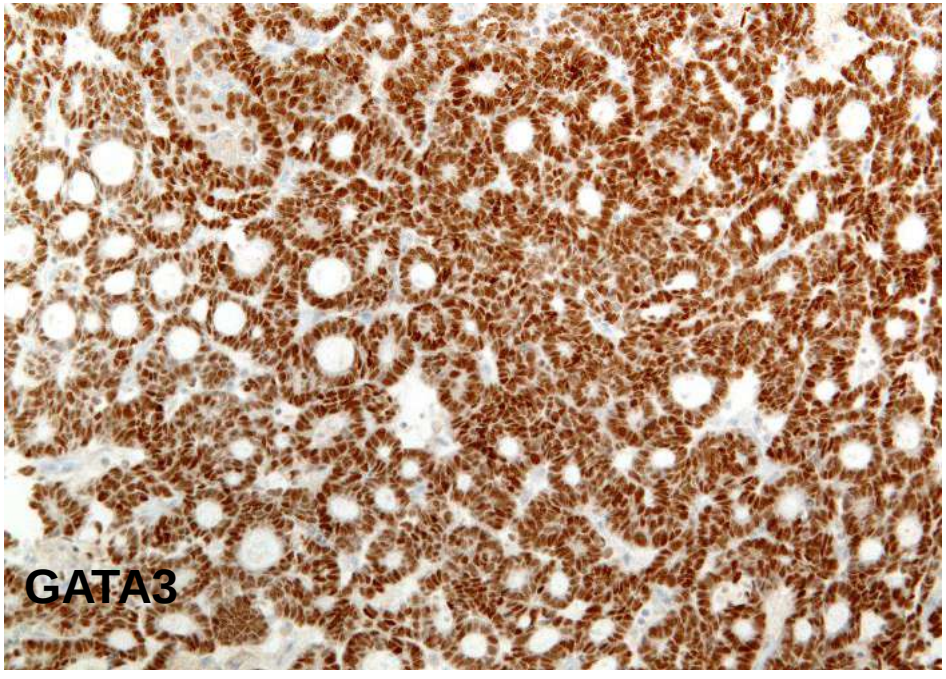
GATA3

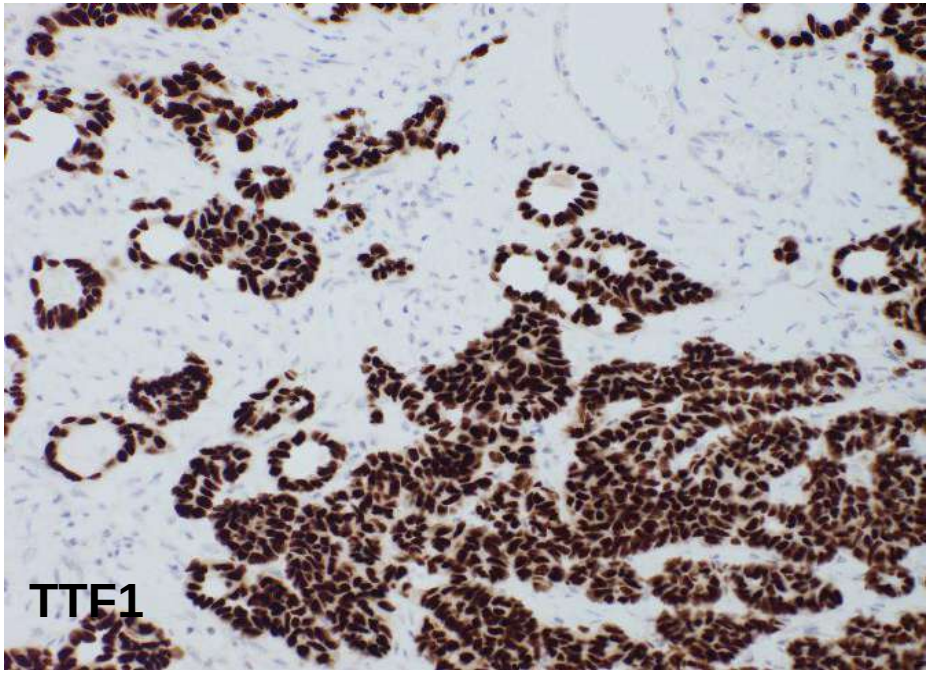
TTF1

IMMUNOHISTOCHEMISTRY-MESONEPHRIC ADENOCARCINOMA

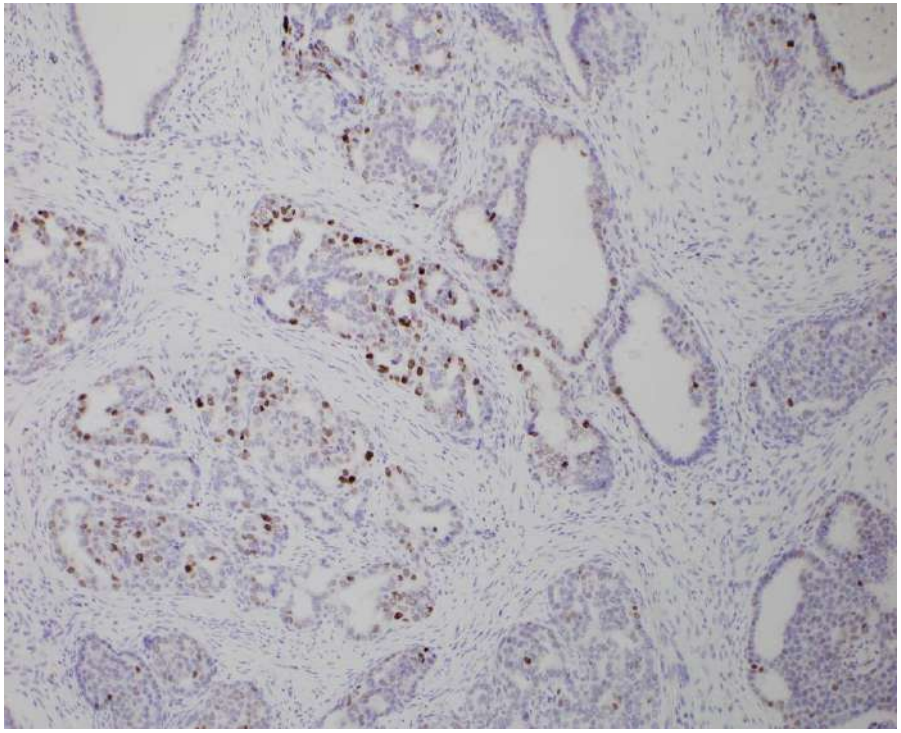

p53

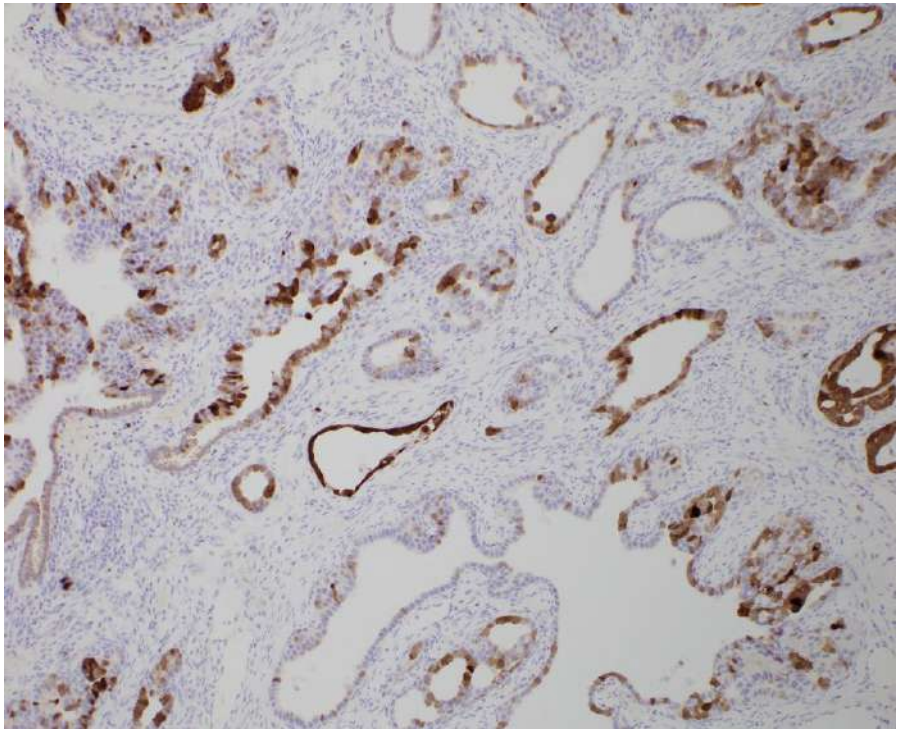

p16

MOLECULAR EVENTS IN CERVICAL MESONEPHRIC ADENOCARCINOMAS

- Modern Pathology 2015; 28; 1504-1514
- 13 of 16 (81%) had ***KRAS* or *NRAS*** mutation
- 62% had mutations in chromatin remodelling genes (*ARID1A, ARID1B, SMARCA4*)
- Different molecular events than in other cervical adenocarcinomas and endometrial adenocarcinomas

DIFFERENTIAL OF MESONEPHRIC ADENOCARCINOMA

- **Diffuse mesonephric hyperplasia**
- HPV-associated and other primary cervical adenocarcinomas (clear cell carcinoma most problematic)
- Endometrial carcinomas (endometrioid, clear cell, serous, carcinosarcoma)
- Subtle cervical involvement by endometrioid carcinoma of corpus
- Mesonephric-like adenocarcinoma

DIFFERENTIATION BETWEEN DIFFUSE MESONEPHRIC HYPERPLASIA AND MESONEPHRIC ADENOCARCINOMA

- **mass lesion versus incidental microscopic finding**
- lobular pattern suggests hyperplasia
- more crowding, destructive stromal invasion, nuclear atypia and mitotic activity in carcinoma
- various architectural patterns more in keeping with mesonephric adenocarcinoma
- sometimes vascular and perineural infiltration and extension beyond cervix in adenocarcinoma
- OCCASIONALLY IMPOSSIBLE OR VERY DIFFICULT MORPHOLOIGCALLY
- demonstration of *KRAS* or *NRAS* mutation may be useful in confirming adenocarcinoma (no mutations in mesonephric hyperplasia- PMID 28703285)

CASE 4

- F35
- Repeat LLETZ following LLETZ with CIN III at margins

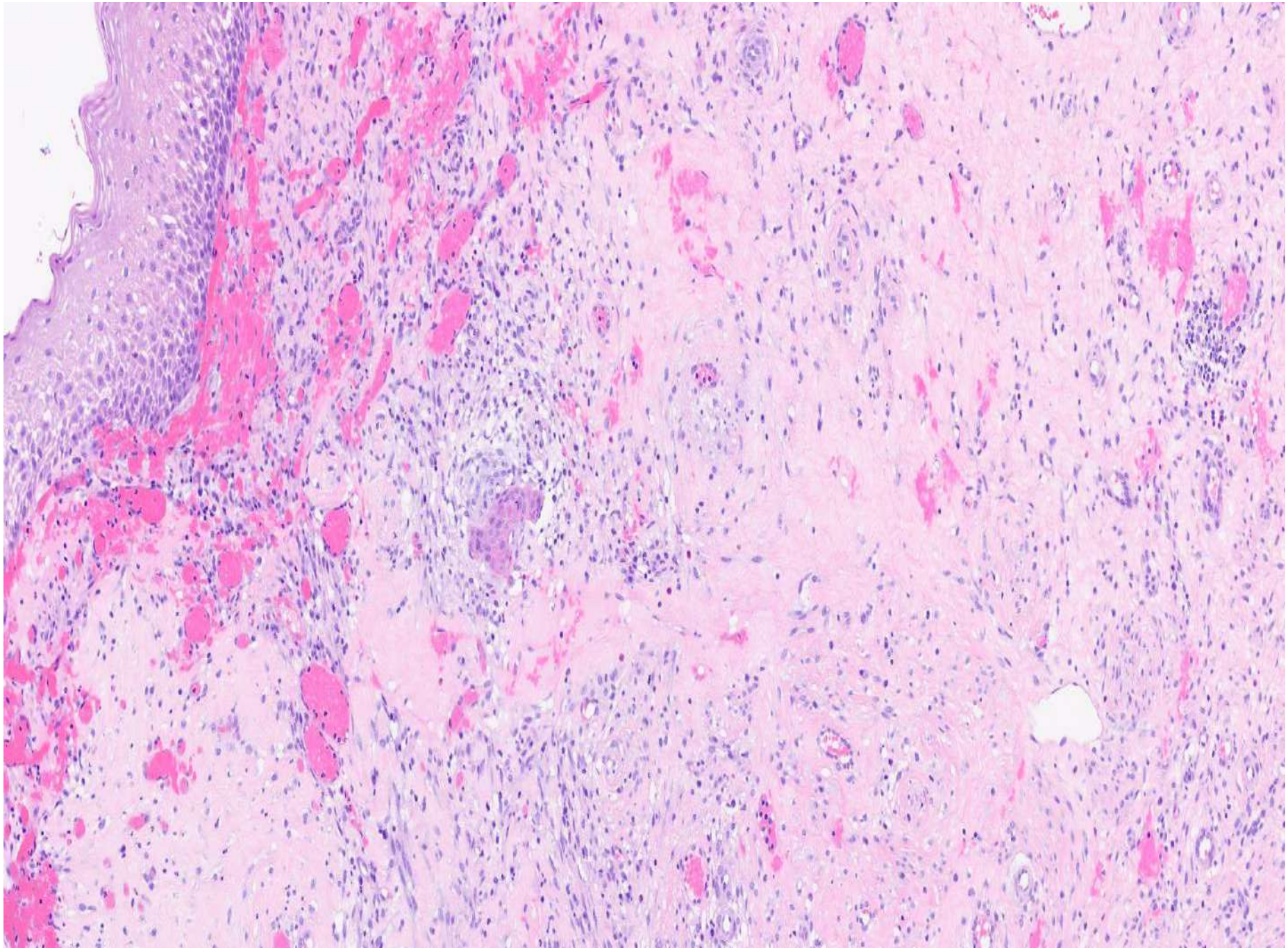

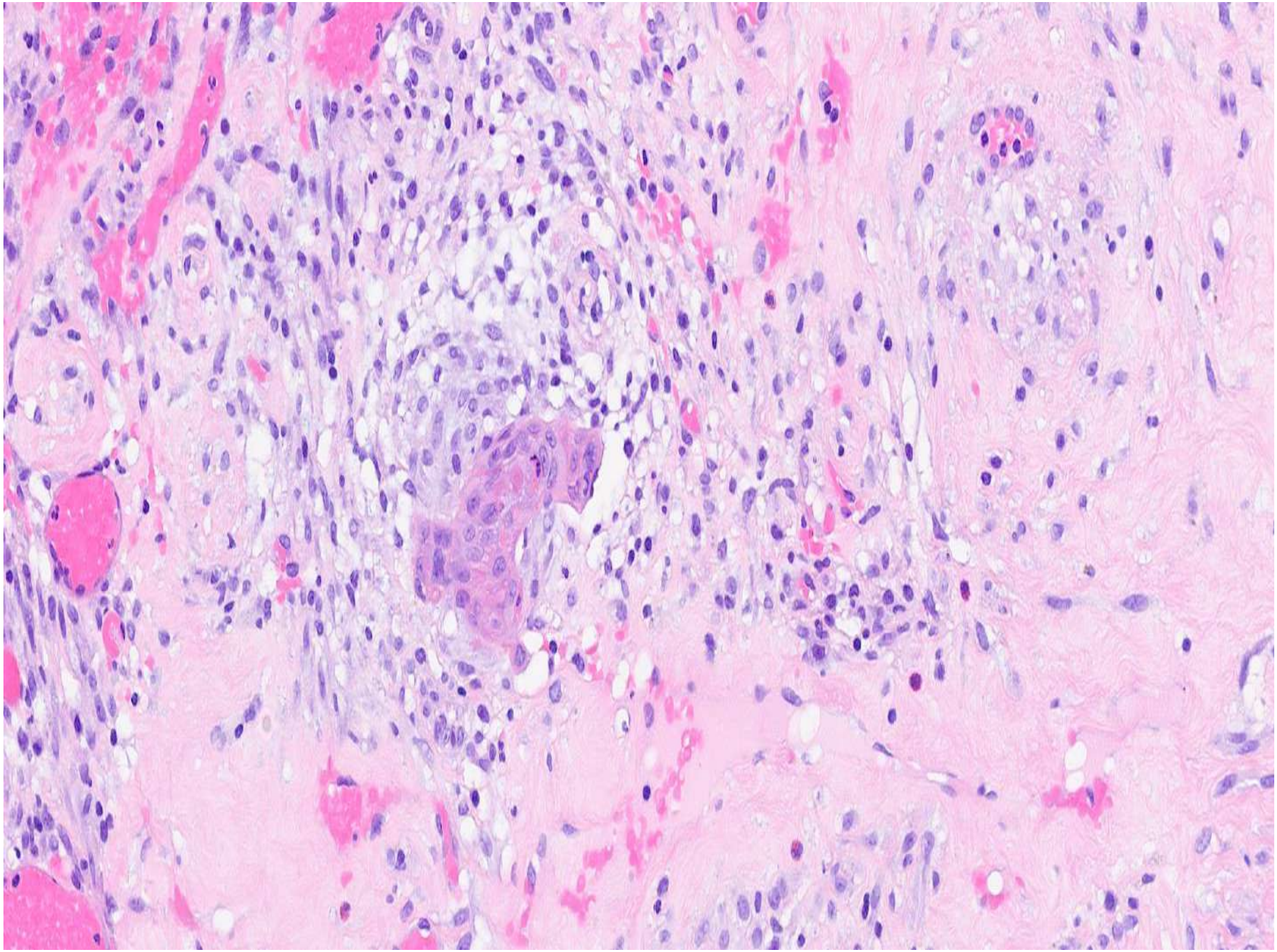

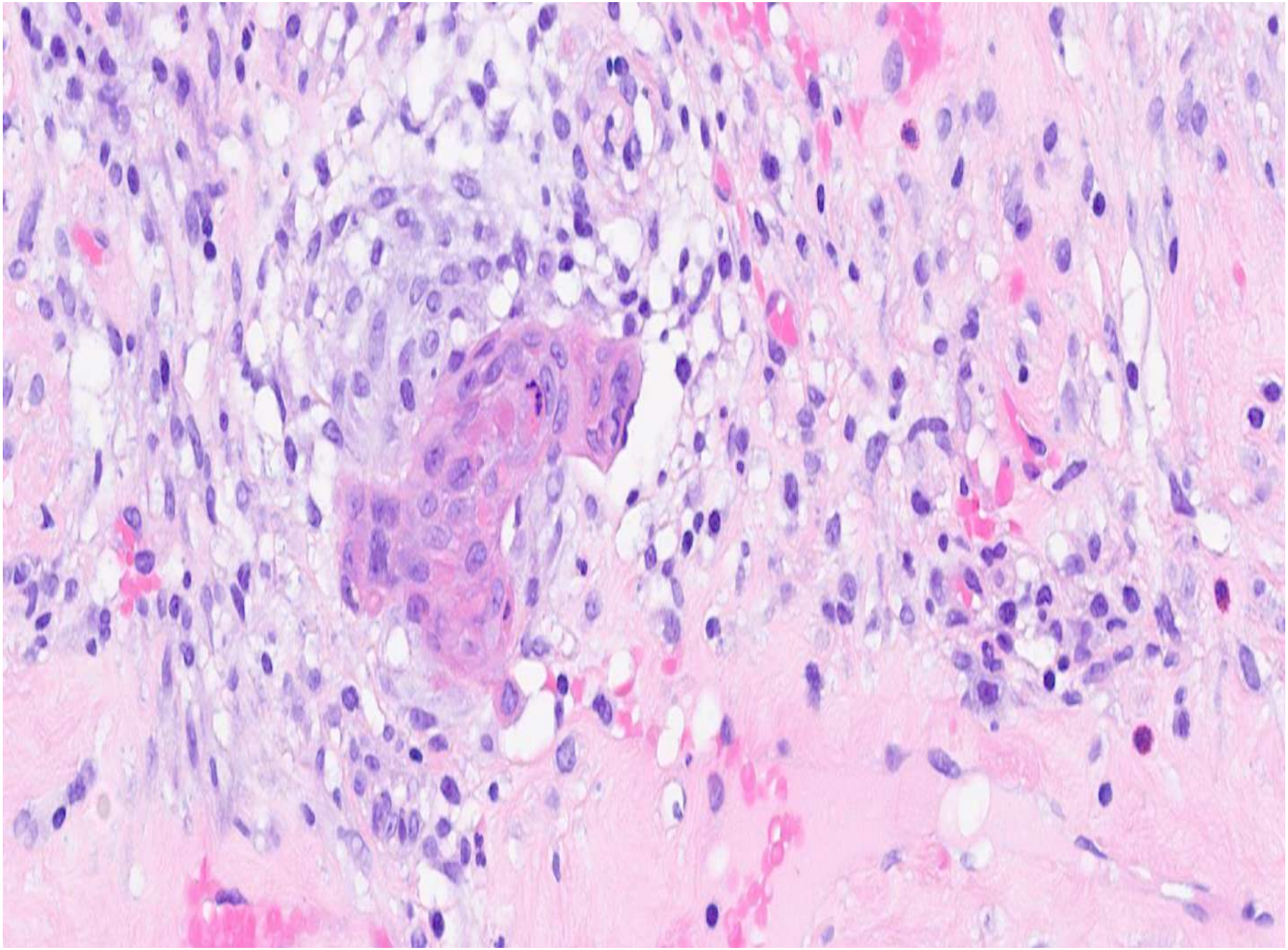

? DIAGNOSIS

ORIGINAL DIAGNOSIS

- No residual CIN
- Single small focus of squamous cell carcinoma (FIGO IA1)

DIAGNOSIS- PSEUDOINVASION FOLLOWING CERVICAL BIOPSY- PMID 21896582

Downloaded from jcp.bmj.com on November 17, 2011 - Published by group.bmj.com

Original article

Pseudoinvasion of benign squamous epithelium following cervical biopsy: a pseudoneoplastic phenomenon mimicking invasive squamous carcinoma

David P Boyle, W Glenn McCluggage

PSEUDOINVASION FOLLOWING CERVICAL BIOPSY- PMID 21896582

- Pseudoneoplastic lesion following biopsy or loop excision which may mimic squamous cell carcinoma
- Typically hypereosinophilic appearance
- May be associated granulation-type reaction and/ or haemosiderin and/ or histiocytes and multinucleate giant cells
- Sometimes in spaces which may mimic LVSI
- p16 may be useful

PSEUDOINVASION FOLLOWING CERVICAL BIOPSY- PMID 21896582

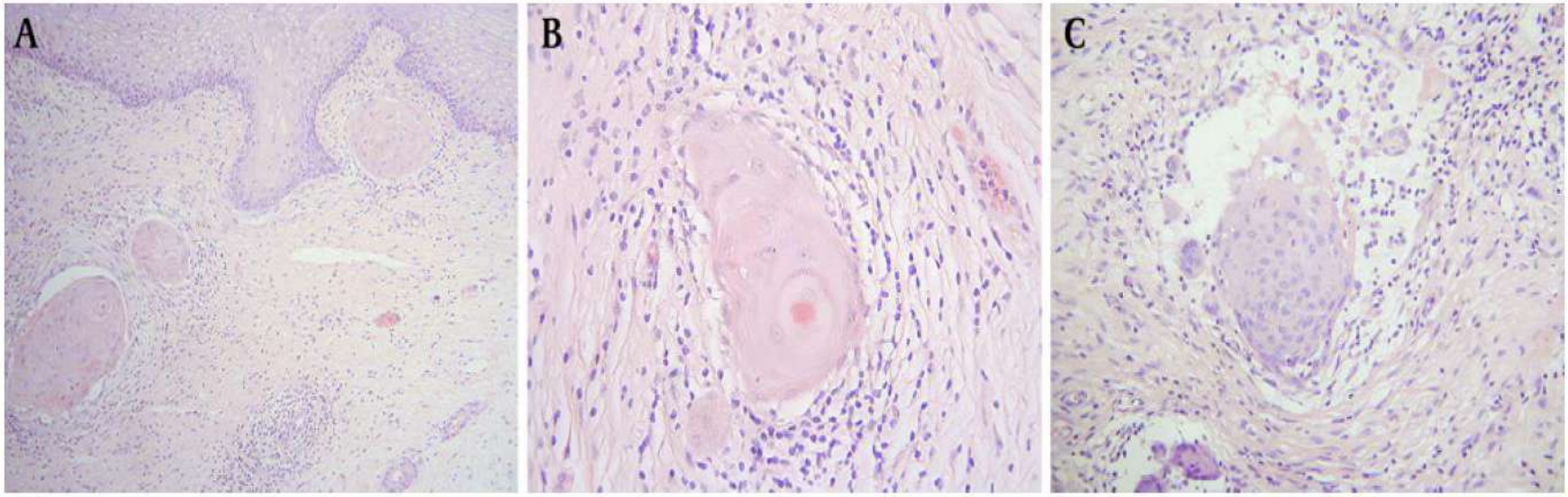

Figure 1 (A) Nest of squamous cells present deep to normal surface squamous epithelium. (B) The nests of squamous cells have a hypereosinophilic appearance. (C) The surrounding stroma is oedematous and inflamed and has a granulation tissue-like appearance.

PSEUDOINVASION FOLLOWING CERVICAL BIOPSY- PMID 21896582

Figure 2 (A) The nests of squamous cells are surrounded by inflammatory cells, including multinucleate giant cells. (B) Some of the nests of squamous epithelium are surrounded by clefts representing retraction artefact but simulating lymphovascular invasion.

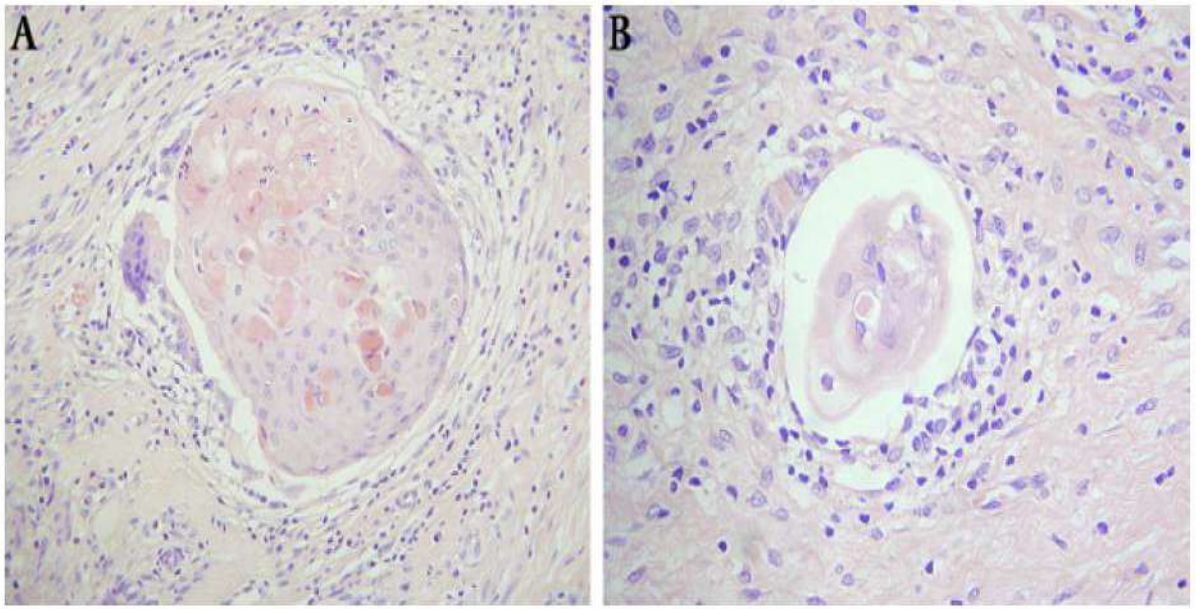

PSEUDOINVASION IN CONDYLOMA FOLLOWING CERVICAL BIOPSY

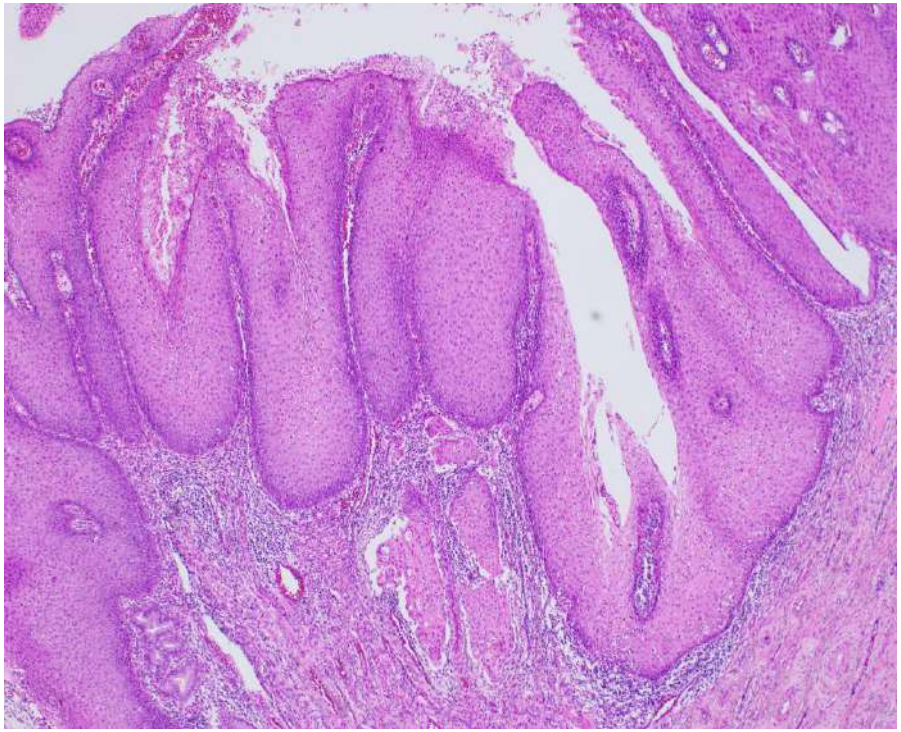

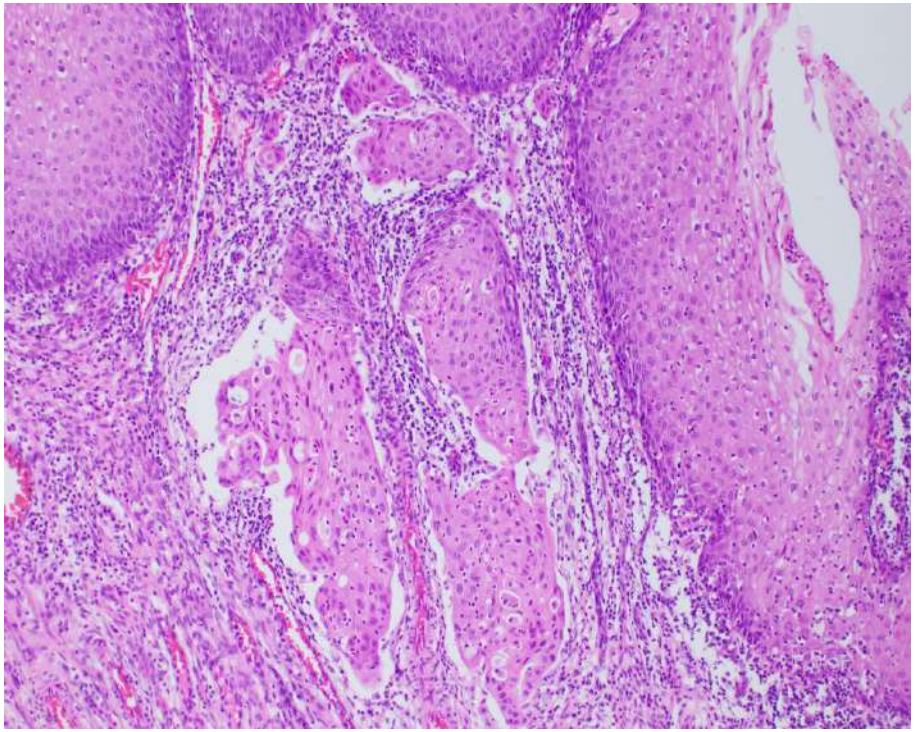

PSEUDOINVASION IN CONDYLOMA FOLLOWING CERVICAL BIOPSY

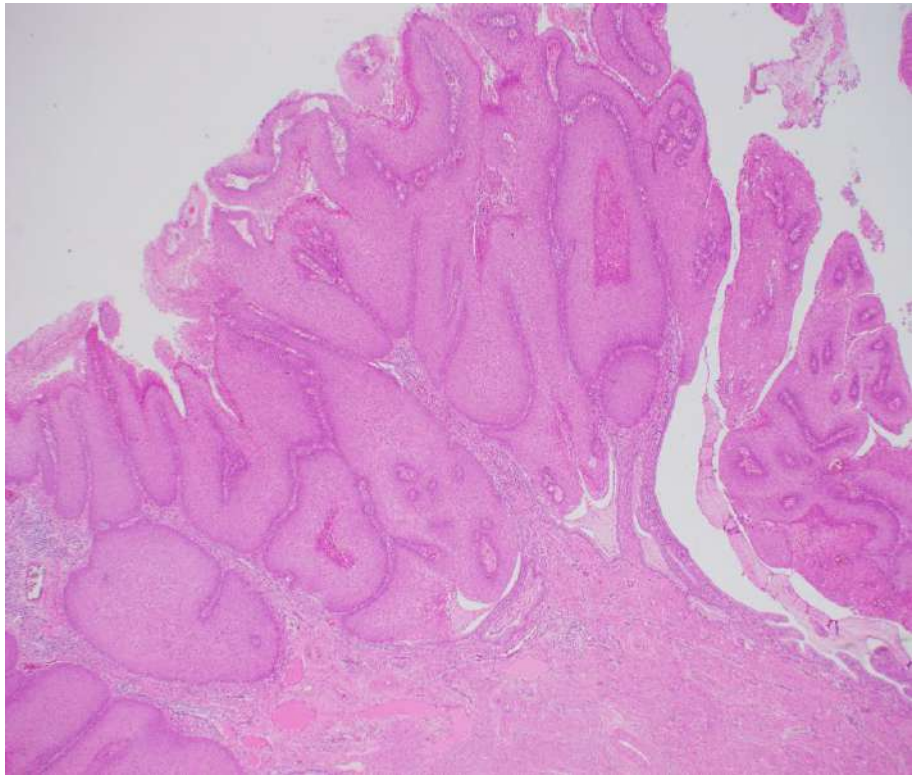

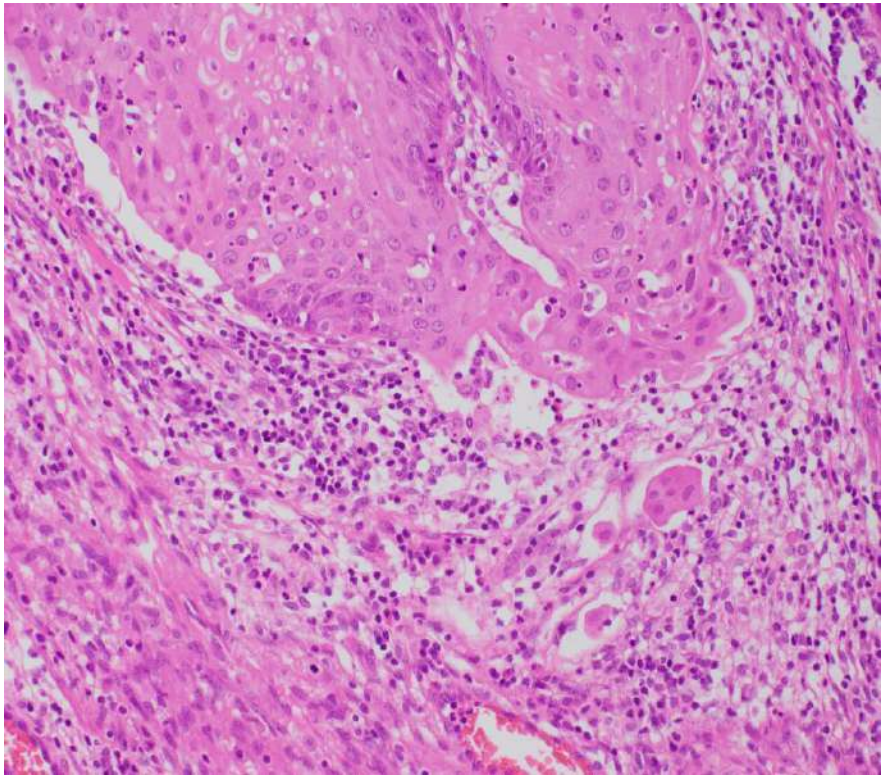

PSEUDOINVASION FOLLOWING CERVICAL BIOPSY- p16

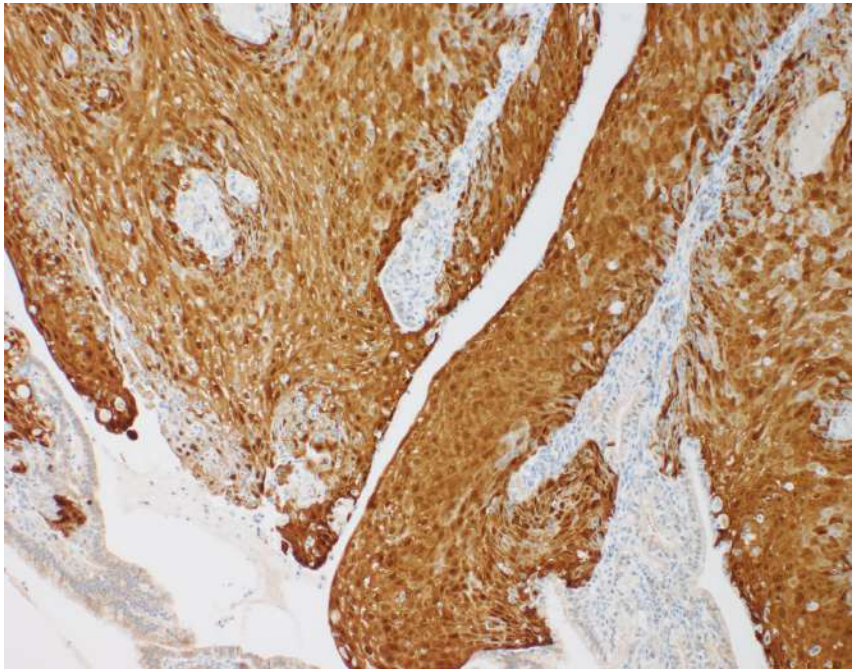

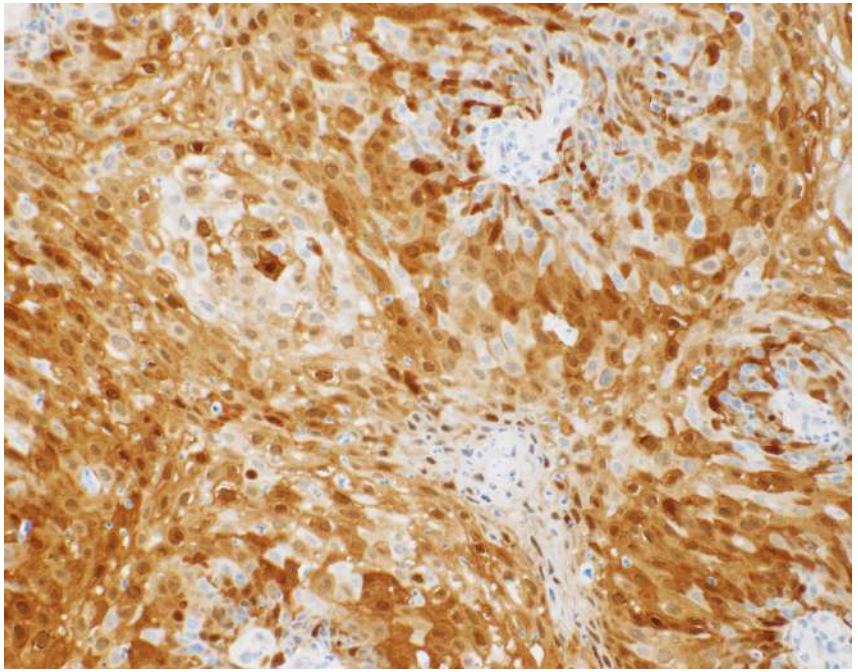

CASE 5

- F41
- Wart-like lesion on surface of cervix
- Punch biopsy reported as squamous cell carcinoma
- SUBSEQUENT LLETZ PERFORMED

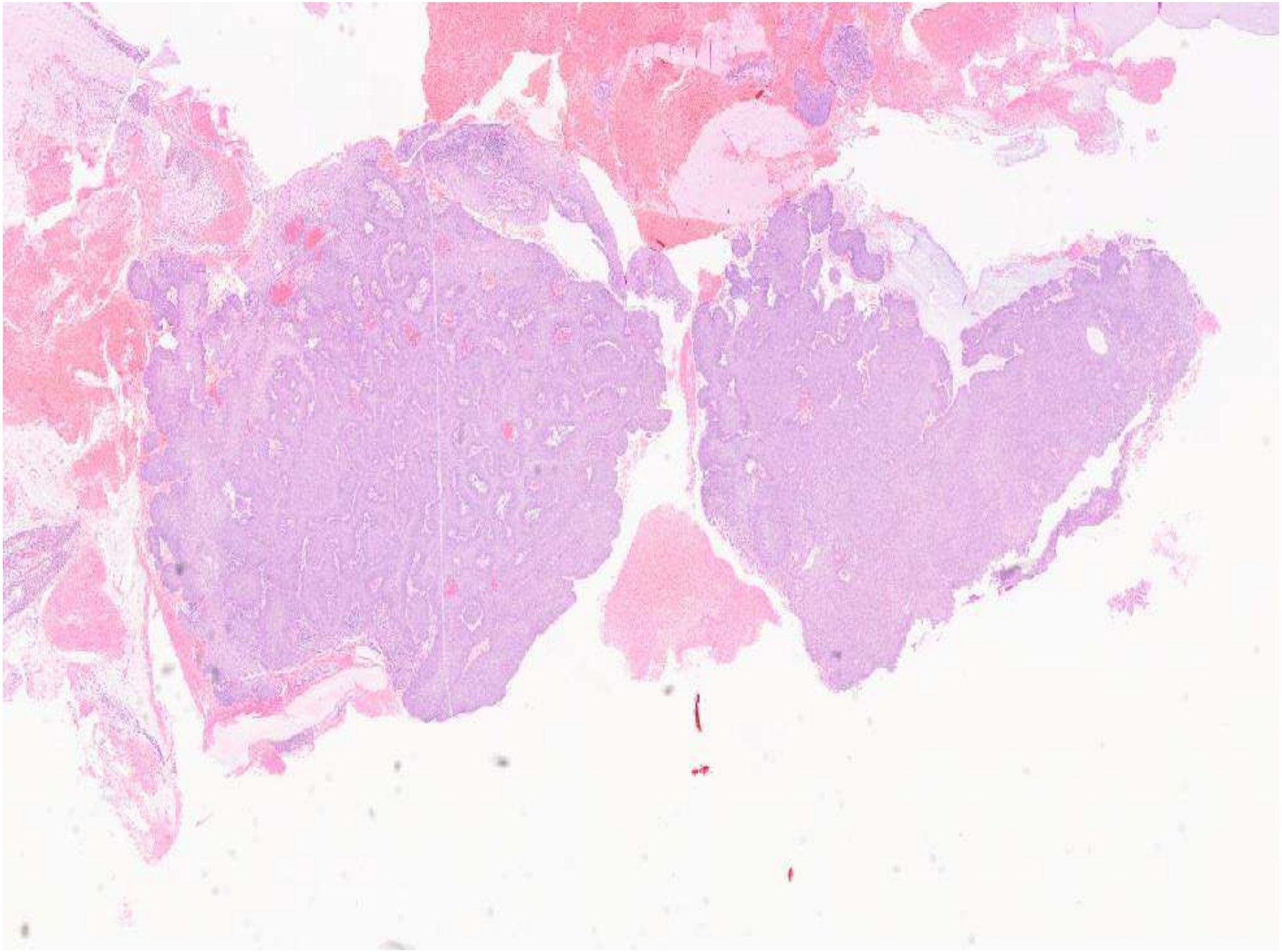

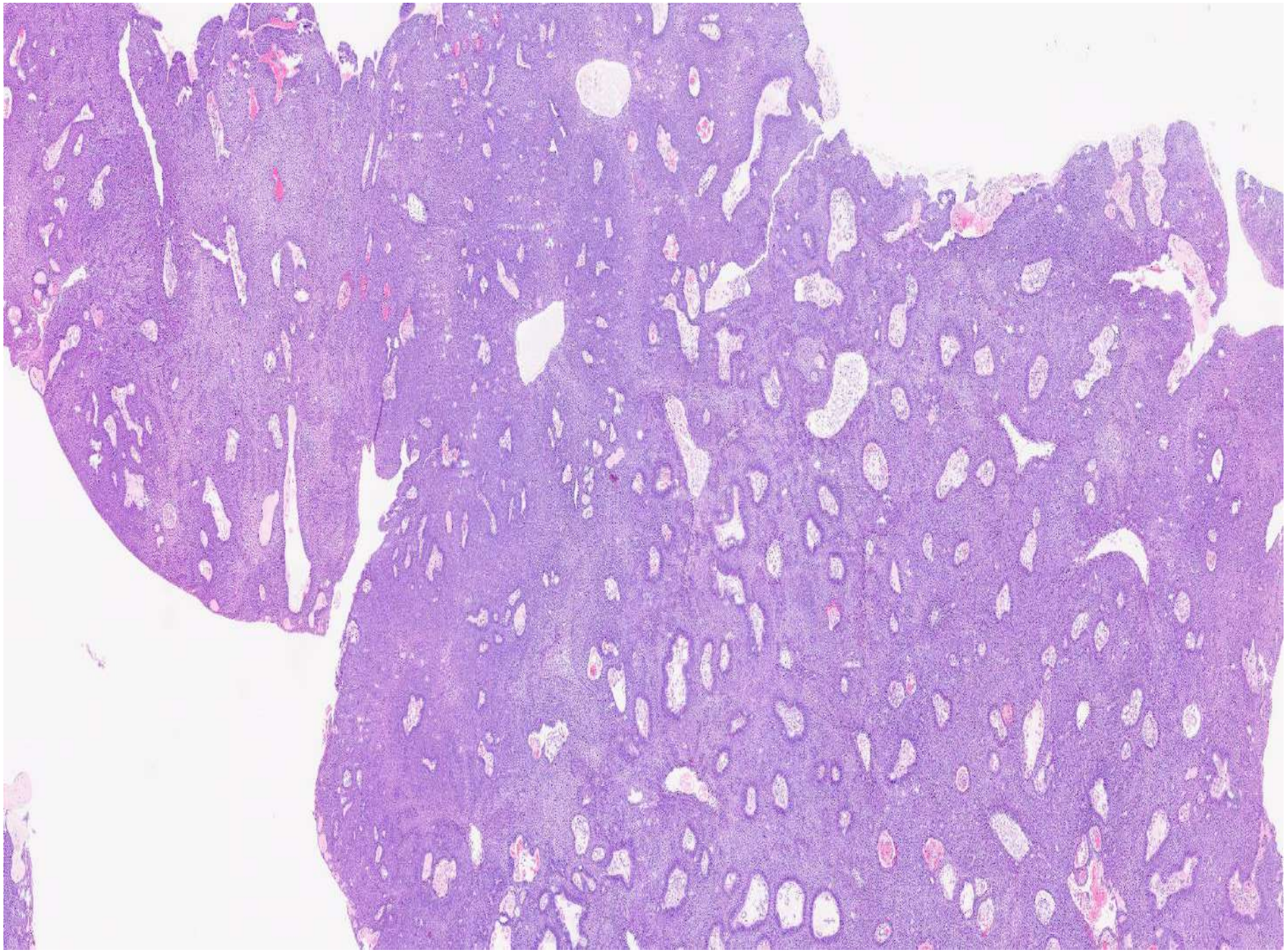

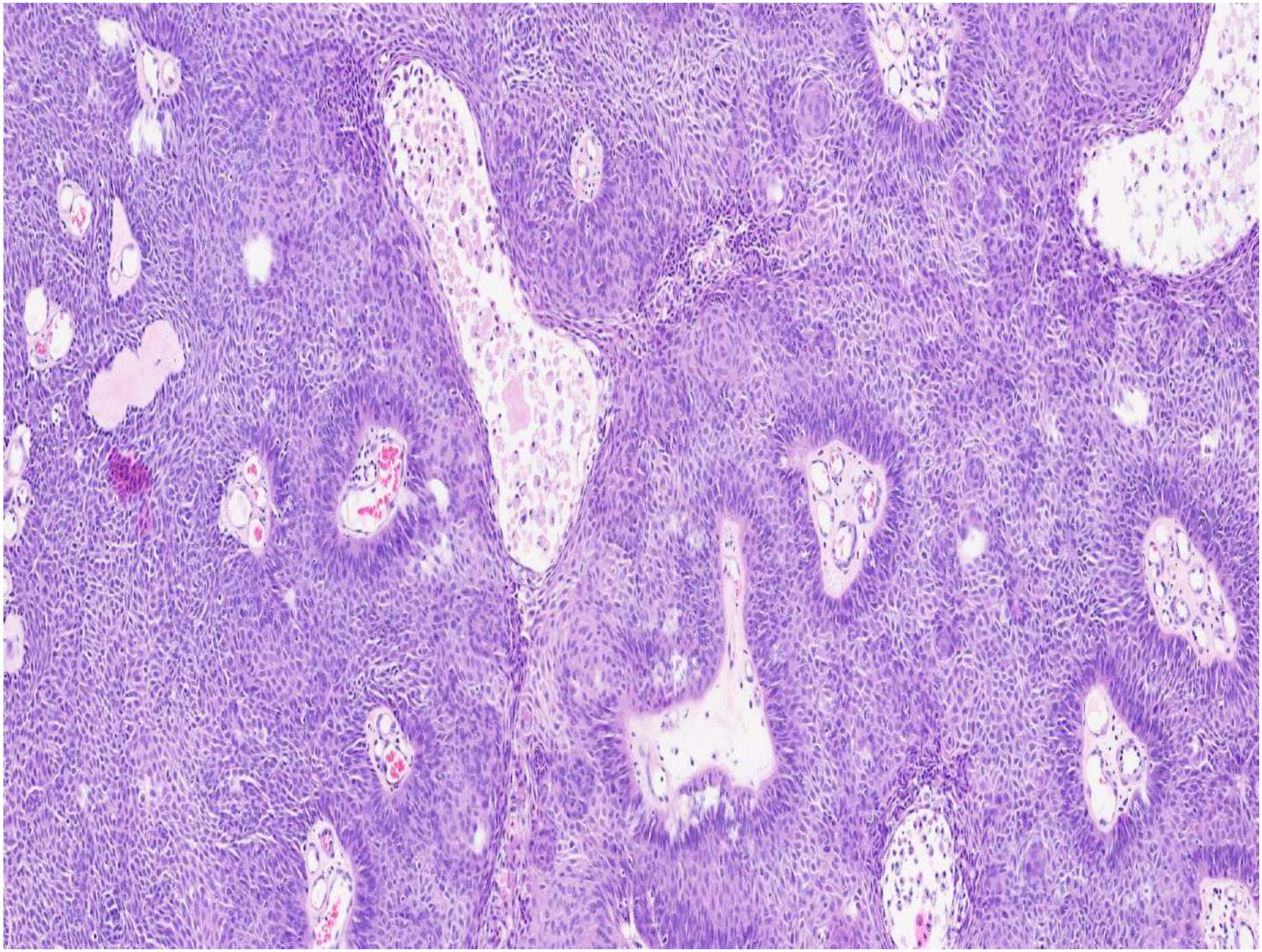

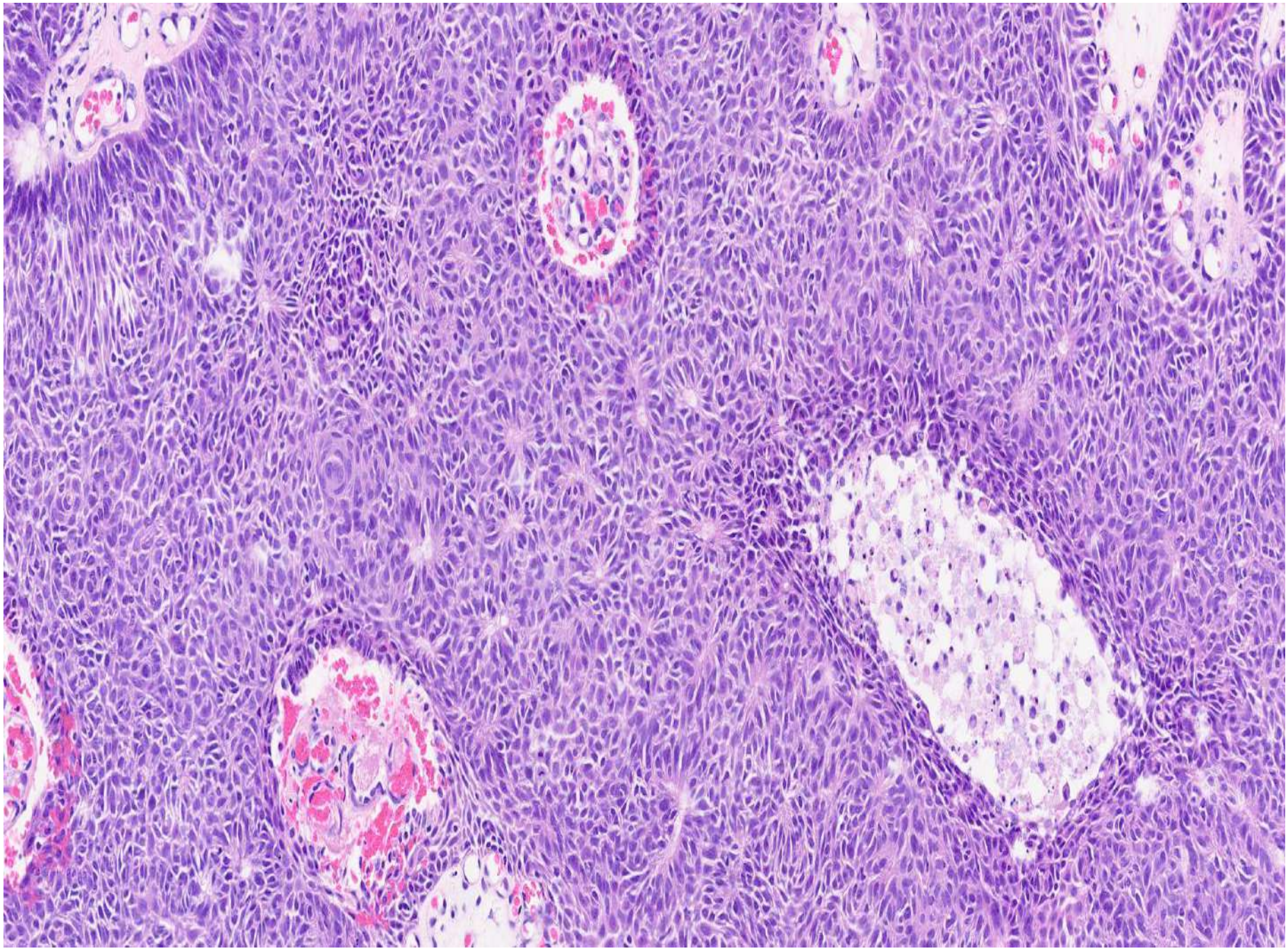

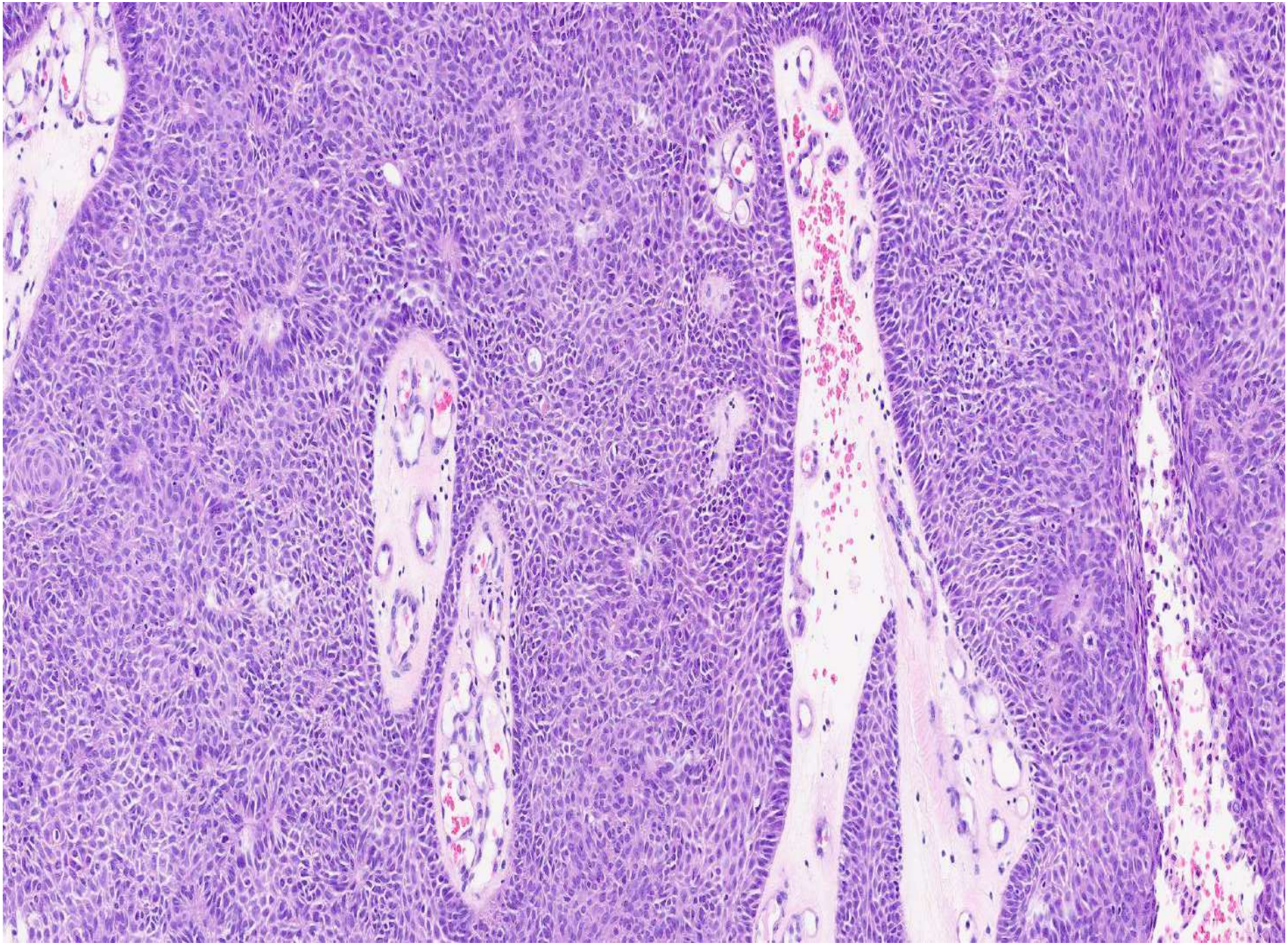

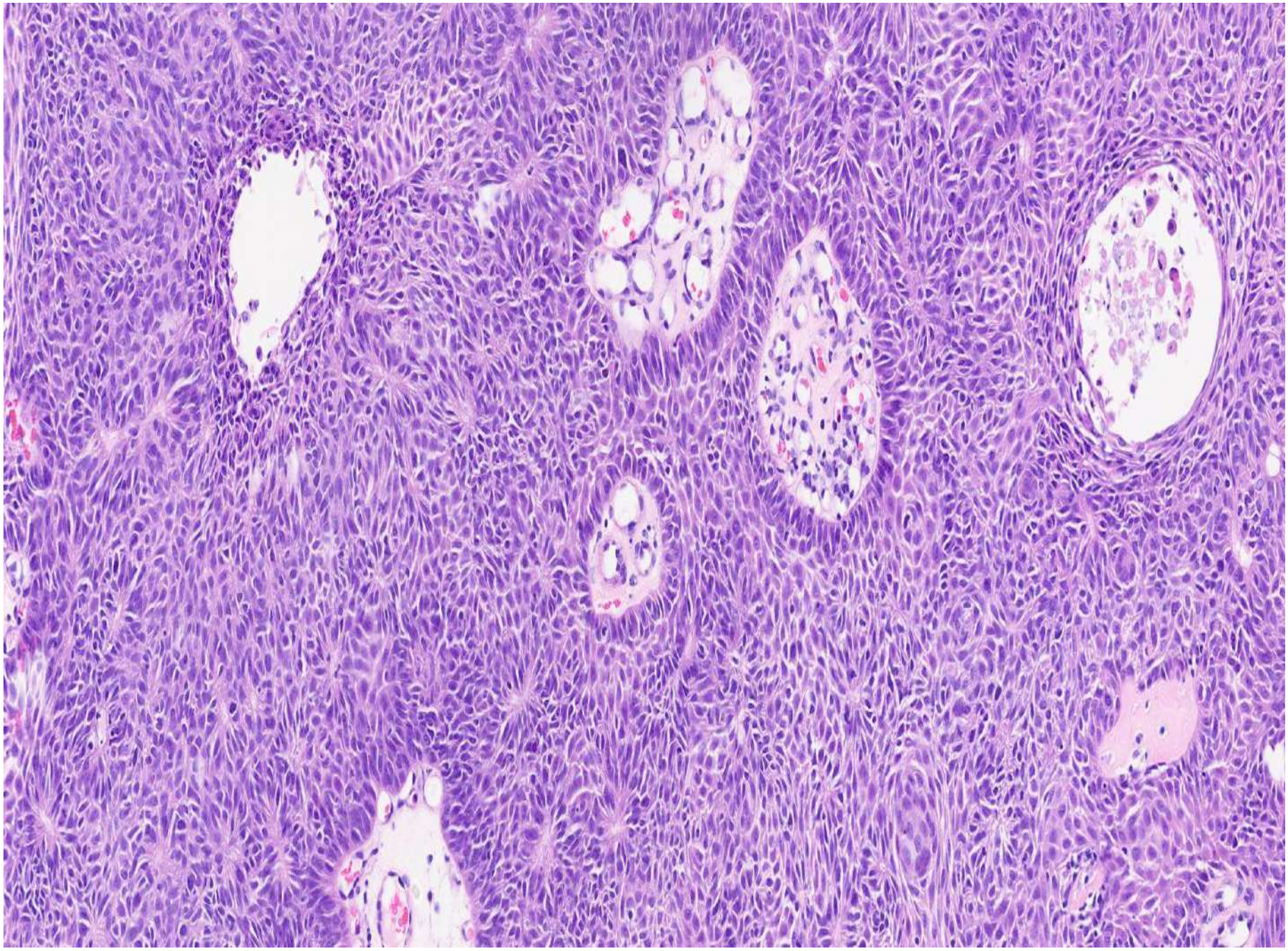

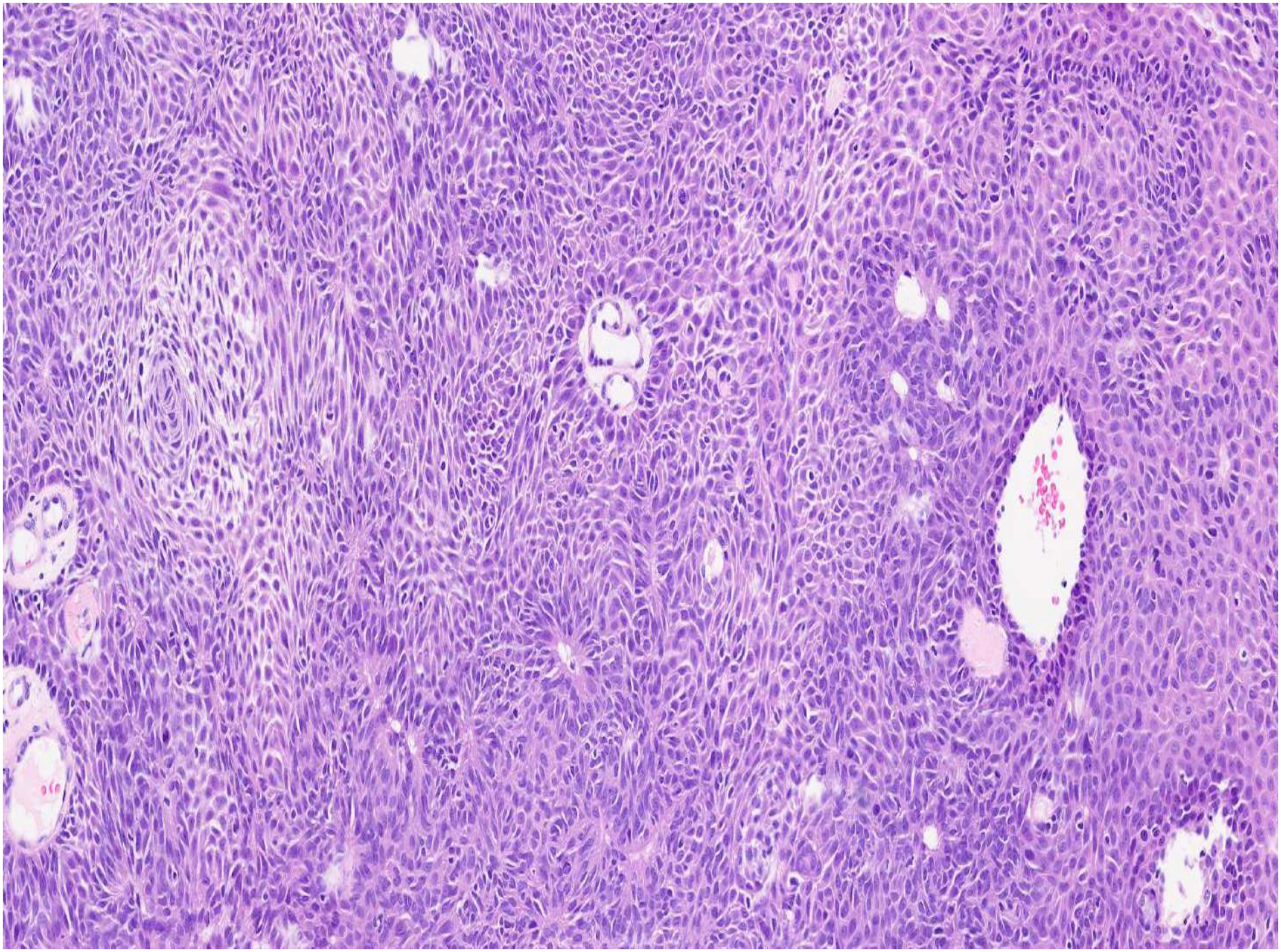

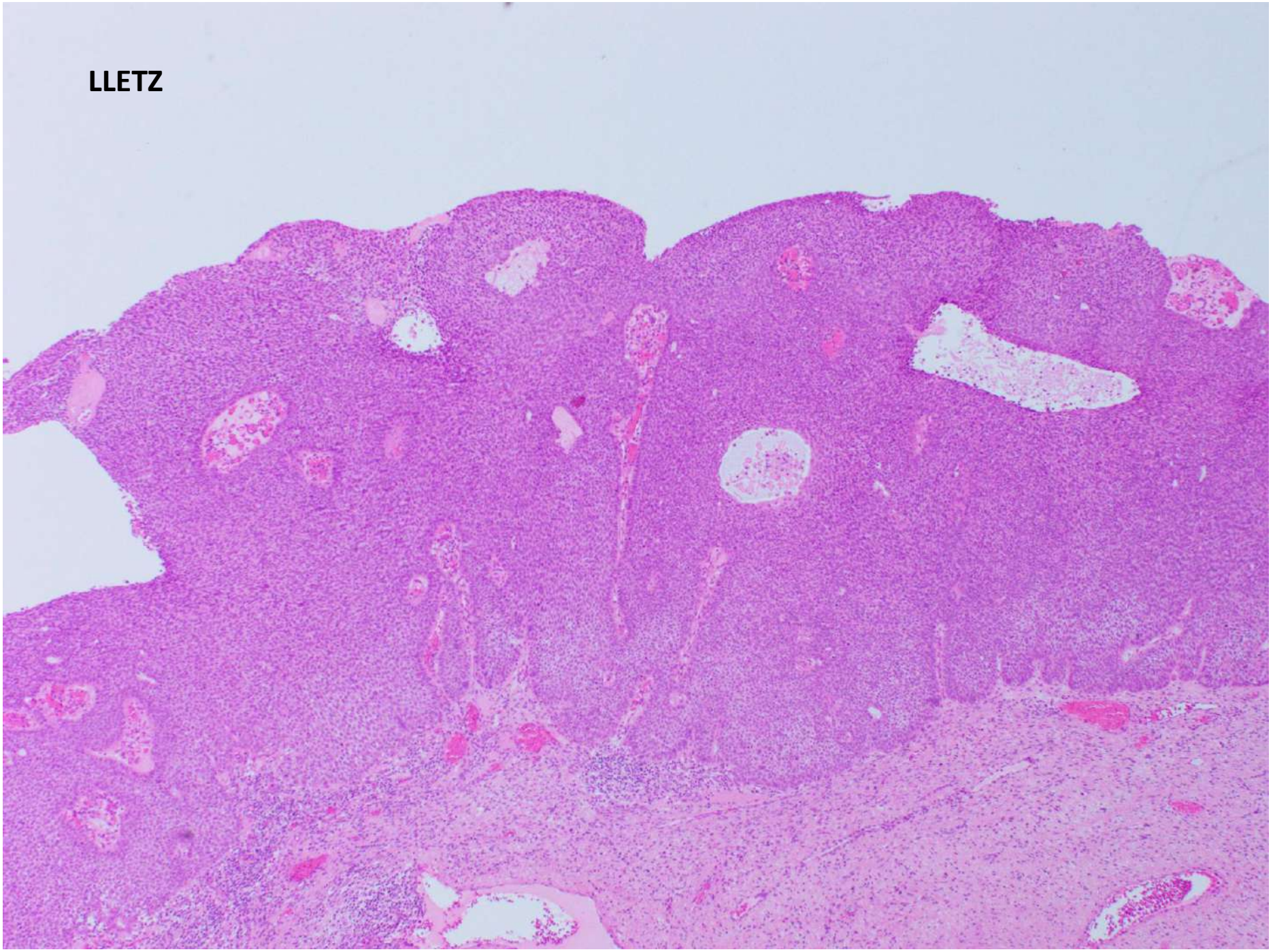
LLETZ

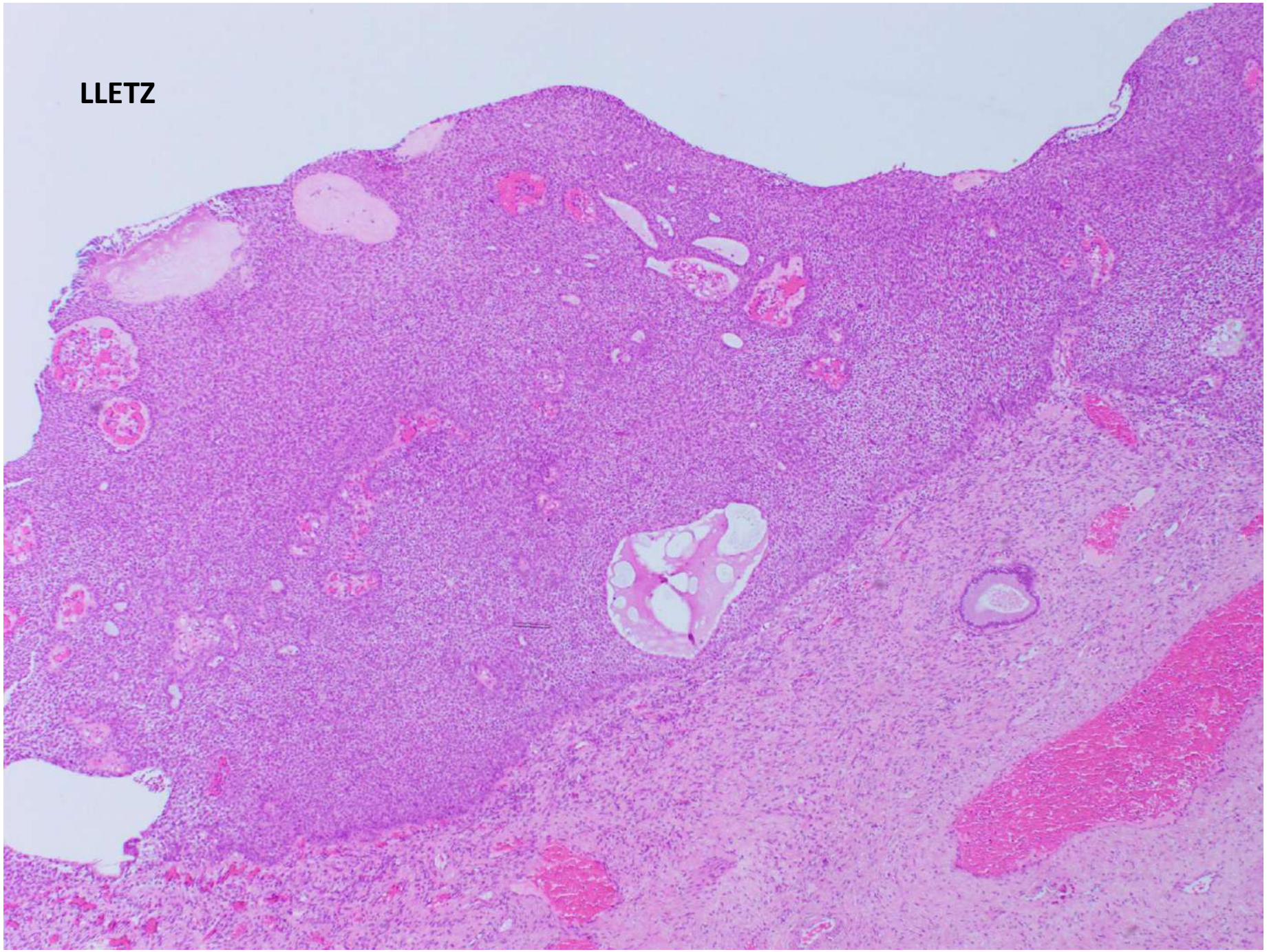
LLETZ

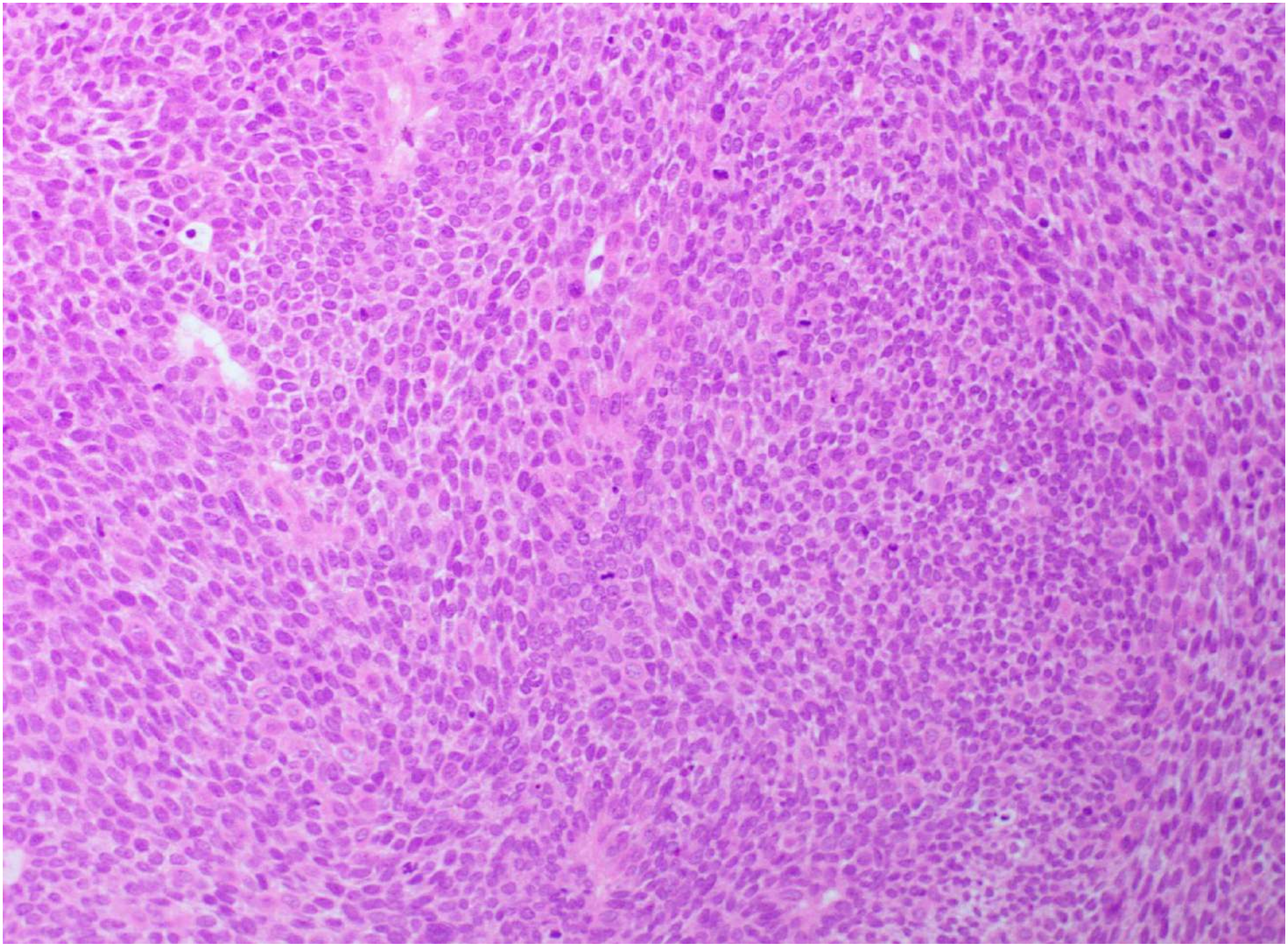

p16

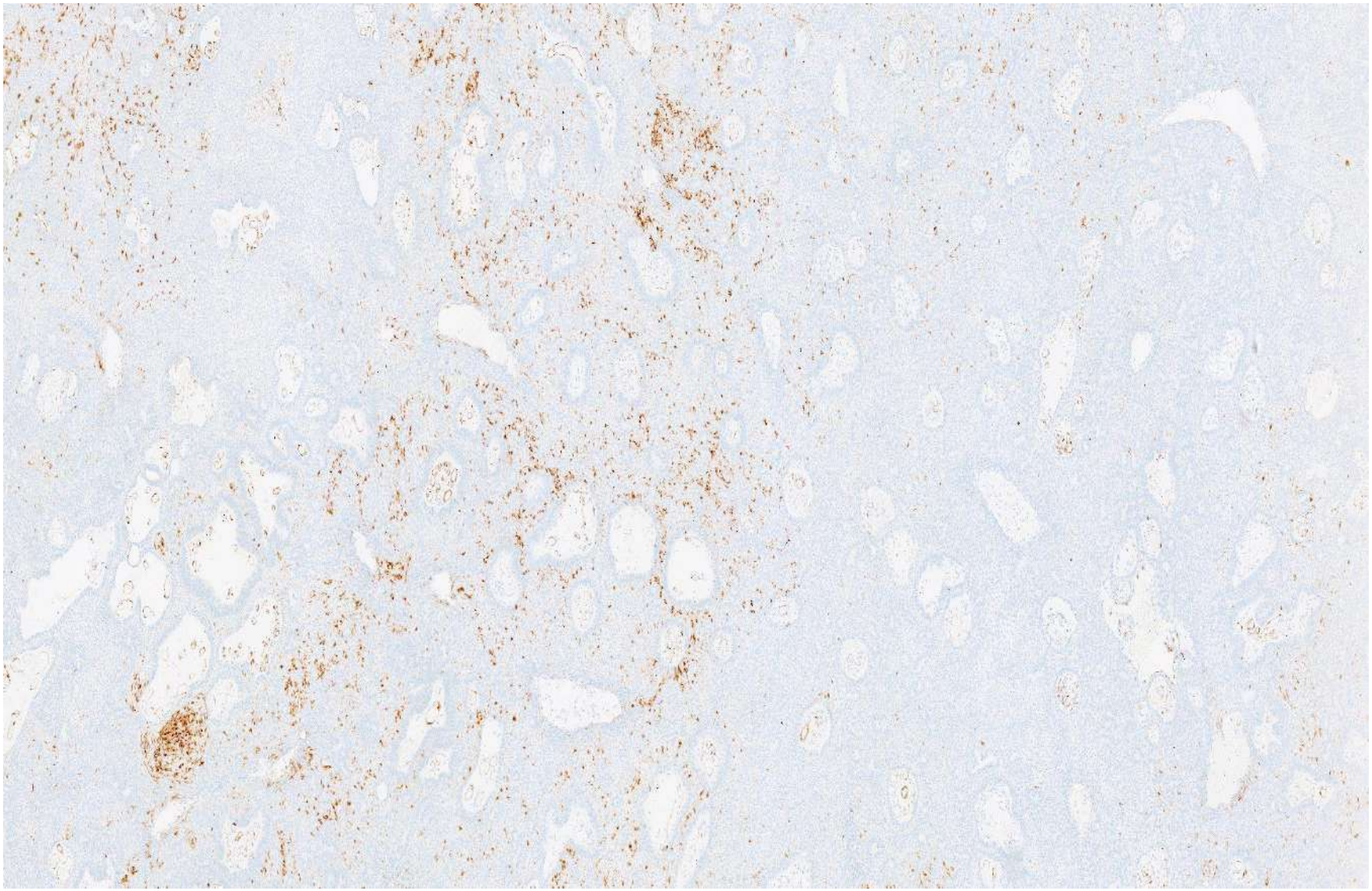

? DIAGNOSIS

PMID 27792064

ORIGINAL ARTICLE

Seborrheic Keratosis-like Lesions of the Cervix and Vagina

Report of a New Entity Possibly Related to Low-risk Human Papillomavirus Infection

Karen L. Talia, FRCPA, MBBS and W. Glenn McCluggage, FRCPath†*

DIAGNOSIS- SEBORRHOEIC KERATOSIS-LIKE LESION

- AJSP (PMID 27792064)
- 7 cases (age 41-70)
- 3 cervix, 2 upper vagina, 1 cervix and vagina, 1 undetermined
- morphology-plaque-like or “stuck-on”- but this is often not appreciable on a biopsy
- interconnecting trabeculae; basaloid appearance; squamous eddies; peripheral palisading; basement membrane-like material
- limited follow-up- benign

MOLECULAR

- 3 of 7 cases HPV 42 positive (update 7 of 11 cases HPV 42 positive)
- others HPV negative (using a PCR molecular test which covers a large number of low-risk and high-risk HPV types)
- EXAMPLE OF UNUSUAL TUMOUR TYPE ASSOCIATED WITH A SPECIFIC HPV TYPE

PMID 35538210

USCAP

www.nature.com/modpathol

ARTICLE

Check for updates

Association of HPV42 with digital papillary adenocarcinoma and the use of in situ hybridization for its distinction from acral hidradenoma and diagnosis at non-acral sites

Chad Vanderbilt[1], Thomas Brenn[2], Andrea P. Moy[1], Gordon Harloe[3], Charlotte Ariyan[4], Edward Athanasian[4] and Klaus J. Busam[1]✉

© The Author(s), under exclusive licence to United States & Canadian Academy of Pathology 2022

CASE 6

- F 34
- Wedge biopsy of large cervical mass

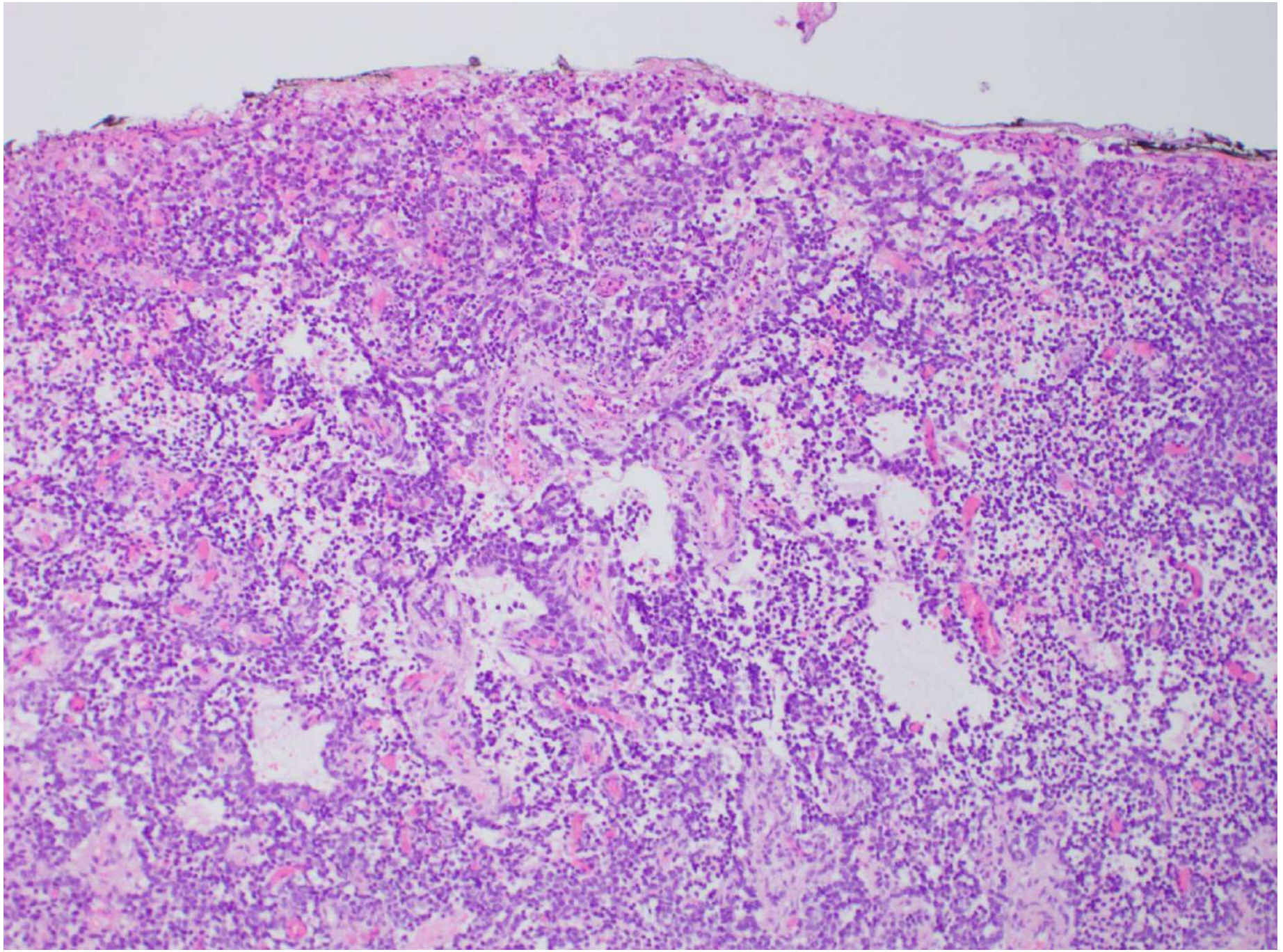

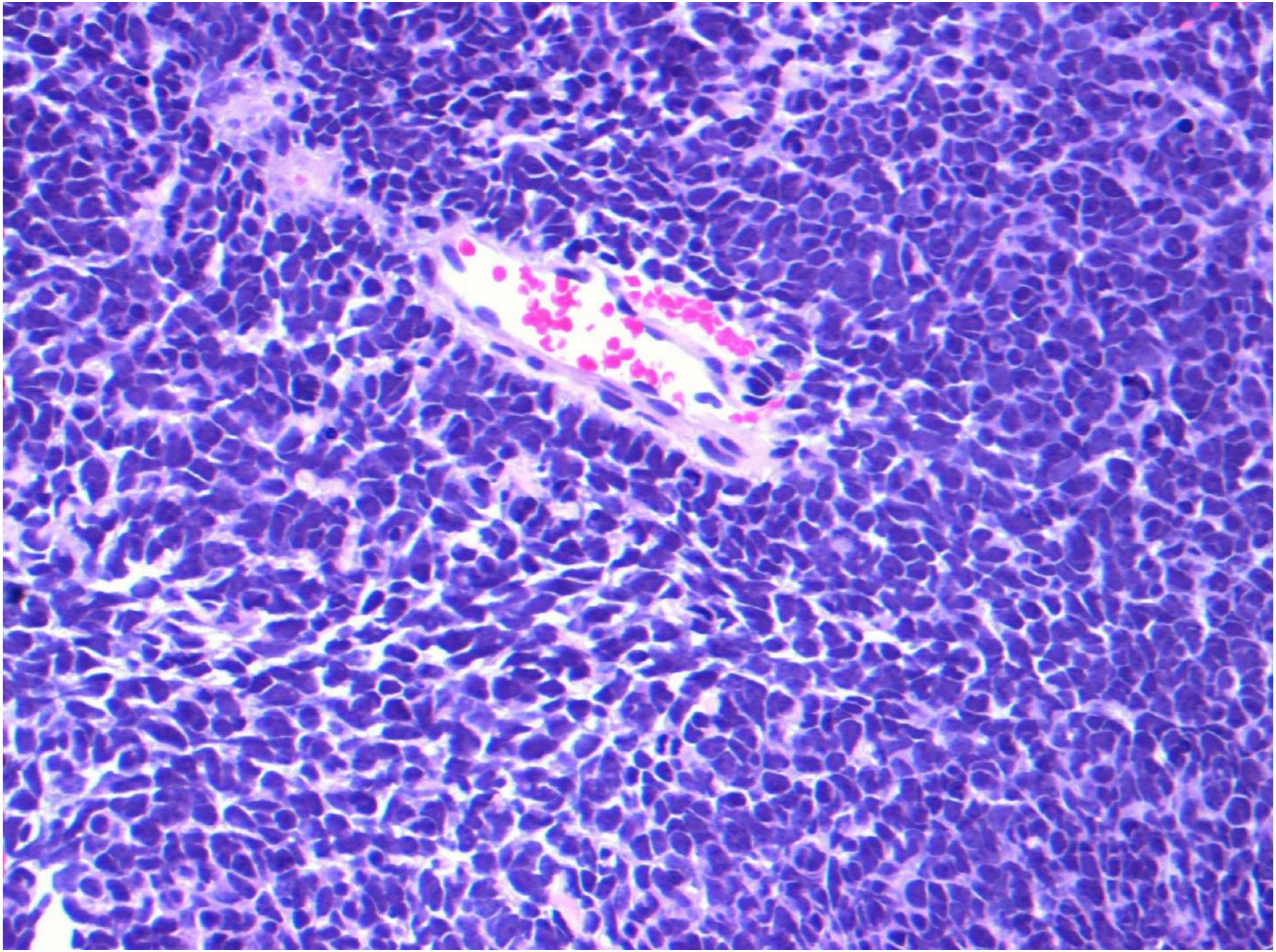

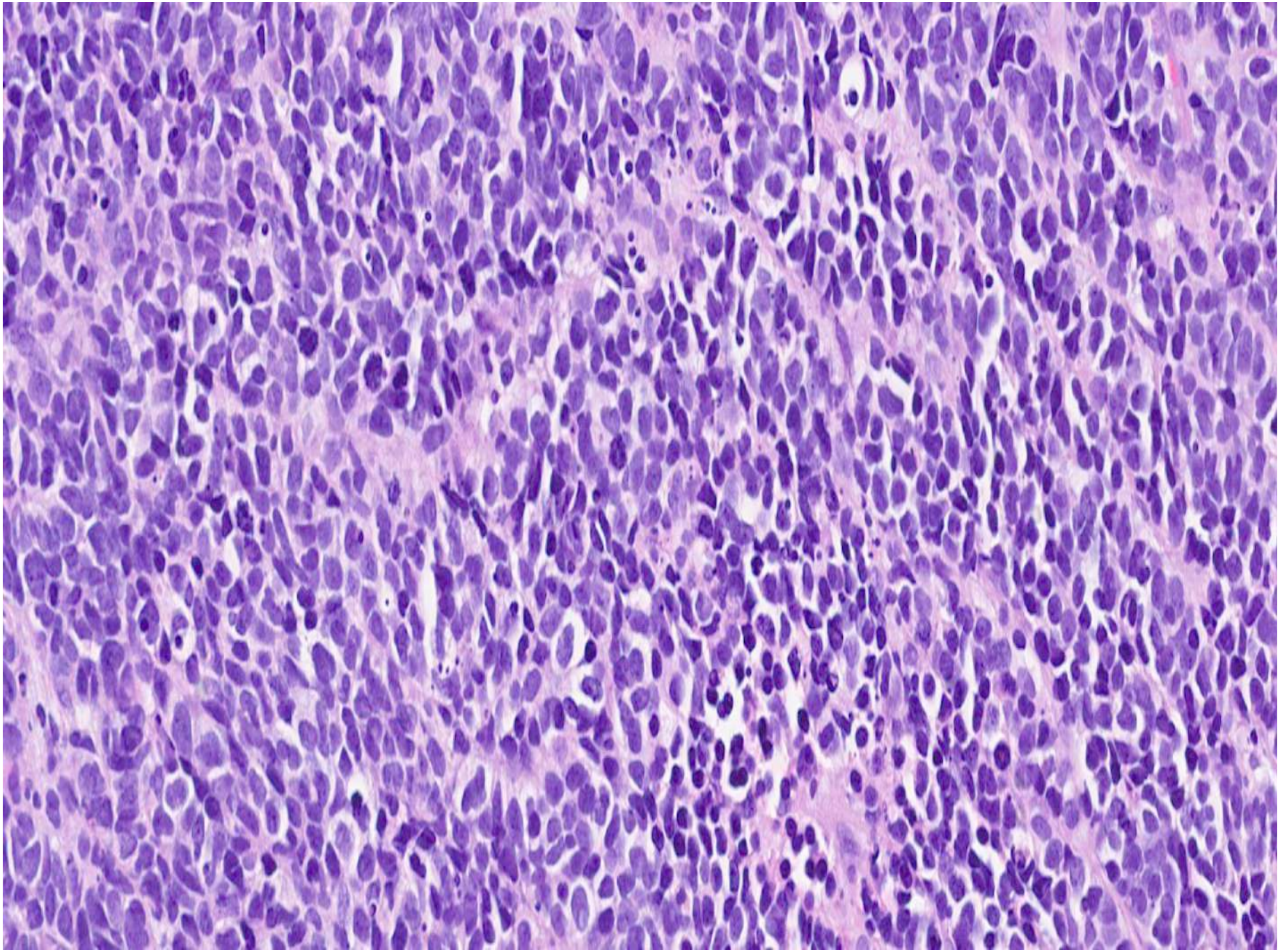

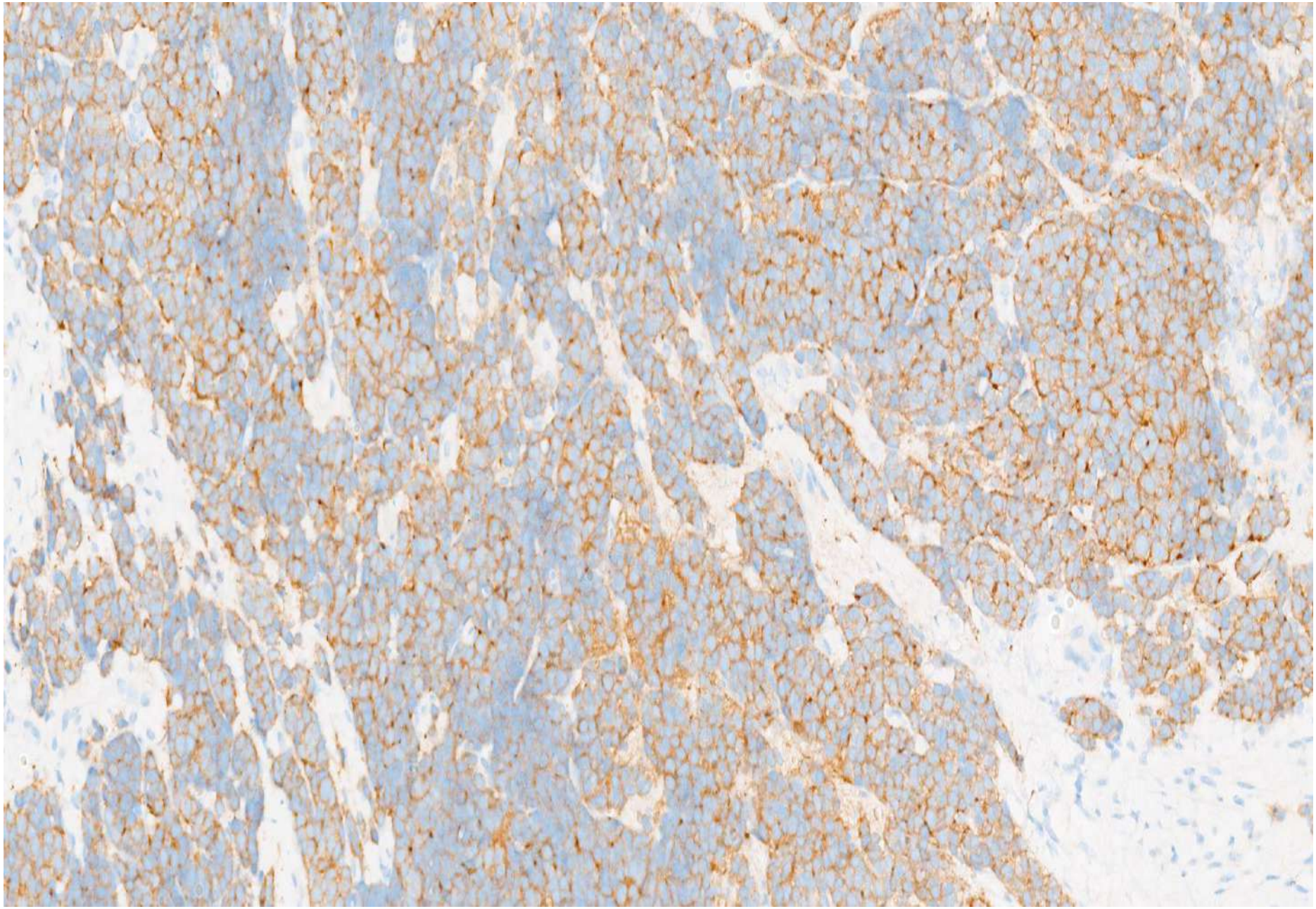

synaptophysin

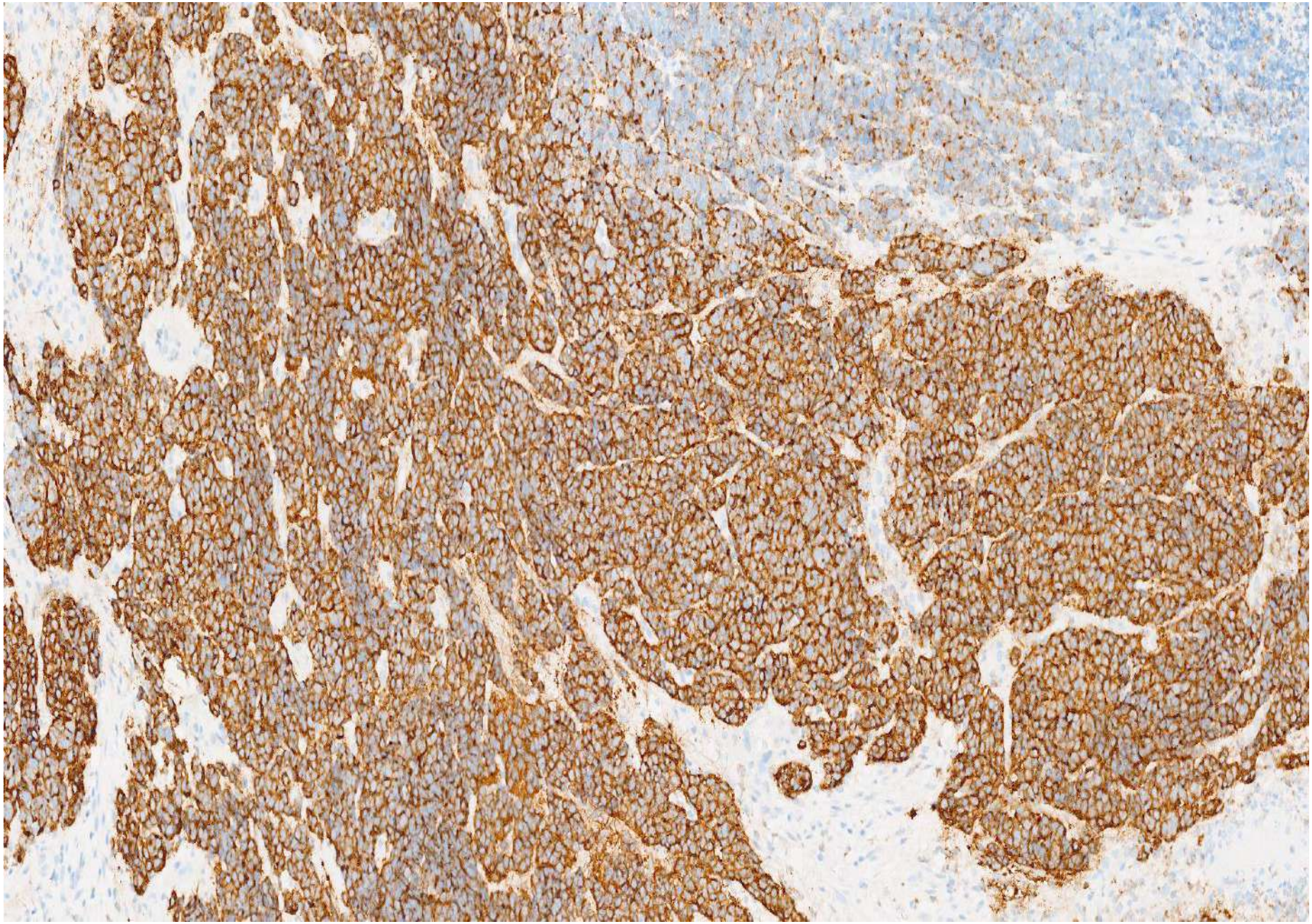

chromogranin

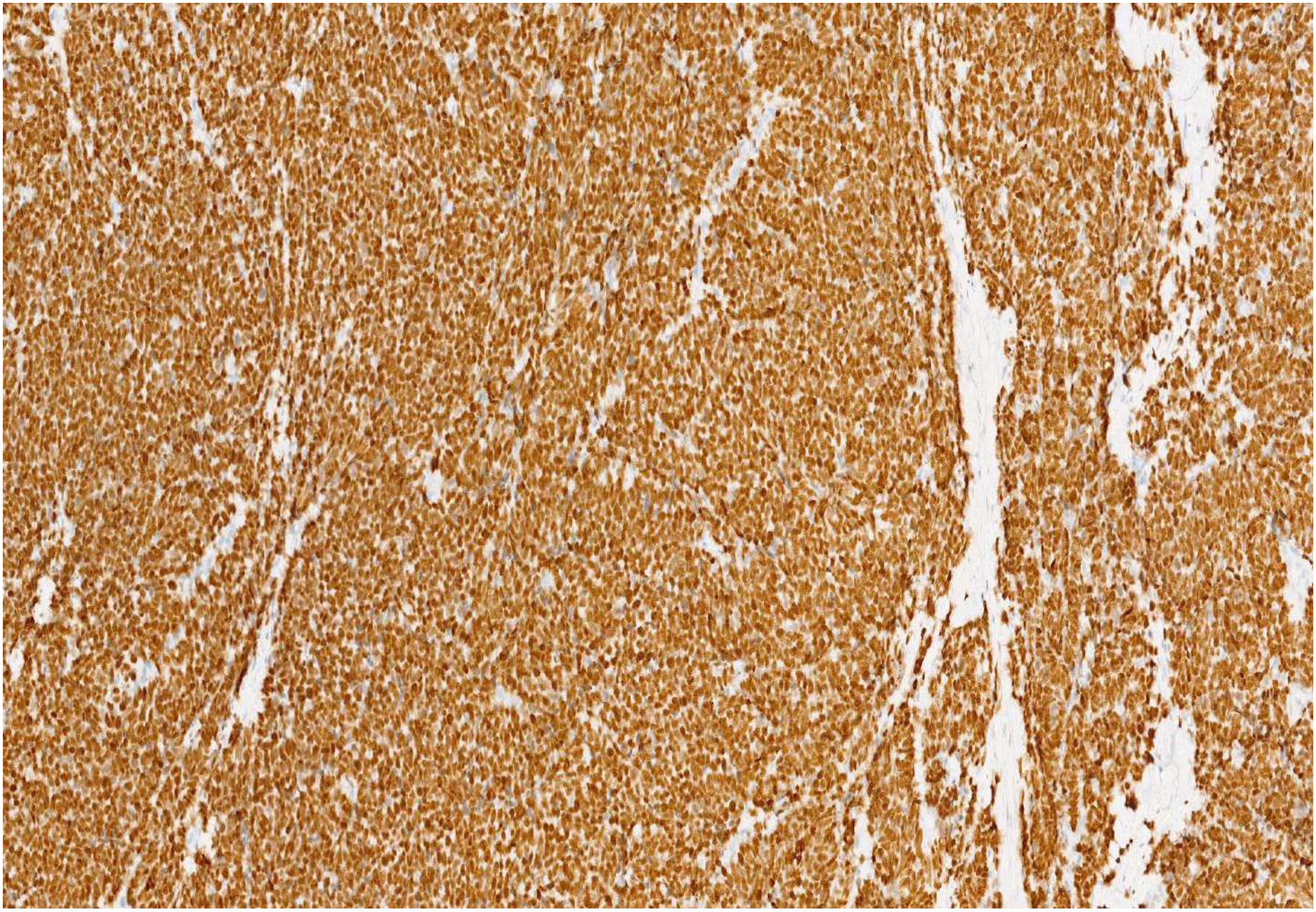

TTF1

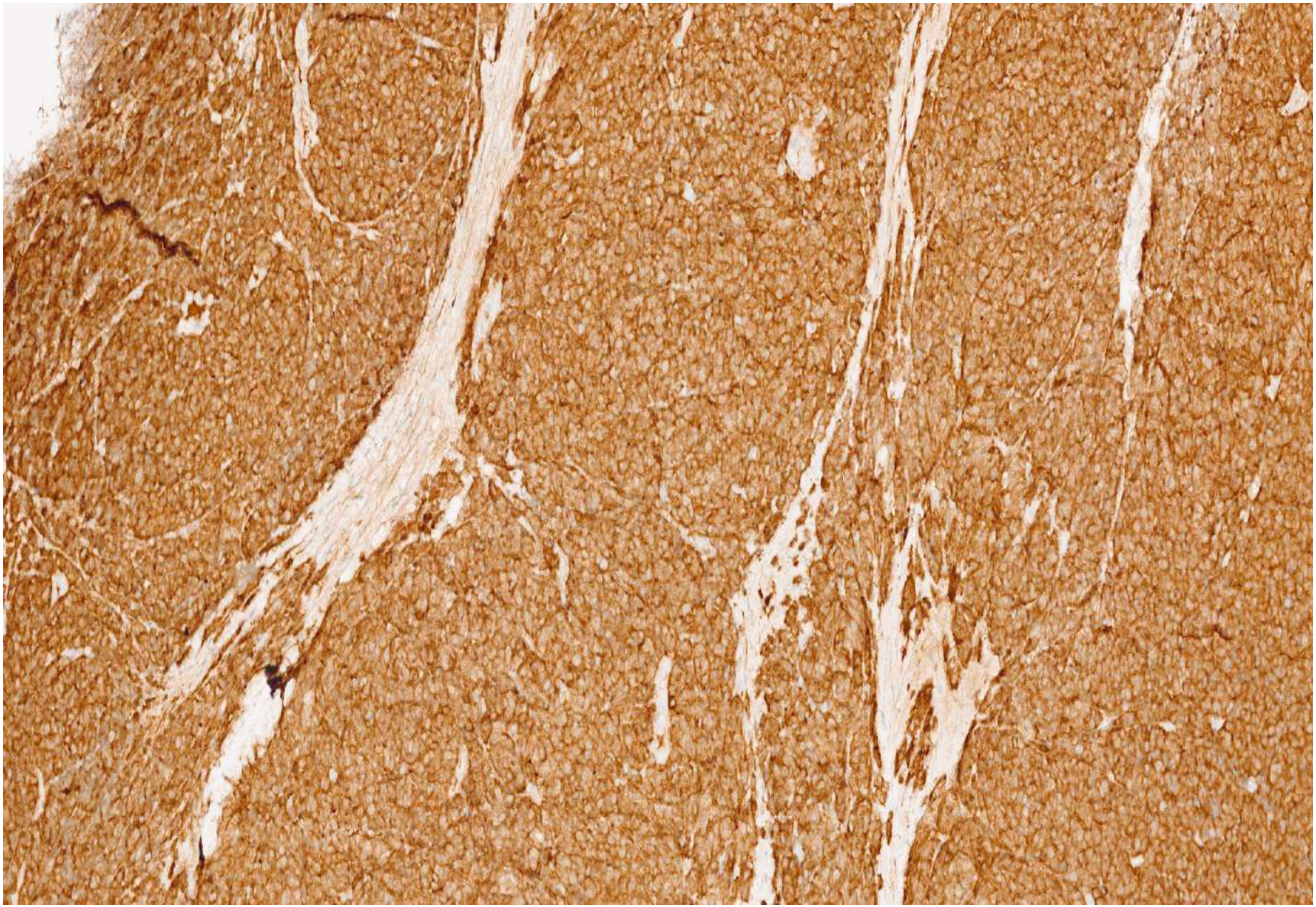

p16

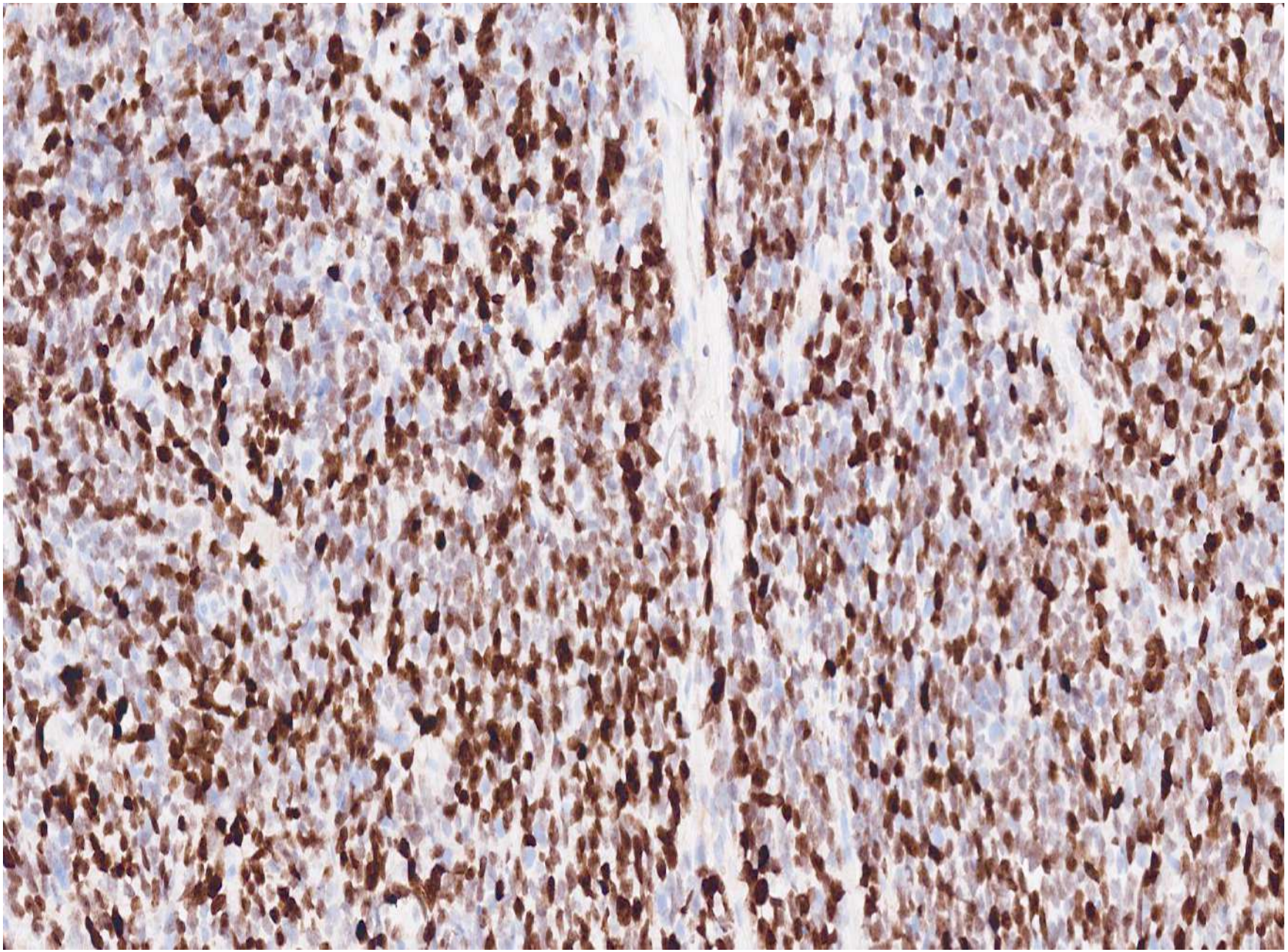

MIB1

? DIAGNOSIS

DIAGNOSIS

- Cervical small cell neuroendocrine carcinoma (SCNEC)

CERVICAL NEUROENDOCRINE NEOPLASMS (WHO 2003)

- typical carcinoid
- atypical carcinoid
- small cell **neuroendocrine** carcinoma (most common)
- large cell neuroendocrine carcinoma

CERVICAL NEUROENDOCRINE NEOPLASMS (WHO 2014 and 2020)

- low grade neuroendocrine **tumour** (NET) (carcinoid and atypical carcinoid)
- high grade neuroendocrine **carcinoma** (NEC) (small cell and large cell neuroendocrine carcinoma)
- also category of carcinoma admixed with neuroendocrine carcinoma

CERVICAL NEUROENDOCRINE CARCINOMAS

- often young females
- SCNEC/LCNEC (can be morphological overlap and occasionally admixtures)
- usually HPV-associated neoplasms (HPV 18 > 16) (may be useful in ascertaining site of origin)- more useful than p16 since may also be positive in HPV-independent neuroendocrine carcinomas
- significant association with premalignant/malignant glandular lesions (more uncommonly squamous lesions); may be underestimated since often only punch biopsy performed
- SCNEC- not small cell carcinoma (get small cell variant of squamous carcinoma and causes confusion)
- SCNEC- can make diagnosis in absence of neuroendocrine marker positivity, although usually at least one positive
- LCNEC- need neuroendocrine marker positivity

SCNEC- LARGER CELLS

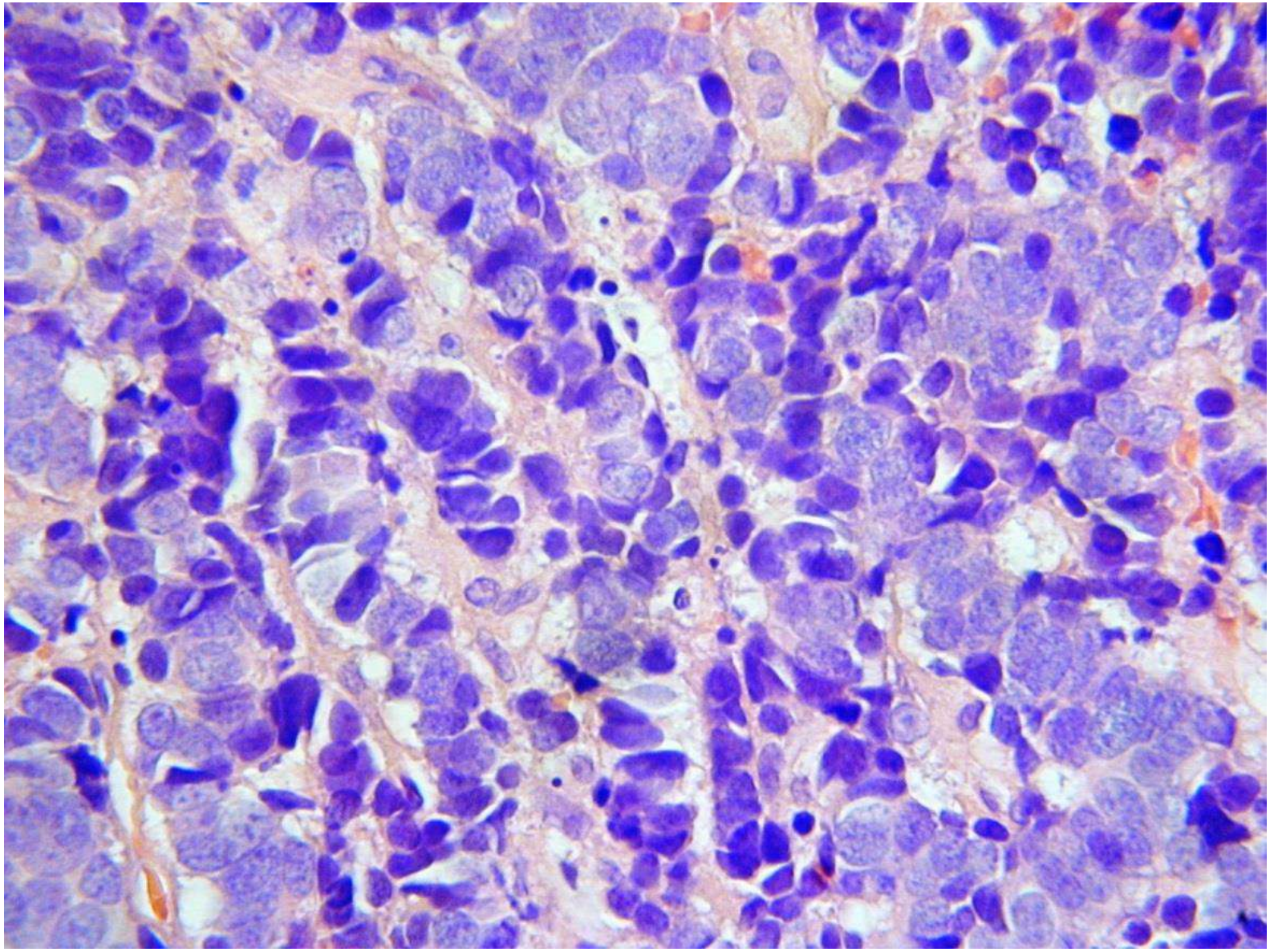

SCNEC ADMIXED WITH ADENOCARCINOMA

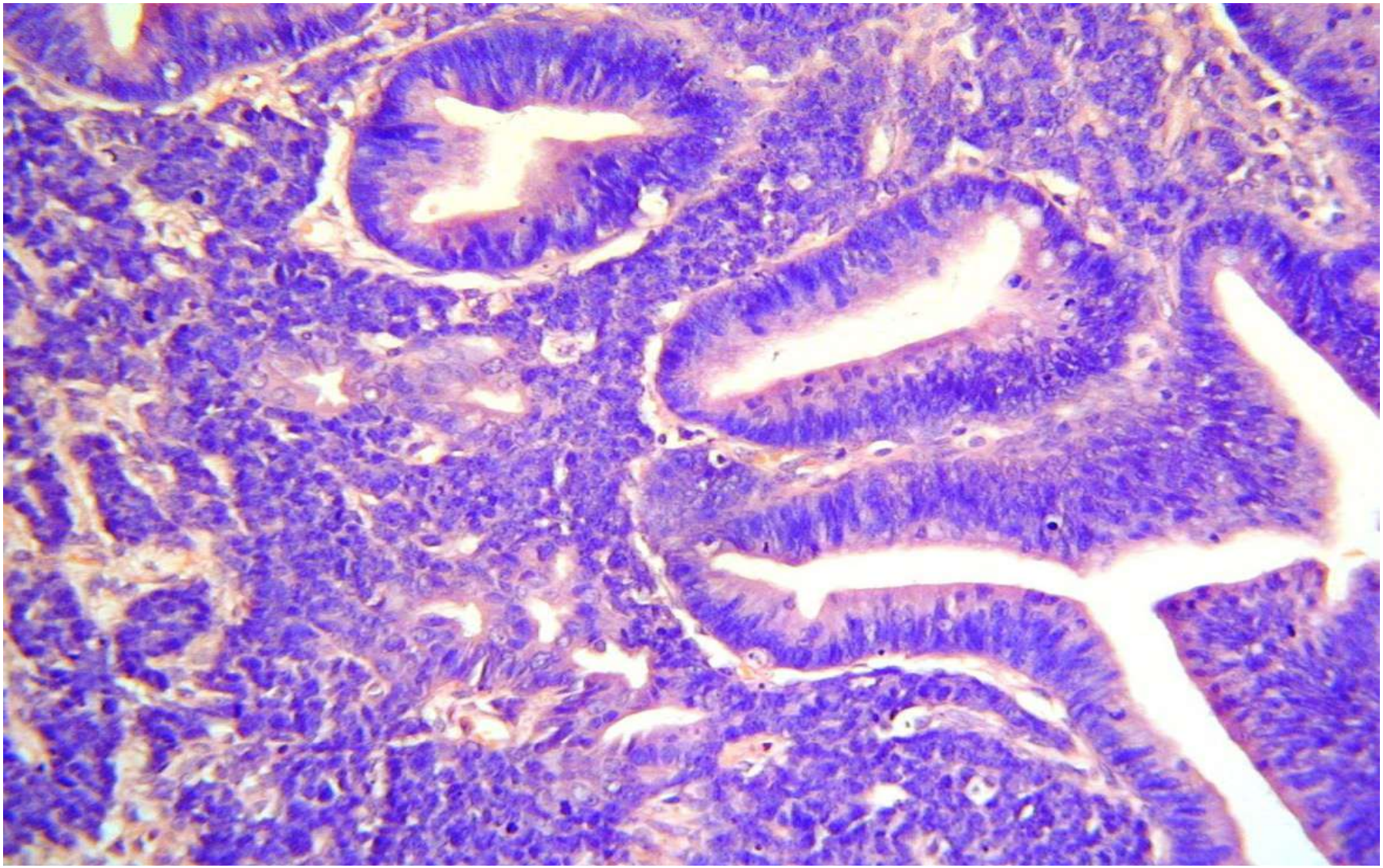

LARGE CELL NEUROENDOCRINE CARCINOMA (LCNEC)

- insular, trabecular, glandular/ acinar, rosettes, solid growth patterns
- more than scant cytoplasm
- often extensive necrosis
- may see eosinophilic cytoplasmic granules
- may get nuclear palisading
- **need immunohistochemical evidence of neuroendocrine differentiation**

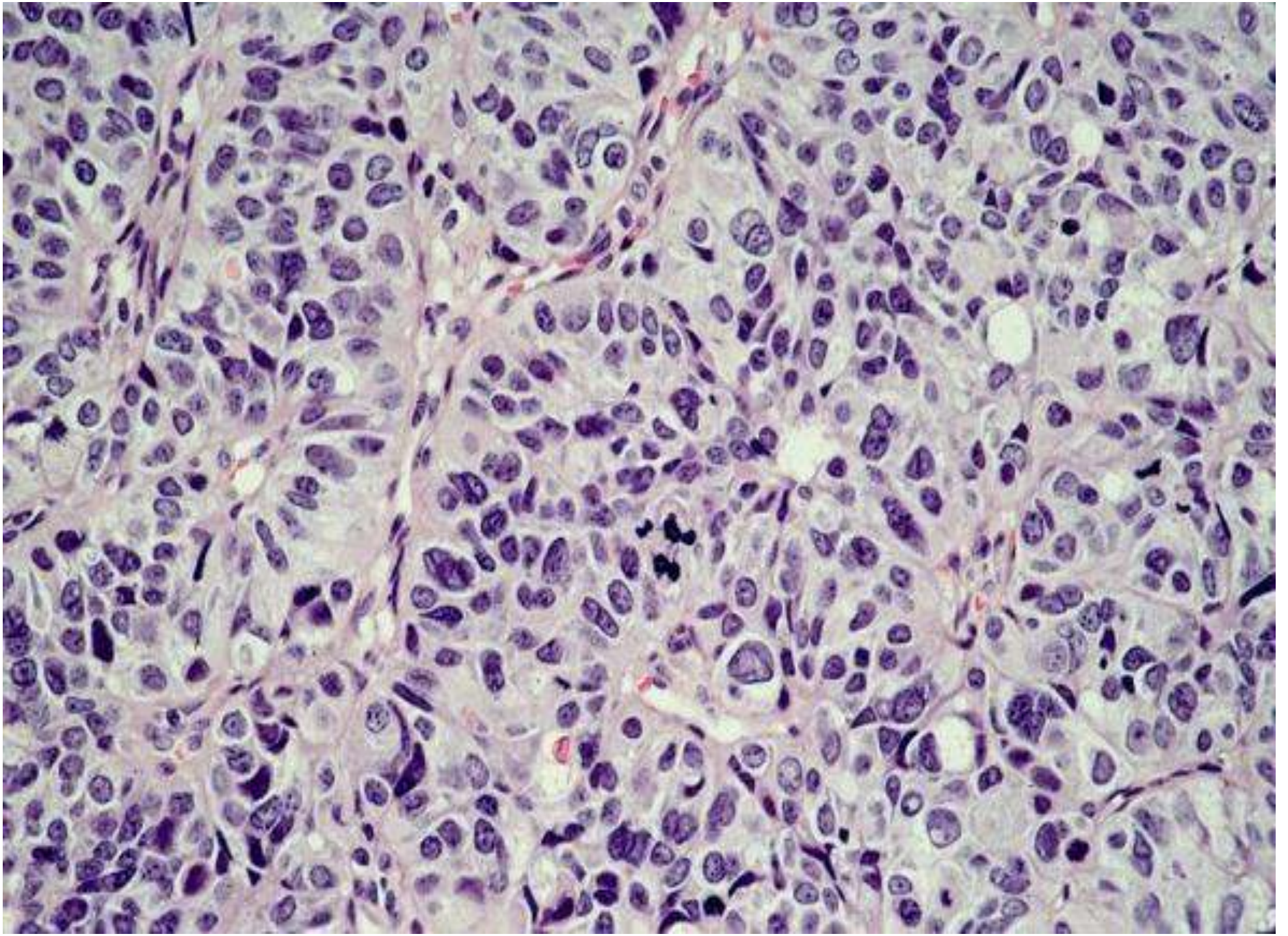

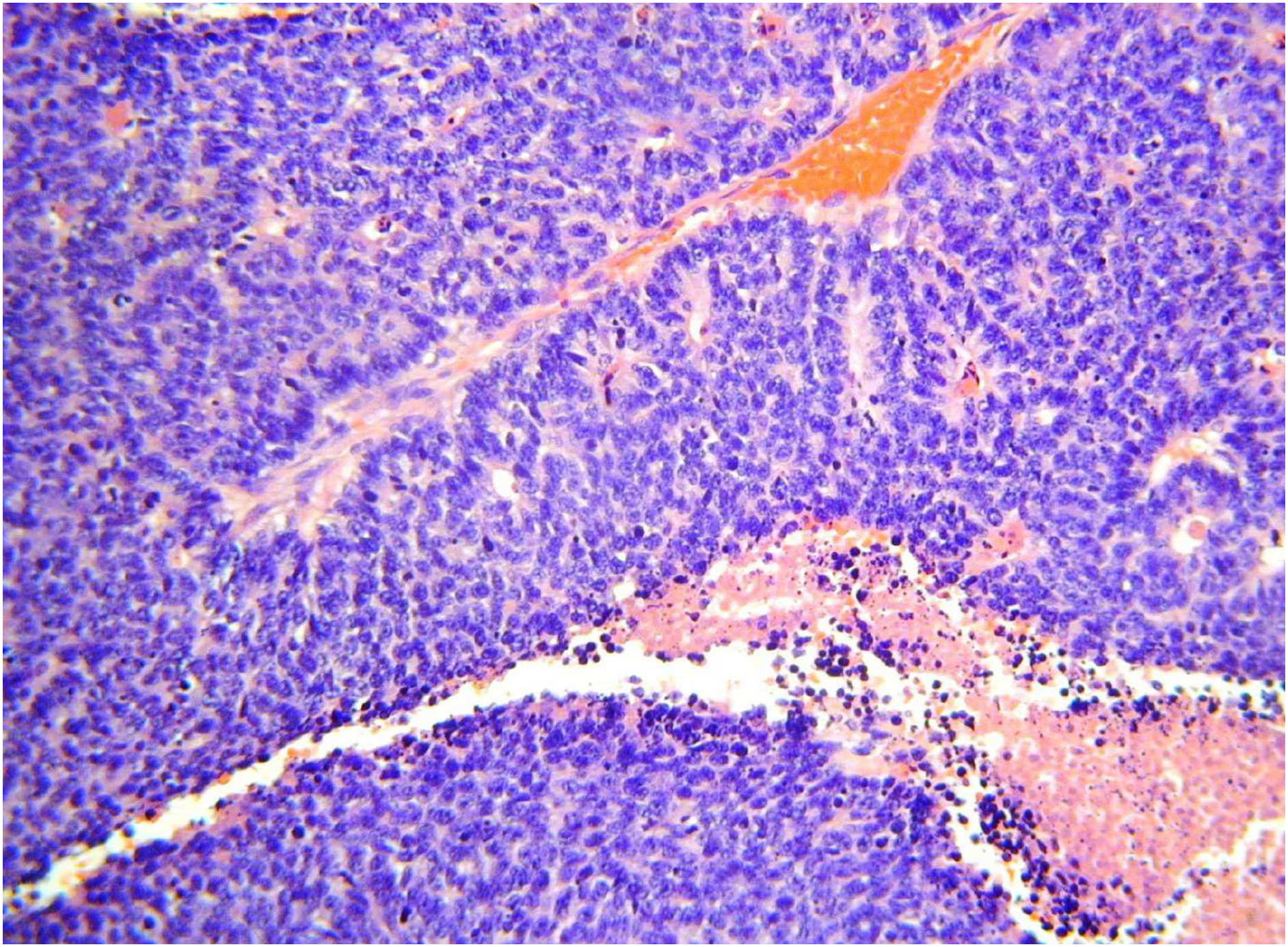

LCNEC ADMIXED WITH ADENOCARCINOMA

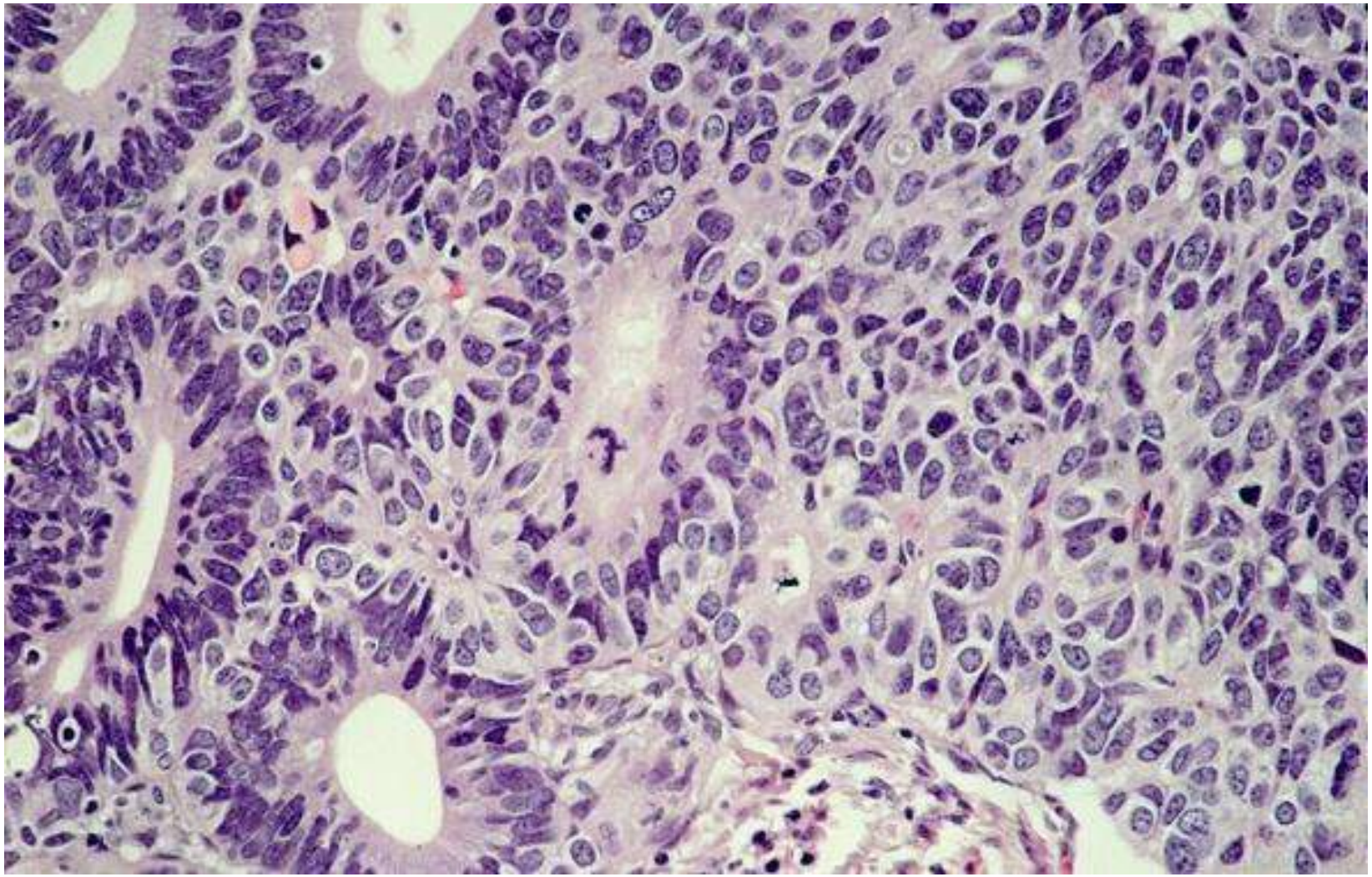

ADMIXTURE OF SCNEC AND LCNEC

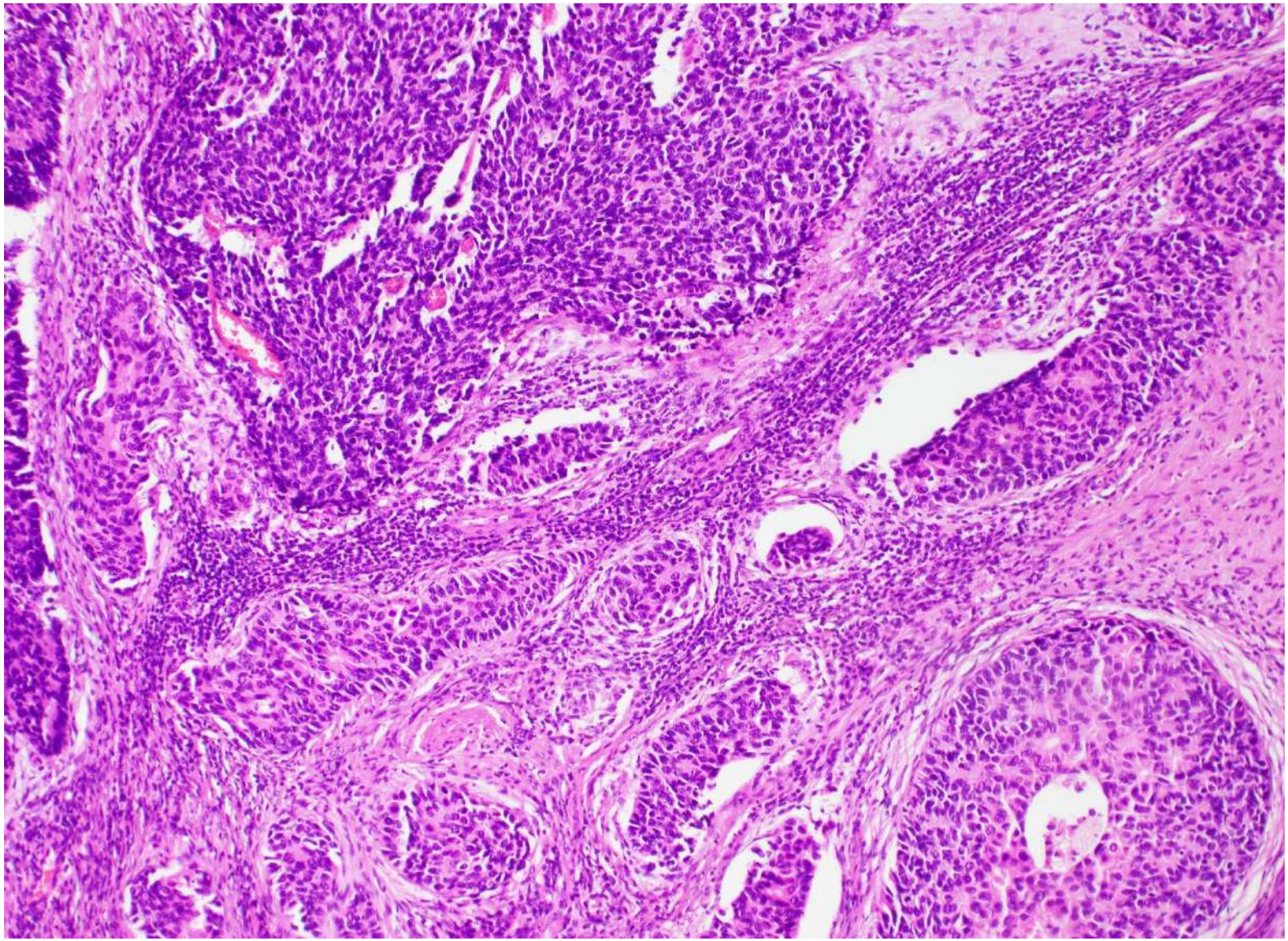

NEUROENDOCRINE MARKERS IN CERVICAL NEUROENDOCRINE CARCINOMAS (AJSP 2010;34;525-532; PMID 20182342)

- 52% chromogranin positive (most specific)
- 90% CD56 positive (sensitive but non-specific)
- 90% synaptophysin positive (sensitive)
- 43% PGP9.5 positive

CHROMOGRANIN- NEED TO LOOK ON HIGH POWER

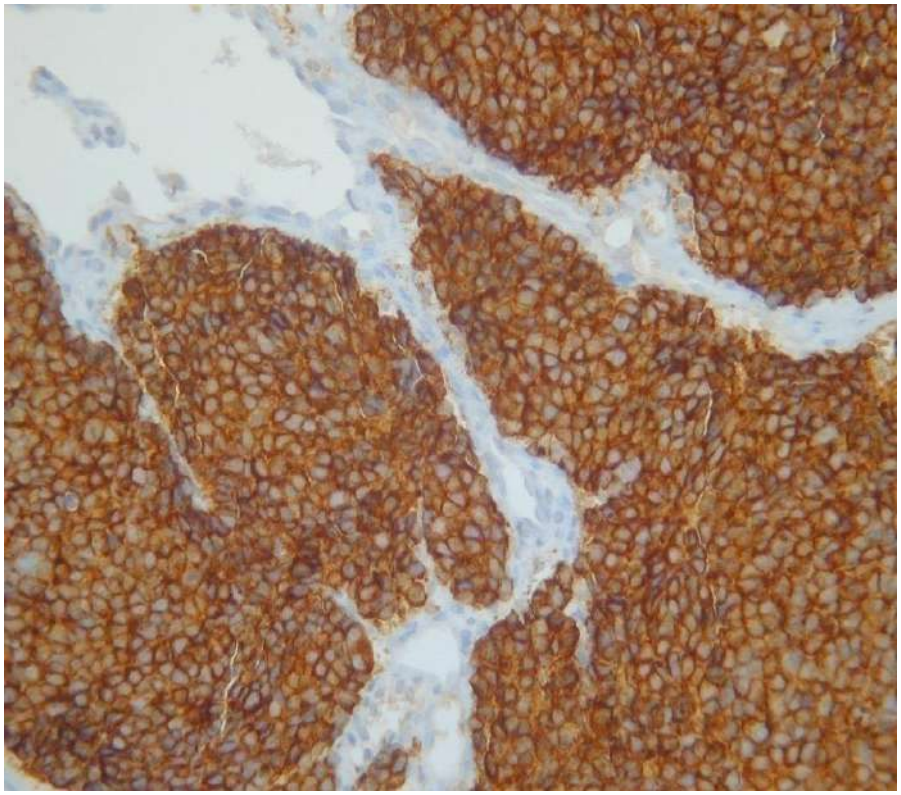

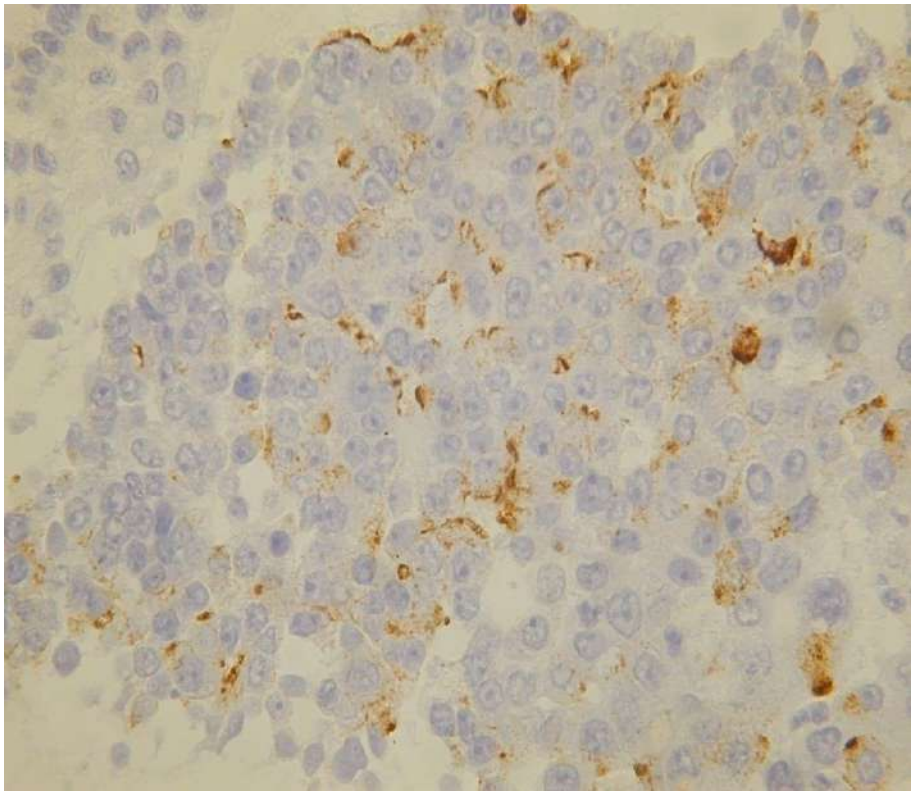

TTF1 IN CERVICAL NEC (AJSP 2010;34;525-532; PMID 20182342)

- 71% of cervical neuroendocrine carcinomas positive (85% SCNEC; 50% LCNEC)
- immunoreactivity often diffuse
- of no value in distinction from a pulmonary metastasis

TTF1 IN CERVICAL SCNEC

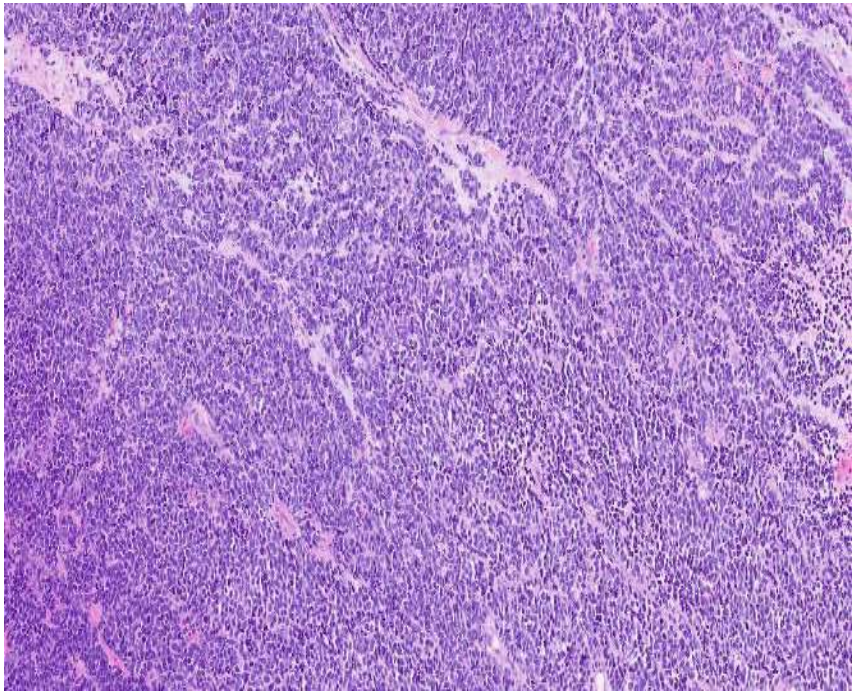

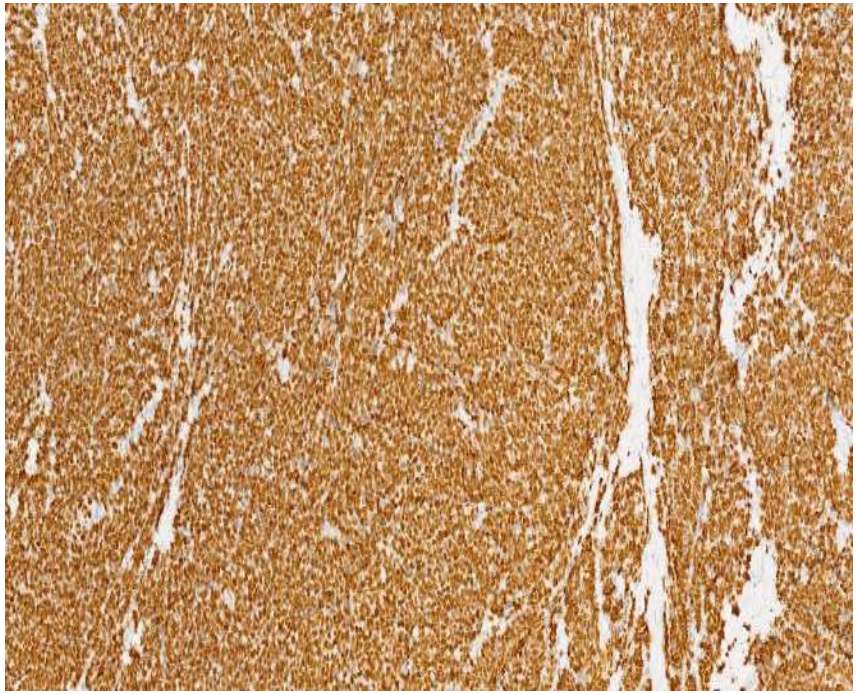

p16- AJSP 2010;34;525-532; PMID 20182342)

- all except 1 case diffusely positive
- due to association with high-risk HPV
- p16 positivity may occur due to non-HPV related mechanisms (pulmonary and head and neck small cell carcinomas often positive)
- p16 positivity probably of limited value in confirming cervical primary
- HPV studies may be of use

p16 in cervical SCNEC

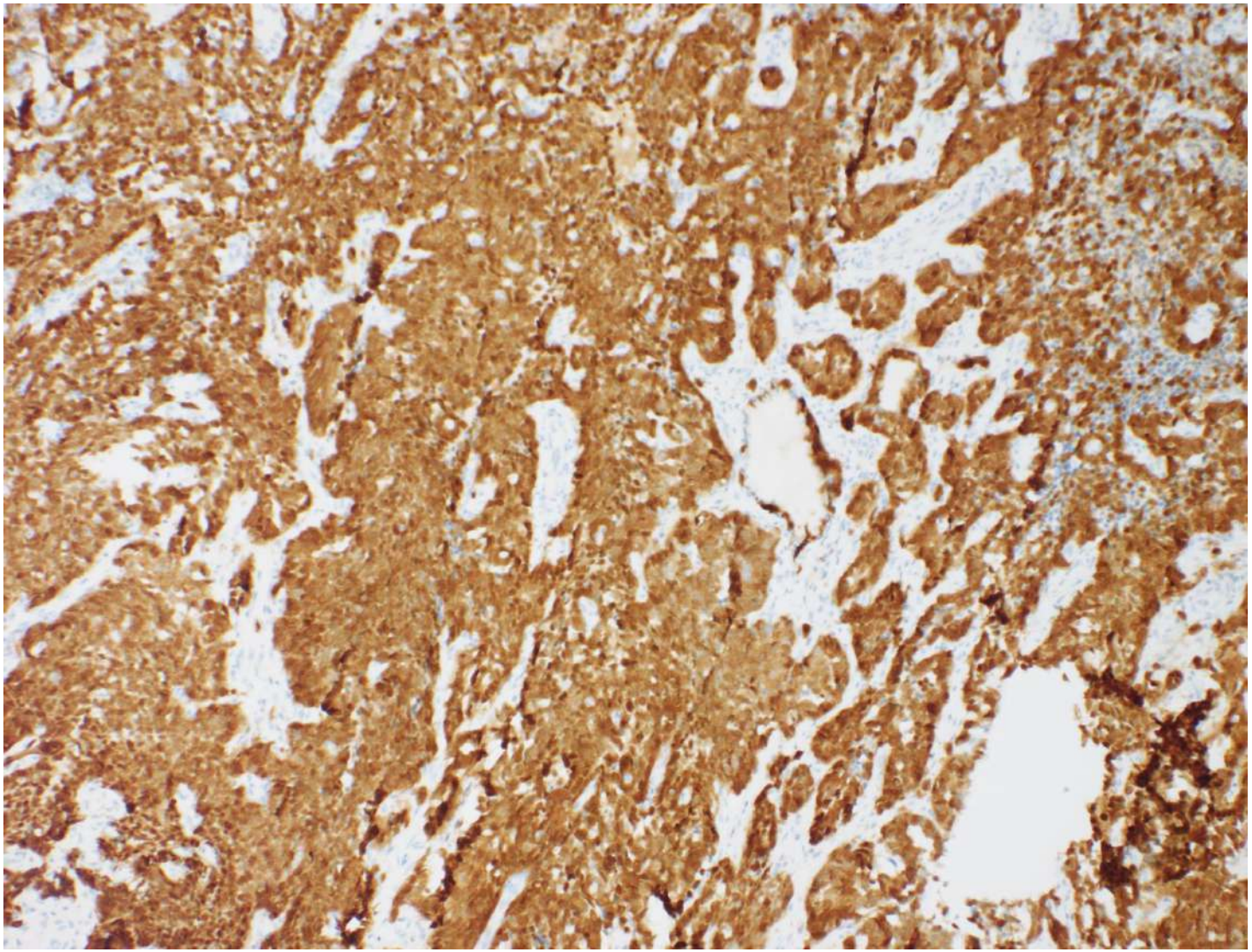

p63

- in cervix, useful nuclear marker of squamous cell carcinoma
- most (not all) adenocarcinomas and neuroendocrine carcinomas negative
- traditionally considered to be useful in distinction between SCNEC and small cell squamous and between LCNEC and poorly differentiated squamous or adenocarcinoma
- 9 of 21 neuroendocrine carcinomas (7 SCNEC, 2 LCNEC) positive; 5 with diffuse nuclear positivity (AJSP 2010;34;525-532; PMID 20182342)

p63 IN CERVICAL SCNEC

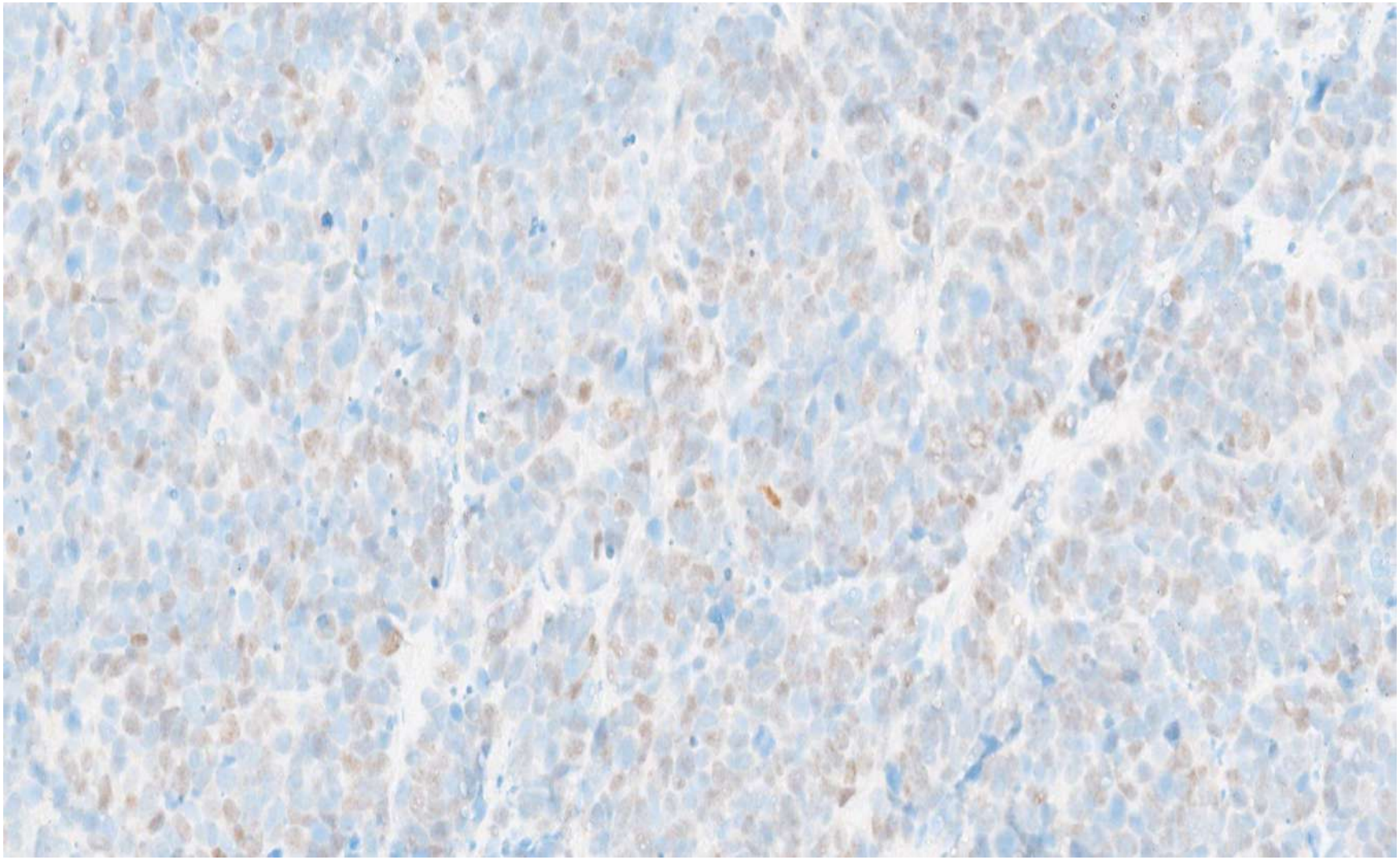

p63 in ADENOCARCINOMA AND SCNEC CERVIX

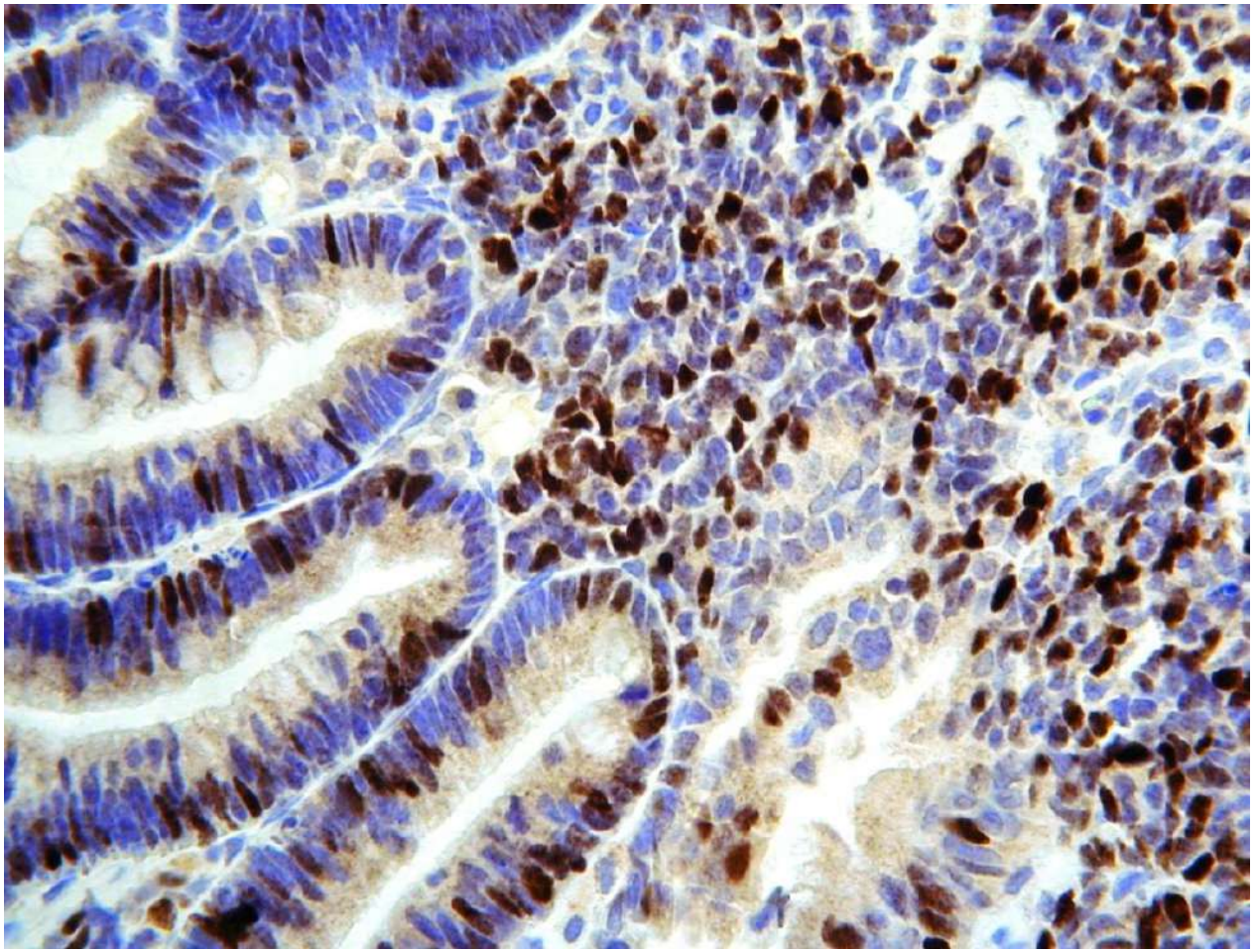

ASSOCIATION BETWEEN CERVICAL NEUROENDOCRINE CARCINOMA AND AIS/ADENOCARCINOMA

- AIS/ADENOCARCINOMA found in some cases (probably under-recognised since often only punch biopsy undertaken)
- ? neuroendocrine cells in AIS/ADENOCARCINOMA is origin of some cervical neuroendocrine carcinomas

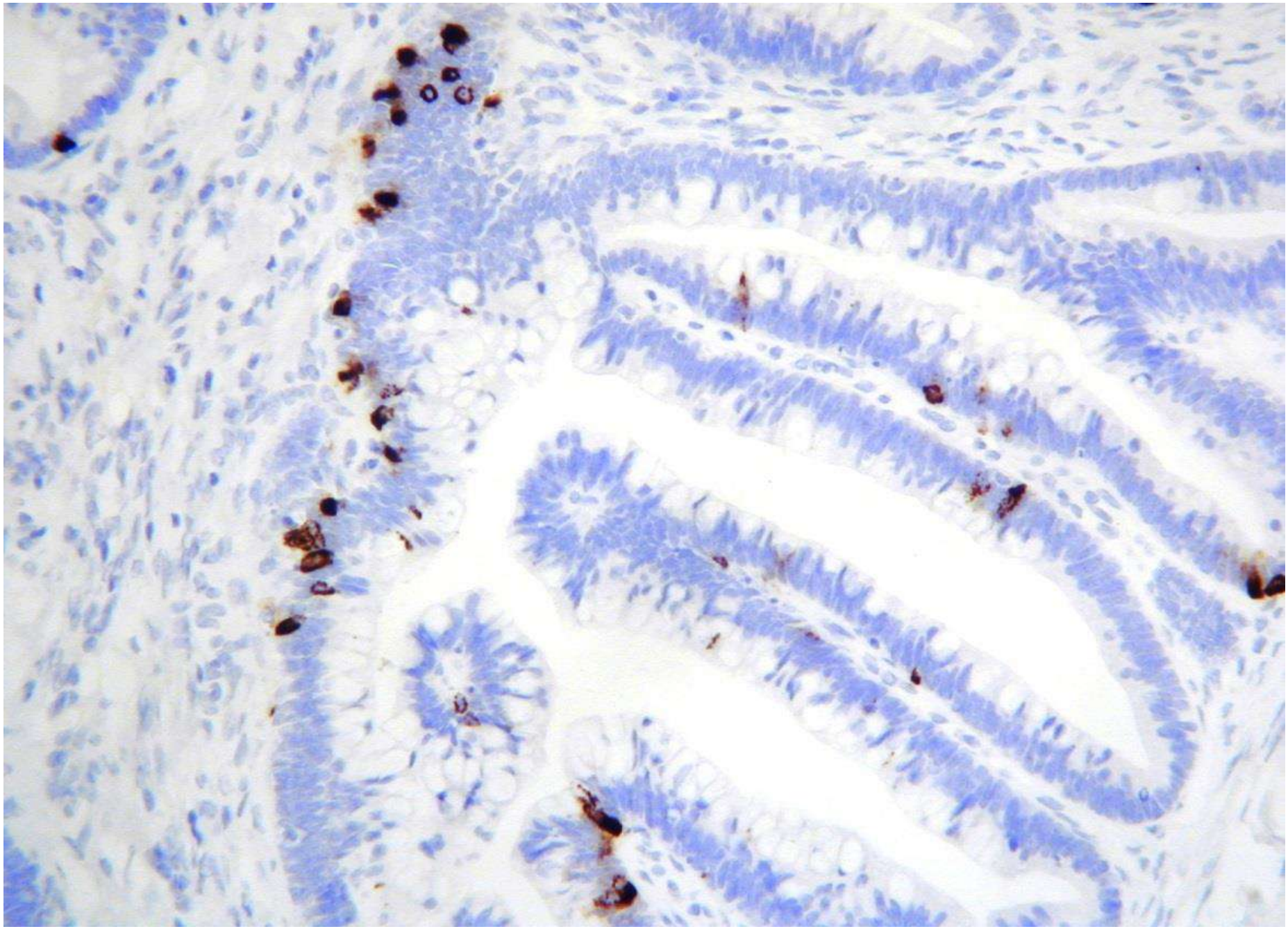

chromogranin

CERVIX-NEUROENDOCRINE TUMOUR (NET)

- Previously called typical and atypical carcinoid
- very rare
- occasional reports in literature but many not convincing from reviewing pictures
- occasional reported cases HPV-associated but ? some HPV-independent

PMID 35075048

International Journal of Gynecological Pathology
00:1–10, Lippincott Williams & Wilkins, Baltimore
Copyright © 2022 by the International Society of Gynecological Pathologists

Original Article

Low-grade Neuroendocrine Tumor of The Cervix: Report of 3 Cases of a Rare Neoplasm With Review of The Literature

Shatrughan Sah, F.R.C.Path., Pallavi V. Borkar, M.D., Catherine Wight, F.R.C.Path., Paul Kelly, F.R.C.Path., Kay J. Park, M.D., and W. Glenn McCluggage, F.R.C.Path.

LOW-GRADE NEUROENDOCRINE TUMOUR (NET) OF THE CERVIX: REPORT OF THREE CASES OF A RARE NEOPLASM WITH REVIEW OF THE LITERATURE

- PMID 35075048
- Case 1- pure grade 2 NET with nodal metastasis (FIGO stage IIIC1); HPV-independent
- Case 2- grade 1 NET associated with HSIL, AIS and HPV-associated adenocarcinoma (FIGO stage IA1); HPV-associated
- Case 3- chemoradiation for FIGO stage IIIC1 (radiology) NEC; salvage hysterectomy residual tumour was grade 1 NET; HPV-associated; may be maturation effect secondary to chemoradiation

CERVICAL LOW-GRADE NET

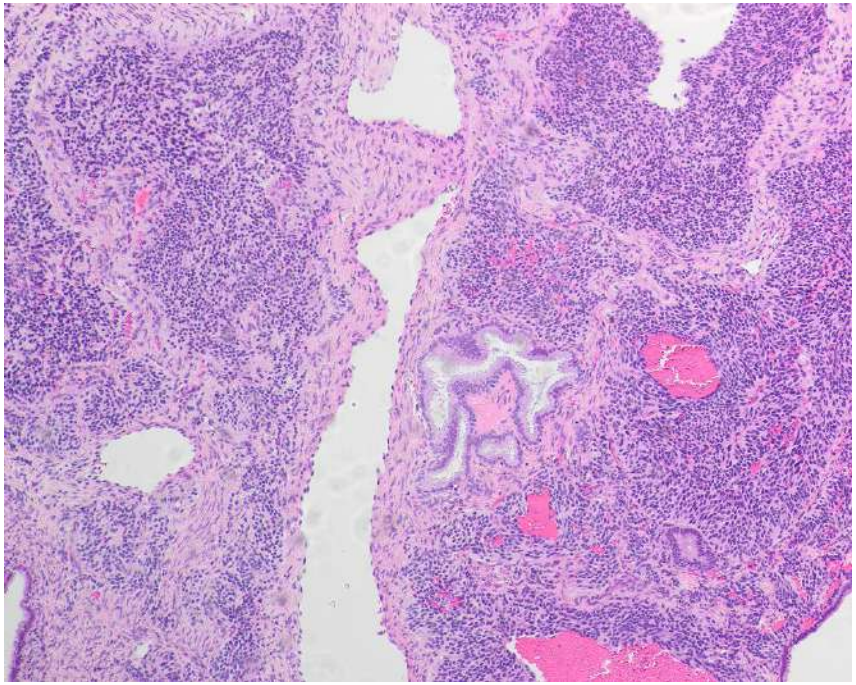

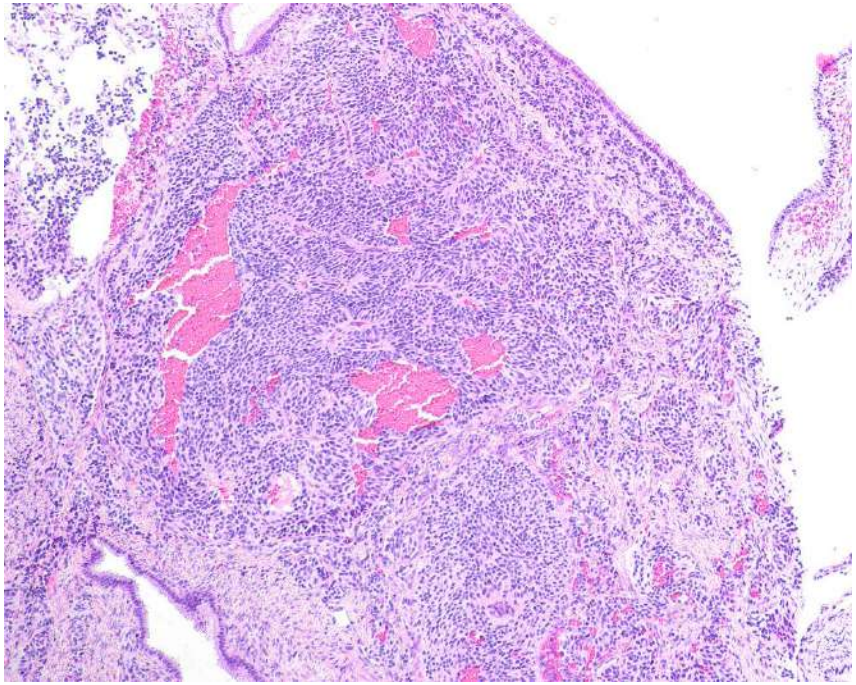

CASE 1

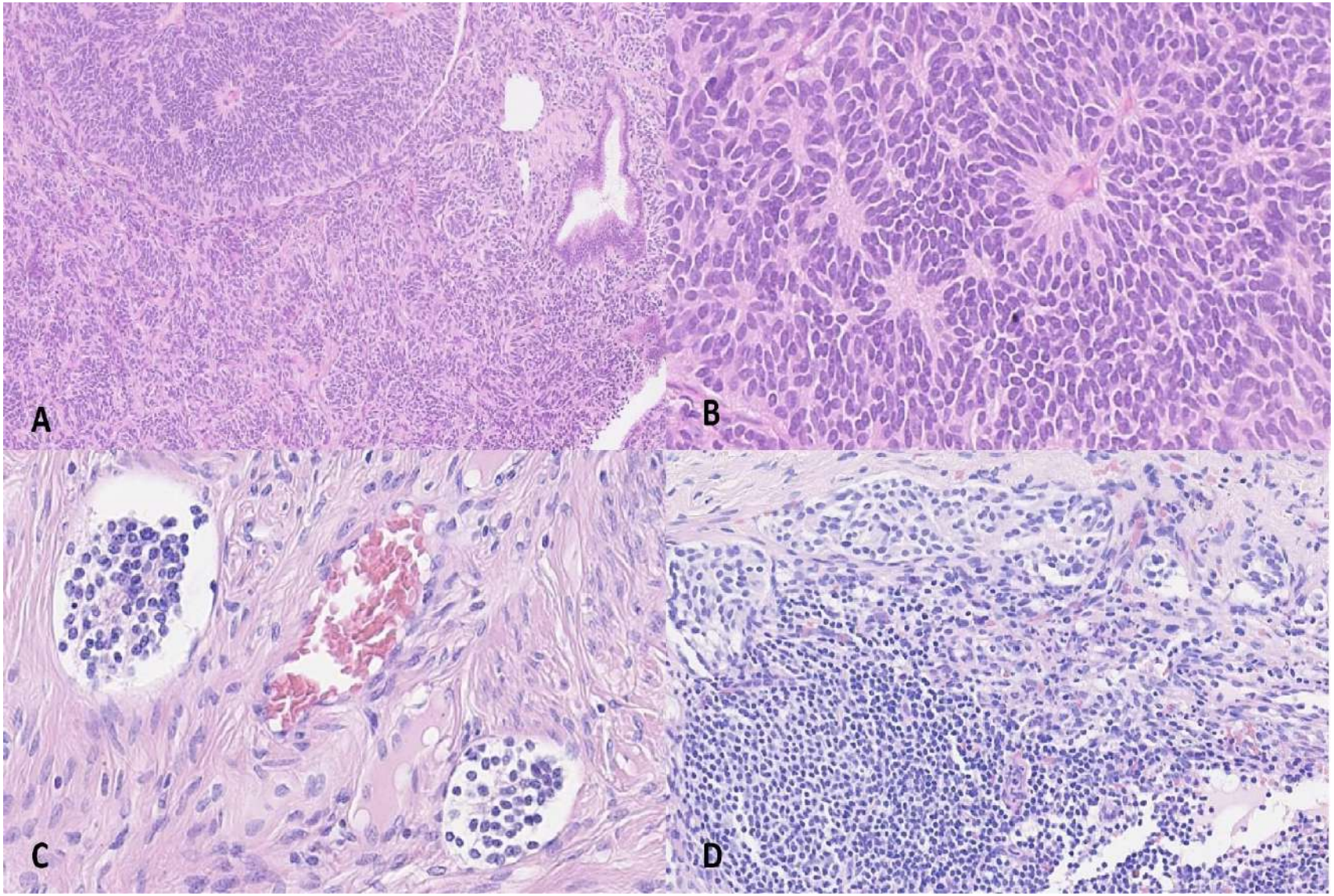

CASE 1

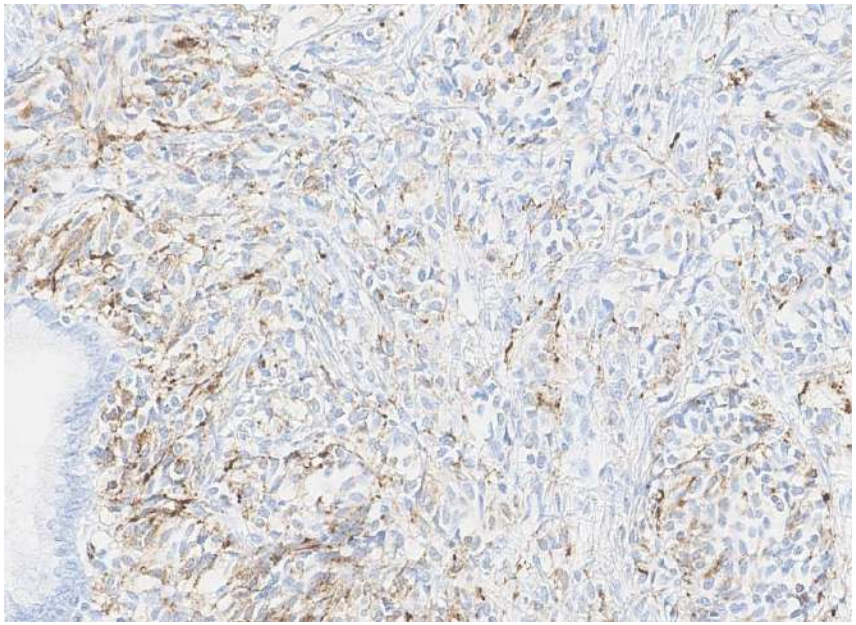

p16

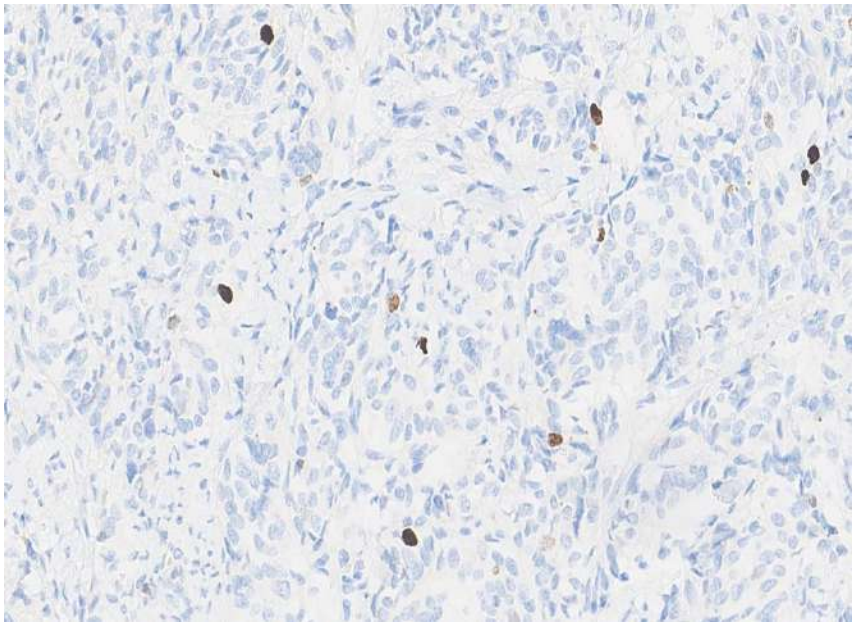

Ki67/ MIB1

CASE 1

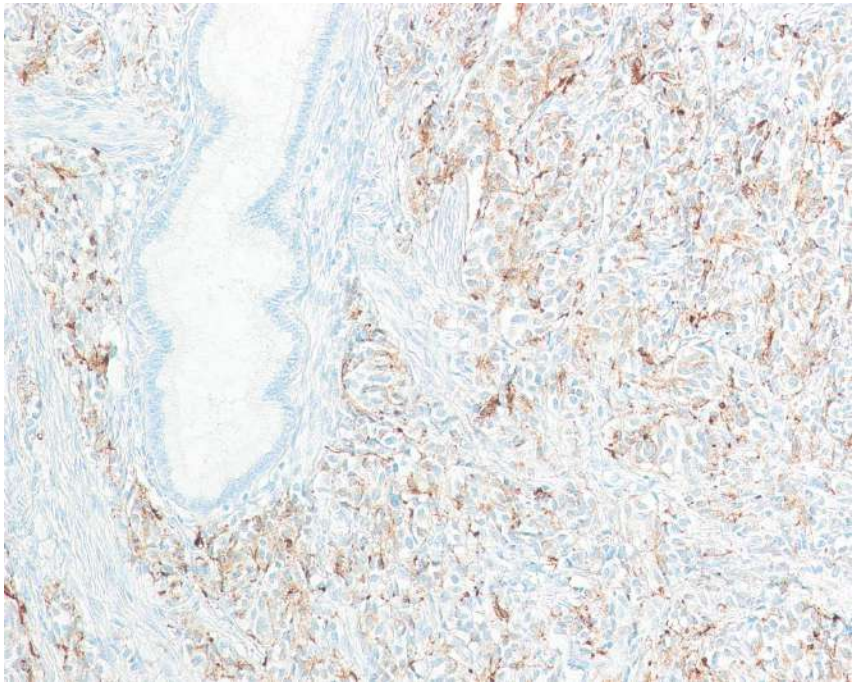

chromogranin

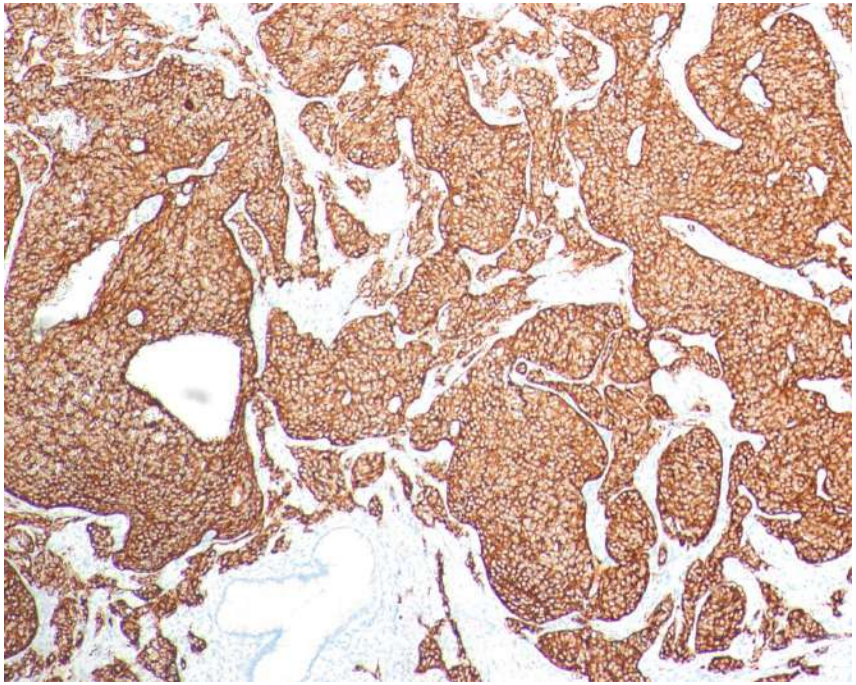

synaptophysin

CASE 7

- F 50
- Radical hysterectomy, BSO and pelvic lymphadenectomy following biopsy diagnosis of uterine serous carcinoma with obvious cervical involvement
- On gross examination, no tumour in uterine corpus

CERVIX

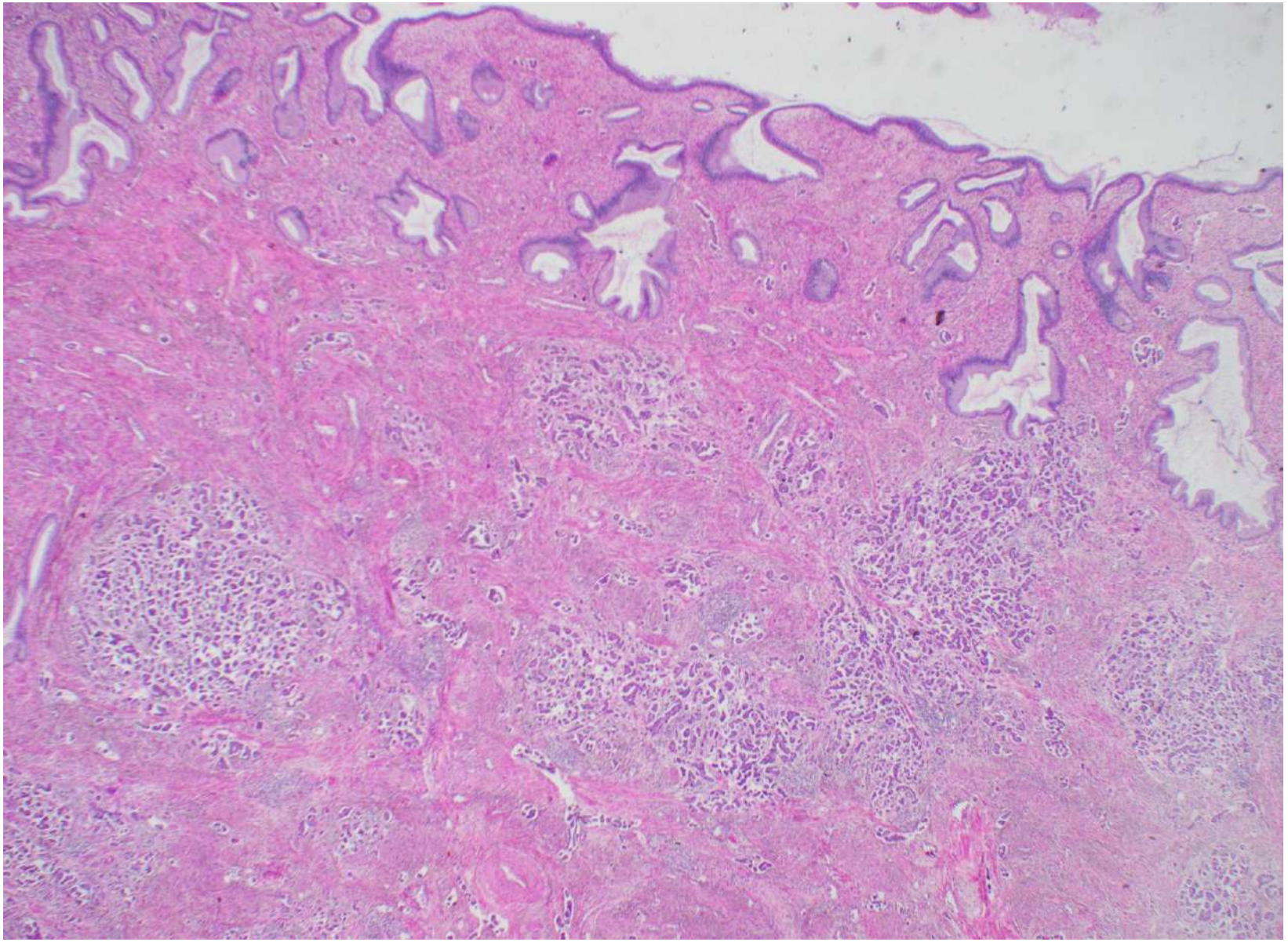

CERVIX

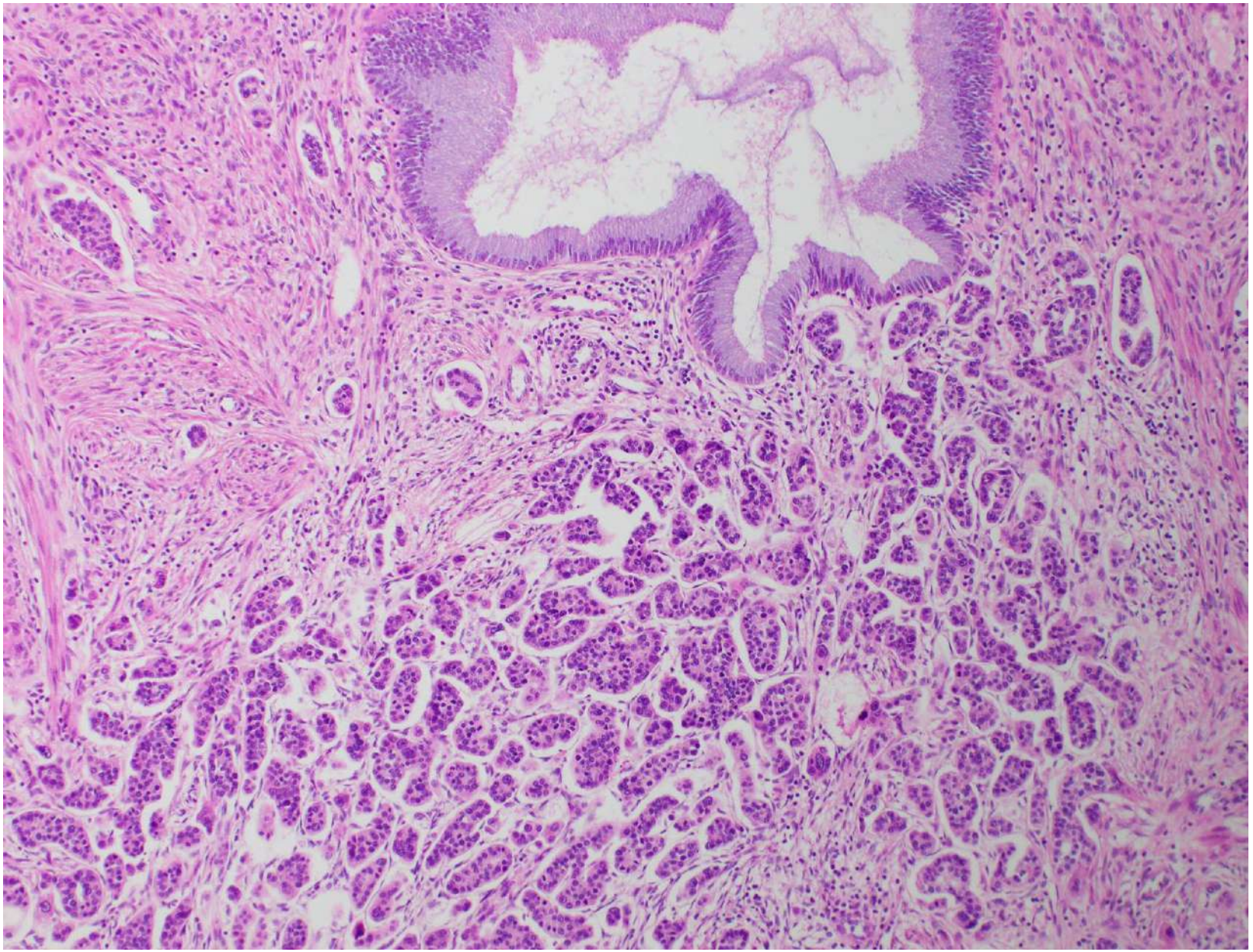

CERVIX

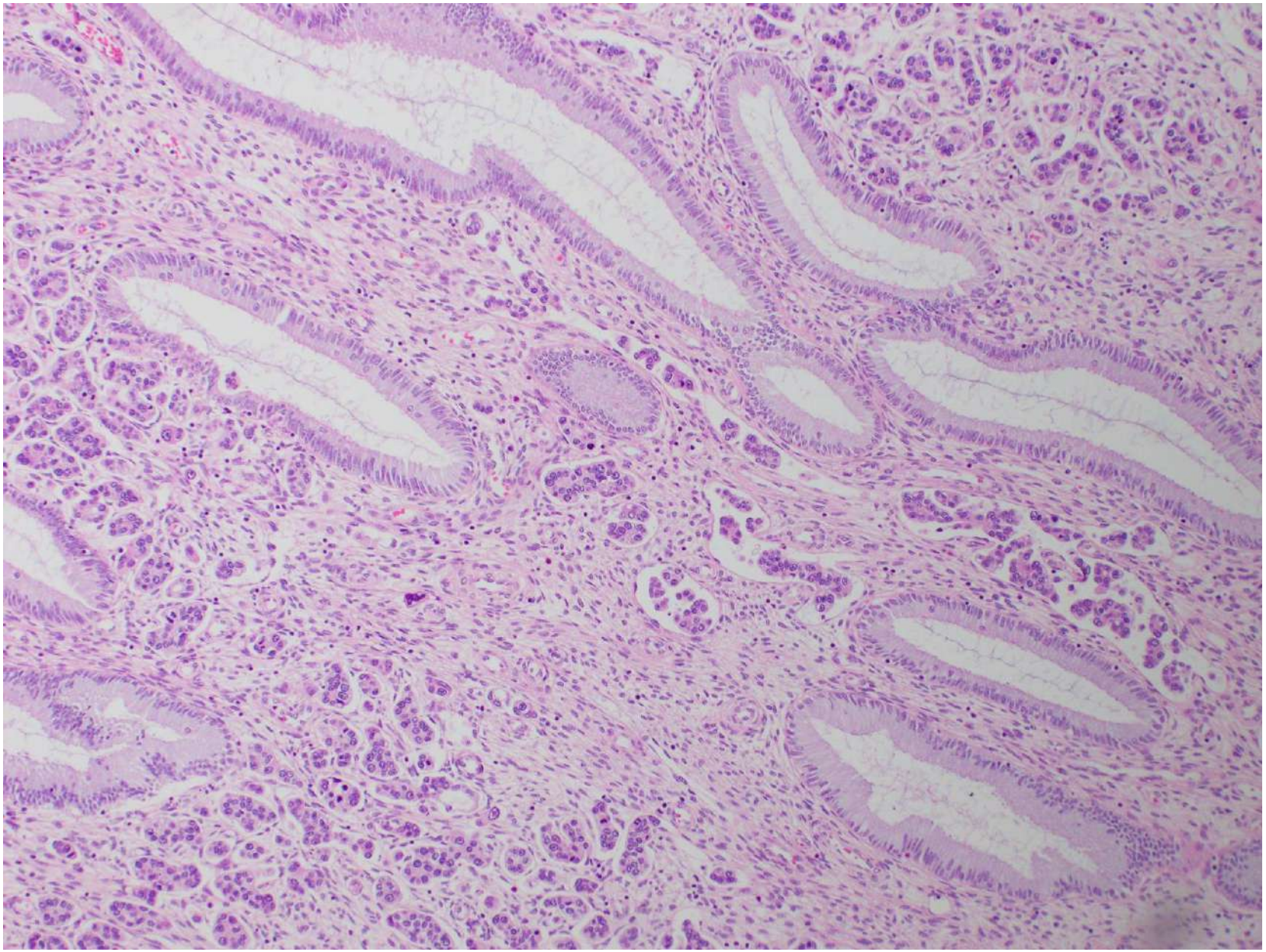

CERVIX

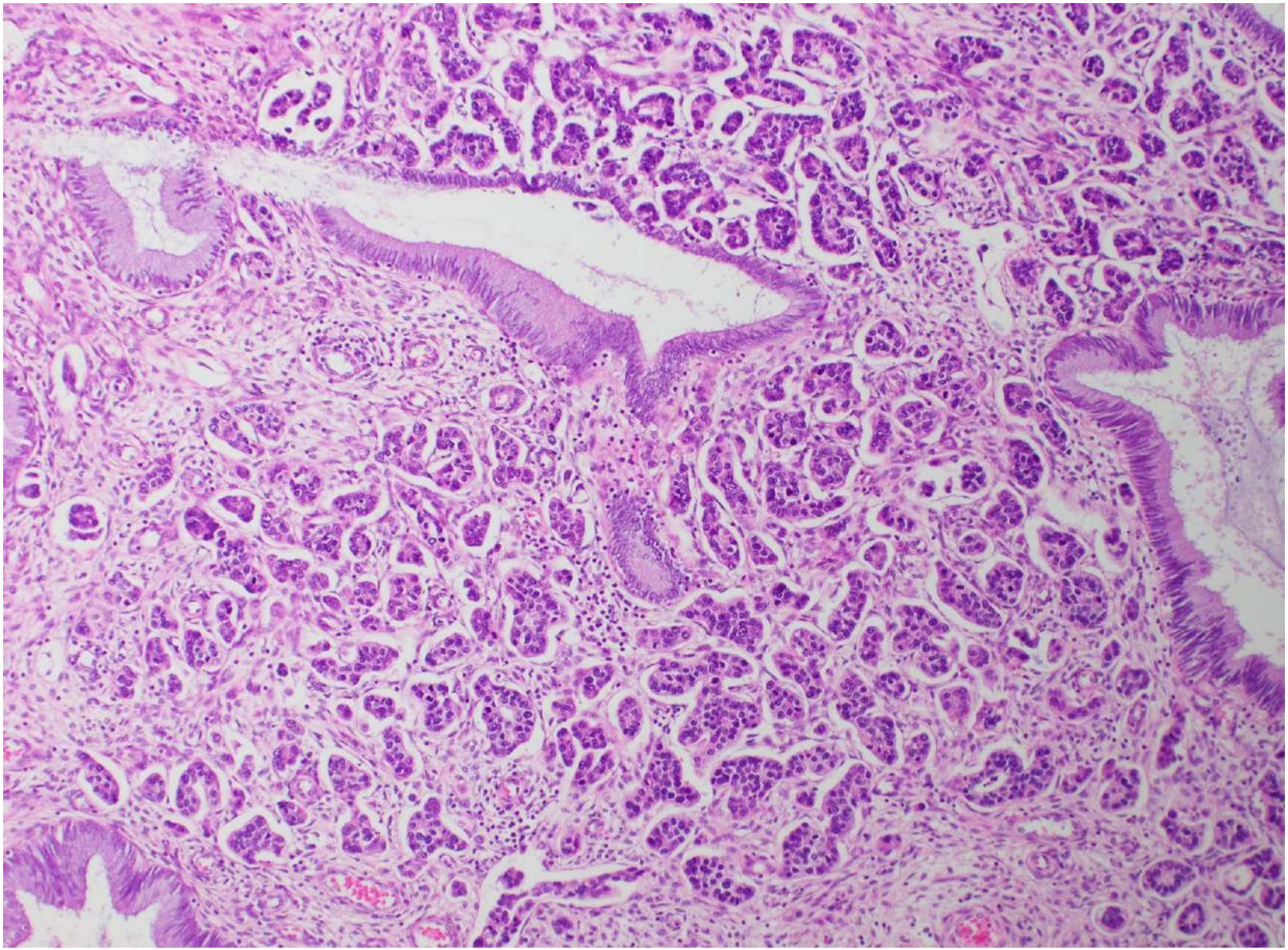

CERVIX

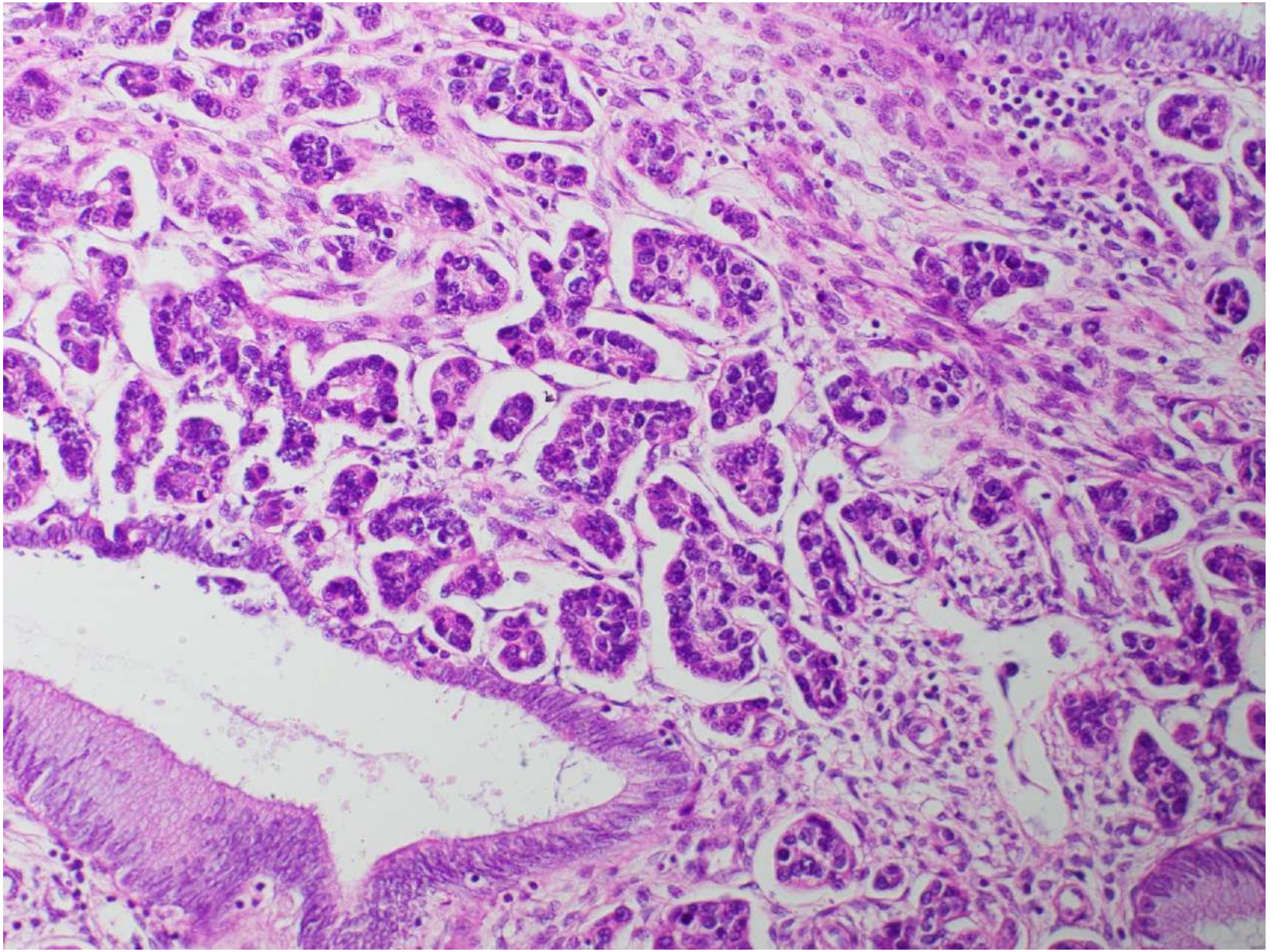

CERVIX

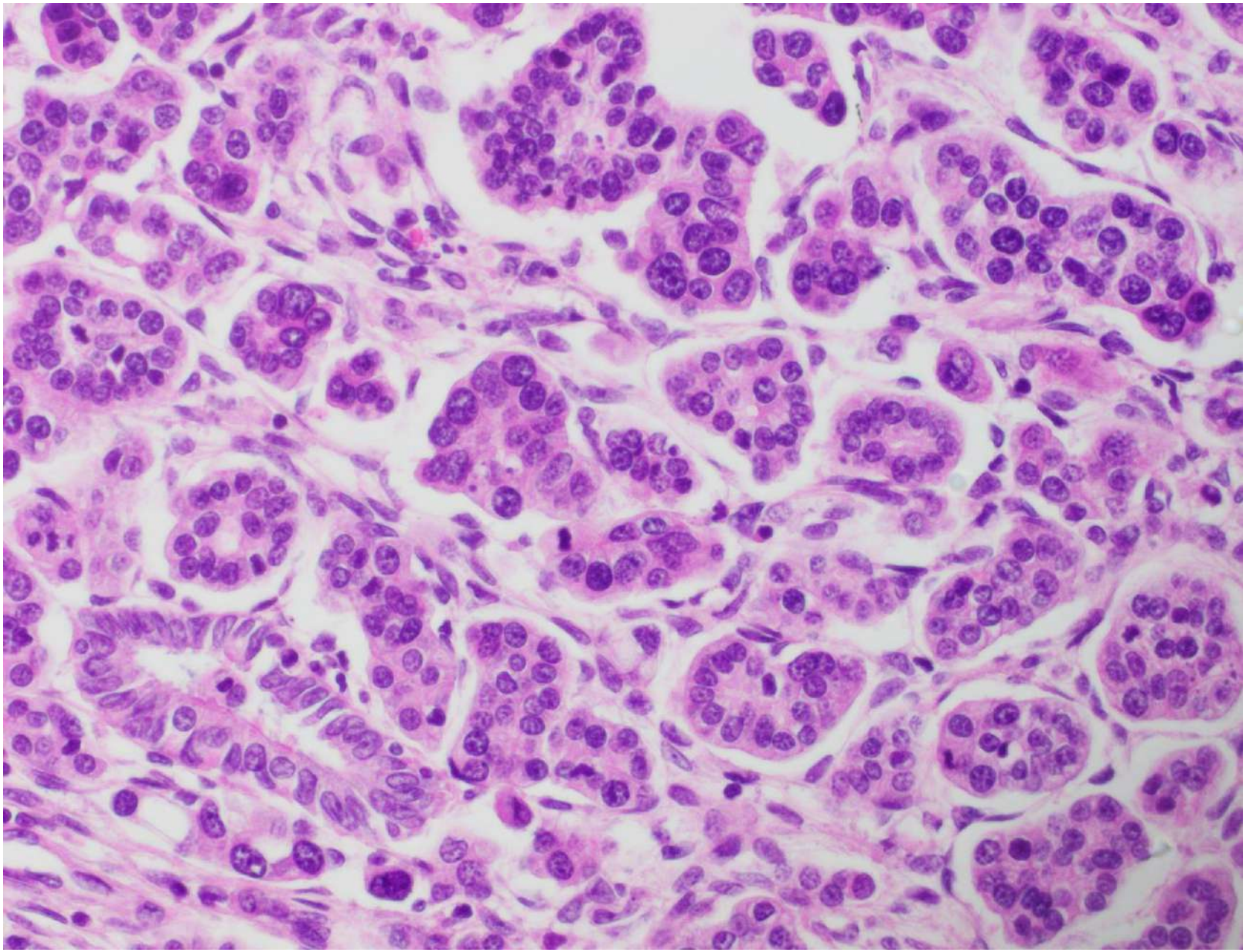

OVARY AND PELVIC NODES

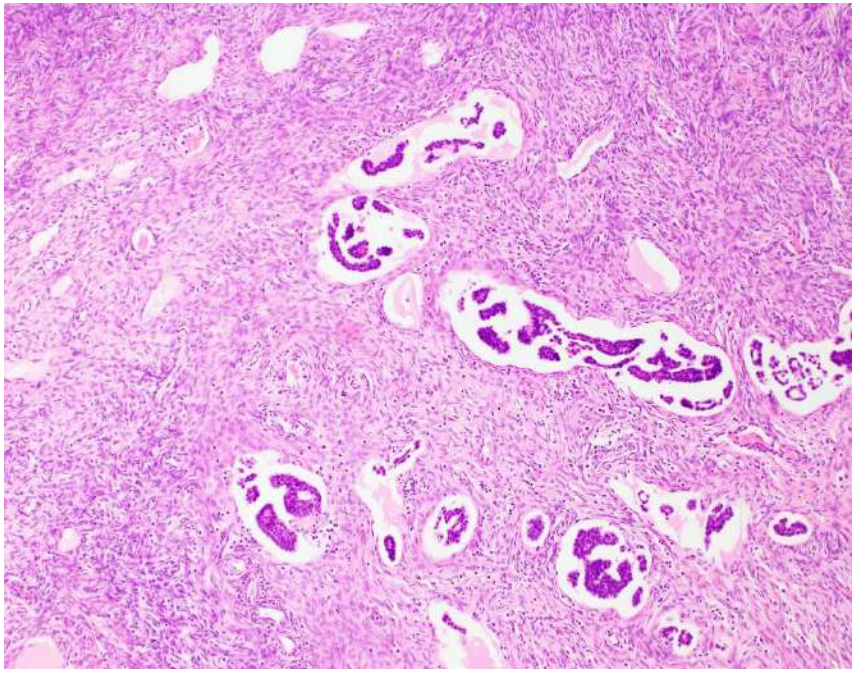

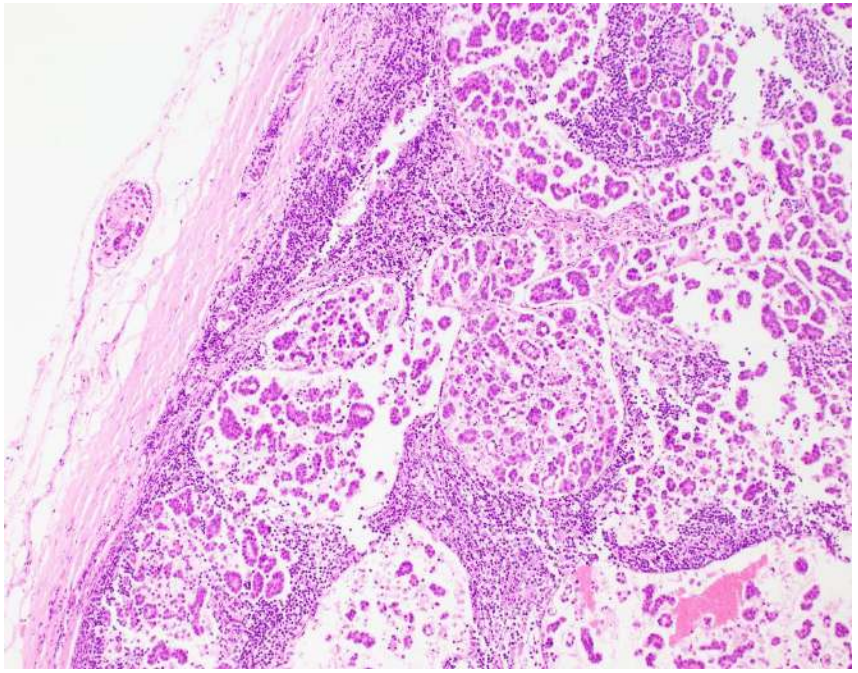

DISTRIBUTION OF TUMOUR

- Cervix- in stroma and extensively in vessels
- Corpus- nothing in endometrium; tumour in myometrial vessels
- Tumour in vessels in ovaries and tubes
- Multiple bilateral pelvic nodes involved

IMMUNOHISTOCHEMISTRY

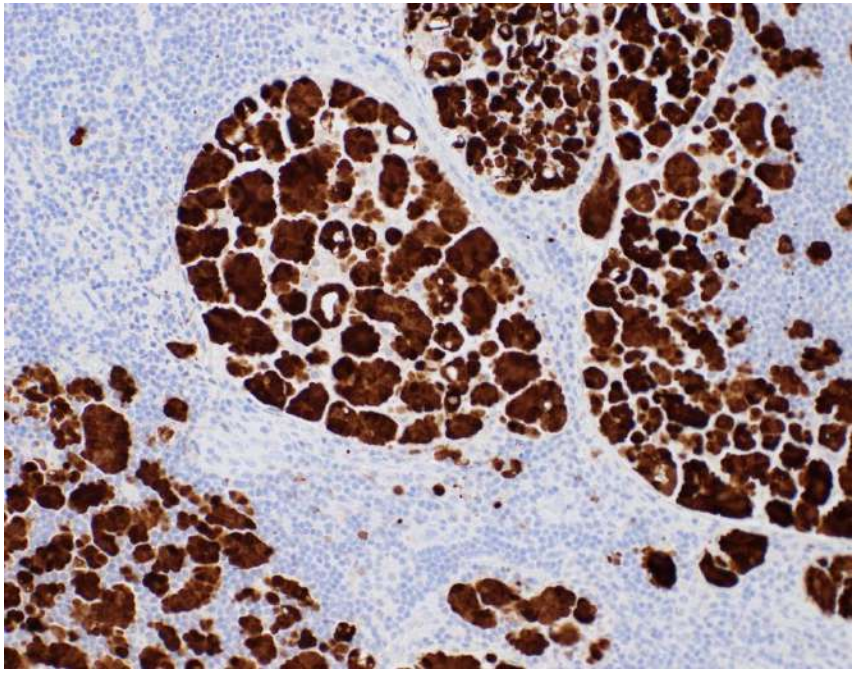

p16

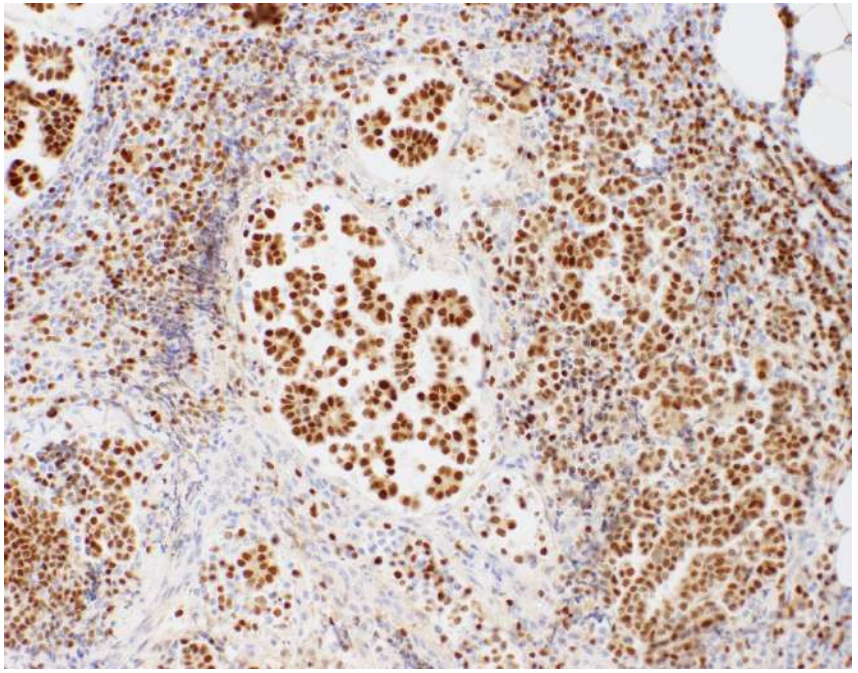

PAX8

p53

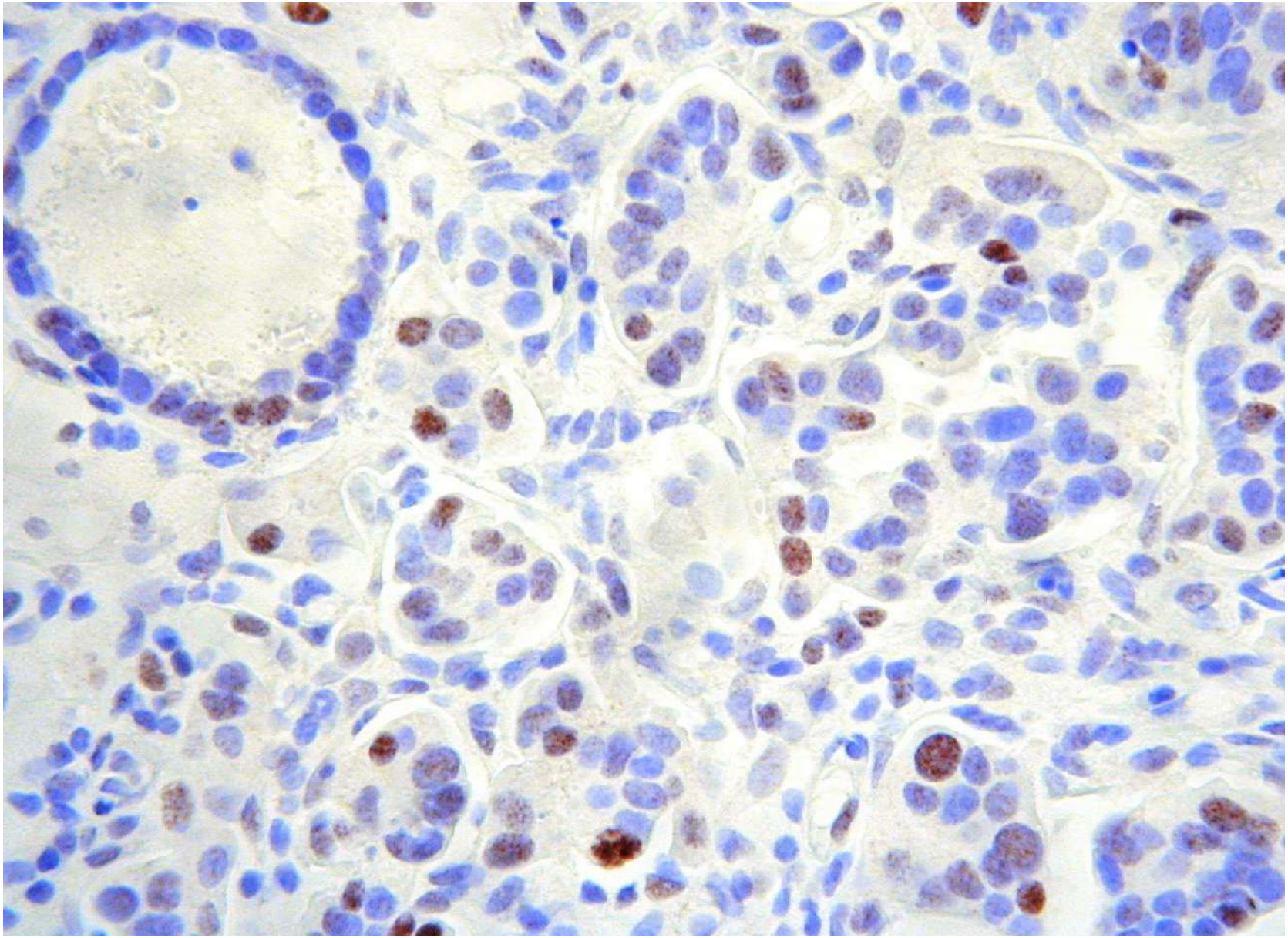

SUMMARY OF IMMUNOHISTOCHEMISTRY

- PAX8, CEA diffusely positive
- p16 diffuse block-type immunoreactivity
- p53 wild-type immunoreactivity
- ER, PR, WT1 negative

? DIAGNOSIS

DIAGNOSIS

- Micropapillary variant of HPV-associated cervical adenocarcinoma
- Molecular studies- HPV 16 positive

MICROPAPILLARY VARIANT OF HPV-ASSOCIATED CERVICAL ADENOCARCINOMA

- AJSP 2019; 43; 802-809
- Histopathology 2018; 72;623-633
- Focal or diffuse finding usually in usual HPV-associated cervical adenocarcinoma (diffuse p16 positive)
- HPV 16 or 18 most commonly
- Almost invariably exhibit prominent LVSI and often nodal involvement
- Aggressive behaviour
- Metastasis is often purely / predominantly micropapillary component
- Can be misdiagnosed as serous carcinoma (cervix, uterine or tubo-ovarian)- p53 almost almost always wild-type in micropapillary cervical adenocarcinoma
- Can also get micropapillary architecture in HPV-independent cervical adenocarcinomas (gastric, mesonephric)- don’t use term micropapillary adenocarcinoma for these

PMID 30864975

Published in final edited form as:
Am J Surg Pathol. 2019 June ; 43(6): 802–809. doi:10.1097/PAS.0000000000001245.

Micropapillary Cervical Adenocarcinoma: A Clinicopathologic Study of 44 Cases.

Isabel Alvarado-Cabrero, MD, PhD,
Chief of the Pathology Department Hospital de Oncologia, CMN, SXXI Instituto Mexicano del Seguro Social Mexico

W. Glenn McCluggage, FRCPath,
Belfast Health and Social Care Trust, Belfast, United Kingdom

Rafael Estevez-Castro, MD,
Hospital de Especialidades, CMN, SXXI Instituto Mexicano del Seguro Social Mexico

Delia Pérez-Montiel, MD,
Instituto Nacional de Cancerologia México

Simona Stolnicu, MD, PhD,
University of Medicine and Pharmacy, Tirgu Mures, Romania

Raji Ganesan, MD,
Birmingham Women's and Children's NHS foundation Trust, United Kingdom

Josefa Vella, MBCh, MSc, FRCPath,
Birmingham Women's and Children's NHS Foundation Trust, United Kingdom

Rosario Castro, MD,
Instituto de Patología y Citología Dominican Republic

Javier Canedo-Matute, MD,
Laboratorio de Patología y Citología (LAPACI), Colombia

Jessica Gomez-Cifuentes, MD,
Fundacion Universitaria de Ciencias de la Salud Hospital San José, Colombia

Vilma M Rivas-Lemus, MD,
Hospital San Juan de Dios de Santa Ana El Salvador

Kay J. Park, MD,
Department of Pathology, Memorial Sloan Kettering Cancer Center, USA

Robert A. Soslow, MD,
Department of Pathology, Memorial Sloan Kettering Cancer Center, USA

Esther Oliva, MD,
Department of Pathology, Massachusetts General Hospital, USA

Raquel Valencia-Cedillo, MD
Hospital de Oncología, CMN, SXXI Instituto Mexicano del Seguro Social, Mexico

CAN ALSO GET MICROPAPILLARY GROWTH IN HPV-INDEPENDENT CERVICAL ADENOCARCINOMAS

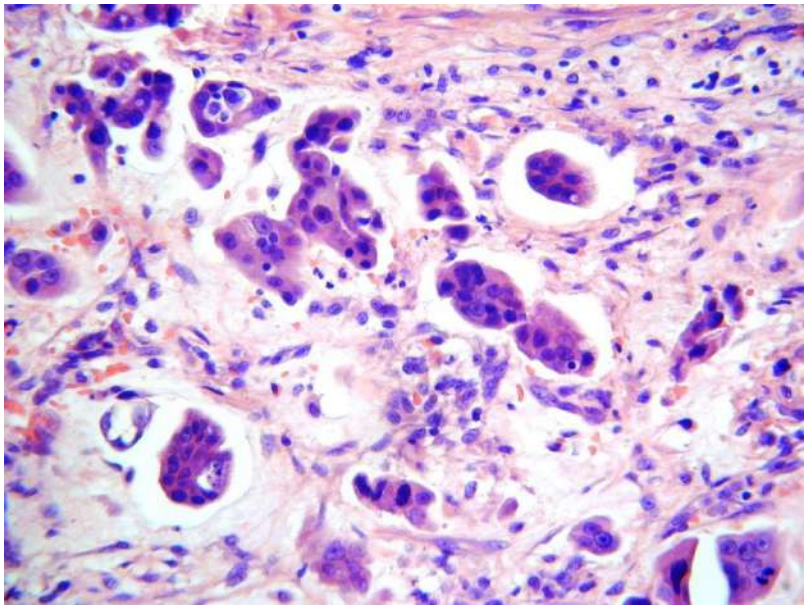

gastric-type

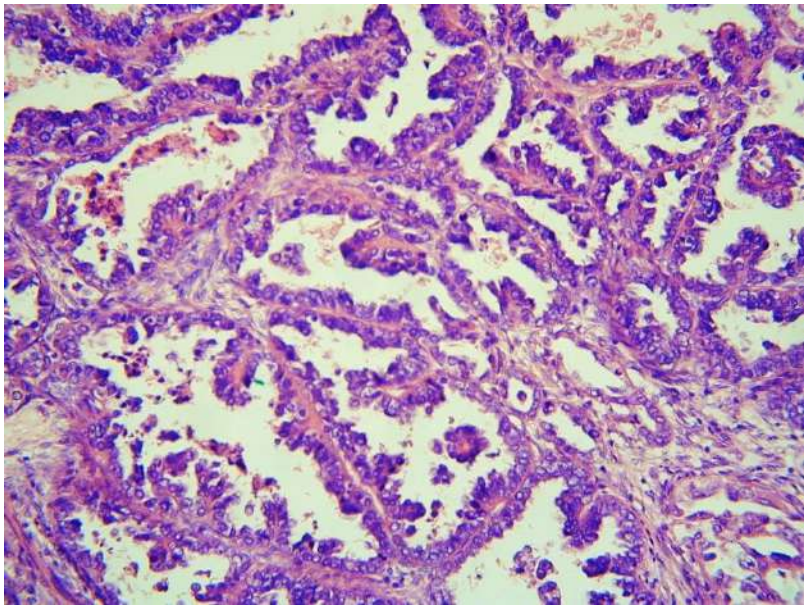

mesonephric

MICROPAPILLARY ADENOCARCINOMAS

- Reported in many organs- breast, urinary tract, lung, colon etc
- Small cohesive micropapillary arrangements of cells, no fibrovascular cores, often in clear spaces resembling vessels
- Usually aggressive behaviour (poor prognosis)
- Often extensive lymphovascular involvement

SEROUS ADENOCARCINOMA CERVIX

- now accepted that true serous carcinoma does not exist in cervix
- not included in WHO 2020
- cases diagnosed as primary cervical serous carcinoma represent spread from undetected endometrial (or tubo-ovarian) primary or HPV-associated (including micropapillary) mimicking serous carcinoma (these will be p53 wild-type)
- TIP- high-risk HPV associated lesions almost never exhibit mutation-type p53 staining; exception is a few cervical neuroendocrine carcinomas
- if tumour exhibits block-type p16 and mutation-type p53 staining, almost certainly HPV-independent neoplasm (for example uterine serous or tubo-ovarian HGSC)

HPV-ASSOCIATED MIMICKING SEROUS CARCINOMA

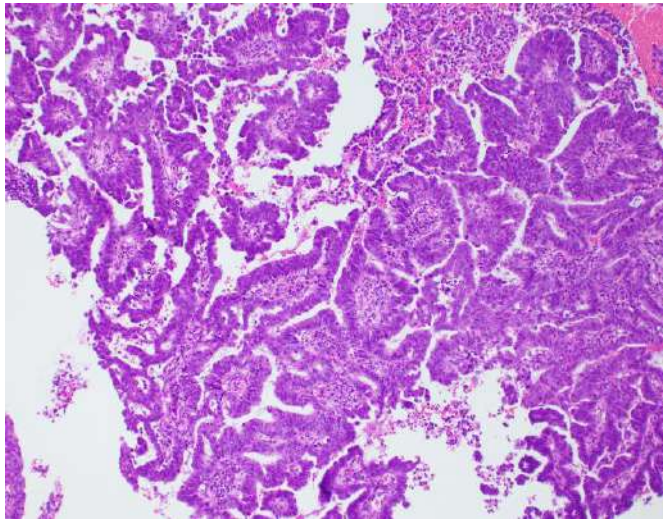

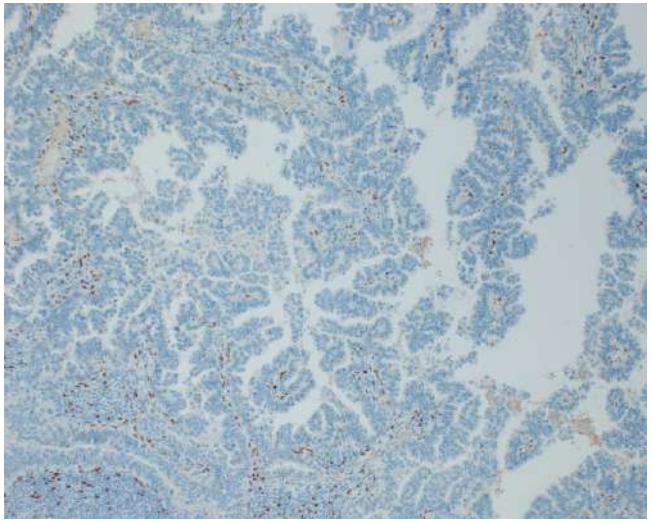

ER

p16

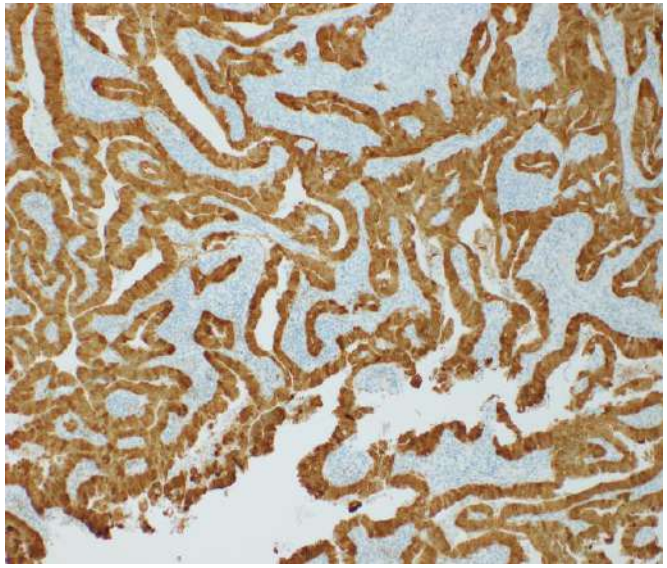

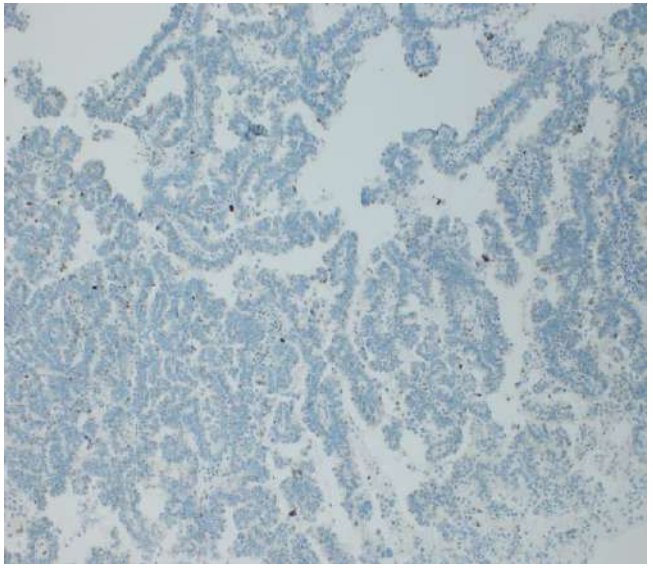

p53