The British Association of Gynaecological Pathologists

Lecturer – Matt Evans



I am a consultant cellular pathologist, specialising in biomarker, thoracic and gynaecological pathology. I work extensively with industry and with UK regulators in the roll-out of new biomarkers in a tumour-agnostic fashion. I am also heavily involved in the training of pathologists to interpret biomarker tests – particularly PD-L1 – both in the UK and internationally.

The British Association of Gynaecological Pathologists

Everyday Dilemmas in Gynaecological Pathology

- Significance and interpretation of subclonal p53/MMR IHC
- Dr Matt Evans
- University Hospital Southampton, Black Country Pathology Services, Central and South Genomic Laboratory Hub
- 7th March 2025

The British Association of Gynaecological Pathologists

Speaker disclosures

- I have the following to disclose

Agilent Technologies, Amgen, AstraZeneca, Boehringer Ingelheim, Bristol-Myers Squibb, Eli Lilly, Incyte Biosciences, Jazz Pharmaceuticals, Merck Sharp & Dohme, Pfizer, Roche, Servier



Subclonal p53 and MMR abnormalities

Matt Evans

Consultant Cellular Pathologist

Pathology Lead, Central and South Genomic Laboratory Hub

NHS
Black Country Pathology Services

NHS
Central and South
Genomic Medicine Service Alliance

NHS
University Hospital Southampton
NHS Foundation Trust

What are subclonal alterations?

Clonal

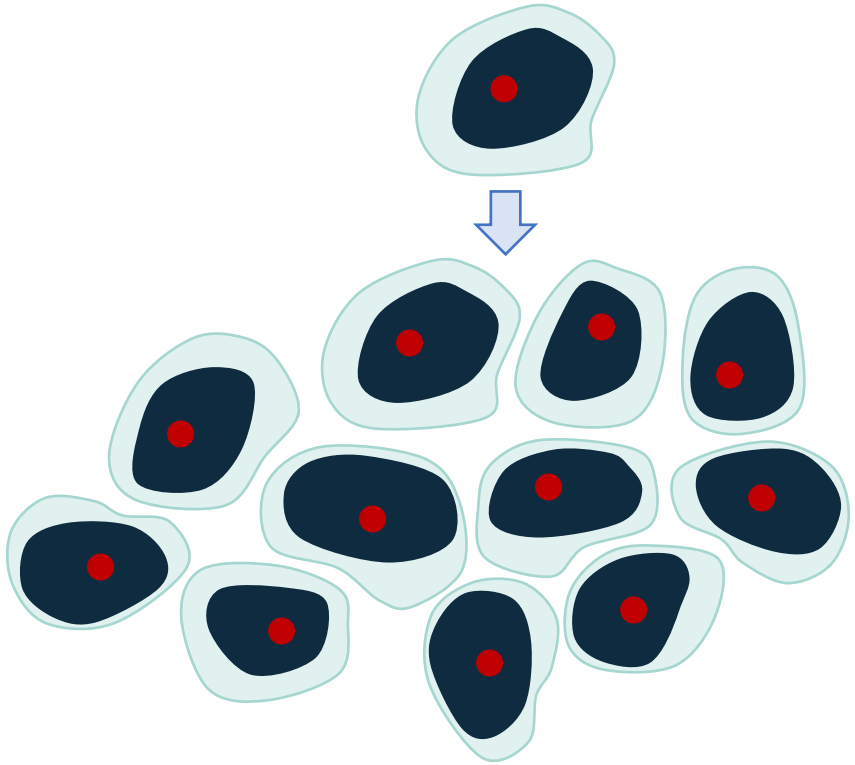

Subclonal

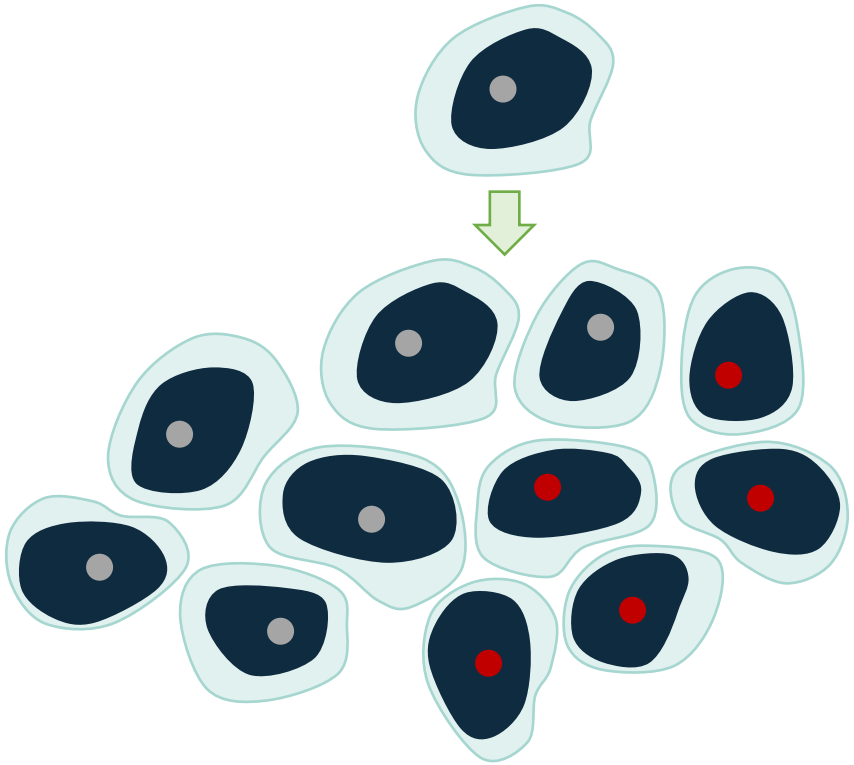

Subclonal p53/*TP53* alterations

Clinical history

PATIENT

62 years old, female

SPECIMEN TYPE

Endometrial pipelle

CLINICAL DETAILS

PMB

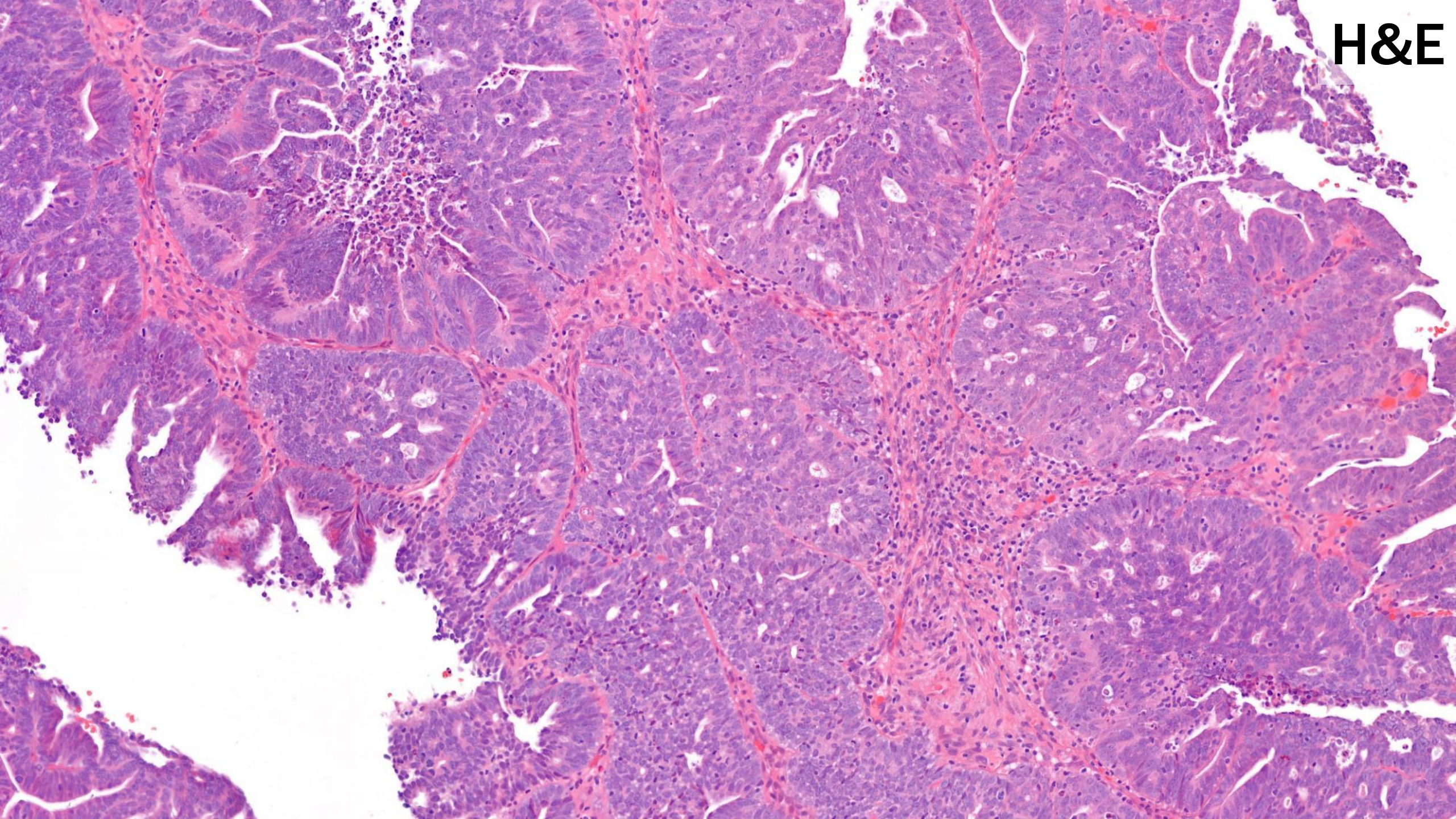
H&E

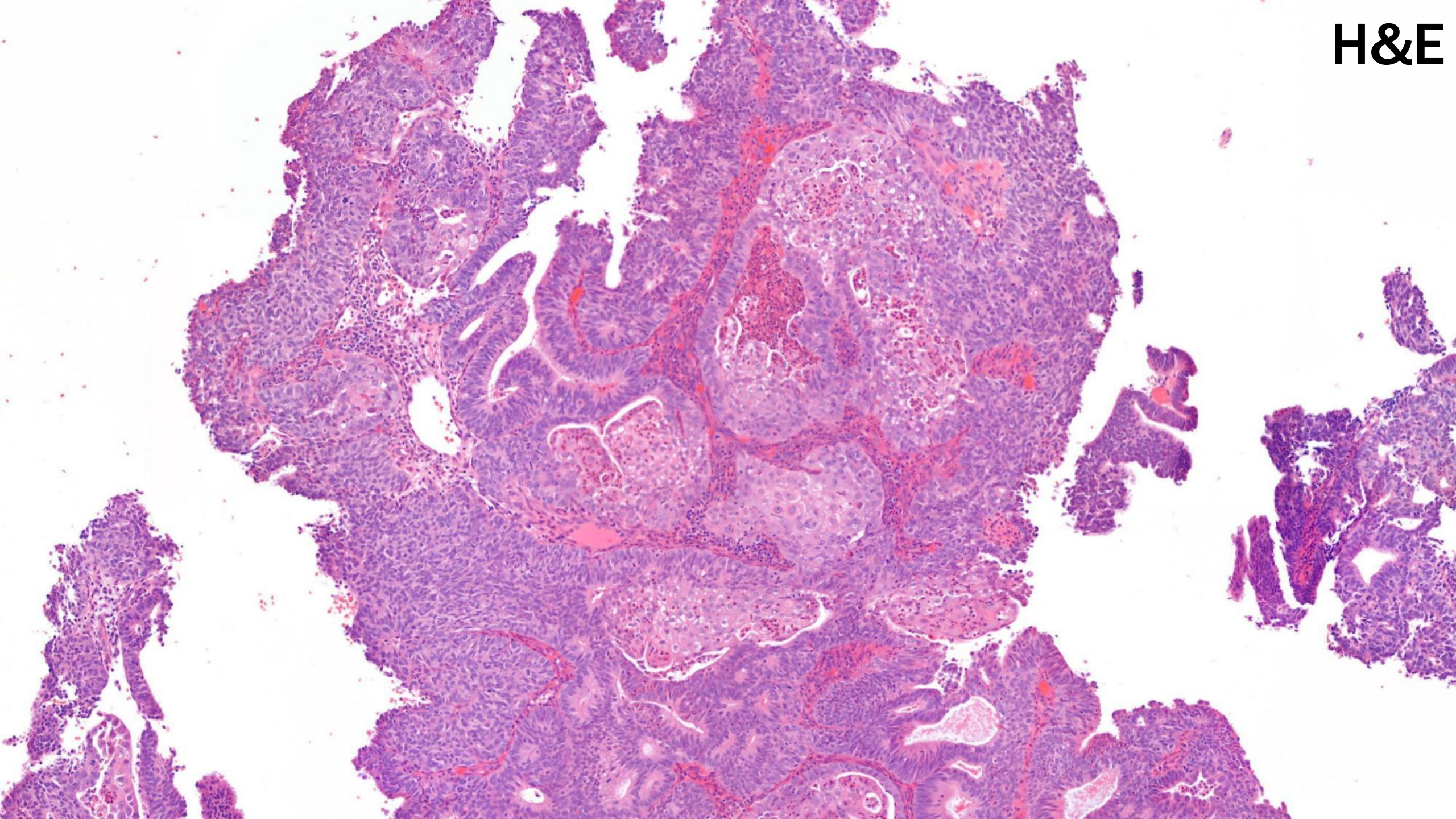
H&E

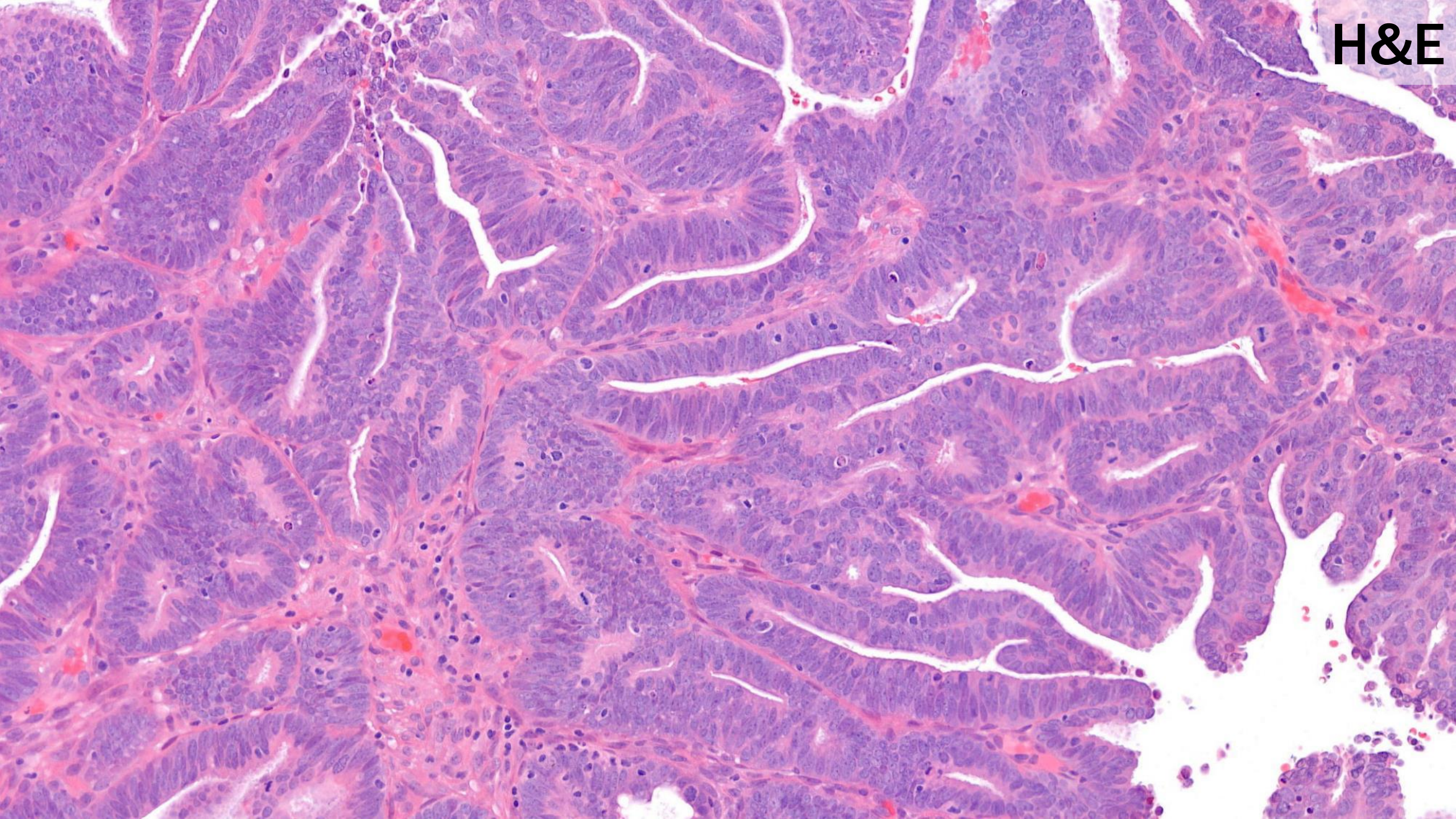
H&E

Diagnosis

DIAGNOSIS
Endometrioid adenocarcinoma, FIGO grade 2 on the basis of the material here

MMR: MMR-proficient (pMMR)
ER: Positive (Quick score 8/8)

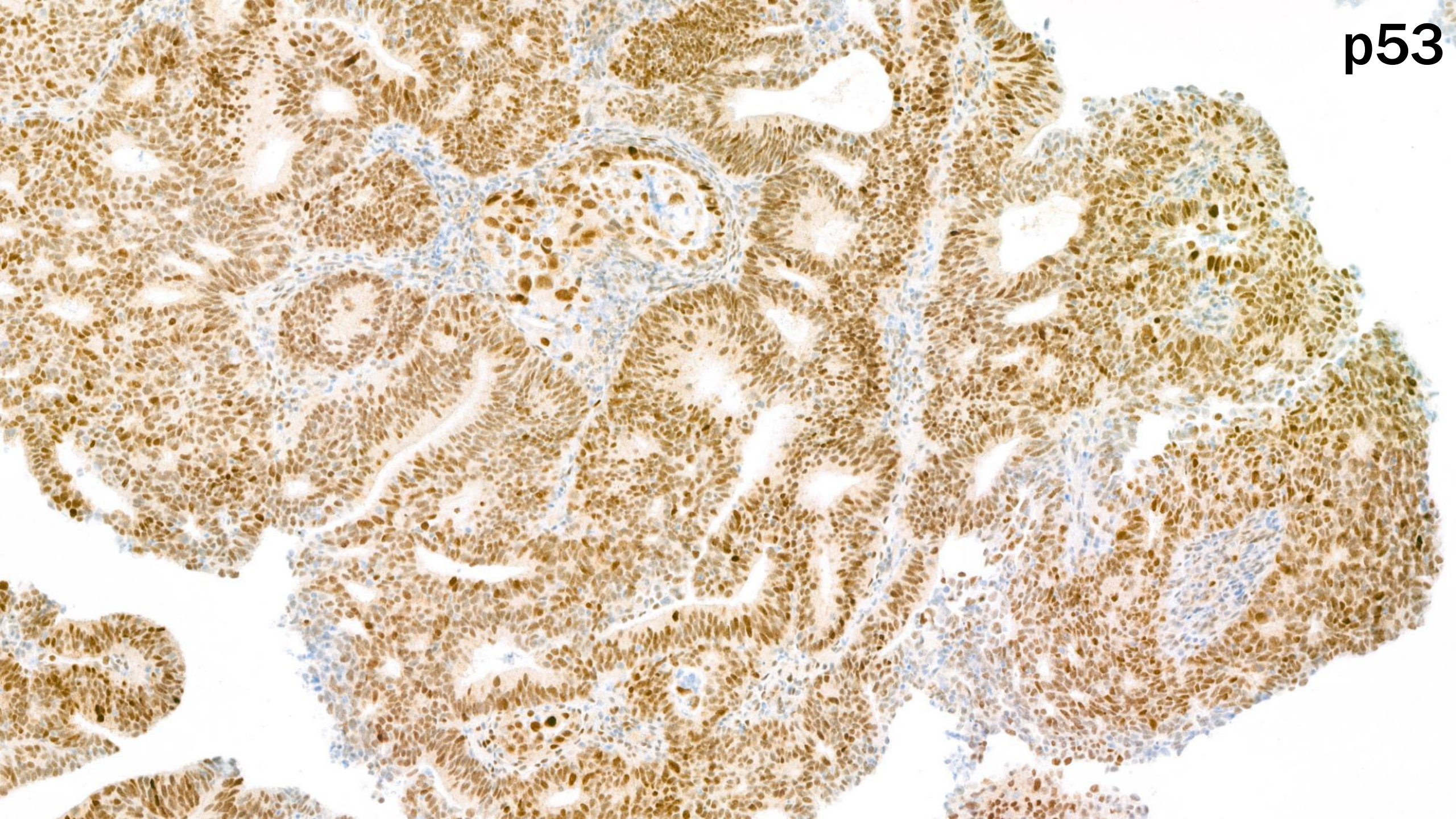
p53

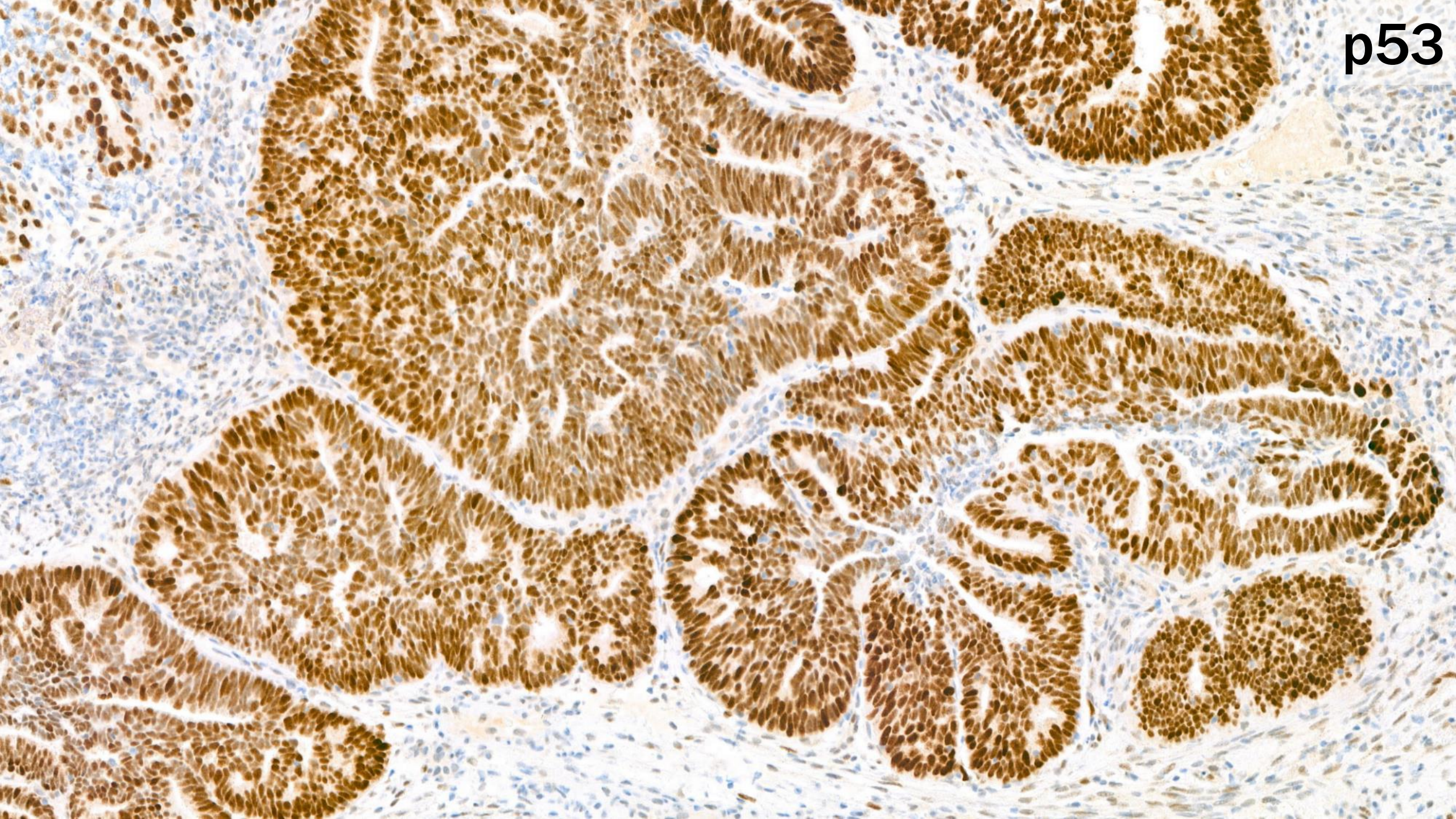
p53

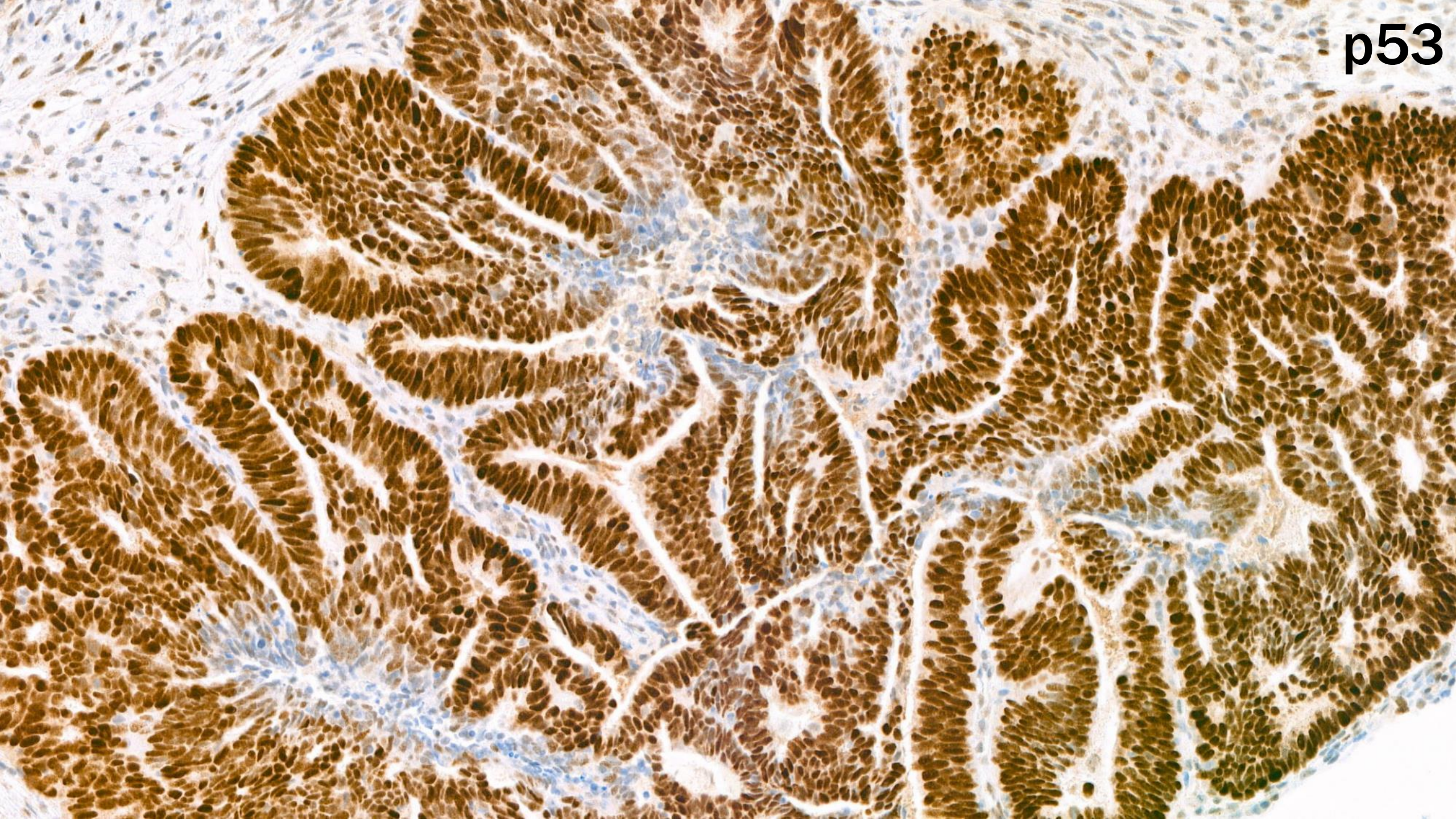
p53

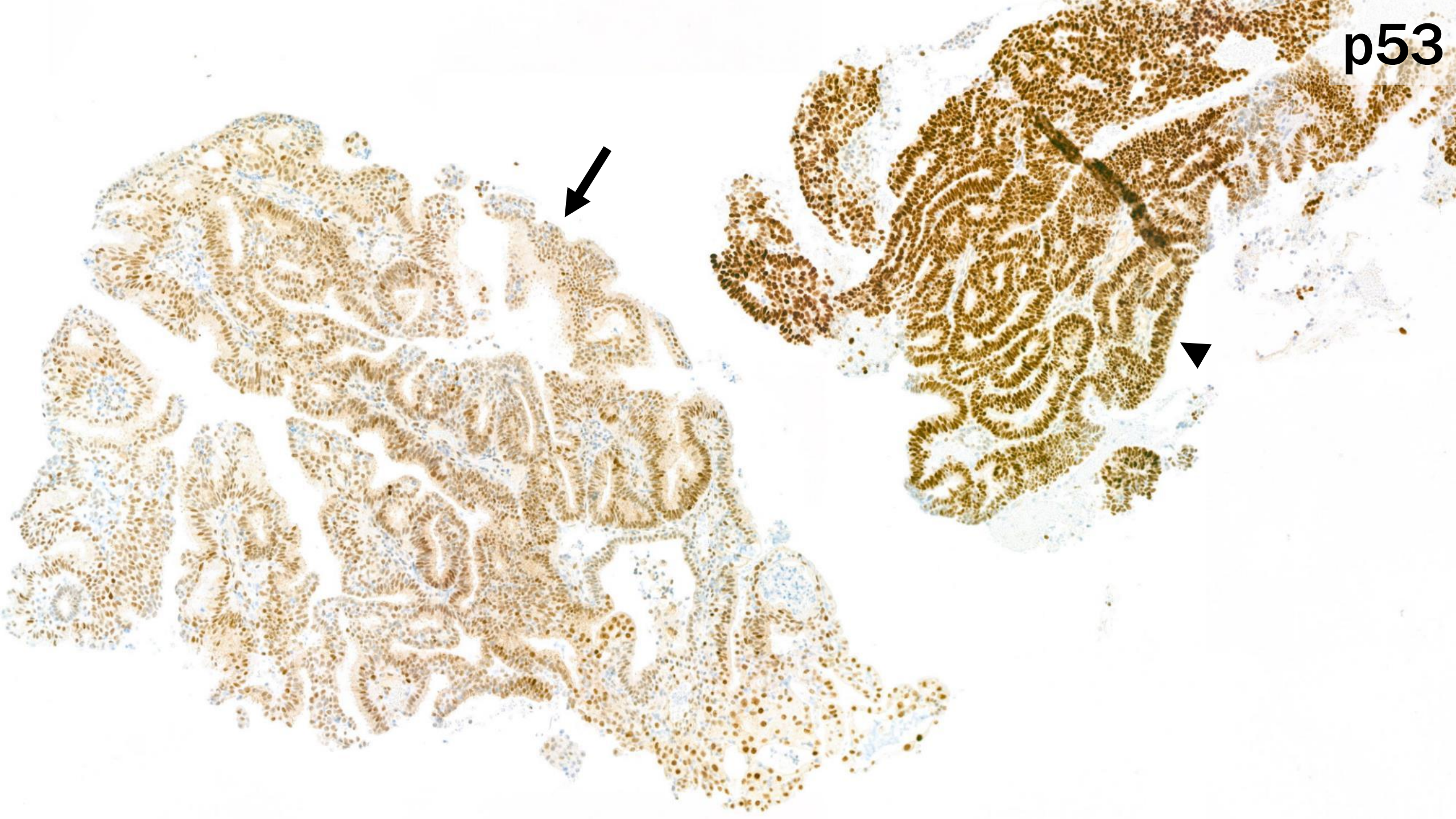
p53

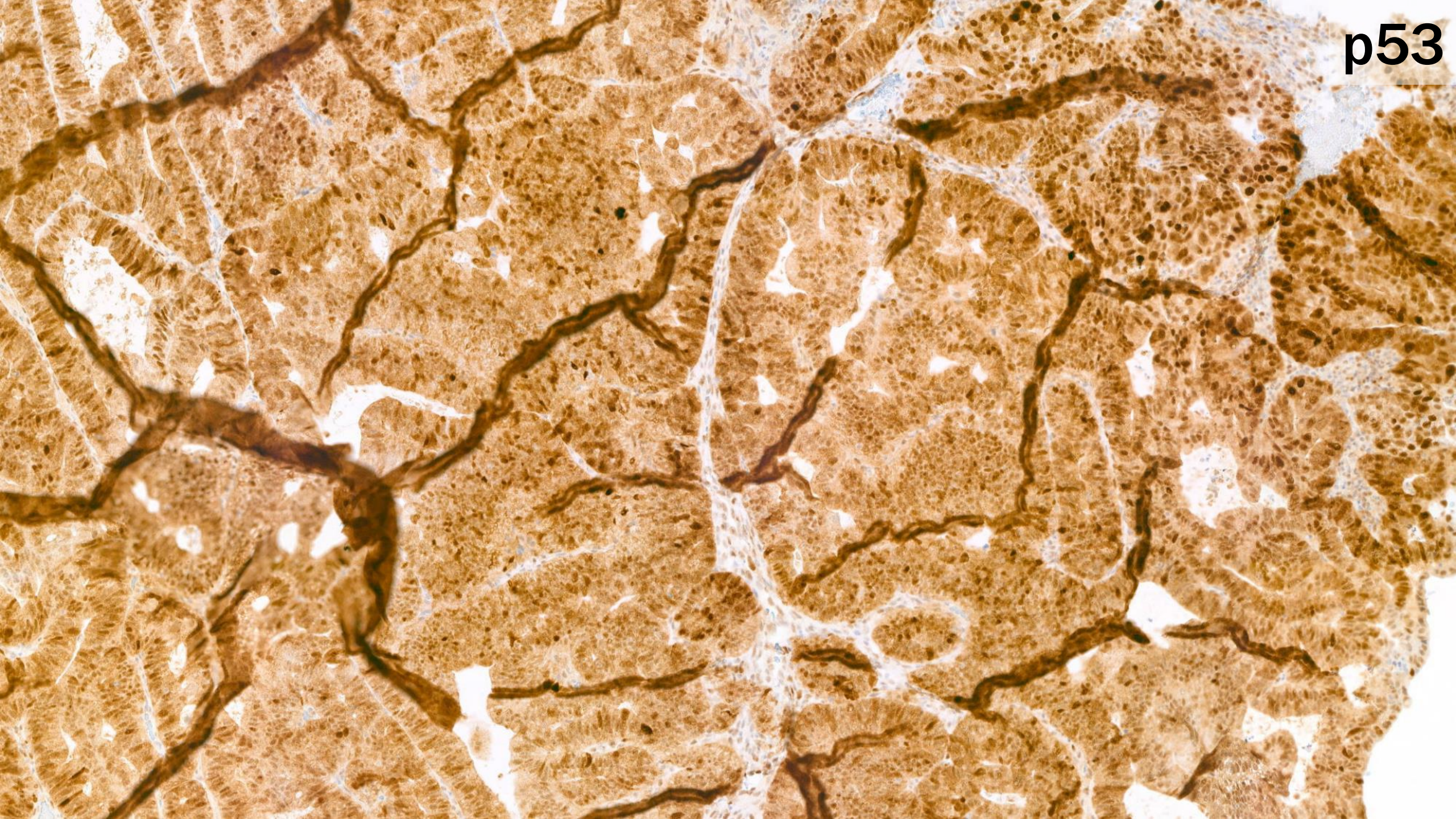
p53

Why does p53 matter?

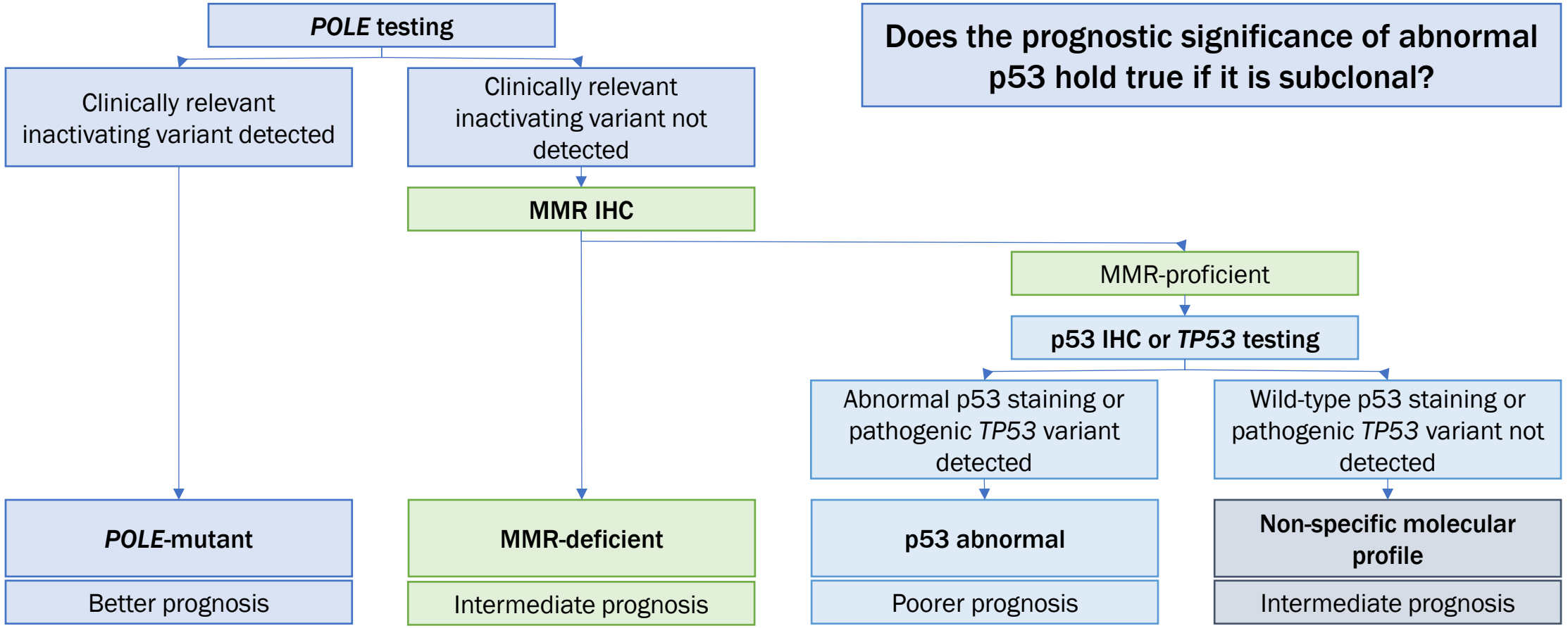

NHS Black Country Pathology Services
NHS Central and South Genomic Medicine Service Alliance
NHS University Hospital Southampton NHS Foundation Trust

Does a subclonal p53 alteration have the same prognostic significance?

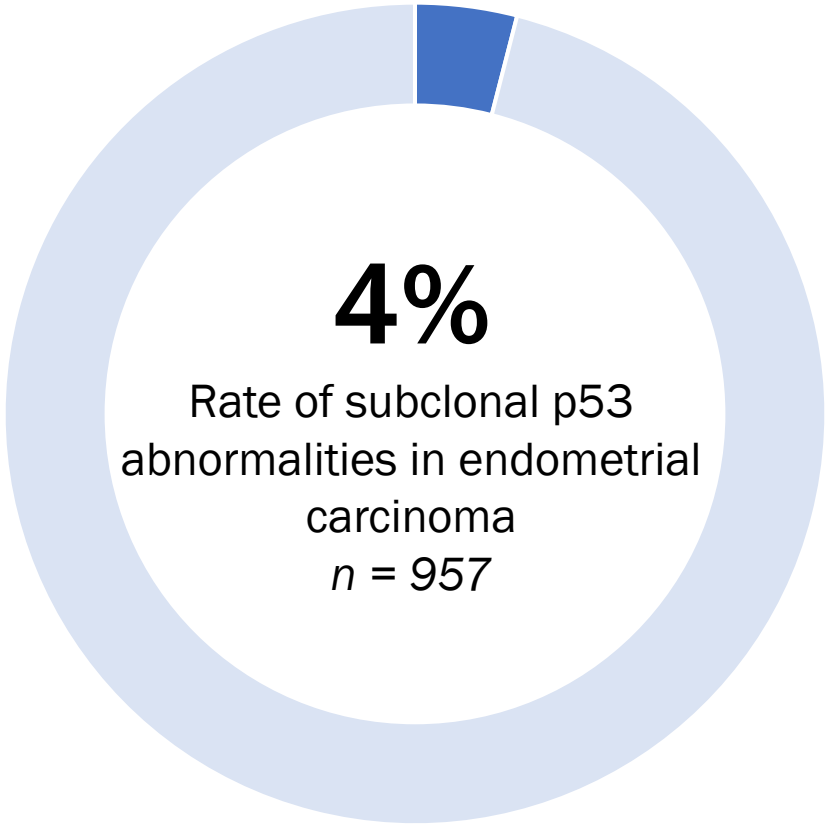

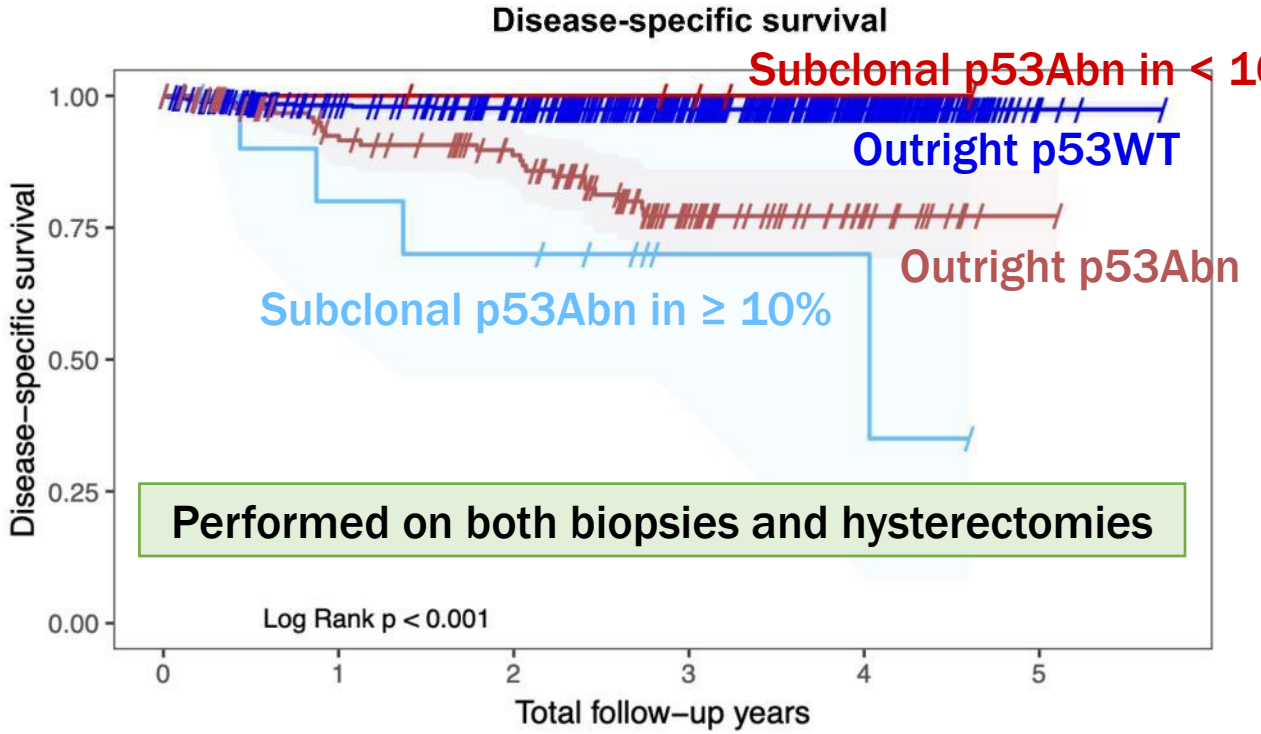

Performed on both biopsies and hysterectomies

Subclonal p53 on biopsy → repeat on hysterectomy

Huvila, J., Thompson, E. F., Vanden Broek, J., Lum, A., Senz, J., Leung, S., ... & Jamieson, A. (2023). Subclonal p53 immunostaining in the diagnosis of endometrial carcinoma molecular subtype. *Histopathology*, *83*(6), 880-890.

So this patient likely has aggressive disease?

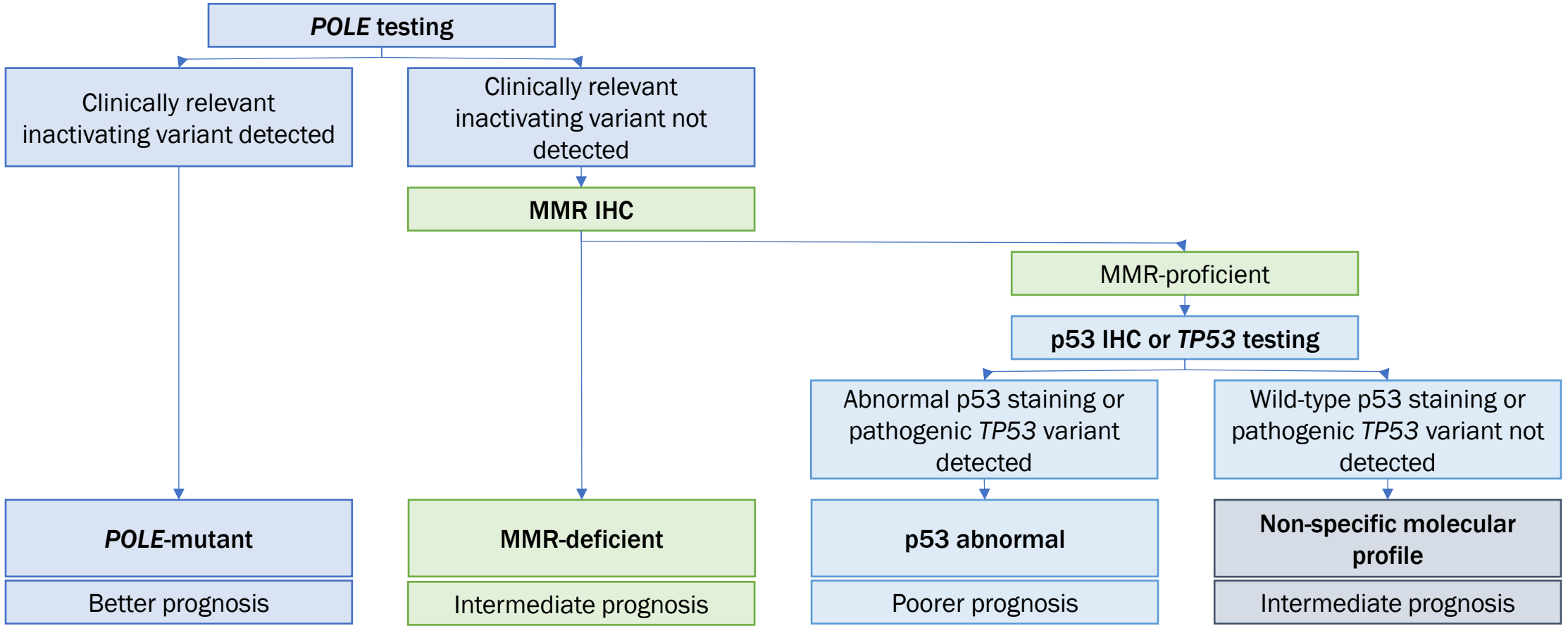

NHS Black Country Pathology Services
NHS Central and South Genomic Medicine Service Alliance
NHS University Hospital Southampton NHS Foundation Trust

POLE testing

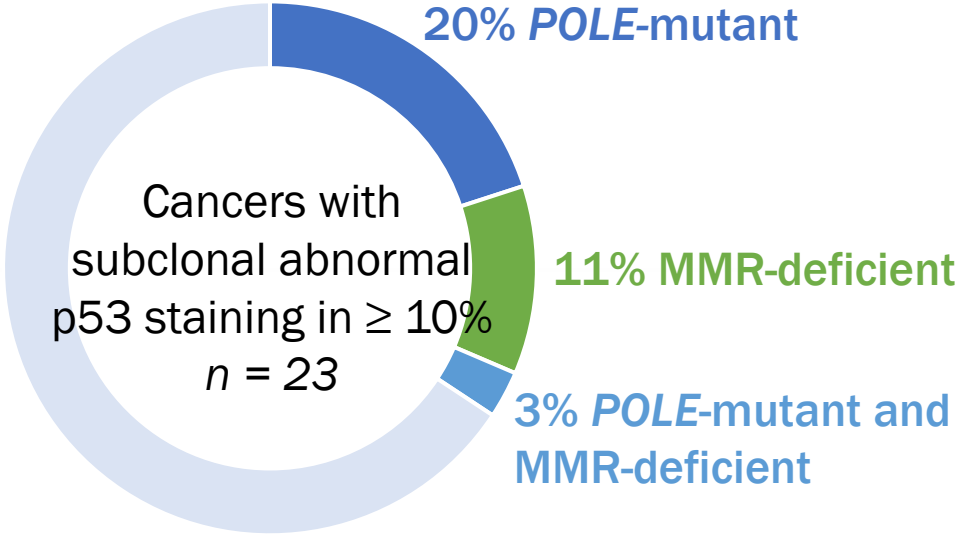

REPORT

REPORT SUMMARY:

Detection of POLE variant, c.857C>G p.(Pro286Arg).

Report interpretation:

[redacted] has endometrial cancer. Molecular testing of the POLE, NTRK1, NTRK2 and NTRK3 genes has been requested to facilitate clinical management. Percentage of neoplastic cells, reported by referring centre, is estimated to be >20%% in the FFPE sections provided (Block Ref: 23HS41941J).

Molecular analysis detected POLE gene [NM_006231.4] pathogenic sequence variant, c.857C>G p.(Pro286Arg). This variant is the most common pathogenic variant found in endometrial cancer (León-Castillo et al., 2020. PMID: 23636398). Somatic POLE proofreading domain pathogenic variants occur in approximately 7-12% of endometrial cancers and are associated with favourable prognosis (Church et al. 2015, PMID: 25505230).

NTRK1, NTRK2 and NTRK3 investigations are ongoing and these results will be reported in due course.

These results are dependent upon the information supplied being correct and complete.

Huvila, J., Thompson, E. F., Vanden Broek, J., Lum, A., Senz, J., Leung, S., ... & Jamieson, A. (2023). Subclonal p53 immunostaining in the diagnosis of endometrial carcinoma molecular subtype. *Histopathology*, *83*(6), 880-890.

Subclonal MMR defects

Clinical history

PATIENT

61 years old, female

SPECIMEN TYPE

Endometrial curettings

CLINICAL DETAILS

PMB. Endometrial polyp. Appearances suspicious for malignancy.

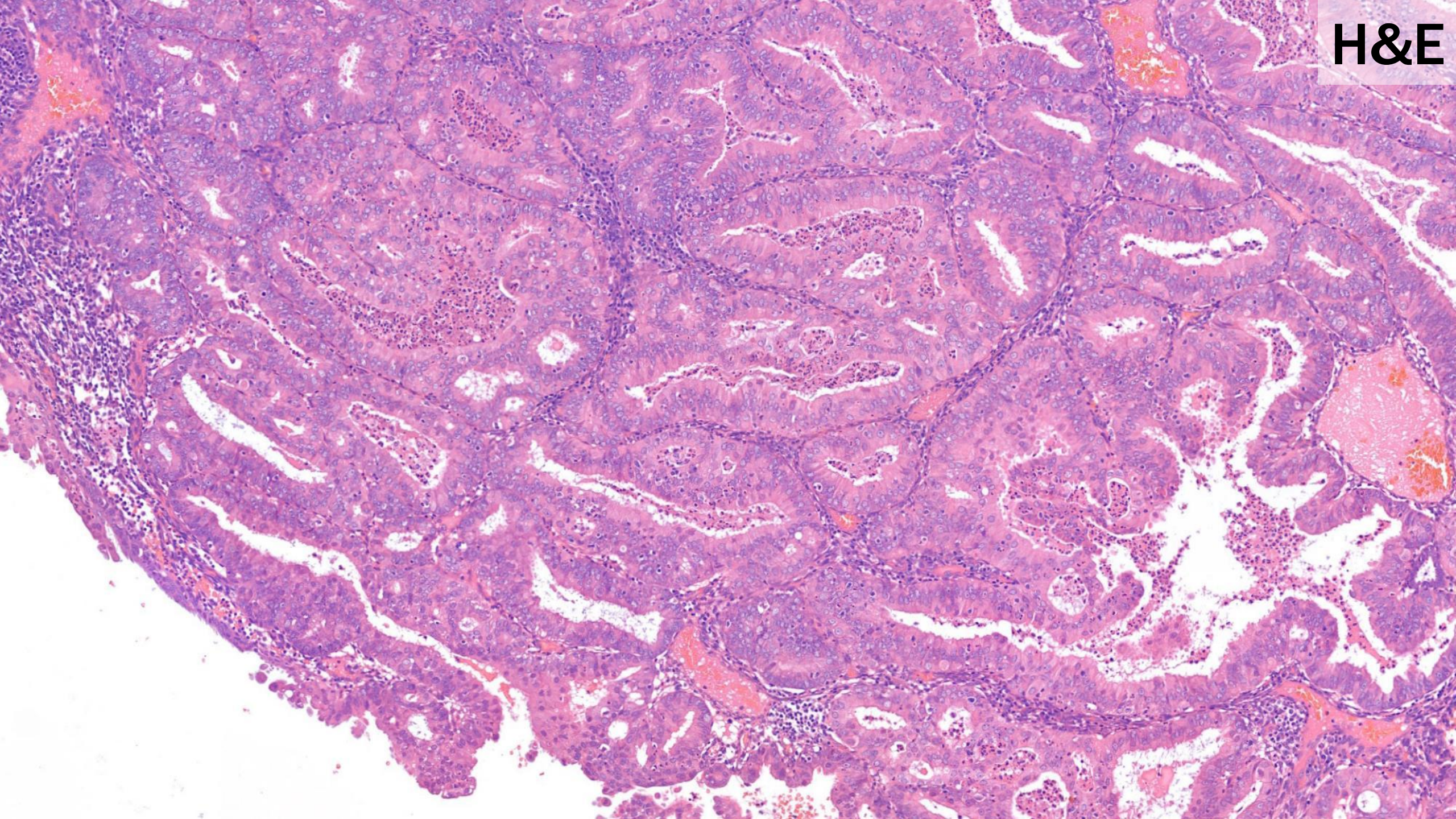
H&E

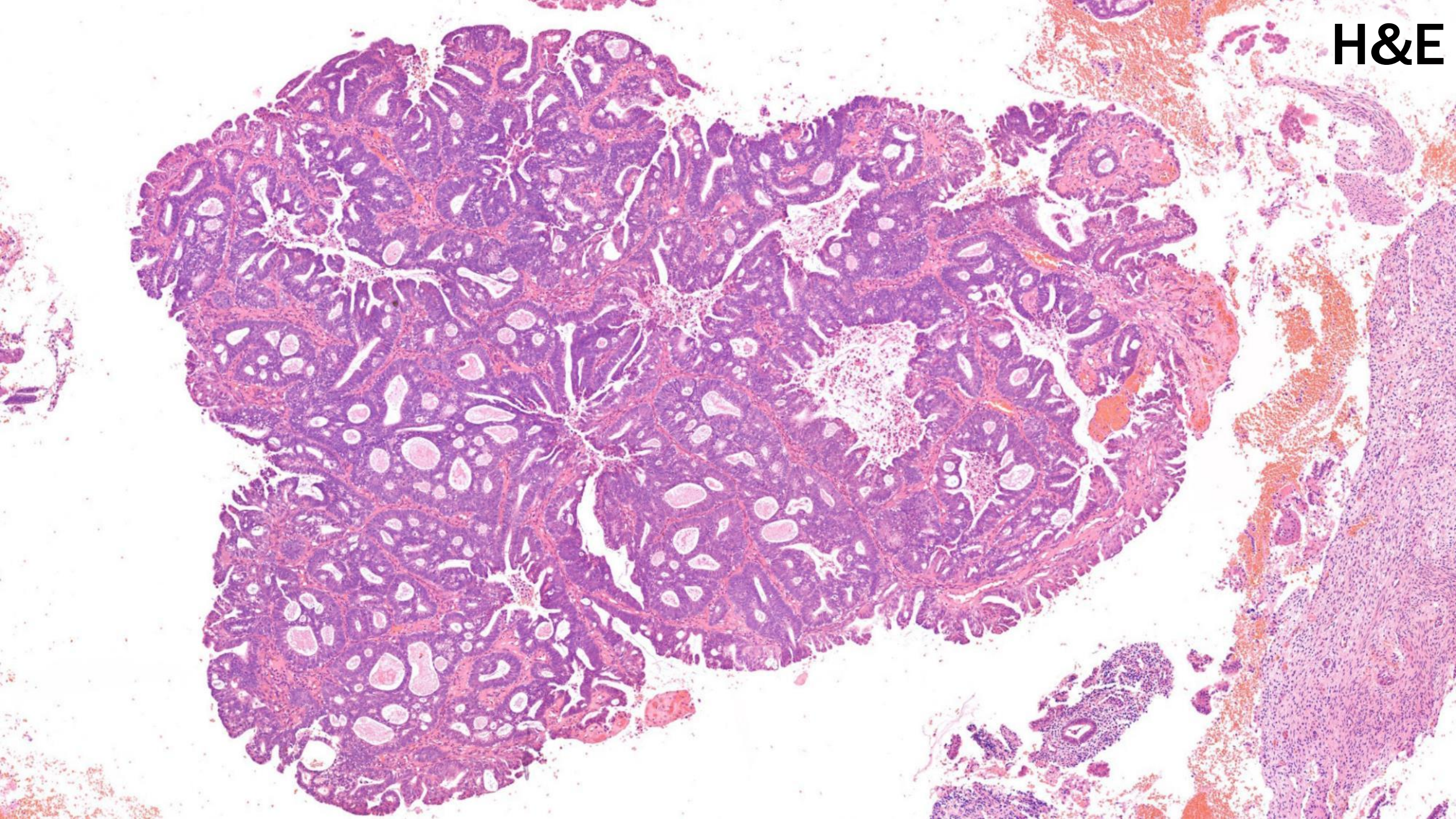
H&E

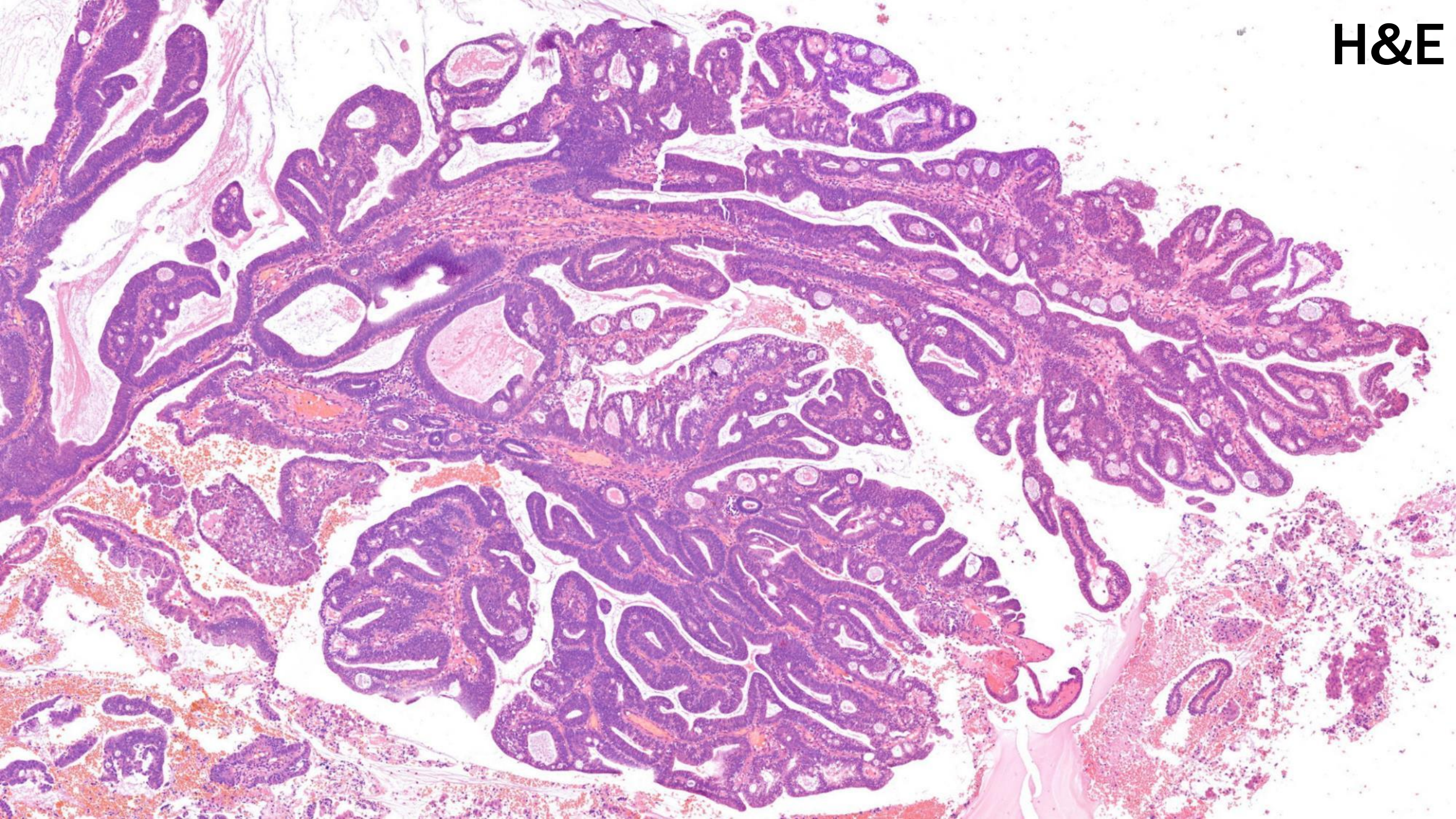
H&E

Diagnosis

DIAGNOSIS

Endometrioid adenocarcinoma, FIGO grade 2 on the basis of the material here (solid components in other blocks)

p53: Wild-type

ER: Positive (Quick score 7/8)

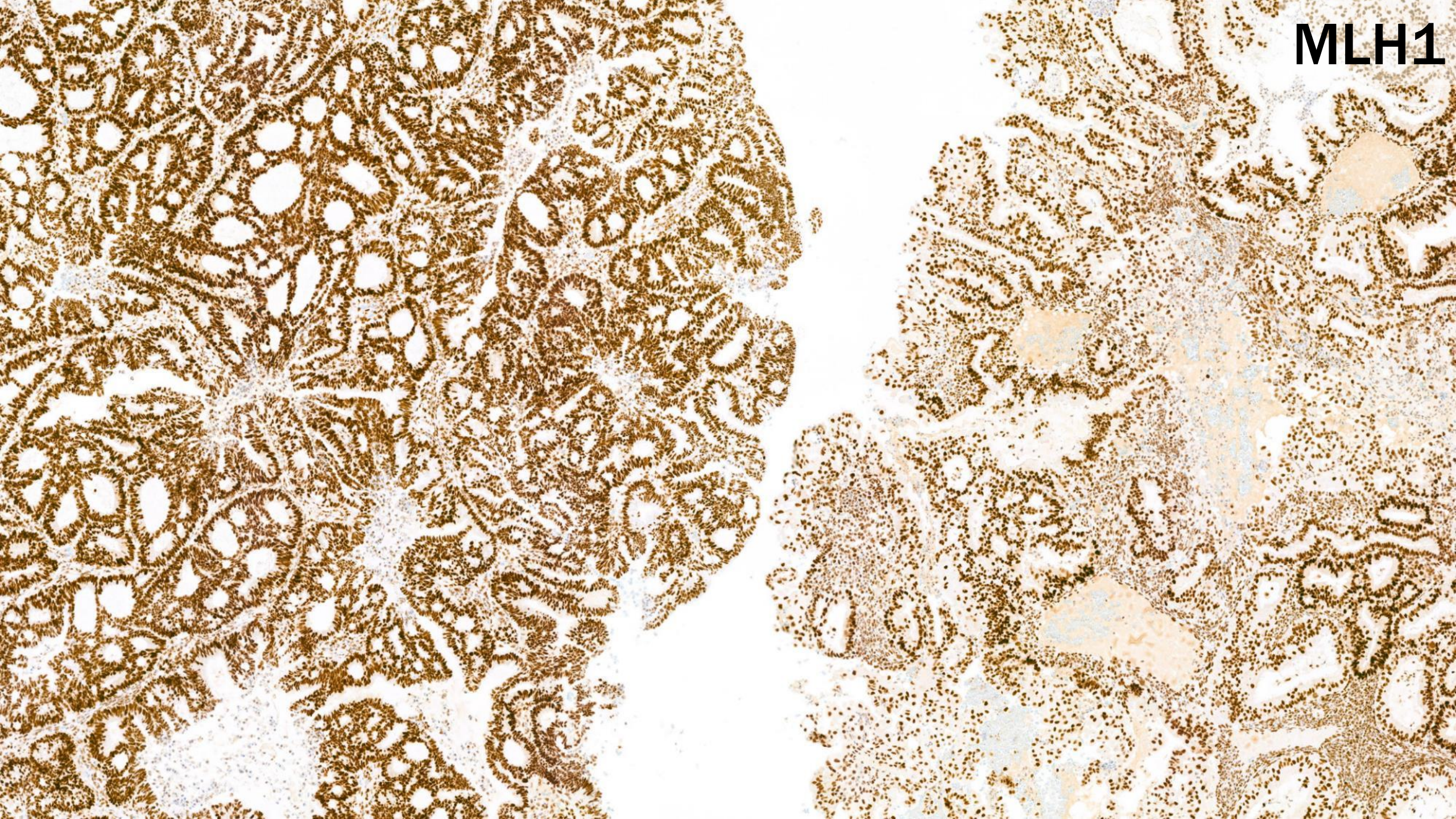
MLH1

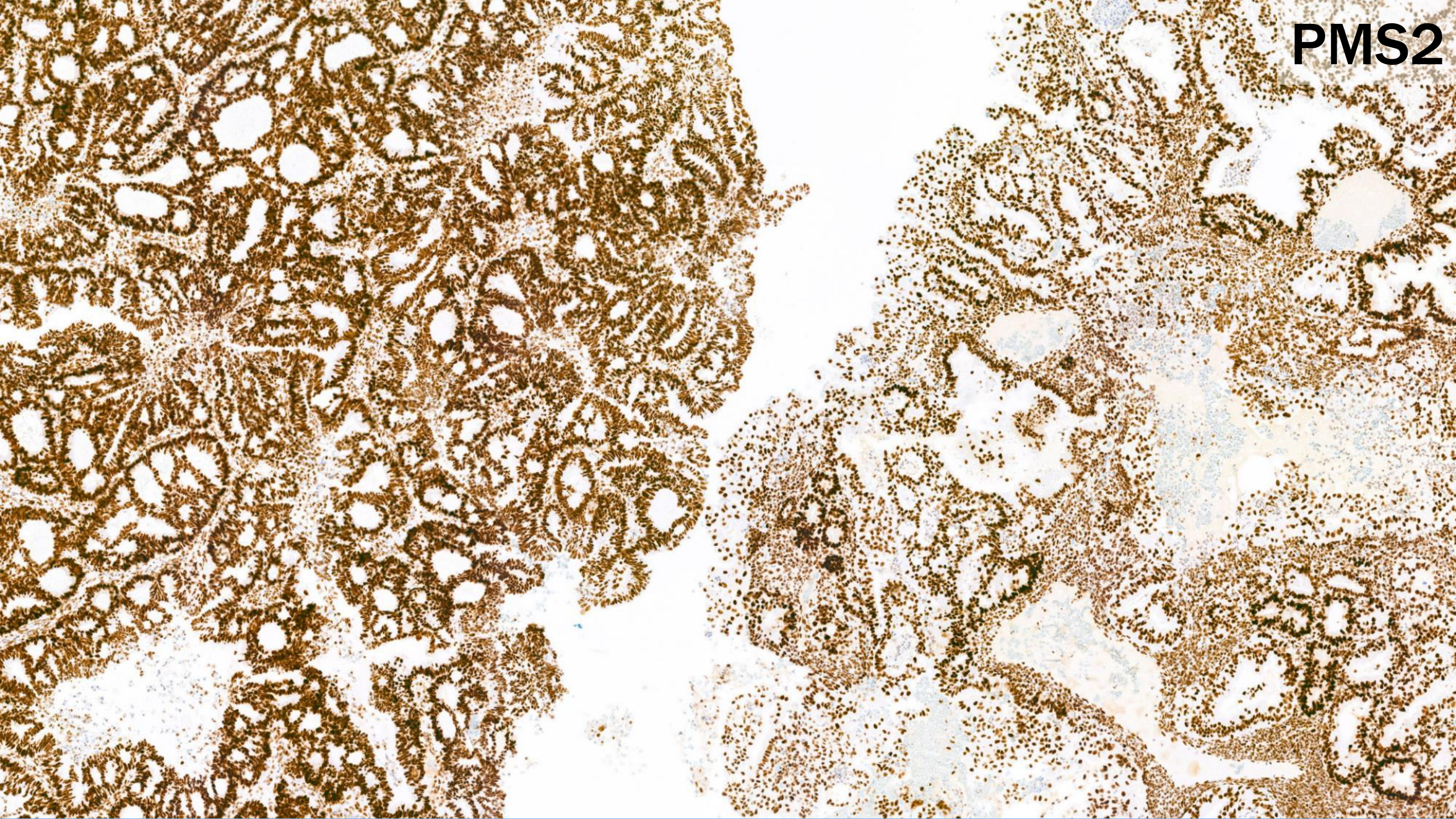
PMS2

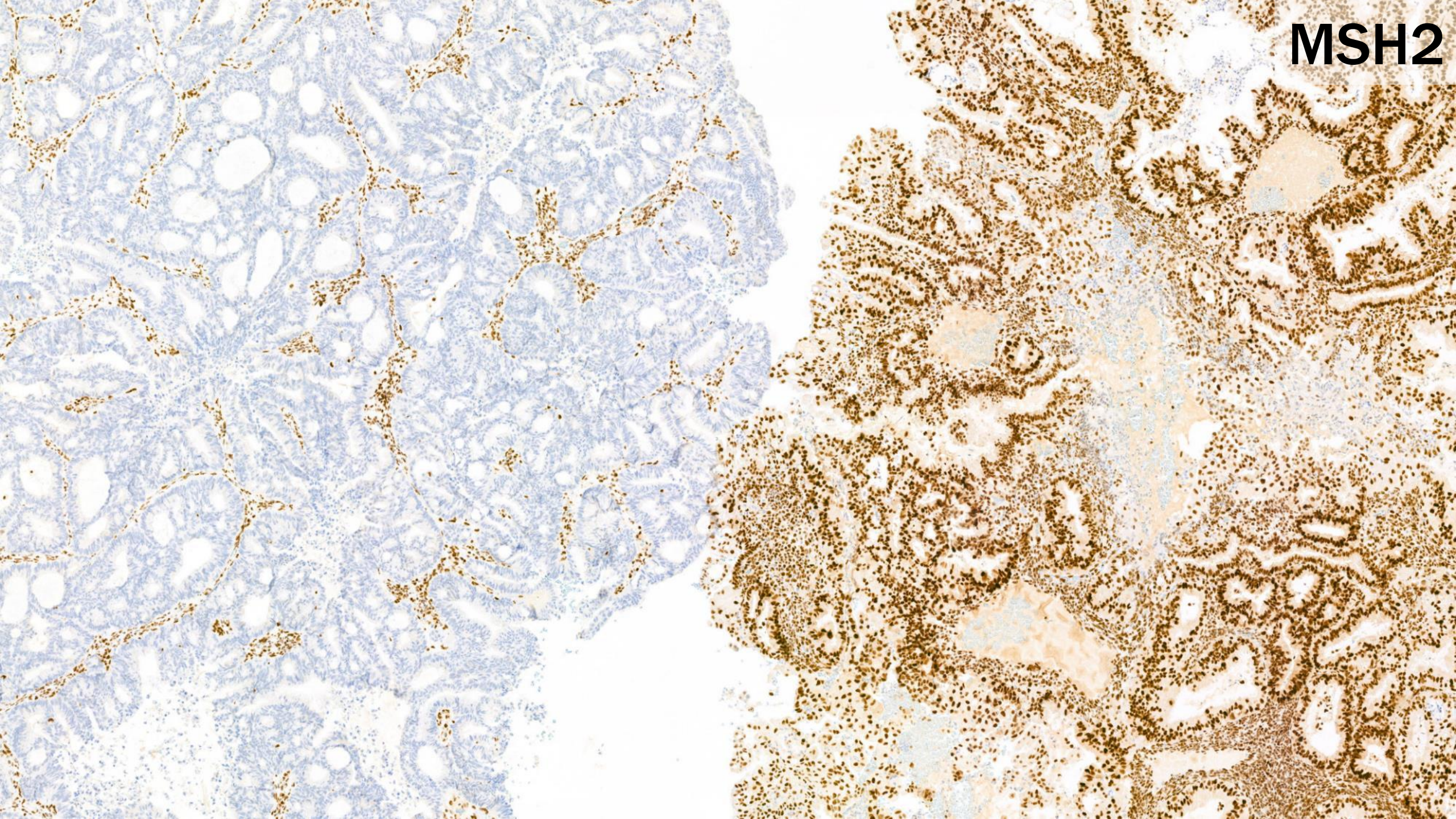
MSH2

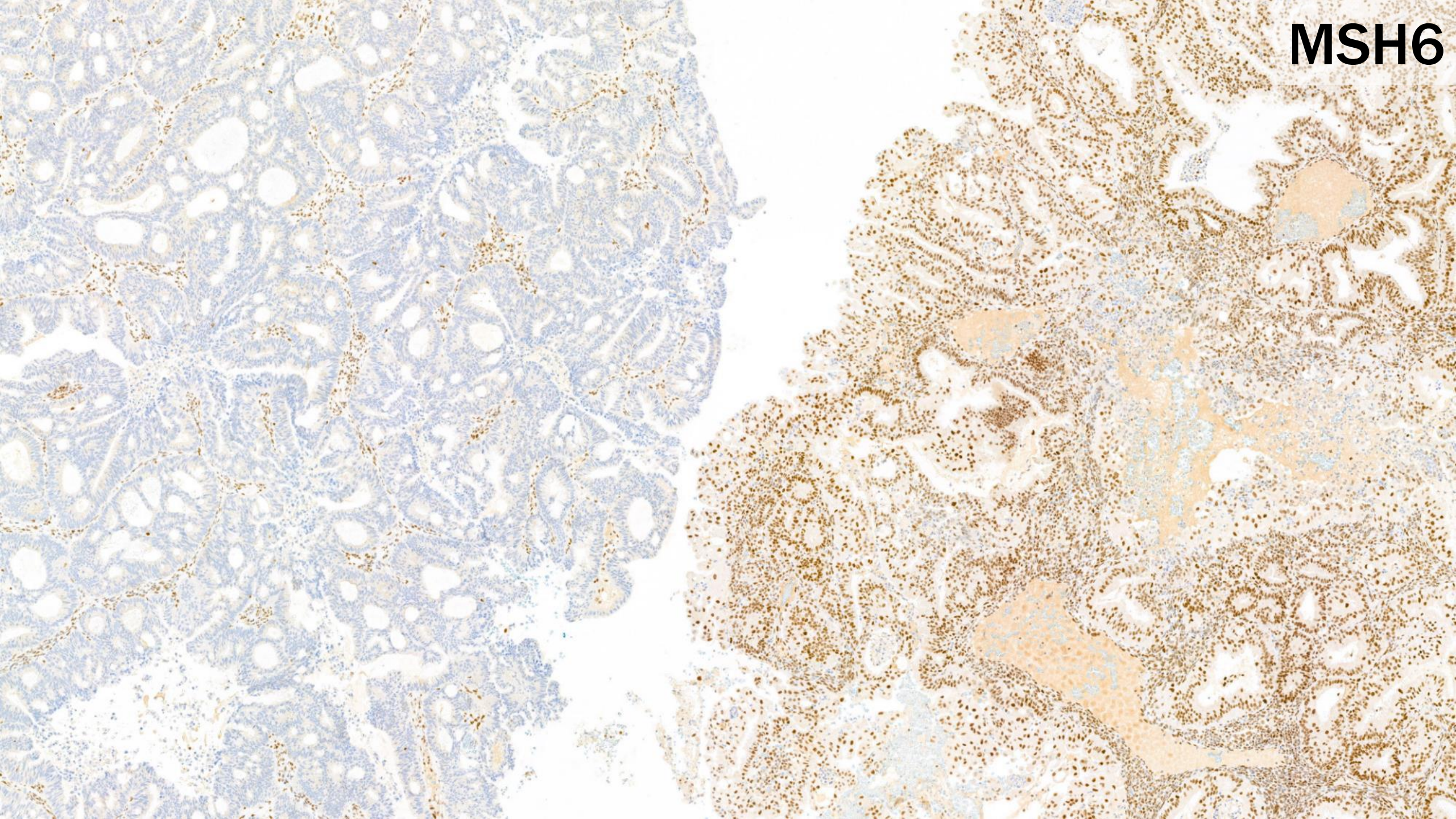
MSH6

Why is MMR status important?

Prognostic

An MMR-defect (in the absence of a clinically relevant *POLE* variant) places the patient in the intermediate risk group

Diagnostic

An MMR defect – depending on the pattern of loss – can be an indicator of underlying Lynch syndrome

Predictive

In the UK, an MMR defect allows patients with metastatic disease to access immune checkpoint inhibitors *without* chemotherapy

Do subclonal MMR defects have the same prognostic implications?

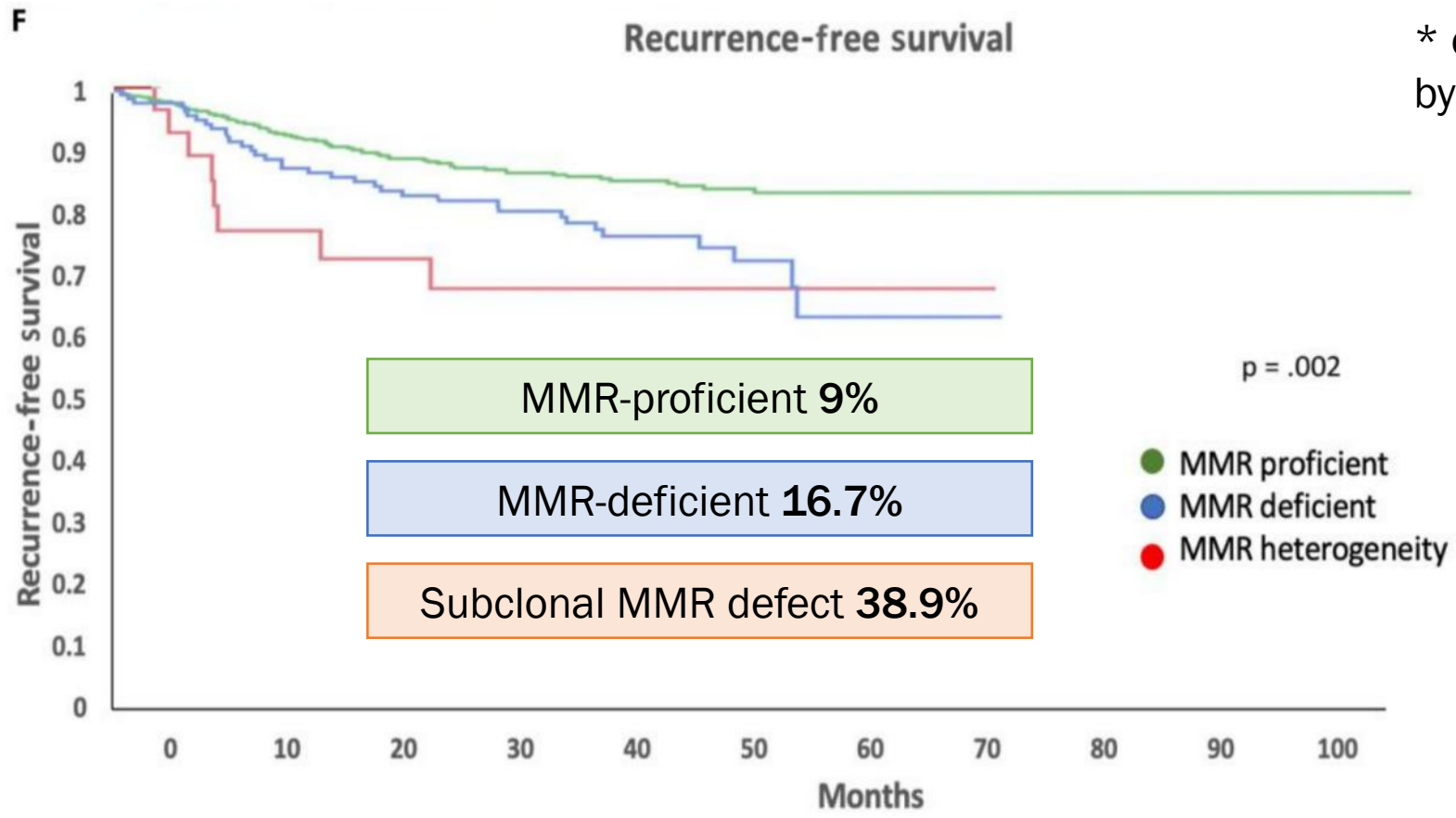

* did not stratify by *POLE* and p53

Riedinger, C. J., Esnakula, A., Haight, P. J., Suarez, A. A., Chen, W., Gillespie, J., ... & Cosgrove, C. M. (2024). Characterization of mismatch-repair/microsatellite instability-discordant endometrial cancers. *Cancer*, *130*(3), 385-399.

Do subclonal MMR defects mean the same in terms of Lynch syndrome?

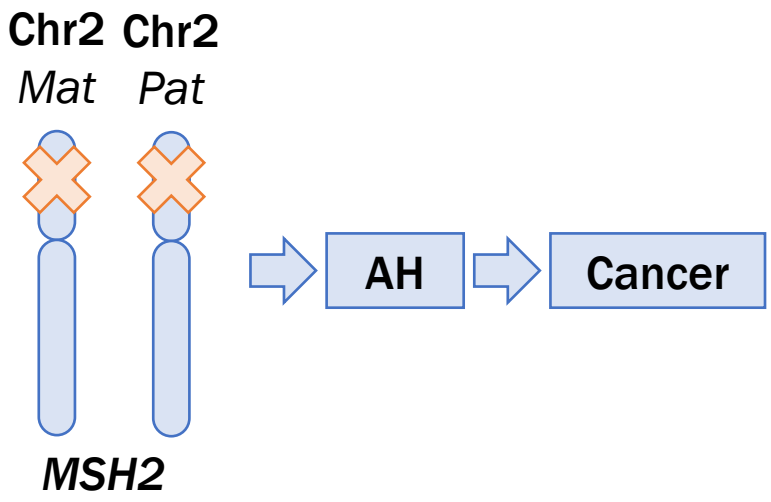

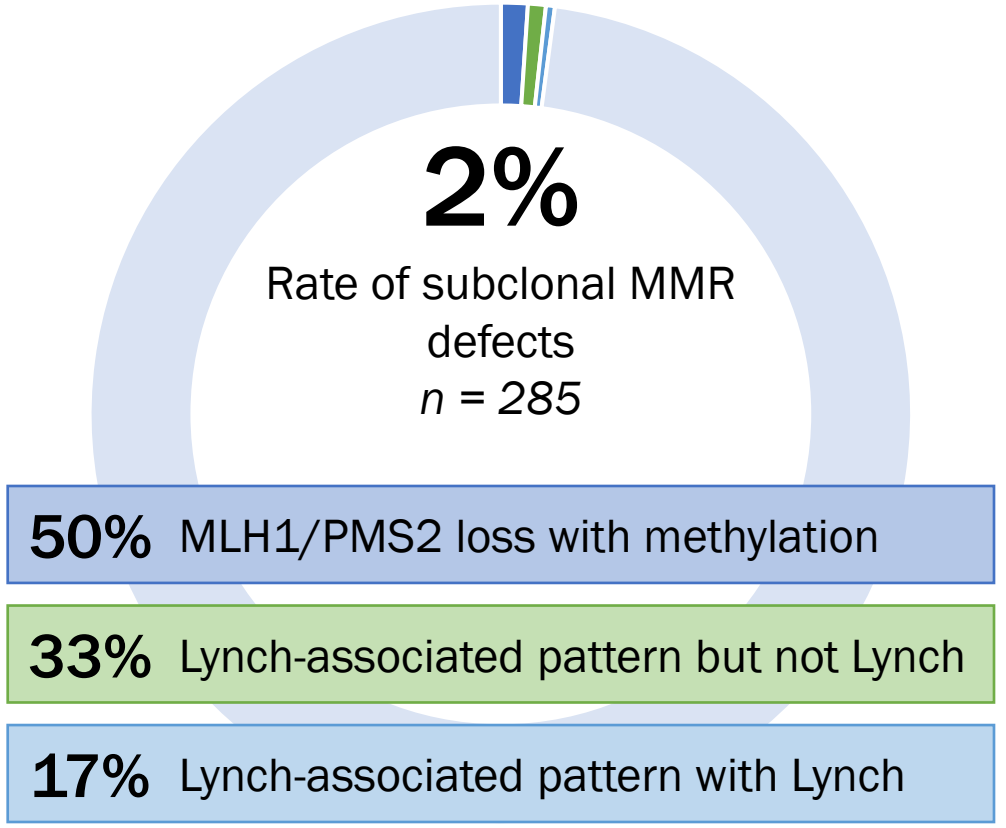

Mendoza, R. P., Wang, P., Schulte, J. J., Tjota, M. Y., Jani, I., Martinez, A. C., ... & Bennett, J. A. (2023). Endometrial carcinomas with subclonal loss of mismatch repair proteins: a clinicopathologic and genomic study. *The American Journal of Surgical Pathology*, *47*(5), 589-598.

How could a patient with Lynch syndrome have a subclonal MMR defect?

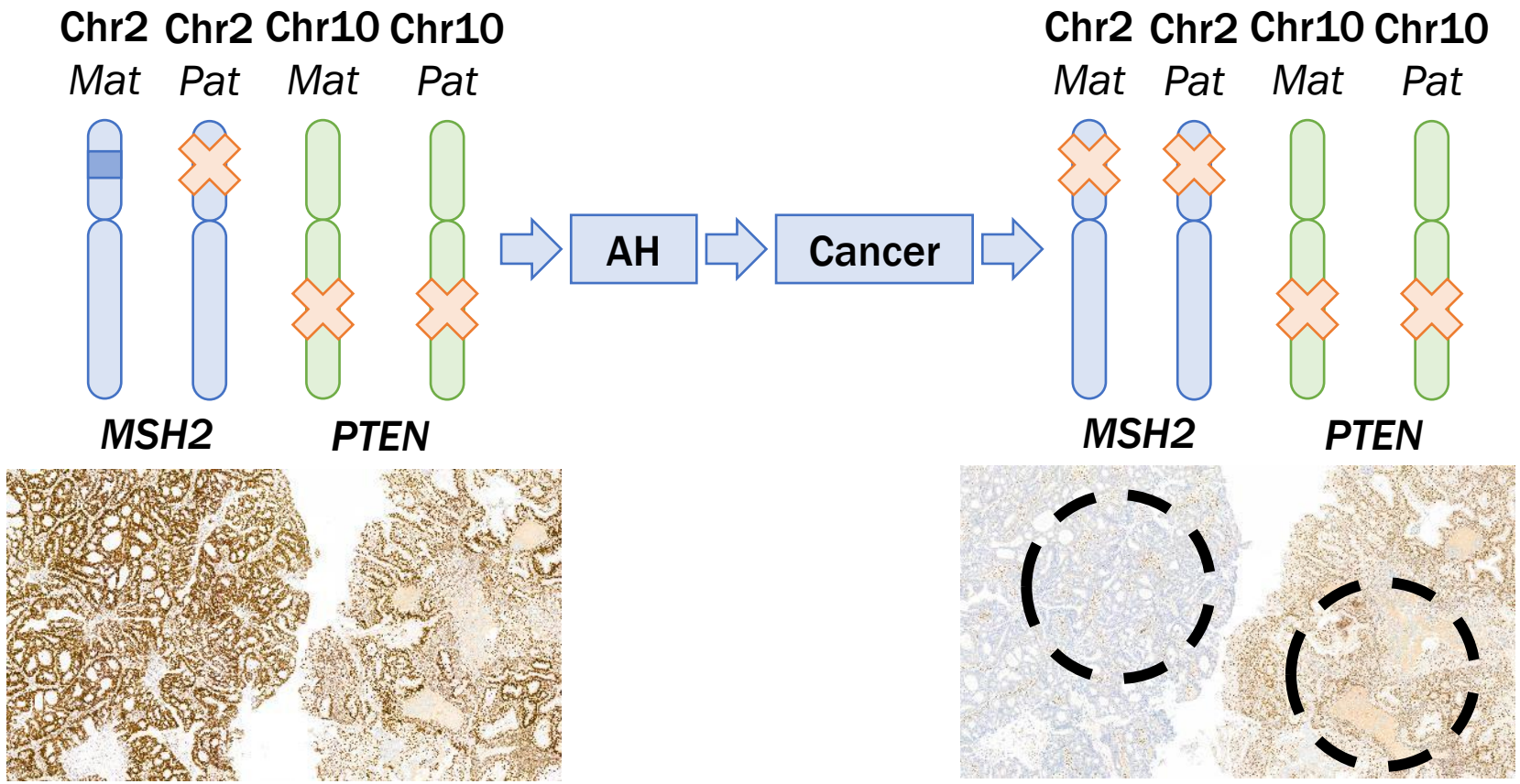

Do subclonal MMR defects mean the same in terms of immune checkpoint inhibitors?

JEMPERLI is indicated as monotherapy for the treatment of adult patients with mismatch repair deficient (dMMR)/ microsatellite instability-high (MSI-H) recurrent or advanced EC that has progressed on or following prior treatment with a platinum-containing regimen.

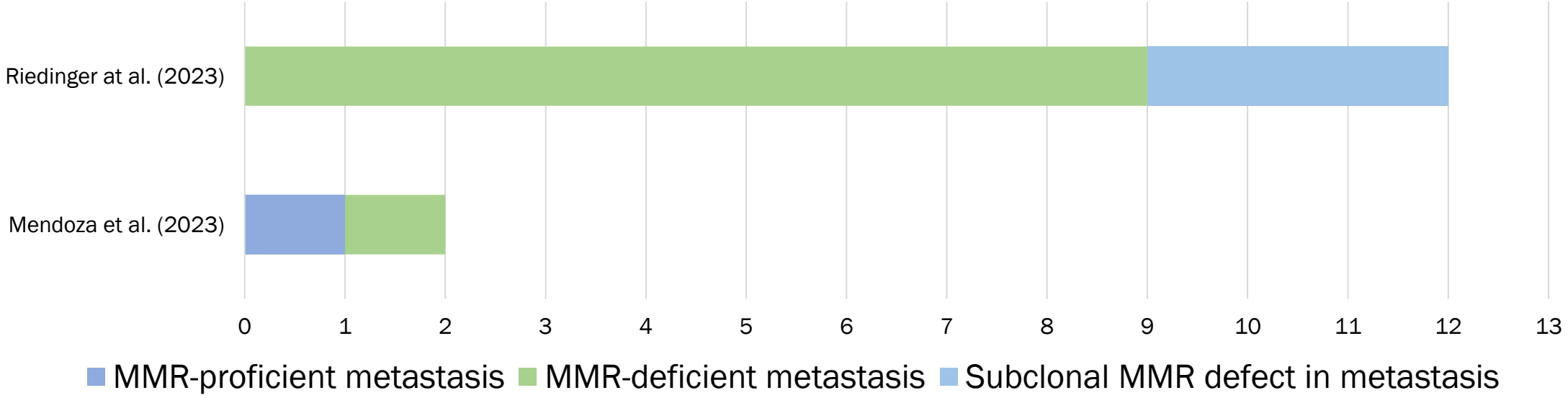

JEMPERLI, G. *500 mg concentrate for solution for infusion: summary of product characteristics. 2020.*
Mendoza, R. P., Wang, P., Schulte, J. J., Tjota, M. Y., Jani, I., Martinez, A. C., ... & Bennett, J. A. (2023). Endometrial carcinomas with subclonal loss of mismatch repair proteins: a clinicopathologic and genomic study. *The American Journal of Surgical Pathology*, *47*(5), 589-598.
Riedinger, C. J., Esnakula, A., Haight, P. J., Suarez, A. A., Chen, W., Gillespie, J., ... & Cosgrove, C. M. (2024). Characterization of mismatch-repair/microsatellite instability-discordant endometrial cancers. *Cancer*, *130*(3), 385-399.

Does the 10% rule from p53 also apply to MMR?

Subclonal expression may occur in a minority of cases. Subclonal expression is defined as a focal loss of expression; in order to identify this and distinguish it from variable expression as a result of a fixation artefact, normal staining must be seen in the internal control in the area showing loss of expression in tumour cells. An arbitrary cut-off of 10% is suggested to avoid reporting this pattern in cases where it is extremely focal and of unlikely clinical significance.

Singh, N., Wong, R., Tchrakian, N., Allen, S. G., Clarke, B., & Gilks, C. B. (2020). Interpretation and reporting terminology for mismatch repair protein immunohistochemistry in endometrial cancer. *BAGP Guidance Document: MMR Immunohistochemistry interpretation and terminology*.

How do I report these cases?

DIAGNOSIS
The tumour cells show SUBCLONAL loss of nuclear expression of the mismatch repair proteins MSH2 and MSH6. There is preserved nuclear staining for MLH1 and PMS2. There is immunohistochemical evidence of a mismatch repair deficiency. This is regarded as an MMR-deficient (dMMR) neoplasm which is expected to show microsatellite stability (MSI).

Interpretation is challenging:
1. It seems unlikely that this patient has Lynch syndrome in view of the subclonal nature of the MMR defect. However, the significance of subclonal MMR defects from the perspective of Lynch syndrome is not well understood. **I therefore recommend referral to Clinical Genetics Services for completeness.**
2. Whether this tumour should be considered MMR-deficient for the purposes of prescription of immune checkpoint inhibitors is unclear, since the tumour contains both MMR-deficient and MMR-proficient components. **If this patient later develops metastatic or recurrent disease, repeat MMR immunohistochemistry on a metastasis/recurrence is strongly advised, with treatment being determined by the MMR status of the metastasis/recurrence.**

Conclusion

I've got a subclonal pattern – what should I do?!

p53
Could this be a mixed carcinoma?
***POLE* and MMR testing is essential** *POLE* variant or MMR defect trumps p53
≥ 10% abnormal p53 Manage as p53 abnormal
< 10% abnormal p53 Manage as p53 wild-type
Repeat on resection if subclonal pattern seen on biopsy

MMR
Be sure it isn't technical artefact 10% rule has been proposed
Prognostic significance uncertain May indicate more aggressive disease
Lynch syndrome is possible but unlikely Work up as per complete loss
Methylation testing may give false negatives Only likely to be present in the deficient cells
Immune checkpoint inhibitor response uncertain I suggest repeating on recurrence and using the MMR status of the recurrence to guide treatment

NHS
Black Country Pathology Services

NHS
Central and South
Genomic Medicine Service Alliance

NHS
University Hospital Southampton
NHS Foundation Trust

Thank you