The British Association of Gynaecological Pathologists

Lecturer - Dr Nataliya Piletska

Consultant Pathologist based at Maidstone Hospital with a particular interest in gynae pathology, in addition to skin pathology, cytology and post mortems.



The British Association of Gynaecological Pathologists

Mock Exam

- Dr Nataliya Piletska
- Maidstone and Tunbridge Wells NHS Trust
- 24 September 2025

The British Association of
Gynaecological Pathologists

Mock Exam

Short Cases 1 - 10

Short case 1

63-year-old woman

Hysterectomy, BSO and lymph node dissection

Ovarian mass (serous borderline tumour)

Specimen: Para-aortic lymph node

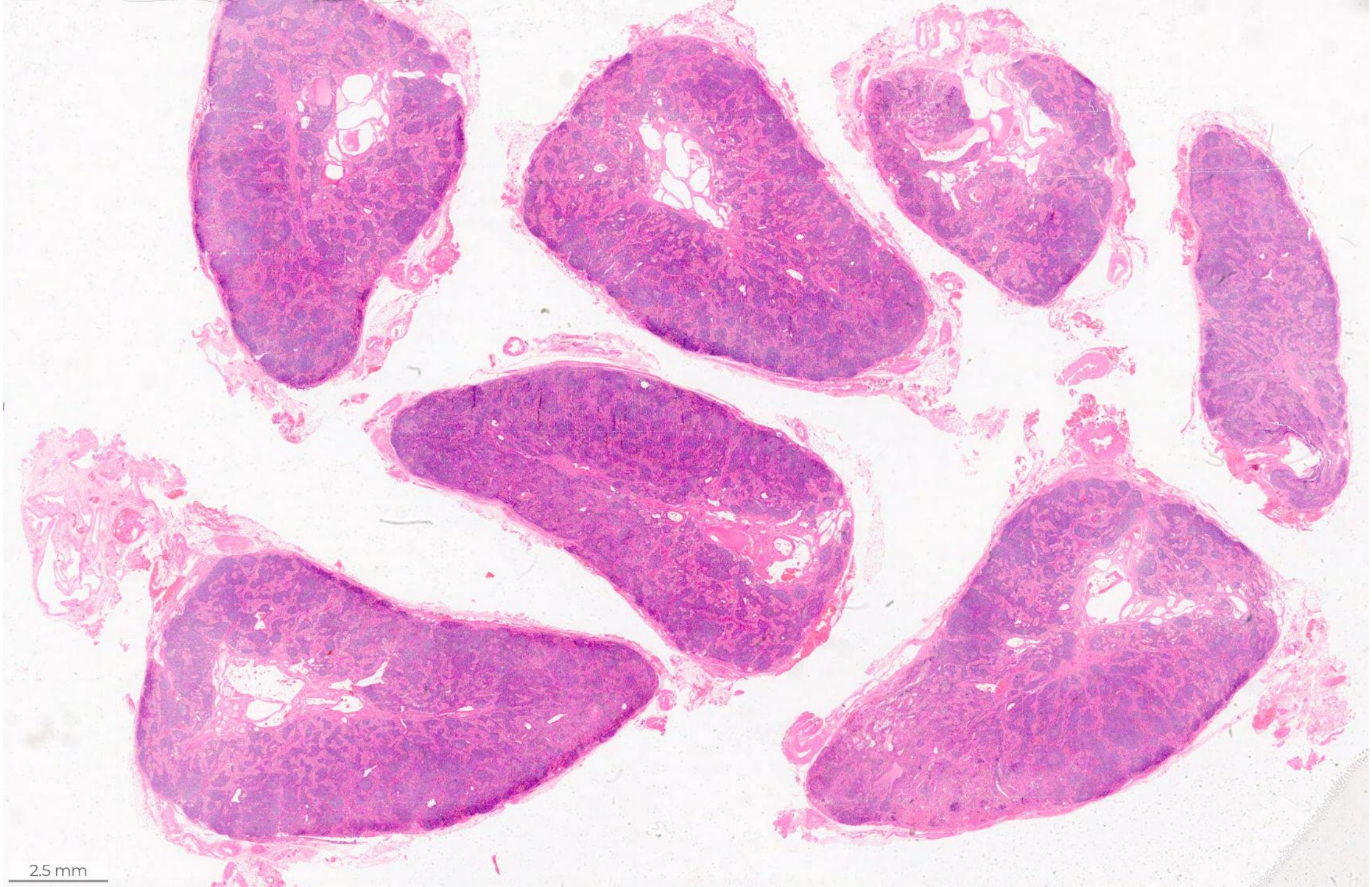
2.5 mm

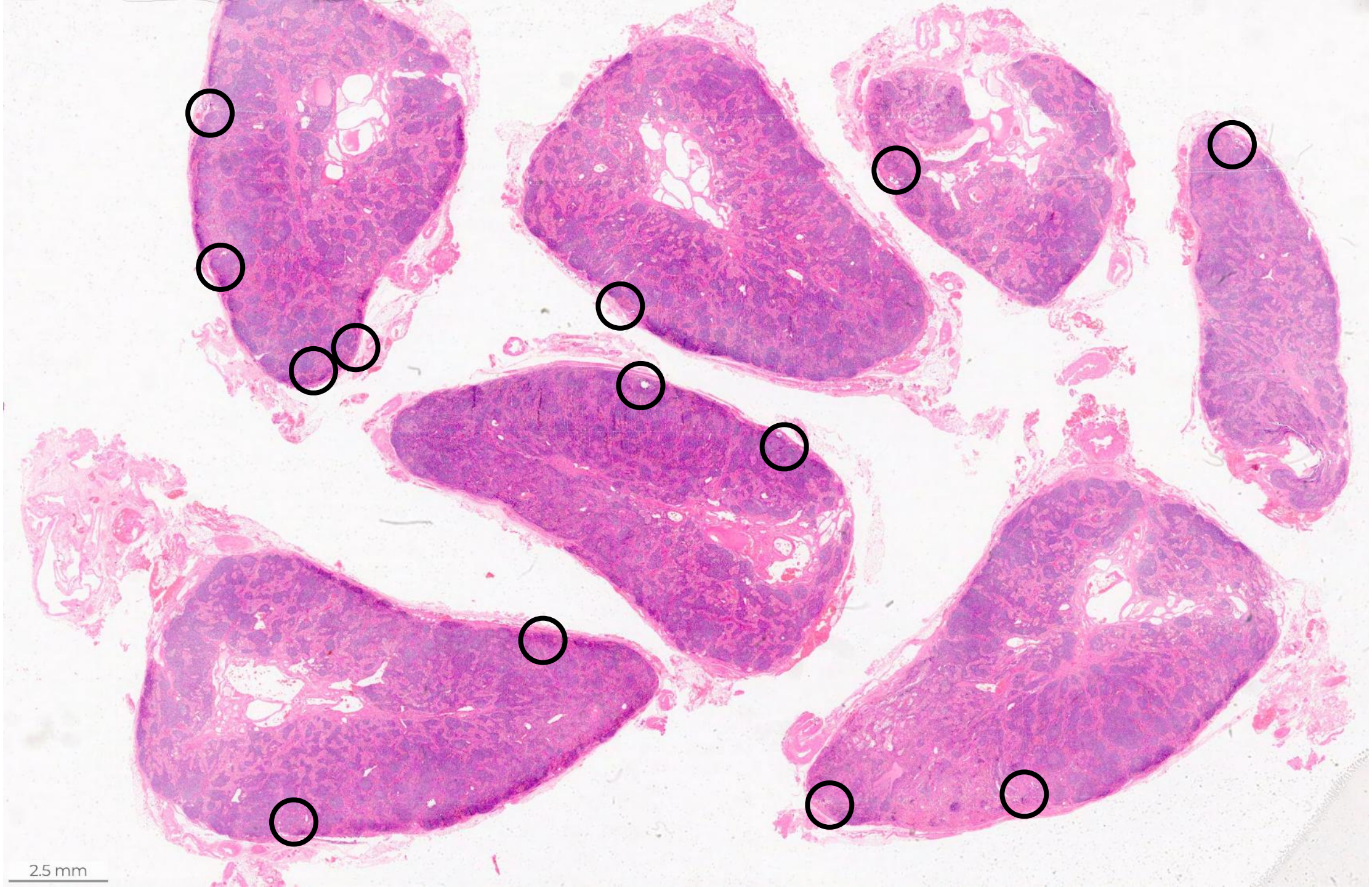
2.5 mm

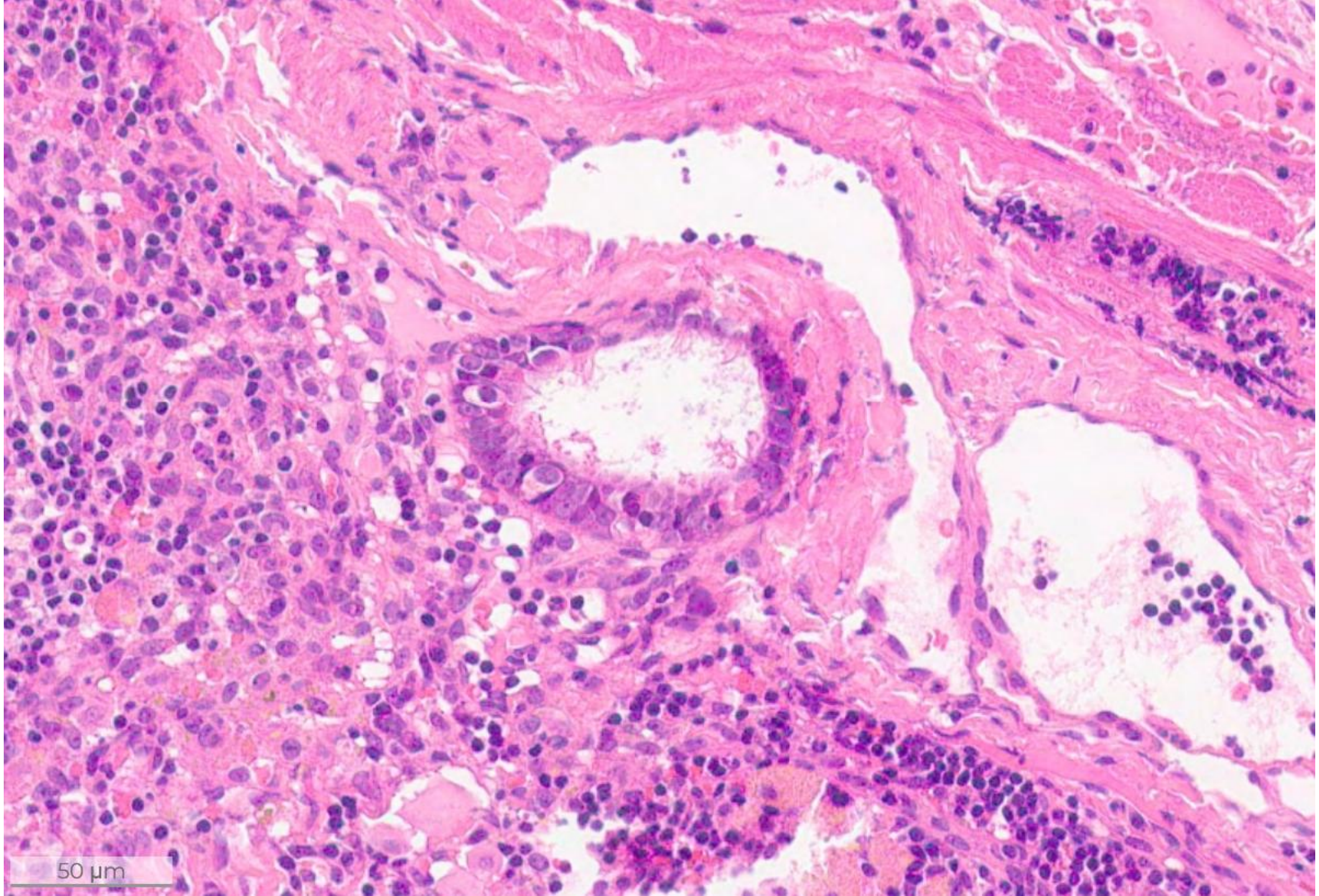
50 µm

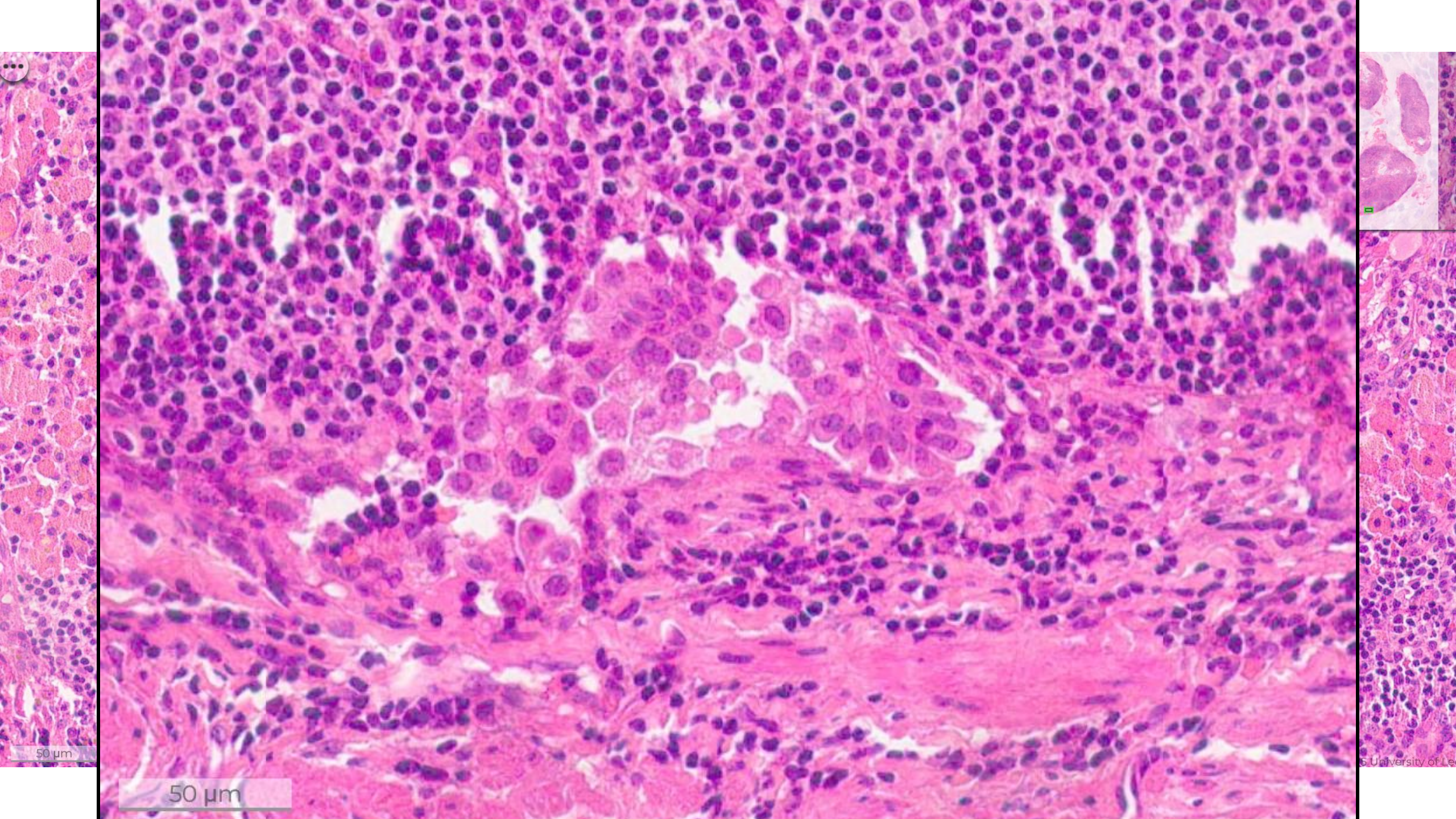
50 µm

Short case 1: Serous borderline tumour involving a lymph node

- Non-invasive, low-grade, proliferative serous epithelial neoplasm
- Presents with symptoms of an ovarian mass
- Wide age range, median = 50 years
- Generally > 5 cm. Approximately 1/3 are bilateral

Sh
inv

- Hie
  the
- Str
- Mi
  wit

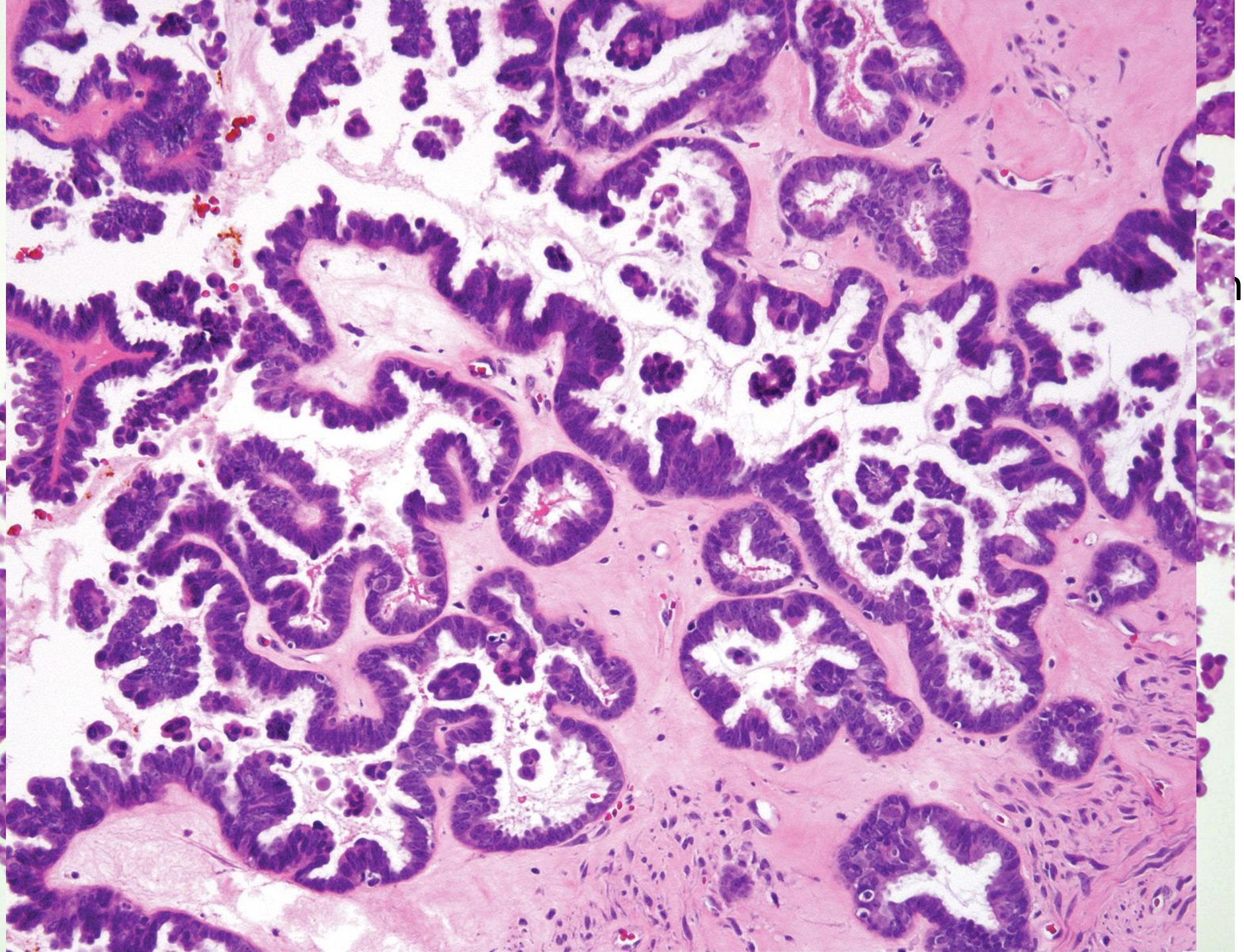

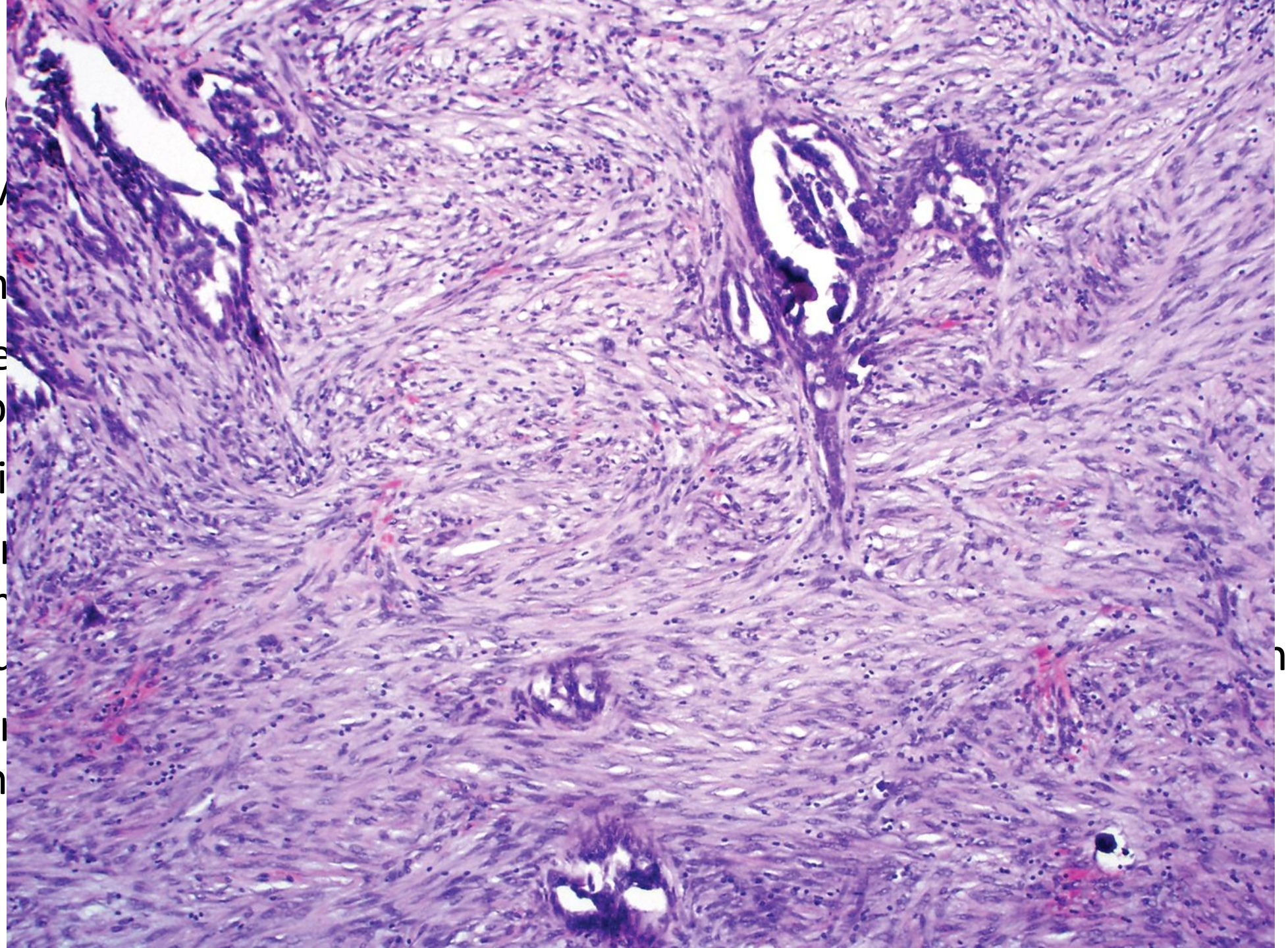

Sh
inv

- Im
- De
  ap
- If i
- Ly
  sin
  clu nts
- Ly
  en

Short case 1: Borderline serous tumour involving a lymph node

MarkM	Features
1.5 or 1	Fails to diagnose
2	Does not commit to a diagnosis, inadequate morphological description
2.5	Adequate description with confident diagnosis of BST involvement of LN but no additional information
3	Some additional information, as mentioned below:
3.5	Good description, identifies endosalpingiosis and borderline serous involvement of LN (which often coexist). Mention good prognosis (LN involvement generally considered of little / no clinical significance)

Short case 2

27-year-old woman

Androgen insensitivity syndrome with bilateral groin lesions

Specimen: Left groin lesion

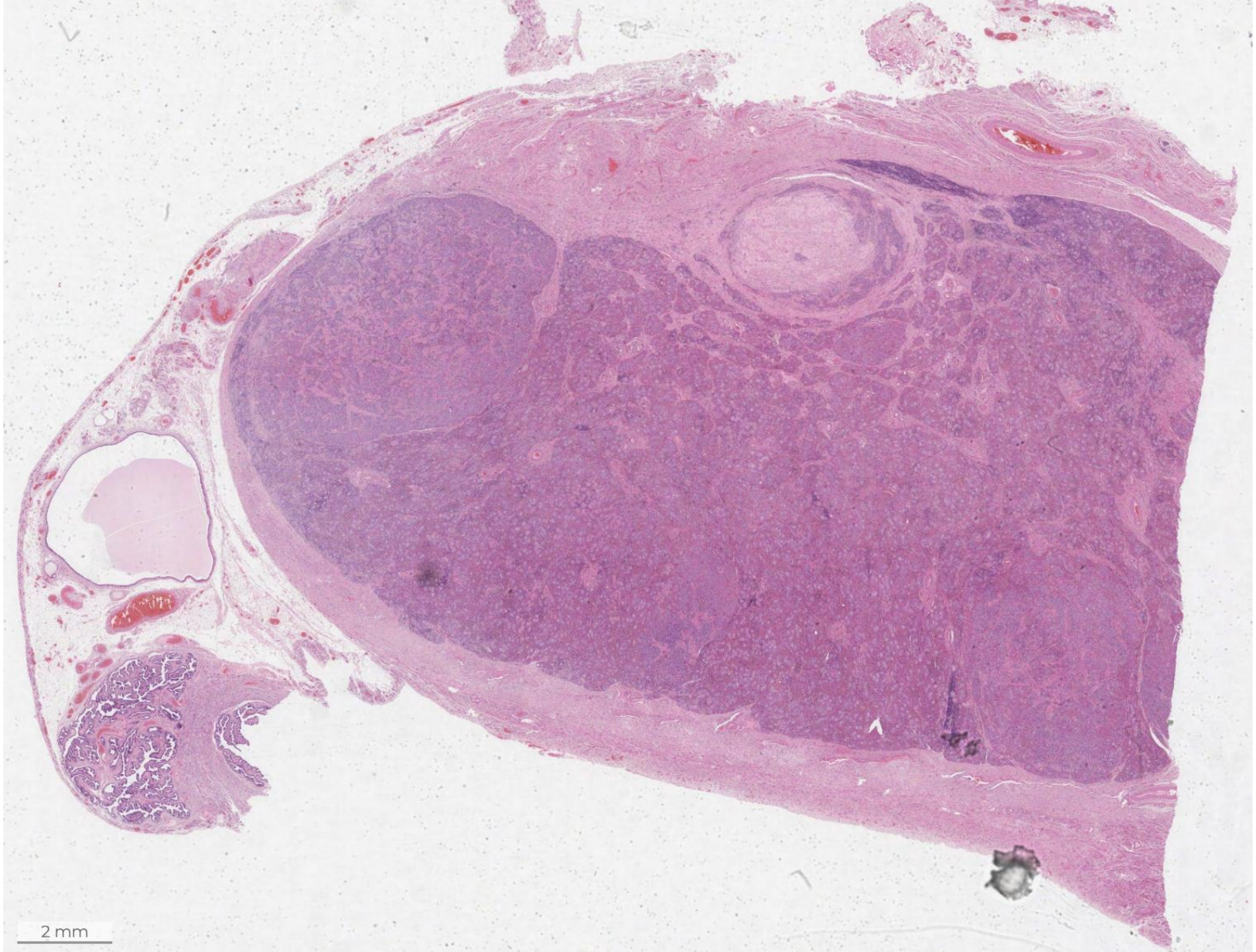
2 mm

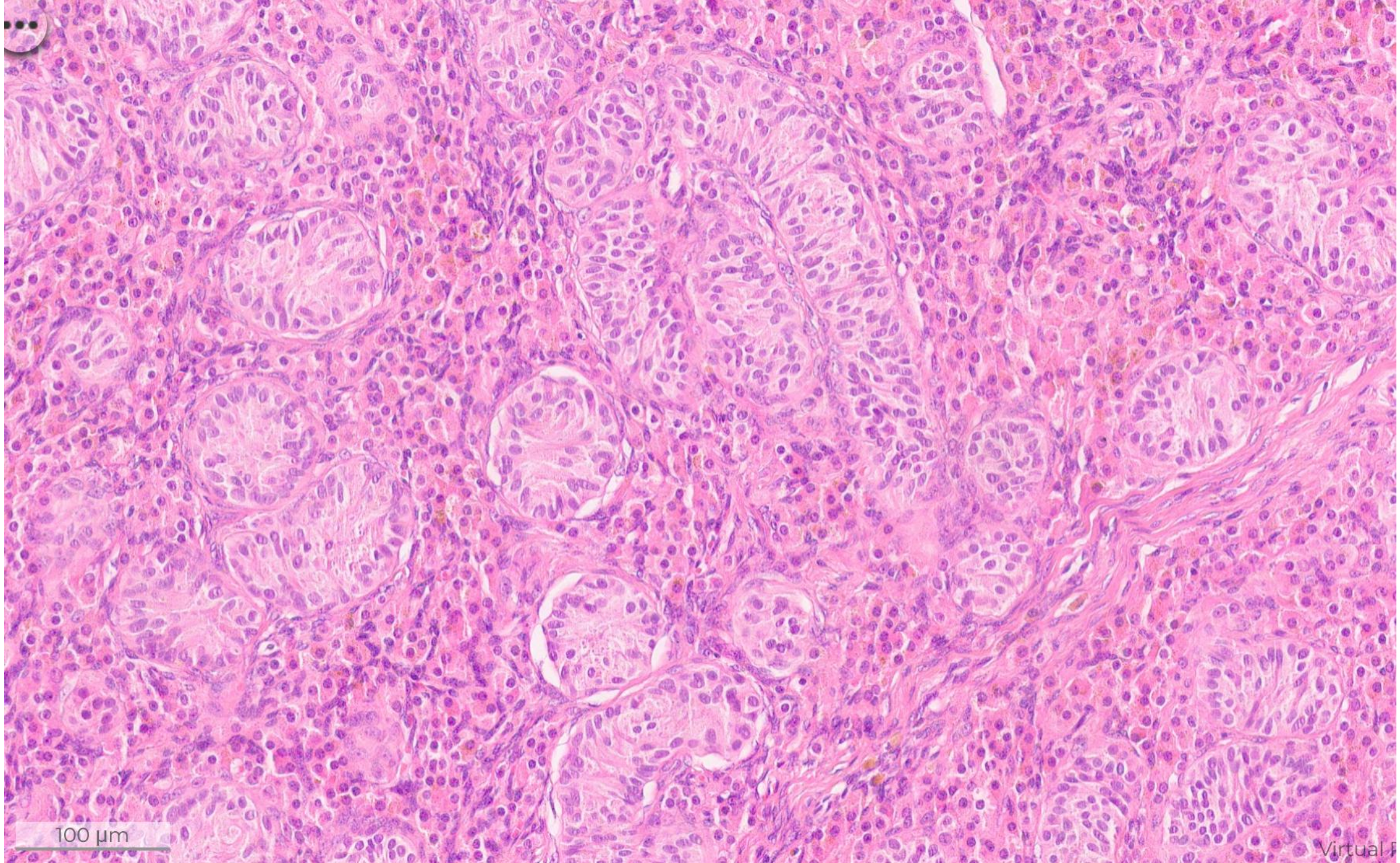
100 µm

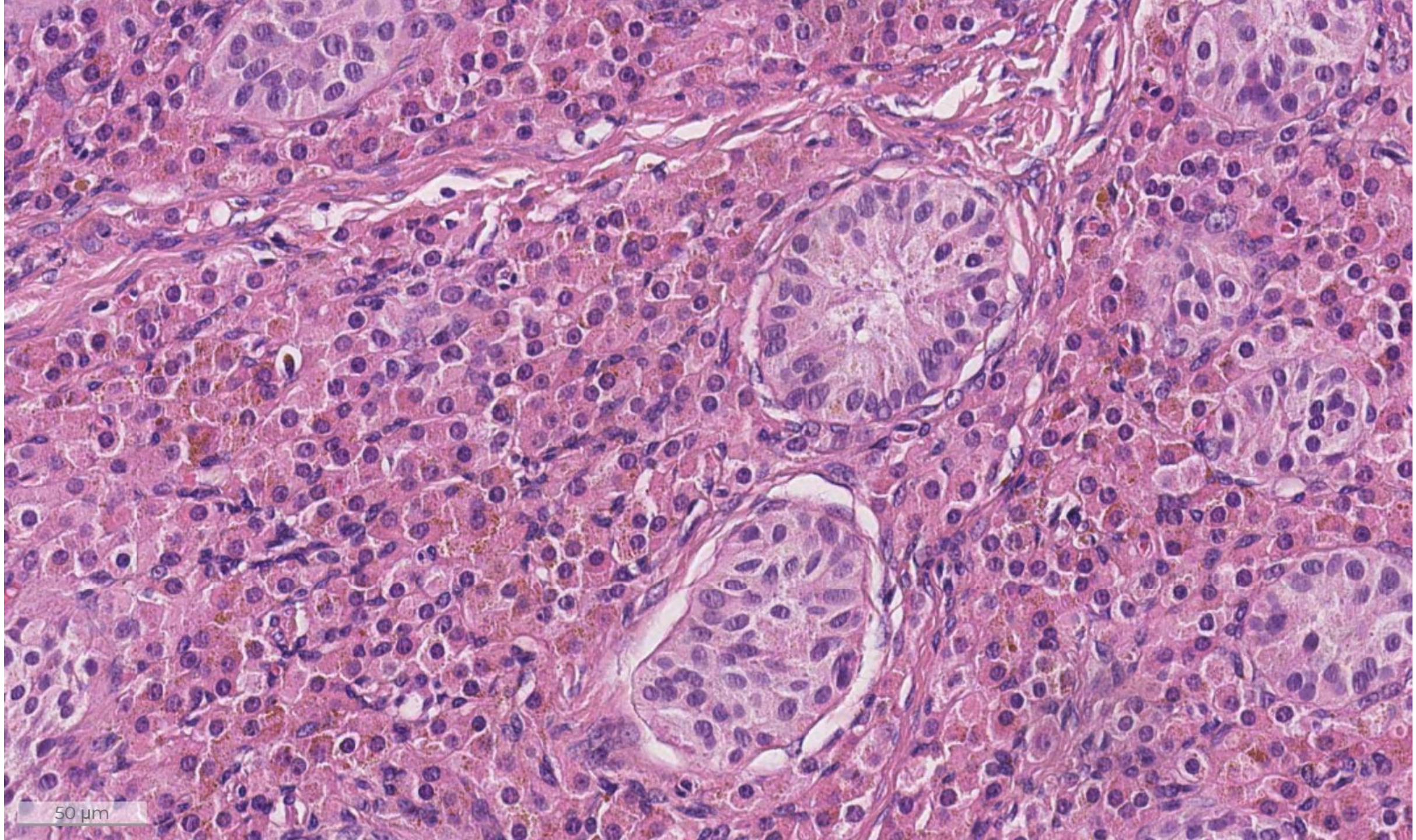
50 µm

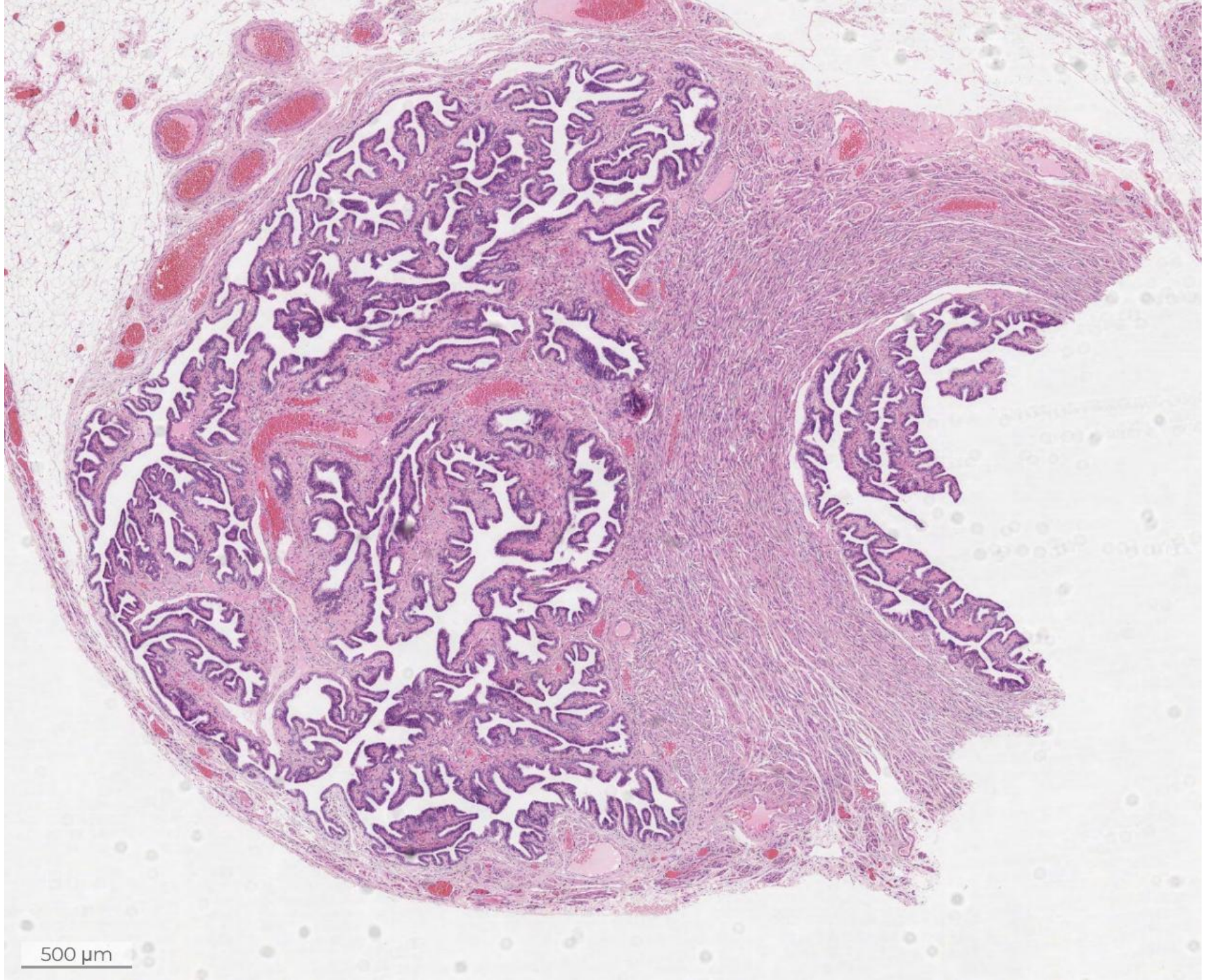
500 µm

Short case 2: Well-differentiated Sertoli Leydig cell tumour

- <0.5% of ovarian neoplasms. About 97% are unilateral
- Presentation may involve hormonal manifestations (40-60% androgenic, occasional oestrogenic) or symptoms related to presence of ovarian mass
- Wide age range of 1-84 years (mean: 25 years)
- Subdivided into well/moderately/poorly differentiated forms based on degree of tubular differentiation of Sertoli cell component and quantity of primitive gonadal stroma. Leydig cells decrease with increasing grade
- Moderately to poorly differentiated forms most common (DICER1 and FOXL2 mutations reported only in these)

Short case 2: Well-differentiated Sertoli Leydig cell tumour

- Solid with/without cystic areas, fleshy and pale yellow/pink/grey
- 2 – 35 cm (mean: 12 – 14 cm)

- Well-differentiated SLCTs = Sertoli cells in open / closed tubules without significant nuclear atypia or mitotic activity. Fibrous stroma contains Leydig cells in clusters, cords, and singly. Cells may be vacuolated, contain lipofuscin, and have Reinke crystals
- Survival rate = almost 100%

Short case 2: Well-differentiated Sertoli Leydig cell tumour

Mark	Features
1.5 or 1	Fails to diagnose
2	Does not commit to a diagnosis, inadequate morphological description
2.5	Adequate description with confident diagnosis but no additional information
3	Some additional information, as mentioned below:
3.5	Good description, mention sporadic nature with DICER1 / FOXL2 mutations only seen in moderately/poorly differentiated forms. Mention excellent prognosis, advise discussion at MDM

Short case 3

44-year-old woman

Severe dyskaryosis

Specimen: Cervical LLETZ

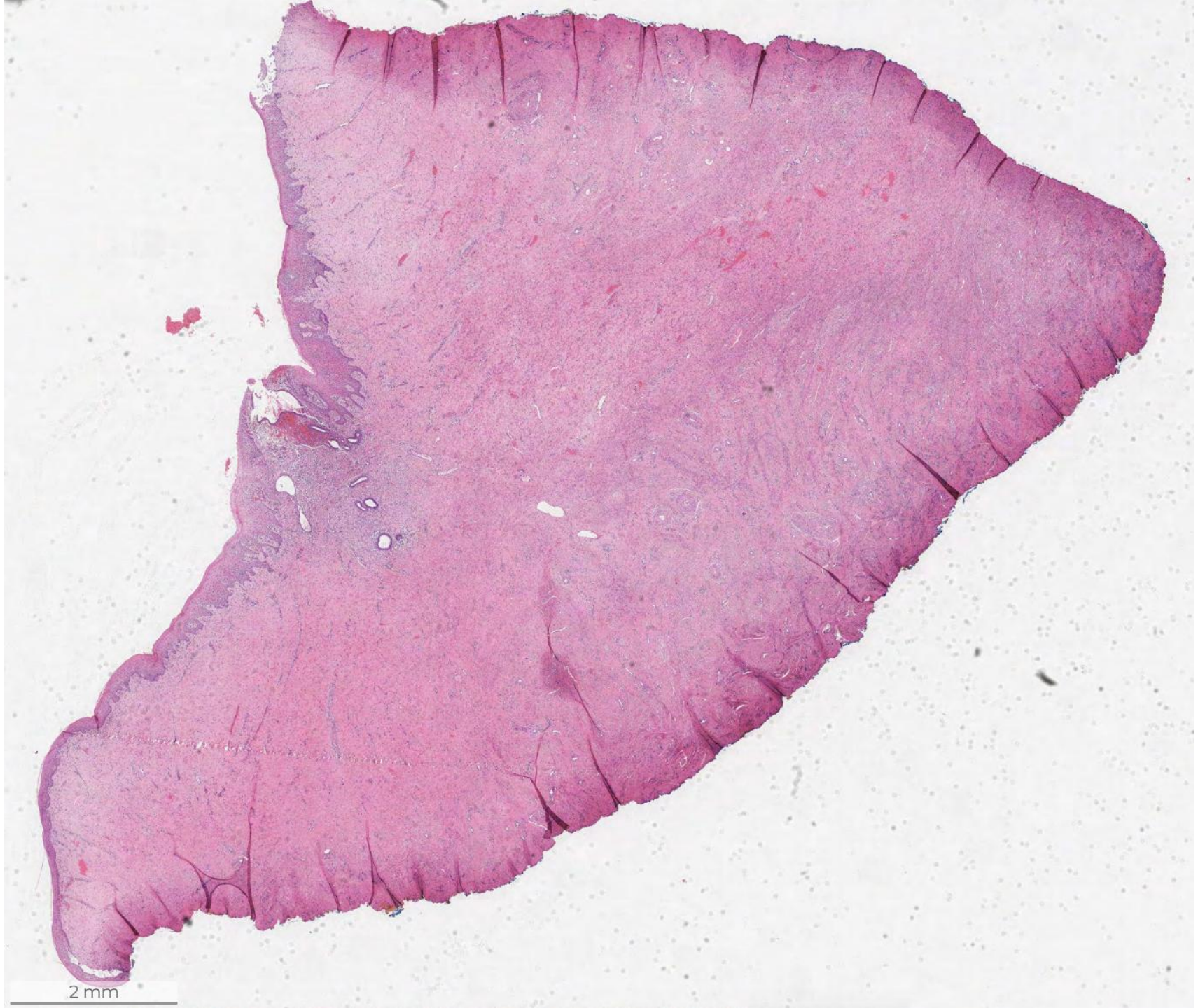
2 mm

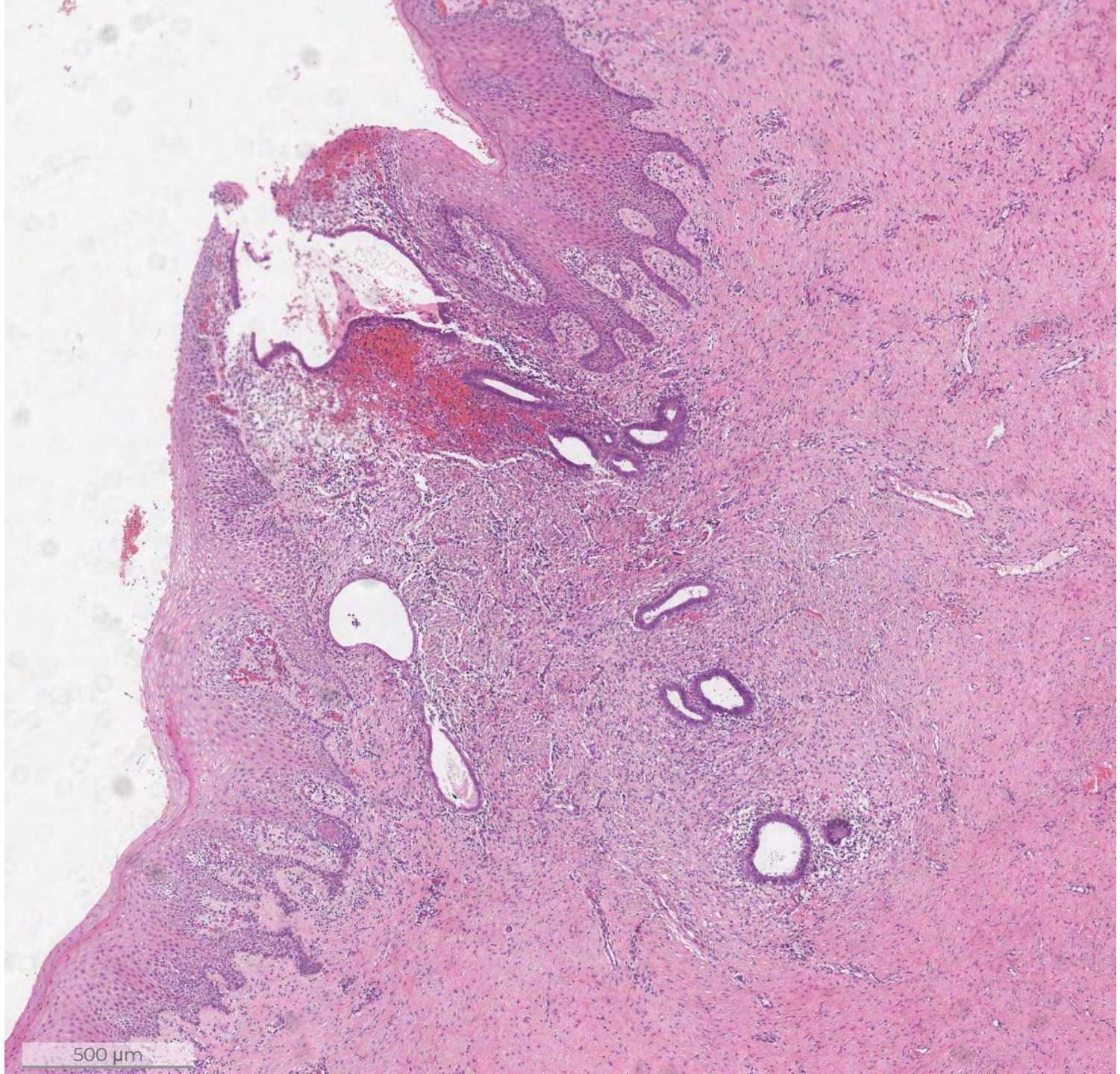
500 µm

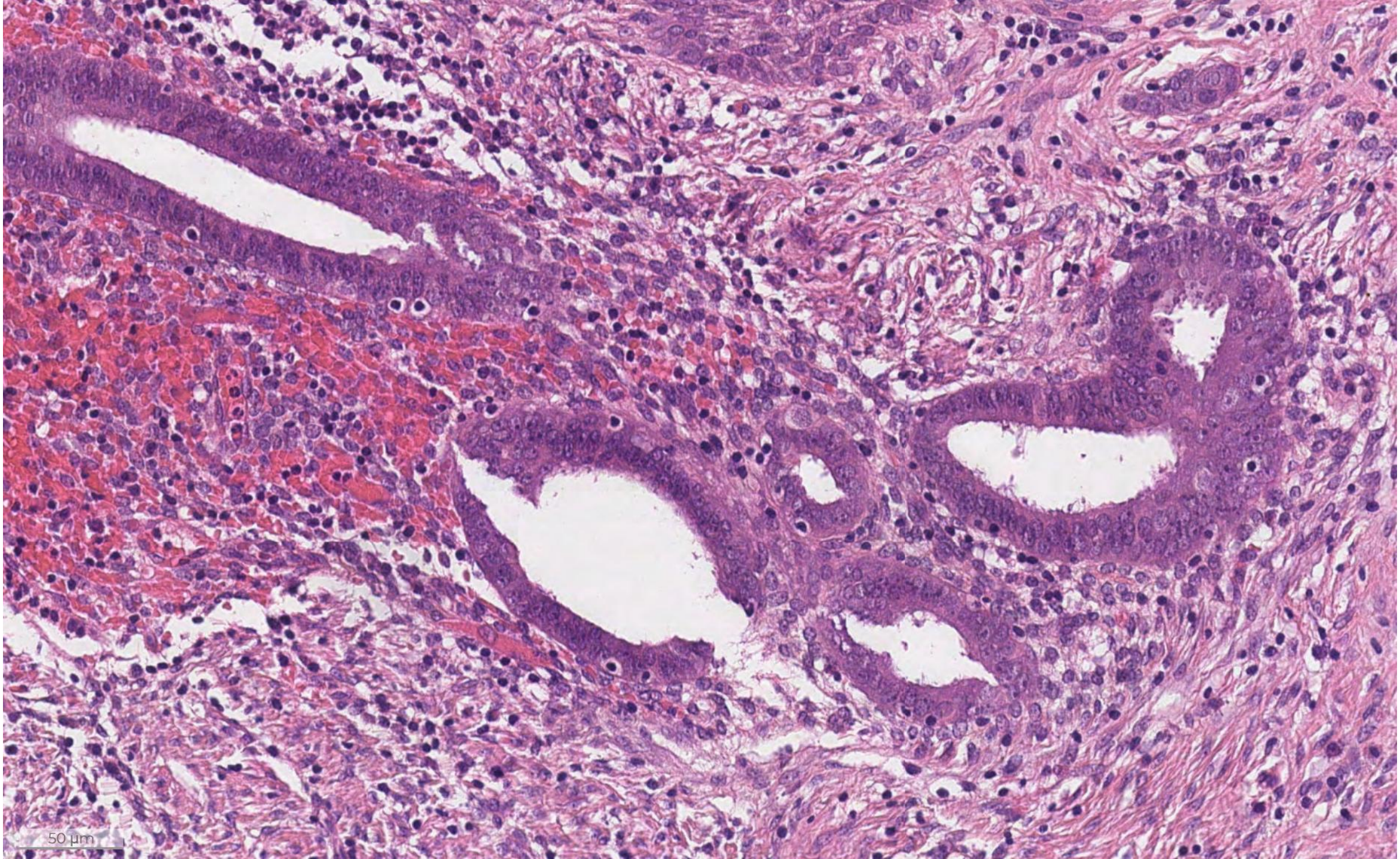
50 µm

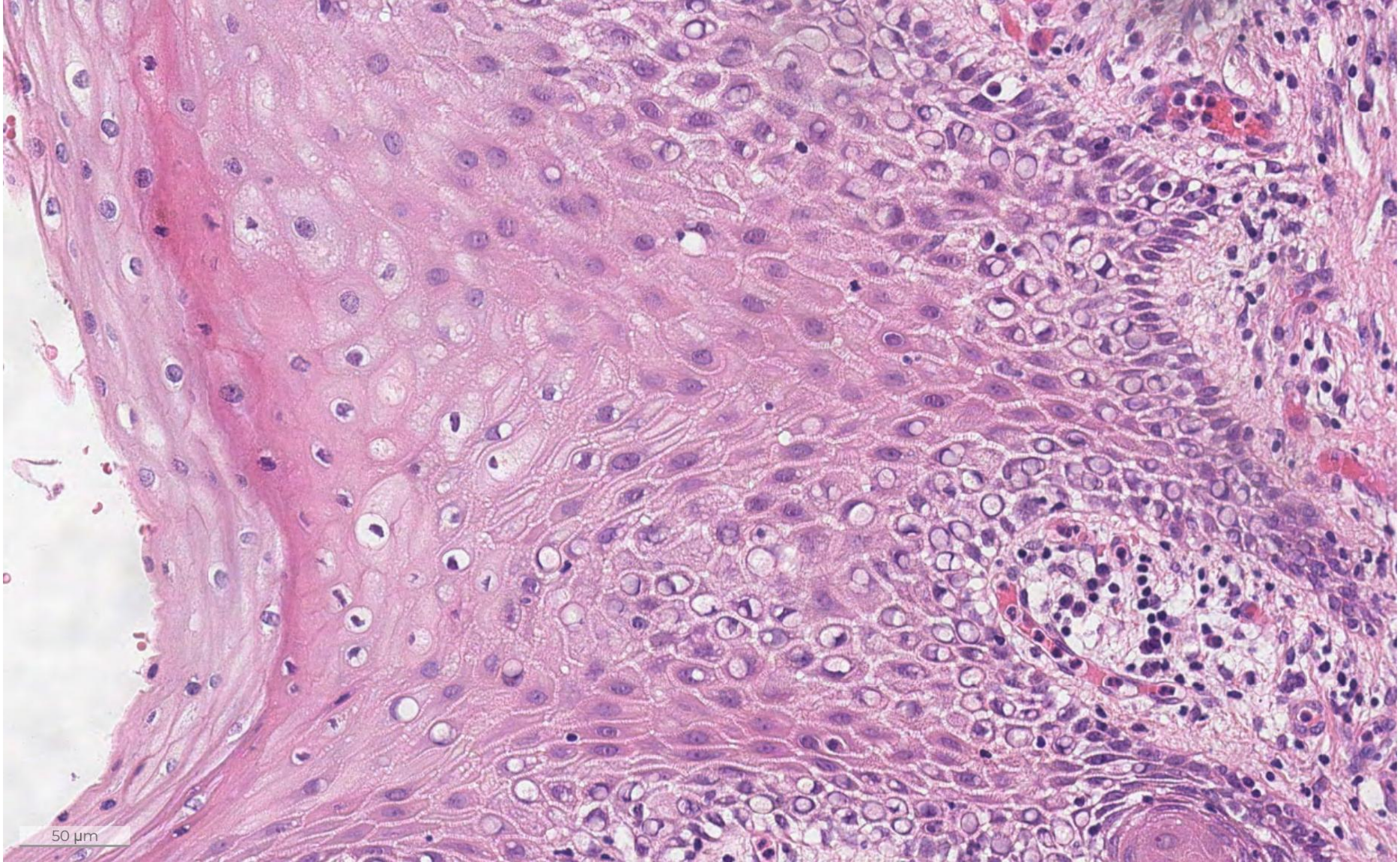
50 µm

Short case 3: Endometriosis

- May cause postcoital/abnormal uterine bleeding
- Mean age: 37 (range: 20 – 51 years)
- Two out of three:
  - Endometrial glands with basal nuclei
  - Spindled stroma
  - Haemorrhage

Short case 3: Endometriosis

Differential diagnoses:

- Tuboendometrioid metaplasia
  - Ciliated, secretory and intercalated cells
  - Regular glands, minimal mitoses, rare crowding or atypia
  - Usually no/little inflammation
- CGIN/adenocarcinoma
  - Apical mitosis, basal apoptosis

	Endometriosis	TEM	CGIN/ adenocarcinoma
P16	Negative/mosaic	Negative/mosaic	Block
BCL2	Strong, diffuse	Strong, diffuse	Negative
Ki62	Low/moderate	Low	High

Short case 3: Endometriosis

Mark	Features
1.5 or 1	Fails to diagnose
2	Does not commit to a diagnosis, inadequate morphological description
2.5	Adequate description with confident diagnosis but no additional information
3	Good description, suggests differentials (TEM, CGIN) but concludes with endometriosis as the final diagnosis. Requires Colposcopy MDM discussion

Short case 4

41-year-old woman

Right vulval cyst

Specimen: Right vulval excision biopsy

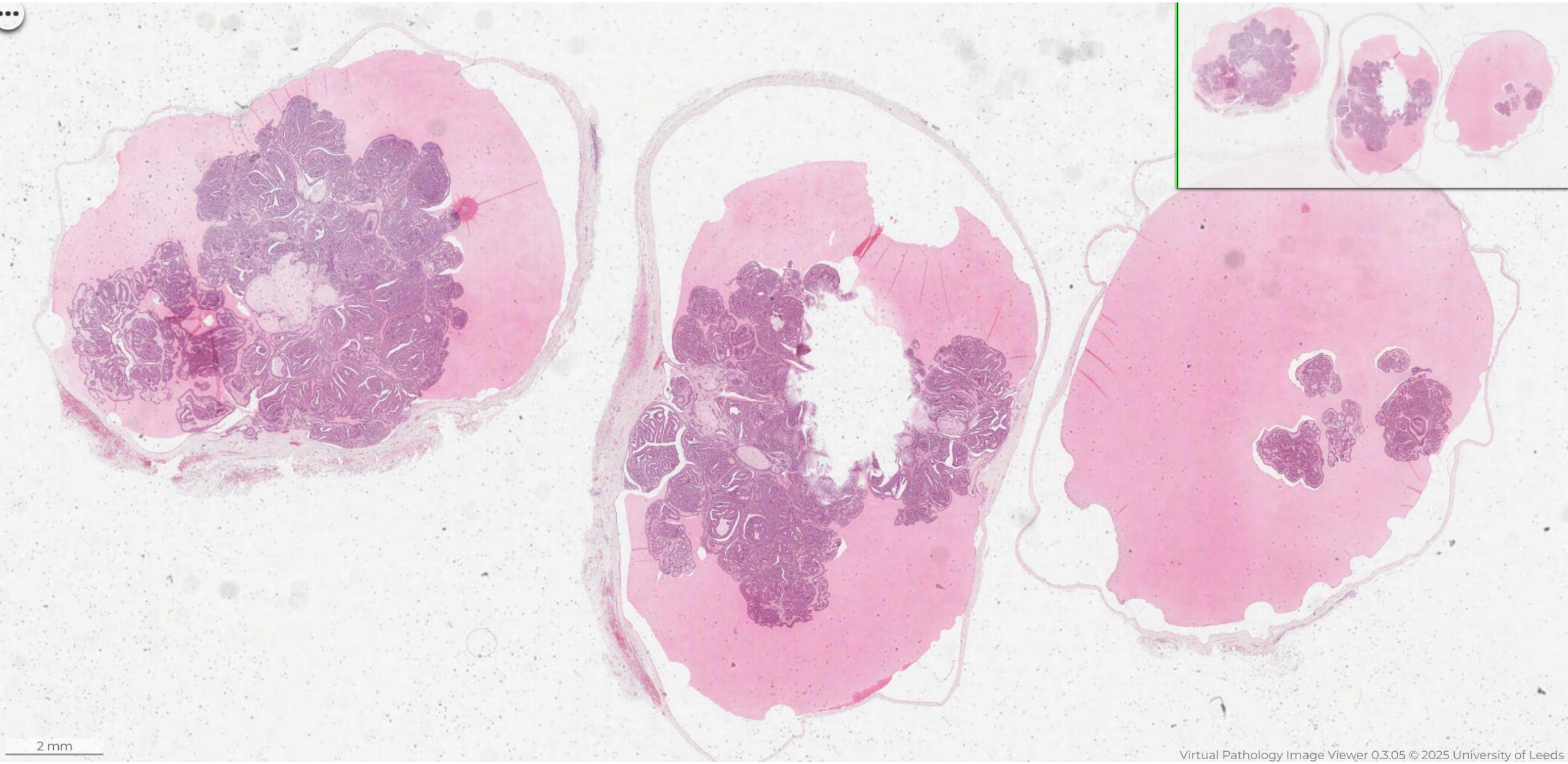

Virtual Pathology Image Viewer 0.3.05 © 2025 University of Leeds

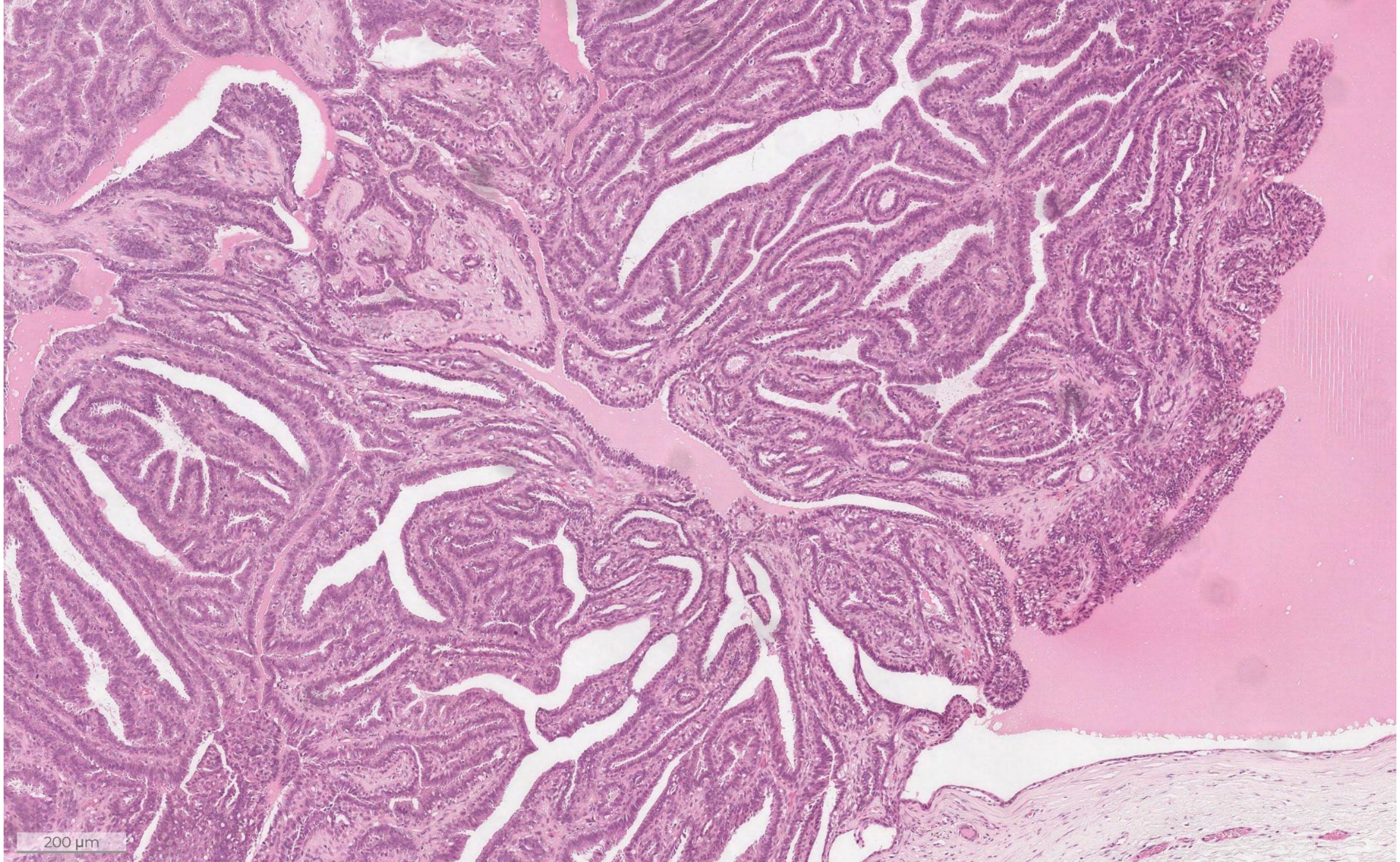
200 µm

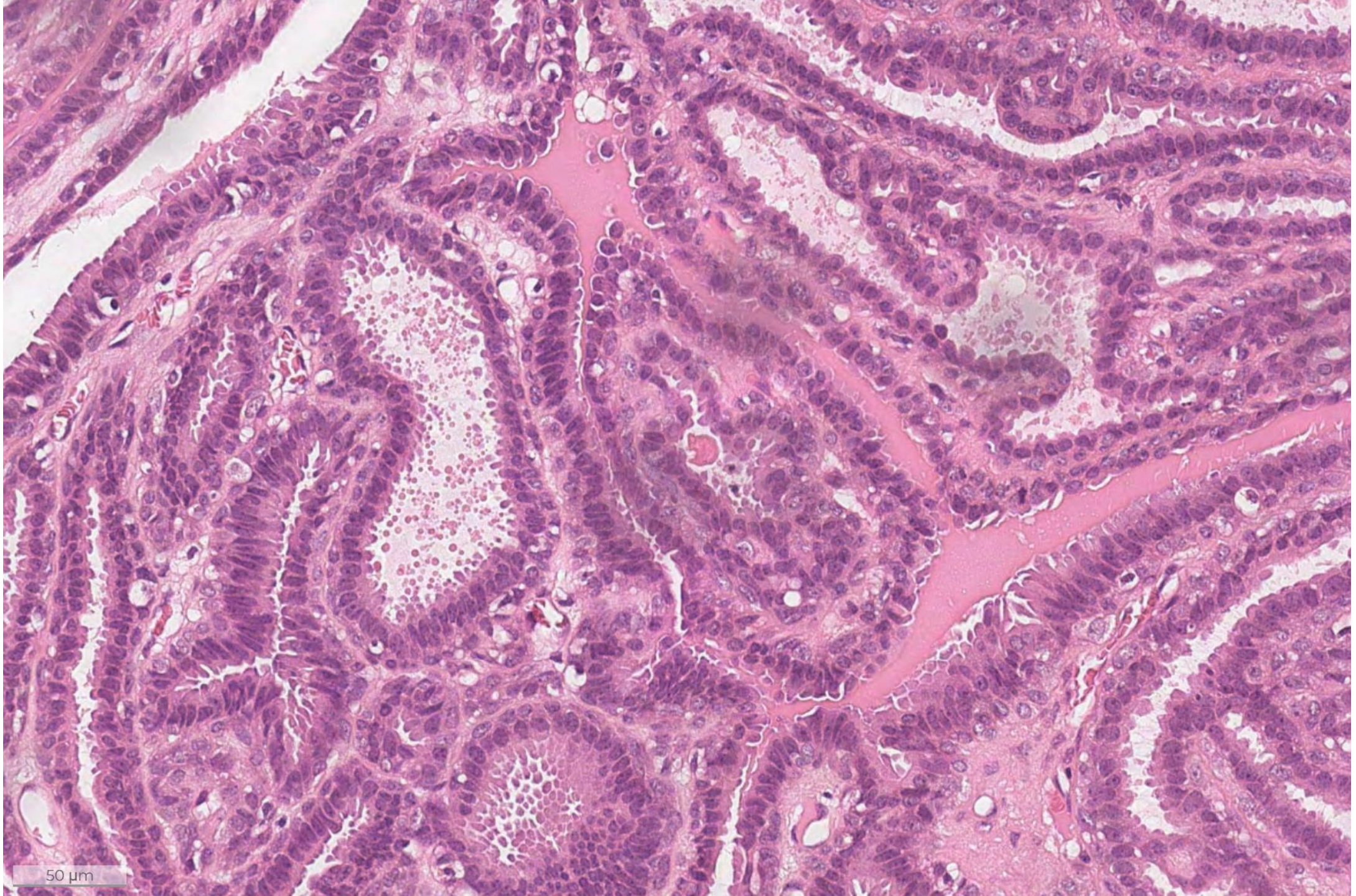
50 µm

Short case 4: Hidradenoma papilliferum

- Benign tumour
- Wide age range, mostly 30 – 40 years
- Most commonly seen in the interlabial sulcus/labia majora
- Solitary, firm, circumscribed, tan/red nodule with overlying ulceration
- Solid/variably cystic cut surface, ~1.5 cm
- Complex branching and interconnecting tubules and papillae
- Central delicate fibrovascular cores lined by uniform, cuboidal to columnar secretory cells and underlying myoepithelial cells. Mitoses often present
- IHC: CK7, EMA, CEA, ER, PR, AR positive. S100 highlights myoepithelial cells

Short case 4: Hidradenoma papilliferum

Mark	Features
1.5 or 1	Fails to diagnose
2	Does not commit to a diagnosis, inadequate morphological description
2.5	Adequate description with confident diagnosis but no additional information
3	Good description, mention benign status, could describe confirmatory IHC (not necessary for Dx)

Short case 5

61-year-old woman

History of vulval SCC, lichen sclerosus, radiotherapy

Specimen: 12 o’clock cruciates of left posterior WLE of vulva

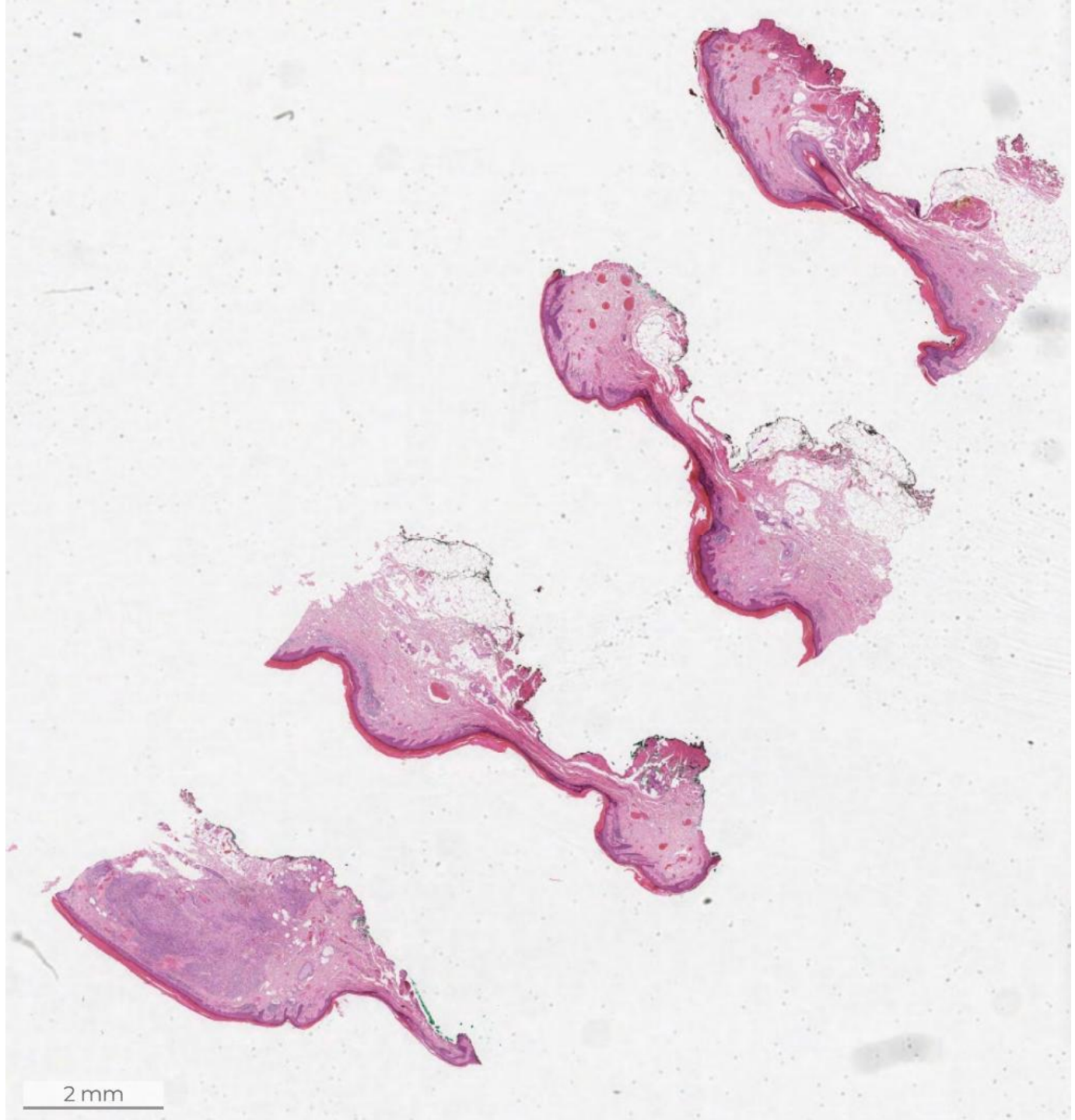
2 mm

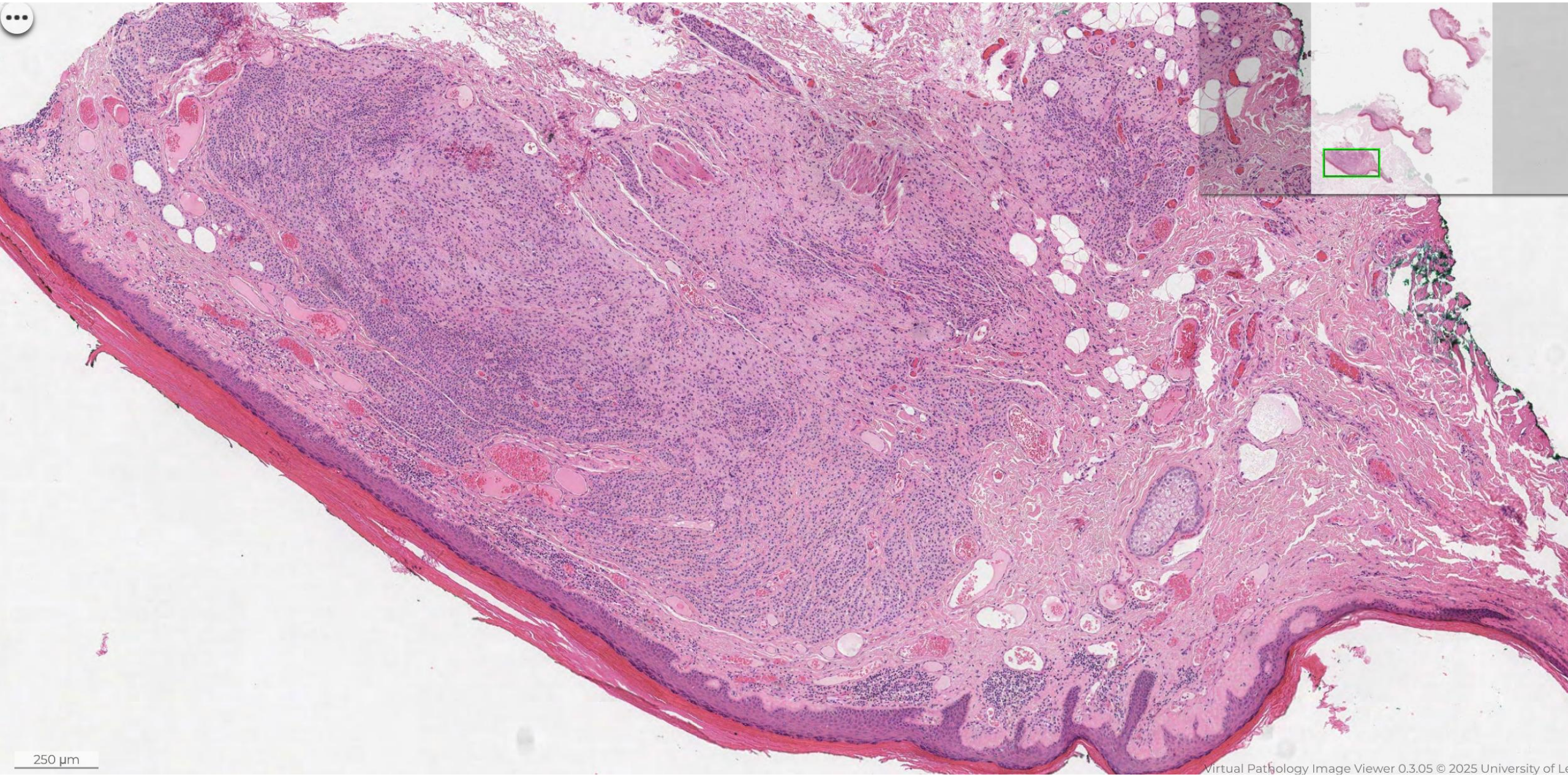
250 µm
Virtual Pathology Image Viewer 0.3.05 © 2025 University of Le

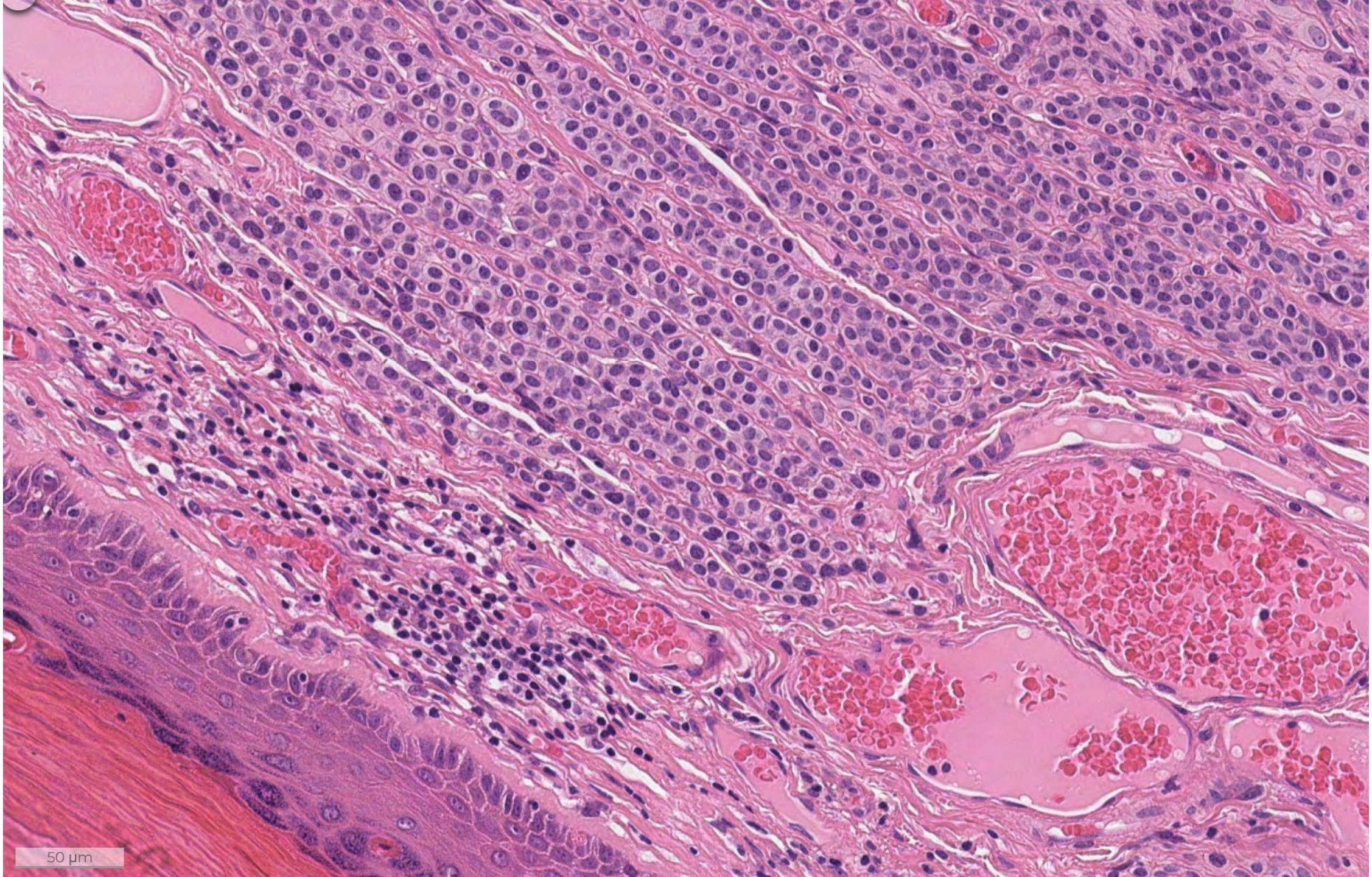
50 µm

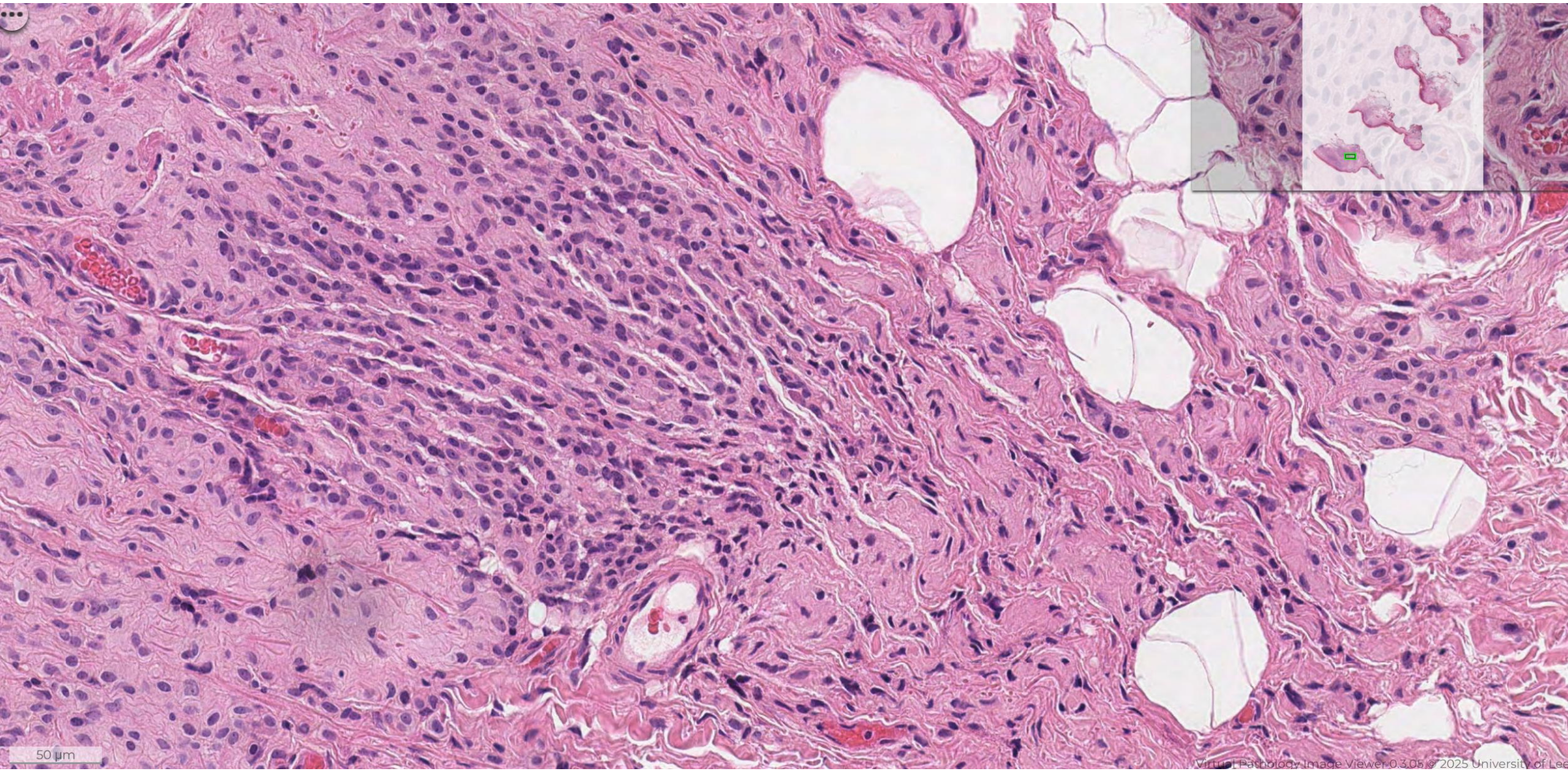
50 µm
Virtual Pathology Image Viewer 0.3.05 © 2025 University of Lee

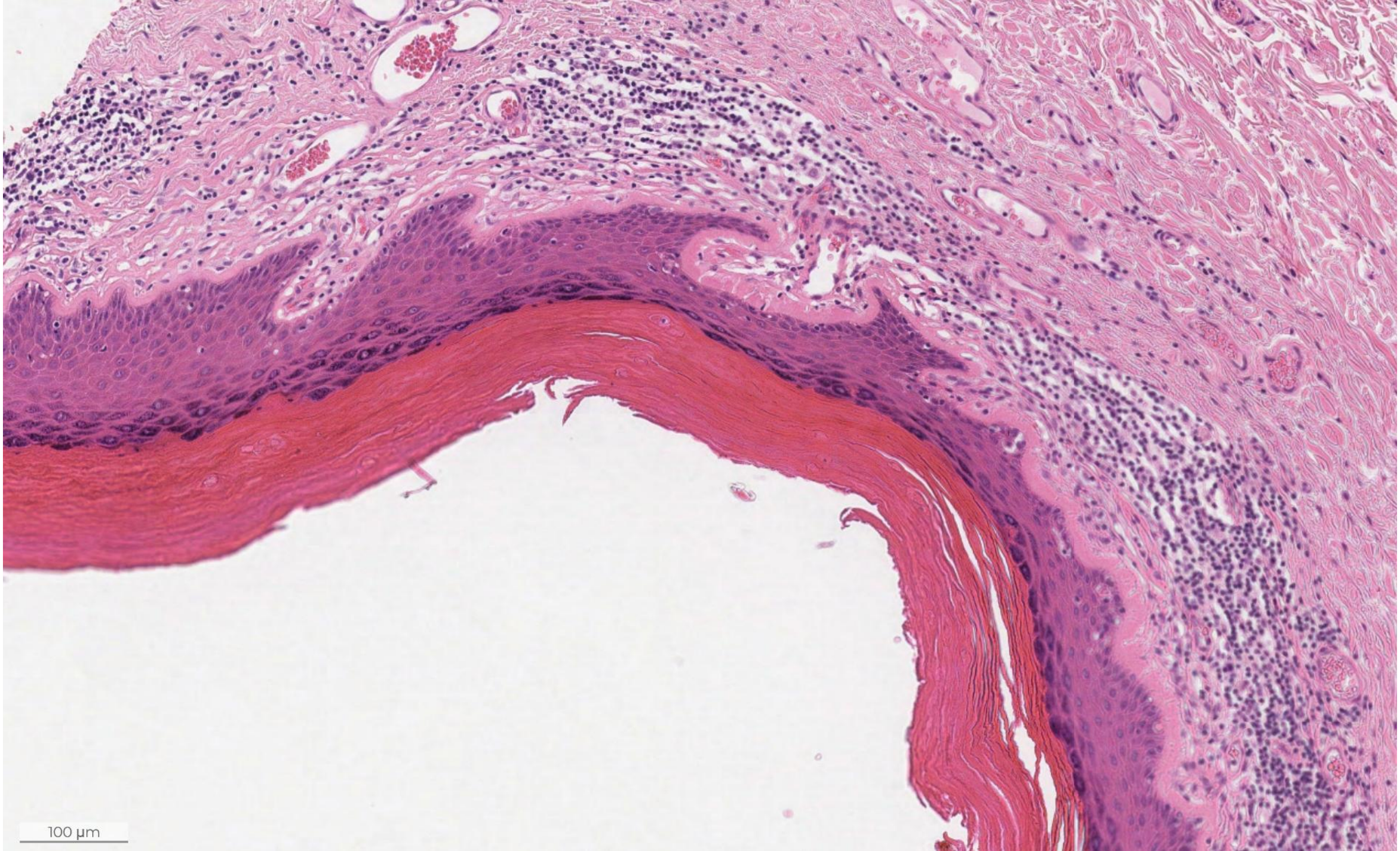
100 µm

Short case 5: Benign intradermal melanocytic naevus and lichen sclerosus

Benign intradermal melanocytic naevus

- Intradermal proliferation of benign melanocytes showing normal maturation with depth

Lichen sclerosus

- Immune mediated chronic fibroinflammatory condition of vulval skin typically seen in postmenopausal women
- Intensely pruritic, may become excoriated. Associated with increased risk of HPV-independent VIN and SCC

Short case 5: Benign intradermal melanocytic naevus and lichen sclerosus

- Vacuolar interface reaction pattern with dermal sclerosis (homogenisation and hyalinisation of collagen) intervening between underlying band of chronic inflammation.
- Early lesions may show only inflammation with no/minimal fibrosis, acanthosis and luminal hyperkeratosis and hypergranulosis

Short case 5: Benign intradermal melanocytic naevus and lichen sclerosus

Mark	Features
1.5 or 1	Fails to diagnose
2	Does not commit to a diagnosis, inadequate morphological description
2.5	Adequate description with confident diagnosis of benign intradermal melanocytic naevus but no additional information
3	Some additional information, as mentioned below:
3.5	Good description of a benign intradermal melanocytic naevus. Identify features of lichen sclerosus in the background vulval mucosa. Mention association with HPV-independent VIN and SCC.

Short case 6

47-year-old woman

Cervical cancer IA1 on LLETZ

Hysterectomy and BSO

Specimen: Left ovary

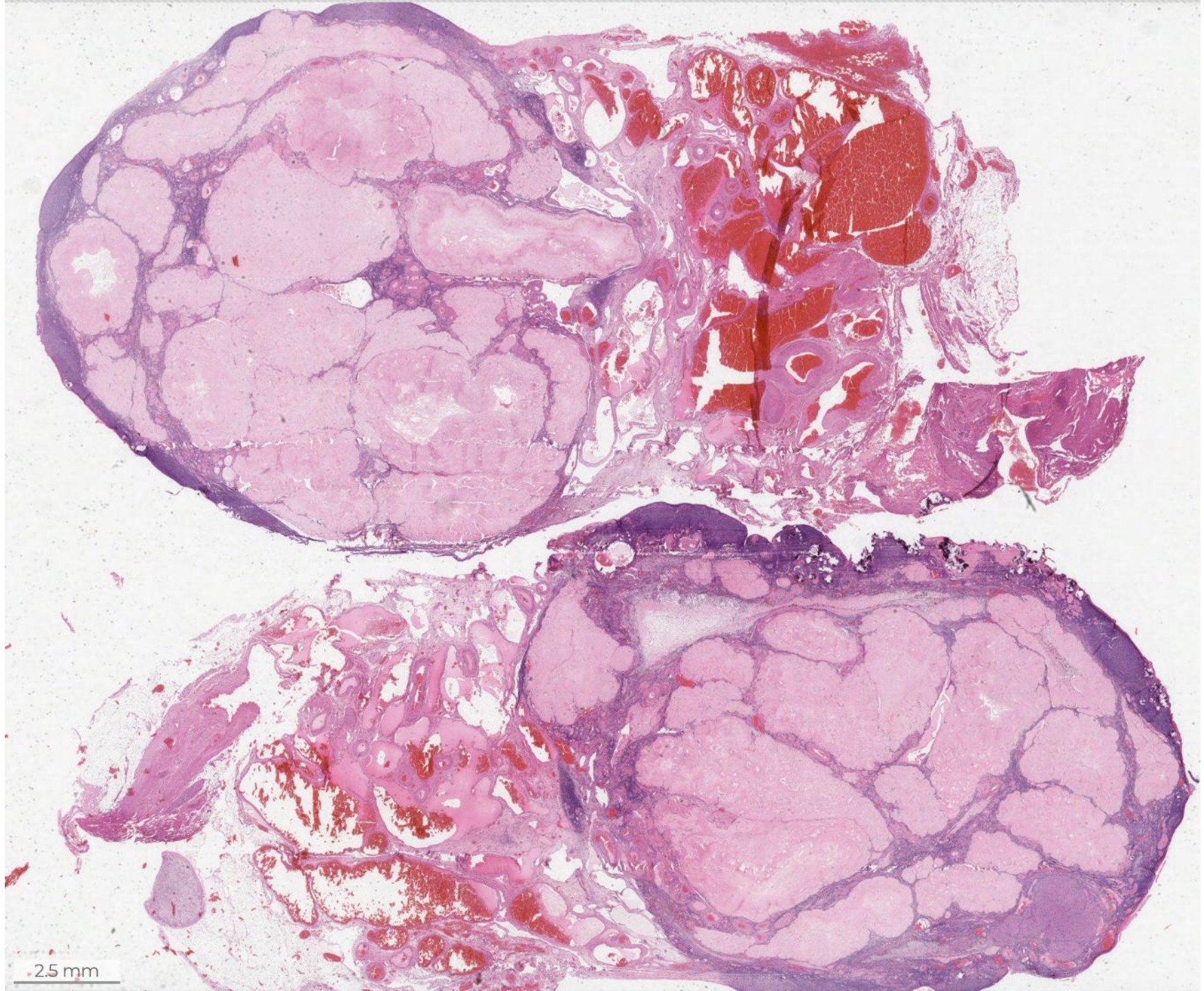
2.5 mm

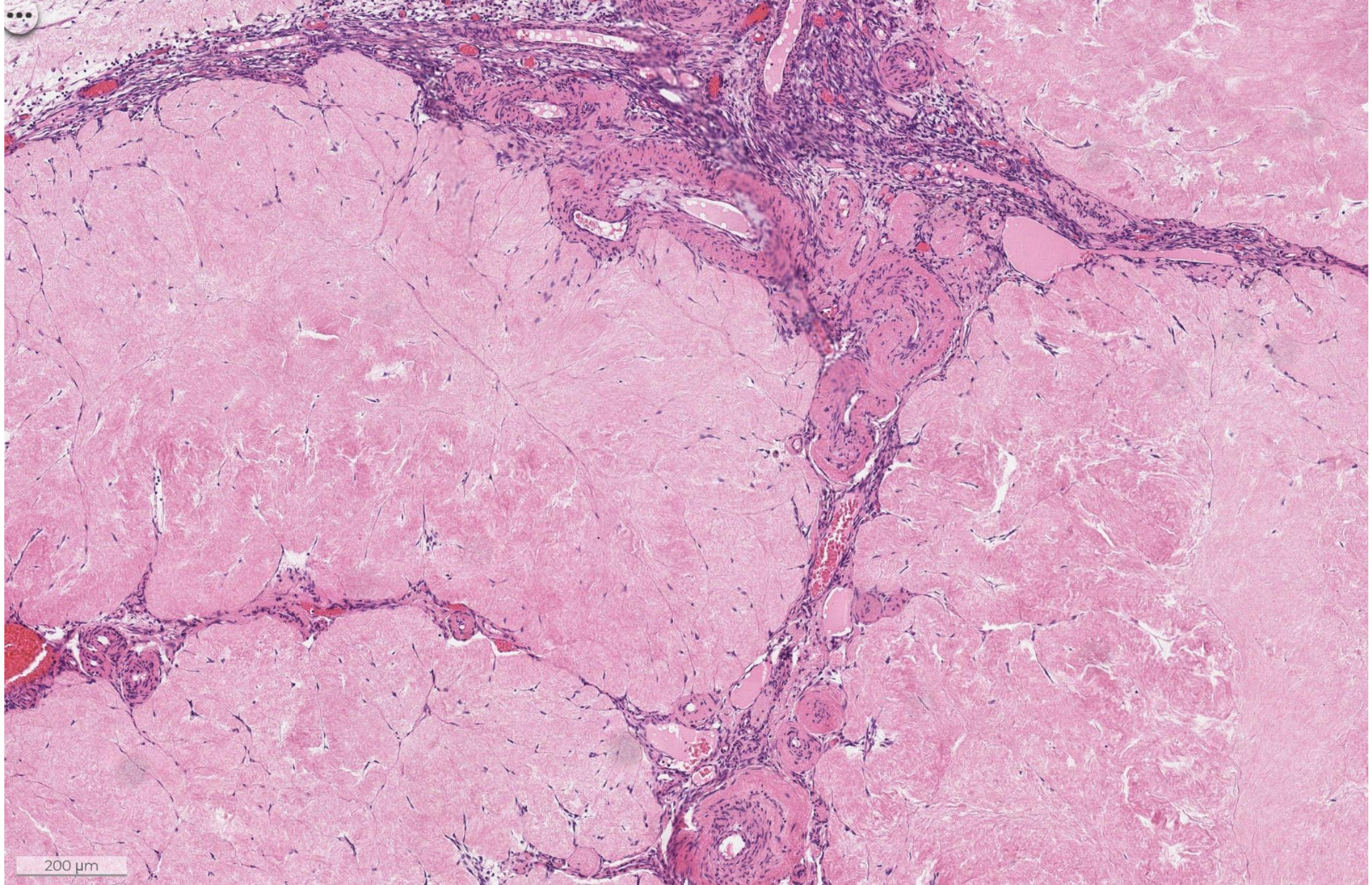
200 µm

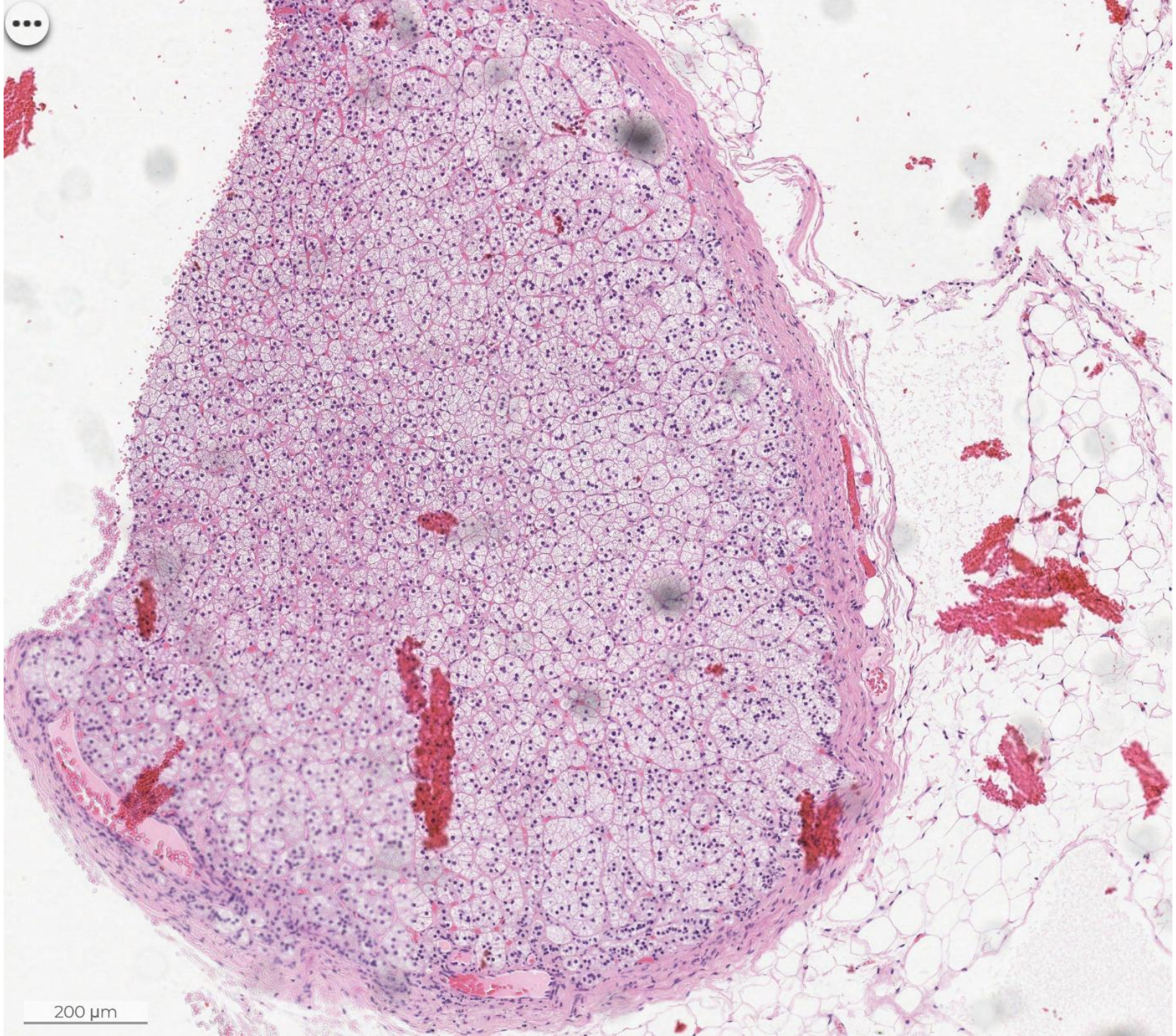
200 µm

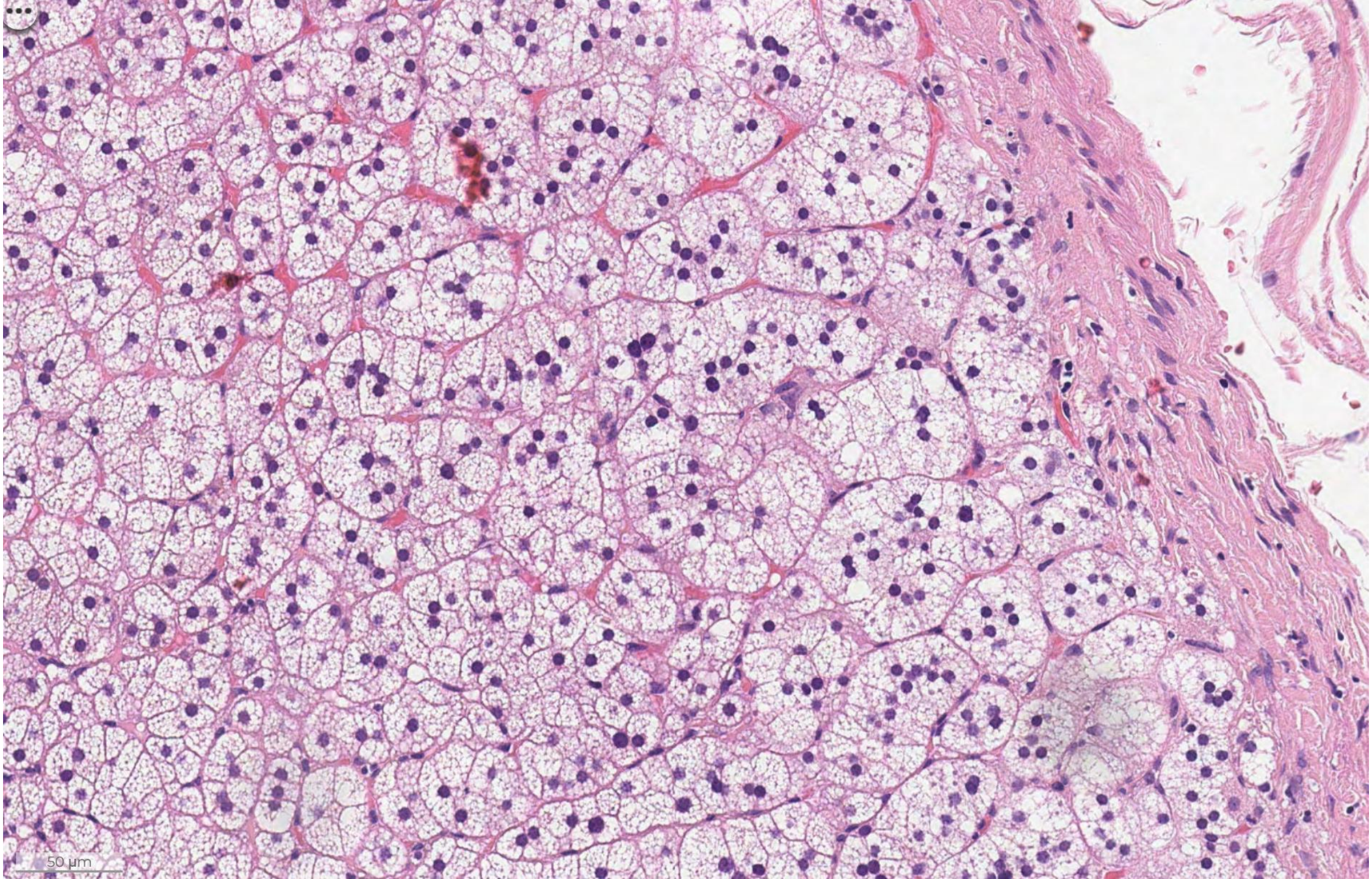
50 µm

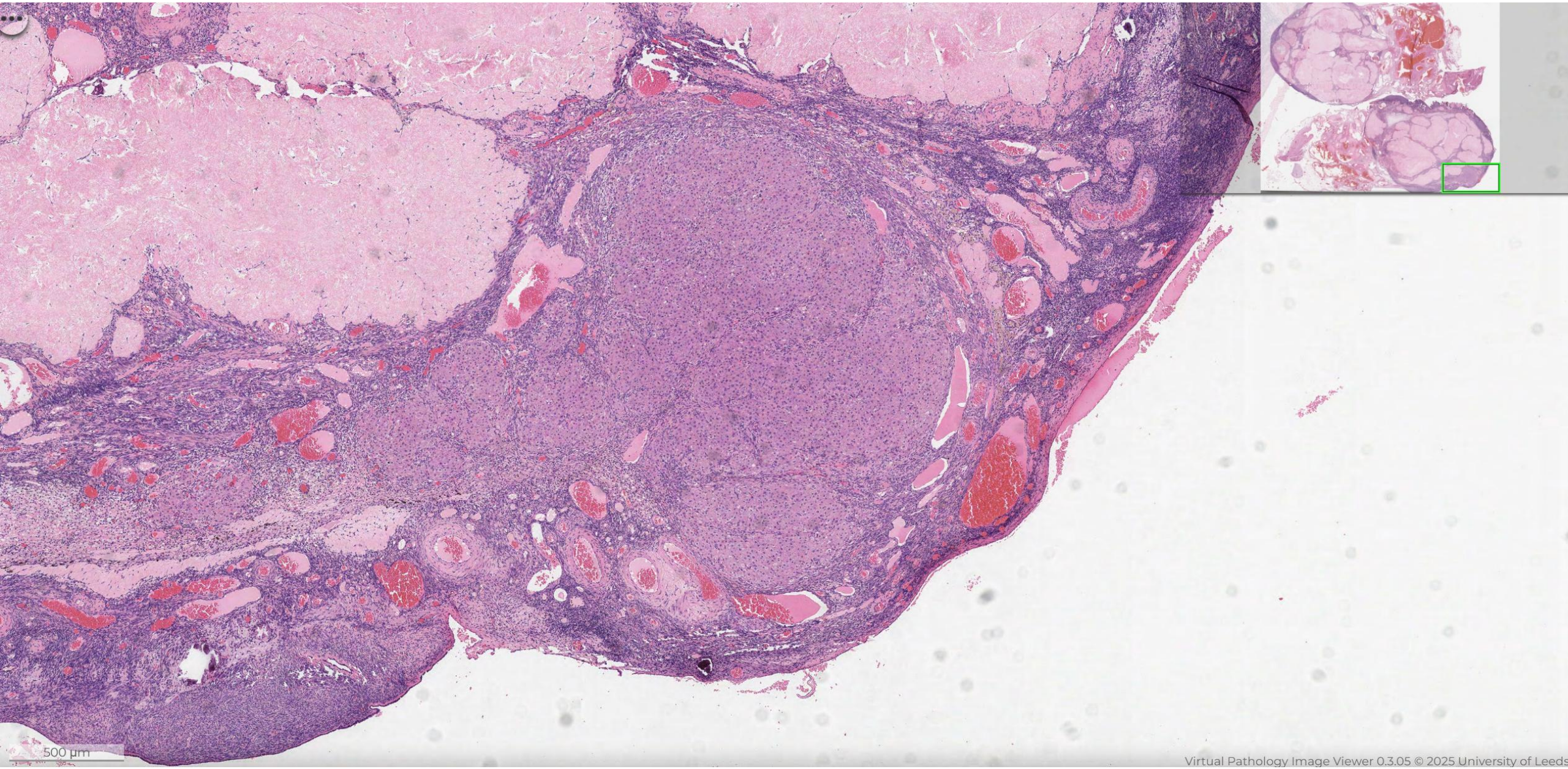

Virtual Pathology Image Viewer 0.3.05 © 2025 University of Leeds

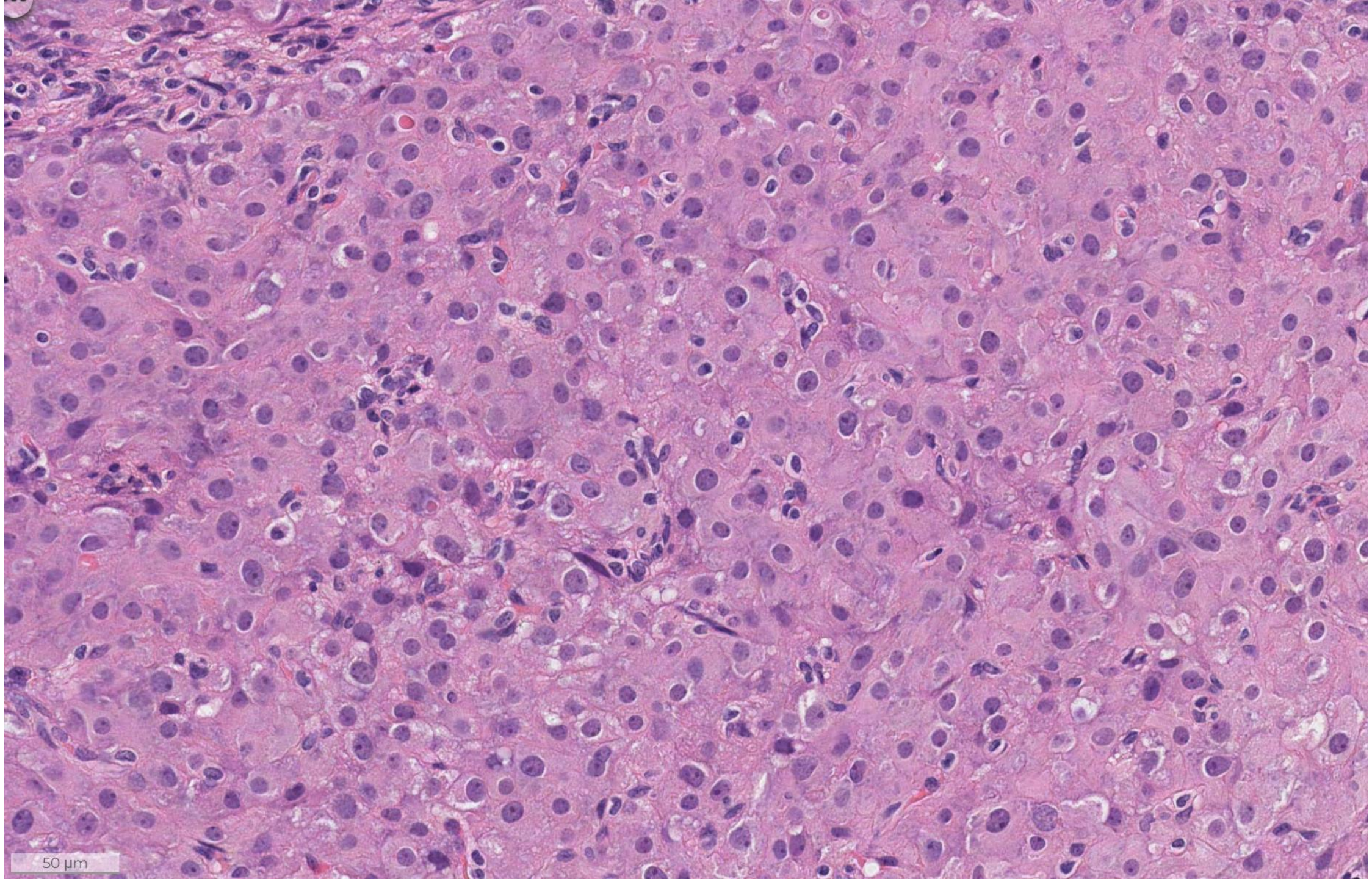
50 µm

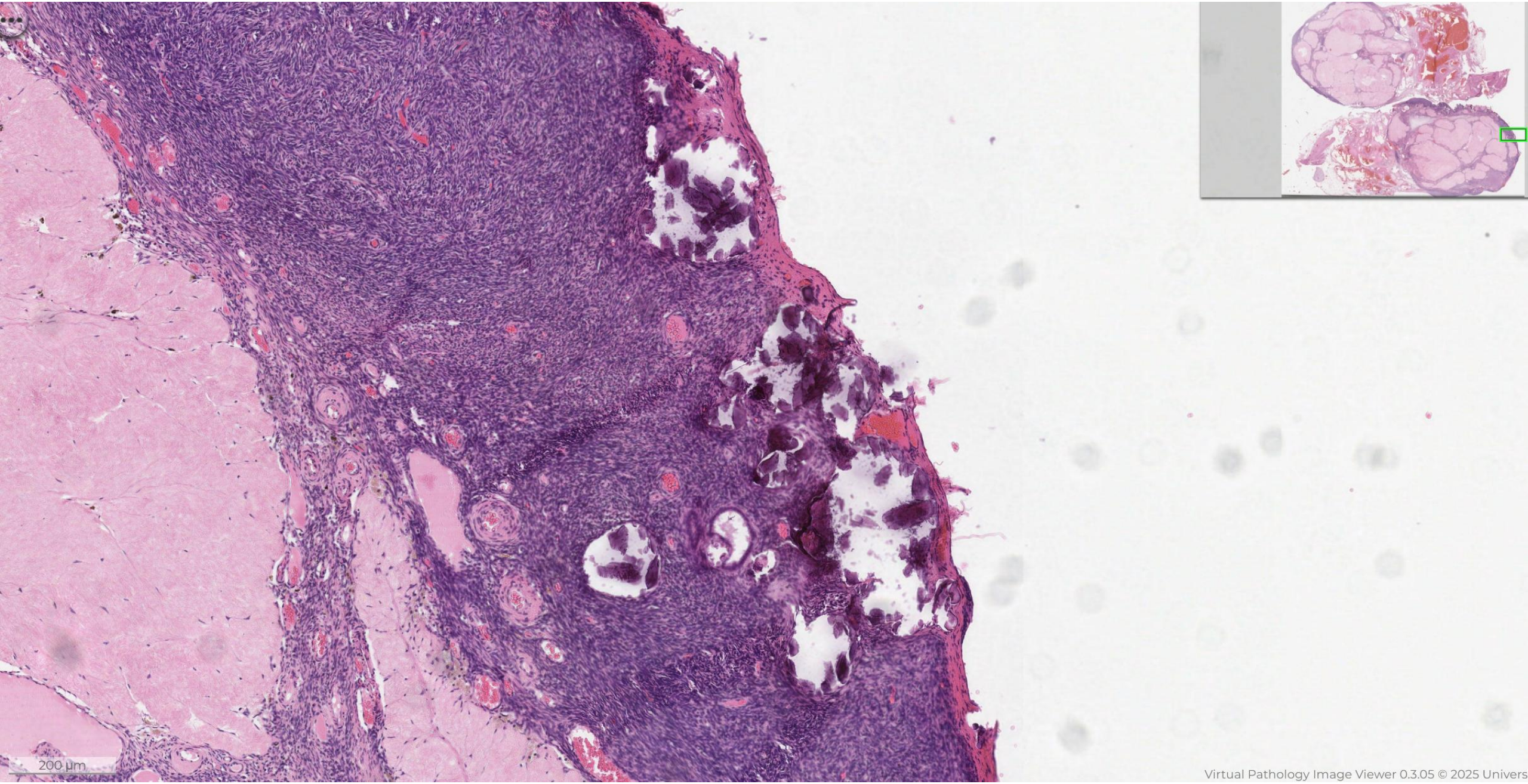
200 µm
Virtual Pathology Image Viewer 0.3.05 © 2025 Univers

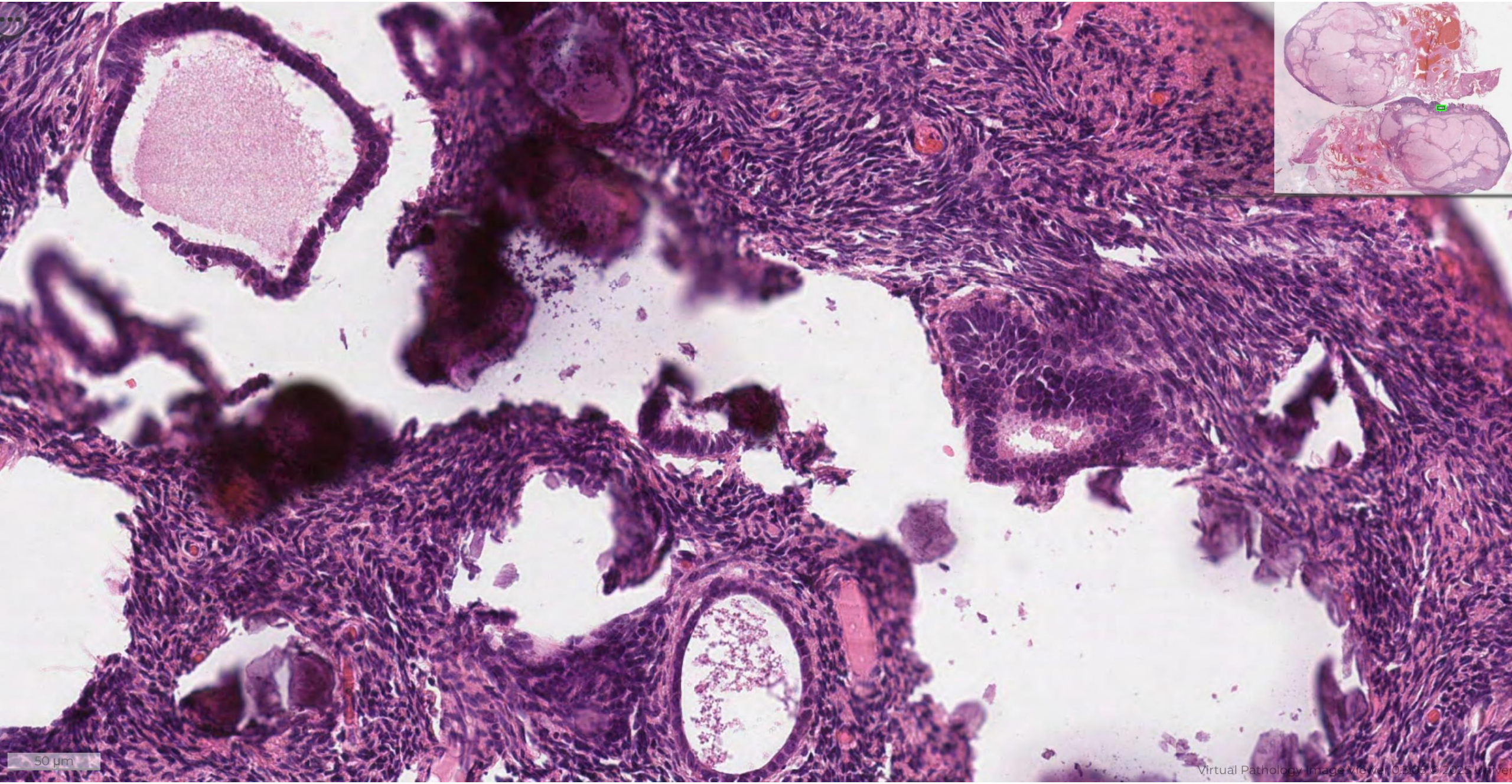
50 µm

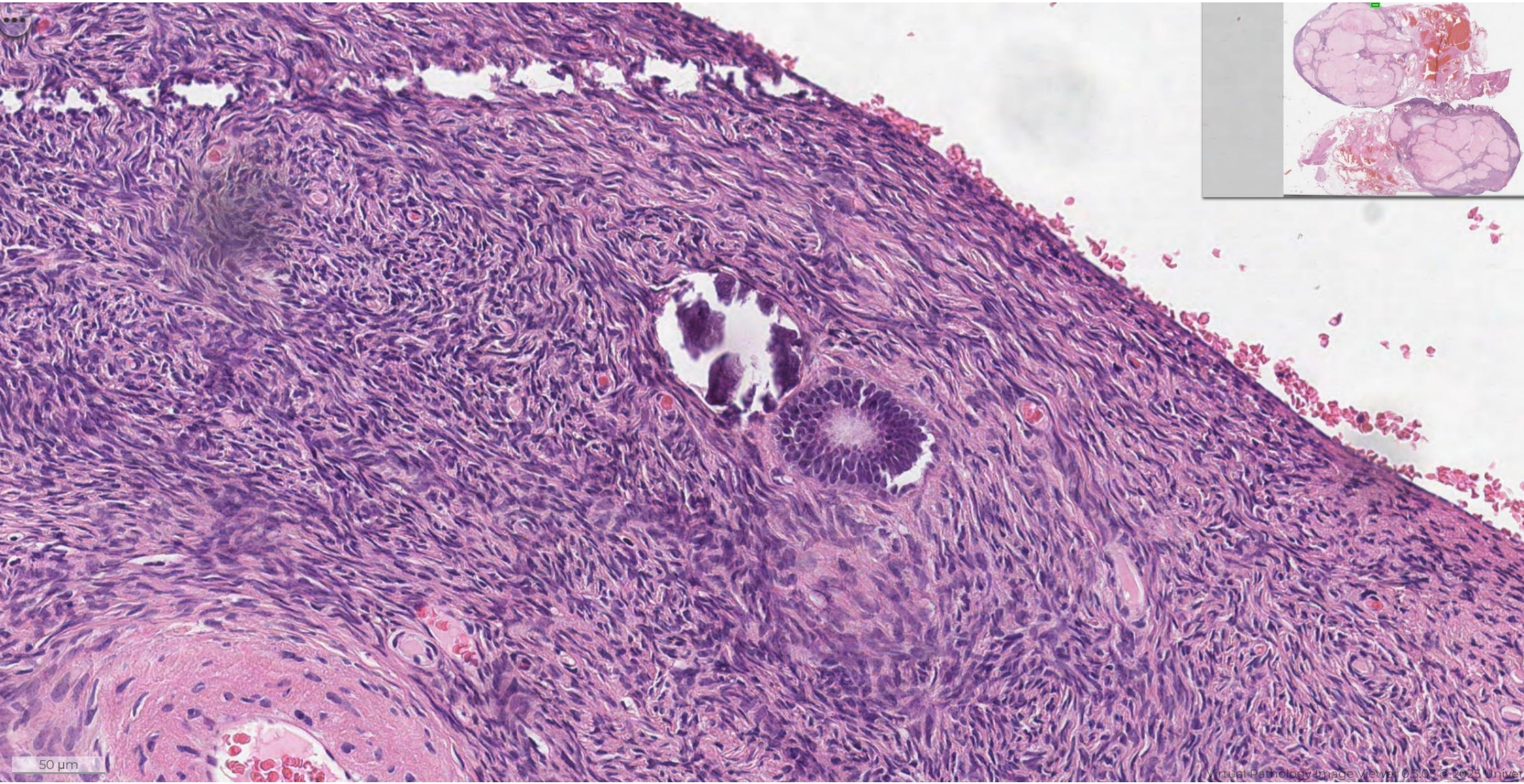
50 µm

Short case 6: Adrenal rest, pseudodecidualised stroma, endosalpingiosis

Adrenal rest

- Ectopic adrenal tissue, commonly involving paraovarian / ovarian / paratubal / infundibulopelvic ligament / broad ligament
- Typically single, <10 mm, hormonally silent, detected incidentally
- Adrenal cortex (large polygonal cells, distinct cell membranes, vesicular eosinophilic to clear cytoplasm, bland nuclei). Medulla component rarely present
- Positive: SF1, MelanA, Inhibin A
- Negative: PAX8

Short case 6: Adrenal rest, pseudodecidualised stroma, endosalpingiosis

Pseudodecidualised stroma

- Ectopic deposit of decidual reaction without accompanying glands
- Can be located in ovary, FTs, cervix, vagina, peritoneum, lymph nodes
- Suggested pathophysiology: Decidual reaction of endometriotic sites, entrapment of coelomic remnants during embryologic development
- May mimic metastatic SCC during frozen section
- Circumscribed nests of polygonal decidual cells with abundant granular eosinophilic cytoplasm, defined cell borders, small round/oval nuclei

Short case 6: Adrenal rest, pseudodecidualised stroma, endosalpingiosis

Endosalpingiosis

- Benign ectopic glands lined by Fallopian tube type ciliated epithelium
- Typically asymptomatic, incidental, in women of reproductive age
- 33% associated with endometriosis
- 3 types of cells: ciliated columnar cells, nonciliated columnar secretory mucous cells, intercalated cells
- Positive: PAX8, WT1, ER, PR
- Negative: Calretinin, D2-40

Short case 6: Adrenal rest, pseudodecidualised stroma, endosalpingiosis

Mark	Features
1.5 or 1	Fails to diagnose
2	Does not commit to a diagnosis, inadequate morphological description
2.5	Adequate description with confident diagnosis of adrenal rest +/- pseudodecidualised stroma +/- endosalpingiosis, but no additional information
3	Good description, some additional information, as mentioned below:
3.5	Typical sites of adrenal rest, confirmatory IHC. Suggested pathophysiology of ectopic decidua and endosalpingiosis. Association between endosalpingiosis and endometriosis. Potential for ectopic decidua to mimic SCC (given history)

Short case 7

72-year-old woman

Postmenopausal bleeding

Specimen: Vaginal polyp

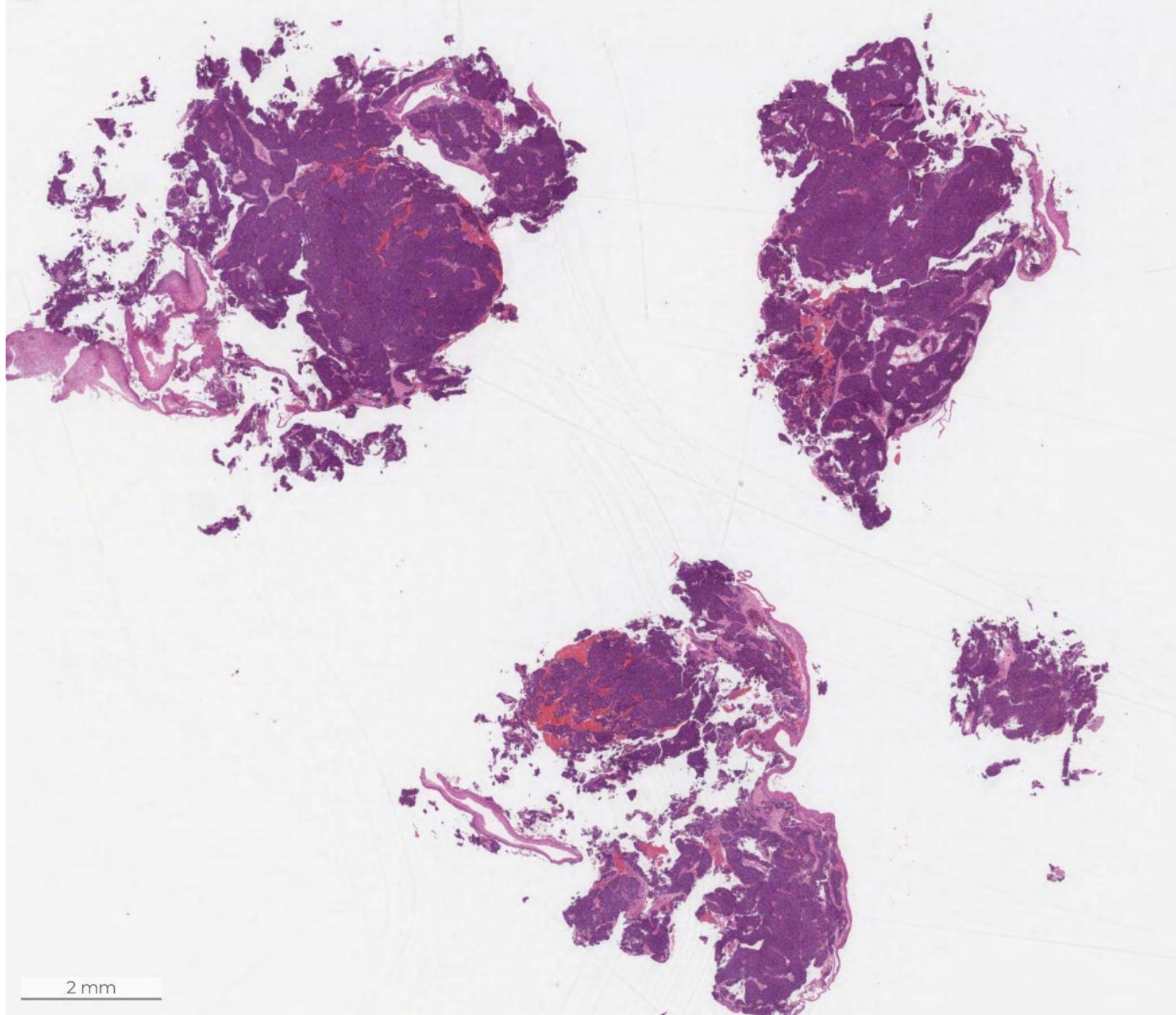
2 mm

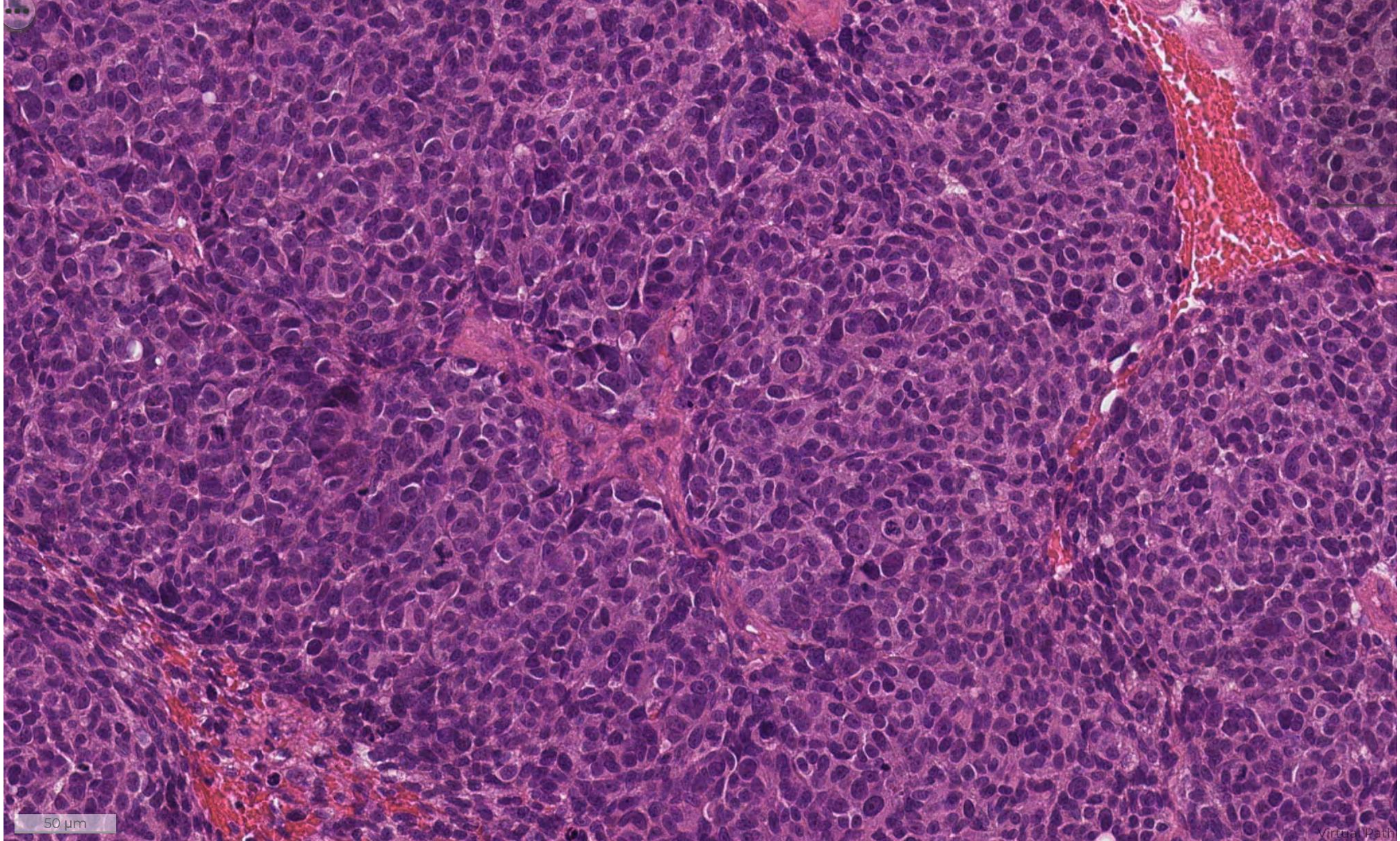
50 µm

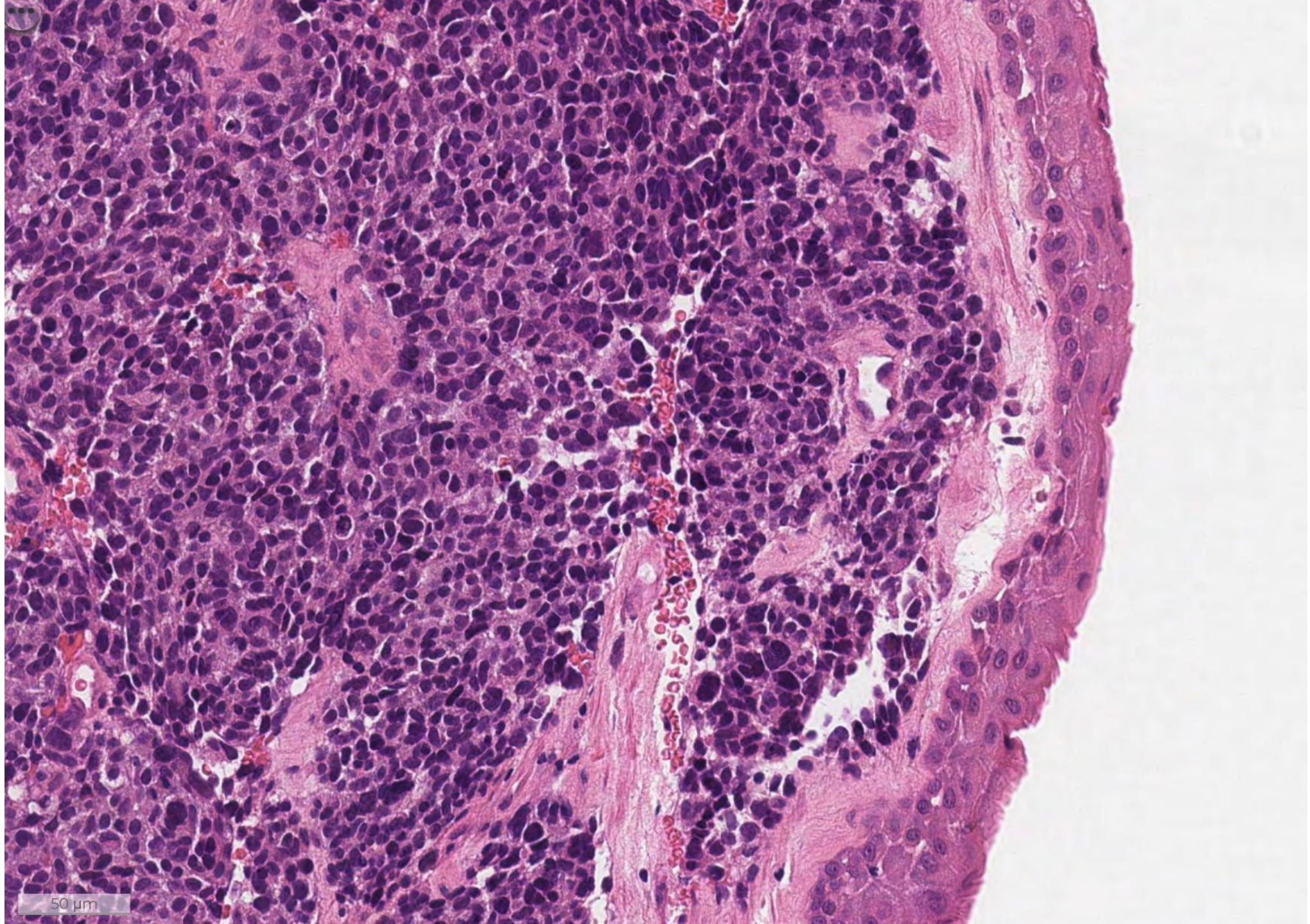
50 µm

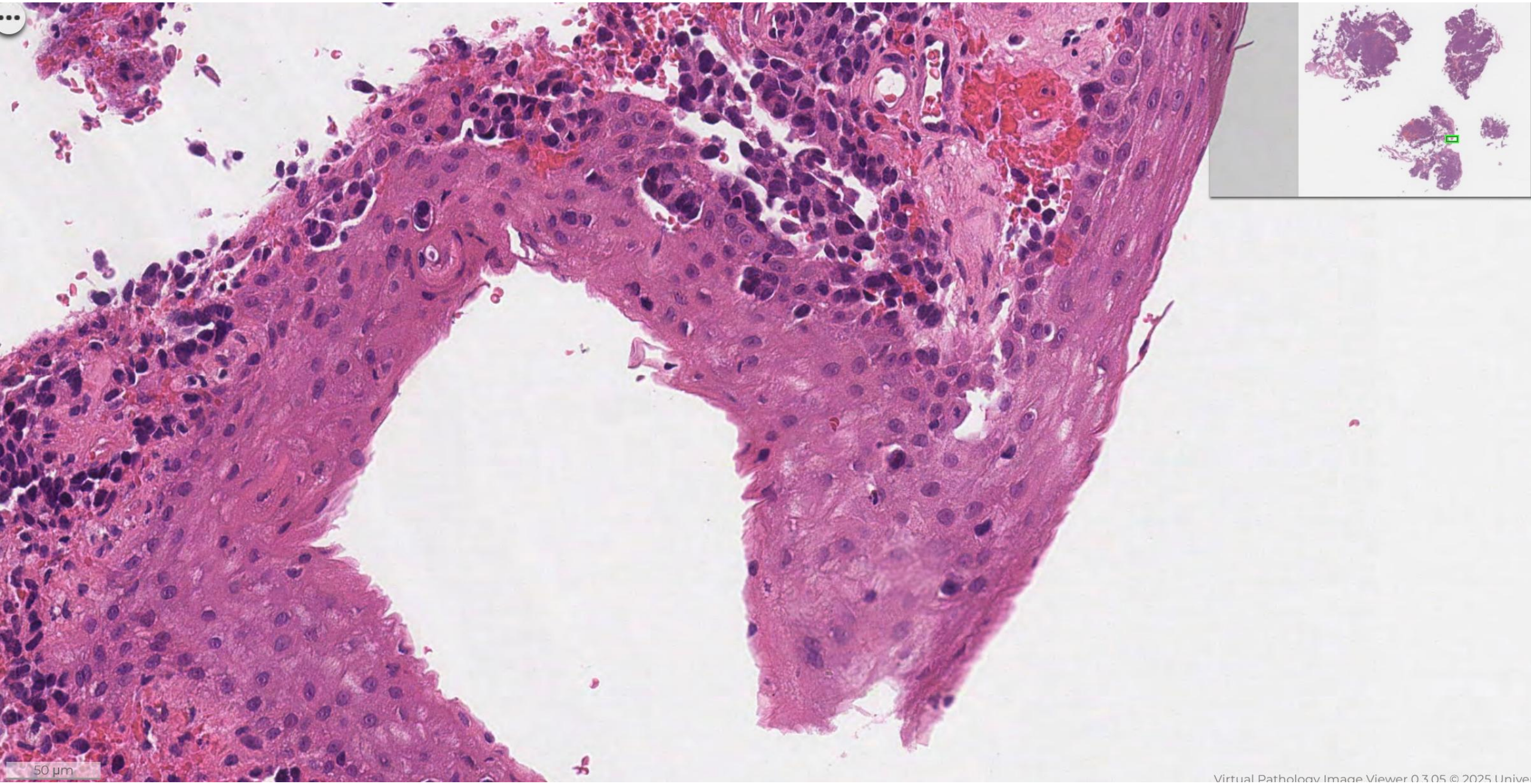
50 µm
Virtual Pathology Image Viewer 0.3.05 © 2025 Unive

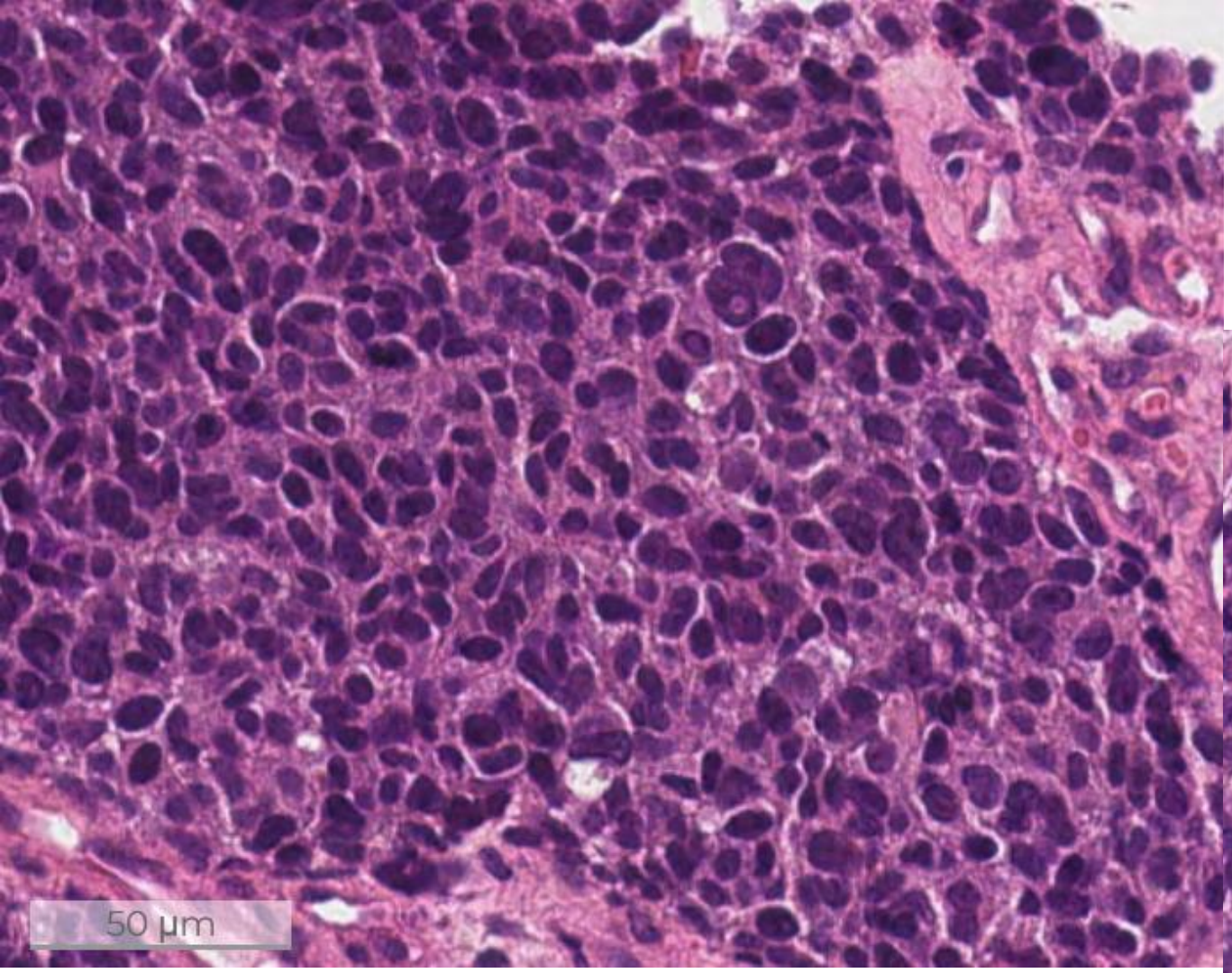
50 µm

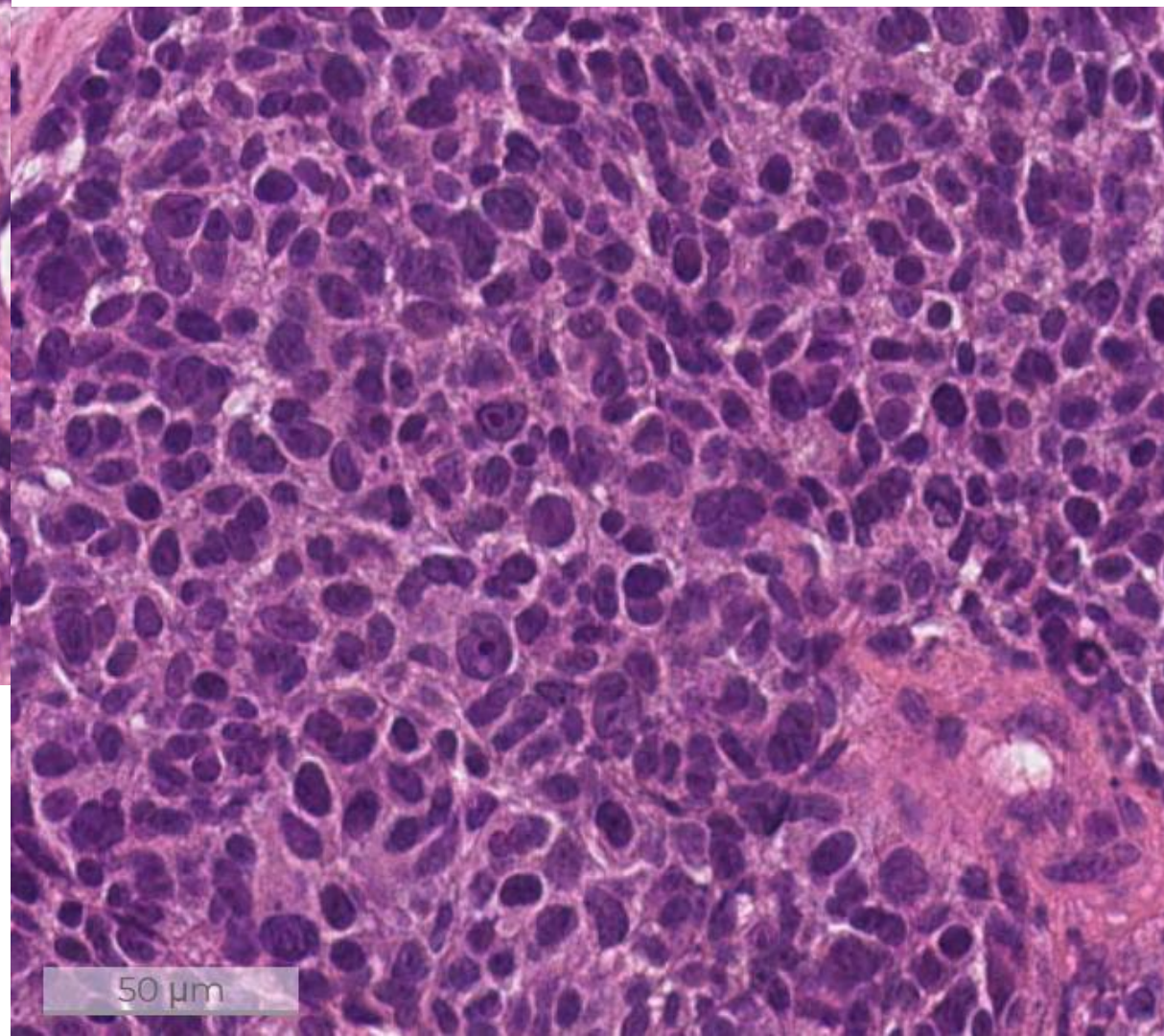
50 µm

Short case 7: Malignant melanoma

Malignant tumour, proposed differentials:

- Poorly differentiated carcinoma e.g. SCC: p63, p40, p16 (if HPV associated)
- Malignant melanoma: SOX10, S100, Melan A, HMB45, PRAME
- Lymphoma
- Soft tissue tumour

Short case 7: Malignant melanoma

- Primary malignant melanocytic tumour (although should consider possibility of metastasis). <5% vulval/vaginal malignancies
- Arises from melanocytes in vaginal mucosa. Not UV radiation related
- Predominantly postmenopausal women in 50-70s
- Vaginal melanomas most commonly in anterior lower 1/3 of vagina
- Compared to cutaneous melanomas: higher rate of KIT mutations, rare BRAF mutations

Short case 7: Malignant melanoma

- Presentation often delayed (symptoms nonspecific and variable, rare self inspection)
- Symptoms: asymptomatic, pruritis, spontaneous bleeding, atypical discharge, distinct mass, lymphadenopathy if advanced
- Polypoid mass
- Histological growth pattern: nodular (most common)
- Prognostic factors: tumour thickness, ulceration, stage, LVI, LN involvement, multifocal involvement, mitoses, tumour infiltrating lymphocytes, age

Short case 7: Malignant melanoma

Mark	Features
1.5 or 1	Fails to diagnose
2	Inadequate morphological description
2.5	Adequate description, suggesting differentials and an IHC panel. No additional information
3	Good description, include differentials and IHC panel, favour malignant melanoma. Mention lack of VAIN.
3.5	Good description, include differentials and IHC panel, favour malignant melanoma. Mention lack of VAIN. Prognostic factors, refer to MDM for management, WLE with adequate margins, SLNB recommended

Short case 8

73-year-old woman

Postmenopausal bleeding, thickened endometrium

Specimen: Endometrial biopsy

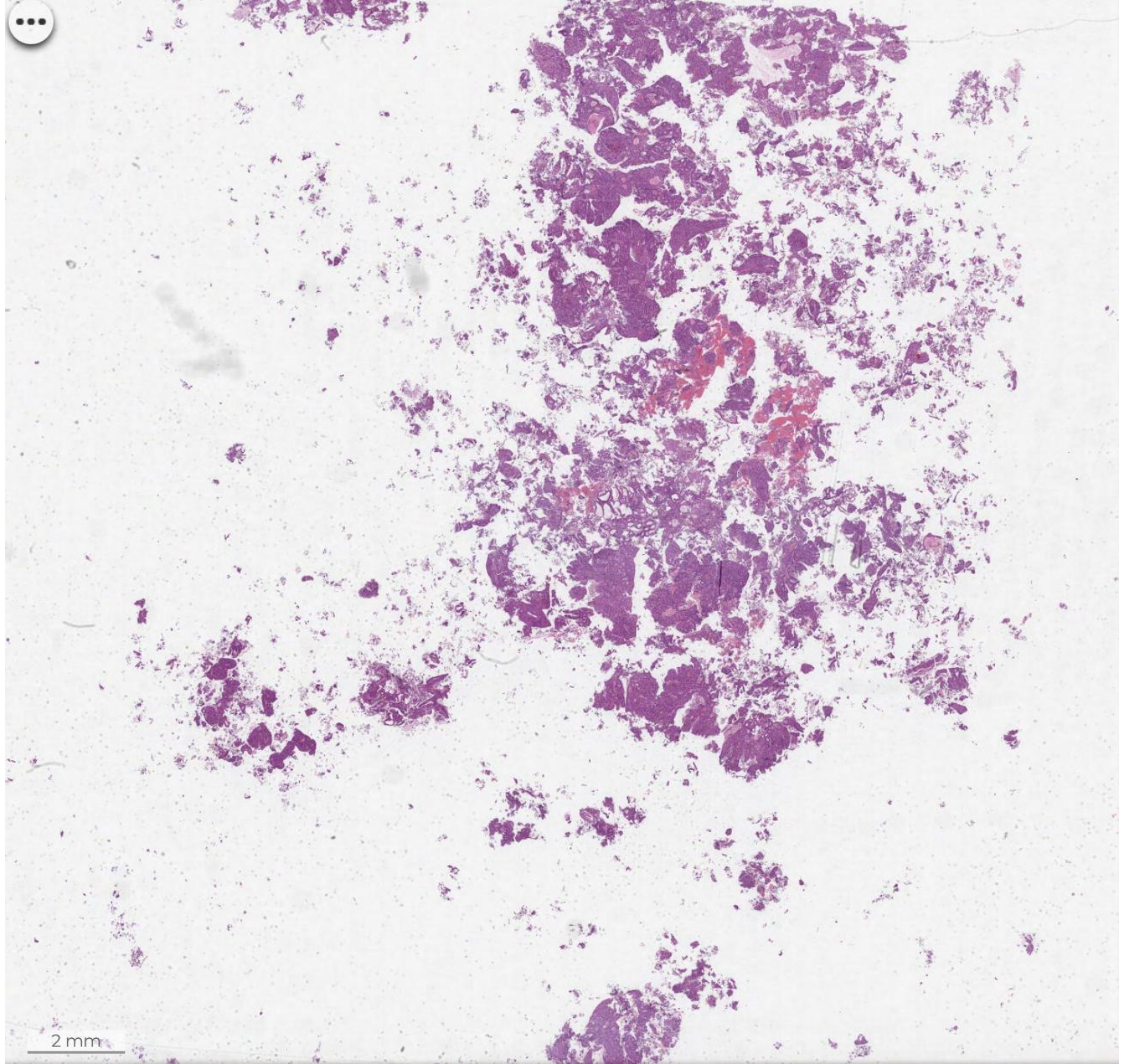
2 mm

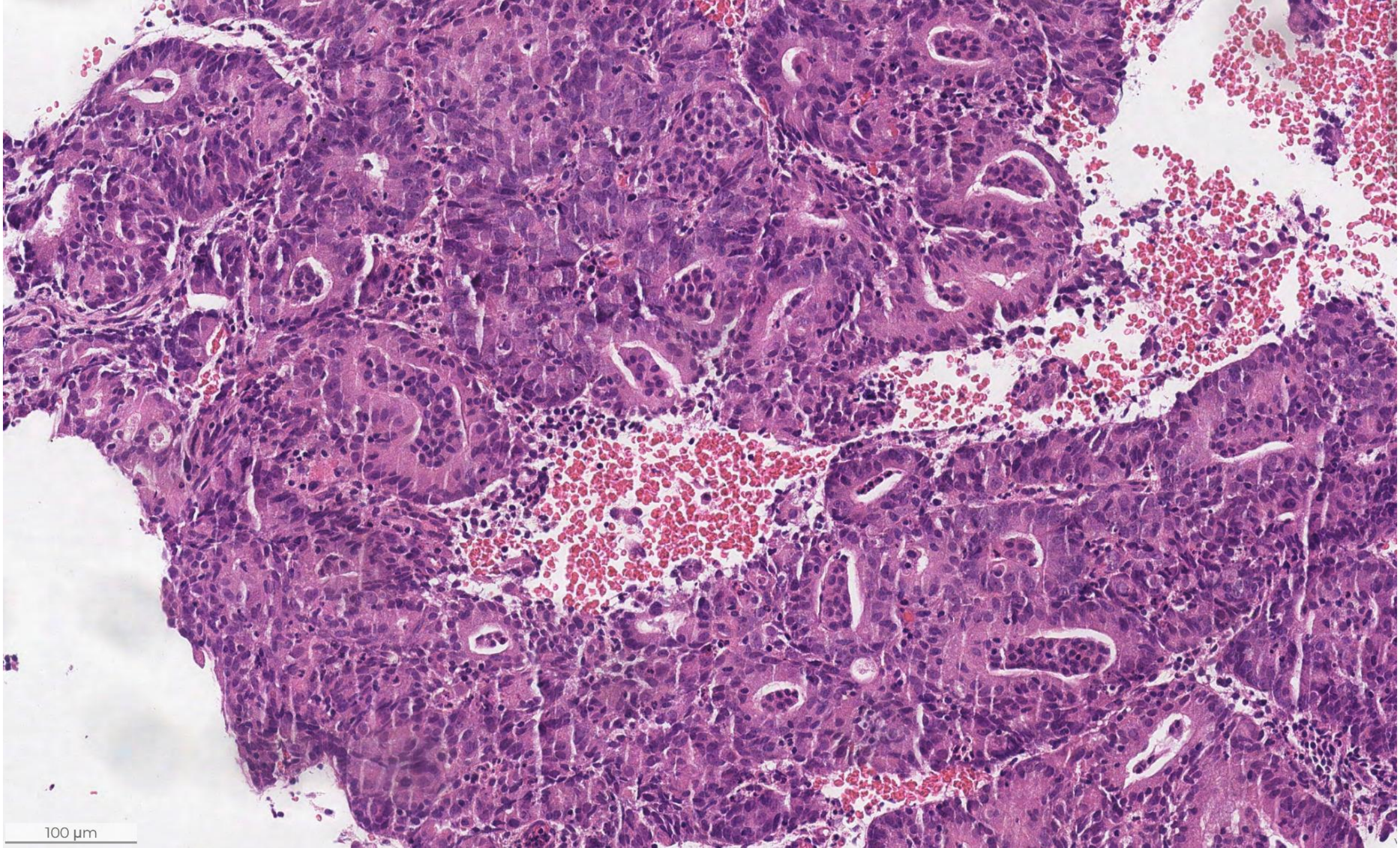
100 µm

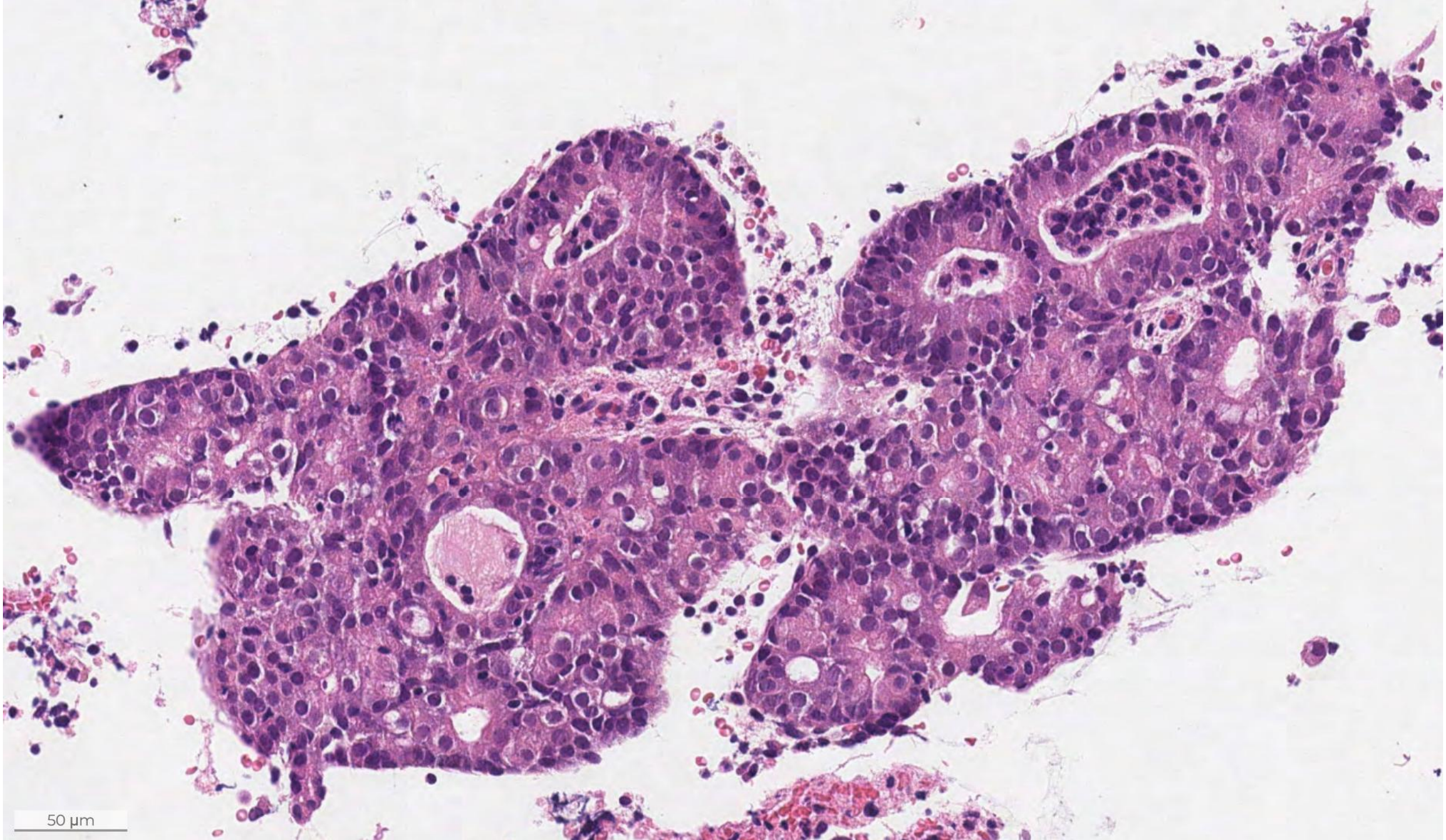
50 µm

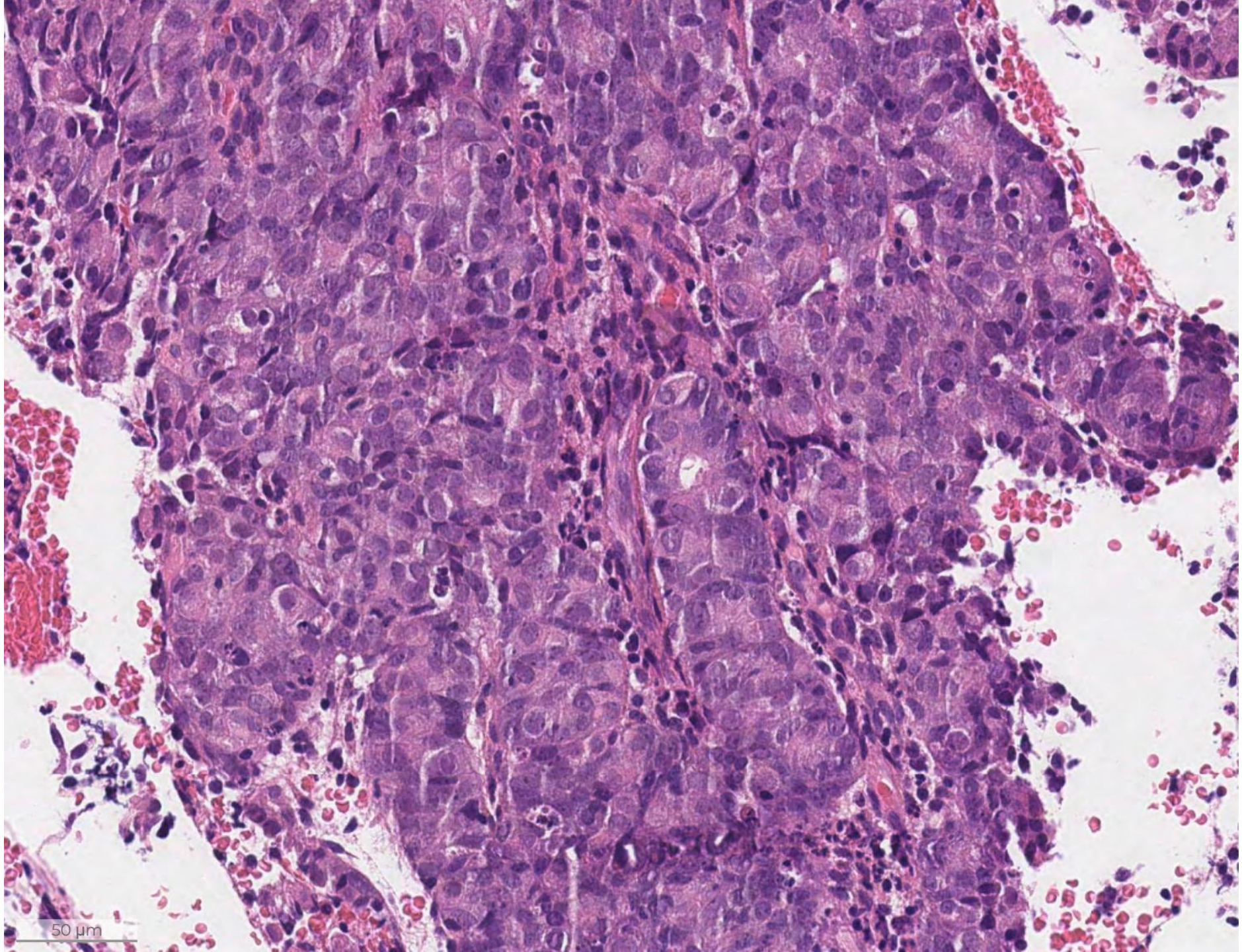
50 µm

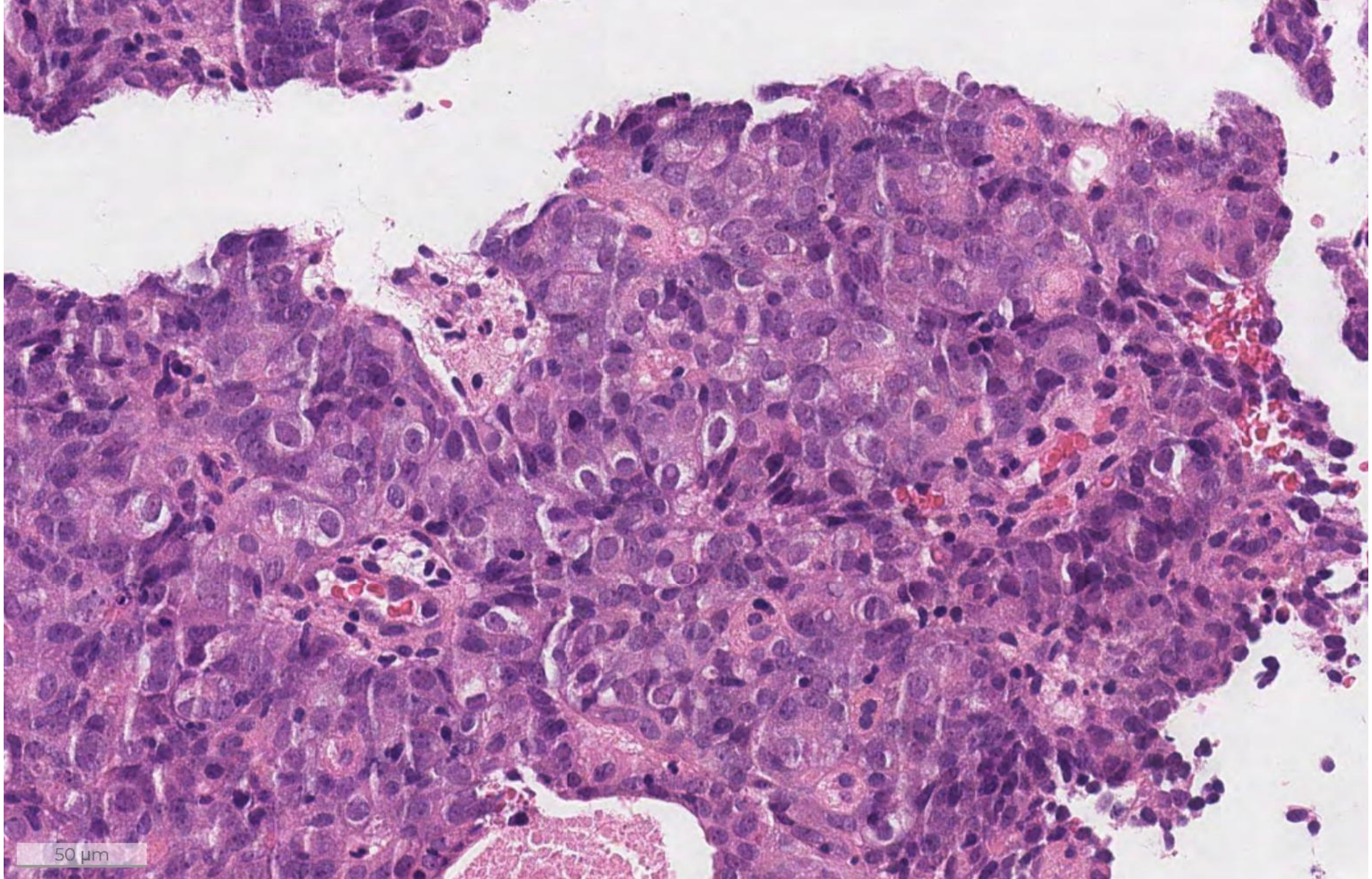
50 µm

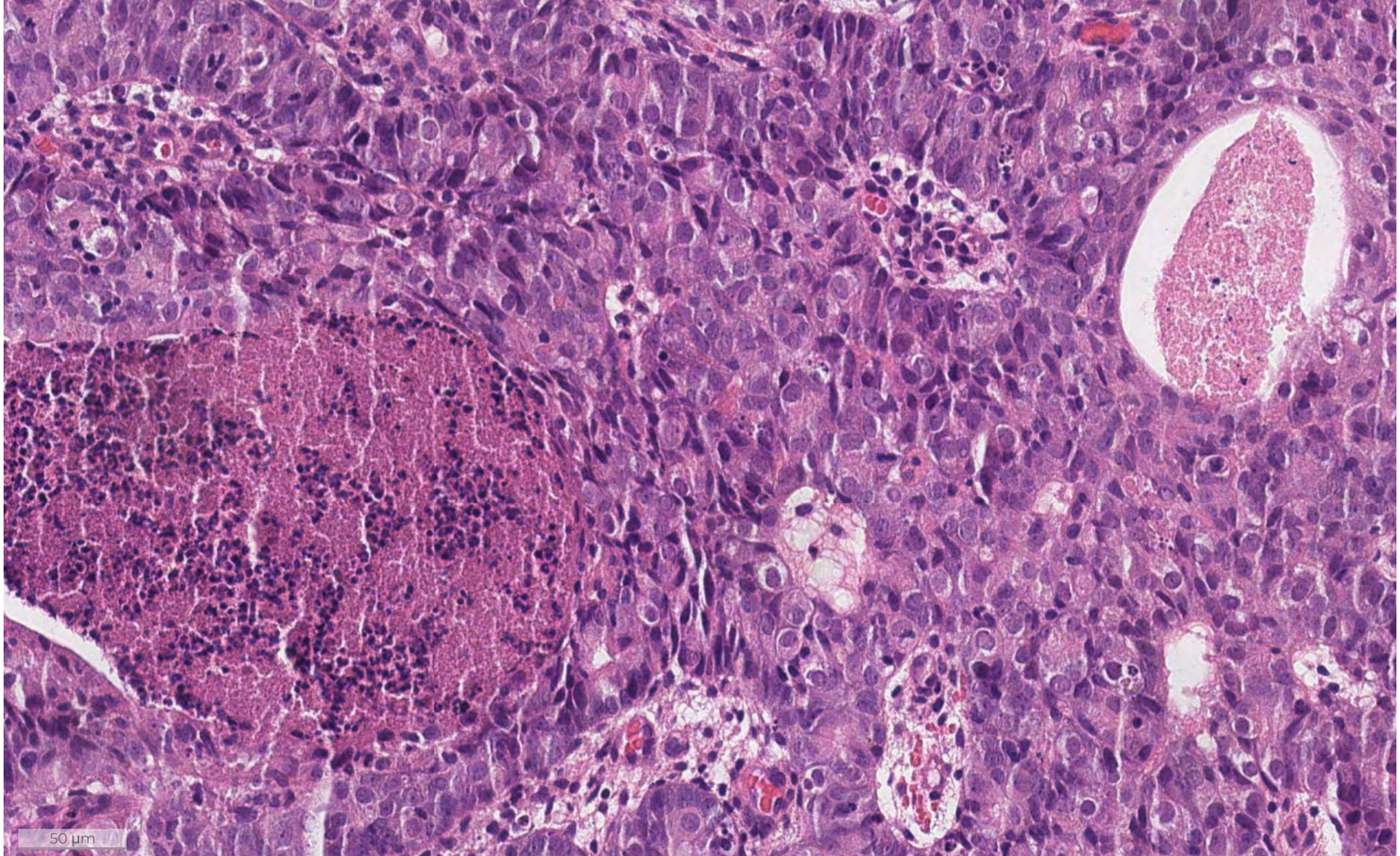
50 µm

Short case 8: Grade 3 endometrioid endometrial adenocarcinoma

- Mostly postmenopausal women (90% > 50 years), median: 63 years
- Abnormal/postmenopausal bleeding
- Vast majority of malignancies of uterine corpus
- Risk factors: early menarche, late menopause, nulliparity, obesity, tamoxifen, PCOS
- Four molecular subtypes: POLE mutated, MMR deficient, p53-mutant and no specific molecular profile (NSMP)
- FIGO grading criteria according to solidity of architecture: G1 (≤ 5%), G2 (6 – 50%), G3 (> 50%)

Short case 8: Grade 3 endometrioid endometrial adenocarcinoma

- (Villo)glandular/solid architecture, columnar cells with pseudostratified nuclei, smooth luminal outlines
- Eosinophilic and granular cytoplasm
- Nuclear atypia mild to moderate with inconspicuous nucleoli (except if high-grade
- Squamous differentiation in 10 – 25%
- IHC: Strong diffuse ER/PR, patchy p16, p53 wt

- DDx: Serous endometrial adeno, endocervical adeno

Short case 8: Grade 3 endometrioid endometrial adenocarcinoma

Mark	Features
1.5 or 1	Fails to diagnose
2	Does not commit to a diagnosis, inadequate morphological description
2.5	Adequate description with confident diagnosis but no additional information
3	Some additional information, as mentioned below:
3.5	Good description with IHC, mention differentials (and how these would differ in terms of morphology, IHC), mention four molecular subtypes, advise MDM discussion for further management

Short case 9

48-year-old woman

Fibroid uterus

Hysterectomy and BSO

Specimen: Fallopian tube 2

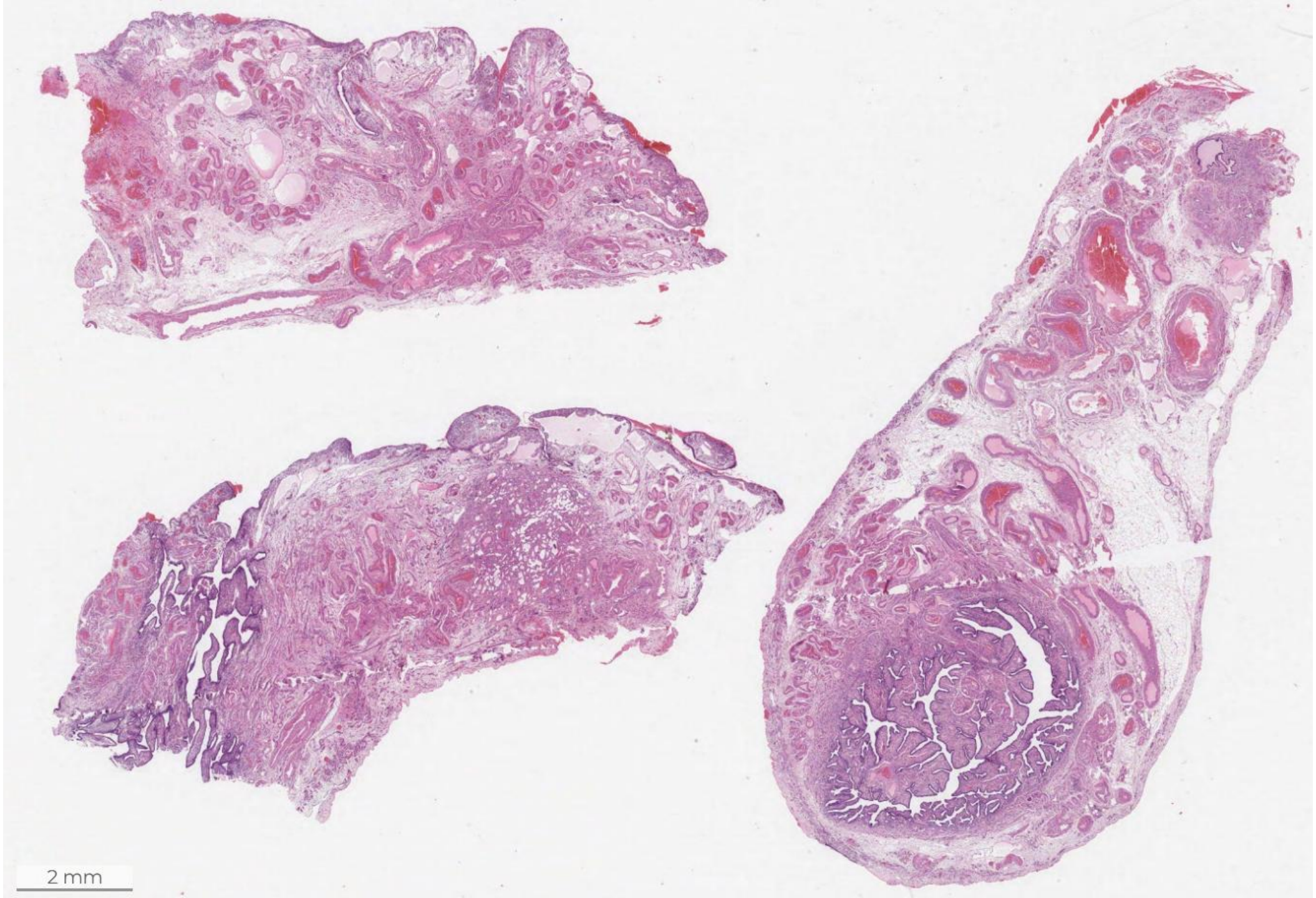
2 mm

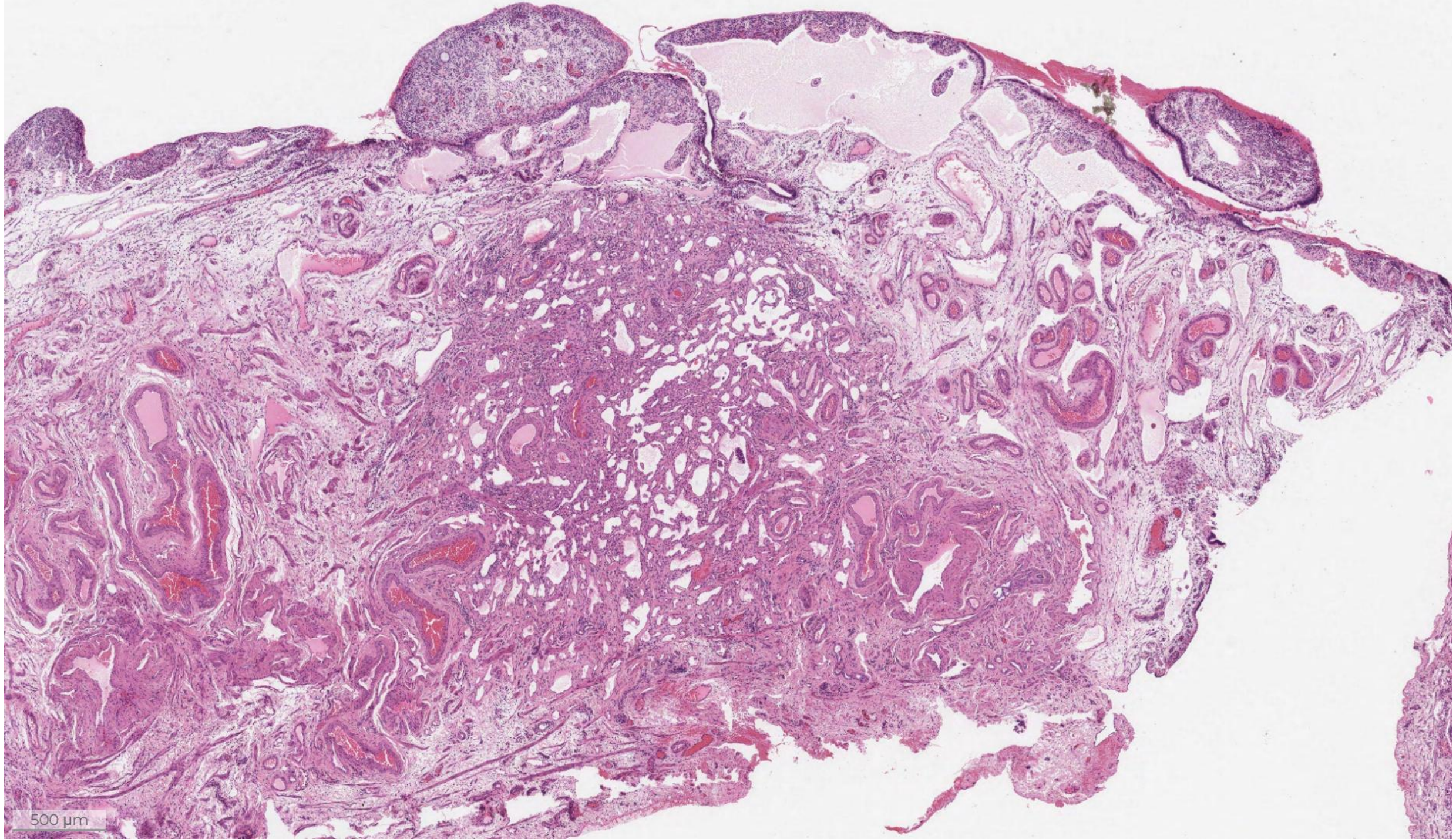
500 µm

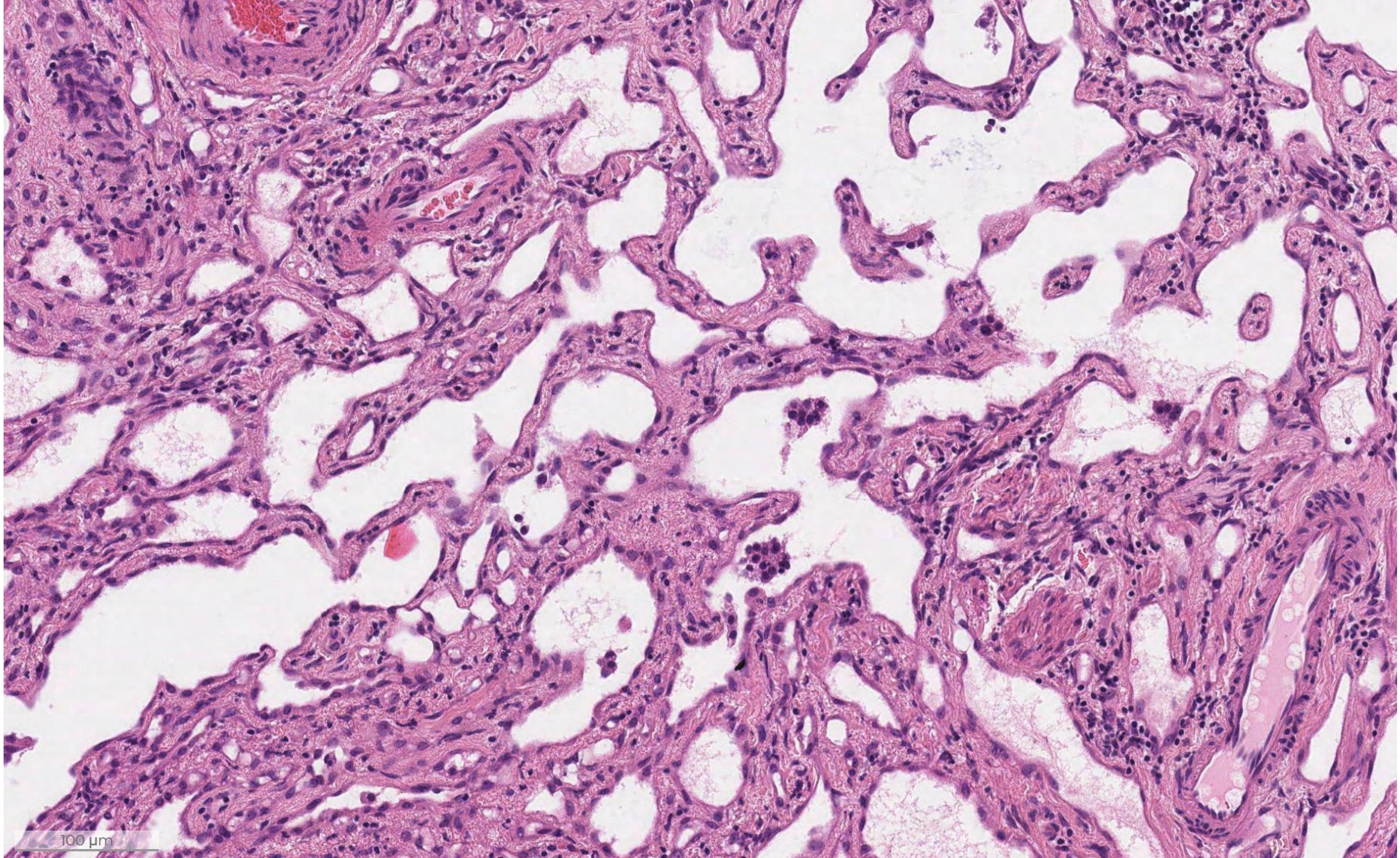
100 µm

Short case 9: Adenomatoid tumour

- Benign, uncommon neoplasm of mesothelial origin
- Locations: uterus, FT, ovary, peritoneum
- Usually asymptomatic, incidental, although can present as mass
- Tubal tumours may measure 1 – 2 cm and are subserosal. Most uterine tumours are in outer half of myometrium

Short case 9: Adenomatoid tumour

- Slit-like, tubular or cystic branching spaces and solid areas intermixed with smooth muscle bundles
- Cuboidal or flat cells with mild to moderate atypia
- IHC not necessary (positive: calretinin, WT1, D2-40, AE1/AE3, CAM5.2)

Short case 9: Adenomatoid tumour

Mark	Features
1.5 or 1	Fails to diagnose
2	Does not commit to a diagnosis, inadequate morphological description
2.5	Adequate description with confident diagnosis but no additional information
3	Good description, mention mesothelial origin, describe confirmatory IHC (although not necessary for Dx)

Short case 10

54-year-old woman

Right ovarian mass

Hysterectomy, BSO, lymph nodes, omentum

Specimen: Right ovary

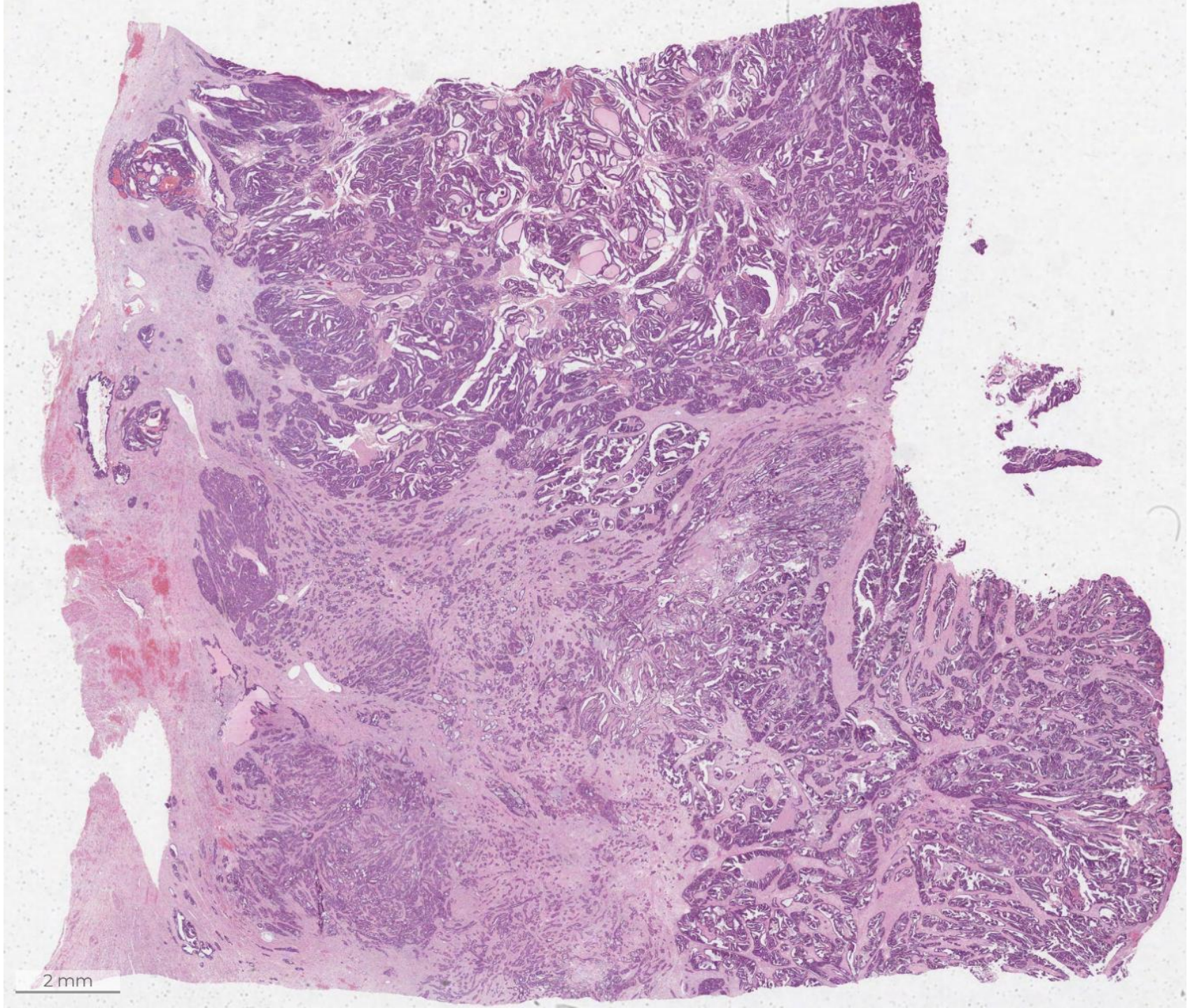
2 mm

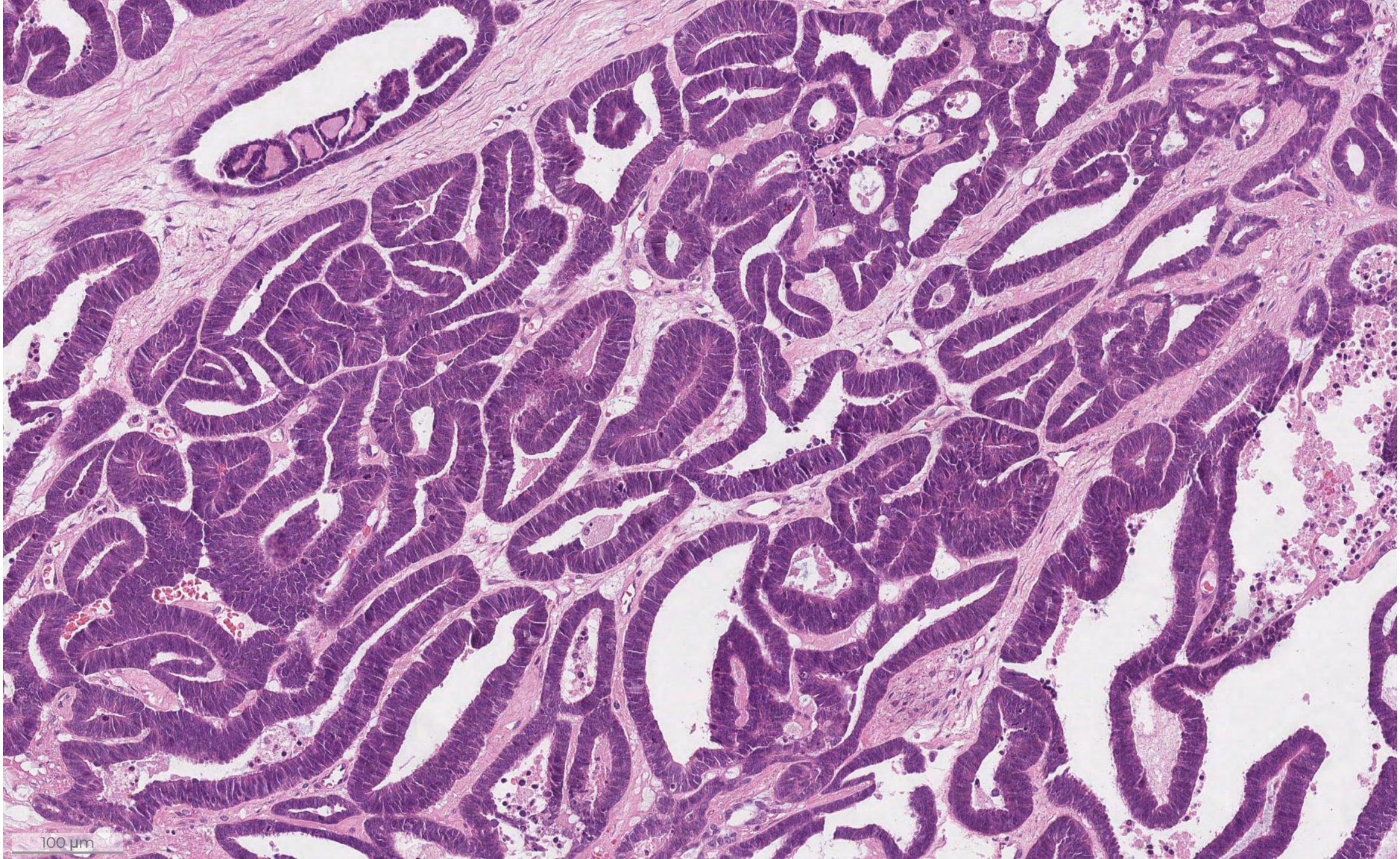
100 µm

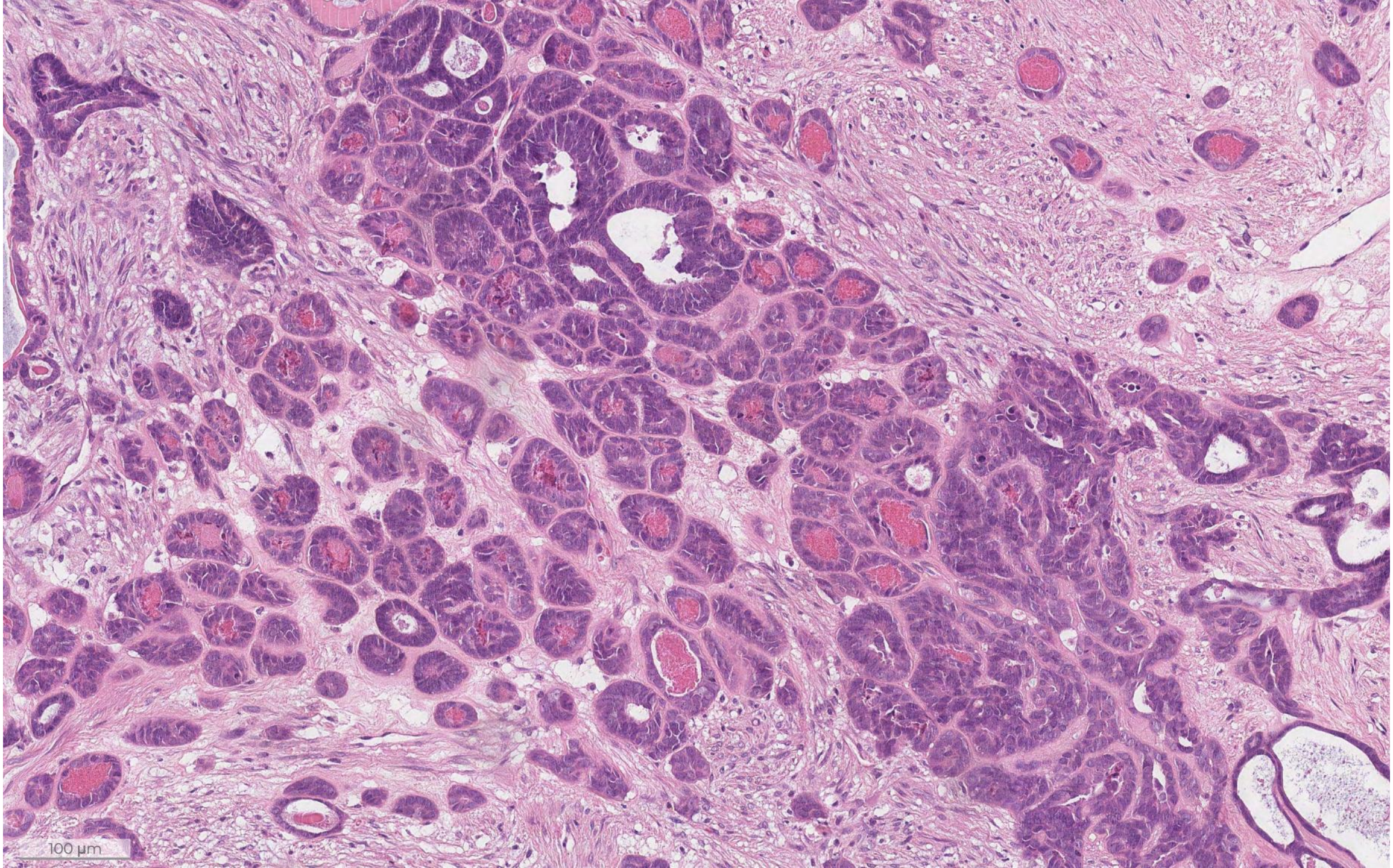
100 µm

Short case 10: Mesonephric-like adenocarcinoma of the ovary

- Presentation: pelvic/abdominal pain. Mostly stage I at presentation
- Usually postmenopausal, commonly associated with endometriosis
- Usually unilateral, variable size (4 – 32 cm), solid or mixed solid/cystic
- Tubular, glandular (pseudoendometrioid), ductal (with slit-like or angulated glands), papillary, and solid patterns
- Dense eosinophilic material within lumen
- Nuclei: dense/vesicular chromatin, inconspicuous nucleoli, crowding
- No squamous or mucinous differentiation

Short case 10: Mesonephric-like adenocarcinoma of the ovary

- Positive: PAX8, GATA3, TTF1, CD10 (luminal staining)
- Negative: ER, PR, WT1
- Usually MMR proficient and p53 wildtype

- High risk of recurrence and metastasis

Short case 10: Mesonephric-like adenocarcinoma of the ovary

Mark	Features
1.5 or 1	Fails to diagnose
2	Does not commit to a diagnosis, inadequate morphological description
2.5	Adequate description with confident diagnosis but no additional information
3	Some additional information, as mentioned below:
3.5	Good description, mention IHC, rare with high risk of recurrence/metastasis, advise MDM discussion

The British Association of Gynaecological Pathologists

Mock Exam

Thank you for your attention

Any questions?