The British Association of Gynaecological Pathologists

Lecturer – Dr William Boyle

Consultant pathologist based at Birmingham Women's Hospital.
Gynaecological and autopsy pathologist.



The British Association of Gynaecological Pathologists

Mock Exam

- Dr Will Boyle
- Birmingham Women's Hospital
- 24th September 2025

Format

Each case dealt with in turn:

1. Recap of histology with discussion
2. Answer
3. Principle histological features
4. Differential diagnosis and how to resolve
5. Extra information

Case 11

- Specimen: Omental biopsy
- Age: 58
- Clinical: Omental and peritoneal nodularity

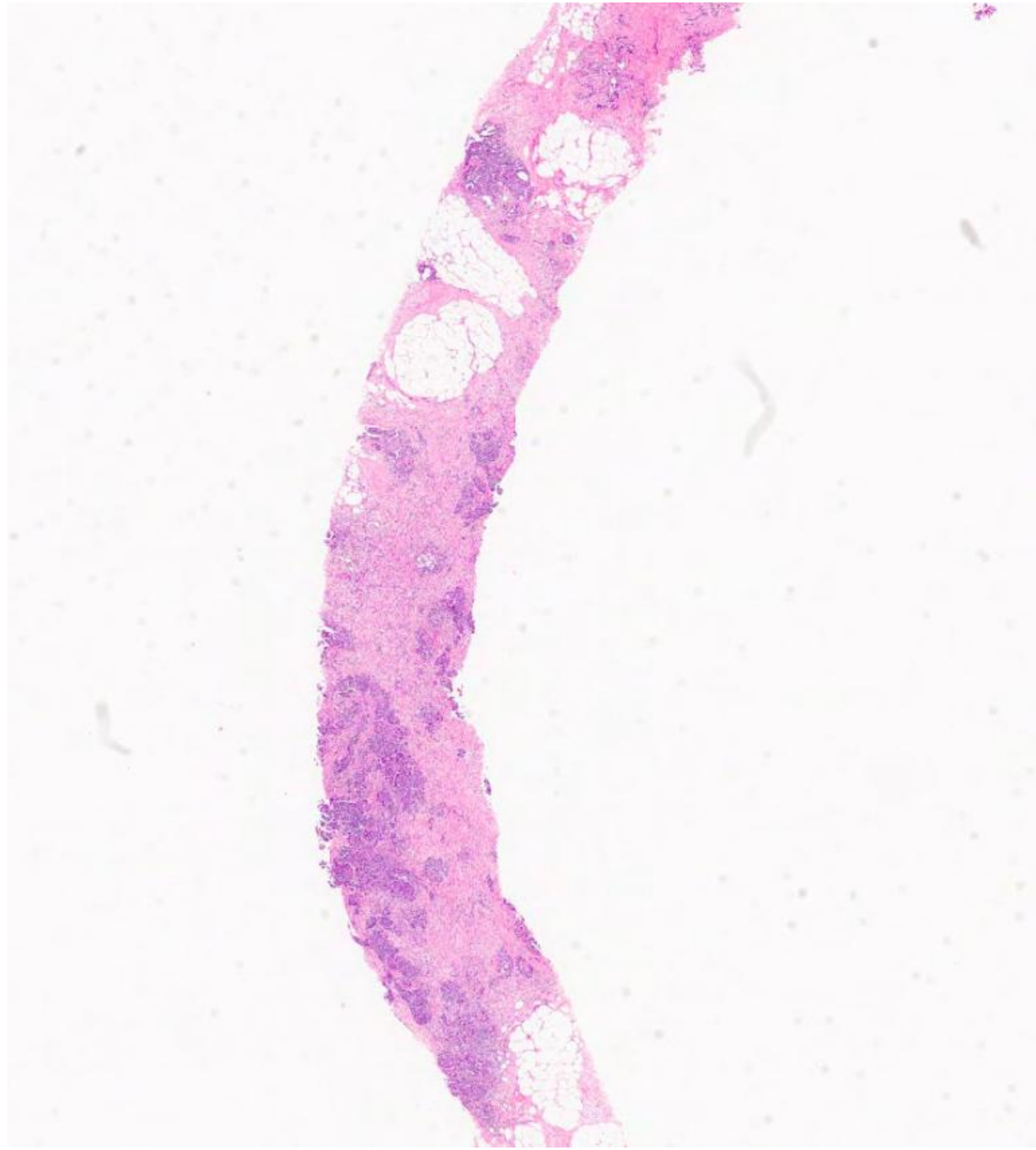

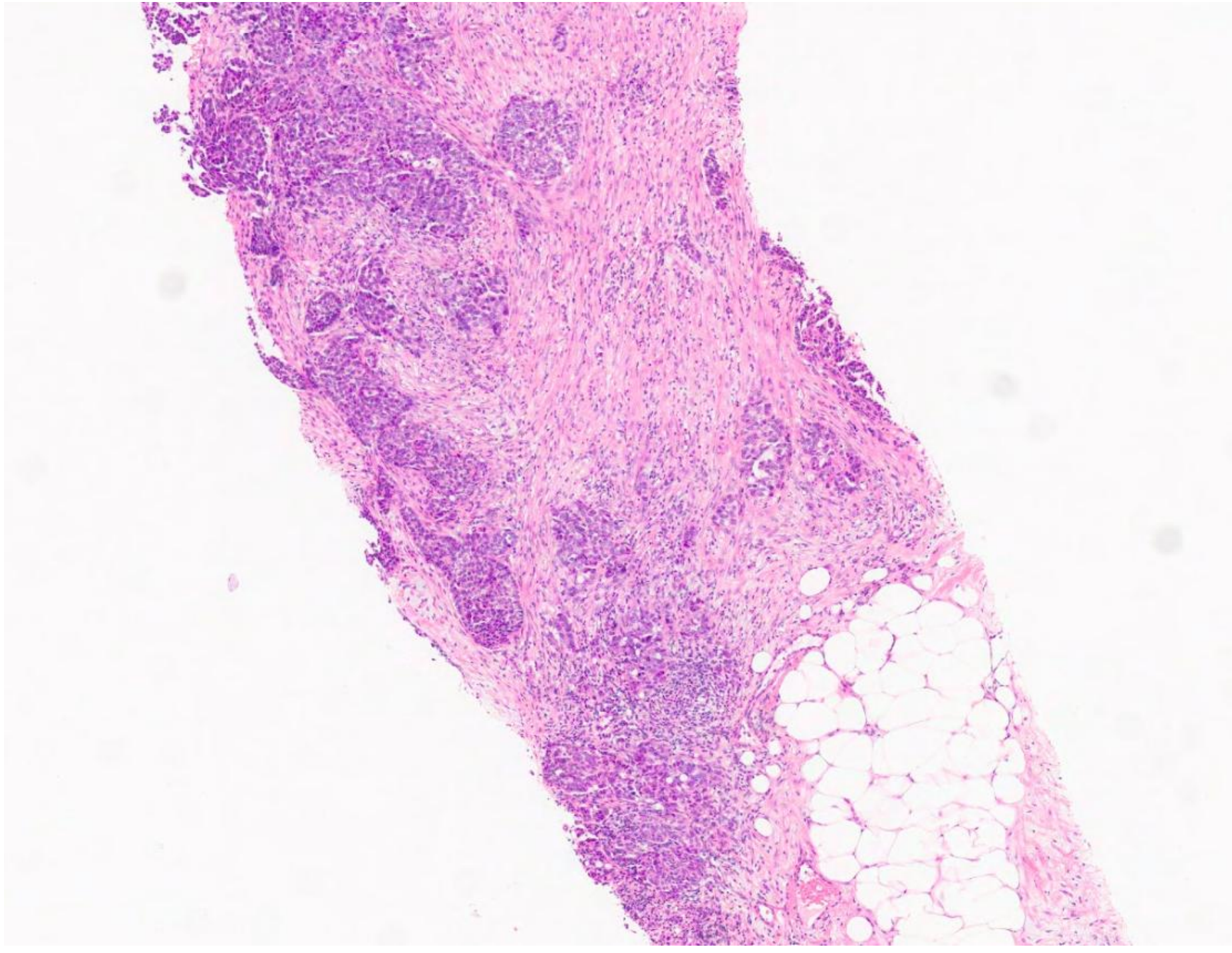

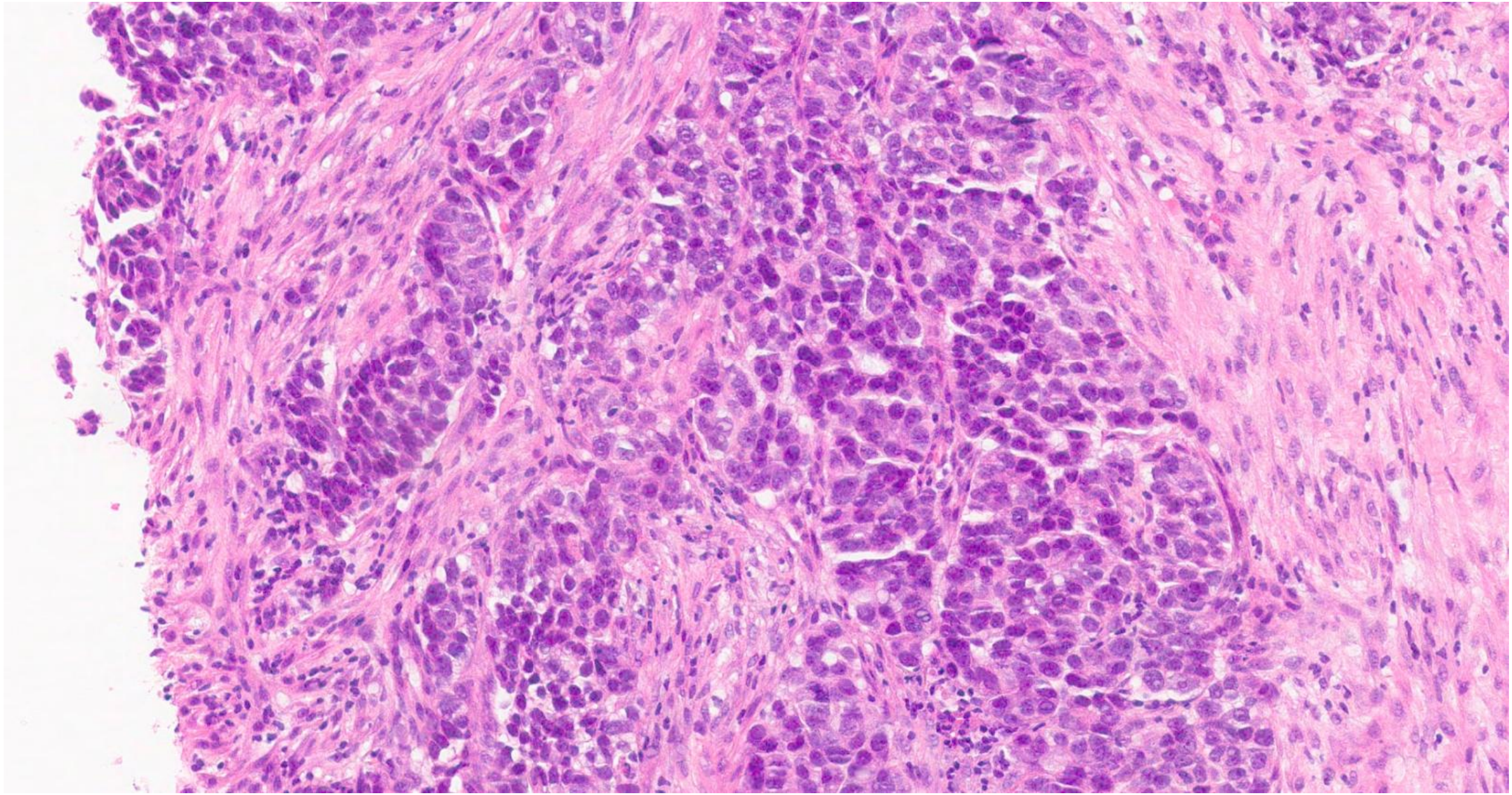

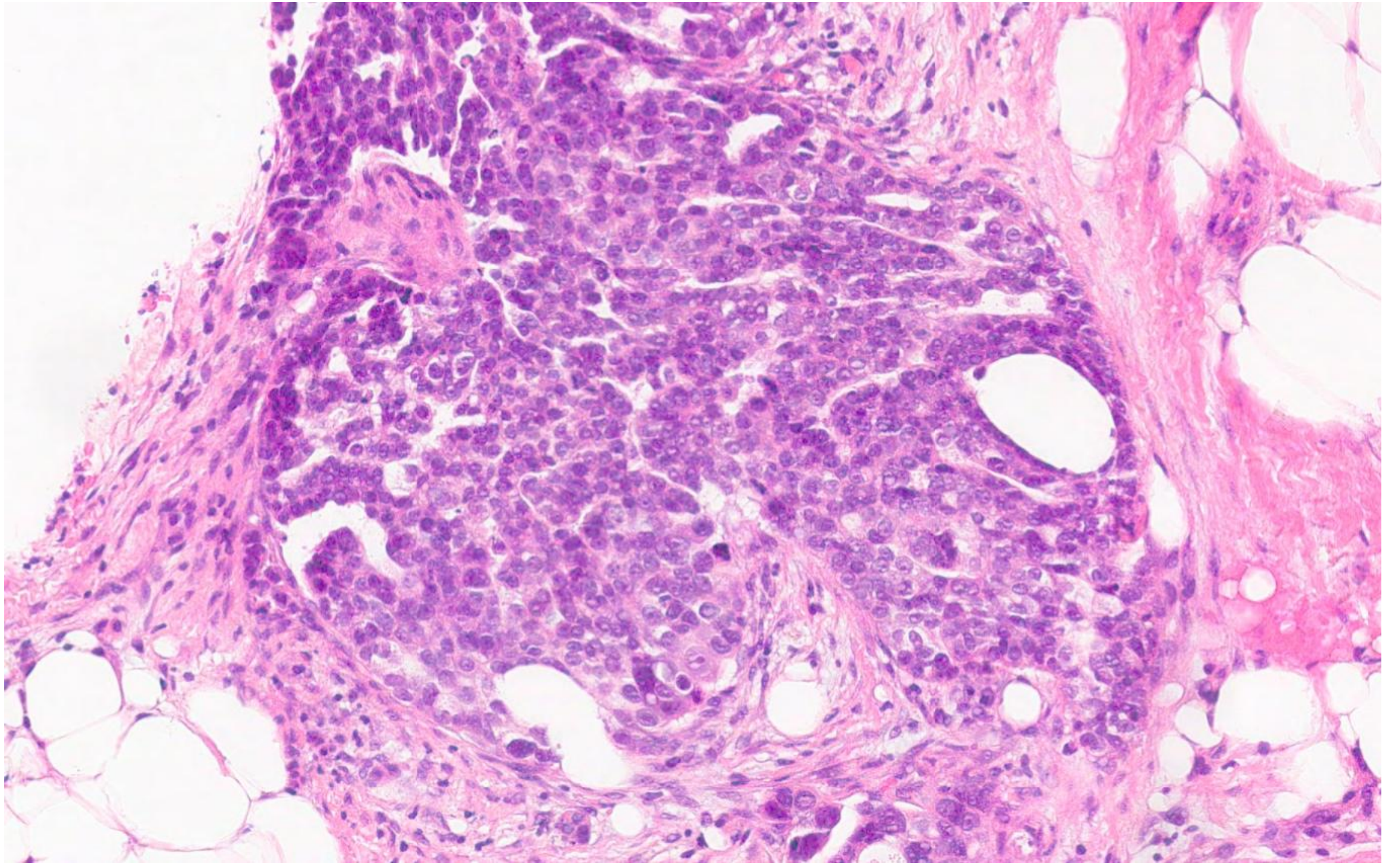

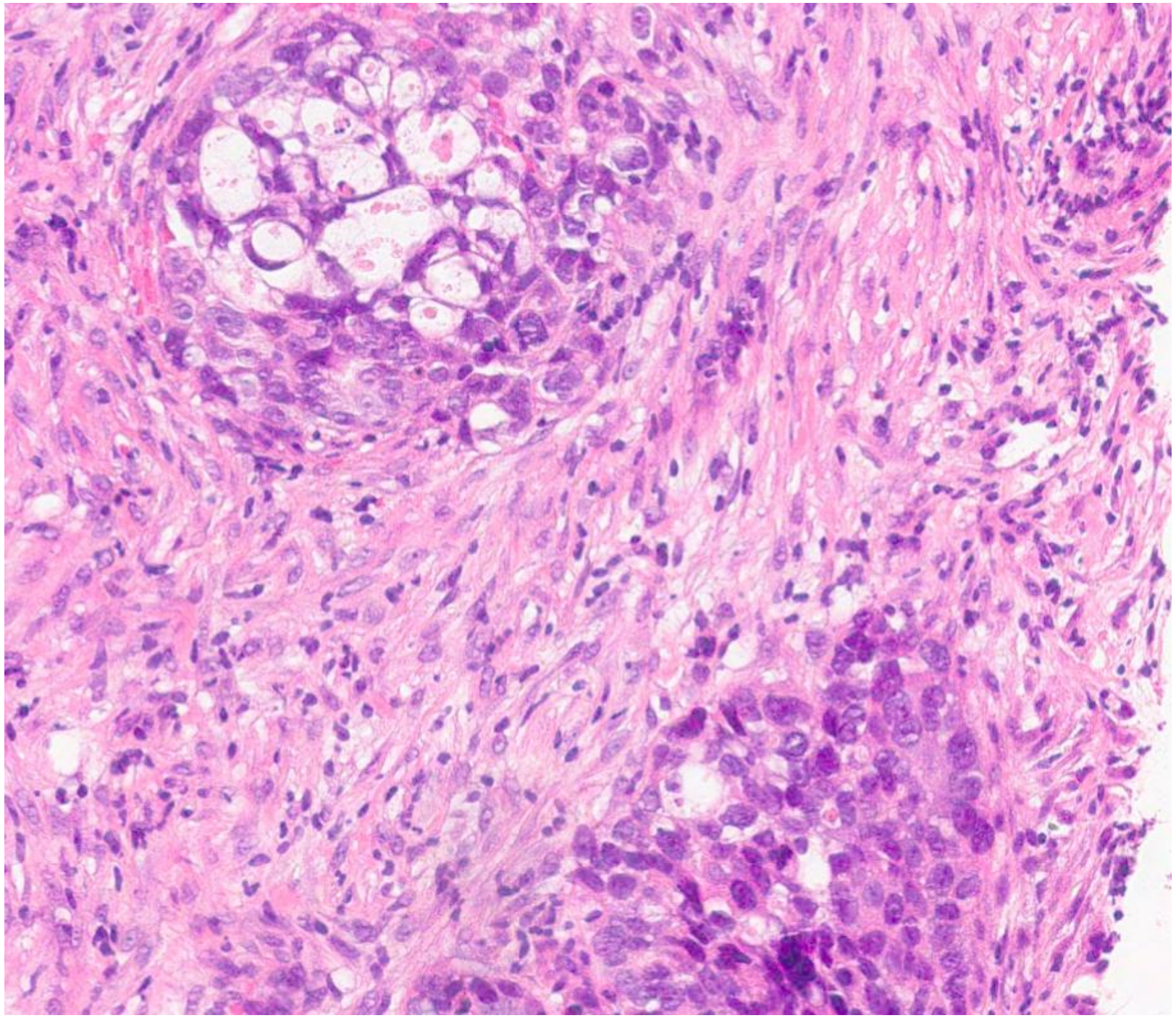

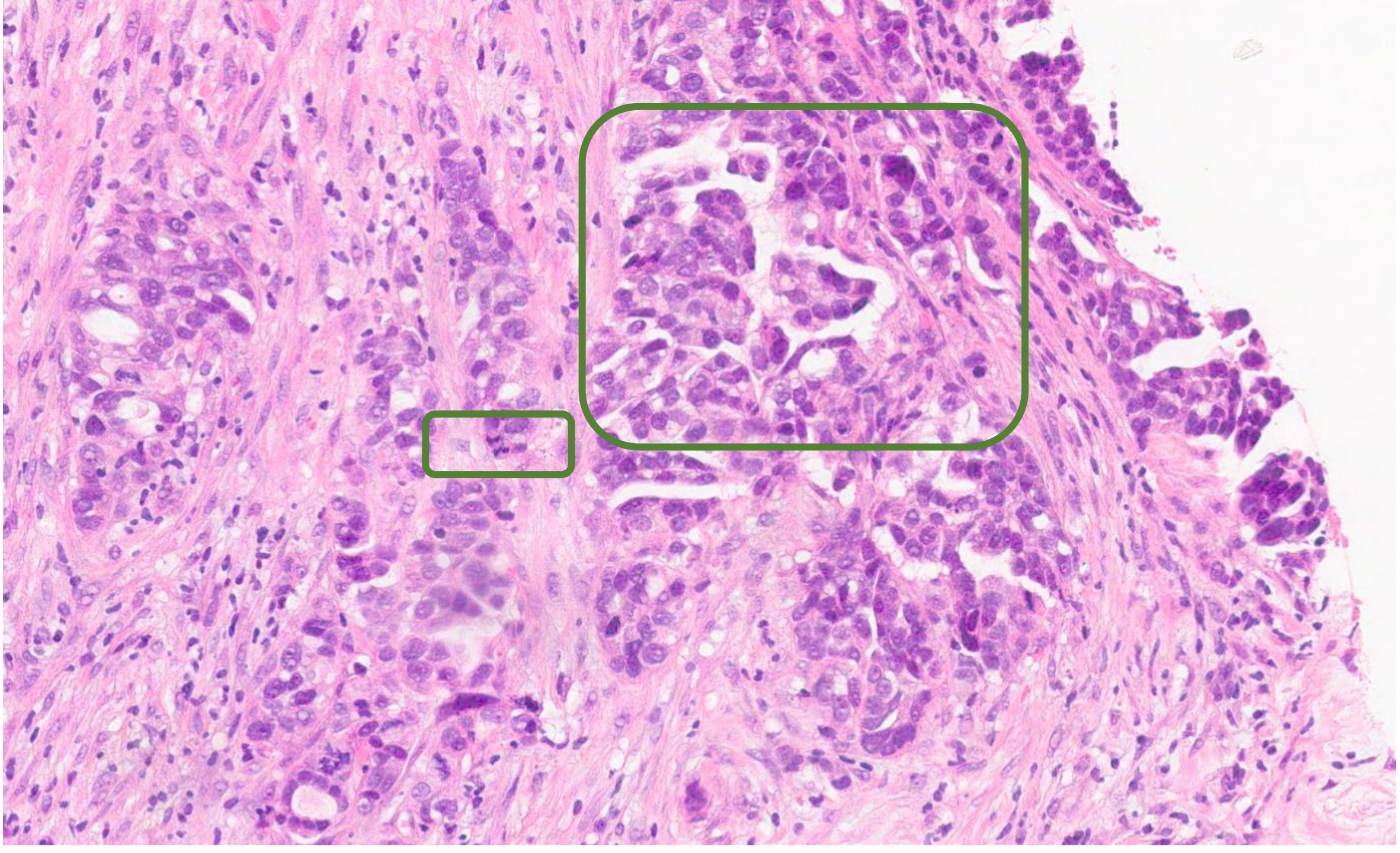

Metastatic high-grade carcinoma

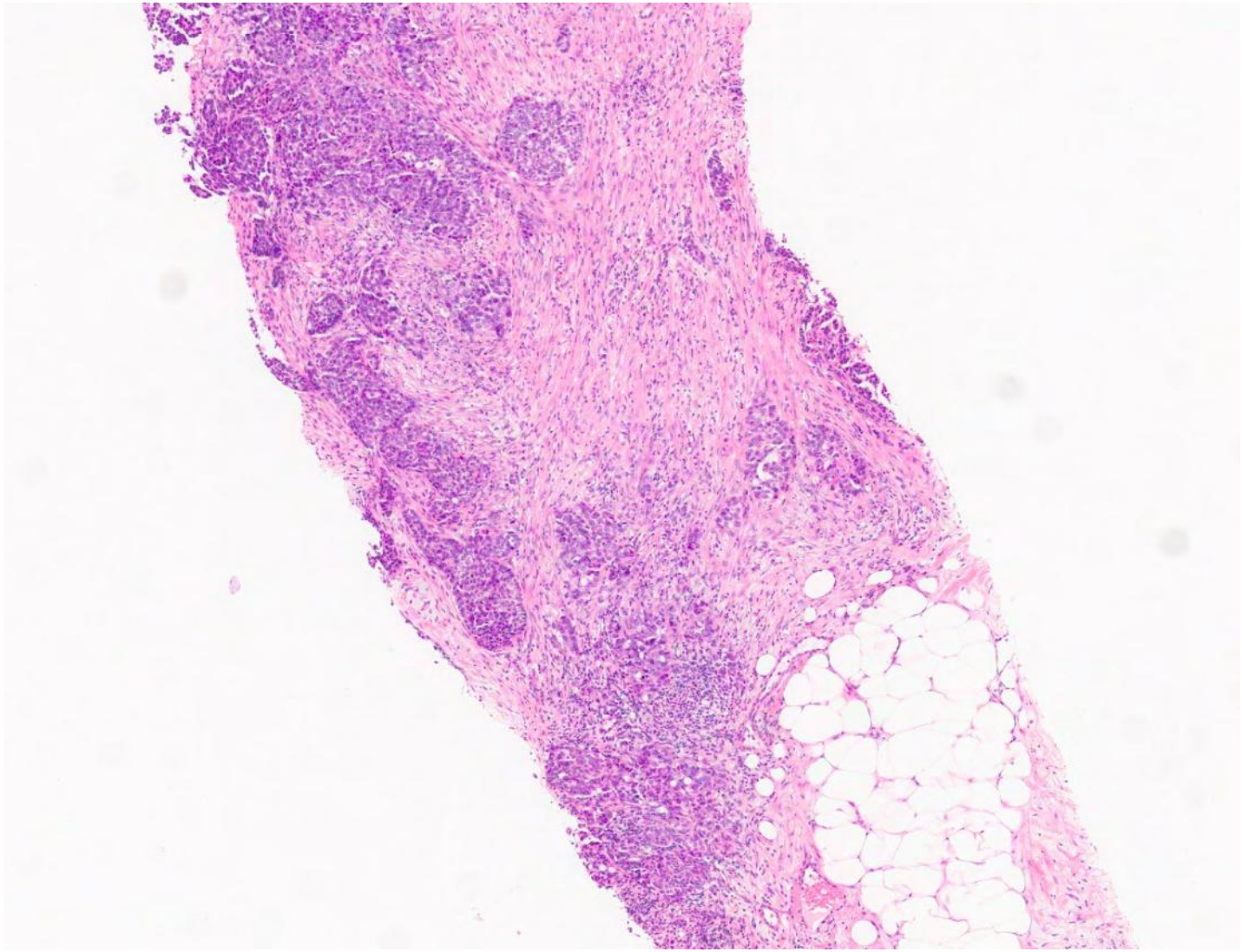

Case 11 – Metastatic high-grade carcinoma

Suggestions for how to answer
In real life, you would do IHC, so do the same now!

- Brief morphological description

- DIAGNOSIS: Metastatic high-grade carcinoma +/- favour metastatic high grade serous carcinoma
- IHC panel to resolve

Case 11 – High-grade serous carcinoma

Principle histological features

- Significant nuclear pleomorphism (> 3x variation in size) with large, bizarre and multinucleated forms, prominent nucleoli.
- High mitotic index (typically >12 per 10 hpf), necrosis.
- Typically shows solid islands, papillary architecture, formation of glands with slit-like luminal spaces.
- May see psammoma bodies.

Case 11 – High-grade serous carcinoma

From experience:

- The atypia may appear more subtle in a diagnostic biopsy compared to a resection.
- The degree of atypia can be variable within a tumour. May see relatively uniform areas with scattered atypical/bizarre cells.
- Papillary architecture may be very focal or absent altogether.

Case 11 – Metastatic high-grade carcinoma

DDx and how to resolve

- Low grade serous carcinoma

Cells with high N:C ratio
Papillary architecture
WT1+

Typically, small clusters/papillae surrounded by clefts
Uniform appearance
<3-fold variation in nuclear size
Mitoses infrequent (<12 / 10 hpf)
Numerous psammoma bodies more likely
p53 wild type

Case 11 – Metastatic high-grade carcinoma

IHC	**P53**	**WT1**	**ER**	**CK7**	**CK20**	**CDX2**	**PAX8**
Tubo-ovarian high grade serous	Aberrant	+	+	+	-	-	+
Uterine serous carcinoma	Aberrant	-	-	+	-	-	+
Endometrioid carcinoma	Usually wild type	-	+	+	-	-	+
Colorectal carcinoma	Usually wild type	-	-	-	+	+	-

Case 11 – High grade serous carcinoma

Extra marks?

- Immuno table
- Purported origin of most extra-uterine high-grade serous carcinomas: STIC
- TP53 the driver mutation so should expect aberrant p53 expression (overexpression, null, cytoplasmic)
- SET appearance more common in BRCA1 mutations: solid, pseudoendometrioid, transitional cell carcinoma-like
- All advanced stage high-grade tubo-ovarian carcinomas should have HRD testing:
  - Predicts response to PARPi
  - Screening for BRCA syndrome

Case 12

- Specimen: Hysterectomy
- Age: 88
- Clinical: 10 cm well-circumscribed myometrial tumour

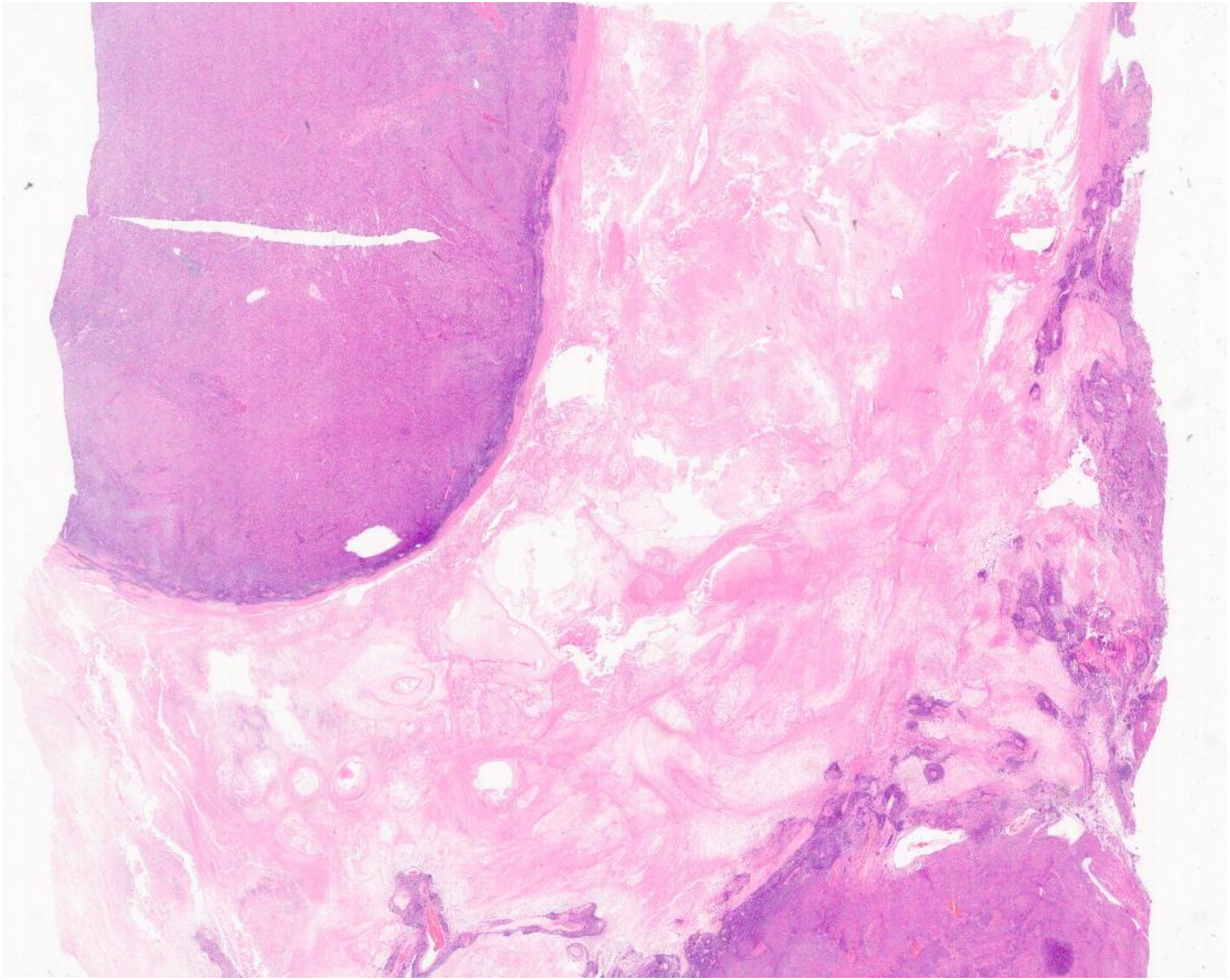

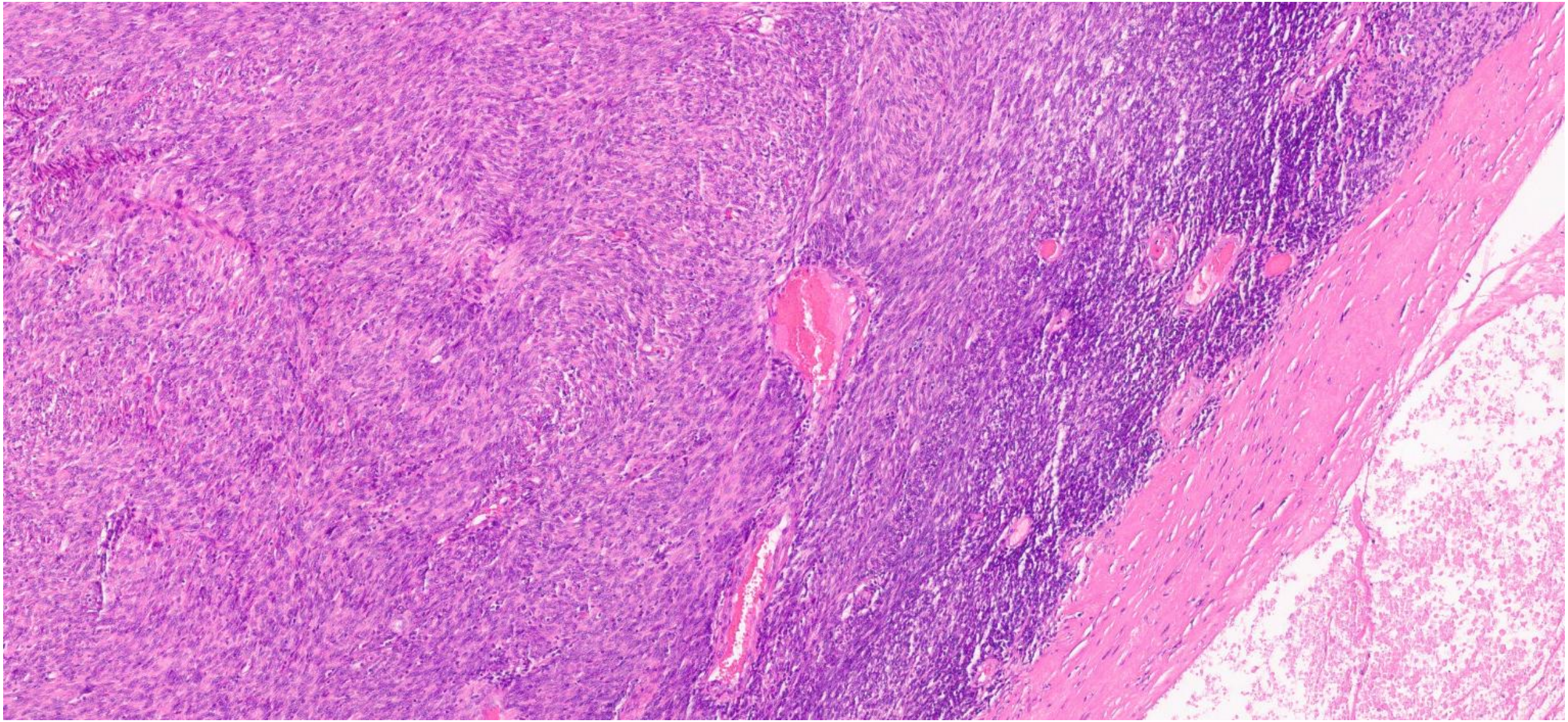

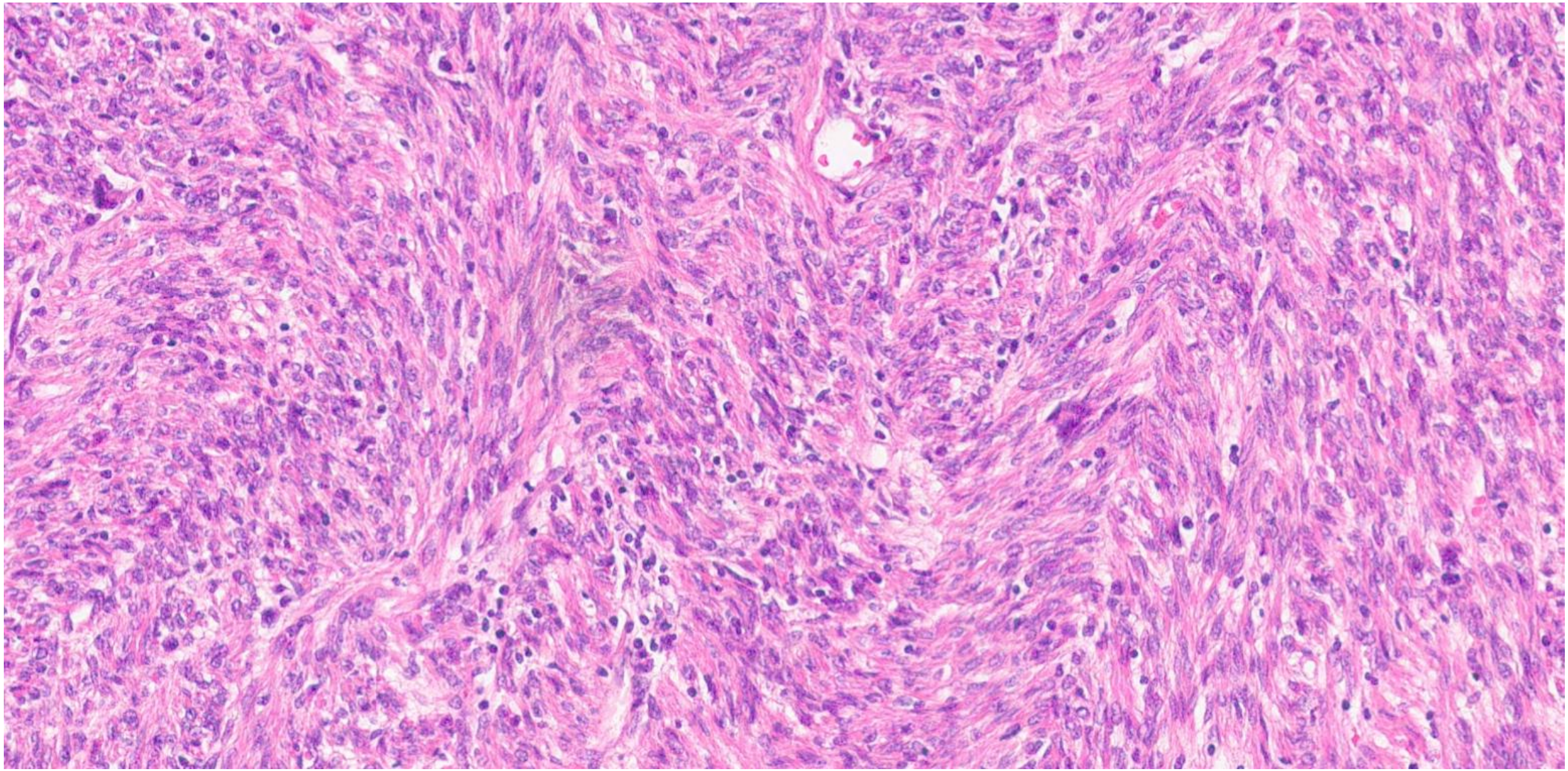

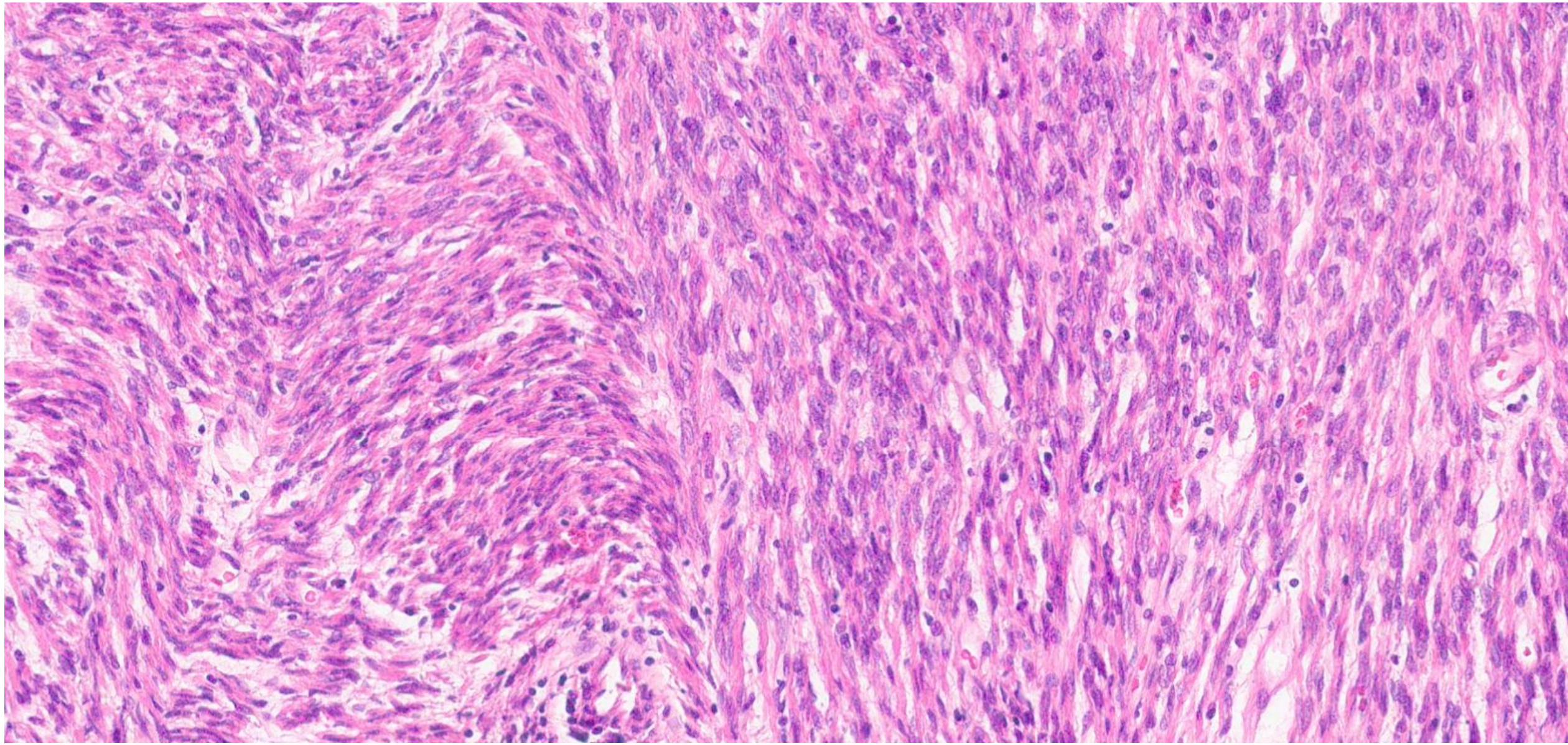

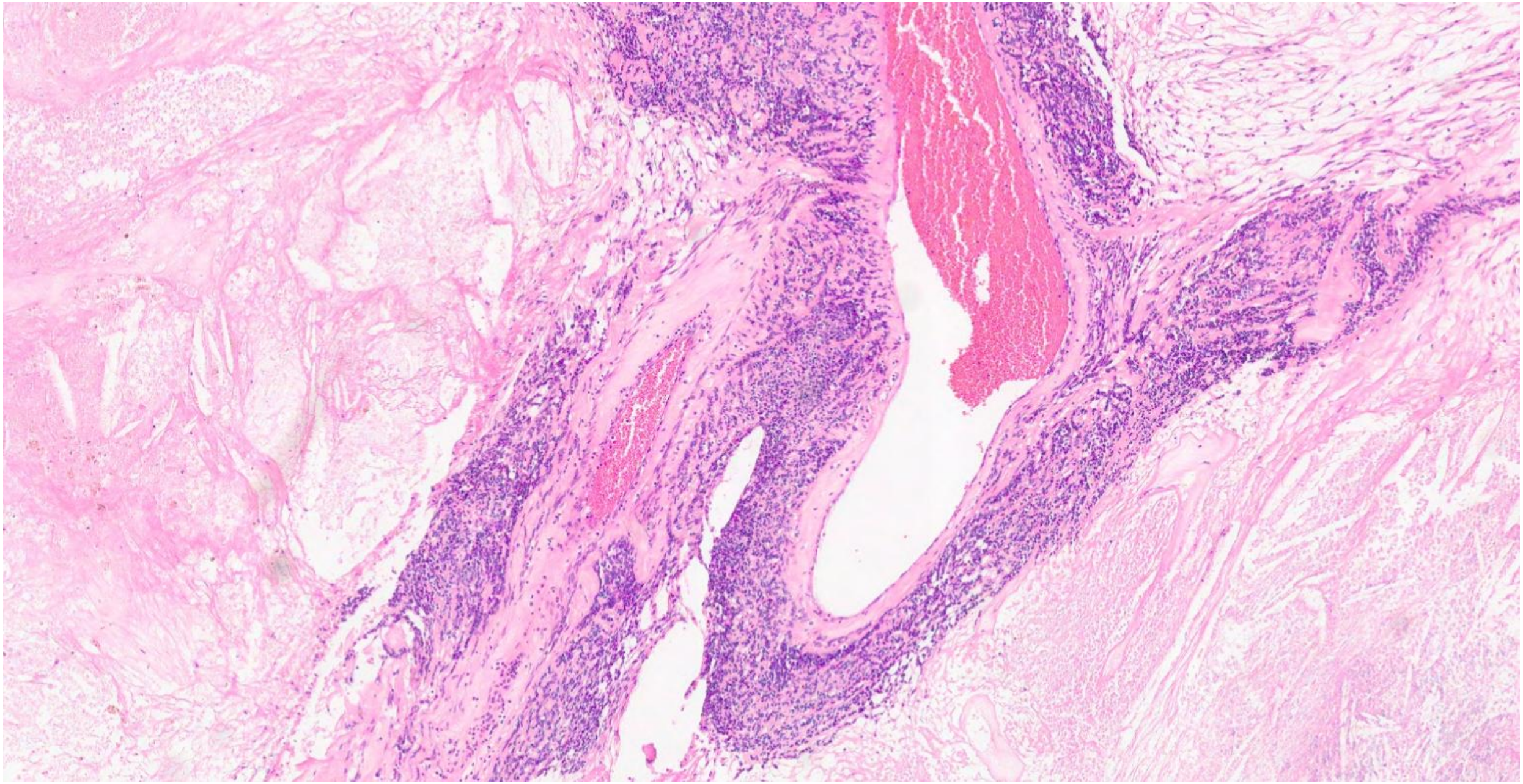

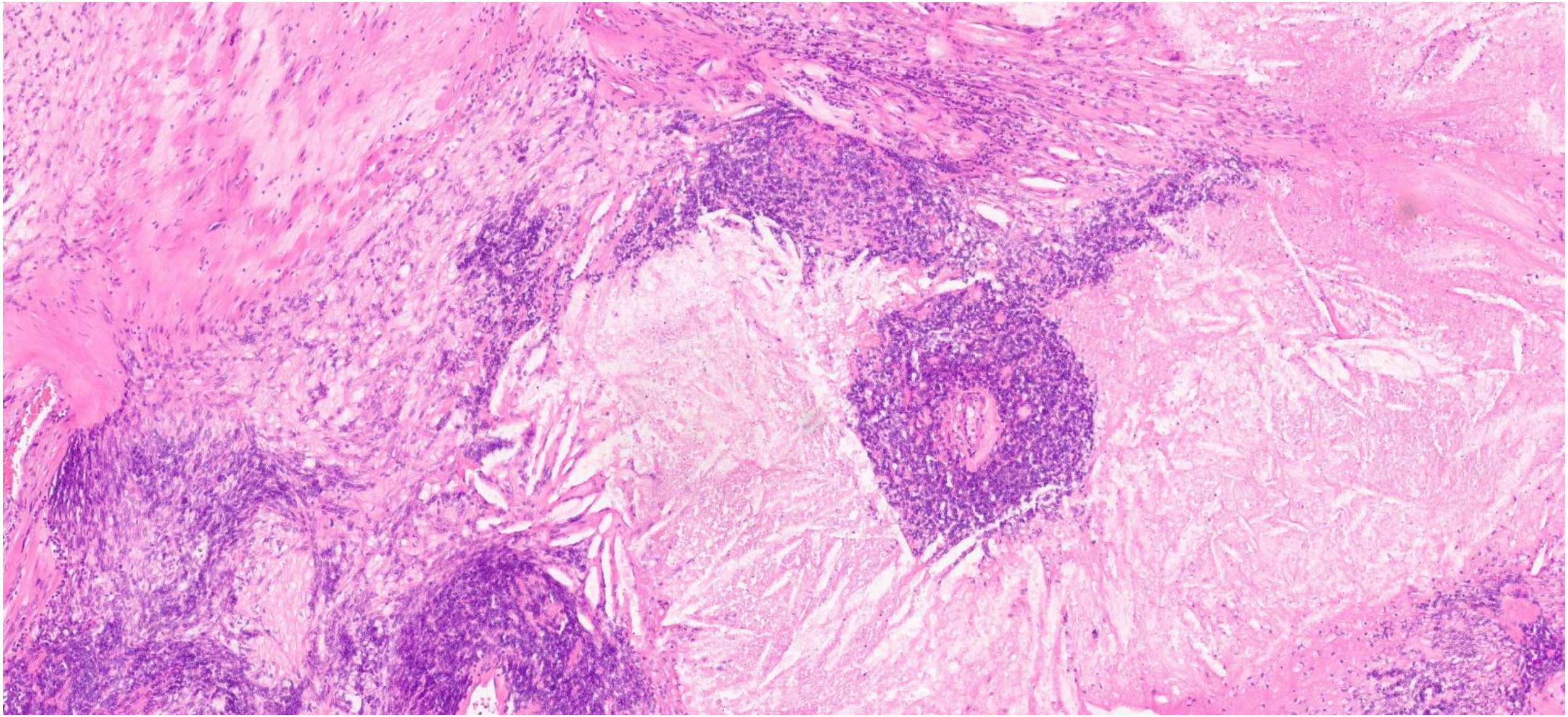

Leiomyosarcoma

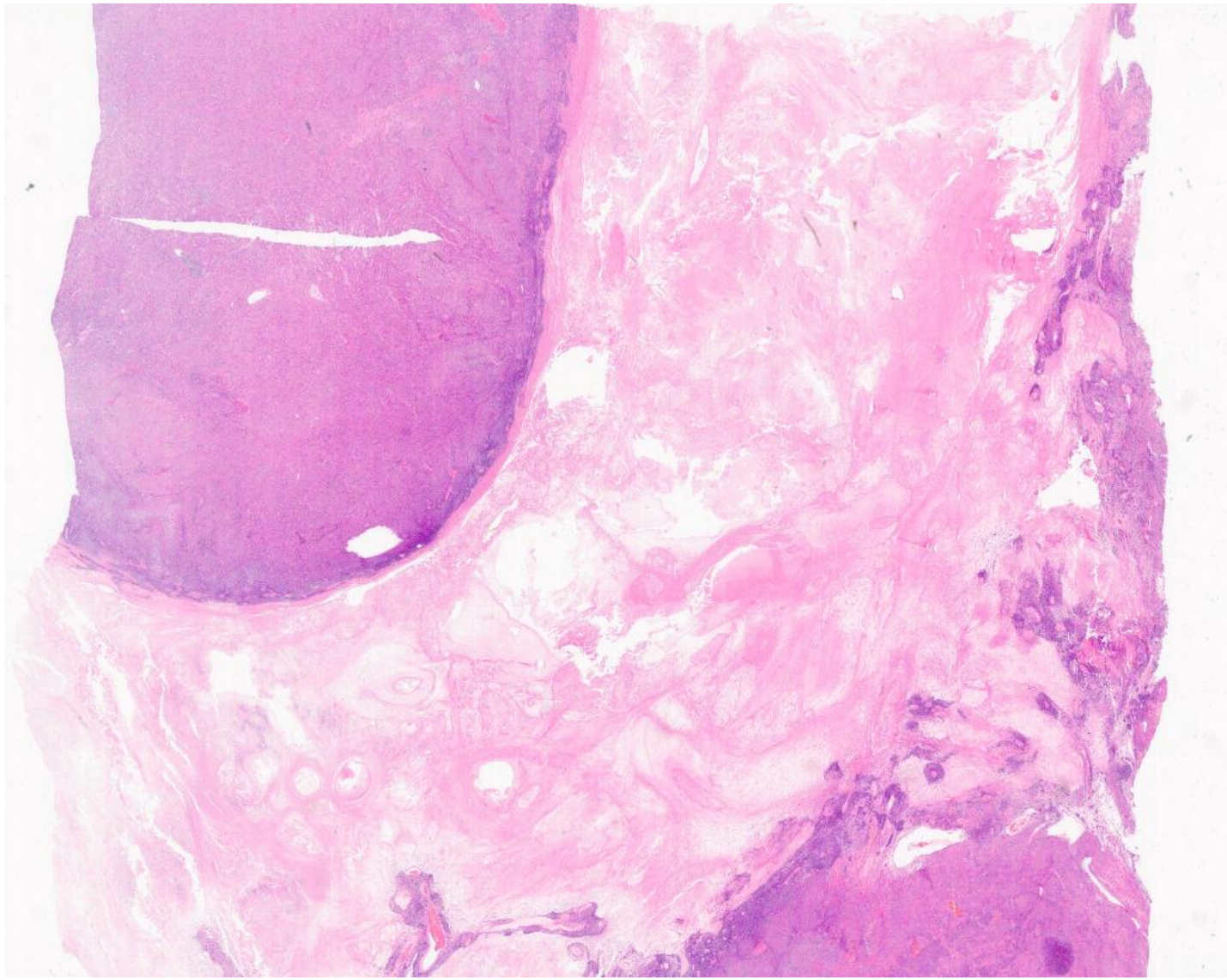

Case 12 – Leiomyosarcoma

Principle histological features

- Cellular fascicles; infiltrative border or pushing border

- Essential diagnostic criteria for conventional/spindle cell type:
  - Requires ***2 of 3*** of the following:

Marked cytological atypia
≥ 10 mitoses / 10 high power fields
Coagulative type tumour cell necrosis

Case 12 – Leiomyosarcoma

Principle histological features

- Cellular fascicles; infiltrative border or pushing border

- Essential diagnostic criteria for conventional/spindle cell type:
  - Requires ***2 of 3*** of the following:

Marked cytological atypia
≥ 10 mitoses / 10 high power fields
Coagulative type tumour cell necrosis

- Spindle / elongated cells
- Hyperchromatic nuclei with moderate nuclear pleomorphism
- Multinucleated and osteoclast-like giant cells may be seen

Case 12 – Leiomyosarcoma

Principle histological features

- Cellular fascicles; infiltrative border or pushing border

- Essential diagnostic criteria for conventional/spindle cell type:
  - Requires ***2 of 3*** of the following:

Marked cytological atypia
≥ 10 mitoses / 10 high power fields
Coagulative type tumour cell necrosis

- Abrupt transition from viable tumor cells to necrotic cells
- Granulation tissue surrounding necrosis is absent
- Viable tumour surrounds large vessels

Case 12 – Leiomyosarcoma

Principle histological features

- Less common types (difficult):
  - Myxoid leiomyosarcoma
    - Hypocellular with myxoid stroma (beware hydropic change); macro assessment important
    - Atypia, but can be subtle
    - Different histological criteria for malignancy
  - Epithelioid leiomyosarcoma:
    - Greater than 50% round or polygonal cells with eosinophilic or clear cytoplasm
    - Nests, cords and sheets
    - Different histological criteria for malignancy

Case 12 – Leiomyosarcoma

IHC	CD10	ALK1	Caldesmon	SMA	Desmin	ER	p53	HMB-45
Leiomyosarcoma	+/-	-	+	+	+	+	May be aberrant	-
LG-Endometrial stromal sarcoma	Diffuse +	-	-	-	-	+	Wild type	-
PEComa	-/+	-	+	+/-	+/-	-	Wild type	+
Inflammatory myofibroblastic tumour	-/+	+	+	+	+	-	Wild type	-

Case 12 – Leiomyosarcoma

DDx and how to resolve

▪ Leiomyoma variants	Fascicular architecture Can be cellular Can be mitotically active Can show nuclear atypia + Smooth muscle markers	Does not have 2 of 3 histological features of LMS Mitotic activity below threshold for STUMP / malignancy Atypia symplastic and usually not diffuse p53 always expected to be wild type
▪ Smooth muscle tumour of uncertain malignant potential	Smooth muscle tumour Coagulative necrosis or mitotic activity or marked atypia	Only has 1 of the 3 LMS criteria

Case 12 – Leiomyosarcoma

Extra marks?

- Immuno table

- High recurrence rate (50 - 70%) regardless of stage at initial diagnosis
- More favorable prognosis if tumor is < 5 cm and confined to the uterus
- No good evidence for adjuvant treatments, chemorads/hormonal therapy palliative in advanced/recurrent disease

Case 13

- Specimen: Ovary
- Age: 29
- Clinical: Hysterectomy for left adnexal mass

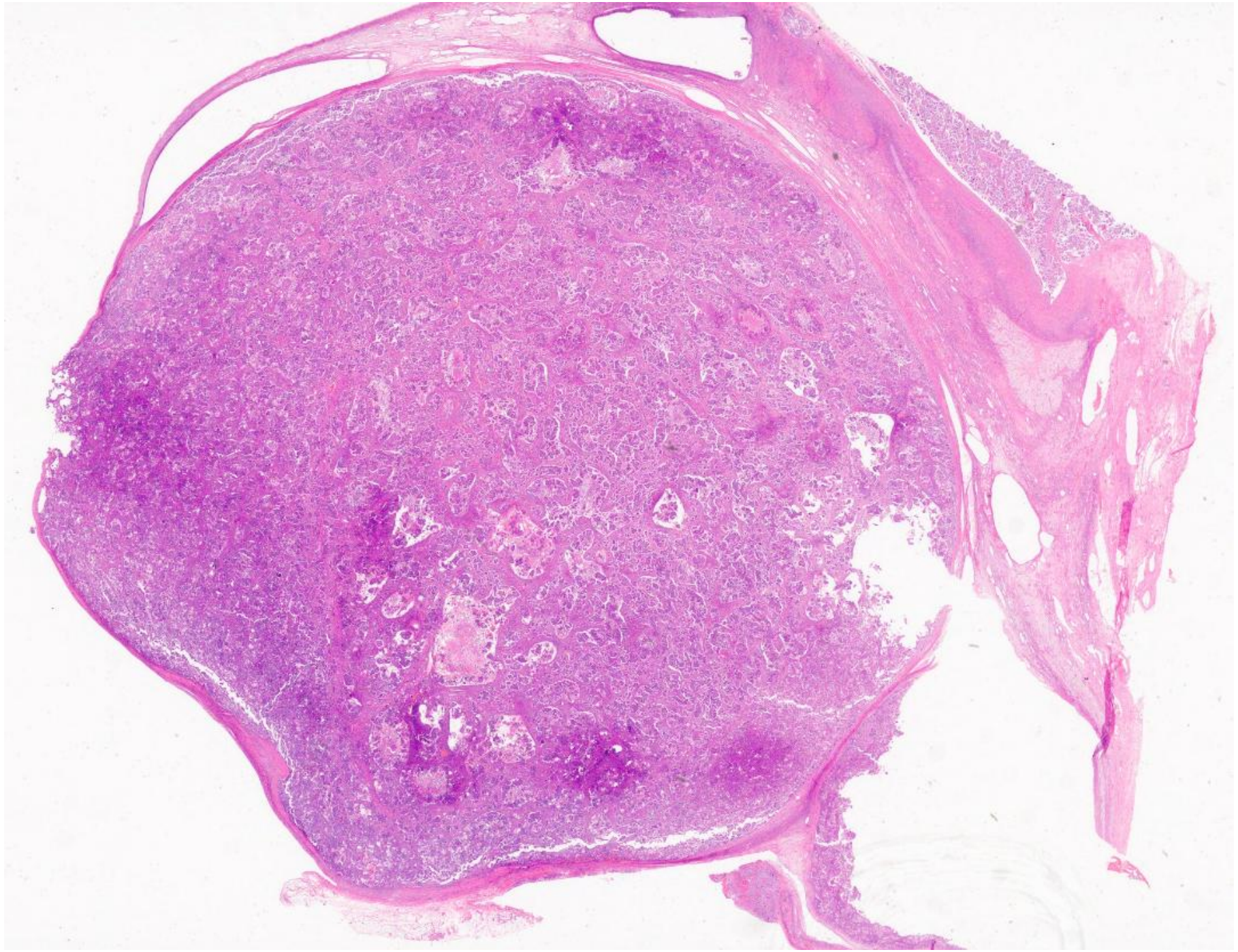

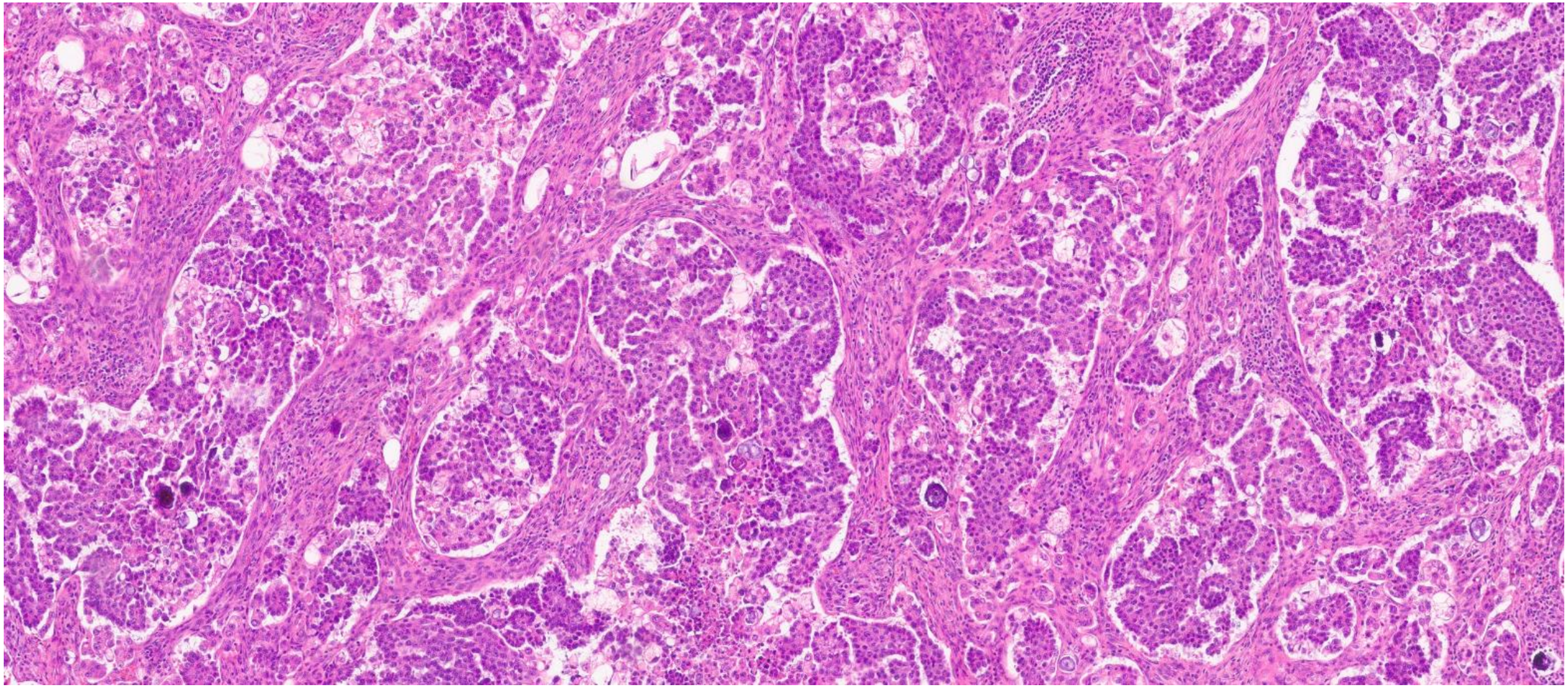

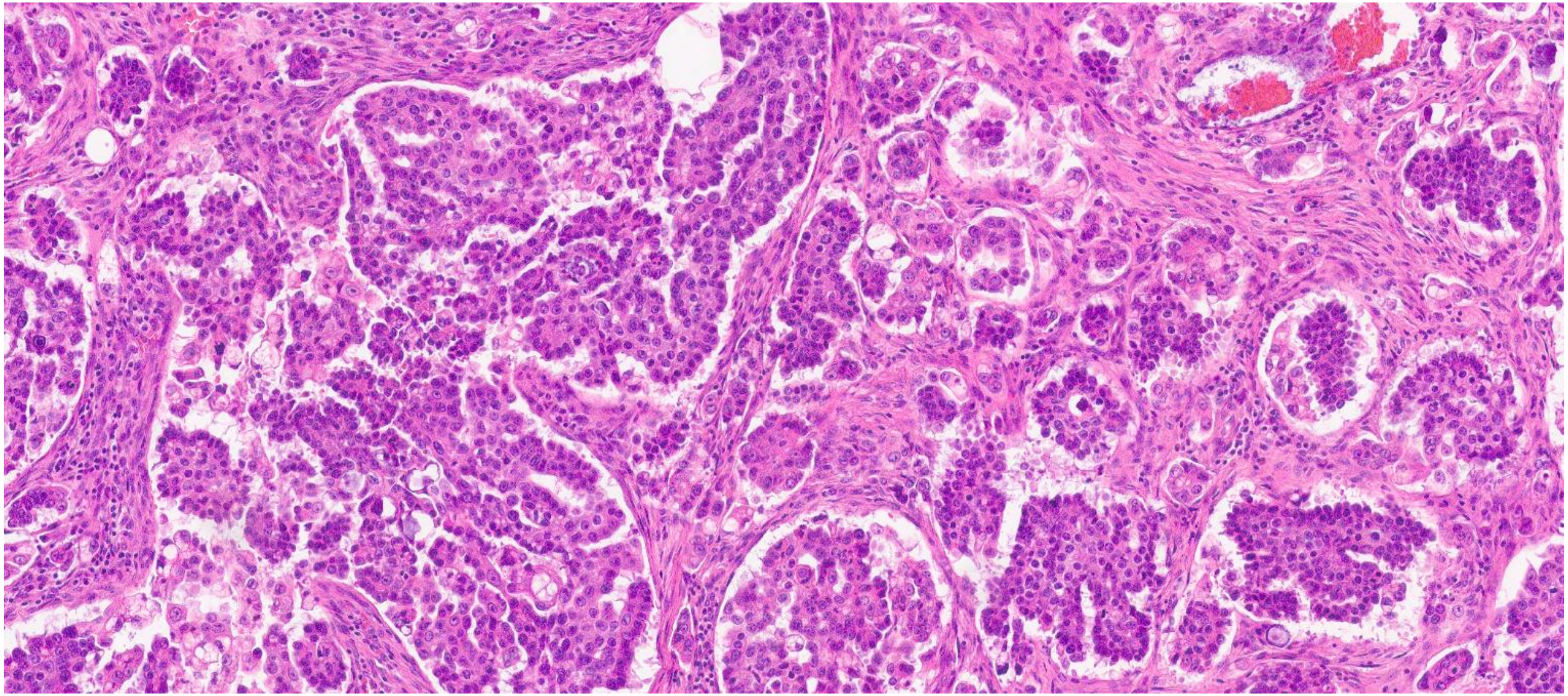

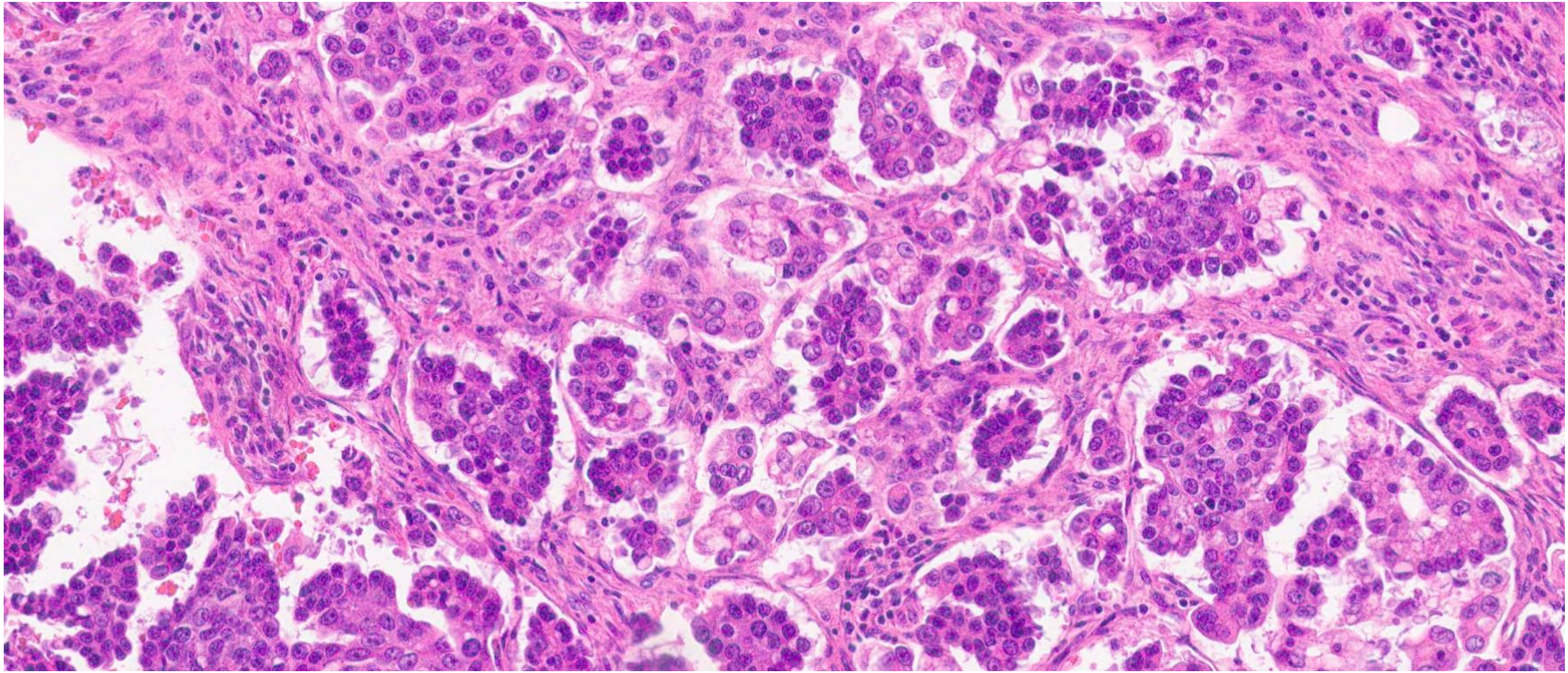

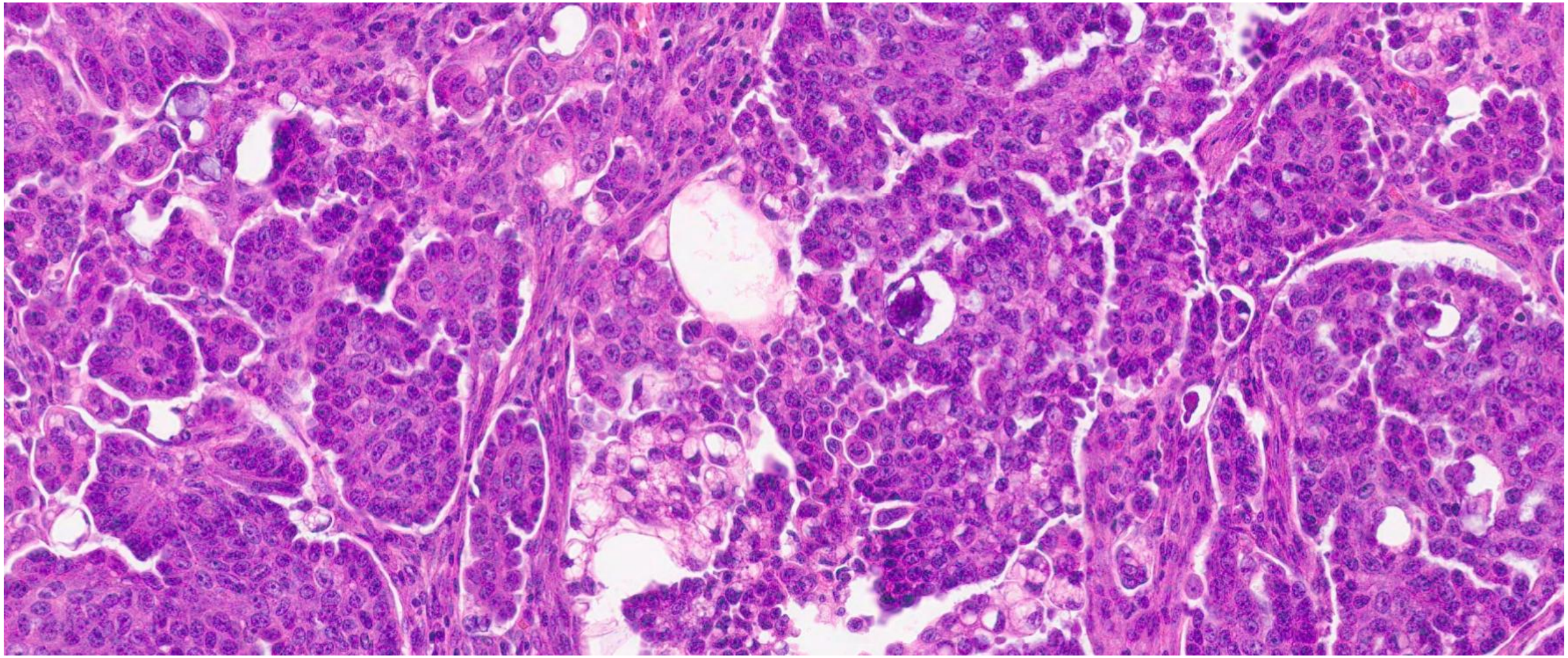

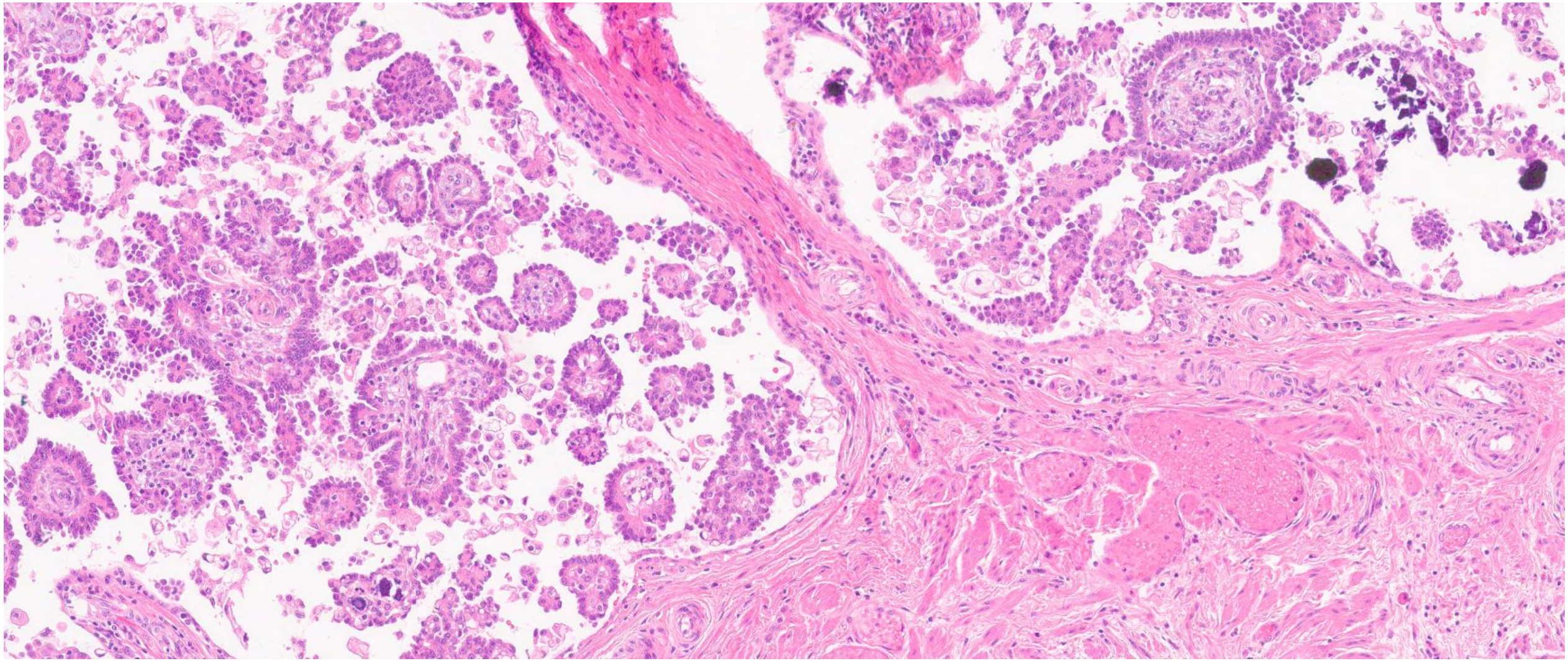

Low grade serous carcinoma

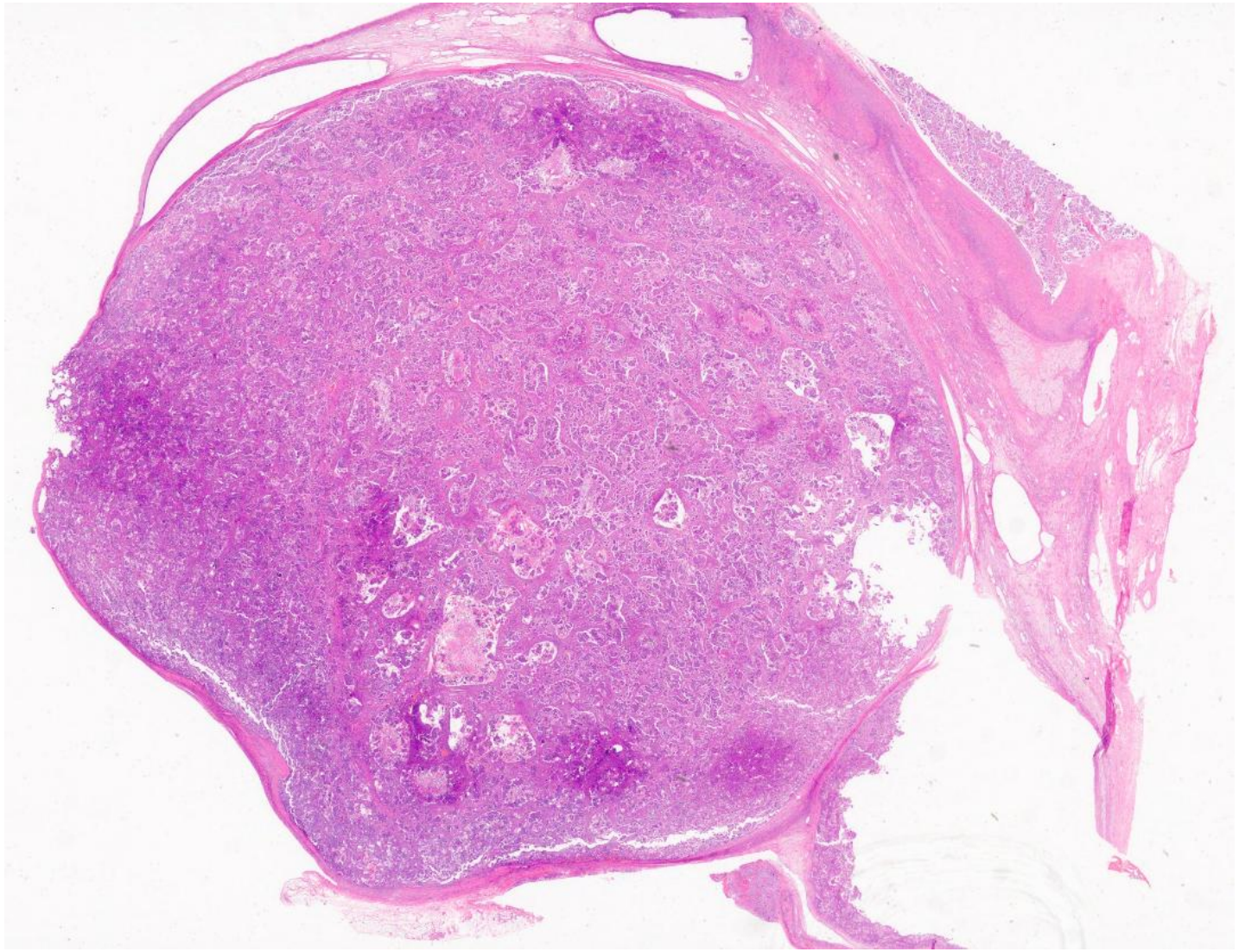

Case 13 – Low grade serous carcinoma

Principle histological features

- Uniform population of small cuboidal cells with scant cytoplasm.
- Mild to moderate nuclear atypia.
- Less than 3-fold variation in size.
- Low mitotic index: < 12 mitotic figures per 10 high power fields.
- Psammoma bodies.
- Invasion characterised by papillae or micropapillae (or inverted macropapillae with broad fibrovascular cores), often surrounded by clefts.
- Background of serous borderline tumour.

Case 13 – Low grade serous carcinoma

DDx and how to resolve

▪ Serous borderline tumour (+/-) microinvasion	Cuboidal to columnar cells with mild to moderate atypia (less than threefold variation in nuclear size) and few mitotic figures	Invasion / invasive foci <5mm confluent Invaginations with smooth contours rather than irregular islands eliciting desmoplastic response /surrounded by clefts
▪ High grade serous carcinoma	Cells with high N:C ratio Papillary architecture WT1+	High grade atypia, mitoses ++ p53 aberrant
▪ Seromucinous borderline tumour/ endometrioid carcinoma showing seromucinous morphology	Cystic tumour with cells showing no/mild atypia Hierarchical branching architecture	Ciliated, mucinous and indifferent cells Papillary cores oedematous and contain polymorphs WT1 -

Case 13 – Low grade serous carcinoma

Extra marks?

- Expected to be p53 wild type, ER+, WT1+
- Discuss criteria for invasion vs microinvasion.
- Various molecular alterations have been described, especially KRAS, NRAS and BRAF mutations.

Case 14

- Specimen: Ovary
- Age: 59
- Clinical: Hysterectomy for bilateral ovarian masses

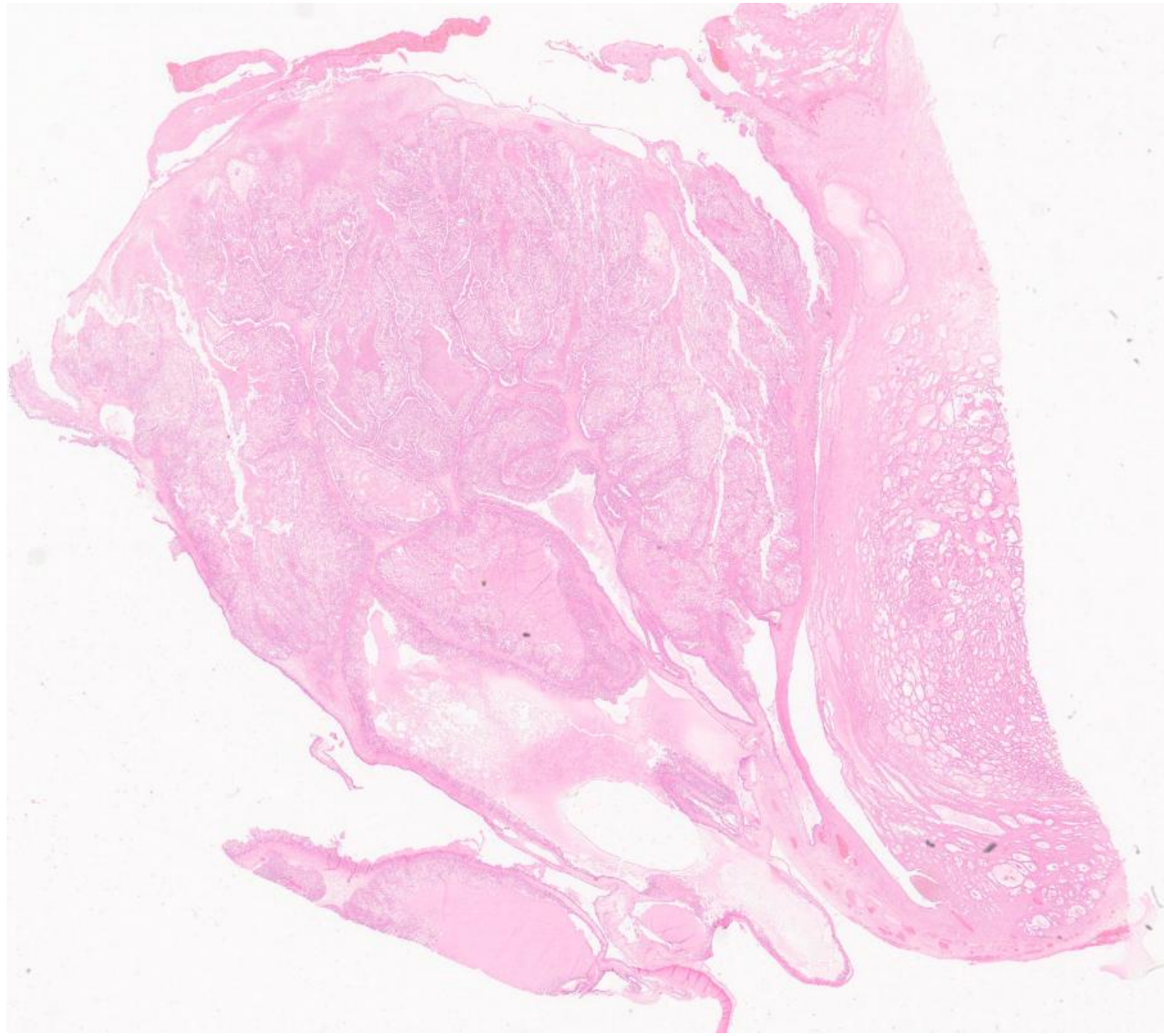

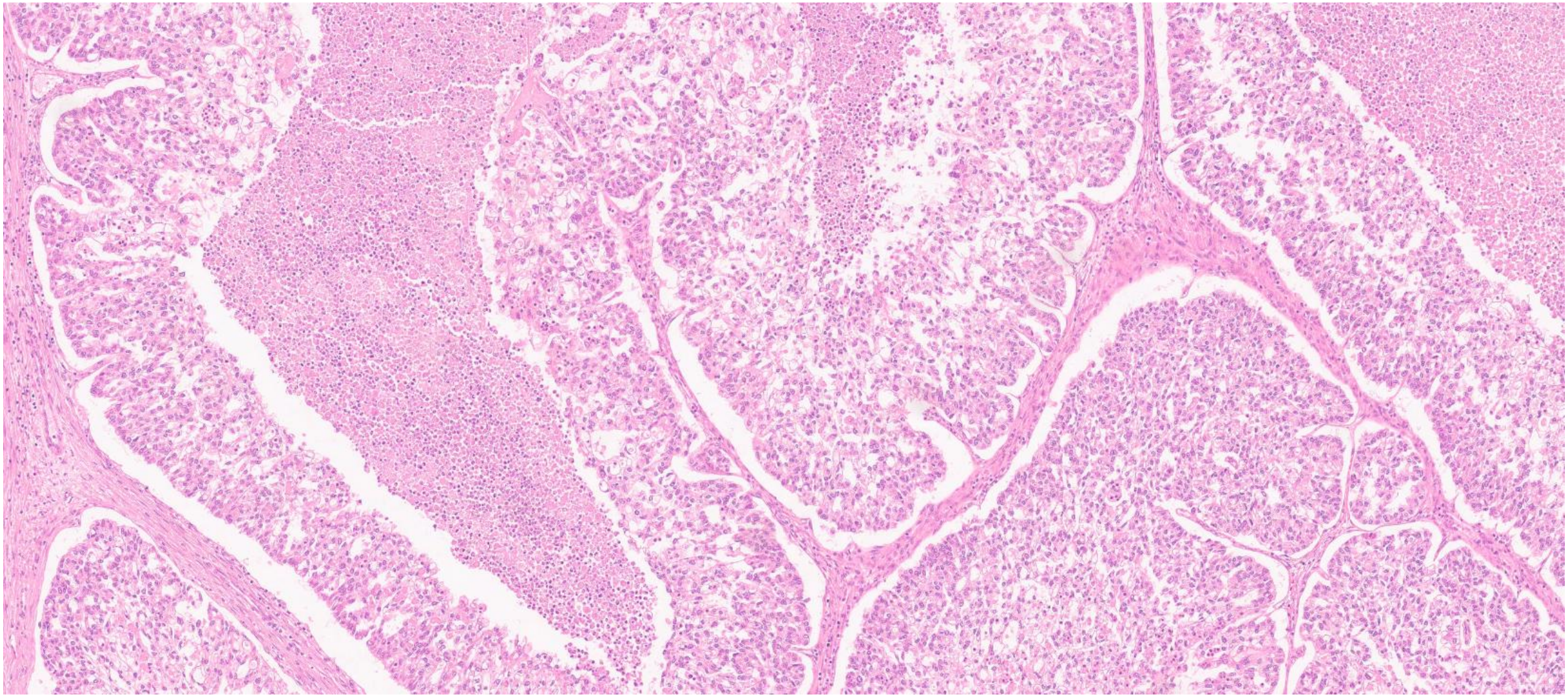

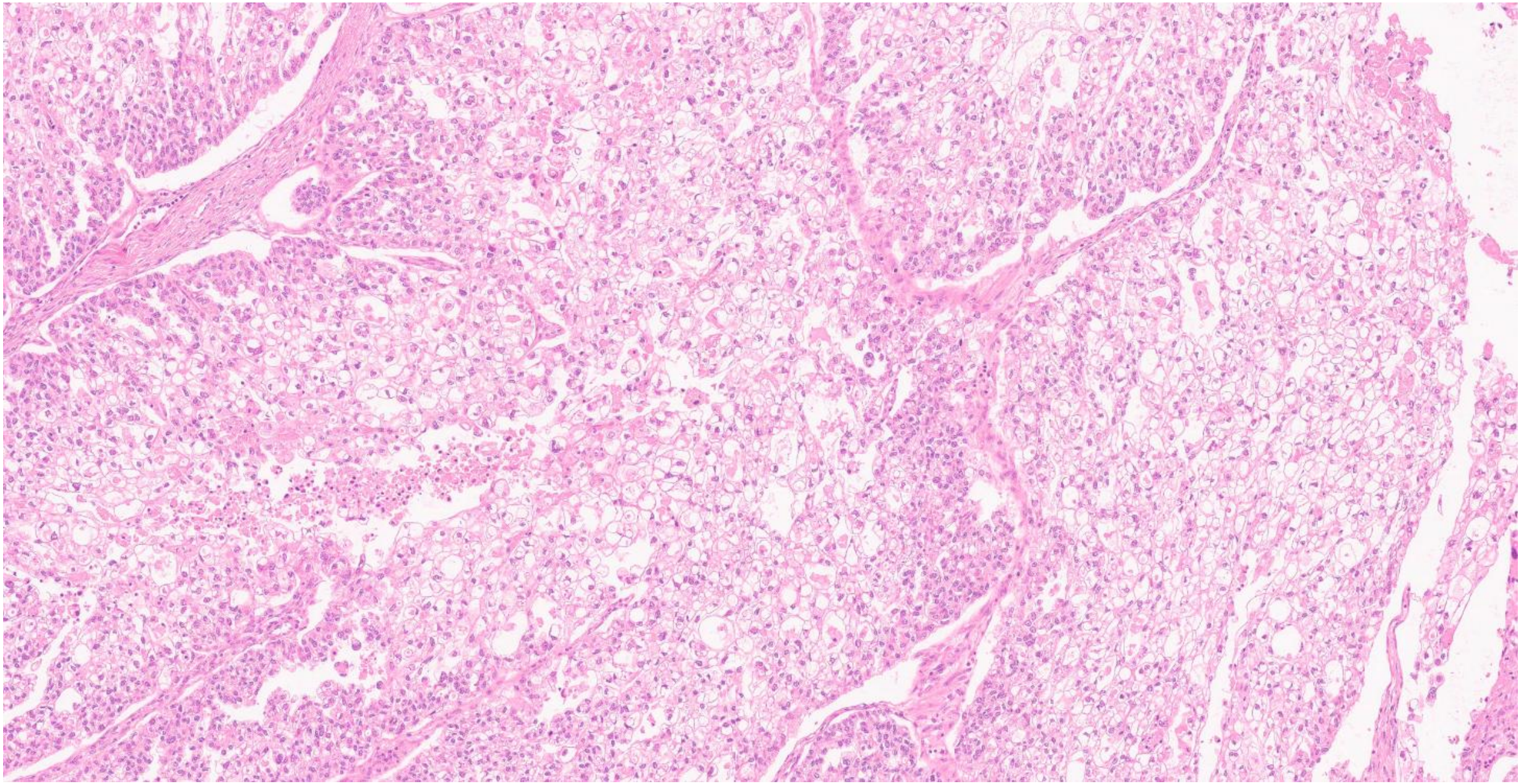

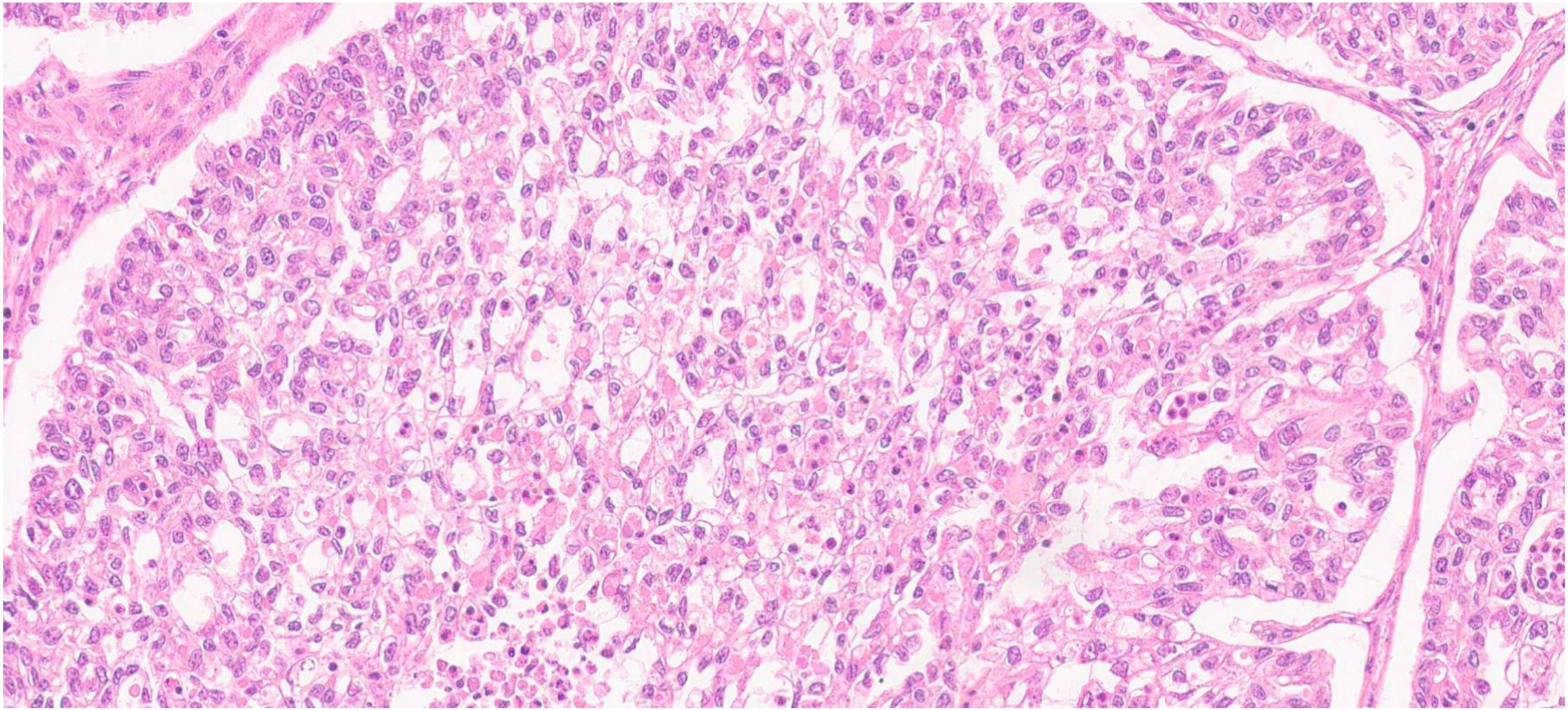

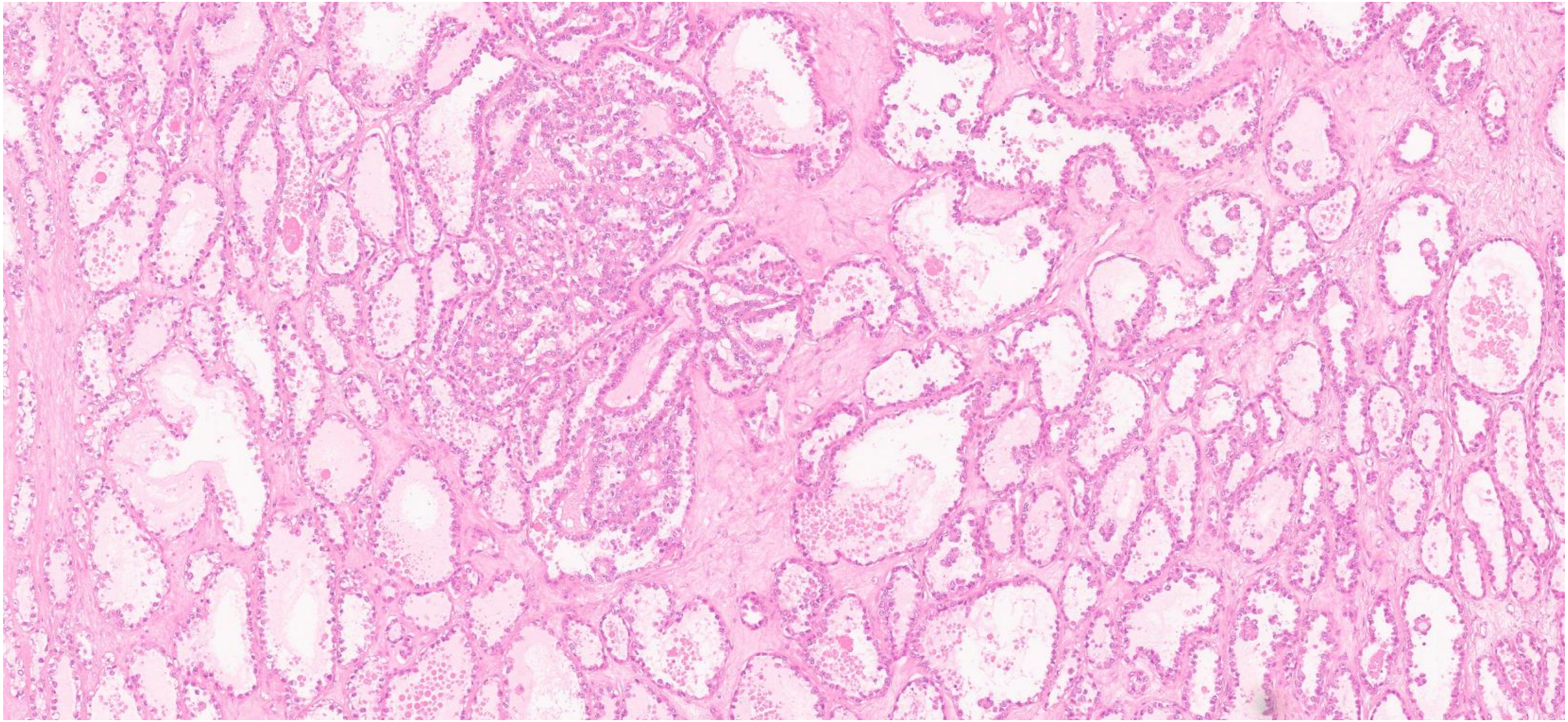

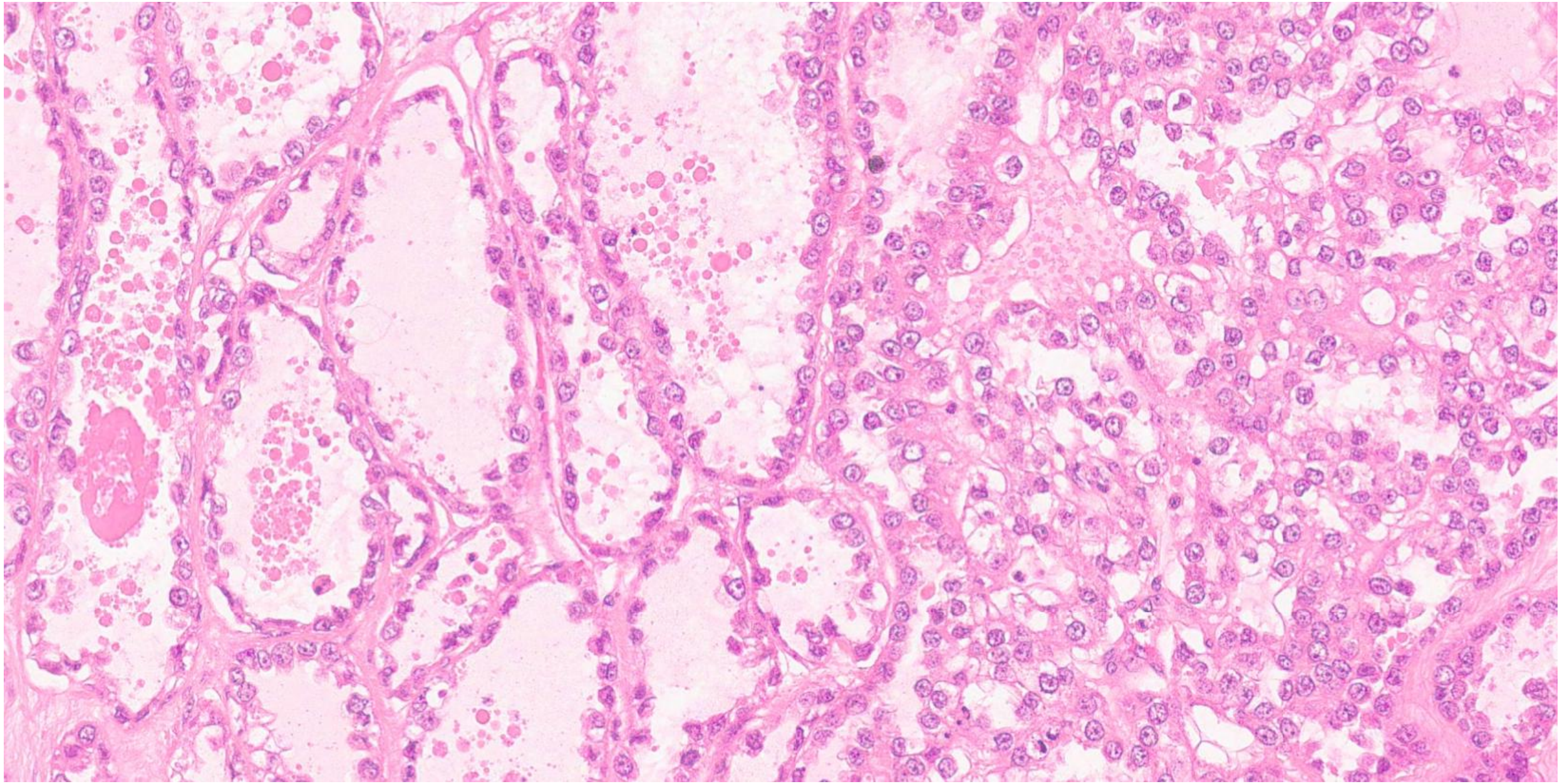

Ovarian clear cell carcinoma

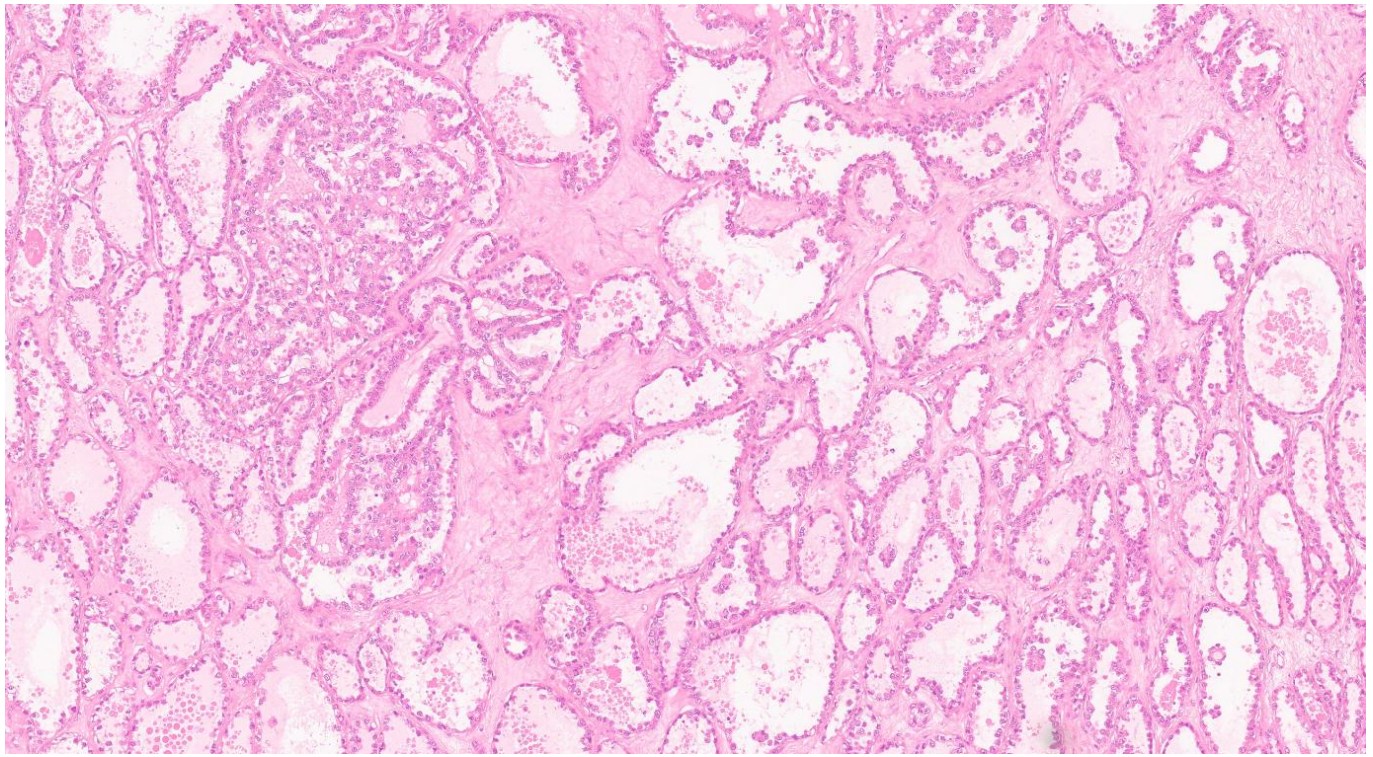

Case 14 – Clear cell carcinoma

- **Principle histological features**

- Three growth patterns: usually admixed
  - Papillary (small, simple, non-branching, can have micropapillary tuffts)
  - Tubulocystic (tubules and small cysts, often containing dense eosinophilic secretions)
  - Solid (diffuse sheets)
- Polygonal/cuboidal cells with clear of eosinophilic cytoplasm; hobnailing.
- Typically high-grade uniform atypia, often focal pleomorphism
- Eosinophilic hyaline globules

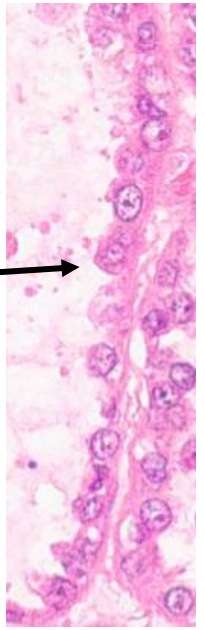

Case 14 – Clear cell carcinoma

DDx and how to resolve

▪ Other carcinoma with clear cell change	Malignant epithelial cells with clear cytoplasm	• Clear cell morphology is normally focal • Depending on tumour type: elongated, stratified, pleomorphic nuclei • Lack of characteristic features: polygonal cells with uniform atypia and hobnailing • Immunoprofile
▪ Dysgerminoma	Uniform clear polygonal cells with distinct cell membranes	• Younger age • Predominantly solid (tubocystic, papillary, trabeculated less common or focal) • Lymphoplasmacytic infiltrate in septations • Immunoprofile

Case 14 – Clear cell carcinoma

Extra marks?

IHC	Napsin A	AMACR	WT1	ER	p53	SALL4	OCT3/4
CCC	+	+	-	-	Wild type, minority aberrant	-	-
High grade serous carcinoma	-	-	+	+	Aberrant	-	-
Dysgerminoma	-	-	-	-	Wild type	+	+

Case 14 – Clear cell carcinoma

Extra marks?

- Association with endometriosis
- An indication for MMR immunohistochemistry because of an association with Lynch syndrome

Case 15

- Specimen: Anal biopsy
- Age: 56
- Clinical: ?anal tumour

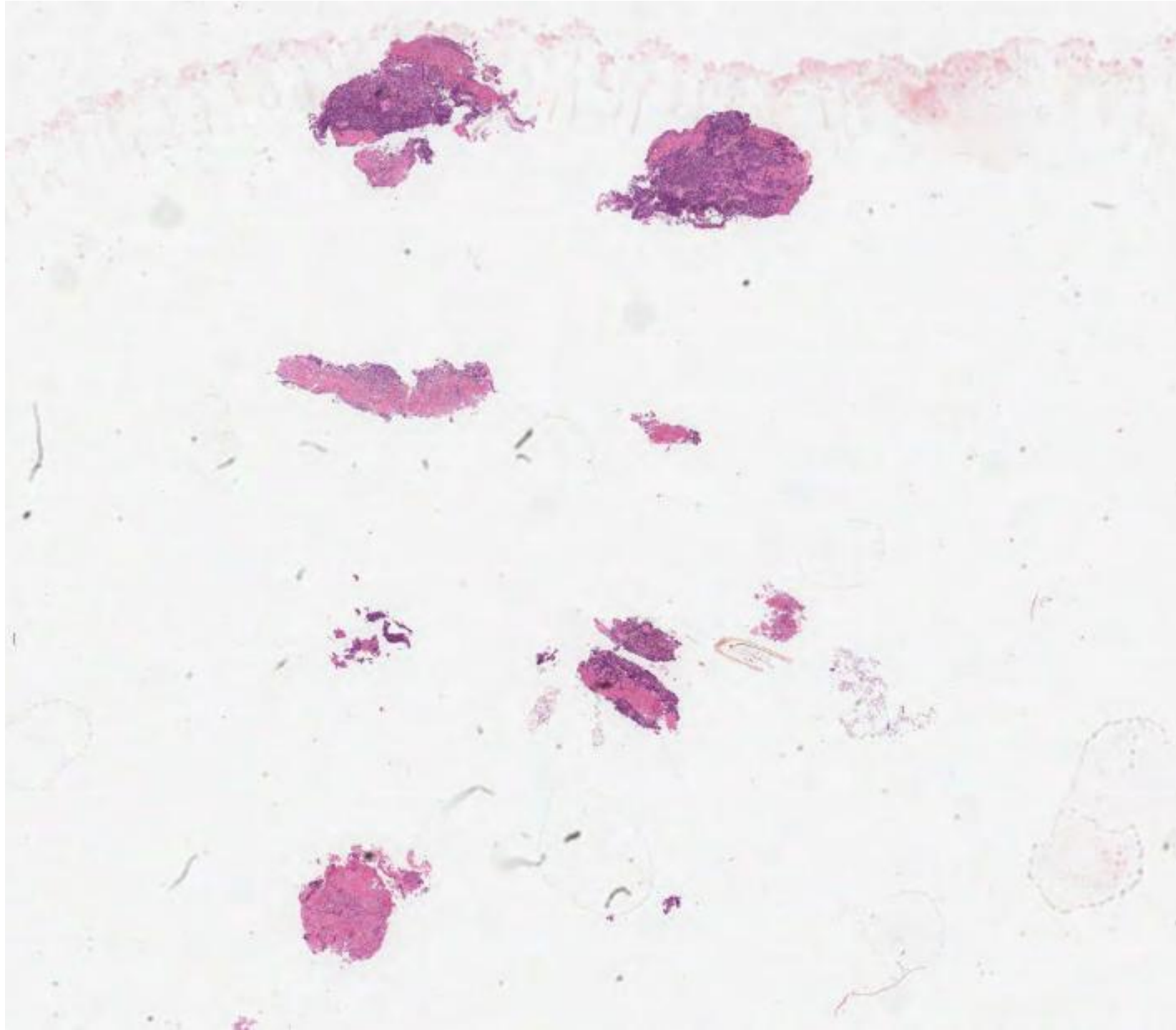

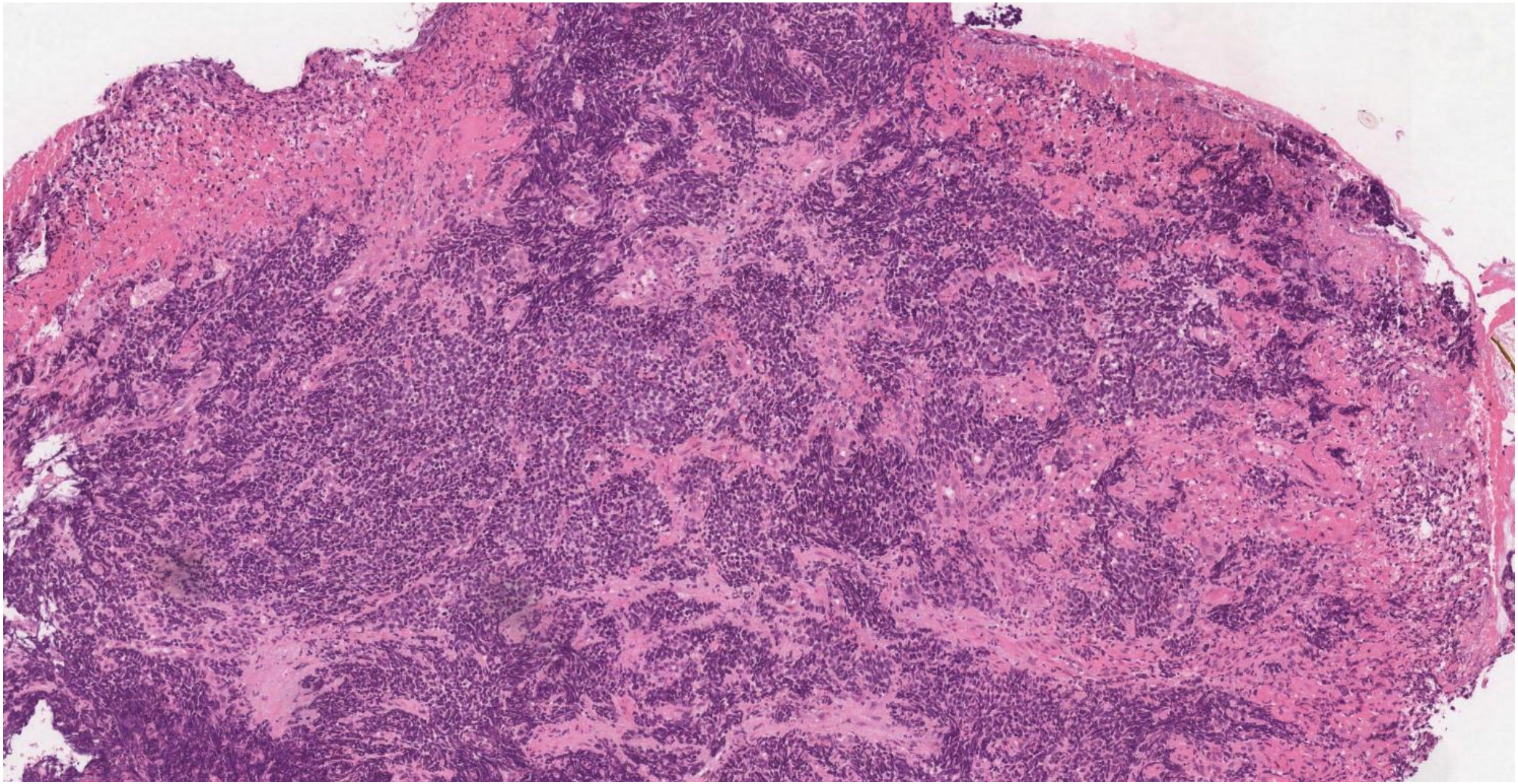

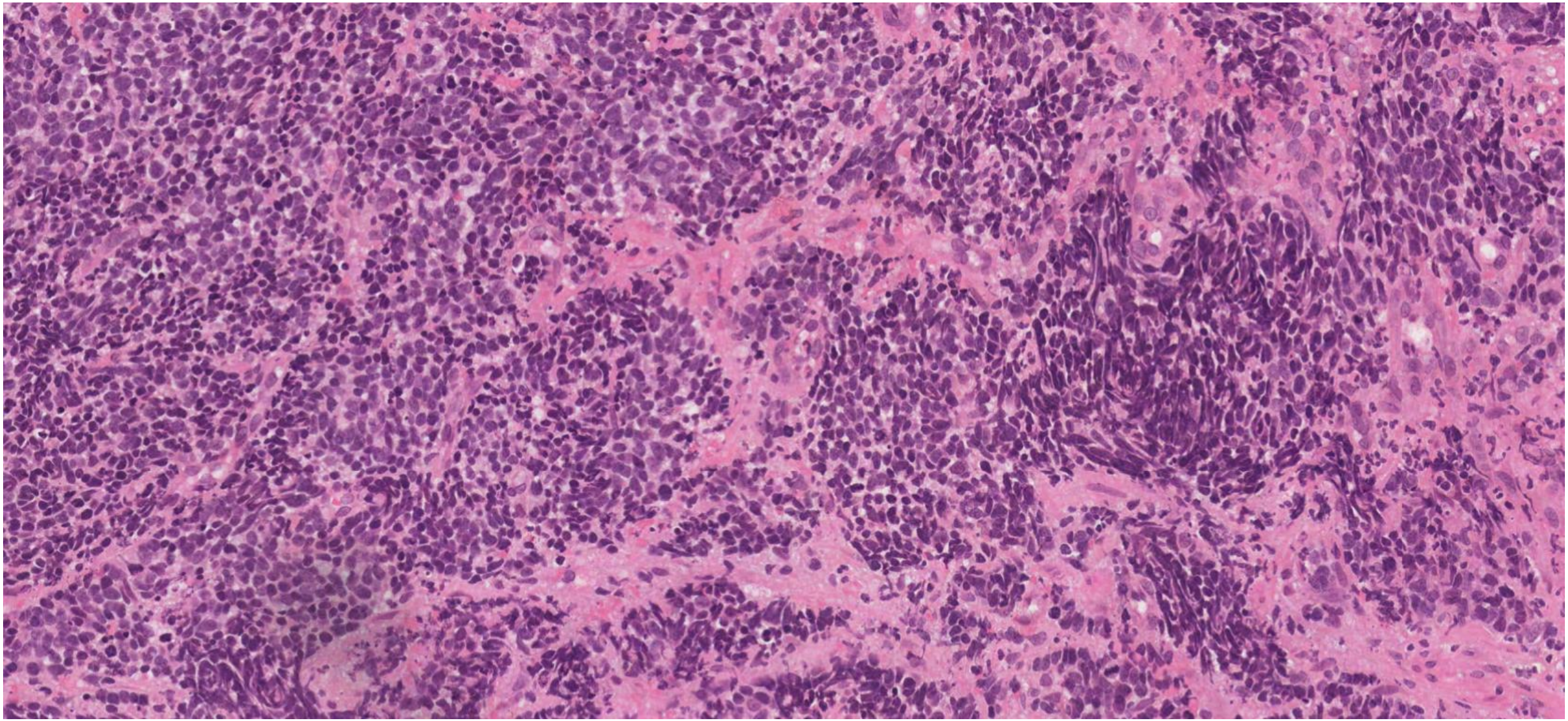

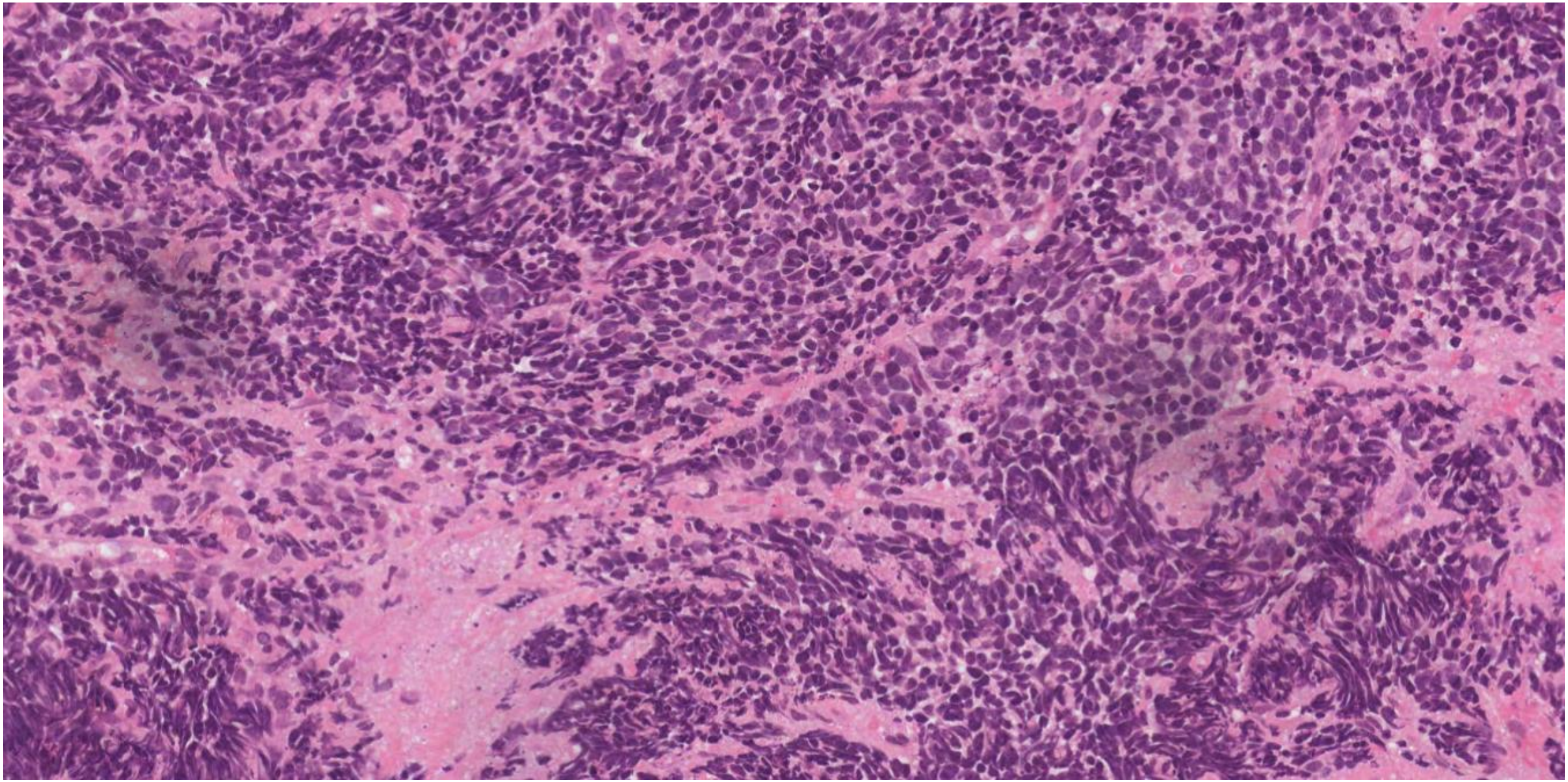

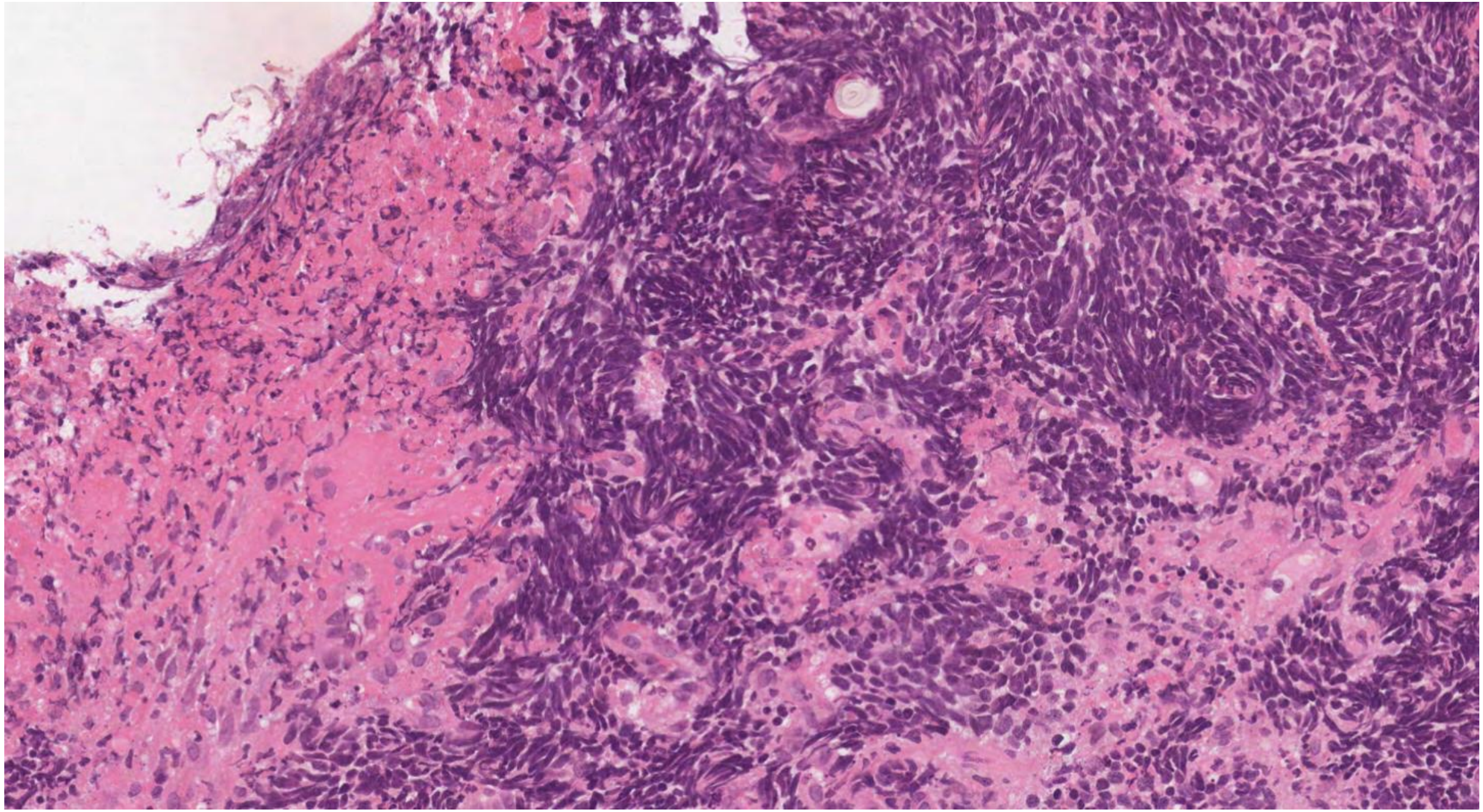

Poorly differentiated neuroendocrine carcinoma (small cell)

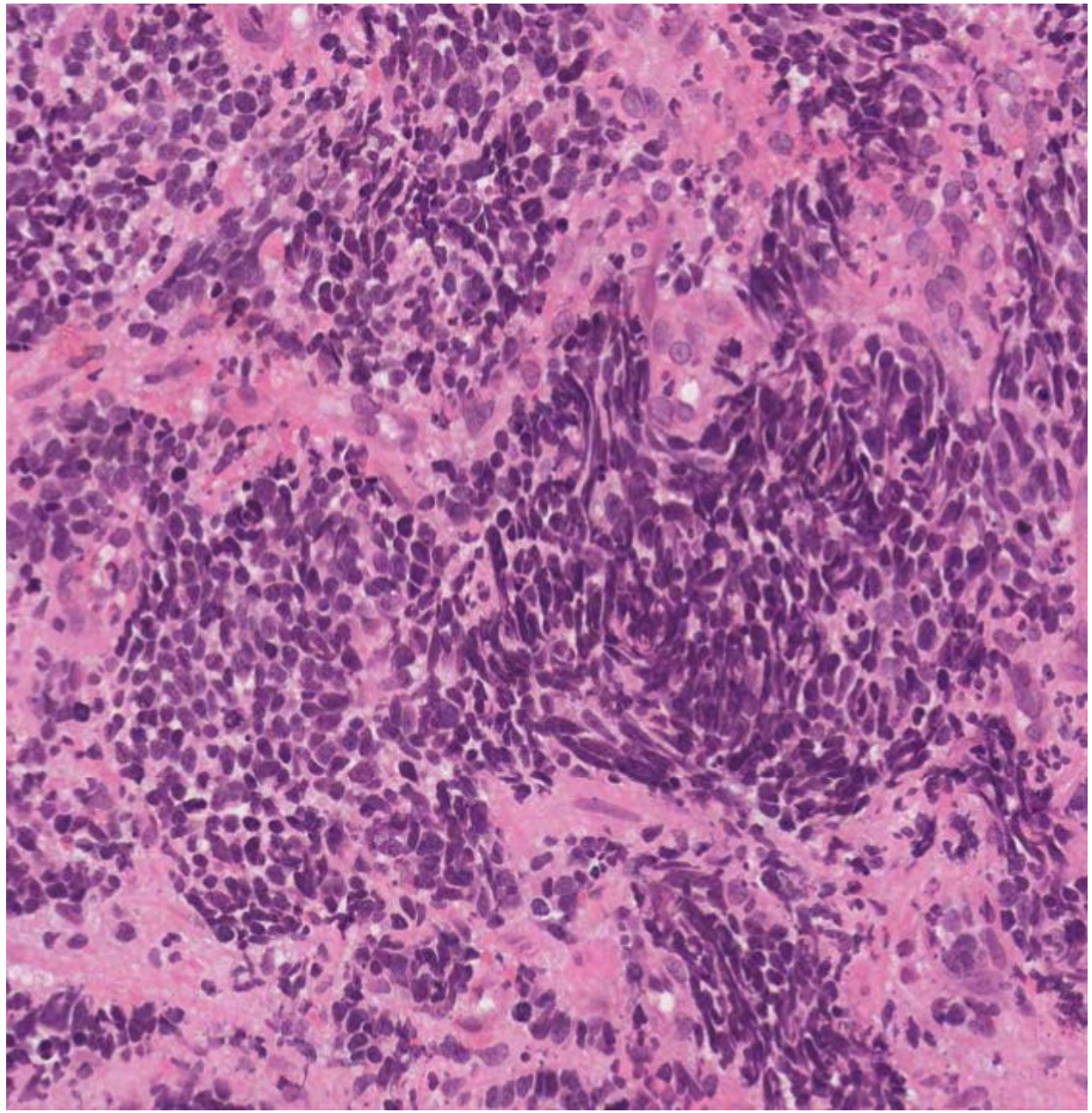

Case 15 – Poorly diff. NEC / Small cell carcinoma

Principle histological features

- Basophilic. Small to medium-sized (c/w lymphocyte) cells with minimal cytoplasm
- Finely dispersed chromatin without distinct nucleoli
- Nuclear moulding and smudging
- High mitotic rate
- Necrosis and apoptosis
- Azzopardi phenomena: basophilic nuclear material lining blood vessel walls

Case 15 – Poorly diff. NEC / Small cell carcinoma

DDx and how to resolve

▪ Melanoma	Poorly differentiated discohesive tumour	Melanin pigment Plasmacytoid cells, macronucleoli MelanA, S100, SOX10, HMB45 + Synaptophysin, ChromograninA, CD56 -
▪ Lymphoma	Poorly differentiated discohesive tumour	Less likely to show moulding, smudging LCA / CD45+ Synaptophysin, ChromograninA, CD56 -
▪ High grade carcinoma, e.g. SCC	Poorly differentiated	Less likely to show moulding, discohestion, etc. Synaptophysin, ChromograninA, CD56 -

Case 15 – Poorly diff. NEC / Small cell carcinoma

Answer example:

The biopsy is infiltrated by a necrotic high-grade tumour formed of small-medium basaloid cells with hyperchromatic nuclei and high N:C ratios. The tumour shows nuclear moulding / smudging and apoptotic bodies.

Diagnosis: Poorly differentiated malignant tumour, favour small cell neuroendocrine carcinoma

IHC	**Synaptophysin Chromogranin, CD56**	**FLI1**	**CD99**	**PanCK**	**p63**	**SOX10**	**MelanA**	**CD45**
Small cell NEC	+	-	-	Cytoplasmic dot	-	-	-	-
Poorly differentiated SCC	-	-	-	+	+	-	-	-
Melanoma	-	-	-	-	-	+	+	-
Lymphoma	-	-	-	-	-	-	-	+
Ewing's sarcoma	-	+	Strong diffuse	-/+	-	-	-	-

Case 15 – Poorly diff. NEC / Small cell carcinoma

Extra marks?

- Consider primary vs metastatic
    - Clinical and radiological distinction (CDX2, TTF1, PAX8 not reliable for primary site assignment)
- Dismal prognosis

Case 16

- Specimen: Ovary
- Age: 81
- Clinical: Terminal ileum and ovarian tumours

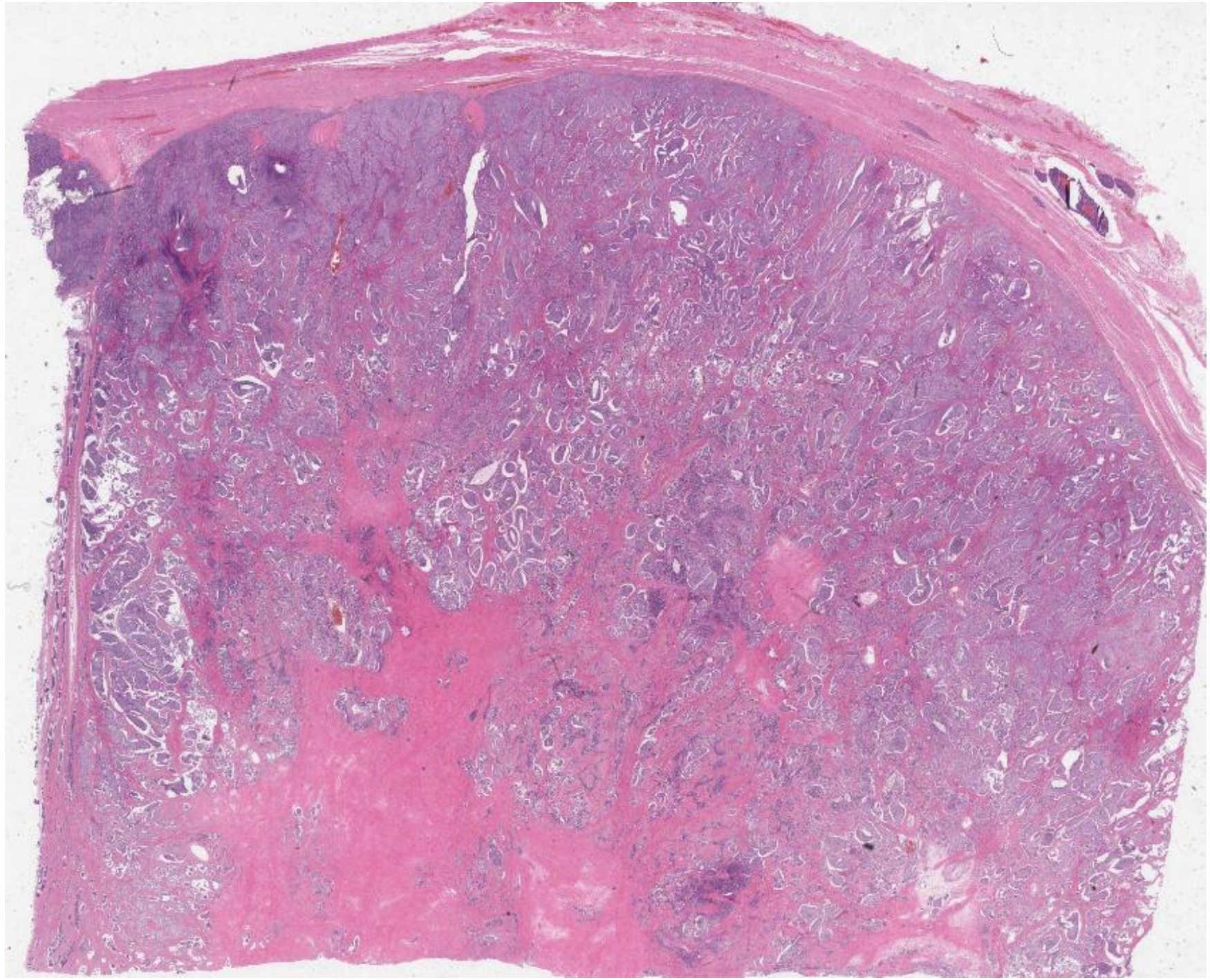

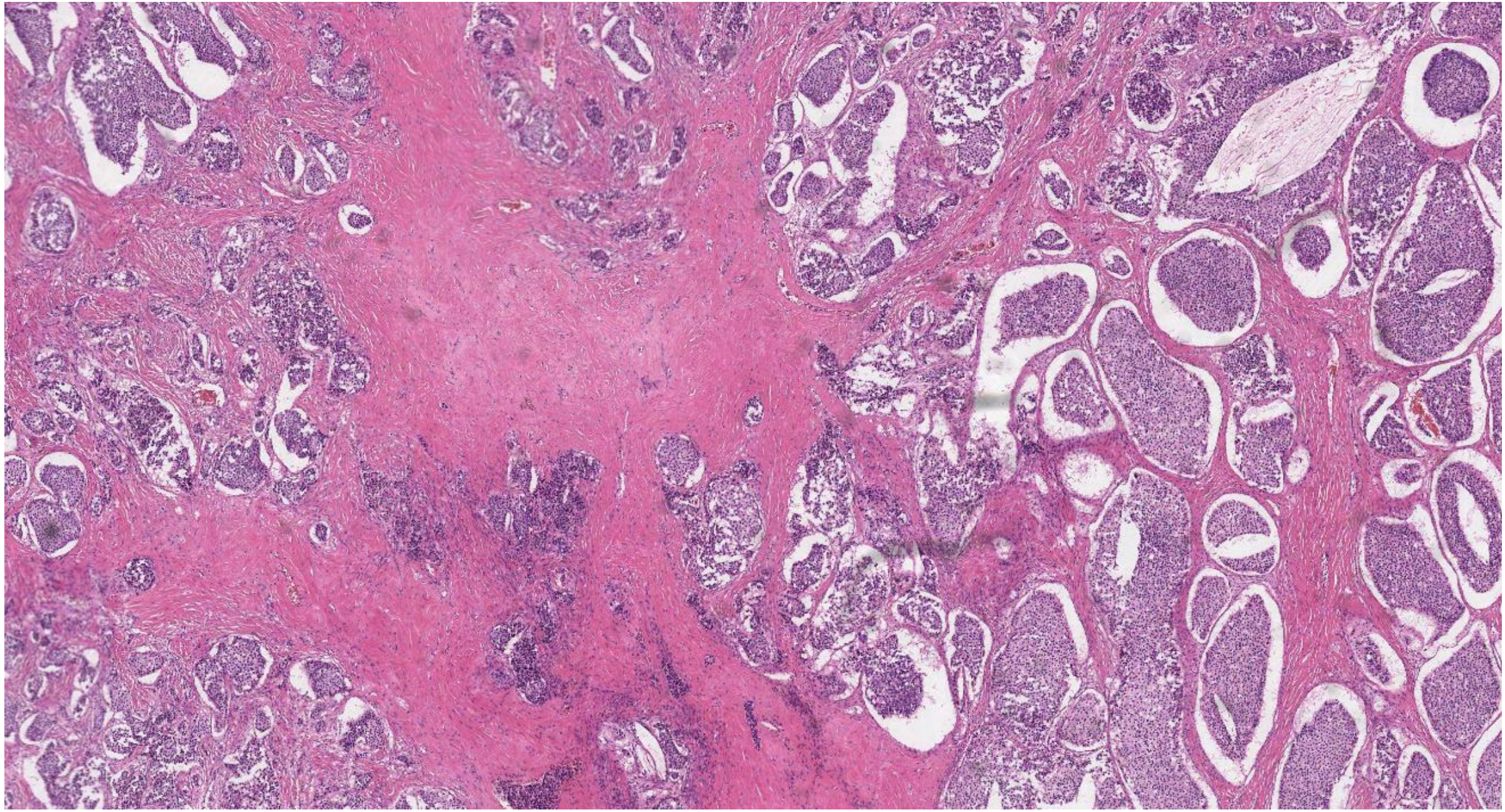

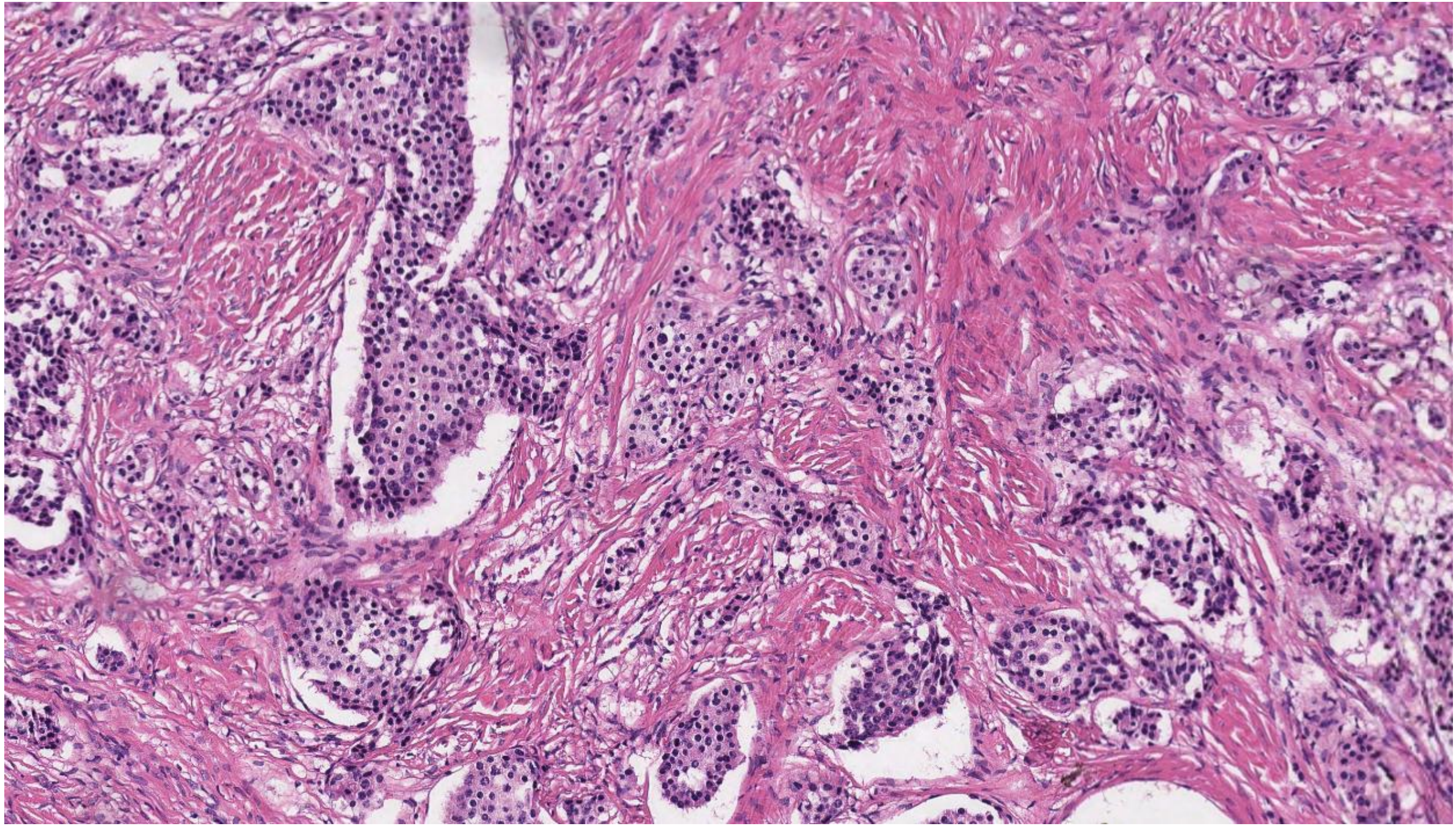

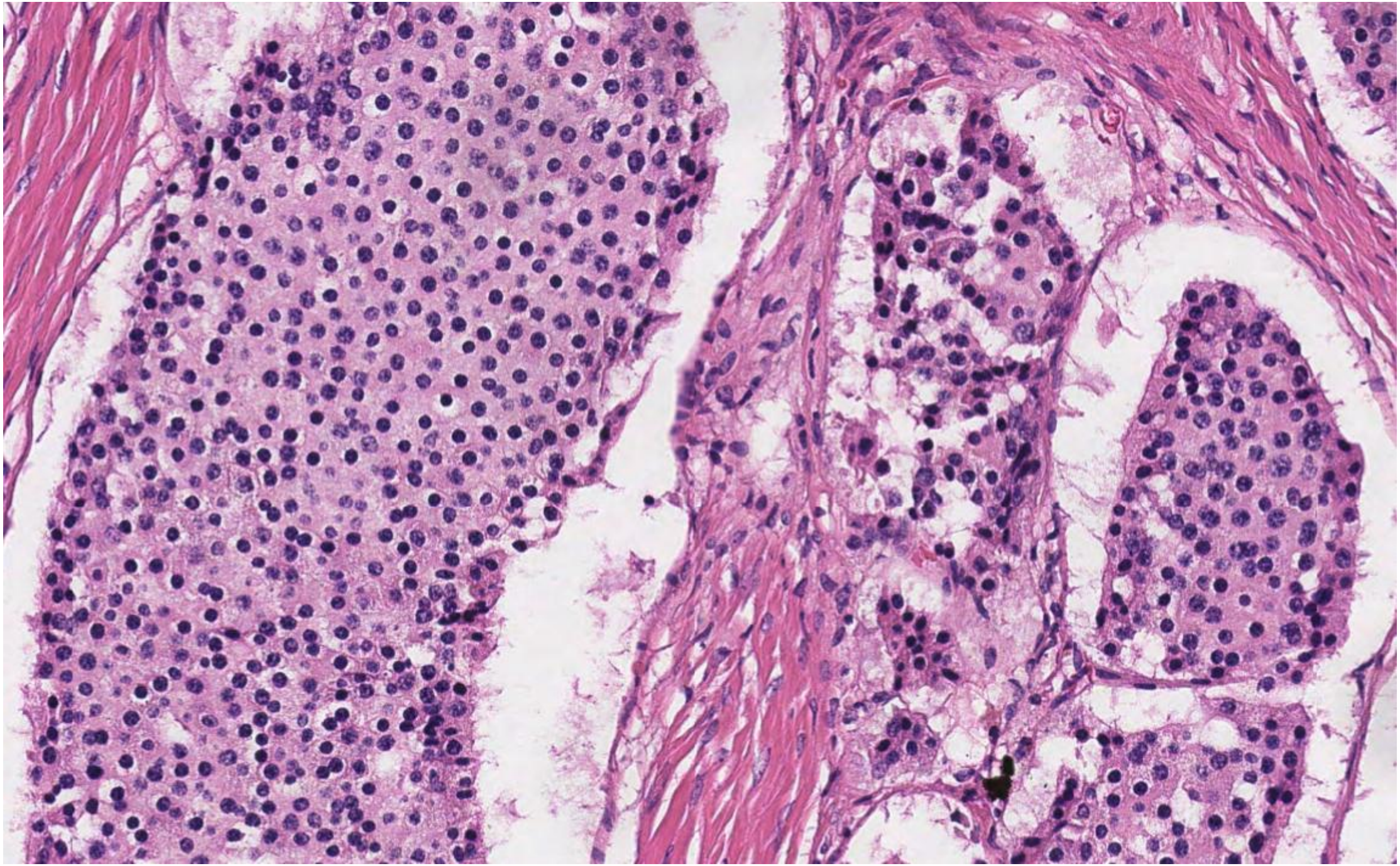

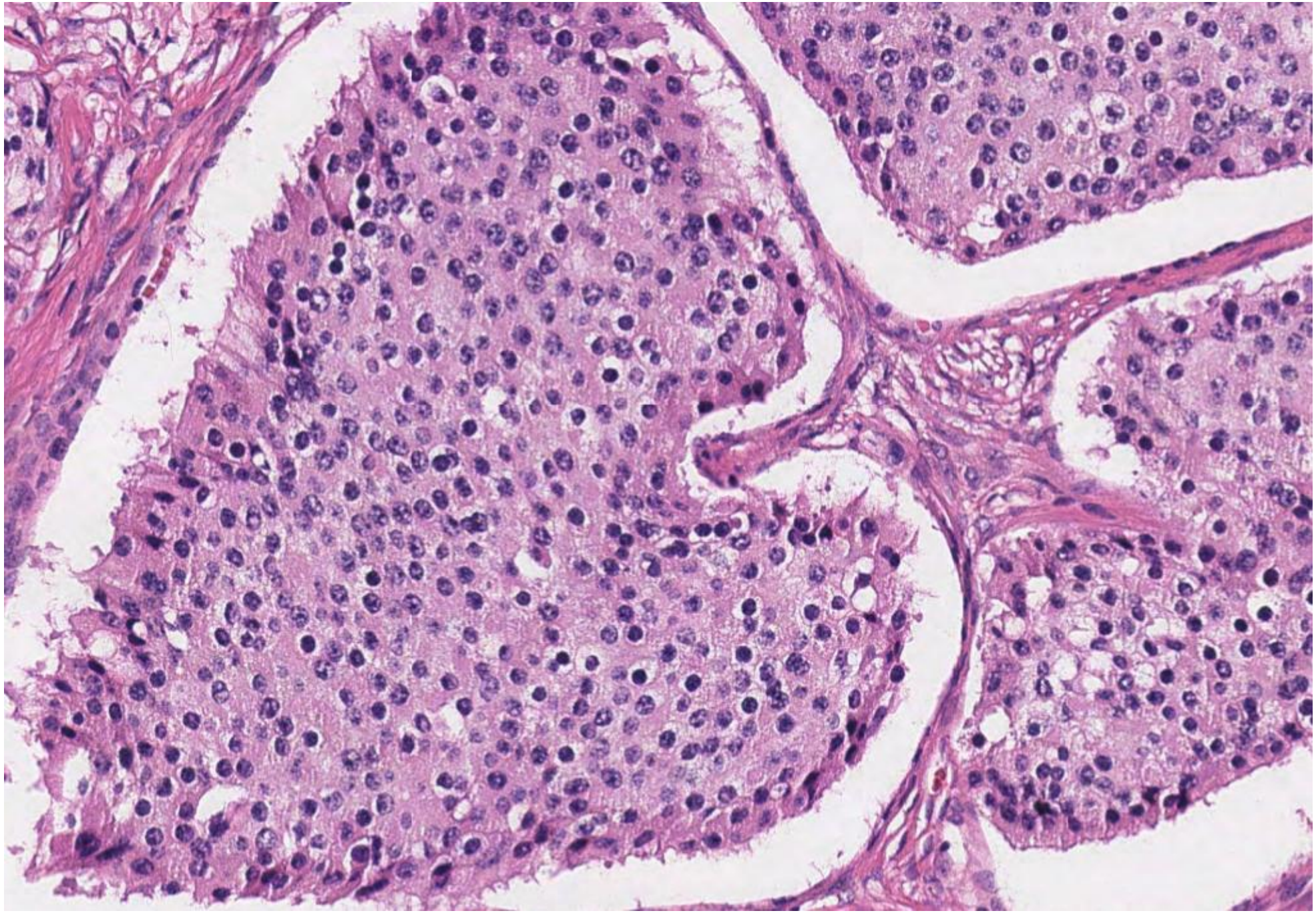

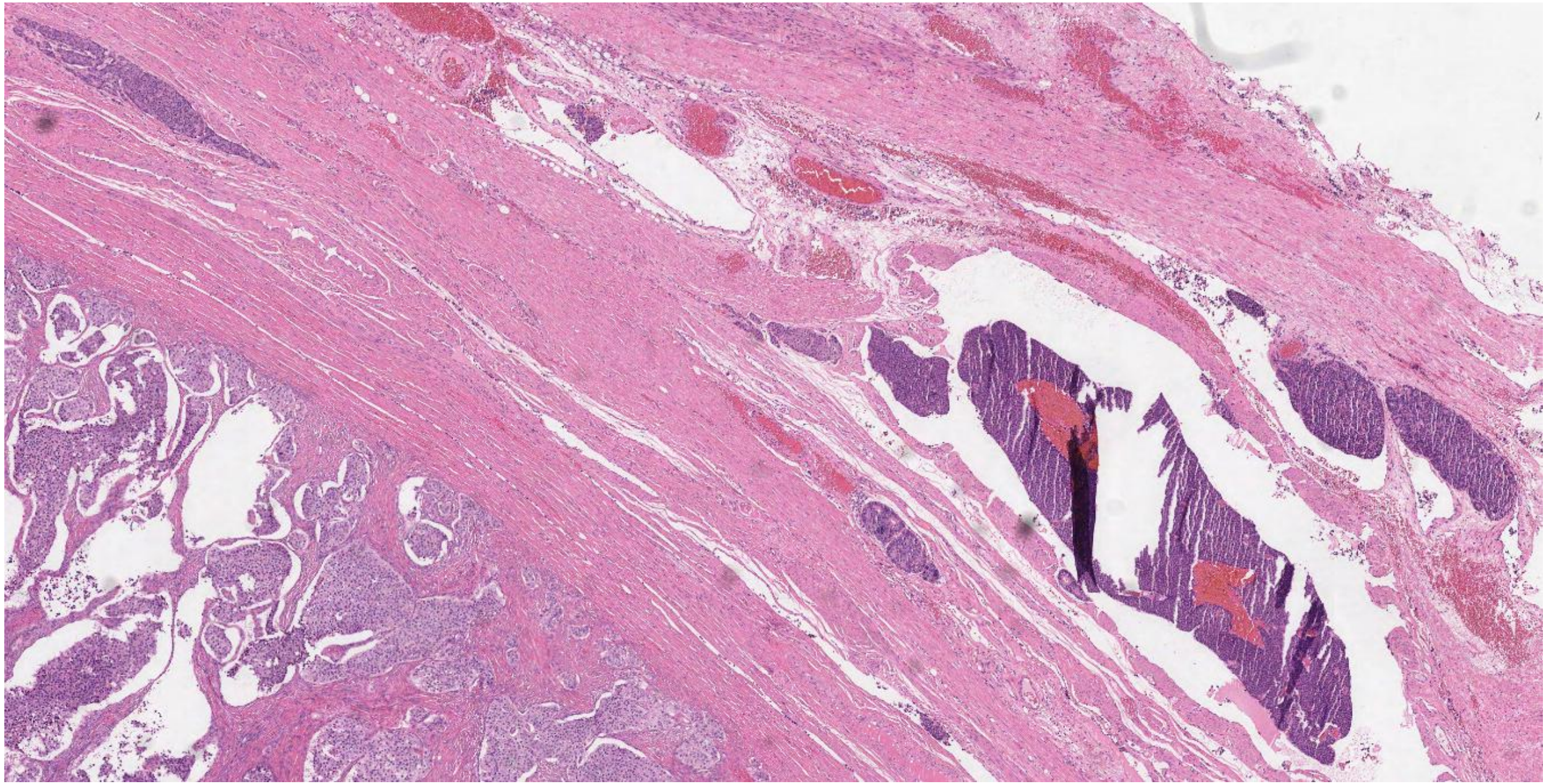

Well-differentiated neuroendocrine tumour

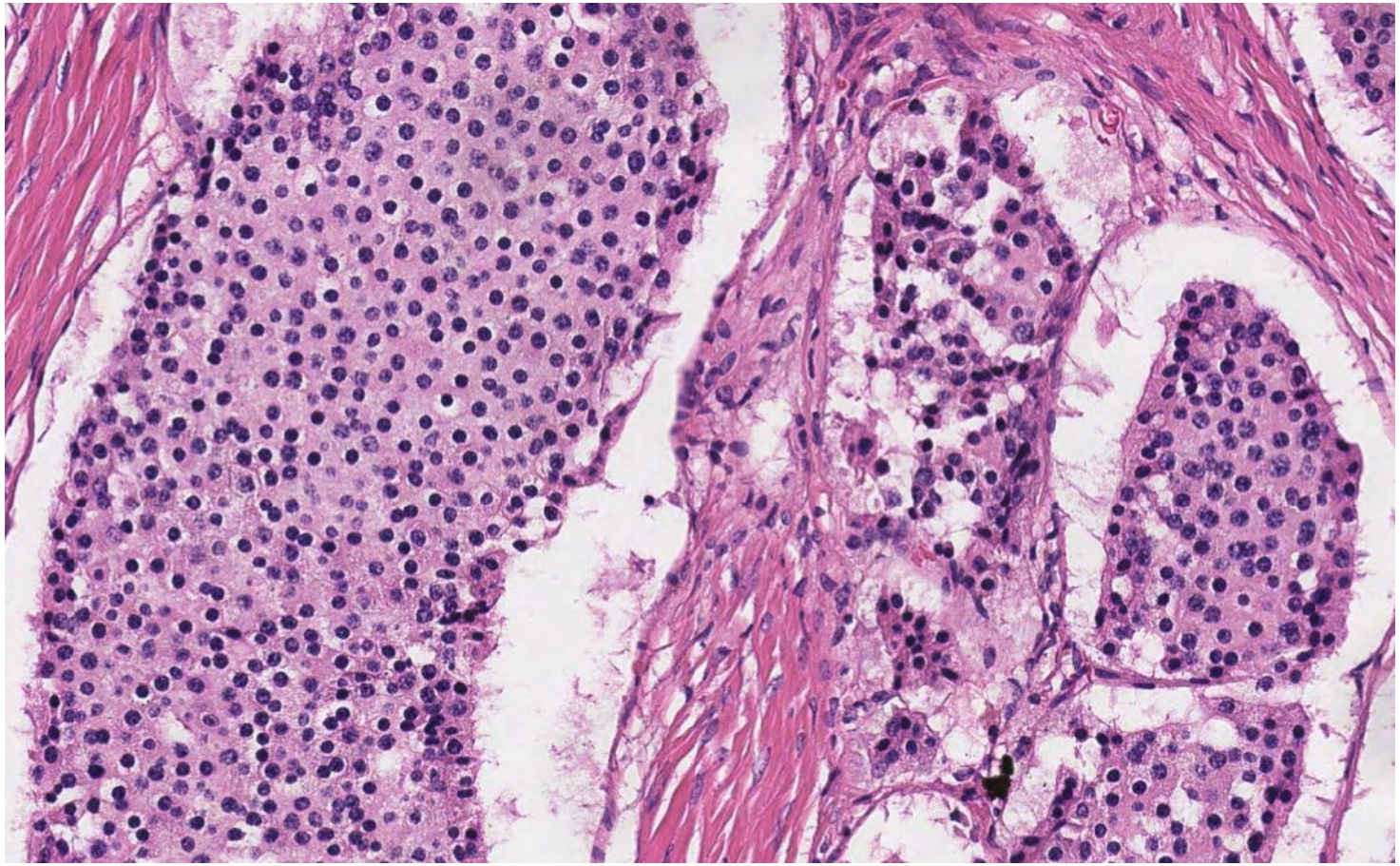

Case 16 – Well differentiated NE tumours

OVARIAN CARCINOID - Principle histological features

- Usually a small, solid (or occasionally cystic) nodular tumour.

- Insular carcinoid: Solid nests, often with peripheral acini
- Trabecular carcinoid: Ribbons, cords, trabeculae
- Mucinous carcinoid (rare): Acini (with goblet cells) floating in extra-cellular mucin

- Uniform cells with central, round to oval nuclei, salt and pepper chromatin, granular cytoplasm.

- Can occur as pure monodermal teratoma or be seen in association with mature teratoma or struma ovarii.

Case 16 – Well differentiated NE tumours

METASTATIC WELL-DIFFERENTIATED NEUROENDOCRINE TUMOURS - Principle histological features

- Most commonly insular; trabecular also reported.
- Mucinous carcinoid resembles goblet cell carcinoma of appendix, so this should be considered.
- No cytomorphologic differences

- More likely to be bilateral and have a multinodular low power appearance with peripheral / cortical distribution.
- The presence of an underlying teratoma or struma makes metastasis unlikely.

Case 16

Additional extra marks?

- Recognising the carcinoid will get you a passing mark. Discussing the possibility of this being metastatic will enhance your score
- Ovarian carcinoids express neuroendocrine markers (synaptophysin, chromogranin, CD56), CDX2, and are typically CK7+ and CK20-.
- IHC is unhelpful in the distinction from metastatic well-differentiated neuroendocrine tumours arising in the GI tract.
- Larger ovarian carcinoids and WD-NETs can uncommonly be associated with carcinoid syndrome: serotonin secretion leads to flushing, tachycardia, GI symptoms and wheeze.

Case 17

- Specimen: Vulva
- Age: 62
- Clinical: Previous VSCC. Now left labia lesion ?recurrence.

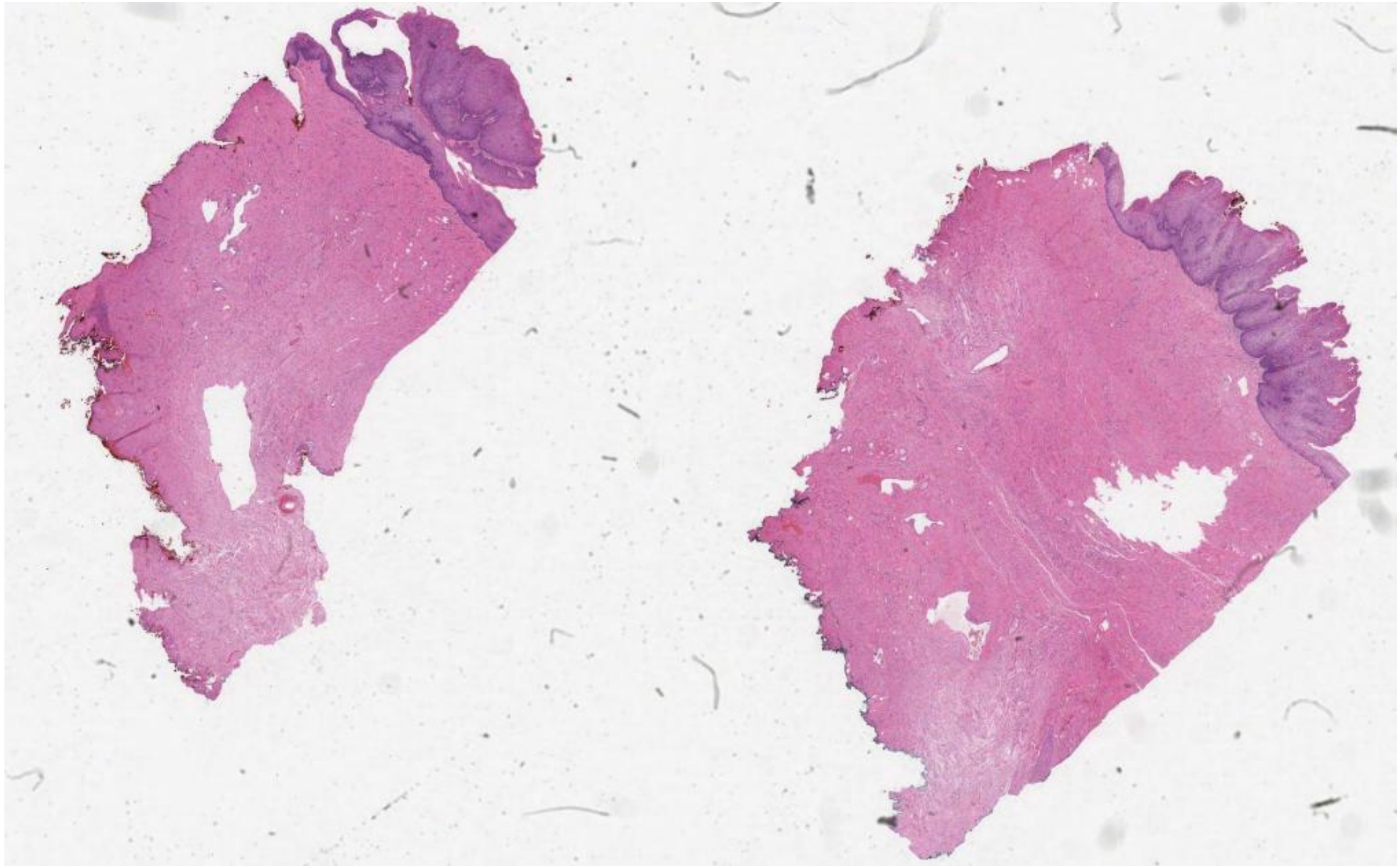

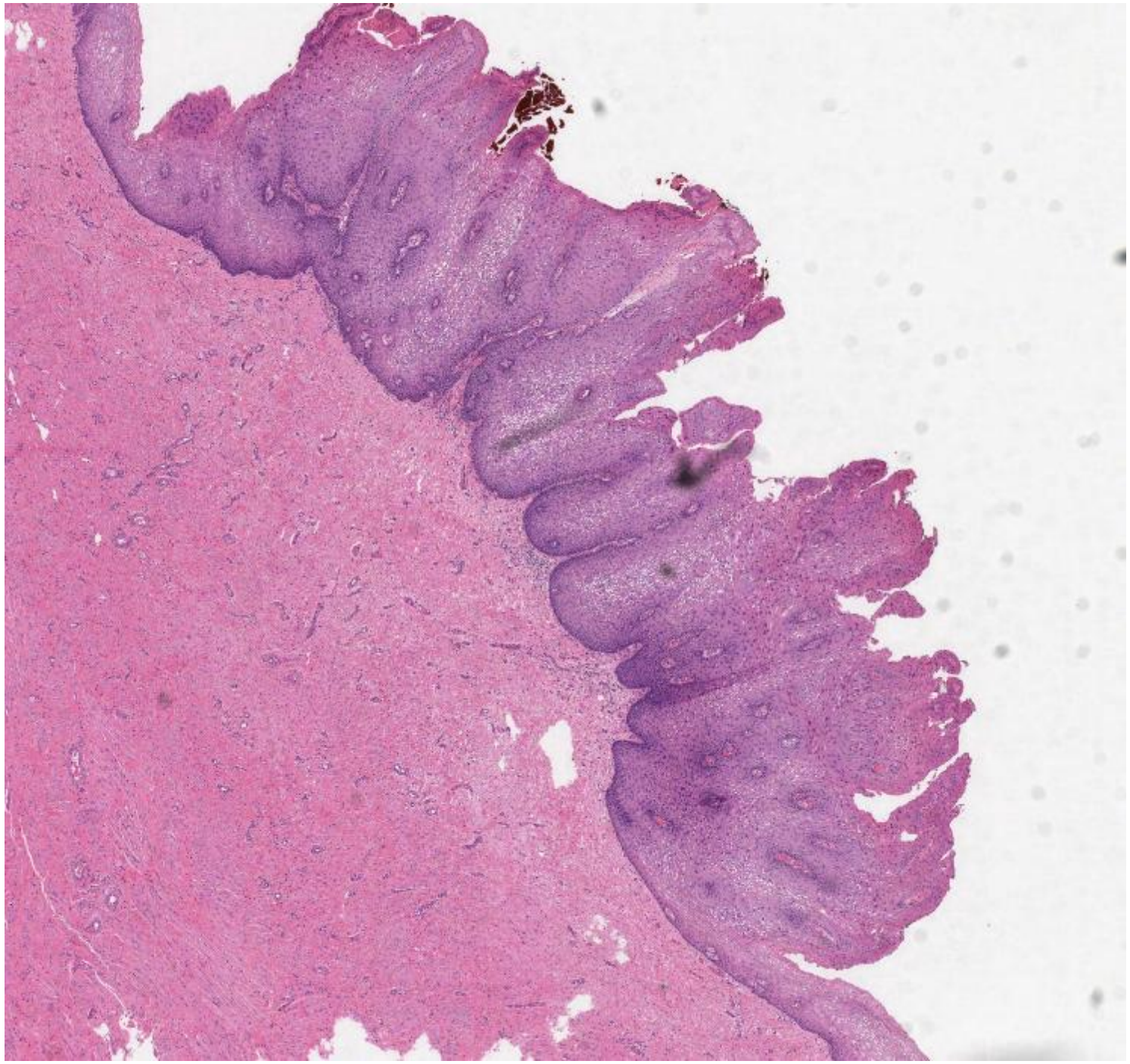

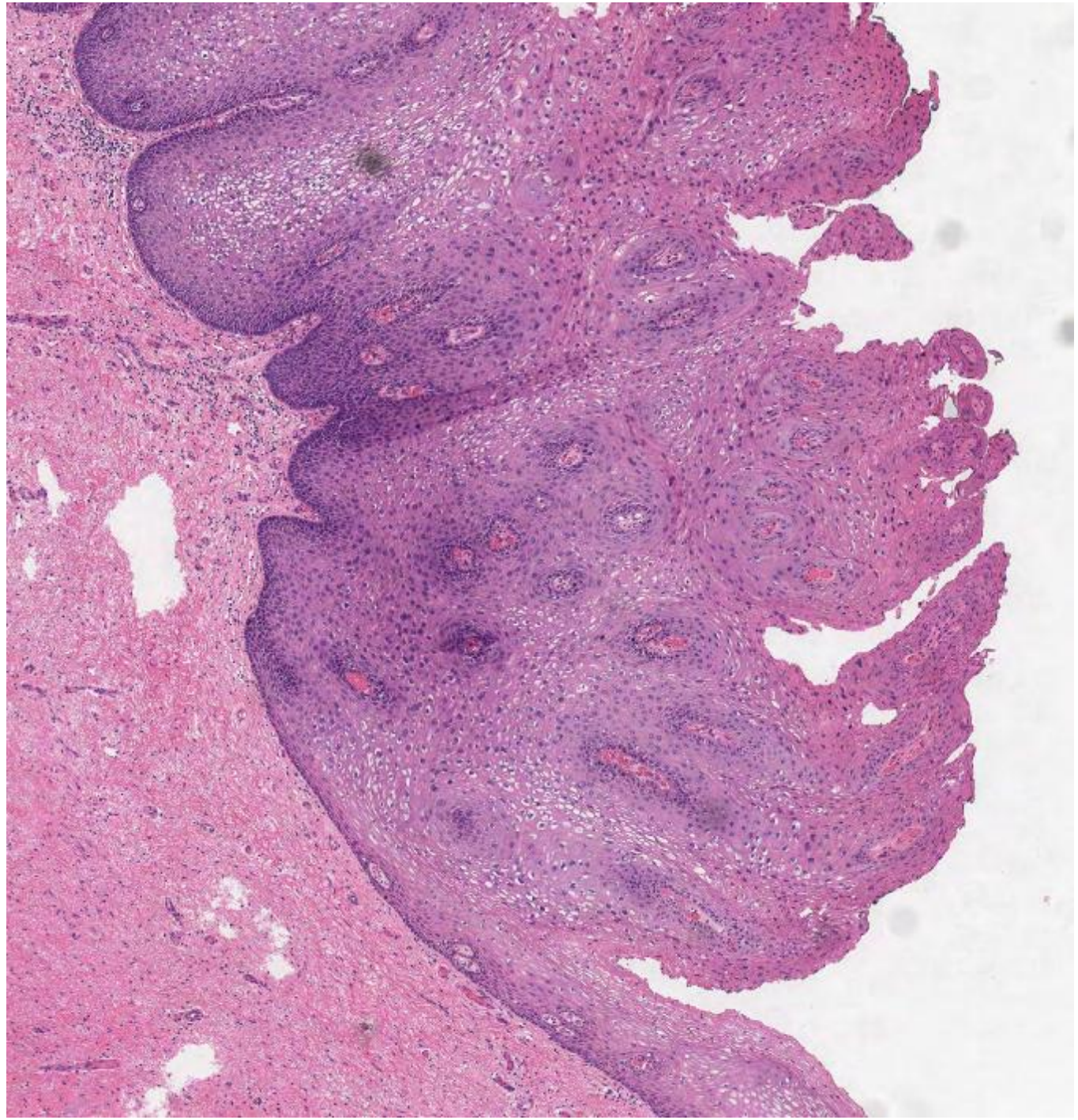

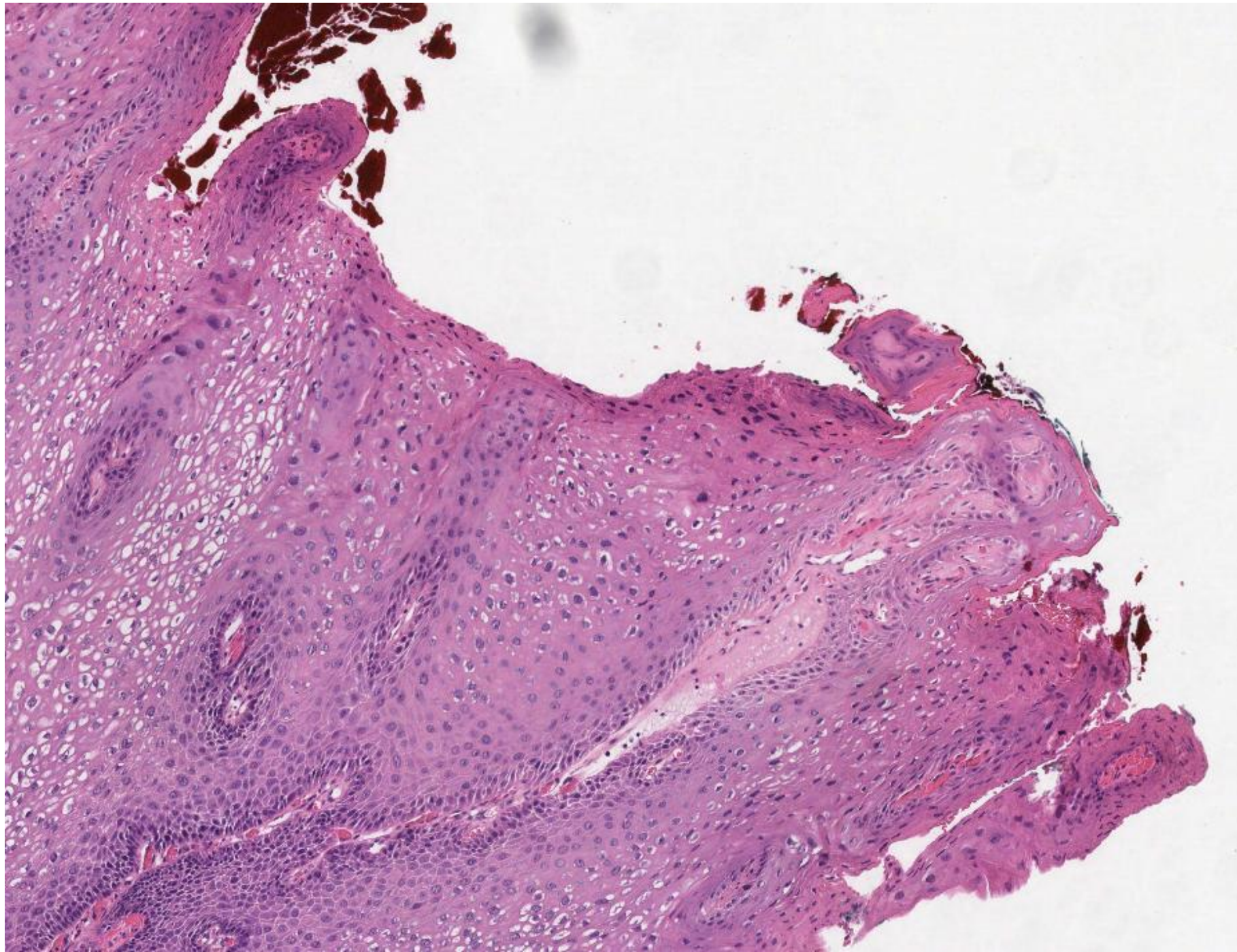

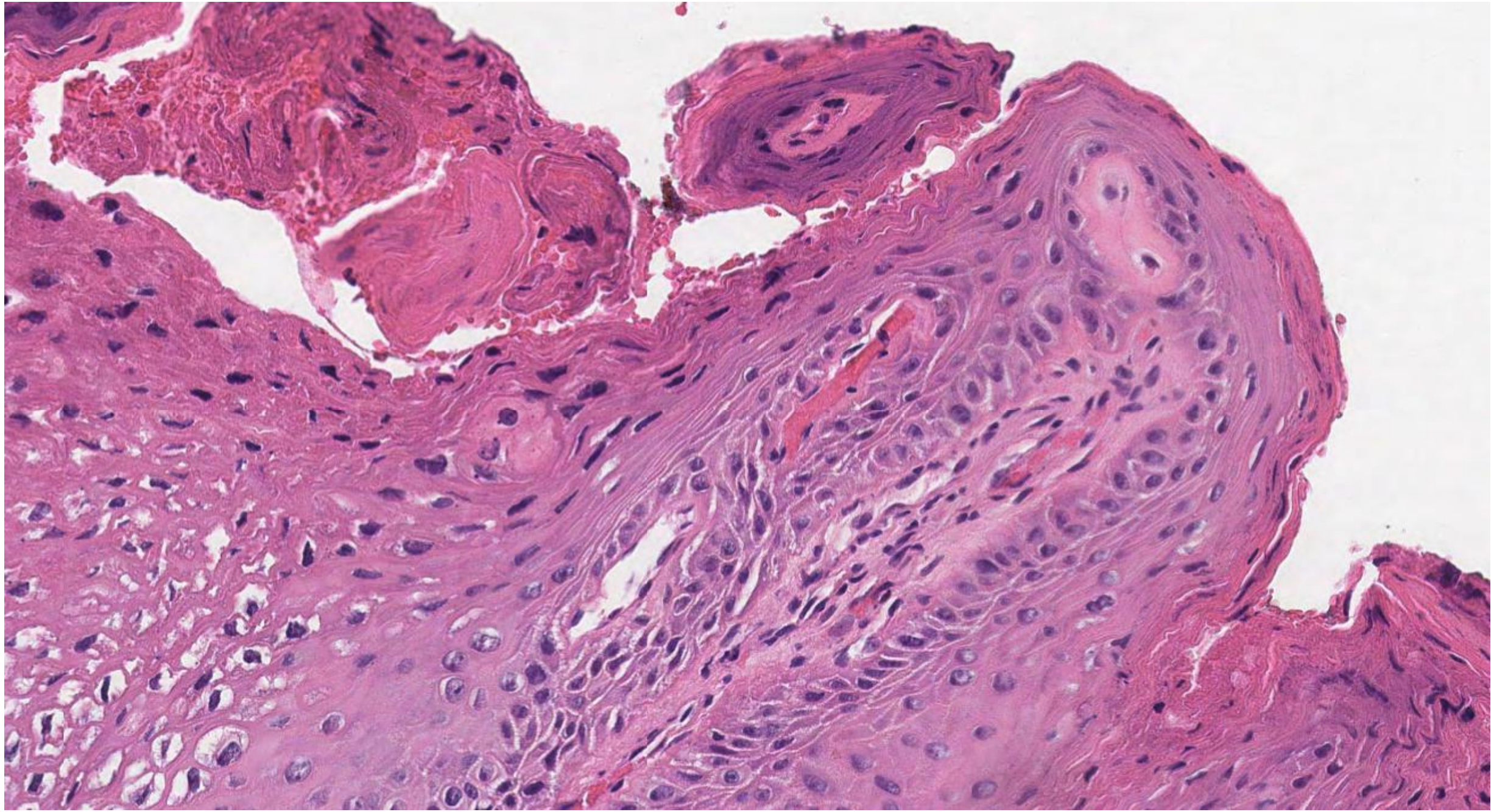

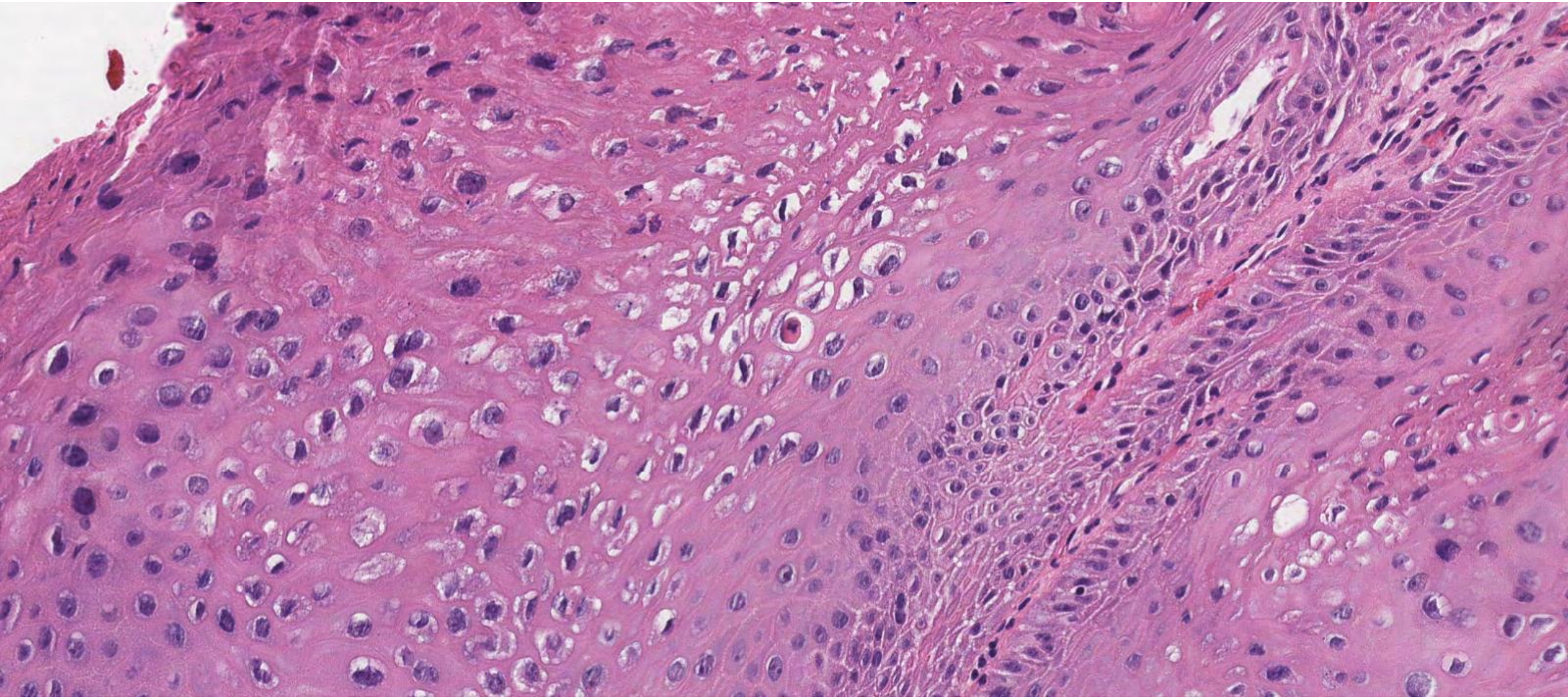

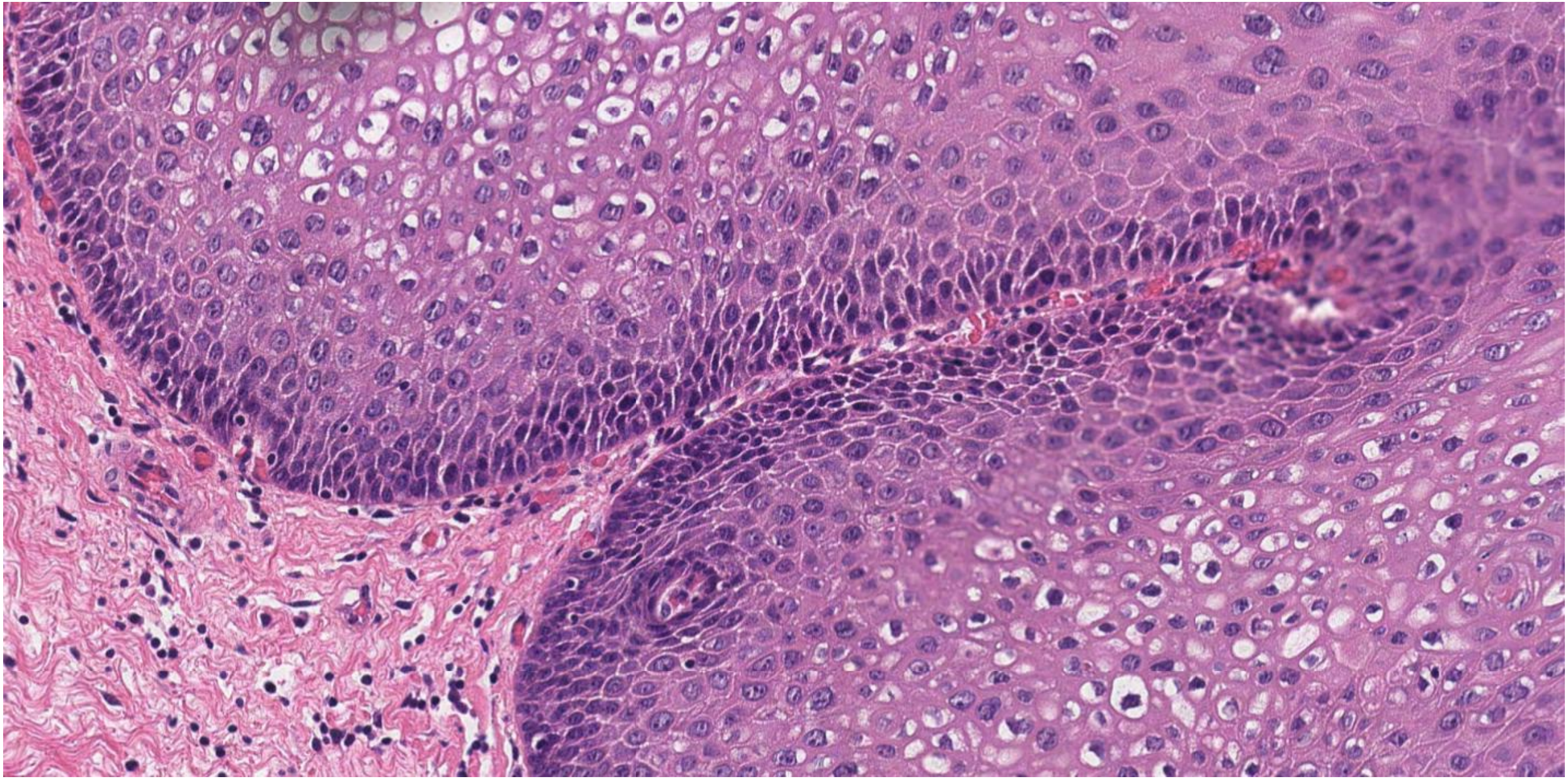

Condyloma

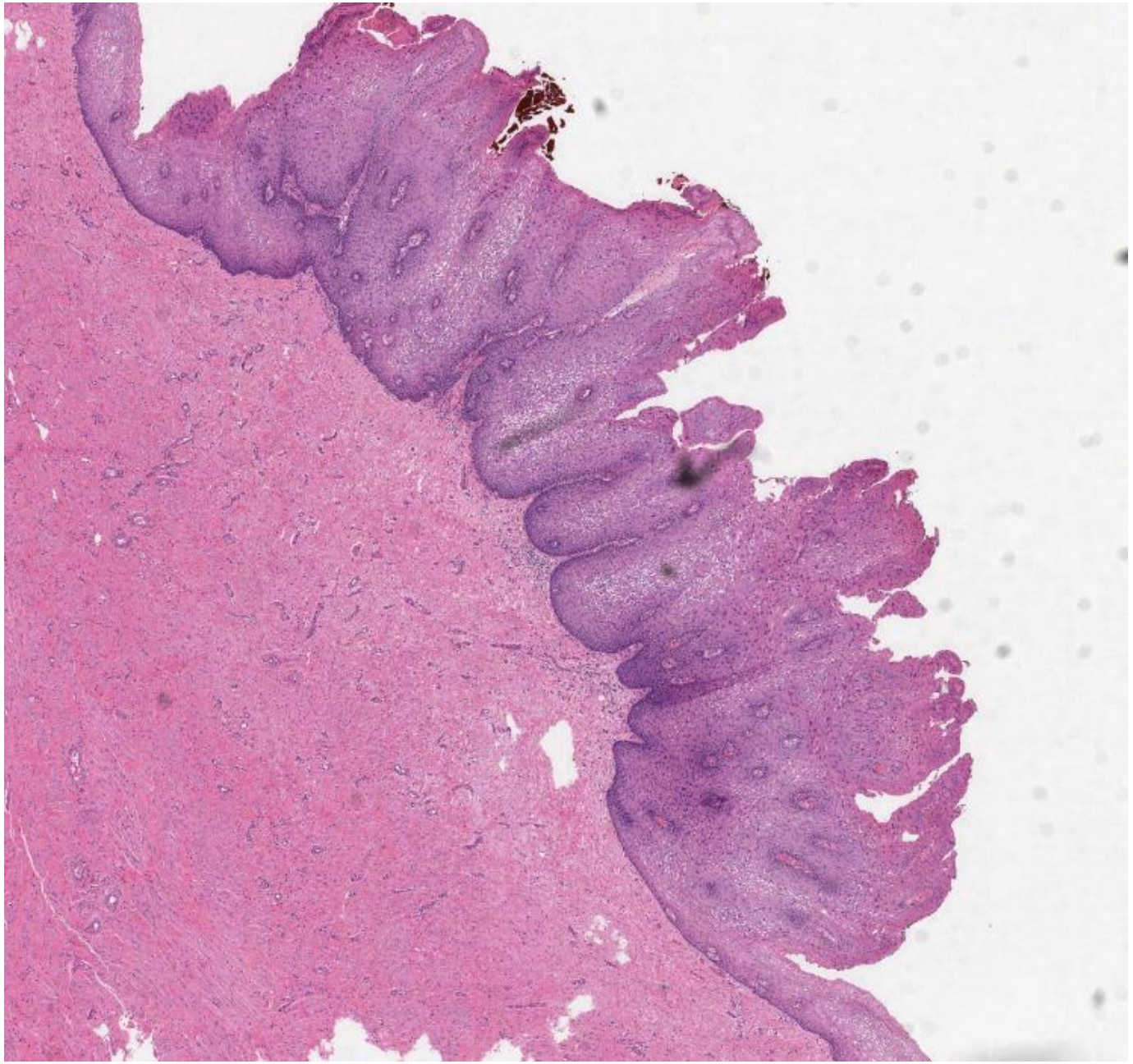

Case 17 – Vulval condyloma

Principle histological features

- Warty architecture
- Acanthosis, papillomatosis, hyperkeratosis and hypergranulosis
- Broad papillae with rounded ends
- Viral cytopathic effects:
  - variable koilocytosis, binuclear cells

Case 17 – Condyloma

DDx and how to resolve

▪ High-grade uVIN / HPVa VIN	Basaloid, acanthotic epithelium, viral cytopathic effects	Full-thickness nuclear atypia and mitoses
▪ dVIN	Often warty and acanthotic	Basal nuclear atypia Abnormal p53 immunohistochemistry
▪ VaVIN (HPV-independent, p53 wild type VIN)	Warty acanthotic lesion lacking atypia Wild-type p53	No viral cytopathic effects Typically present as ?SCC in older patients

Case 17

Additional extra marks?

- Limited scope
- Associated with low-risk genital HPV types (e.g. 6, 11)
- No real risk of progression to cancer

Case 18

- Specimen: Cervical biopsy
- Age: 22
- Clinical: Abnormal area on cervix seen when suturing perineal tear

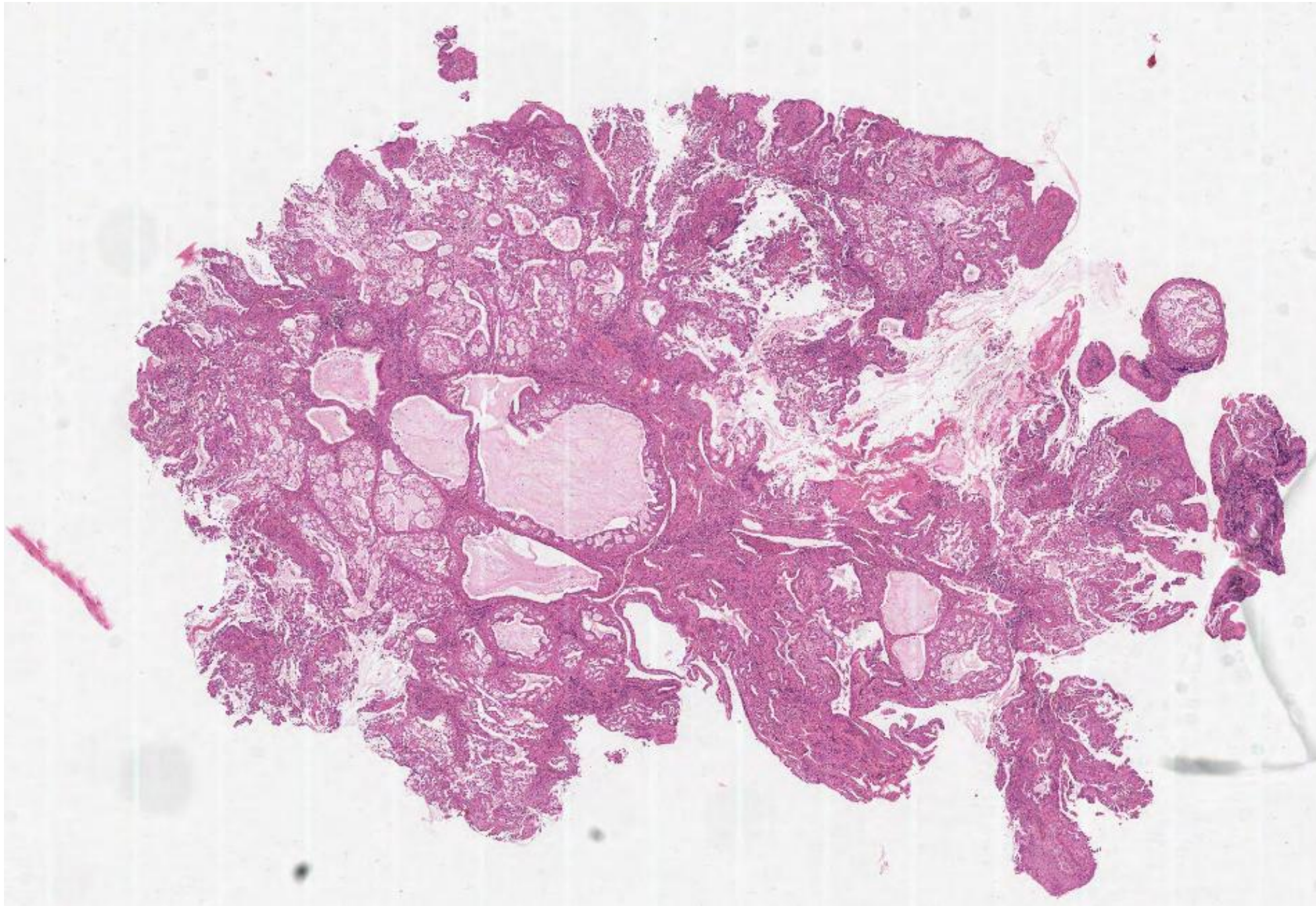

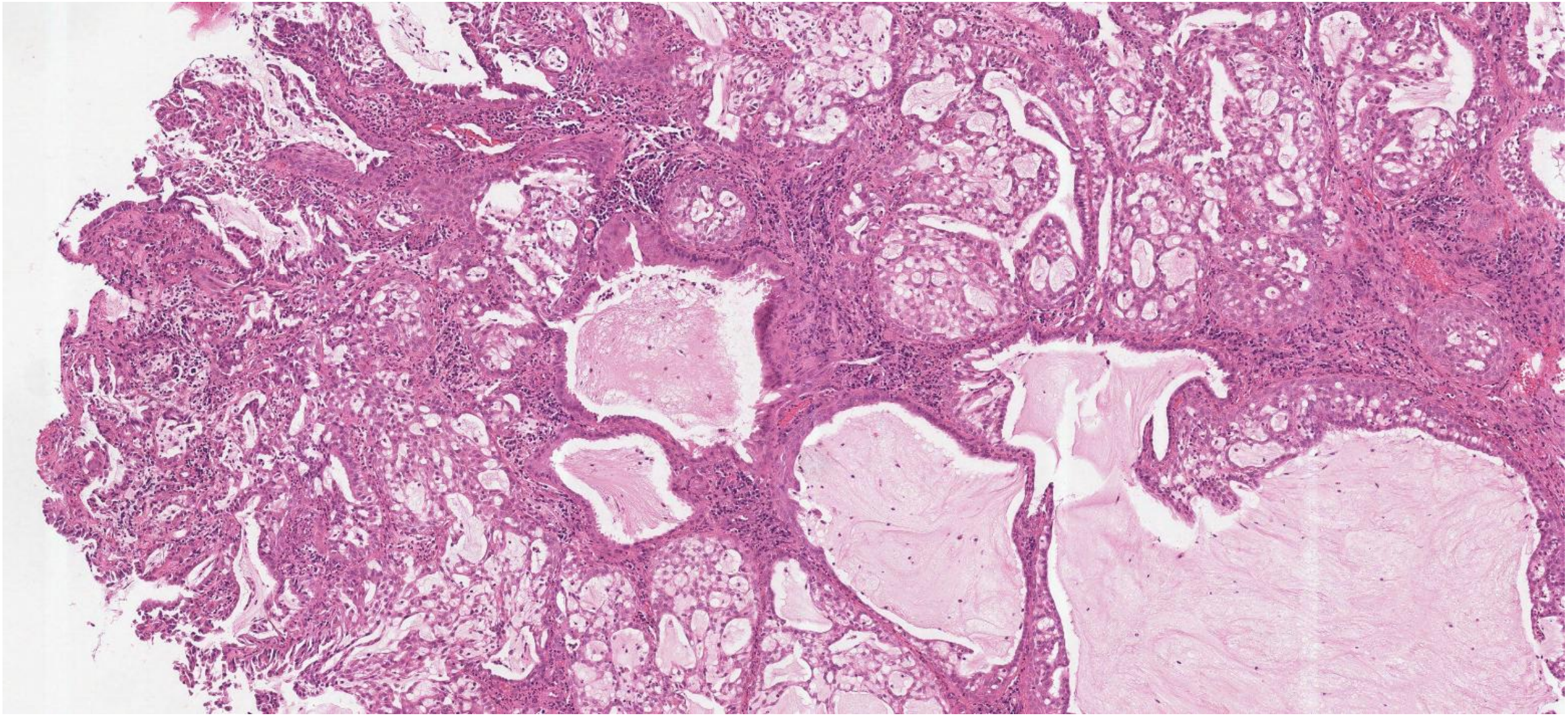

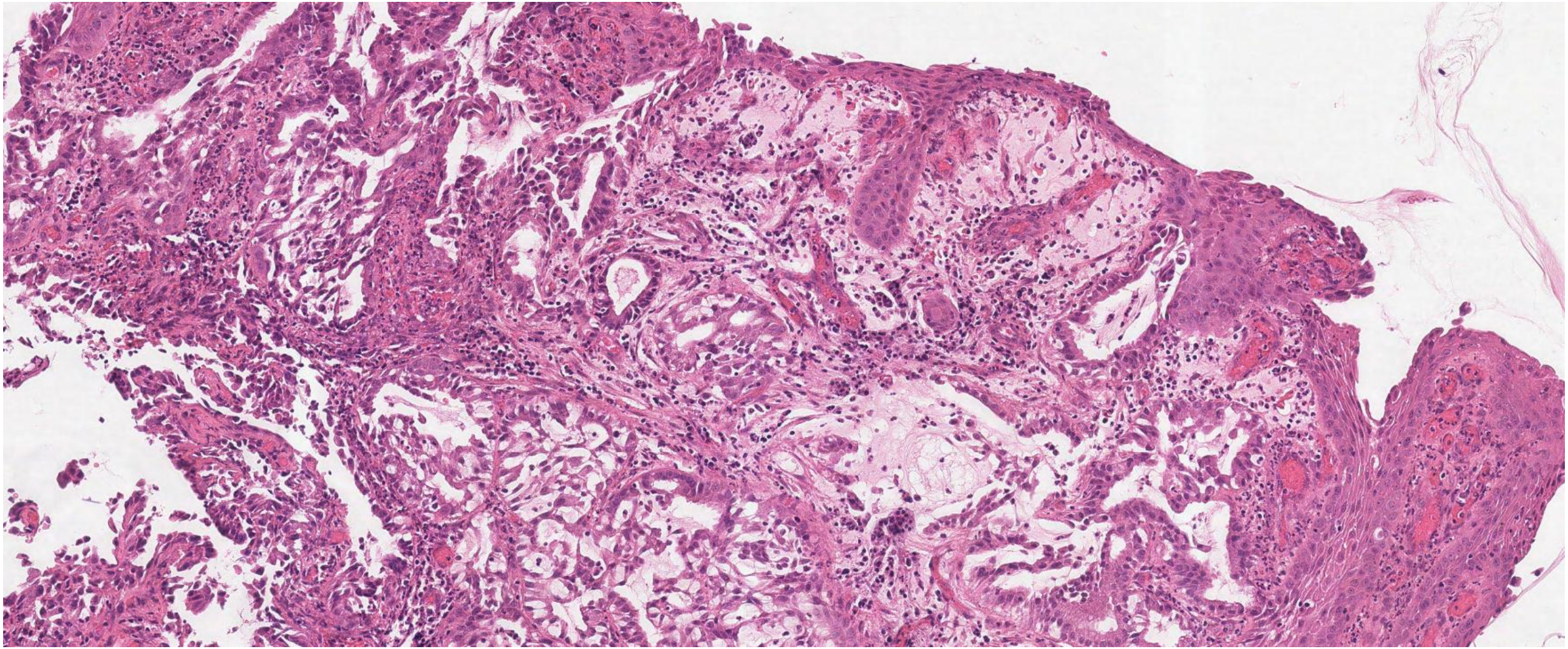

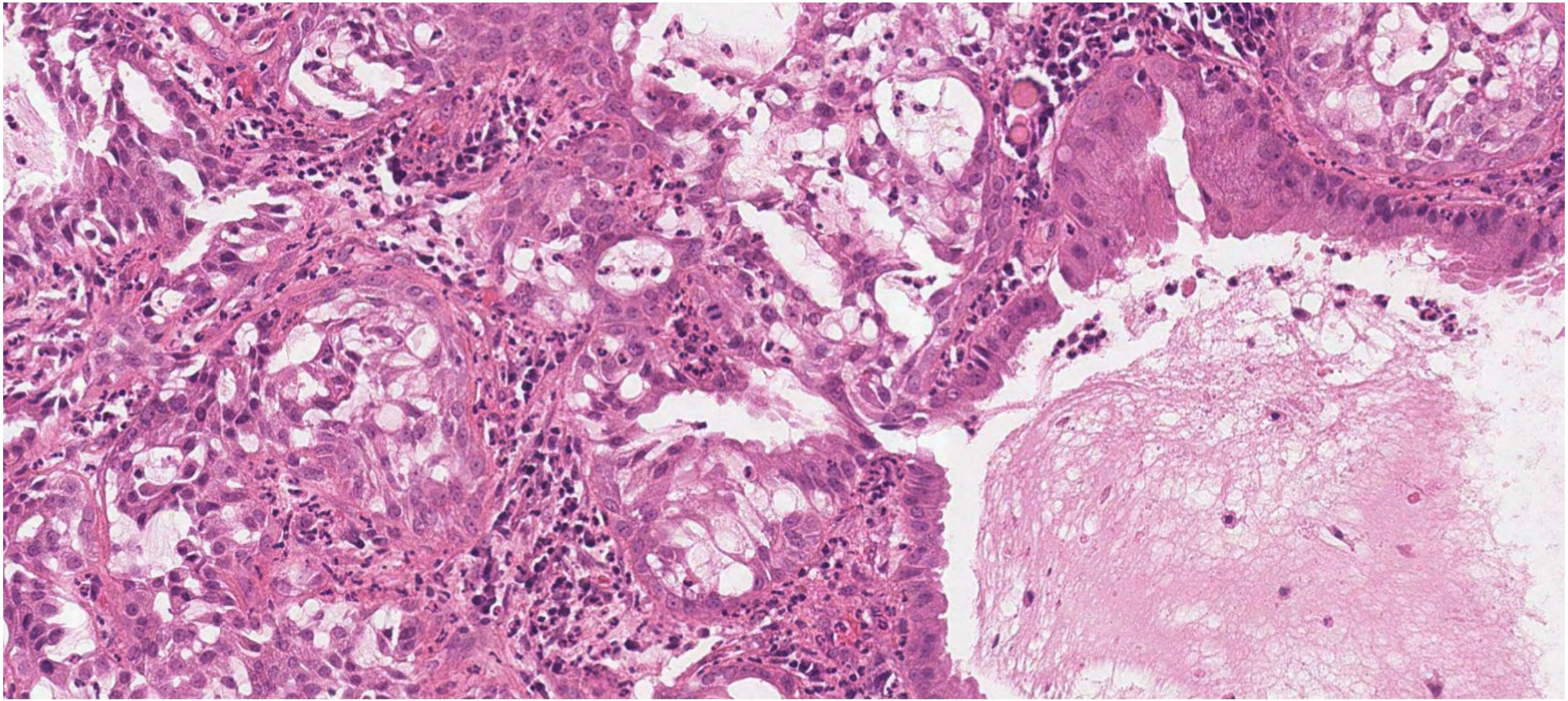

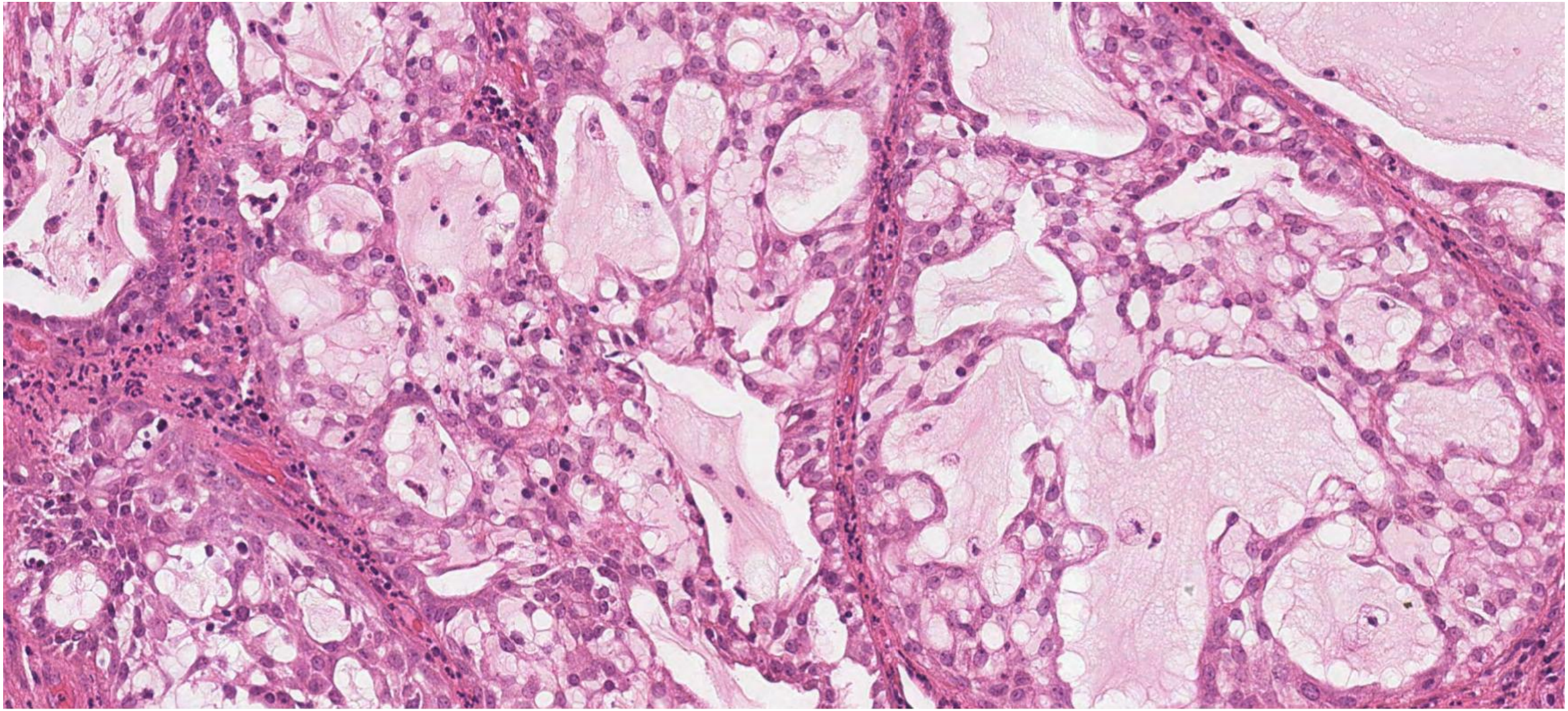

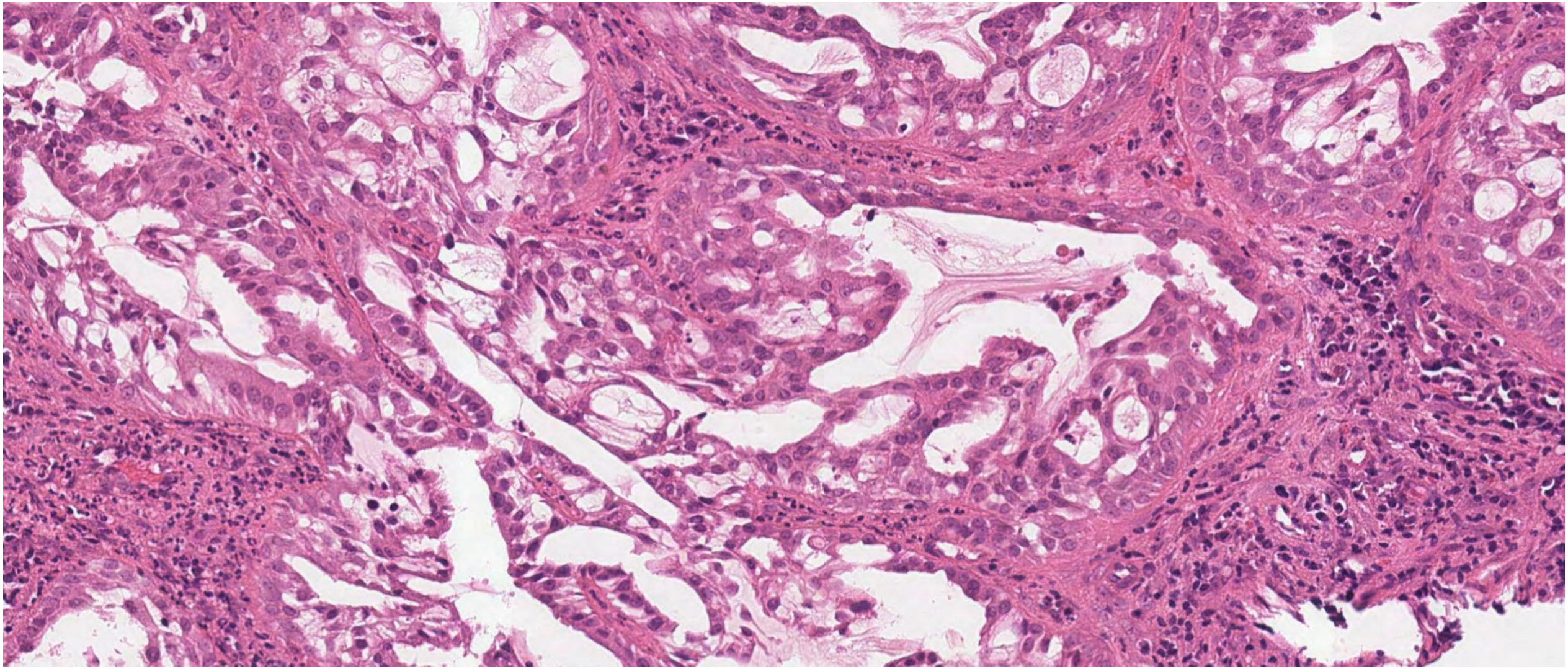

Microglandular hyperplasia

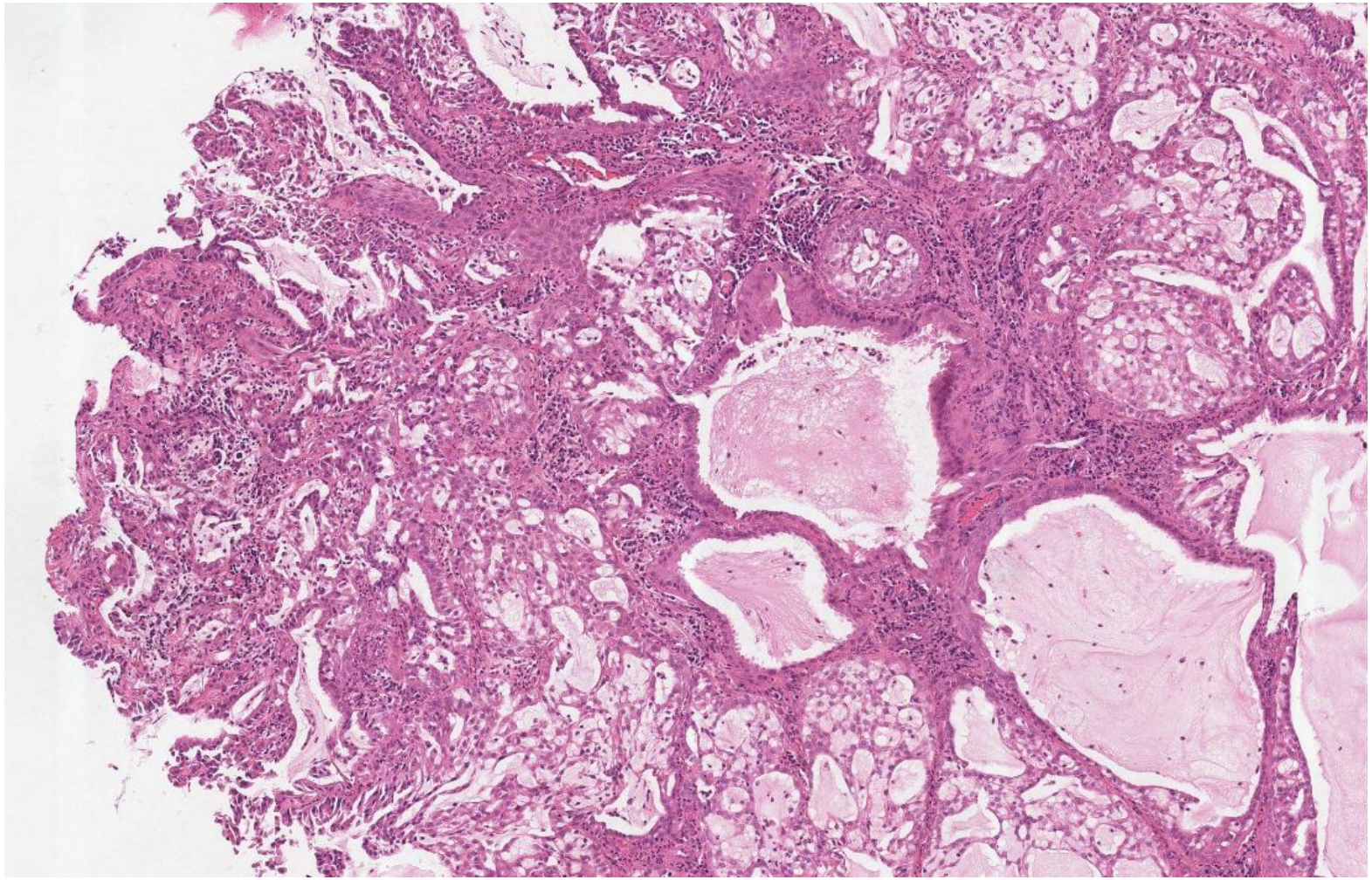

Case 18 – Microglandular hyperplasia

- **Principle histological features**

- Typically superficially located in endocervical canal; can be exophytic
- Complex proliferation of back-to-back tubular or dilated glands; scant intervening stroma
- Intraluminal mucin with acute inflammation and stromal inflammation
- Bland cuboidal cells +/- cytoplasmic vacuoles
- Variable presence of reserve cells
- Mitotic activity and atypia not expected

Microglandular hyperplasia in endocervix

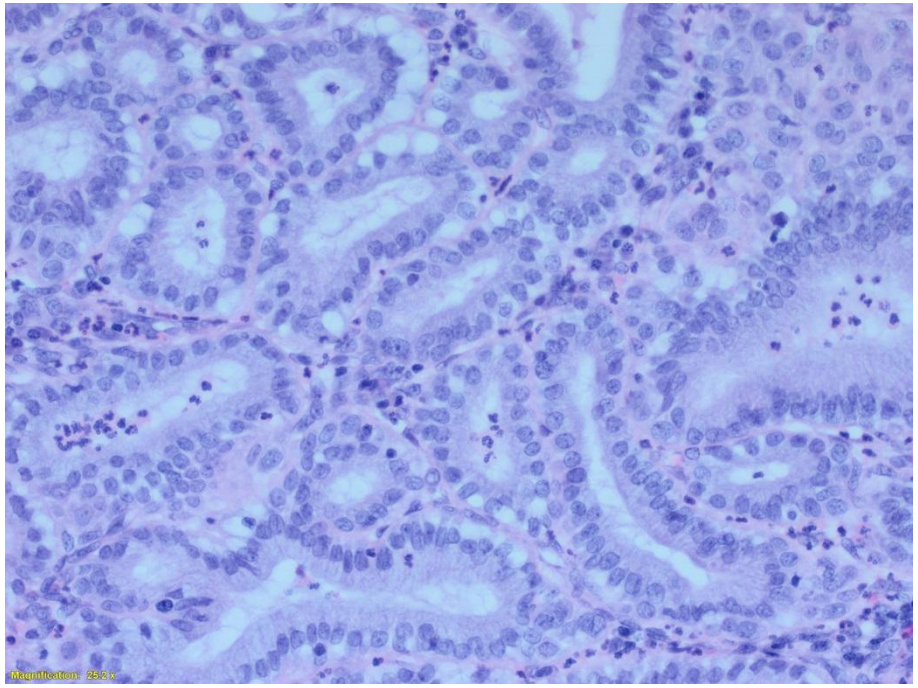

Endometrioid carcinoma with microglandular pattern

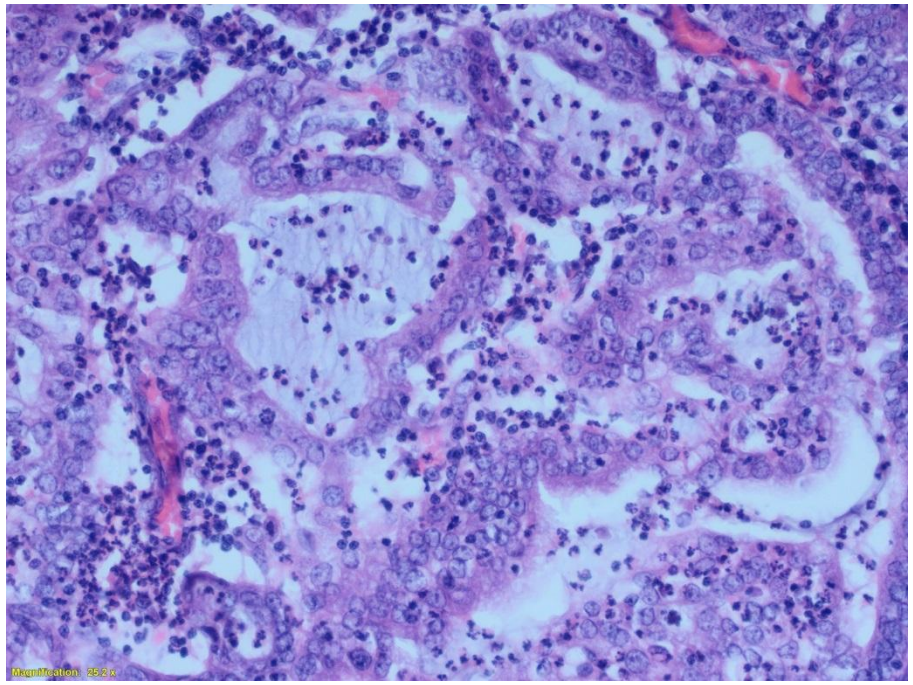

Misdiagnosis possible on endometrial biopsy

How to distinguish

- Large volume of material with microglandular architecture in a biopsy raises alarm bells, especially if no progestogenic stimulus
- Look out for more conventional endometrioid morphology
- Atypia and mitotic activity great than expected for MGH
- Immuno not necessarily reliable
  - MGH vimentin negative, Endometrioid carcinoma vimentin positive ?
  - Hormone receptors not consistent but negative/weak/focal points to MGH (diffuse positivity unhelpful)
  - p63 and CK17 highlighting reserve cells

Case 19

- Specimen: Endometrial polyp
- Age: 56
- Clinical: Post menopausal bleeding

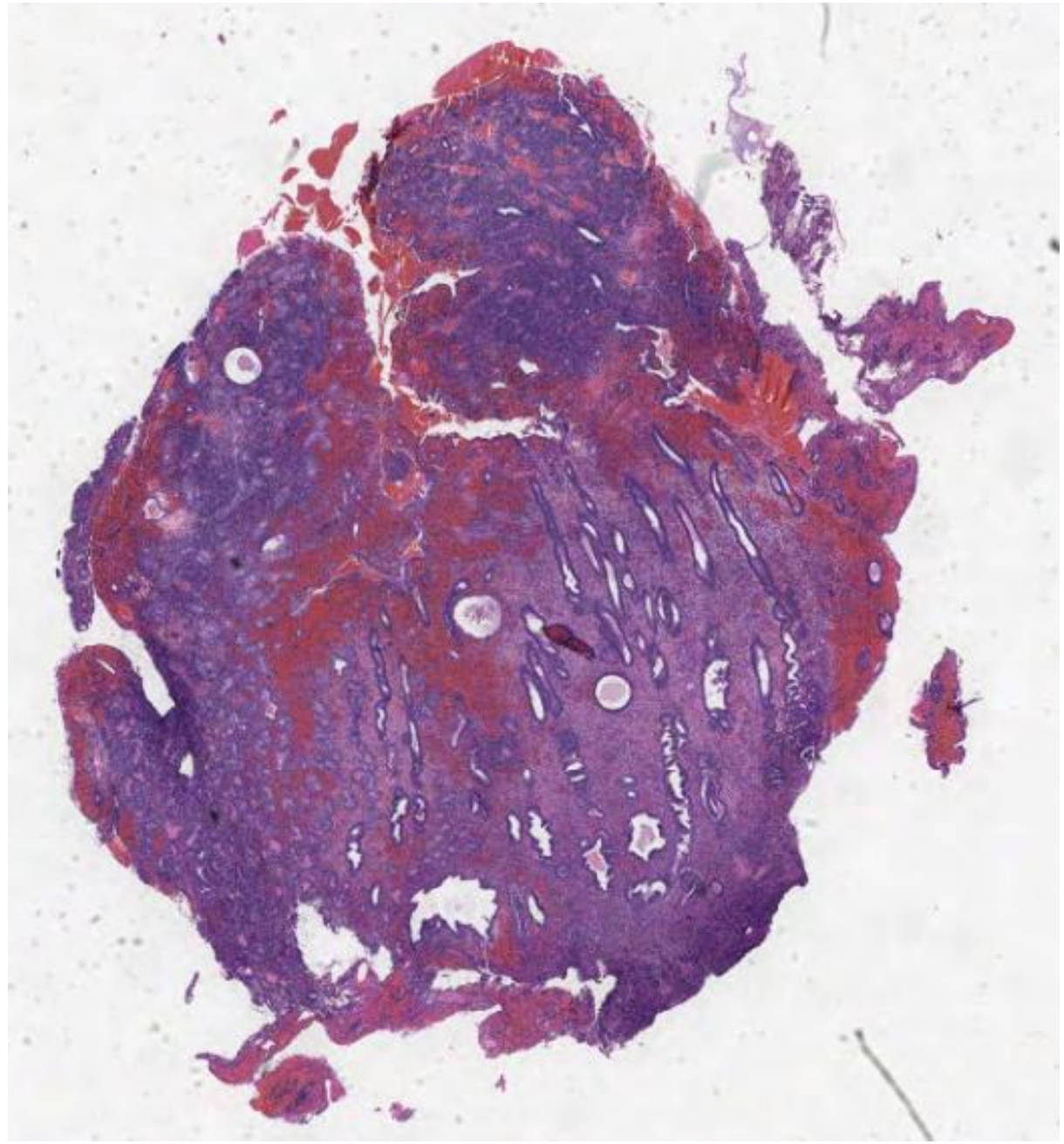

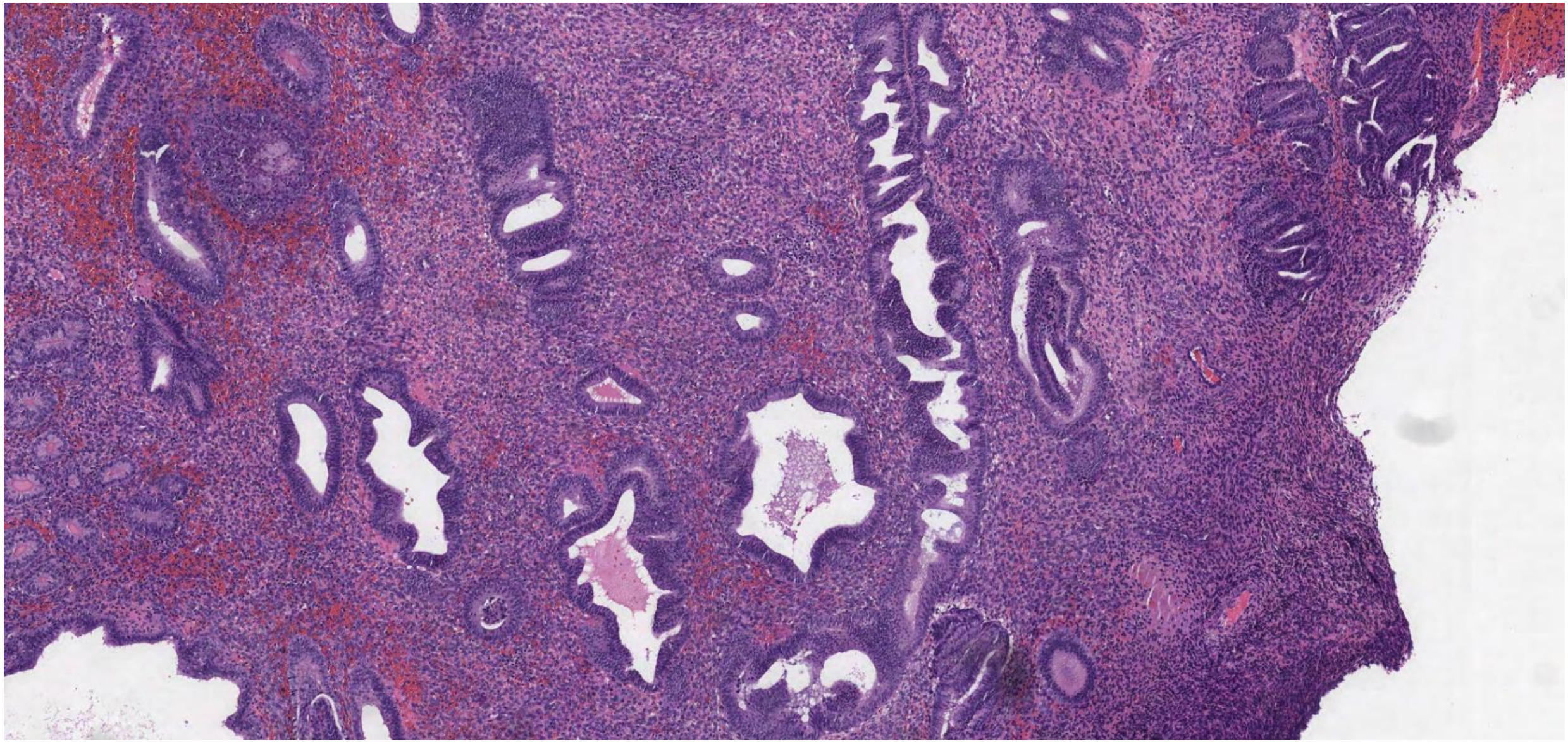

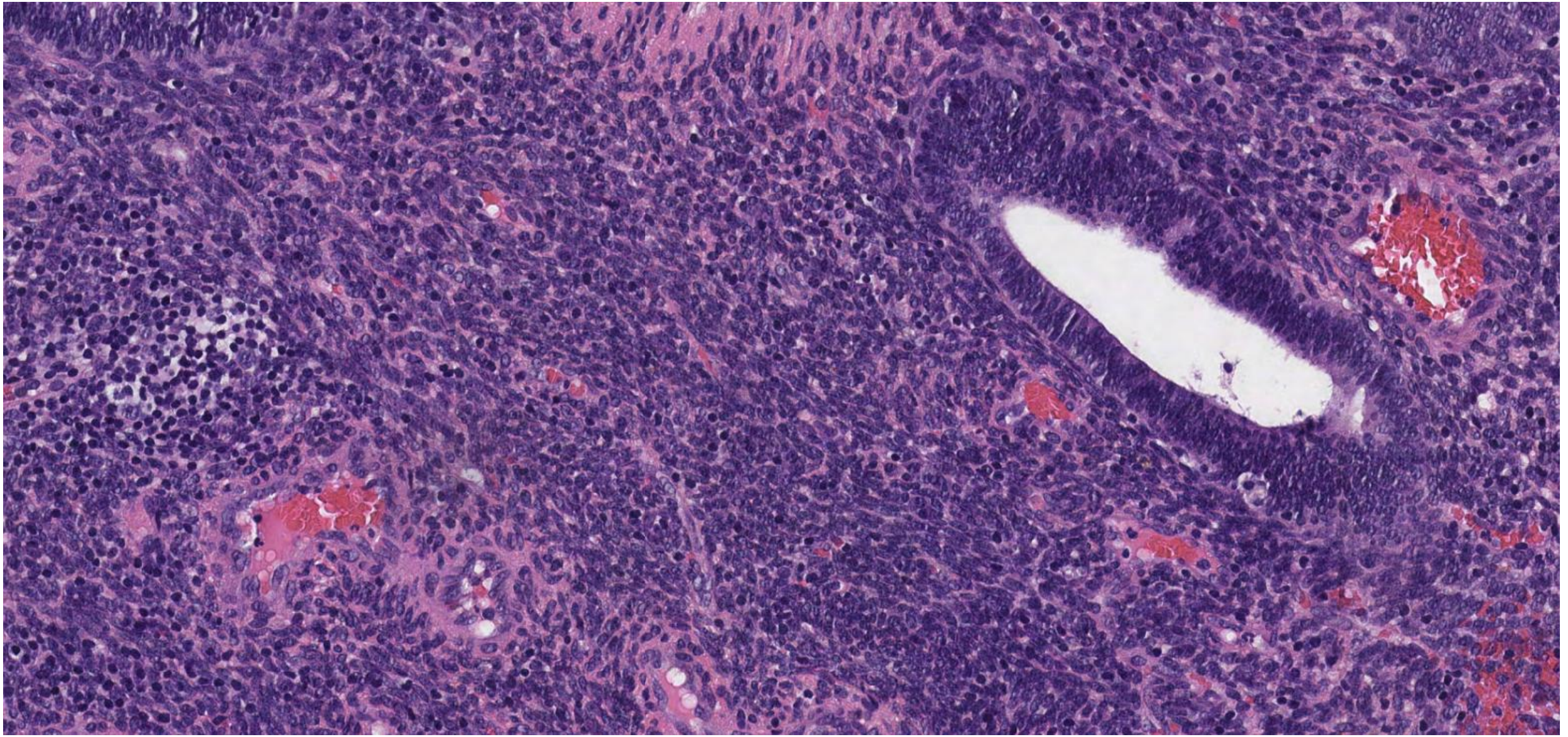

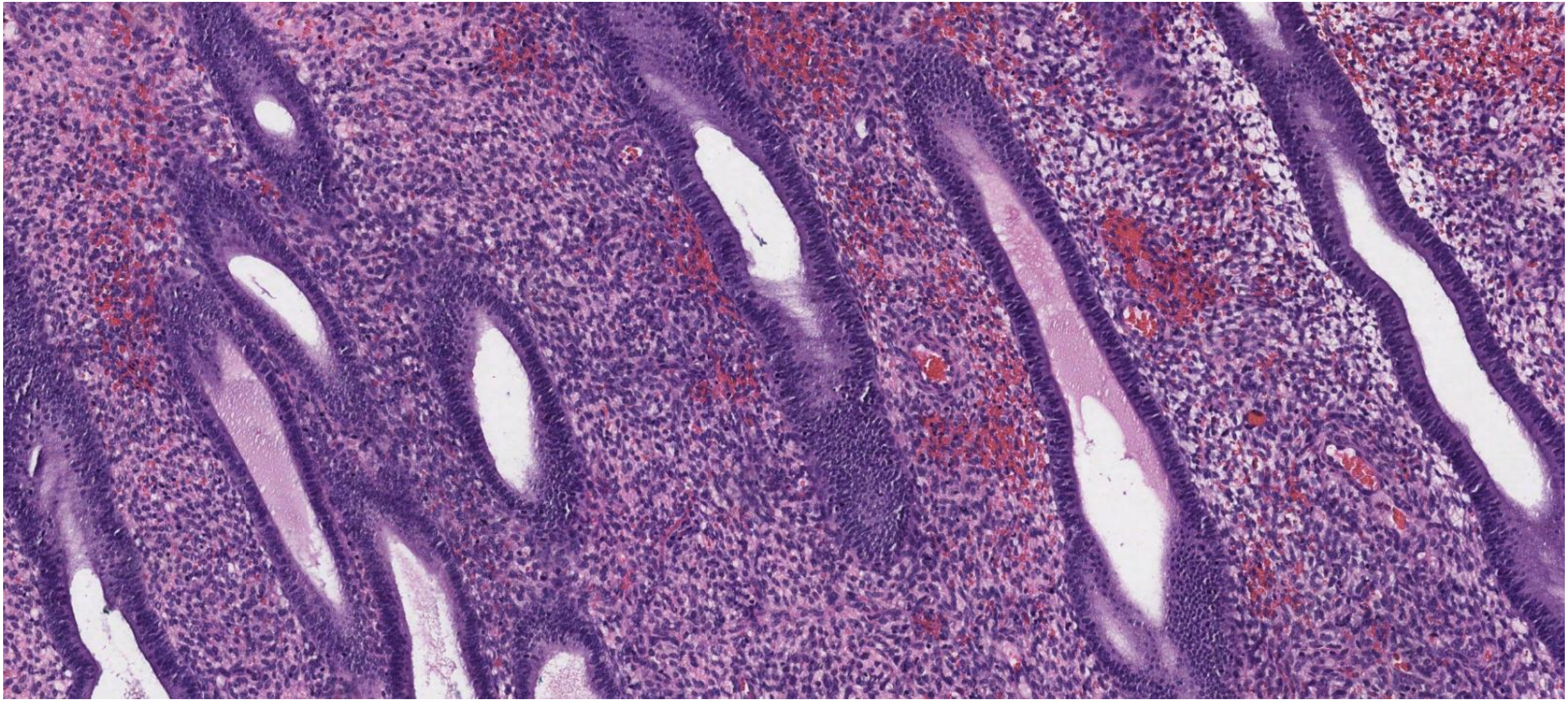

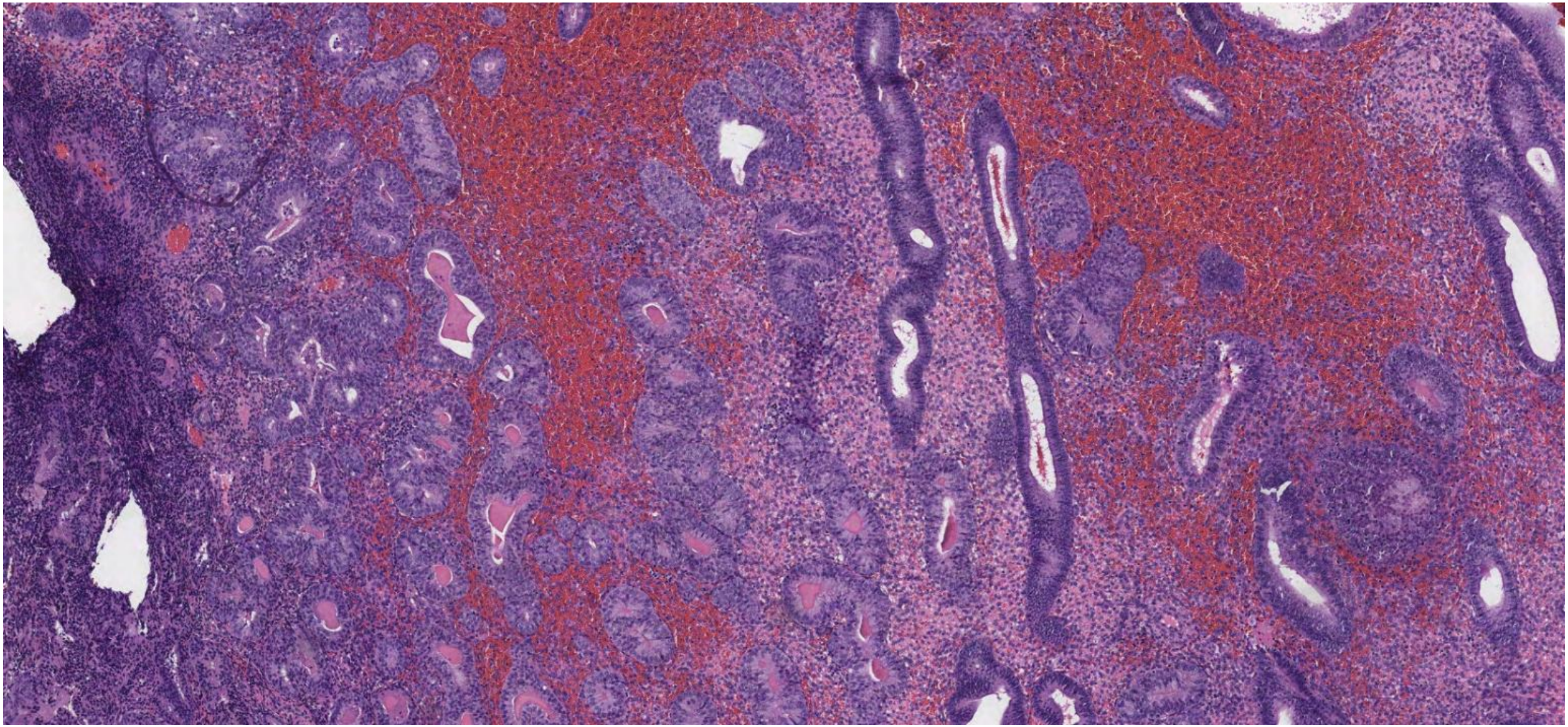

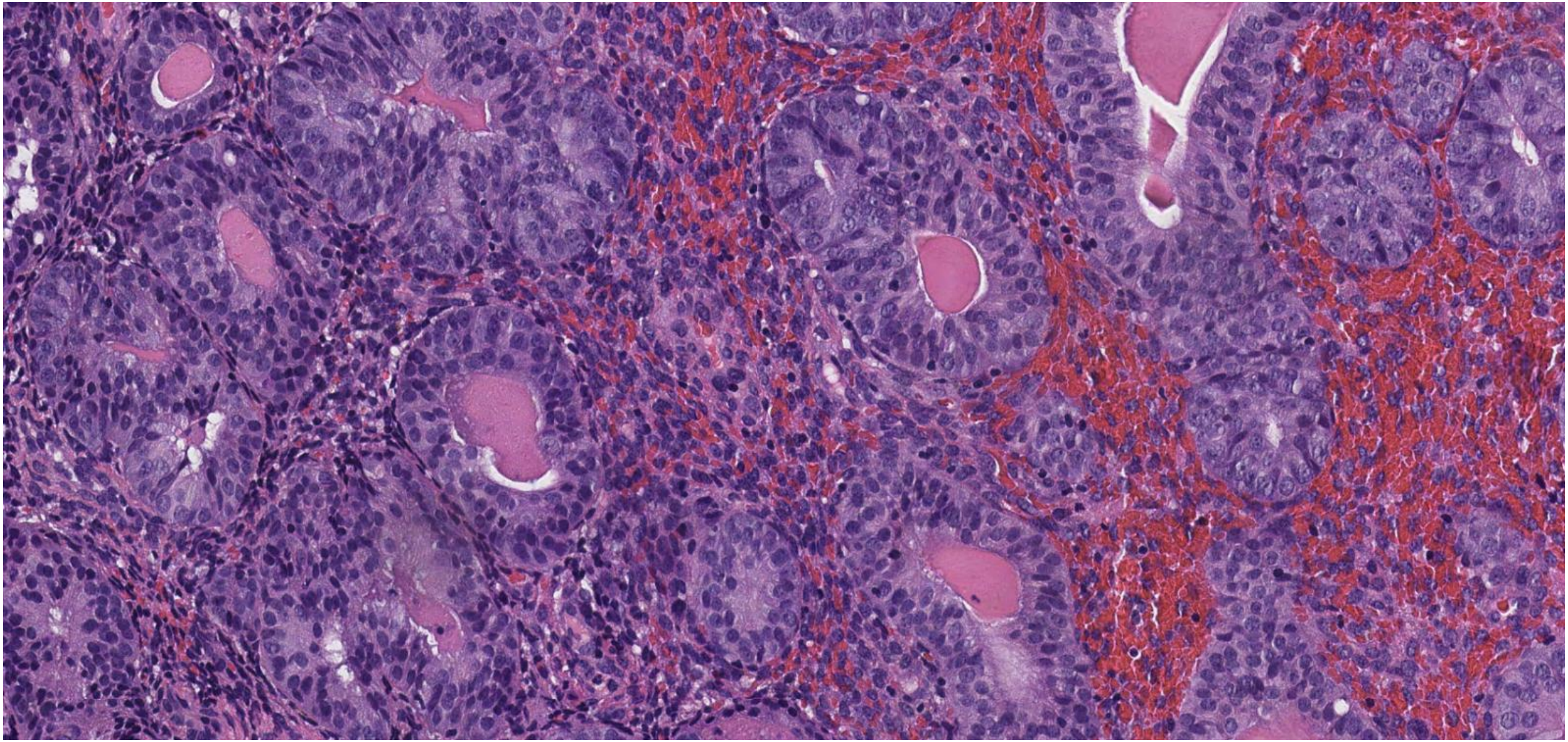

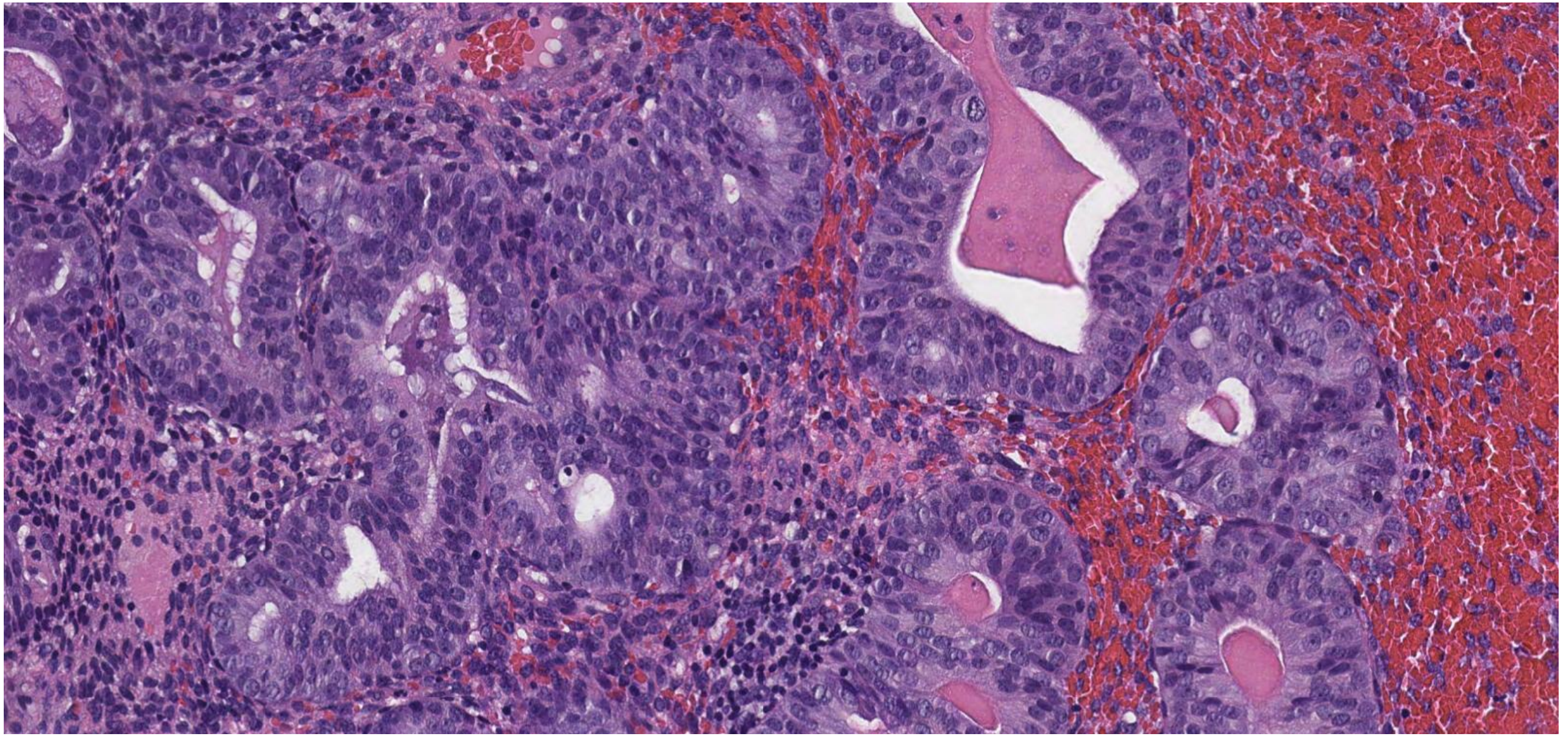

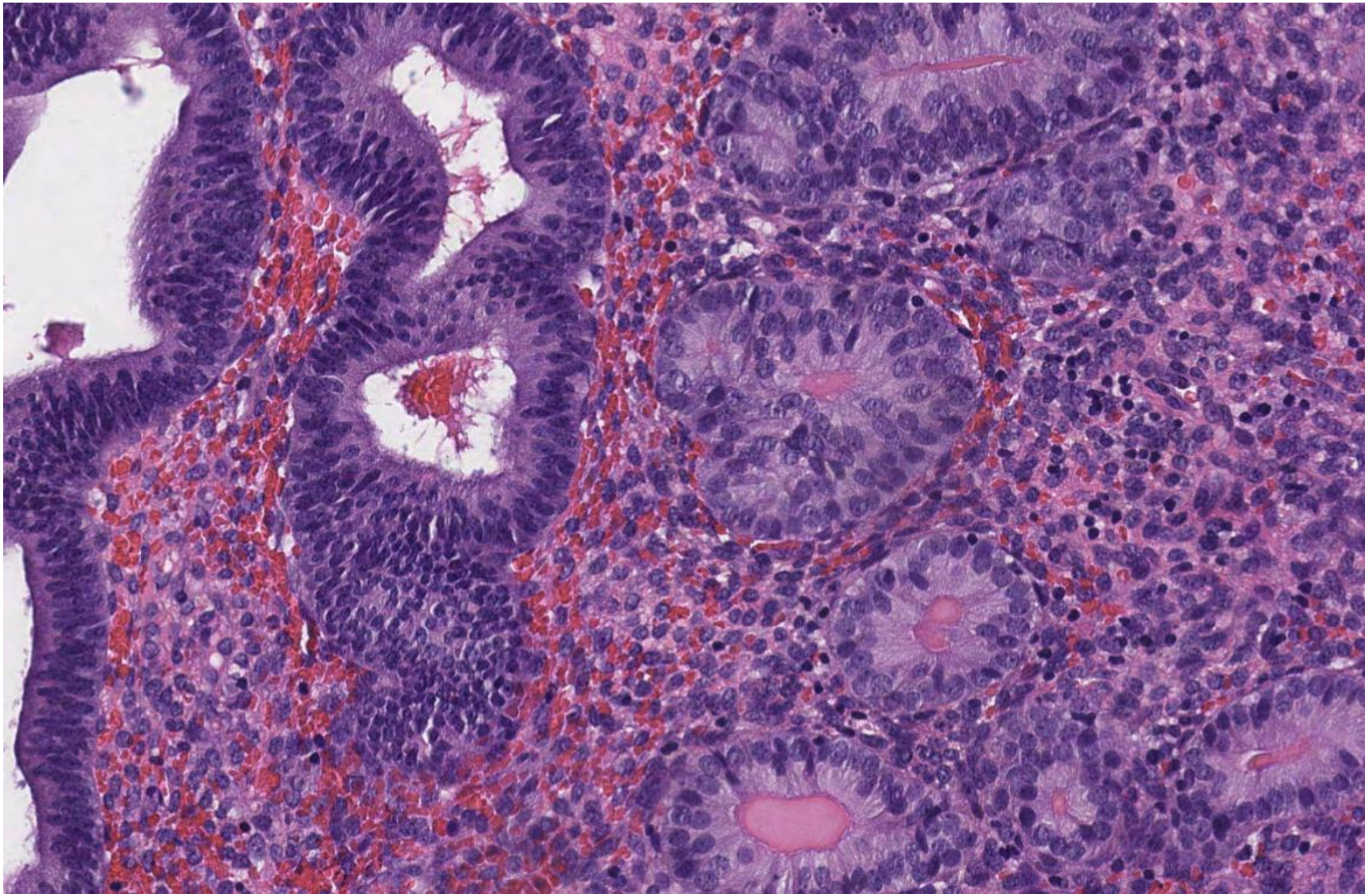

Atypical hyperplasia (in an endometrial polyp)

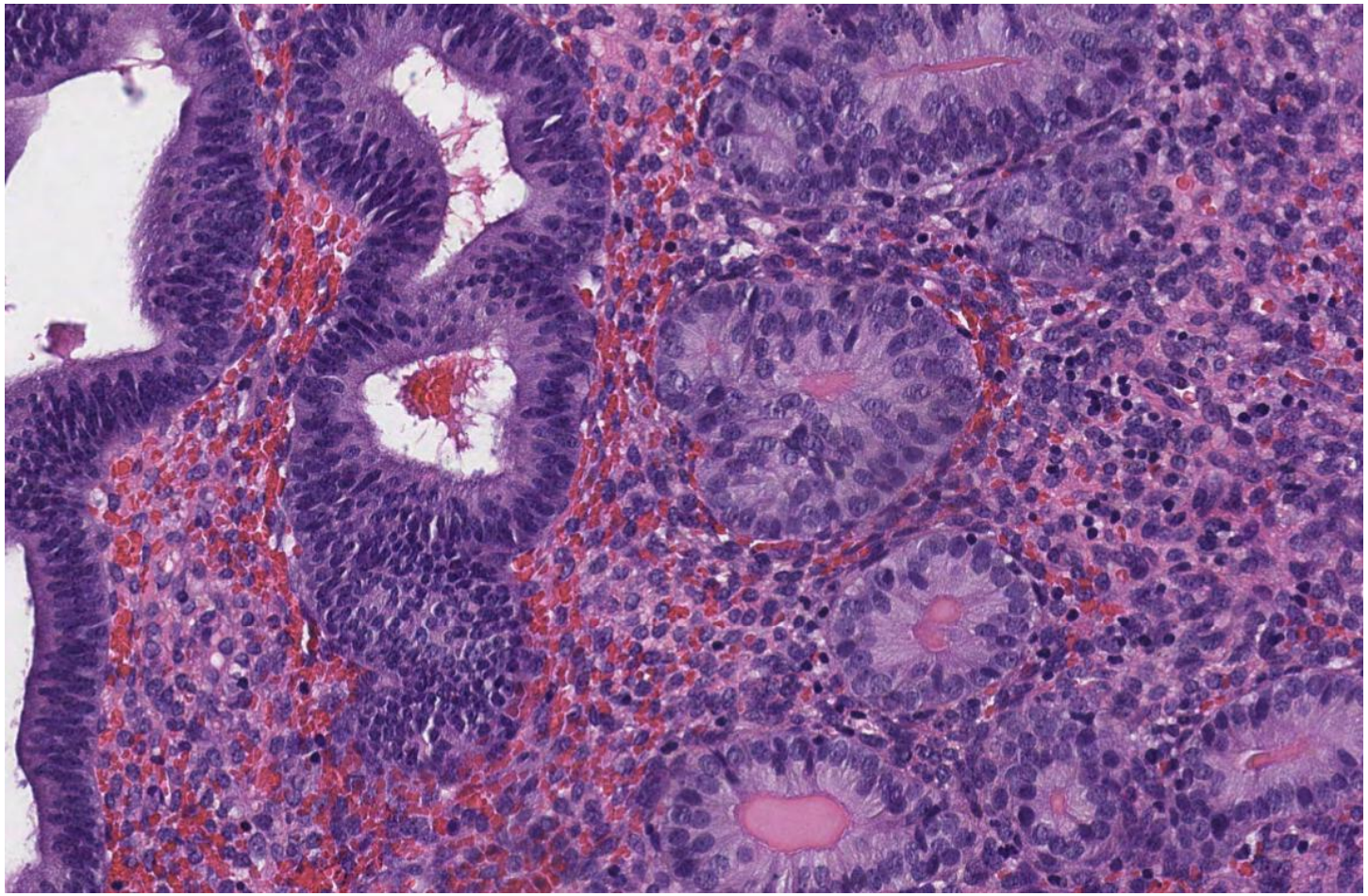

Case 19 – Atypical hyperplasia

Principle histological features

Architecture

- Closely packed glands such that gland to stroma ratio is > 2:1 but stroma is still present between glandular basement membranes (however minimal)
- No or minimal gland fusion or cribriform architecture
- Glands show cystic dilatation or irregular luminal contours (budding, angulation, invagination, outpouching, papillary projections)

Cytology

- Typically enlarged, rounded and irregular nuclear contours, coarse chromatin, nucleoli
- Loss of polarity / stratification
- Superimposed metaplastic changes can be seen

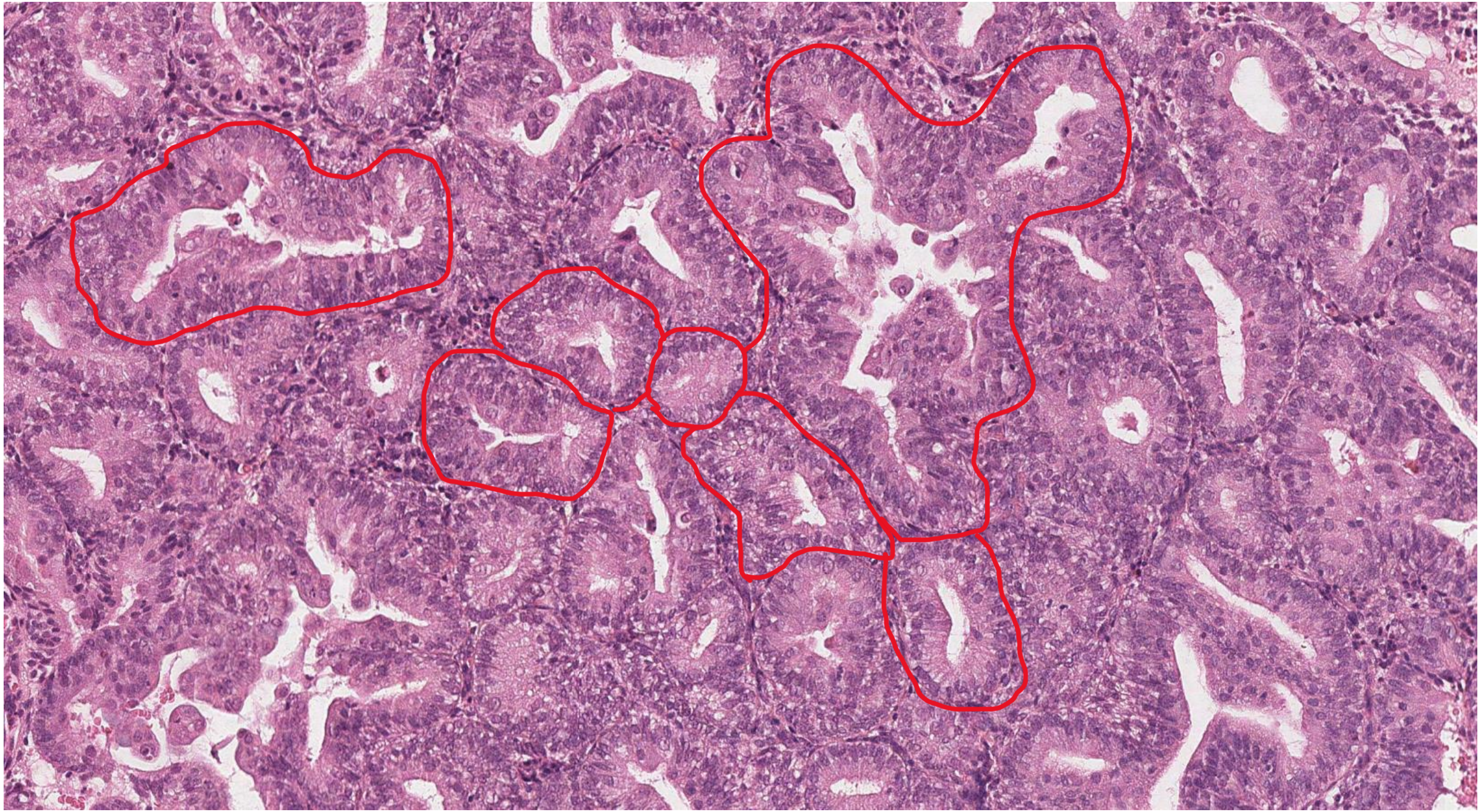

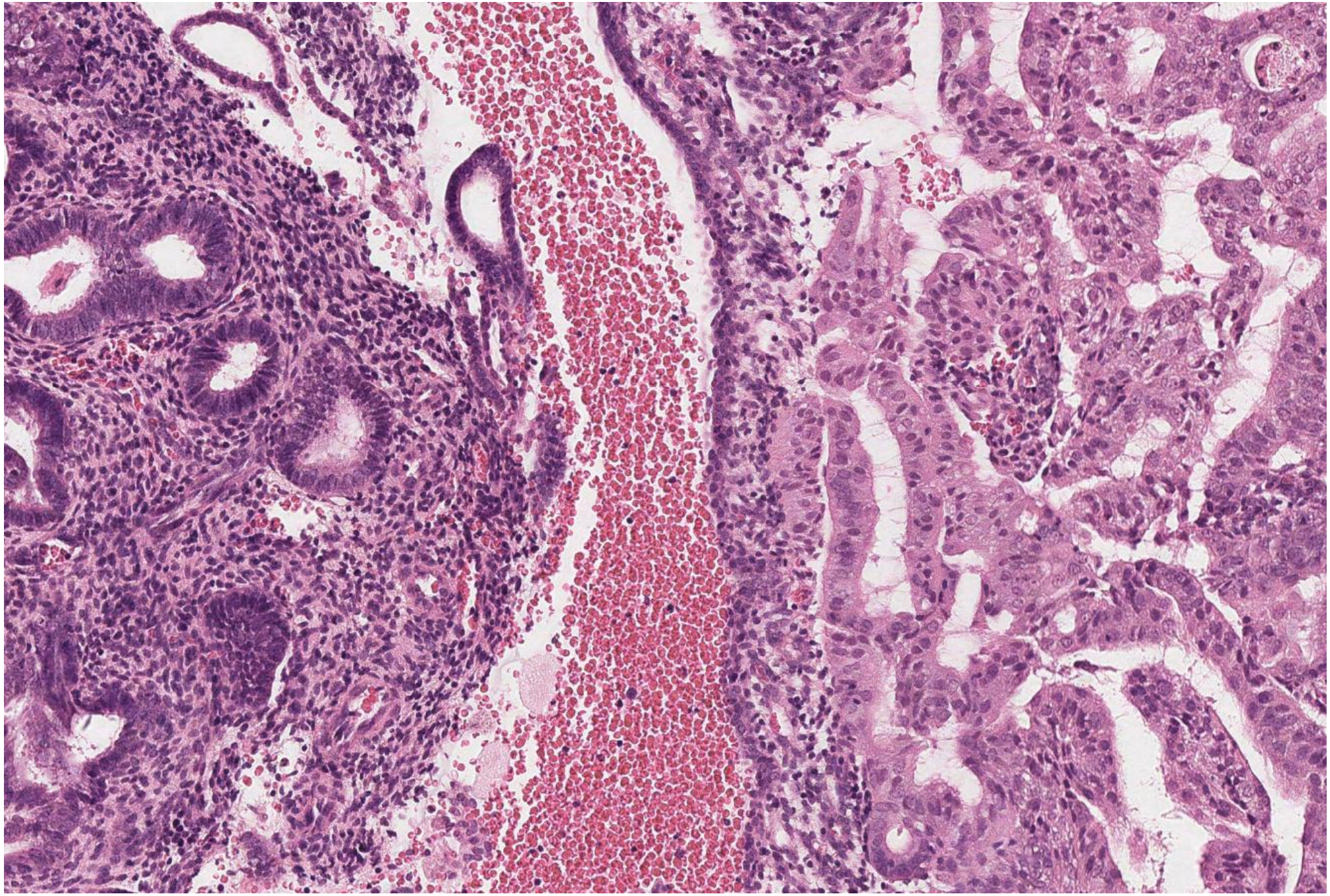

Case 19 – Atypical hyperplasia

Extra information

- Synonymous with EIN (Endometrial intraepithelial carcinoma)
- High risk of concurrent or subsequent endometrioid carcinoma
- Hysterectomy +/- BSO is preferred treatment
- Fertility sparing options esp. if AH confined to polyp – Mirena with follow-up biopsy no sooner that 6 months after insertion.

Case 19 – Atypical hyperplasia

DDx and how to resolve

▪ Non-atypical hyperplasia	Raised gland to stroma ratio	Does not show cytological atypia
▪ Grade 1 endometrioid carcinoma	Crowded atypical glands, usu. proliferative type +/- metaplastic changes	Fusion of glands, intraglandular bridging, cribriform +/- myoinvasive
▪ Mesonephric-like carcinoma	Invasion as dispersed/non-fused glands seen	Should see low cuboidal, bland epithelial cells lining tubules, at least focally i.e. less nuclear atypia ER negative (or minimal, focal +) TTF1, GATA3, luminal CD10 +

Case 19 – Atypical hyperplasia

DDx and how to resolve

- Non-atypical hyperplasia — Raised gland to stroma ratio — Does not show cytological atypia
- Grade 1 endometrioid carcinoma — Crowded atypical glands, usu. proliferative type +/- metaplastic changes — Fusion of glands, intraglandular bridging, cribriform +/- myoinvasive

Distinction not always possible on biopsy

Case 20

- Specimen: POC
- Age: 37
- Clinical: History of recurrent miscarriage.

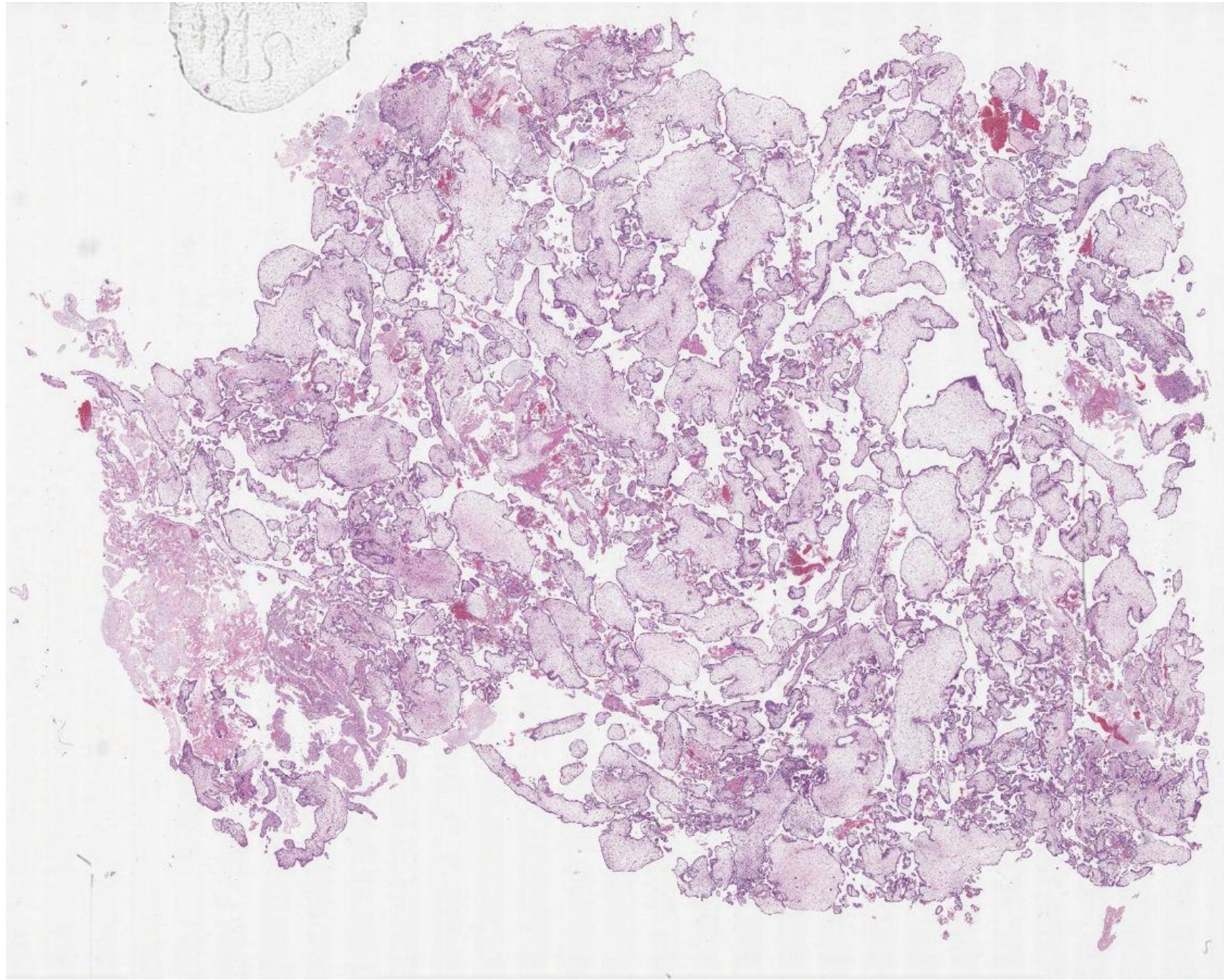

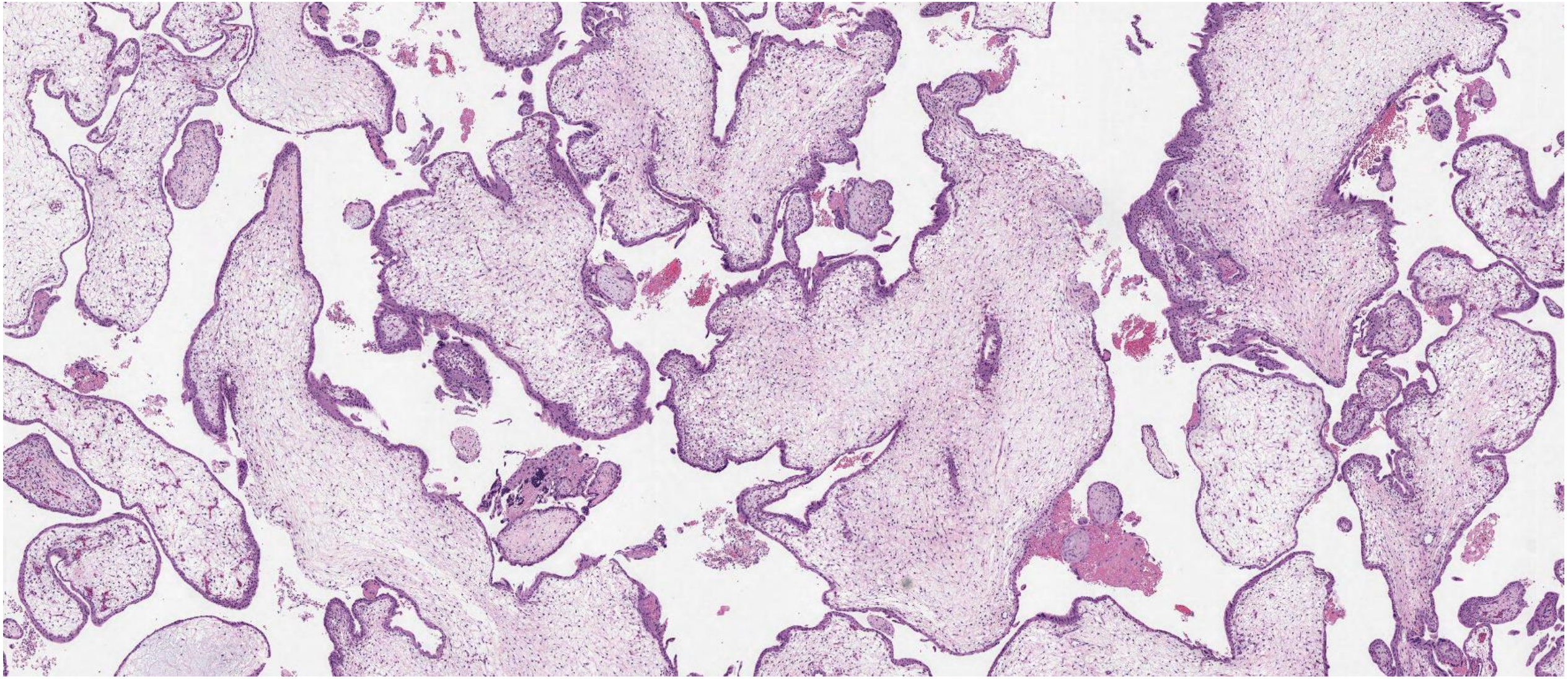

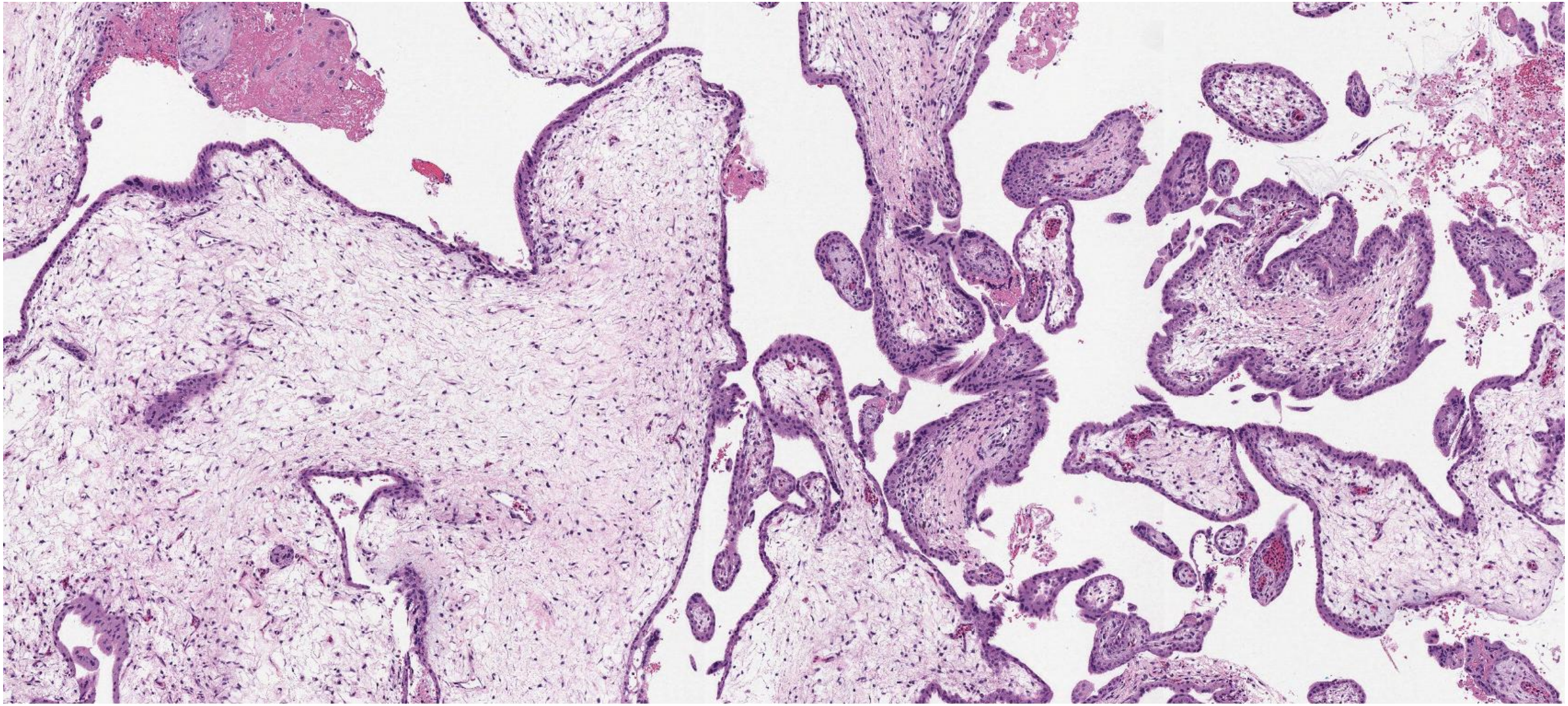

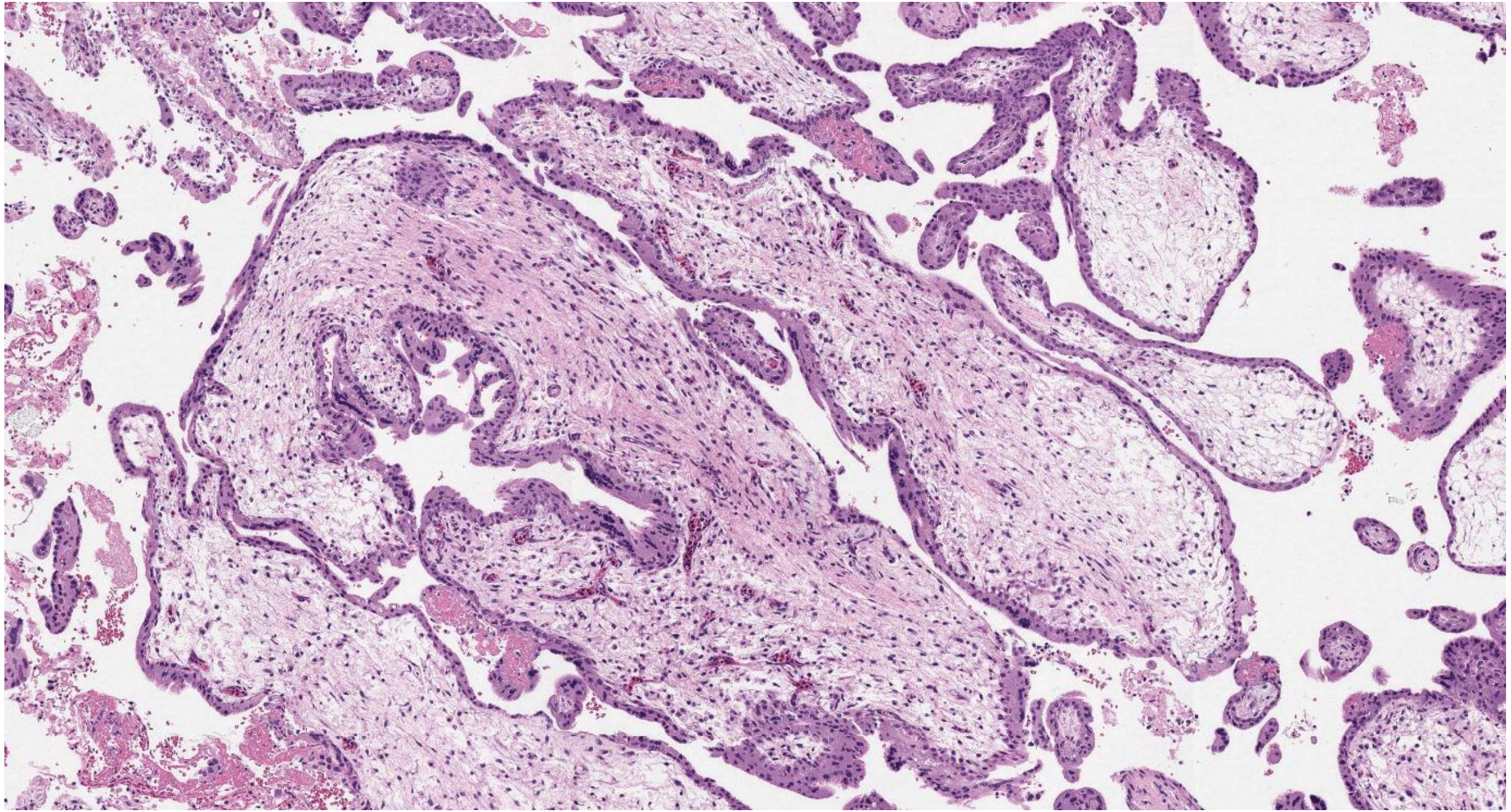

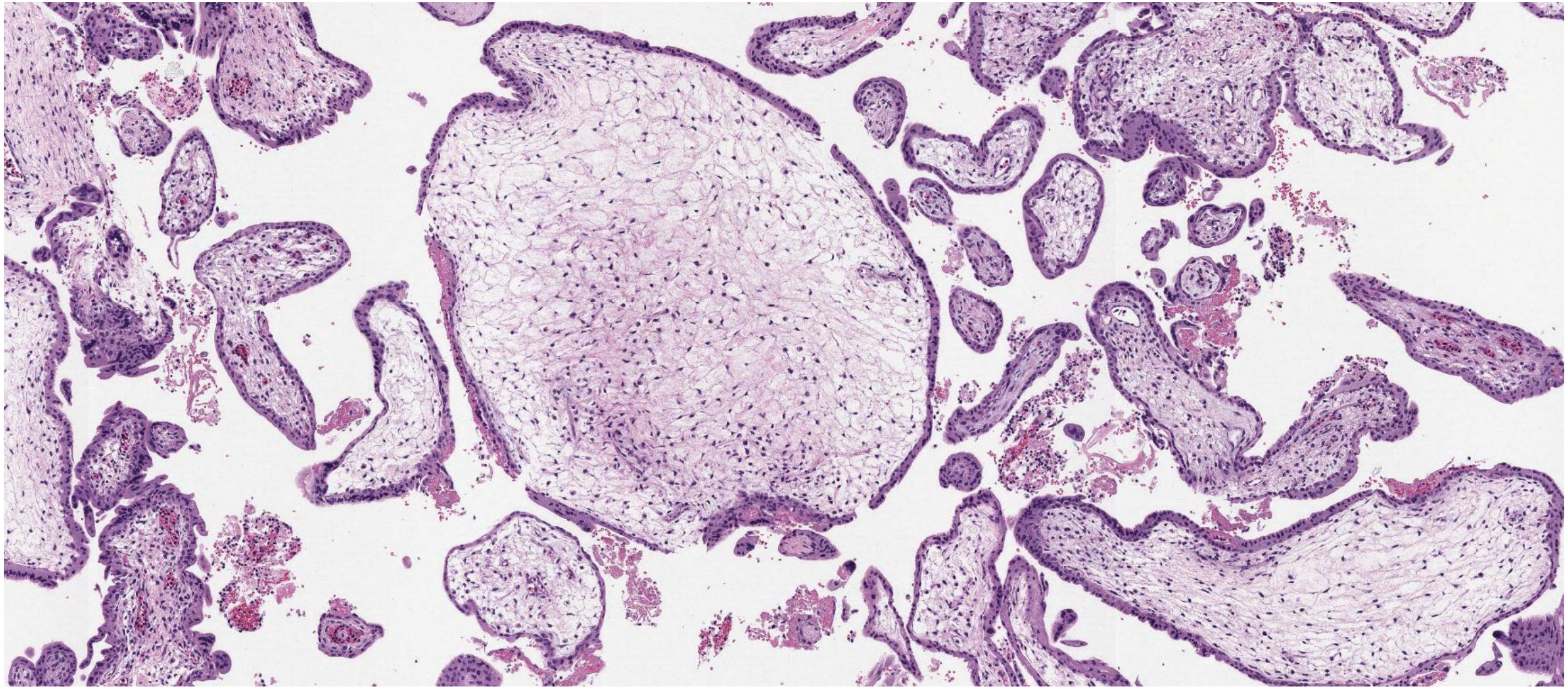

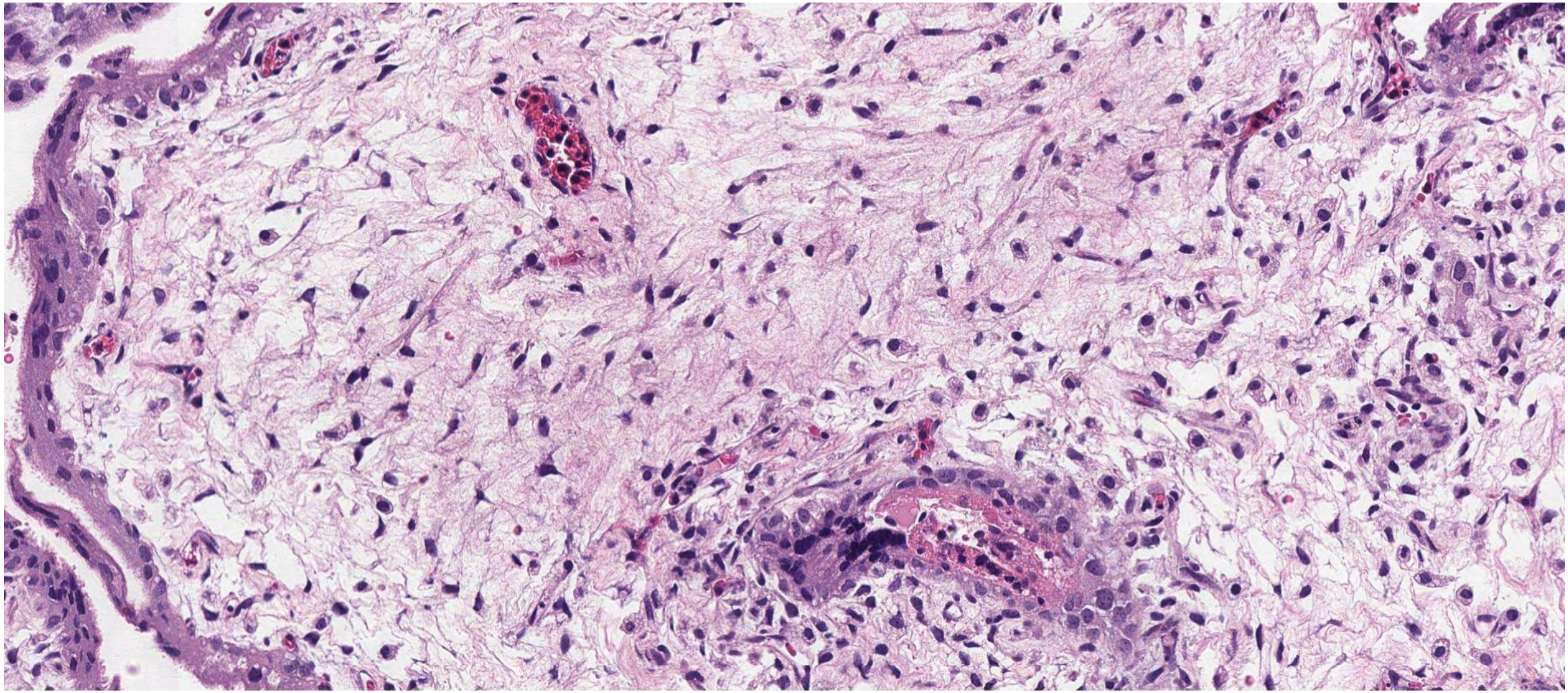

Partial hydatidiform mole

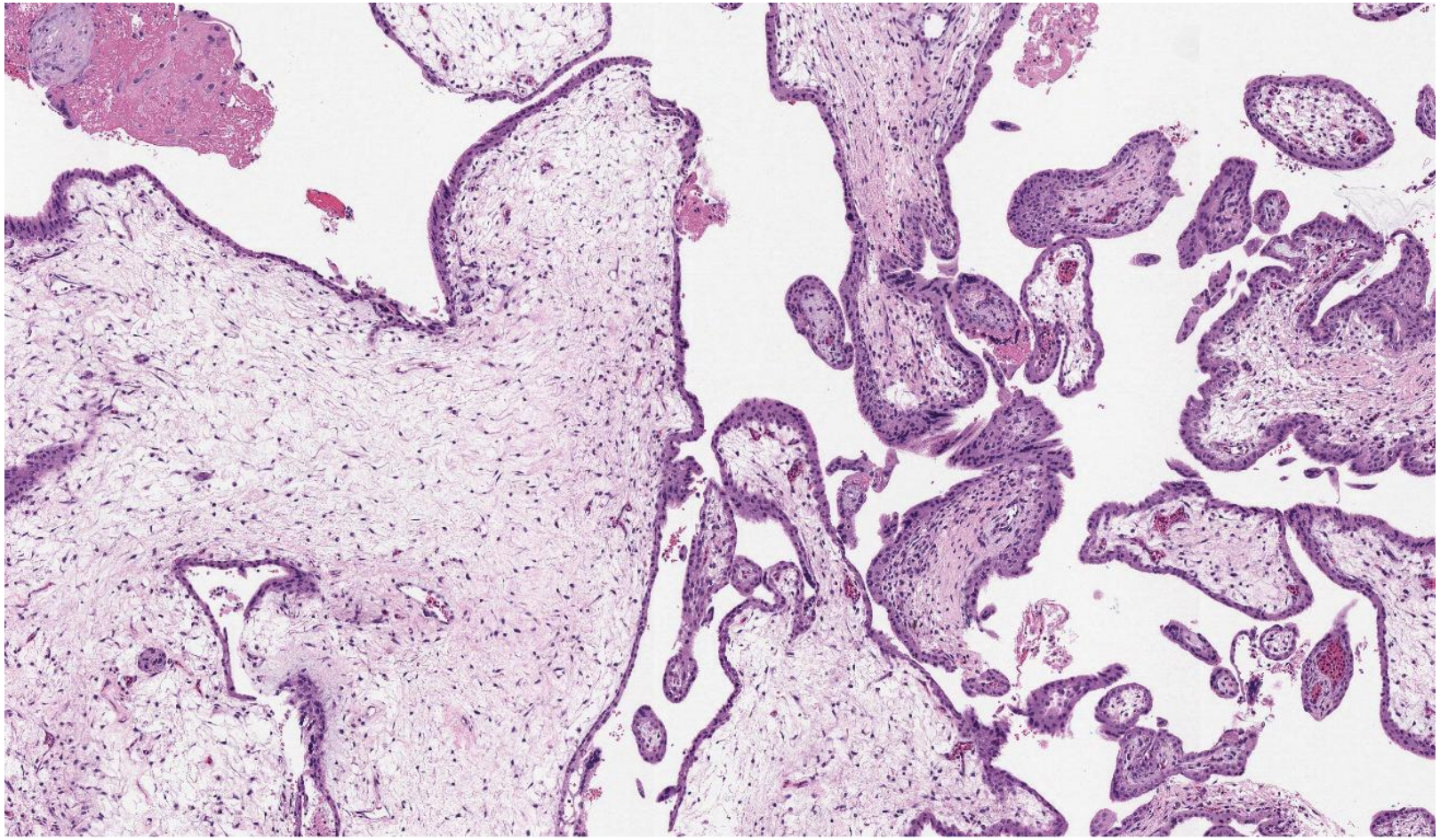

Case 20 – Partial mole

Principle histological features

- A dual population of chorionic villi
- Large villi have scalloped contours, invaginations and inclusions, often cisterns
- Smaller villi are often fibrotic
- Trophoblast can show patchy multifocal finger-like proliferation
- No trophoblast atypia
- Fetal somatic tissue / nucleated red blood cells are possible

Case 20 – Partial mole

Extra information

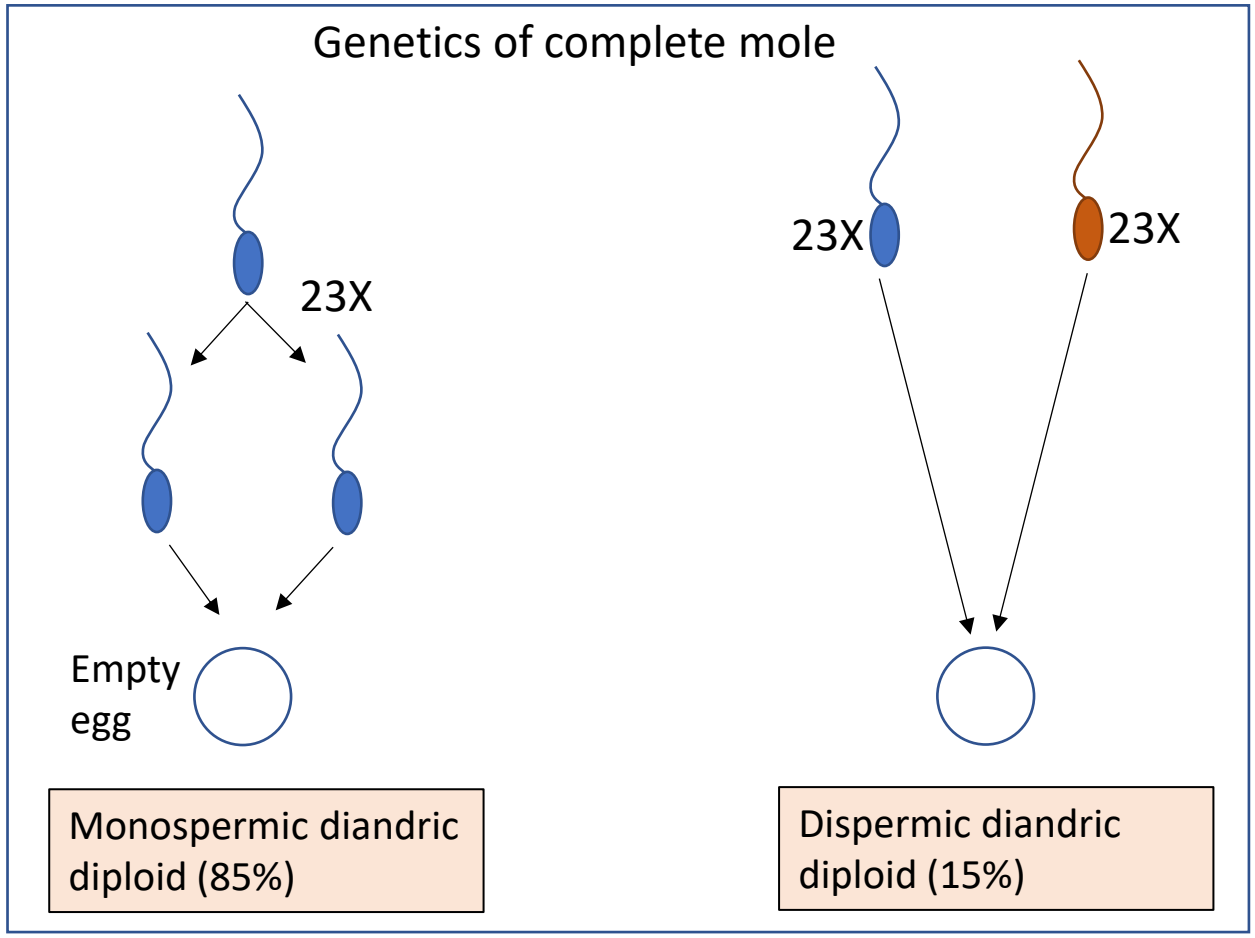

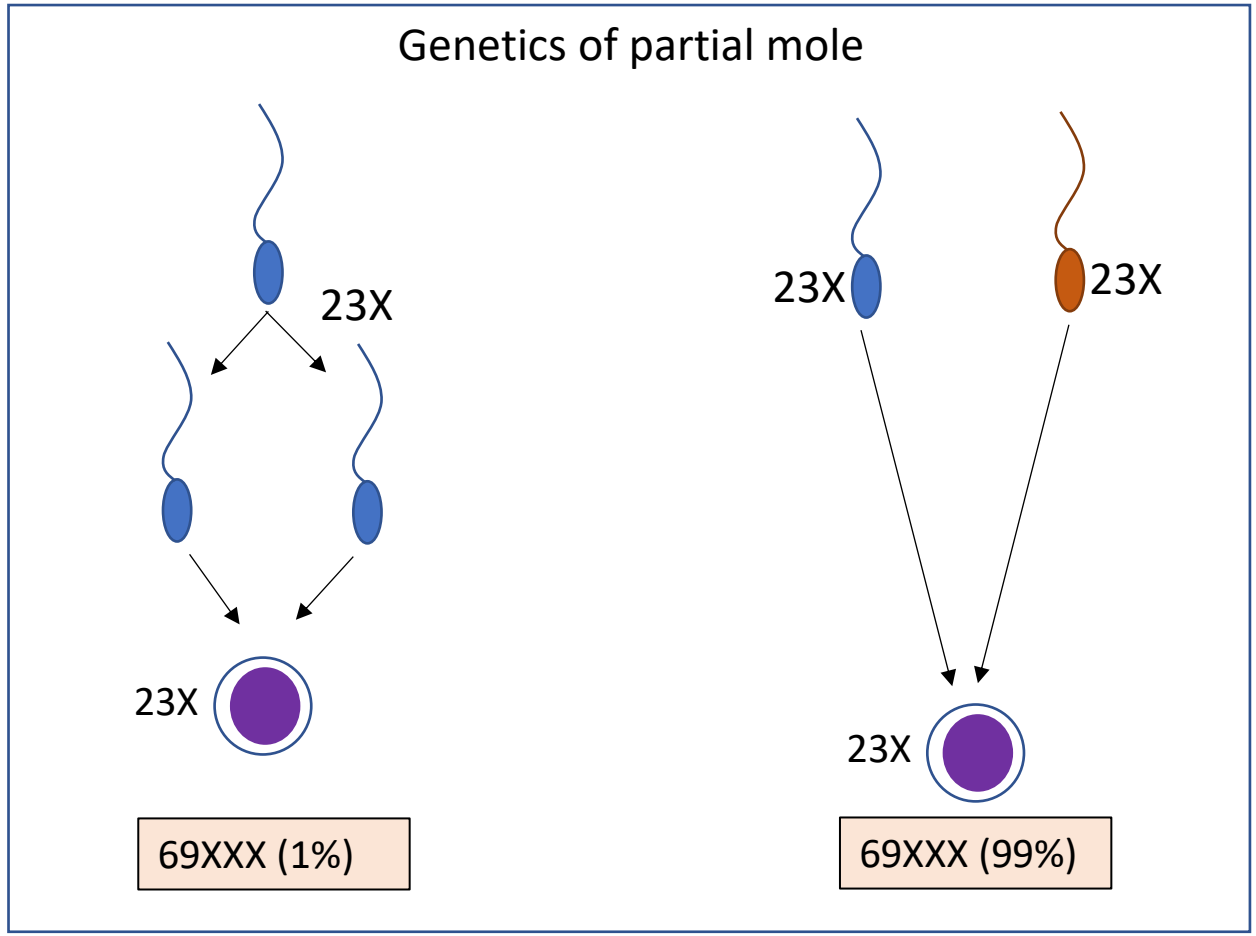

Case 20 – Partial mole

Extra information

- Molar pregnancies are associated with a risk of progression to gestational trophoblastic neoplasia
  - Persistent mole
  - Invasive mole
  - Distant metastases
  - Gestational choriocarcinoma

Case 20 – Partial mole

Extra information

- Molar pregnancies are associated with a risk of progression to gestational trophoblastic neoplasia
  - Persistent mole
  - Invasive mole
  - Distant metastases
  - Gestational choriocarcinoma

- Complete mole: 15 – 20% risk of persistent or invasive mole
  2 – 2% risk of choriocarcinoma

- Complete mole: 0.5 – 5% risk of persistent or invasive mole
  0.015% risk of choriocarcinoma

- Specialised clinical management with serial bHGC measurements

Case 20 – Partial mole

DDx and how to resolve

▪ Complete mole	Abnormal, enlarged, hydropic chorionic villi Abnormal trophoblast proliferation	Uniformly large villi + circumferential trophoblast ++ Apoptotic debris Atypia in extravillous trophoblast No fetal tissue or nucleated red blood cells Loss of p57 on IHC in villous cytotrophoblast + stroma
▪ Hydropic abortus	Oedematous chorionic villi +/- cisterns	Variable villous size, not dual Mild irregularity in villous shape No abnormal trophoblast proliferation
▪ Twin pregnancy: complete mole + normal gestation	Dual population of enlarged, abnormal villi + smaller villi	Molar villi show typical features for complete mole: atypia, cavitation, marked trophoblastic proliferation Loss of p57 only in molar villi

Short surgical cases 11 - 12

Omental biopsy	Metastatic high grade (serous) carcinoma
Hysterectomy	Leiomyosarcoma
Ovary	Low grade serous carcinoma
Ovary	Clear cell carcinoma
Anal biopsy	High grade neuroendocrine carcinoma / small cell
Ovary	(Metastatic) well-differentiated neuroendocrine tumour
Vulva	Condyloma
Cervical biopsy	Microglandular hyperplasia
Endometrial polyp	Atypical hyperplasia in an endometrial polyp
POC	Partial hydatidiform mole

Tips for answering SS questions

- Information provided within the question may or may not be useful, but should not mislead.
  - e.g. elderly patient, germ cell tumour unlikely.

Tips for answering SS questions

- **Succinct** histological description.

- If you spot the diagnosis, aim to use specific descriptors associated with certain entities (if those features are there!).
  - Adult granulosa cell tumour – Call-Exner bodies.
  - Adenosarcoma – Phyloides-like architecture.
  - Serous borderline tumour – Heirarchical branching.

- If unsure of the diagnosis, say what you see.

Tips for answering SS questions

- Reach a 'bottom line' diagnosis. Clearly identify it as such.

- A firm diagnosis is not always expected.
- Better to provide a suitable differential diagnoses and a way to resolve using ancillary tests than to confidently provide a wrong answer.

- Single slide, limited time
  - Be careful about spending time providing a tumour stage, searching for LSVI, tumour dimensions, margin status

Tips for answering SS questions

- After your diagnosis line or conclusion, aim to gain additional marks by providing extra information
  - Immunohistochemistry table
  - Molecular information
  - Awareness of staging and other prognostic factors
  - Awareness of clinical presentation and clinical implications



Thank you

Questions