The British Association of Gynaecological Pathologists

21st Annual Meeting in Collaboration with ISGyP

5th and 6th June 2025

- Role of IHC for the practicing pathologist in non-mucinous ovarian carcinoma
- Dr Richard Wong
- Department of Pathology, United Christian Hospital, Hong Kong
- 6th June 2025

The British Association of Gynaecological Pathologists

Speaker disclosures

- ❑ I have no financial conflicts of interest to disclose

Case-based discussion of diagnostic IHC in non-mucinous ovarian carcinomas

- The presentation will focus on diagnostic challenges with commonly used IHC markers in the typing of ovarian carcinomas, including
  - High grade serous carcinoma
  - Clear cell carcinoma
  - Endometrioid carcinoma
  - Mesonephric-like carcinoma
  - Other uncommon types or mixed carcinoma
- Illustrative cases and discussion of relevant literature
- Questions from the audience

Case 1

- 64 years old
- Left ovarian tumour (11 cm) involving the left tube

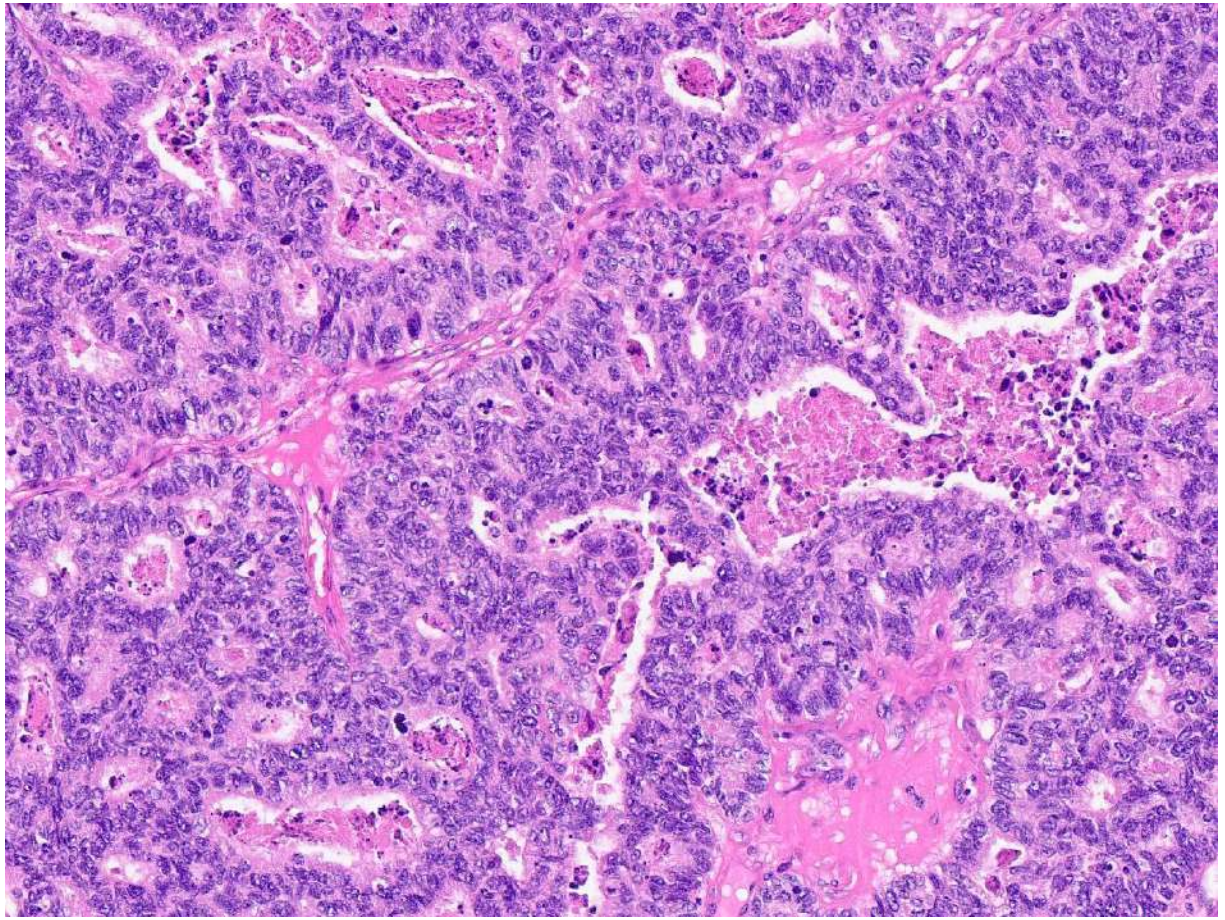

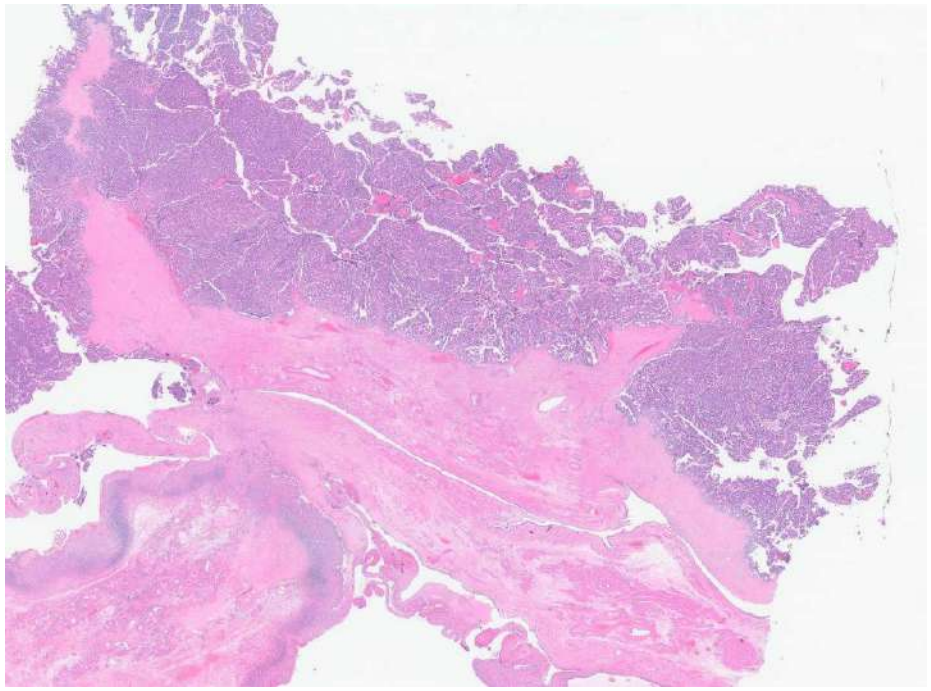

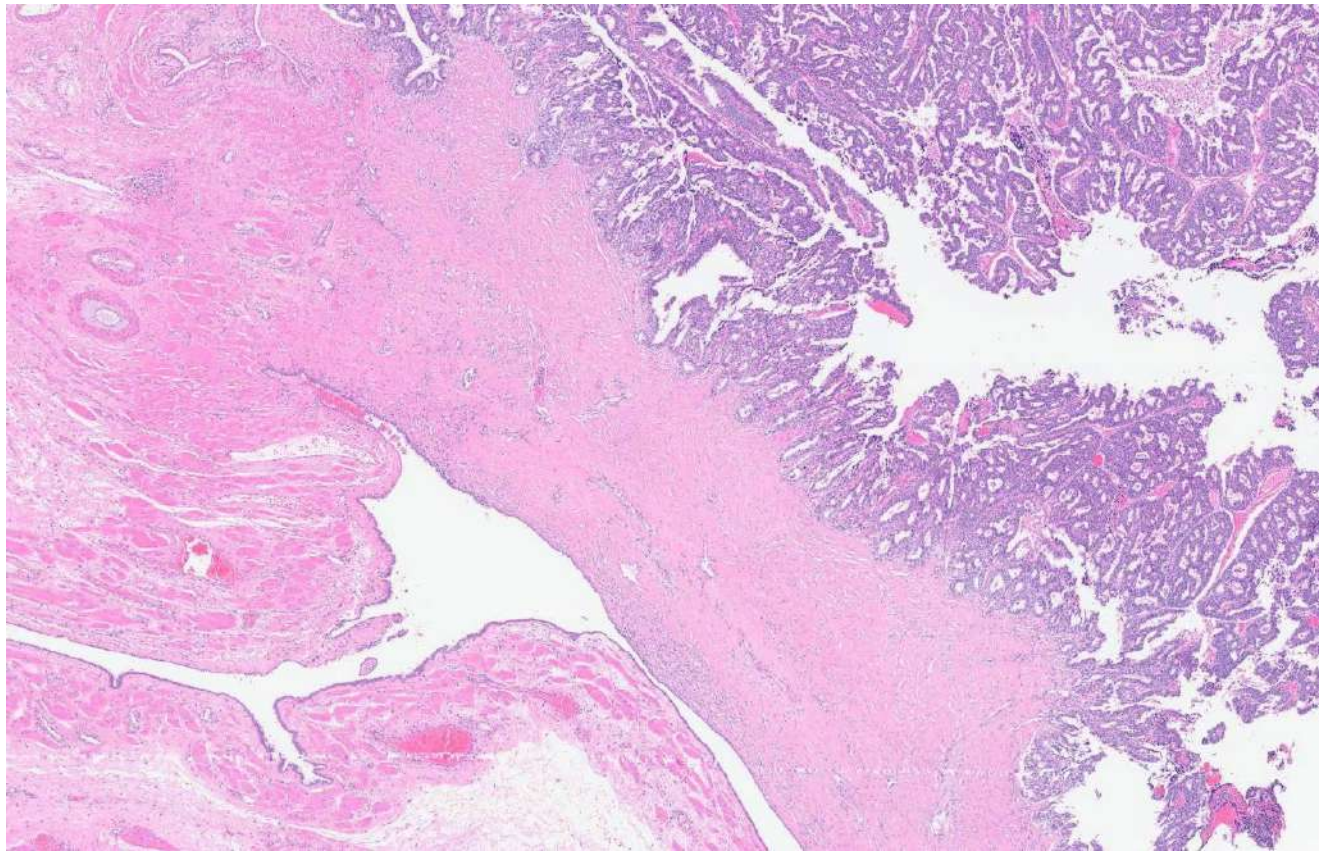

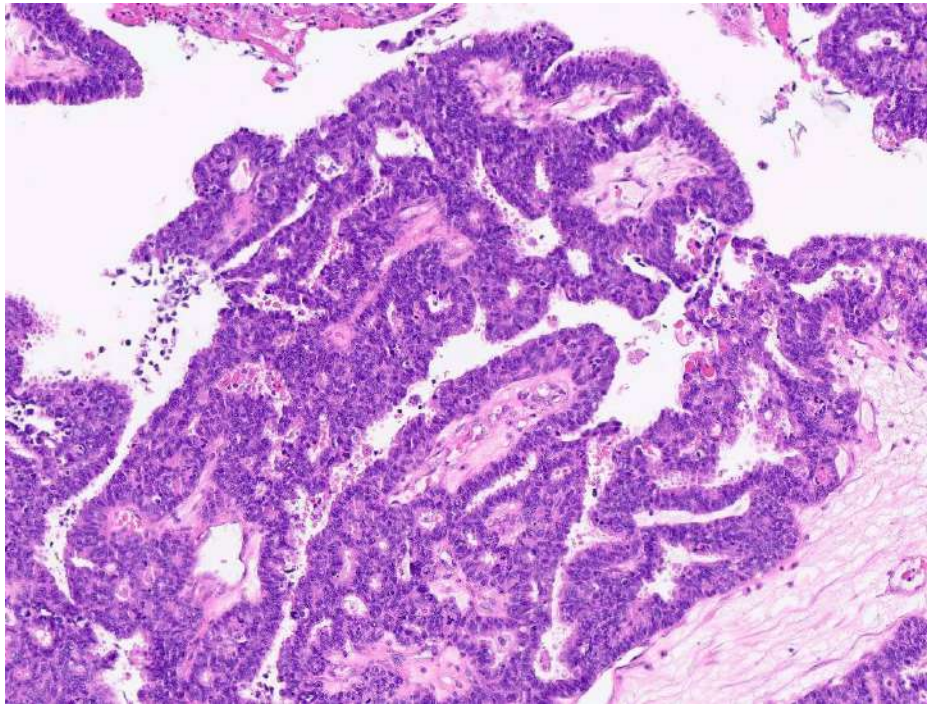

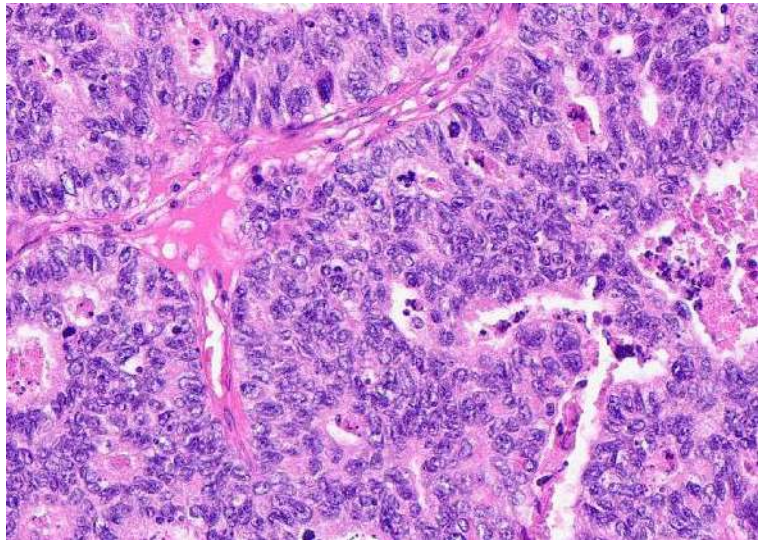

Morphological features of a high grade adenocarcinoma

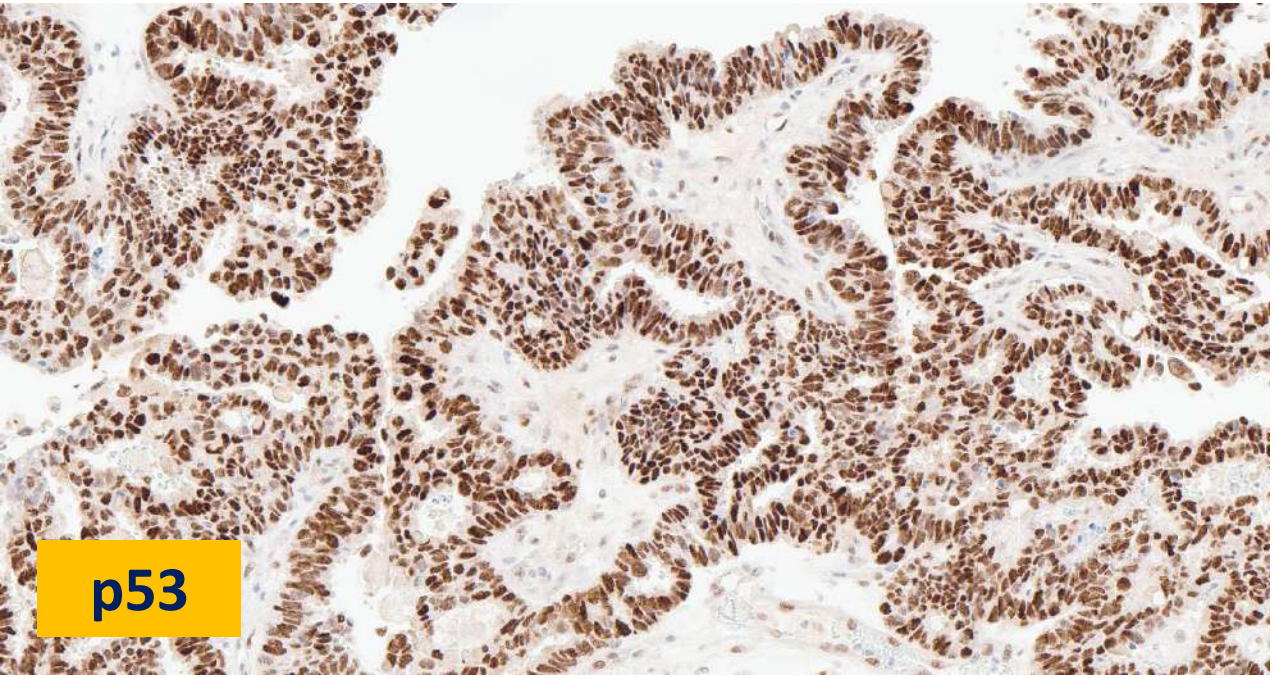
p53

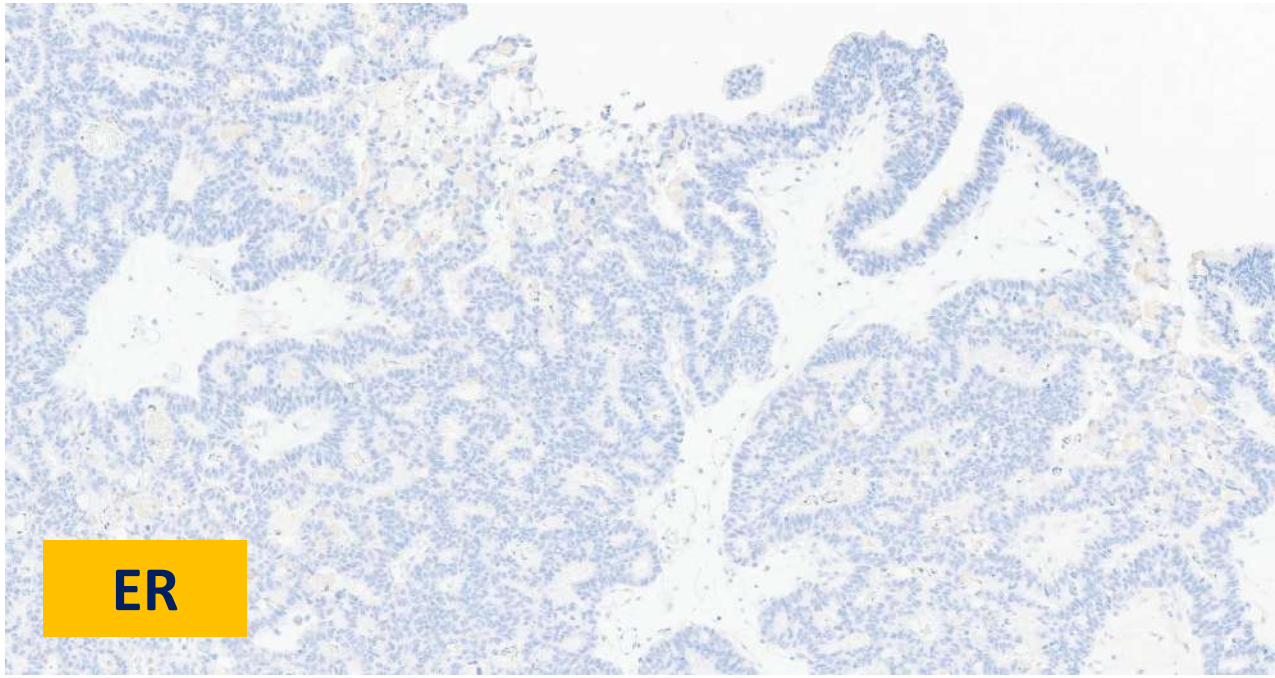
ER

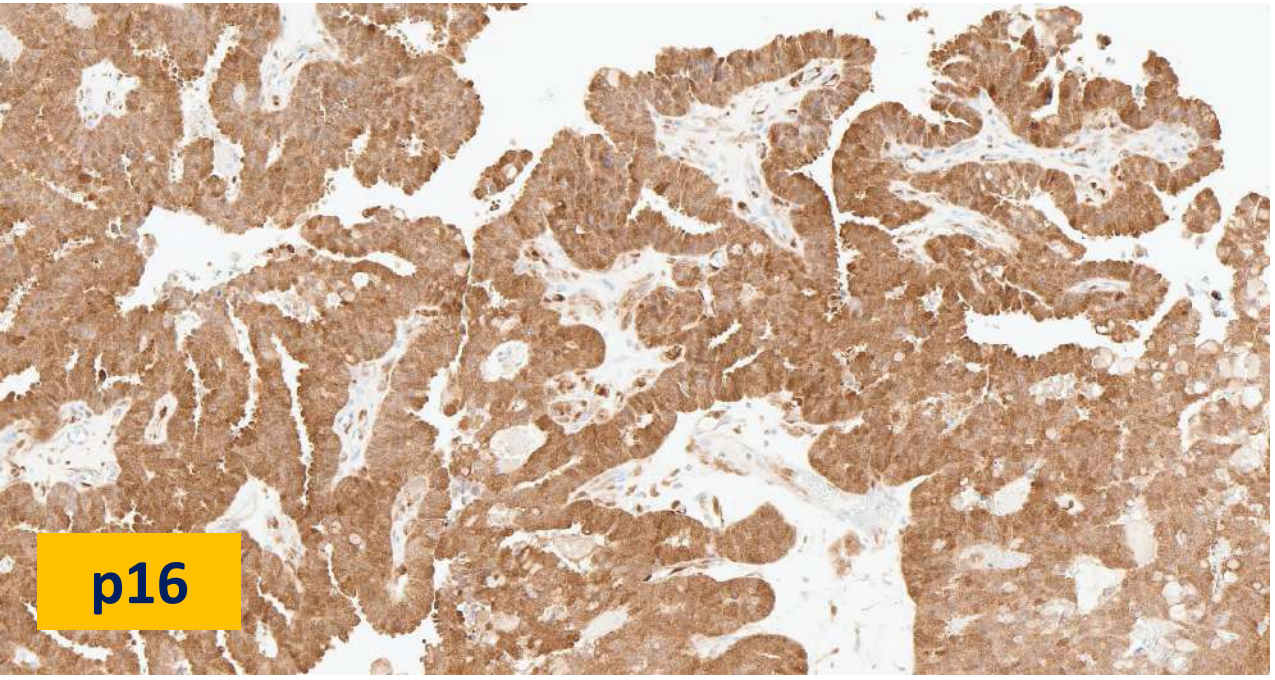
p16

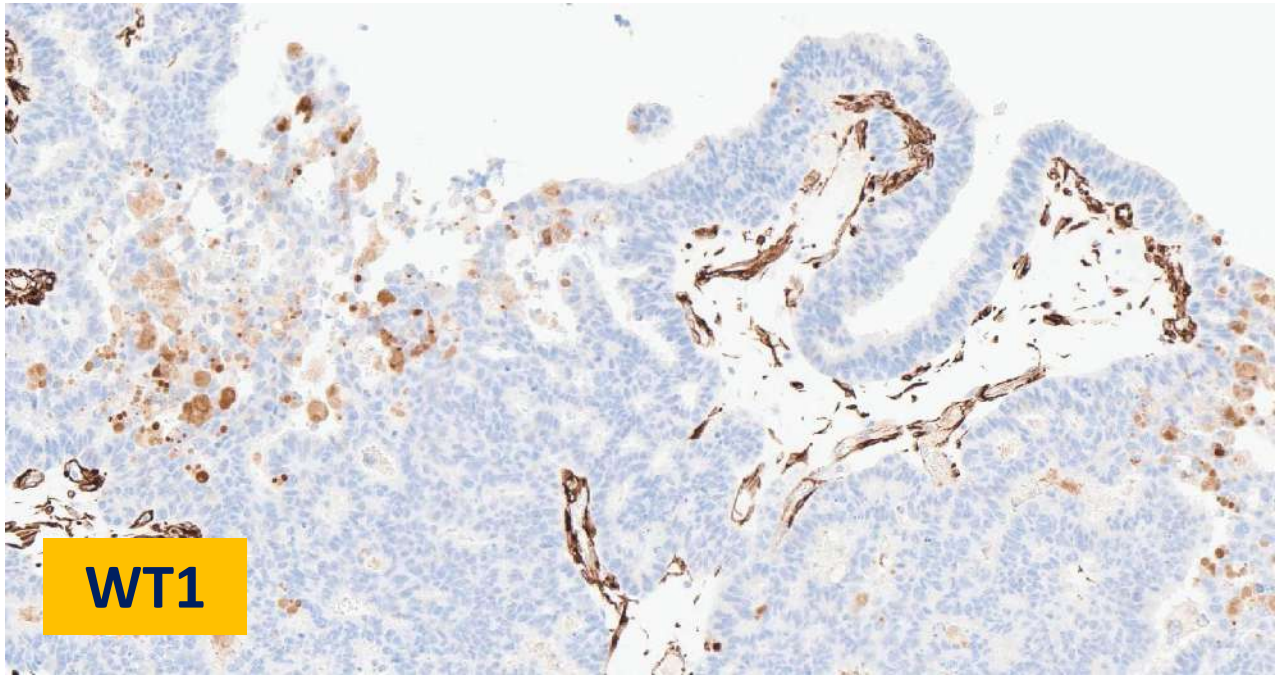
WT1

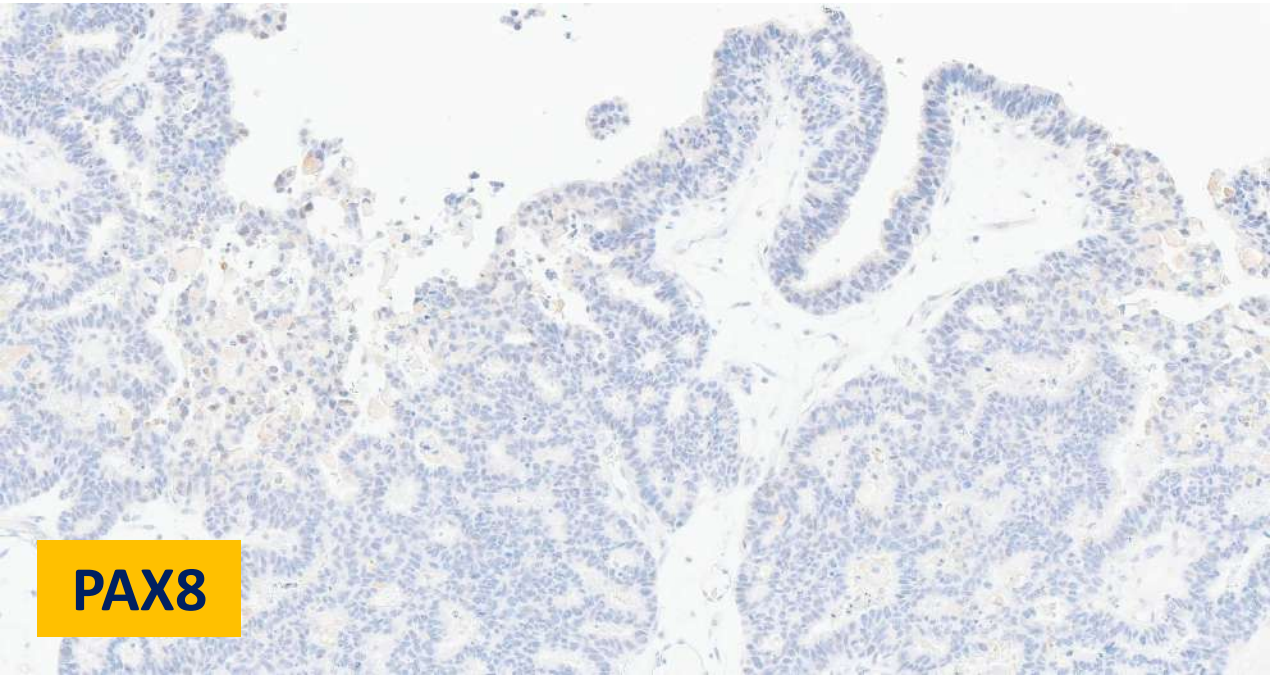
PAX8

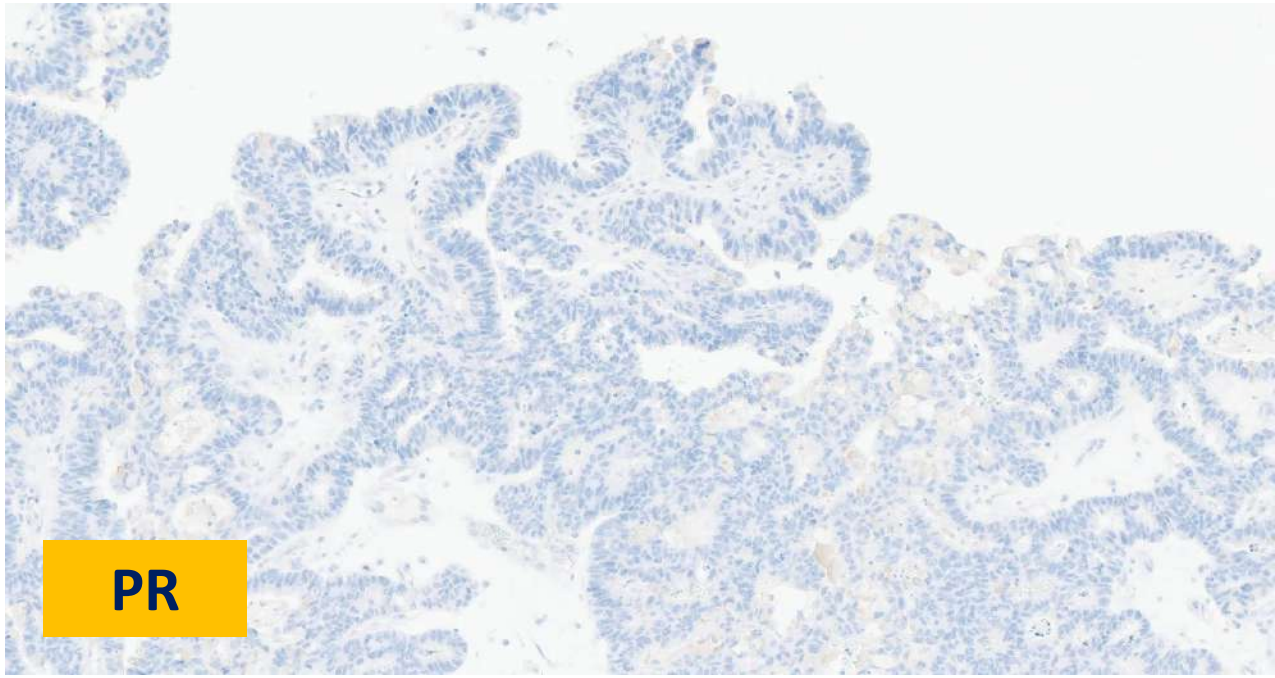
PR

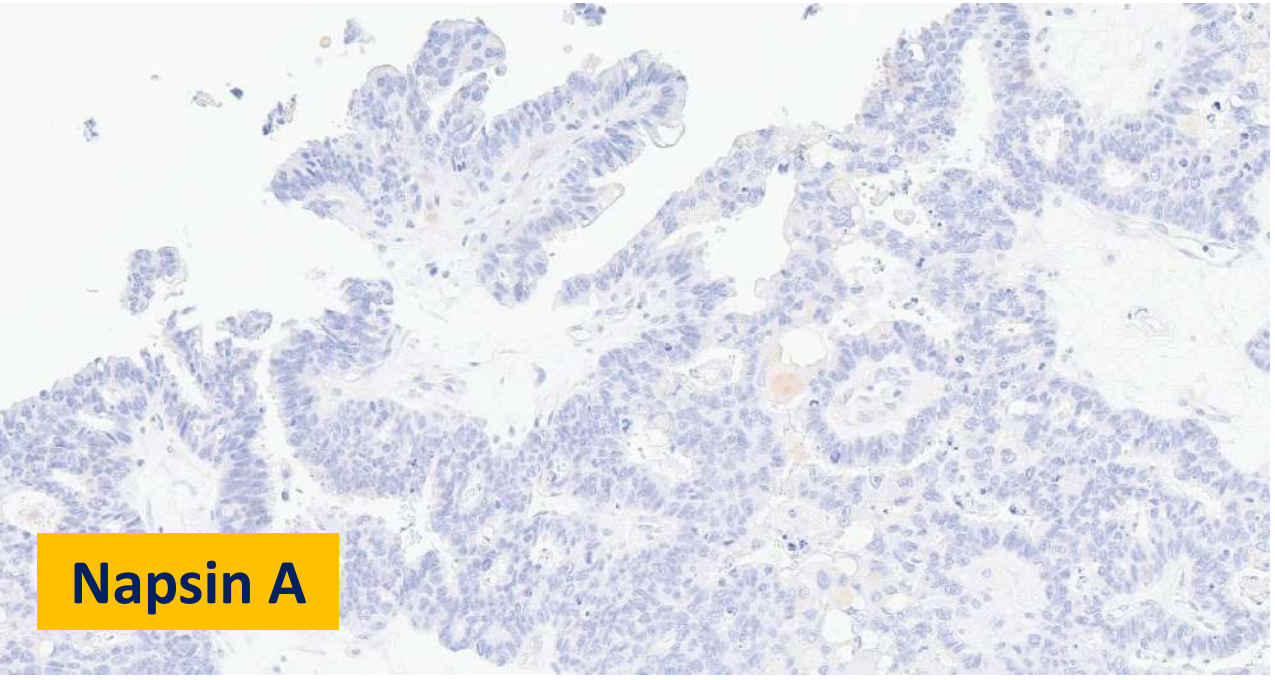
Napsin A

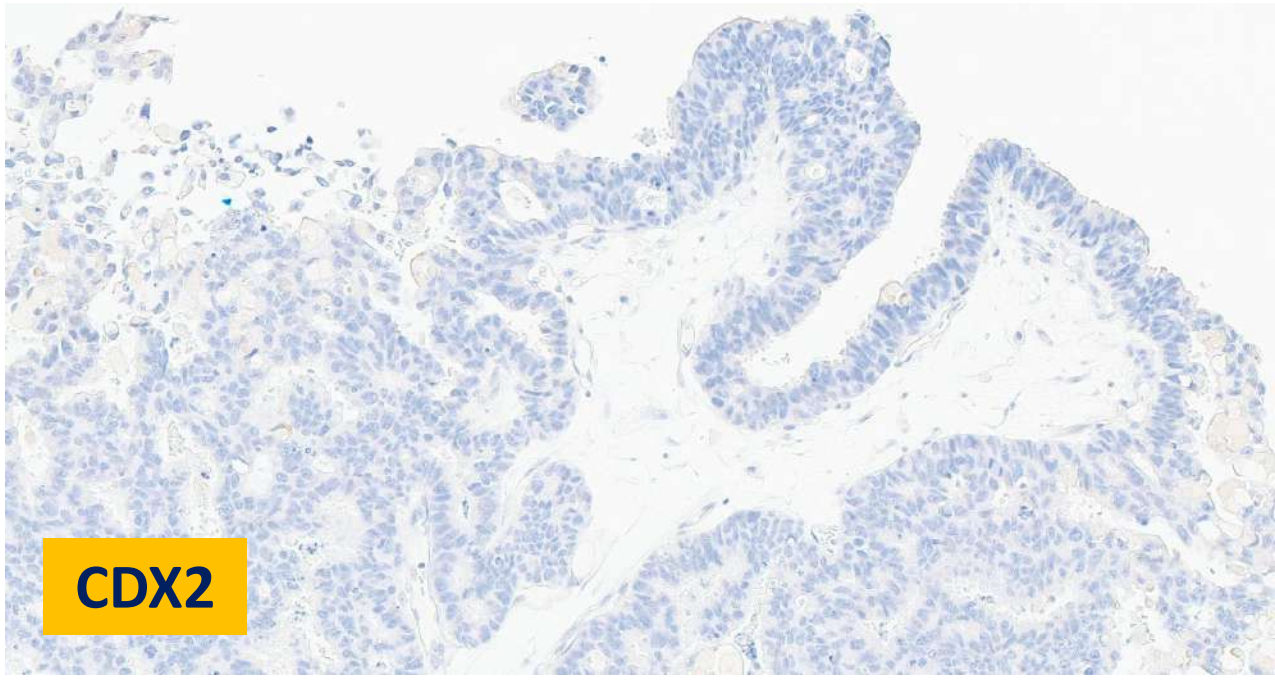
CDX2

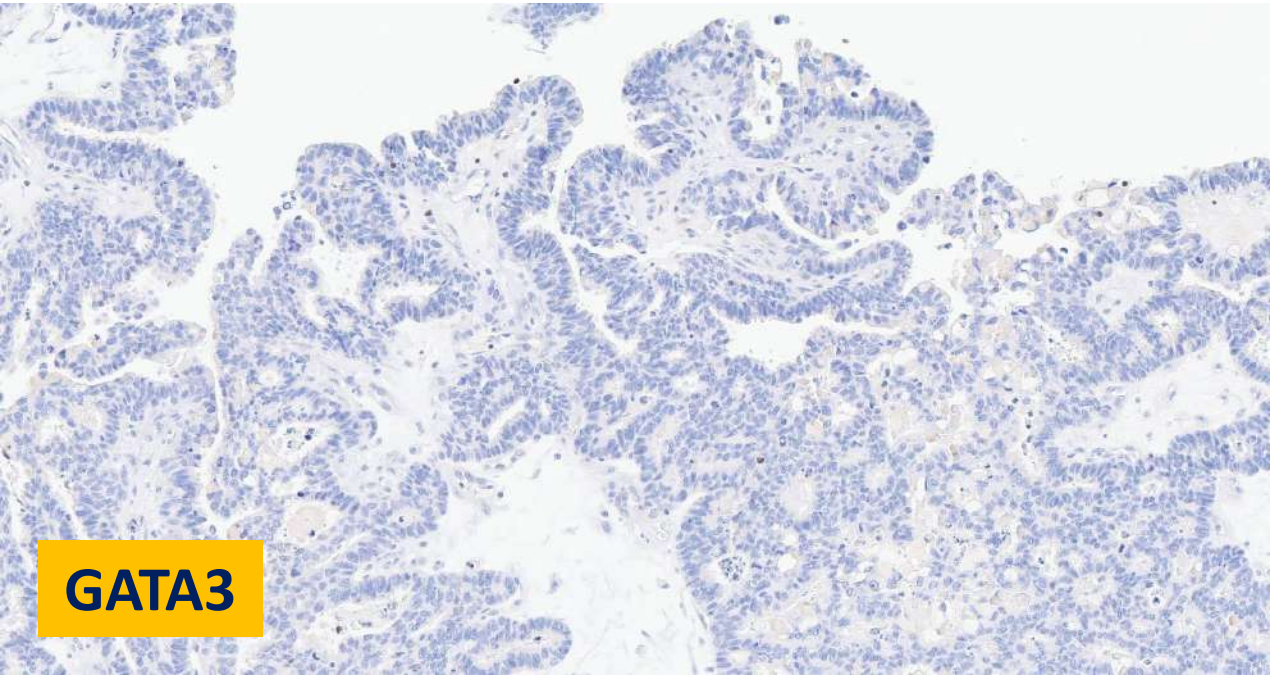
GATA3

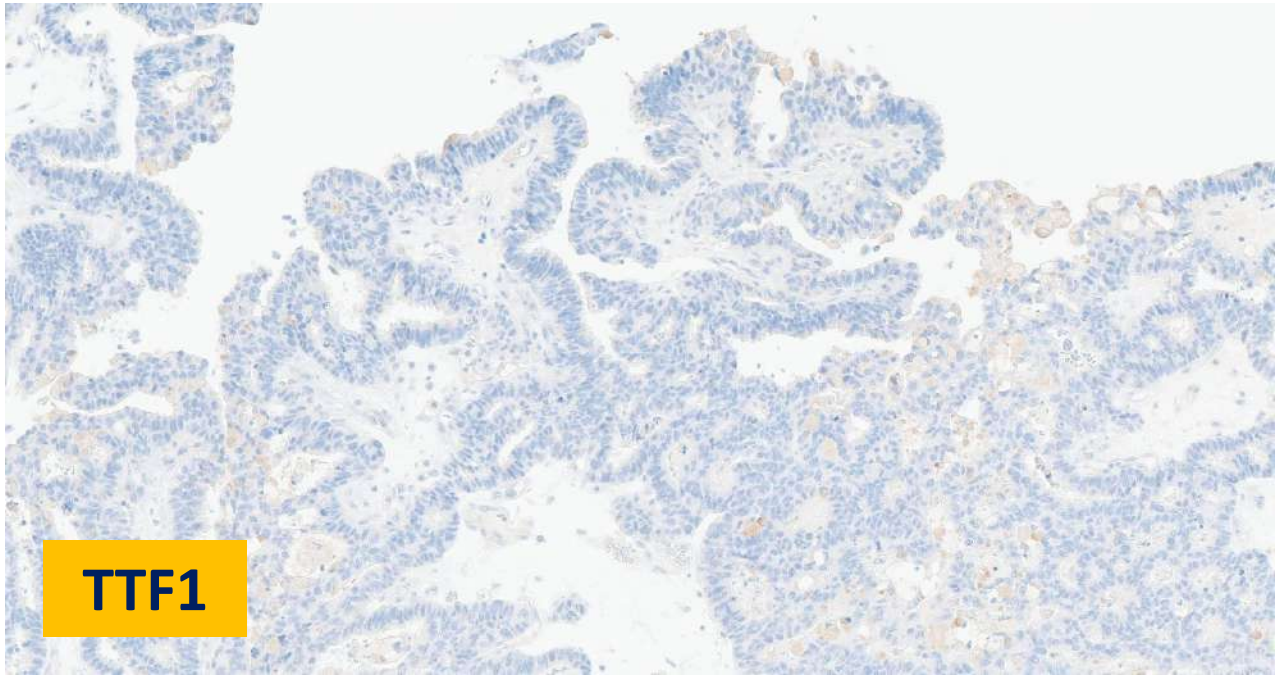
TTF1

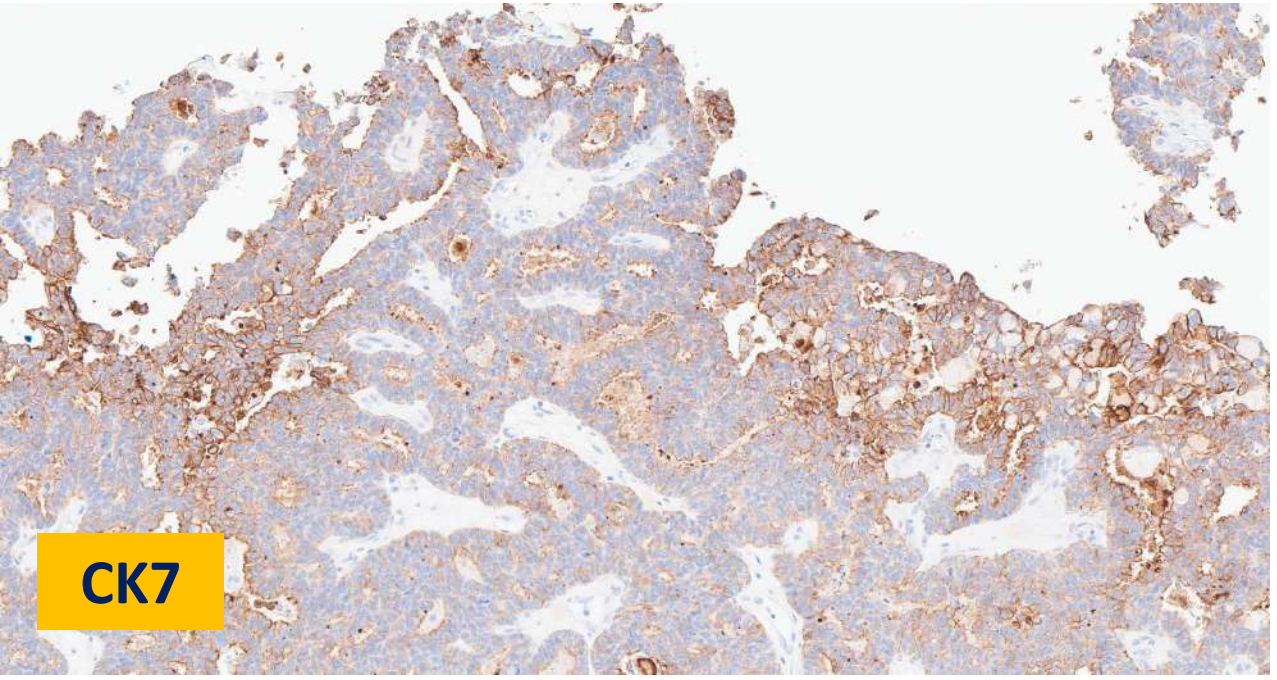
CK7

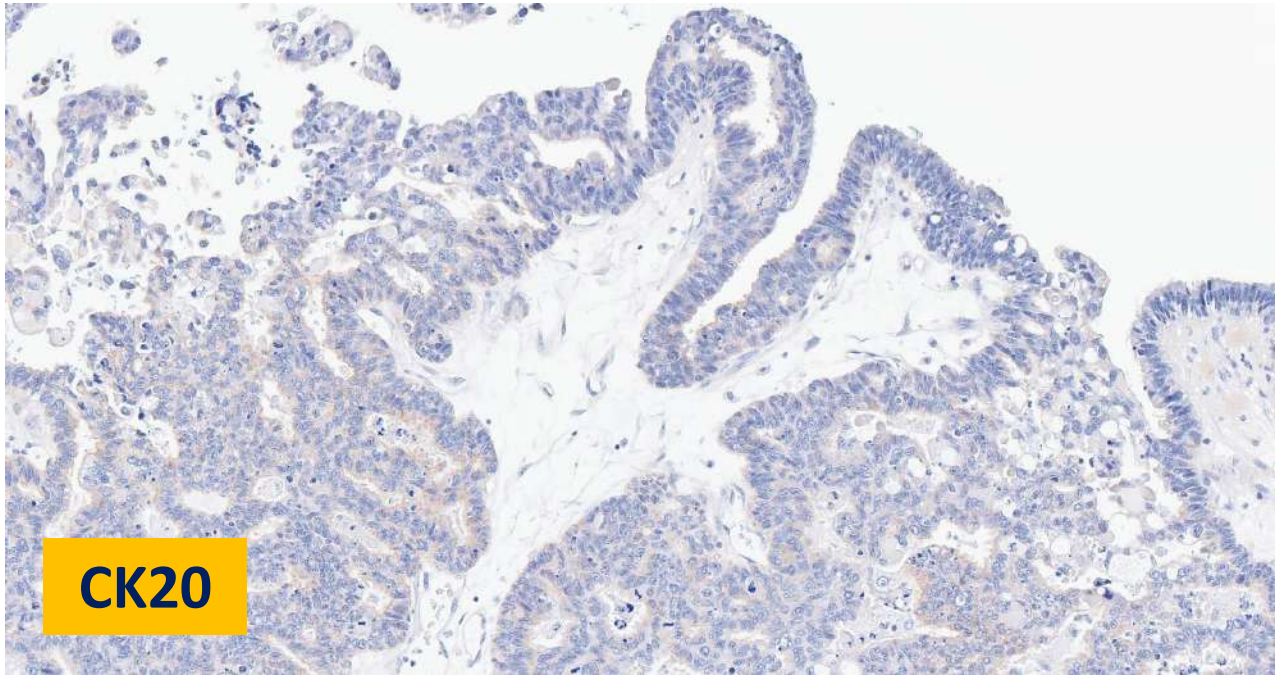
CK20

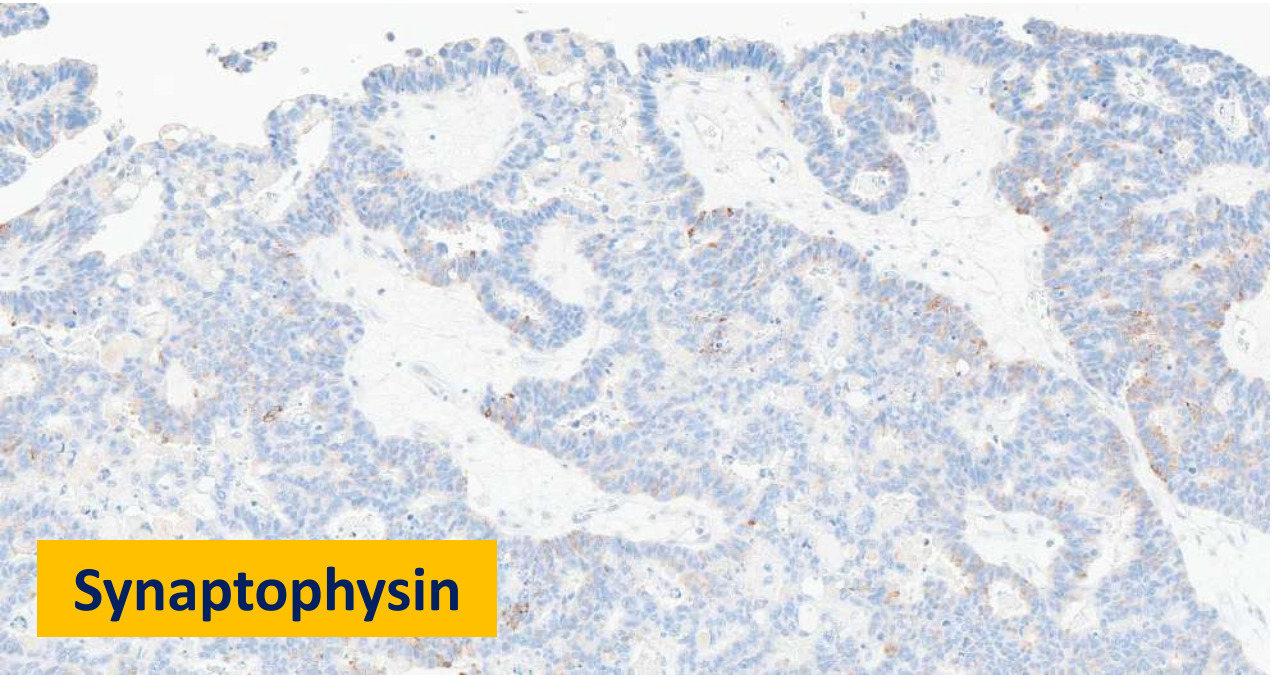
Synaptophysin

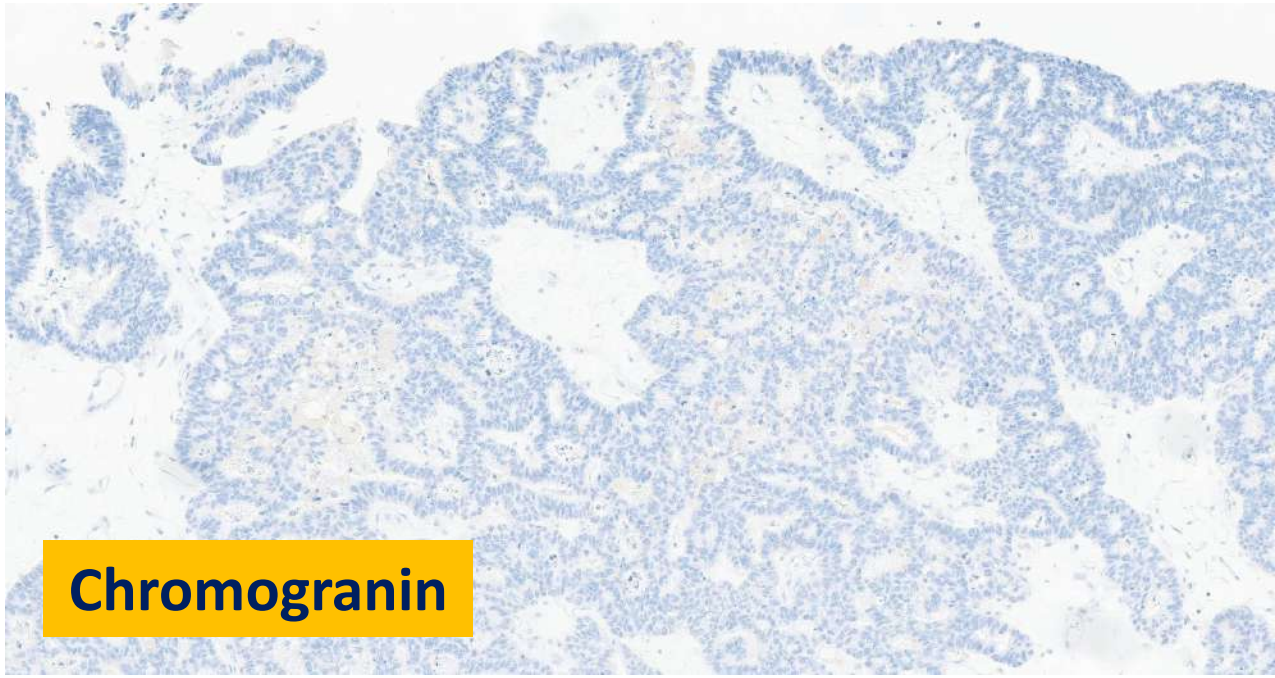
Chromogranin

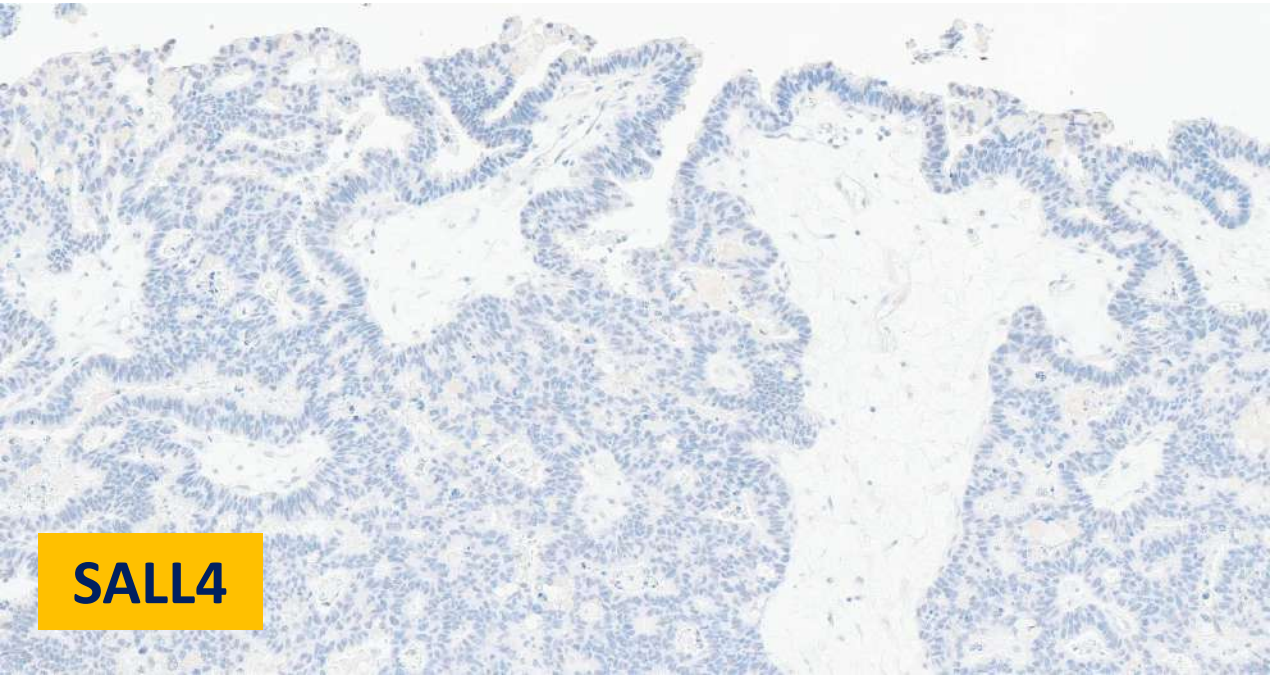
SALL4

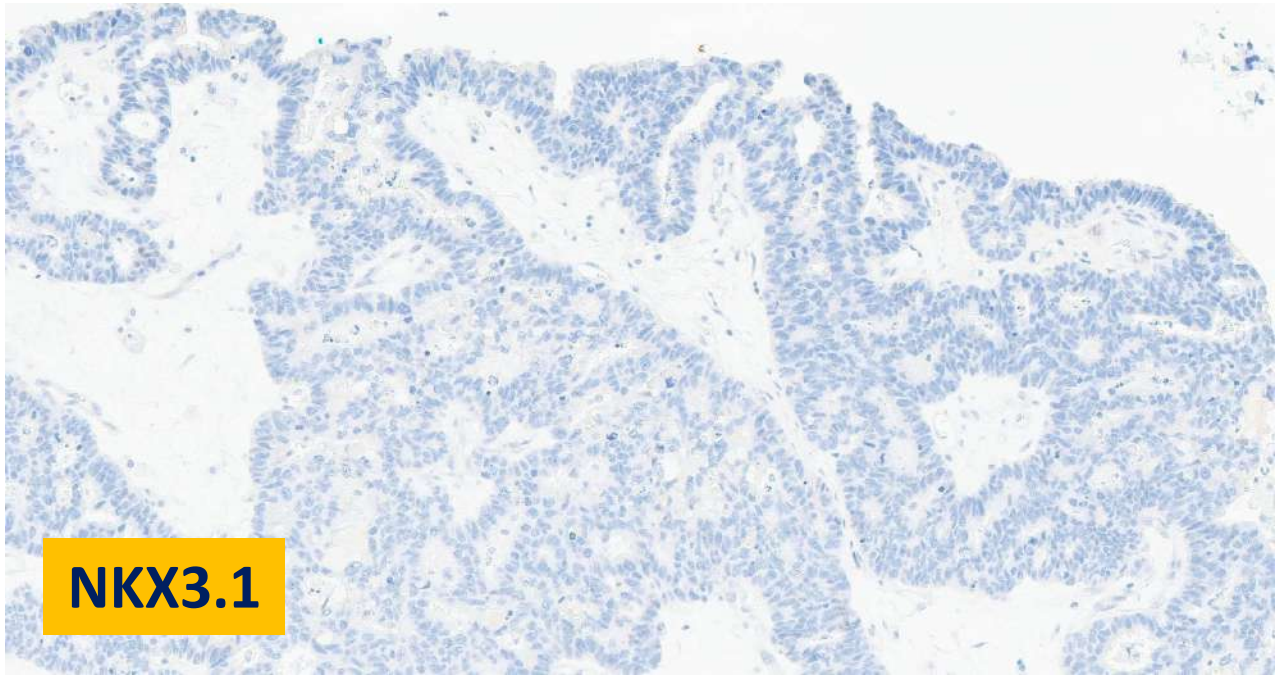
NKX3.1

Case 1 – High grade serous carcinoma?

- Adenocarcinoma with high grade nuclear features throughout and no squamous/mucinous features
- Tubal serosa involved by carcinoma but no STIC or tubal mucosal involvement
- **p53 mutant (overexpression)**
- **p16 diffusely positive**
- ER & PR negative
- **WT1 negative**
- **PAX8 negative**
- Napsin A negative
- CK7 positive / CK20 negative
- Synaptophysin focal (<10%) and weak (considered non-specific)
- Negative for all other markers
  - CDX2, GATA3, TTF1, chromogranin, SALL4, NKX3.1

Unexpected (or non-prototypical) IHC findings in high grade serous carcinoma

- The typical IHC profile for HGSC (**PAX8+ WT1+ p53abn**) is frequently used to confirm the diagnosis, but a small subset of cases may exhibit non-prototypical results for these markers
- **PAX8** is positive in 93 – 99% of ovarian HGSC
  - Nonaka et al. (2008): 96.4% (81/84)
  - Laury et al. (2011): 99% (164/165)
  - Ordóñez (2013): 93% (42/45)
- **WT1** is positive in 94.7 – 96.7% of ovarian HGSC
  - Al-Hussaini et al. (2004): 94.7% (36/38)
  - Köbel et al. (2016): 96.7% (1322/1367)

1-7% PAX8 negative
3-5% WT1 negative

Nonaka D, Chiriboga L, Soslow RA. Am J Surg Pathol 2008;32:1566-71.
Laury AR, Perets R, Piao H, et al. Am J Surg Pathol 2011;35:816-26.
Ordóñez NG. Mod Pathol. 2013;26:553-62.
Al-Hussaini M, Stockman A, Foster H, et al. Histopathology. 2004;44:109-15.
Köbel M, Rahimi K, Rambau PF, et al. Int J Gynecol Pathol 2016;35:430-41.

Unexpected (or non-prototypical) IHC findings in high grade serous carcinoma

- **p53 IHC** shows mutant expression in 93.9% of ovarian HGSC (1367 cases, Köbel et al. 2016)
  - Wild-type p53 expression in HGSC may be due to certain types of mutations (truncating or splice site mutations) or misinterpretation of IHC (e.g. fixation issues) (Köbel et al. 2019)
  - A re-appraisal of HGSC cases from TCGA suggested those cases lacking TP53 mutation were either not HGSC or HGSC associated with low grade serous component (Vang et al. 2016)
  - A study of HGSCs lacking *TP53* mutation by NGS found some cases had focal 'LGSC-like' morphology (moderate atypia, micropapillary pattern) while other cases with 'usual HGSC' features often show abnormal p53 IHC (Chui et al. 2021)

Vang R, Levine DA, Soslow RA, et al. Int J Gynecol Pathol 2016;35:48-55.
Köbel M, Rahimi K, Rambau PF, et al. Int J Gynecol Pathol 2016;35:430-41.
Köbel M, Luo L, Grevers X, et al. Int J Gynecol Pathol 2019;38:353-362.
Chui MH, Momeni Boroujeni A, Mandelker D, et al. Mod Pathol 2021;34:490-501.

Case 1 – How to handle the unexpected IHC?

- Review of the slides did not show morphological features of low grade endometrioid or other histotypes
- PAX8 and WT1 repeated on another section with same results
- Clinical history and imaging: no evidence of another primary
- Signed out as “high grade adenocarcinoma” of ovary with a comment on the differential diagnosis (HGSC, high grade endometrioid, metastasis)
- Tumour board: manage as HGSC
- Patient treated with chemotherapy and well upon follow up for 4 years now

Case 2

- 49 years old
- Bilateral ovarian tumours
  - Right ovary: 3 cm mass
  - Left ovary: 6 cm mass involving the left tube

Left ovary

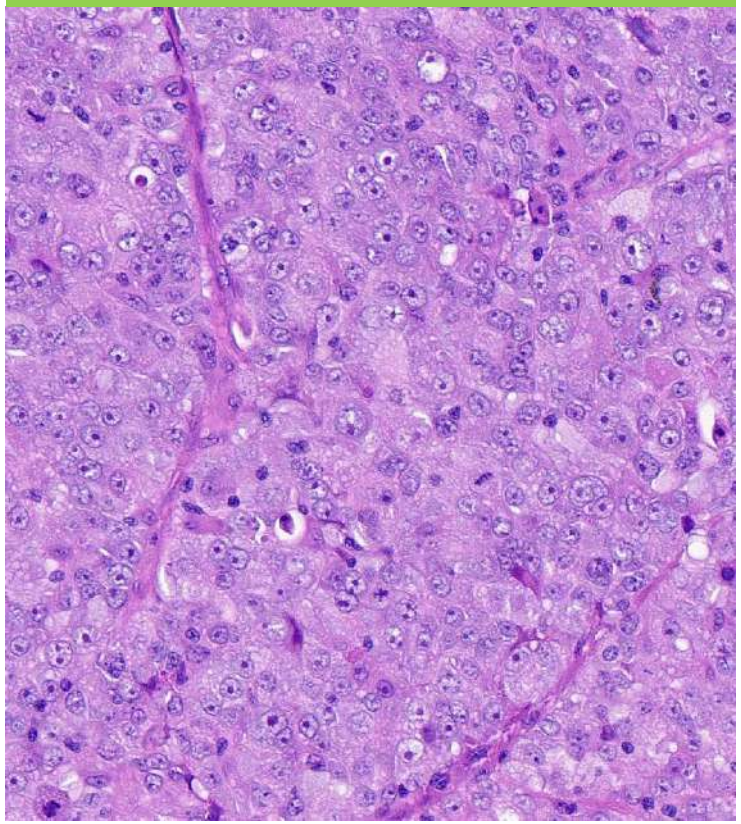

Right ovary

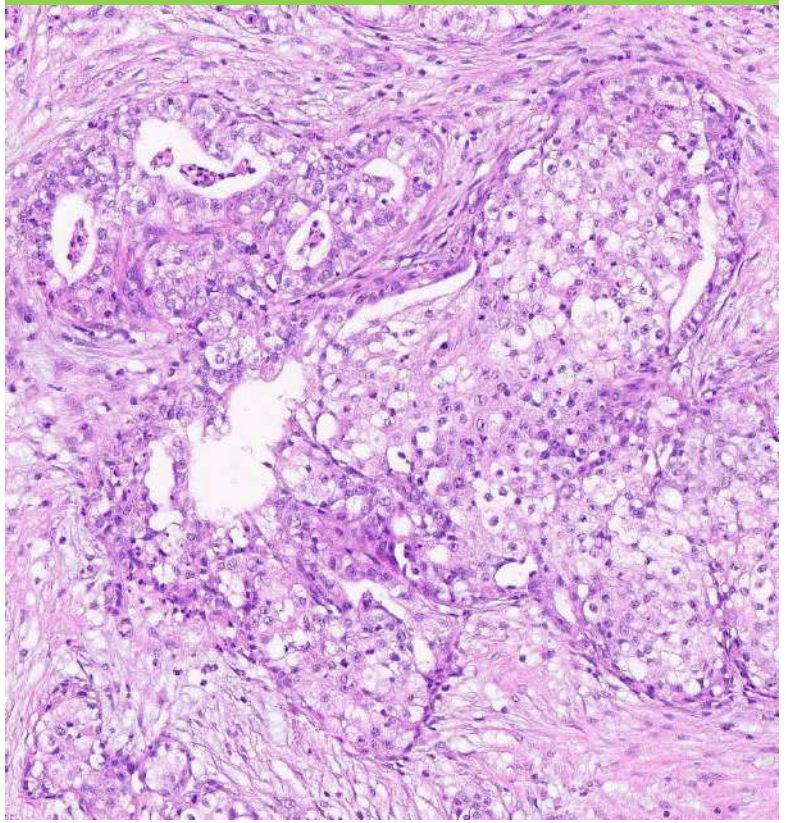

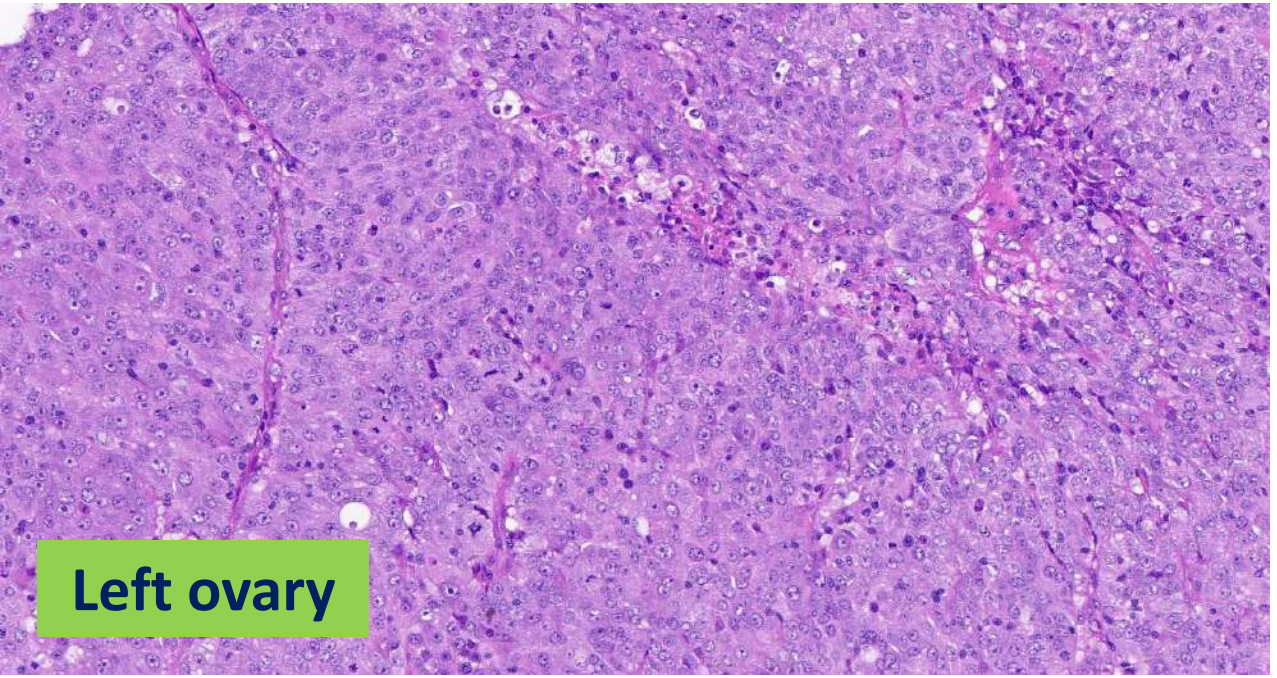
Left ovary

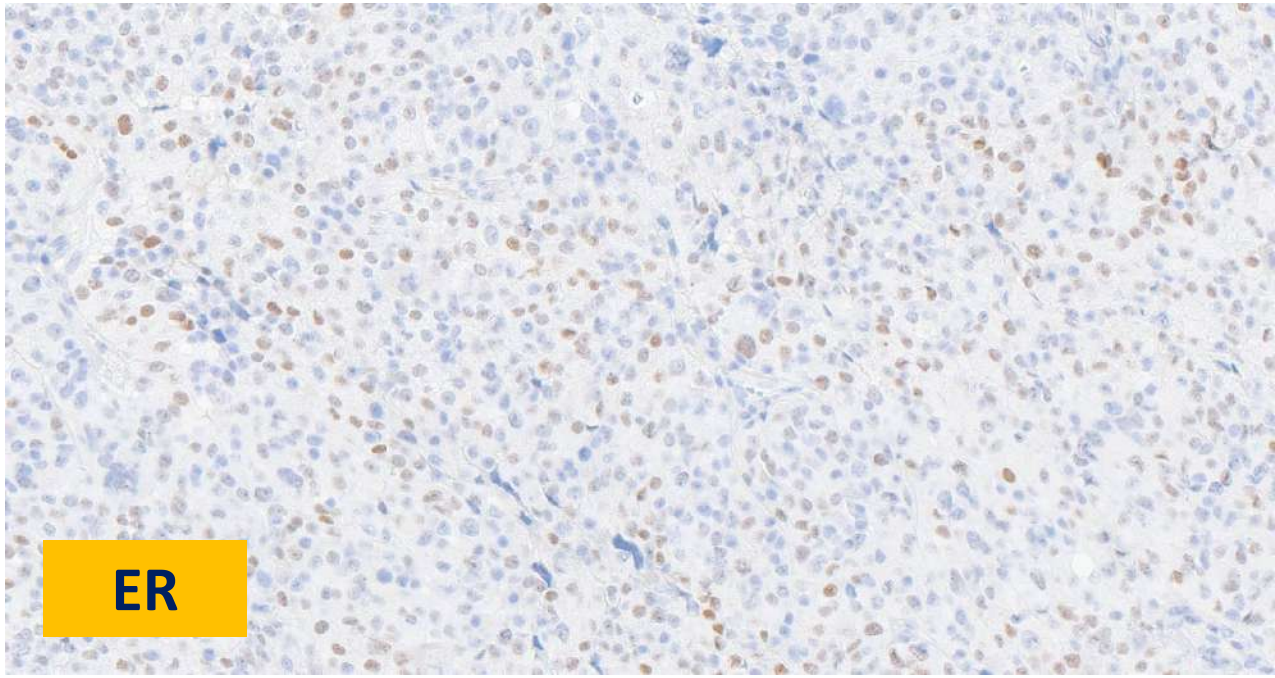
ER

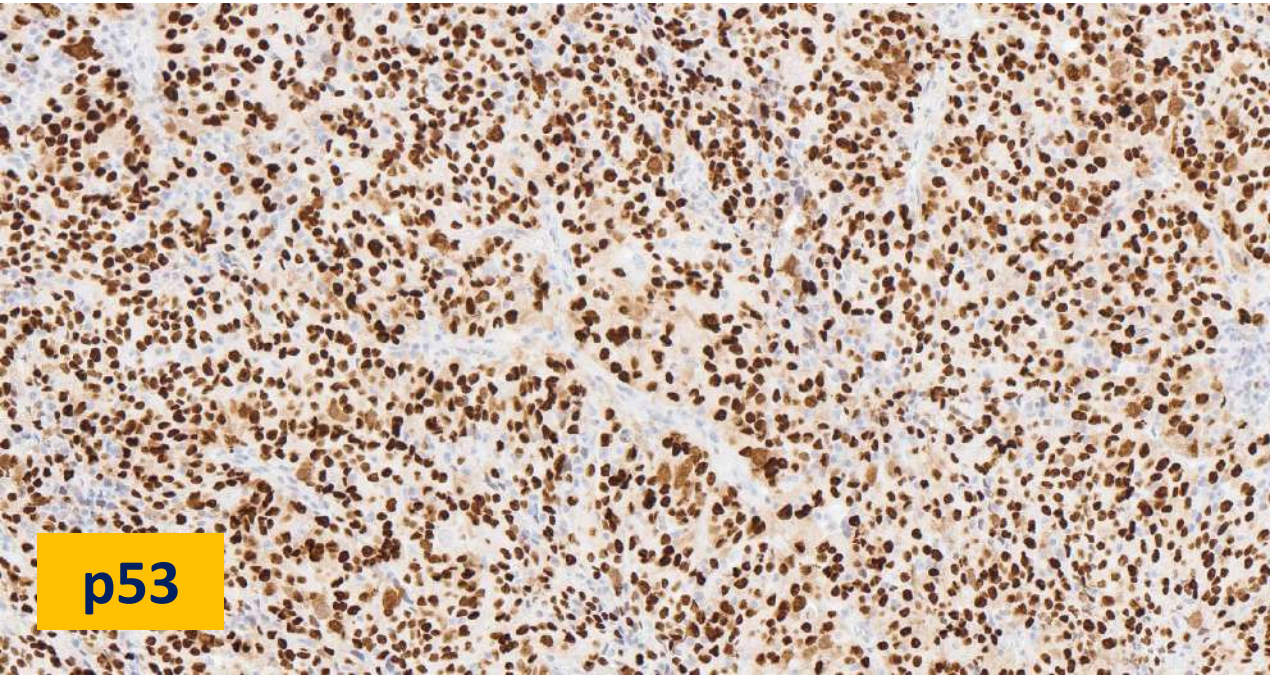
p53

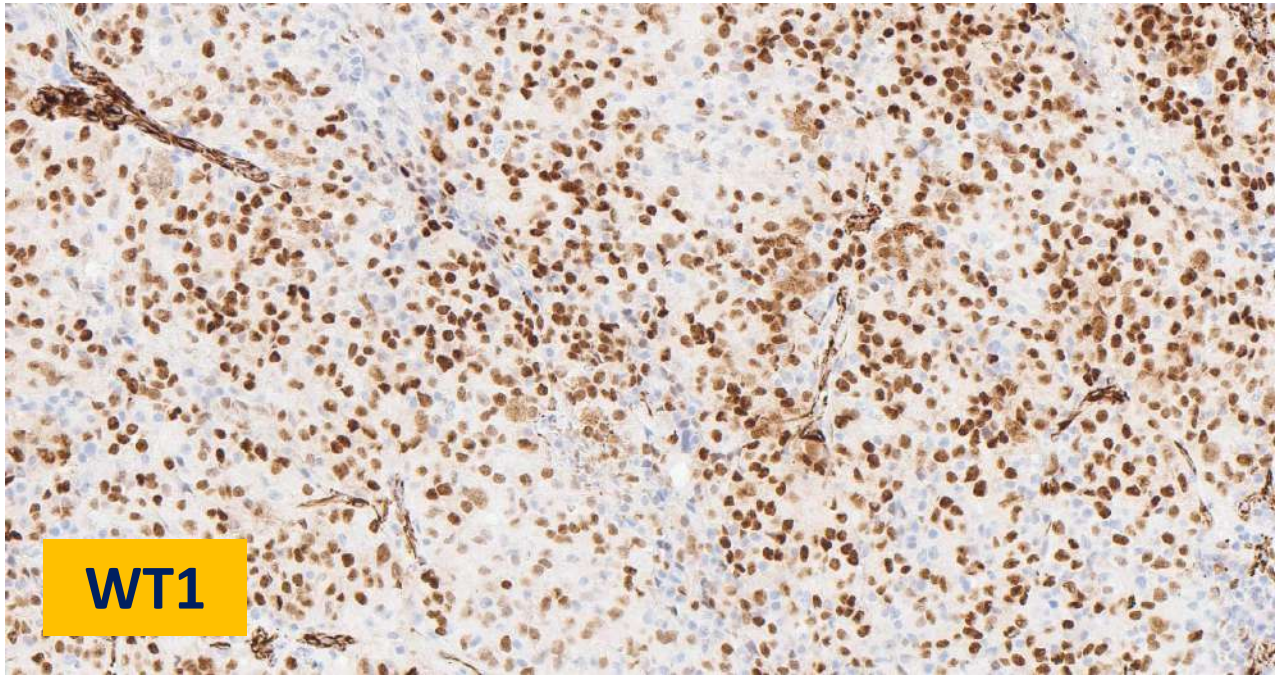
WT1

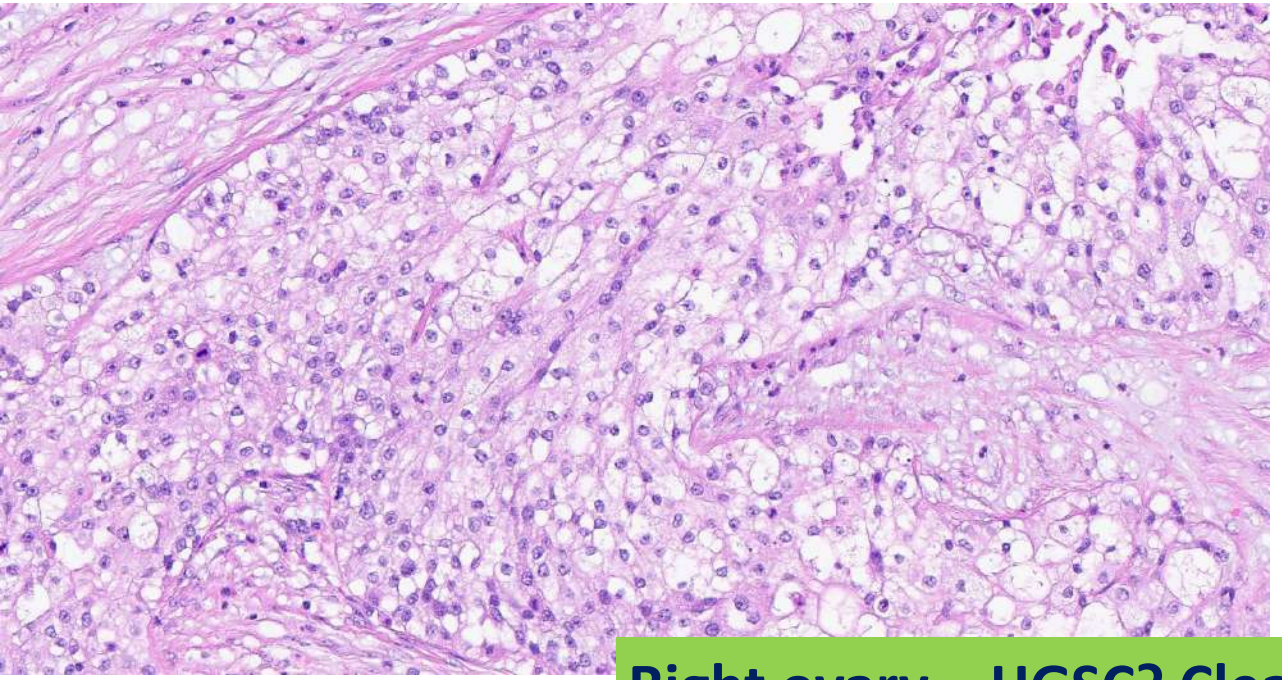
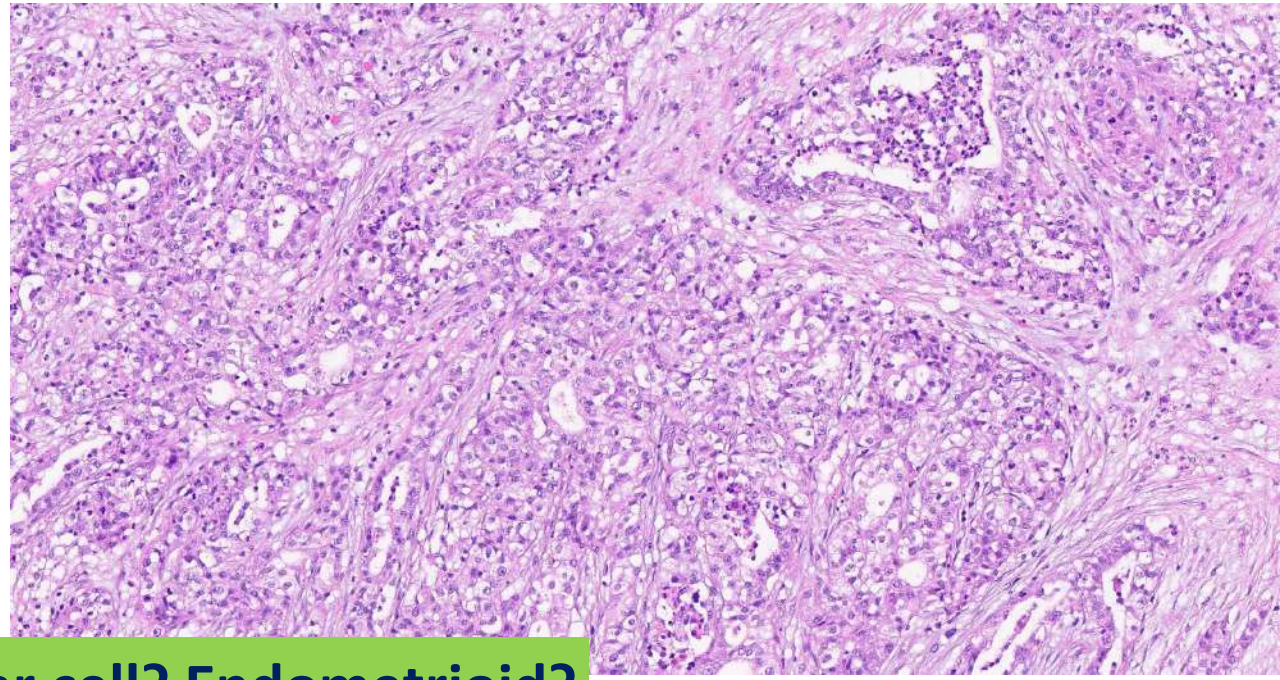

Right ovary – HGSC? Clear cell? Endometrioid?

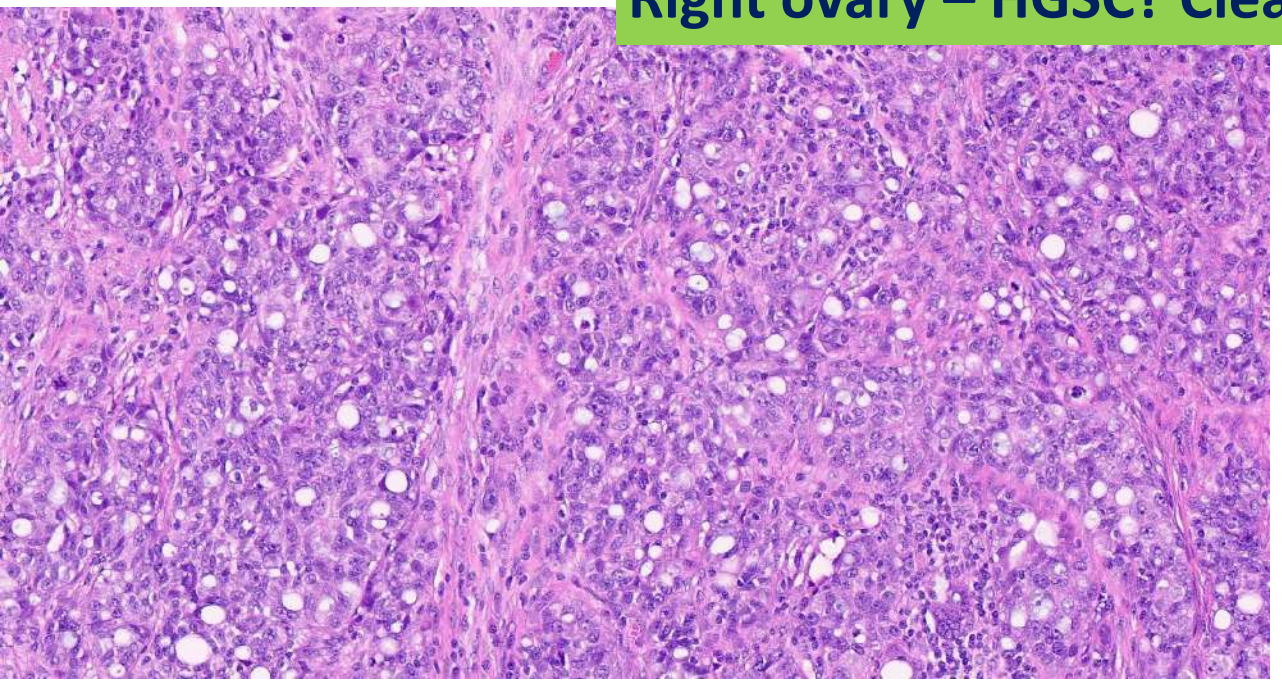
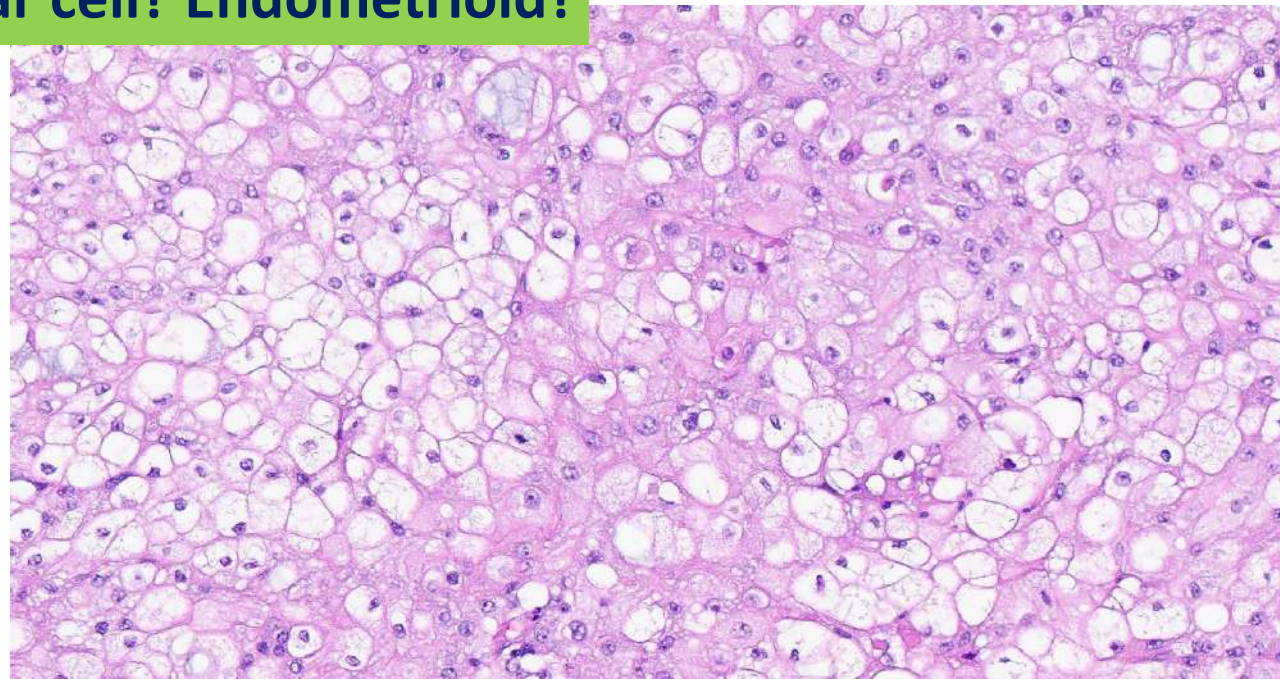

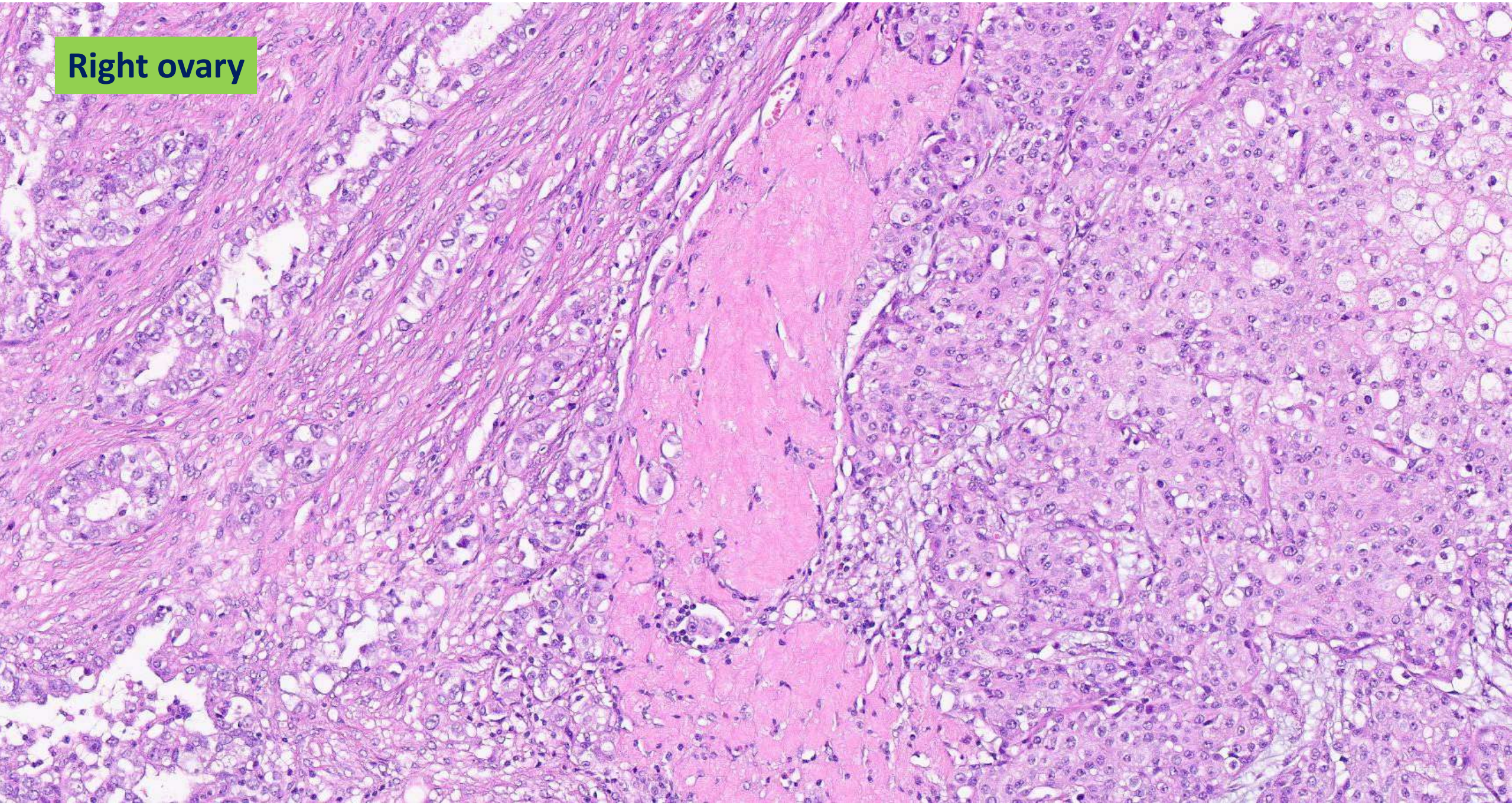
Right ovary

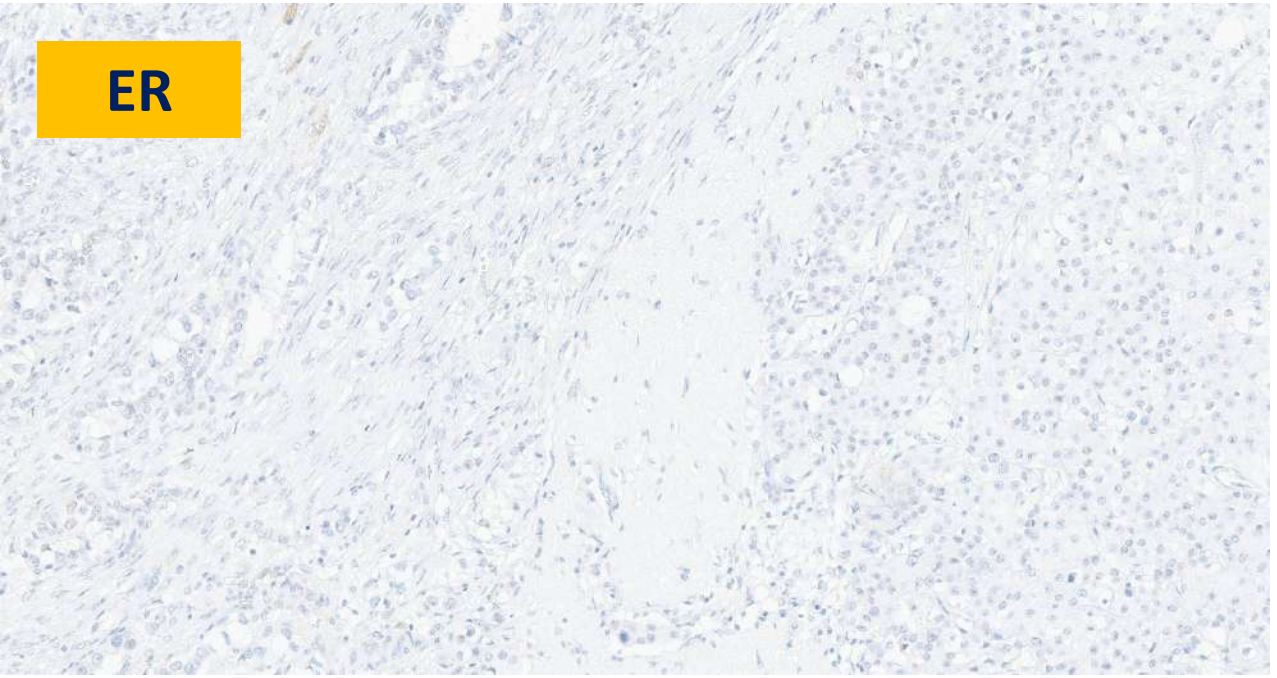
ER

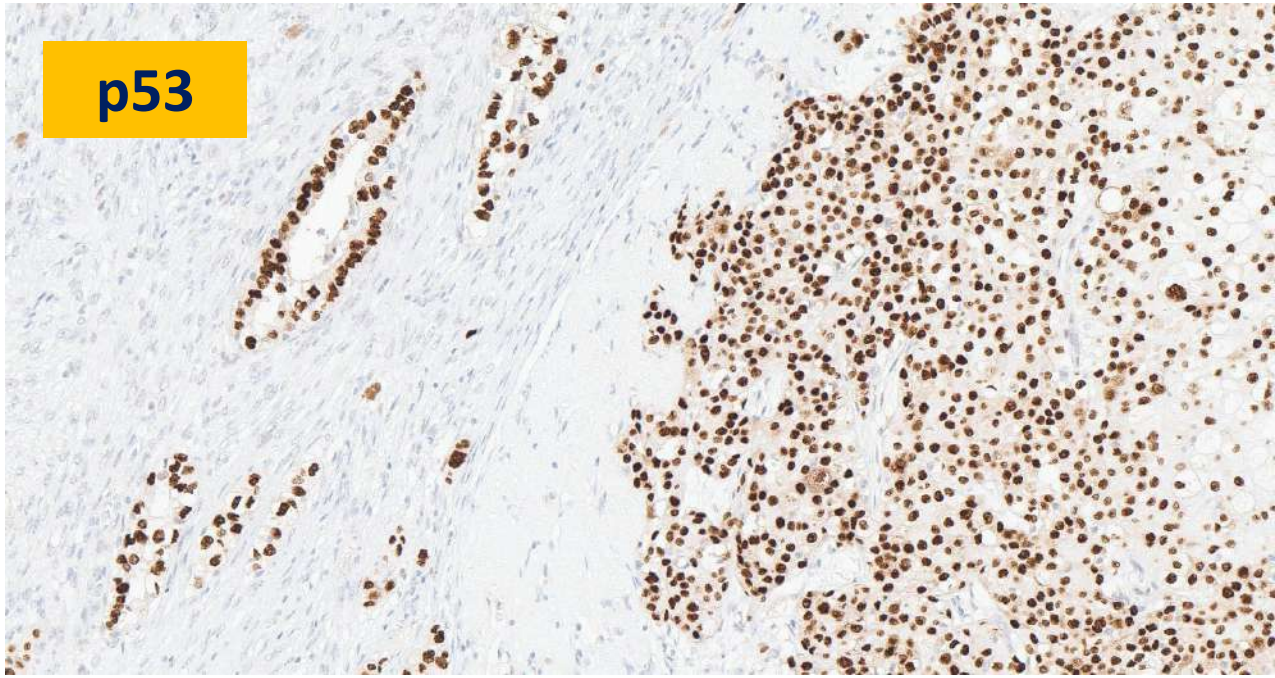
p53

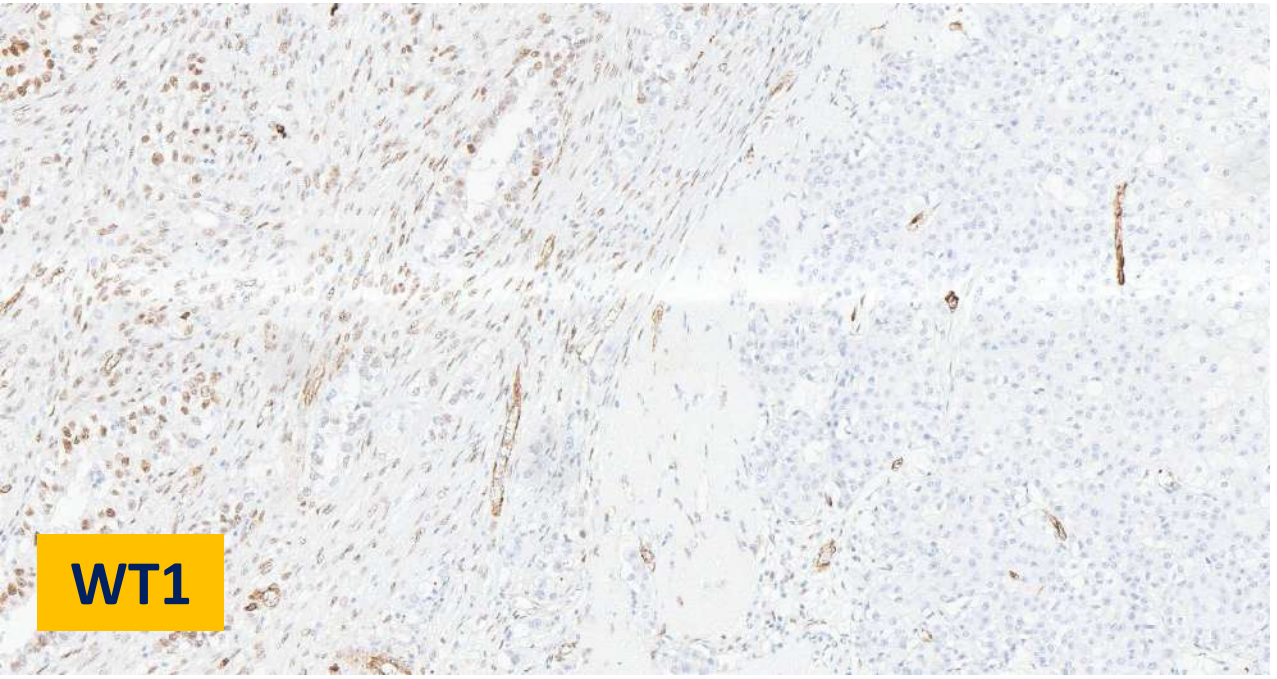
WT1

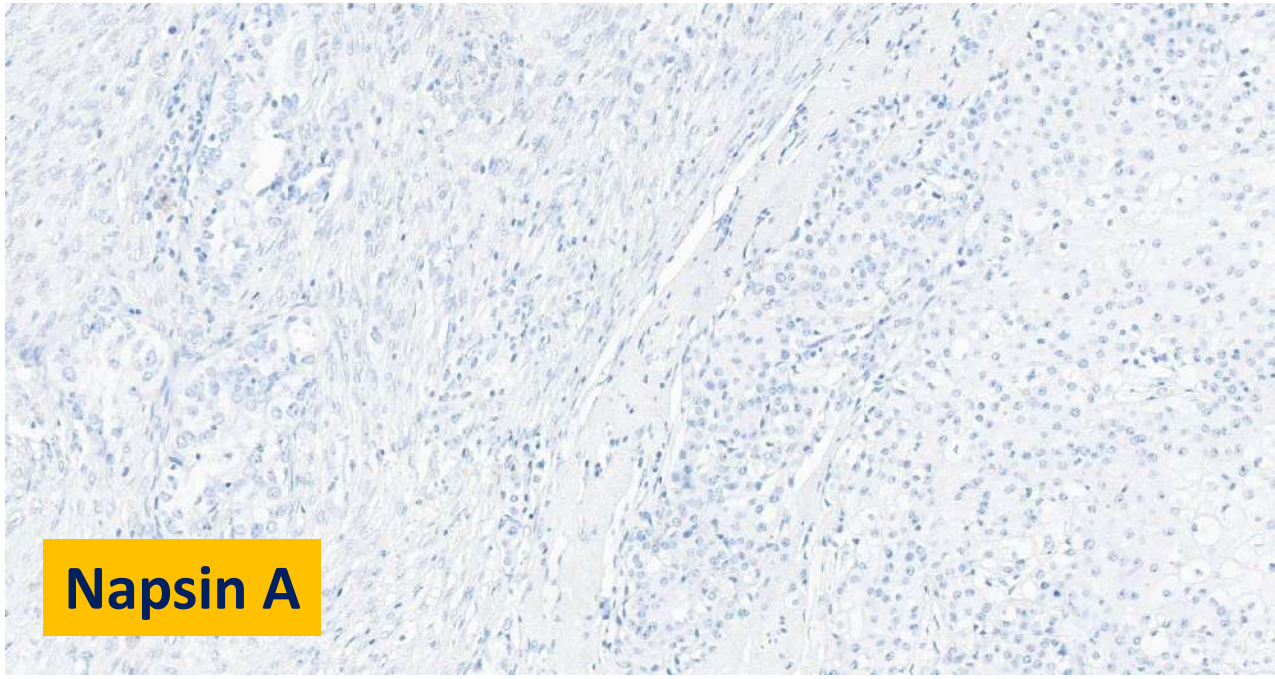
Napsin A

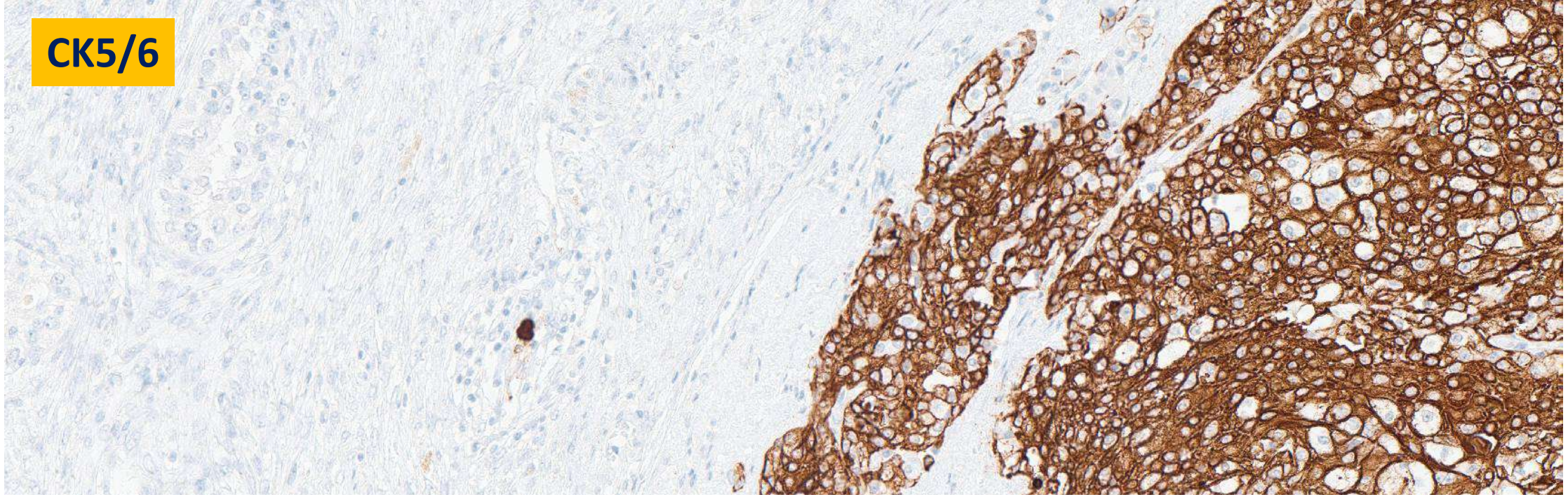
CK5/6

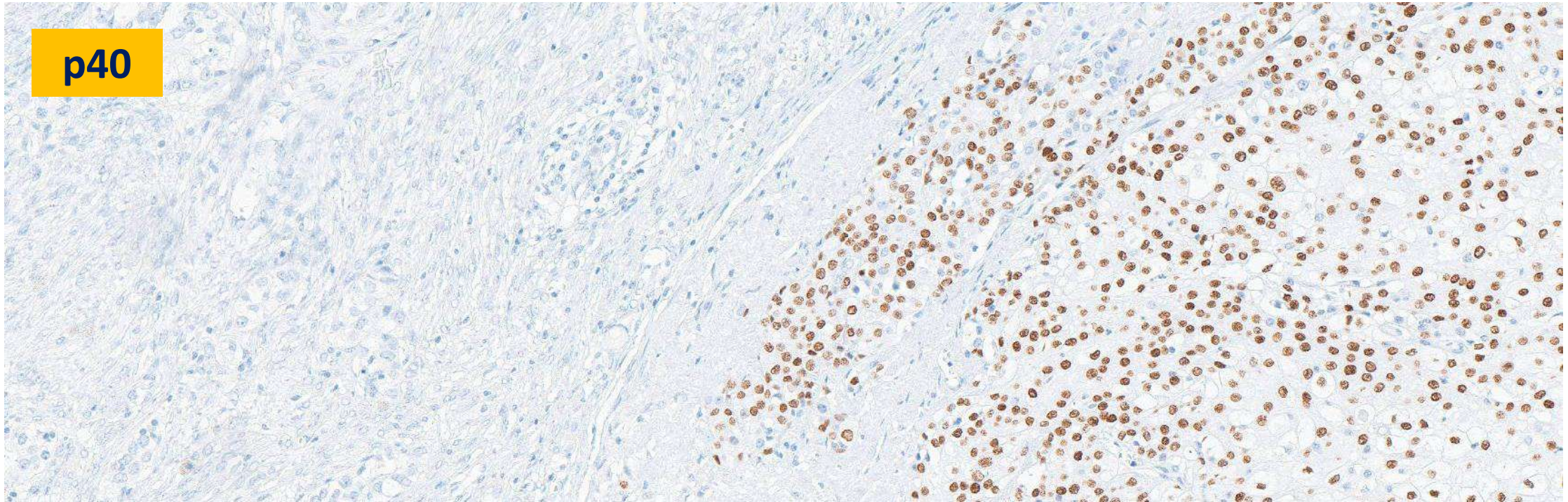
p40

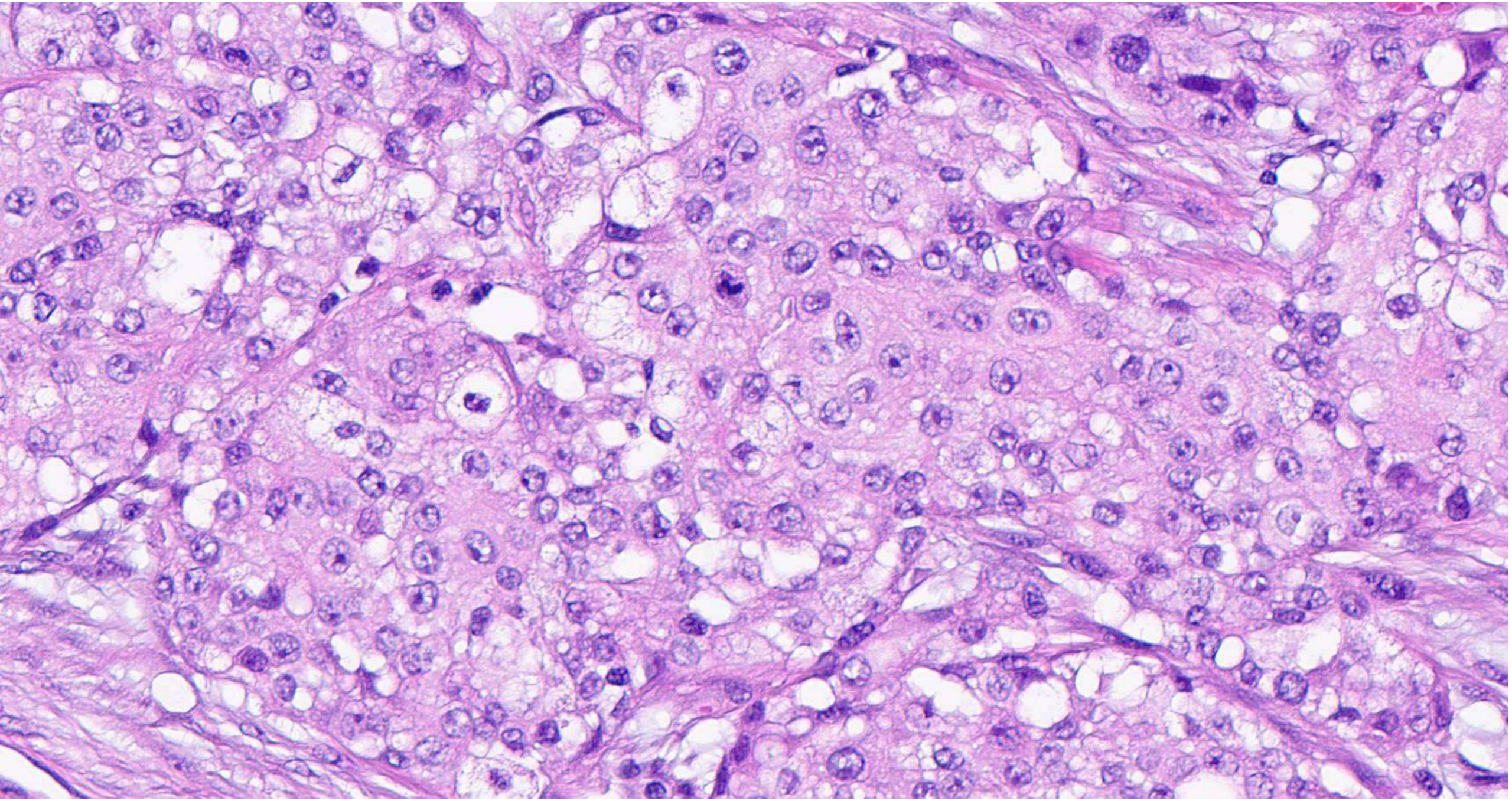

High grade serous carcinoma with squamous differentiation

- Squamous differentiation in HGSC has been reported in rare isolated cases
- Potential source of confusion with endometrioid or clear cell carcinoma (or clear cell change)
- Diagnosed by squamous features (intercellular bridges and keratinization) with IHC confirmation (p63, p40, CK5/6)
  - IHC allows distinction from 'squamoid' features described in HGSC (Tomonobe et al. AJSP 2023)

Tomonobe H, Ohishi Y, Hachisuga K, et al. Am J Surg Pathol. 2023;47:967-976.

- No known biological significance

Papillary Serous Carcinoma of the Ovary with Squamous Differentiation

Ulbright TM, Roth LM, Sutton GP. Int J Gynecol Pathol. 1990;9:86-94.

Case Report

Serous Carcinoma of the Ovary With Squamous Differentiation: A Case Report and A Literature Review

Roberts DE, Lombard CM. Int J Gynecol Pathol. 2013;32:459-63.

Primary ovarian serous carcinomas with extensive squamous differentiation: a case report and literature review

Check for updates

Sun Y, Chen Y, Zhang X, et al. BMC Womens Health. 2021;21:193.

Germ cell tumour or trophoblastic differentiation in ovarian carcinomas

- Carcinomas with **somatically derived** germ cell tumour or trophoblastic components are recognized in the endometrium and ovaries
- These components may show morphological and IHC features of **yolk sac tumour** or **choriocarcinoma** (or rarely, epithelioid trophoblastic tumour)
- Various types of ovarian carcinomas (including carcinosarcoma) and borderline tumours have been implicated

Yolk sac tumours of the female genital tract in older adults derive commonly from somatic epithelial neoplasms: somatically derived yolk sac tumours

McNamee T, Damato S, McCluggage WG. Histopathology. 2016;69:739-751.

Malignant tumours of the uterus and ovaries with Mullerian and germ cell or trophoblastic components have a somatic origin and are characterised by genomic instability*

Acosta AM, Sholl LM, Cin PD, et al. Histopathology. 2020;77:788-797.

Molecular characterization of uterine and ovarian tumors with mixed epithelial and germ cell features confirms frequent somatic derivation

Skala SL, Liu CJ, Udager AM, et al. Mod Pathol. 2020;33:1989-2000.

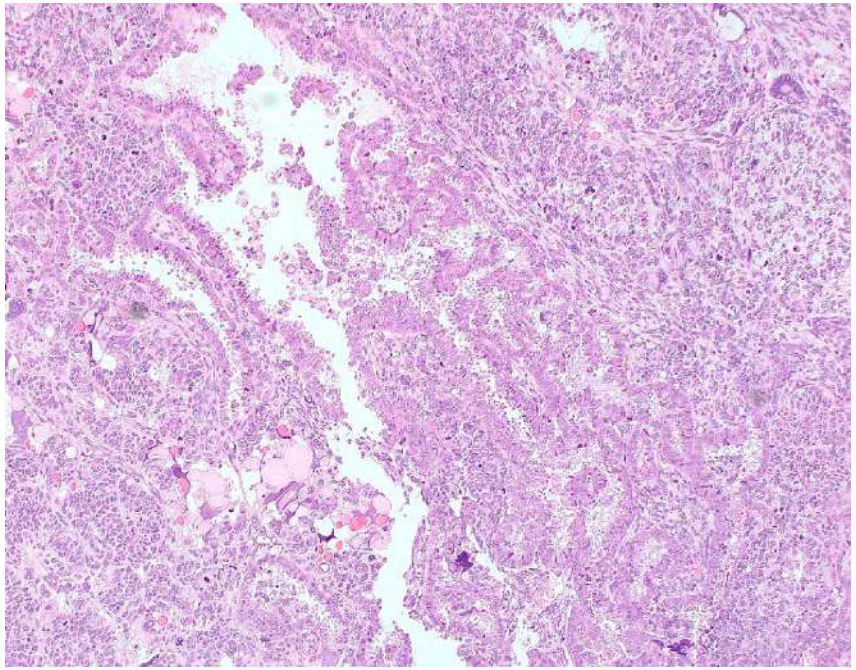

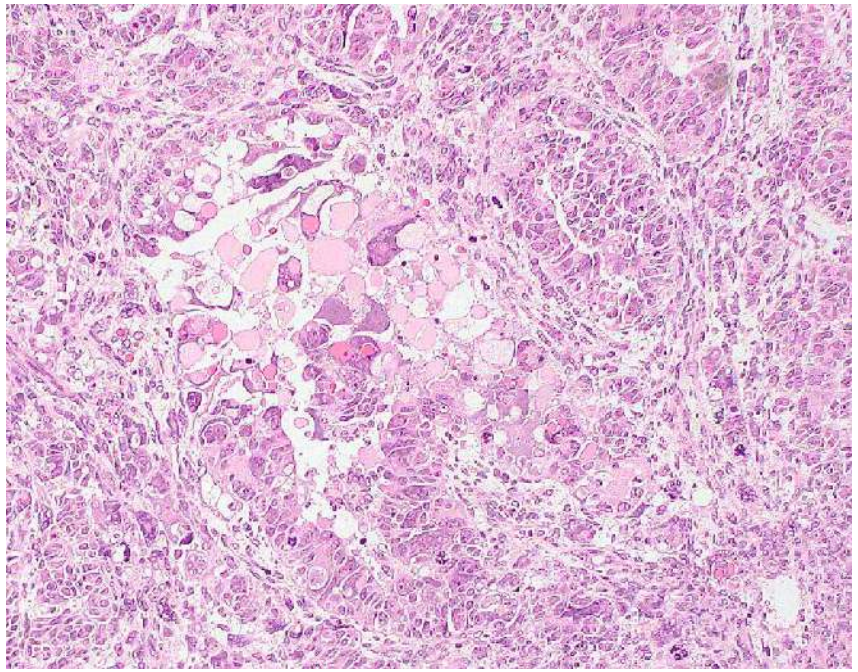

Ovarian carcinosarcoma with high grade serous carcinoma and yolk sac tumour components

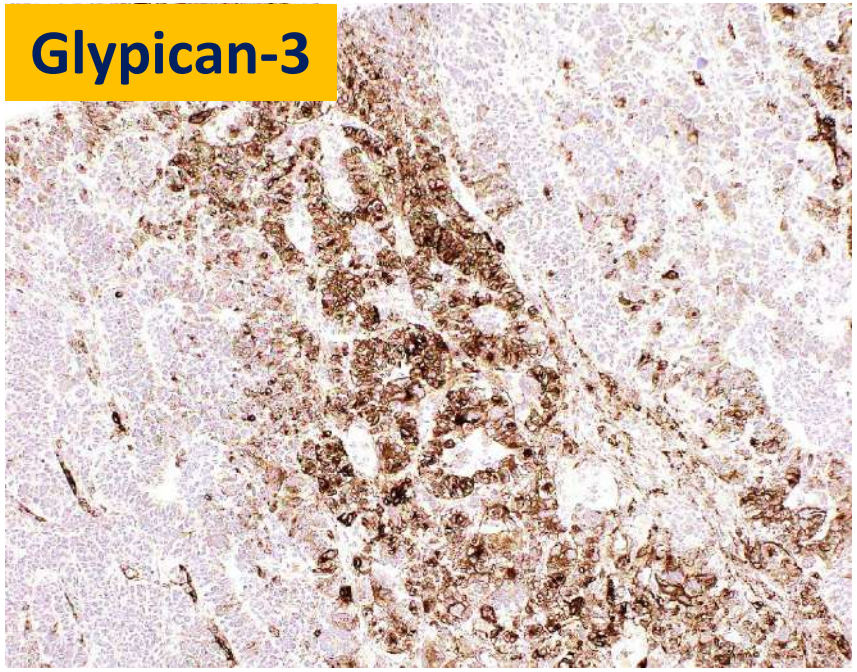

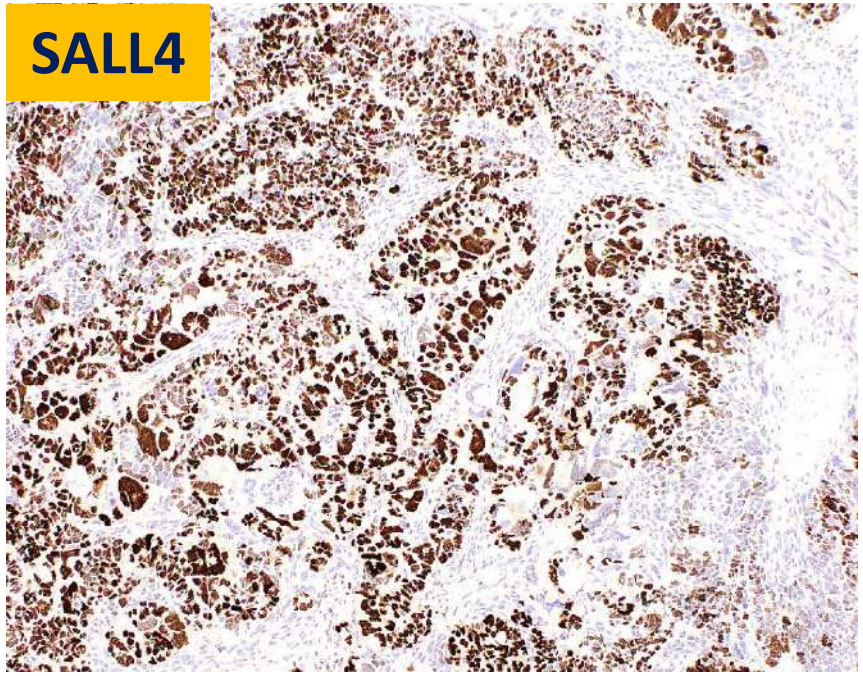

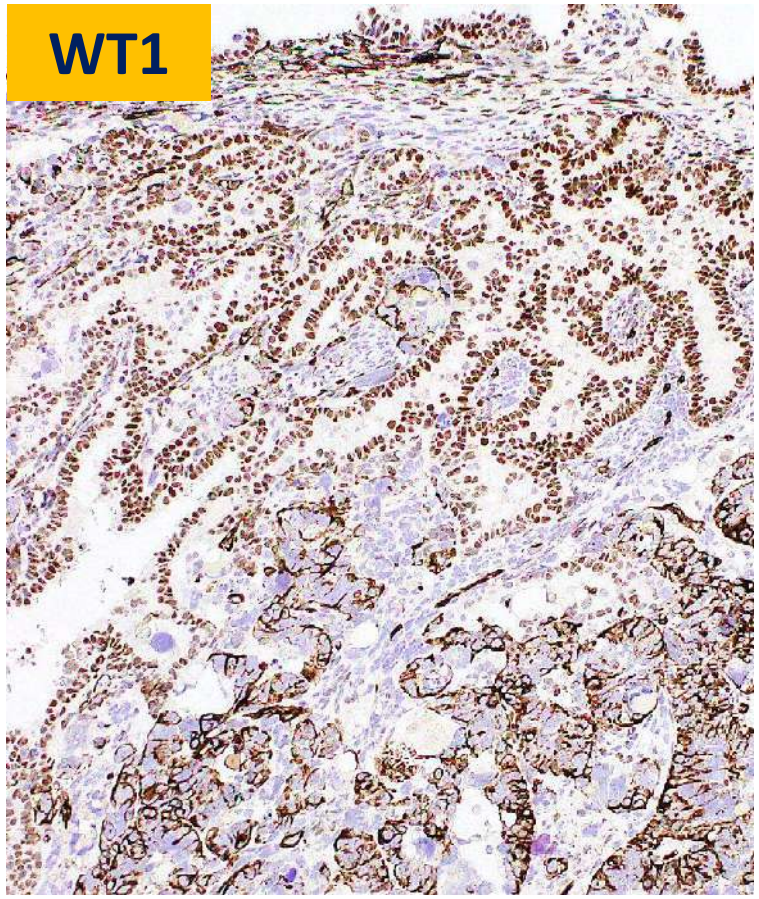

Case 3

- 58 years old
- Pelvic mass biopsy

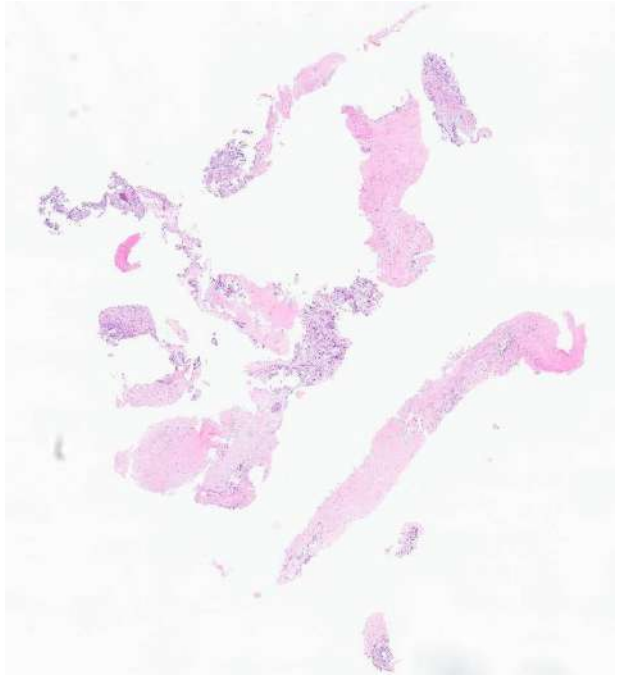

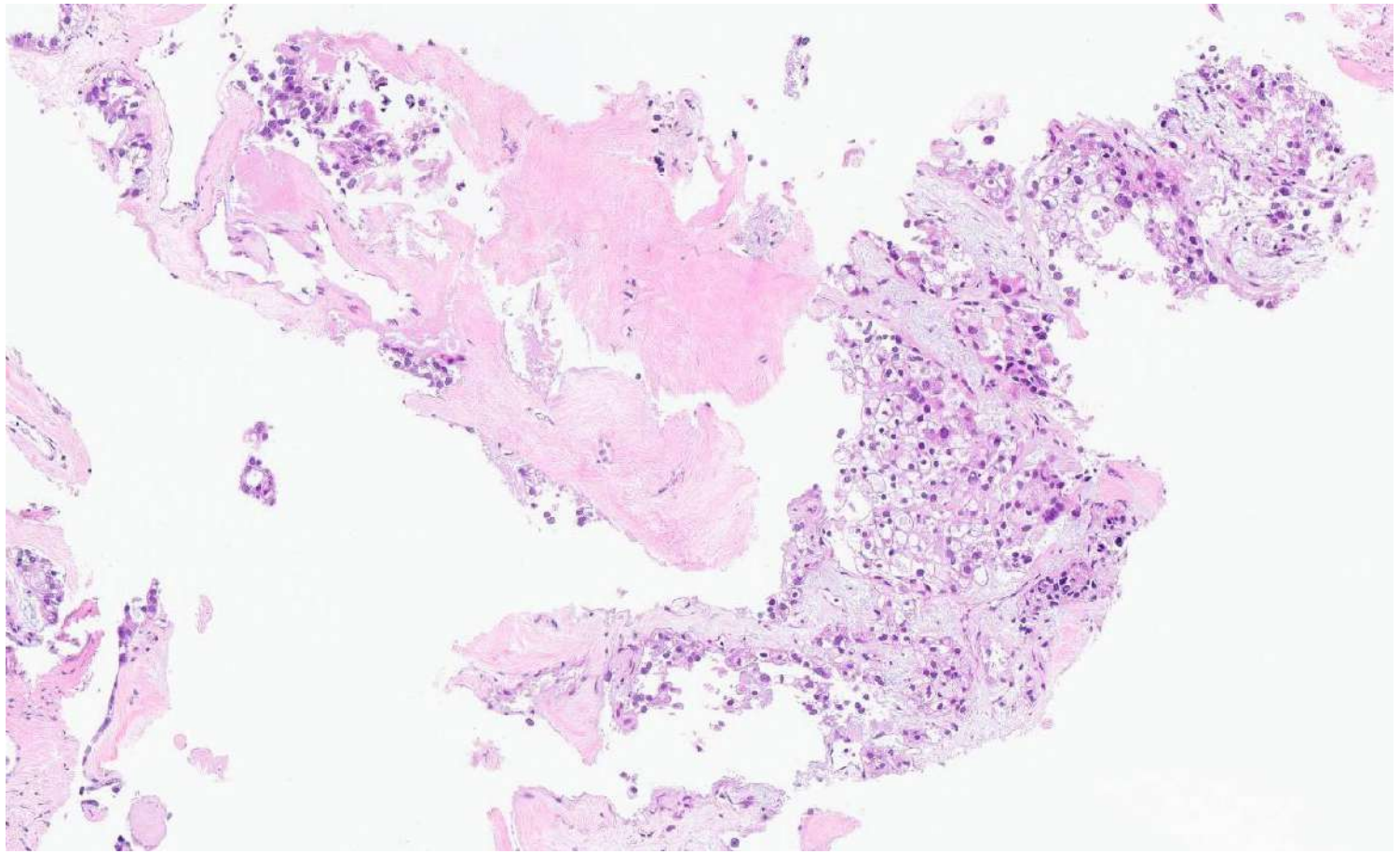


ER

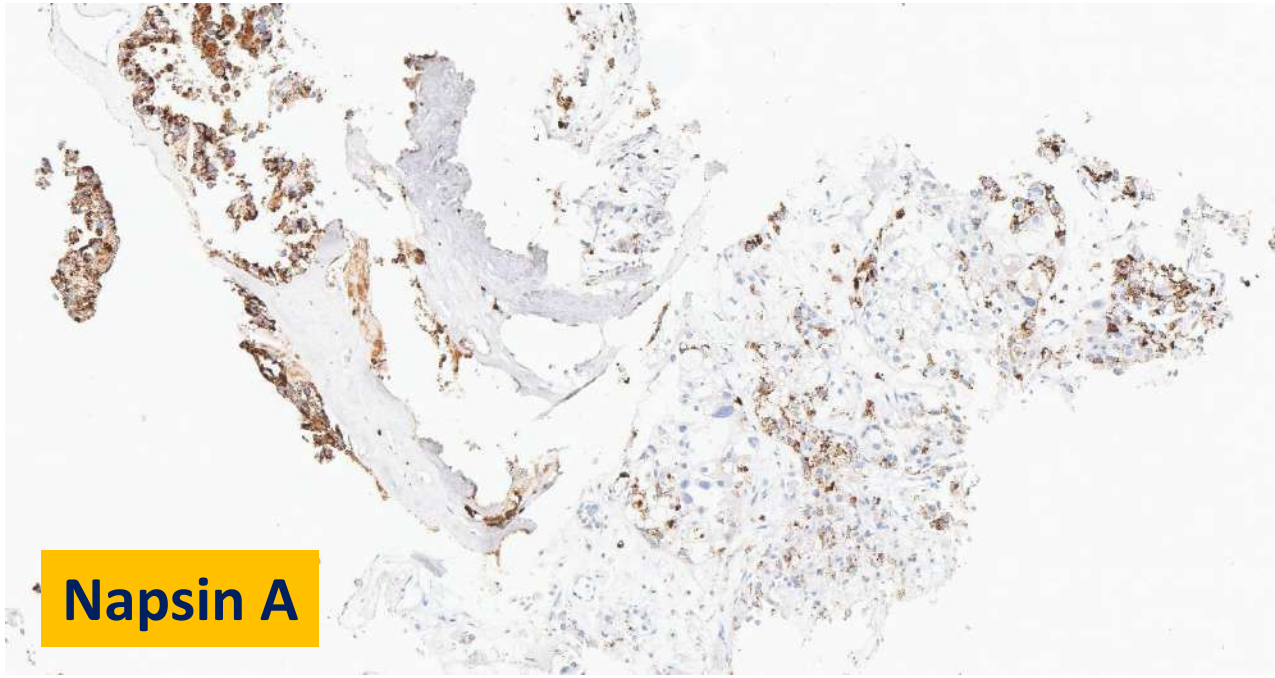
Napsin A

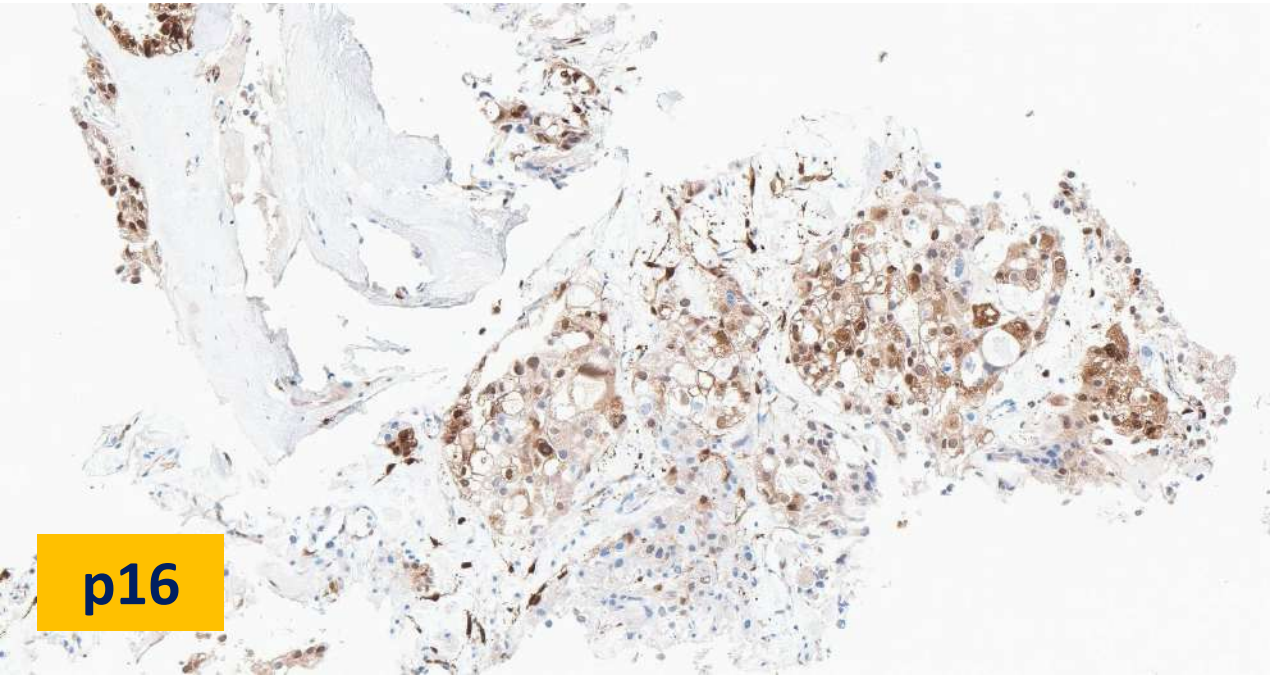
p16


p53

Unexpected (or non-prototypical) IHC findings in ovarian clear cell carcinomas (CCC)

- Typical IHC profile of ovarian CCC: ER –, p53wt, WT1 –, Napsin A +
- Non-prototypical IHC profiles possible in a minority of ovarian CCC
  - Focal ER staining may occur in 10.9% (Köbel et al. 2009)
  - Abnormal p53 expression may occur in 5.6 – 11.5%
    - Parra-Herran et al. 2019: 6.7% (6/90)
    - Köbel et al. 2023: 11.5% (86/748)
    - Wilkins et al. 2023: 5.6% (4/71)
  - WT1 staining rarely seen in 0.9 – 3.1% (Köbel et al. 2009; Köbel et al. 2016)
  - Napsin A can be negative in 4.5 – 8.2% (Iwamoto et al. 2015; Köbel et al. 2016)
  - p16 is often patchy/heterogeneous, but may be diffuse (block) or absent (Rambau et al. 2018)

Köbel M, Kalloger SE, Carrick J, et al. Am J Surg Pathol. 2009;33:14-21.
Iwamoto M, Nakatani Y, Fugo K, et al. Hum Pathol. 2015;46:957-62.
Köbel M, Rahimi K, Rambau PF, et al. Int J Gynecol Pathol 2016;35:430-41.
Rambau PF, Vierkant RA, Intermaggio MP, et al. J Pathol Clin Res. 2018;4:250-261.
Parra-Herran C, Bassiouny D, Lerner-Ellis J, et al. Am J Surg Pathol. 2019;43:1591-1599.
Köbel M, Kang EY, Weir A, et al. J Pathol Clin Res. 2023;9:208-222.
Wilkins R, Lin LH, Xia R, et al. Am J Clin Pathol. 2023;160:466-476.

Case 3

- Abnormal p53 expression is an independent prognostic factor for shorter overall survival in ovarian clear cell carcinomas (Köbel et al. 2023; Wilkins et al. 2023) and not against this diagnosis

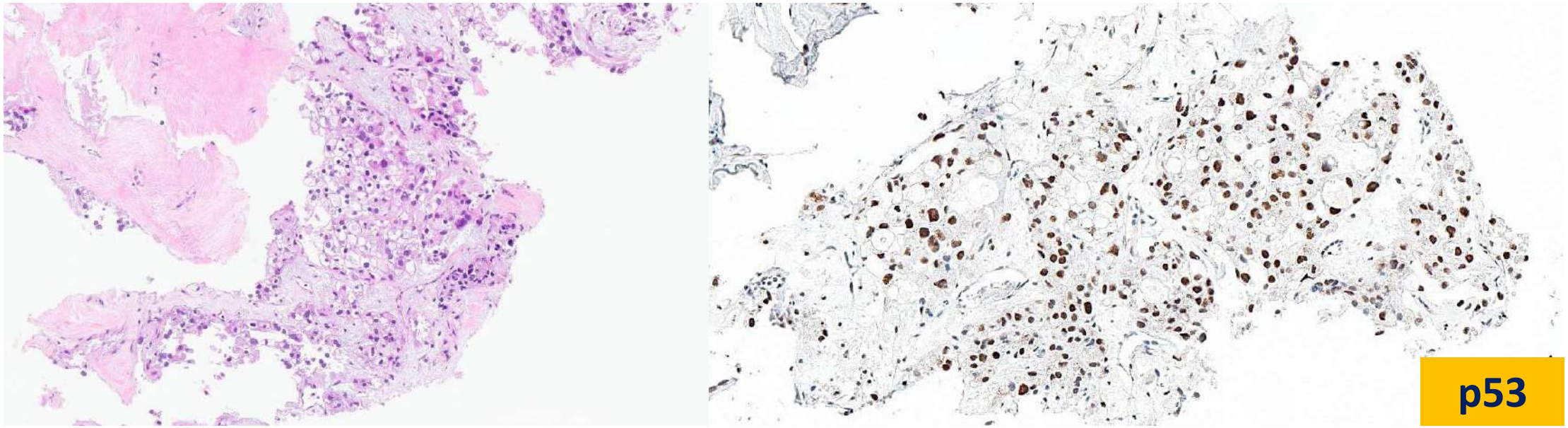

Köbel M, Kang EY, Weir A, et al. J Pathol Clin Res. 2023;9:208-222.
Wilkins R, Lin LH, Xia R, et al. Am J Clin Pathol. 2023;160:466-476.

Case 4

- 62 years old
- Left ovarian tumour

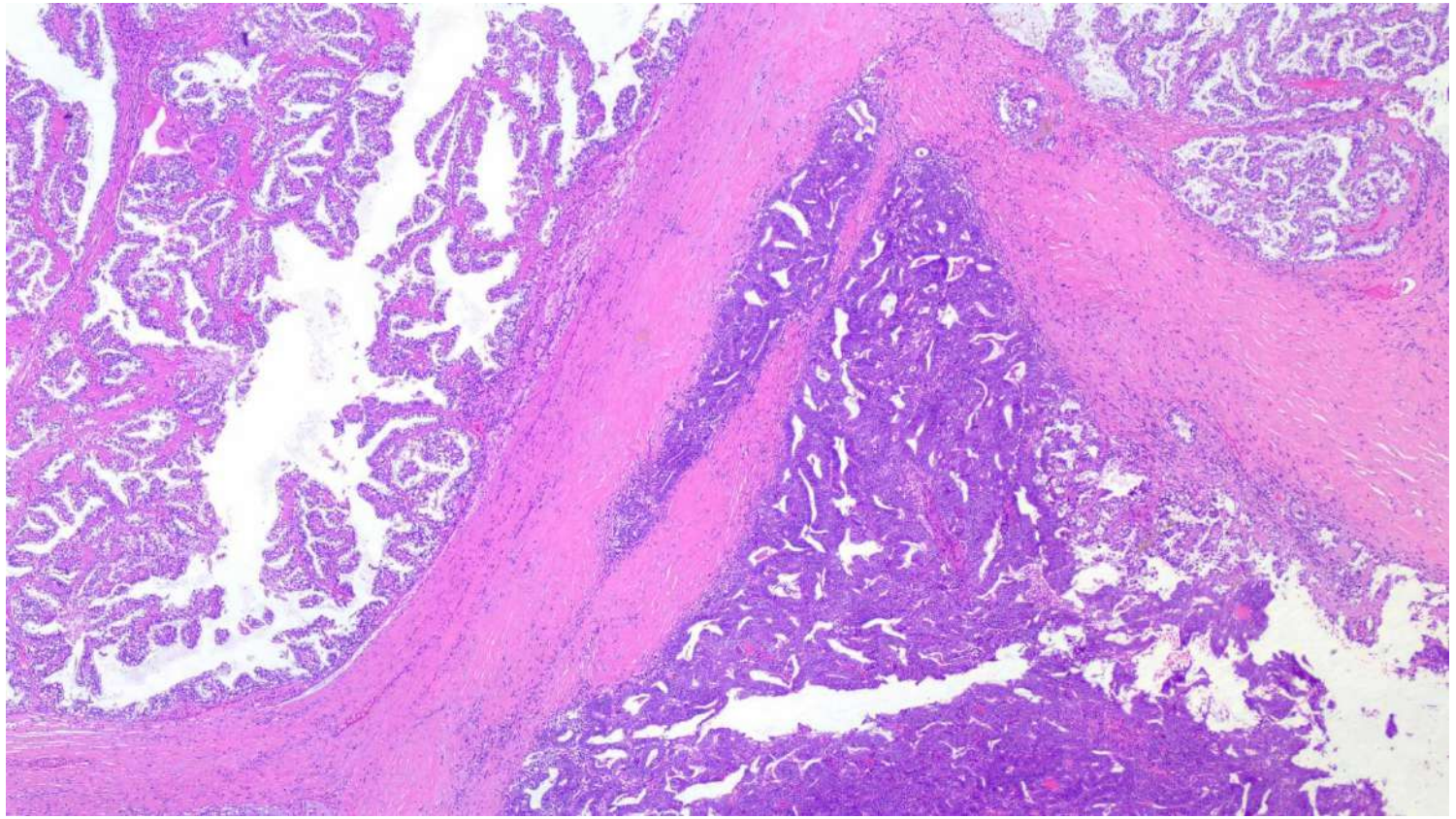

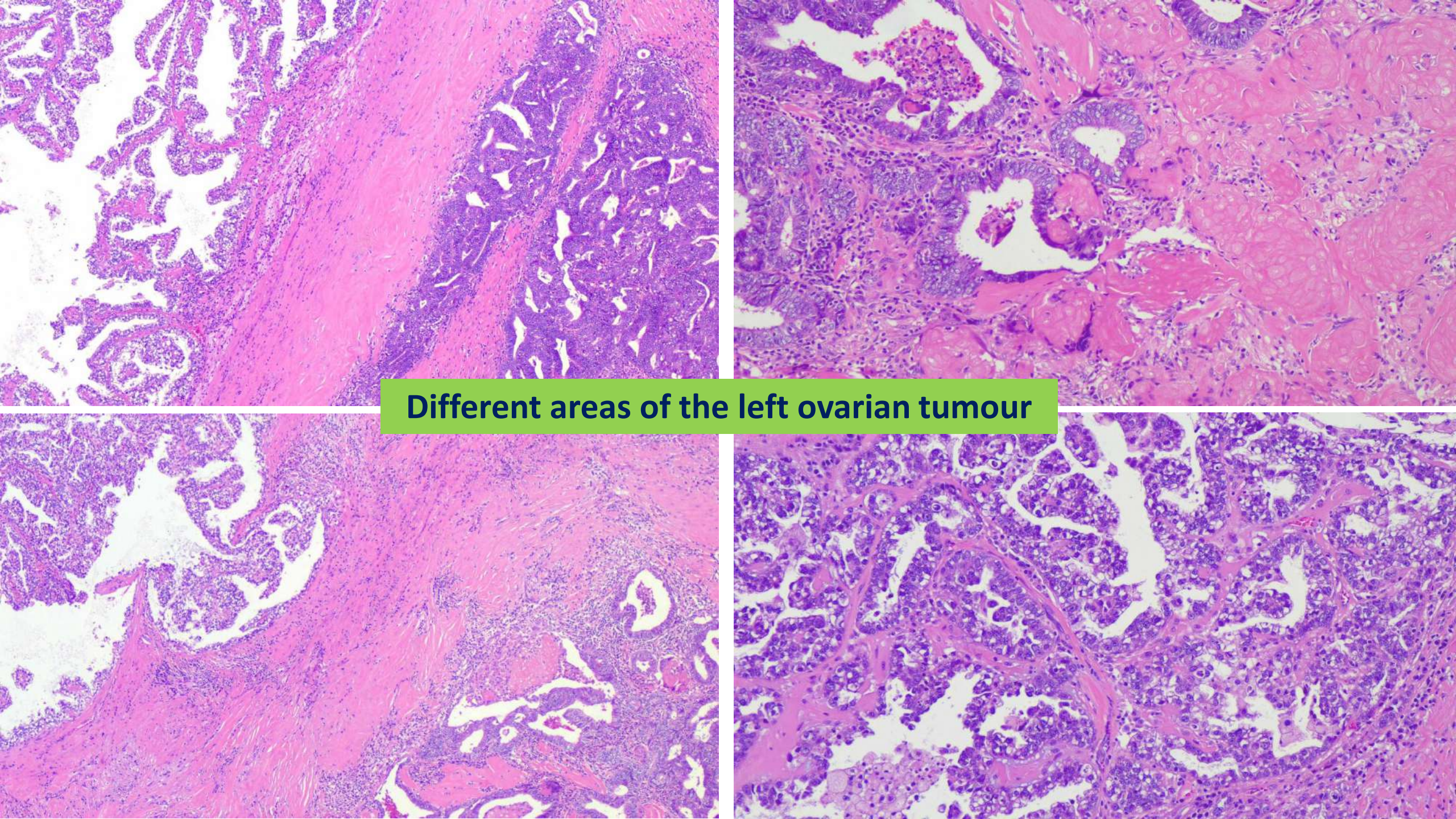

Different areas of the left ovarian tumour

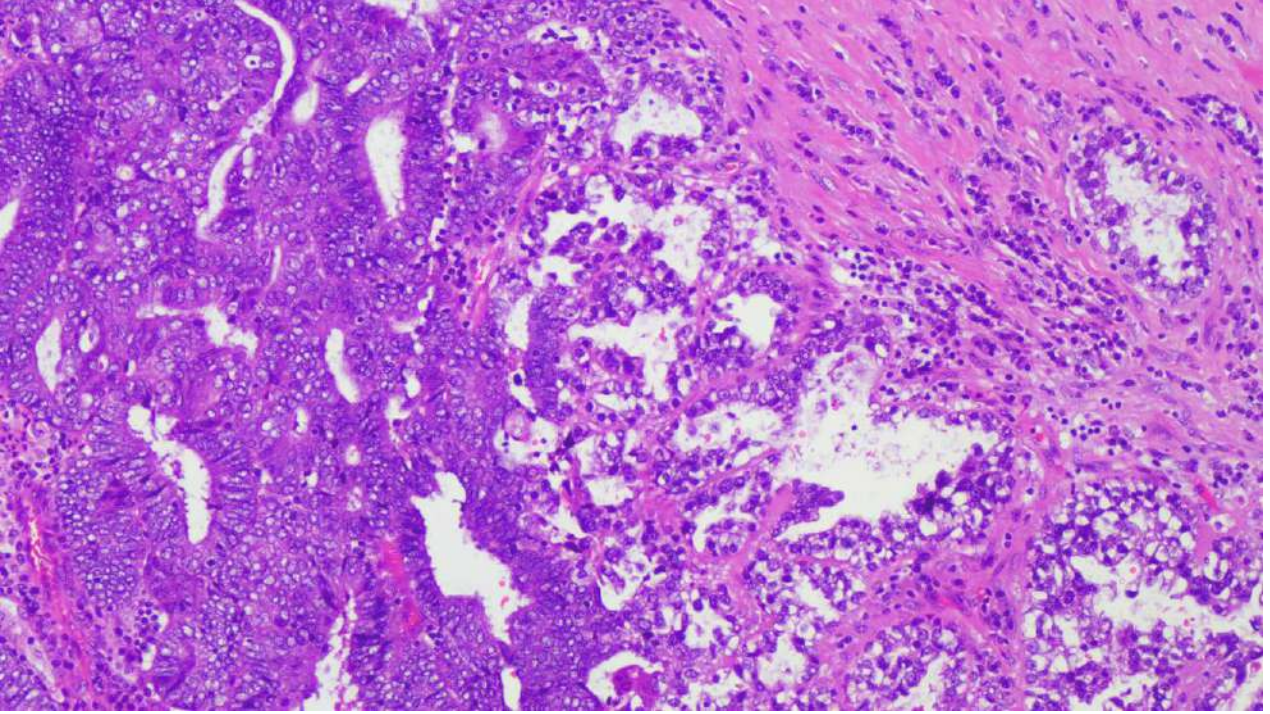

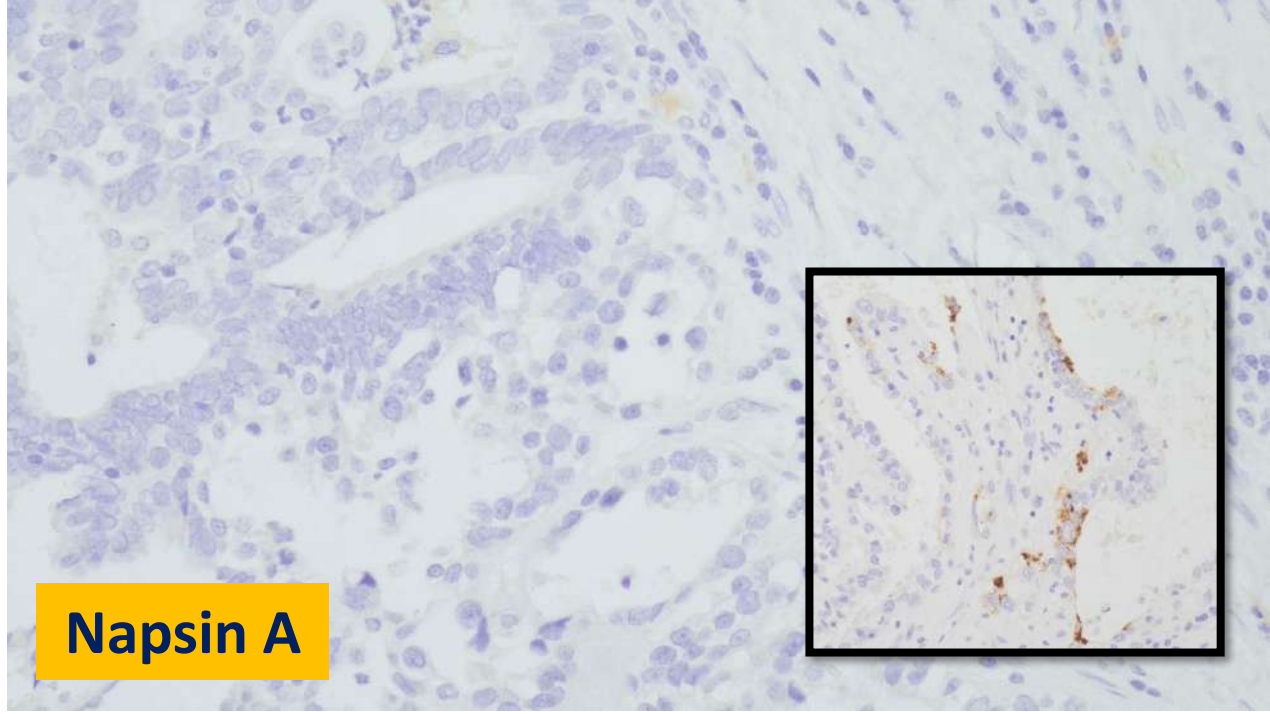
Napsin A

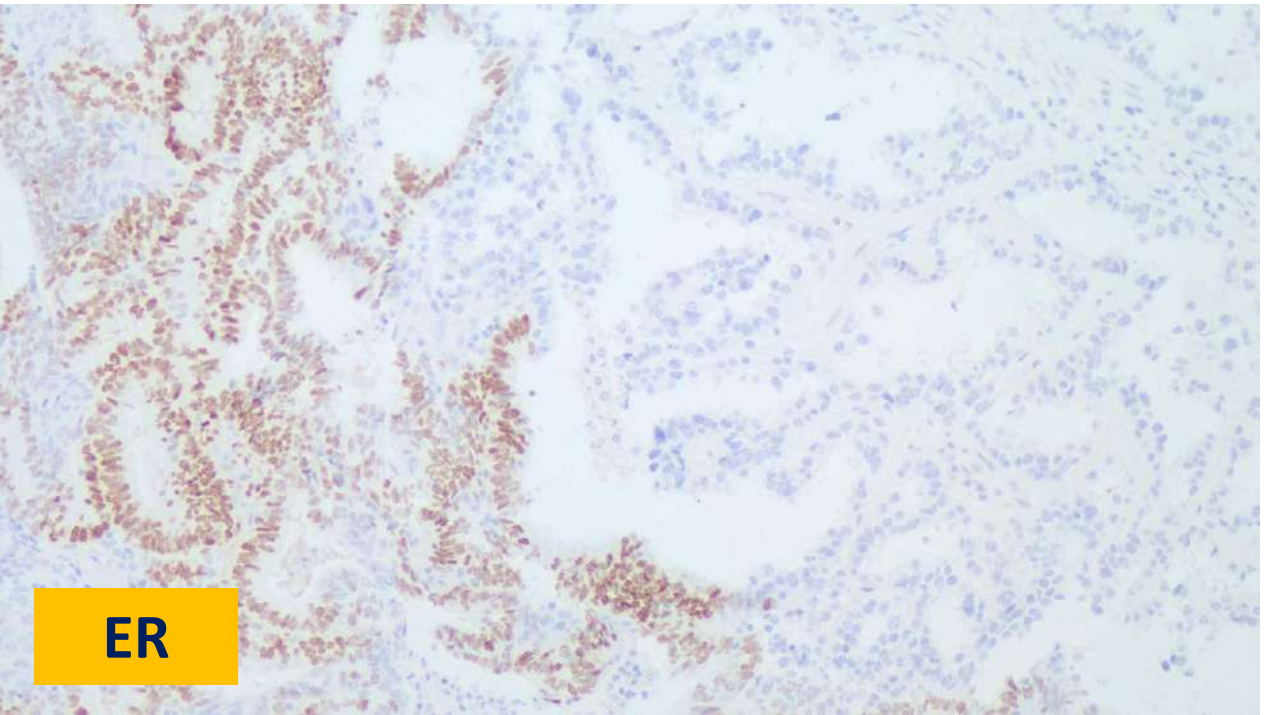
ER

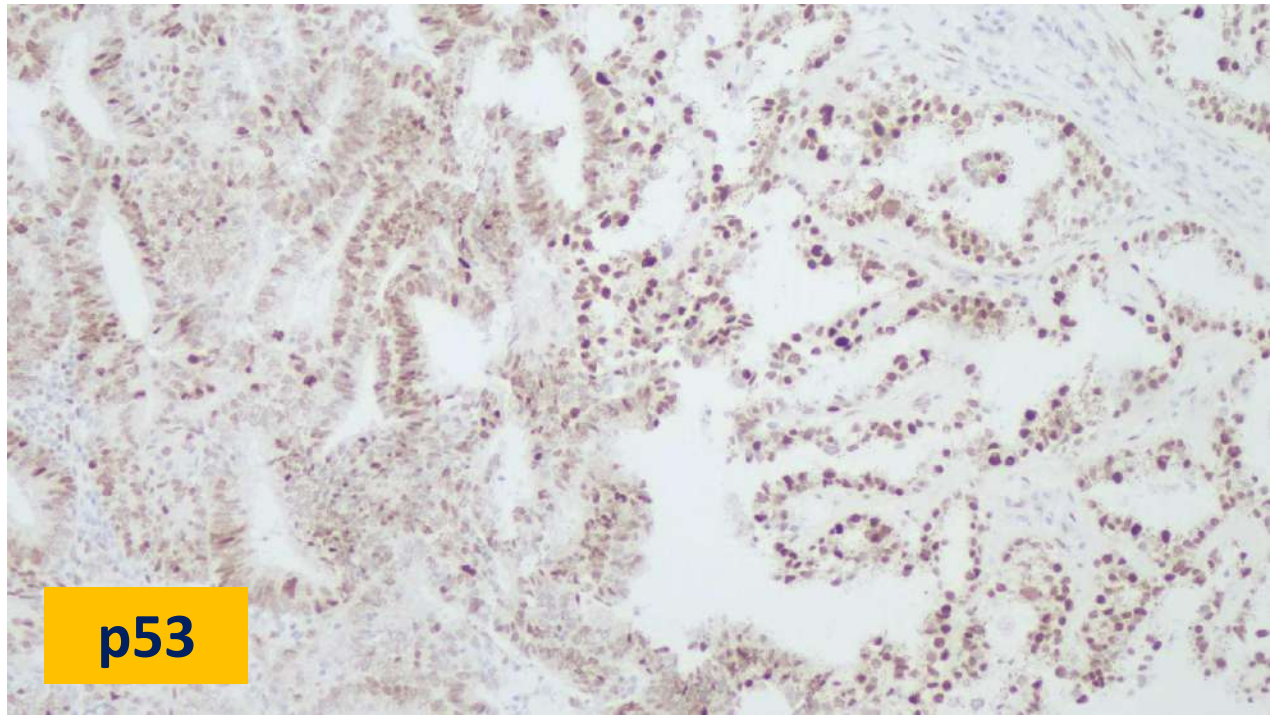
p53

Case 4 – Mixed endometrioid and clear cell carcinoma

Endometrioid carcinoma component

- ER positive
- Napsin A negative
- p53 wild-type

Clear cell carcinoma component

- ER negative
- Napsin A focally positive
- p53 wild-type

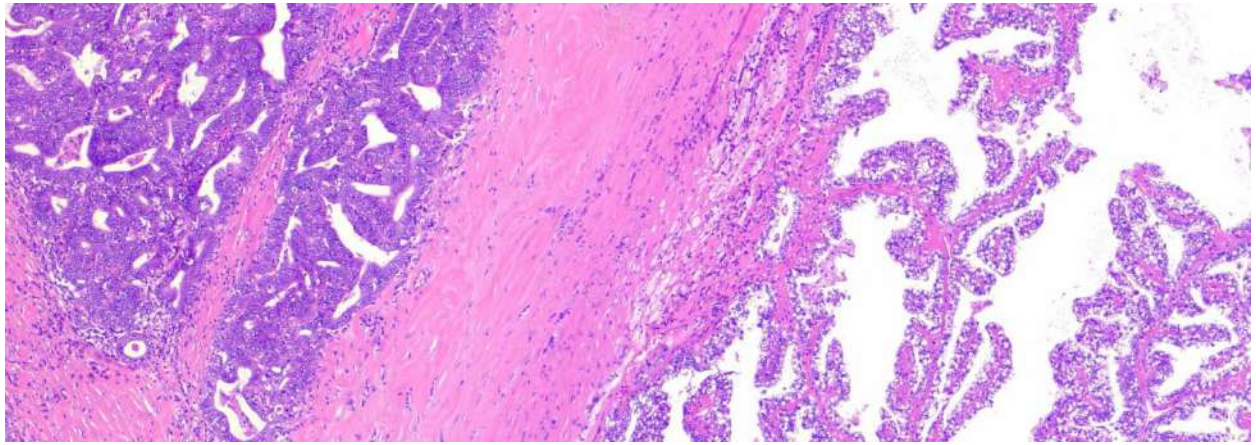

Mixed carcinoma of the ovary

- Ovarian carcinoma comprising 2 or more histotypes
- The different components should be distinctive by both morphology and IHC
- No requirement on minimum percentage (any percentage is ok)
- The grade (if applicable) and percentage for each histotype should be stated
- Usually associated with endometriosis
- Mixed endometrioid and clear cell carcinoma is the most common type (some are MMR deficient)
- Other reported combinations include endometrioid/LGSC, mesonephric-like/LGSC, etc.

Mackenzie R, Talhouk A, Eshragh S, et al. Am J Surg Pathol. 2015;39:1548-57.

Case 5

- 53 years old
- Left ovarian tumour

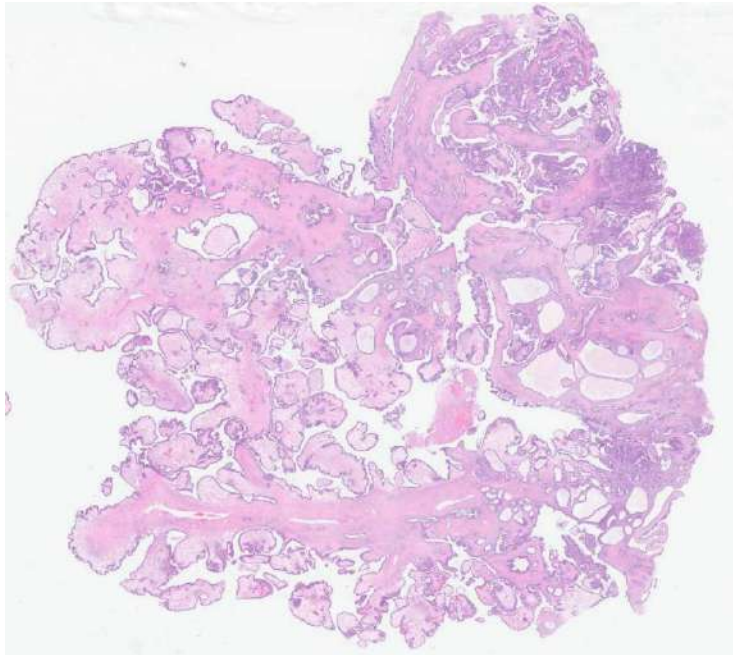

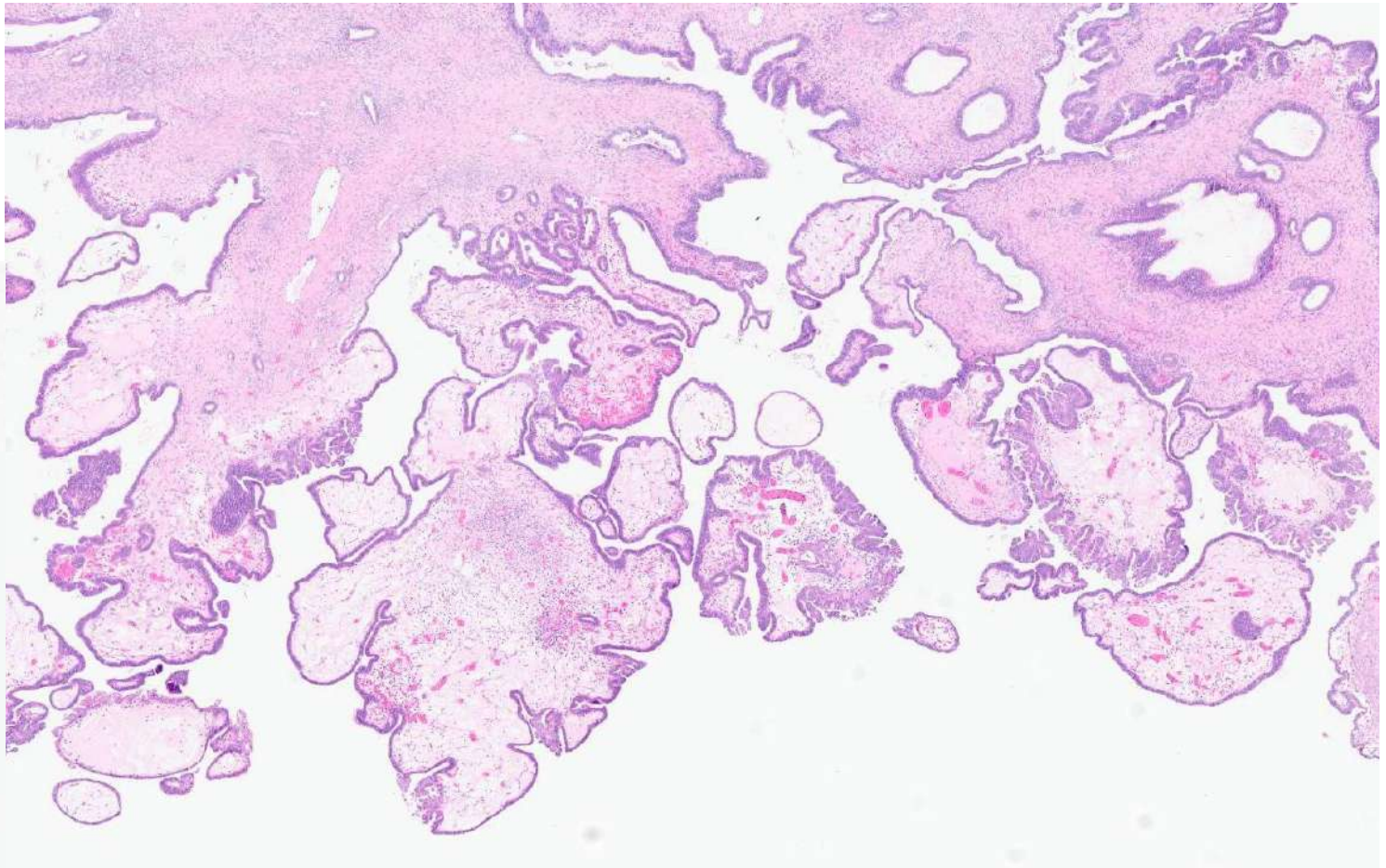

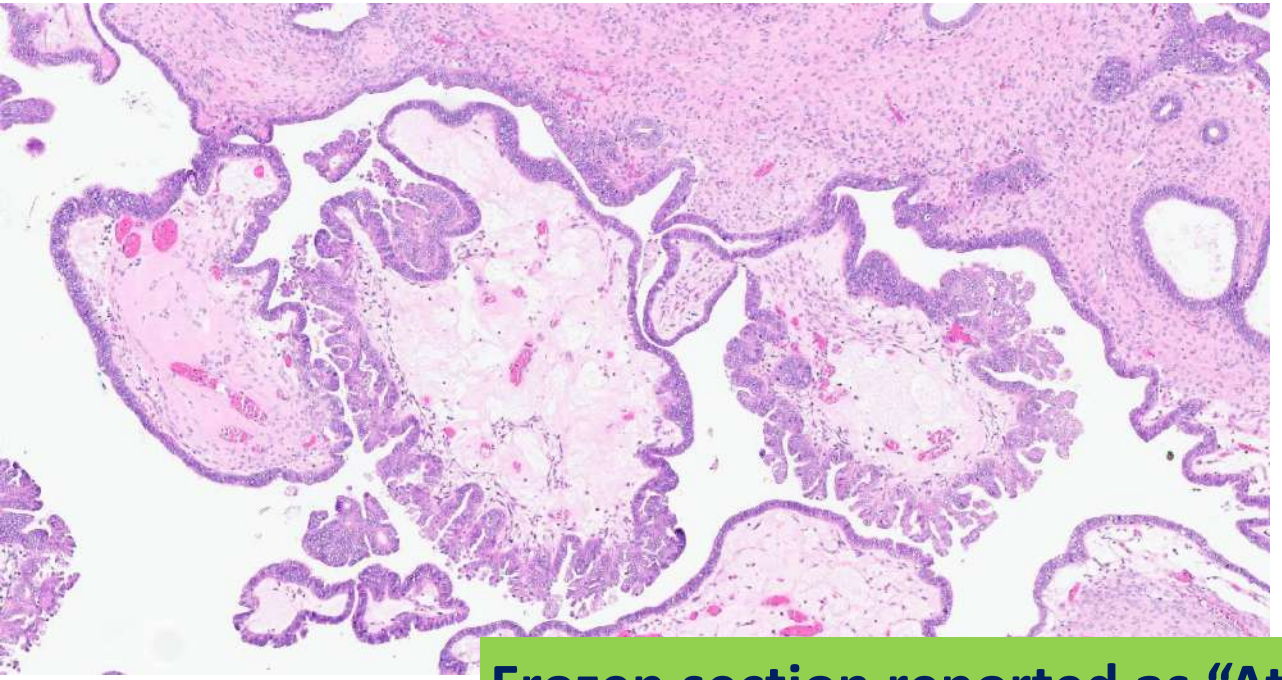

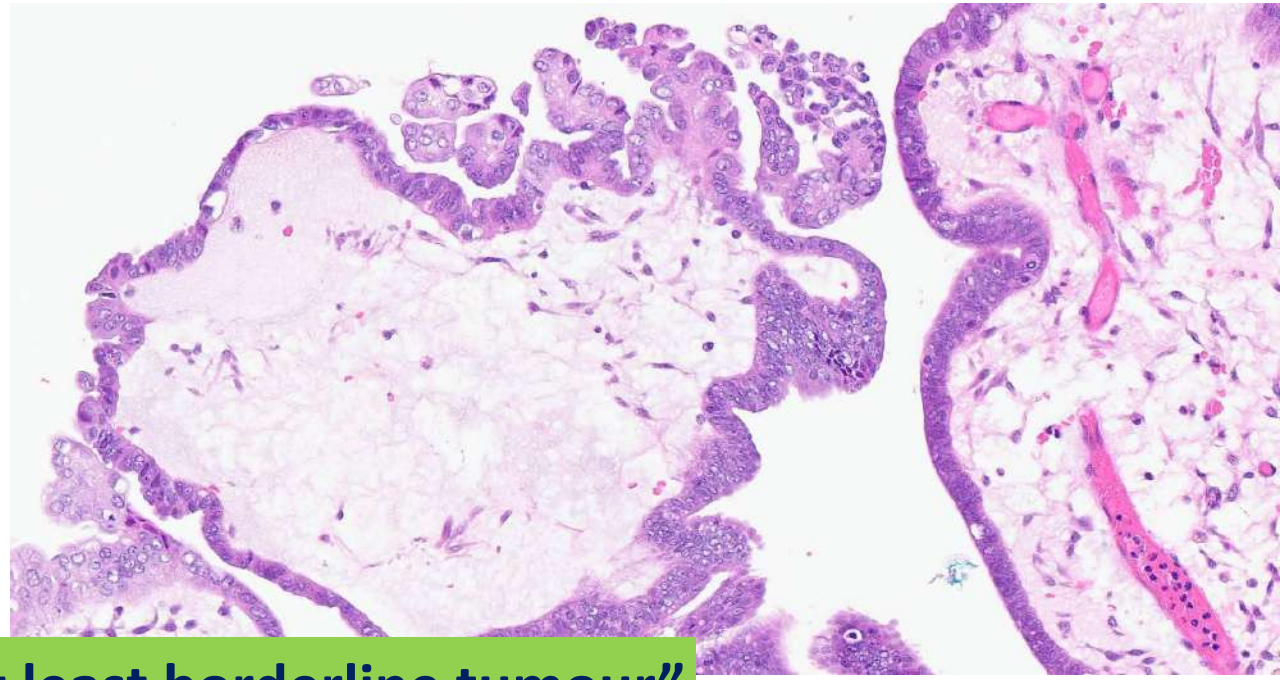

Frozen section reported as “At least borderline tumour”

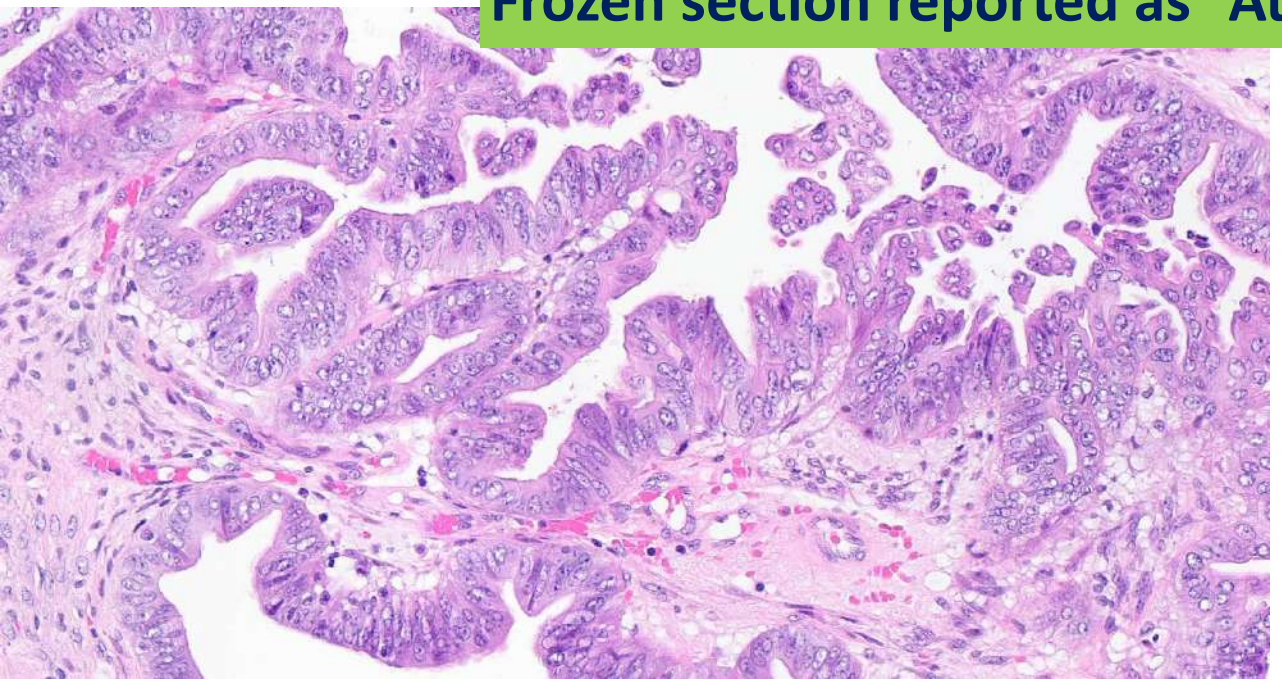

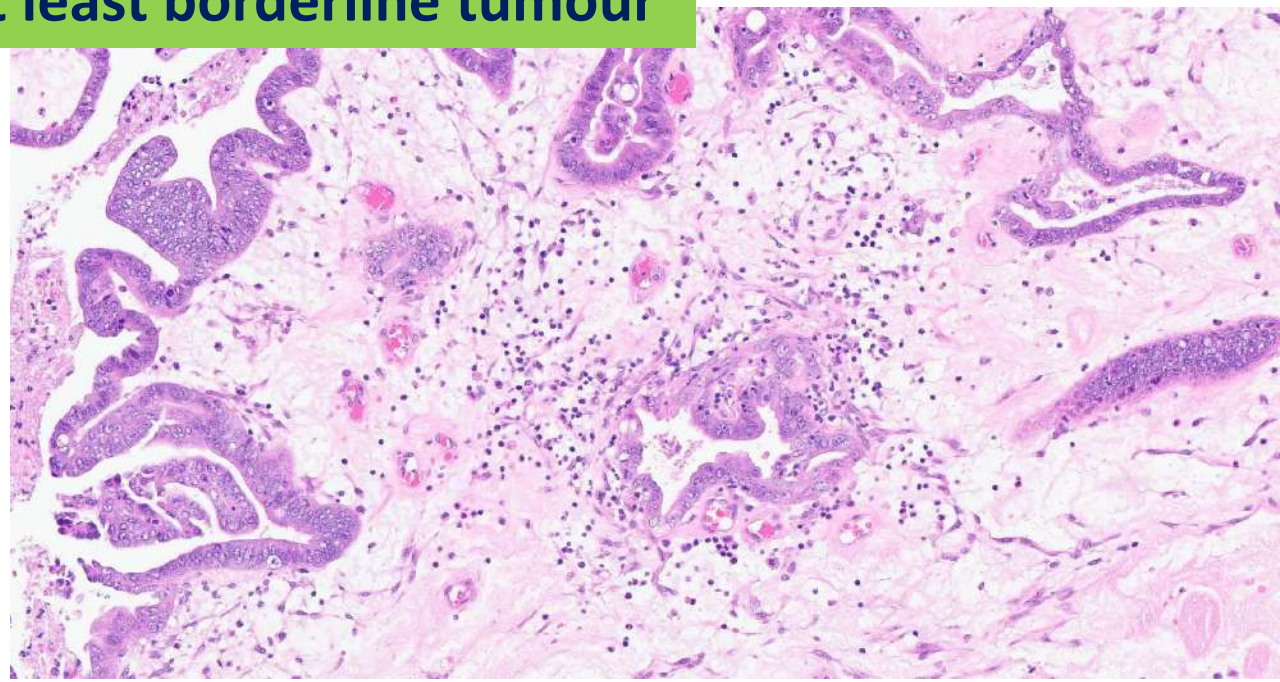

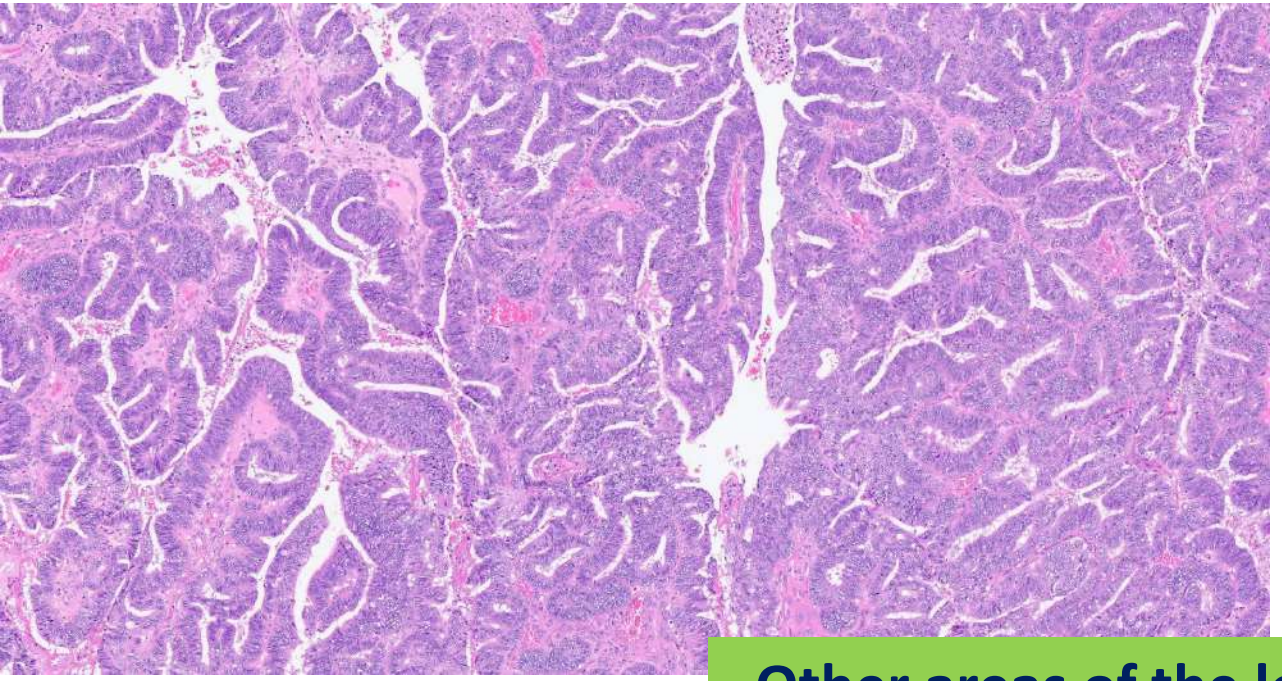

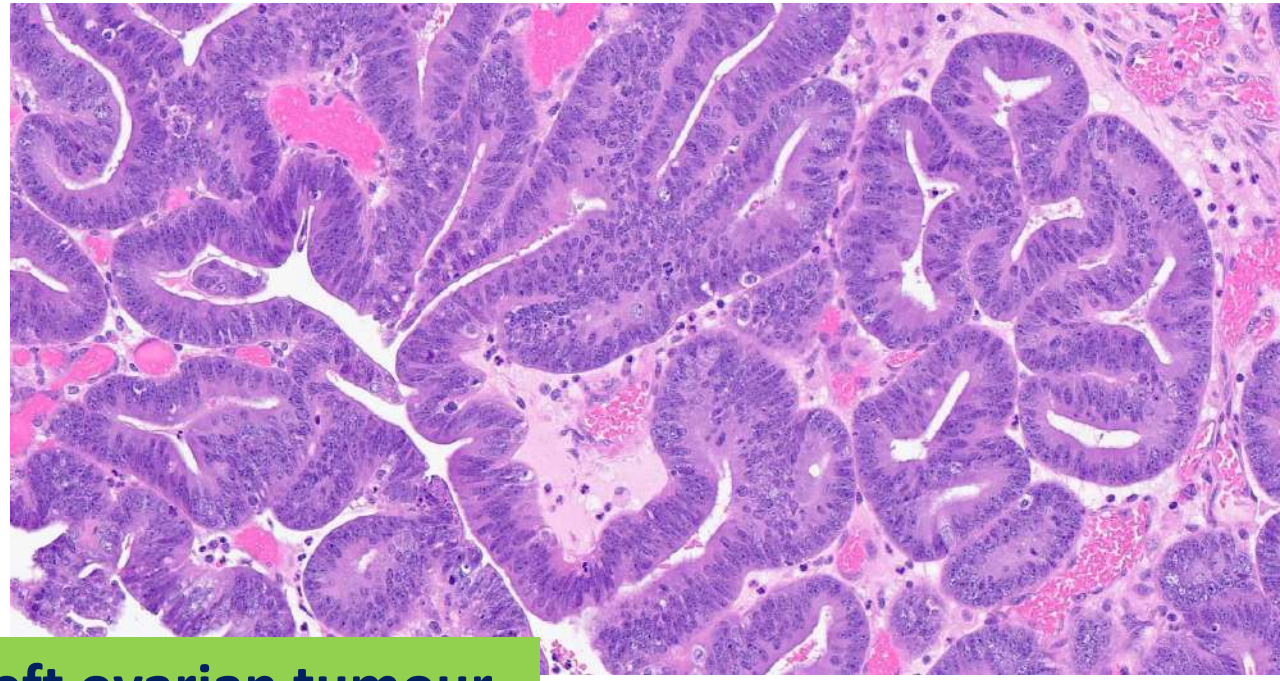

Other areas of the left ovarian tumour

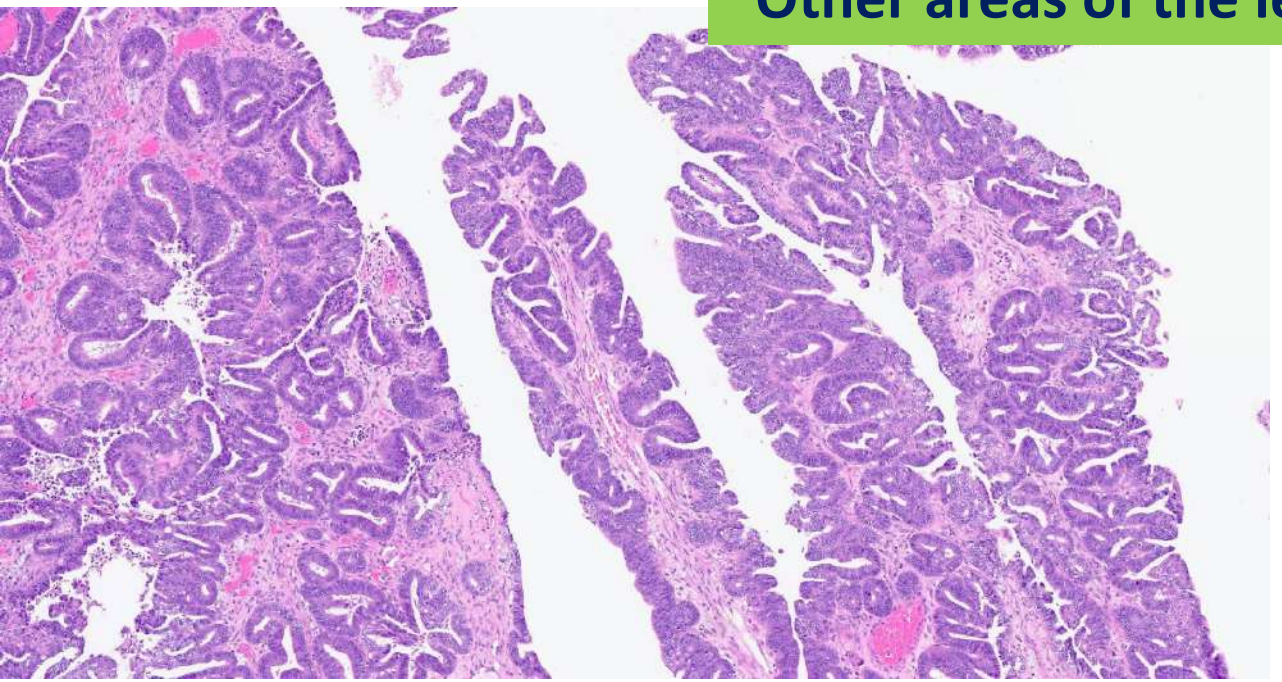

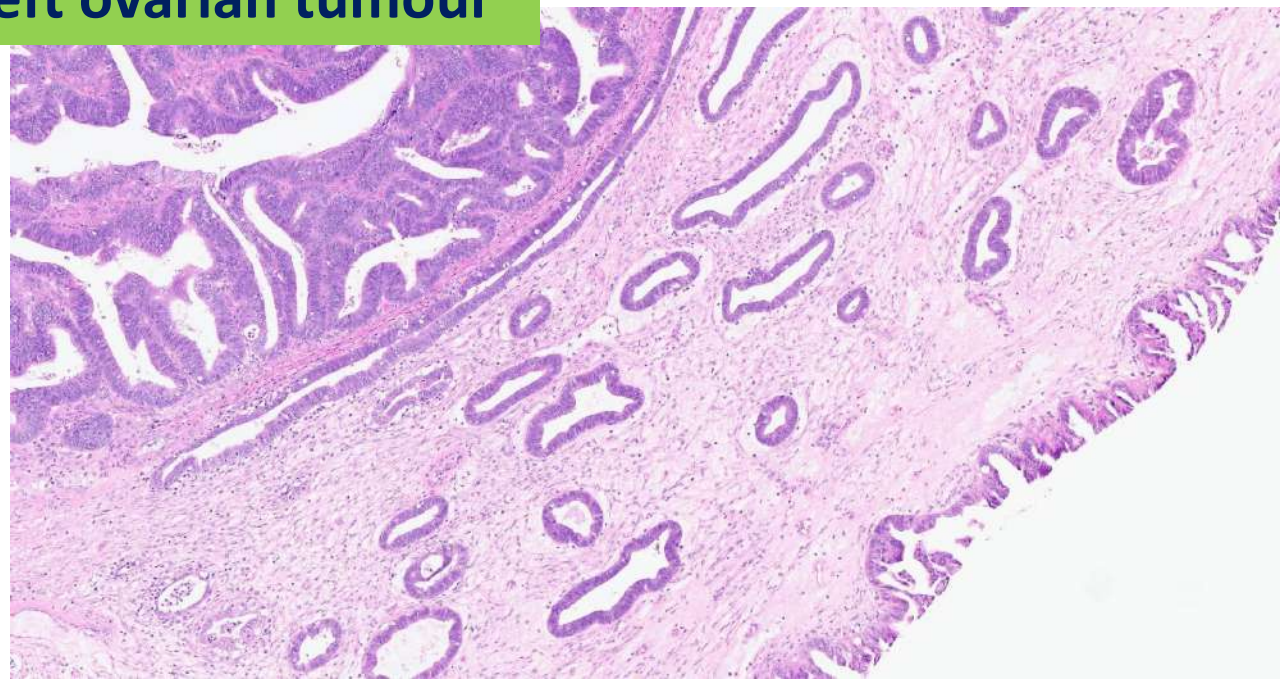

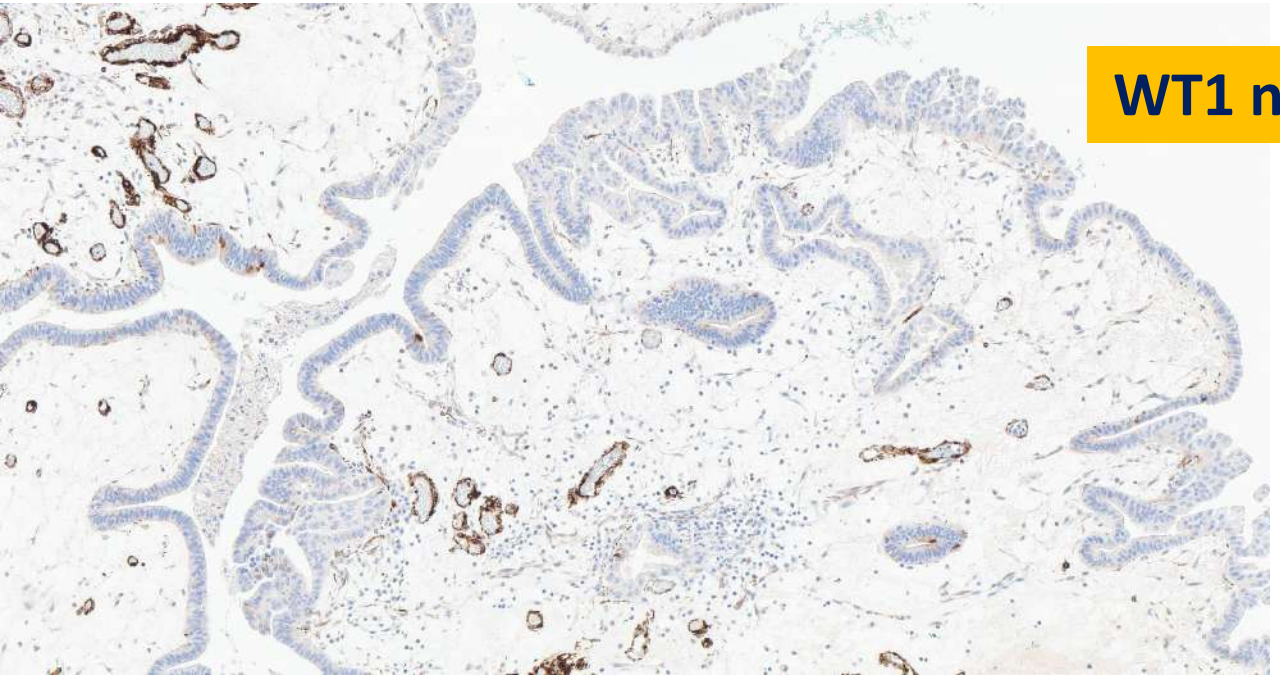

WT1 negative

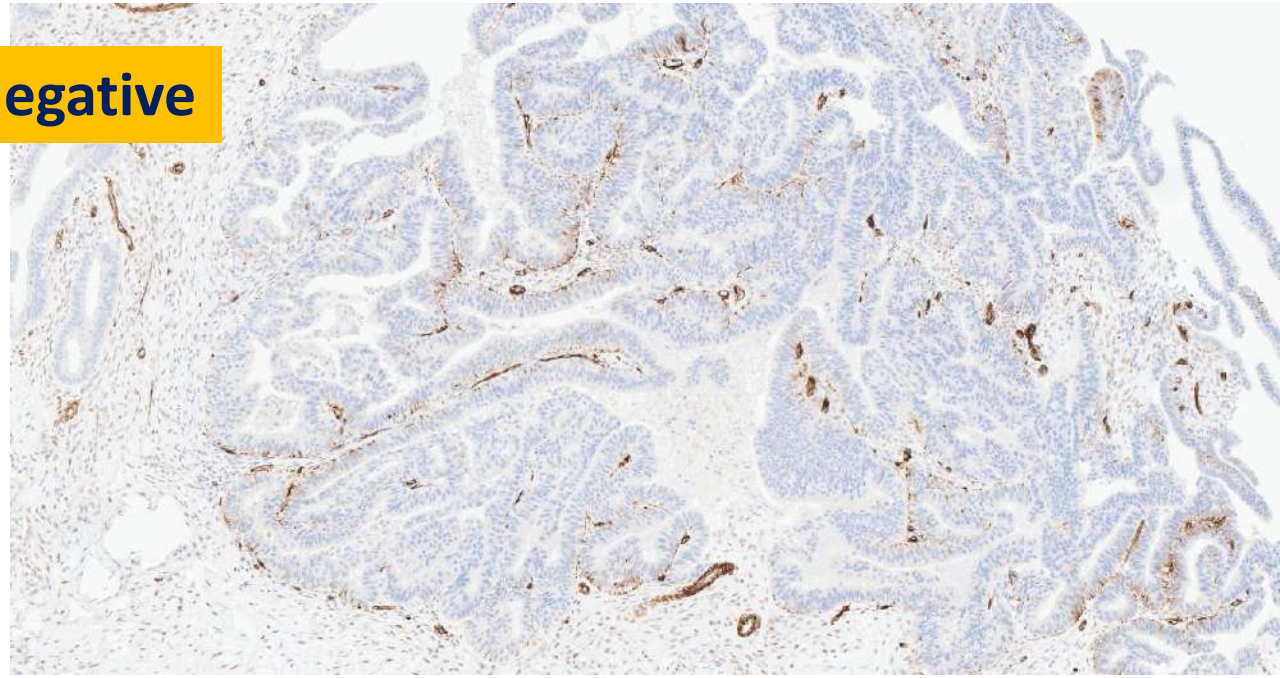

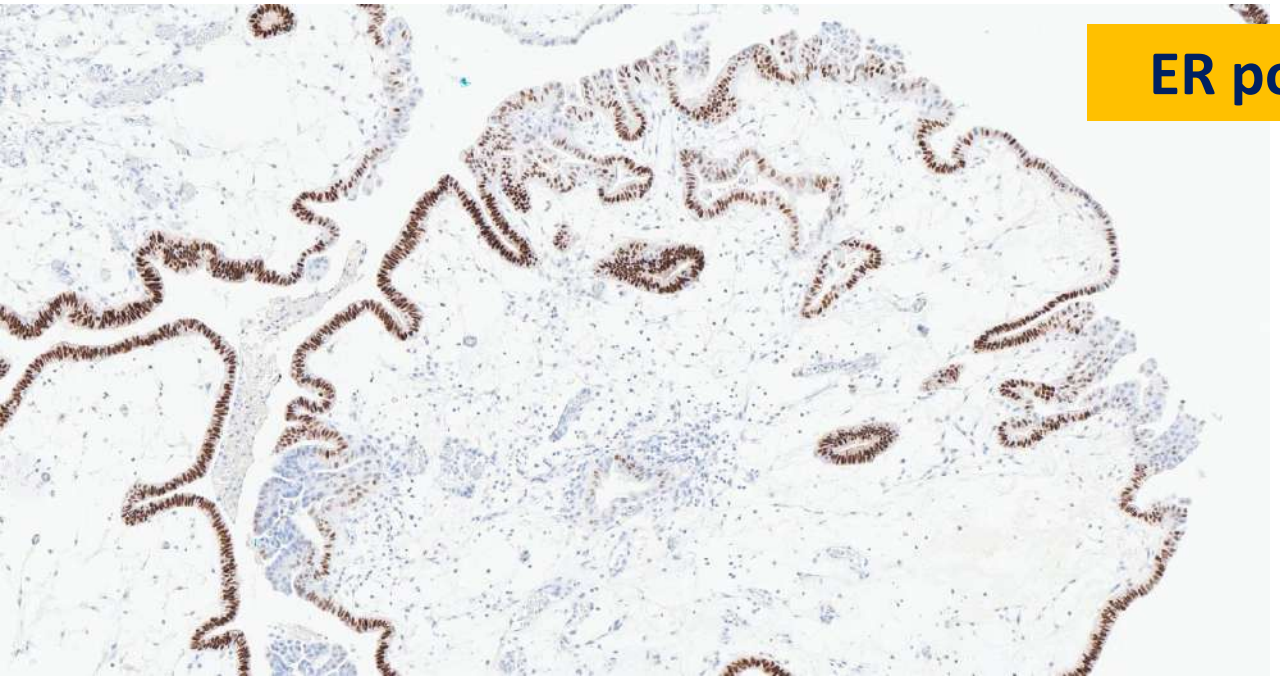

ER positive

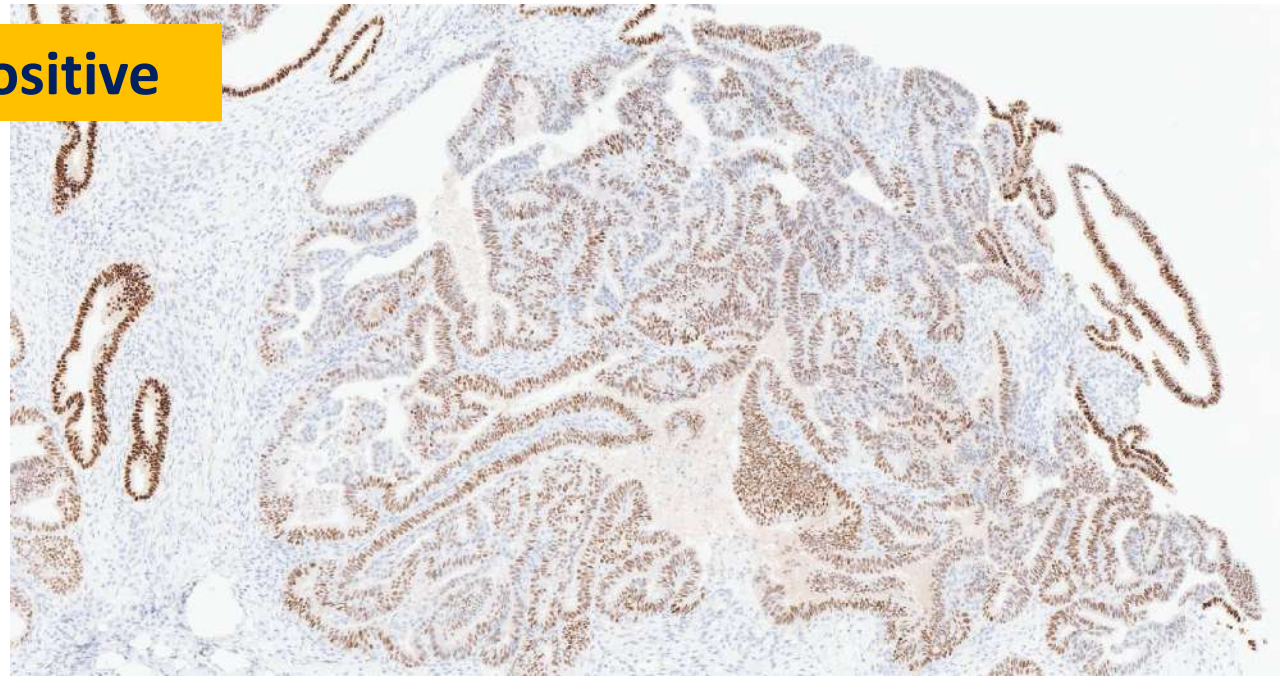

Ovarian endometrioid carcinoma resembling serous borderline tumour

- One of the morphological patterns that may be seen in ovarian endometrioid carcinomas
- Distinction from serous borderline tumour
  - Typical endometrioid morphology usually present but may be a minor component (sampling!)
  - Relatively monomorphic cell population
  - Squamous elements or cytoplasmic clearing
  - WT1 negative or focal



Original Article

Endometrioid Adenocarcinoma of the Ovary Mimicking Serous Borderline Tumor: Report of a Series of Cases

Sorsiah Mansor, F.R.C.Path and W. Glenn McCluggage, F.R.C.Path

Mansor S, McCluggage WG. Int J Gynecol Pathol. 2014;33:470-6.



The diverse morphology and immunophenotype of ovarian endometrioid carcinomas

Karen L. Talia[1], W. Glenn McCluggage[2]

Talia KL, McCluggage WG. Pathology. 2023;55:269-286.

Case 6

- 40 years old
- Right ovarian tumour

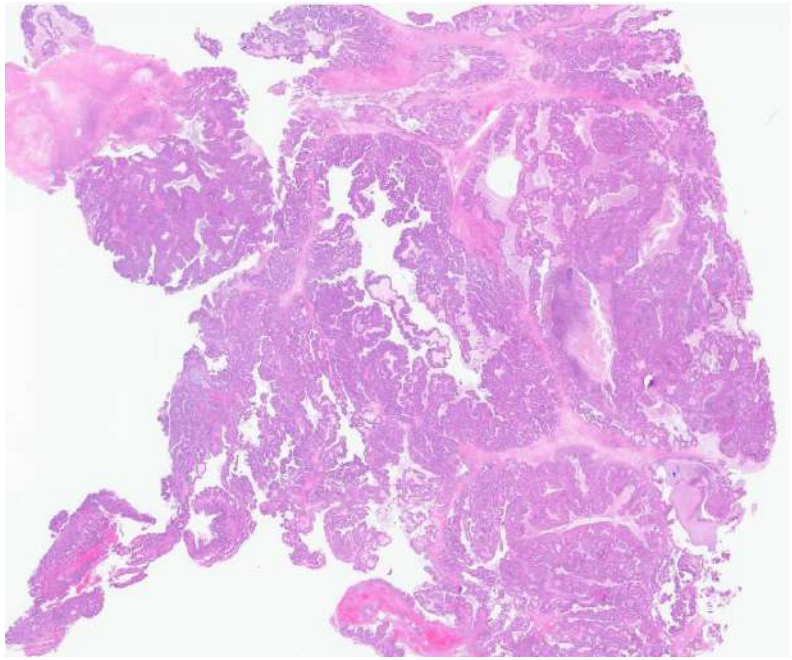

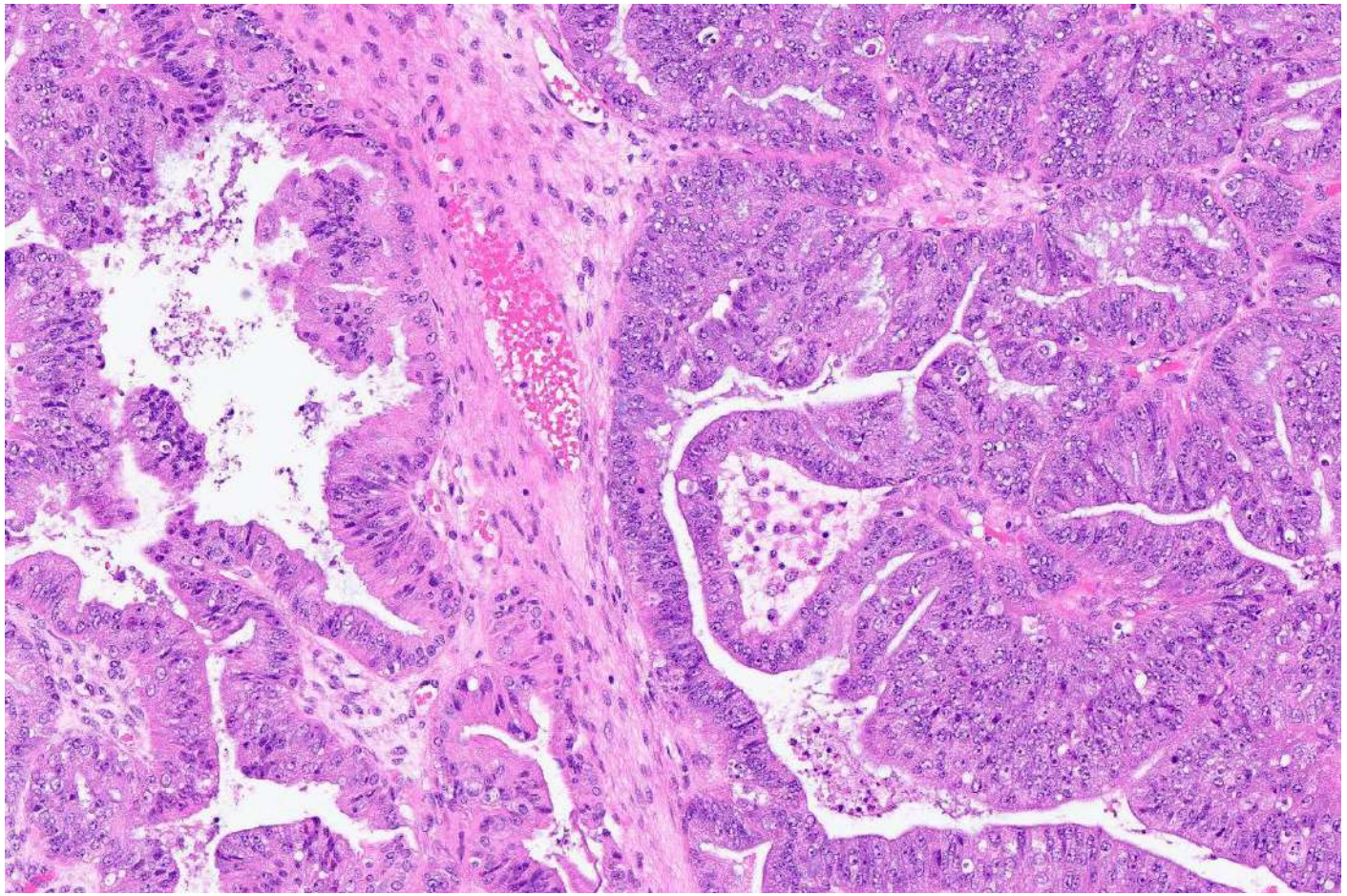

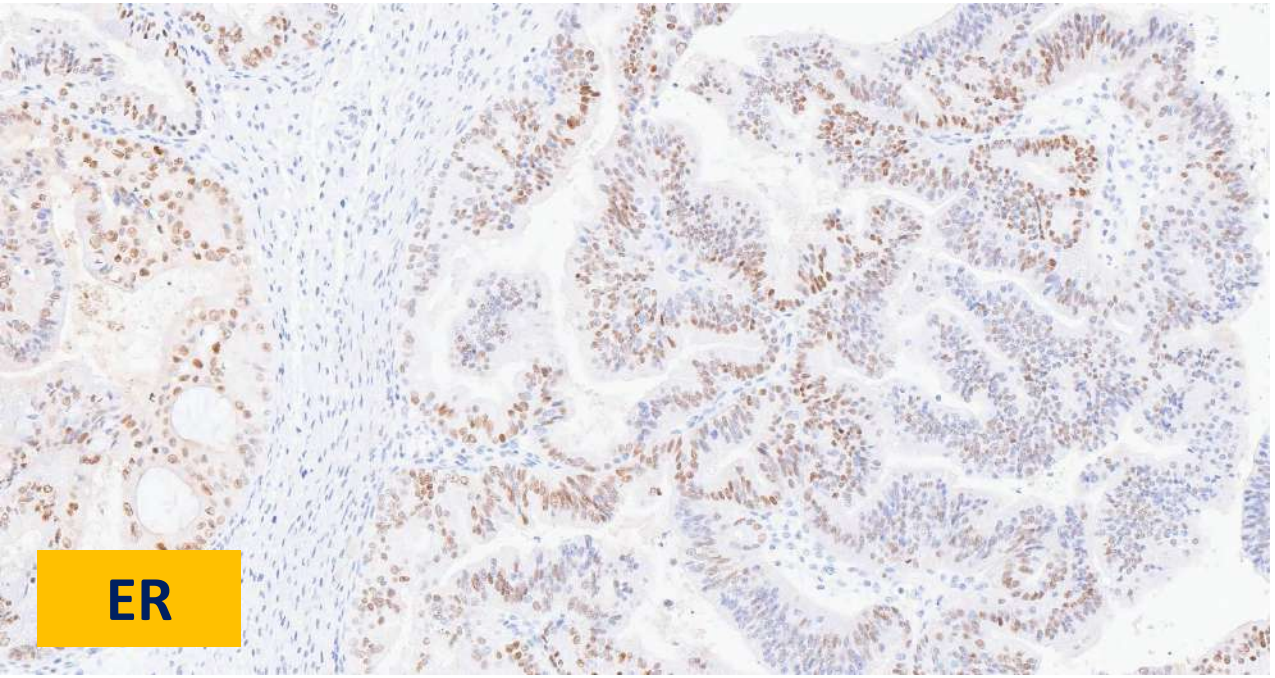
ER

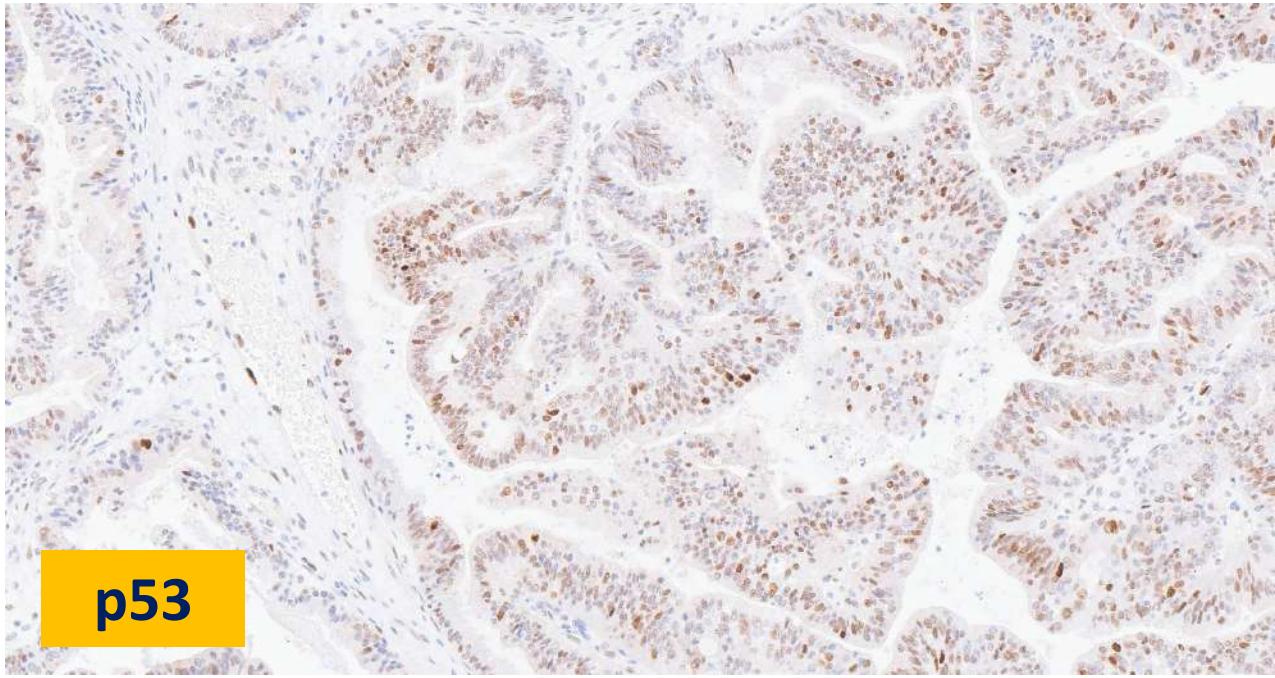
p53

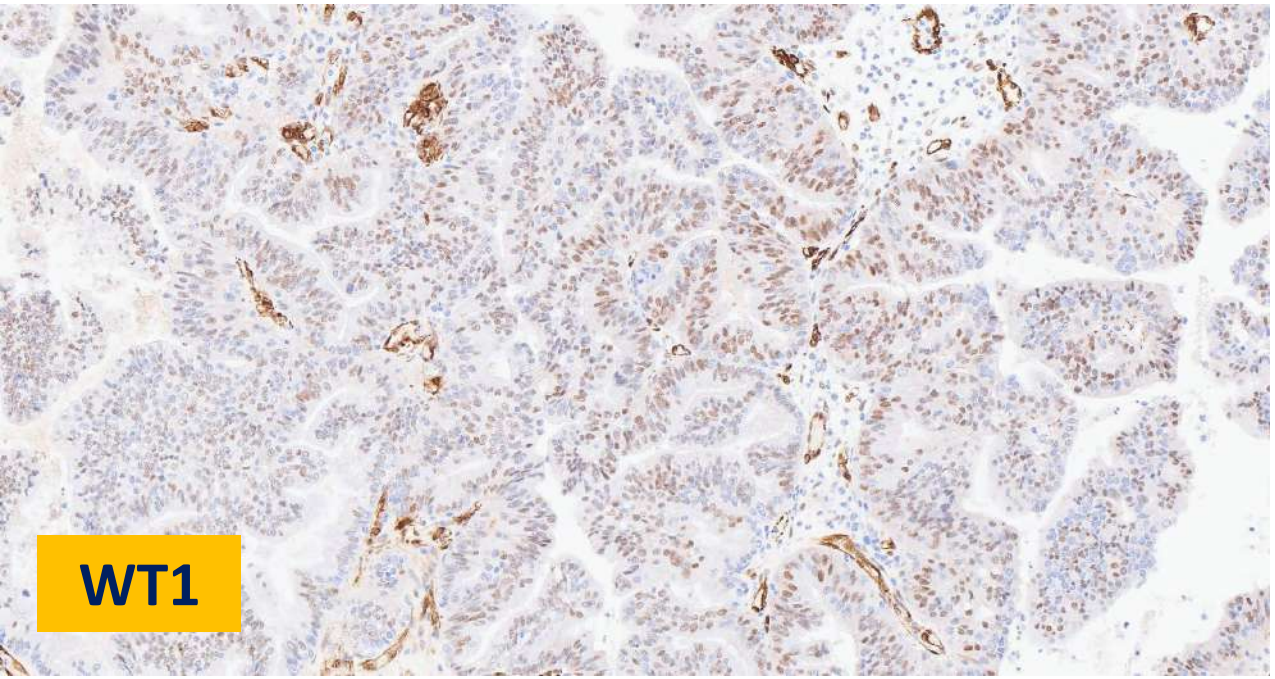
WT1

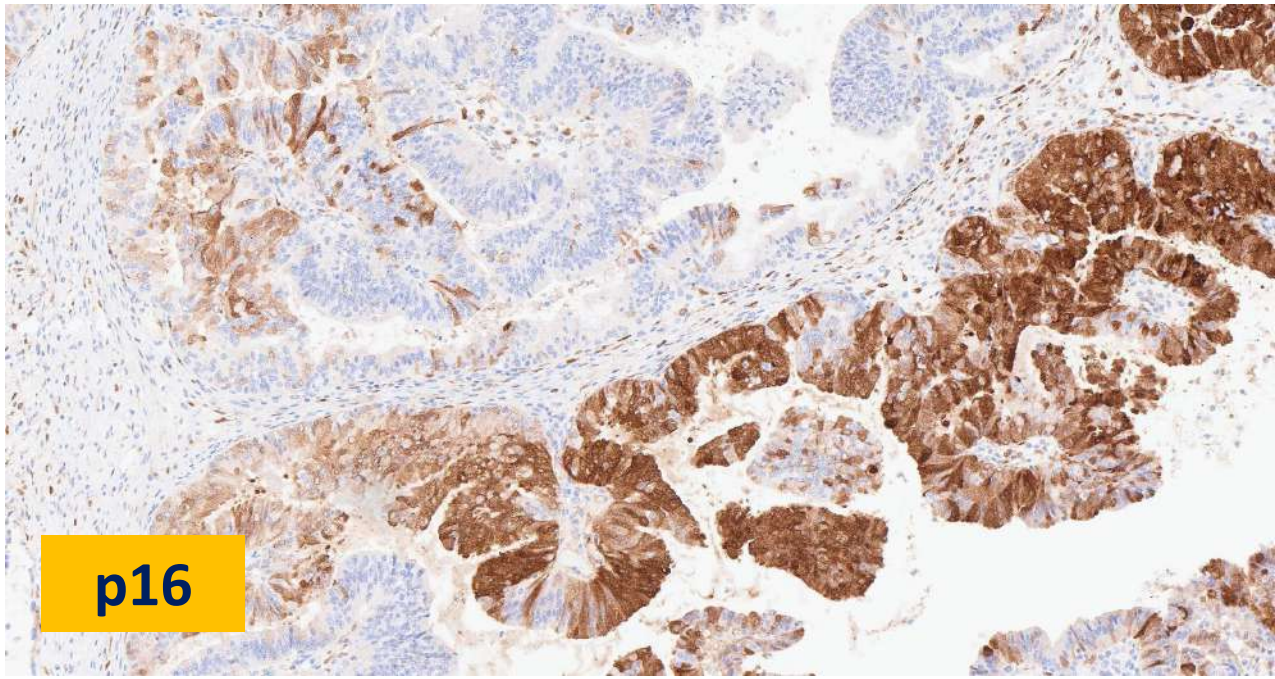
p16

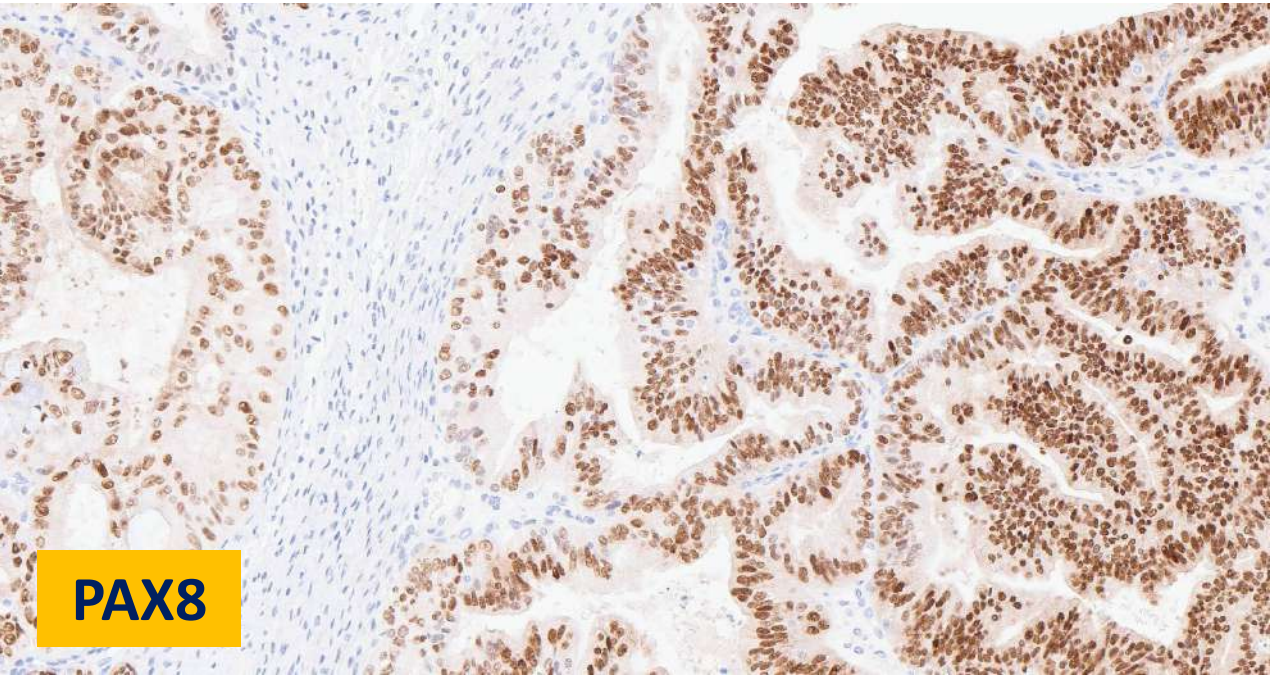
PAX8

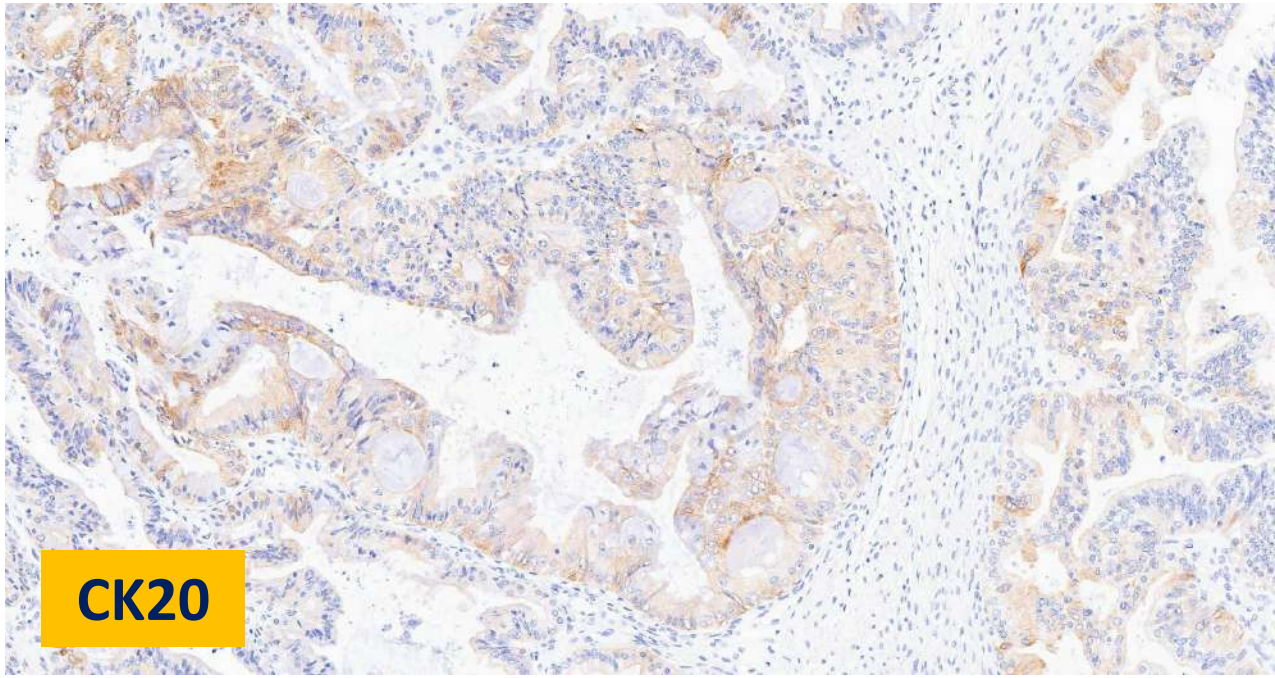
CK20

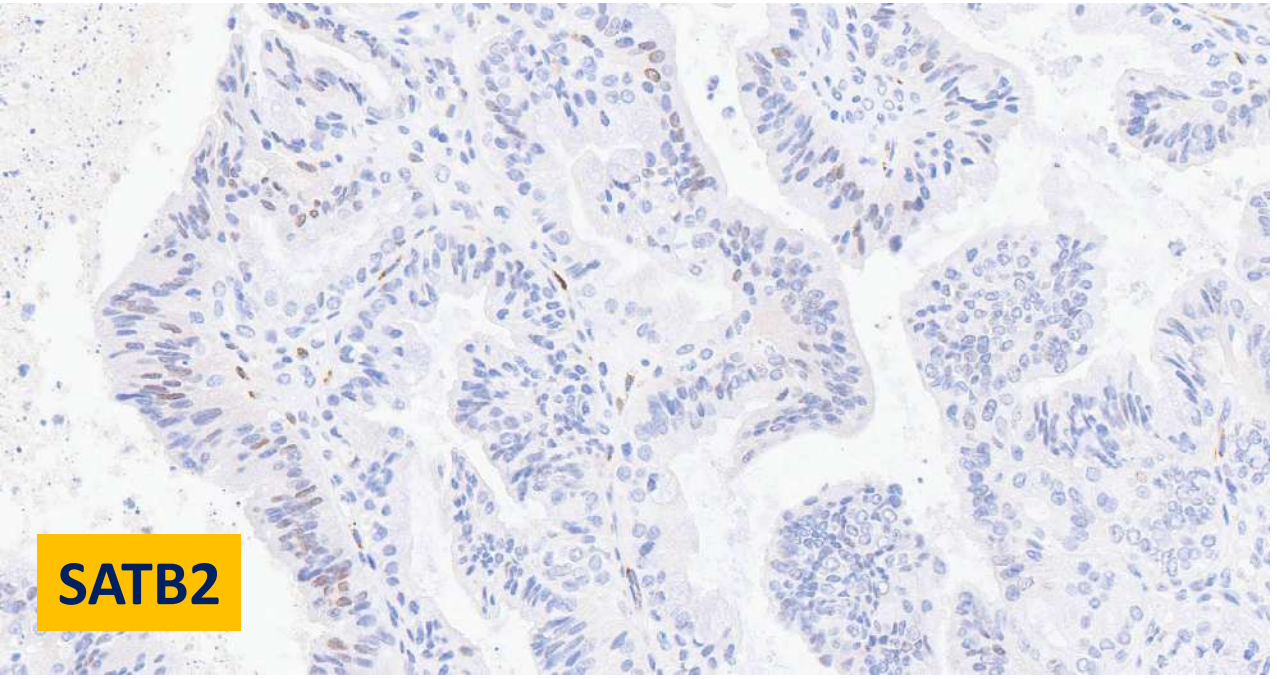
SATB2

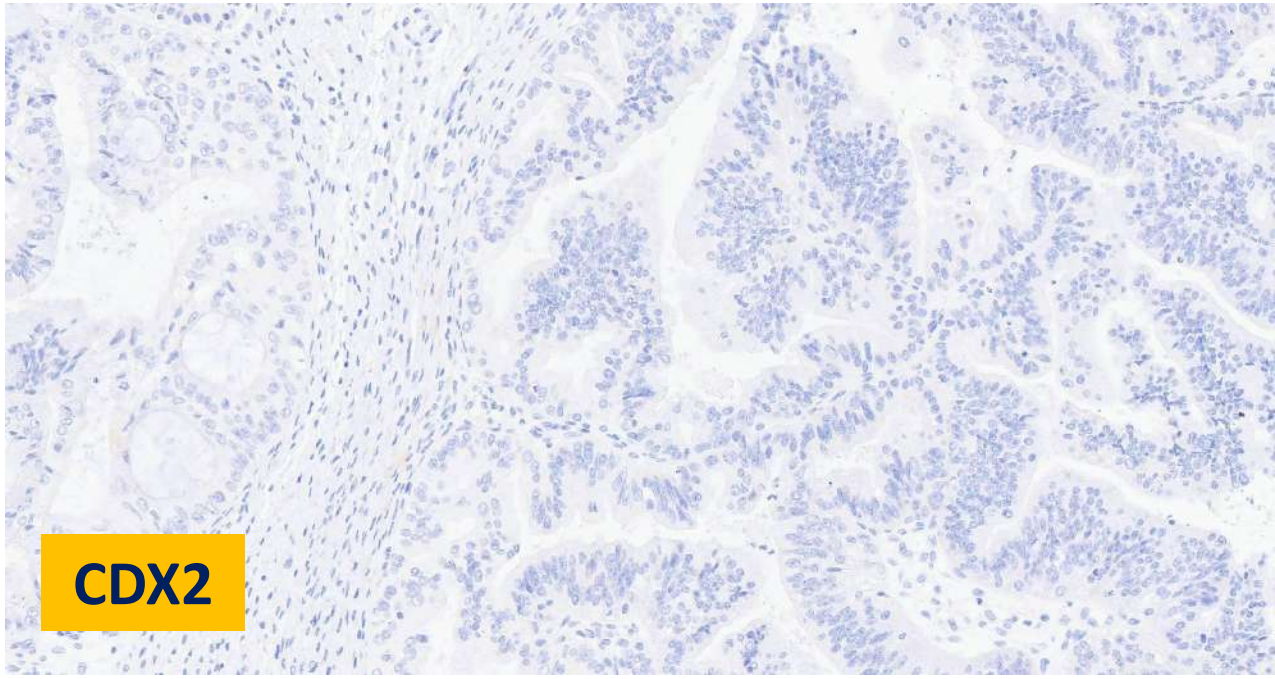
CDX2

Case 6 – Mixed histotypes?

- Adenocarcinoma with low grade endometrioid morphology
- ER focally positive
- p53 wild-type
- **WT1 focally positive**
- p16 patchy (non-block)
- PAX8 positive
- **CK20 focally positive**
- **SATB2 focally positive**
- CDX2 negative

- Could it be an ovarian carcinoma with endometrioid, serous and intestinal differentiation?

WT1 expression in ovarian endometrioid carcinomas

- WT1 expression present in about 10% of ovarian endometrioid carcinomas
  - Stewart et al. (2008): 9.8% (4/41)
  - Köbel et al. (2016): 10.1% (36/356)
- May be focal or diffuse
- May be seen in cases with or without endometriosis
- Endometrioid borderline tumours may also be WT1 positive
- Some cases may have concurrent positive WT1 and abnormal p53 expression
  - 3.3% of ovarian endometrioid carcinomas based on Köbel et al. 2019



WT1 expression in endometrioid ovarian carcinoma with and without associated endometriosis

C. J. R. Stewart*, B. A. Brennan*, T. Chan* and J. Netreba†

Stewart CJ, Brennan BA, Chan T, et al. Pathology. 2008;40:592-9.

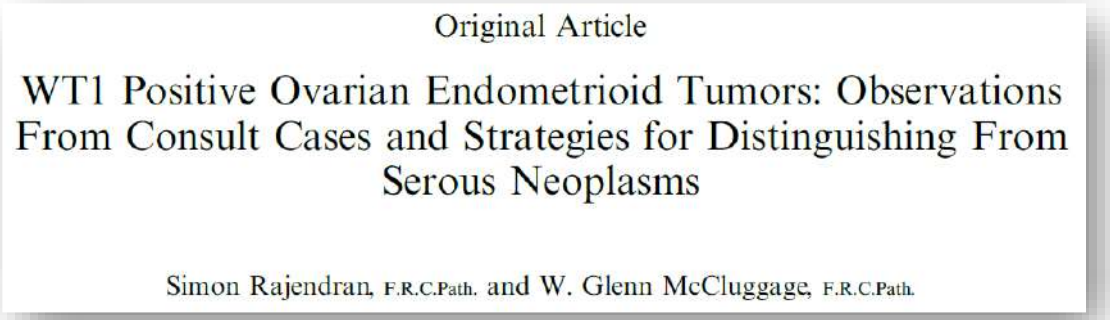

Original Article

WT1 Positive Ovarian Endometrioid Tumors: Observations From Consult Cases and Strategies for Distinguishing From Serous Neoplasms

Simon Rajendran, F.R.C.Path. and W. Glenn McCluggage, F.R.C.Path.

Rajendran S, McCluggage WG. Int J Gynecol Pathol. 2022;41:191-202.

Köbel M, Rahimi K, Rambau PF, et al. Int J Gynecol Pathol 2016;35:430-41.
Köbel M, Luo L, Grevers X, et al. Int J Gynecol Pathol 2019;38:353-362.

“Aberrant” IHC profiles in ovarian endometrioid carcinomas

- Ovarian endometrioid carcinomas may show a wider range of immunophenotypes than other types of ovarian carcinomas
- CK7, PAX8, CA125, ER and PR may be occasionally negative for individual cases

- Markers that may be positive in ovarian endometrioid carcinomas:
  - WT1
  - CK20
  - CDX2
  - SATB2
    - Le Page et al. (2019): 23.8%
  - TTF1
  - Napsin A
    - Köbel et al. (2016): 8.2%

Talia KL, McCluggage WG. Pathology. 2023;55:269-286.
Rajendran S, McCluggage WG. Int J Gynecol Pathol. 2022;41:191-202.

Köbel M, Rahimi K, Rambau PF, et al. Int J Gynecol Pathol 2016;35:430-41.
Le Page C, Köbel M, Meunier L, et al. J Pathol Clin Res. 2019;5:177-188.

Case 6 – Endometrioid carcinoma

- Adenocarcinoma with low grade endometrioid morphology
- ER focally positive
- p53 wild-type
- WT1 focally positive
- p16 patchy (non-block)
- PAX8 positive
- CK20 focally positive
- SATB2 focally positive
- CDX2 negative

- Morphology first – assess whether the tumour has typical endometrioid features
- Look at the entire IHC panel instead of focusing on single markers

Case 7

- 68 years old
- History of endometriosis with total hysterectomy and bilateral salpingo-oophorectomy
- Recent colonoscopy found rectal lesion with biopsy reported as “high grade dysplasia
- Pelvic tumour biopsy

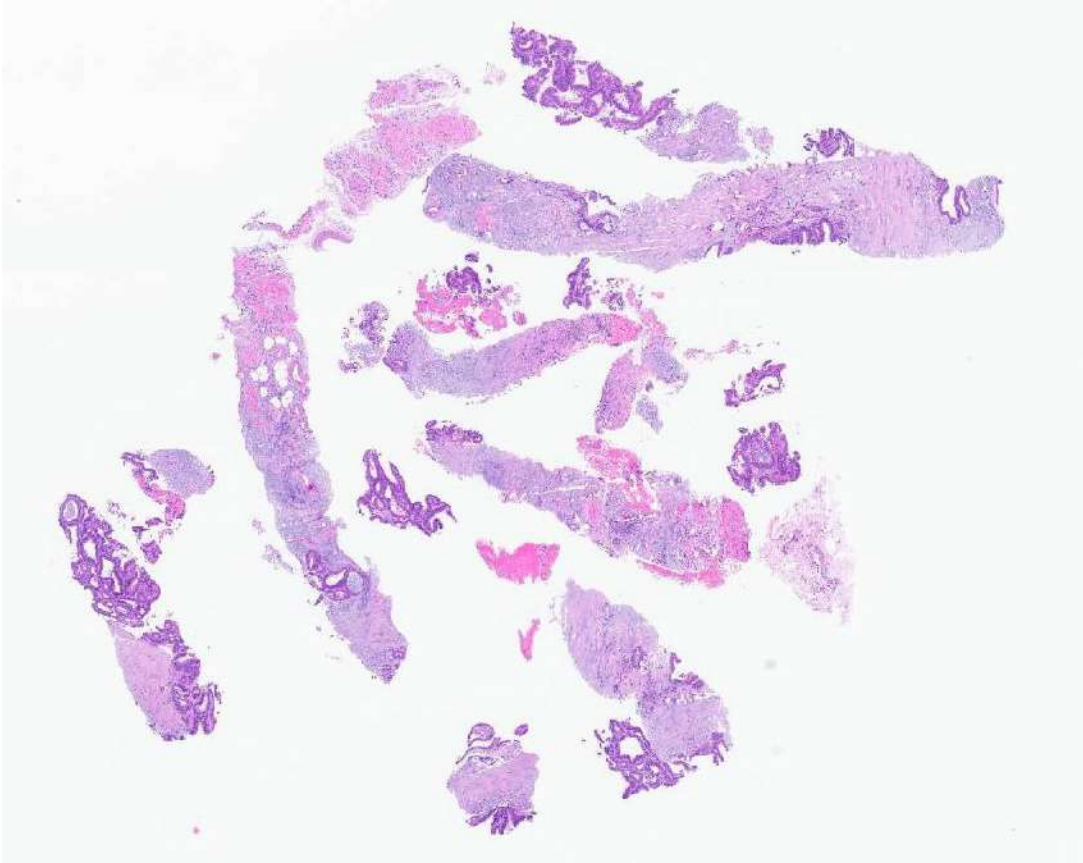

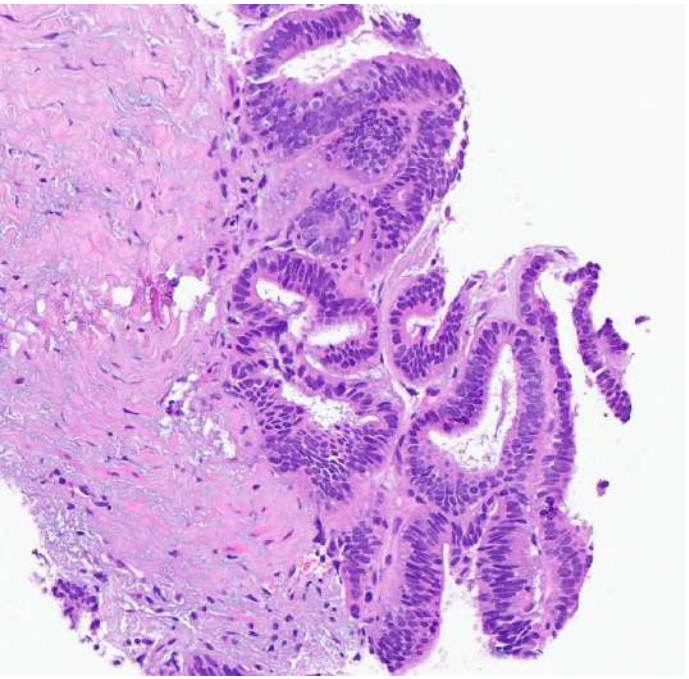
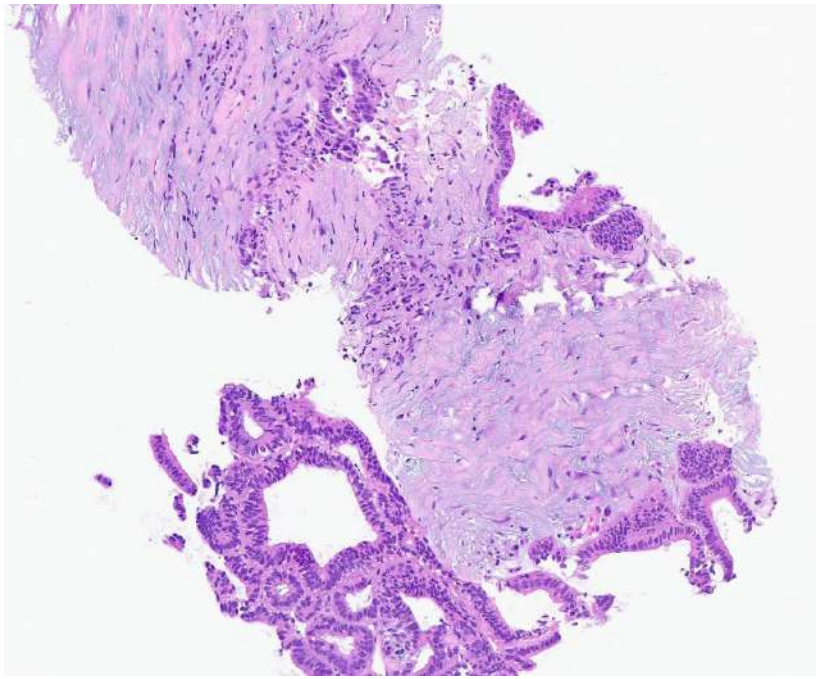
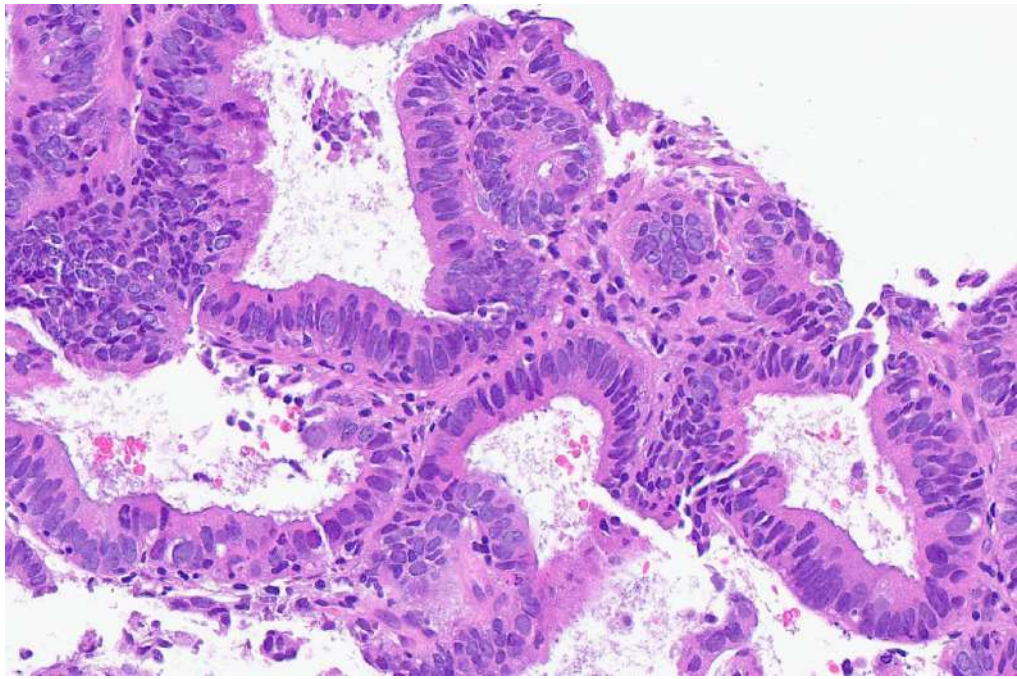
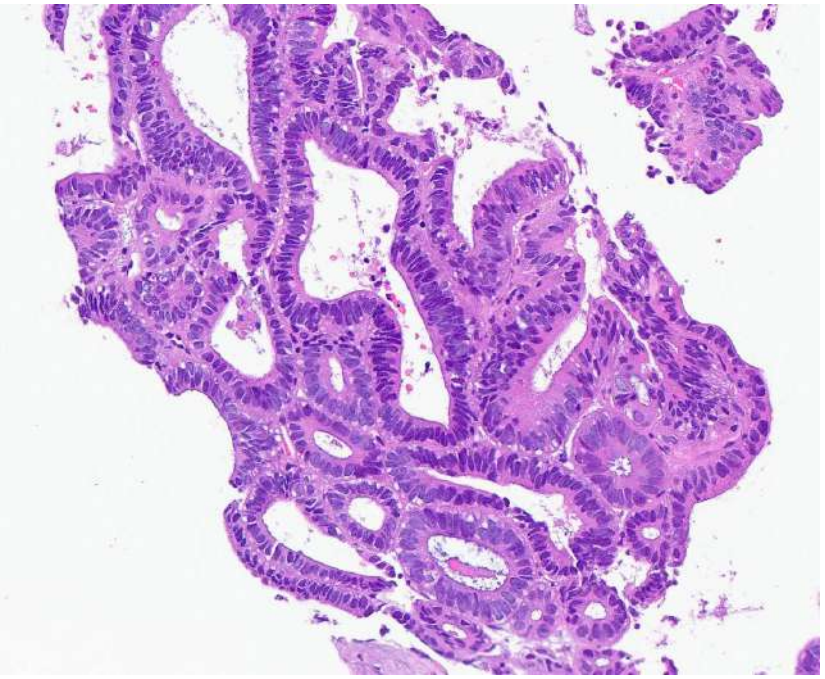
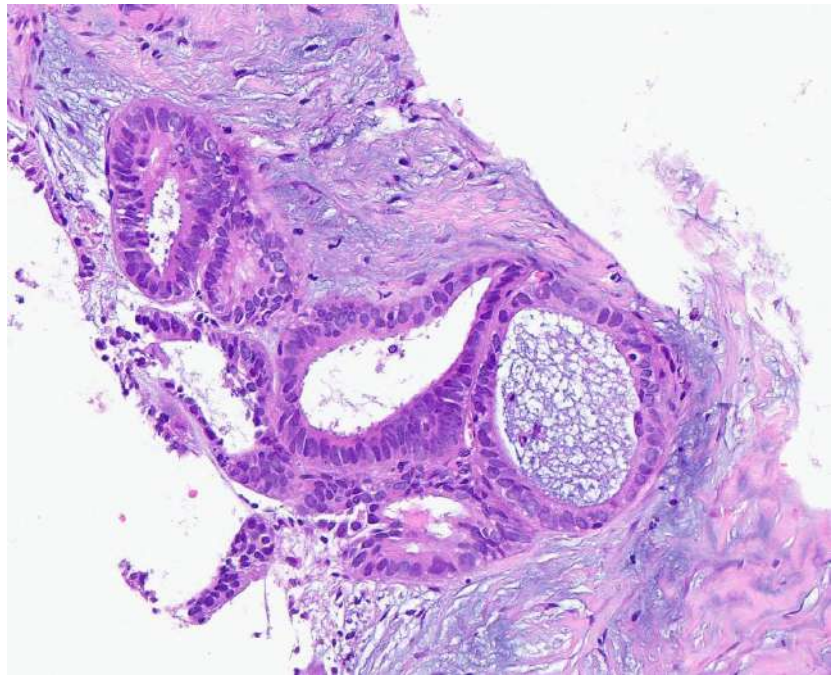

Pelvic tumour biopsy

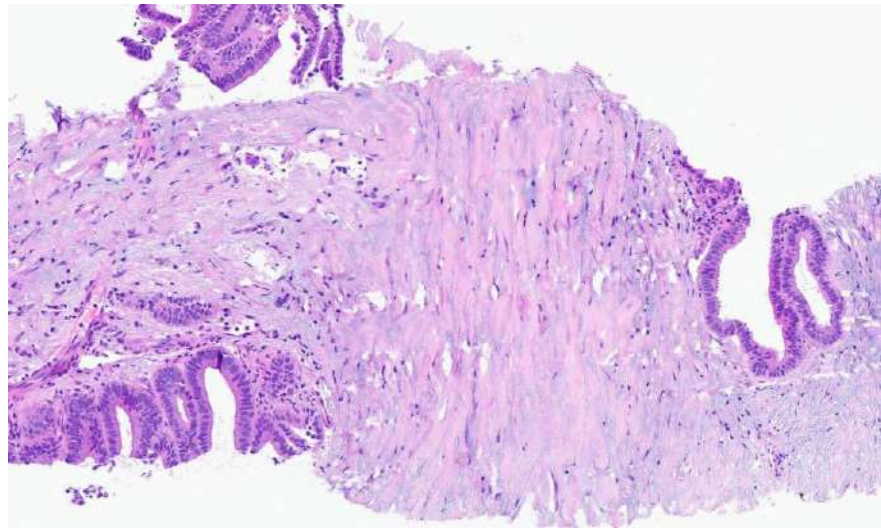

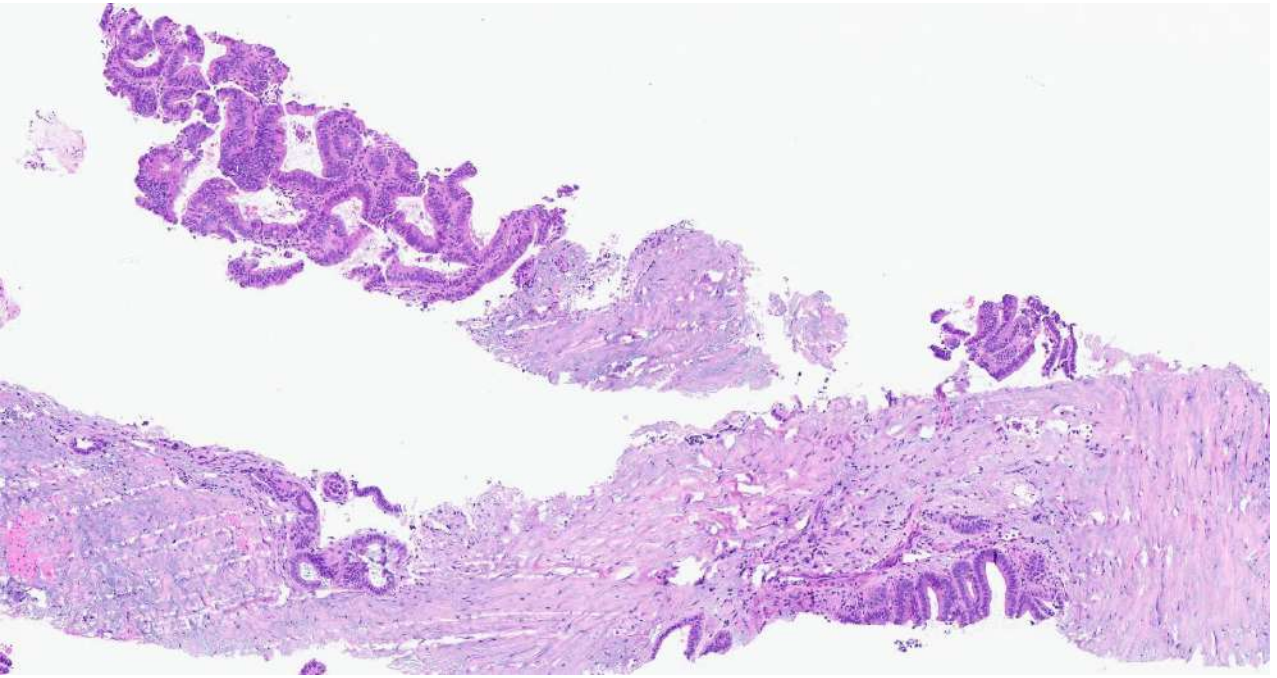

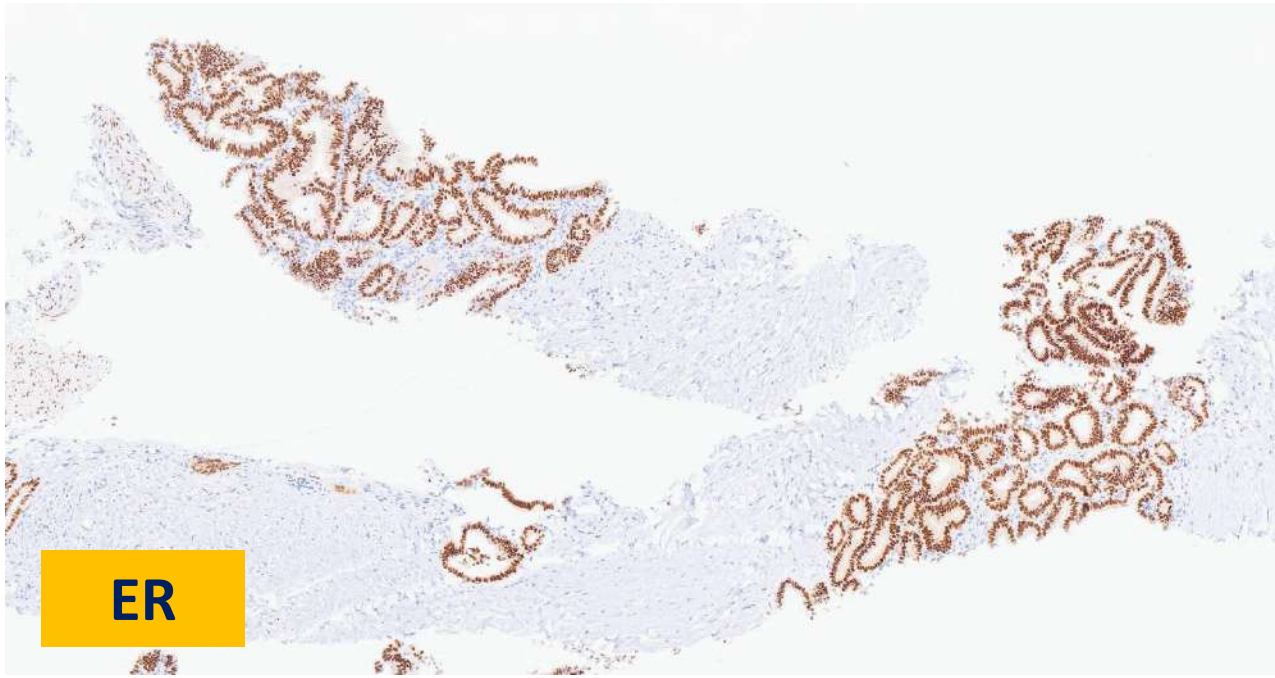
ER

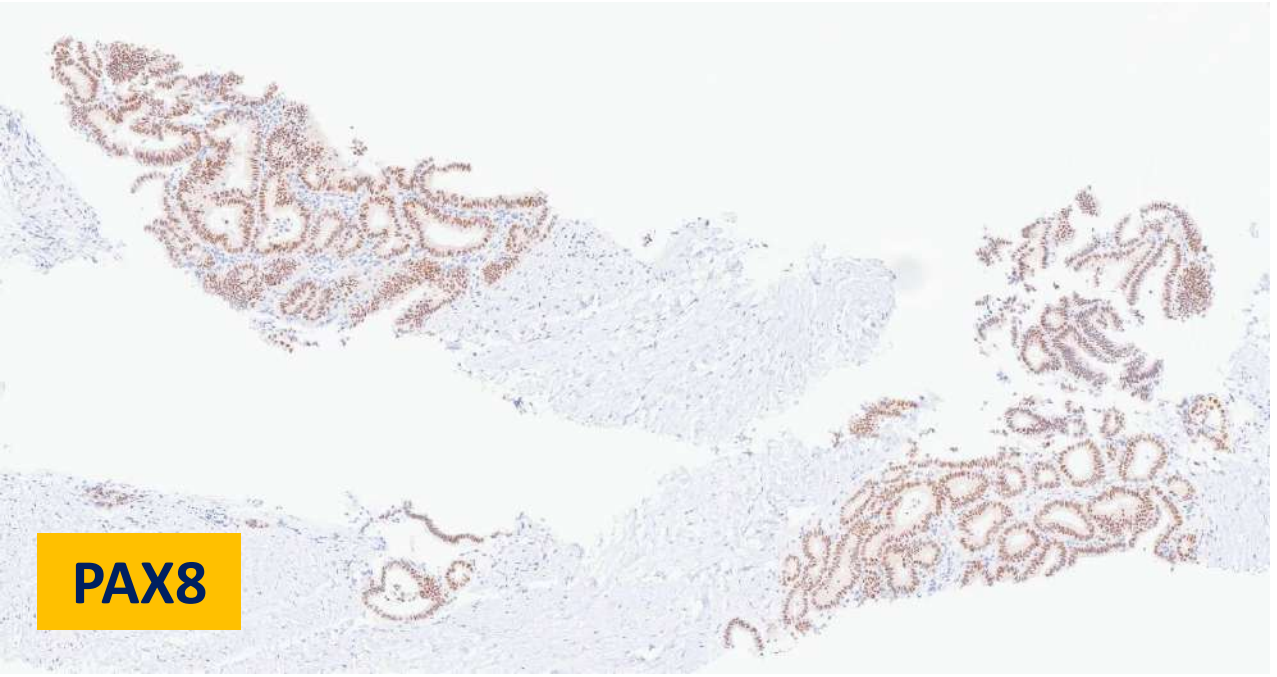
PAX8

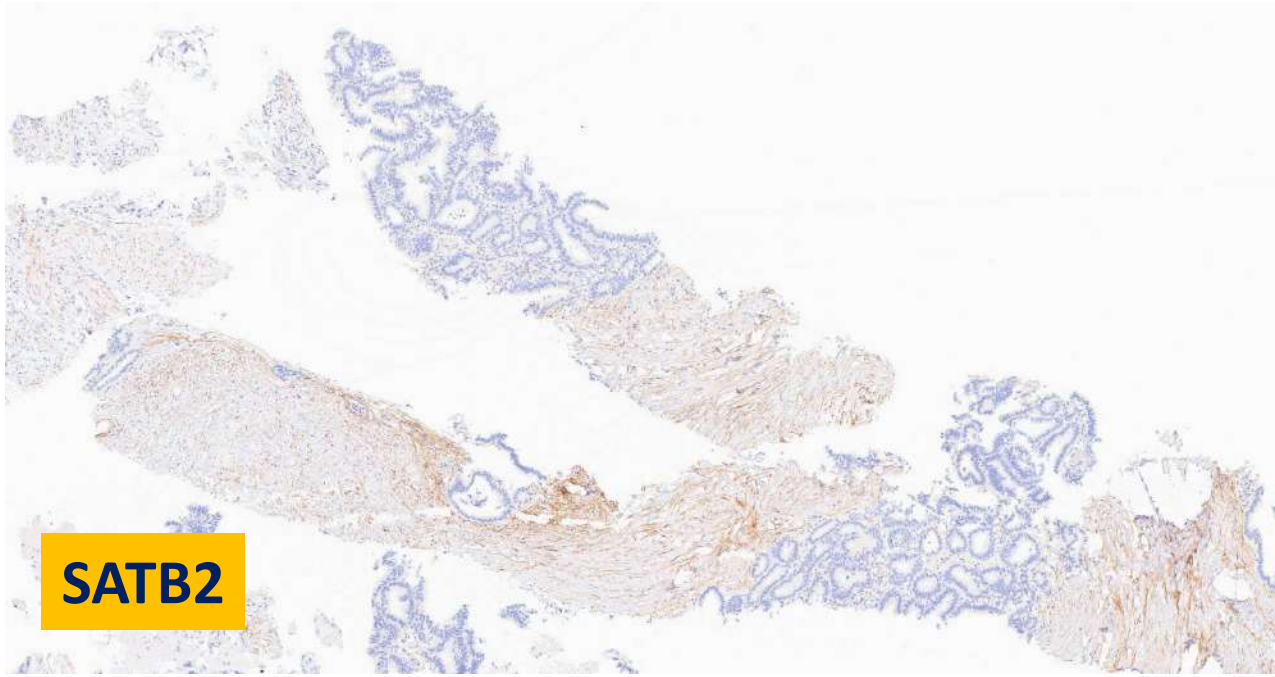
SATB2

Case 7

- Pelvic tumour biopsy reported as adenocarcinoma, favour endometrioid type
  - ER and PAX8 positive
  - SATB2 negative
- Question was raised at tumour board about the rectal high grade dysplasia as the pelvic mass is close to the rectal lesion on imaging
- Rectal biopsy was reviewed

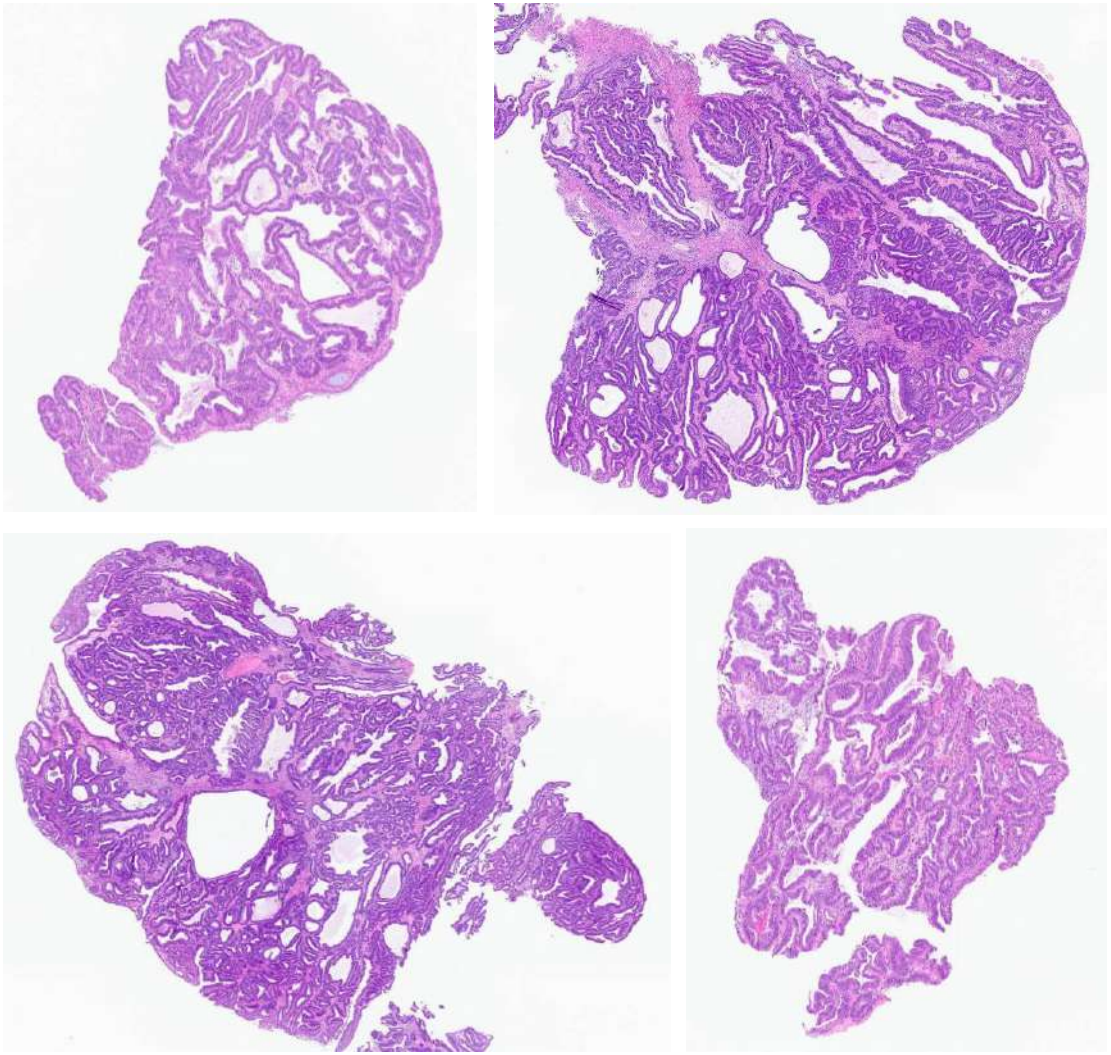

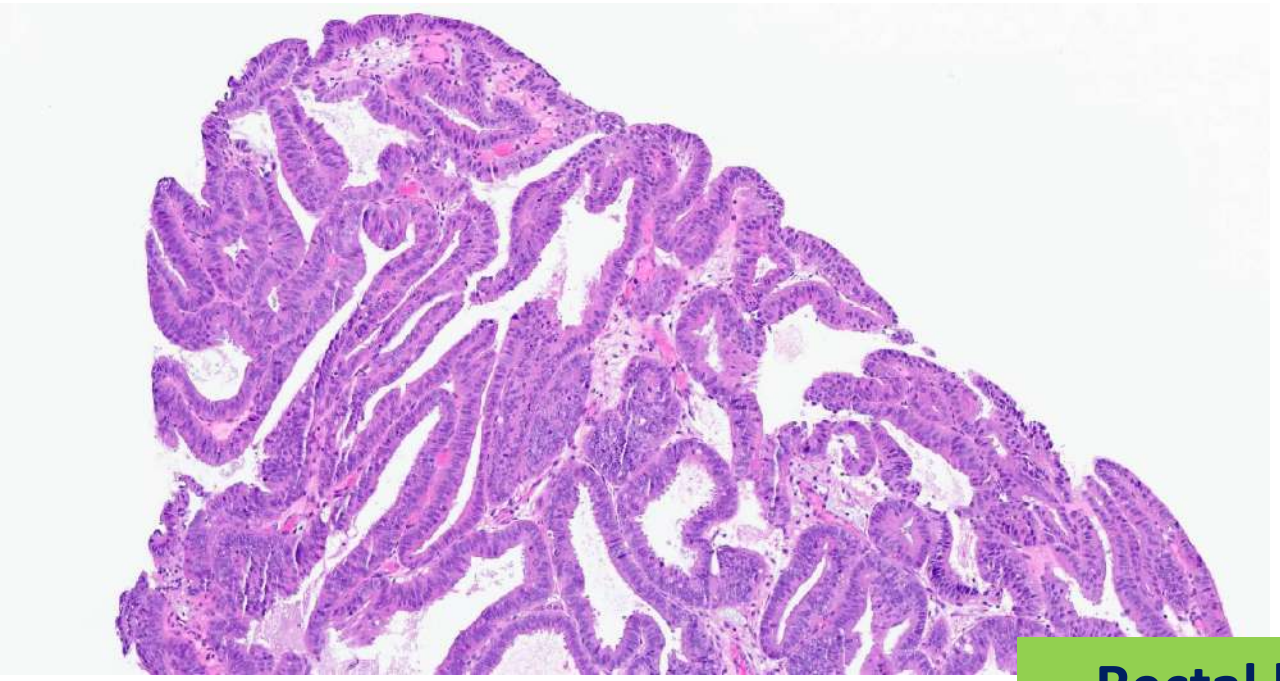

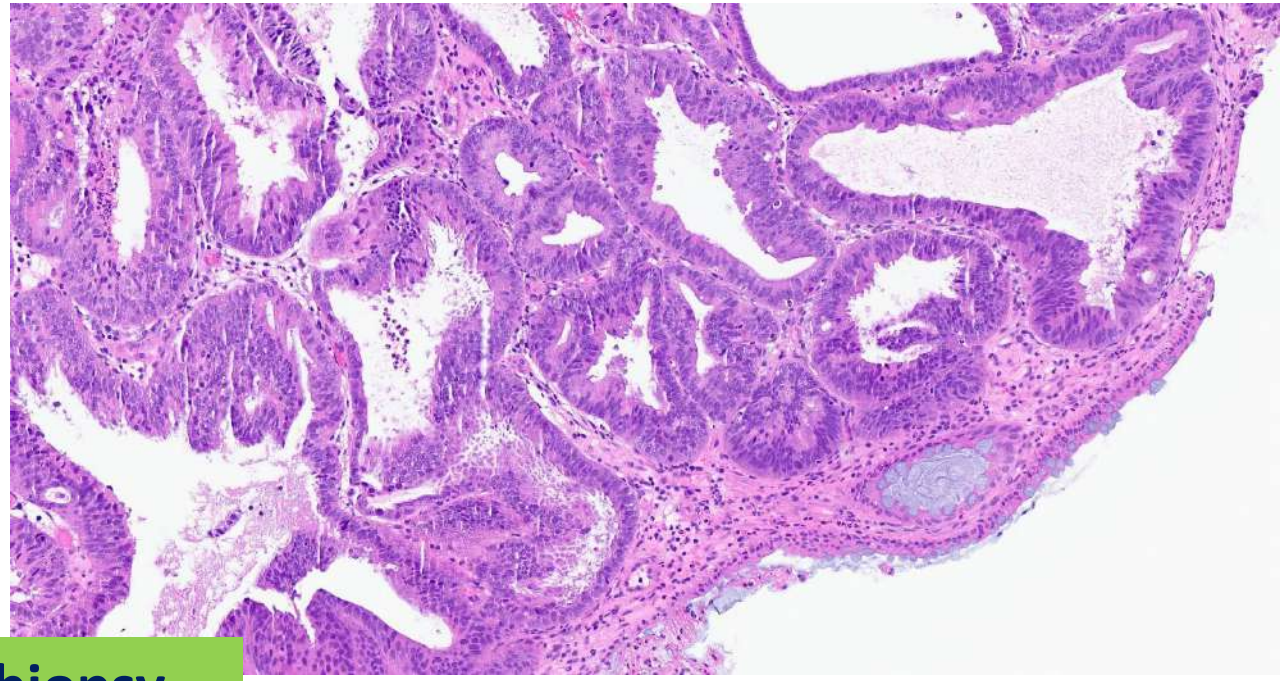

Rectal biopsy

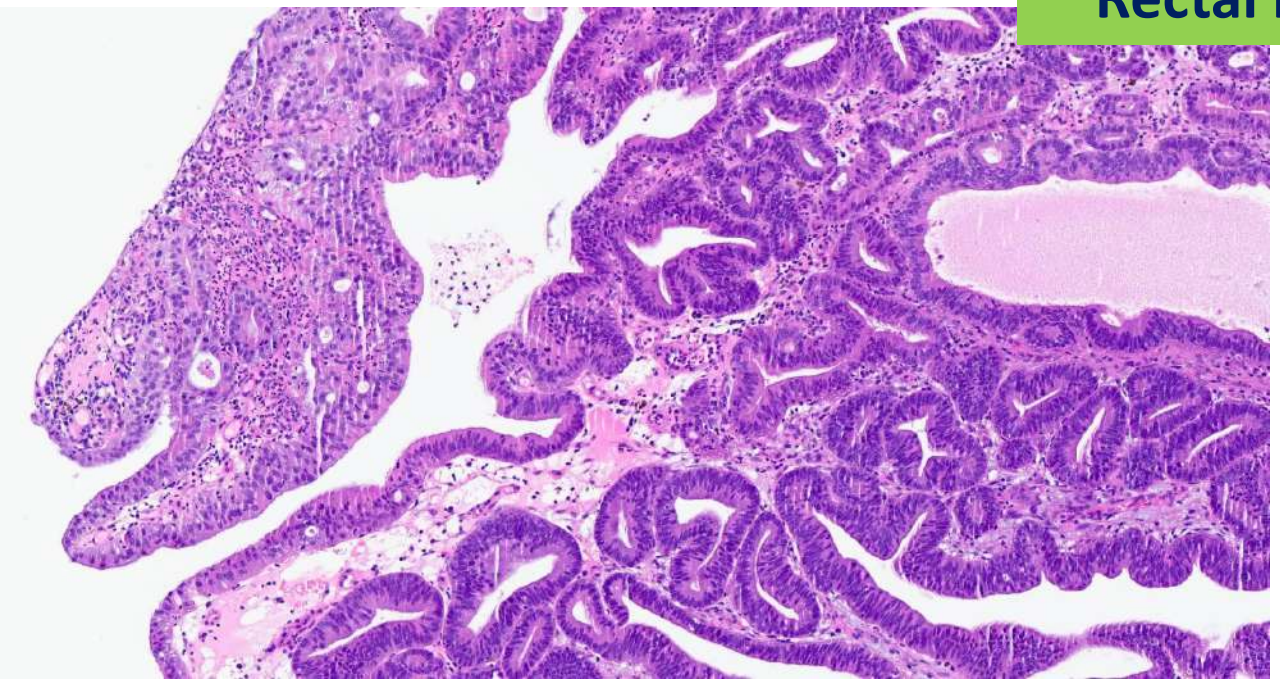

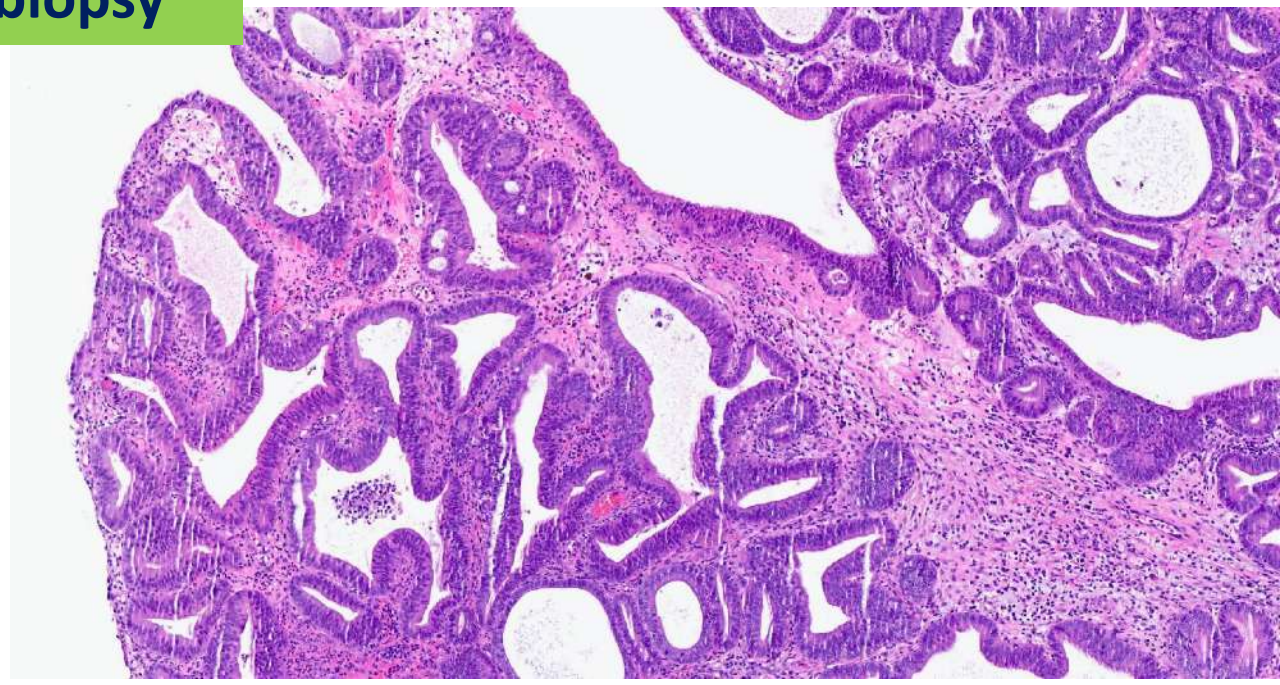

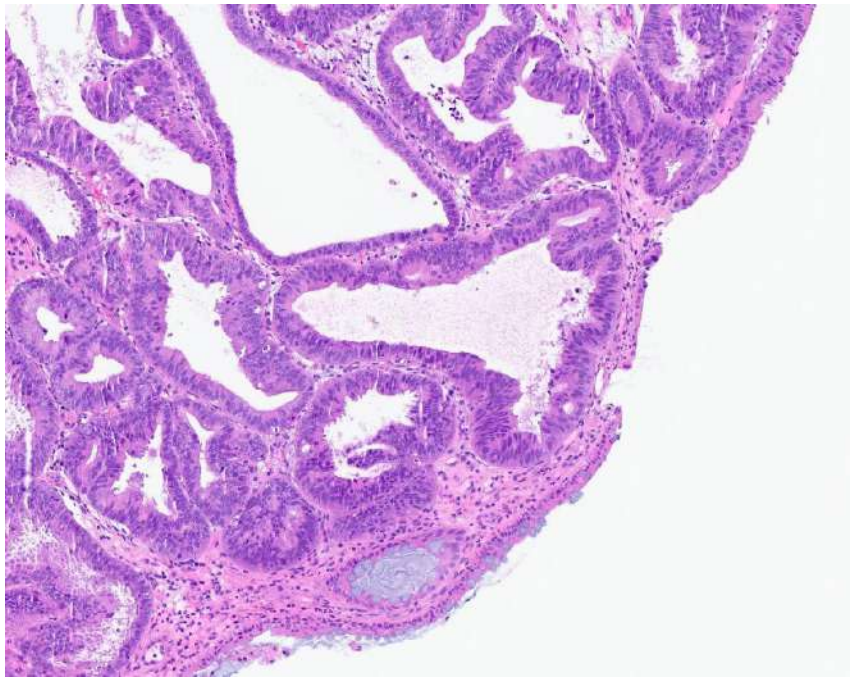


CK20

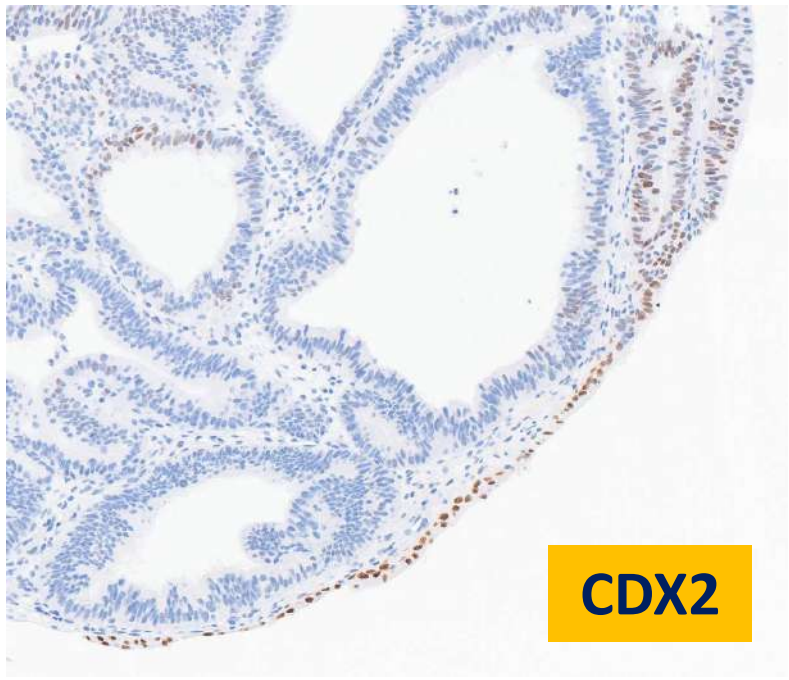
CDX2


ER


PAX8


p53


SATB2

Case 7

- Rectal involvement by endometrioid carcinoma (likely originating from pelvic endometriosis)
  - Subsequent resection demonstrated endometrioid carcinoma associated with endometriosis at the rectovaginal septum

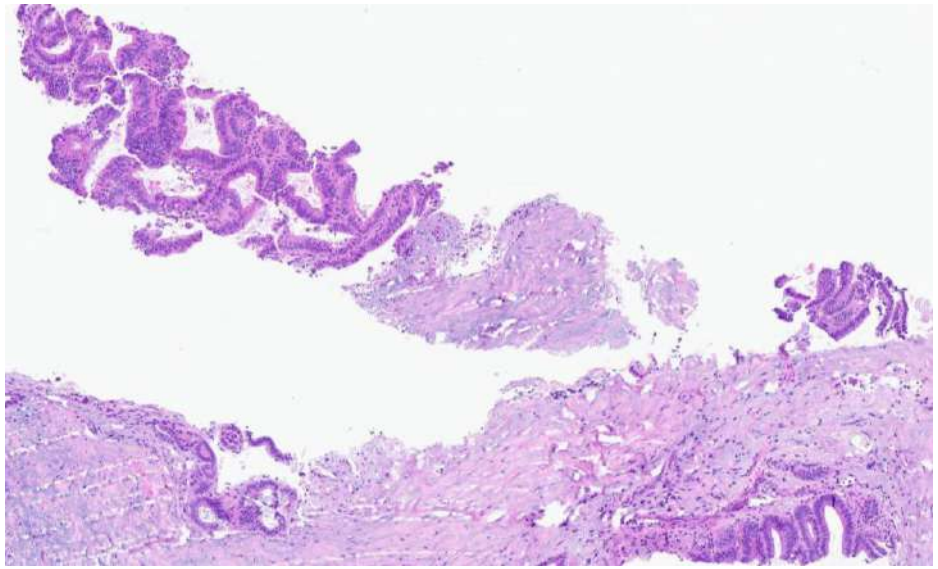

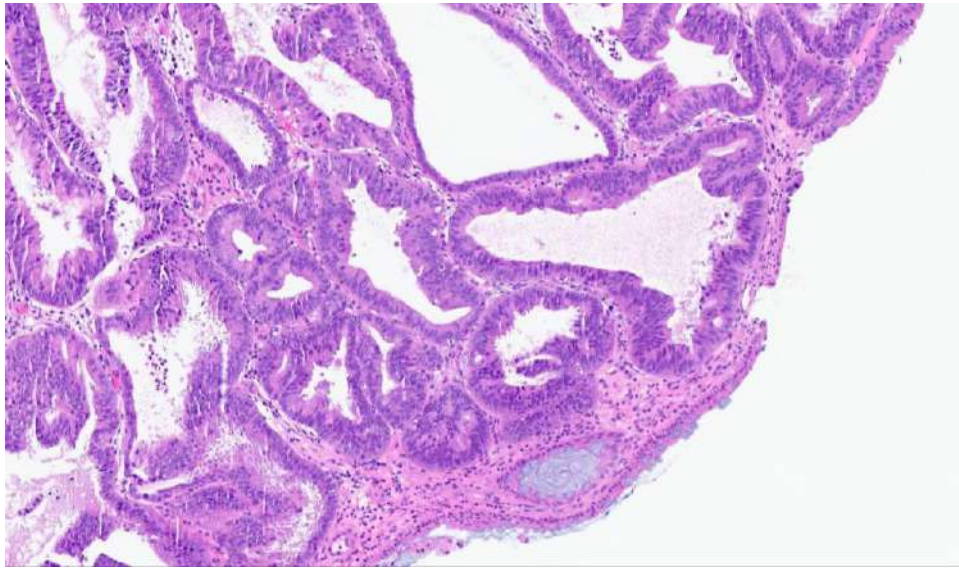

Carcinomas associated with extraovarian endometriosis

- Limited data available in the literature (mostly case reports)
- Endometrioid, clear cell and mesonephric-like carcinomas (or mixed types) may be associated with endometriosis
- Endometriosis-associated carcinomas may arise from pelvic soft tissue, gastrointestinal tract (e.g. sigmoid, rectum), urinary tract (e.g. bladder) or surgical scars
- Diagnostic challenges for endometrioid carcinoma may be related to foci resembling endometrial hyperplasia or borderline tumours
- IHC helps to confirm the diagnosis/typing and exclude other primaries
- Clinical history and imaging are crucial

Gadducci A, Zannoni GF. Anticancer Res. 2020;40:2429-2438.

Case 8

- 59 years old
- Suspected ovarian malignancy with liver metastasis
- Peritoneal nodule biopsy

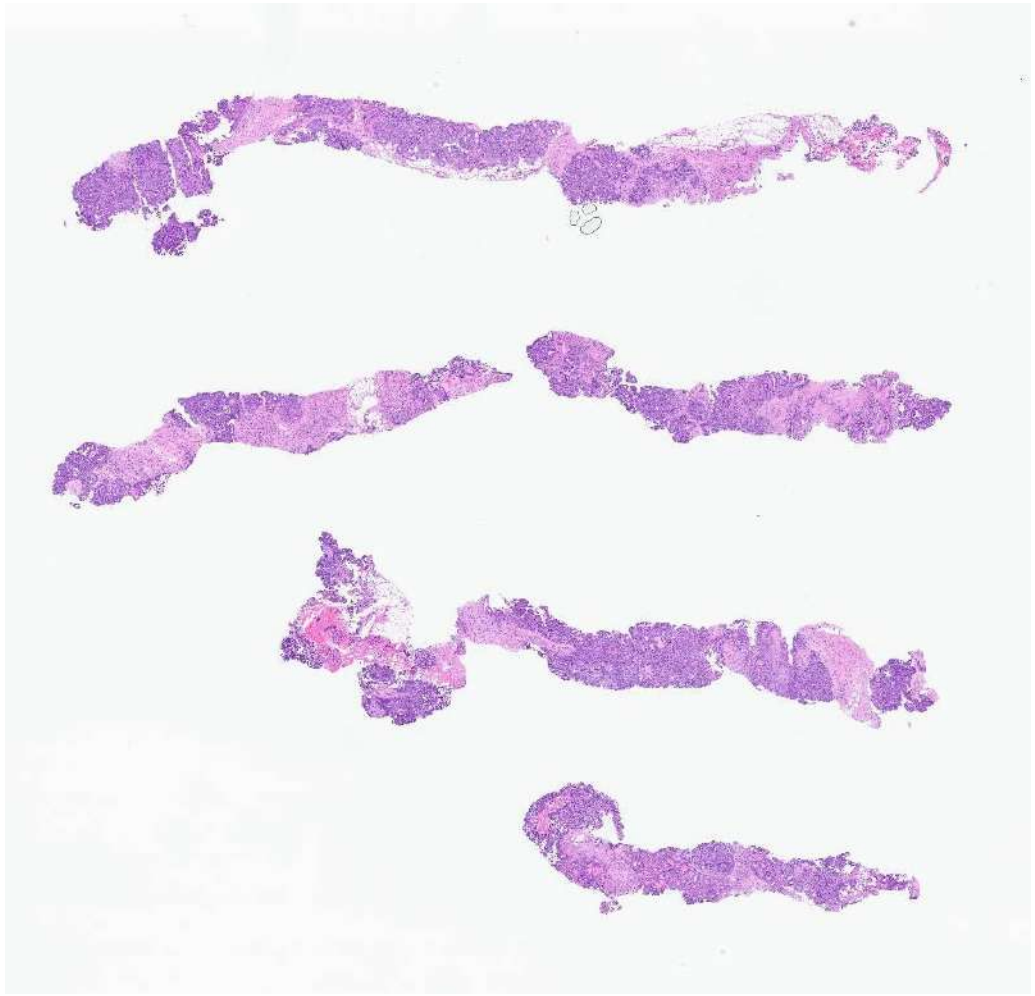

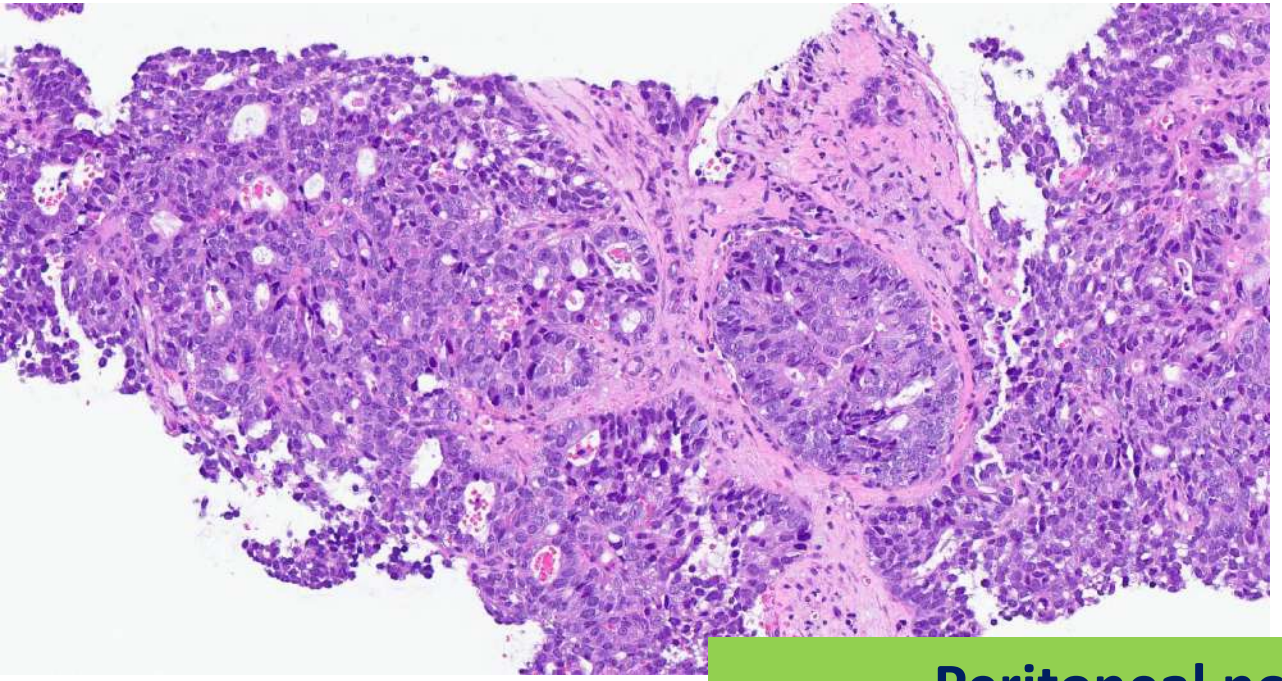

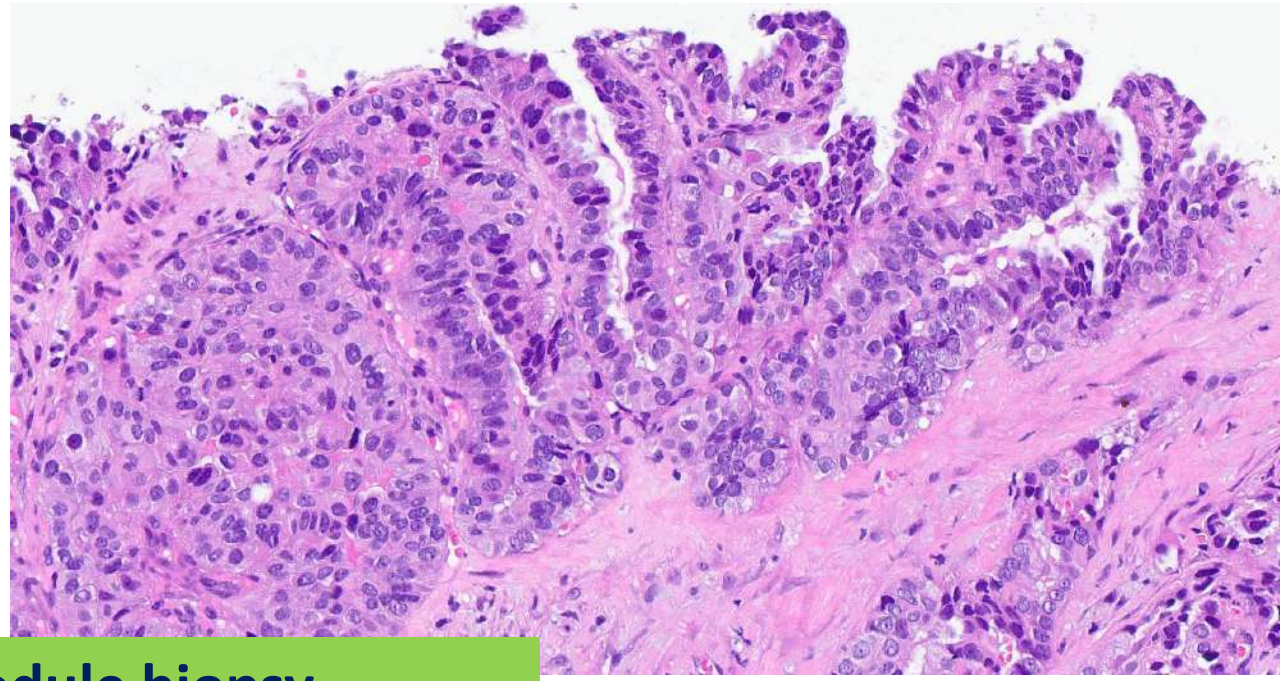

Peritoneal nodule biopsy

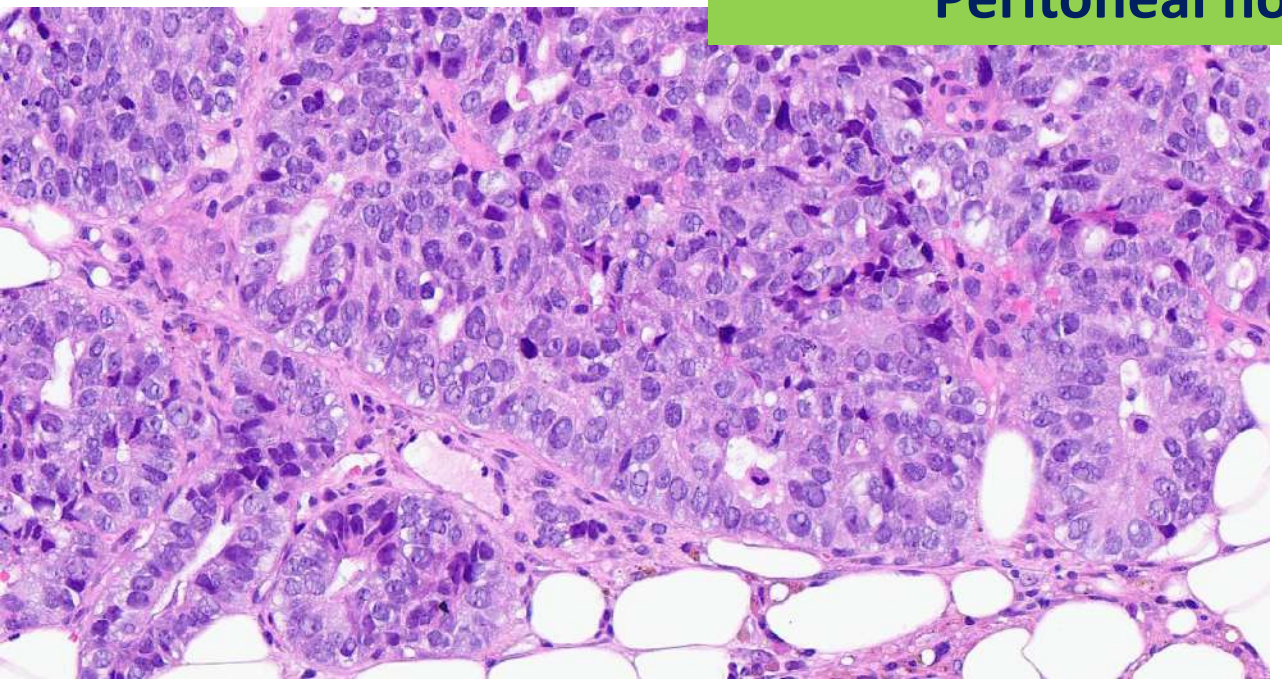

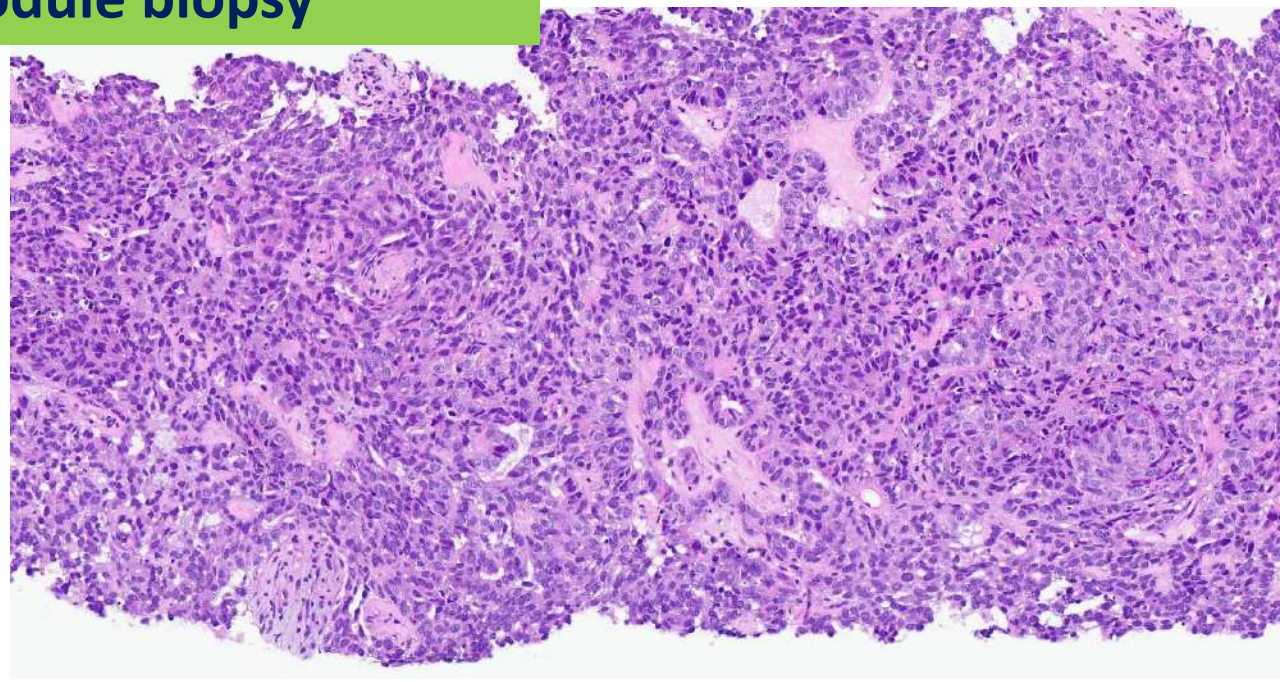

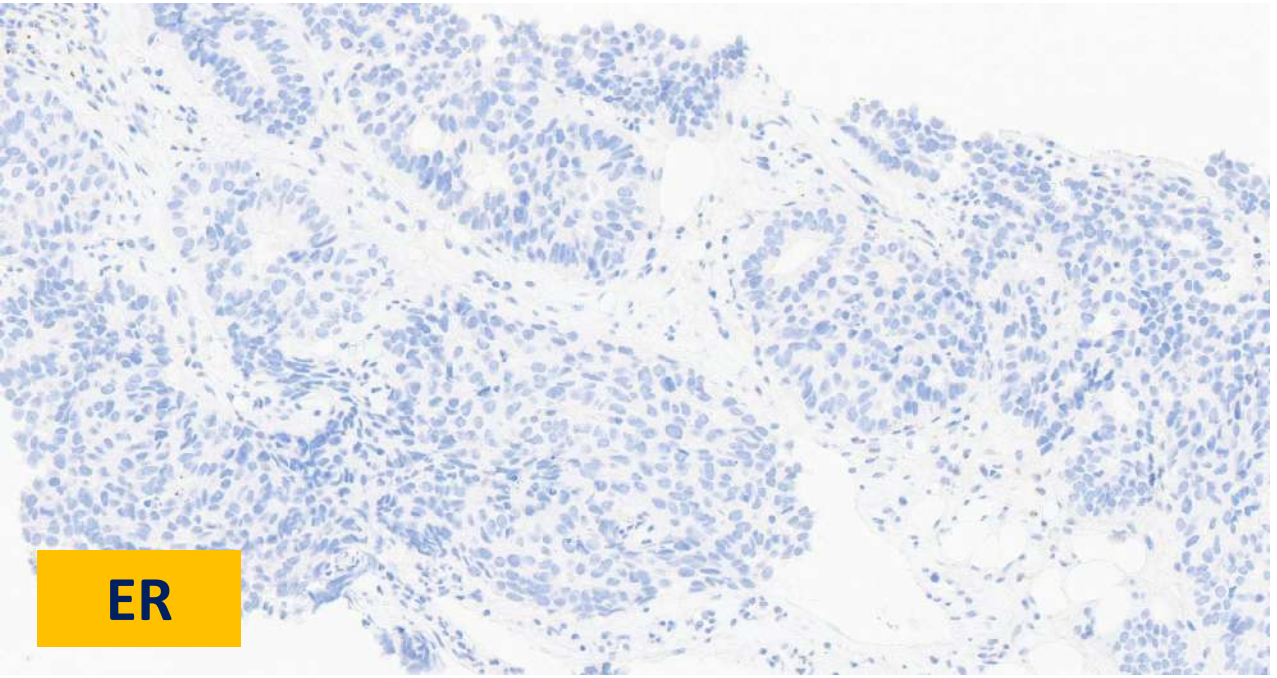
ER

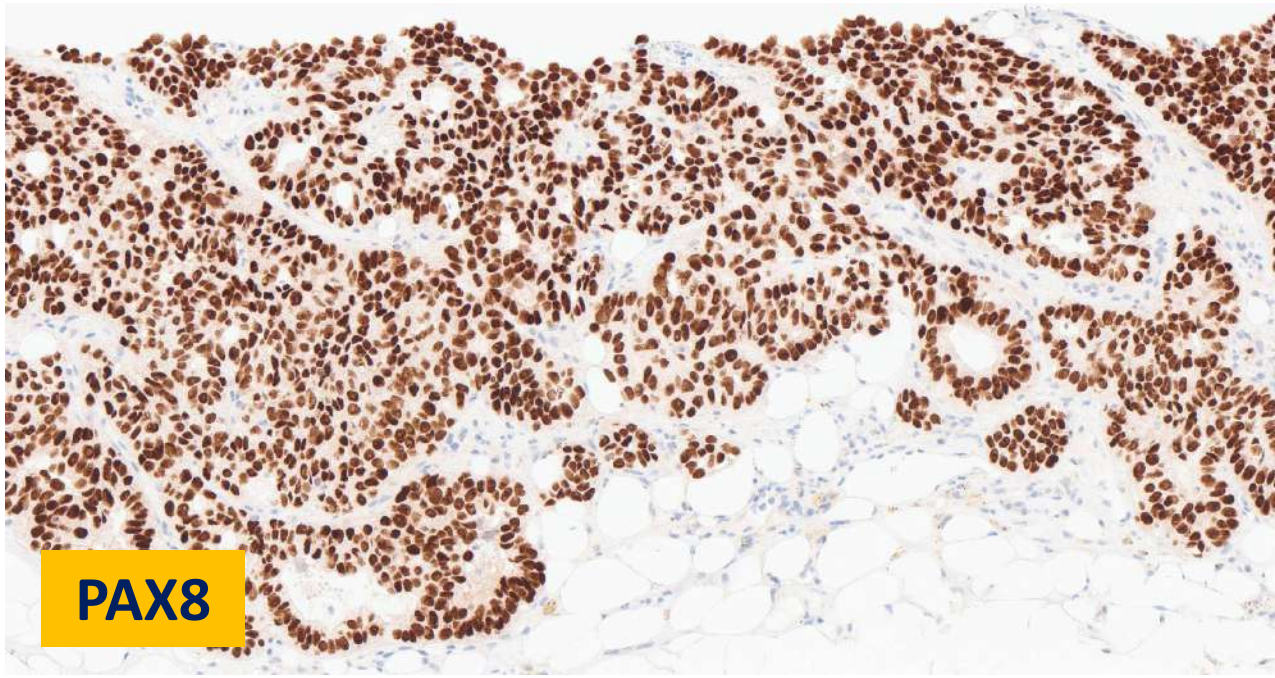
PAX8

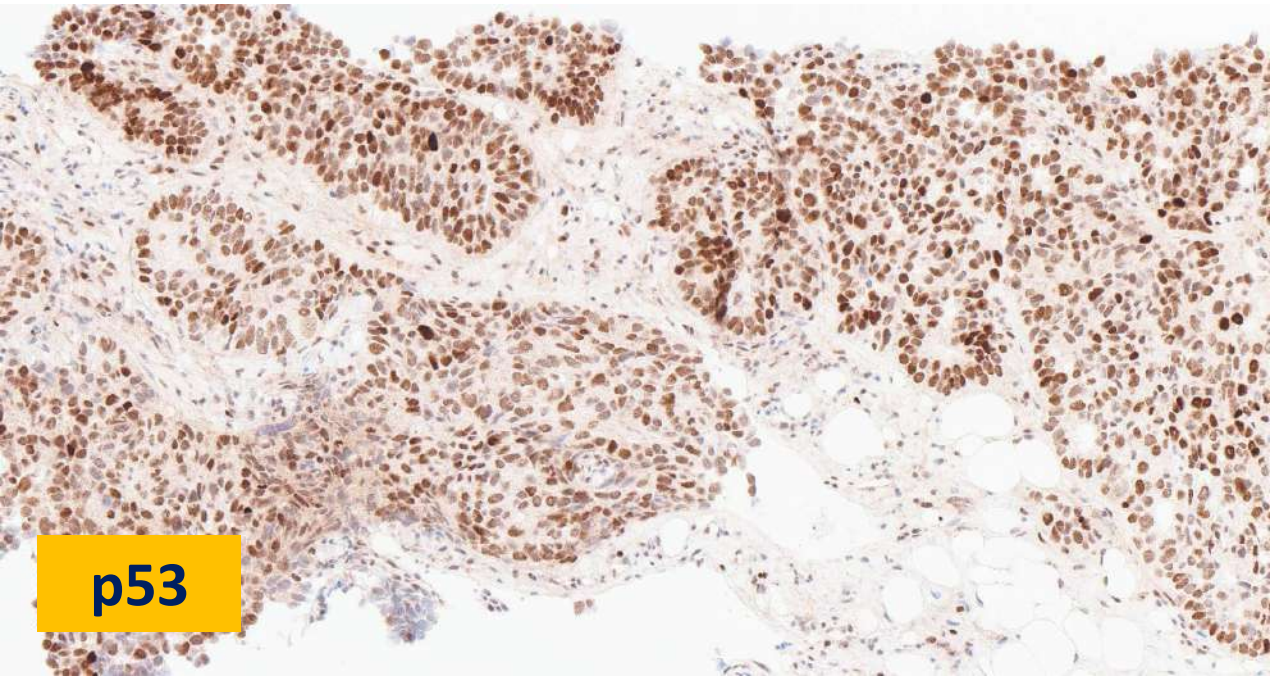
p53

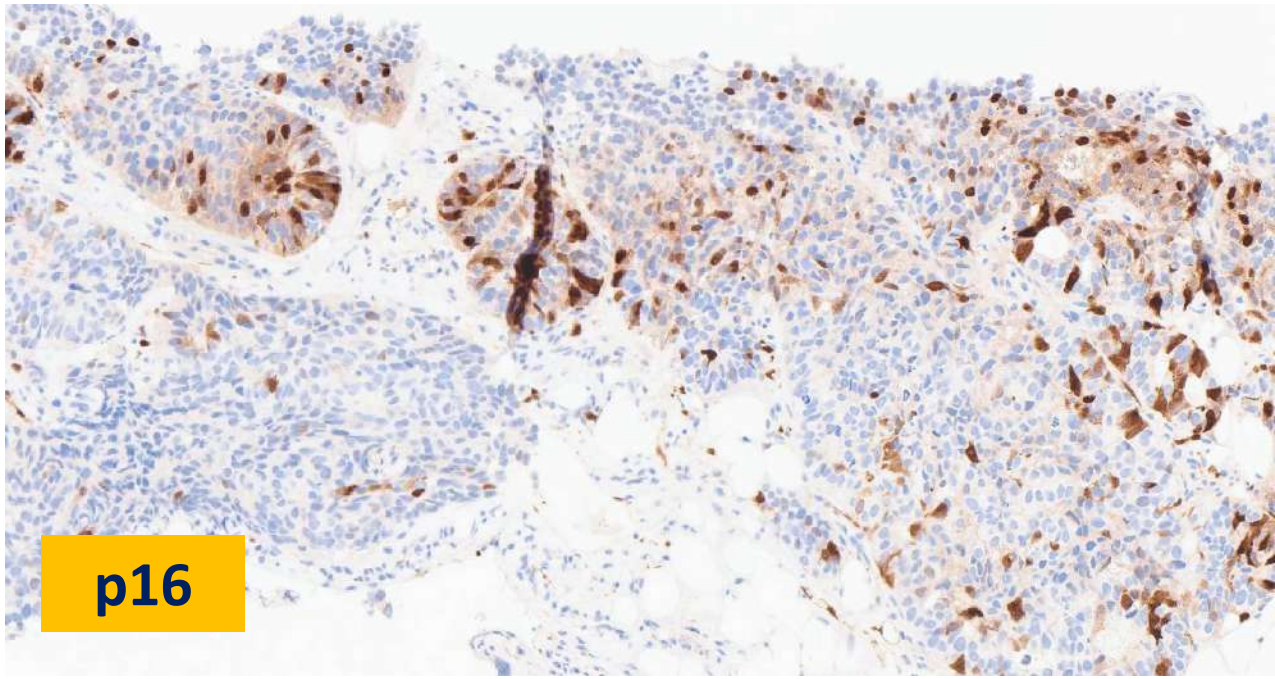
p16

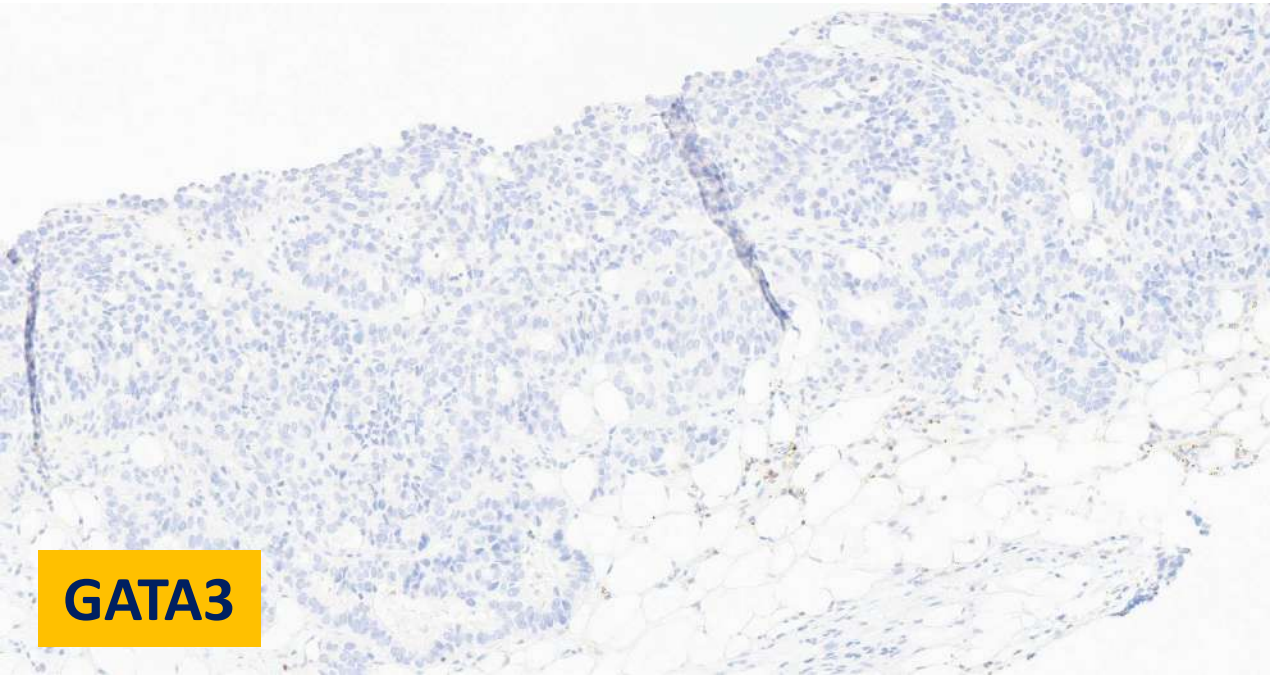
GATA3

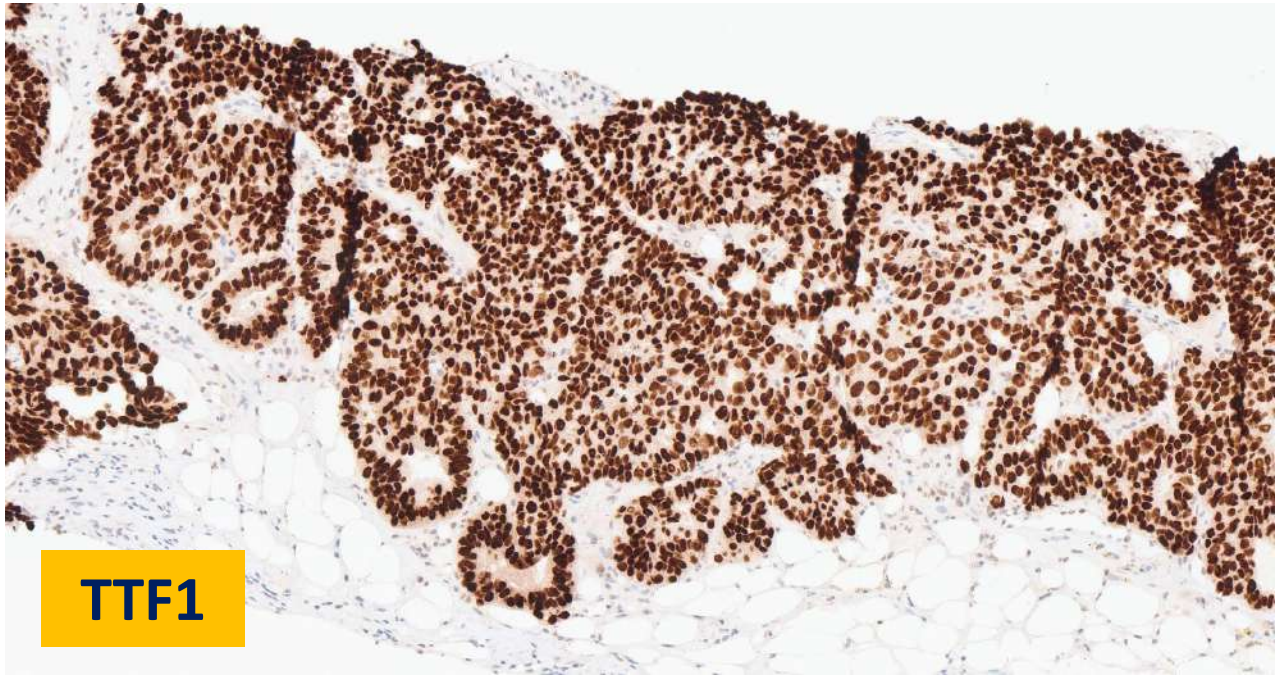
TTF1

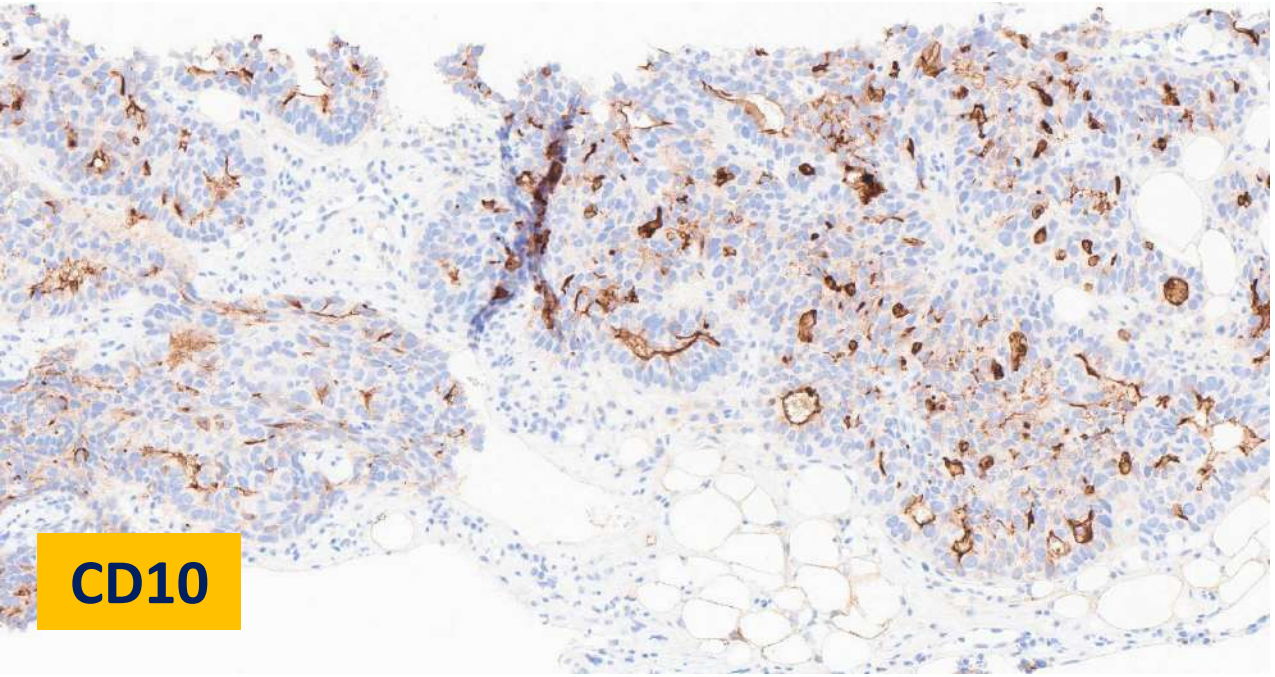
CD10


Thyroglobulin

Case 8

- Adenocarcinoma with solid and tubular/ductal architecture, oval/angulated vesicular nuclei and frequent mitotic activity
- **ER negative**
- **PAX8 positive**
- p53 wild-type
- p16 patchy (non-block)
- GATA3 negative
- **TTF1 diffusely positive**
- **CD10 luminal staining**
- Thyroglobulin negative

- Diagnosis: suggestive of **mesonephric-like carcinoma**
- Based on morphology, IHC profile and clinical/imaging evidence of ovarian tumour
- Correlation with imaging to evaluate the differentials of endometrial (mesonephric-like carcinoma) or cervical (mesonephric carcinoma) primary

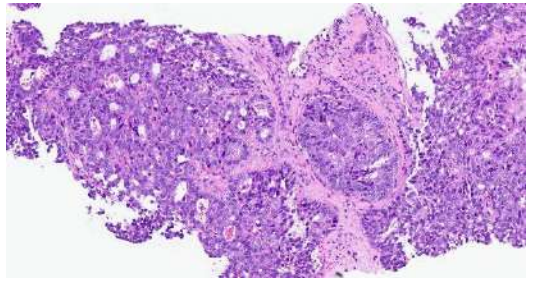

Ovarian mesonephric-like carcinoma

- Broad range of morphological patterns (tubular, pseudoendometrioid, ductal, papillary, solid, etc.)
- Variable IHC profile but the key IHC features are
  - Expression of GATA3 or TTF1
  - Absent or significantly reduced expression of ER/PR

  *Caution: consider endometrioid if substantial ER/PR expression and very focal GATA3/TTF1
- Often associated with endometriosis
- May be combined with carcinoma or borderline tumour of another type
  - Usually endometriosis-associated neoplasms (e.g. seromucinous borderline tumour, endometrioid carcinoma, clear cell carcinoma)
- IHC in these combined tumour may be challenging to interpret

Deolet E, Arora I, Van Dorpe J, et al. Am J Surg Pathol. 2022;46:124-133.
Euscher ED, Marques-Piubelli ML, Ramalingam P, et al. Am J Surg Pathol. 2023;47:635-648.

Case 9

- 72 years old
- Left ovarian tumour

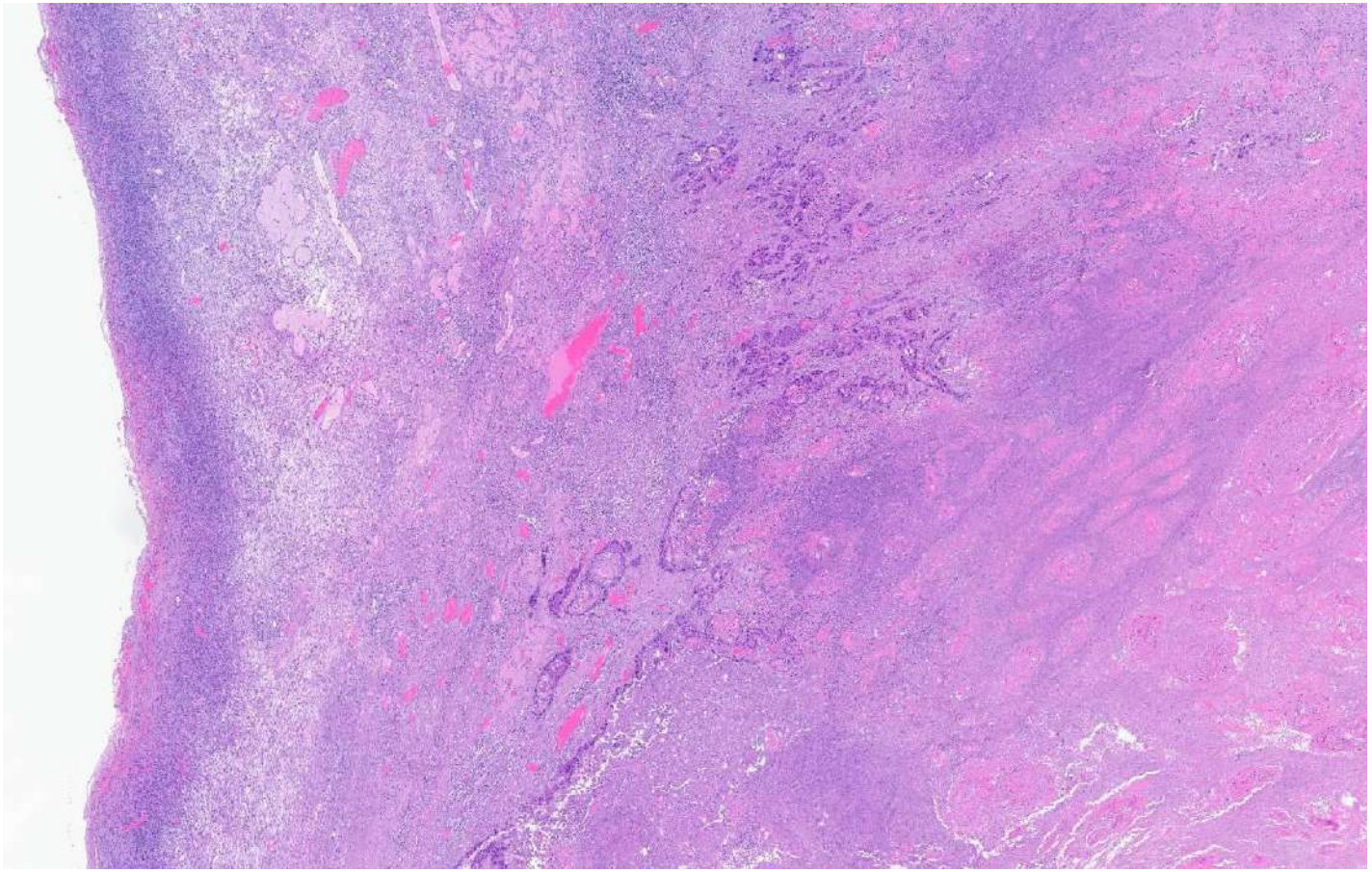

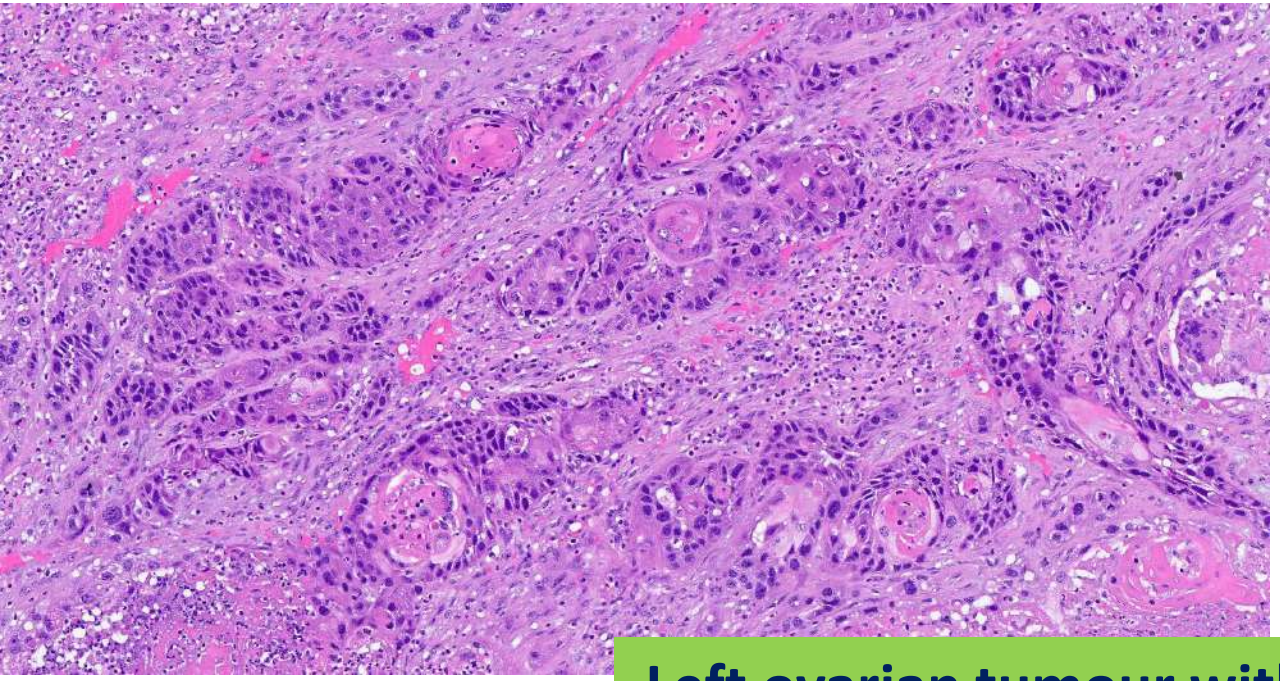

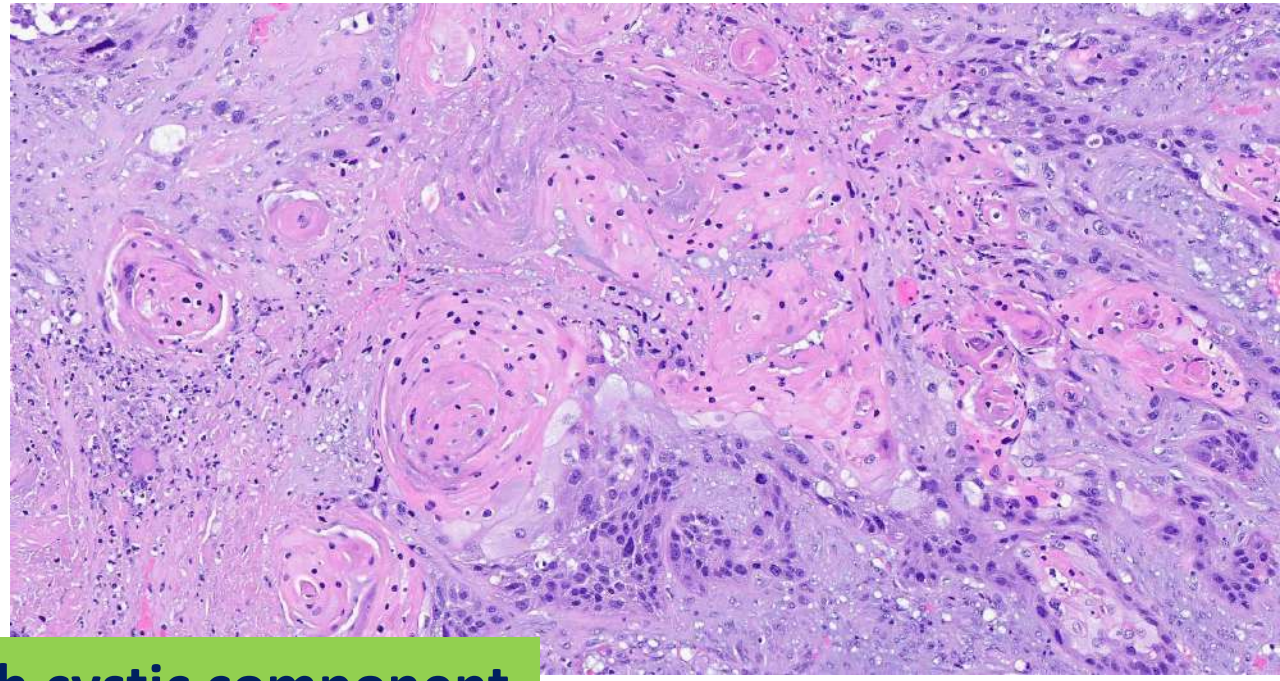

Left ovarian tumour with cystic component

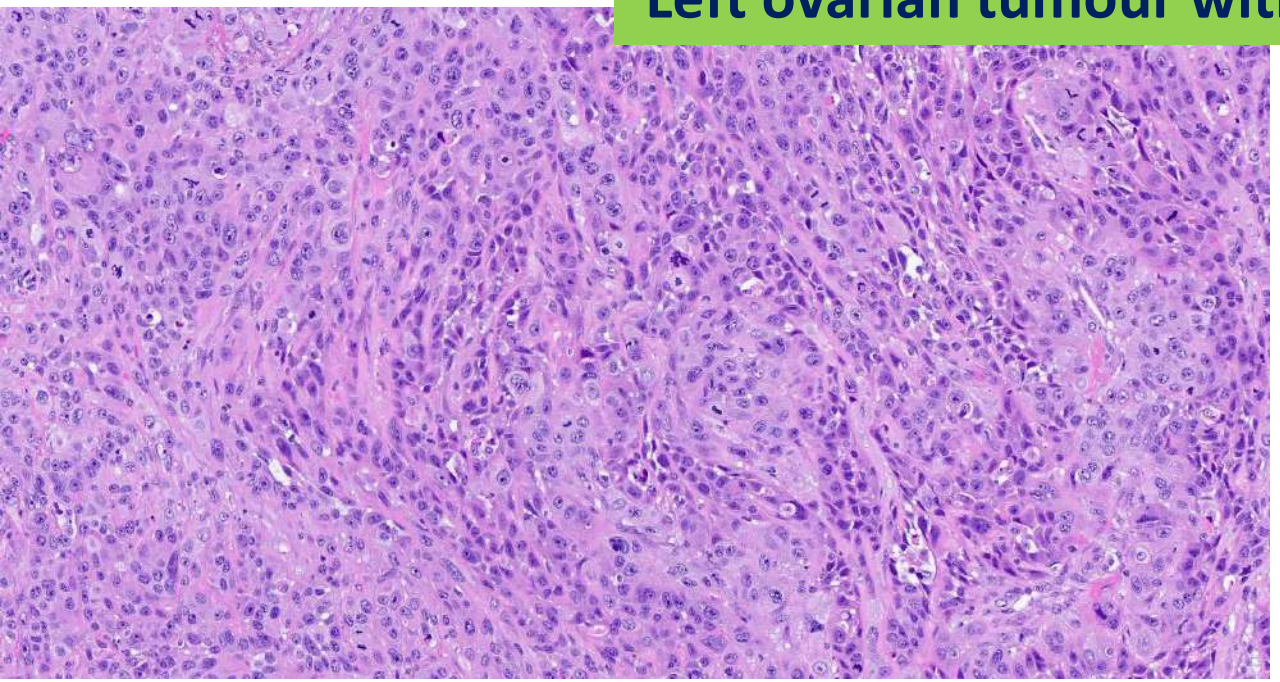

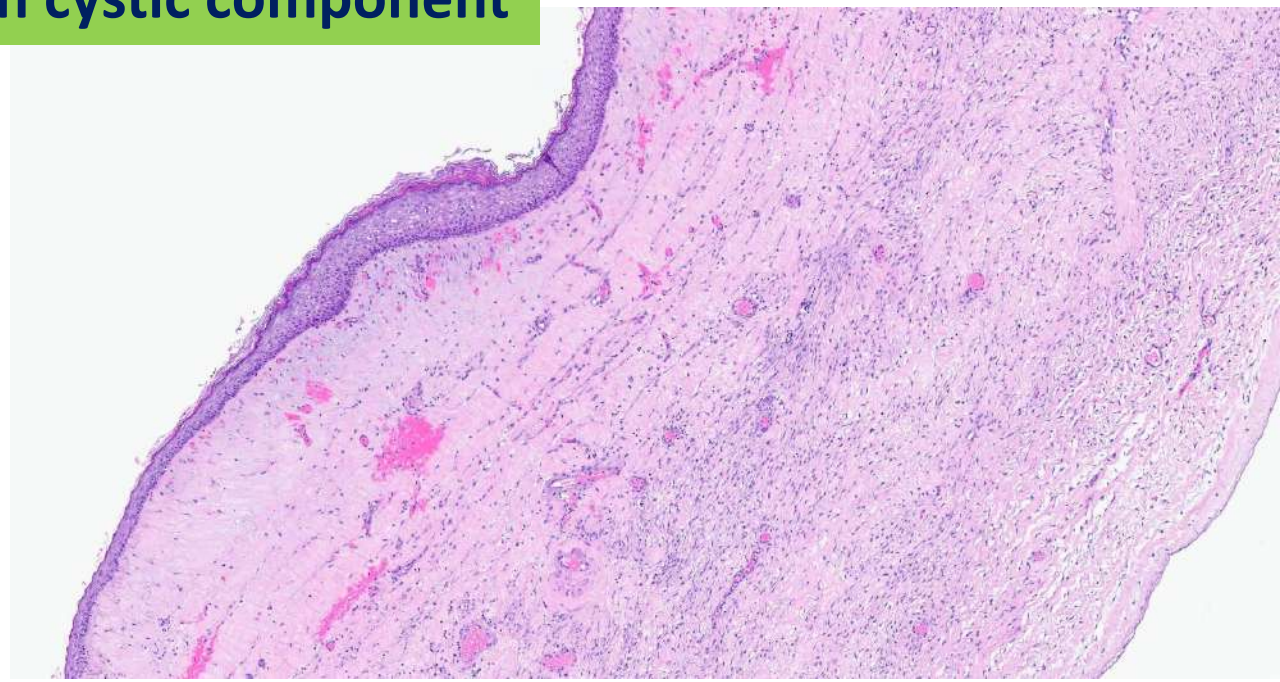

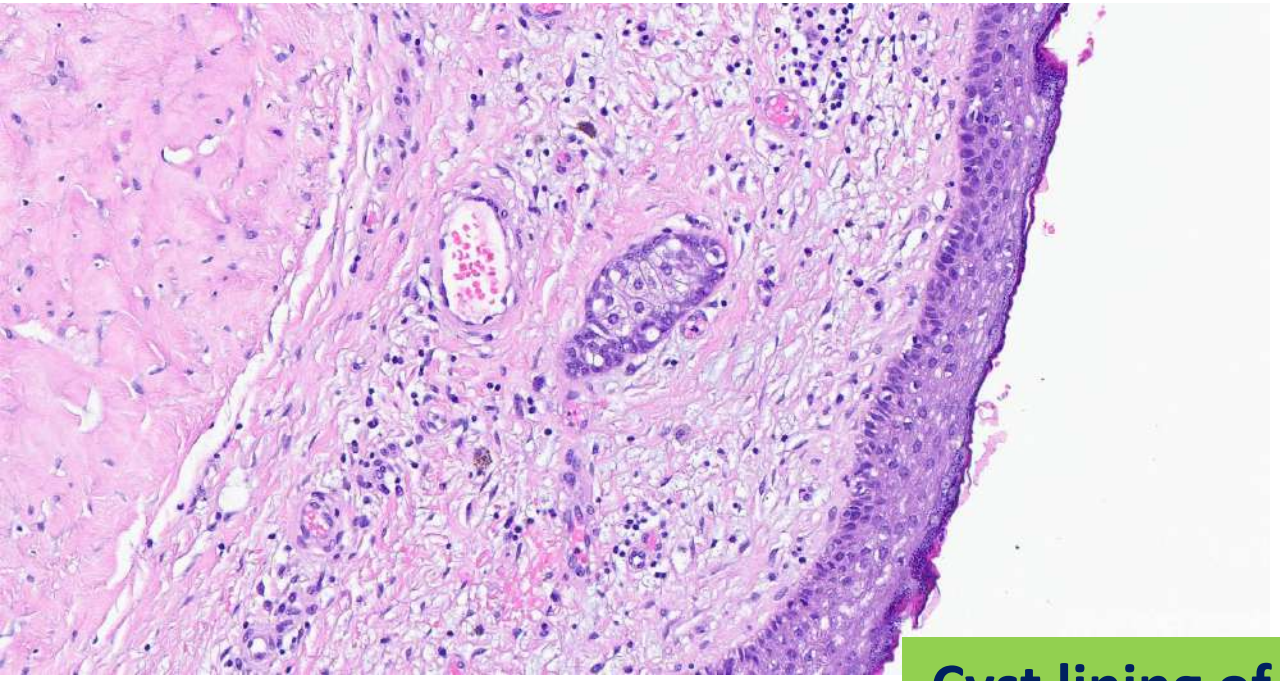
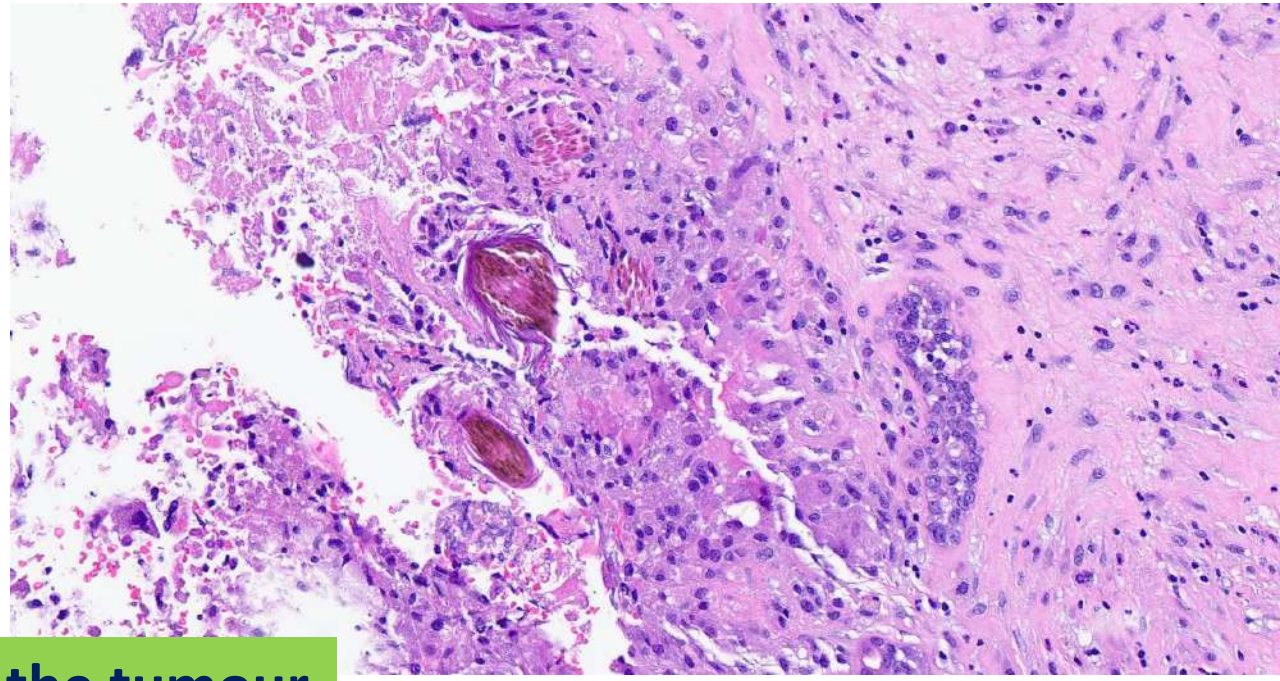

Cyst lining of the tumour

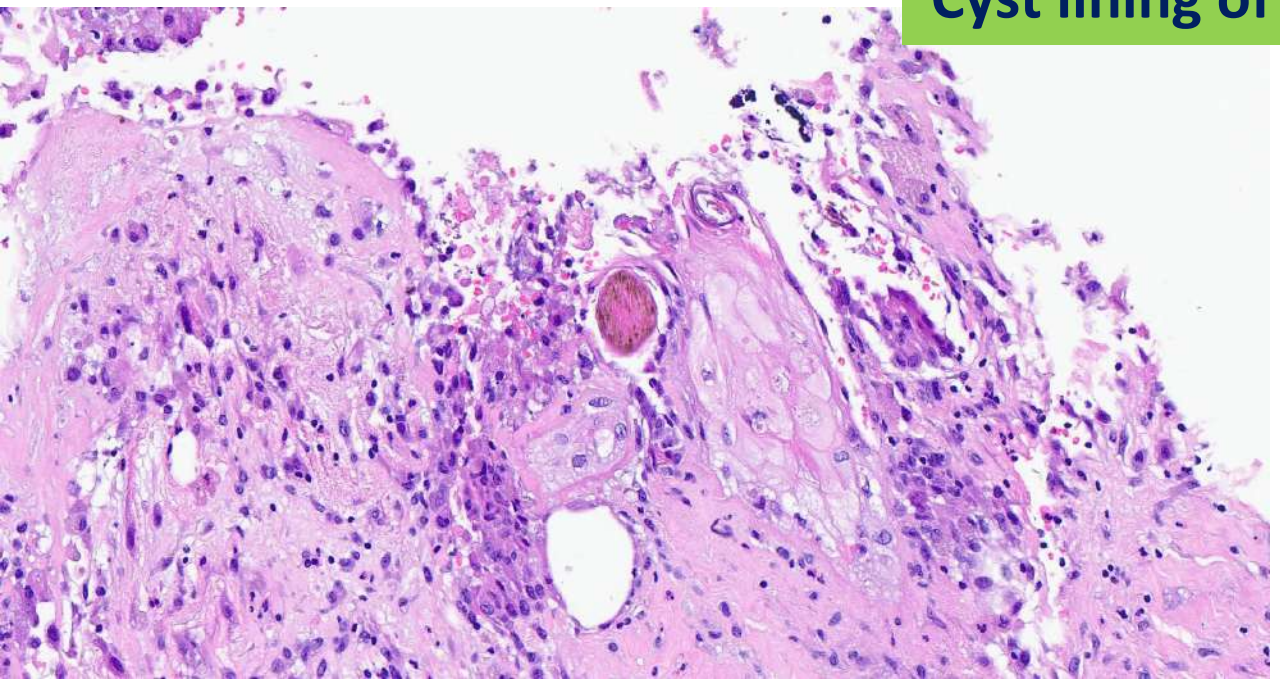
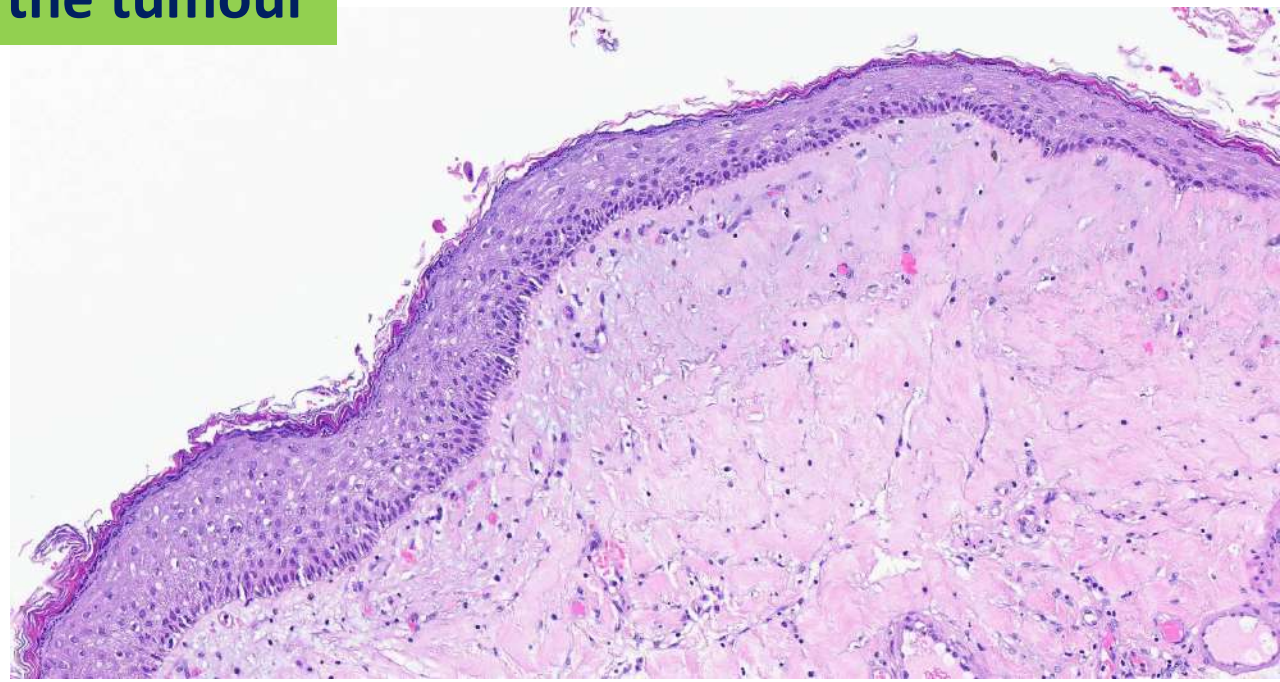

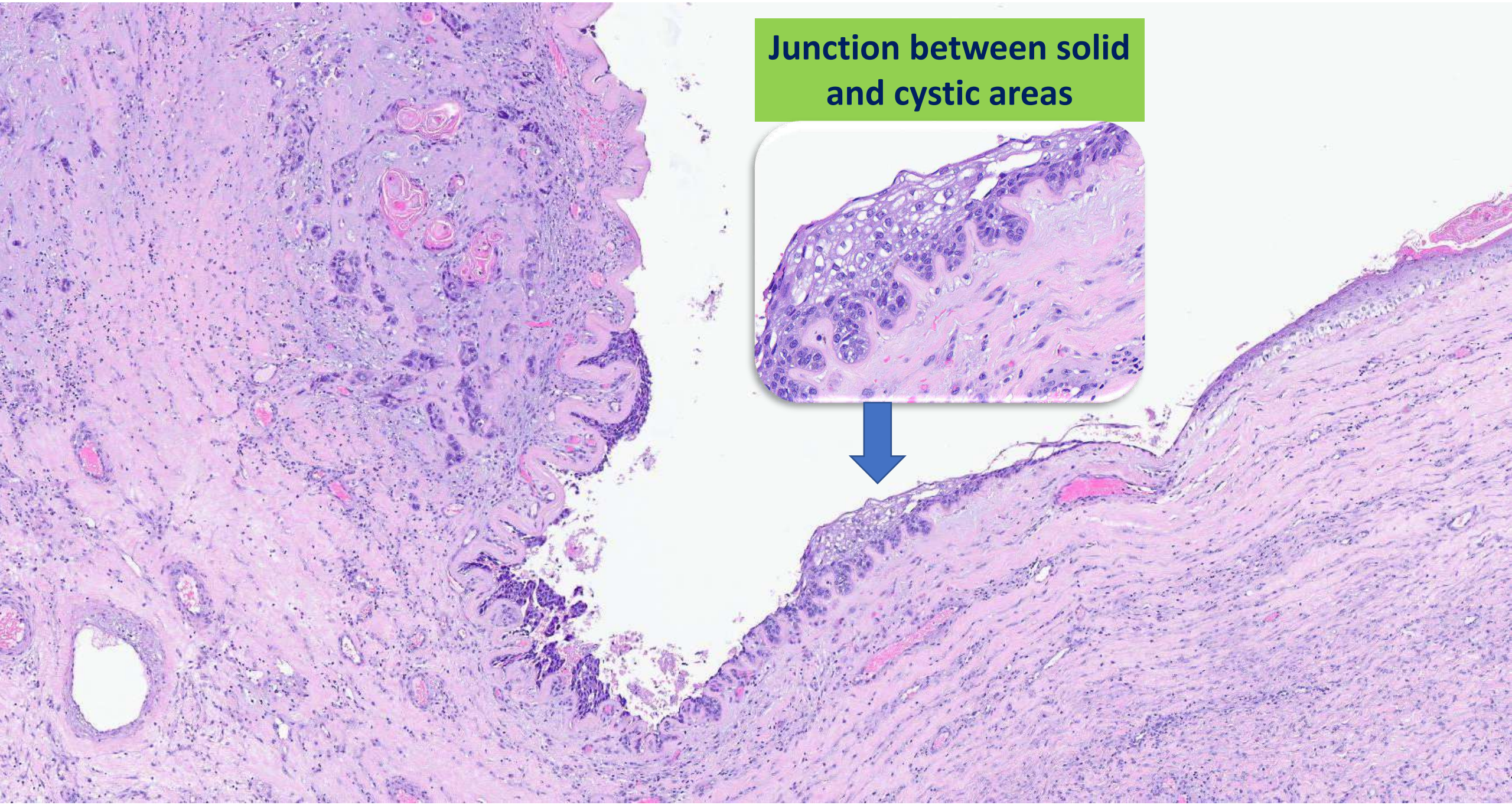
Junction between solid and cystic areas

p53

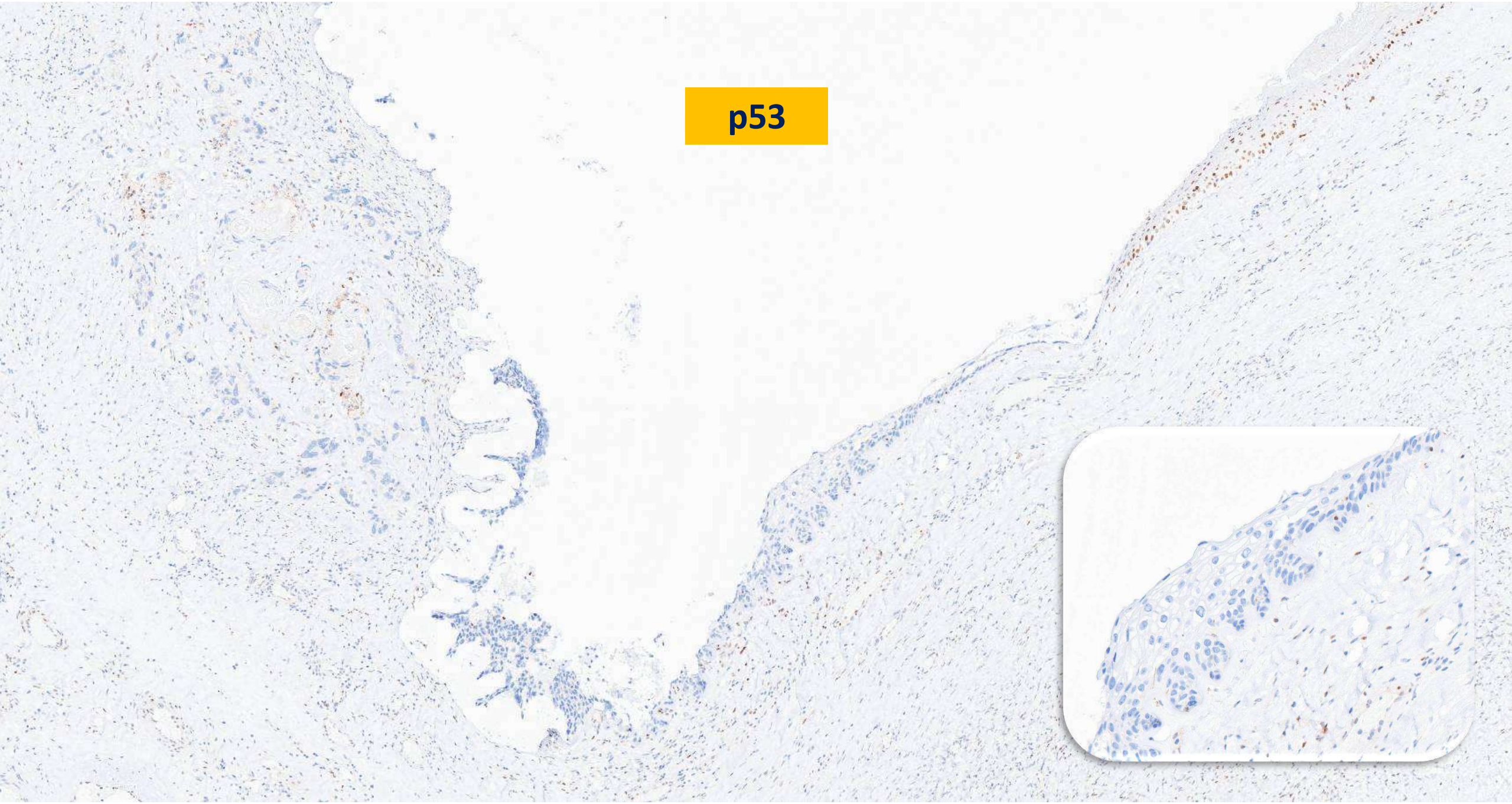

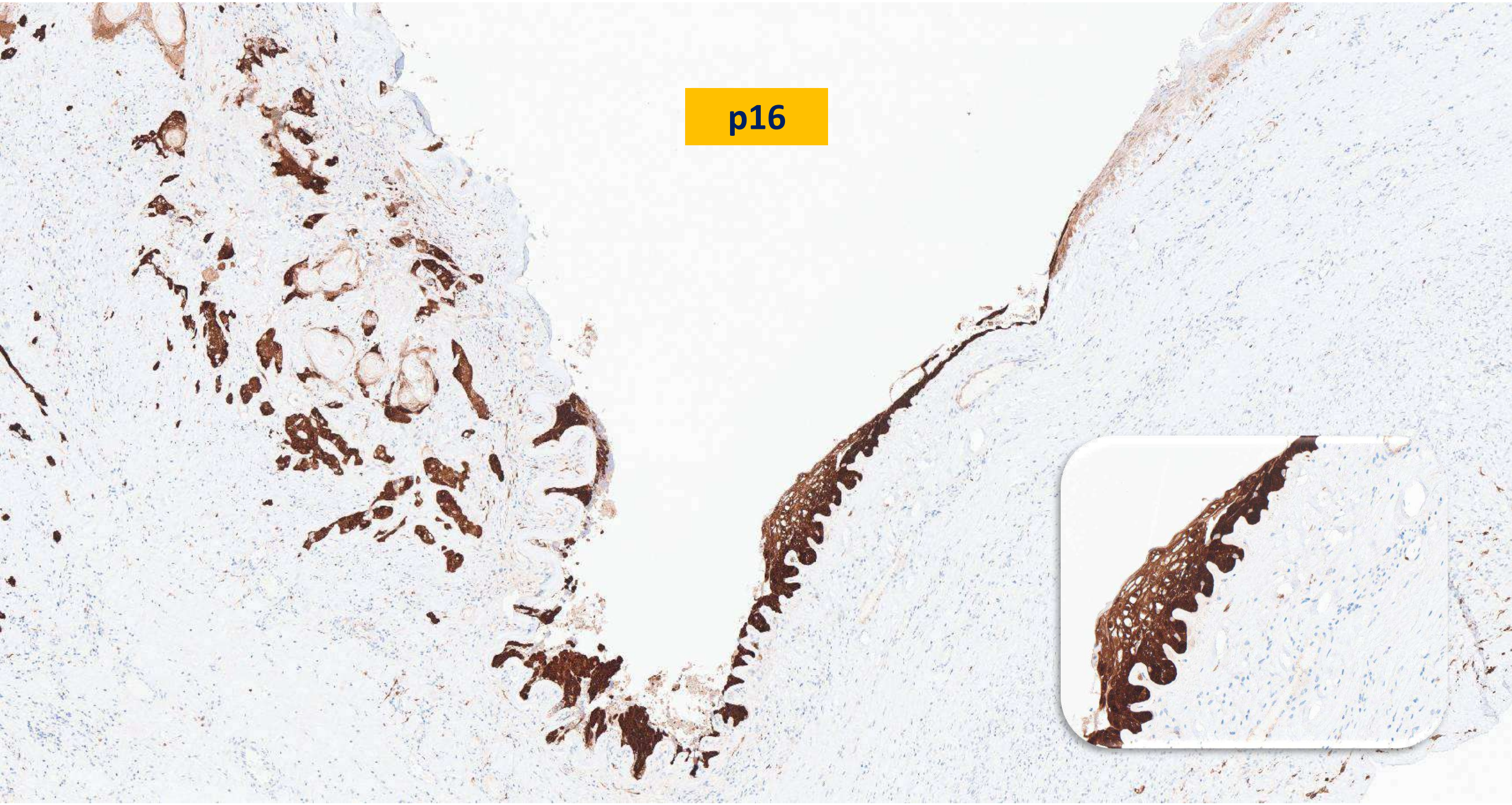
p16

Case 9

- Squamous cell carcinoma arising in mature cystic teratoma

- The invasive carcinoma and adjacent dysplastic squamous epithelium show diffuse p16 and null-type p53 expression

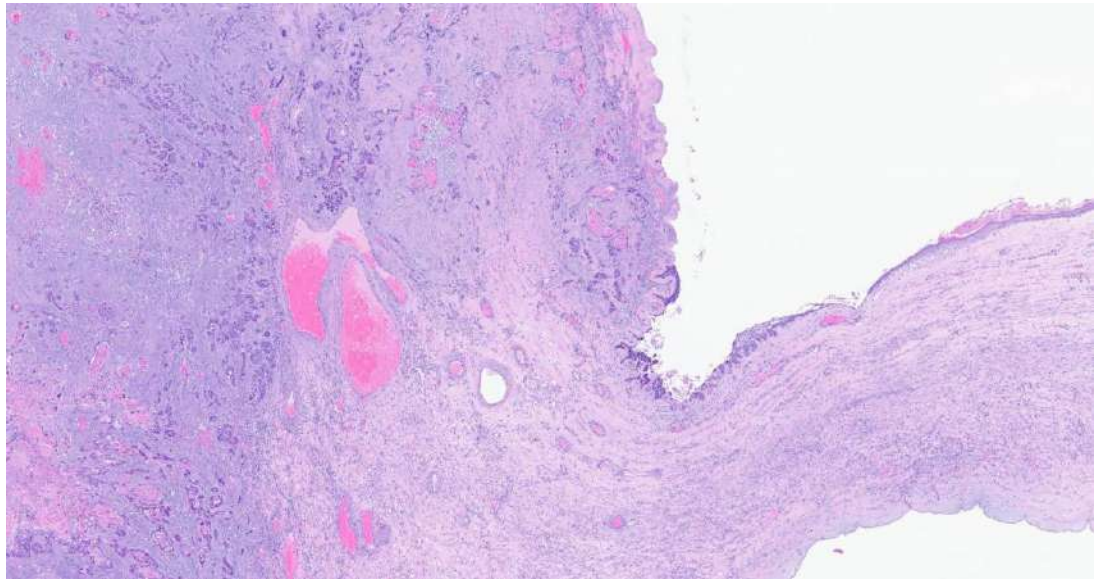

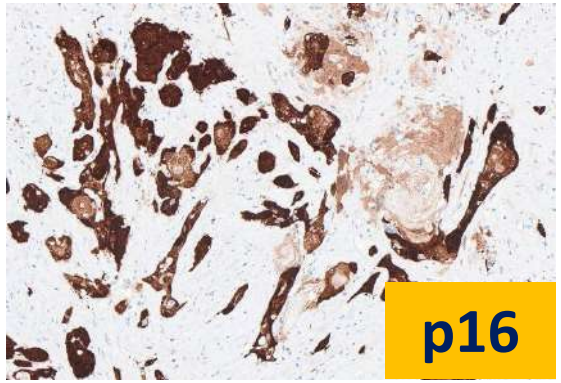

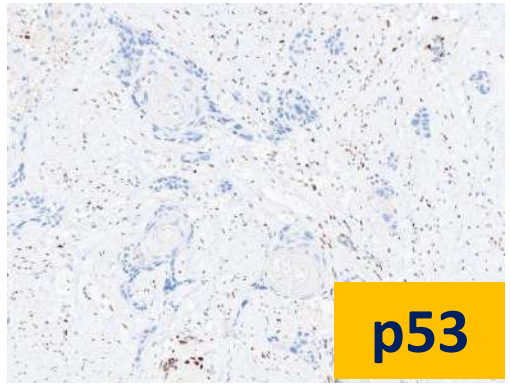

Squamous cell carcinoma of the ovary

- Reported cases often associated with mature teratoma, some with endometriosis or Brenner tumour, or without coexisting lesions
- SCC arising in mature teratoma is generally aggressive
- Chao et al. (2025) found frequent *TP53* mutations in ovarian SCC arising in mature teratomas, some cases with *CDKN2A*, *PIK3CA*, *PTEN* or *KMT2D* mutations

- Differential diagnosis:
  - Metastatic HPV-associated SCC
  - Endometrioid or serous carcinoma with squamous differentiation
- Not much data on the IHC profile but some case reports mentioned negative p16 staining
- Interpretation of p16 is best combined with p53 in this context

Pins MR, Young RH, Daly WJ, Scully RE. Am J Surg Pathol. 1996;20:823-33.
Chao A, Lai CH, Chao AS, et al. J Mol Med (Berl). 2025;103:101-111.
Yoo SH, Son EM, Sung CO, Kim KR. Korean J Pathol. 2013;47:549-56.
Park JY, Song JS, Choi G, et al. Int J Gynecol Pathol. 2010;29:328-34.

The role of IHC in non-mucinous ovarian carcinomas

- Awareness of “aberrant” or non-prototypical IHC profiles for high grade serous, clear cell and endometrioid carcinomas
- Divergent differentiation in ovarian carcinomas (e.g. squamous, somatically derived germ cell tumour components)
- Mixed carcinomas or carcinomas combined with borderline tumours (especially endometrioid, clear cell and mesonephric-like tumours)
- Tumours involving or arising from extraovarian sites (e.g. pelvic endometriosis, rectal involvement)
- Use a panel of IHC markers and correlate with imaging studies (especially for small biopsies)

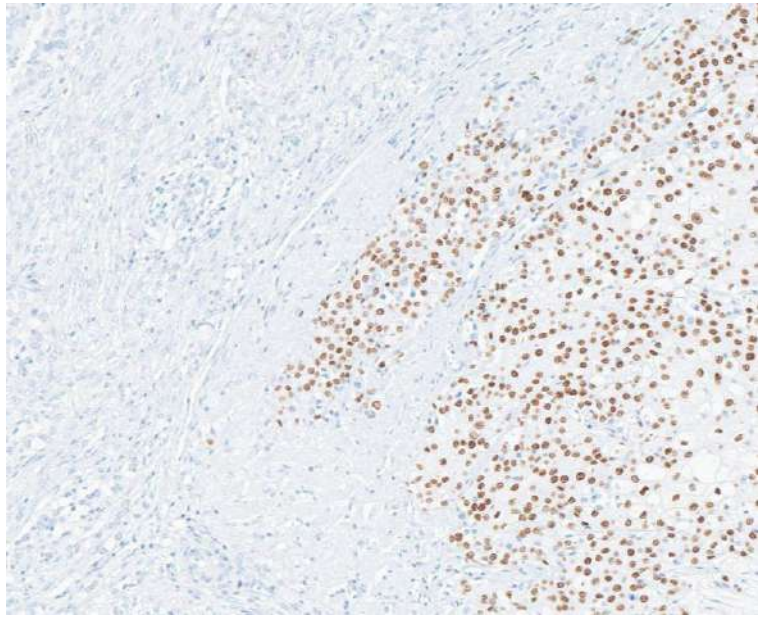
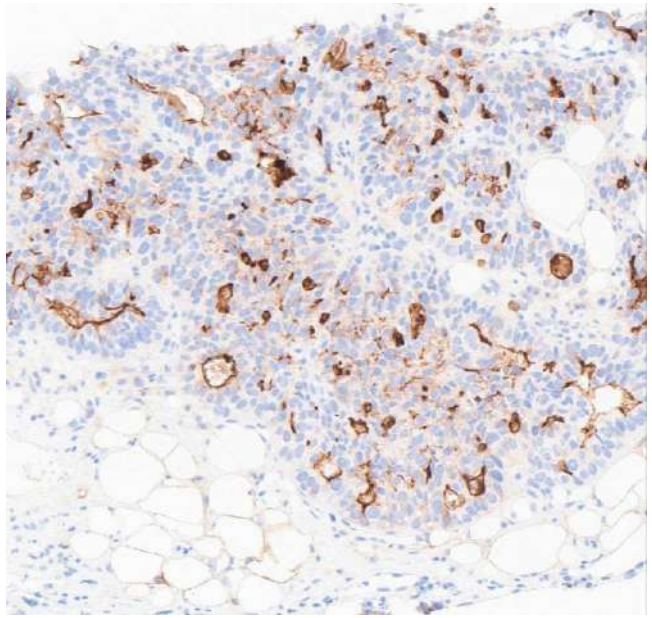
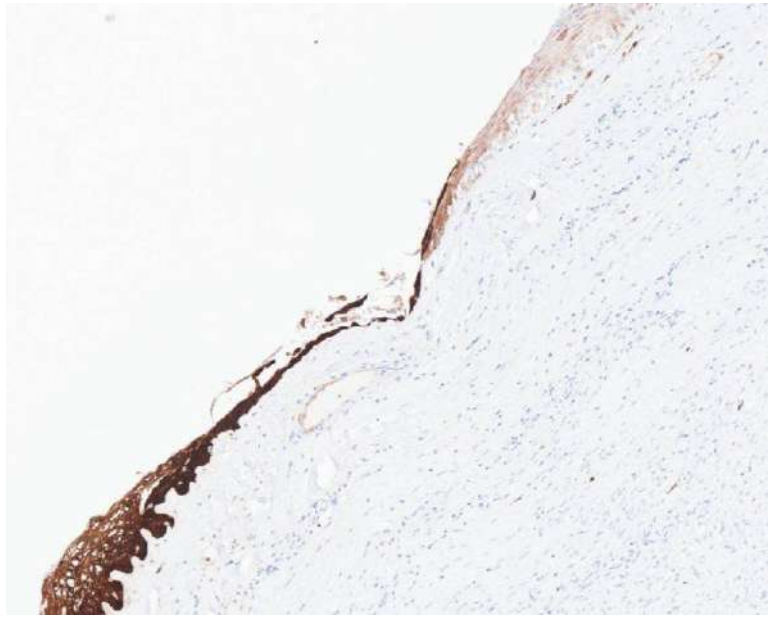

Thank you!

