# Problematic issues in classifying uterine smooth muscle tumors

**Joseph Rabban MD MPH**
Professor
Pathology Department
University of California San Francisco
San Francisco, CA, USA

UCSF
University of California
San Francisco

UCSF PATHOLOGY


Necrosis in uterine smooth muscle tumor


Necrosis in uterine smooth muscle tumor
Diagnostic Pathologists

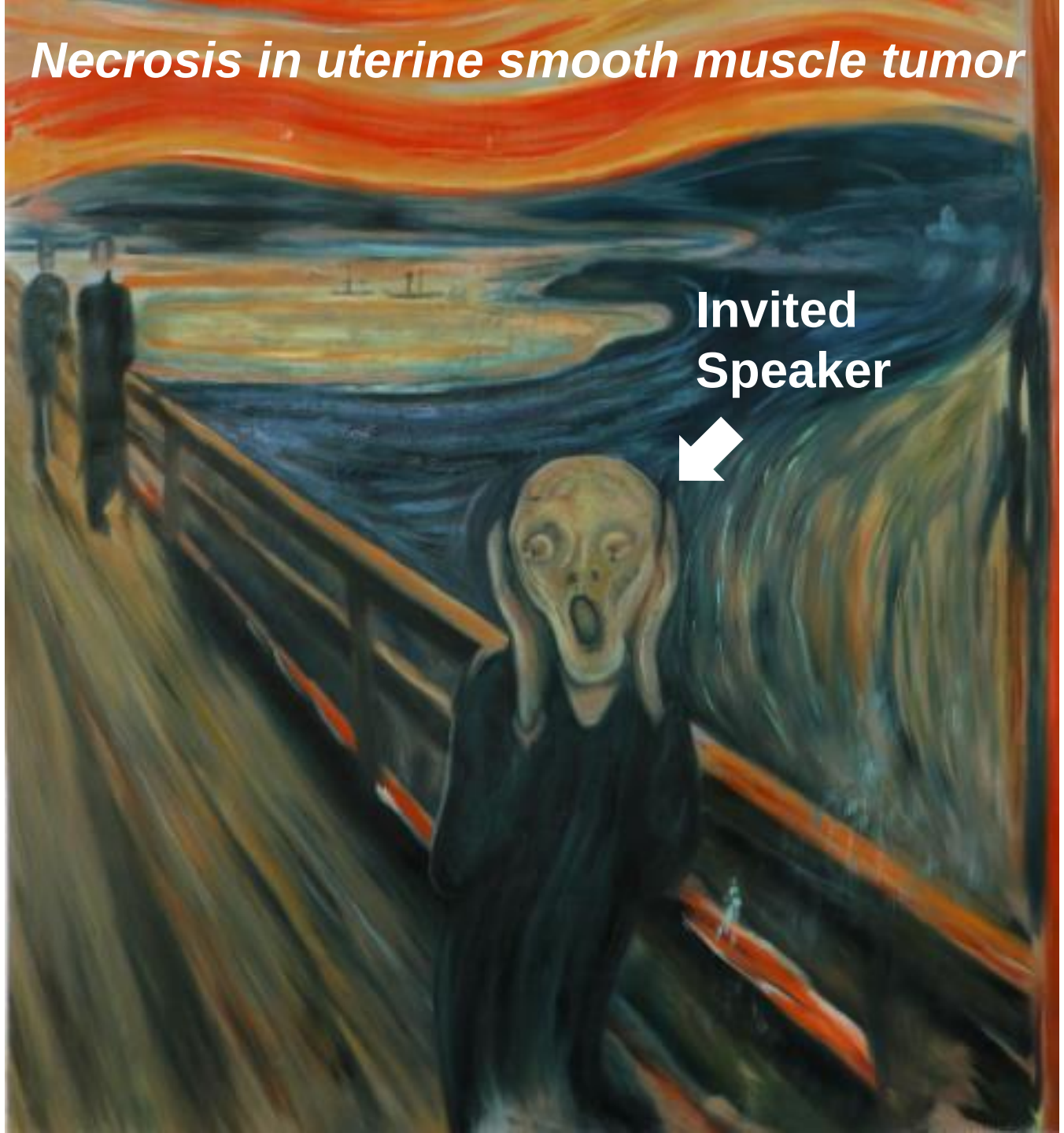
Necrosis in uterine smooth muscle tumor
Invited
Speaker


*Necrosis in uterine smooth muscle tumor*
Glenn, Marisa, Brooke
Me

# Outline of Talk

- **Significance of tumor-type necrosis in prognostic classification of uterine smooth muscle tumors**
- **Definition of tumor-type necrosis**
- **Mimics of tumor-type necrosis**
- **Ambiguous types of necrosis:  Practical algorithm for managing cases**
    - *Integration of clinical context, macroscopy, tissue sampling strategy and microscopy*

## W.H.O. criteria for prognostic classification of uterine smooth muscle tumors

*Role of tumor-type necrosis*

| Spindle Cell Leiomyosarcoma | Epithelioid Leiomyosarcoma | Myxoid Leiomyosarcoma |
|---|---|---|
| At least **2** criteria: | At least **1** criterion: | At least **1** criterion: |
| **Tumor type necrosis** | **Tumor type necrosis** | **Tumor type necrosis** |
| **Moderate/severe atypia** | **Moderate/severe atypia** | **Moderate/severe atypia** |
| **≥10 mitoses / 10 hpf** | **≥4 mitoses / 10 hpf** | **≥1 mitoses / 10 hpf** |
| | | **Infiltrative growth** |

*No new criteria in 5th edition WHO system*

# W.H.O. criteria for prognostic classification of uterine smooth muscle tumors

*Role of tumor-type necrosis*

| **Spindle Cell Leiomyosarcoma** |
| --- |
| At least **2** criteria: |
| |
| **Tumor type necrosis** |
| **Moderate/severe atypia** |
| **≥10 mitoses / 10 hpf** |

## New prognostic risk score for stage I tumors:

PMID: 35121810

| *Score based on presence of:* | *# points* |
| --- | --- |
| • **Tumor-type necrosis** | 1 |
| • **Mitosis >24 / 2.4 mm²** | 2 |
| • **Atypical mitoses** | 2 |
| • **LVSI** | 3 |
| • **Serosal abutment** | 5 |

| *Risk group:* | *# total points* |
| --- | --- |
| • **Low** | <3 |
| • **Intermediate** | 3-5 |
| • **High** | >5 |

# W.H.O. criteria for prognostic classification of uterine smooth muscle tumors

*Role of tumor-type necrosis*

| **Spindle Cell Leiomyosarcoma** |
| --- |
| At least **2** criteria: |
| |
| **Tumor type necrosis** |
| **Moderate/severe atypia** |
| **≥10 mitoses / 10 hpf** |

**New prognostic risk score for stage I tumors:**

PMID: 35121810

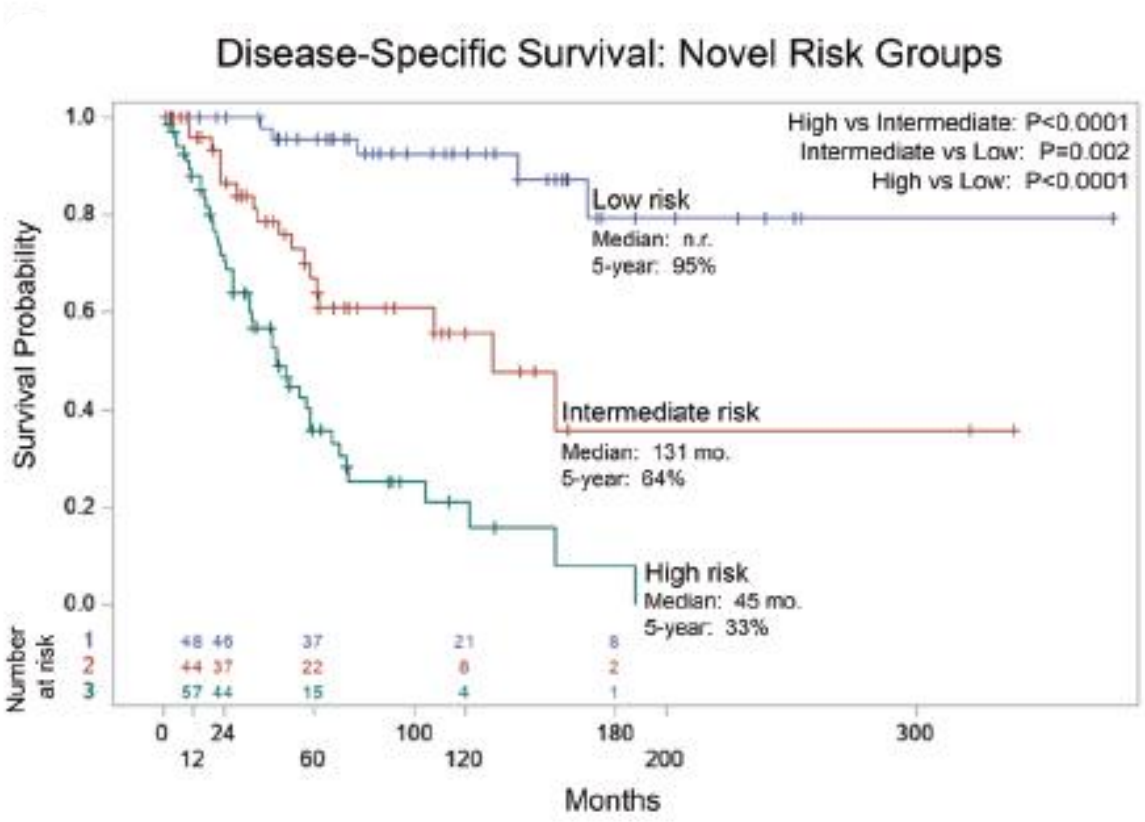

# W.H.O. criteria for prognostic classification of uterine smooth muscle tumors

*Role of tumor-type necrosis*

| **Spindle Cell Leiomyosarcoma** |
| --- |
| At least **2** criteria: |
| |
| **Tumor type necrosis** |
| **Moderate/severe atypia** |
| **≥10 mitoses / 10 hpf** |

**What if this is the only criterion present:**

*What is the appropriate tumor classification ?*

# W.H.O. criteria for prognostic classification of uterine smooth muscle tumors

*Role of tumor-type necrosis*

| Spindle Cell Leiomyosarcoma |
| --- |
| At least **2** criteria: |
| |
| **Tumor type necrosis** |
| **Moderate/severe atypia** |
| **≥10 mitoses / 10 hpf** |

**What if this is the only criterion present:**

*What is the appropriate tumor classification ?*

| Smooth Muscle Tumor of Uncertain Malignant Potential (STUMP) |
| --- |
| • Significance |
| **28% risk of recurrence** |
| (based on outcome of 18 cases in literature) |
| • Management |
| **Surveillance long term** |

## W.H.O. criteria for prognostic classification of uterine smooth muscle tumors

*Role of tumor-type necrosis*

1. **Drives classification as leiomyosarcoma** (depending on cell type)
2. **Drives prognosis of stage I leiomyosarcoma** (using new risk score)
3. **Predicts recurrence in cases that fail to meet criteria for leiomyosarcoma** (STUMP)

# Outline of Talk

- Significance of tumor-type necrosis in prognostic classification of uterine smooth muscle tumors

- **Definition of tumor-type necrosis**

# Definition of Tumor-Type Necrosis

***Synonyms***

- **Tumor cell necrosis**
- **Tumor type necrosis**
- **Coagulative necrosis**
- **Coagulative tumor cell necrosis**
- **Necrosis**



**Leiomyosarcoma or STUMP**

***Synonyms***

- **Tumor cell necrosis**
- **Tumor type necrosis**
- **Coagulative necrosis**
- **Coagulative tumor cell necrosis**
- **Necrosis**

**Leiomyosarcoma or STUMP**

***Synonyms***

- **Ischemic necrosis**
- **Hyalin necrosis**
- **Degenerative necrosis**
- **Benign necrosis**
- **Necrosis**

**Benign**

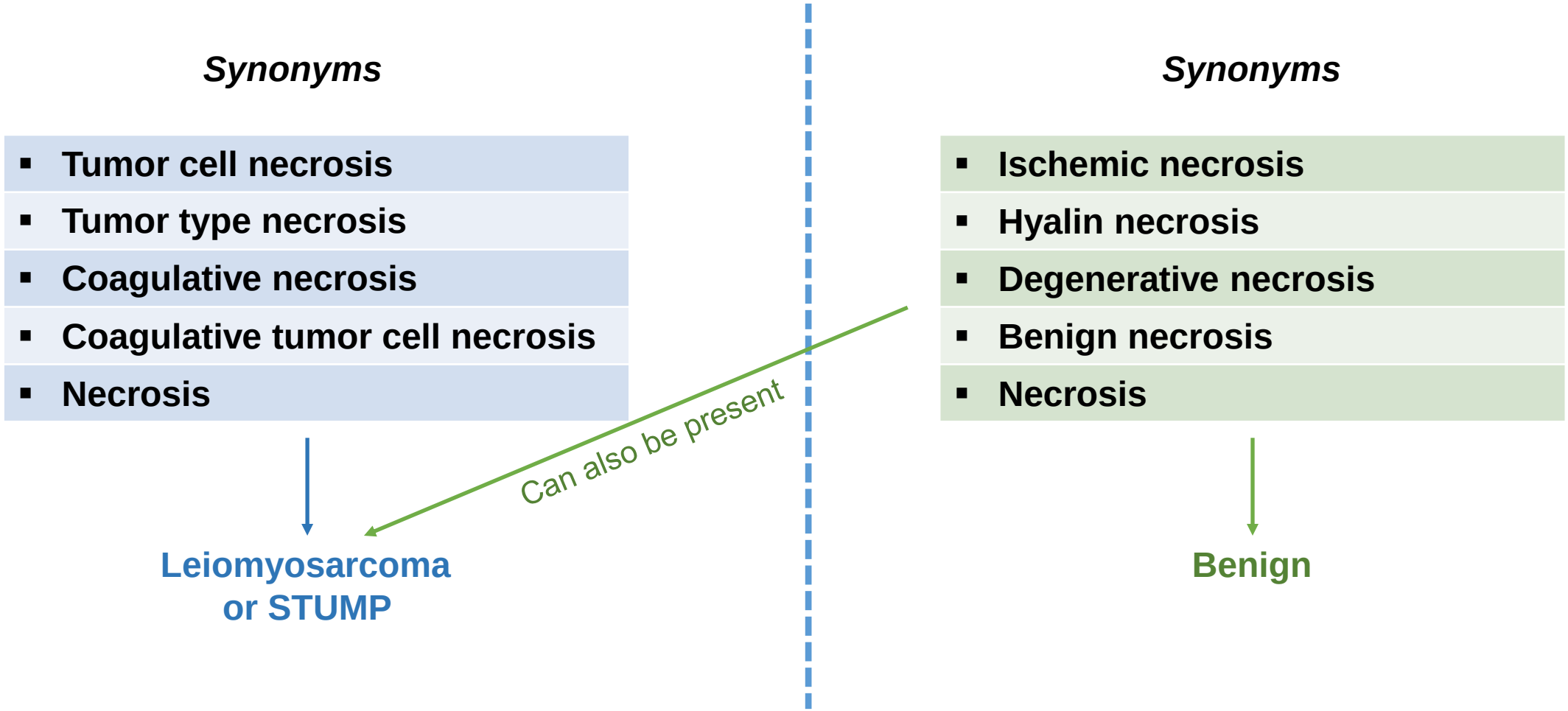
Synonyms
Tumor cell necrosis
Tumor type necrosis
Coagulative necrosis
Coagulative tumor cell necrosis
Necrosis
Leiomyosarcoma
or STUMP
Can also be present
Synonyms
Ischemic necrosis
Hyalin necrosis
Degenerative necrosis
Benign necrosis
Necrosis
Benign

# Definition of Tumor-Type Necrosis

*Landmark outcome-based study*

The American Journal of Surgical Pathology *18(6): 535–558, 1994*
© 1994 Raven Press, Ltd., New York

## Problematic Uterine Smooth Muscle Neoplasms

### A Clinicopathologic Study of 213 Cases

Stephen W. Bell, M.D., Richard L. Kempson, M.D., and
Michael R. Hendrickson, M.D.

PMID: 8179071

# Definition of Tumor-Type Necrosis

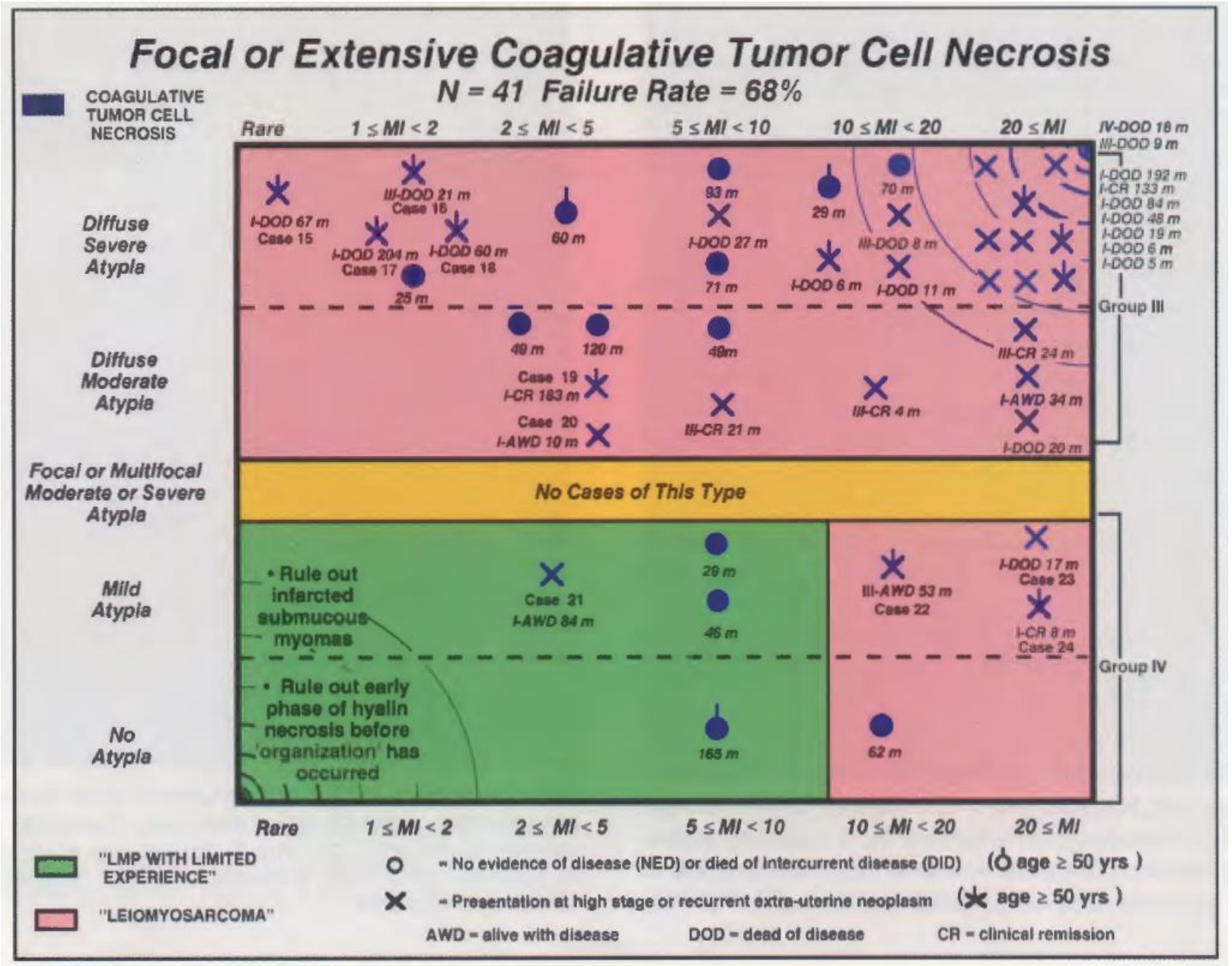


PMID: 8179071

# Definition of Tumor-Type Necrosis

*Stanford study definition:*

***Essential criteria:***

- **Abrupt transition between viable and necrotic cells**
- **No intervening zone of granulation tissue or hyalinized tissue**

***Non-essential features:***

- **Ghost outlines of tumor cells**
- **Peritheliomatous pattern of viable cells**

***Not criteria in isolation:***

- **Individual pyknotic cells**
- **Hemorrhage**

PMID: 8179071

# Definition of Tumor-Type Necrosis

*Direct interface between viable and non-viable tumor without intervening granulation tissue*

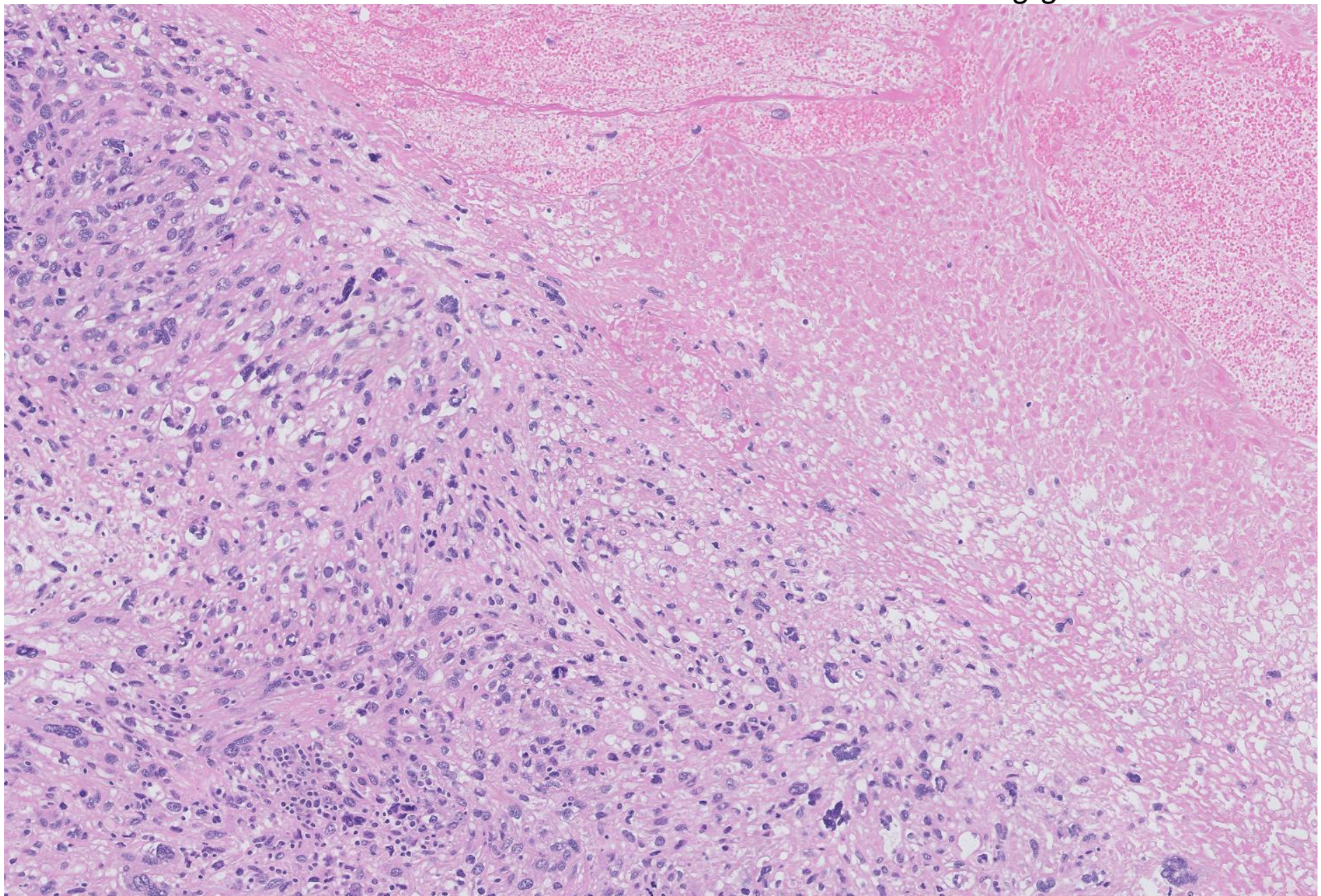

# Definition of Tumor-Type Necrosis

*Direct interface between viable and non-viable tumor without intervening granulation tissue*

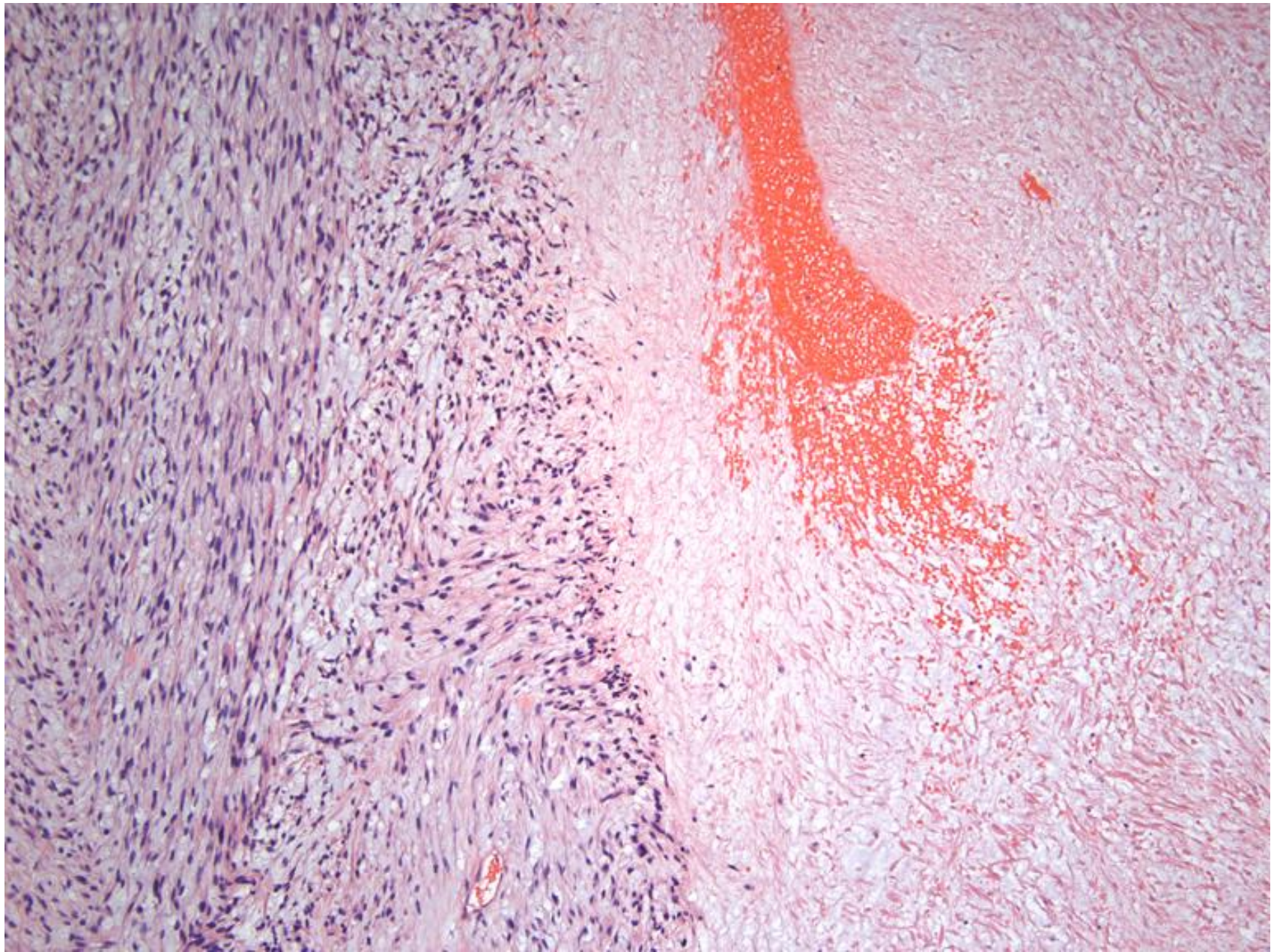

# Definition of Tumor-Type Necrosis

***Geographic pattern**: irregularly undulating contours of necrotic zones*

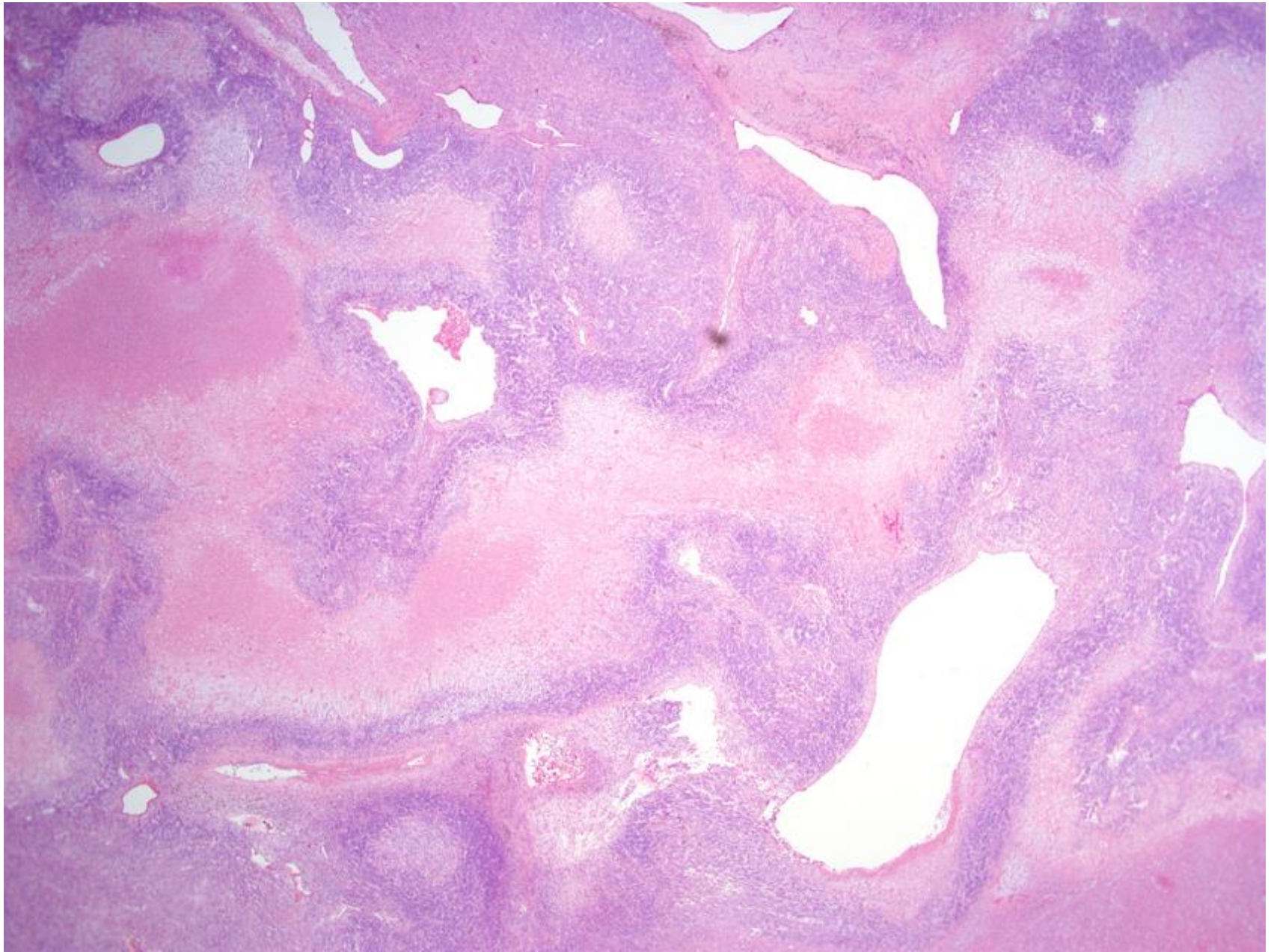

# Definition of Tumor-Type Necrosis

***Geographic pattern**: irregularly undulating contours of necrotic zones*

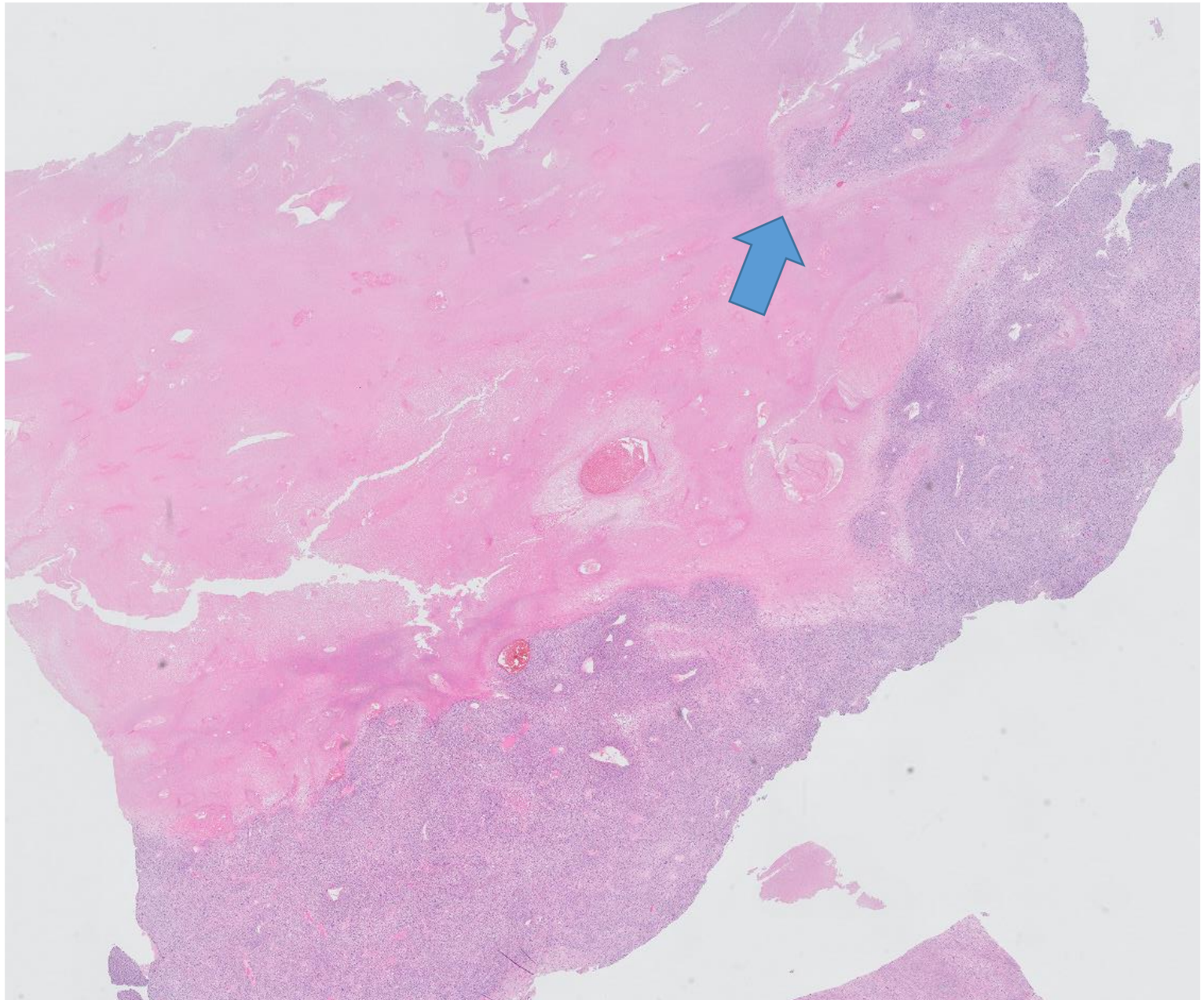

# Definition of Tumor-Type Necrosis

***Peritheliomatous pattern**: viable tumor cells clinging around blood vessels in a sea of necrosis*

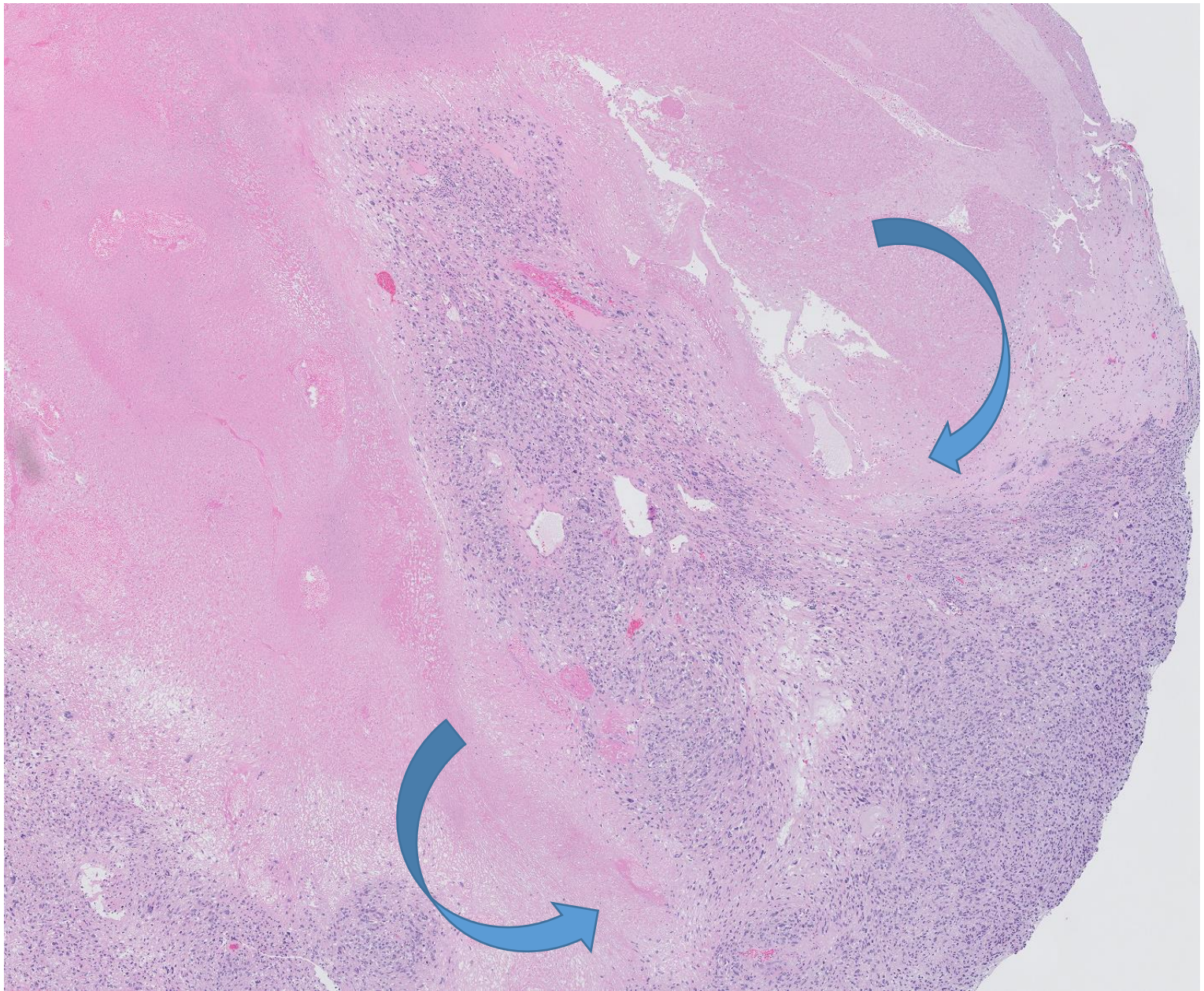

# Definition of Tumor-Type Necrosis

***Peritheliomatous pattern**: viable tumor cells clinging around blood vessels in a sea of necrosis*

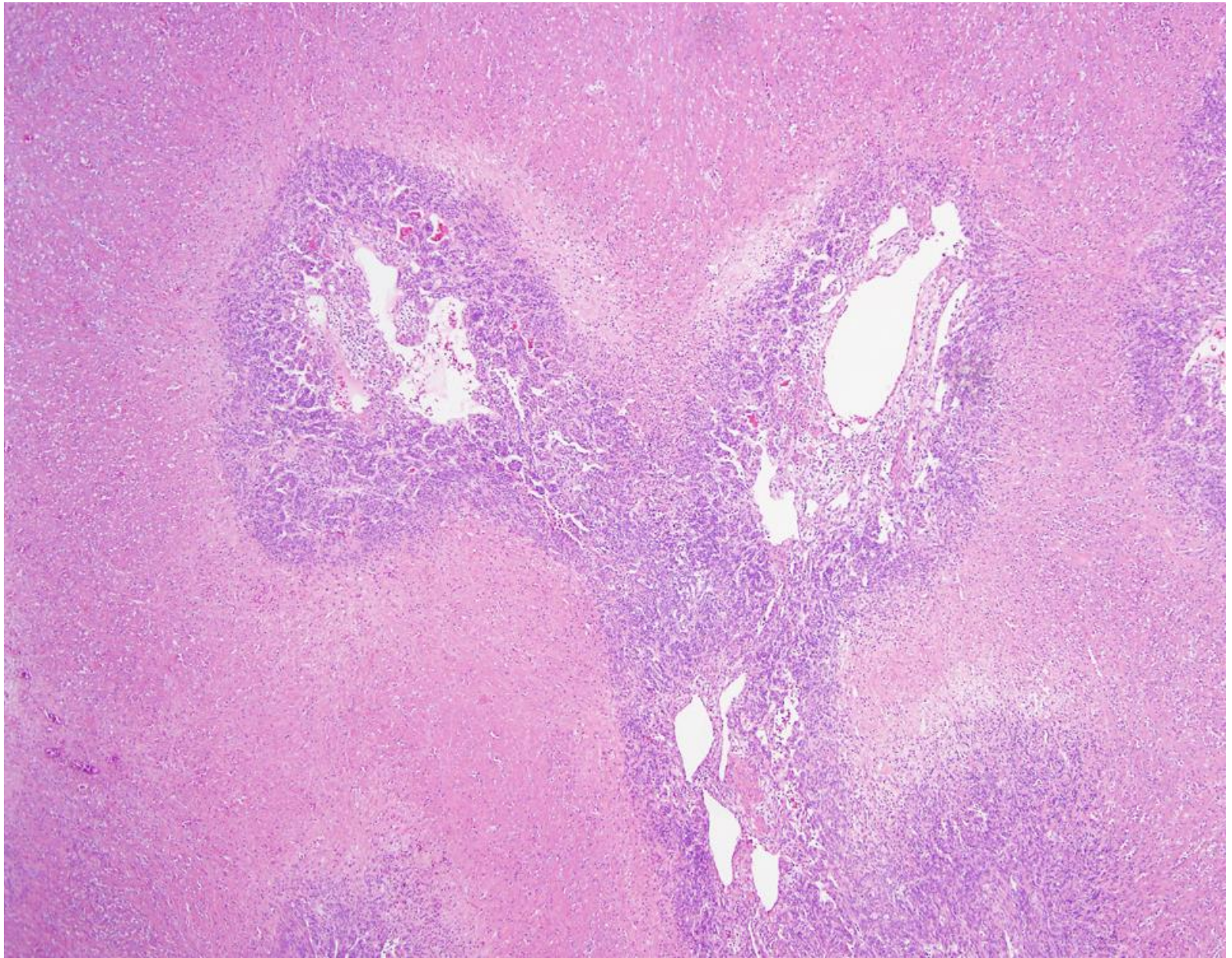

# Definition of Tumor-Type Necrosis

***Peritheliomatous pattern**: viable tumor cells clinging around blood vessels in a sea of necrosis*

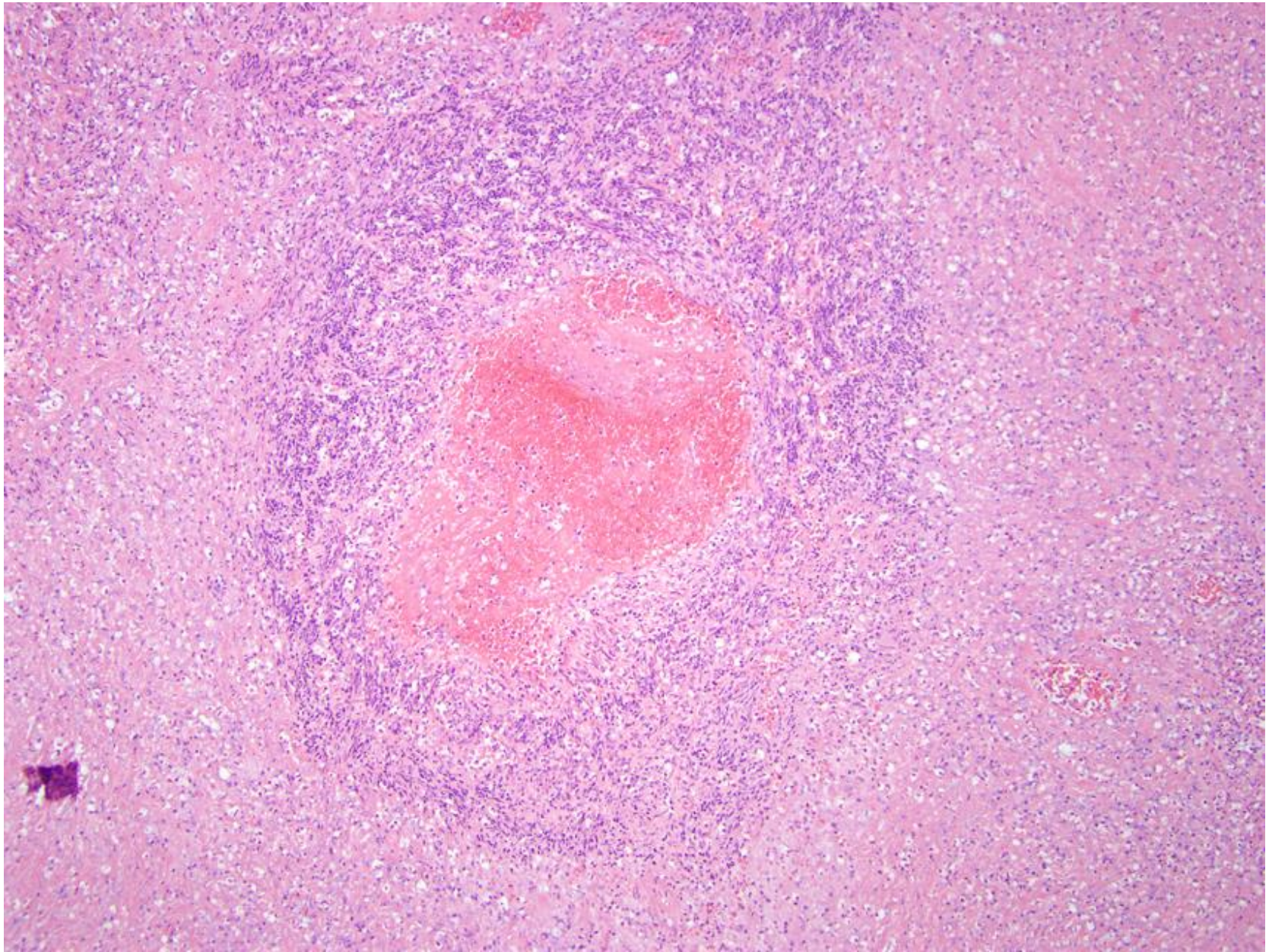

## Definition of Tumor-Type Necrosis

*Ghost outlines of tumor cells in necrotic tissue*

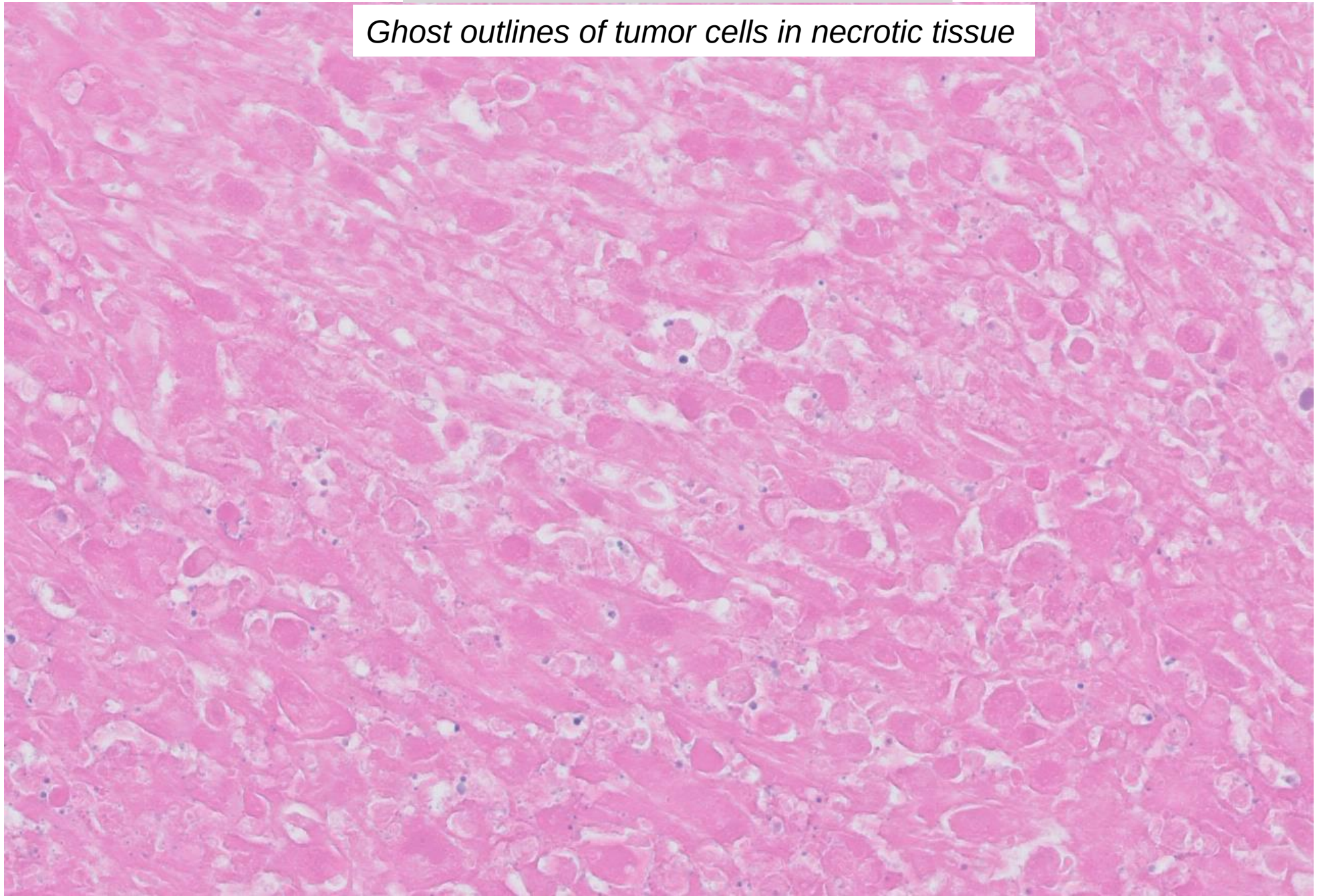

# Definition of Tumor-Type Necrosis

*Rare ghost outlines of tumor cells in necrotic tissue*

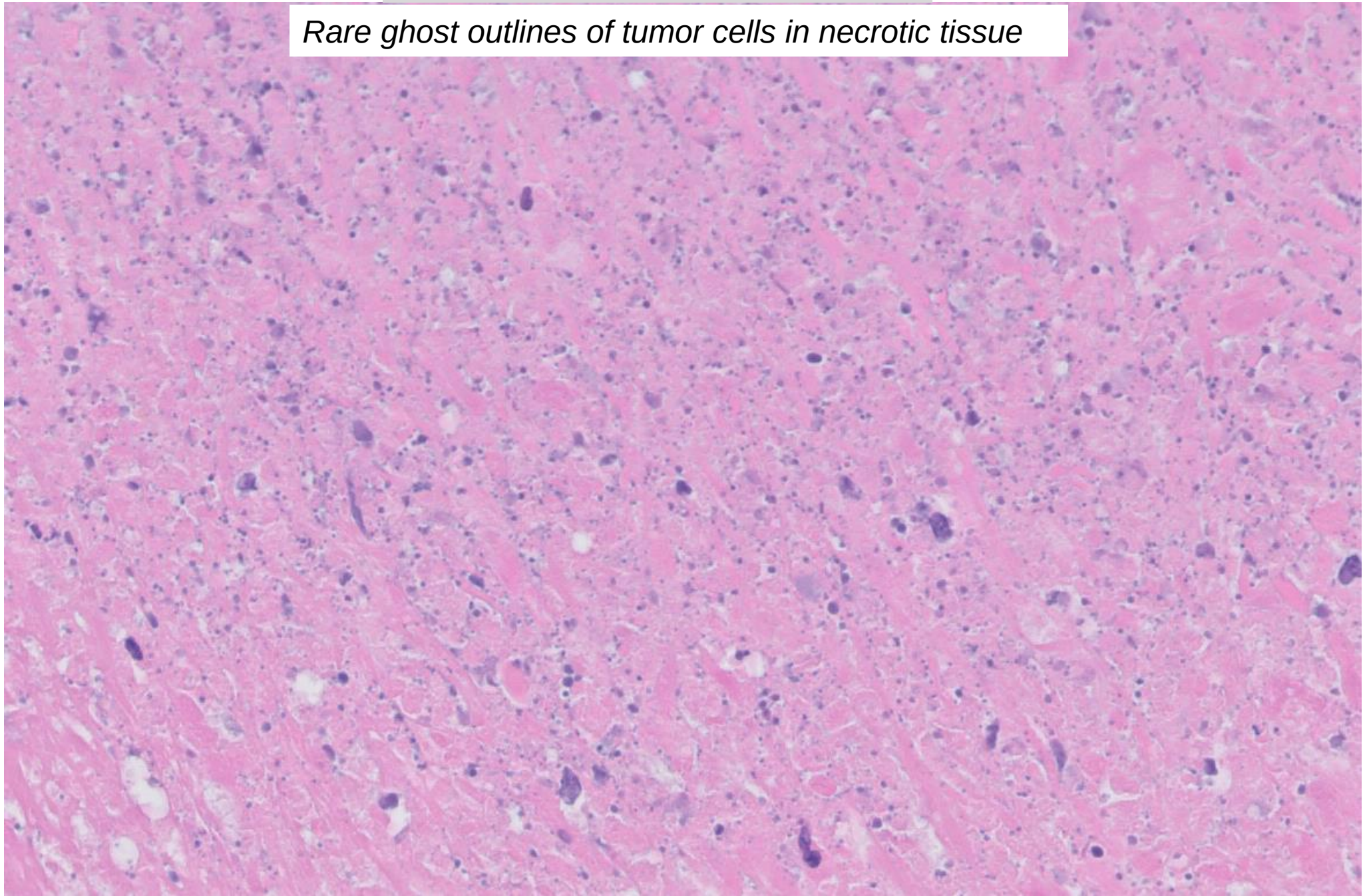

# Definition of Tumor-Type Necrosis

*Ghost outlines of blood vessels in necrotic tissue*

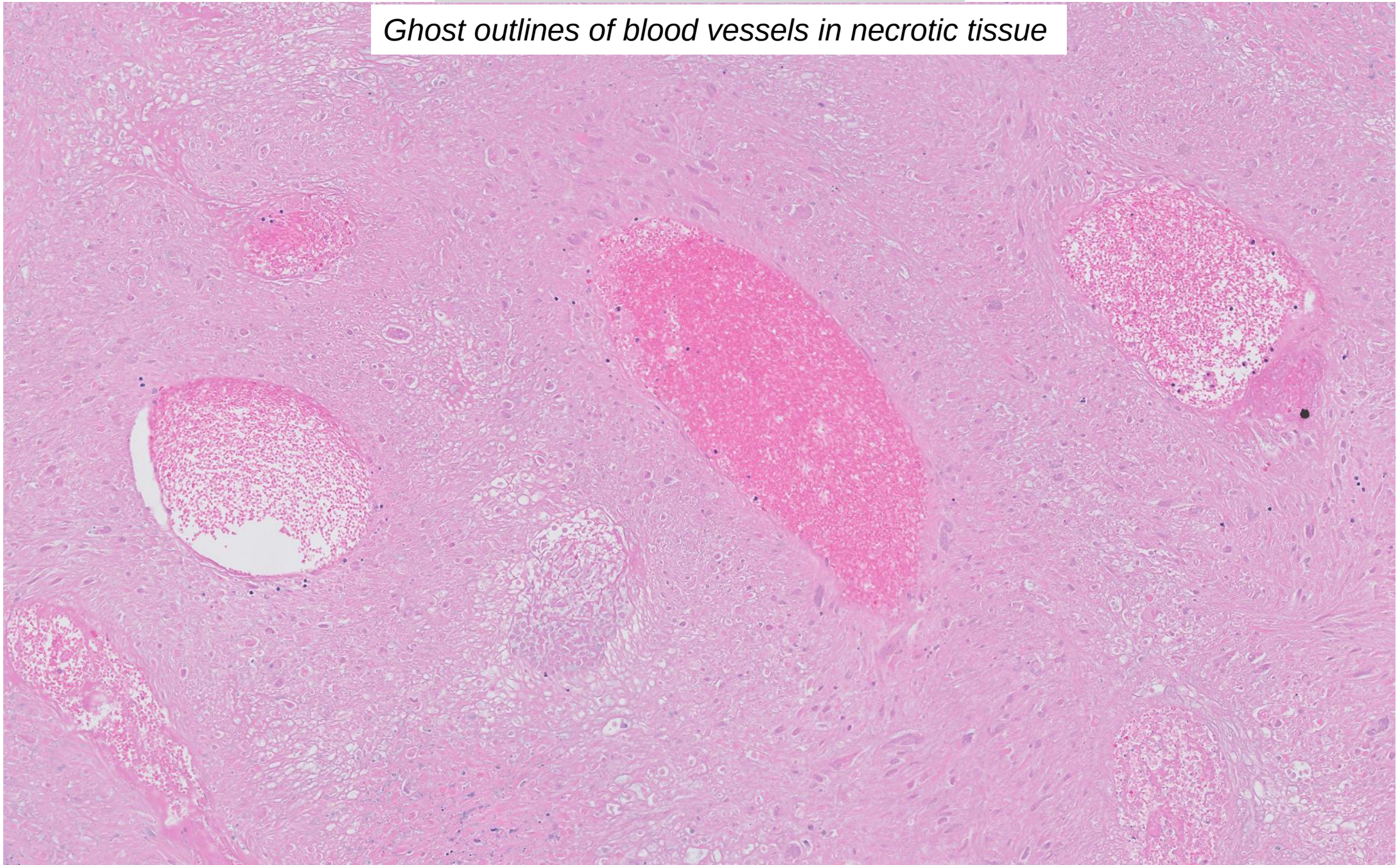

## Definition of Tumor-Type Necrosis

*Can granulation tissue be present in uterine leiomyosarcoma ?*

- **Yes, focally.**
  - **Granulation tissue does not exclude the diagnosis of leiomyosarcoma**
    *as long as the WHO criteria for sarcoma are fulfilled*

- **<u>Practical recommendation</u>:**
  - **Extensive tissue sampling is advised to maximize certainty of interpretation.**
  - **Correlate with evaluation of atypia and mitotic index**

# Outline of Talk

- Significance of tumor-type necrosis in prognostic classification of uterine smooth muscle tumors
- Classic definition of tumor-type necrosis
- **Mimics of tumor-type necrosis**

# Mimics of Tumor-Type Necrosis in Leiomyoma

- Ischemic degeneration
- Perinodular hyalinization
- Surface ulceration
- Myxoid degeneration
- Alveolar pattern edema

# Benign Degenerative Necrosis

| Causes of Degeneration | Examples |
|---|---|
| Spontaneous ischemia | ▪ Spontaneous<br>▪ Pregnancy-associated |
| Pharmacologic therapy | ▪ Progestogens<br>▪ Oral contraceptives<br>▪ Gonadotropin-releasing hormone analogs<br>▪ Tranexamic acid |
| Minimally invasive therapy | ▪ Uterine artery embolization<br>▪ Cryotherapy ablation<br>▪ Radiofrequency thermal ablation |
| Surface ulceration | ▪ Submucosal / prolapsed fibroid |

# Benign Degenerative Necrosis

| Causes of Degeneration | Examples |
|---|---|
| Spontaneous ischemia | ▪ Spontaneous<br>▪ Pregnancy-associated |
| ★ Pharmacologic therapy | ▪ Progestogens<br>▪ Oral contraceptives<br>▪ Gonadotropin-releasing hormone analogs<br>▪ Tranexamic acid |
| ★ Minimally invasive therapy | ▪ Uterine artery embolization<br>▪ Cryotherapy ablation<br>▪ Radiofrequency thermal ablation |
| Surface ulceration | ▪ Submucosal / prolapsed fibroid |

➡ **Many patients undergo some form of fibroid treatment before myomectomy**

- ➢ Degenerative changes are therefore commonly present
- ➢ Familiarity with spectrum of degenerative changes reduces mis-interpretation as tumor type necrosis

# Benign Degenerative Necrosis

*General Features*

| | Benign |
|---|---|
| **Focality** | **Unifocal*** |
| **Contours** | **Simple** |
| **Interface with viable cells** | **Granulation tissue** |
| **Peritheliomatous growth** | **No** |
| **Atypical ghost cells** | **No** |

* *Hormone therapy can cause multifocal ischemic degeneration*

# Benign Degenerative Necrosis

*General Features*

| | Benign | Tumor-type |
|---|---|---|
| **Focality** | **Unifocal*** | **Multifocal** |
| **Contours** | **Simple** | **Geographic** |
| **Interface with viable cells** | **Granulation tissue** | **Direct / abrupt** |
| **Peritheliomatous growth** | **No** | **Yes** |
| **Atypical ghost cells** | **No** | **Yes** |

* *Hormone therapy can cause multifocal ischemic degeneration*

# Benign Degenerative Necrosis

*Single zone of necrosis*

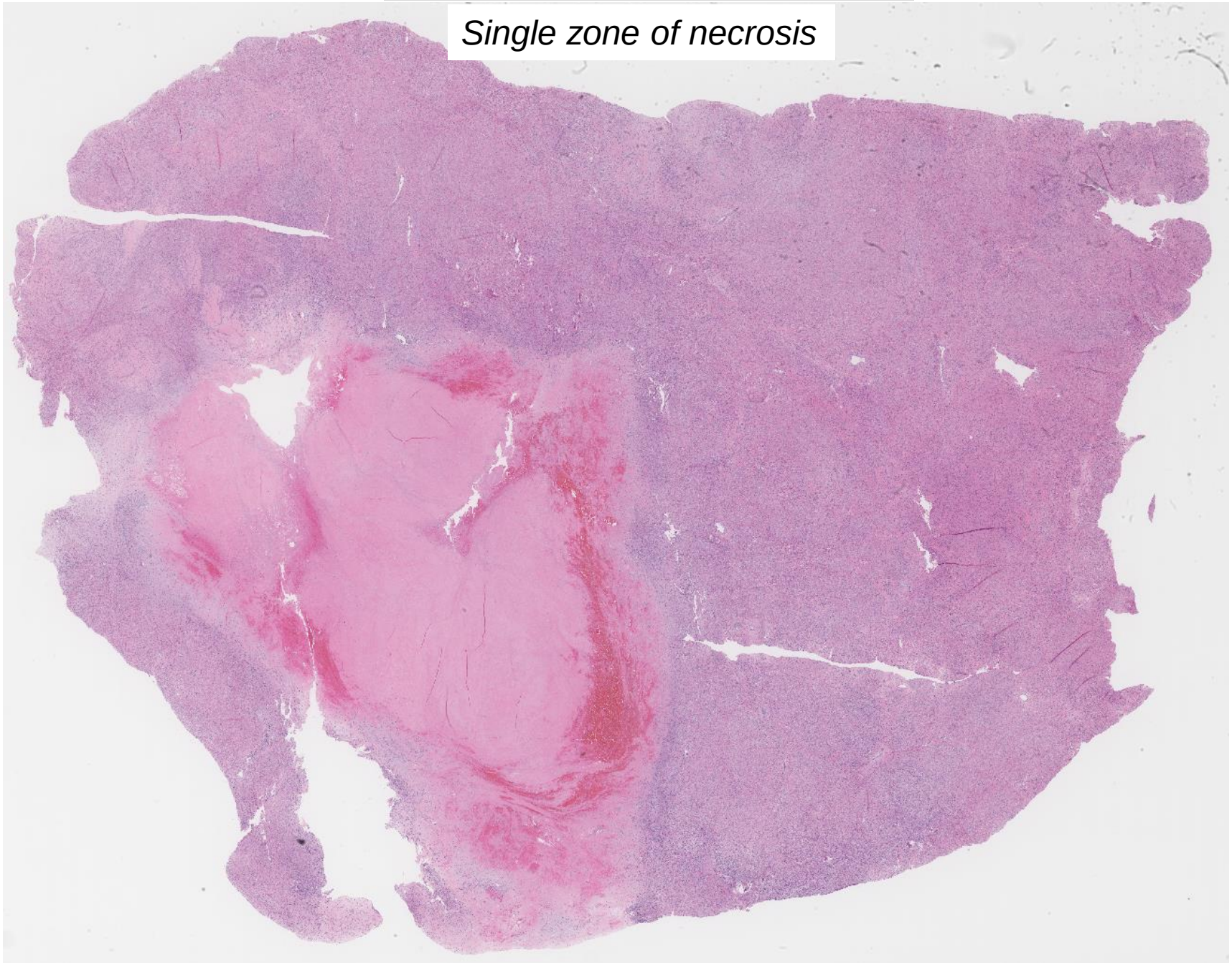

# Benign Degenerative Necrosis

*Appearance of granulation tissue is time dependent*

## Earlier Phase Granulation Tissue

| |
|---|
| **Neo-vascularization** |
| **Fibroblast proliferation** |
| **Inflammatory cells** |
| **Histiocytes** |
| **Hemorrhage** |

## Later Phase Granulation Tissue

| |
|---|
| **Hyalinization / fibrosis** |
| **Minimal vessels, fibroblasts, inflammation** |

# Benign Degenerative Necrosis

*Granulation tissue between viable and non-viable cells*

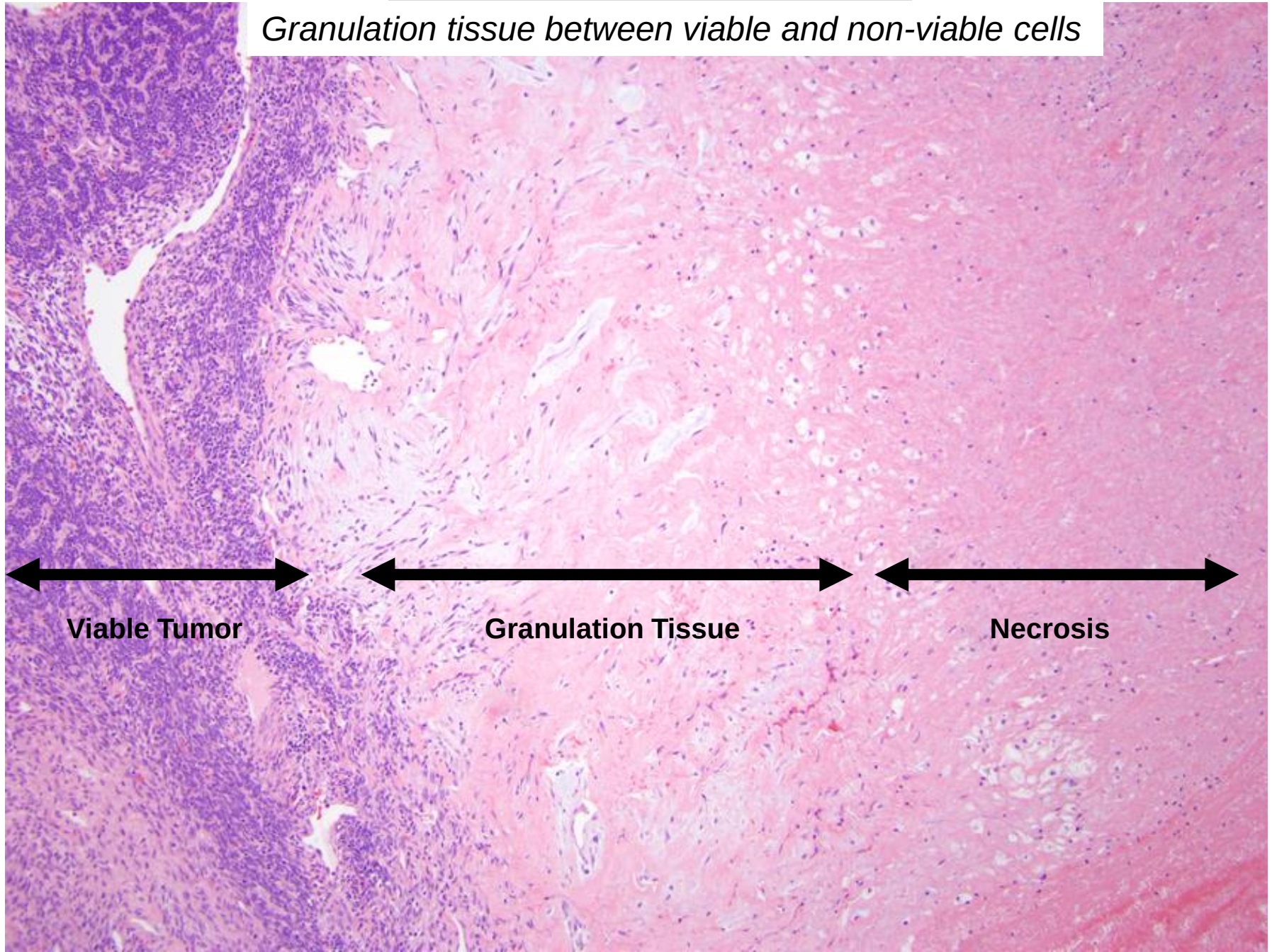

# Benign Degenerative Necrosis

*Early granulation tissue:  neovascularization*

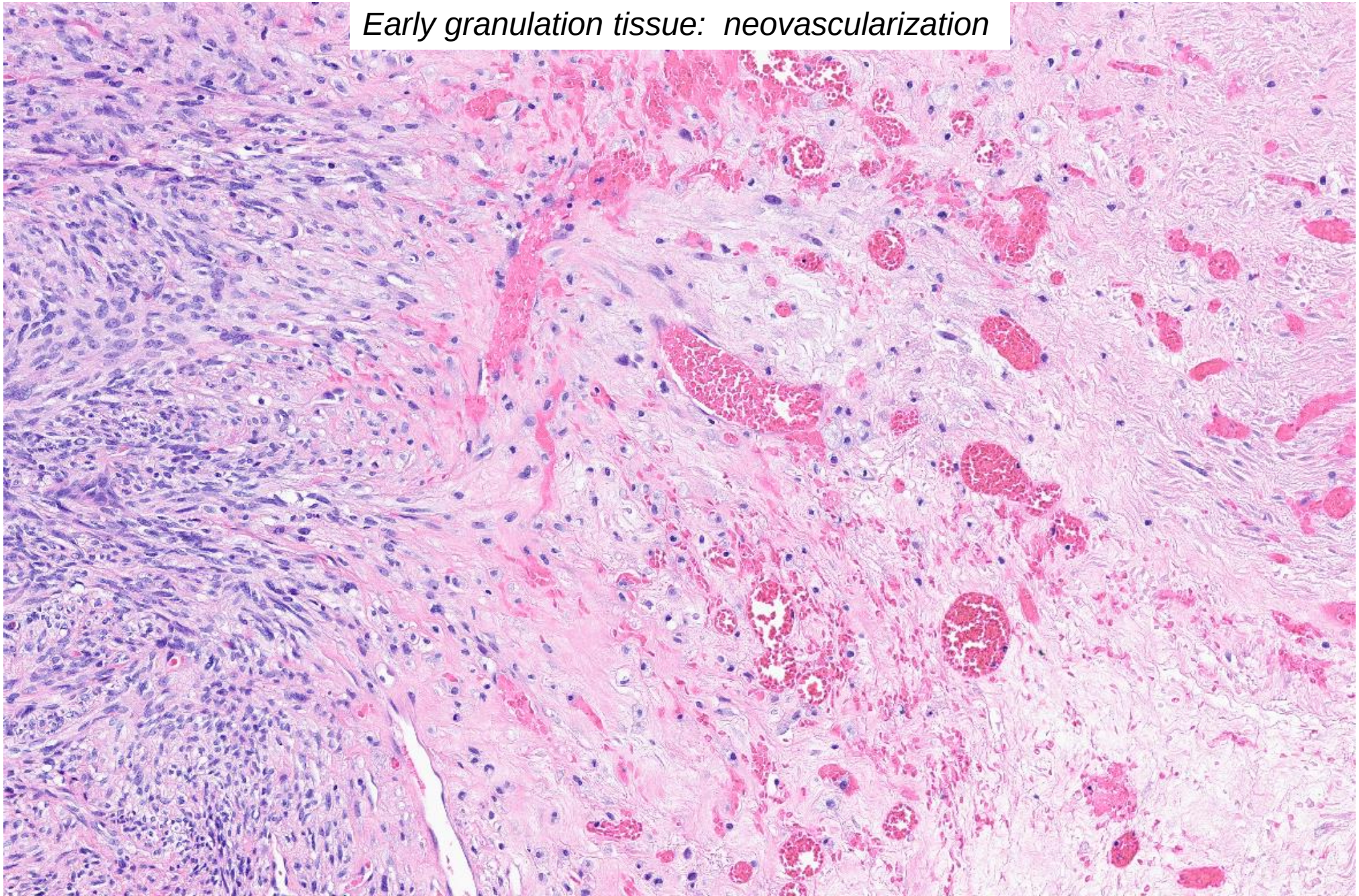

# Benign Degenerative Necrosis

*Granulation tissue:  vessels, fibroblasts, collagen*

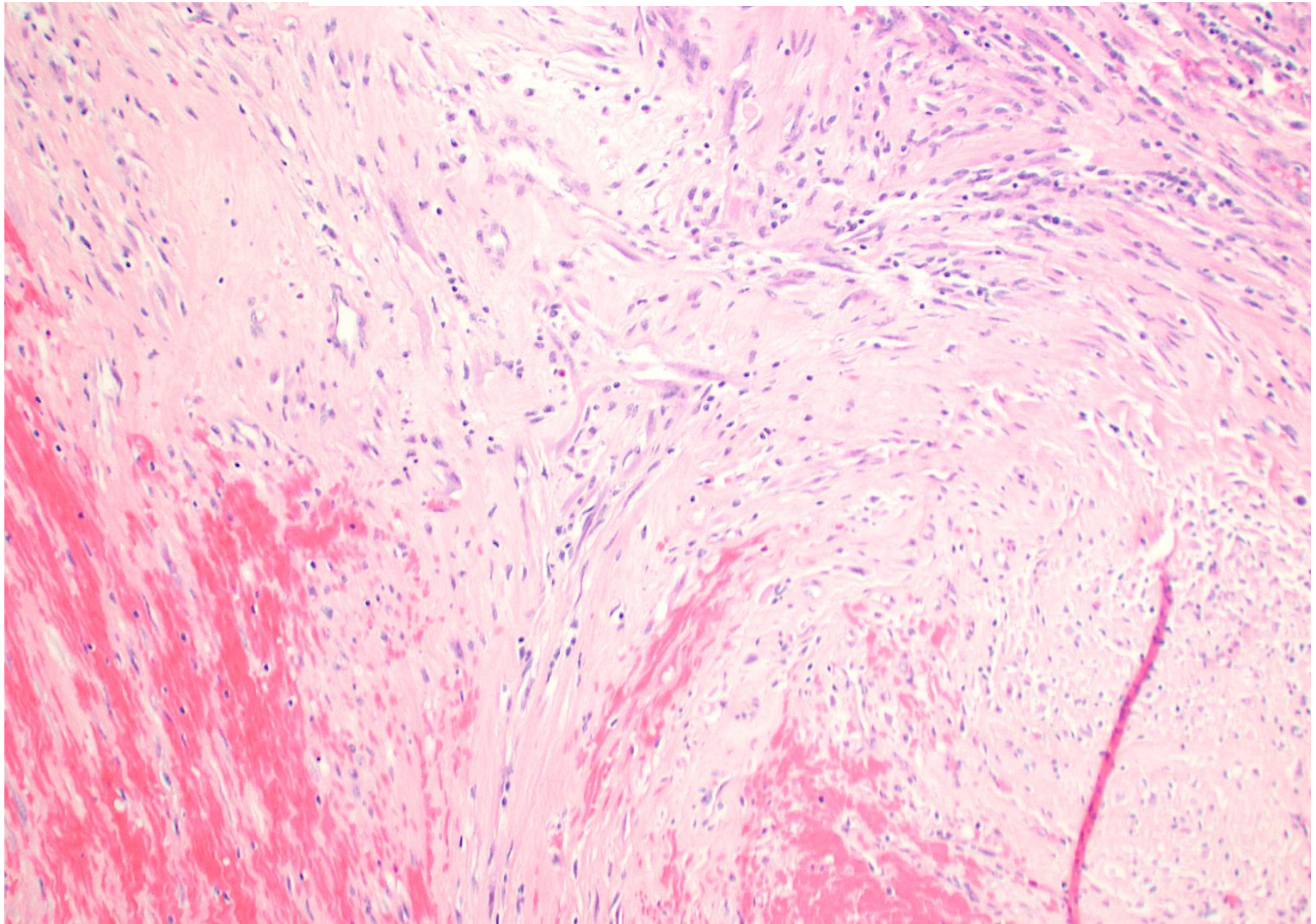

**Benign Degenerative Necrosis**

*Hemorrhagic granulation tissue*

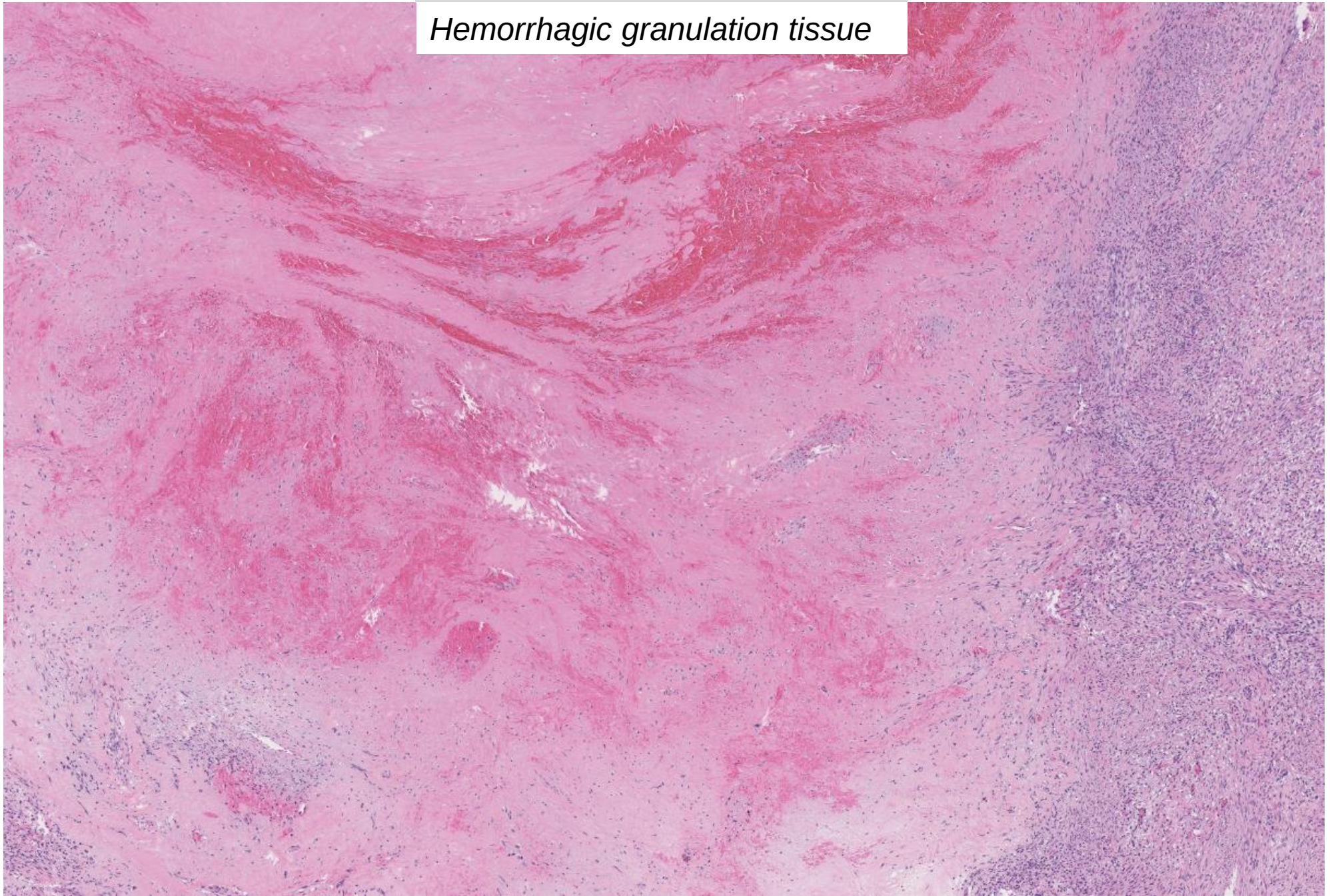

# Benign Degenerative Necrosis

*General Features*

| | Benign | Exceptions to the rule |
|---|---|---|
| **Focality** | **Unifocal** | **Multifocal degeneration due to hormonal alterations** |
| Contours | Simple | |
| Interface with viable cells | Granulation tissue | |
| Peritheliomatous growth | No | |
| Atypical ghost cells | No | |



# Benign Degenerative Necrosis

*Hormone Associated Changes*

## Clinical Context

- **Pregnancy**
- **Progestins**

| Indication |
| --- |
| Contraception |
| Endometriosis |
| Menorrhagia |
| Hormone replacement |

- **Gonadotropin releasing hormone agonists**

| Indication |
| --- |
| Fibroid management |

## Historical Terminology

- **“Red-degeneration”**
- **Apoplectic leiomyoma**

PMID: 21398323, 14615835, 8604809, 26685083

# Benign Degenerative Necrosis

*Hormone Associated Changes*

## Spectrum & extent of features

- **Depends on type, dose, and duration of hormone exposure**

## Growth patterns

- Early: **Single or multiple stellate microscopic foci of degeneration**
- Later: **Larger zones of degeneration, hemorrhage, cystic change**
  - *Peripheral rim of hypercellularity and mitoses*
- **Stroma: edema, myxoid features, hemorrhage or hyalinization**

## Cytologic features

- **“Shrunken” appearance**
- **Bright eosinophilic / epithelioid cytoplasm**
- **Pyknotic nuclei**

## Uncommon features

- **Lymphocytic infiltrate**
- **Vasculitis**

PMID: 21398323, 14615835, 8604809, 26685083

# Progestin-Associated Necrosis in Leiomyoma

*Multifocal microscopic foci of degeneration*

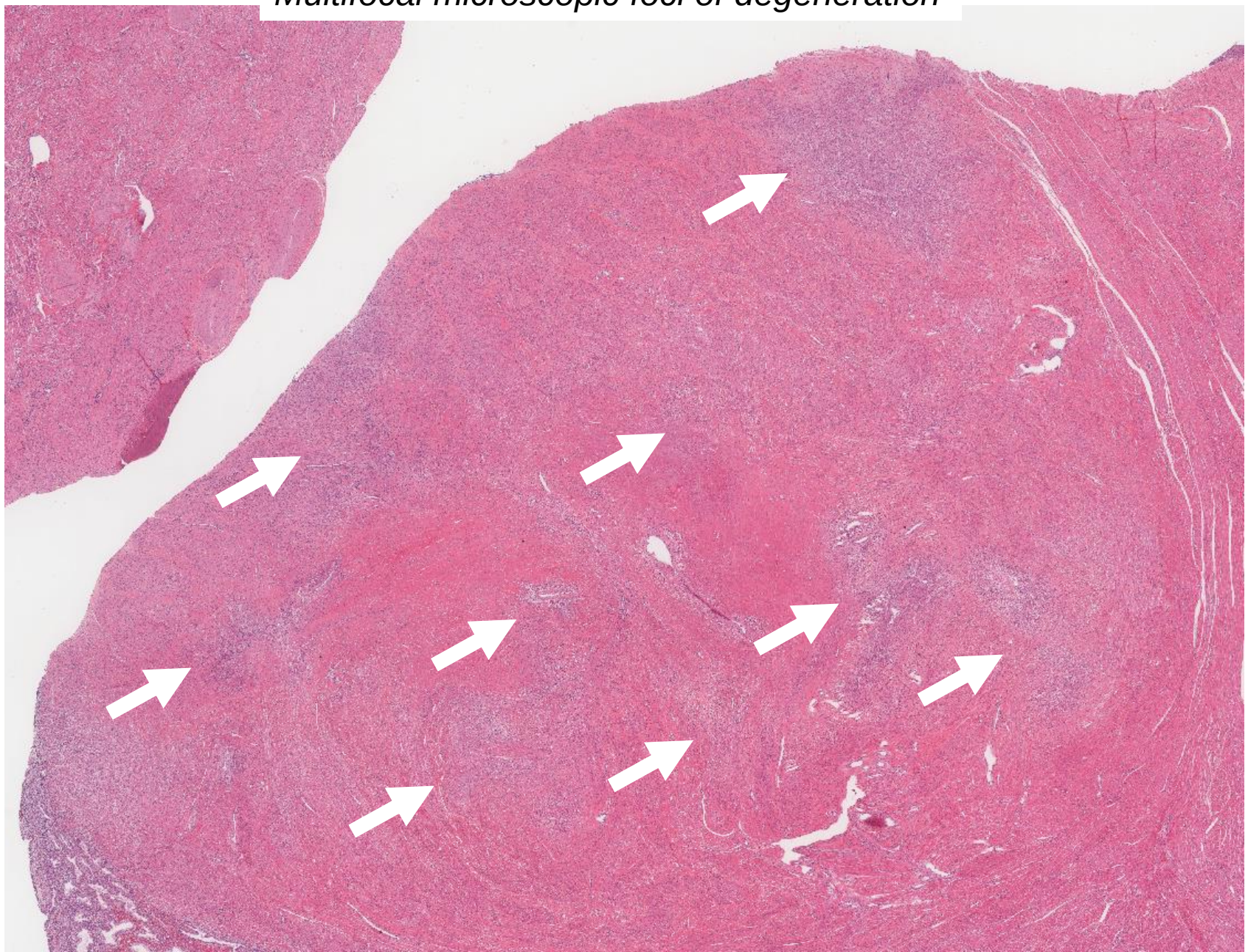

# Progestin-Associated Necrosis in Leiomyoma

*Stellate microscopic focus of necrosis with hypercellular rim*

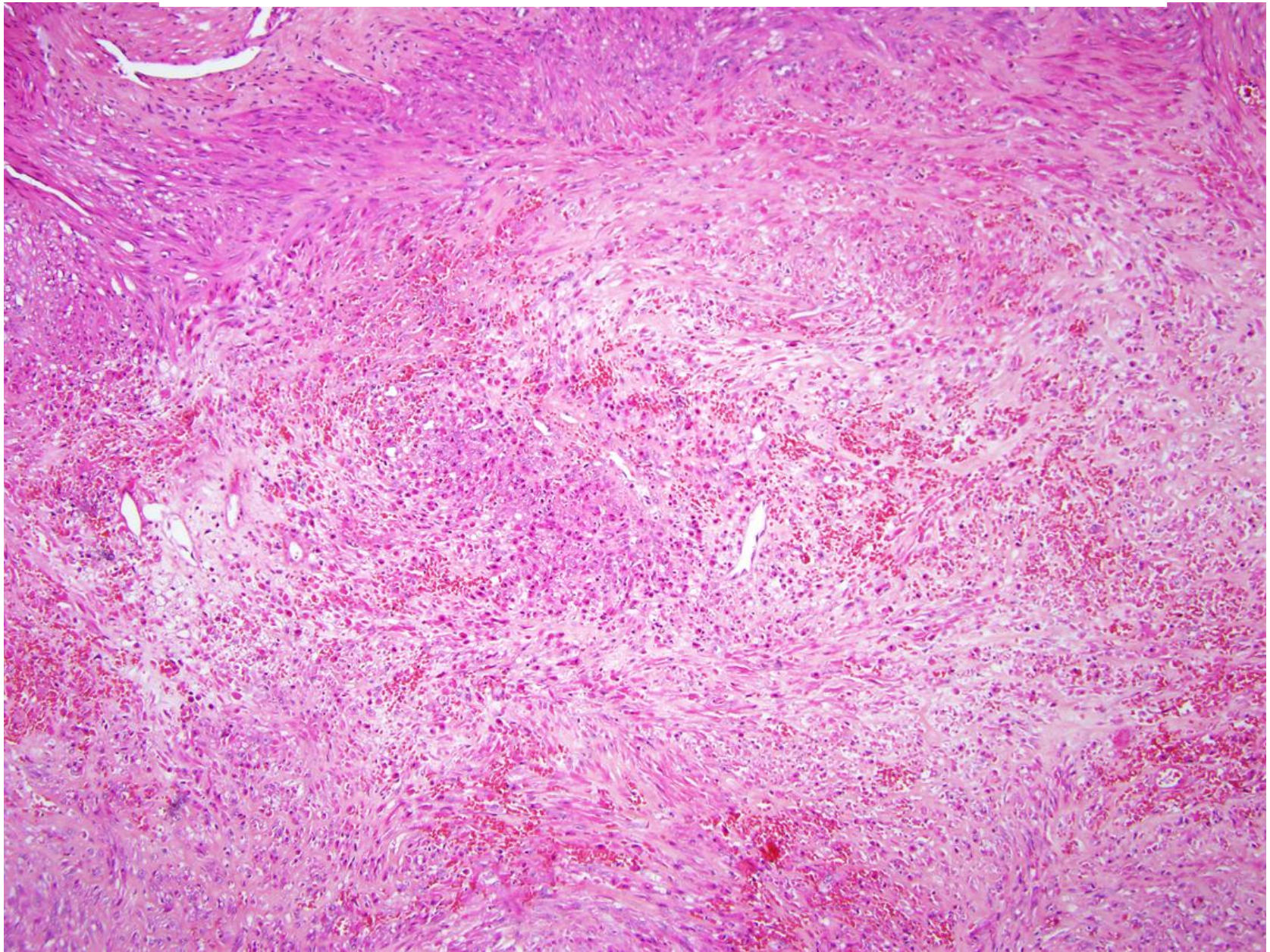

# Progestin-Associated Necrosis in Leiomyoma

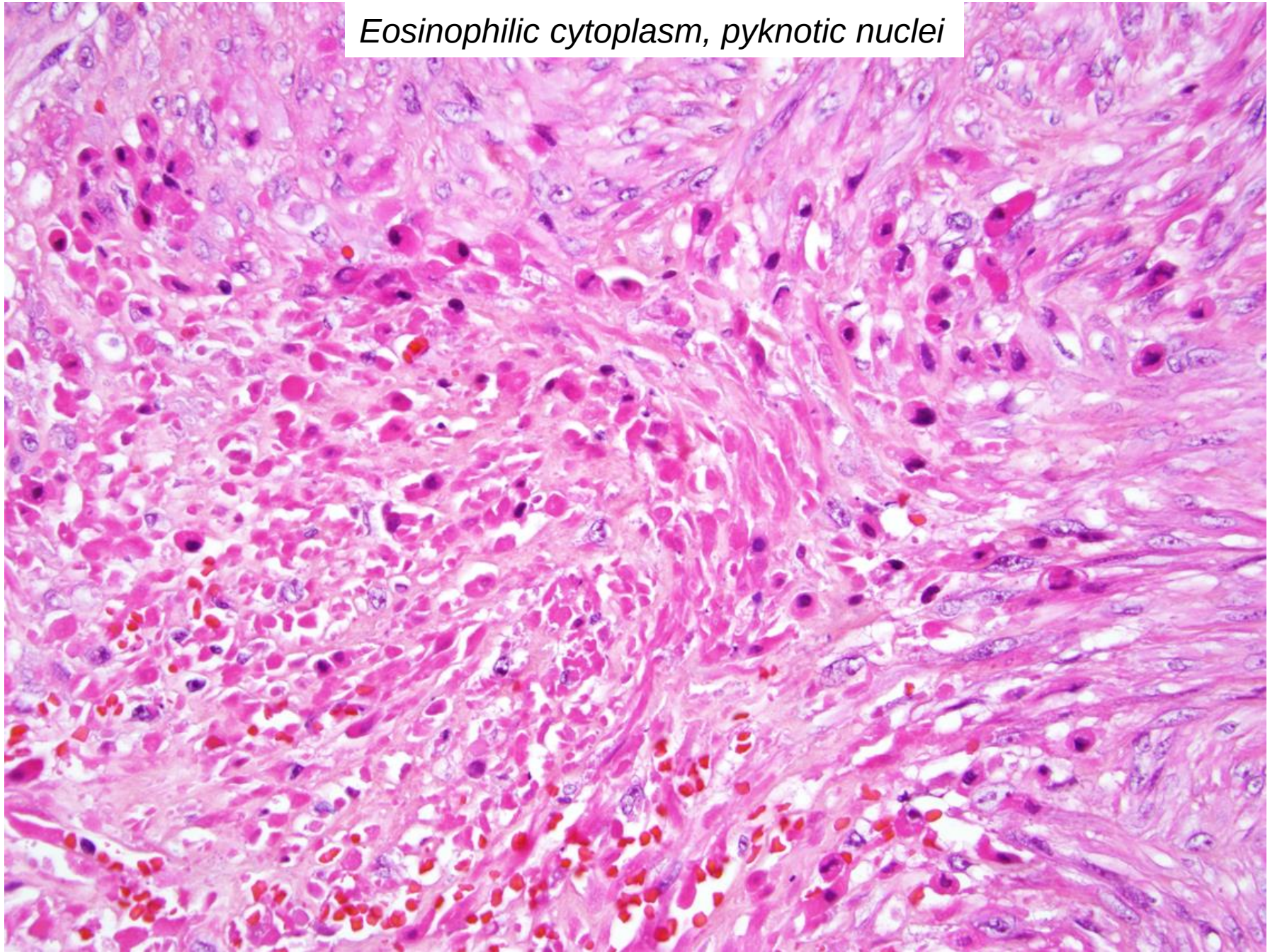

# Progestin-Associated Pyknosis in Leiomyoma

- *Diffuse “shrunken” pyknotic cells without necrosis*
- *Pitfall for classifying as “epithelioid” smooth muscle tumor*

*(overdiagnosis as STUMP/sarcoma)*

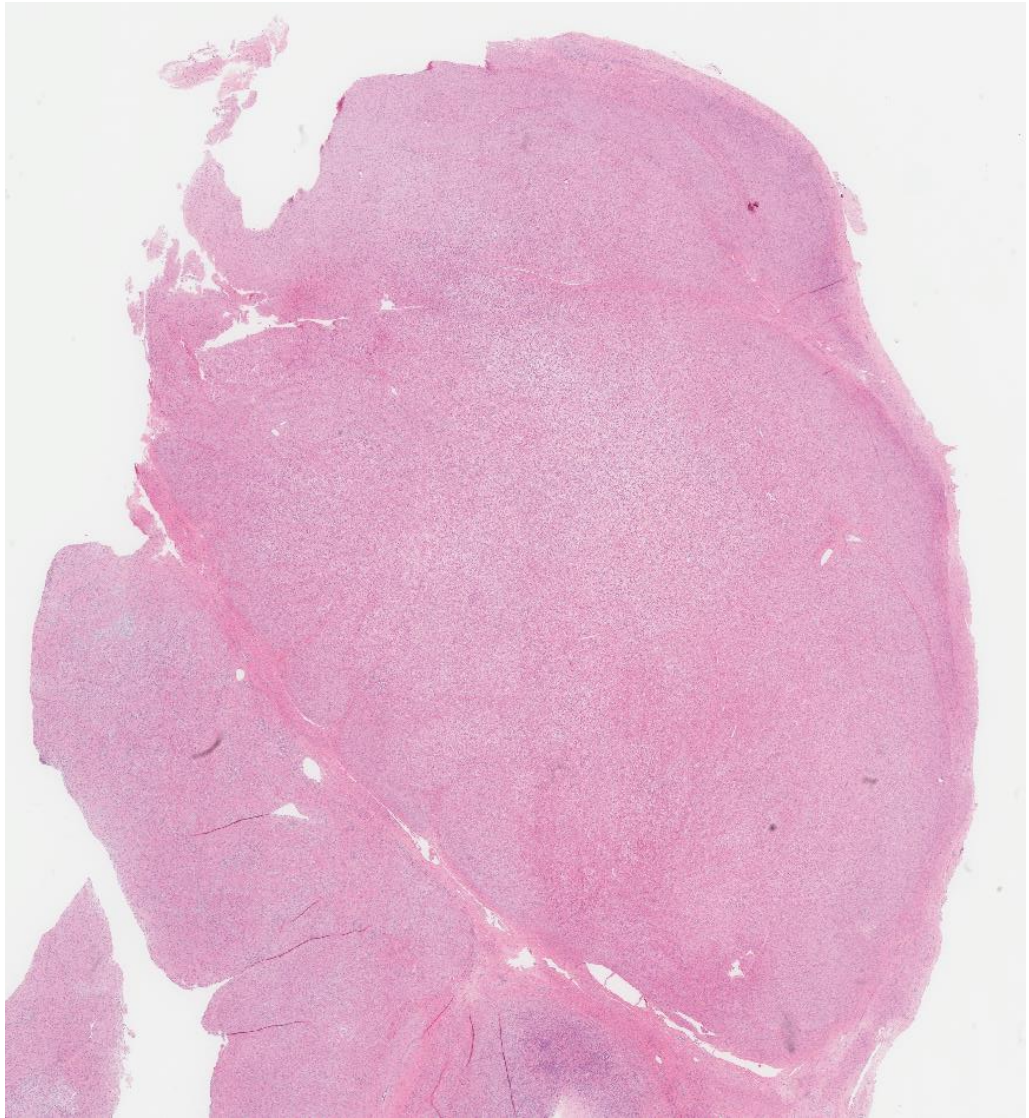

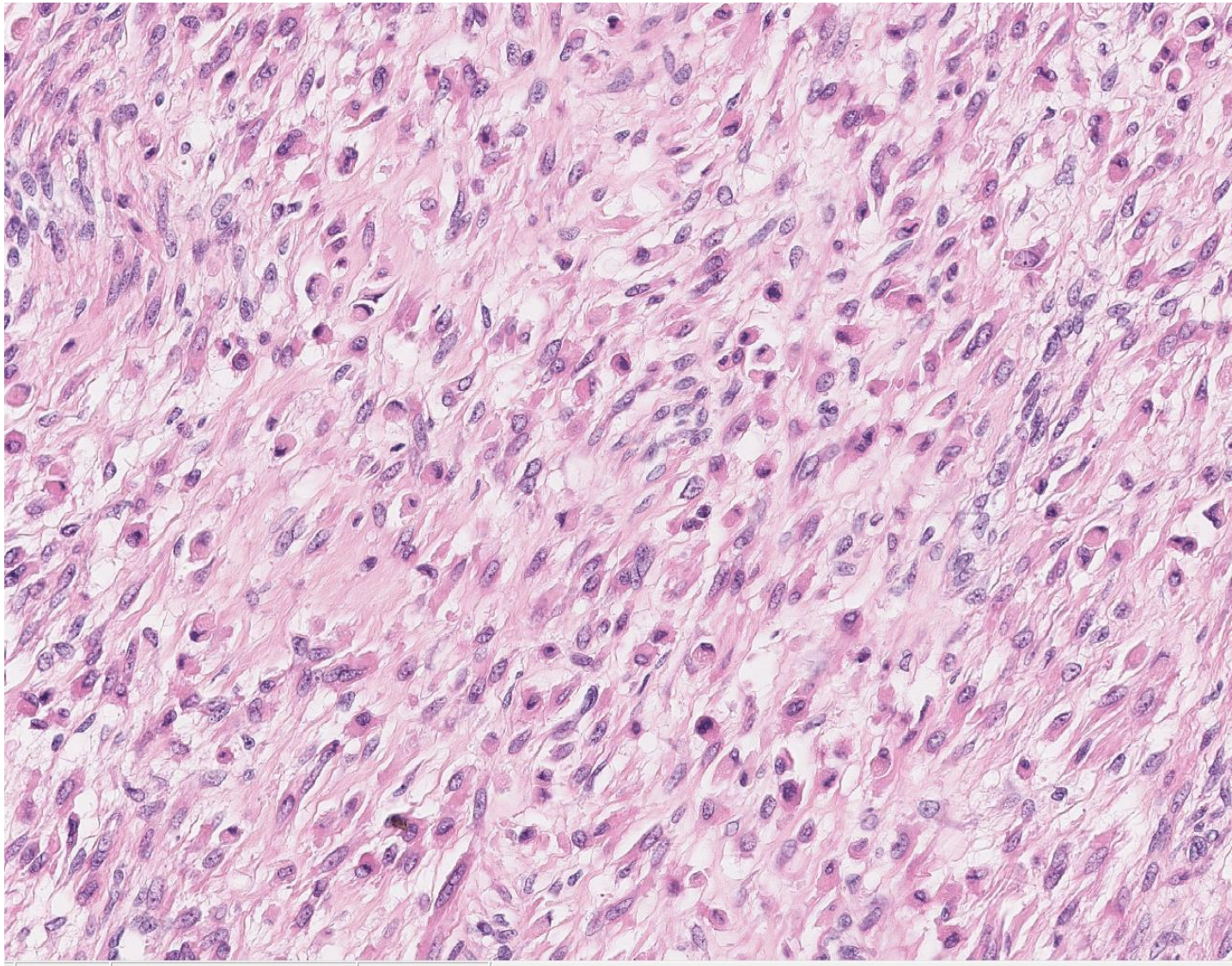

# Benign Degenerative Necrosis

*Minimally-invasive Treatment Changes*

## Uterine Artery Embolization

- **Ischemic degeneration**
- **Intravascular embolic material**
- **Perivascular foreign body reaction**

## Cryotherapy ablation

- Histopathology not well described

## Radiofrequency thermal ablation

- Histopathology not well described

# Uterine Artery Embolization of Leiomyoma

*Intravascular gelatin microspheres and foreign body giant cell reaction*

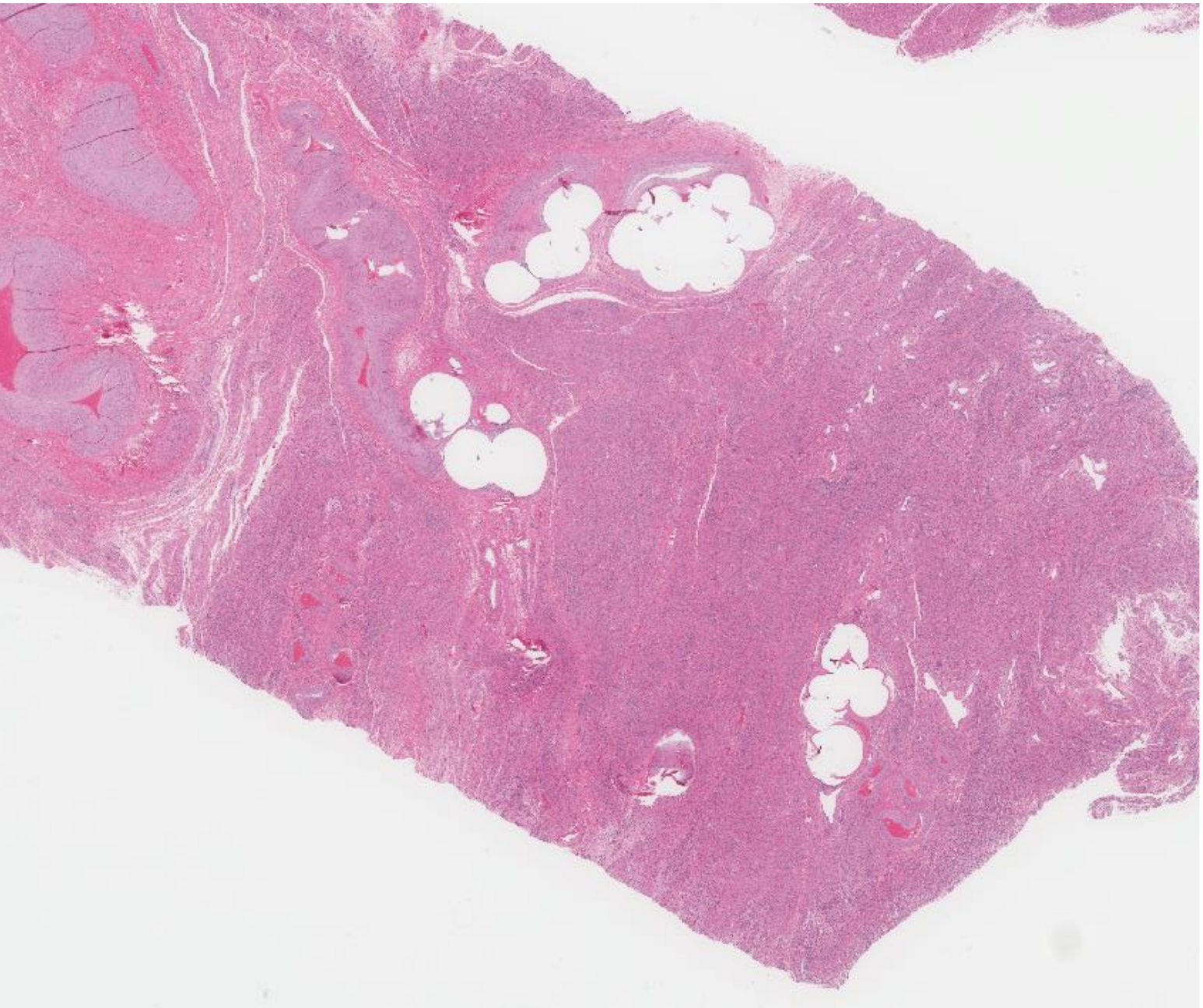

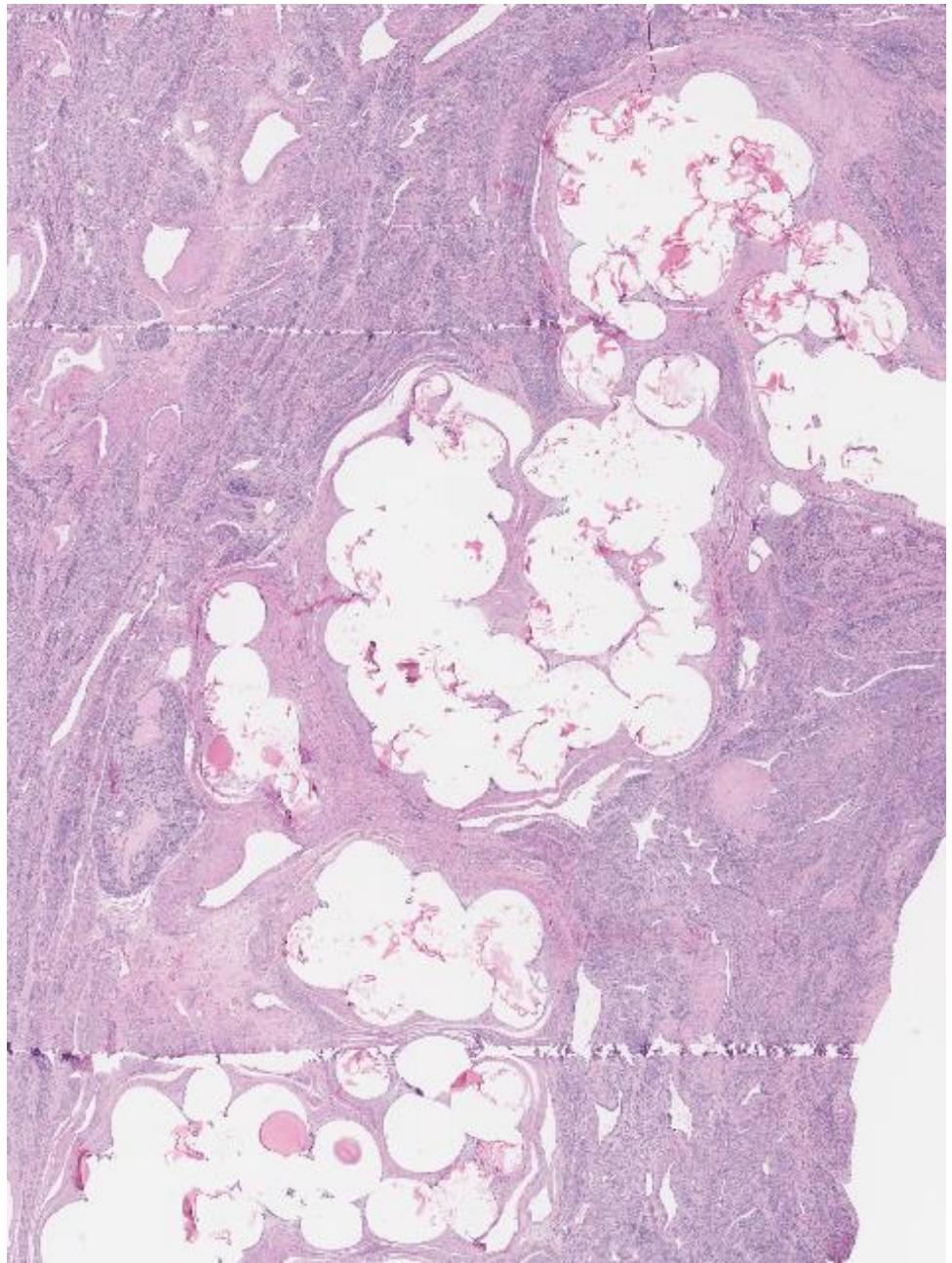

# Uterine Artery Embolization of Leiomyoma

*Intravascular gelatin microspheres and foreign body giant cell reaction*

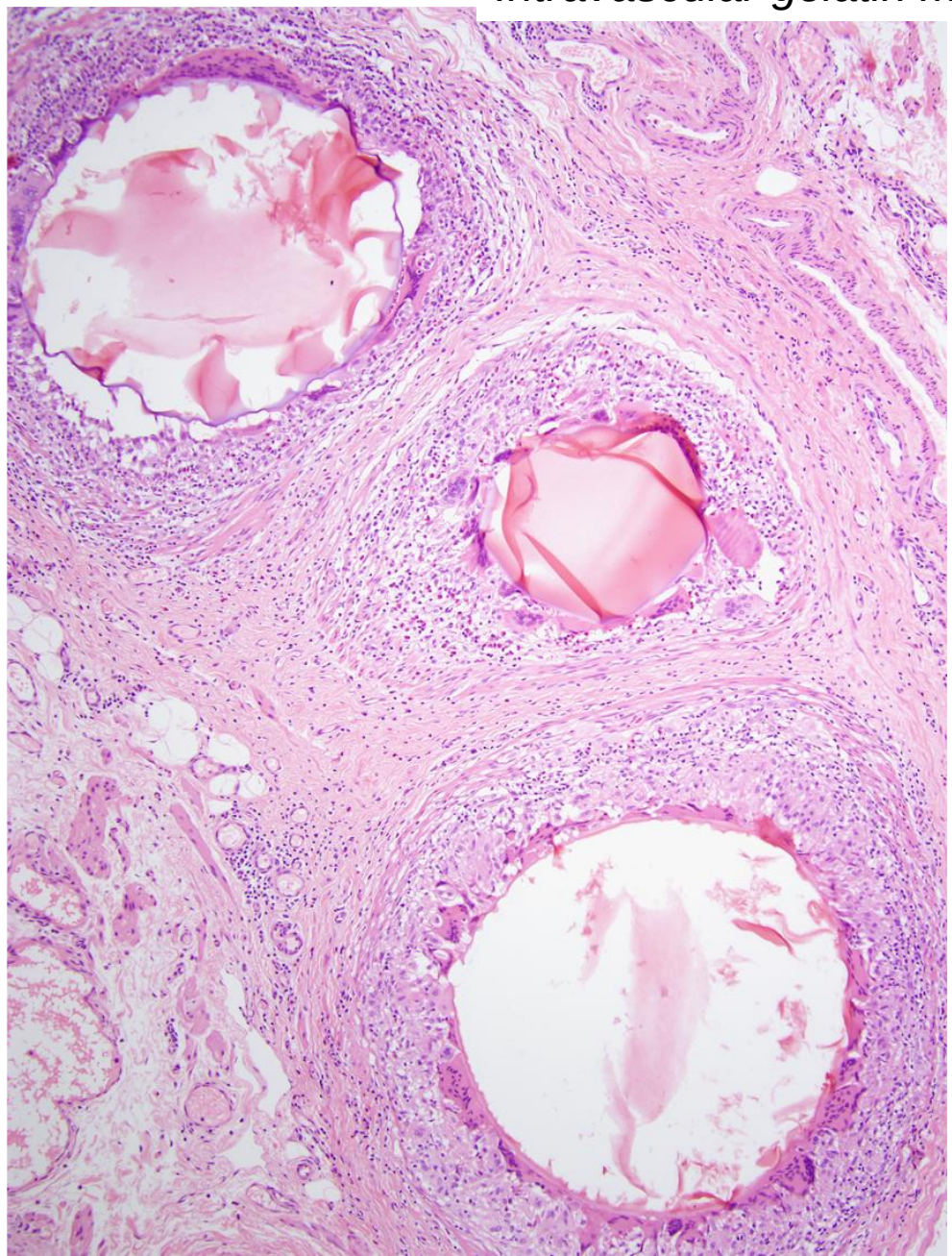

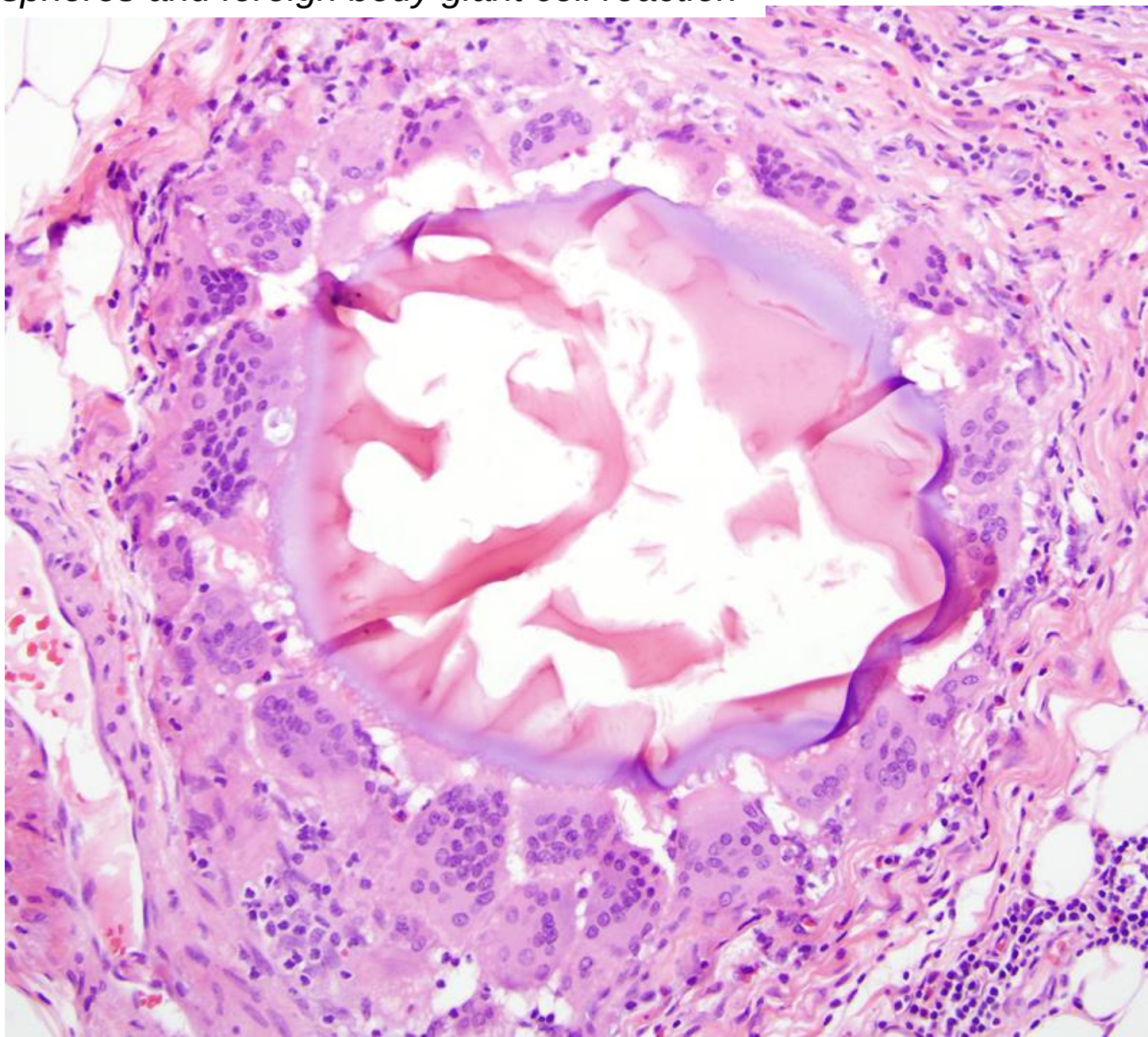

# Benign Degenerative Necrosis

*Other Types of Pharmacologic-associated Changes*

## Tranexamic acid therapy

- **Non-hormonal option to control menorrhagia**
- **Synthetic derivative of amino acid lysine**
  - Reversibly blocks lysine-binding sites on plasminogen, inhibits plasminogen activator
  - Exerts anti-fibrinolytic activity

## Effects in leiomyomas

- **Ischemic necrosis**
- **Organizing intravascular thrombi**
  - Papillary endothelial hyperplasia-like change

PMID: 17667546

# Tranexamic Acid-treated Leiomyoma

*Intravascular organizing thrombi*

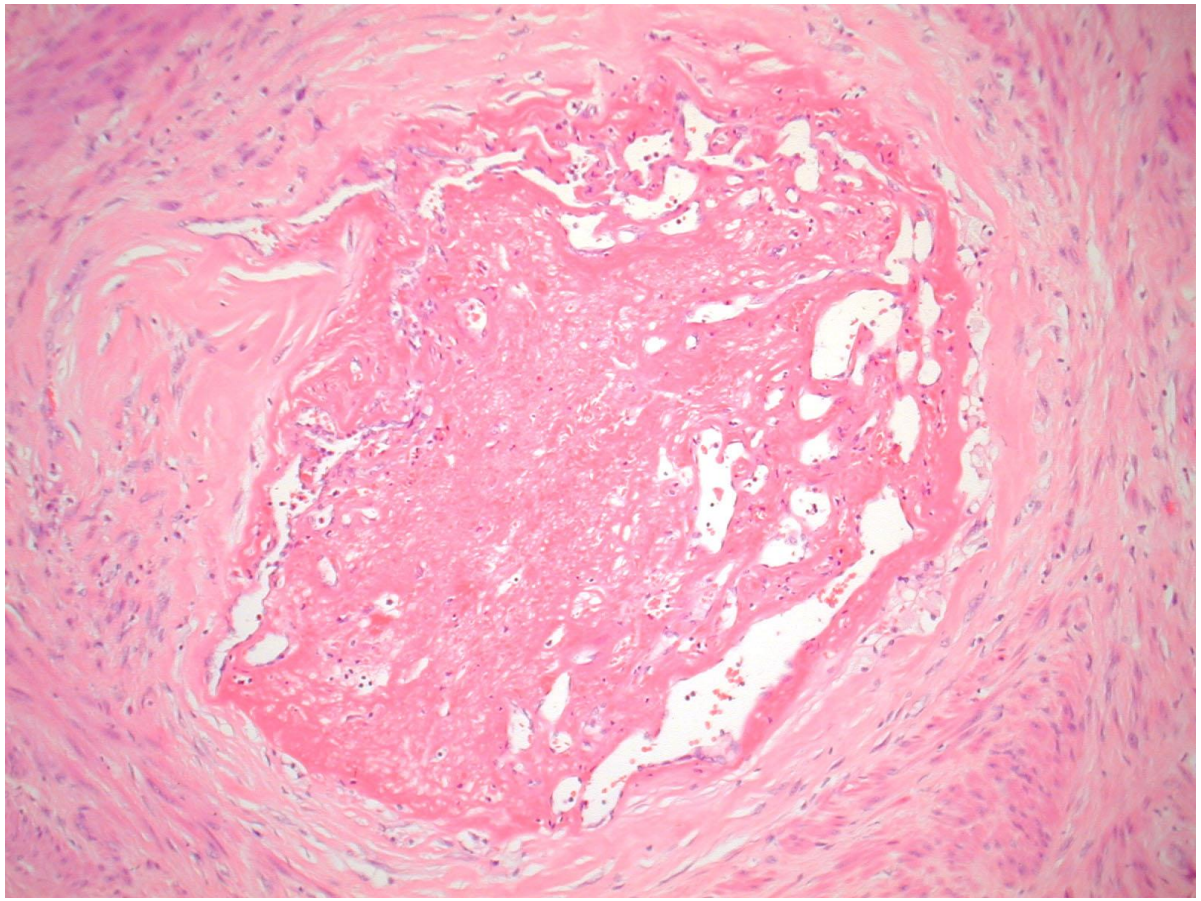

*Intravascular papillary endothelial hyperplasia-like features*

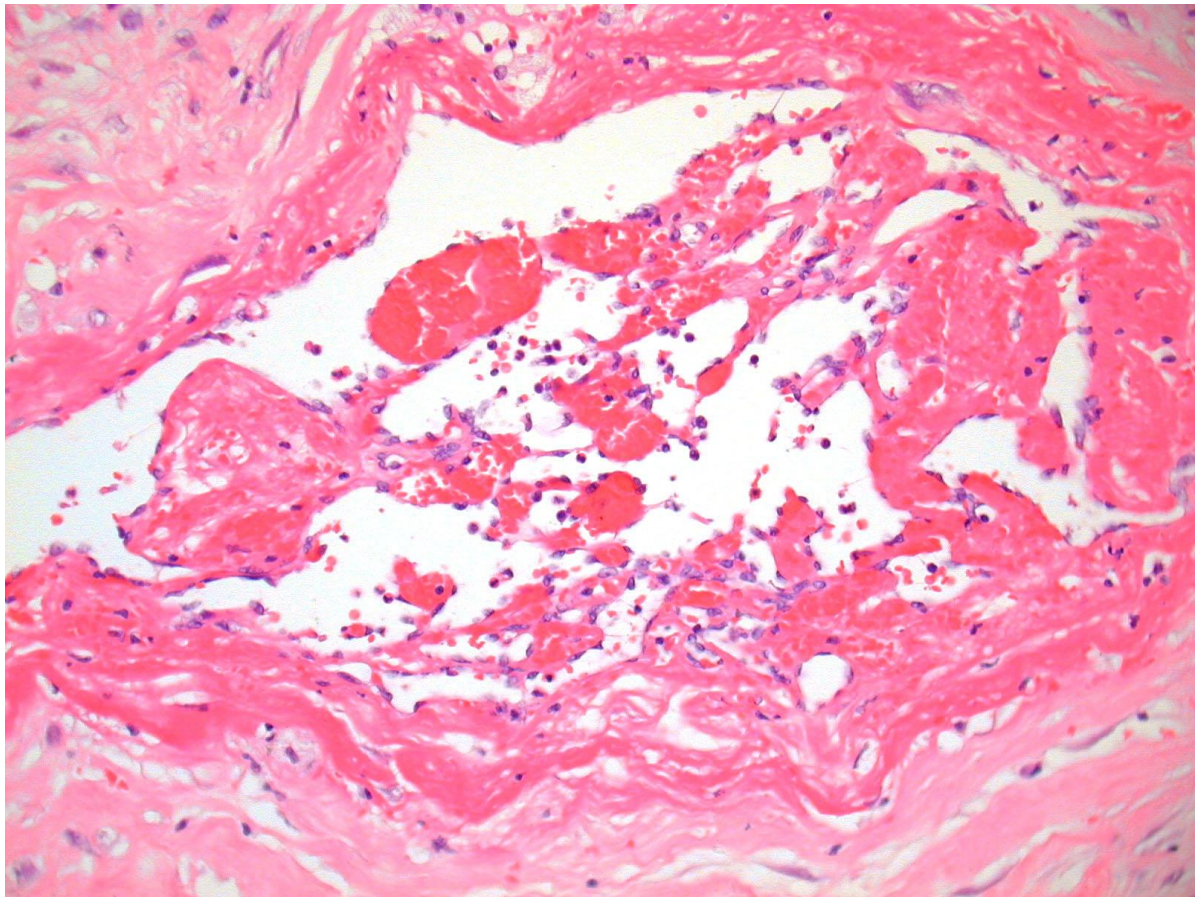

Images courtesy of Philip Ip, MD, Hong Kong

# Benign Degenerative Necrosis

*General Features*

| | Benign | Exception to the rule |
|---|---|---|
| Focality | Unifocal | |
| **Contours** | **Simple** | **Massive “apopletic” degeneration can appear geographic** |
| Interface with viable cells | Granulation tissue | |
| Peritheliomatous growth | No | |
| Atypical ghost cells | No | |



# Progestin-Associated Necrosis in Leiomyoma

*Massive infarct mimicking geographic tumor type necrosis*

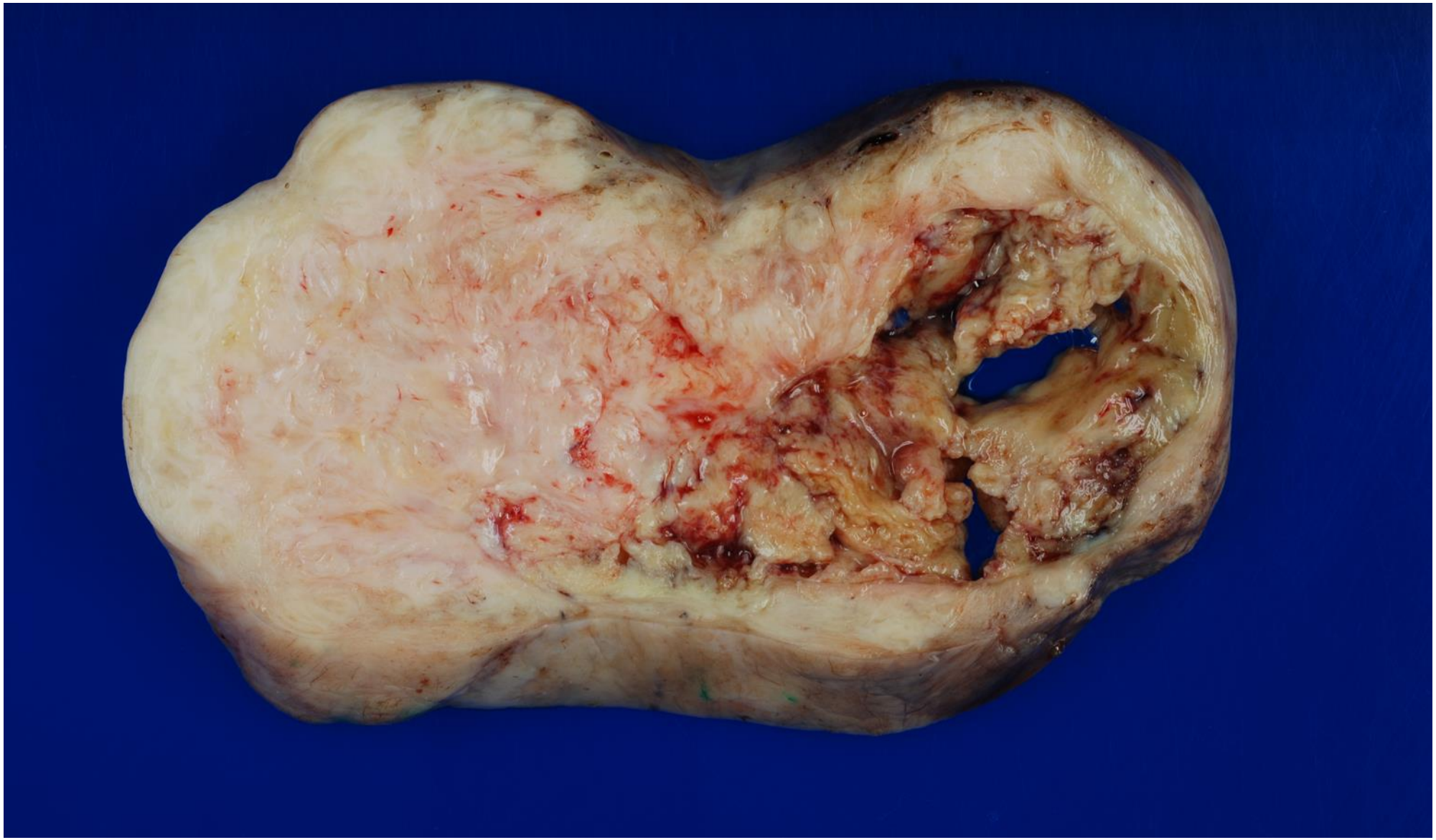

# Progestin-Associated Necrosis in Leiomyoma

*Geographic pattern mimics tumor type necrosis*

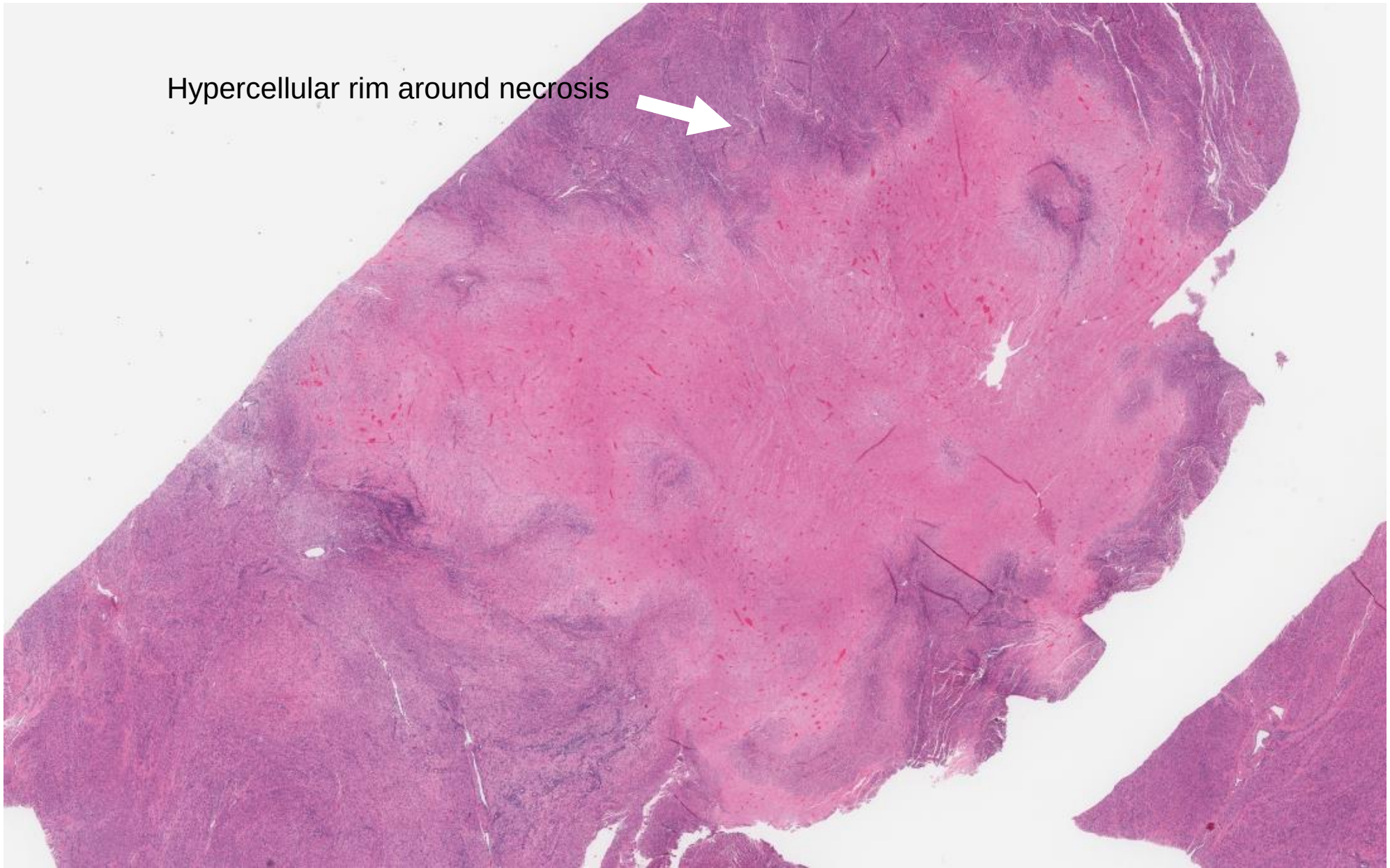

# Progestin-Associated Necrosis in Leiomyoma

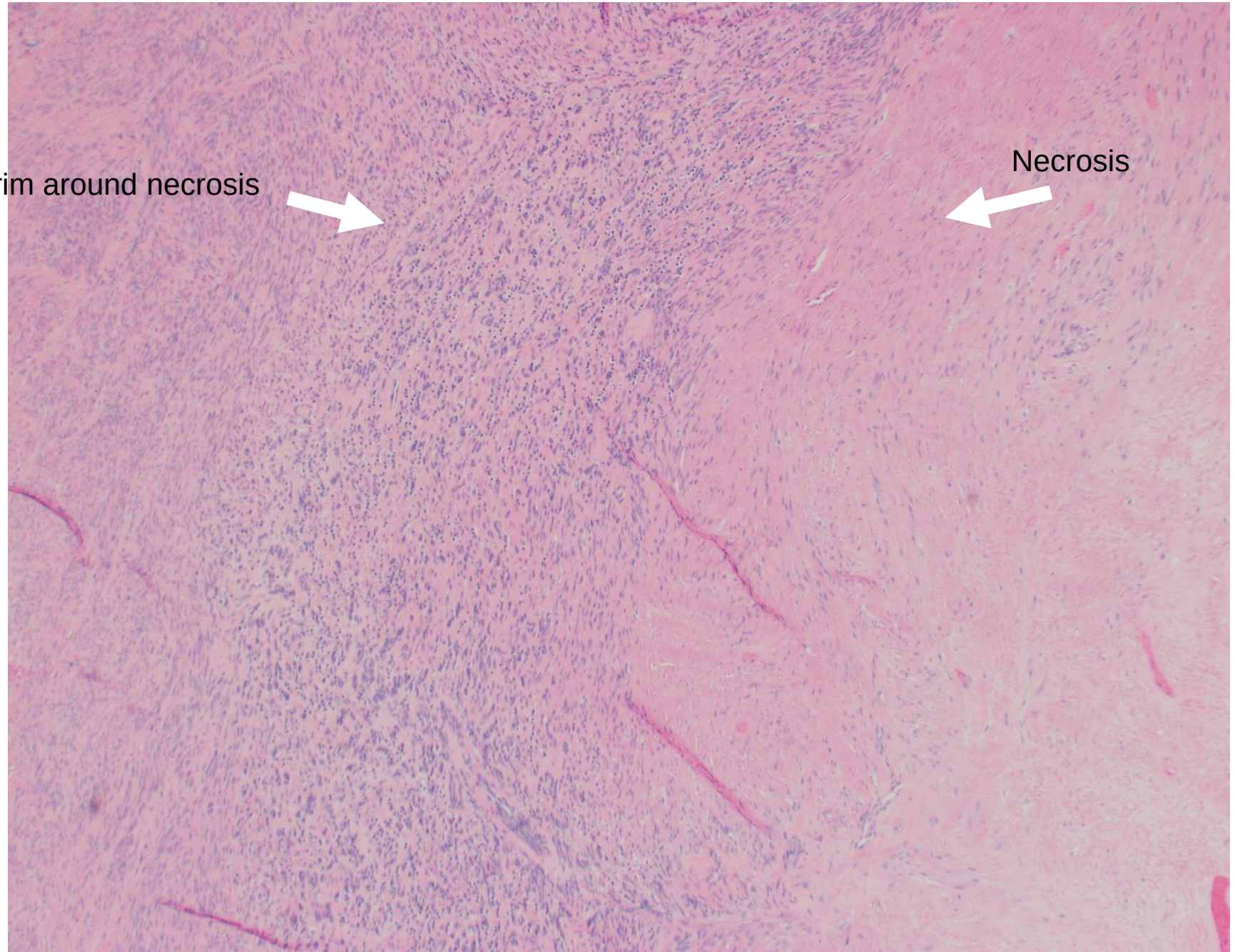

# Progestin-Associated Necrosis in Leiomyoma

*Peripheral rim of hypercellularity and occasional mitoses* *(avoid counting these for mitotic index)*

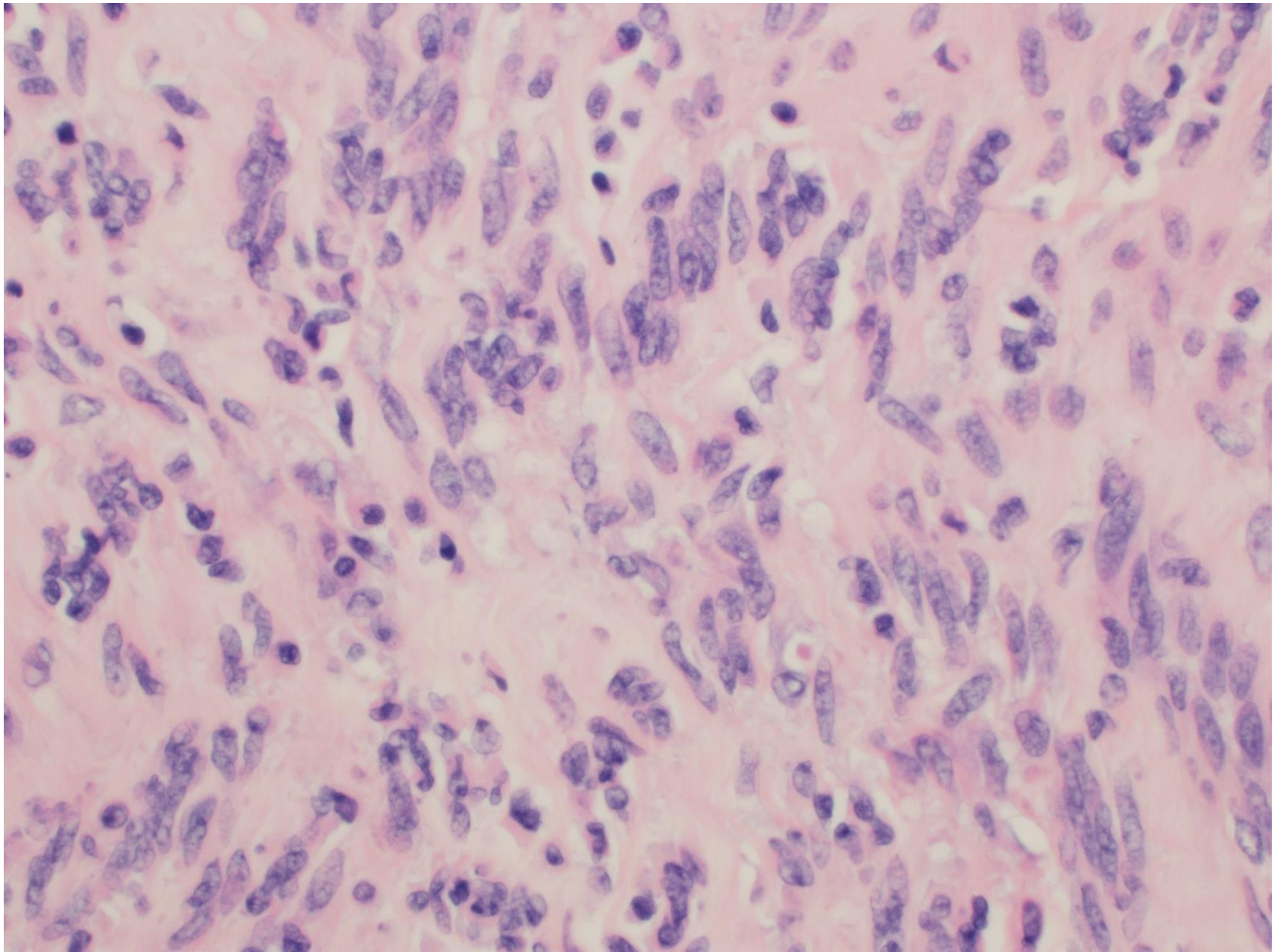

# Benign Degenerative Necrosis

*General Features*

| | Benign | Exception to the rule |
|---|---|---|
| Focality | Unifocal | |
| Contours | Simple | |
| Interface with viable cells | Granulation tissue | |
| **Peritheliomatous growth** | **No** | **Perinodular degeneration of leiomyoma** |
| Atypical ghost cells | No | |



# Benign Degenerative Changes: Perinodular degeneration

*Potential mimic of peritheliomatous pattern in leiomyosarcoma*

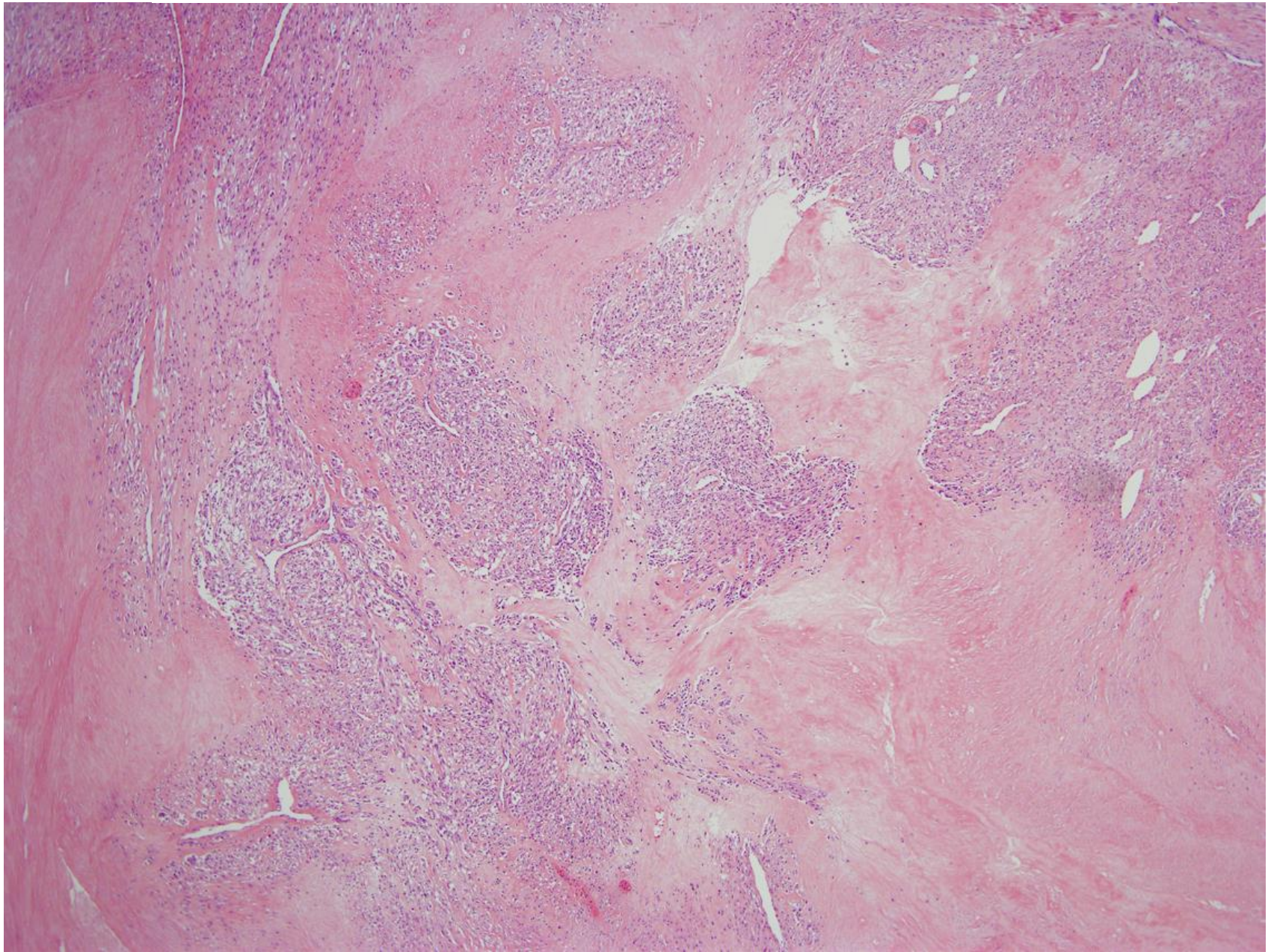

# Benign Degenerative Changes: Perinodular degeneration

*Potential mimic of peritheliomatous pattern in leiomyosarcoma*

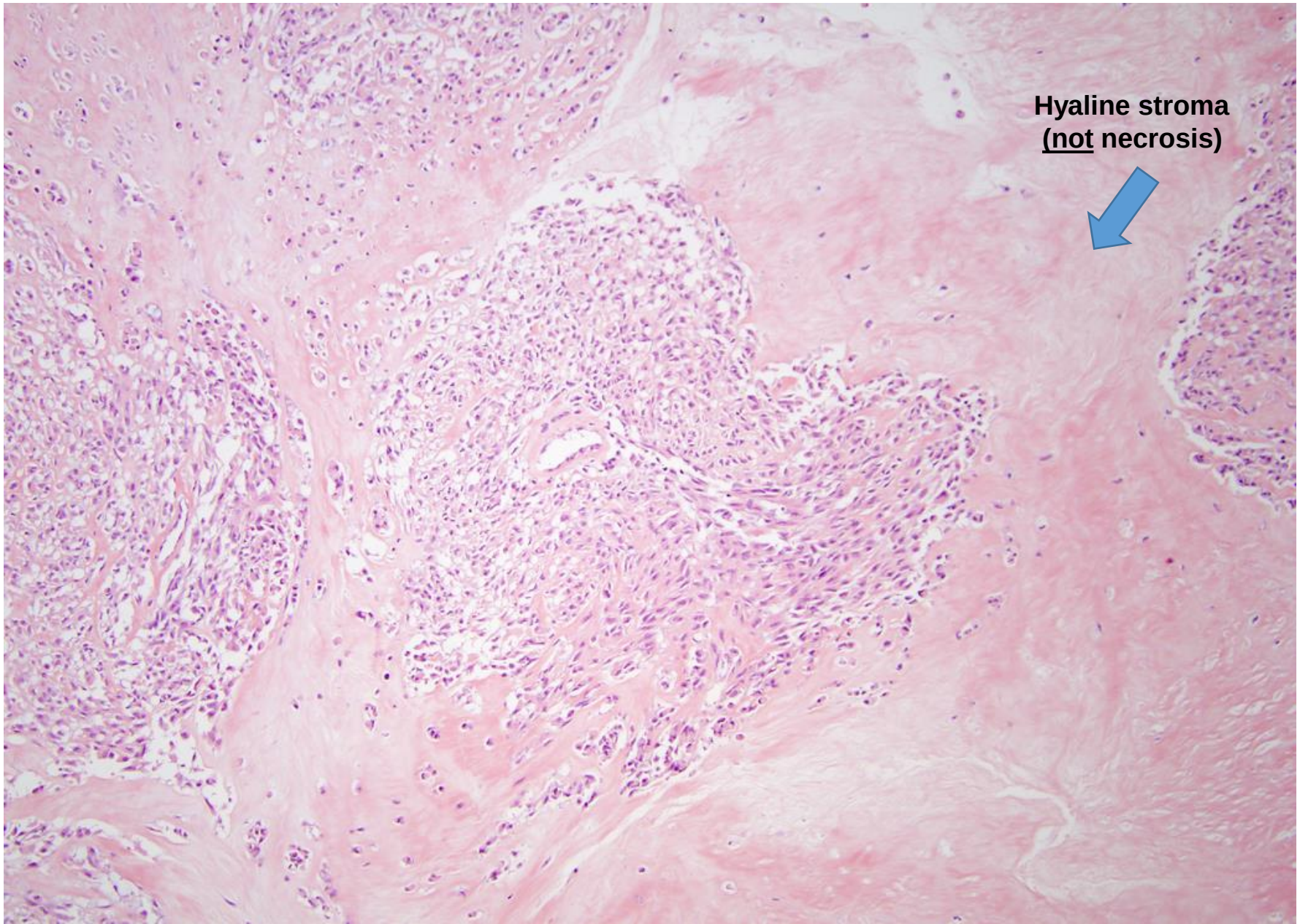

# “Peritheliomatous” Pattern in Uterine Smooth Muscle Tumors

*A potential diagnostic pitfall*



## TWO CASES OF UTERINE FIBROIDS SHOWING PERITHELIOMATOUS CHANGES: LONG IMMUNITY FROM RECURRENCE AFTER OPERATION.*

BY

ALBAN H. G. DORAN, F.R.C.S., SENIOR SURGEON, SAMARITAN FREE HOSPITAL.

and CUTHBERT LOCKYER, M.D., SENIOR PHYSICIAN TO OUT-PATIENTS, SAMARITAN FREE HOSPITAL.



* Read at a meeting of the Obstetrical and Gynaecological Section of the Royal Society of Medicine, October 8th, 1908.

# Benign Degenerative Necrosis

*General Features*

| | Benign | Exception to the rule |
|---|---|---|
| Focality | Unifocal | |
| Contours | Simple | |
| Interface with viable cells | Granulation tissue | |
| Peritheliomatous growth | No | |
| **Atypical ghost cells** | **No** | **Dead nuclei can be difficult to interpret** |



# Vague Criteria for Interpreting Dead Nuclei

12). Within the necrotic foci, coagulative "ghost" outlines of cells could often be discerned, with preservation of nuclei to the extent that hyperchromasia and pleomorphism could be noted. These hyperchromatic but necrotic nuclei contrasted with the generally pale "mummified" appearance of the nuclei of the necrotic cells in hyalin necrosis. Another





Problematic Uterine Smooth Muscle Neoplasms

A Clinicopathologic Study of 213 Cases

Stephen W. Bell, M.D., Richard L. Kempson, M.D., and
Michael R. Hendrickson, M.D.

PMID: 8179071

# Ghost Nuclei in Benign Degenerative Necrosis

## Pyknotic nuclei

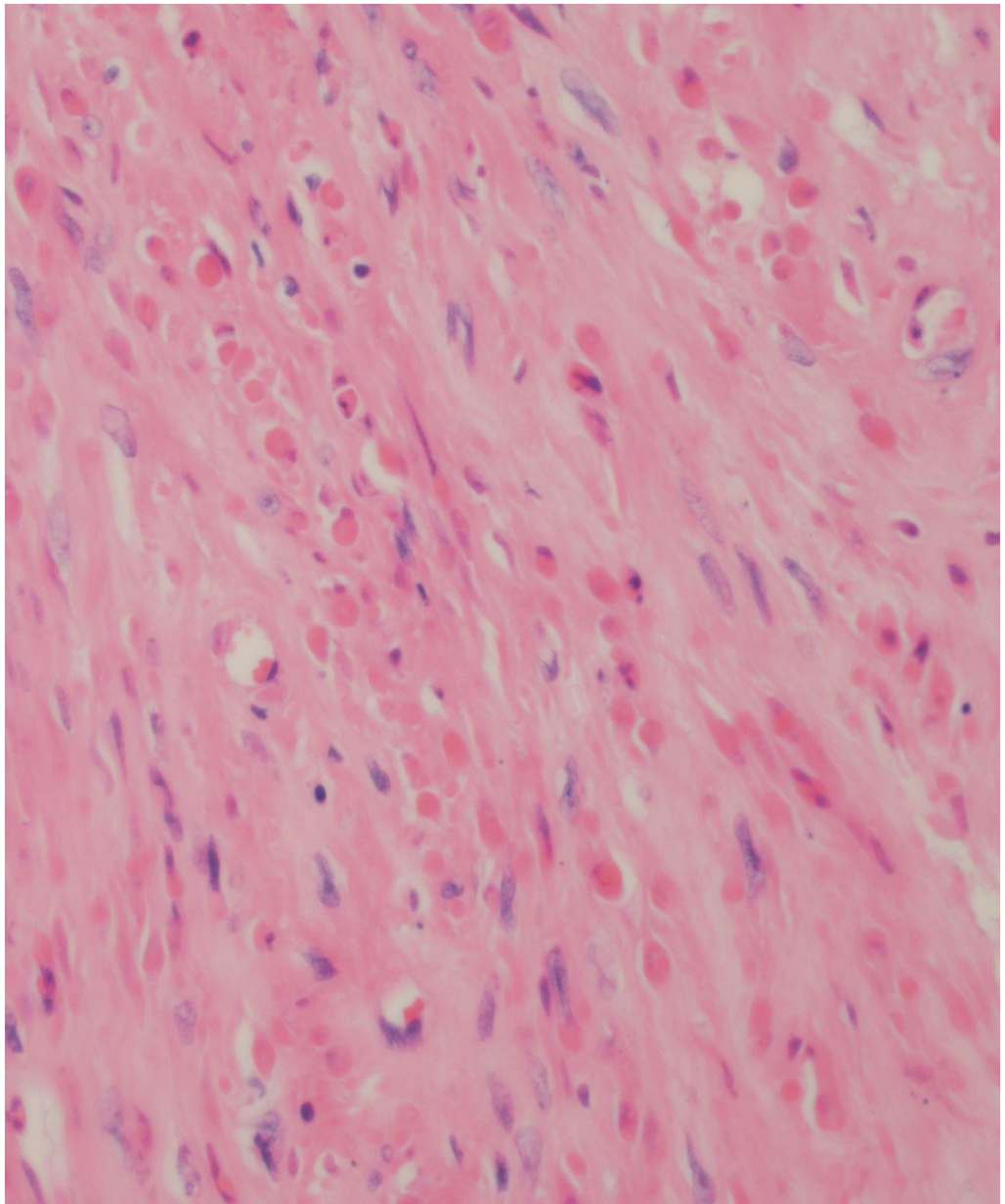

## Bland appearance of nuclear ghosts

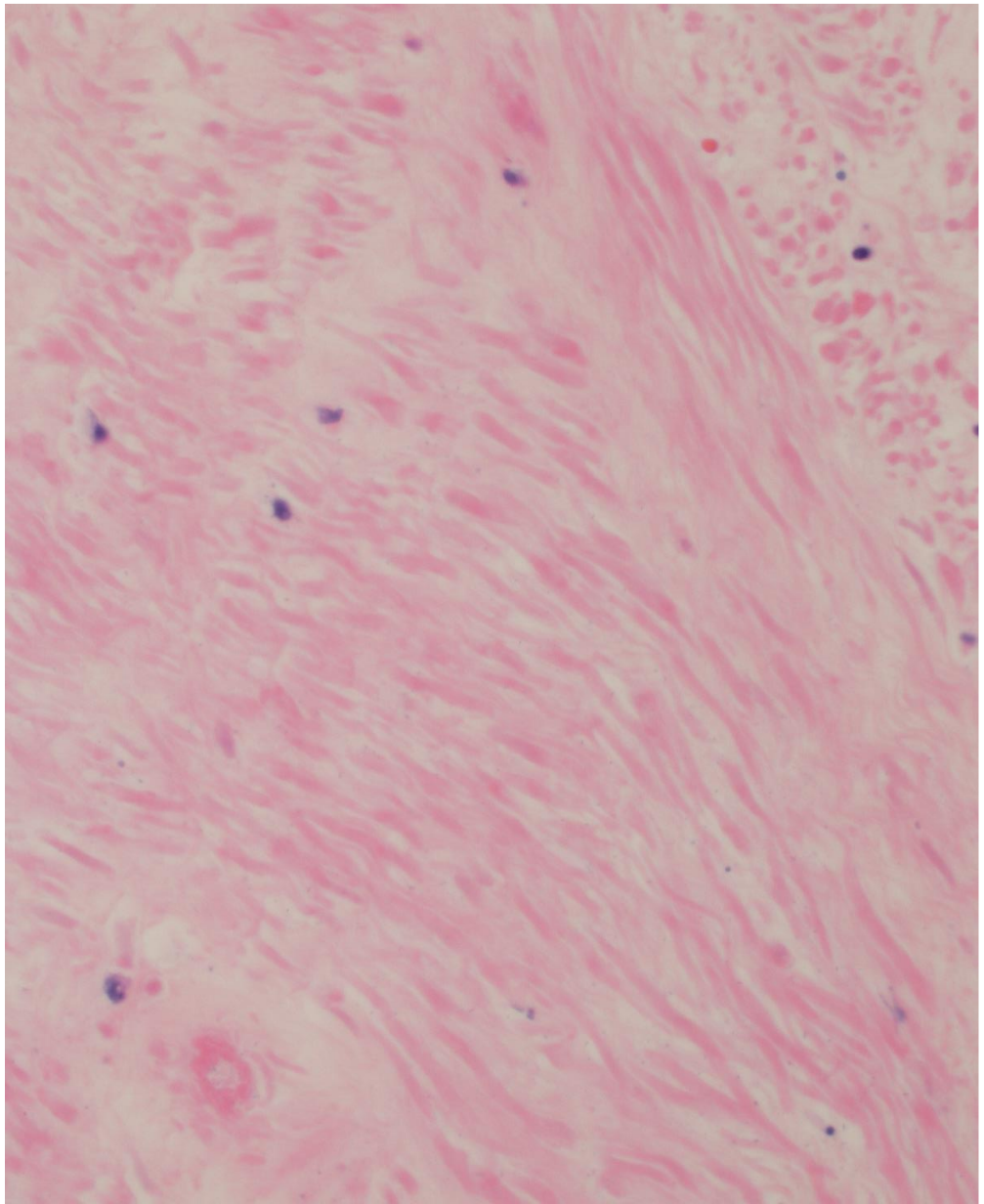

# Ghost Nuclei Can Be Difficult to Interpret

Atypical ?

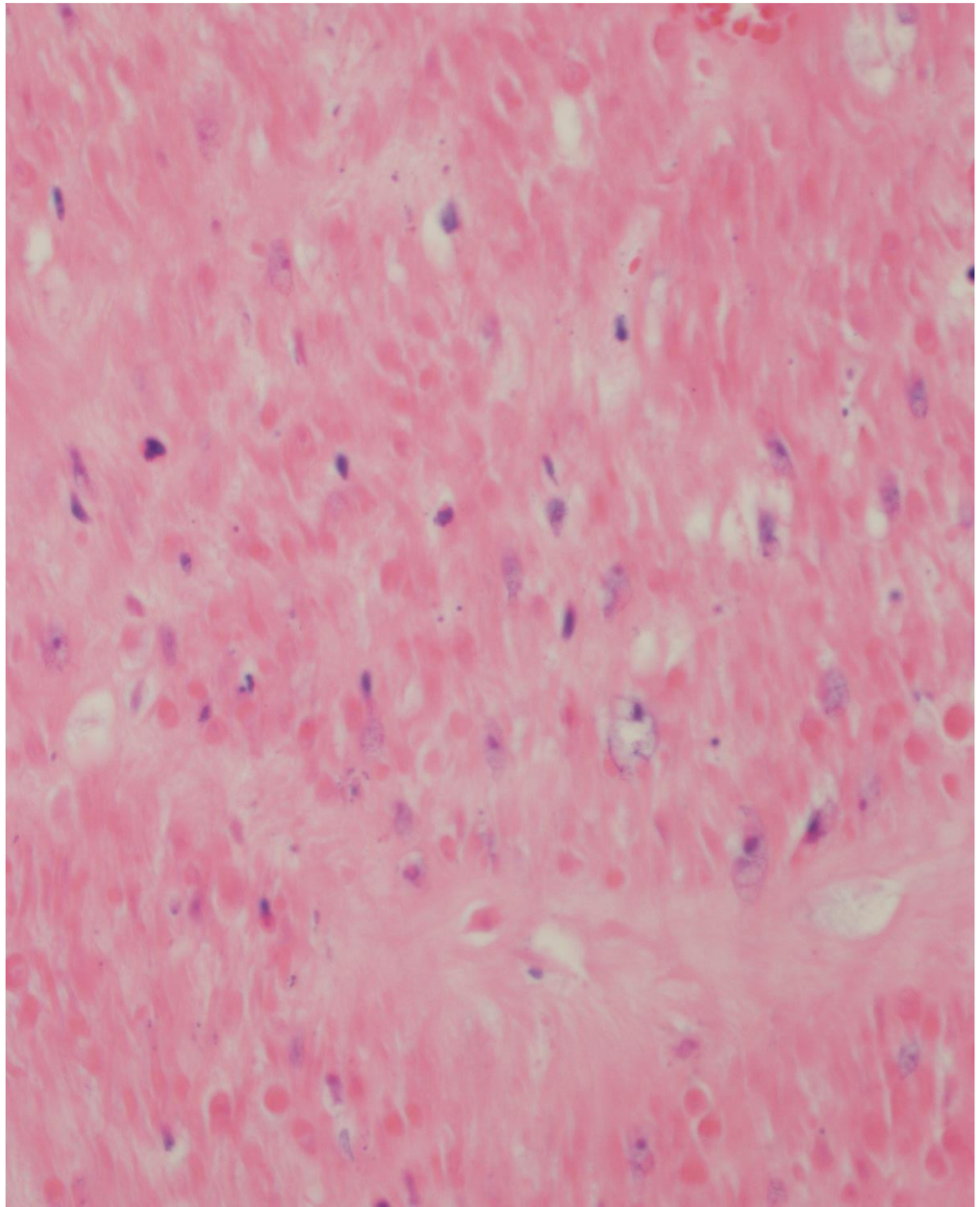

Atypical ?

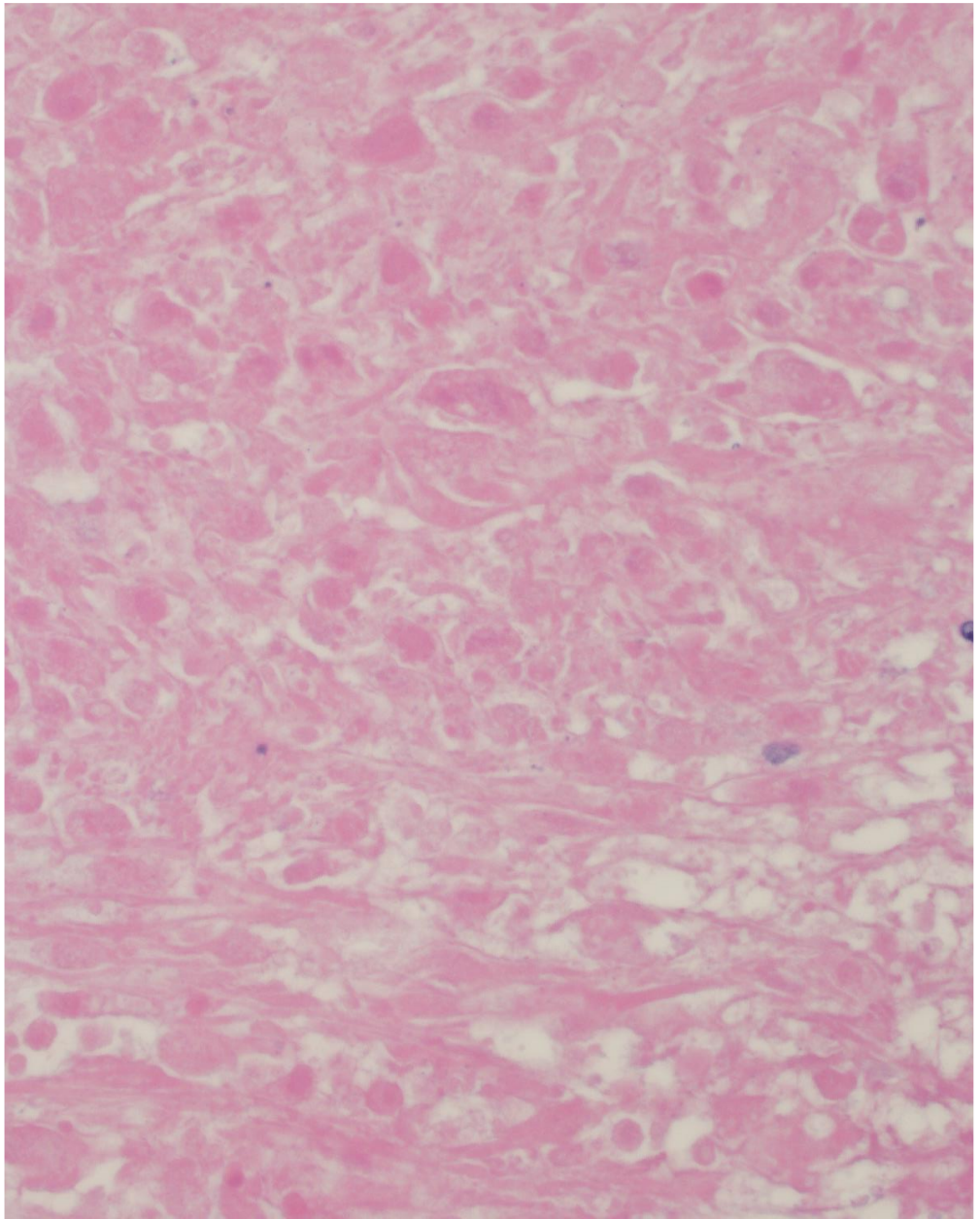

# Mimics of Tumor-Type Necrosis

- Ischemic degeneration
- Perinodular hyalinization
- **Myxoid degeneration** → *also consider possibility of inflammatory myofibroblastic tumor*

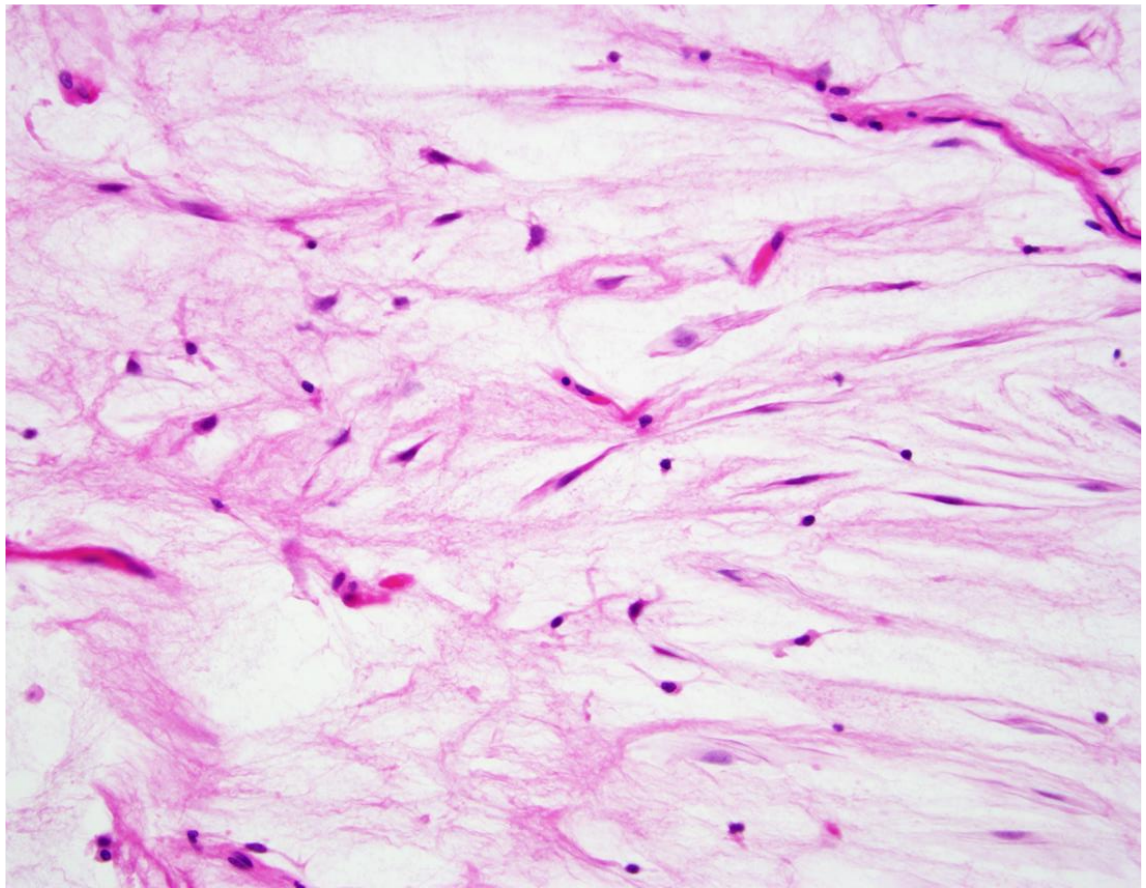

# Mimics of Tumor-Type Necrosis

- Ischemic degeneration
- Perinodular hyalinization
- Myxoid degeneration

**Alveolar pattern edema** → *also consider possibility of fumarate hydratase deficiency*

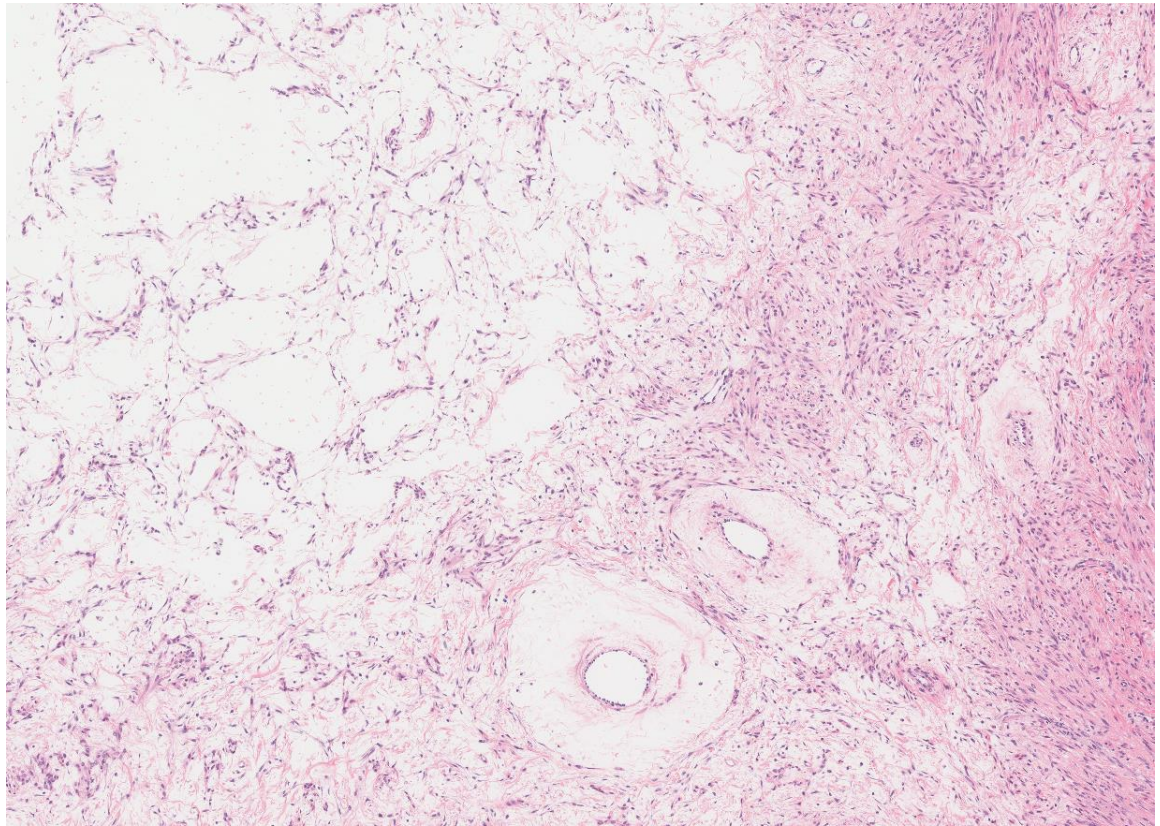

# Outline of Talk

- Significance of tumor-type necrosis in prognostic classification of uterine smooth muscle tumors
- Definition of tumor-type necrosis
- Mimics of tumor-type necrosis

**Ambiguous types of necrosis:** *Practical algorithm for managing cases*

# Ambiguous types of necrosis

***2*** *Scenarios*

## Scenario 1:

**A <u>temporary</u> state of interpretative ambiguity that can be resolved with certainty by applying an algorithm.**

**Final result is a confident classification as either tumor-type necrosis or not.**

## Scenario 2:

**The algorithm failed to resolve the ambiguity.**

**Final result is often to apply the term “STUMP”.**

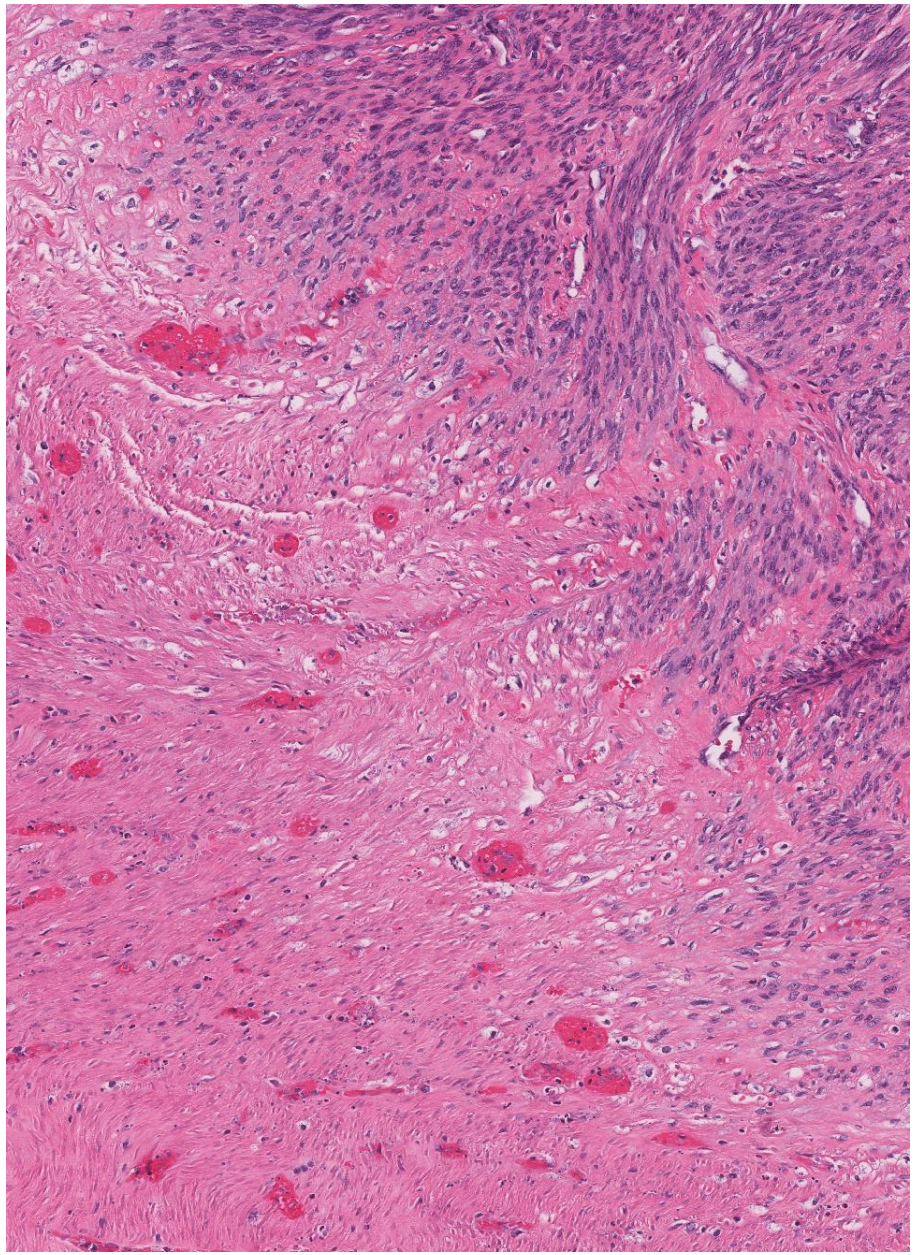

# Ambiguous types of necrosis

ORIGINAL ARTICLE

## Interobserver Variability in the Interpretation of Tumor Cell Necrosis in Uterine Leiomyosarcoma

*Diana Lim, MBBS, FRCPath, FRCPA,* Teresa Alvarez, MD,† Marisa R. Nucci, MD,‡ Blake Gilks, MD,§ Teri Longacre, MD,‖ Robert A. Soslow, MD,¶ and Esther Oliva, MD#*

(*Am J Surg Pathol* 2013;37:650–658)

| | |
|---|---|
| **Full agreement** | **35%** |
| **Partial agreement** | **47%** |
| **No consensus** | **18%** |

**Overall “moderate” agreement**

PMID: 23552382

# Ambiguous types of necrosis

**Experts frequently <u>unable</u> to decide if necrosis was tumor-type versus benign**

| # of Pathologists | % of all cases labeled "indeterminate" necrosis |
|---|---|
| ≥ 1 | 59% |
| ≥ 2 | 29% |
| ≥ 3 | 13% |
| ≥ 4 | 3% |

ORIGINAL ARTICLE

Interobserver Variability in the Interpretation of Tumor Cell Necrosis in Uterine Leiomyosarcoma

*Diana Lim, MBBS, FRCPath, FRCPA,* Teresa Alvarez, MD,† Marisa R. Nucci, MD,‡ Blake Gilks, MD,§ Teri Longacre, MD,‖ Robert A. Soslow, MD,¶ and Esther Oliva, MD#*

PMID: 23552382

# Ambiguous types of necrosis

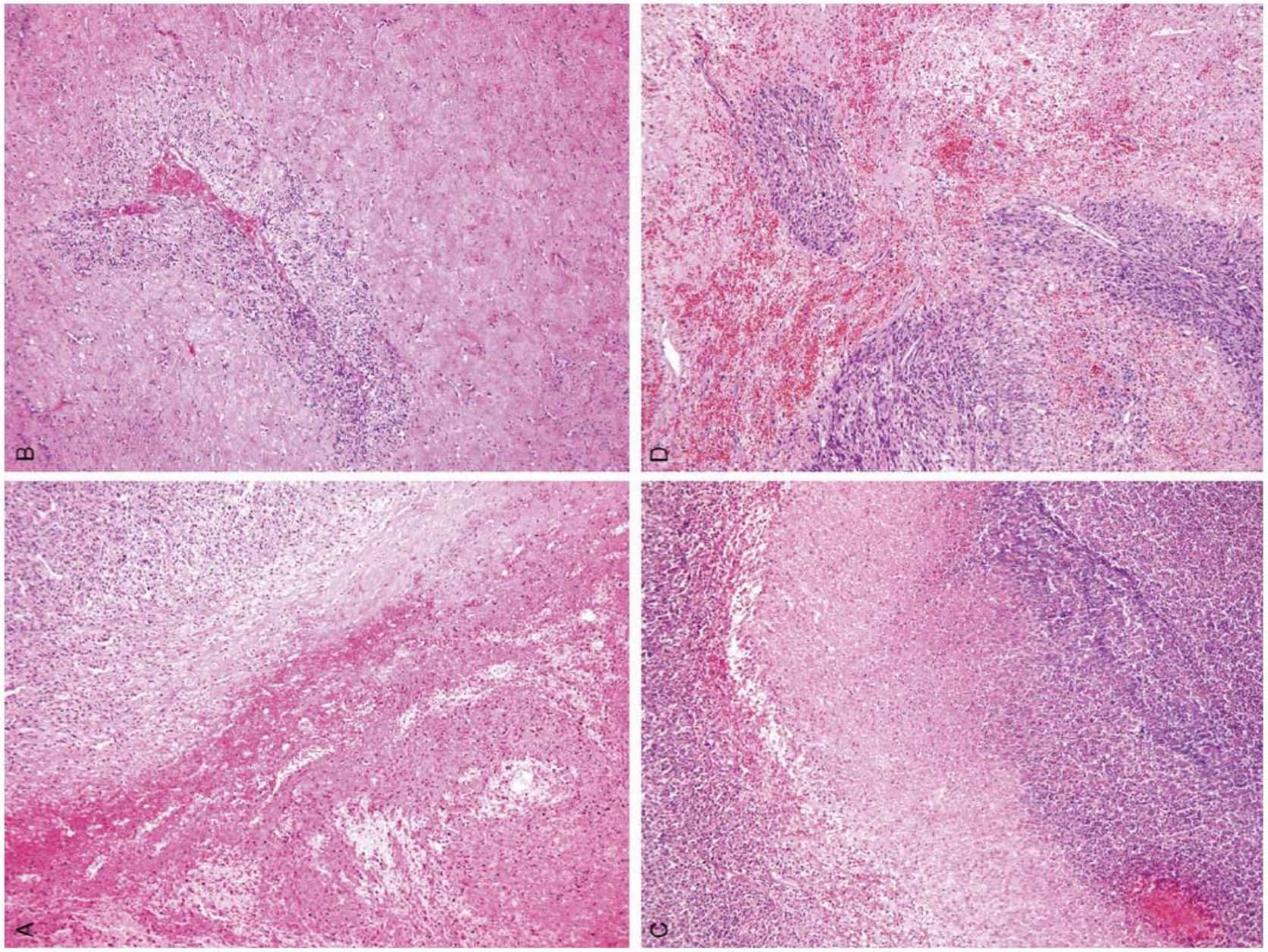


Images from PMID: 23552382

# Ambiguous types of necrosis

**Experts frequently <u>unable</u> to decide if necrosis was tumor-type versus benign**

| # of Pathologists | % of all cases labeled "indeterminate" necrosis |
|---|---|
| ≥ 1 | 59% |
| ≥ 2 | 29% |
| ≥ 3 | 13% |
| ≥ 4 | 3% |



**<u>Study design limitations:</u>**

- **1 H&E slide only**
- **No knowledge of patient age, hormones**
- **No access to macroscopic pathology**
- **No knowledge of tissue sampling strategy**

*Data available in "real life" practice*

PMID: 23552382


KEEP
CALM
AND
ALGORITHM
ON

# Practical “Algorithmic” Approach to Necrosis in Uterine Smooth Muscle Tumors

- **Assess <u>clinical context</u>:** age, pharmacologic treatment, interventions (UAE, cryotherapy, RFA)
- **Assess <u>macroscopy</u>:** size, borders, necrosis
- **Assess <u>tissue sampling strategy</u>:** adequacy, location
- **Assess <u>microscopy</u>:** awareness of criteria and mimics

# Practical “Algorithmic” Approach to Necrosis in Uterine Smooth Muscle Tumors

- **Assess <u>clinical context</u>:** age, pharmacologic treatment, interventions (UAE, cryotherapy, RFA)
- **Assess <u>macroscopy</u>:** size, borders, necrosis
- **Assess <u>tissue sampling strategy</u>:** adequacy, location
- **Assess <u>microscopy</u>:** awareness of criteria and mimics

- **<u>Algorithm Outcome</u>:**

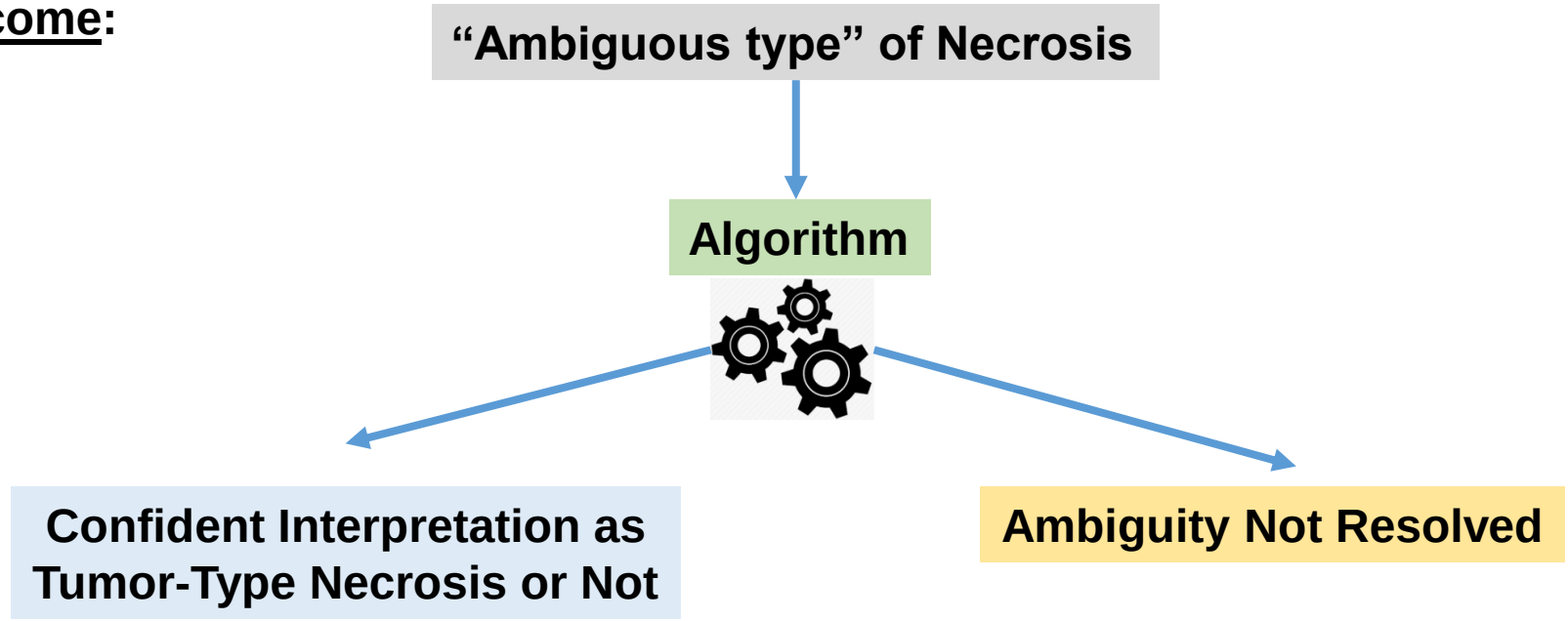

# Practical “Algorithmic” Approach to Necrosis in Uterine Smooth Muscle Tumors

*Assess Clinical Context*

## Patient age

- **Most women with uterine leiomyosarcoma are >50 years**
  - *Leiomyosarcoma is highly unlikely in women <40 years*

## Currently pregnant

- **Necrosis most likely benign / degenerative**
  - *Rule out inflammatory myofibroblastic tumor*

## Progestin therapy

- **Necrosis most likely benign / degenerative**

## Minimally invasive fibroid therapy

- **Necrosis most likely benign / degenerative**

# Practical “Algorithmic” Approach to Necrosis in Uterine Smooth Muscle Tumors

*Assess Clinical Context*

**Patient age**

- **Most women with uterine leiomyosarcoma are >50 years**
  - *Leiomyosarcoma is highly unlikely in women <40 years*

**Currently pregnant**

- **Necrosis most likely benign / degenerative**
  - *Rule out inflammatory myofibroblastic tumor*

**Progestin therapy**

- **Necrosis most likely benign / degenerative**

**Minimally invasive fibroid therapy**

- **Necrosis most likely benign / degenerative**

**Caveat:**

**Rare exceptions may occur**

---

**Risk of sarcoma in clinical “fibroids” is 1:8300 to 1:352**

PMID: 29398899

# Practical “Algorithmic” Approach to Necrosis in Uterine Smooth Muscle Tumors

*Assess Macroscopy*

## Tumor size

- **Mean diameter of uterine leiomyosarcoma is 10 cm**
  - *However, 25% are < 5 cm*

## Tumor borders

- **Infiltrative growth raises concern for sarcoma**
  - *However, not pathognomonic for malignancy (can be present in cellular leiomyoma, IMT)*

## Tumor texture

| | Top consideration |
|---|---|
| ▪ **Dense/firm**<br>▪ **Rubbery**<br>▪ **Whorled** | Leiomyoma |
| ▪ **Fleshy + necrotic** | Leiomyosarcoma |
| ▪ **Hemorrhagic**<br>▪ **Cystic** | Either |

# Uterine Leiomyosarcoma

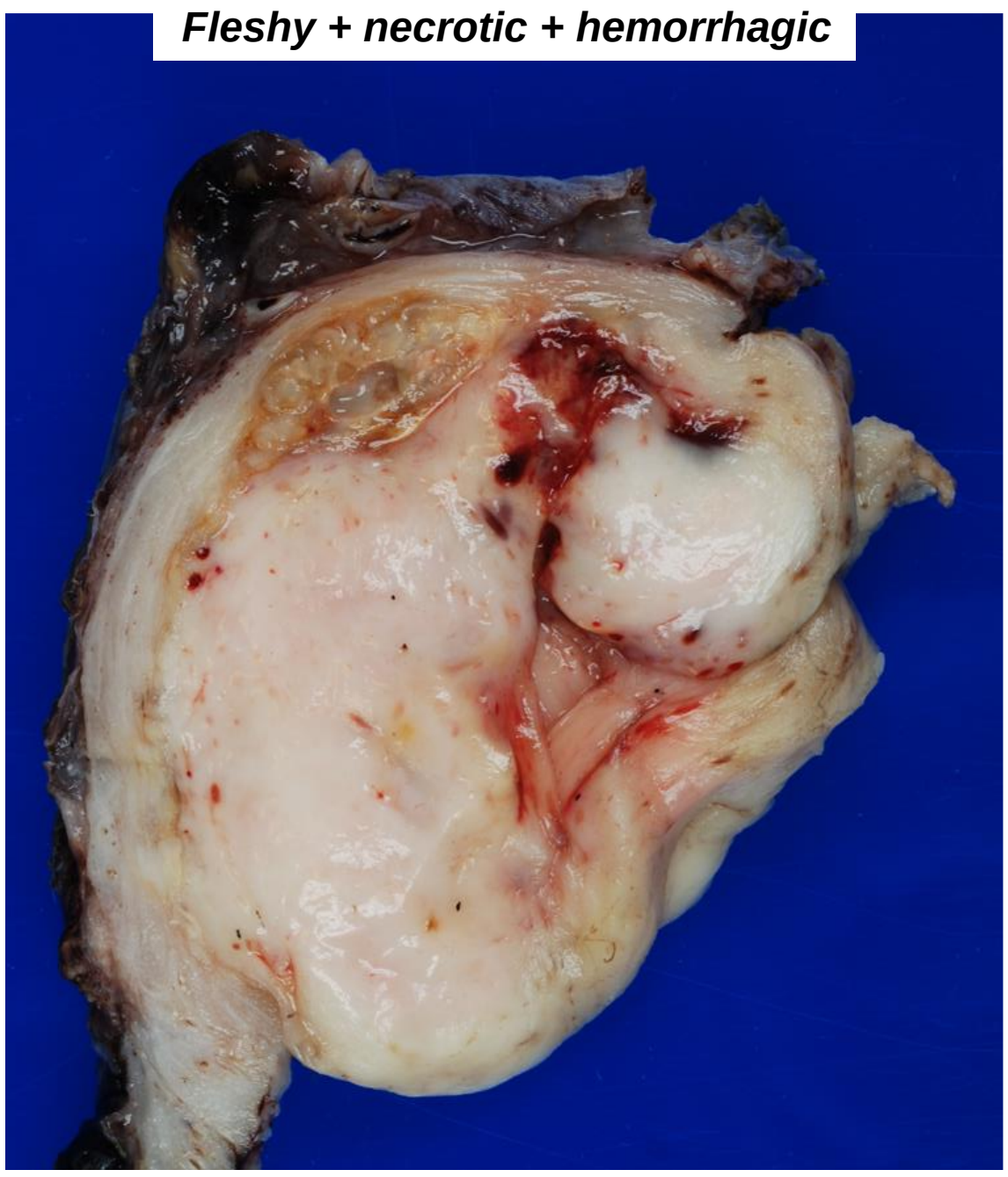


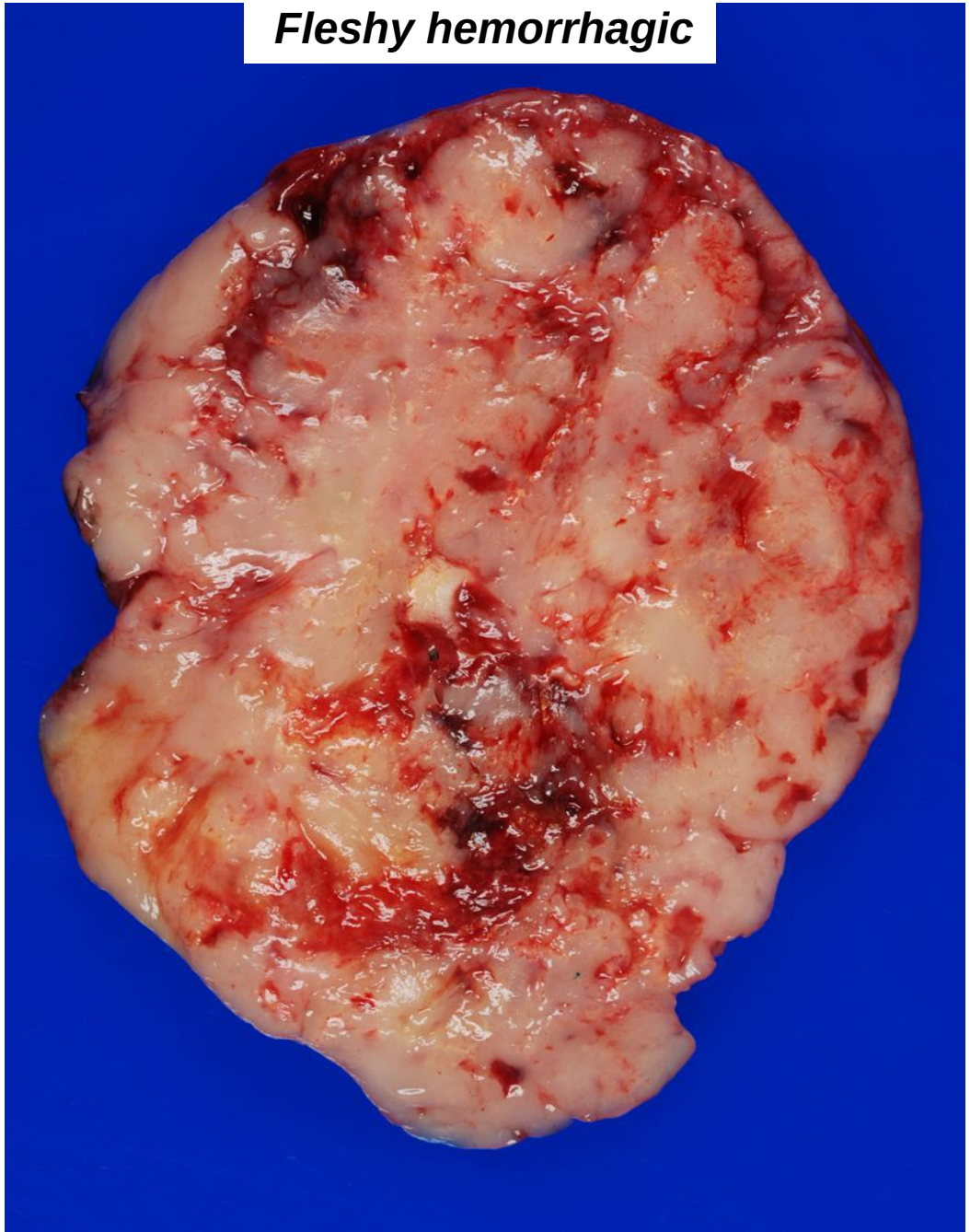

# Hemorrhage / cystic changes that merit extensive tissue sampling

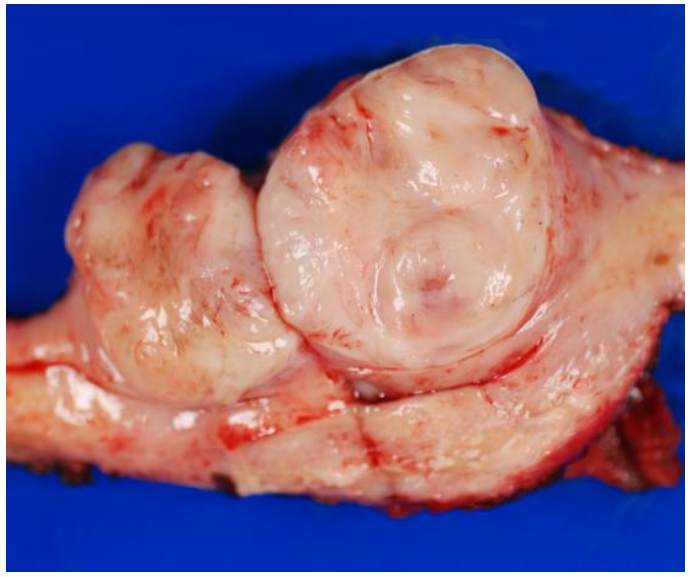

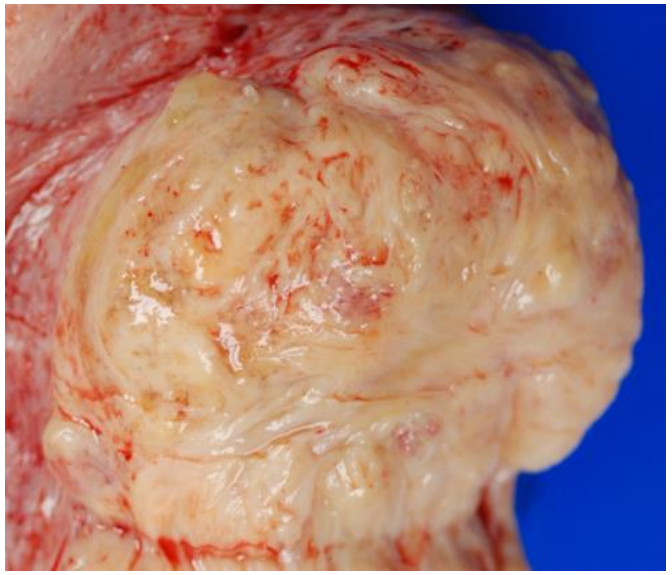

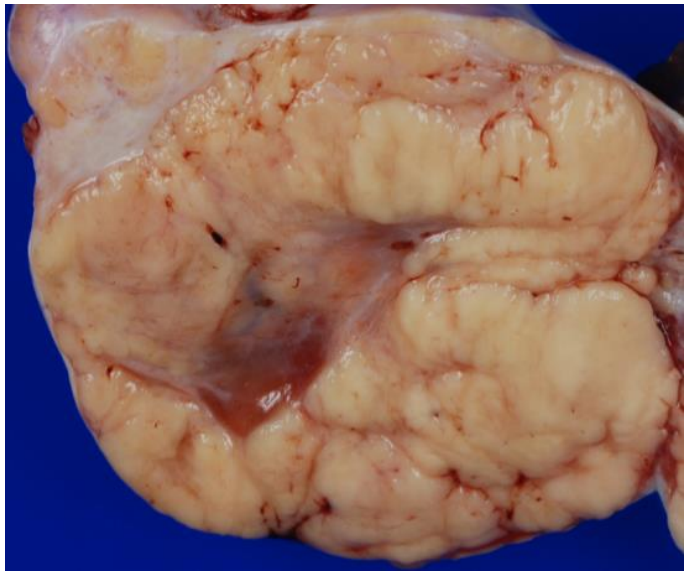



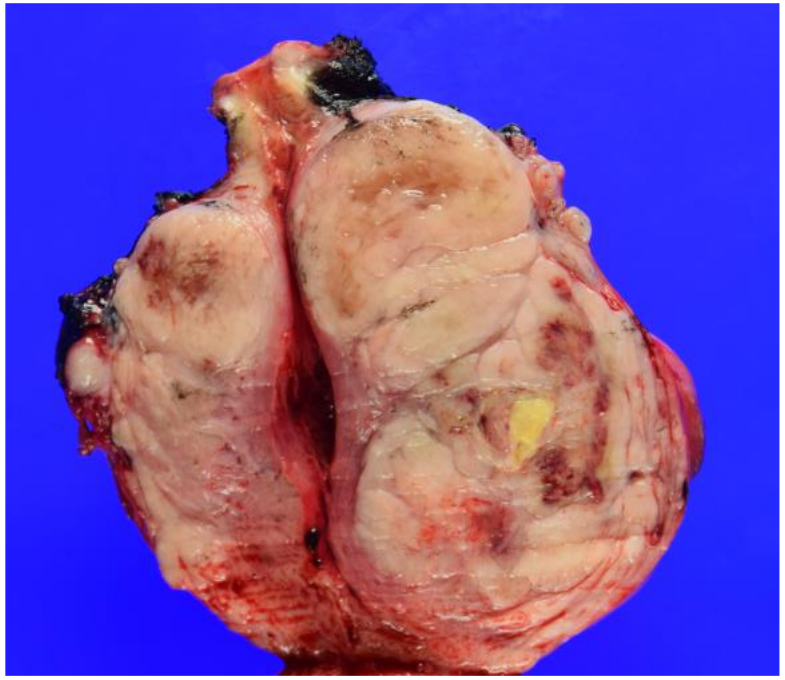

# Practical “Algorithmic” Approach to Necrosis in Uterine Smooth Muscle Tumors

- **Assess clinical context:** age, pharmacologic treatment, interventions (UAE, cryotherapy, RFA)
- **Assess macroscopy:** size, borders, necrosis
- **Assess tissue sampling strategy:** adequacy, location

# Practical “Algorithmic” Approach to Necrosis in Uterine Smooth Muscle Tumors

## *Assess Tissue Sampling Strategy*

- **Tissue sampling protocol for uterine “fibroids” varies between institutions**
- **My institution’s strategy:**

| Macroscopic size | Necrosis / hemorrhage / cysts | Strategy |
|---|---|---|
| ≥ 5 cm | No | 1 section each |
| All under 5 cm | No | 1 section each, up to 5 cassettes total |
| Any | Yes | ▪ Several sections of viable tissue<br>▪ Several sections of interface with necrosis<br>▪ Few sections of necrosis |

- **Royal College of Pathologists** Tissue Pathways (3-29-2019)

| Necrosis / hemorrhage / cysts | Strategy |
|---|---|
| No | 1 cassette of largest fibroid plus 1 or 2 others selected at random |
| Yes | 1 cassette per 1-2 cm of the mass |

# Tissue Sampling of Necrotic Uterine “Fibroid”

***Include Interface of Viable / Necrotic Tissue***

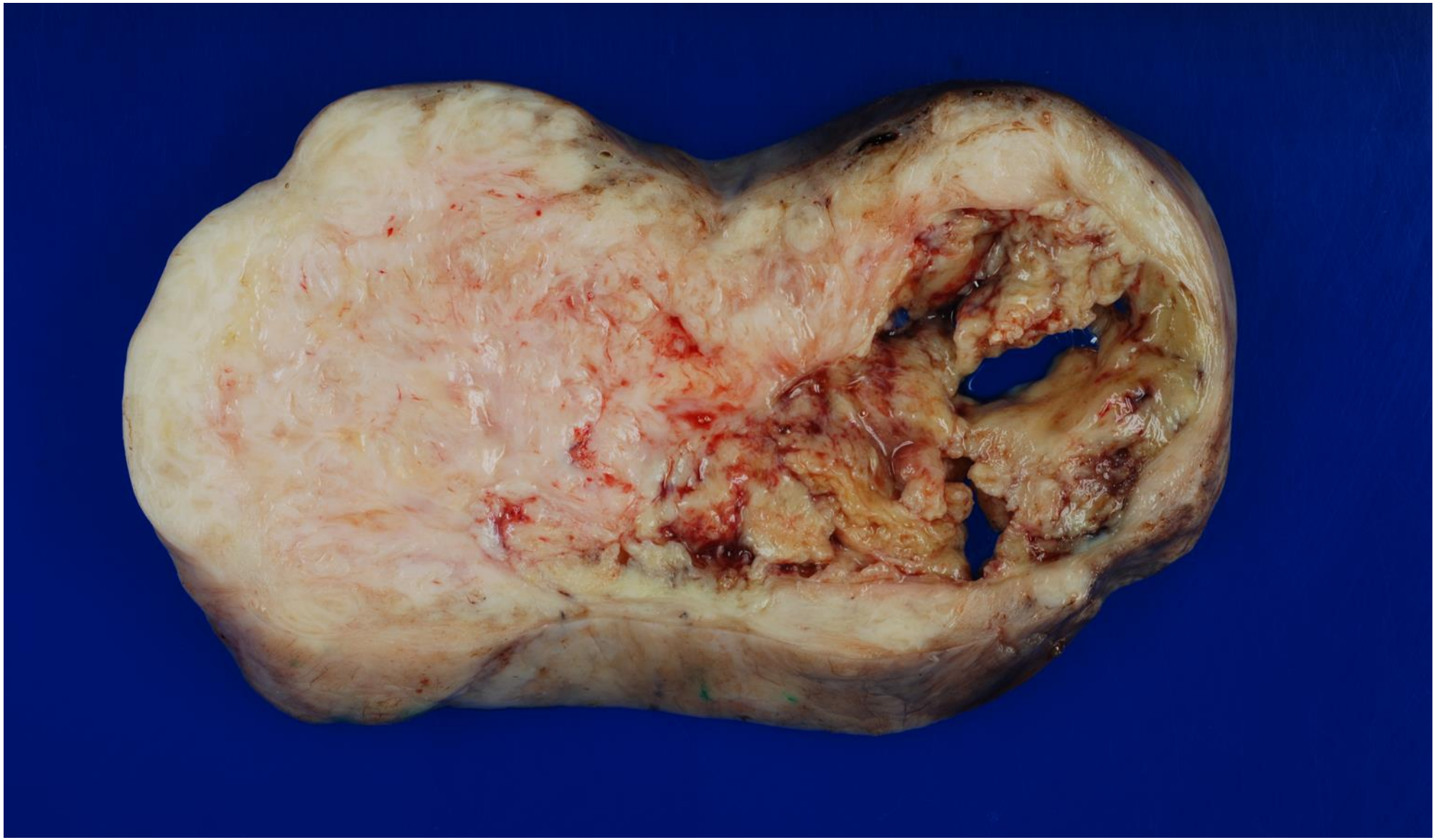

# Tissue Sampling of Necrotic Uterine “Fibroid”

***Include Interface of Viable / Necrotic Tissue***

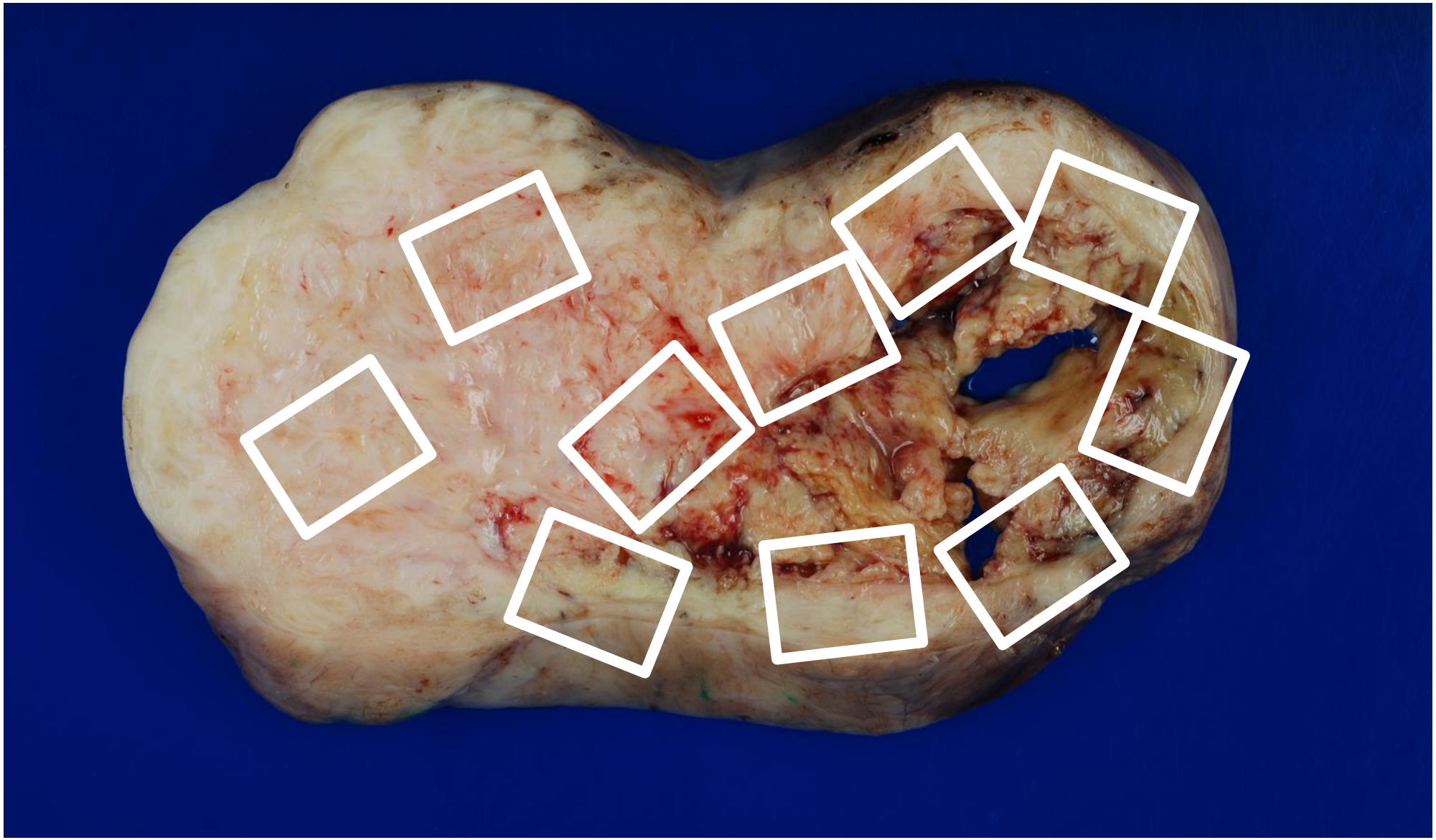

# Tissue Sampling of Necrotic Uterine “Fibroid”

***Include Interface of Viable / Necrotic Tissue***

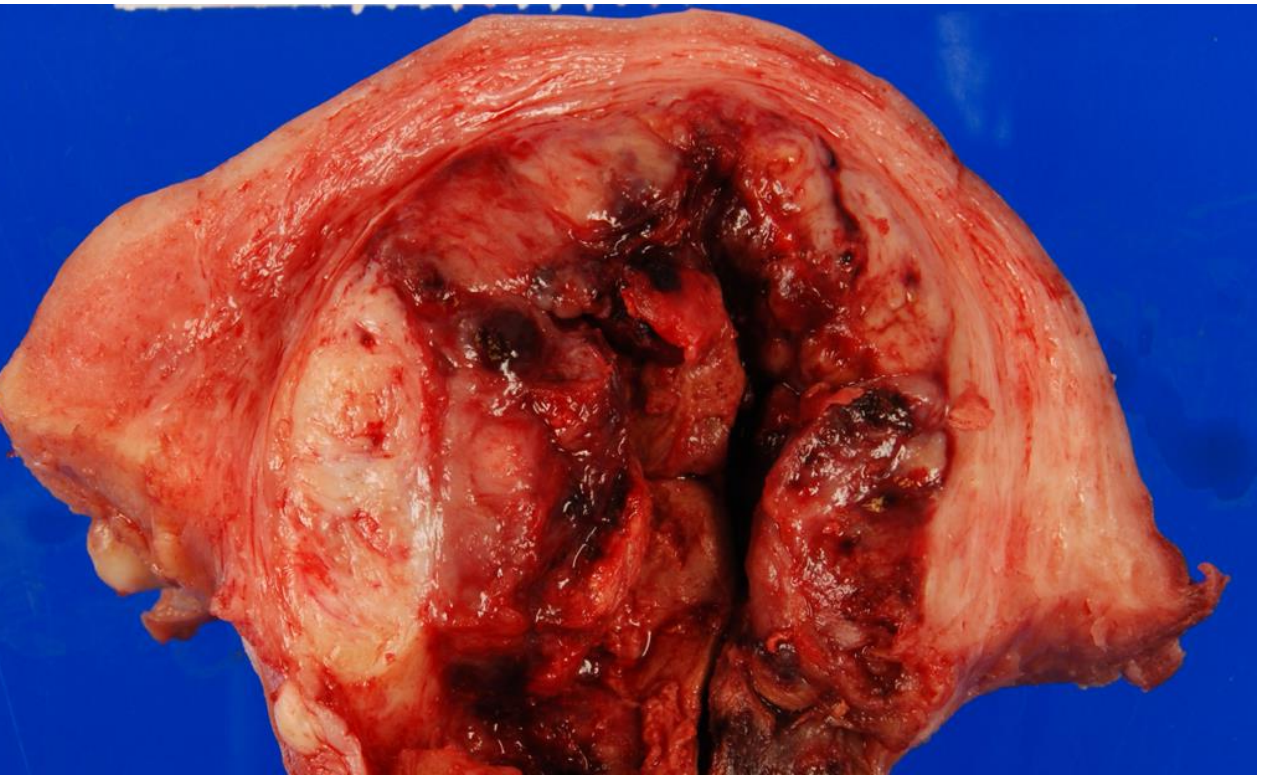

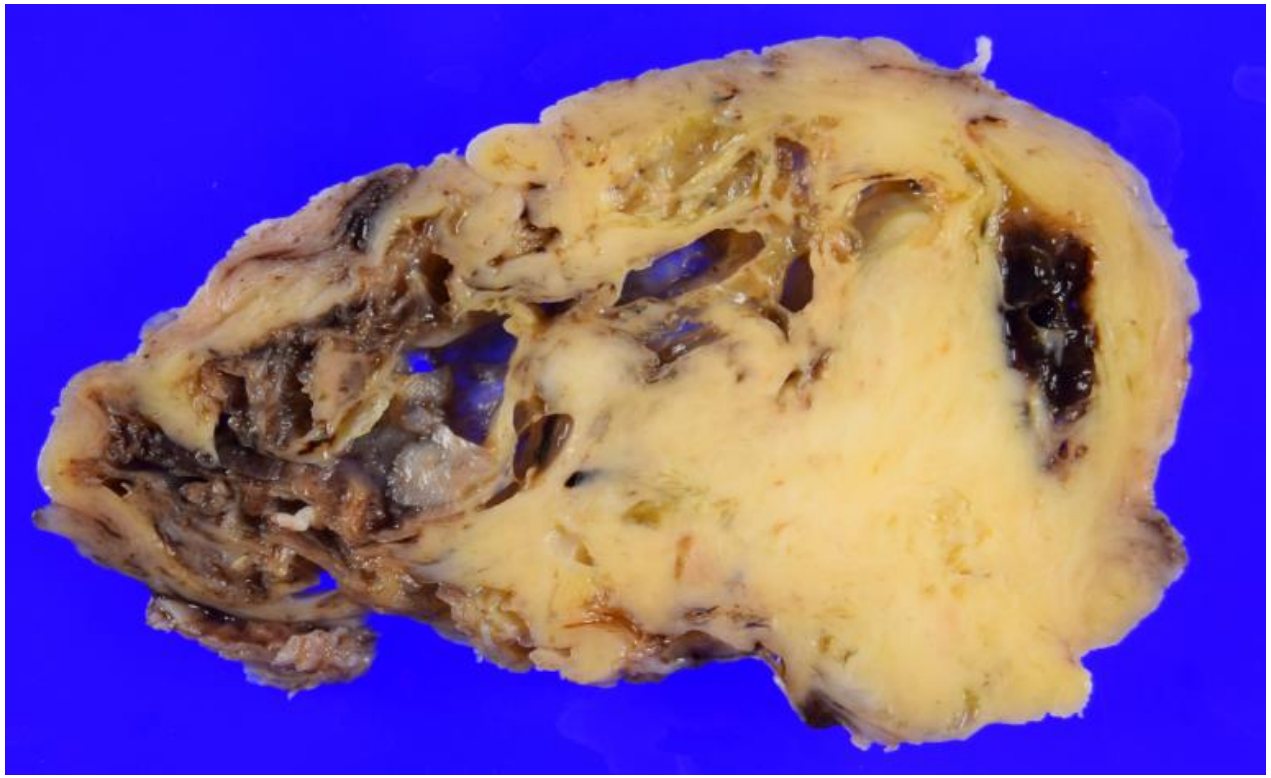

# Single Tissue Section per Cassette Maximizes Spatial Relationships

*Especially when evaluating interface with necrosis*





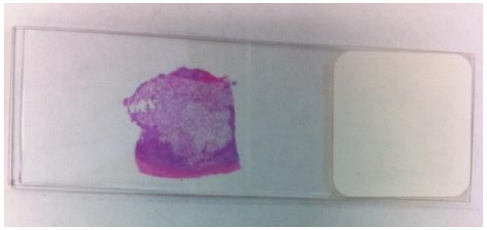









# Tissue Sampling of Hysteroscopic Myomectomy or Morcellated Myomectomy

- **“Data-free” zone**
- **Strategy is institution dependent**
- **My institution’s strategy**

| Weight | Strategy |
|---|---|
| ≤ 10 gr | Entire specimen is submitted |
| >10 gr | Submit 5 cassettes plus 1 cassette for each additional 5 gr up to 10 cassettes |



# Practical “Algorithmic” Approach to Necrosis in Uterine Smooth Muscle Tumors

*Assess Tissue Sampling Strategy*



**If there is “ambiguous” type necrosis:**

- **Re-examine the gross specimen**
- **Confirm that it has been fully dissected** (fully sliced through at 0.5 cm intervals)
- **Determine if tissue sampling is “thorough”**
- **Apply a low threshold for submitting additional tissue**

# Granulation Tissue May be Only Variably Present in Degenerating Leiomyoma

**Initial H&E's**

**Uncertain if granulation tissue is really present**

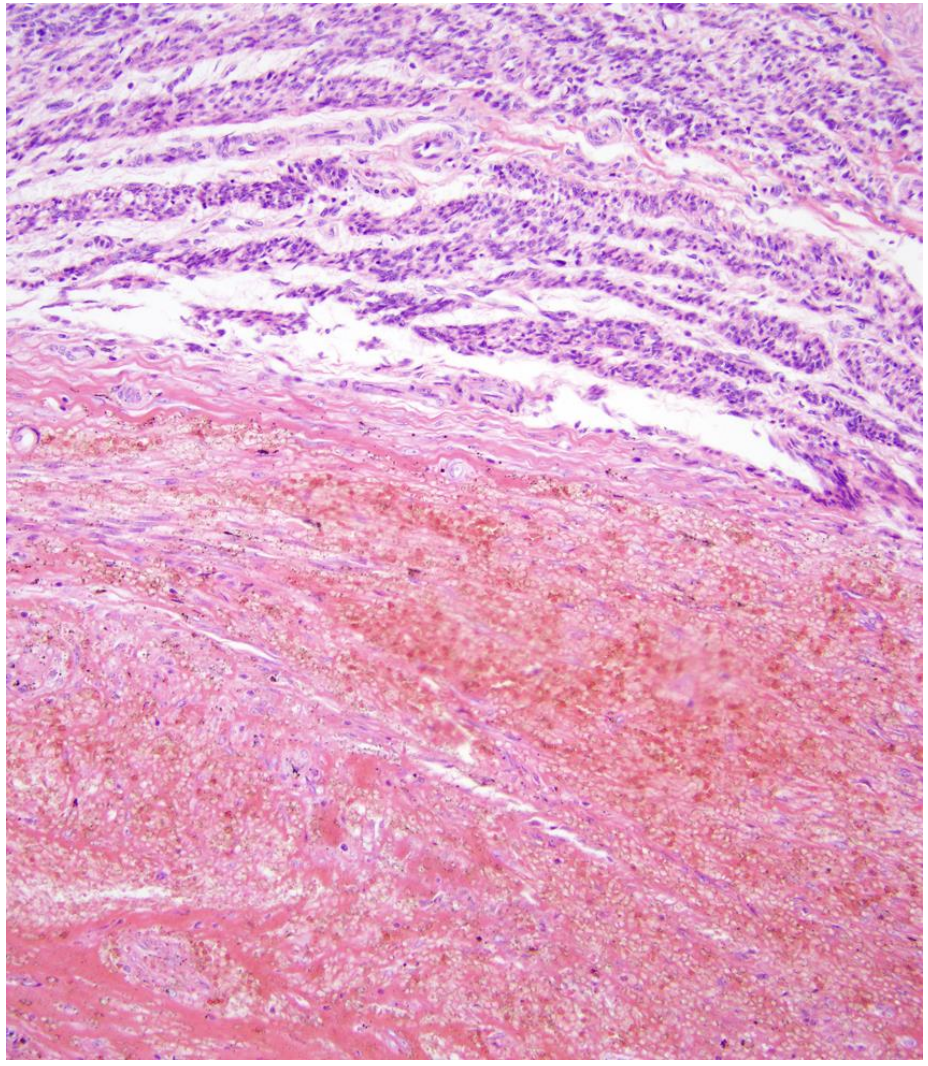

**Additionally submitted H&E's**

**Granulation tissue confirmed to be present**

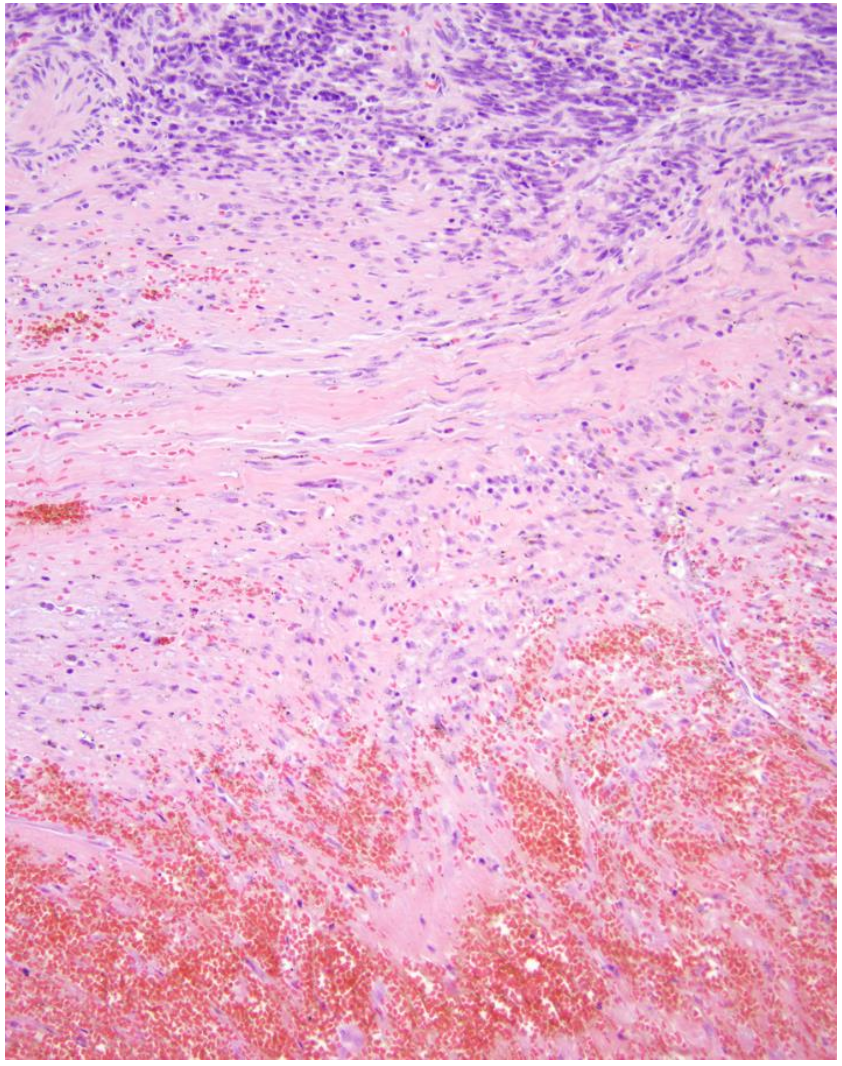

# Practical “Algorithmic” Approach to Necrosis in Uterine Smooth Muscle Tumors

- **Assess clinical context:** age, pharmacologic treatment, interventions (UAE, cryotherapy, RFA)
- **Assess macroscopy:** size, borders, necrosis
- **Assess tissue sampling strategy:** adequacy, location
- **Assess microscopy:** awareness of criteria and mimics

# Practical “Algorithmic” Approach to Necrosis in Uterine Smooth Muscle Tumors

*Assess microscopy using WHO criteria*

- **H&E stain morphologic criteria for tumor-type necrosis versus benign mimics**
- **Special stains / immunohistochemistry ?** *Not accurate enough to reliably distinguish sarcoma vs mimics*

| Test | Comments | |
|---|---|---|
| Trichrome stain | Stains stroma of granulation tissue in leiomyoma but not in leiomyosarcoma | PMID: 17667546 |
| Reticulin stain | “Honeycomb” outline of ghost tumors cells is present in most leiomyosarcoma but only in a minority of leiomyoma | PMID: 25698060 |
| Ki67, p53, p16, PHH3 immunostains | WHO criteria: markers not accurate enough to distinguish leiomyosarcoma versus mimics | |

**Leiomyoma**

**Leiomyosarcoma**

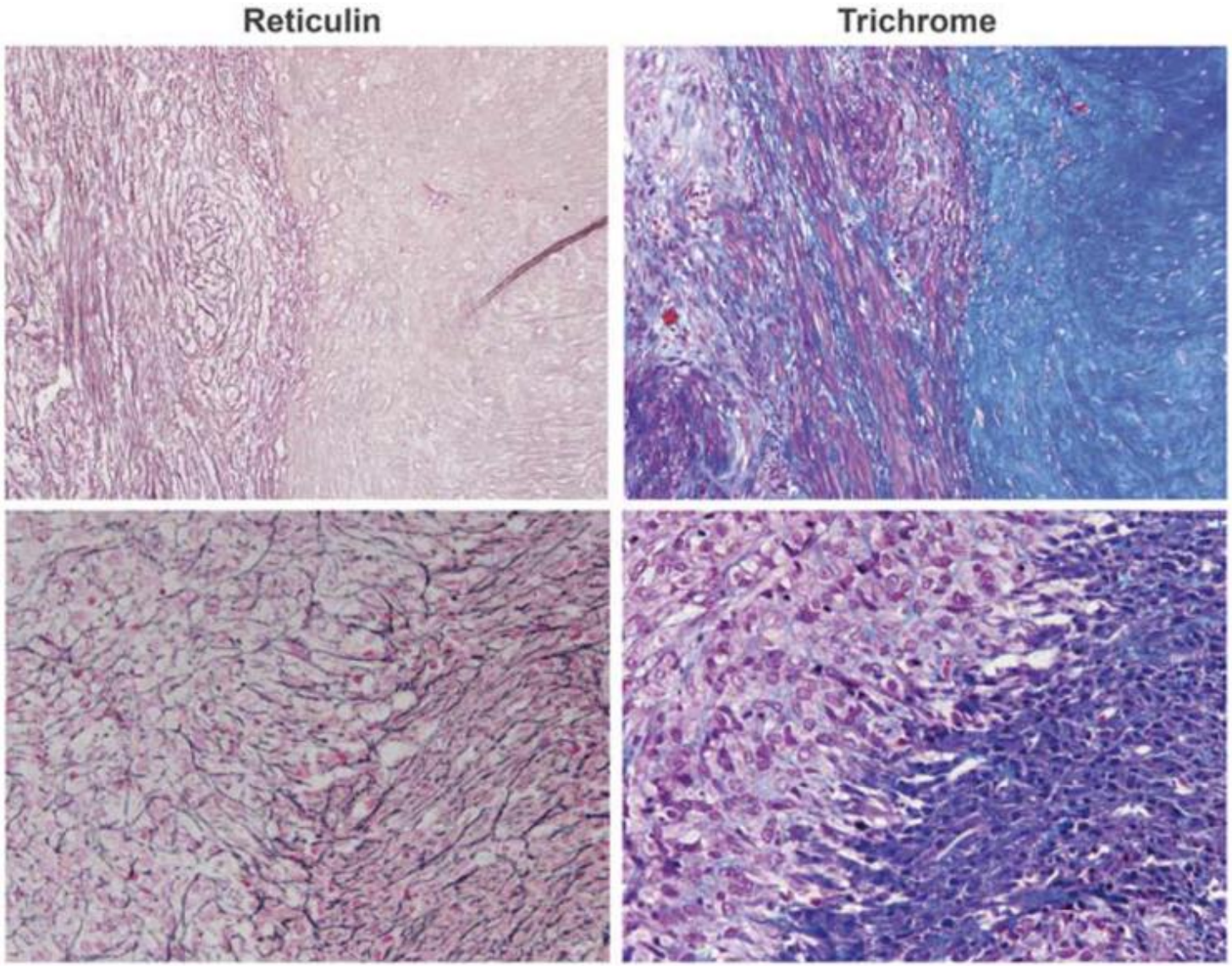


Images from PMID: 25698060

# Practical “Algorithmic” Approach to Necrosis in Uterine Smooth Muscle Tumors

- **Assess clinical context:** age, pharmacologic treatment, interventions (UAE, cryotherapy, RFA)
- **Assess macroscopy:** size, borders, necrosis
- **Assess tissue sampling strategy:** adequacy, location
- **Assess microscopy:** awareness of criteria and mimics

- **Algorithm Outcome:**

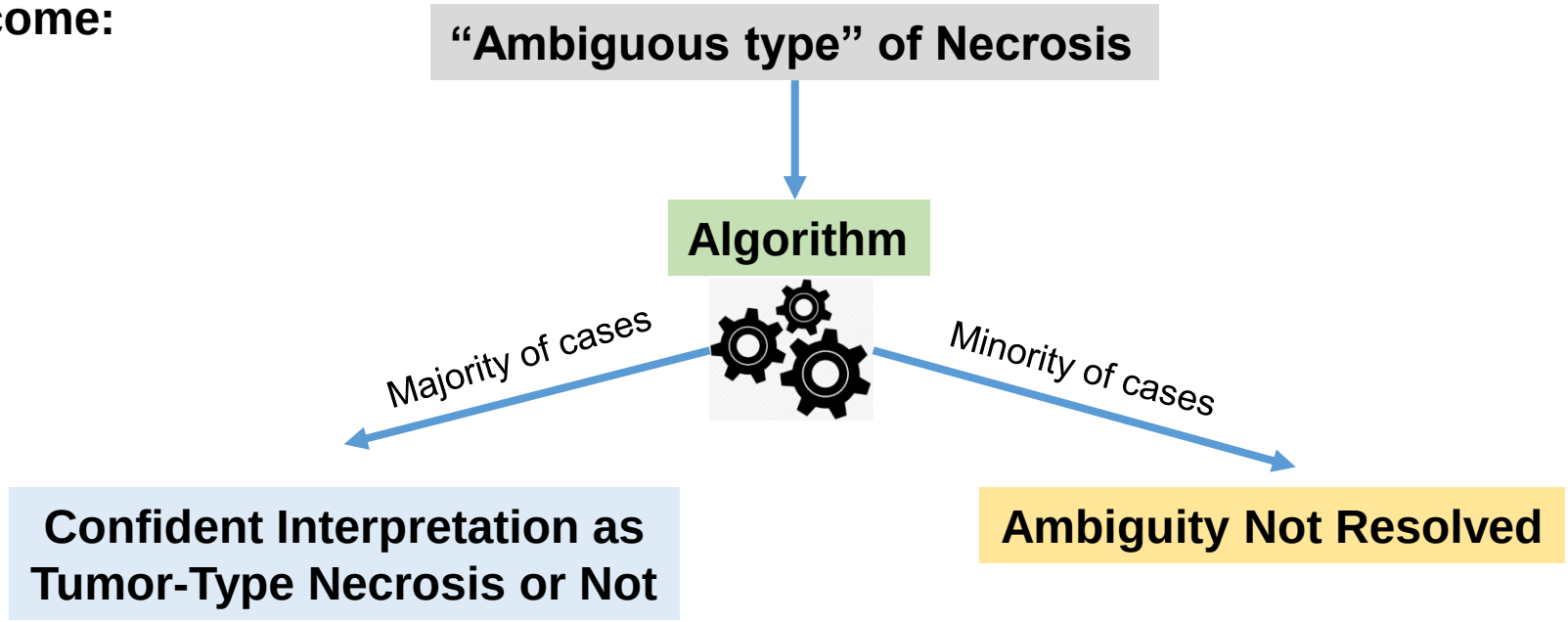

# Outline of Talk

- **Significance of tumor-type necrosis in prognostic classification of uterine smooth muscle tumors**
- **Definition of tumor-type necrosis**
- **Mimics of tumor-type necrosis**
- **Ambiguous types of necrosis:** *Practical algorithm for managing cases*



