The British Association of Gynaecological Pathologists

Lecturer – Professor Glenn McCluggage

I am a consultant Histopathologist in Belfast Health and Social Care Trust, Belfast and an Honorary Professor in Gynaecological Pathology of Queen's University of Belfast. I have published approximately 600 papers in peer reviewed journals, including original publications and many invited editorials and reviews. I am on the Editorial Board of several major pathology journals (Modern Pathology, Human Pathology, Advances in Anatomic Pathology, International Journal of Gynecological Pathology), a member of the International Advisory Board of Journal of Clinical Pathology and associate editor of Histopathology. I am past President of International Society of Gynecological Pathologists and was previously secretary of this society. Previously I was President of the British Association of Gynaecological Pathologists. I am on the council of European Society of Pathology. I have an extremely busy referral practice and receive numerous consultation cases from all over the world. I have been invited to lecture at numerous national and international meetings. I have authored or coauthored the various Royal College of Pathologists datasets in United Kingdom on reporting of gynaecological malignancies and have chaired the ICCR (International Collaboration on Cancer Reporting) panels developing international guidelines for reporting endometrial, ovarian, cervical, vulval and vaginal carcinomas. I am also the ICCR series champion for gynaecological neoplasms. I have been part of the last three World Health Organization (WHO) groups formulating the classification of Tumours of the Female Genital Tract and am one of the editors on the latest 2020 WHO Classification.



The British Association of Gynaecological Pathologists

Benign Endometrial Pathology: Selected Issues

W Glenn McCluggage

Department of Pathology, Belfast Health and Social Care Trust, Belfast, UK

The British Association of Gynaecological Pathologists

Speaker disclosures

Choose one

- ❑ I have no financial conflicts of interest to disclose

ENDOMETRIAL BIOPSIES

- Major part of work-load of general and gynaecological pathologists
- Most are benign and most are straightforward but some biopsies are problematic
- Often not discussed at meetings or in review articles

TO DISCUSS

- problematic endometrial breakdown
- effects of IUD, including Mirena coil
- epithelial metaplasias (selected)
- unusual features in endometrial polyps
- papillary proliferation of endometrium
- atypical polypoid adenomyoma and adenomyoma
- progestogen treatment of atypical hyperplasia and low-grade endometrioid carcinoma

ENDOMETRIAL BREAKDOWN

- menstrual or non-menstrual (need to assess underlying intact endometrium if present)
- in non-menstrual endometrium, breakdown may be sign of hormone imbalance and cause of abnormal bleeding
- sometimes only see surface breakdown without underlying tissue; this is almost always benign; I tend not to call insufficient
- very florid breakdown with papillary syncytial metaplasia (PSM) and stromal aggregates may rarely mimic malignancy, mainly a serous proliferation

MENSTRUAL ENDOMETRIUM

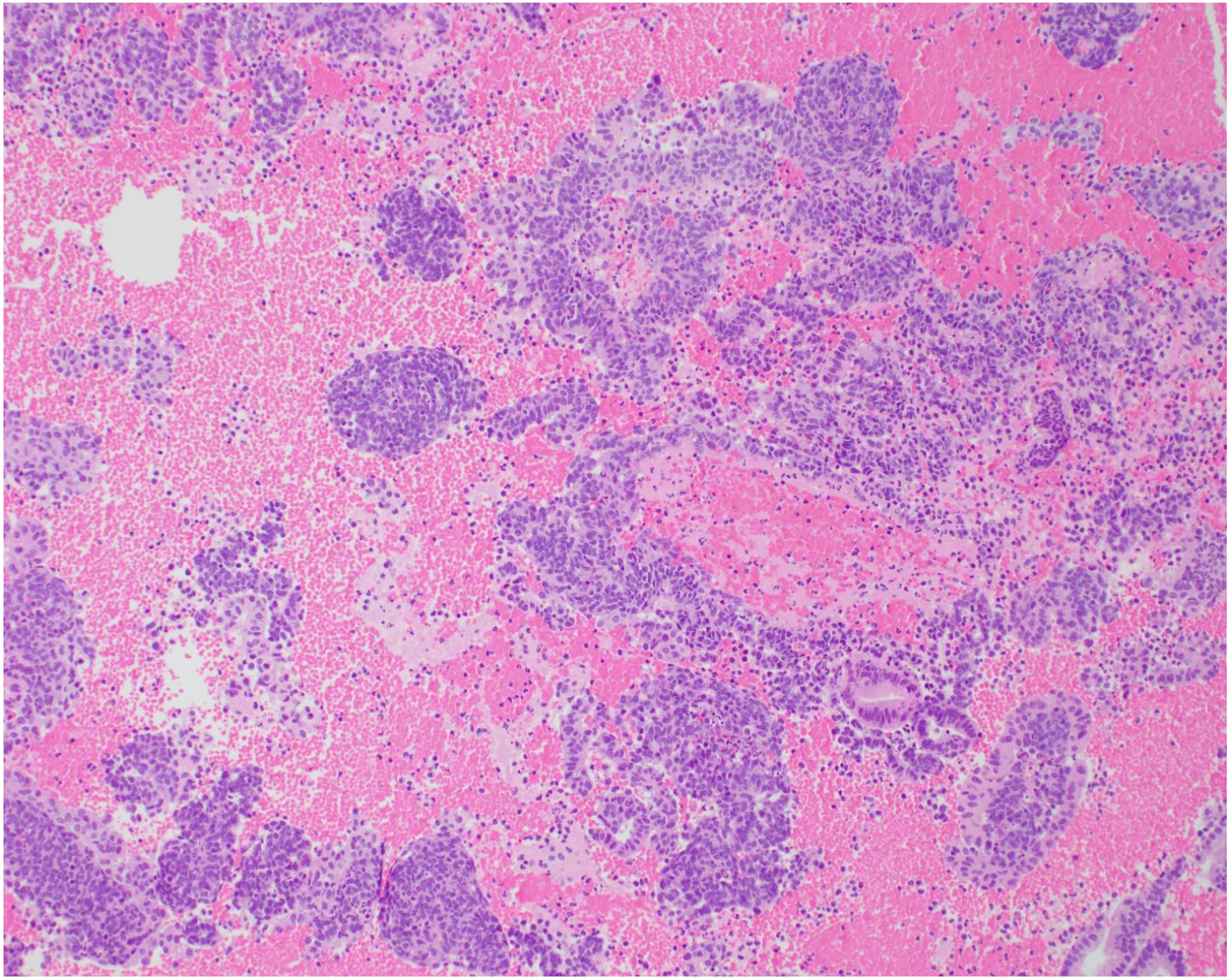

SURFACE BREAKDOWN

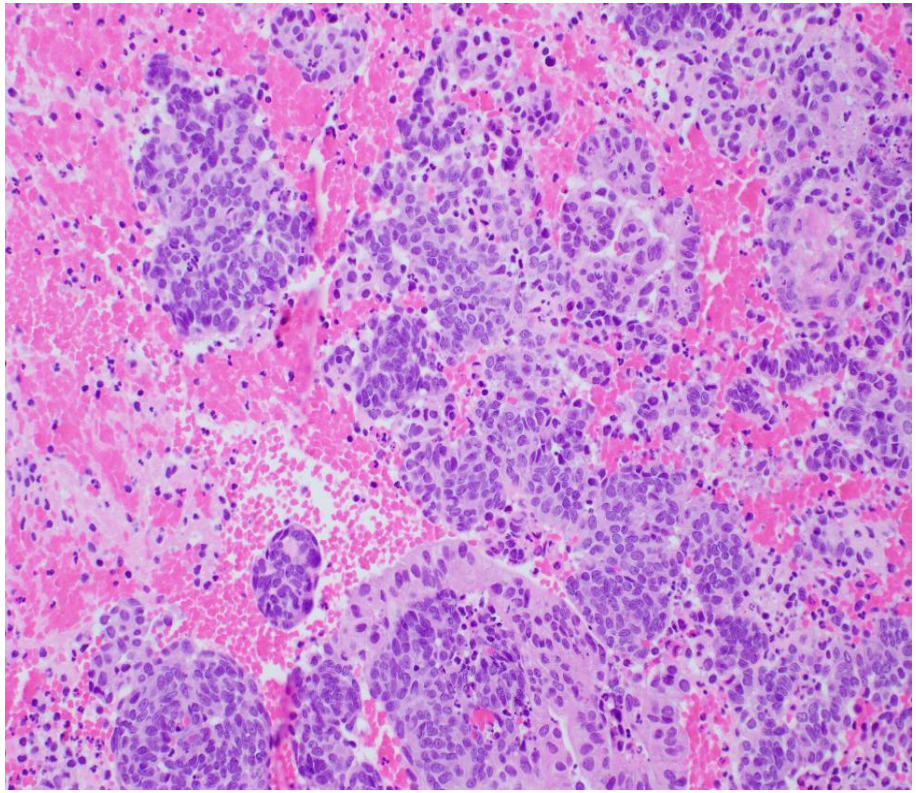

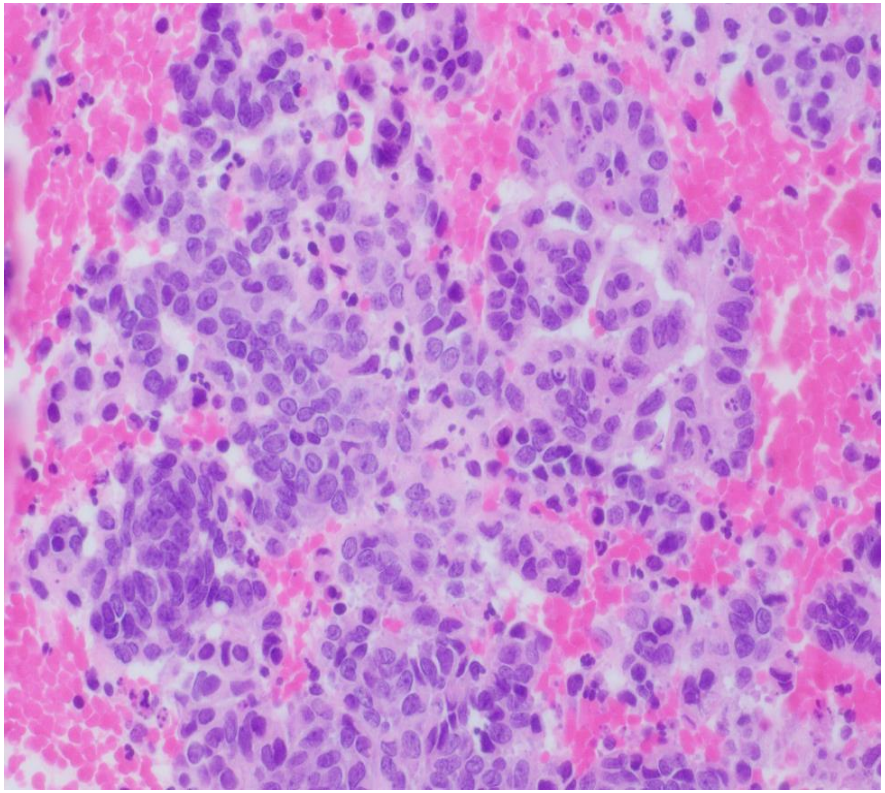

SURFACE BREAKDOWN

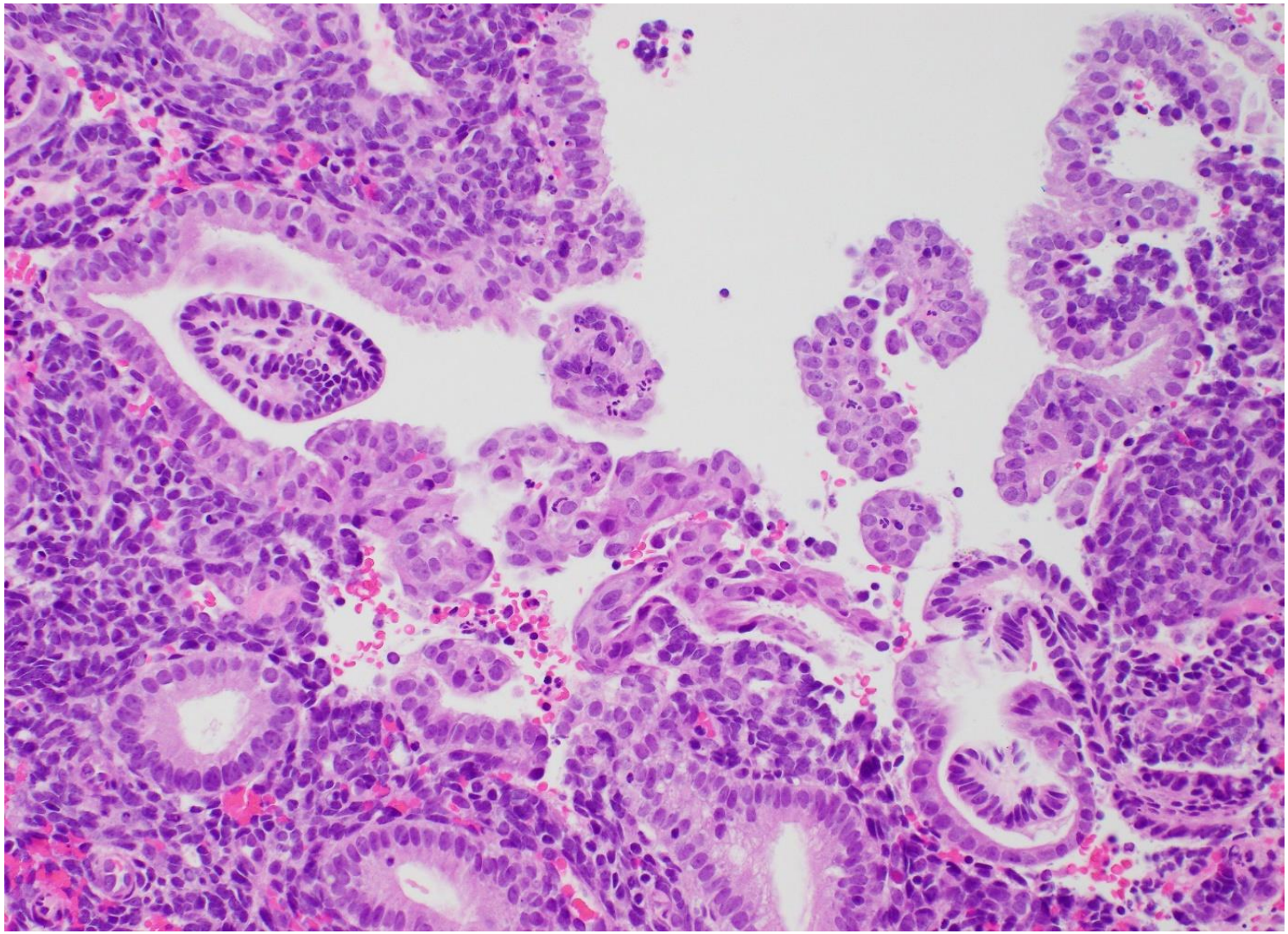

SURFACE BREAKDOWN

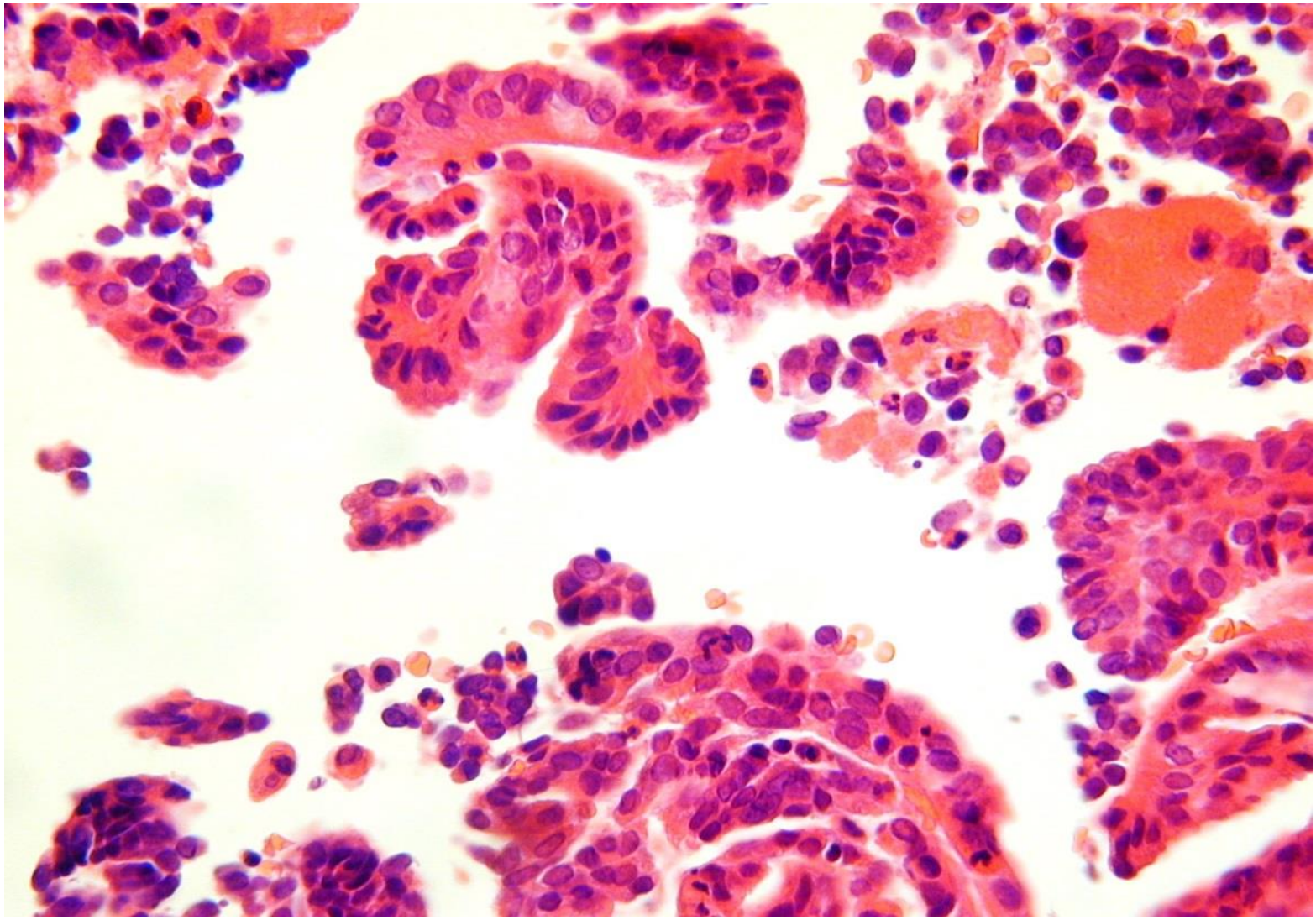

DIFFERENTIAL FROM SEROUS PROLIFERATION

- look for other signs of breakdown (fibrin and fibrin thrombi, stromal aggregates)
- immunohistochemistry- p53, ER, p16, MIB1 (BUT BEWARE)
- immunohistochemistry of PSM: ER often decreased; p53 often increased but “wild-type”; p16 often strongly expressed (also in other surface “metaplasias”)
- ER and p16 of limited value in distinguishing between serous proliferation and benign surface proliferations/ metaplasias- need to rely on p53

PMID 22498936

International Journal of Gynecological Pathology
31:206–210, Lippincott Williams & Wilkins, Baltimore
© 2012 International Society of Gynecological Pathologists

Original Article

Papillary Syncytial Metaplasia Associated With Endometrial Breakdown Exhibits an Immunophenotype That Overlaps With Uterine Serous Carcinoma

W. Glenn McCluggage, F.R.C.Path, and Hilary A. McBride, F.I.B.M.S.

IMMUNOHISTOCHEMISTRY- SURFACE METAPLASTIC CHANGES/ PSM/ IUD EFFECT

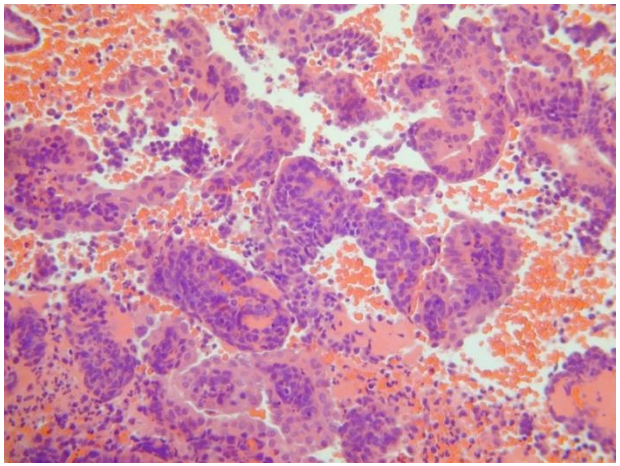

ER

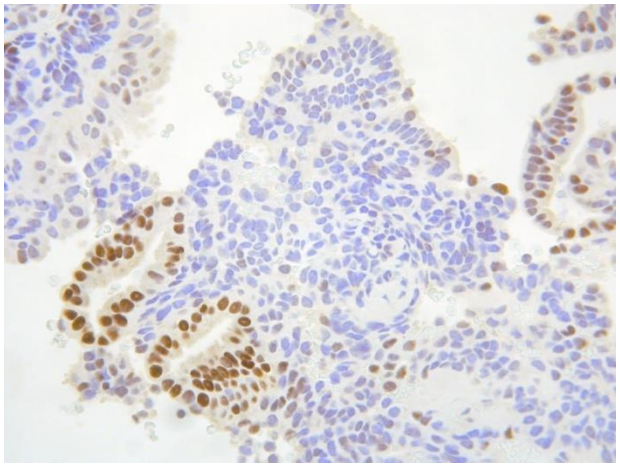

p53

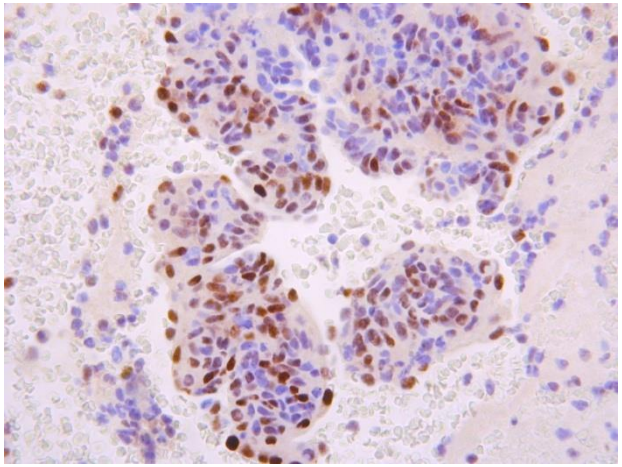

p16

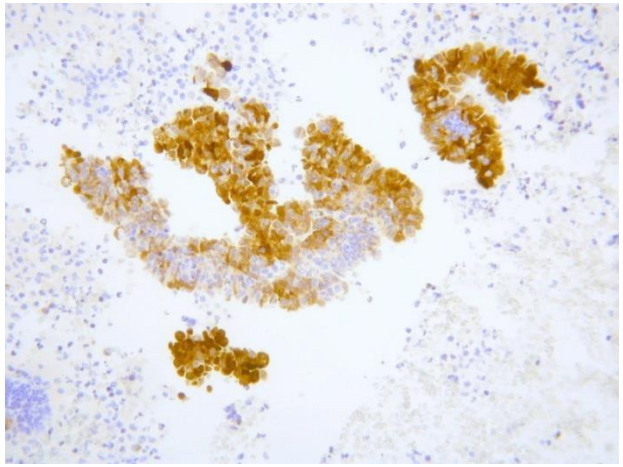

IUD EFFECTS

- Mirena coil
- Mechanical effects of IUDs in general ("reactive" atypical surface epithelial changes)
- Actinomyces/ pseudoactinomyces

PMID 12663645

SHORT REPORT

The effects of the levonorgestrel intrauterine system (Mirena coil) on endometrial morphology

V Phillips, C T Graham, S Manek, W G McCluggage

J Clin Pathol 2003;**56**:305–307

MIRENA COIL- MORPHOLOGIC FEATURES

- SAME AS ORAL PROGESTOGENS BUT TYPICALLY MORE FLORID
- low-power polypoid architecture
- atrophic or weak secretory glands
- stromal expansion and pseudodecidualisation
- inflammatory infiltrate (NK cells) (sometimes true endometritis- get plasma cells)
- stromal necrosis
- stromal myxoid change
- hyaline bodies
- haemosiderin pigment
- rarely calcification or granuloma formation
- “synovial-like” metaplasia
- changes can involve underlying adenomyosis

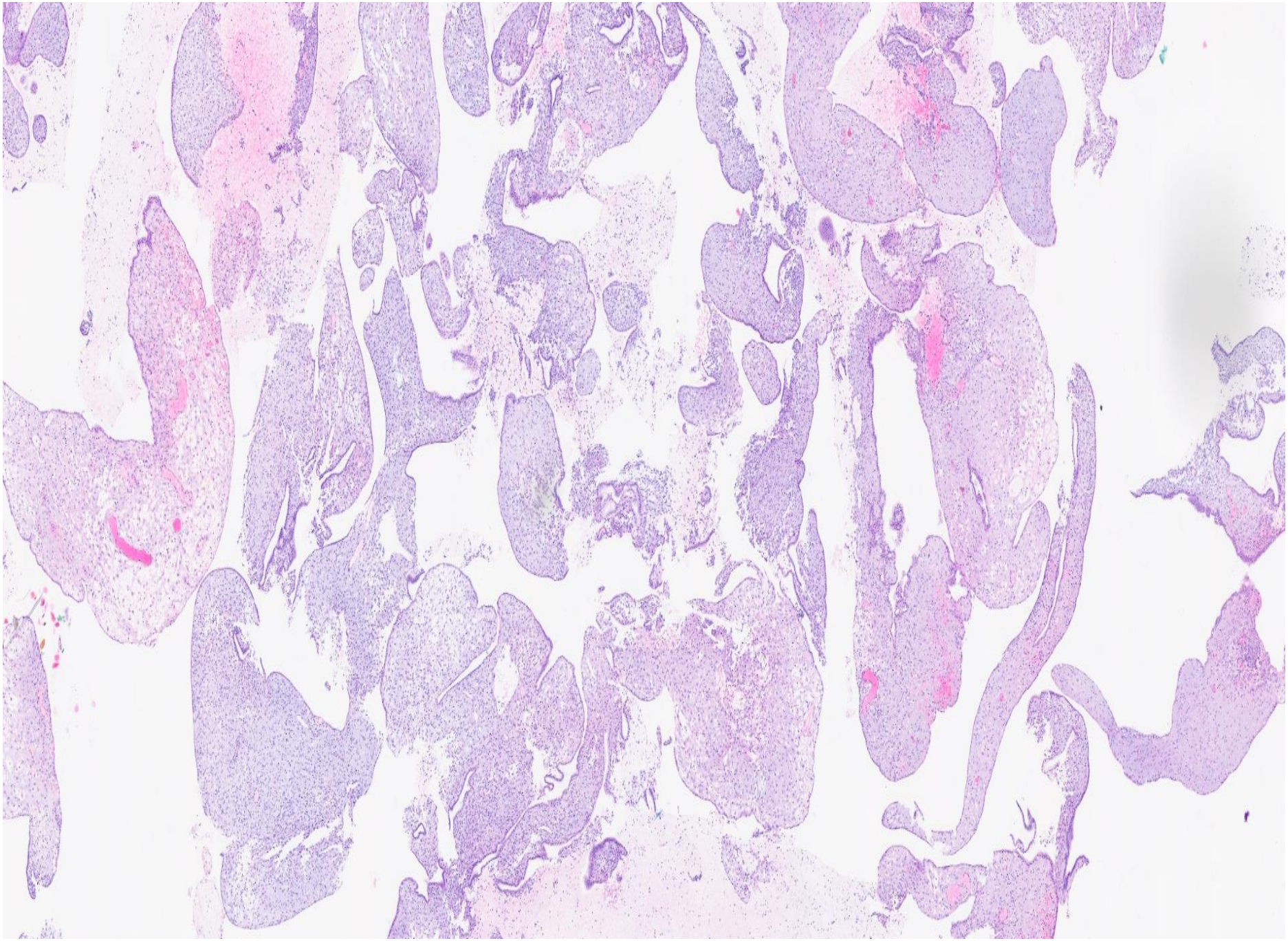

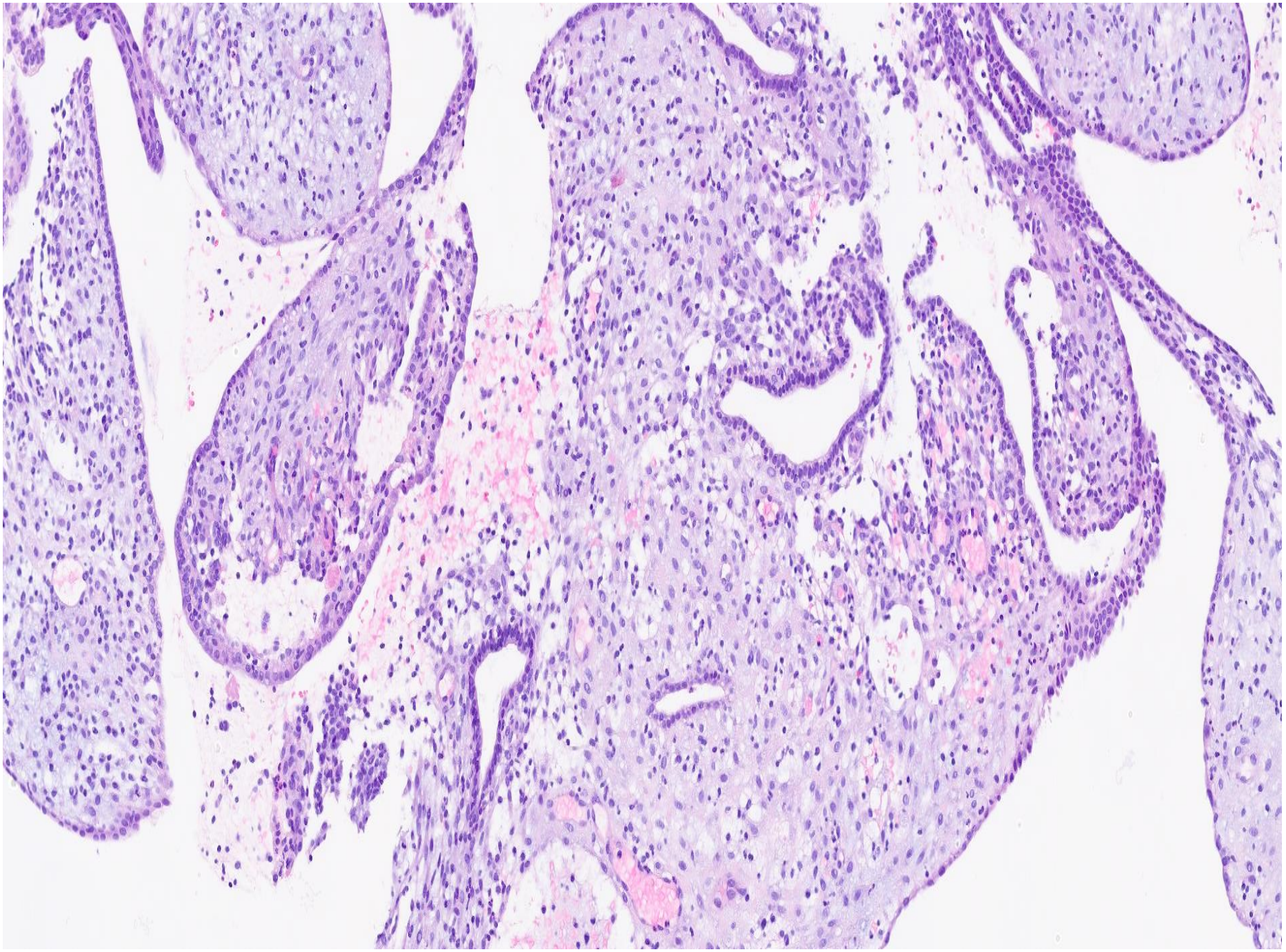

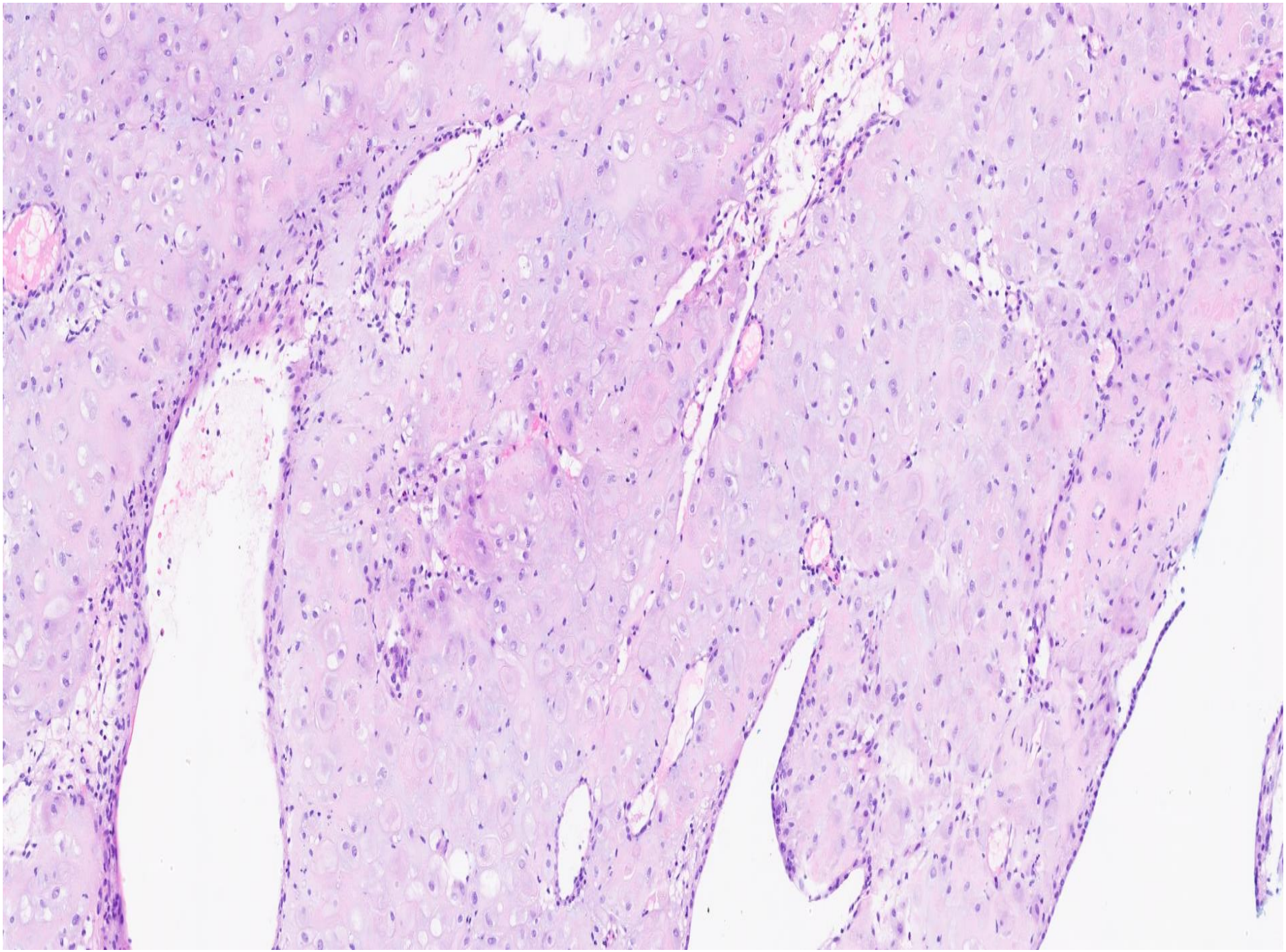

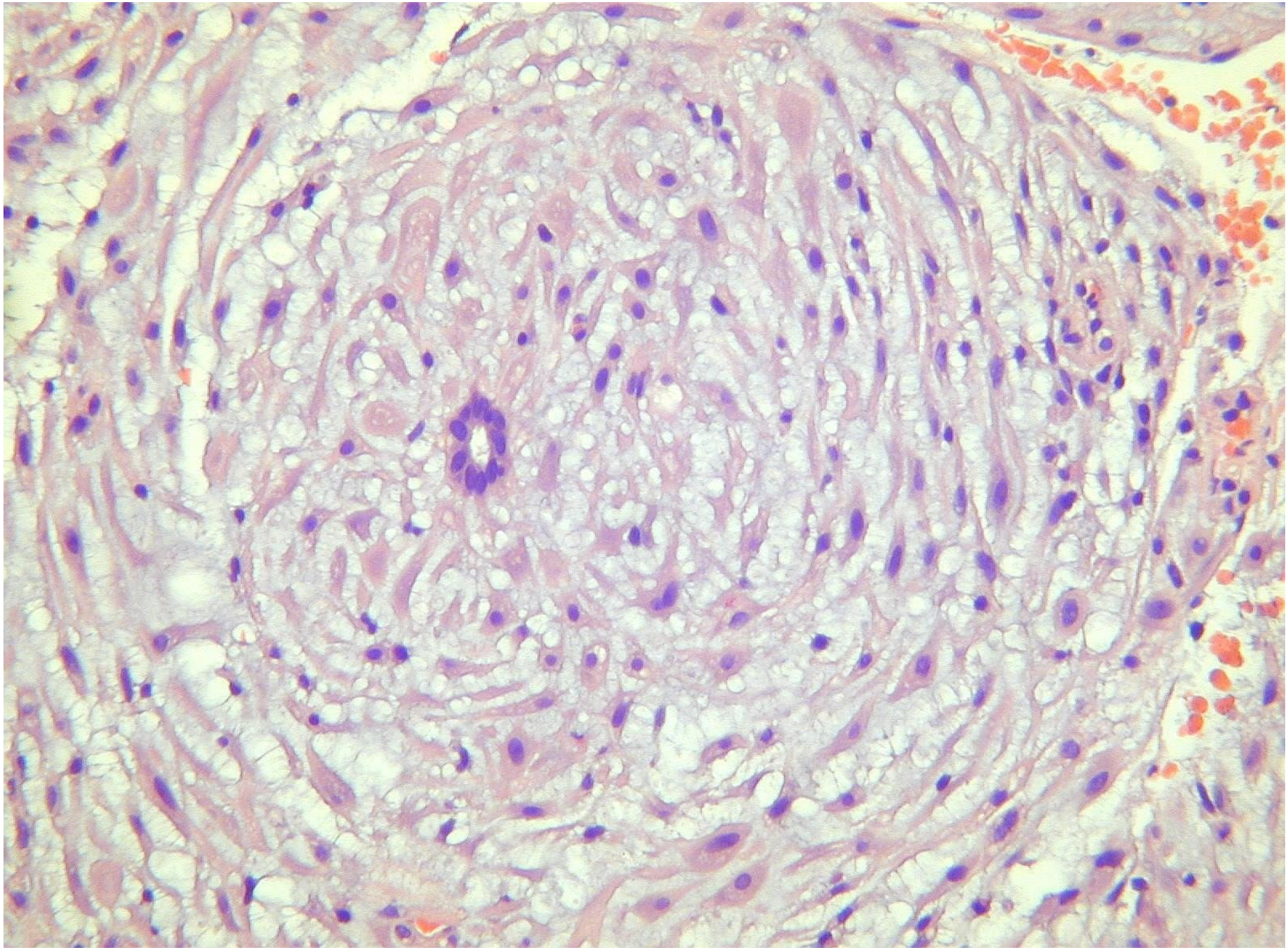

CALCIFICATION

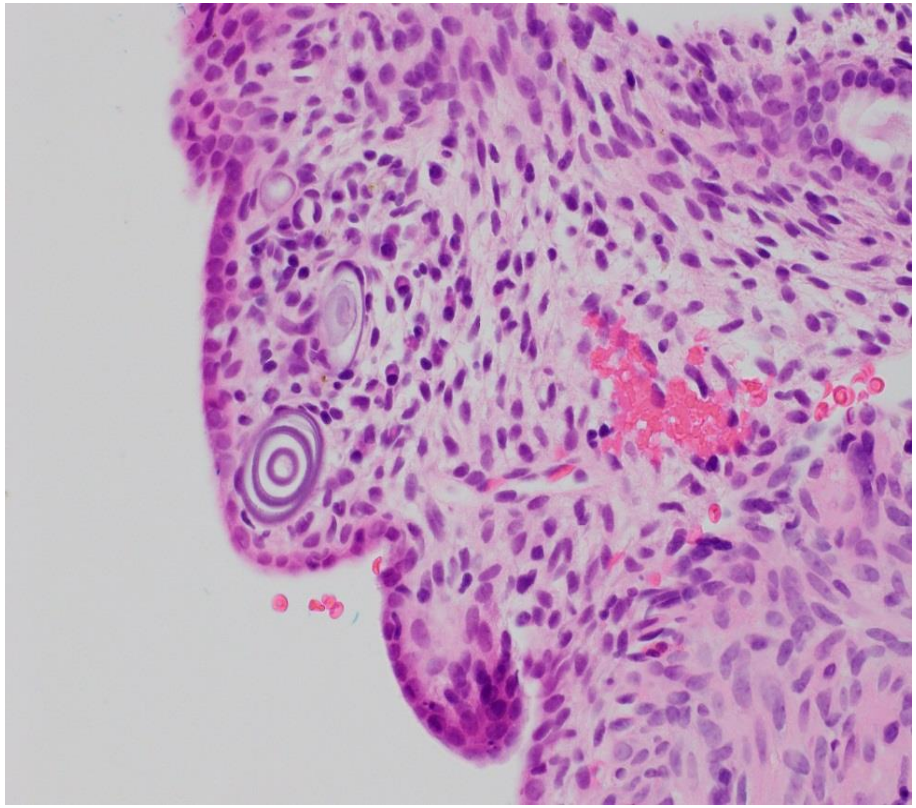

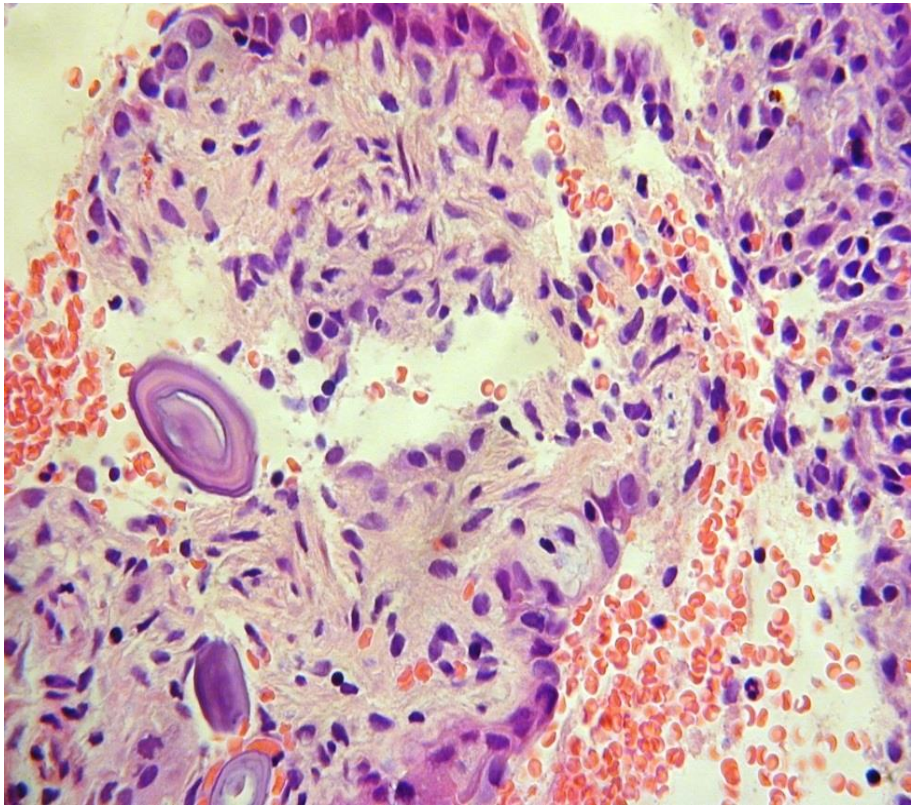

NECROSIS- sometimes abundant with no/ minimal viable tissue and tissue may be passed spontaneously

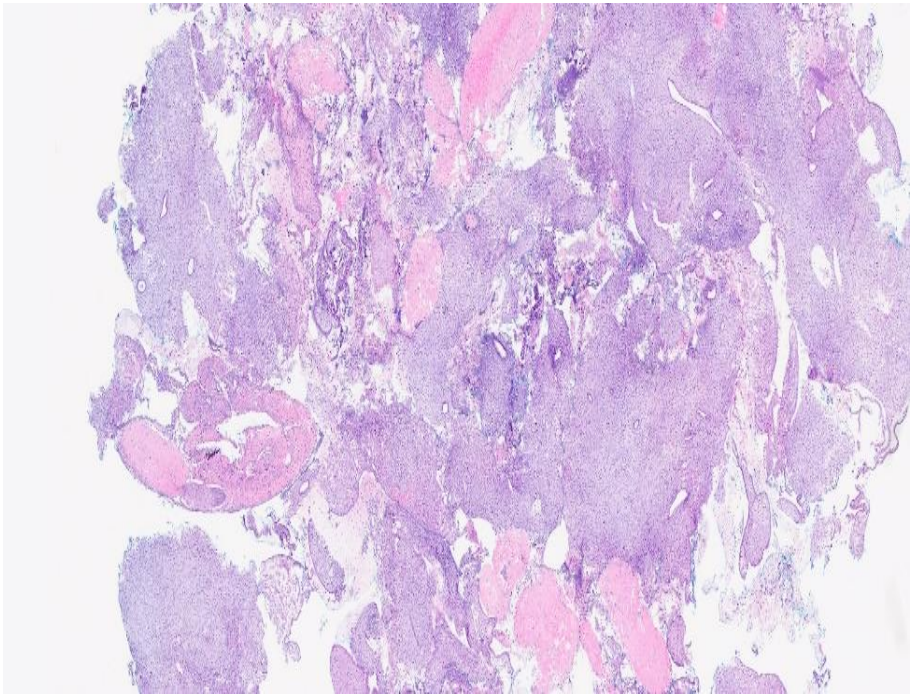

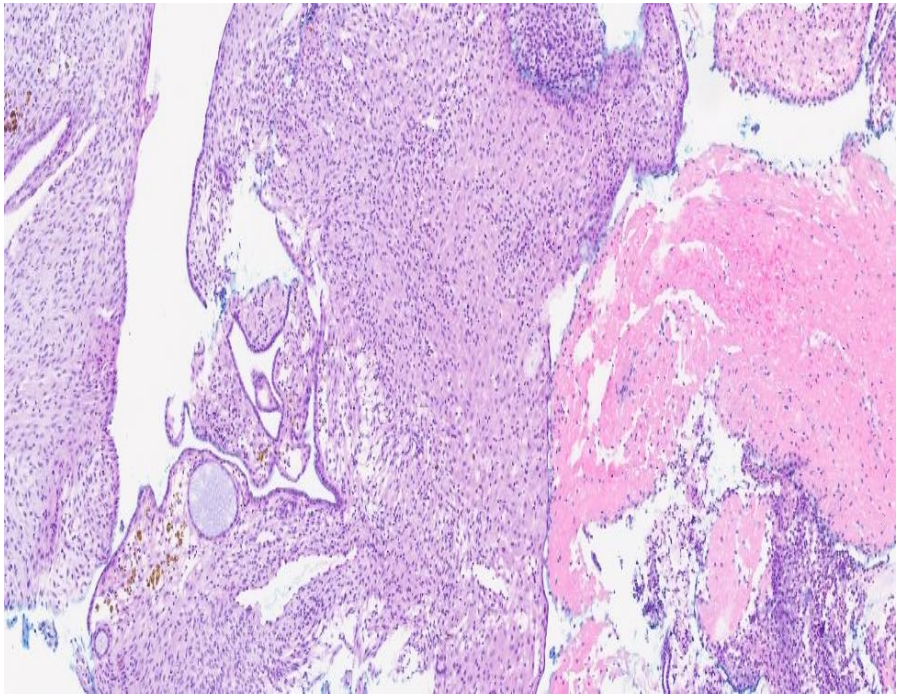

NECROSIS

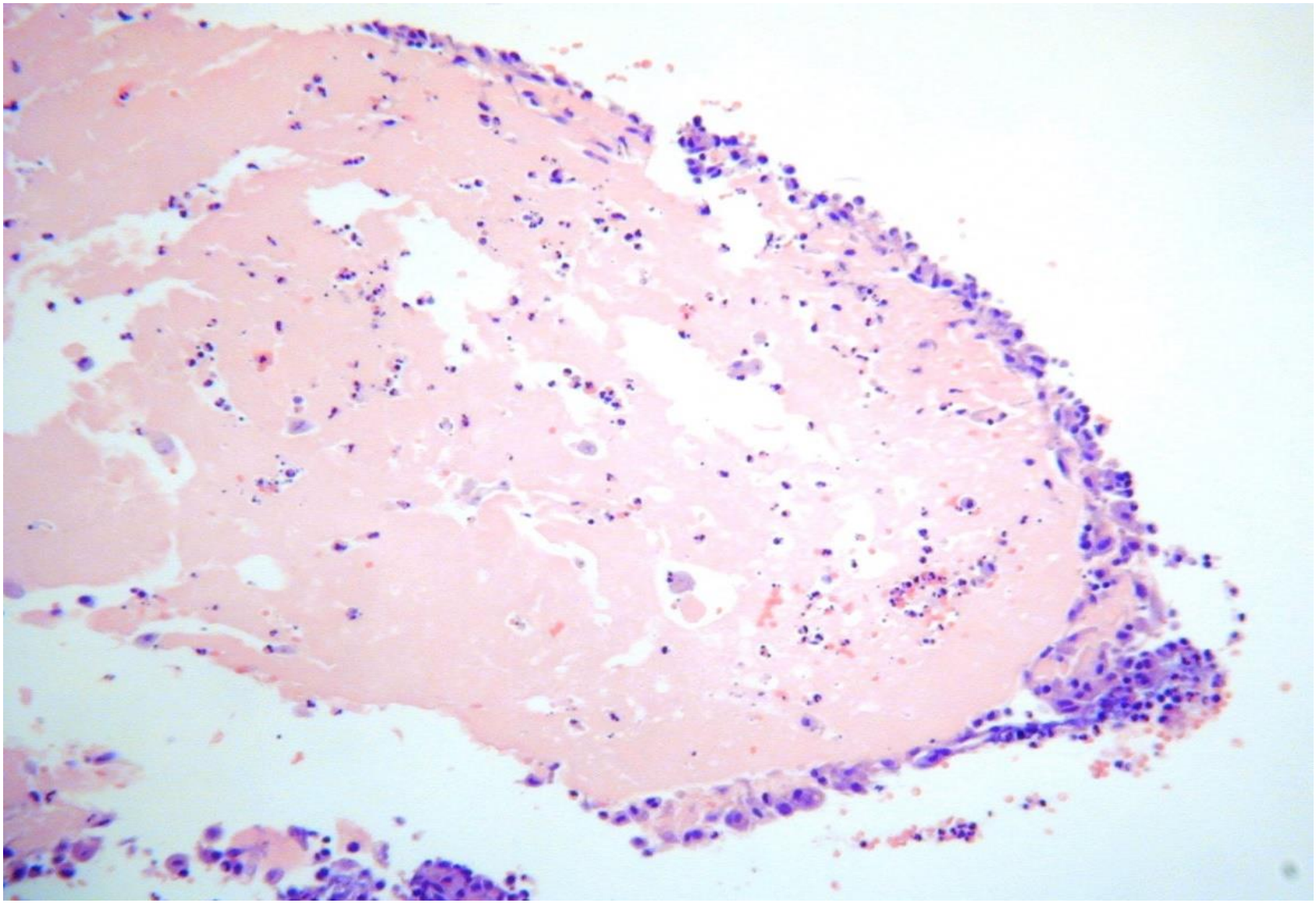

POLYPOID MIMICKING ADENOSARCOMA

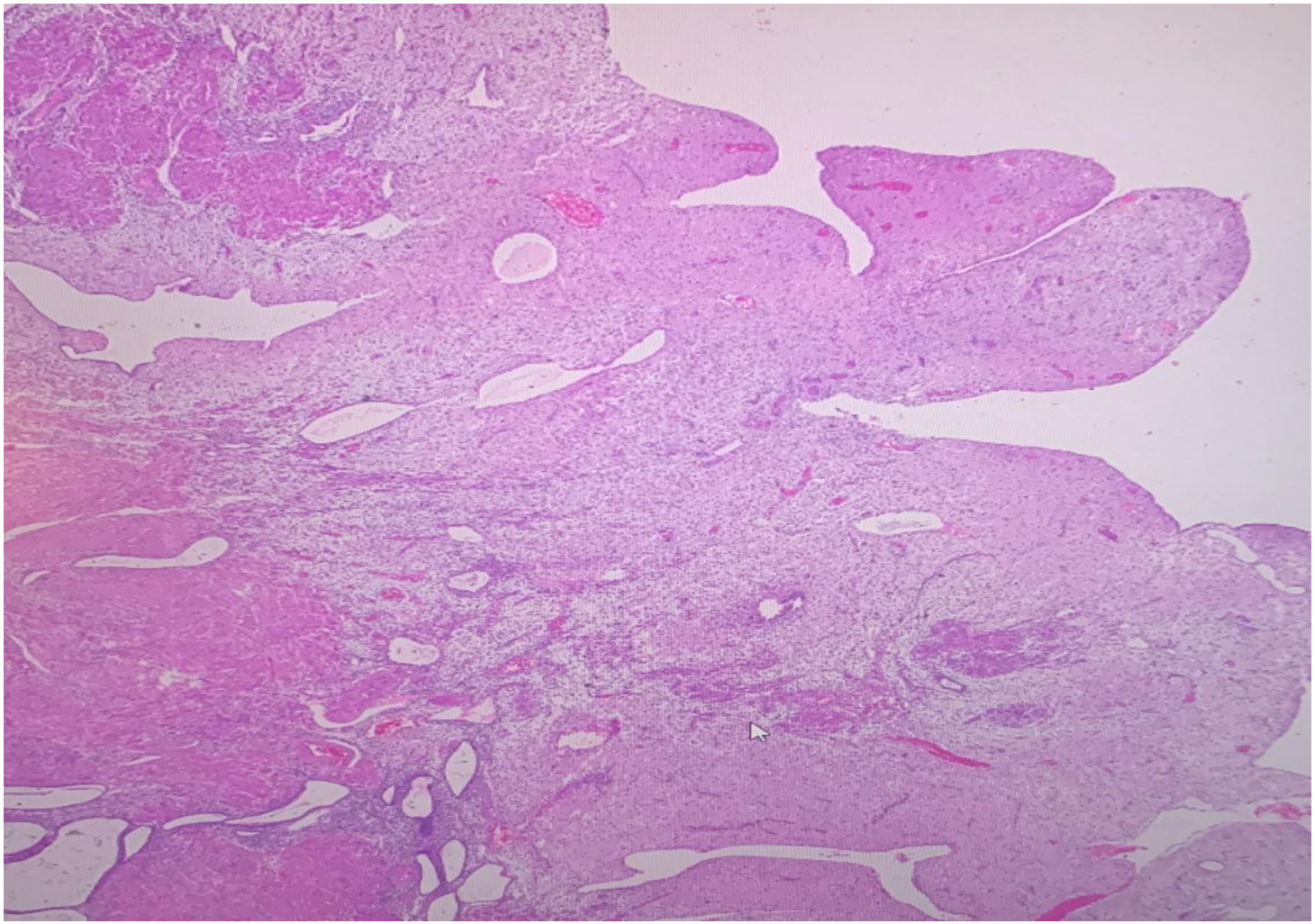

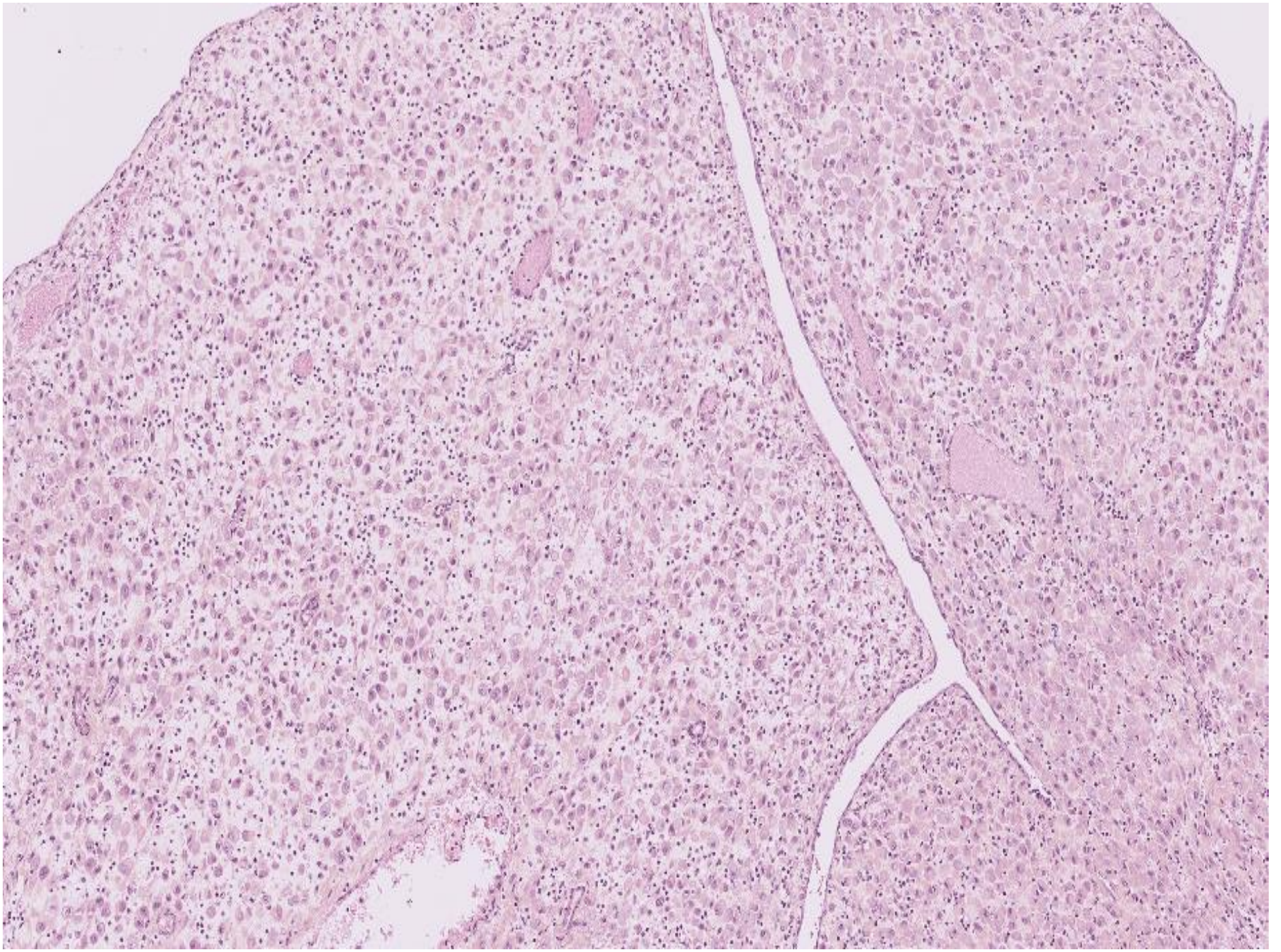

SYNOVIAL-LIKE METAPLASIA- PMID 26447355

International Journal of Gynecological Pathology
34:570–575, Lippincott Williams & Wilkins, Baltimore
© 2015 International Society of Gynecological Pathologists

Original Article

Endometrial Synovial-like Metaplasia Associated With Levonorgestrel-releasing Intrauterine System

Colin J. R. Stewart, F.R.C.P.A. and Robyn Leake, F.R.A.N.Z.C.O.G.

SYNOVIAL-LIKE METAPLASIA- PMID 26447355

- Associated with surface erosion
- Palisaded arrangement of histiocytes and fibroblasts; vimentin and CD68 positive

SYNOVIAL-LIKE METAPLASIA

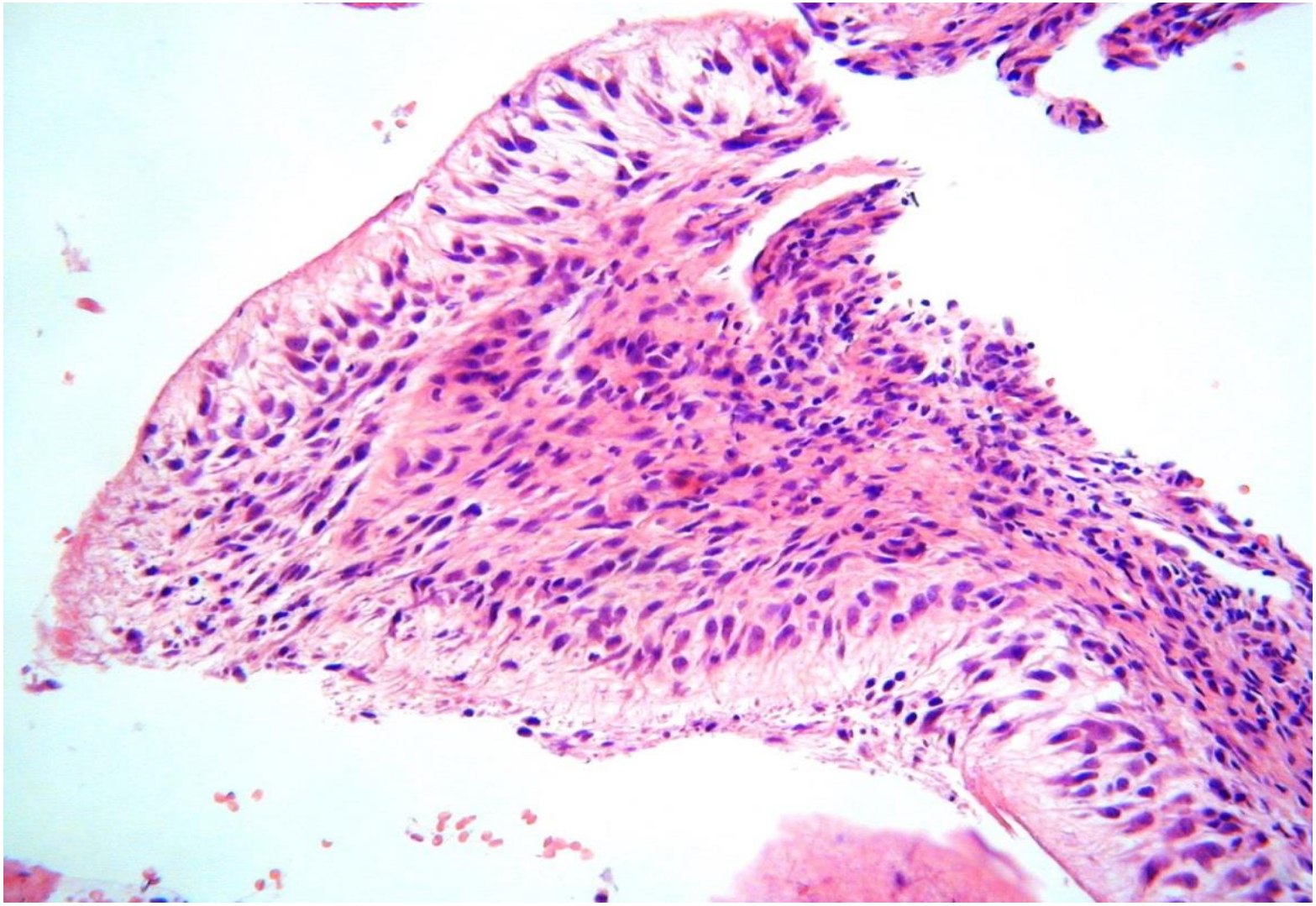

SYNOVIAL-LIKE METAPLASIA

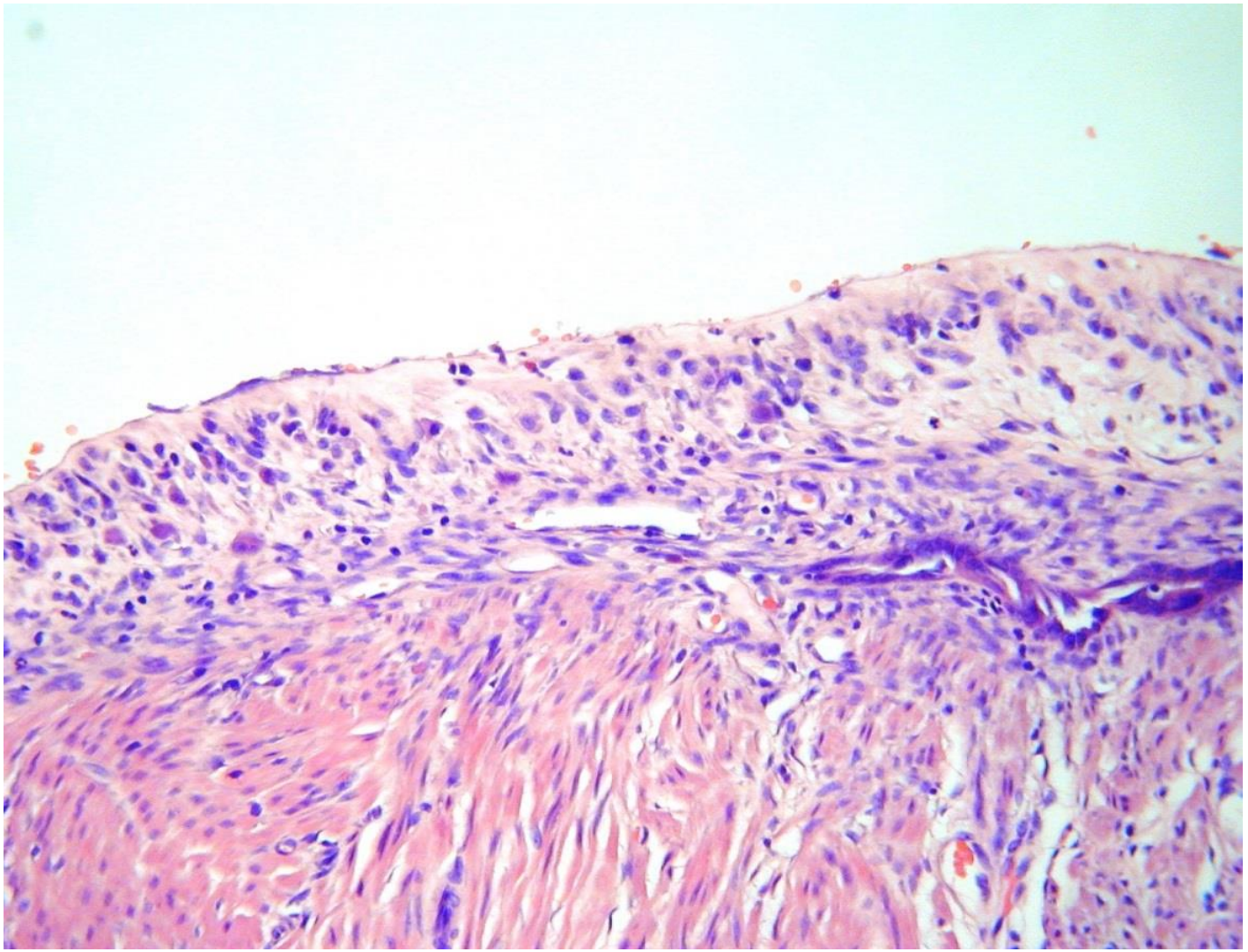

MECHANICAL EFFECTS OF IUD

- surface micropapillary formations
- hobnail cells, sometimes with significant atypia, prominent nucleoli and mitotic activity
- potential for misdiagnosis on scant endometrial biopsy; may raise possibility of serous proliferation
- immunohistochemistry- same comments pertain as for PSM (rely on p53 and not ER or p16)

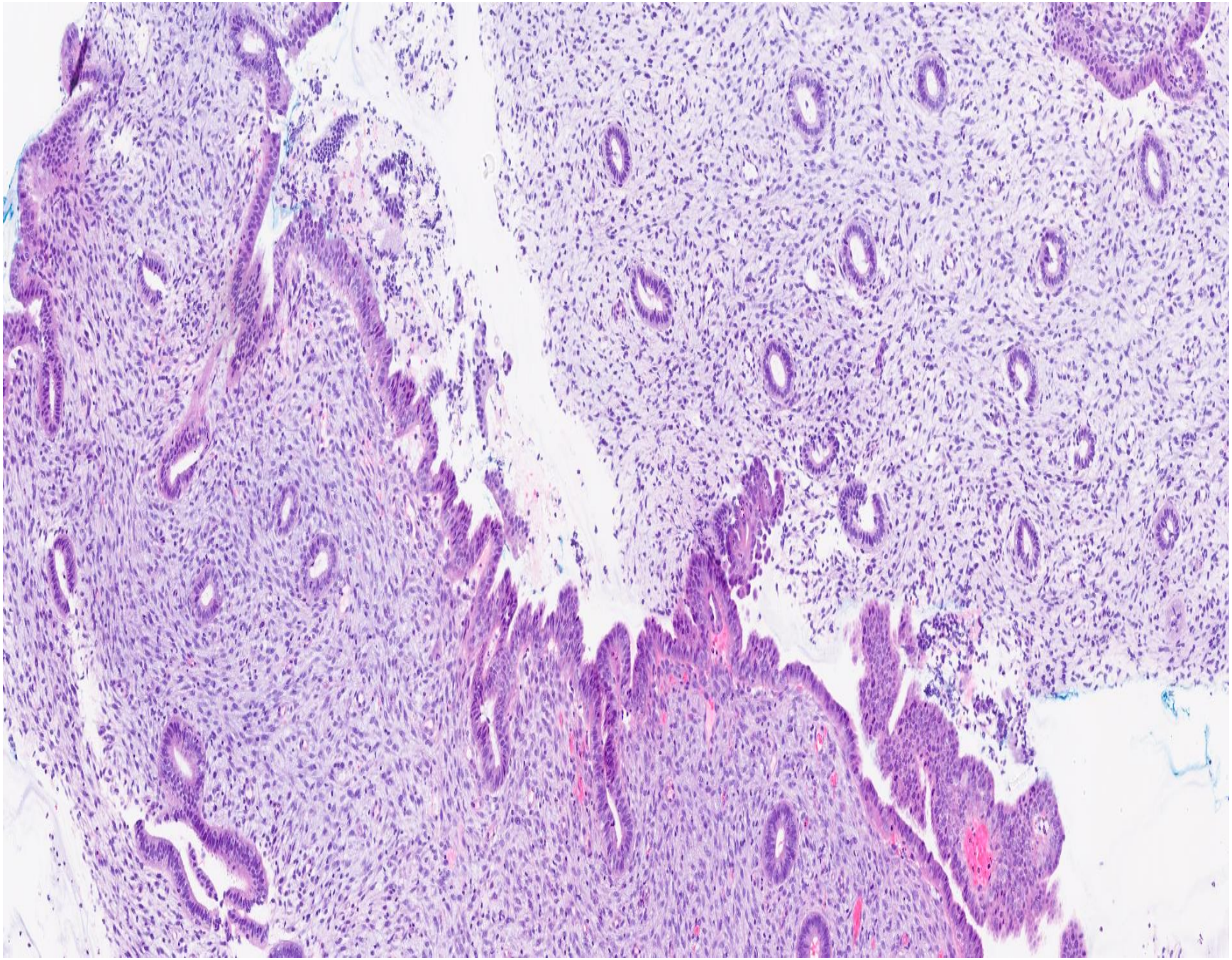

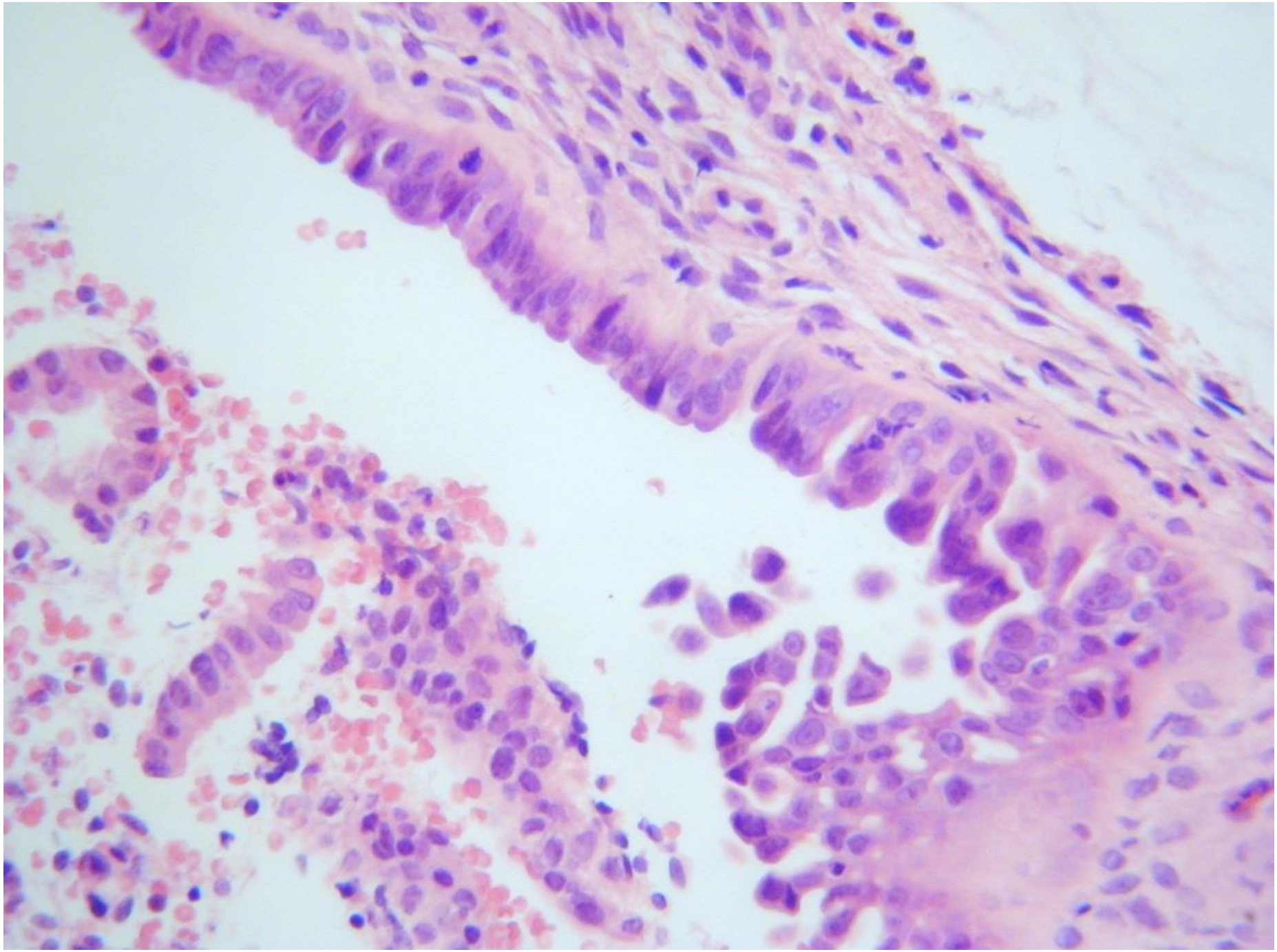

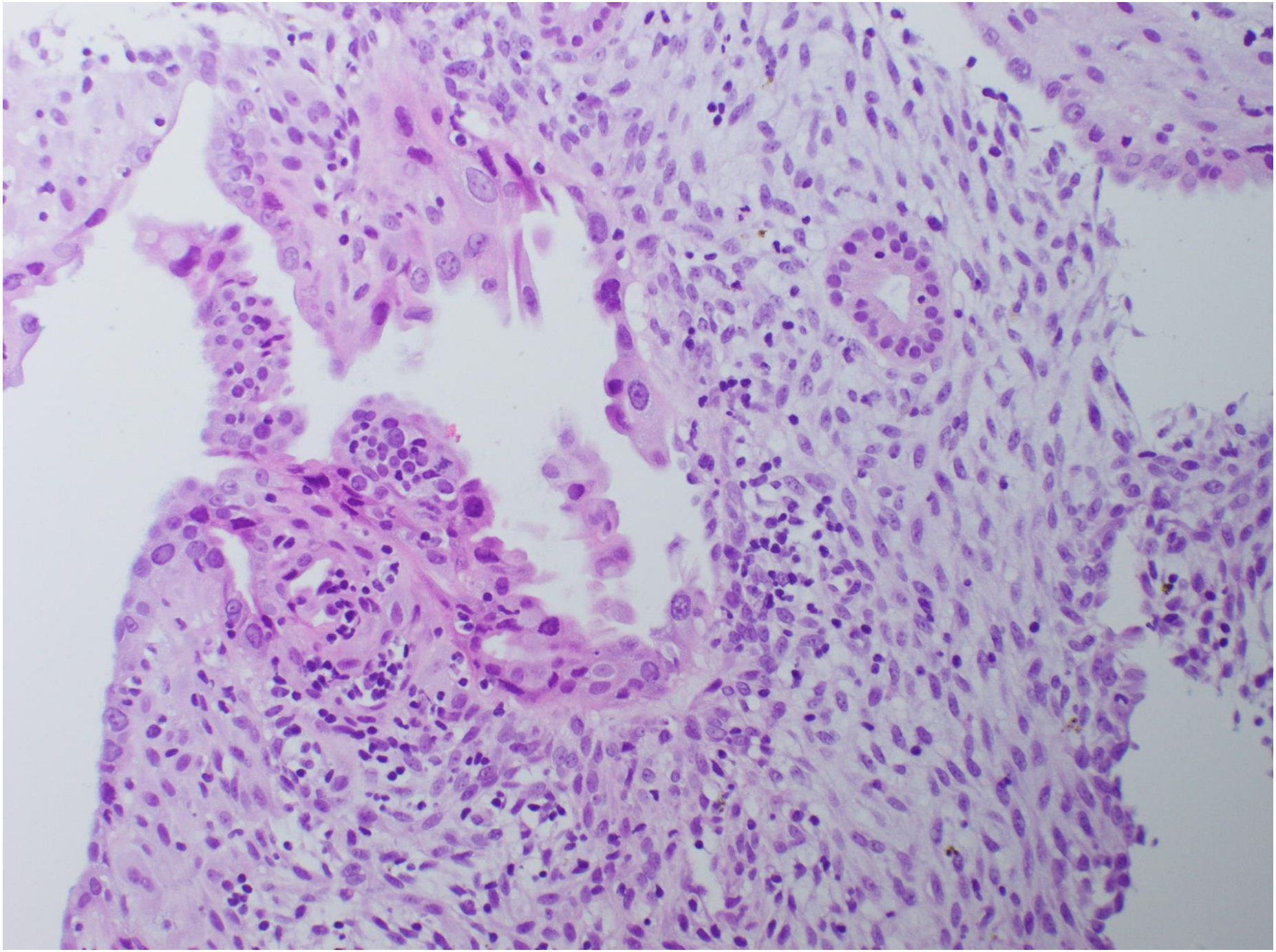

p53

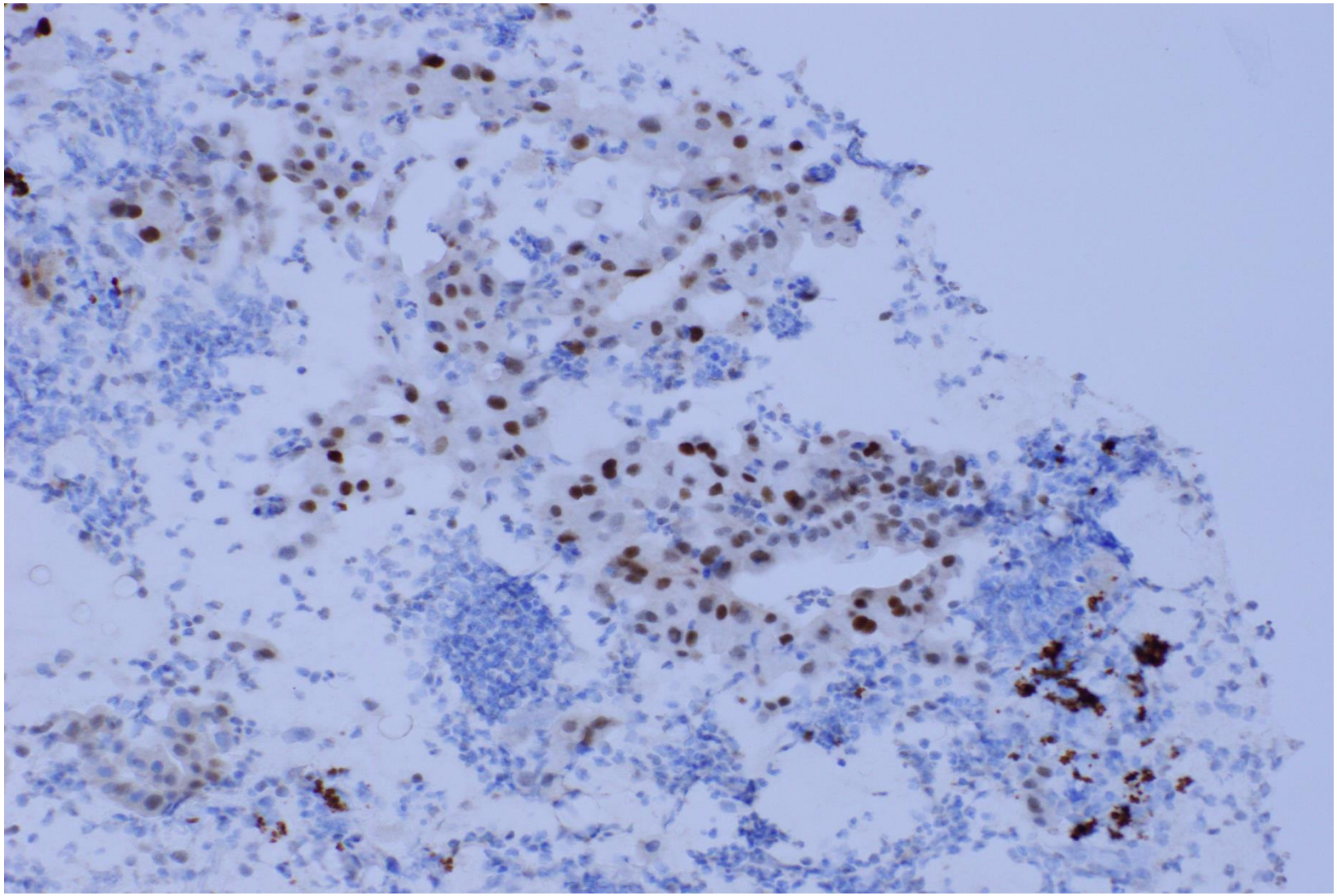

ATYPICAL LOWER UTERINE SEGMENT GLANDS

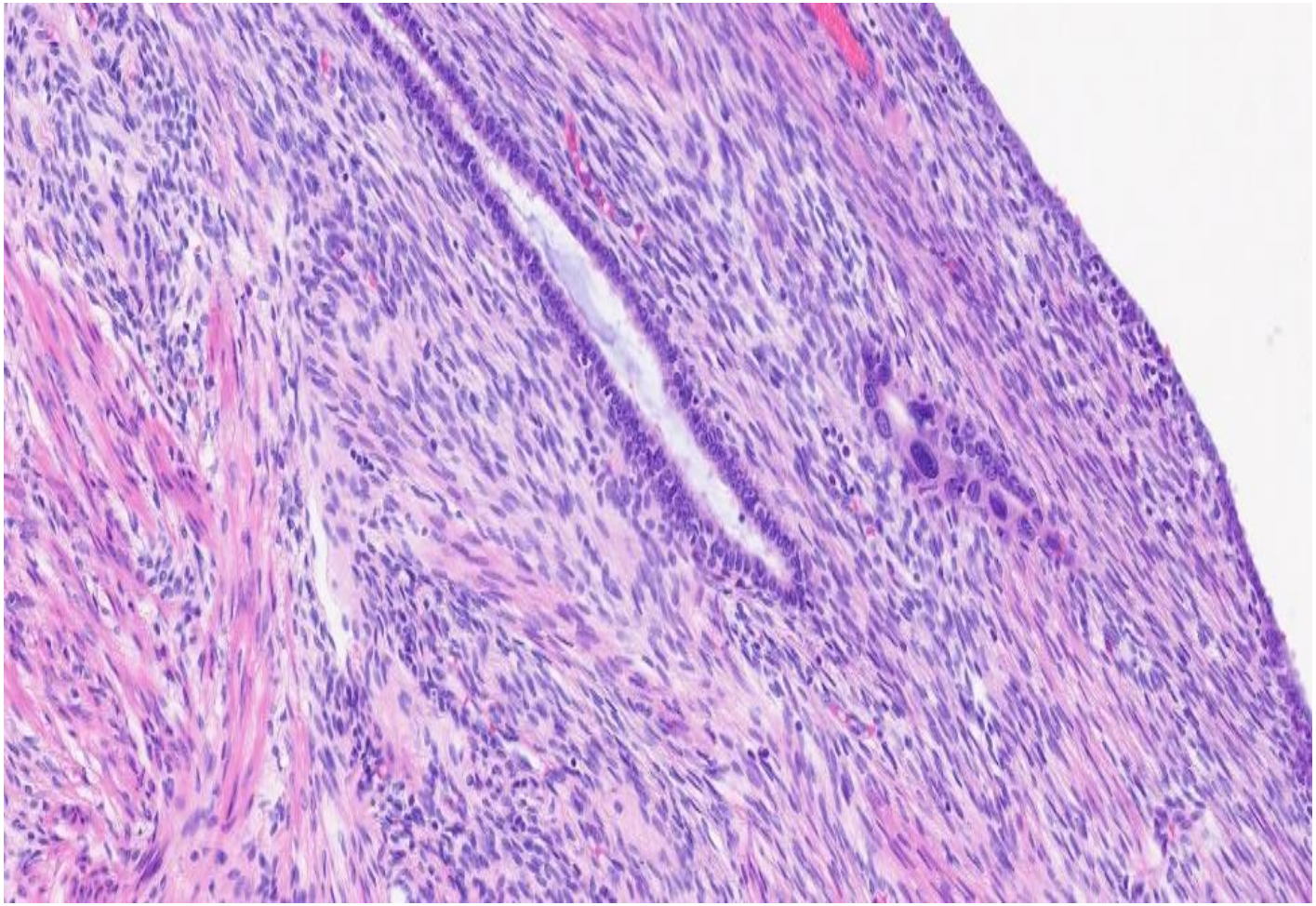

ATYPICAL LOWER UTERINE SEGMENT GLANDS

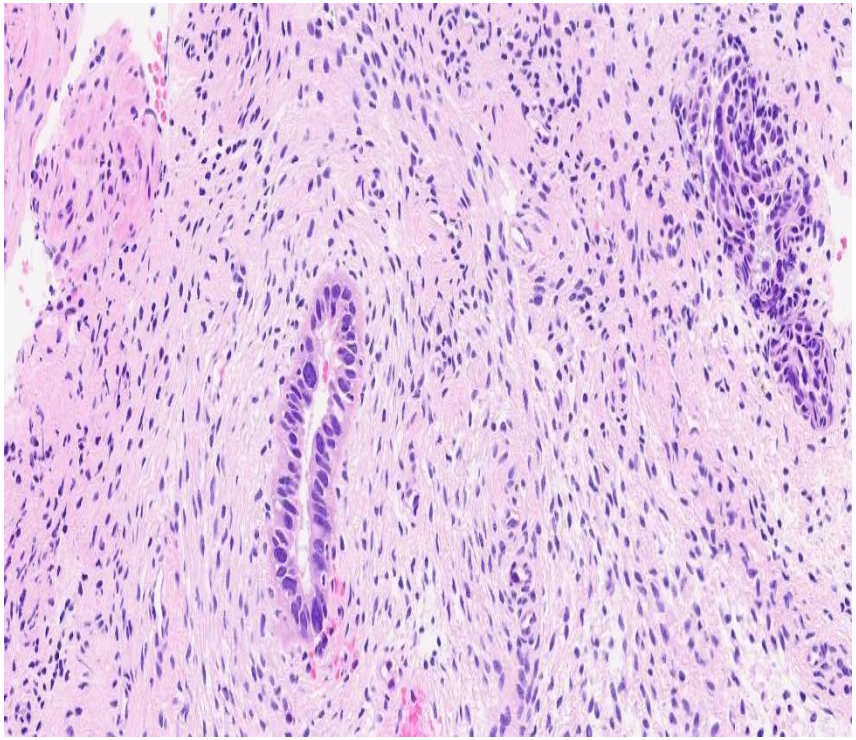

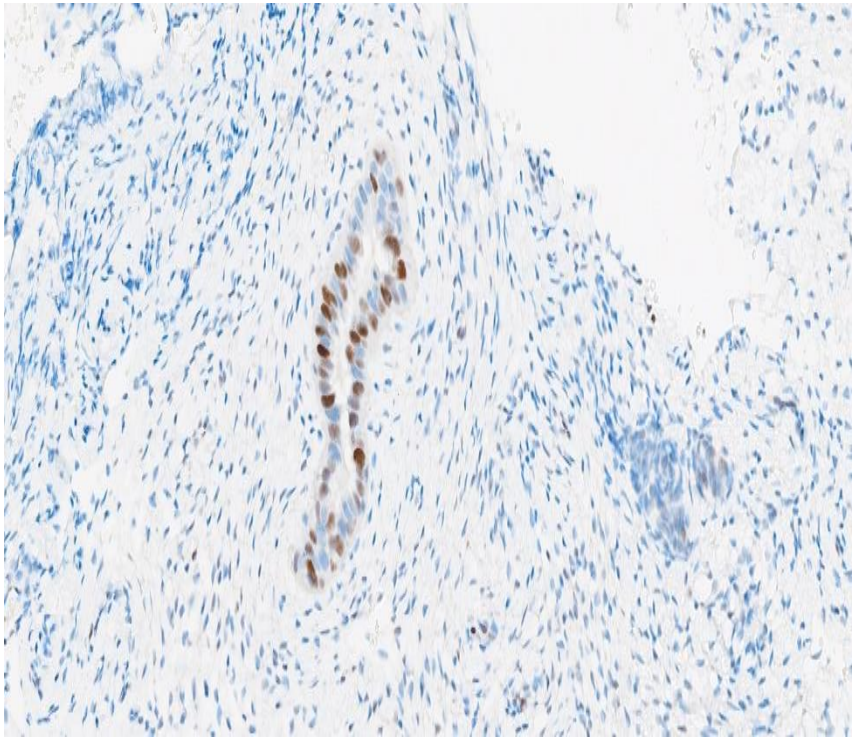

p53

ACTINOMYCES AND PSEUDOACTINOMYCES (J Clin Pathol 2009;62;1123-1126- PMID 19946099)

- both often associated with IUD
- both typically associated with endometritis
- both may be seen in tubo-ovarian abscesses
- important distinction because of antibiotic treatment and risk of ascending infection with actinomyces
- may coexist
- actinomyces (gram and silver positive); PAMRAGs (gram and silver negative)

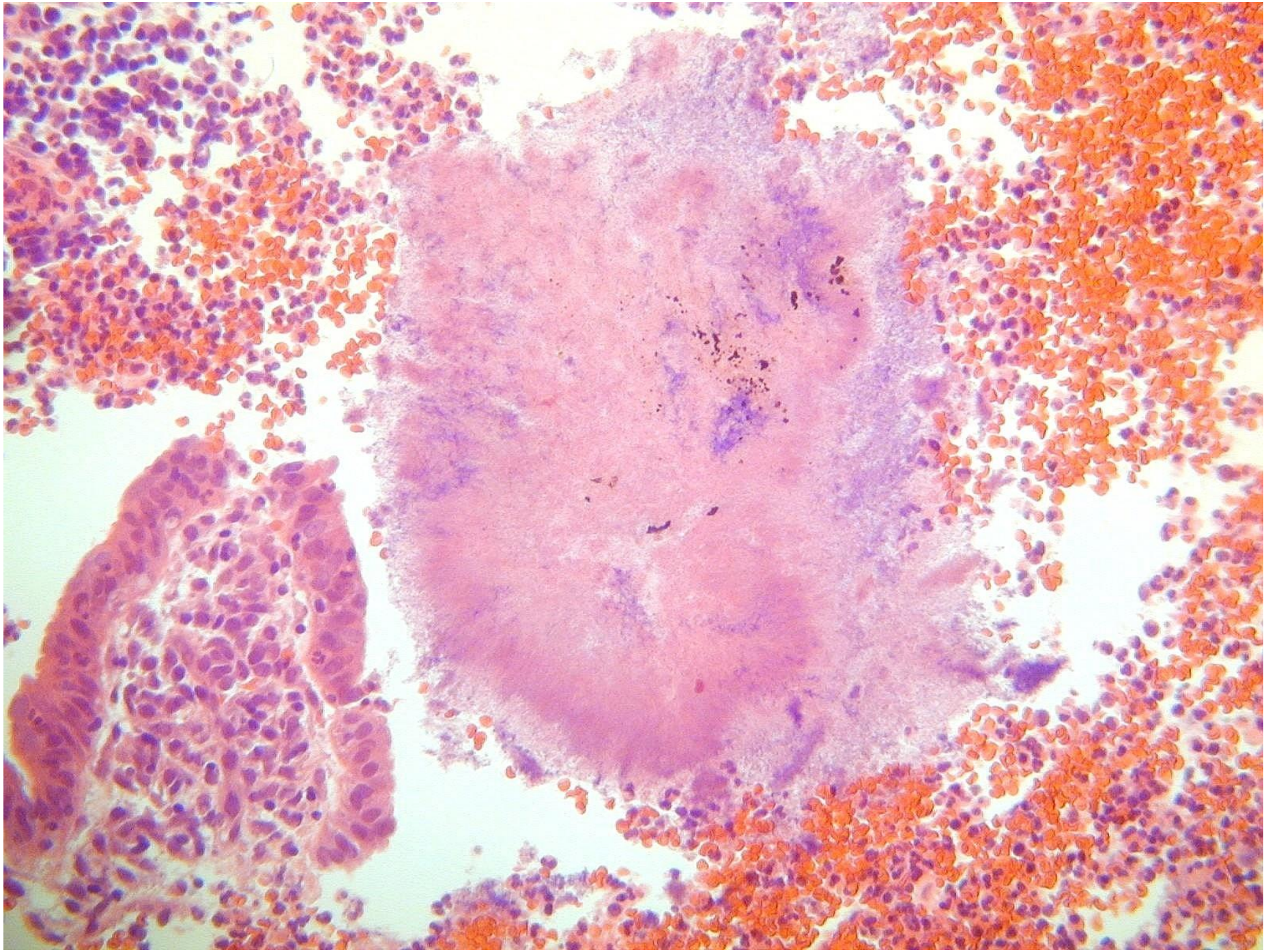

HISTOCHEMISTRY

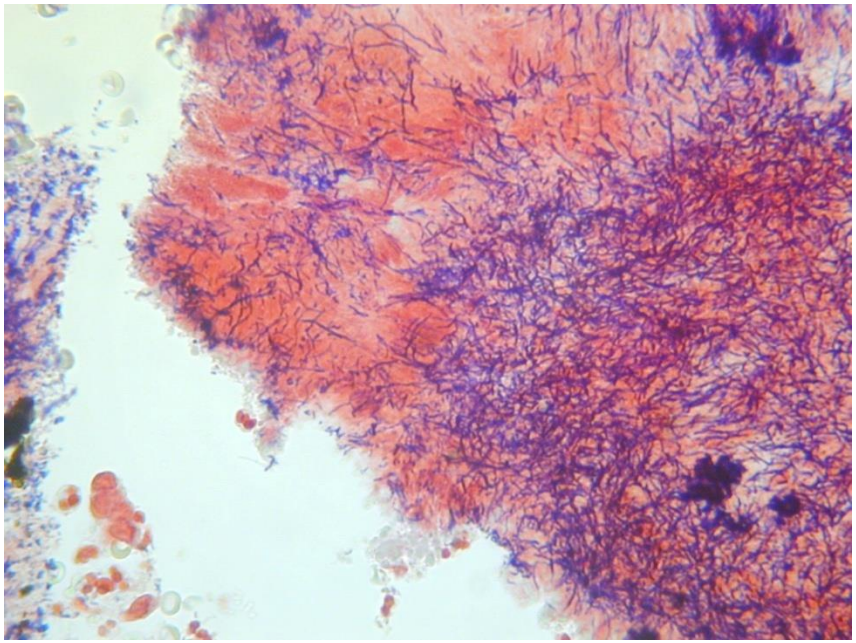

gram

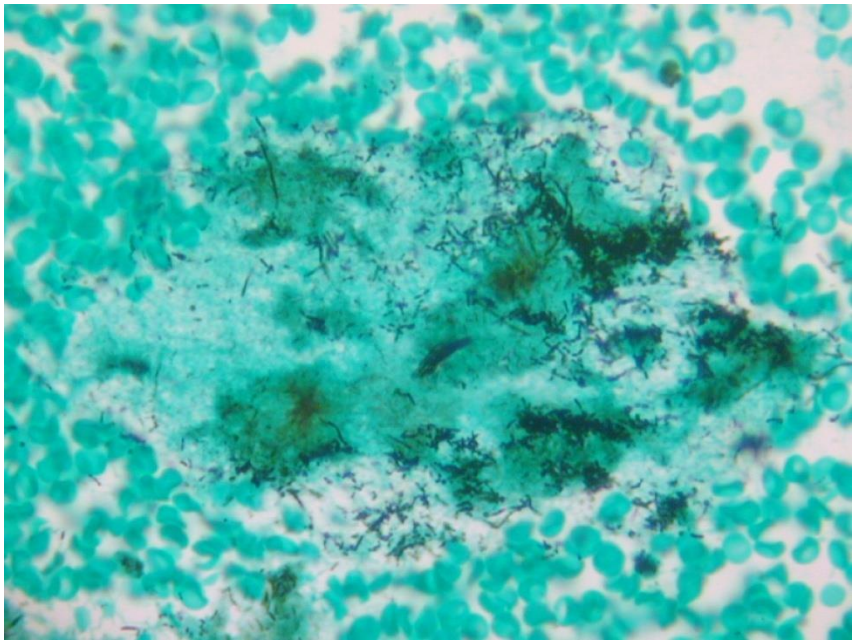

silver

PSEUDOACTINOMYCOTIC RADIATE GRANULES (PAMRAGs)

- more common than actinomyces
- non-infectious
- associated with IUDs and endometritis
- thick club-like projections
- gram and silver stains negative
- may see in dilated endocervical crypts and in abscesses; secondary to inspissated material
- also get combined granules (ALO and PAMRAGs)

PAMRAGs

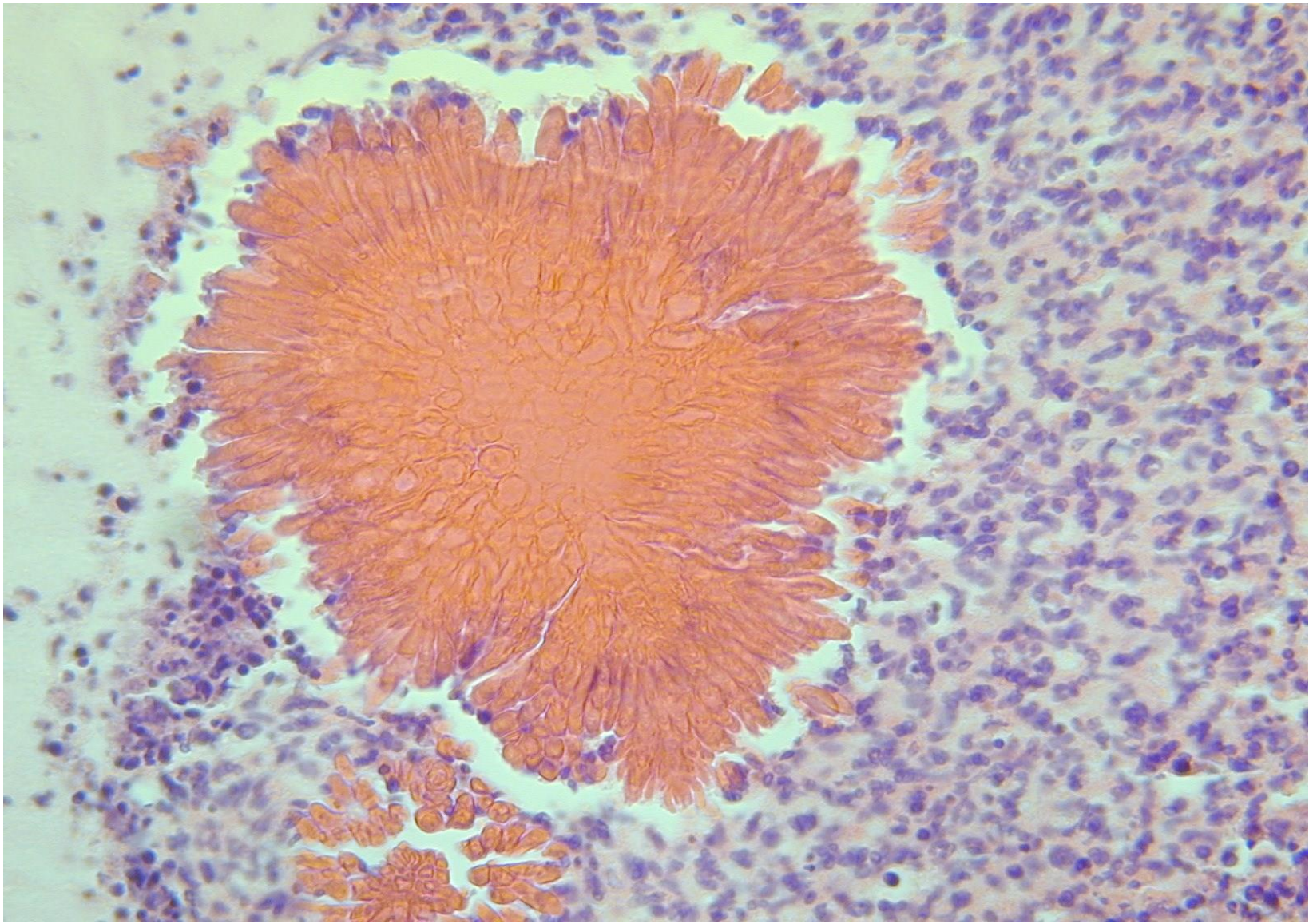

PAMRAGs

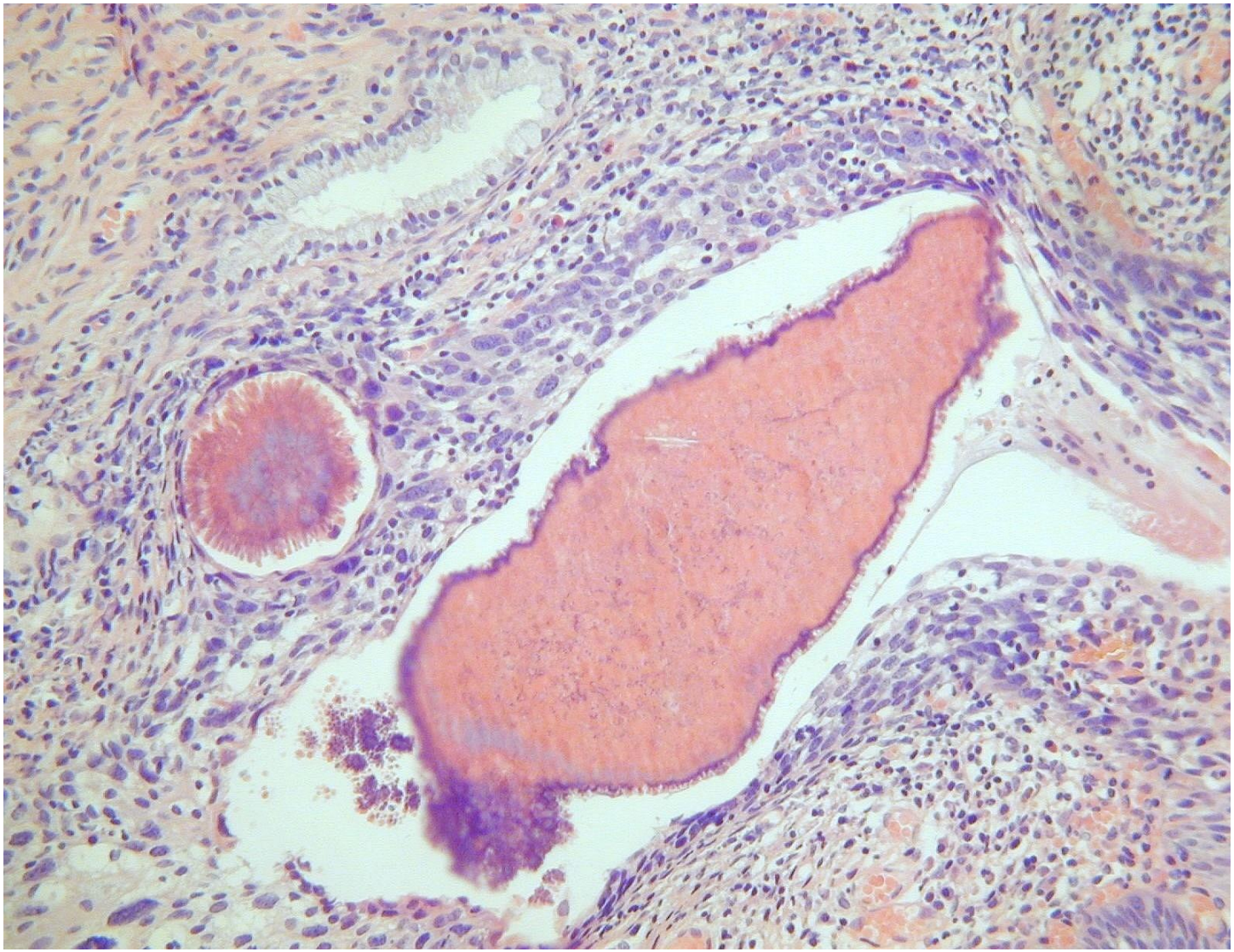

COMBINED GRANULES (ACTINOMYCES AND PAMRAGs)

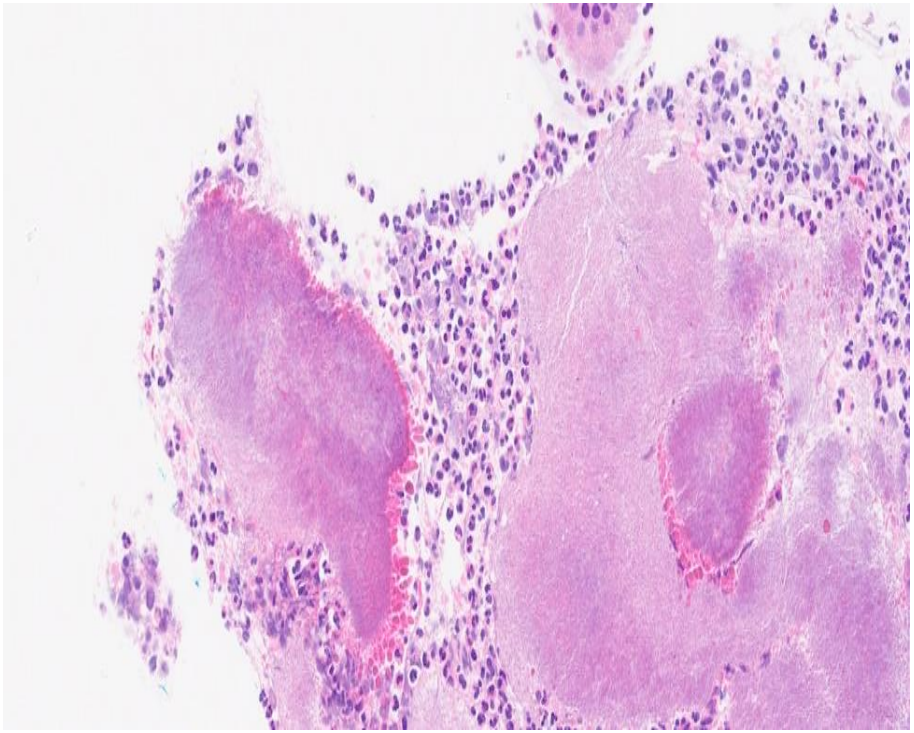

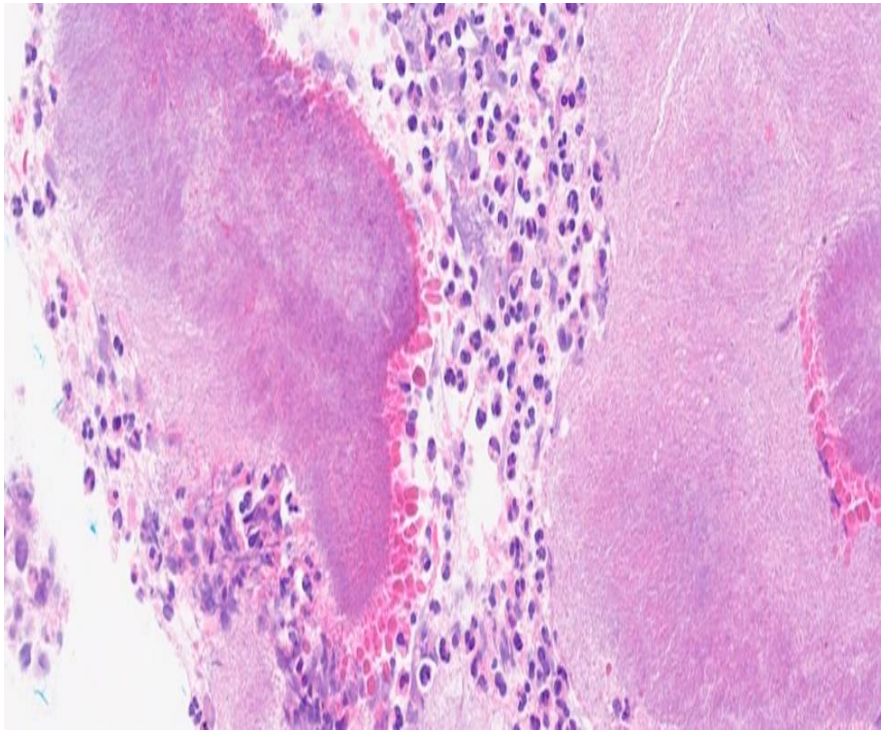

COMBINED GRANULES (ACTINOMYCES AND PAMRAGs)

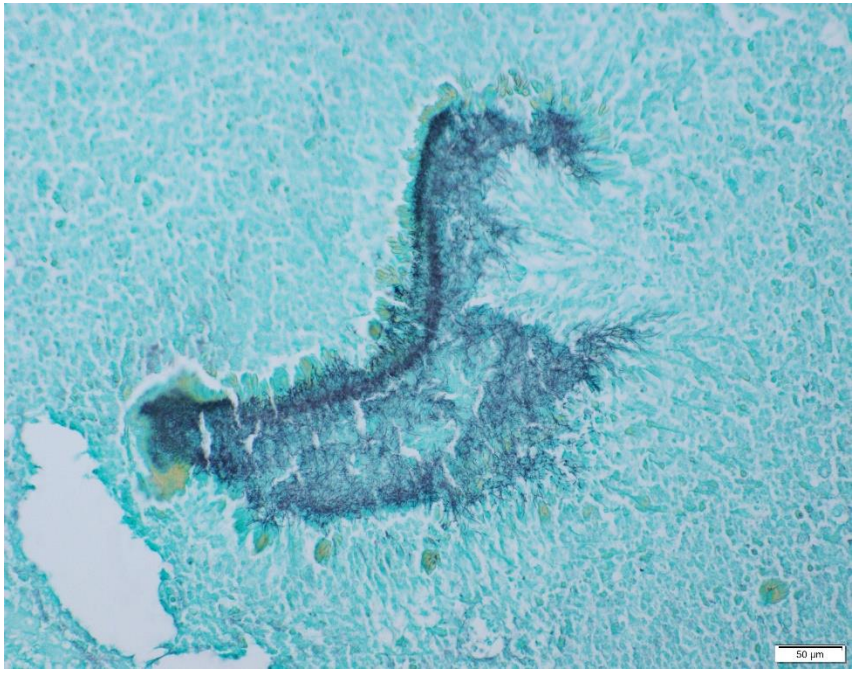

Silver stain

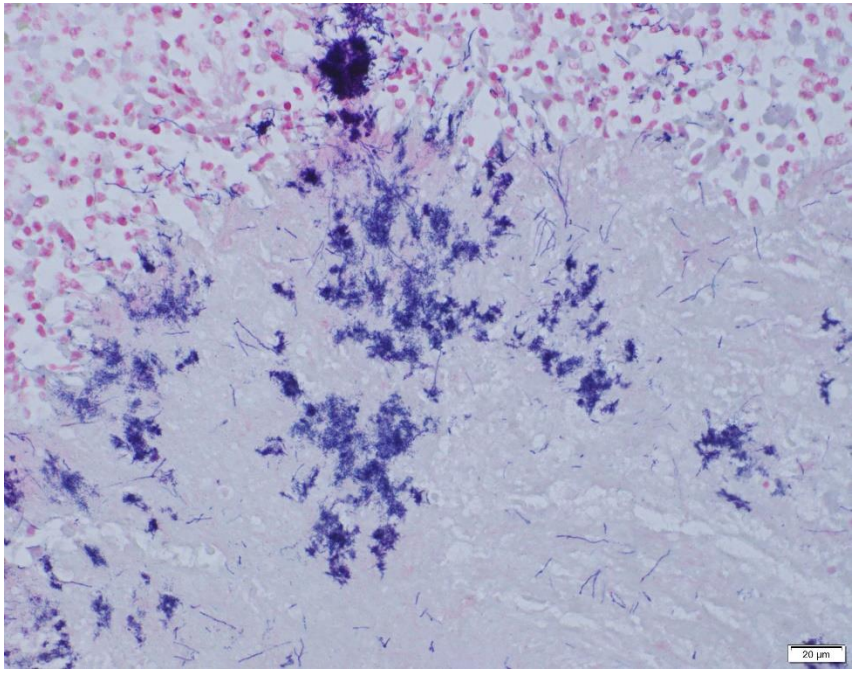

Gram stain

EPITHELIAL METAPLASIAS

- also known as epithelial cytoplasmic change
- common
- various types may coexist
- association with hormones, especially oestrogens
- common in polyps
- association with IUD, endometritis, pyometra
- common in endometrial hyperplasias and endometrioid carcinomas

DISTINCTION OF METAPLASIA FROM HYERPLASIA

- metaplasia often associated with hyperplasia
- try to “ignore” metaplasia when assessing whether hyperplasia present and look for architectural and nuclear changes
- cytology is invariably different to background with metaplasias (cytological demarcation)
- when get a metaplasia with glandular crowding, the cytological demarcation raises the possibility of atypical hyperplasia; new WHO 2020 gets around this (“nuclear appearance is always distinct from the background from which the lesion has emerged”)

TYPES

- ciliated/tubal
- eosinophilic
- **mucinous**
- **squamous (morular or non-morular/ typical)**
- hobnail change
- clear cell
- Arias-Stella effect

MUCINOUS METAPLASIA

- Commonly seen as focal lesion in endometrial polyp with preservation of normal glandular architecture
- Beware rare morphologically complex mucinous proliferations; may be adenocarcinoma even if cytologically bland; WHO 2014- “atypical mucinous glandular proliferation”
- If microglandular architecture beware surface changes in endometrioid carcinoma
- Unusual for hyperplasias to have extensive mucinous differentiation- tend not to use hyperplasia terminology for architecturally complex mucinous lesions
- May need descriptive report
- Both endometrioid carcinomas with mucinous differentiation and gastric-type mucinous carcinomas may be cytologically bland

MUCINOUS PROLIFERATIONS IN ENDOMETRIUM

- PMID: 35499137 (O Fadare)- Advances in Anatomic Pathology
- Mucinous metaplasia
- Atypical mucinous glandular proliferations
- Adenocarcinomas (endometrioid or gastric-type)
- Papillary proliferation of endometrium
- Uterine teratomas, metastases, involvement by LAMN

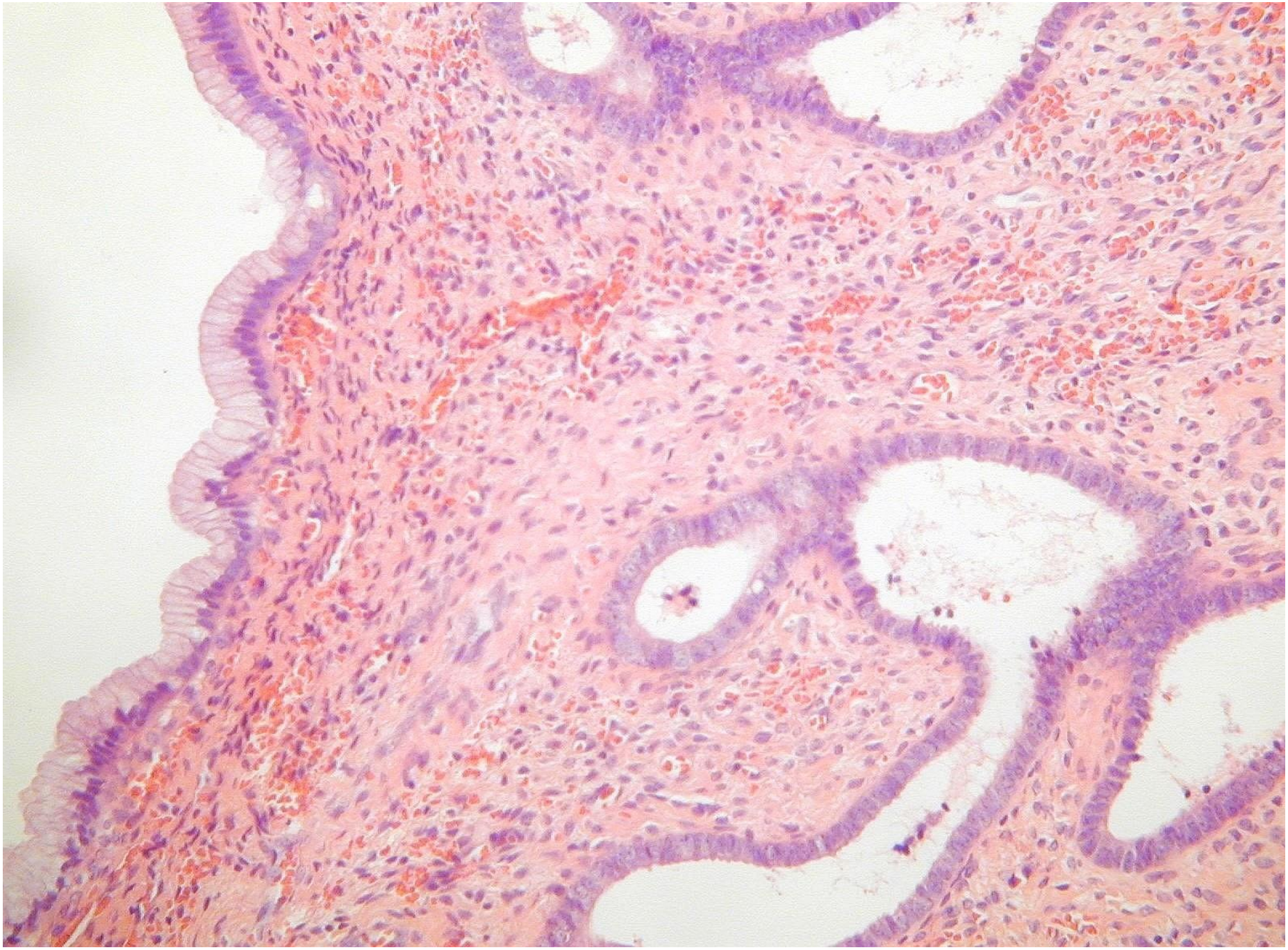

ATYPICAL MUCINOUS GLANDULAR PROLIFERATION

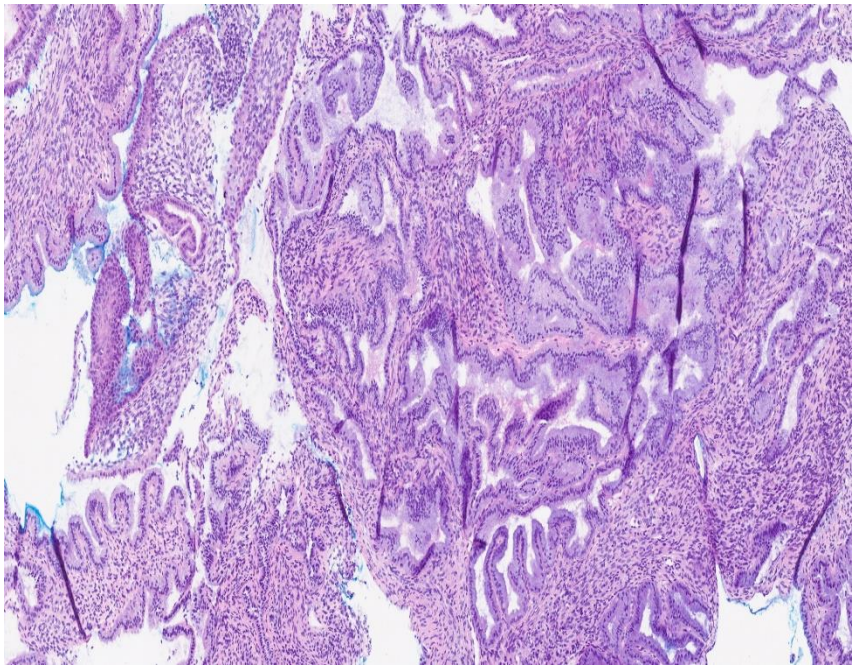

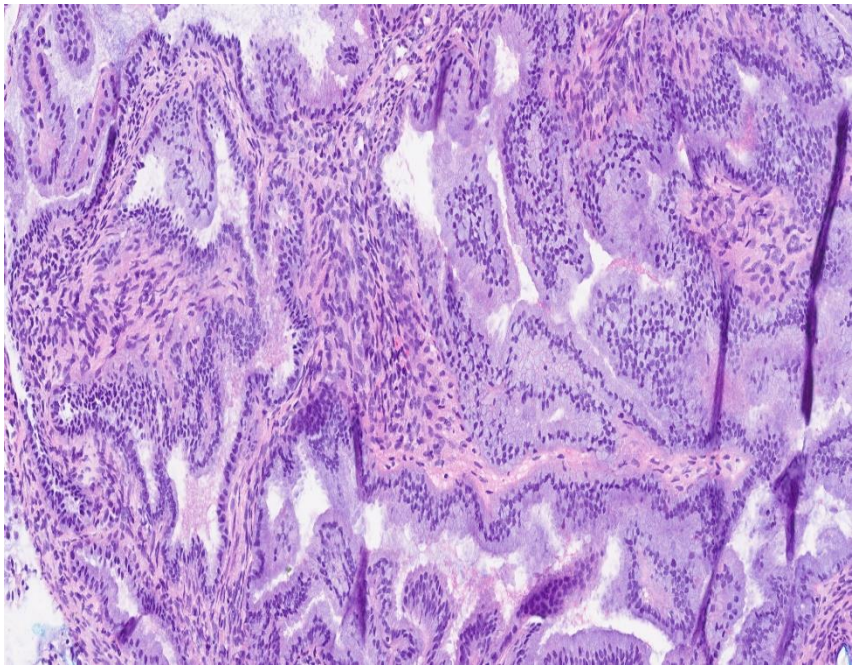

MICROGLANDULAR VARIANT OF ENDOMETRIOID CARCINOMA OF ENDOMETRIUM MIMICKING CERVICAL MGH

- usually on surface of endometrioid carcinoma (sometimes with mucinous features) but may be more widespread
- especially likely to be sampled on biopsy
- microglandular architecture
- may closely mimic cervical microglandular hyperplasia
- **IMMUNOHISTOCHEMISTRY OF LIMITED VALUE- MANY STUDIES WHICH SHOW TOO MUCH OVERLAP (in my opinion, most useful marker is p16)**
- **Recent study (PMID 35347751)- p63 may also be of value (many more p63 positive cells in MGH- subcolumnar reserve cells)**

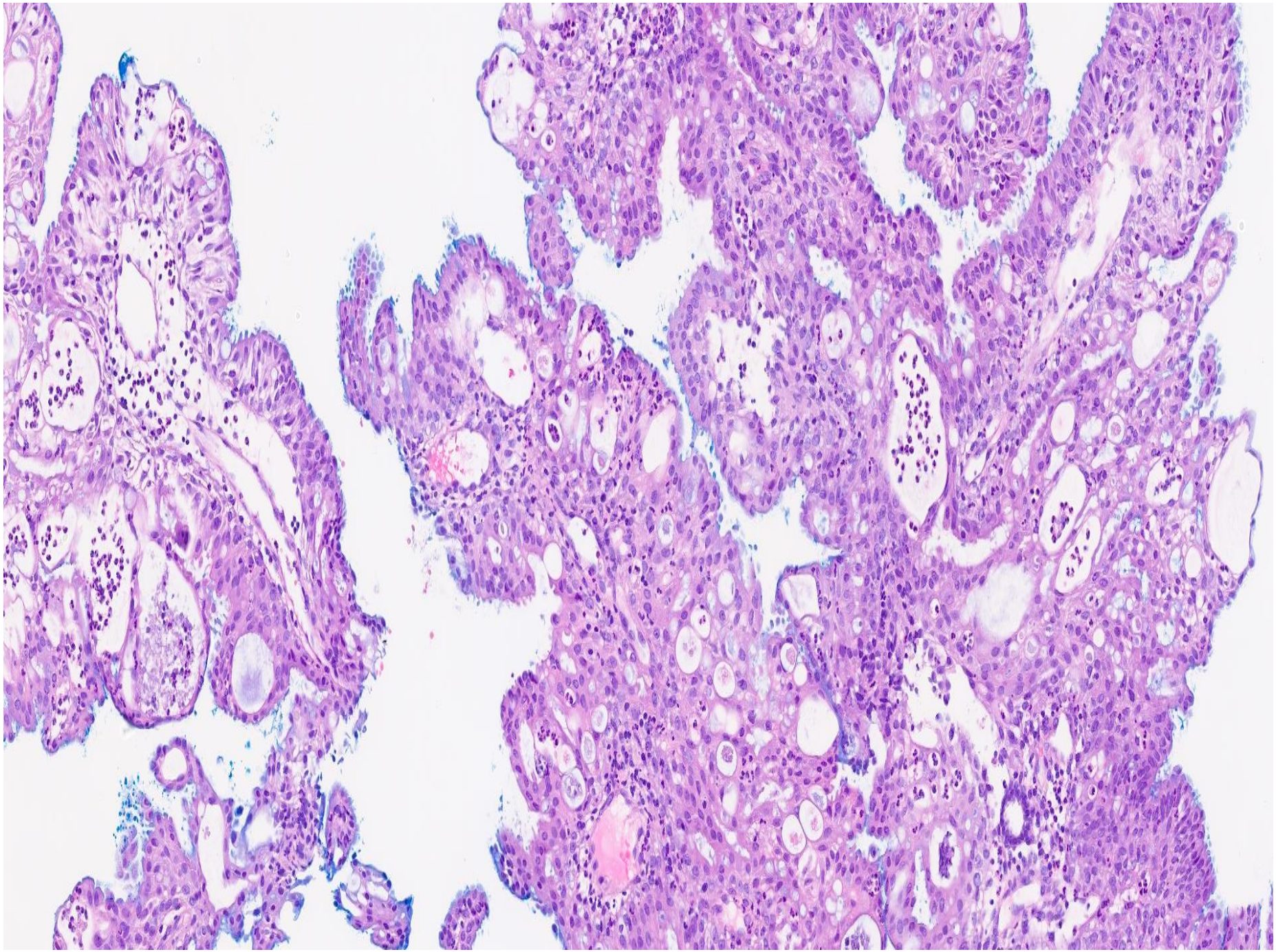

p16 IN 2 CASES OF MICROGLANDULAR FOCI ON SURFACE OF ENDOMETRIOID CARCINOMA

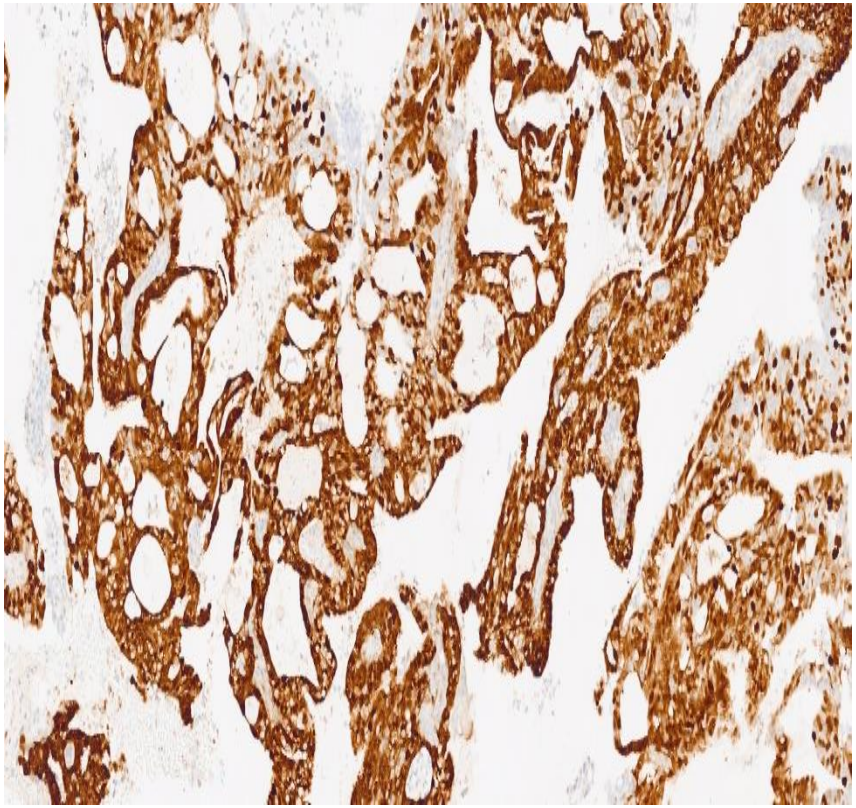

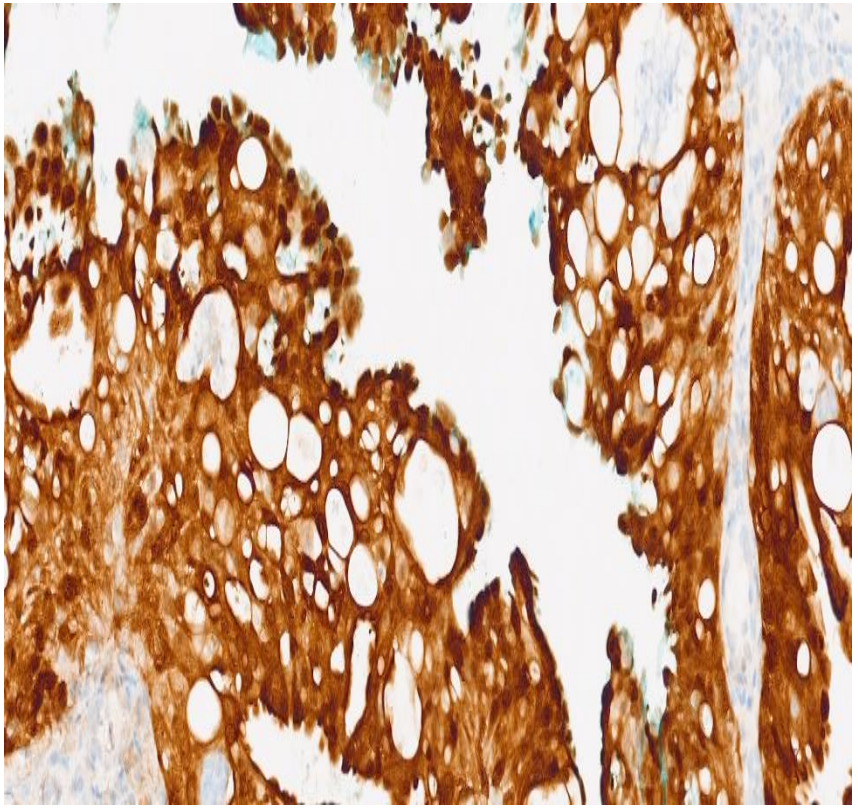

PMP WITH ENDOMETRIAL INVOLVEMENT- PMID 25760906

- Cases of PMP associated with low grade appendiceal mucinous neoplasms (LAMN)
- Presented with mucoid vaginal discharge
- Colonisation of endometrium (and cervix in one case)
- Initially misdiagnosed on endometrial biopsy as mucinous metaplasia

PMP WITH ENDOMETRIAL INVOLVEMENT- PMID 25760906

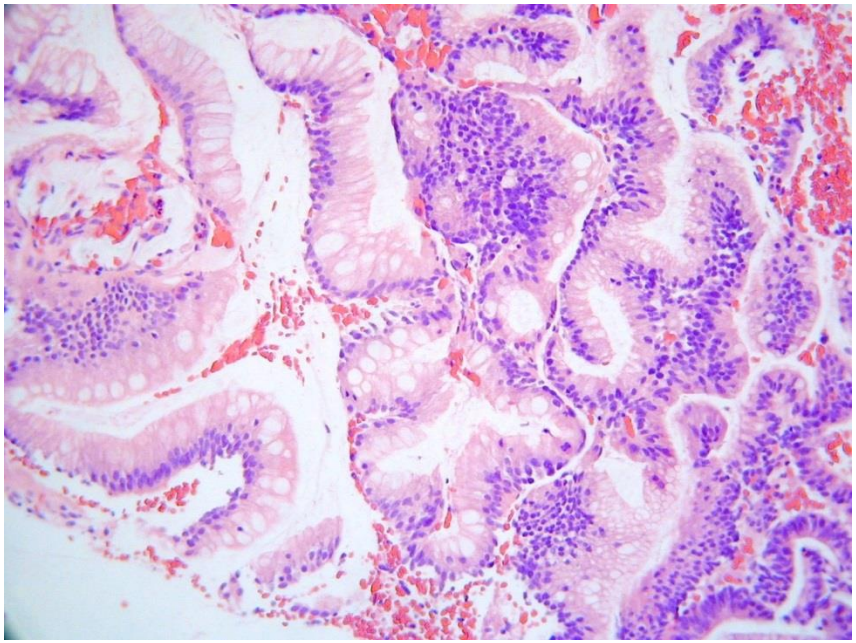

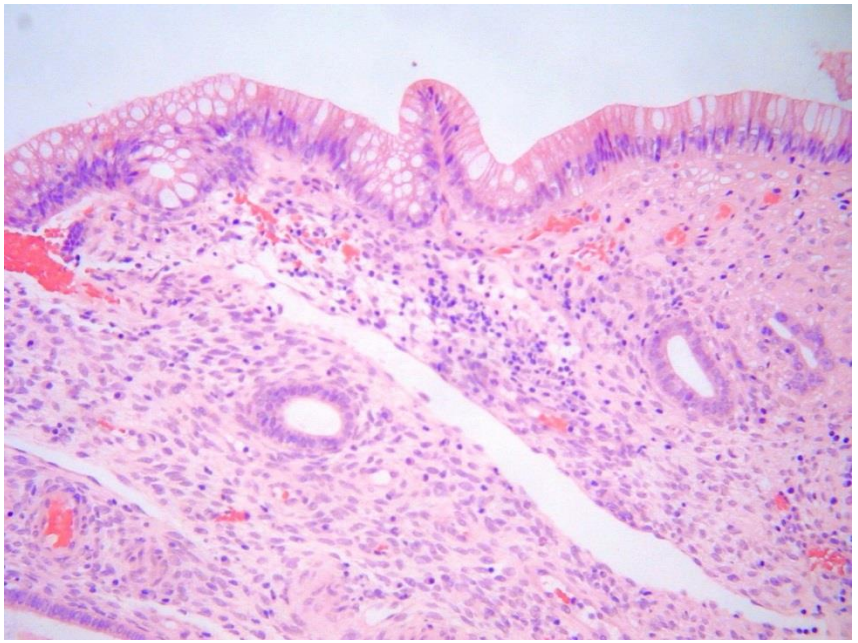

PMP WITH ENDOMETRIAL INVOLVEMENT- PMID 25760906

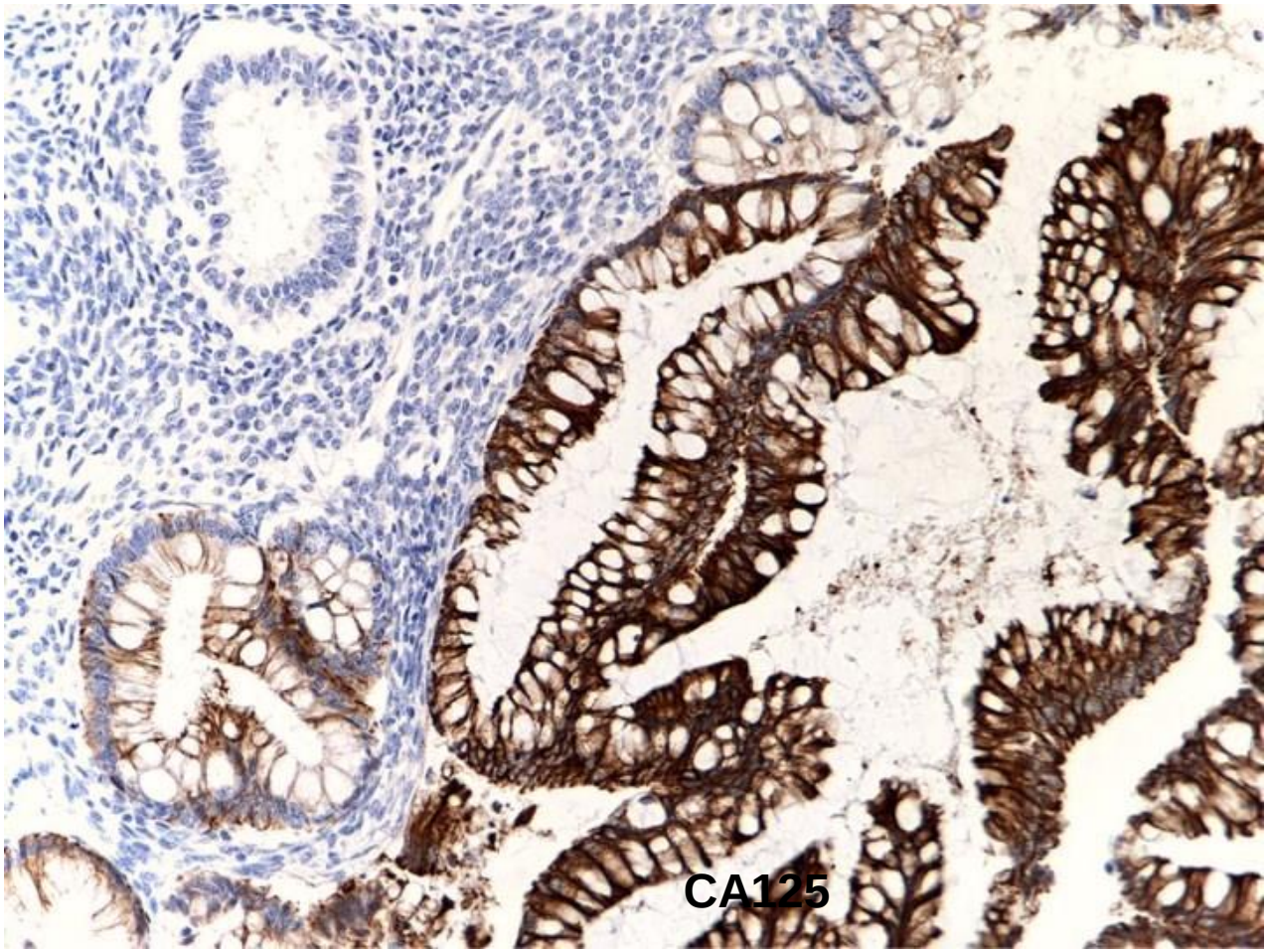

SQUAMOUS METAPLASIA

- 2 types- “typical/ non-morular” and “morular”
- Uncommonly coexist but usually do not
- Different lesions
- Both often associated with endometrioid proliferative lesions (typical also associated with endometritis/ pyometra)

ENDOMETRIOID CARCINOMA WITH SQUAMOUS DIFFERENTIATION

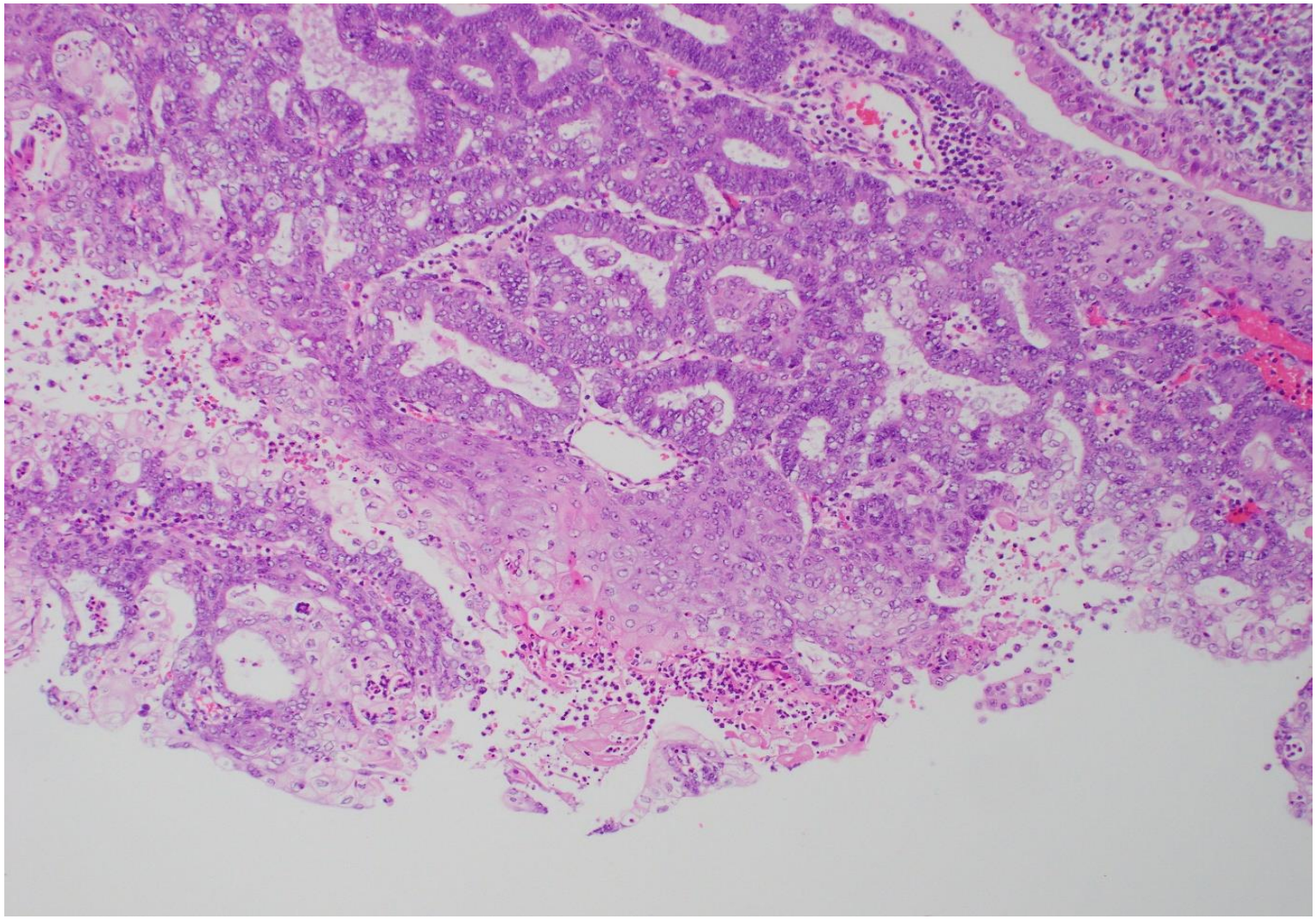

ENDOMETRIOID PROLIFERATIVE LESION WITH MORULES

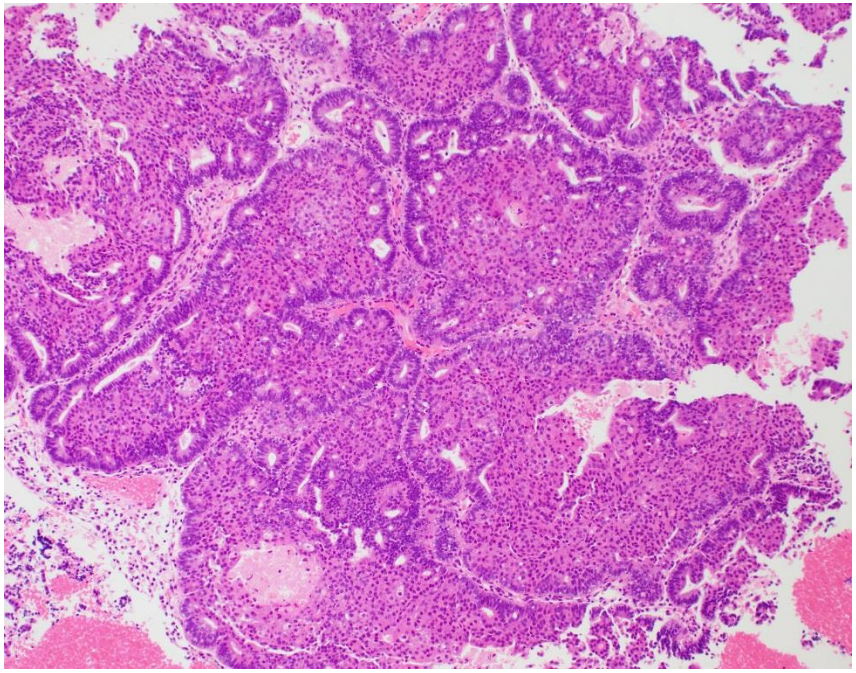

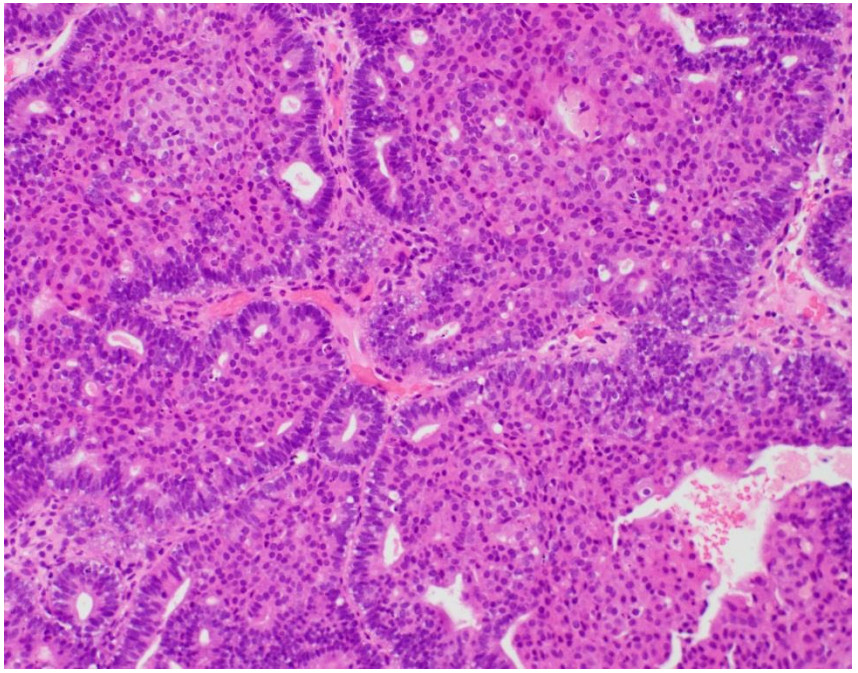

MORULES- OPTICALLY CLEAR NUCLEI

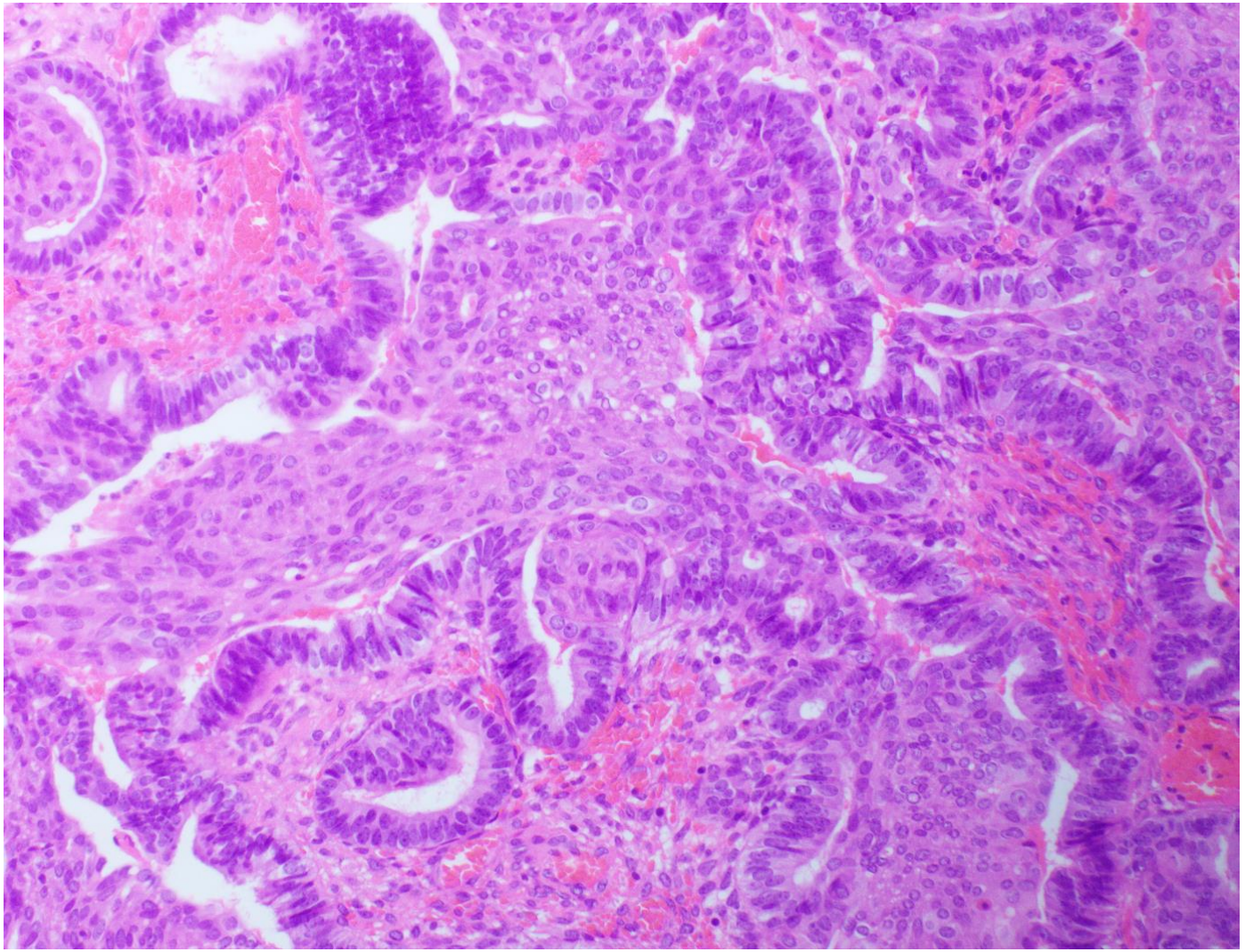

TYPICAL SQUAMOUS ELEMENTS AND MORULES

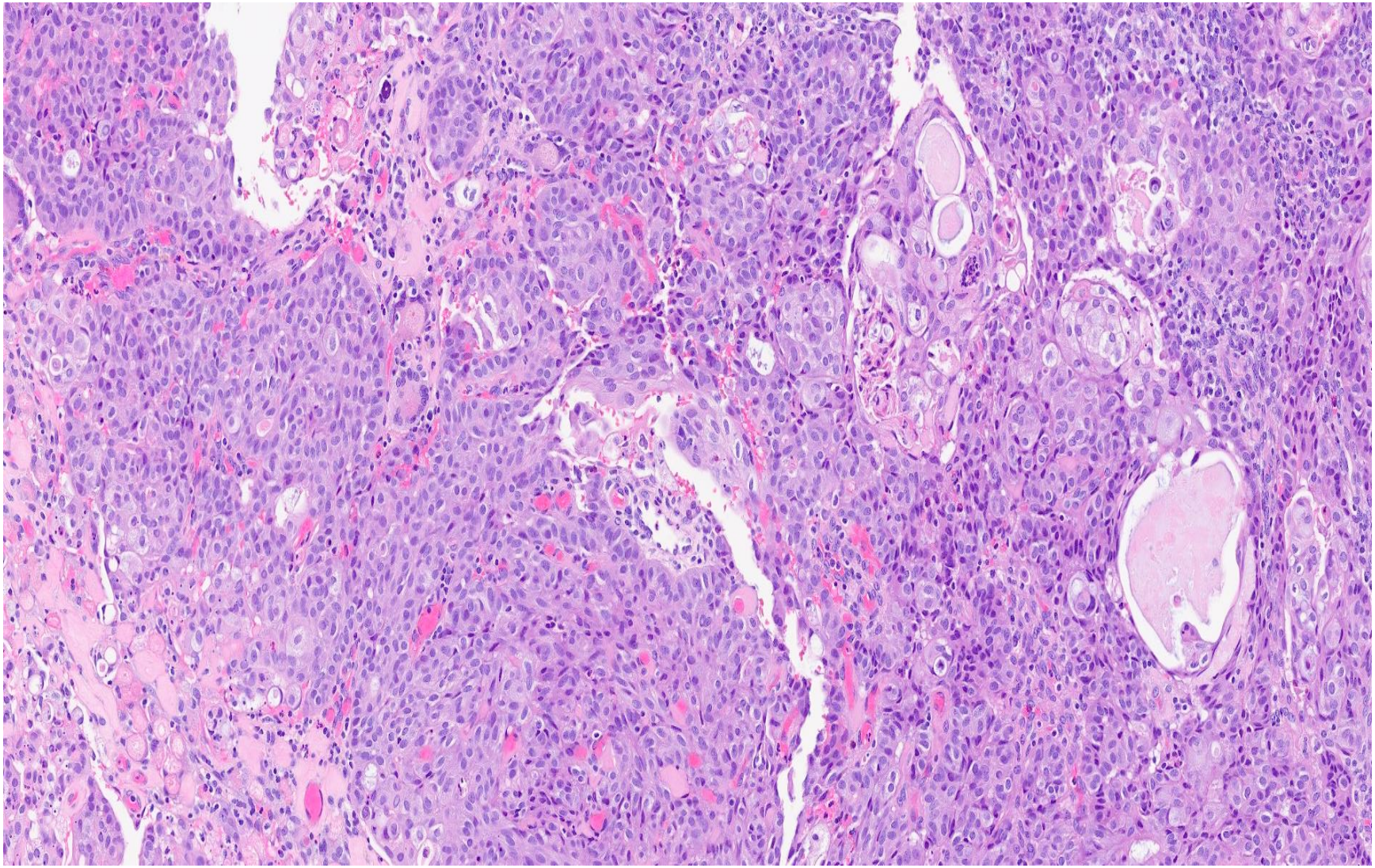

SQUAMOUS MORULES

- closely associated with endometrioid proliferative lesions
- may make assessment of underlying architecture difficult when confluent
- can have spindle cell appearance
- unusual immunophenotype
- what to do if see free floating or in non-hyperplastic endometrium/ polyp (probably resample- could be undersampled hyperplasia or regressed hyperplasia) (not much evidence in literature)

MORULES

In stroma of polyp

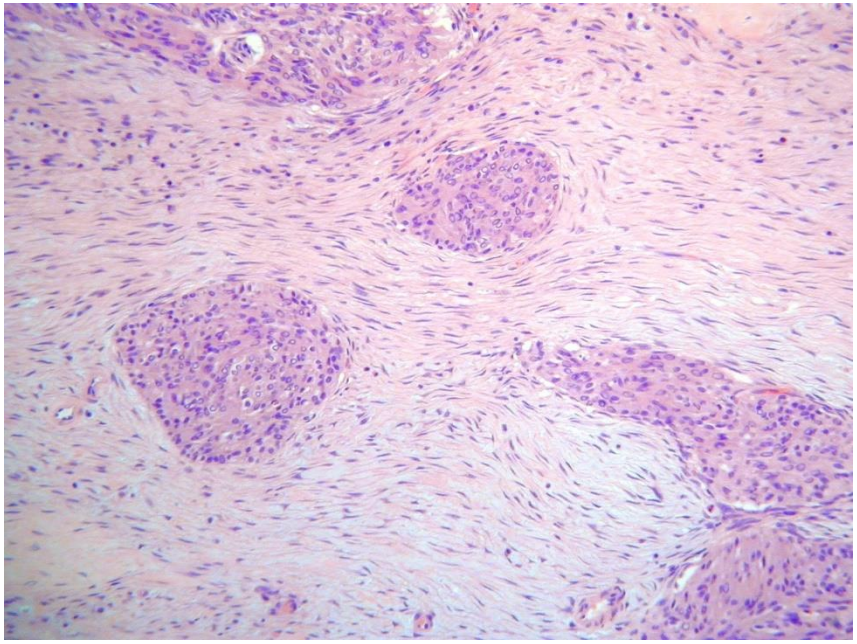

Free morules

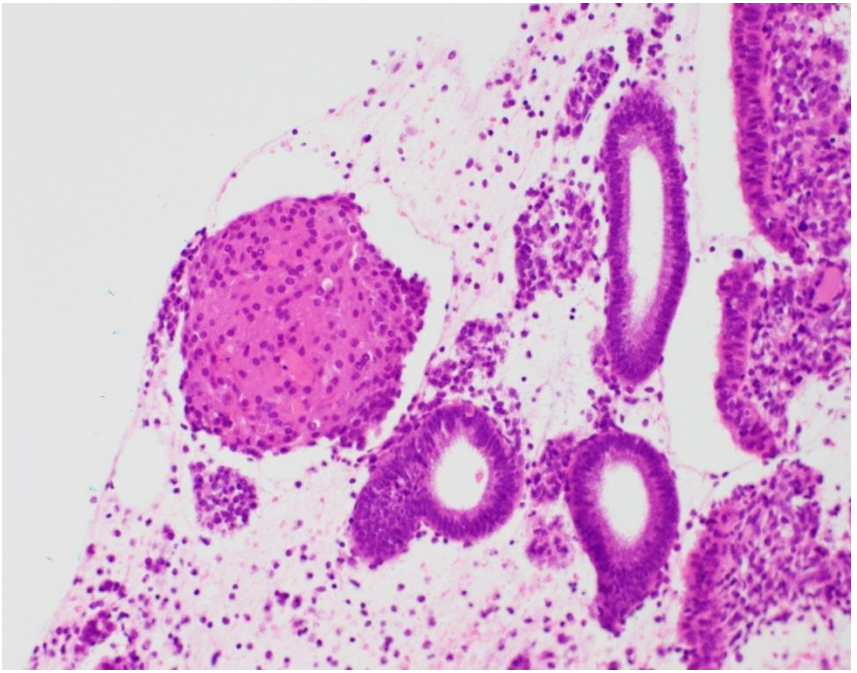

IMMUNOHISTOCHEMISTRY OF MORULES

- ER, PR negative
- CD10 positive
- p16 positive
- p63 negative
- β catenin nuclear and cytoplasmic immunoreactivity (association with β catenin mutation)
- CDX2 nuclear positivity
- SATB2 nuclear positivity (PMID 30085940)
- BEST TO REFER TO AS MORULAR METAPLASIA SINCE DON'T EXPRESS SQUAMOUS MARKERS
- MORULES HAVE A VERY UNUSUAL IMMUNOPHENOTYPE

MORULES- BETA CATENIN

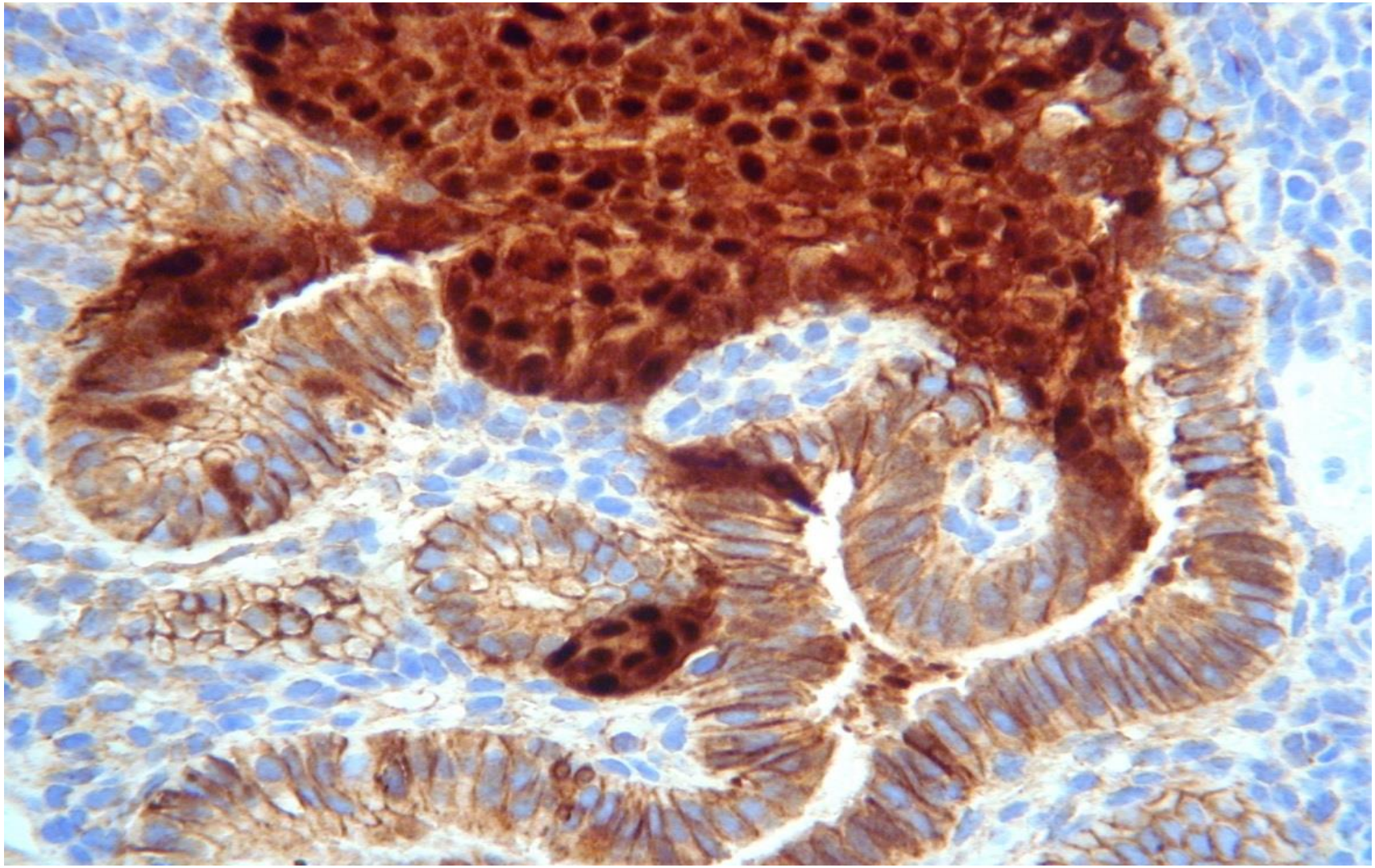

TYPICAL SQUAMOUS ELEMENTS AND MORULES- BETA-CATENIN

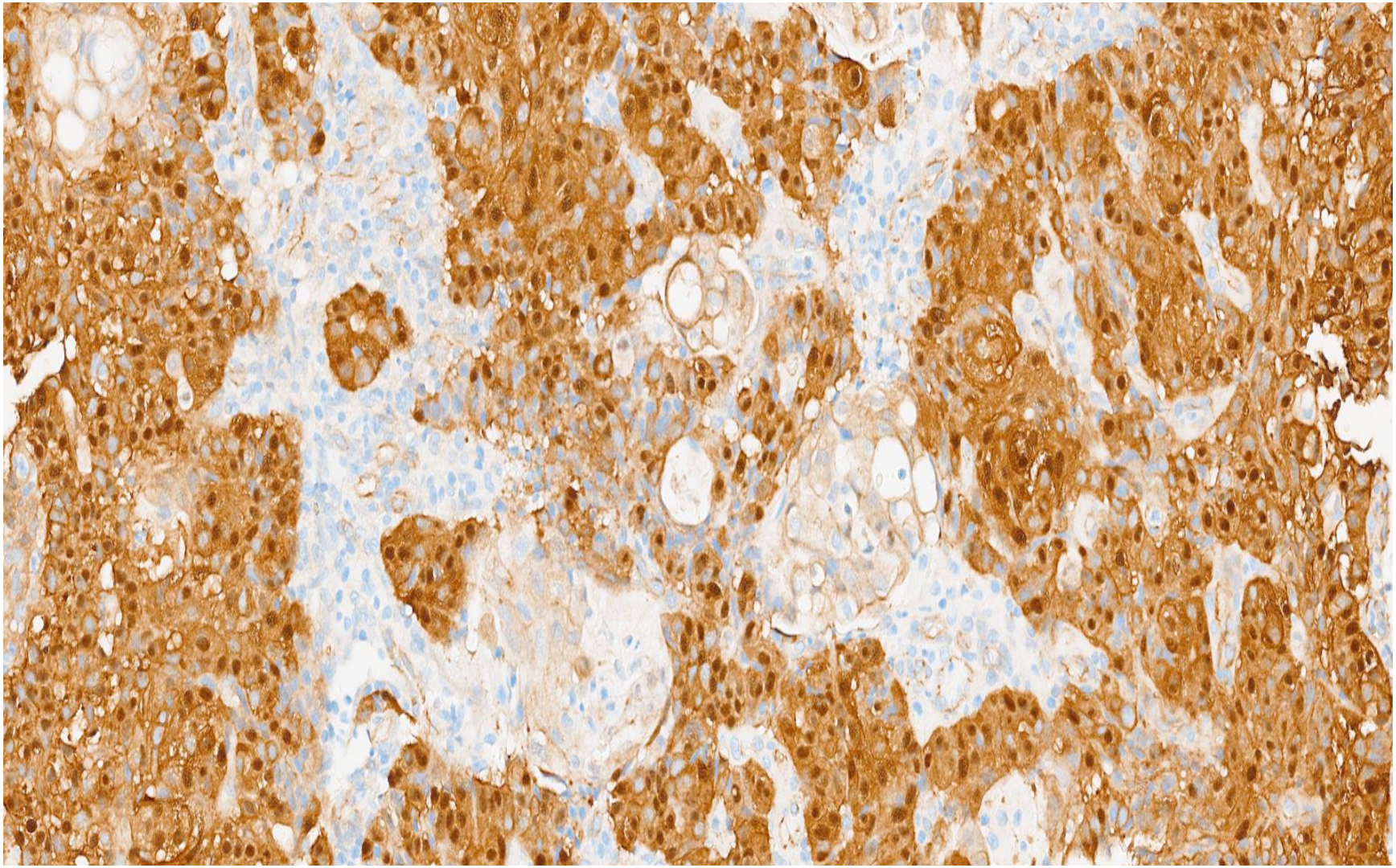

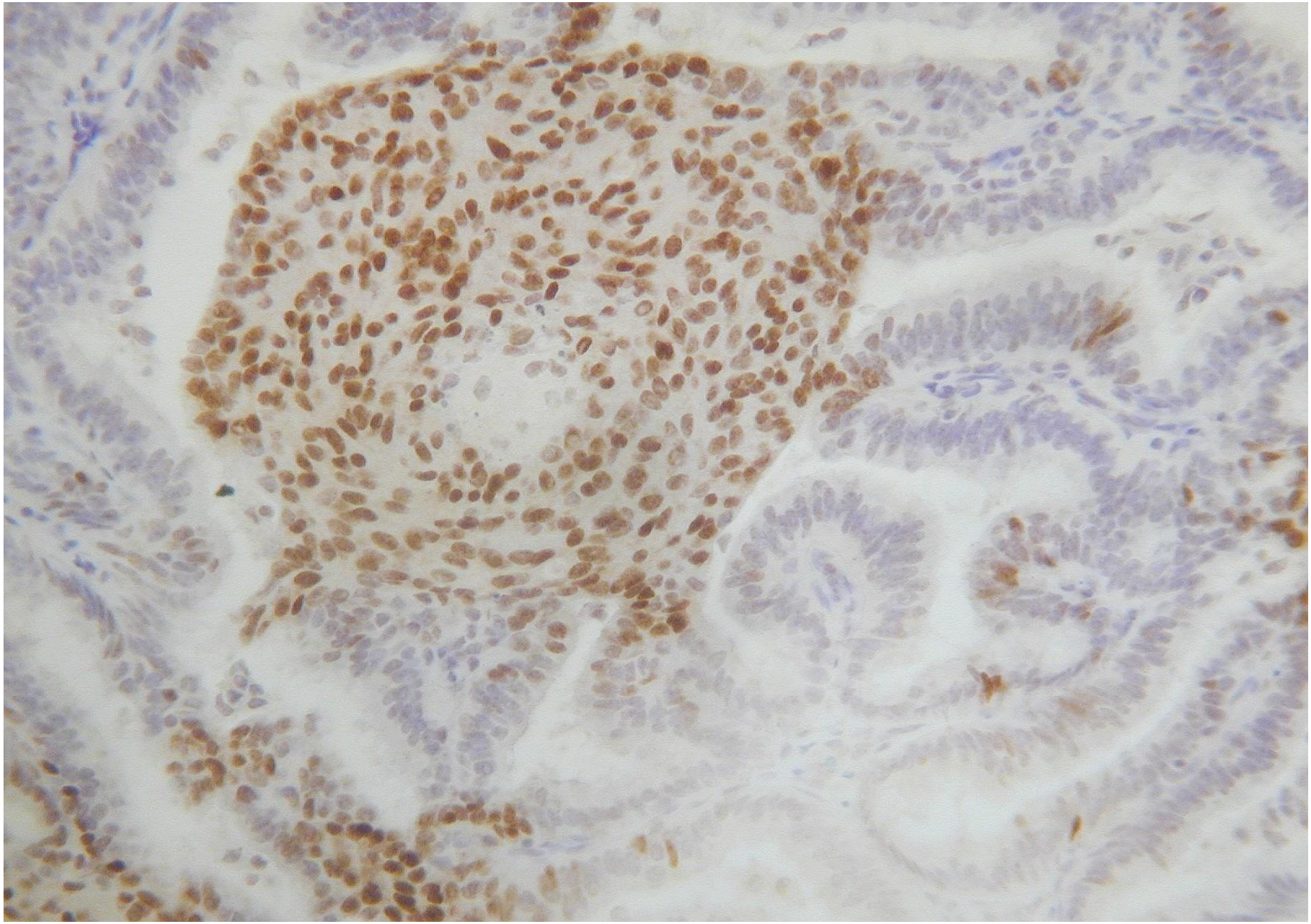

CDX2 in morules

IMMUNOHISTOCHEMISTRY

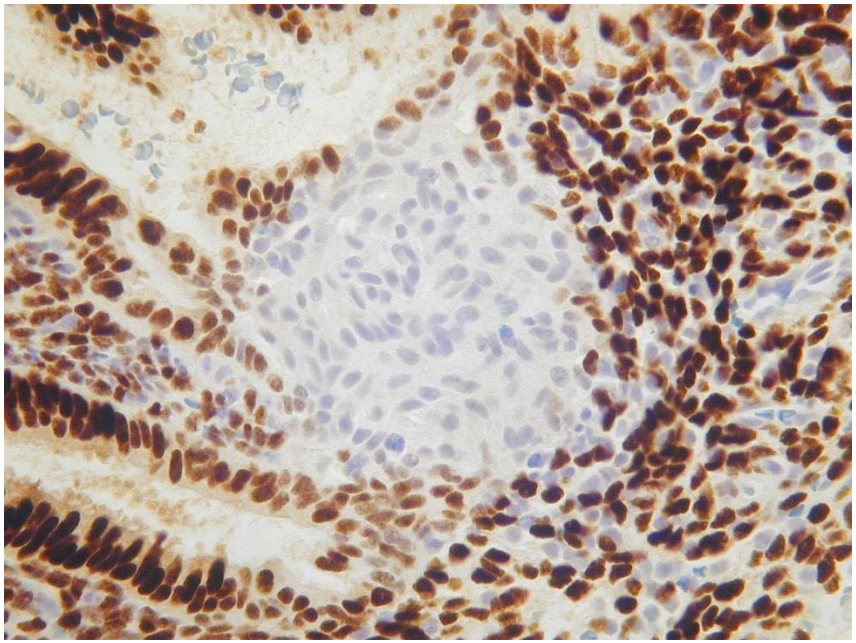

ER

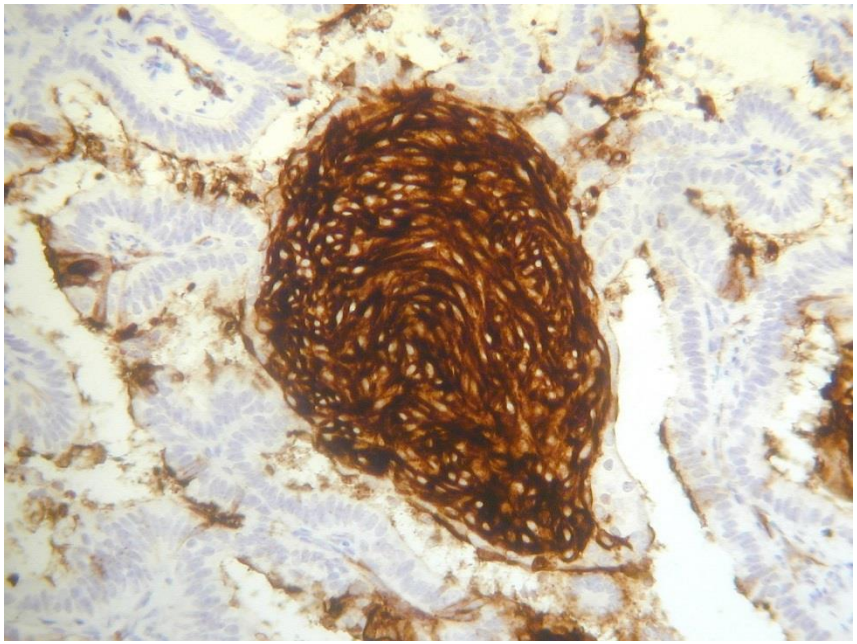

CD10

MORULES CAN HAVE A SPINDLE CELL APPEARANCE

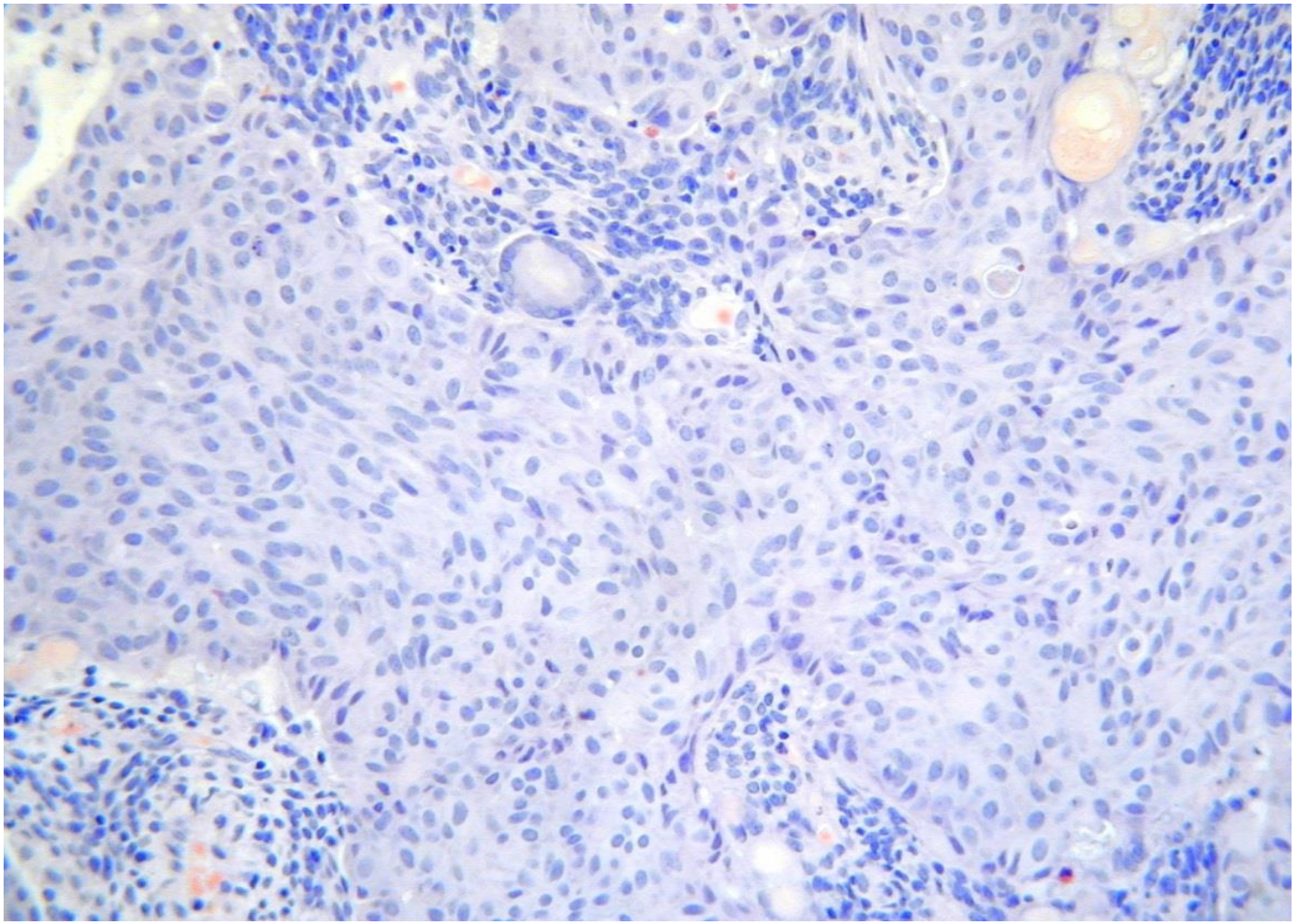

IMMUNOHISTOCHEMISTRY

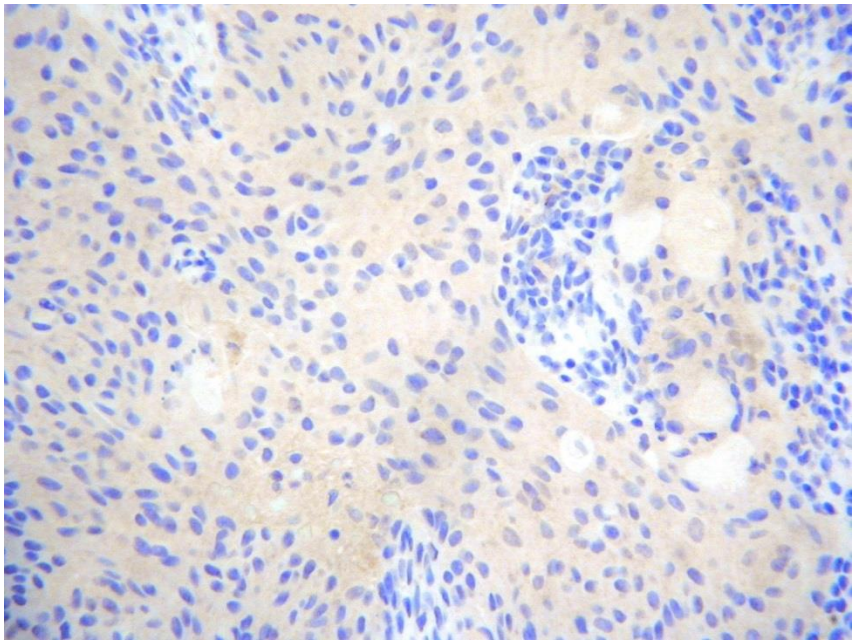

p63

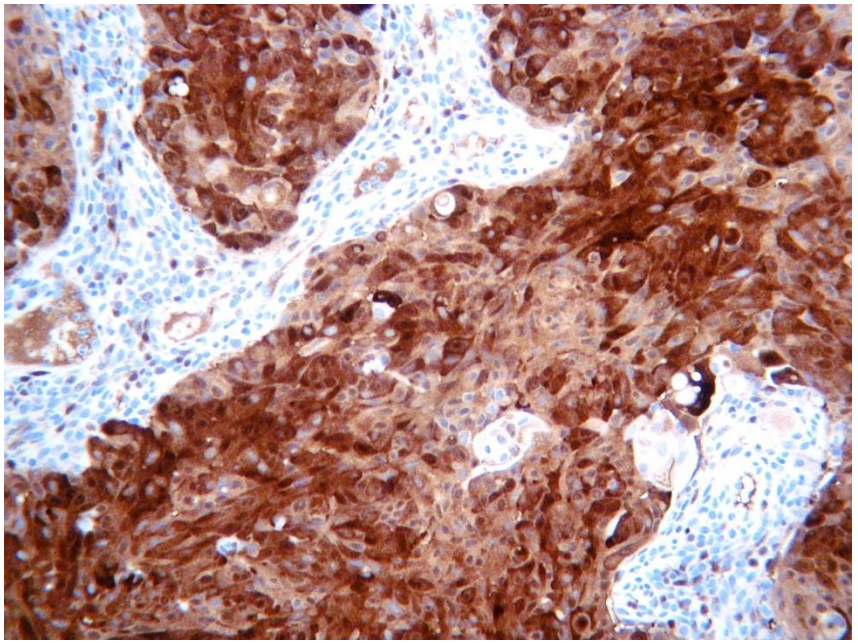

p16

SATB2 IN MORULES (PMID 30085940)

International Journal of Gynecological Pathology
38:397–403, Lippincott Williams & Wilkins, Baltimore
Copyright © 2018 by the International Society of Gynecological Pathologists

Original Article

SATB2 is Consistently Expressed in Squamous Morules Associated With Endometrioid Proliferative Lesions and in the Stroma of Atypical Polypoid Adenomyoma

W. Glenn McCluggage, F.R.C.Path and Koen Van de Vijver, Ph.D.

SATB2 IS POSITIVE IN MORULES

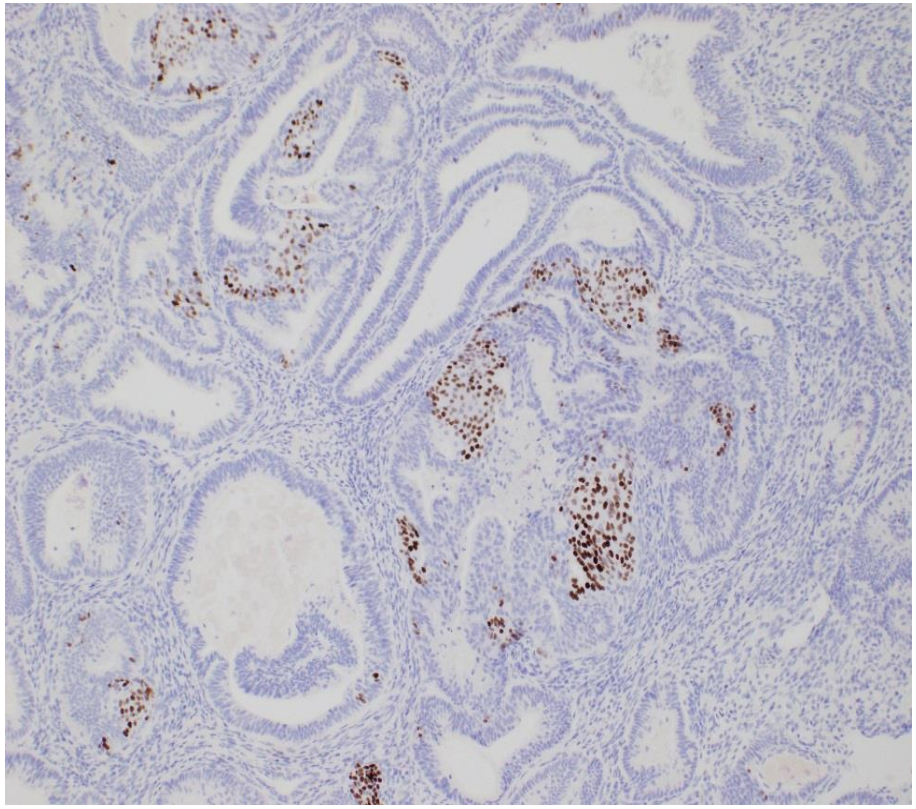

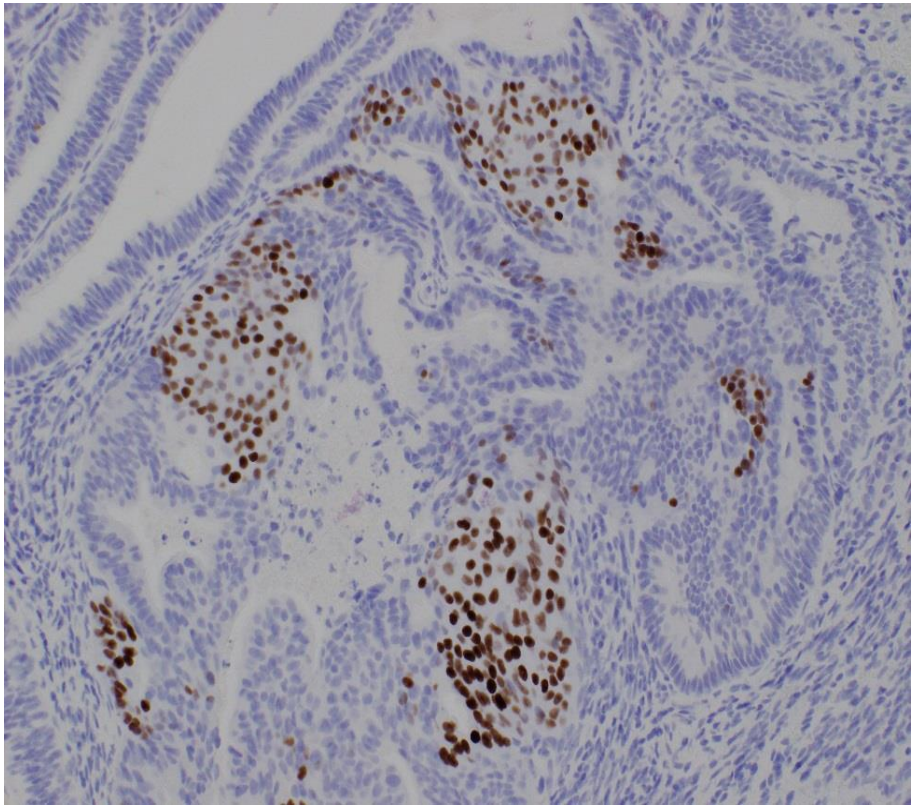

PROBLEMS IN ENDOMETRIAL POLYPS

- proliferative activity may occur in postmenopausal women (I don't mention on report)
- inflammatory cells, including plasma cells, may occur- not endometritis
- epithelial metaplasias common
- rarely stromal metaplasias
- necrosis secondary to torsion; surface atypia and hobnail change secondary to torsion
- symplastic stromal cells
- sex cord-like elements in stroma
- "mesonephric-like " glands
- papillary proliferation
- adenofibroma/ adenosarcoma-like areas (ATYPICAL UTERINE POLYPS)
- cellular stroma mimicking endometrial stromal neoplasm
- hyperplasia in polyp (try to use same criteria as in non-polypoid endometrium); allow a little more glandular crowding in a polyp
- carcinoma in polyp (any morphological type); only use term "polyp-cancer" when confined to a polyp- need to see pre-existing benign glands and can only diagnose on hysterectomy specimen

STROMAL METAPLASIAS IN POLYP-RARE

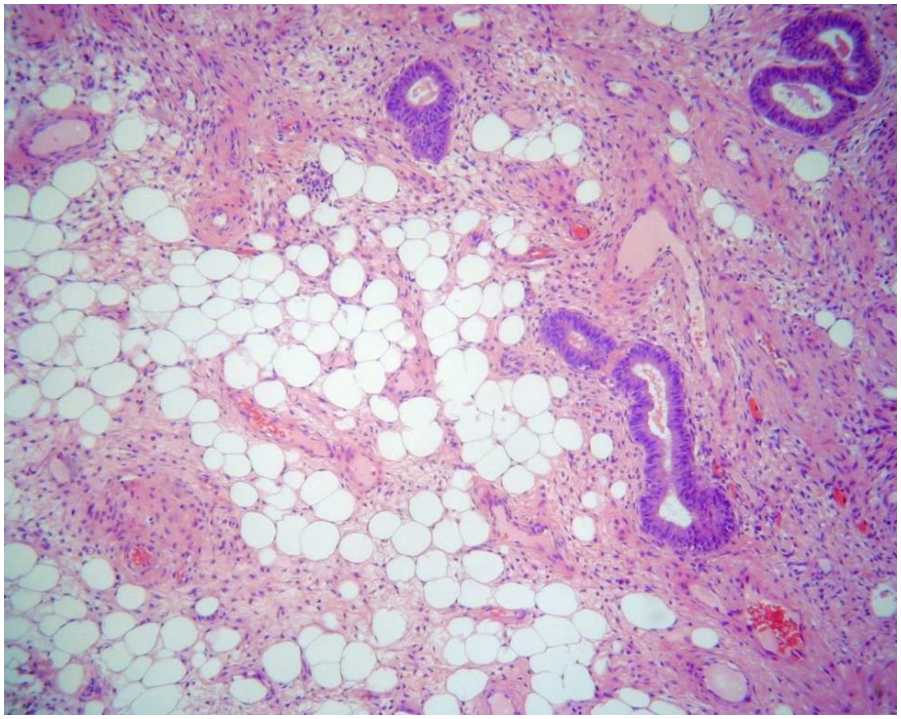

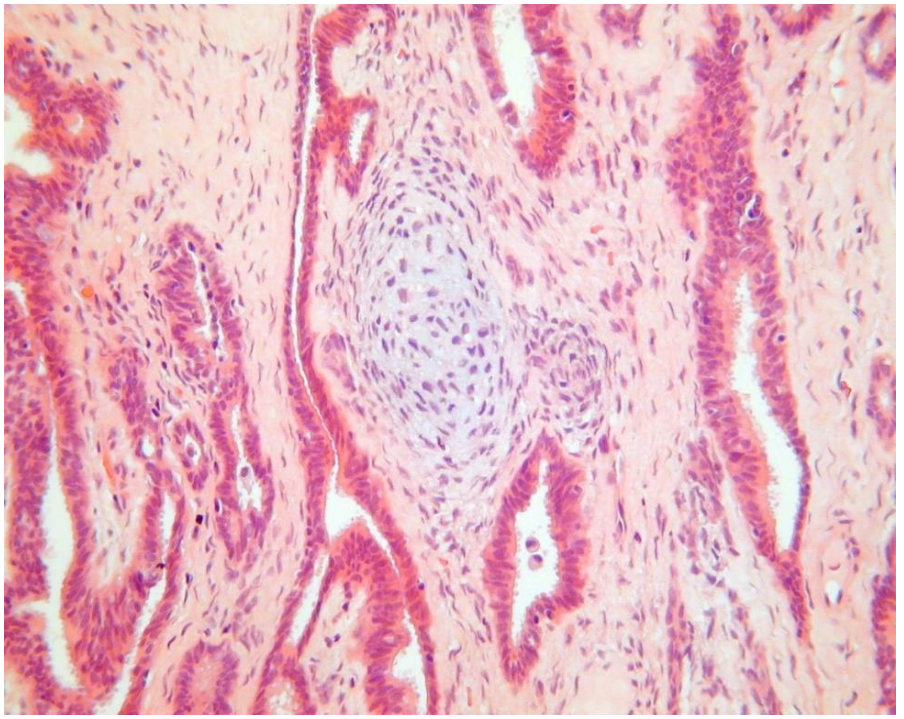

HOBNAIL METAPLASIA IN TORTED/ NECROTIC POLYP

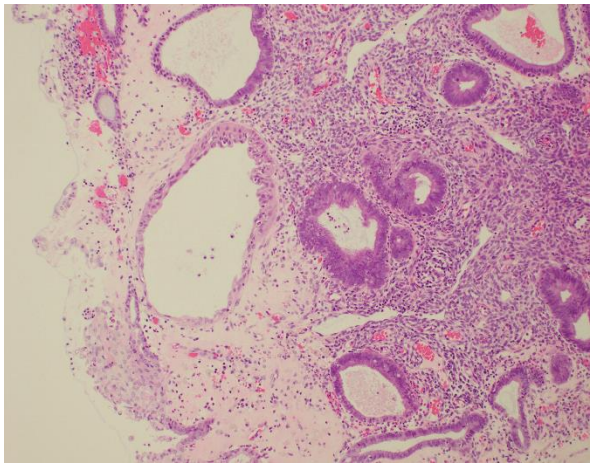

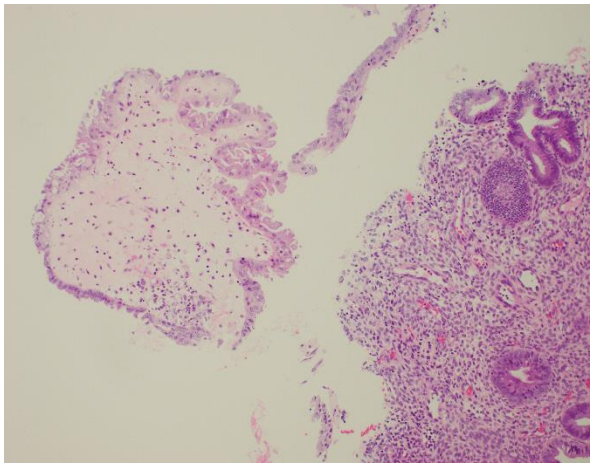

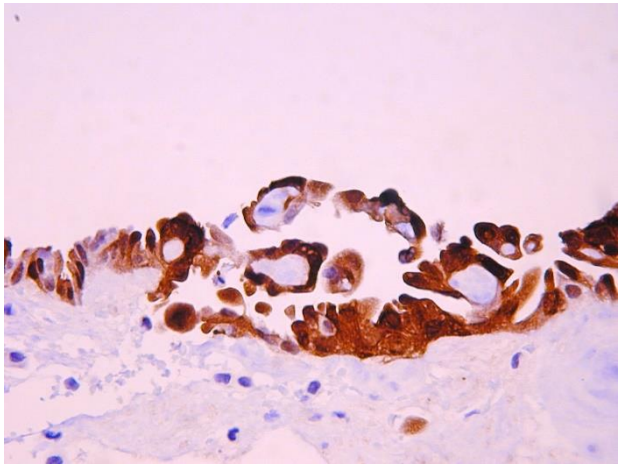

p16

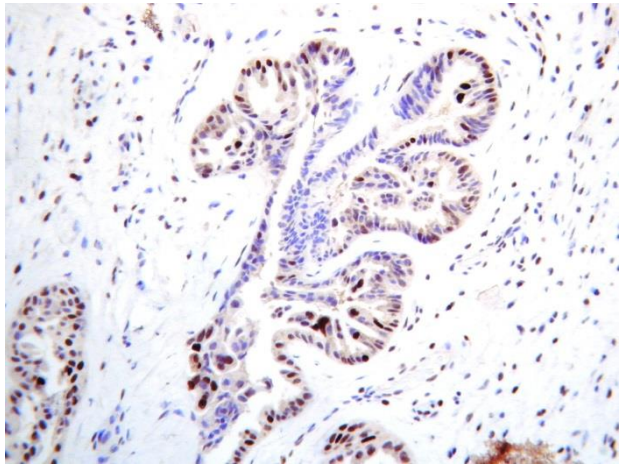

p53

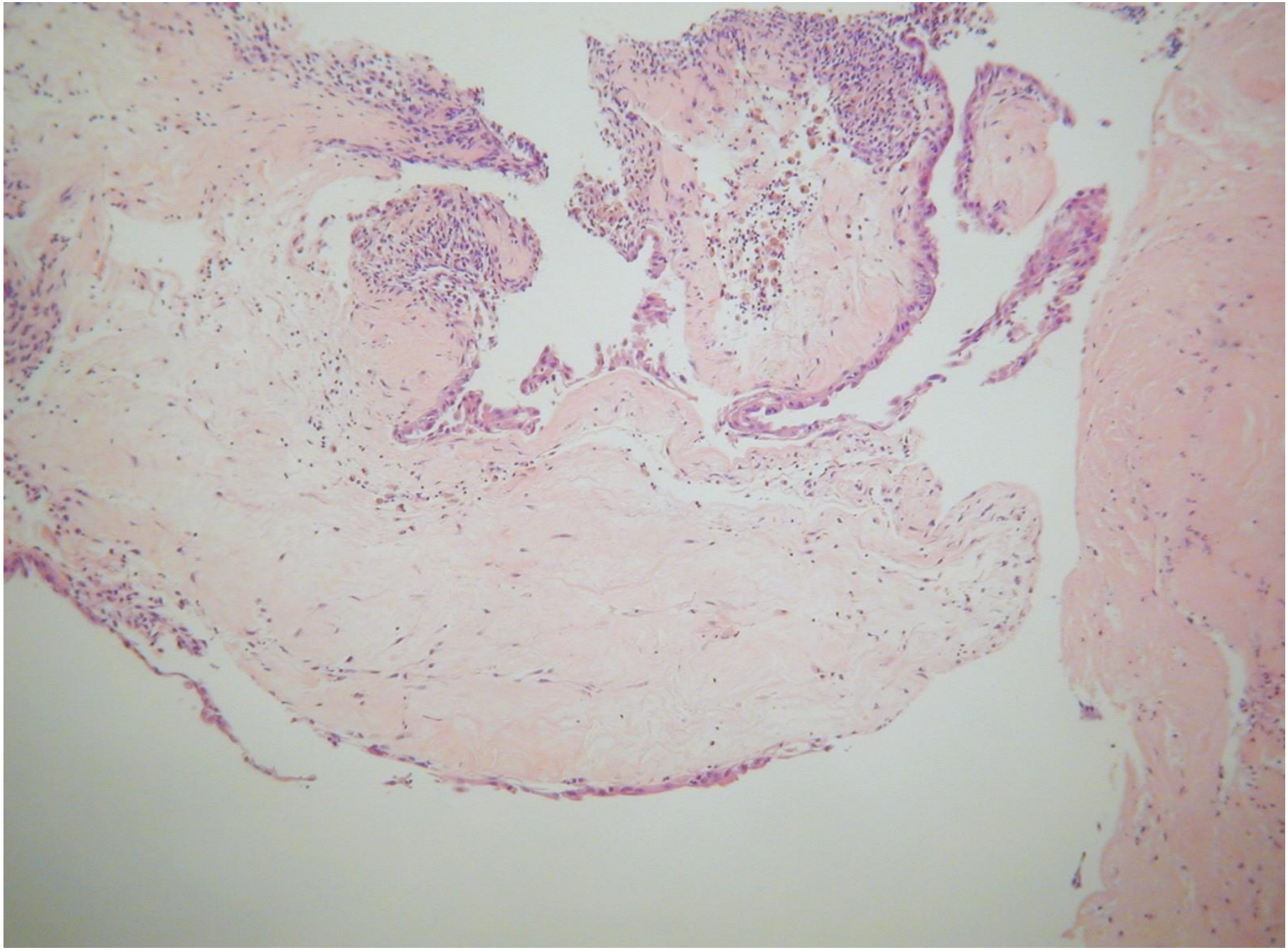

ENDOMETRIAL POLYP- CELLULAR STROMA- MAY CONSIDER ENDOMETRIAL STROMAL NEOPLASM

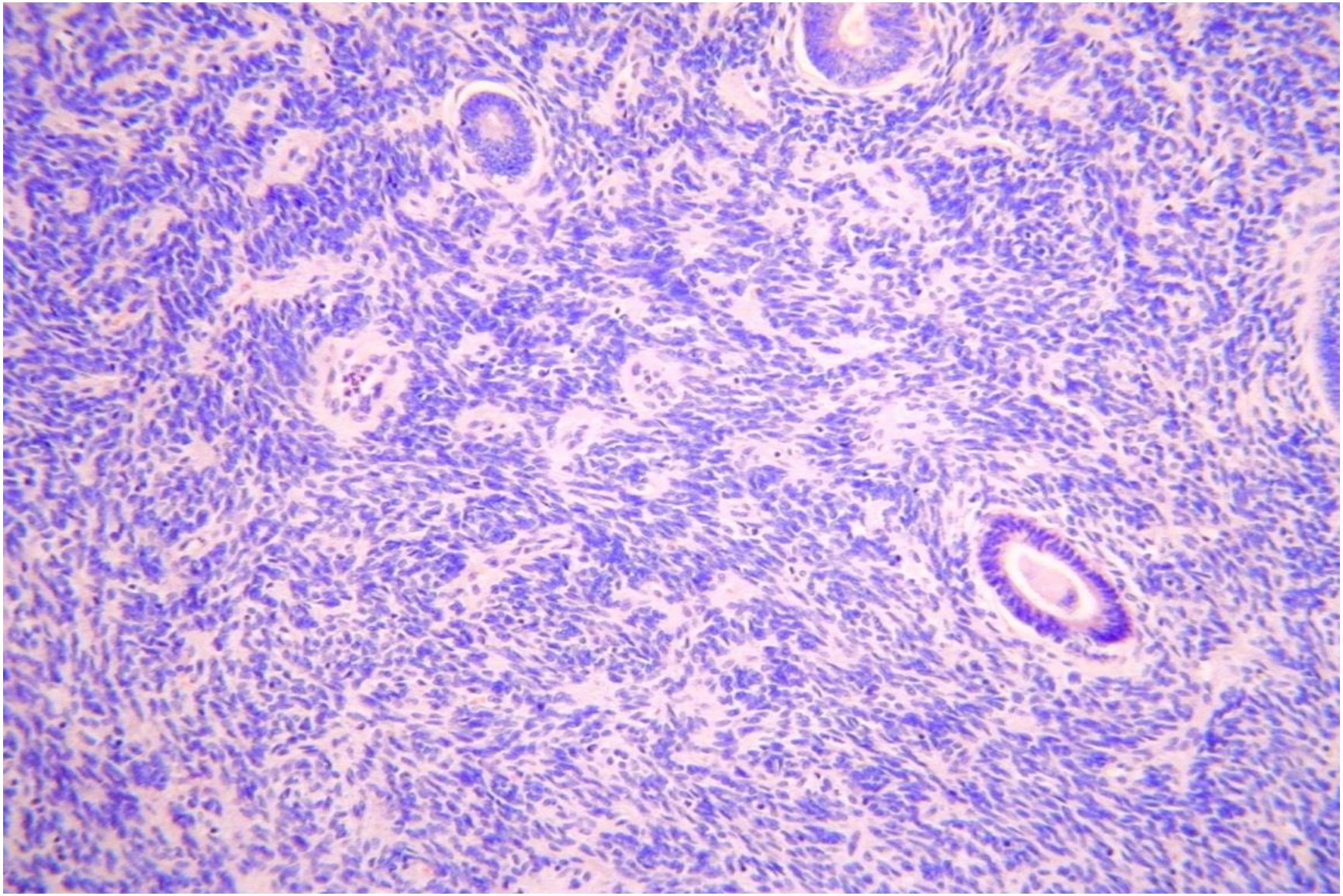

SYMPLASTIC CELLS IN STROMA

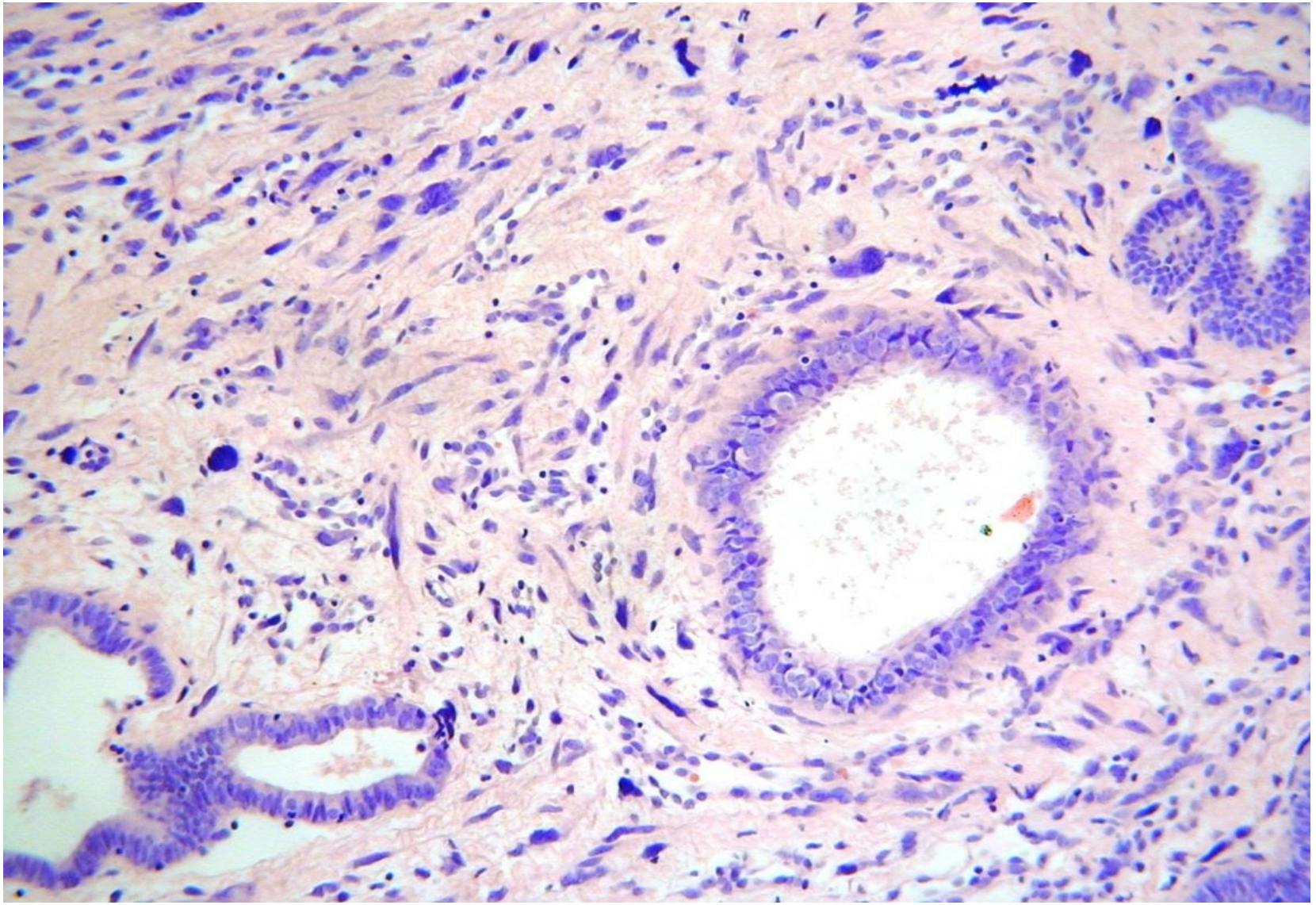

ENDOMETRIAL POLYP- SEX CORD-LIKE STROMA

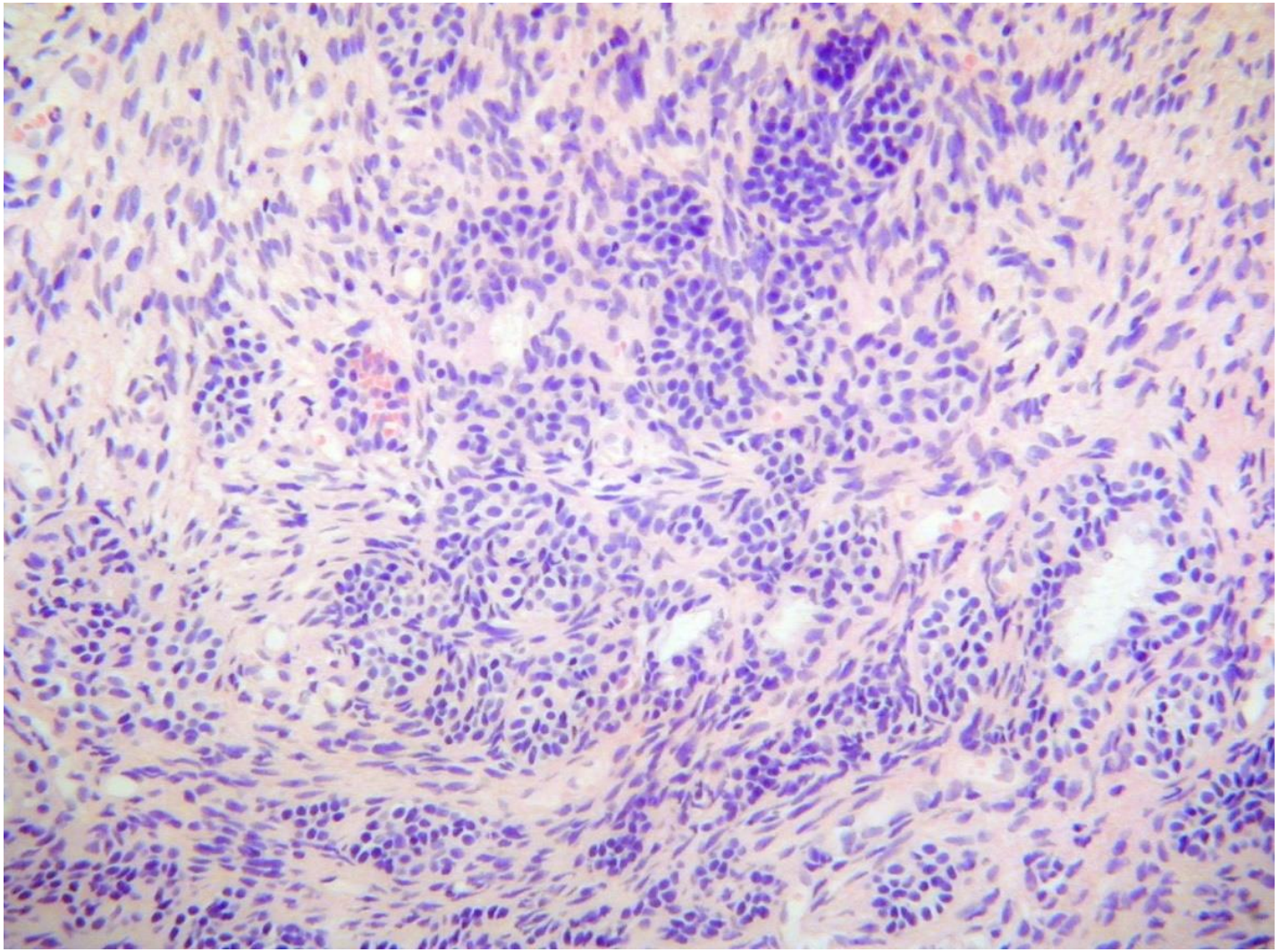

ENDOMETRIAL POLYP WITH "MESONEPHRIC-LIKE" GLANDS

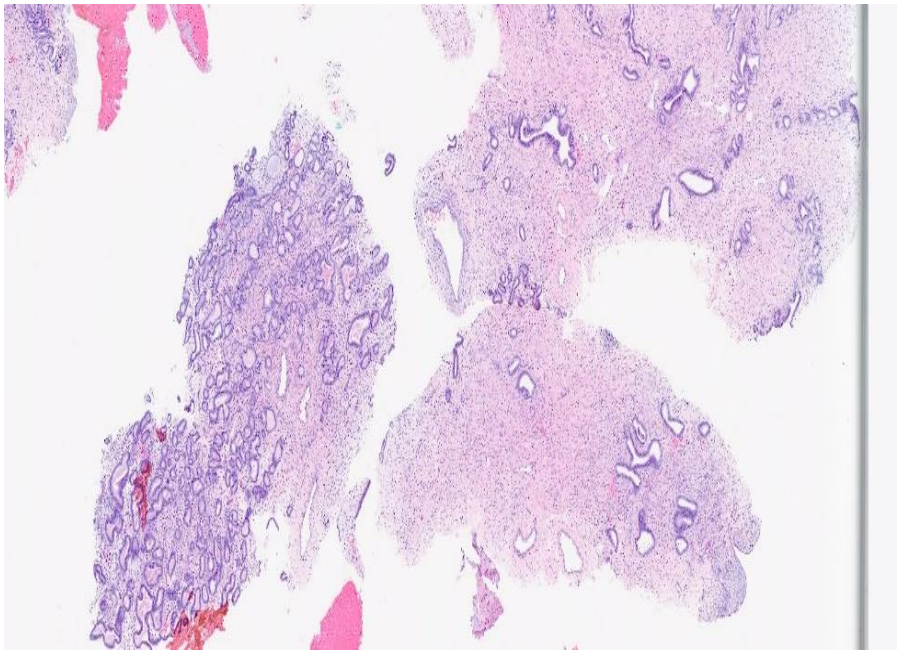

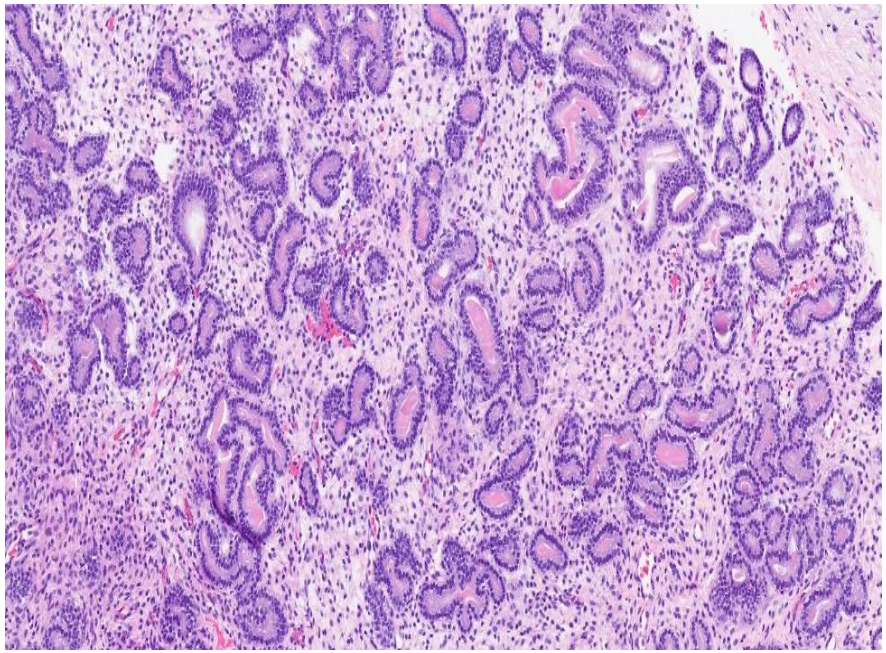

“ATYPICAL UTERINE POLYPS”

- some endometrial or less commonly cervical polyps have some features of adenofibroma/adenosarcoma but not all (polyps with features overlapping with or subdiagnostic of adenosarcoma)
- usually polyps are small and not clinically worrisome
- features include focal phyllodes-like architecture (usually don’t have classical phyllodes-like architecture), intraglandular projections, periglandular increased cellularity, stromal atypia or mitoses
- study- follow up in such cases uneventful (PMID 25118811; AJSP 2015; 39;116-126) – ESPECIALLY IF SMALL
- another study by same group (PMID 34675347; Mod Pathol 2022;35;106-116)
- RESULTS IN LARGE NUMBER OF REFERRAL CASES

ENDOMETRIAL POLYP-ADENOSARCOMA LIKE

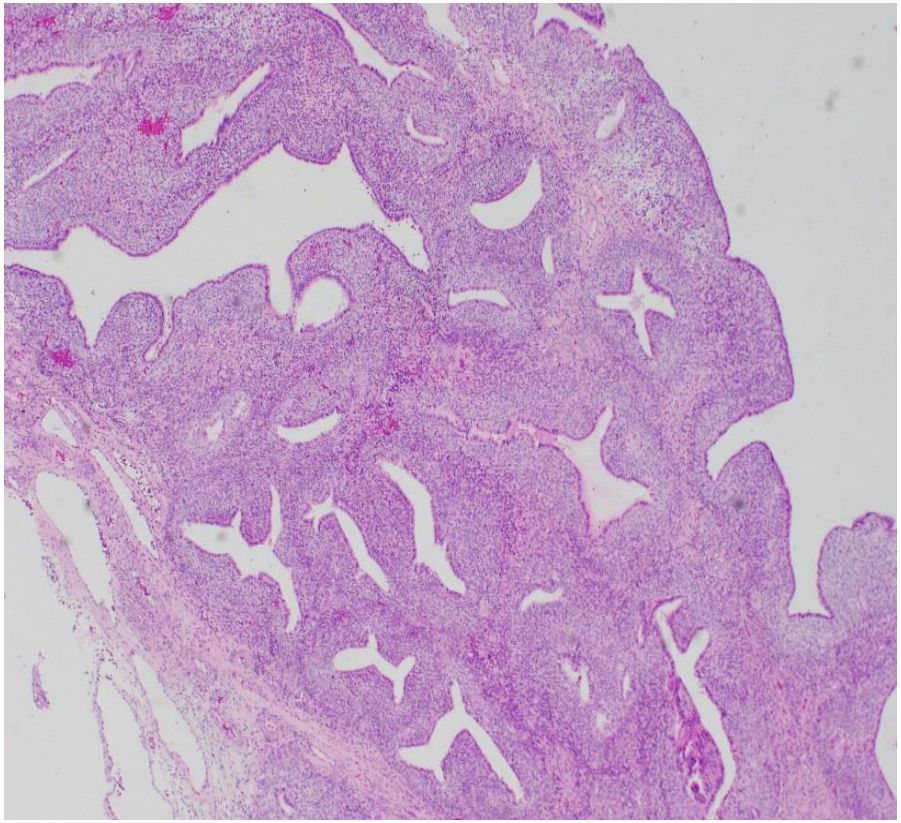

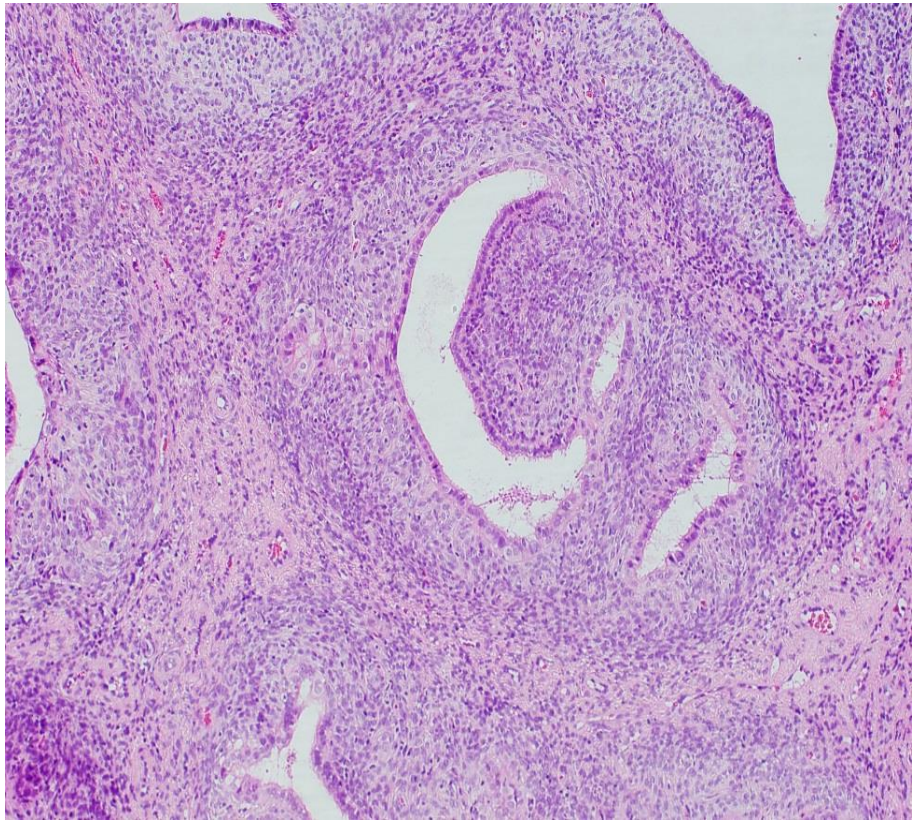

ENDOMETRIAL POLYP-ADENOSARCOMA LIKE





CERVICAL POLYP- ADENOSARCOMA LIKE

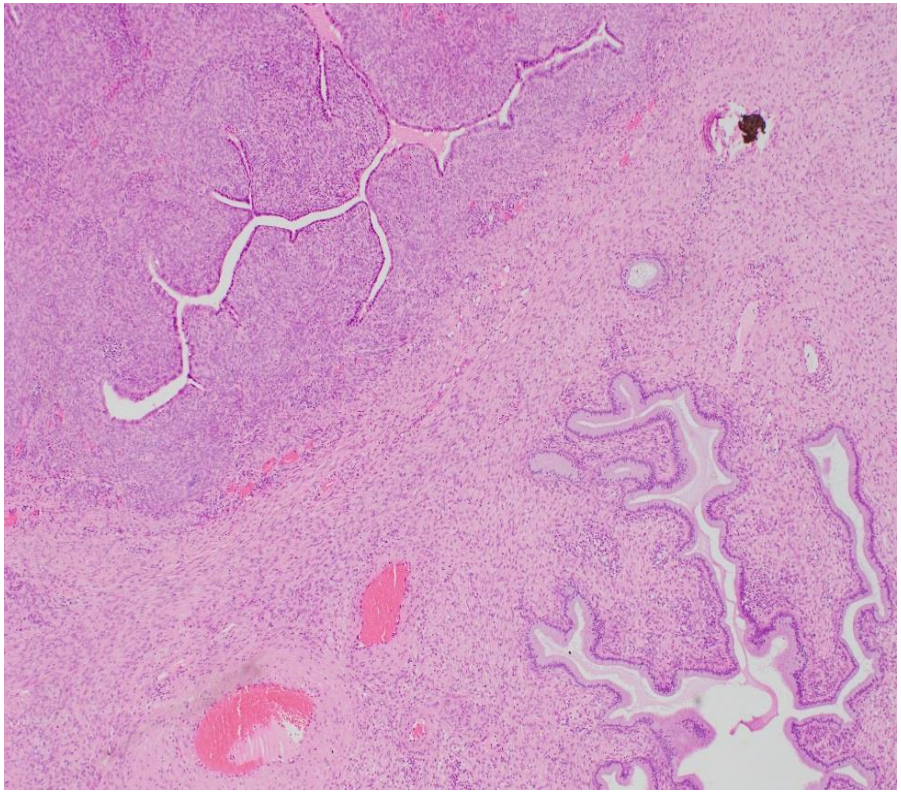

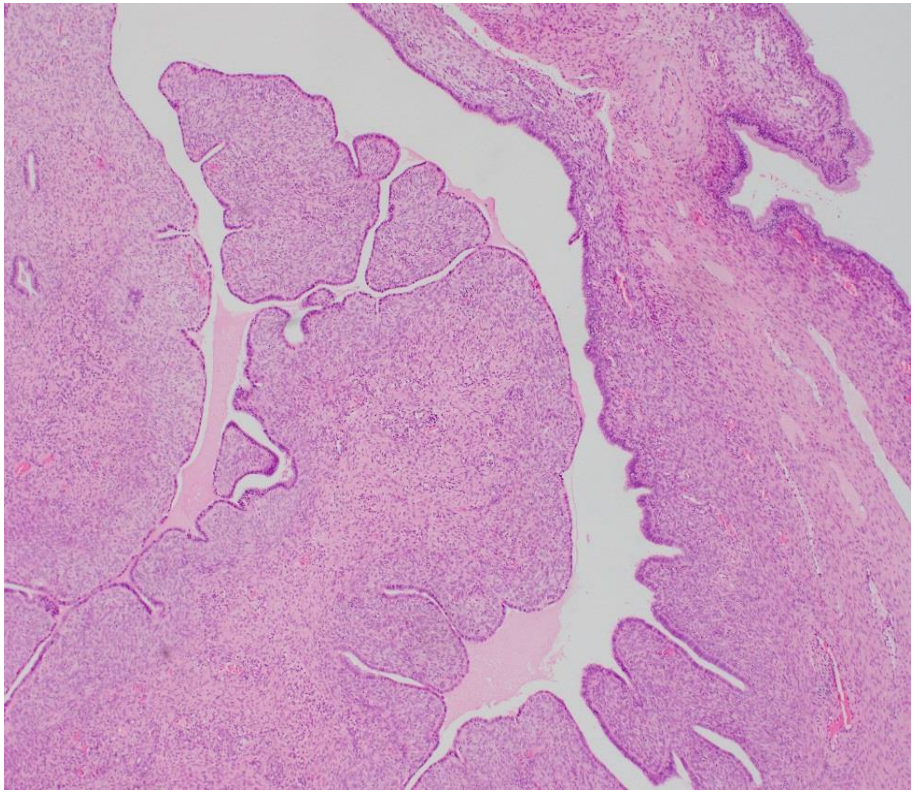

PMID 25118811; AJSP 2015; 39;116-126

ORIGINAL ARTICLE

Uterine Polyps With Features Overlapping With Those of Müllerian Adenosarcoma

A Clinicopathologic Analysis of 29 Cases Emphasizing Their Likely Benign Nature

Brooke E. Howitt, MD, Bradley J. Quade, MD, PhD, and Marisa R. Nucci, MD

PMID 34675347; Mod Pathol 2022;35;106-116

www.nature.com/modpathol

USCAP

ARTICLE

Check for updates

Atypical uterine polyps show morphologic and molecular overlap with mullerian adenosarcoma but follow a benign clinical course

David B. Chapel[1,2✉], Brooke E. Howitt[1,3], Lynette M. Sholl[4], Paola Dal Cin[4] and Marisa R. Nucci[1]

© The Author(s), under exclusive licence to United States & Canadian Academy of Pathology 2021

A subset of clinically benign uterine polyps shows atypical morphologic features worrisome for, but not diagnostic of, Mullerian adenosarcoma. We report clinicopathologic data for 63 polyps from 58 women with atypical morphologic features including abnormal architecture, abnormal periglandular stroma, stromal atypia, and mitoses >2 per 10 hpf. Four (11%) of 36 women with follow-up tissue sampling had residual/recurrent atypical polyp. Twelve (27%) of 44 women underwent hysterectomy subsequent to a diagnosis of atypical polyp. No patient developed adenosarcoma over median follow-up of 150 months. Twenty-one primary atypical polyps underwent molecular profiling. Five (24%) harbored chr 12q13-15 gain or amplification, 9/20 (45%) harbored chr 6q25.1 gain, and 7/21 (33%) had no significant copy number alterations. Gains of chr 1q, chr 8p12, and chr 10q11.21-23, amplifications of chr 12q24.12-13, chr 15p24.1-26.1, and chr 18q21.33, and loss of chr 7 and chr 11q21 were each seen in a single polyp. Mean tumor mutational burden was 3.1 (range, 0.76–8.365) mutations/Mb. Pathogenic point mutations were identified in 12/20 (60%) primary atypical polyps. We propose the term "atypical uterine polyps" for these lesions, which show biologic overlap with early Mullerian adenosarcoma but lack molecular alterations characteristic of clinically aggressive adenosarcoma and appear to follow a benign clinical course. Conservative management with close clinical follow-up and repeat sampling can be considered for these lesions, when clinically appropriate.

Modern Pathology (2022) 35:106–116; https://doi.org/10.1038/s41379-021-00946-z

ATYPICAL UTERINE POLYPS: PMID 34675347

- 63 uterine polyps with features worrisome of, but not diagnostic of, adenosarcoma
- Abnormal architecture, periglandular increased cellularity, stromal atypia, stromal mitotic activity >2 per 10 HPF
- No patient developed adenosarcoma with median follow up of 150 months
- 21 polyps underwent molecular profiling: 24% harboured chr 12q13-15 gains or amplifications and 45% harboured chr 6q25.1 gain: also pathogenic point mutations in 60%
- Proposed term “atypical uterine polyp” for such lesions which show biological overlap with adenosarcoma but lack molecular alterations associated with aggressive behaviour in adenosarcoma and follow a benign clinical course

PAPILLARY PROLIFERATION OF ENDOMETRIUM

- originally described as HYPERPLASTIC PAPILLARY PROLIFERATION OF ENDOMETRIUM (Lehman and Hart) (AJSP; PMID 11684950)
- papillae with fibrovascular stromal cores
- bland cytology
- often associated with epithelial metaplasias, especially mucinous
- most common within and on surface of polyps
- may be misdiagnosed as hyperplasia or architecturally well differentiated adenocarcinoma
- usually benign outcome (but occasionally associated with hyperplasia or carcinoma)

PAPILLARY PROLIFERATION OF ENDOMETRIUM

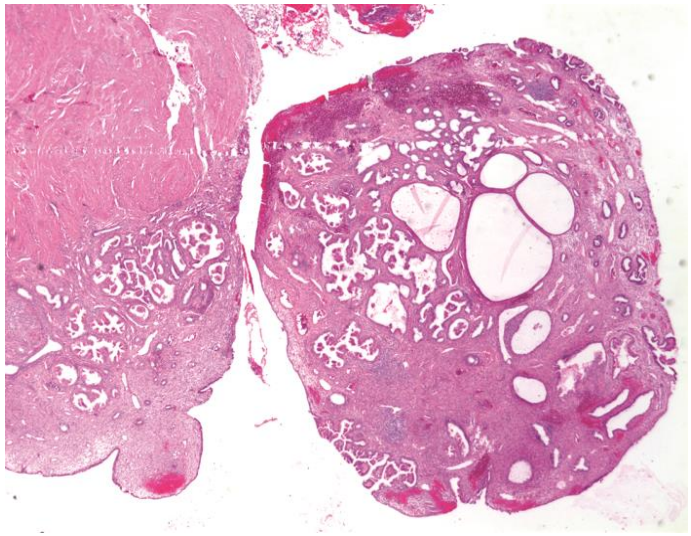

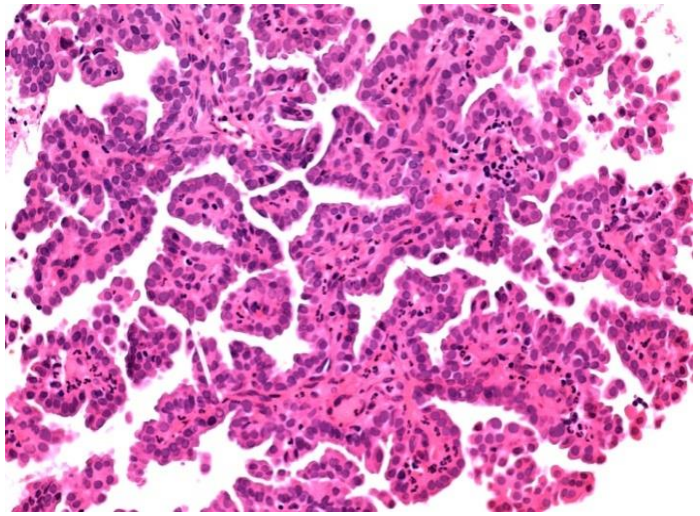

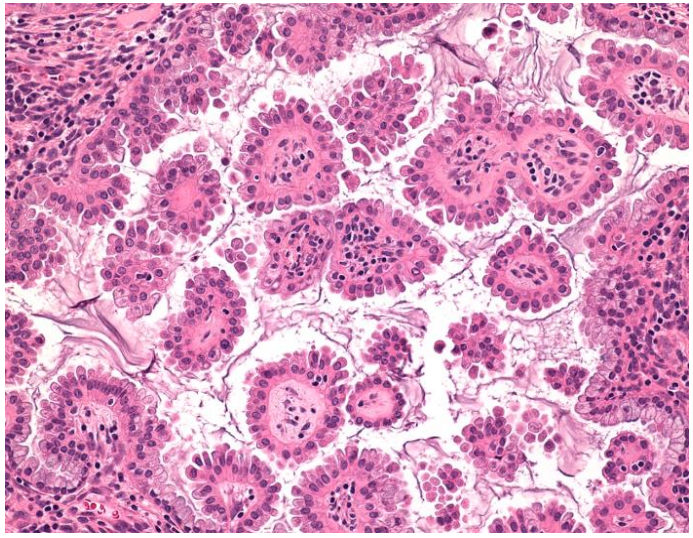

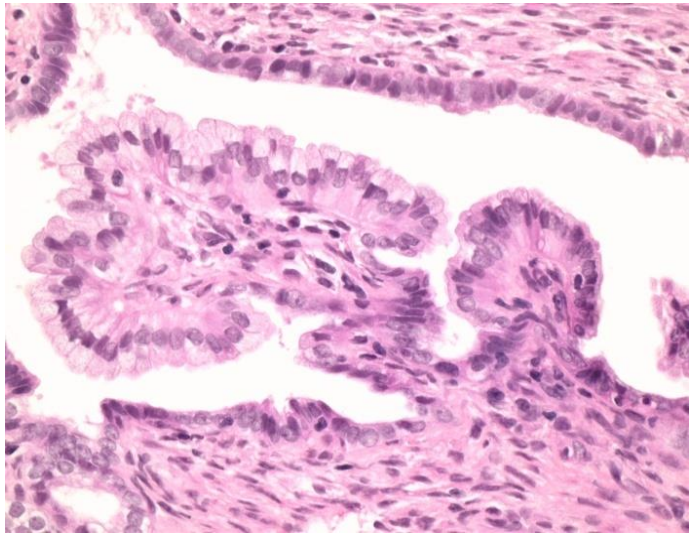

PAPILLARY PROLIFERATION OF ENDOMETRIUM- AJSP 2013;37;167-177

- 59 cases of papillary proliferation of endometrium (PPE)
- group 1- simple/focal papillae; group 2- complex/widespread papillae
- 80% had endometrial polyp
- 90% had epithelial metaplasia- most commonly mucinous
- coexistent or subsequent non-atypical or atypical hyperplasia found in 17% and 13% respectively; 13% had low grade endometrioid adenocarcinoma, either concurrently or subsequently
- group 2 significantly associated with premalignant or malignant change
- **simple papillae- benign- term benign PPE appropriate (may not even mention on report)**
- **complex or widespread papillae- require follow up- report as analogous to atypical hyperplasia- complex PPE**
- associated with *KRAS* mutations

ATYPICAL POLYPOID ADENOMYOMA (APA)

- rare
- usually , but not always, young
- most common low in uterine corpus/ lower uterine segment
- endometrioid glands in myomatous or myofibromatous stroma
- major differential is endometrioid carcinoma invading myometrium
- reasonably easy to diagnose in hysterectomy but often difficult on biopsy
- may recur following polypectomy
- definite association with endometrioid carcinoma (8.8% in one meta-analysis)
- endometrioid carcinoma or atypical hyperplasia may occur in surrounding non-polypoid endometrium or low grade endometrioid carcinoma may occur within APA

MOLECULAR PATHOLOGY OF APA

- AJSP 2015; 39; 1148-55 (PMID) (similar molecular alterations to endometrioid carcinoma and atypical hyperplasia)
- *PTEN* mutations
- *KRAS* mutations
- likely *beta-catenin(CTNNB1)* mutations given common presence of morules (not looked at in study)
- **BEST TO REGARD AS ANALAGOUS TO LOCALISED FORM OF ATYPICAL HYPERPLASIA (similar molecular alterations)**

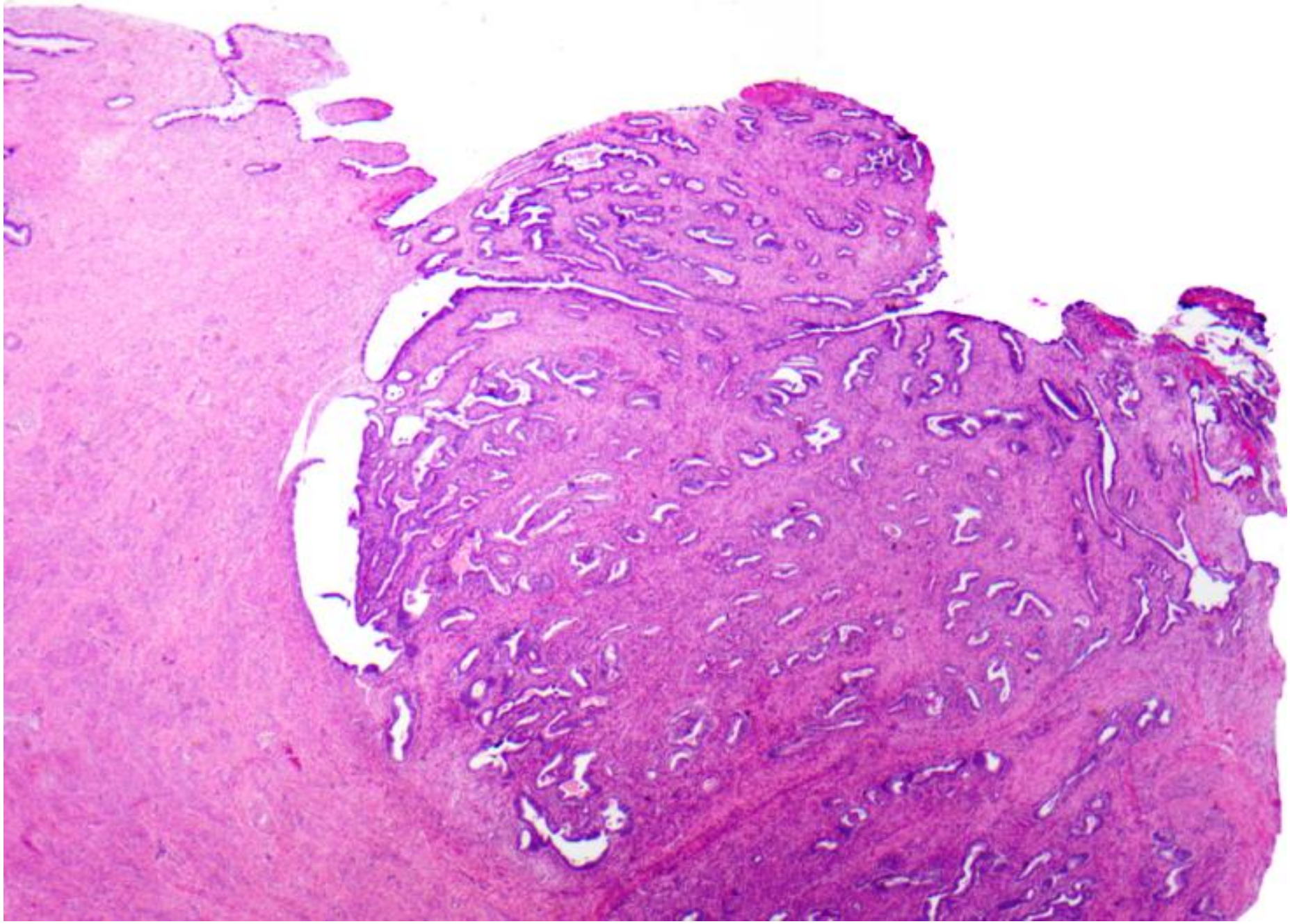

APA

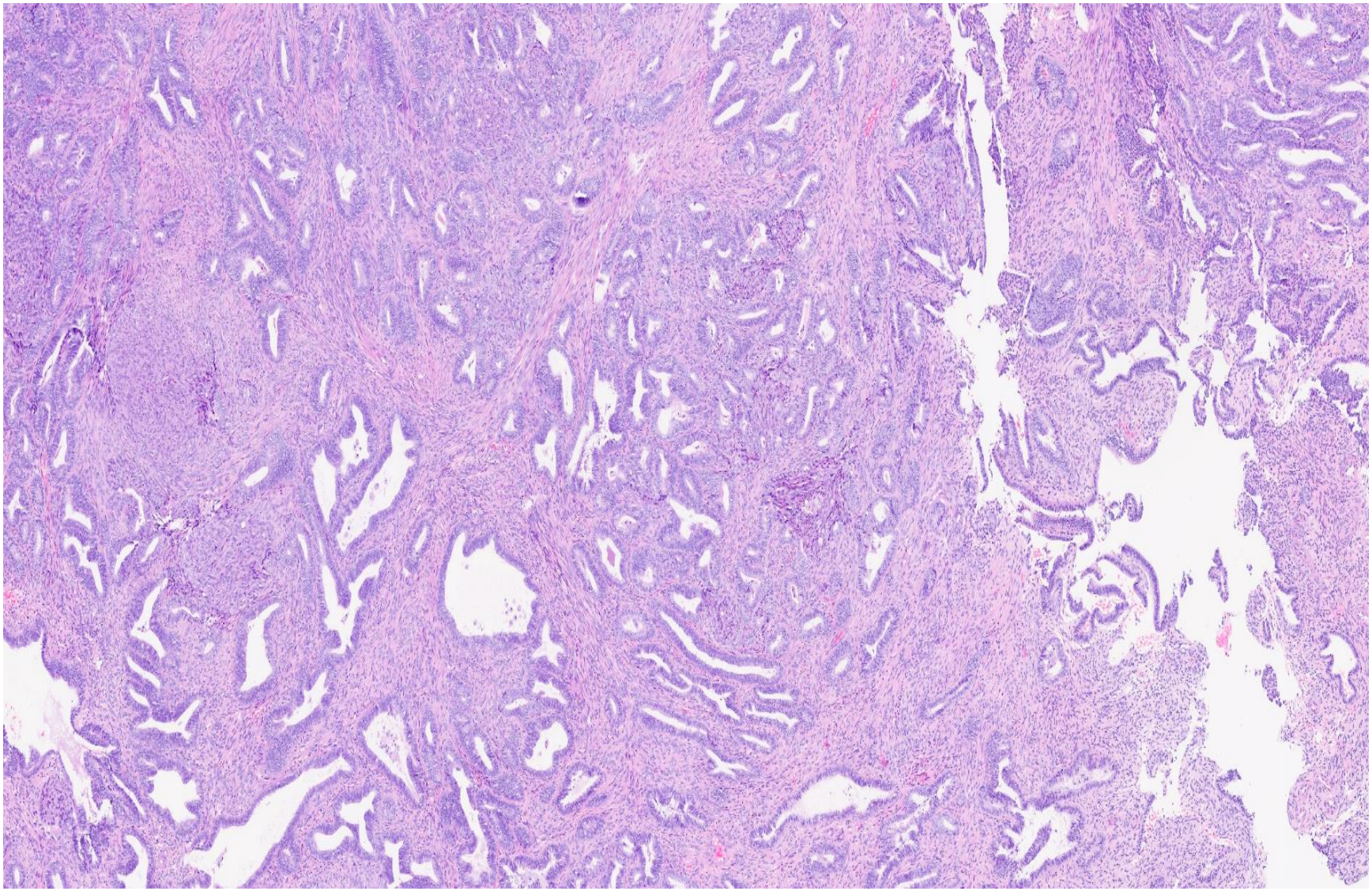

APA

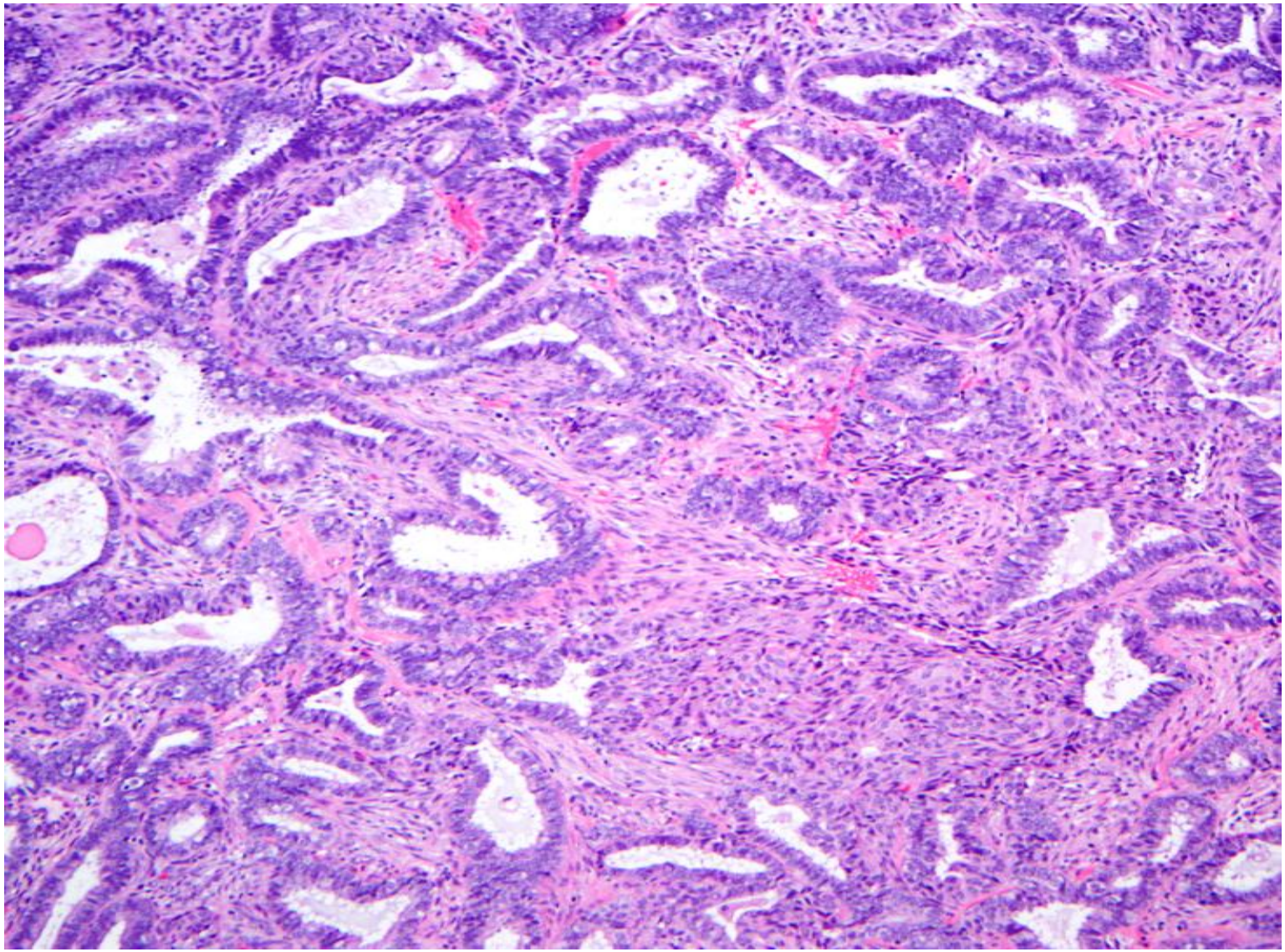

APA

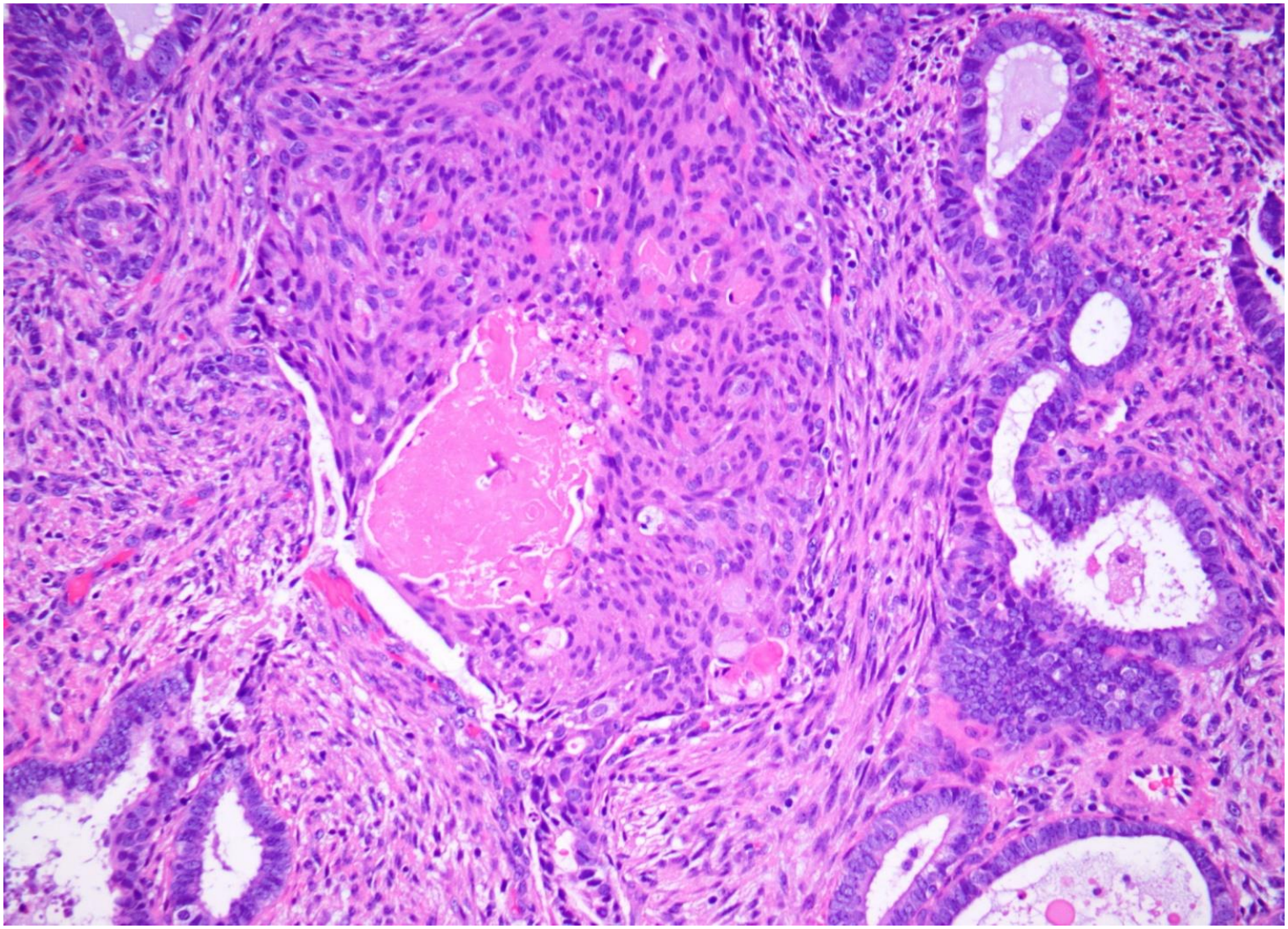

APA- STROMAL MITOSES

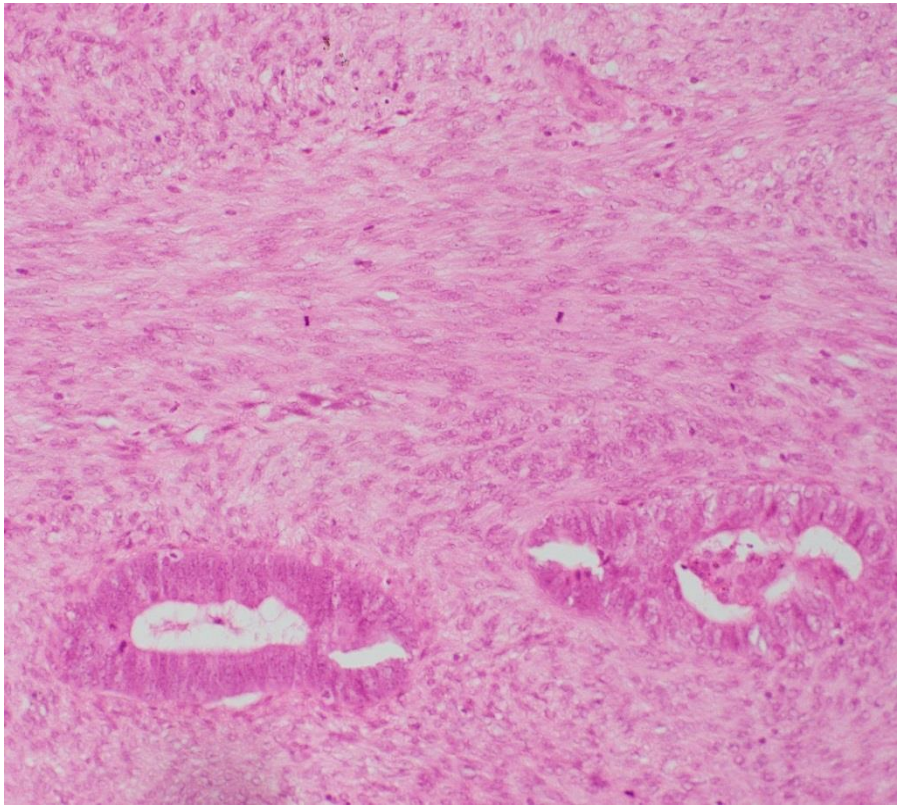

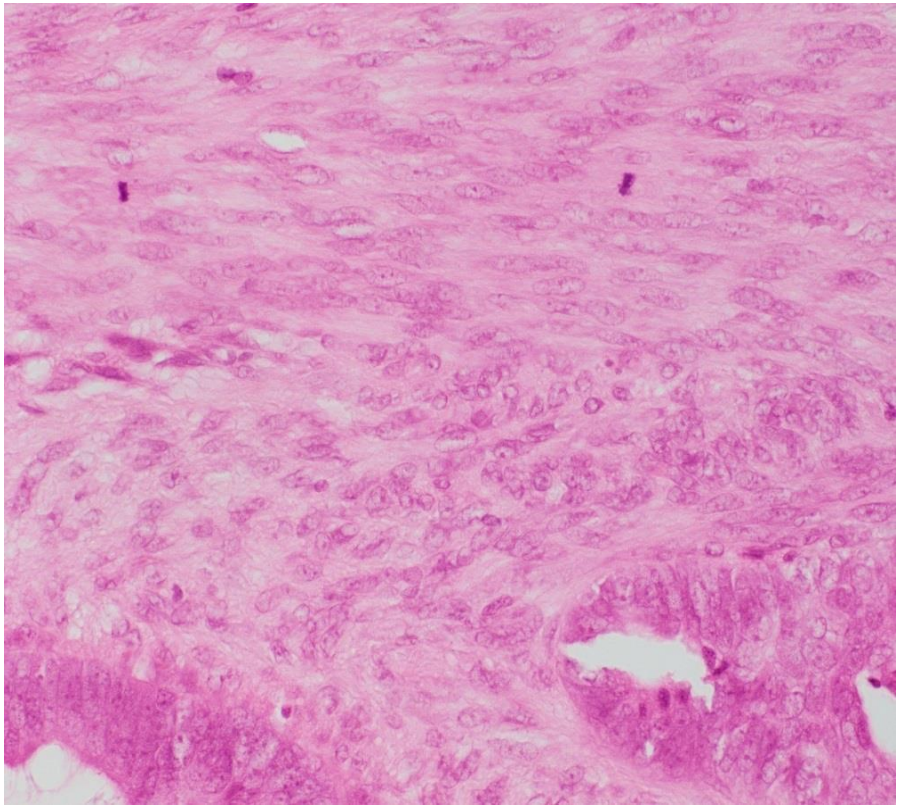

DIFFERENTIAL WITH ENDOMETRIOID CARCINOMA INVADING MYOMETRIUM

- unusual to see myometrial invasion on endometrial biopsy and unusual to see myoinvasive tumour without free tumour fragments
- admixture of normal endometrium and lesion can be a clue
- subtle differences between normal myometrium (long fascicles) and stroma of APA (short fascicles; not so overtly myomatous; may see mitotic figures)

BIOPSY- APA

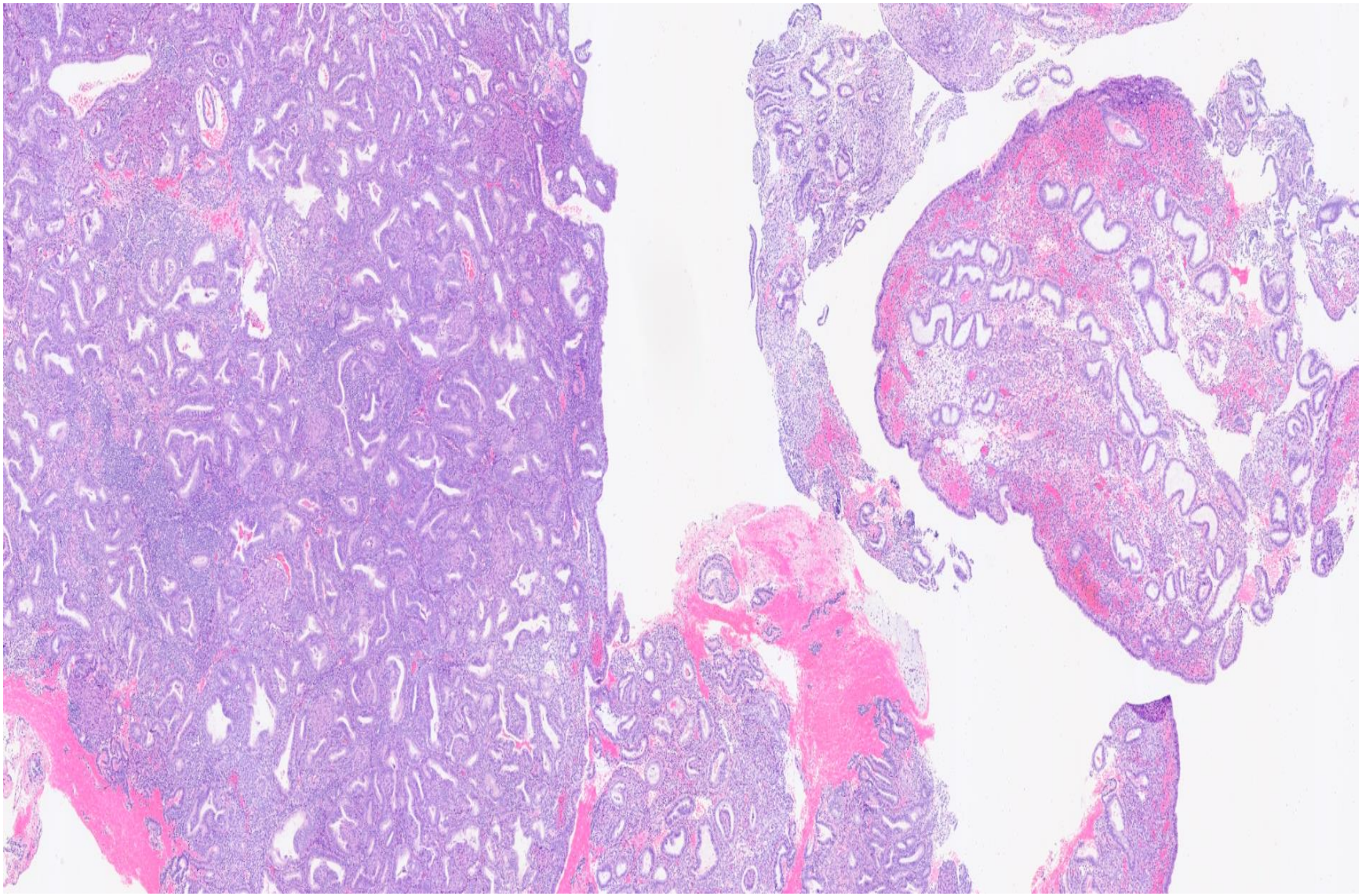

IMMUNOHISTOCHEMISTRY

- traditionally doesn't usually contribute greatly to diagnosis of APA
- H-caldesmon usually largely negative in stromal component (incomplete smooth muscle differentiation) may help to distinguish from myoinvasive endometrioid carcinoma
- CD10 usually negative in stromal component (often "fringe"- pattern staining around myoinvasive glands of endometrioid carcinomas
- NEW MARKERS (SATB2 and p16 promising adjuncts)

APA

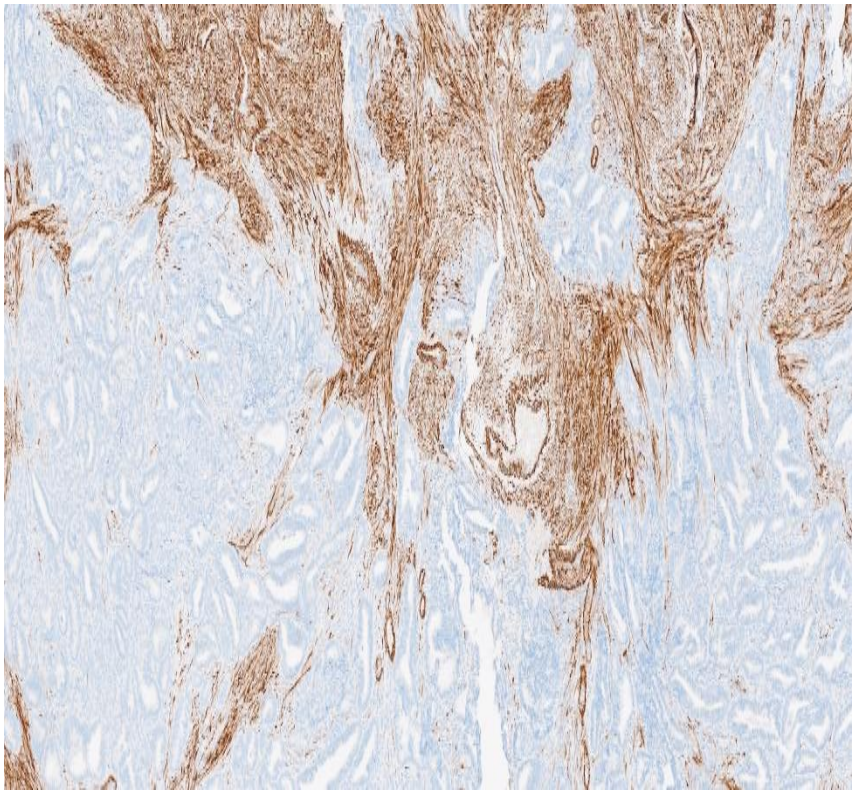

desmin

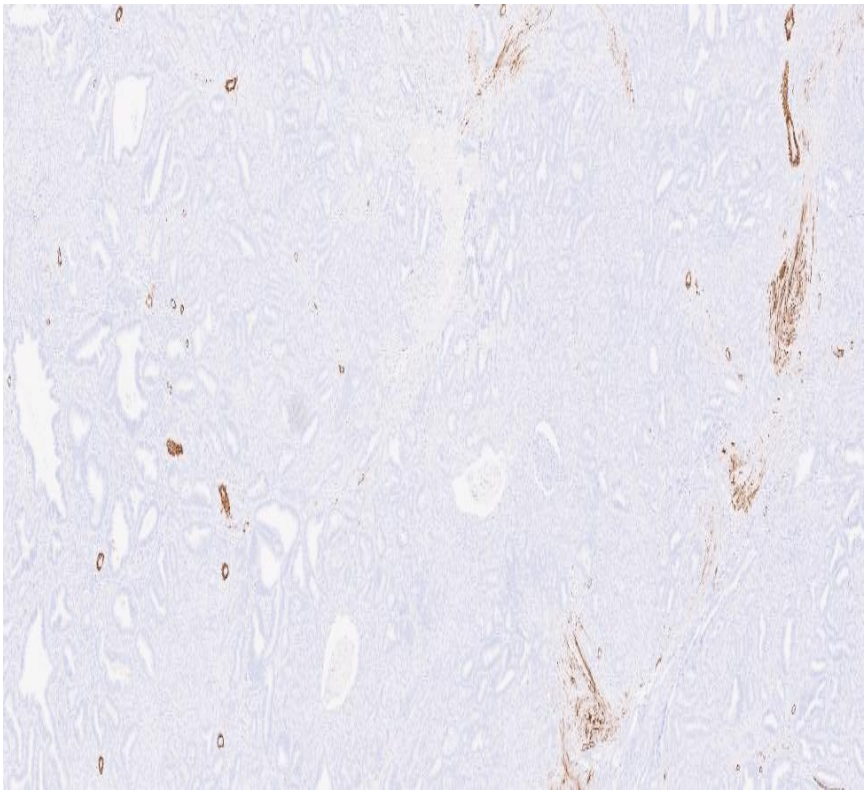

H-caldesmon

SATB2 IN APA (PMID 30085940)

International Journal of Gynecological Pathology
38:397–403, Lippincott Williams & Wilkins, Baltimore
Copyright © 2018 by the International Society of Gynecological Pathologists

Original Article

SATB2 is Consistently Expressed in Squamous Morules Associated With Endometrioid Proliferative Lesions and in the Stroma of Atypical Polypoid Adenomyoma

W. Glenn McCluggage, F.R.C.Path and Koen Van de Vijver, Ph.D.

SATB2 AND p16 IN APA (PMID 33459390)

Histopathology

Histopathology 2021, **79**, 96–105. DOI: 10.1111/his.14338

Patterns of SATB2 and p16 reactivity aid in the distinction of atypical polypoid adenomyoma from myoinvasive endometrioid carcinoma and benign adenomyomatous polyp on endometrial sampling

Helen I Worrell,[1] Andrew P Sciallis[2] & Stephanie L Skala[2,3]

[1]*Beaumont Health, Beaumont Hospital, Troy, MI,* [2]*Department of Pathology, University of Michigan, Ann Arbor, MI, and* [3]*Rogel Cancer Center, University of Michigan, Ann Arbor, MI, USA*

Date of submission 25 November 2020
Accepted for publication 14 January 2021
Published online *Article Accepted* 18 January 2021

SATB2 IN STROMA OF APA

- PMID 30085940
- Stromal cells of APA usually SATB2 positive
- SATB2 usually (not always) negative in stroma of other endometrial polypoid lesions
- Reason for SATB2 positivity unknown

SATB2 IN APA (PMID 30085940)

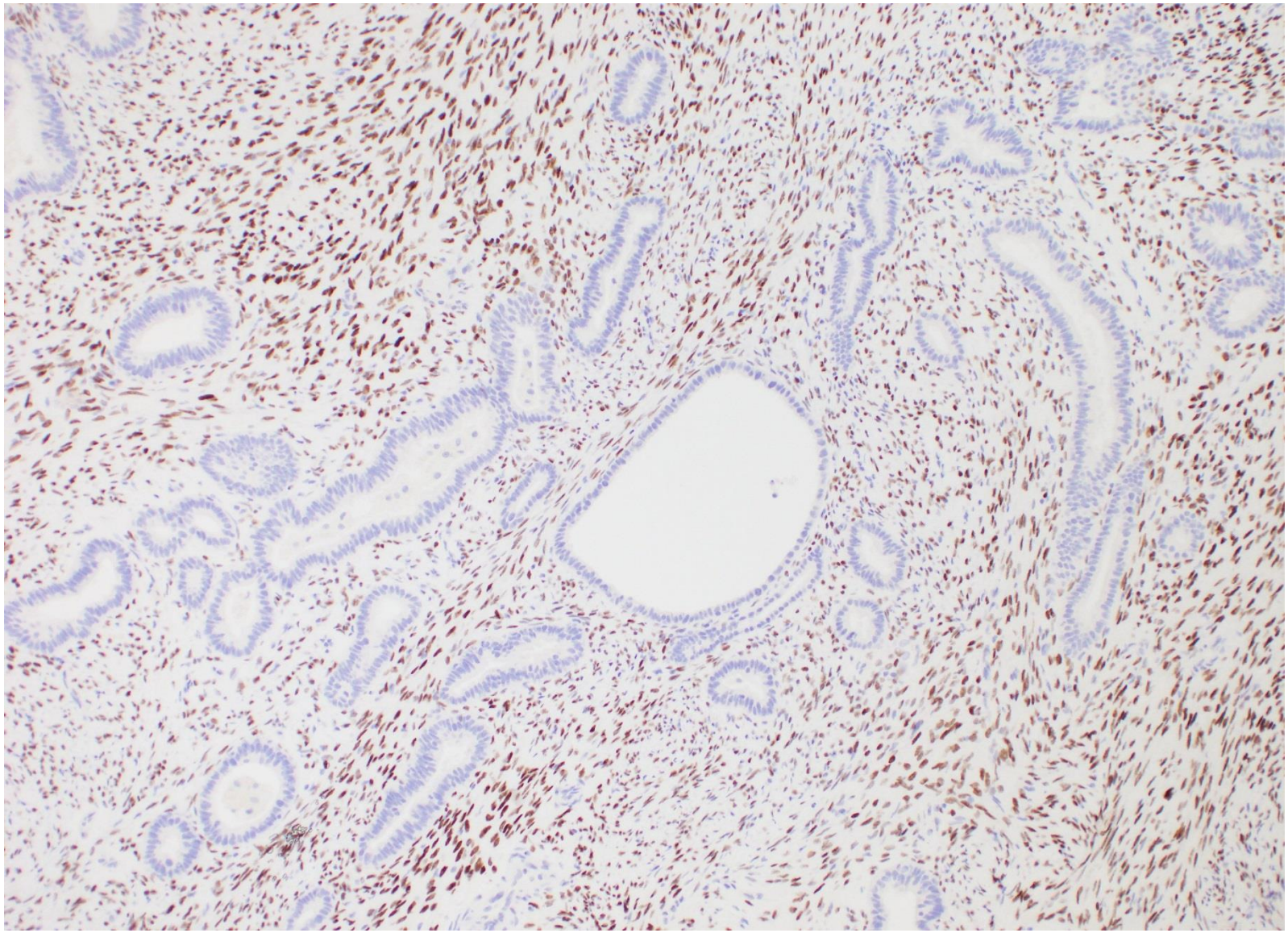

p16 in APA (note that p16 may also be positive in stroma of endometrial polyps- PMID 22772724)

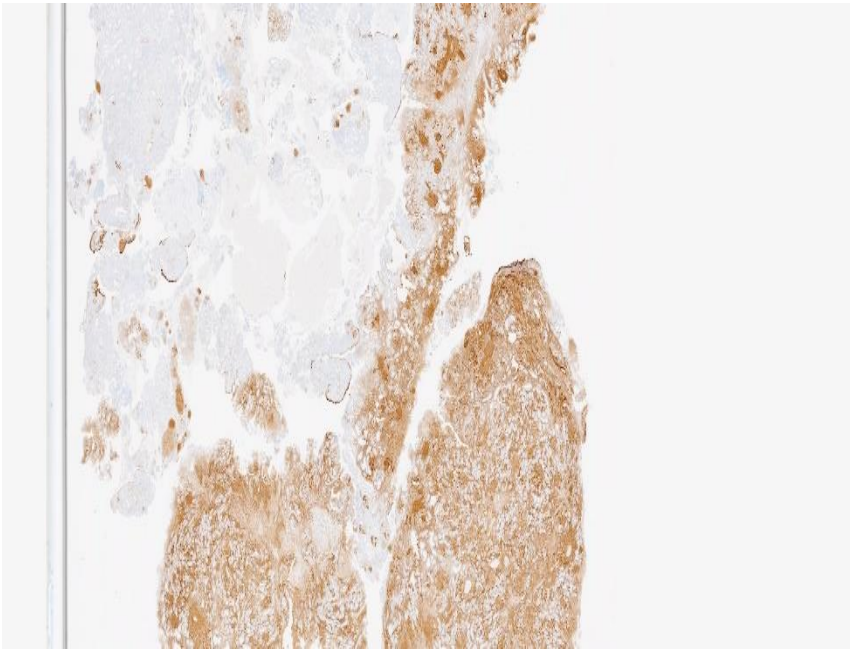

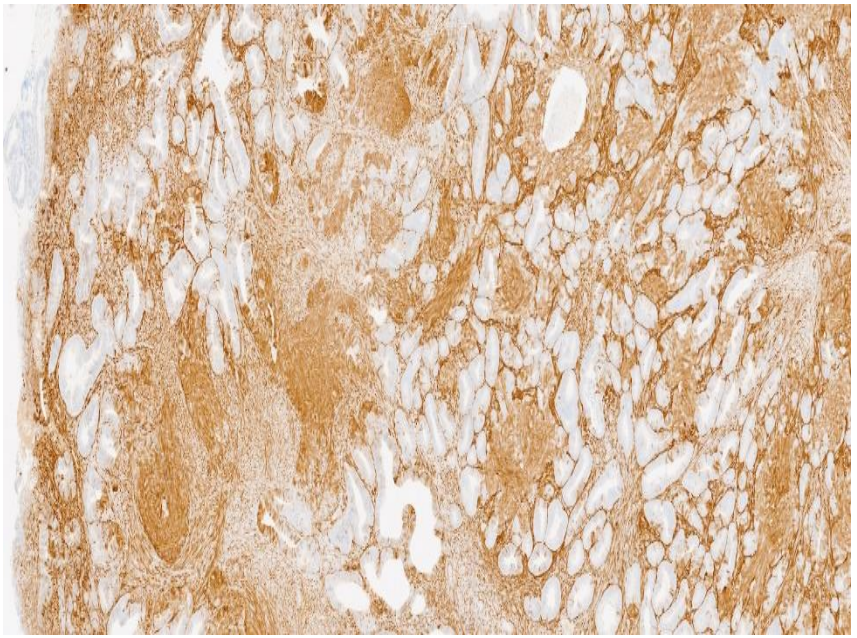

DIFFERENTIAL DIAGNOSIS OF APA

- Benign endometrial polyp (can get minor smooth muscle component)
- Hyperplasia within polyp
- “Adenomyomatous polyp/ adenomyoma”
- Adenosarcoma
- Carcinosarcoma
- Endometrioid carcinoma involving myometrium or with prominent stromal response

DIFFERENTIAL WITH BENIGN ENDOMETRIAL POLYP

- Some benign endometrial polyps contain minor stromal component of smooth muscle; stroma not usually overtly myomatous
- Glandular architecture usually different in polyp- lot of glandular dilatation and not much crowding

SMOOTH MUSCLE IN ENDOMETRIAL POLYP

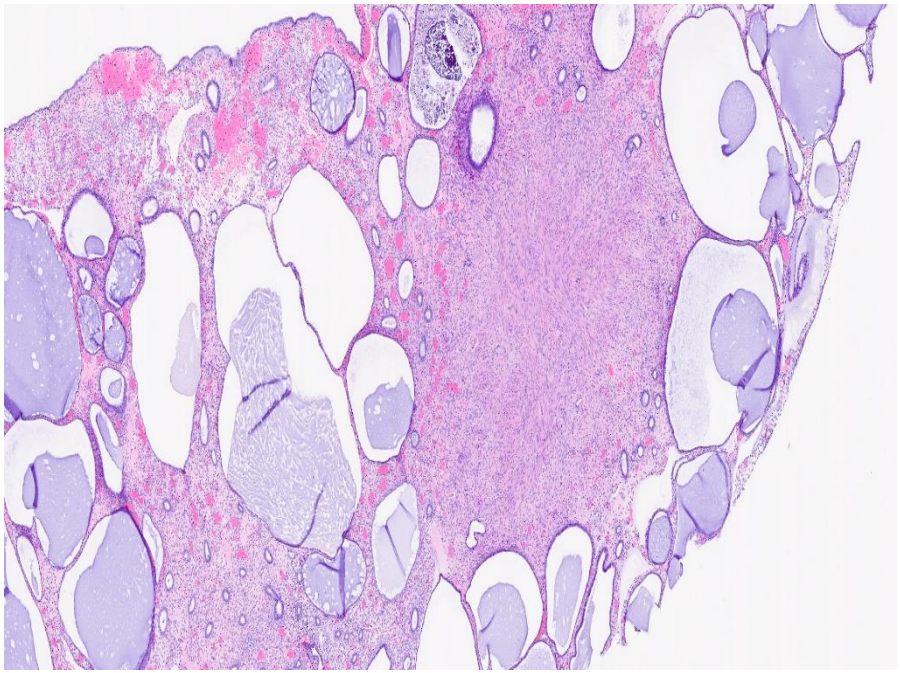

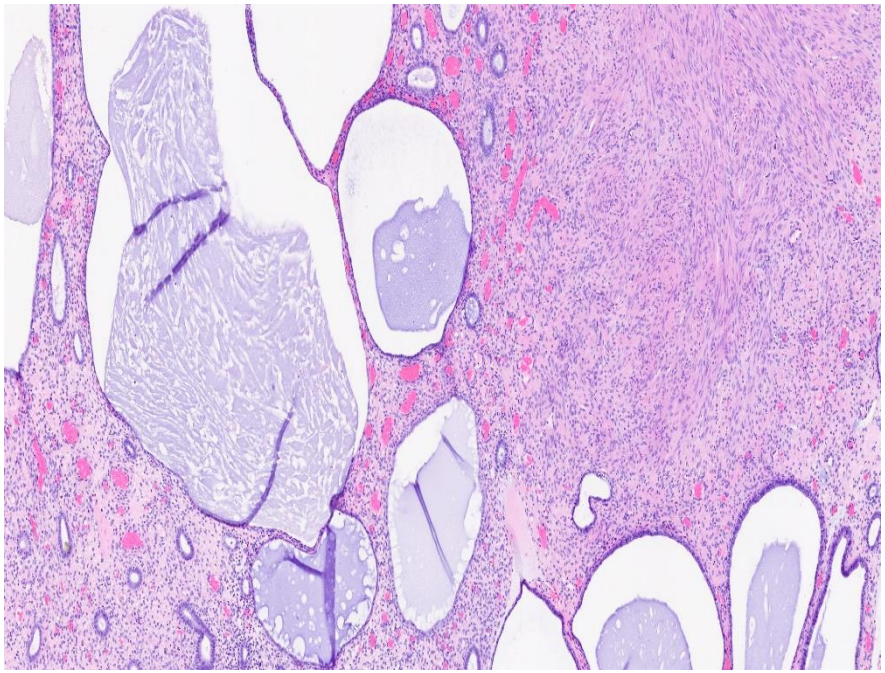

UTERINE ADENOMYOMA: PMID 10907166

International Journal of Gynecological Pathology
19:195–205, Lippincott Williams & Wilkins, Baltimore
© 2000 International Society of Gynecological Pathologists

Uterine Adenomyomas Excluding Atypical Polypoid Adenomyomas and Adenomyomas of Endocervical Type: A Clinicopathologic Study of 30 Cases of an Underemphasized Lesion That May Cause Diagnostic Problems with Brief Consideration of Adenomyomas of Other Female Genital Tract Sites

C. Blake Gilks, M.D., Philip B. Clement, M.D., William R. Hart, M.D., and Robert H. Young, M.D.

UTERINE ADENOMYOMA

- distinct from APA; often get misdiagnosed as APA or adenosarcoma
- sometimes called adenomyomatous polyp
- distinct from endometrial polyp with stromal smooth muscle component
- polypoid or intramural or subserosal lesions may be associated with underlying adenomyosis
- **glands surrounded by endometrial type stroma which is surrounded by usually predominant smooth muscle component (zoning phenomenon); stromal component may be focally inconspicuous (may be highlighted by CD10)**
- can also occur in cervix or outside the uterus (broad ligament- “uterus-like” lesions)
- benign follow-up
- PATHOLOGISTS OFTEN NOT AWARE OF LESION AND RESULTS IN FAIR NUMBER OF REFERRAL CASES

ADENOMYOMA

- Can get various “secondary” changes in glandular and smooth muscle component
- Glandular crowding (resembling hyperplasia), dilatation, metaplasias
- Smooth muscle component may be oedematous and contain thick-walled vessels
- Smooth muscle component may contain adipose tissue, be highly cellular or exhibit symplastic-like atypia

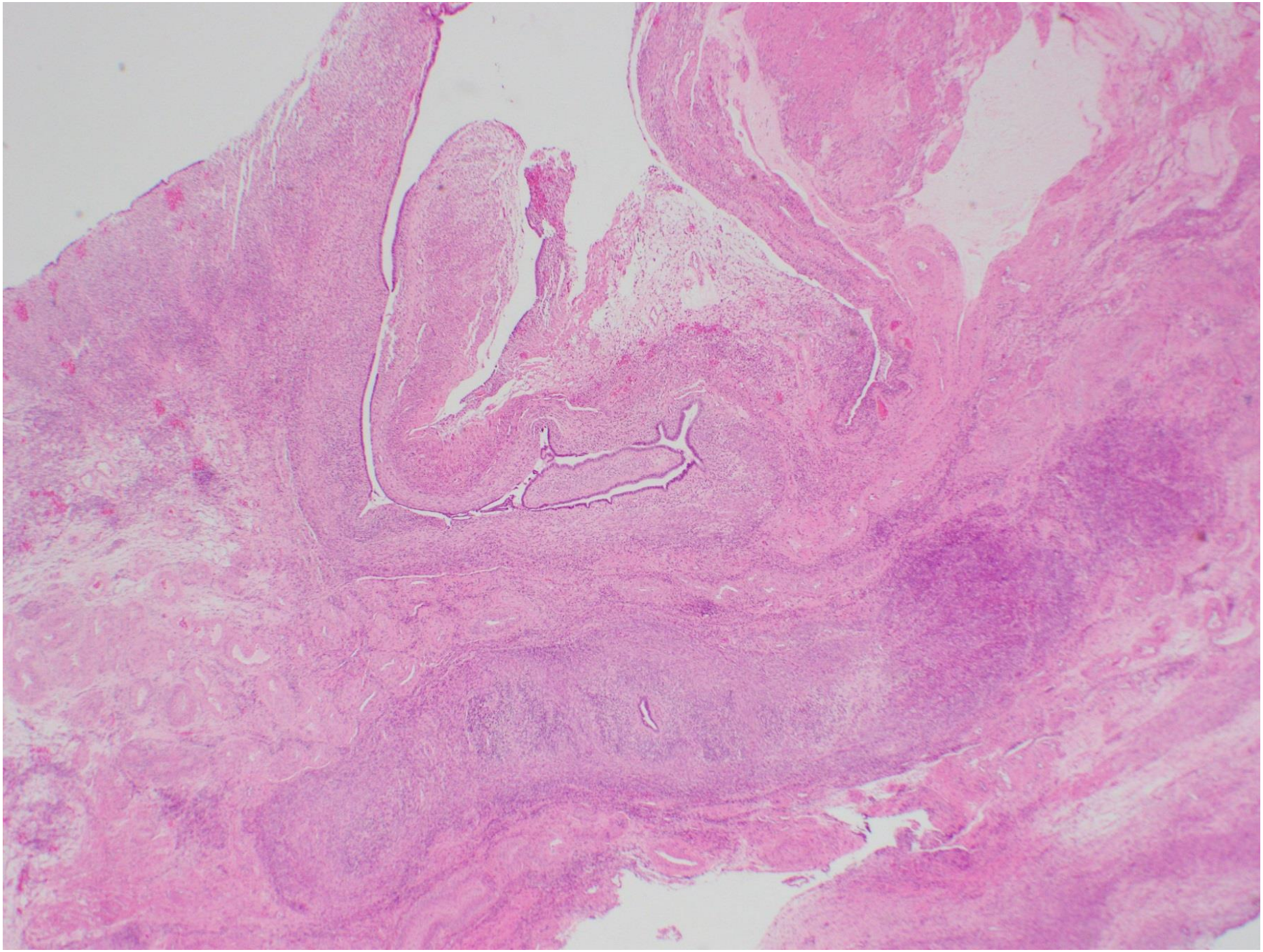

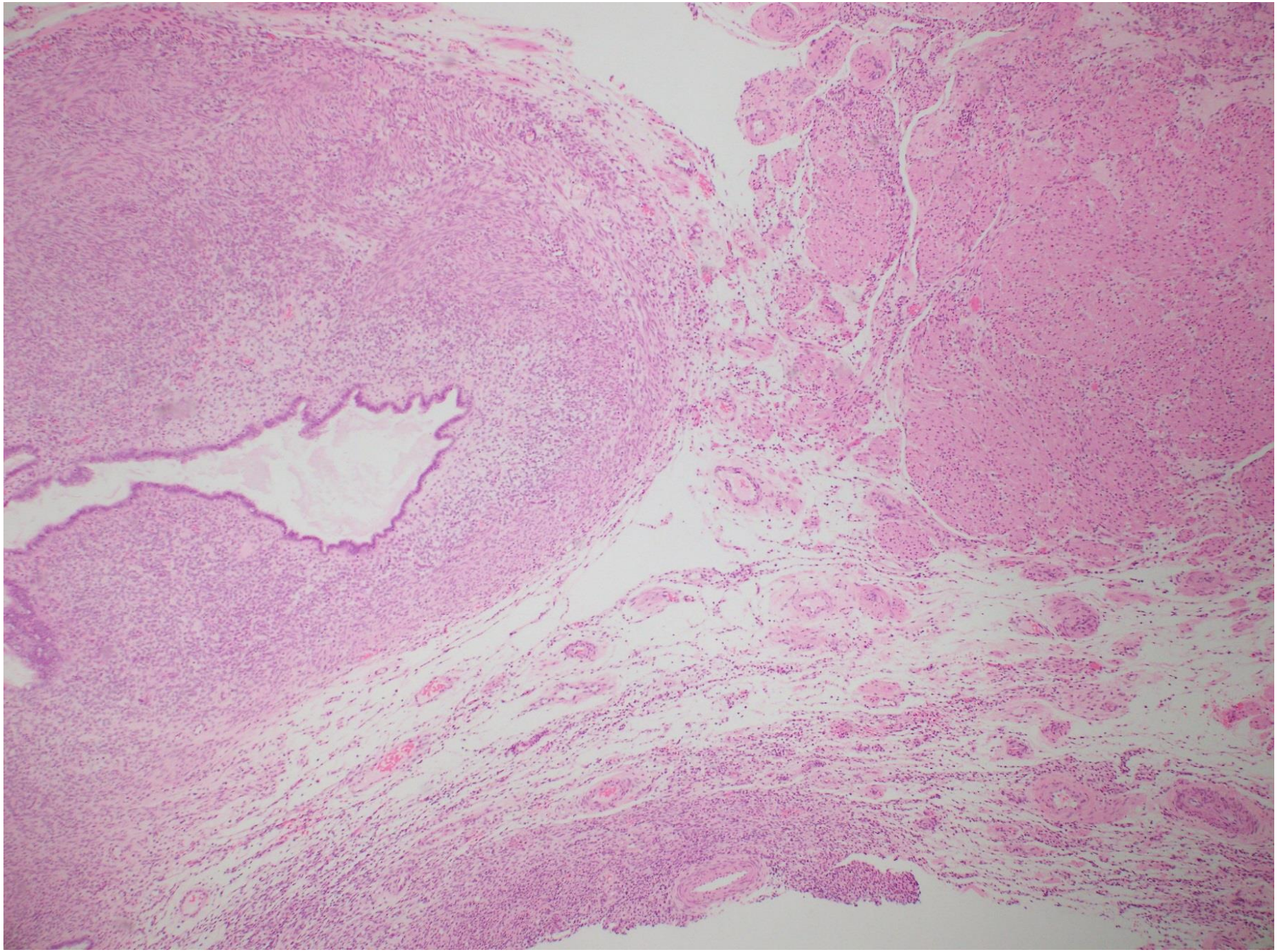

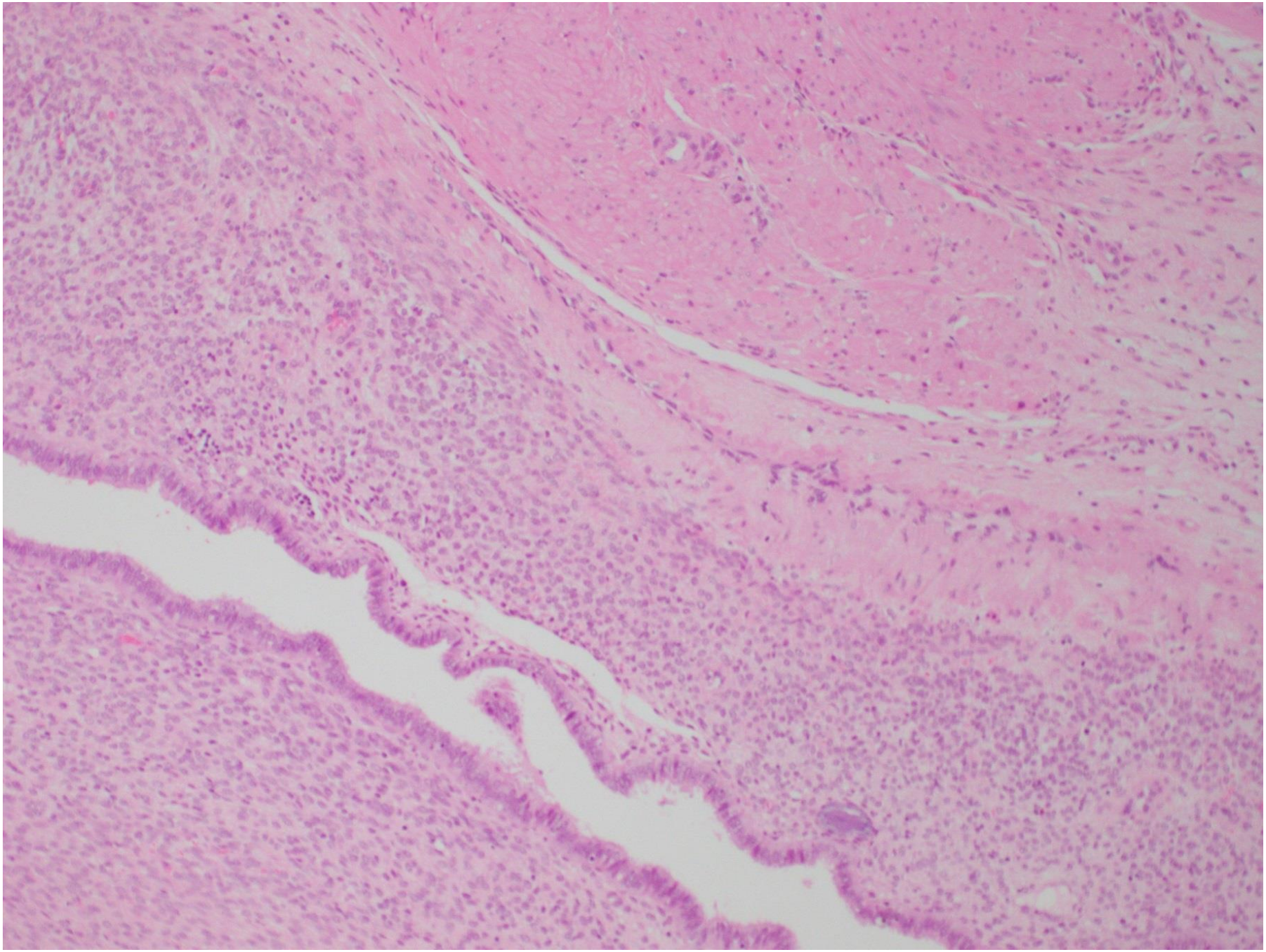

IMMUNOHISTOCHEMISTRY

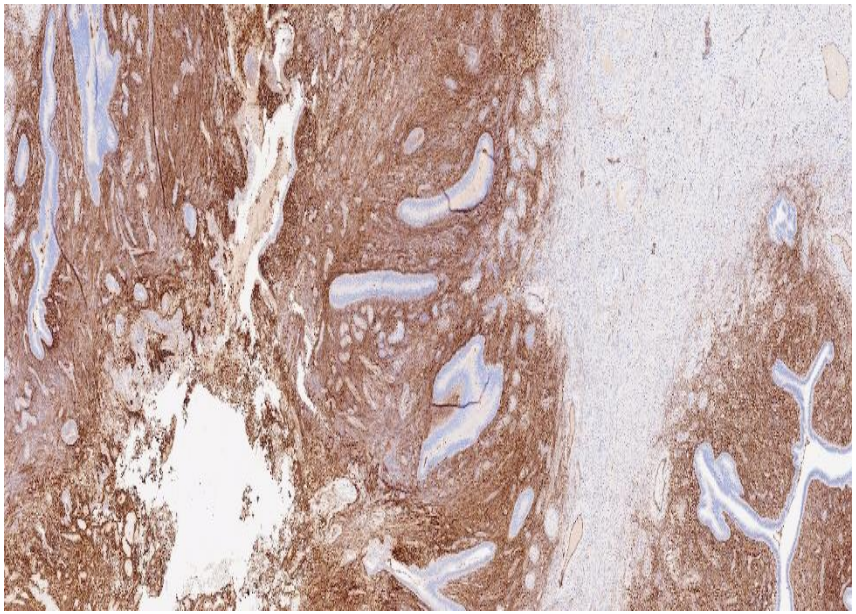

CD10

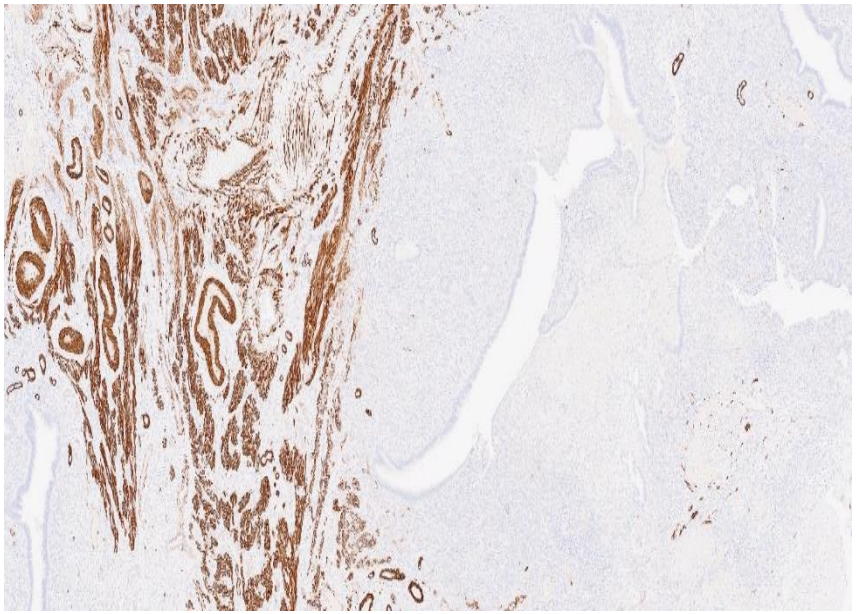

H-caldesmon

PROGESTOGEN TREATMENT OF ATYPICAL HYPERPLASIA (AH) OR ENDOMETRIOID CARCINOMA (EC)

- progestogens now not uncommonly used in management of low-grade (grade 1 or 2) EC or AH
- usually when fertility preservation desired, poor operative risk, “holding” while lose weight
- oral progestogens or IUD or both
- perform MRI by specialist radiologist to try to exclude myoinvasive disease
- discuss at MDT (especially carcinomas)
- good response rate but risk of recurrence, especially if no reduction in BMI (response rate 65-90% for AH; 45-70% for EC)
- may need to stay on progestogens for some time (“slow process”)

MULTIPLE BIOPSIES

- Usually at 3 monthly intervals until normal
- Some guidelines- 2 negative biopsies before taking off progestogens
- In view of risk of recurrence, long-term follow-up with biopsies at 6 or 12 month intervals often undertaken

PMID 17592264

ORIGINAL ARTICLE

Histologic Alterations in Endometrial Hyperplasia and Well-differentiated Carcinoma Treated With Progestins

Darren T. Wheeler, MD, Robert E. Bristow, MD,† and Robert J. Kurman, MD‡*

Abstract: The treatment of complex atypical hyperplasia (CAH) and well-differentiated endometrioid carcinoma (WDC) by progestin therapy has been shown to be a safe alternative to hysterectomy. Accurate assessment for regressive changes induced by the progestins is critical to successful treatment. However, there are few studies detailing the histopathologic changes associated with progestin therapy. A total of 44 patients with CAH or WDC, treated with oral progestins or a progesterone or levonorgestrel-releasing intrauterine device, were followed by endometrial biopsy and/or curettage at 3 to 6 month intervals for a maximum of 25 months. The progestin therapy should be continued for no less than 6 months to accurately assess treatment response. A modified classification for progestin-treated lesions of the endometrium is proposed.

Key Words: endometrial hyperplasia, endometrial carcinoma, endometrioid carcinoma, progestins, progestin therapy, classification of endometrial hyperplasia

(*Am J Surg Pathol* 2007;31:988–998)

ALTERATIONS INDUCED BY PROGESTOGENS

- decrease in glandular crowding and architectural complexity
- decreased nuclear to cytoplasmic ratio
- “induction” of epithelial metaplasias (for example morules, eosinophilic or mucinous metaplasia)
- stromal pseudodecidualisation
- “induction” of surface papillary architecture

SURFACE PAPILLARY CHANGE INDUCED BY PROGESTOGENS

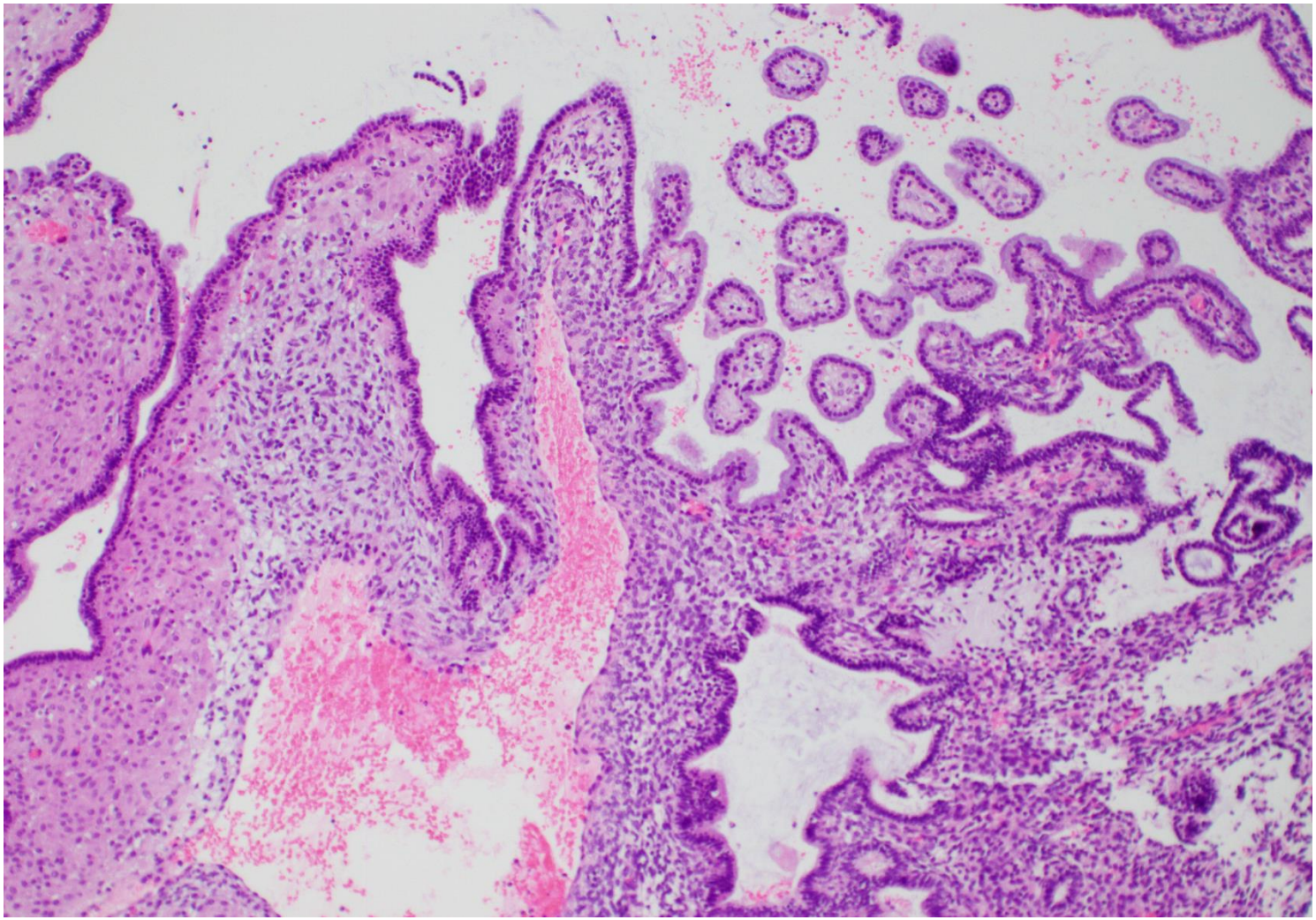

INTERPRETATION AND WORDING OF REPORT DIFFICULT

- easy to report if “normal” progestogen effect
- easy to report if no change or progression
- if abnormal but better- ? persisting hyperplasia, ? responding hyperplasia
- in ideal world, useful to report in conjunction with prior biopsy (often not readily available)
- GUIDANCE ISSUED REGARDING TERMINOLOGY- ISGyP/ BAGP survey

PMID: 33935157

International Journal of Gynecological Pathology
41:142–150, Lippincott Williams & Wilkins, Baltimore
Copyright © 2021 by the International Society of Gynecological Pathologists

Original Article

Survey on Reporting of Endometrial Biopsies From Women on Progestogen Therapy for Endometrial Atypical Hyperplasia/Endometrioid Carcinoma

Raji Ganesan, F.R.C.Path., C. Blake Gilks, M.D., Robert A. Soslow, M.D., and W. Glenn McCluggage, F.R.C.Path.

PMID: 33935157

- Survey showed marked variability in pathological reporting
- On-line digitized cases also revealed marked variability in diagnosis; not surprising since significant interobserver variability in reporting of untreated endometrial hyperplasias

IJGP 2022;41;142-150. PMID: 33935157

TABLE 2. *Morphologic features and treatment implications of the categories provided in the survey*

Category	Morphologic features: glands	Morphologic features: stroma	Treatment implications
Negative for residual hyperplasia/carcinoma	Well-separated, inactive glands Minor glandular Irregularity or dilatation Focal nuclear enlargement that appears reactive or degenerative No cytologic atypia	Stromal decidual change	Treatment has been effective, and can end Follow-up to ensure that there is no recurrence
Residual hyperplasia with treatment effects	Foci of crowded glands and/or papillary architecture. Squamous metaplasia may be prominent No cytologic atypia	Stromal decidual change	Treatment is working but further treatment is needed
Residual atypical hyperplasia with treatment effects	Foci of crowded glands and/or papillary architecture Cytologic atypia present*	Stromal decidual change	Treatment is working but further treatment is needed
Atypical hyperplasia/ endometrioid carcinoma without treatment effects	Atypical hyperplasia/endometrioid carcinoma without stromal decidual change	No stromal decidual change at the site of gland crowding†	The atypical hyperplasia/ endometrioid carcinoma is not responding to progesterone treatment‡
None of the above (describe changes)			

CASE 1-PRE-TREATMENT

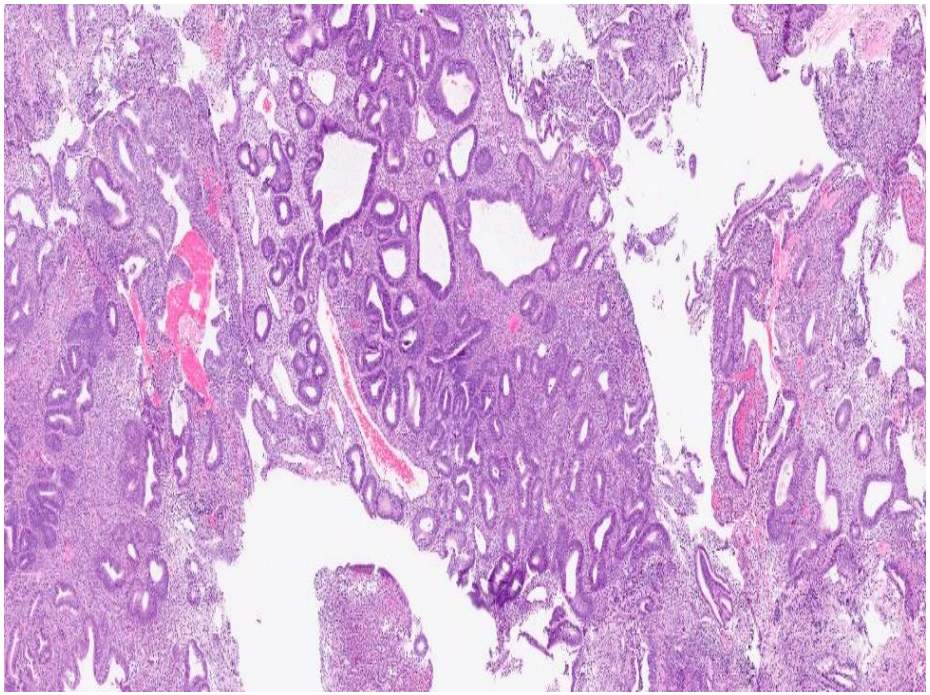

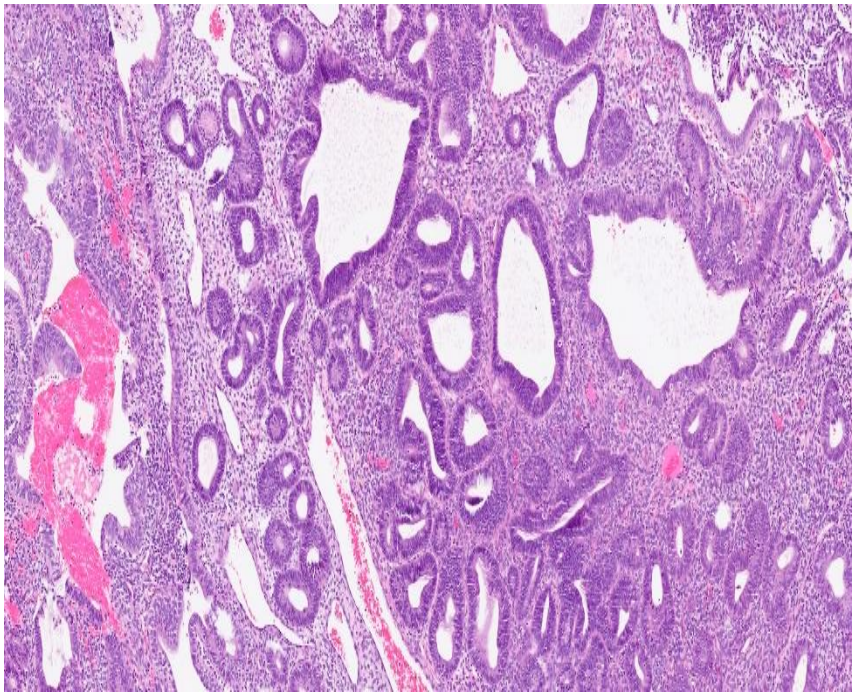

CASE 1- POST-TREATMENT- RESIDUAL HYPERPLASIA WITH TREATMENT EFFECTS

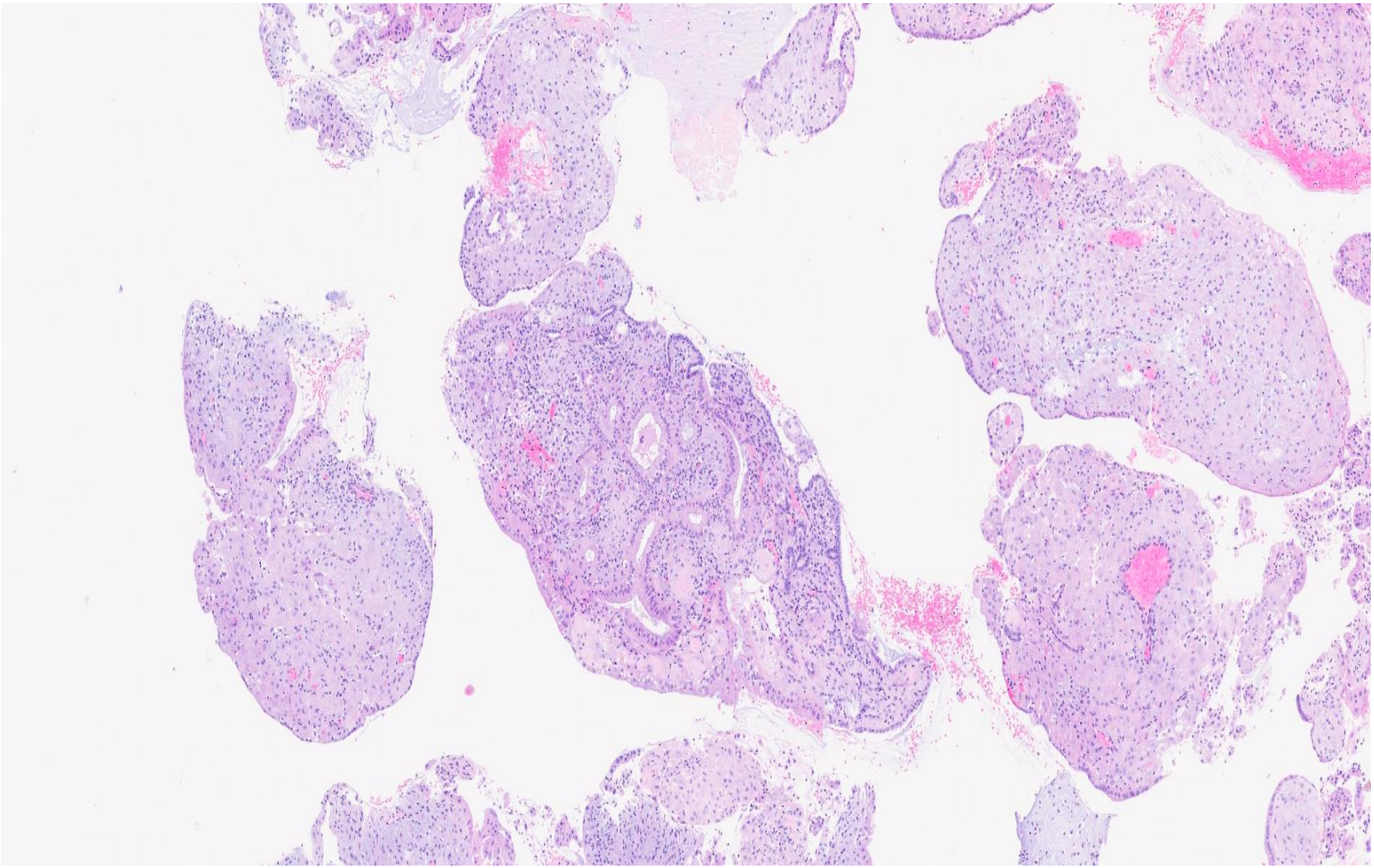

CASE 2- PRE-TREATMENT

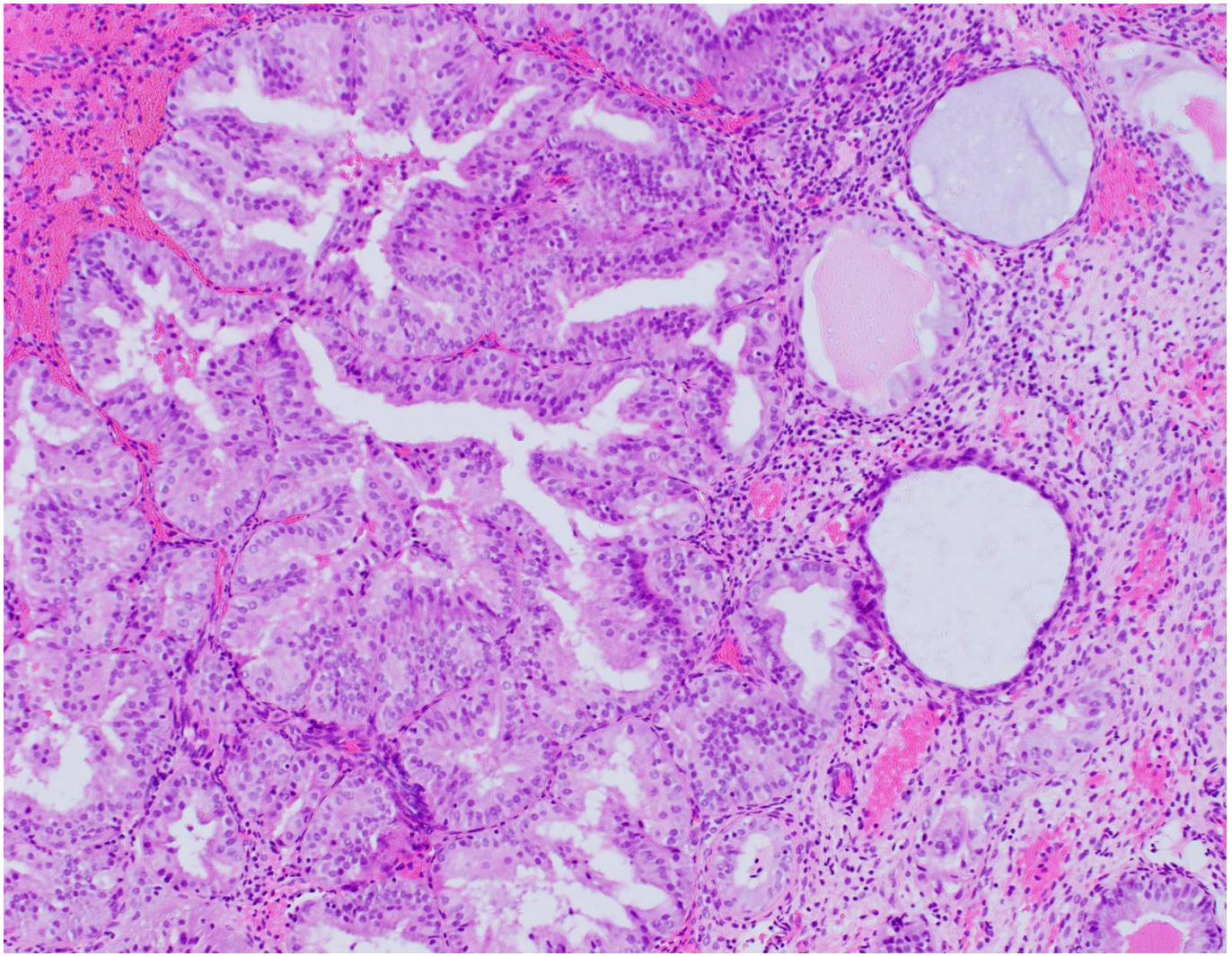

CASE 2- POST-TREATMENT

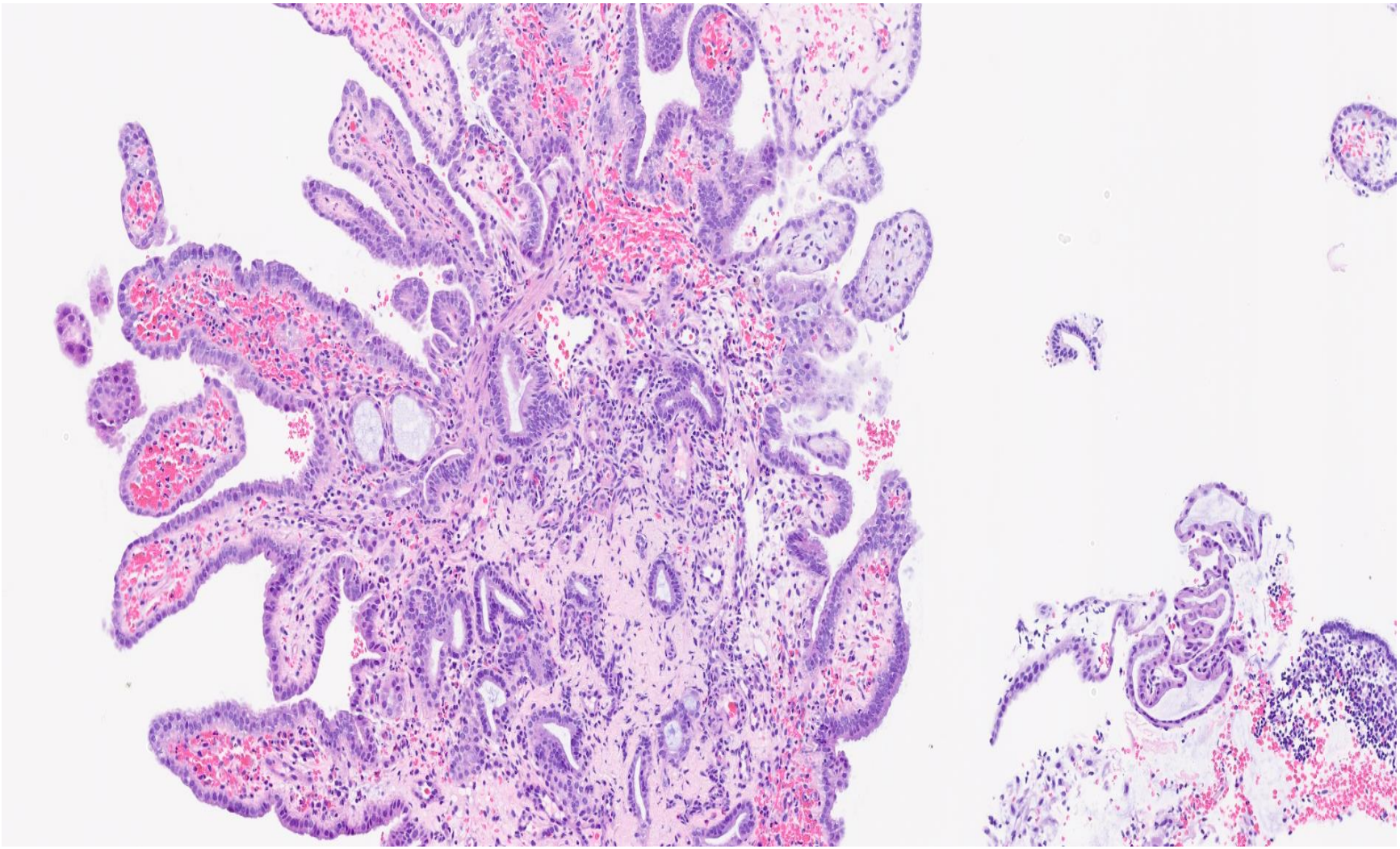

CASE 2-RESIDUAL ATYPICAL HYPERPLASIA WITH TREATMENT EFFECTS

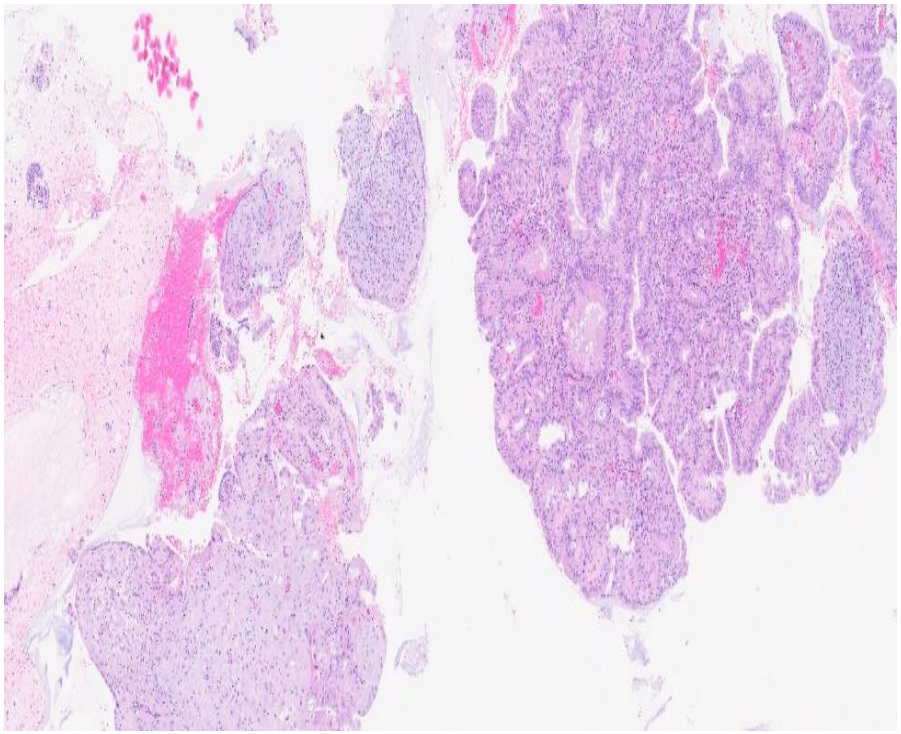

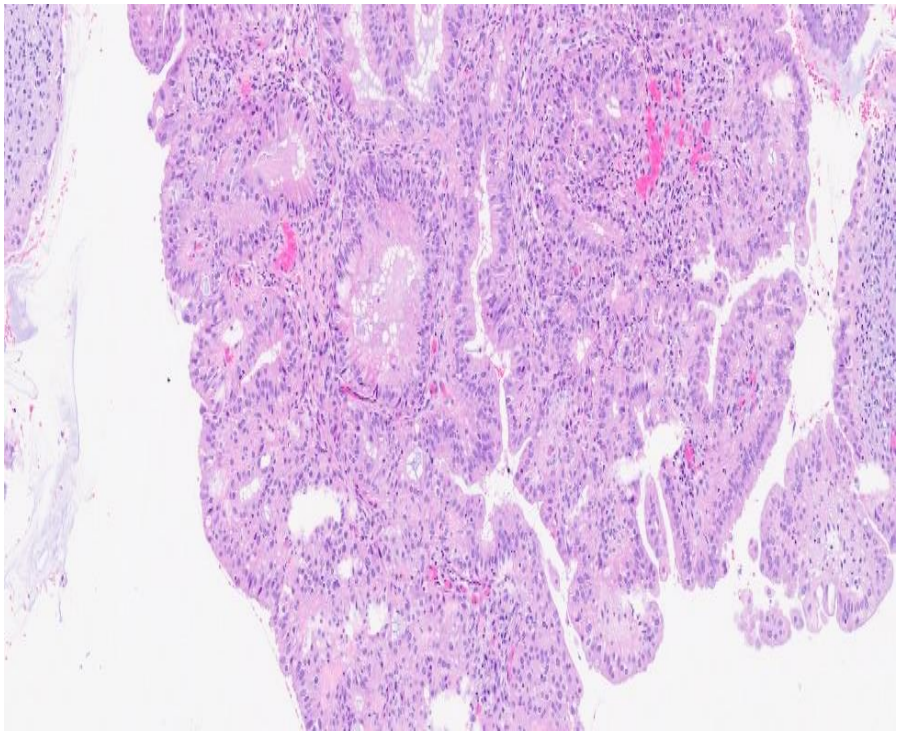

VALUE OF ANCILLARY STUDIES- PMID 34545858

ORIGINAL ARTICLE

OPEN

Reliable Identification of Endometrial Precancers Through Combined Pax2, β-Catenin, and Pten Immunohistochemistry

Mitzi Aguilar, BS, Hao Chen, MD, PhD,* Glorimar Rivera-Colon, MD,* Shuang Niu, MD,* Kelley Carrick, MD,* Katja Gwin, MD,* Ileana C. Cuevas, PhD,* Subhransu S. Sahoo, PhD,* Hao-Dong Li, PhD,* Song Zhang, PhD,†‡ Wenxin Zheng, MD,*‡ Elena Lucas, MD,*‡ and Diego H. Castrillon, MD, PhD*‡*

AJPS 2022: 46: 404-414PMID 34545858

- 111 cases of AH/ EIN
- Aberrant expression of PAX2 (81%), PTEN (51%), beta-catenin (48%)
- Most cases showed aberrant expression of 2 or more markers
- Only 7% of cases showed no aberrant staining with any of these markers
- Useful as adjunct to diagnosis of AH/ EIN
- However, occasional PAX2/ PTEN null glands in normal endometrium (scattered glands)
- May be useful in identifying residual hyperplasia following progestogens since same patterns of immunoreactivity are found following treatment

AJSP 2020:44:1429-1439. PMID 32931681

ORIGINAL ARTICLE

Specific Biomarker Expression Patterns in the Diagnosis of Residual and Recurrent Endometrial Precancers After Progestin Treatment

A Longitudinal Study

Hao Chen, MD, PhD, Elena Lucas, MD,* Amanda L. Strickland, MD,* Kelley Carrick, MD,* Katja Gwin, MD, PhD,* Diego H. Castrillon, MD, PhD,*†‡ Glorimar Rivera-Colon, MD,* Shuang Niu, MD,* Kyle H. Molberg, MD,* and Wenxin Zheng, MD*†‡*

AJSP 2020:44:1429-1439. PMID 32931681

- 265 biopsies (54 patients with history of AH treated with progestogens)
- Morphology review and PTEN/ PAX2 immunohistochemistry
- 89% of original biopsies showed aberrant PTEN and/ or PAX2
- Cases with full pathological response showed normal PTEN/ PAX2
- Cases with recurrent/ persistent AH showed same aberrant pattern of staining as original biopsy
- Cases where morphology was equivocal showed either pattern and aberrant expression was associated with AH on follow-up
- PTEN/ PAX2 immunohistochemistry may be valuable aid in identifying residual AH in post-progestogen biopsies; need to correlate with expression pattern in original biopsy

AJSP 2020:44:1429-1439. PMID 32931681

