The British Association of Gynaecological Pathologists

Lecturer – Mrs Sandie Iles



Advanced Specialist BMS in Gynaecology based at Charing Cross Hospital. I am currently within stage D of my training, portfolio submitted.
I am the dissection training lead for advanced BMS and Resident Doctors.

The British Association of Gynaecological Pathologists

Mock Exam

- Mrs Sandie Iles
- North West London Pathology, Imperial College Healthcare Trust

- 25 September 2024

The British Association of Gynaecological Pathologists

The Exam:

- Half Day:
  - Long cases 1-4
  - OSPE 1: Verbal

- Full Day:
  - Short cases 1-10
  - Short cases 11-20
  - Macros: 1-4
    - Macros: Verbal
  - OSPE 2: Written



The British Association of
Gynaecological Pathologists

Preparation for the exam:

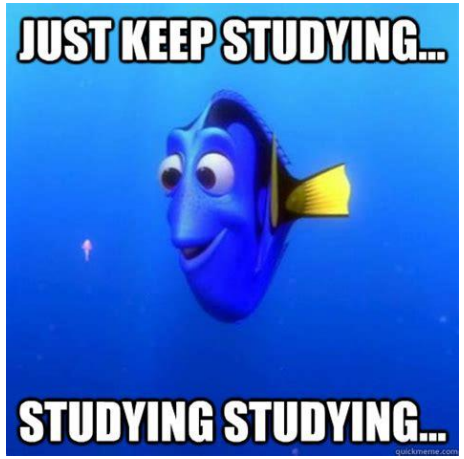

- Reading is important for knowledge But don't forget slide reviews
- Learn the best learning method for you = Don't try and follow what someone else does
- Teach: Dissection and microscopy to BMS and Resident Dr's
- Use your daily workload: When reporting, talk with your Pathologists about associations/ molecular… etc.
- Testing: Timed and hand write
- Don't panic: You do have time to breath……. Have a night off!

The British Association of Gynaecological Pathologists

Hints and Tips:

- Arrive at the time stated on day 1:
  - They don't allow you in before that
  - They have already included lots of set up time
  - Bring your own brain foods (they supply food and drinks but not M&M's or Irn Bru)

- Microscope:
  - Keep inside overnight
  - Take your own H&E slide to check the set up
  - Take: Lens cloth, extra bulb, power cord

- Don't Panic in the verbal sections:
  - If they stop you talking
  - Ask more questions
  - If they ask are you sure?



The British Association of Gynaecological Pathologists

Hints and Tips, Continued….

- Long and Short cases:
  - Read the clinical details, they may not spell something out but may point to it
  - Be safe: You may not be able to give a definitive diagnosis
  - Follow a structure:
    - IHC: Tables are best BUT Must give what this means not just Positive / Negative
    - Don’t waffle, succinct is best. (Your hand will thank you)

- Don’t assume:
  - It may be a benign entity: E.g. deciduosis. Or is it endometriosis with decidual change
  - There may be 2 pathologies
  - IHC: Don’t think this will be a normal panel. They may just be a selection of markers

- Any problem: RAISE! (Before you’ve began to panic)



The British Association of Gynaecological Pathologists

Thank You

- Any Questions?

