The British Association of Gynaecological Pathologists

Masterclass with the Experts in Collaboration with ISGyP 4th June 2025

Practical Issues in Reporting Vulval Biopsies

Dr Karen Talia
The Royal Women's and the Royal Children's Hospital
Melbourne
Australia

4th June 2025

The British Association of Gynaecological Pathologists

Speaker disclosures

- ❑ I have no financial conflicts of interest to disclose

Case 1

55yo

Clinical history:

Vulval plaque, “?VIN”.

No information regarding underlying dermatosis, HPV status.

Procedure:

Wide local excision.

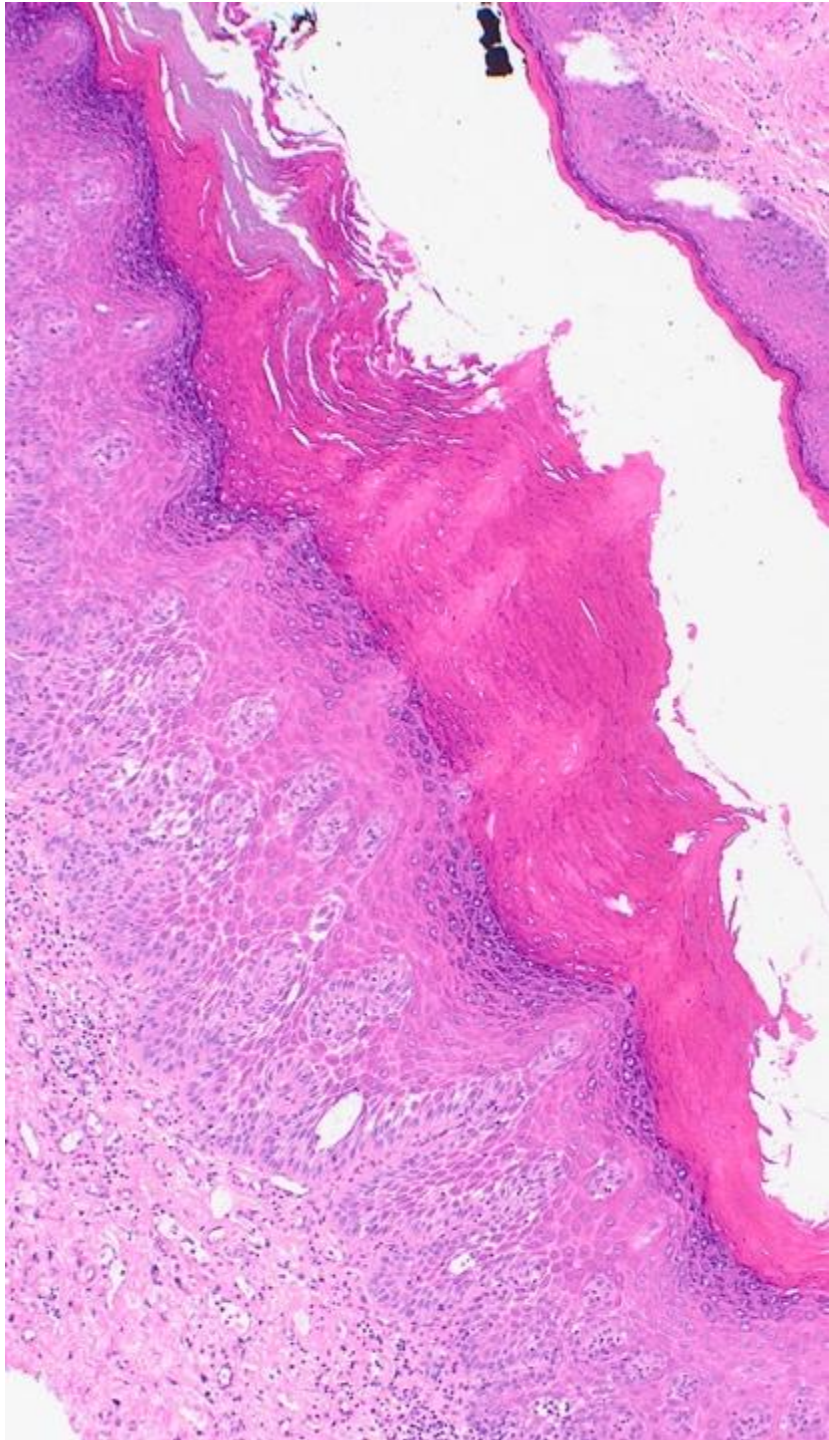

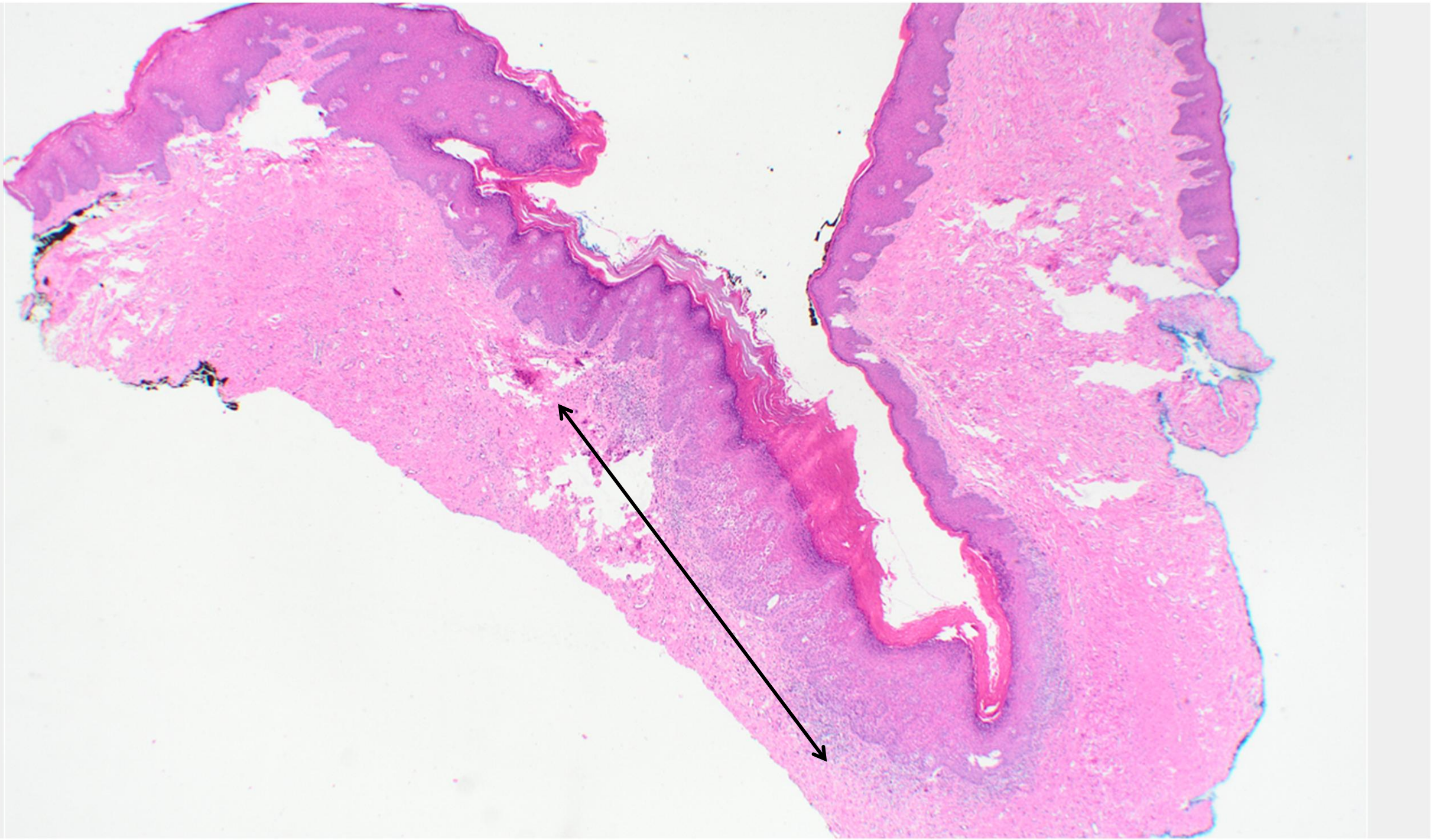

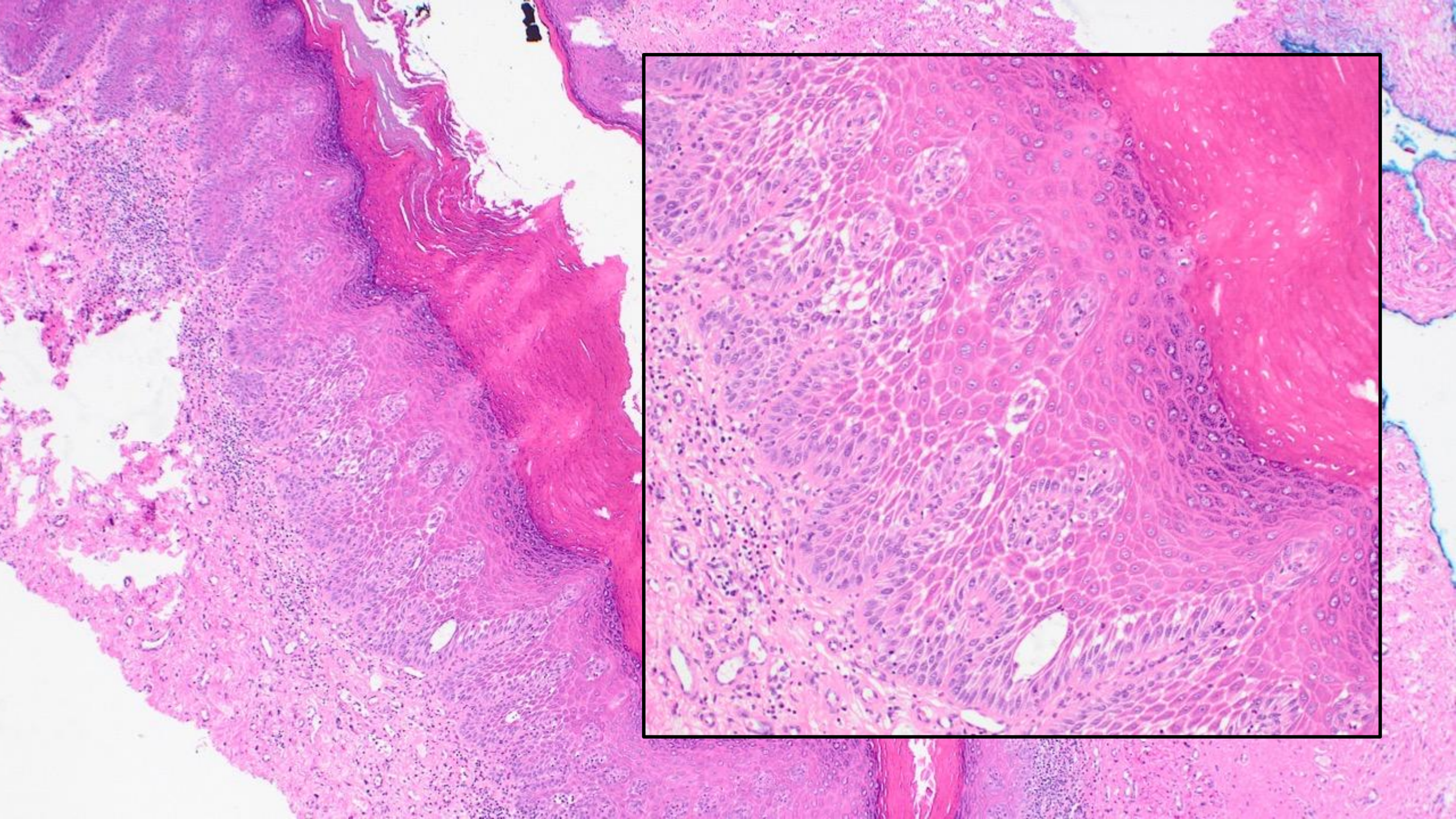

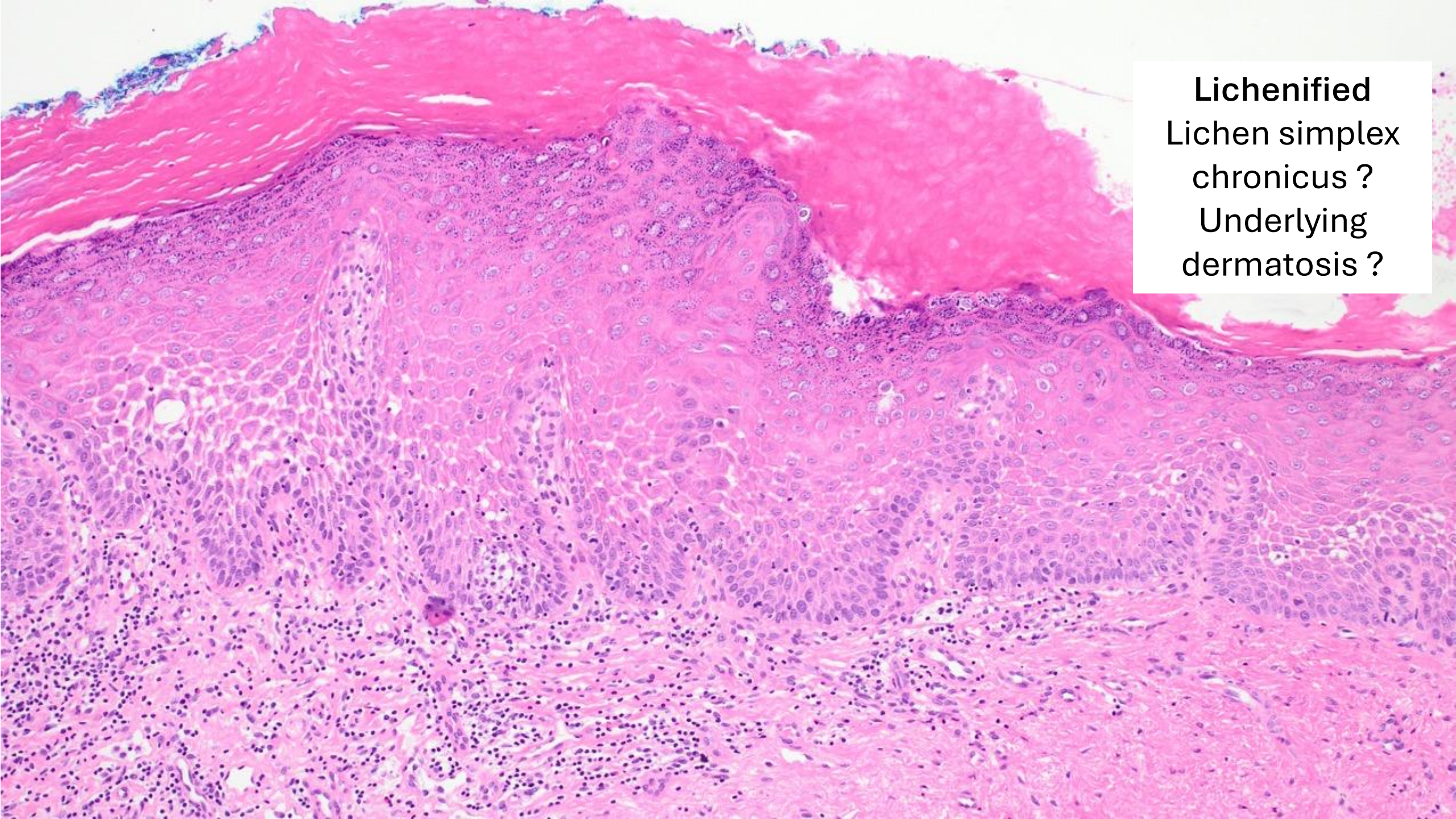
Lichenified
Lichen simplex chronicus ?
Underlying dermatosis ?

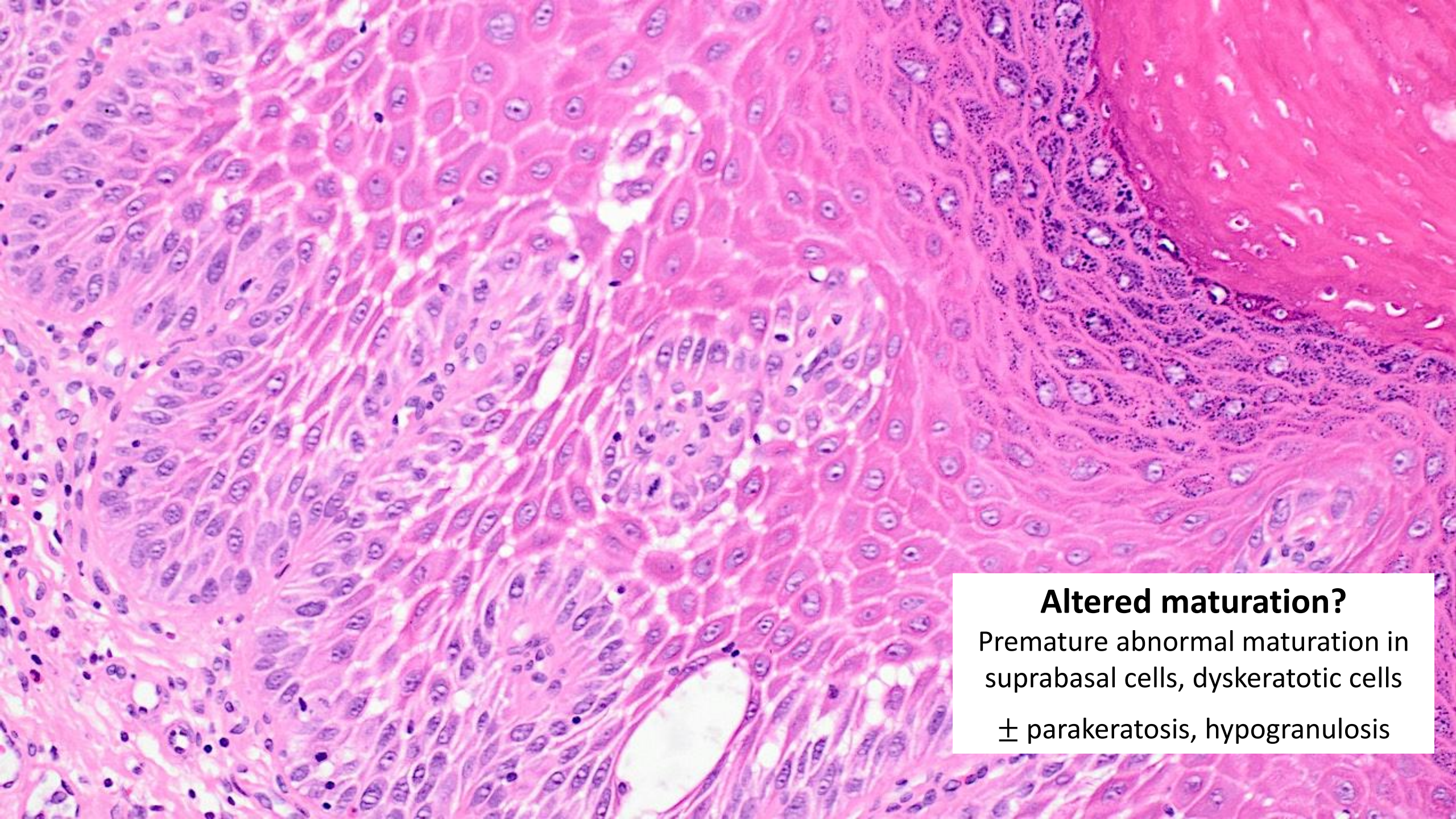
Altered maturation?
Premature abnormal maturation in suprabasal cells, dyskeratotic cells
± parakeratosis, hypogranulosis

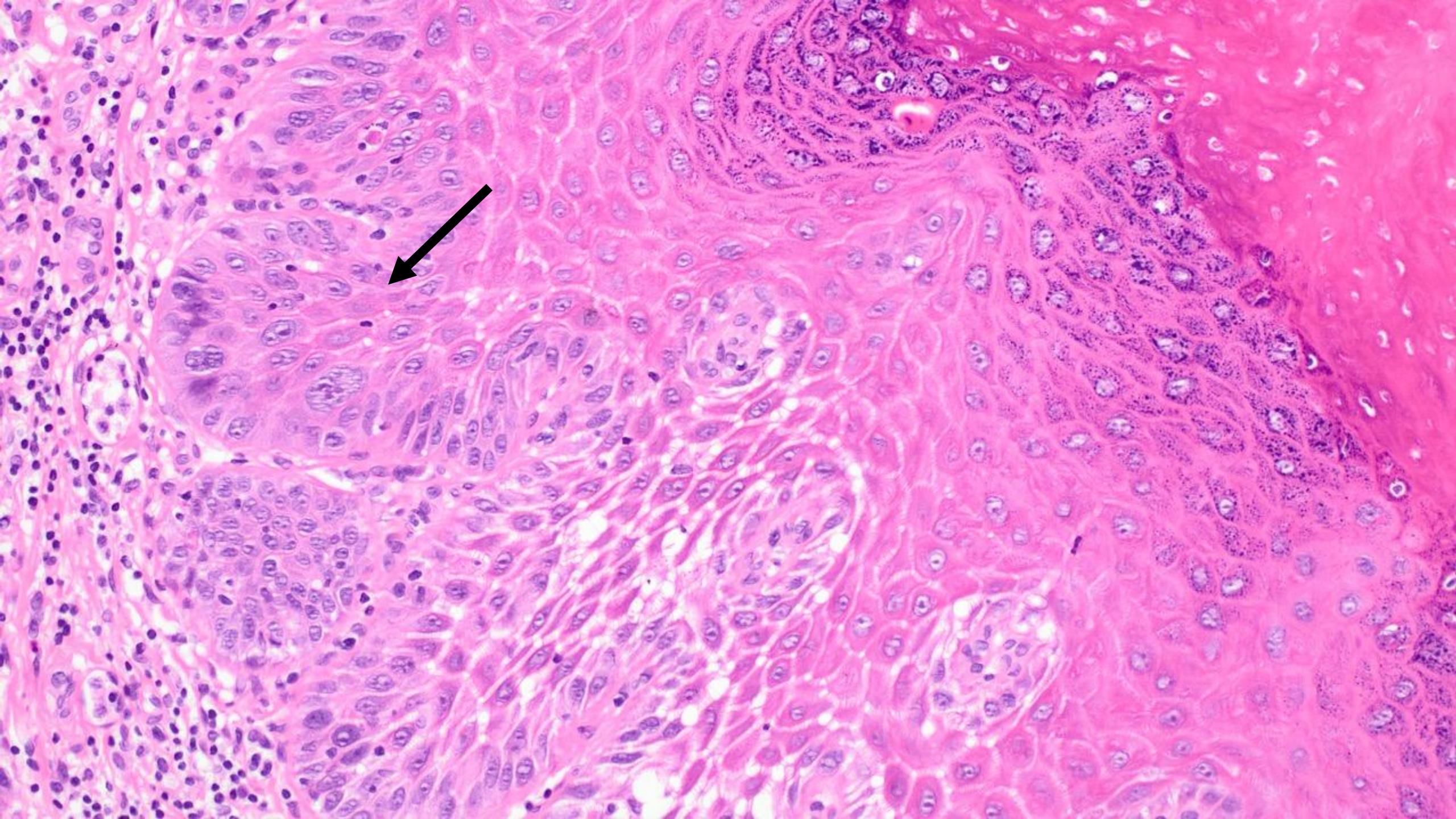

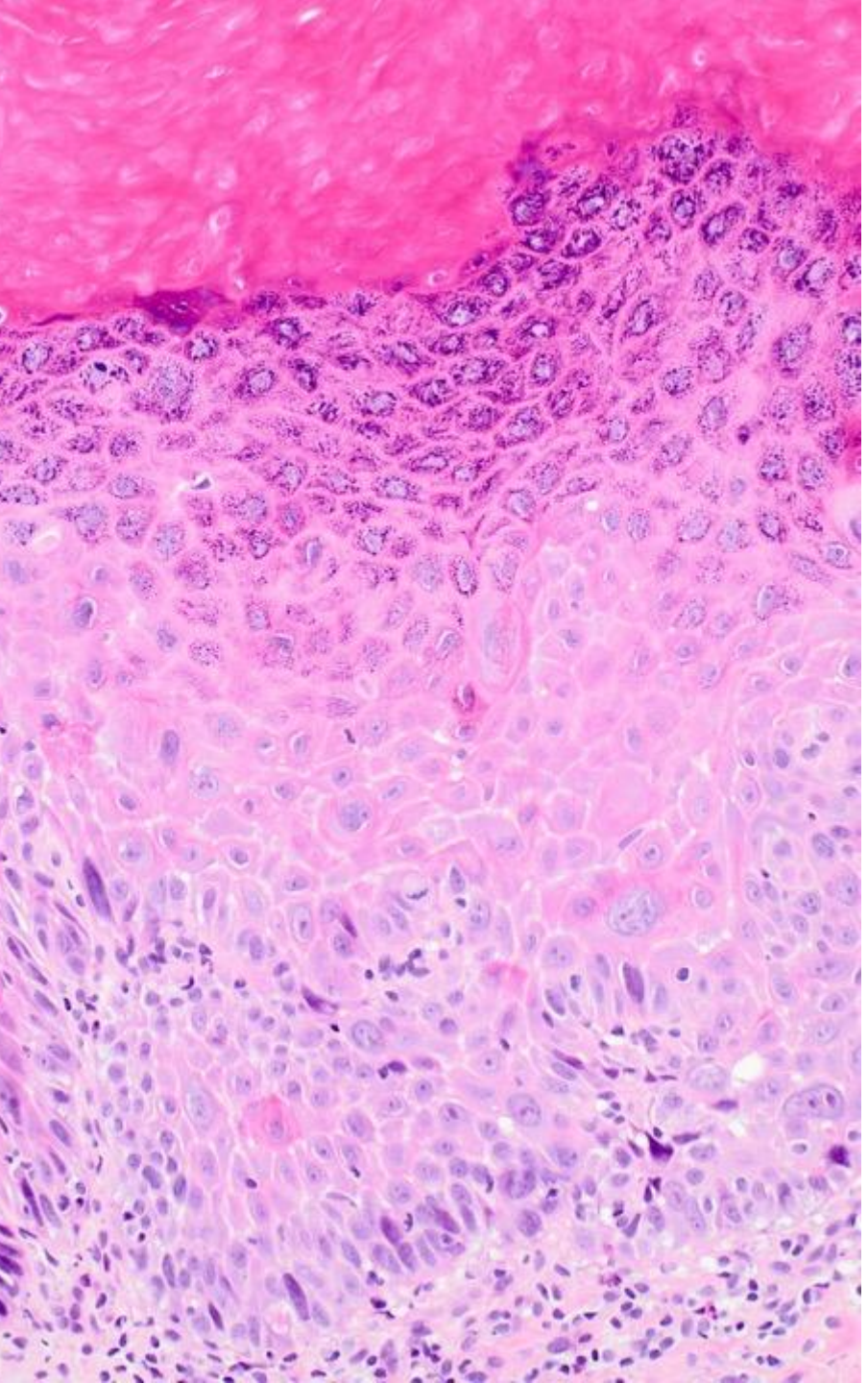

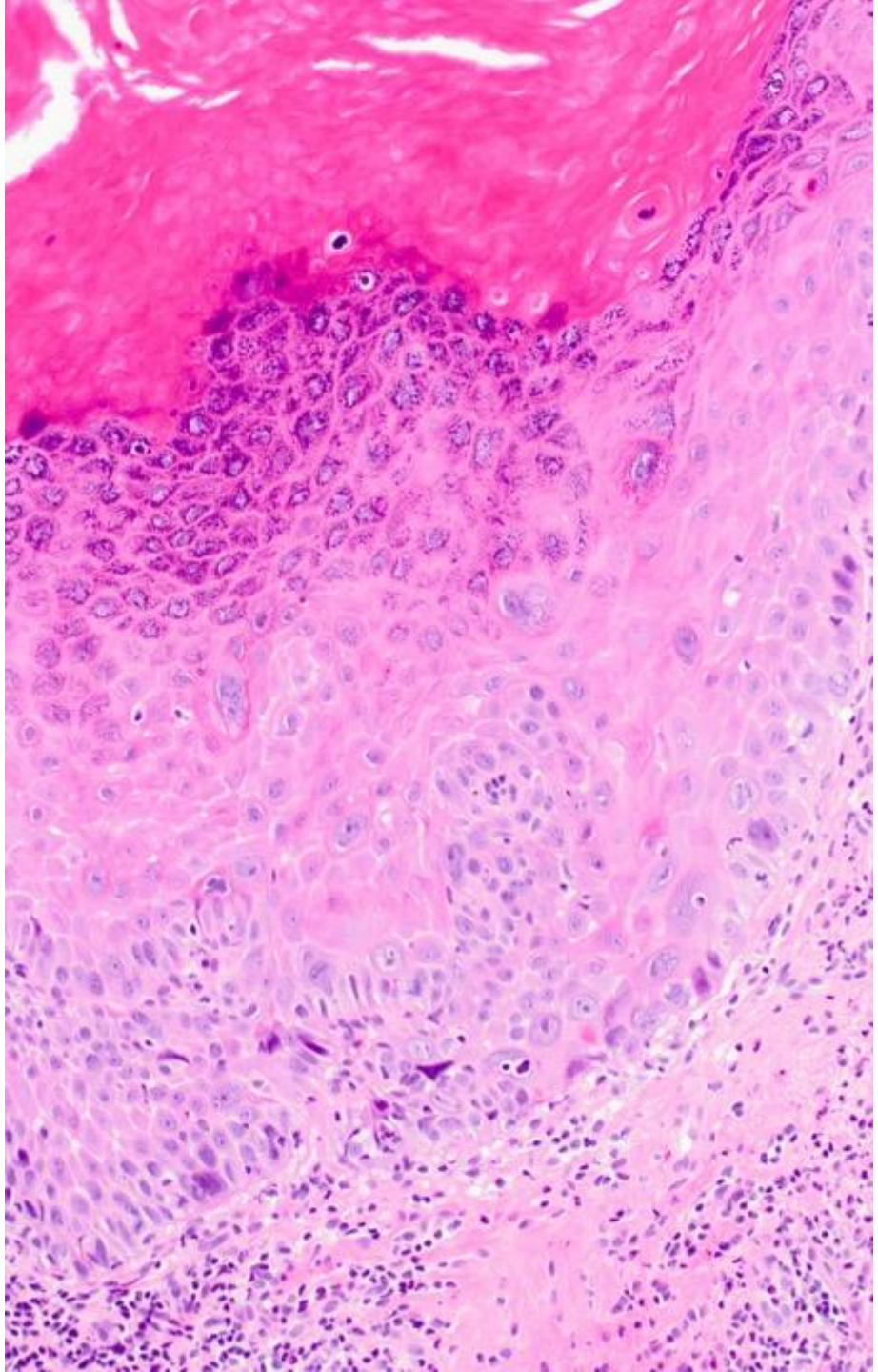

Clinically “?VIN”
Lichenified
Altered maturation
Spongiosis
Lower zone atypia

?Hypertrophic dVIN

Next step:
p16 and p53 IHC

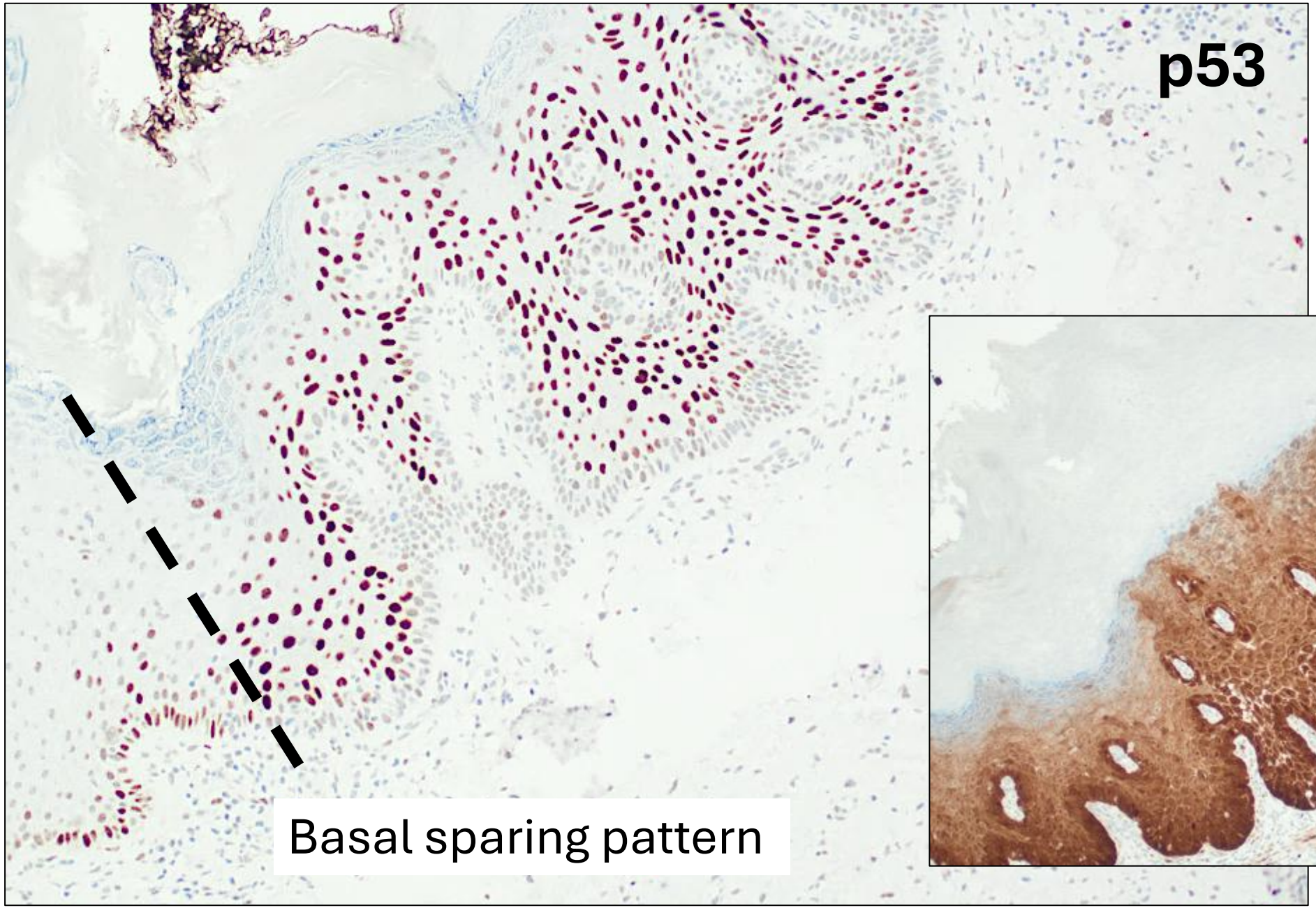

Diagnosis:
HPVA VIN, superimposed LSC

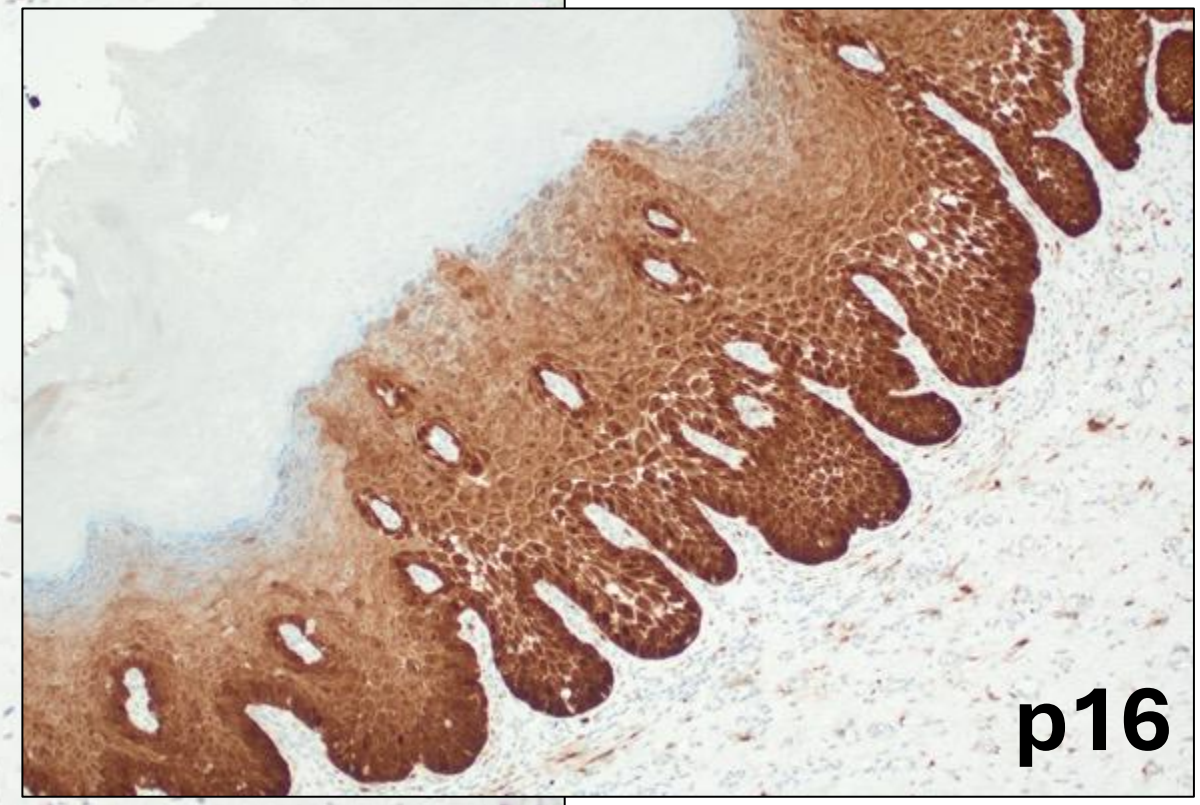

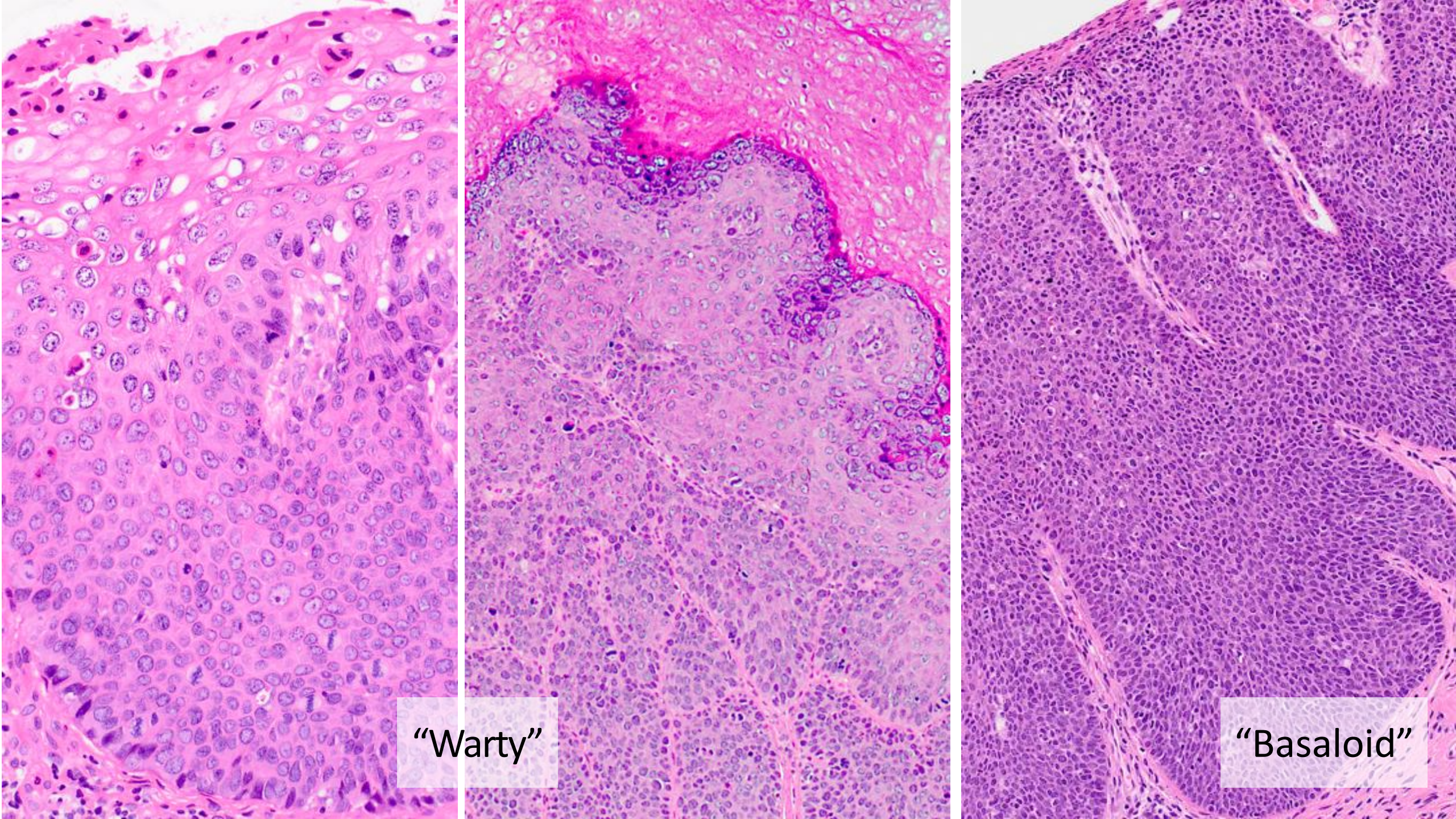
“Warty”
“Basaloid”

HPVA VIN with superimposed LSC - “dVIN-like"

Differentiated Vulvar Intraepithelial Neoplasia-like and Lichen Sclerosus-like Lesions in HPV-associated Squamous Cell Carcinomas of the Vulva

Natalia Rakislova, MD, Laia Alemany, MD, PhD,†‡ Omar Cuevero, MD,†‡ Marta del Pino, MD, PhD,§ Adela Saco, MD, PhD,* Beatriz Quirós, BSc,†‡ Belen Lloveras, MD, PhD,‖ Maria Alejo, MD, PhD,¶ Gordana Halec, MD, PhD,# Wim Quint, MD, PhD,** Silvia de Sanjosé, MD, PhD,†‡ Jaume Ordi, MD, PhD,* and on behalf of VVAP study group*

Classic Vulvar Intraepithelial Neoplasia With Superimposed Lichen Simplex Chronicus: A Unique Variant Mimicking Differentiated Vulvar Intraepithelial Neoplasia

Jaclyn C. Watkins, M.D., M.S., Eric Yang, M.D., Ph.D., Christopher P. Crum, M.D., Michael Herfs, Ph.D., Tarik Gheit, Ph.D., Massimo Tommasino, Ph.D., and Marisa R. Nucci, M.D.



Uniform hyperchromasia basal third
Conspicuous atypia
Less cytoplasmic maturation

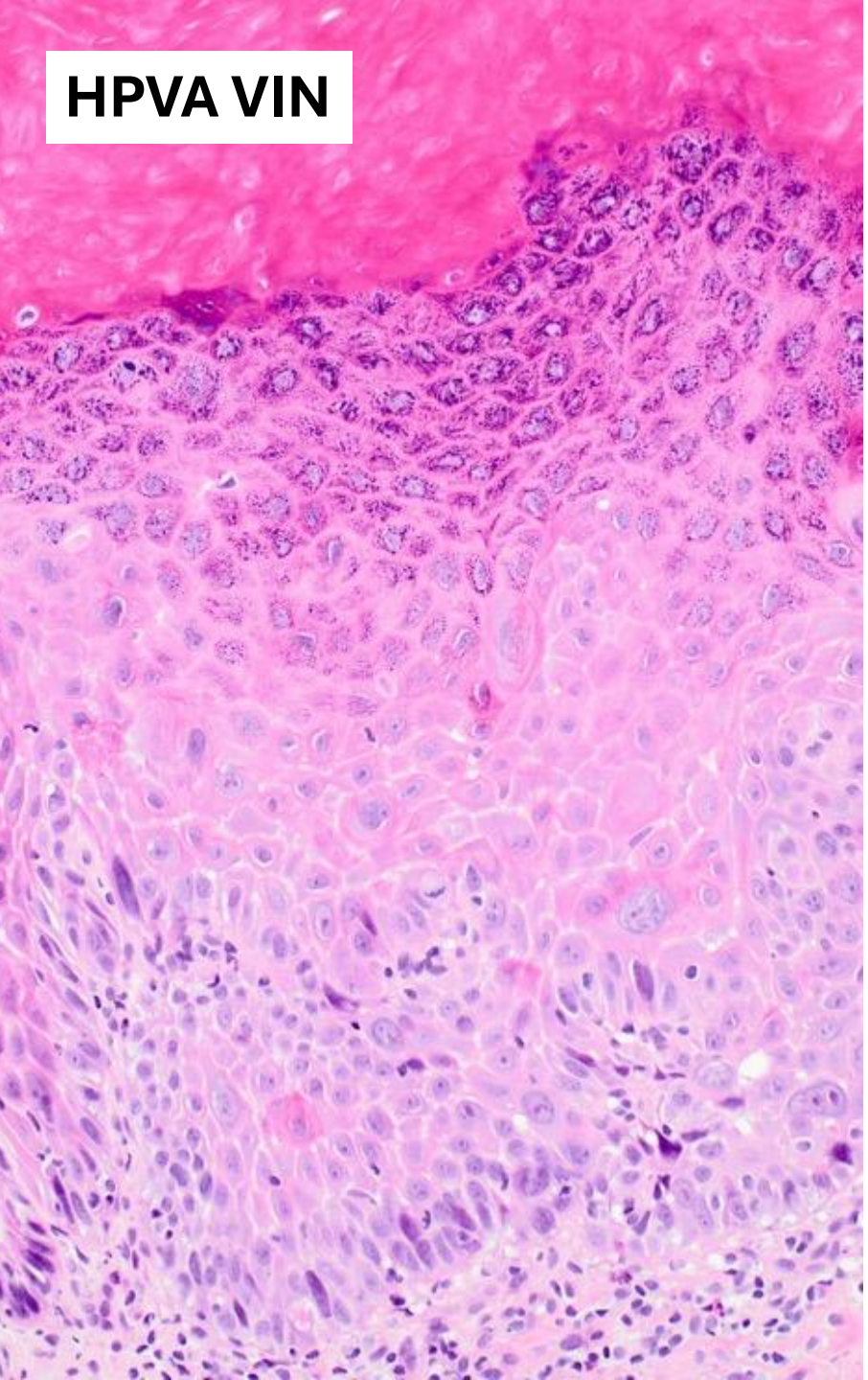

Any new diagnosis of VIN, even if morphology looks typical for HPVA /HPVI, perform p16 and p53

ICCR has endorsed routine use of p16 and p53 in SCC vulva – classification, prognosis

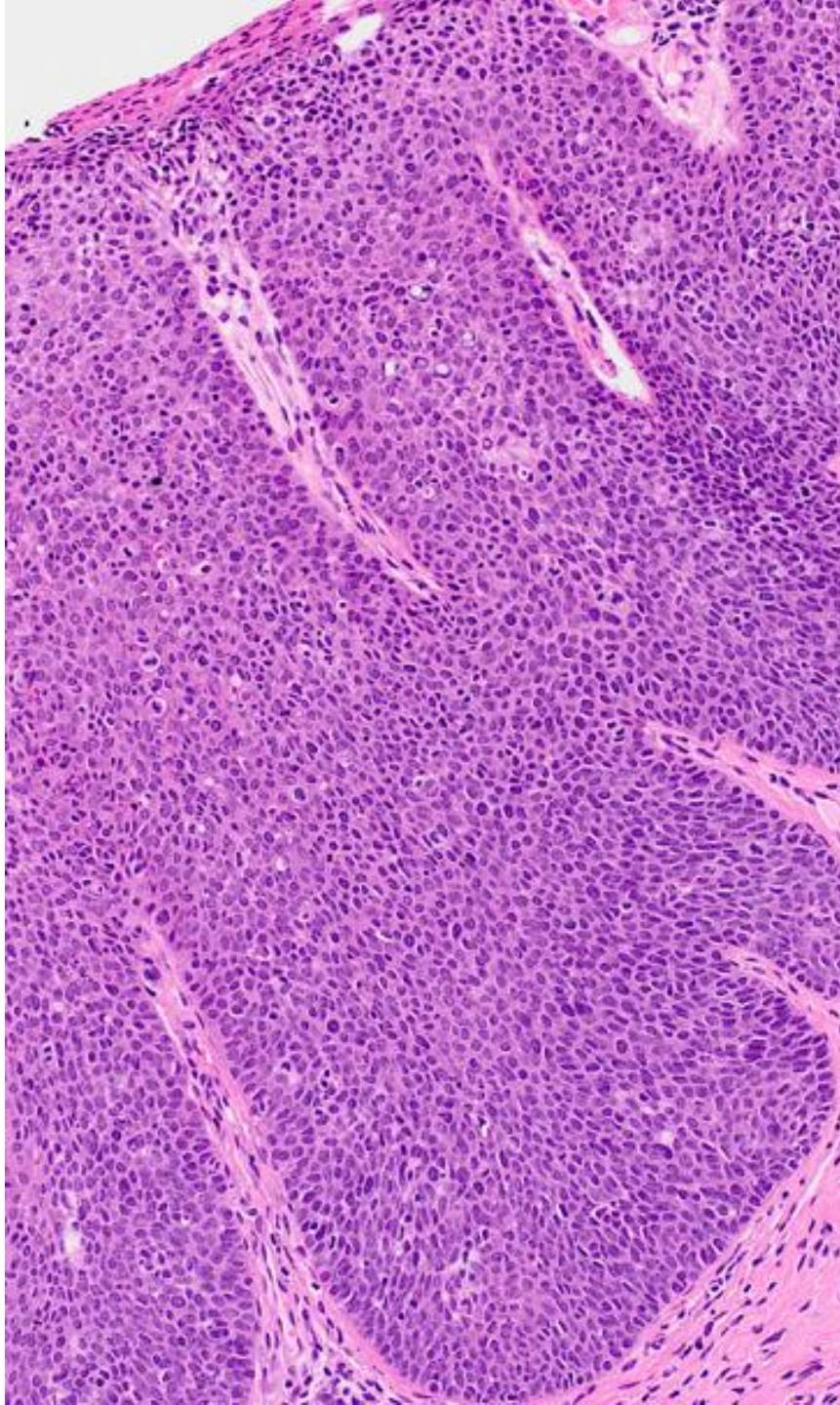

Morphological mimicry in squamous precursors

Original Article

Classic Vulvar Intraepithelial Neoplasia With Superimposed Lichen Simplex Chronicus: A Unique Variant Mimicking Differentiated Vulvar Intraepithelial Neoplasia

Jaclyn C. Watkins, M.D., M.S., Eric Yang, M.D., Ph.D., Christopher P. Crum, M.D., Michael Herfs, Ph.D., Tarik Gheit, Ph.D., Massimo Tommasino, Ph.D., and Marisa R. Nucci, M.D.

IJGP 2018

HPV-negative Vulvar Intraepithelial Neoplasia (VIN) With Basaloid Histologic Pattern

An Unrecognized Variant of Simplex (Differentiated) VIN

Ordi, Jaume MD*; Alejo, Maria MD†; Fusté, Victòria MD*; Lloveras, Belen MD‡; del Pino, Marta MD§; Alonso, Immaculada MD§; Torné, Aureli MD§

AJSP 2009

Differentiated Vulvar Intraepithelial Neoplasia-like and Lichen Sclerosus-like Lesions in HPV-associated Squamous Cell Carcinomas of the Vulva

Natalia Rakislova, MD, Laia Alemany, MD, PhD,†‡ Omar Clavero, MD,†‡ Marta del Pino, MD, PhD,§ Adela Saco, MD, PhD,* Beatriz Quirós, BSc,†‡ Belen Lloveras, MD, PhD,‖ Maria Alejo, MD, PhD,¶ Gordana Halec, MD, PhD,# Wim Quint, MD, PhD,** Silvia de Sanjosè, MD, PhD,†‡ Jaume Ordi, MD, PhD,* and on behalf of VVAP study group*

AJSP 2018

HPV-independent Precursors Mimicking High-grade Squamous Intraepithelial Lesions (HSIL) of the Vulva

Natalia Rakislova, MD, PhD, Laia Alemany, MD, PhD,†‡ Omar Clavero, MD,†‡ Marta del Pino, MD, PhD,§ Adela Saco, MD, PhD,* Lorena Marimon, BSc,* Beatriz Quirós, BSc,†‡ Belen Lloveras, MD, PhD,‖ Inmaculada Ribera-Cortada, MD, PhD,* Maria Alejo, MD, PhD,¶ Michael Pawlita, MD,# Wim Quint, MD, PhD,** Silvia de Sanjose, MD, PhD,†‡ and Jaume Ordi, MD, PhD;*‡ On Behalf of VVAP Study Group*

AJSP 2020

2-4% of HSIL mimic dVIN/LS

Up to 1 in 5 HPVI VIN mimics HSIL **"HSIL-like"** basaloid morphology

HPV-independent Precursors Mimicking High-grade Squamous Intraepithelial Lesions (HSIL) of the Vulva

Natalia Rakislova, MD, PhD, Laia Alemany, MD, PhD,†‡ Omar Clavero, MD,†‡ Marta del Pino, MD, PhD,§ Adela Saco, MD, PhD,* Lorena Marimon, BSc,* Beatriz Quirós, BSc,†‡ Belen Lloveras, MD, PhD,‖ Inmaculada Ribera-Cortada, MD, PhD,* Maria Alejo, MD, PhD,¶ Michael Pawlita, MD,# Wim Quint, MD, PhD,** Silvia de Sanjose, MD, PhD,†‡ and Jaume Ordi, MD, PhD;*‡ On Behalf of VVAP Study Group*

AJSP 2020

HPV DNA, p16, p53 on all

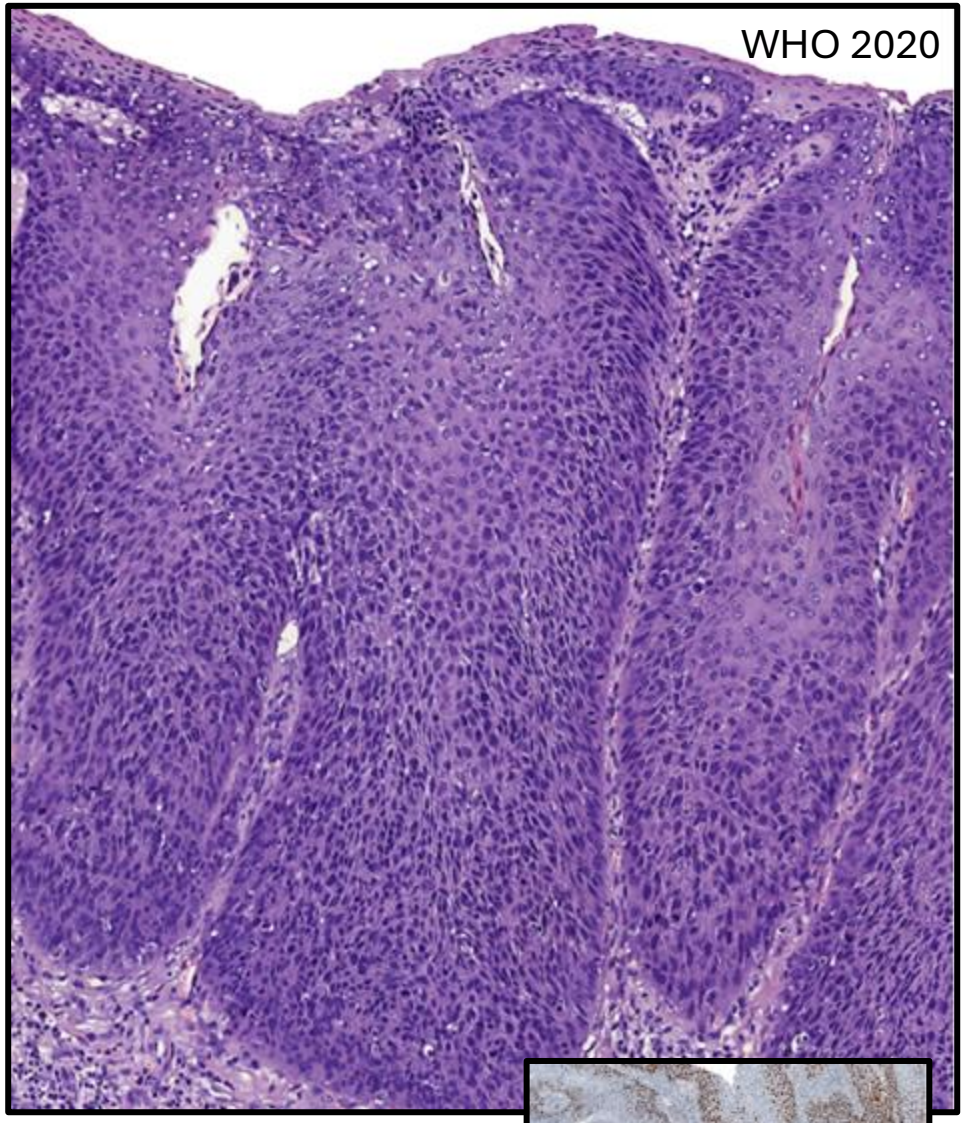

254 HPVI SCC with adjacent VIN

18% HSIL-like

10% basaloid, 5% “warty”, 3% mixed; mean 72y

74% p53abn - Most basaloid dVIN **but not all**

Some HSIL-like VIN was HPVI p53wt

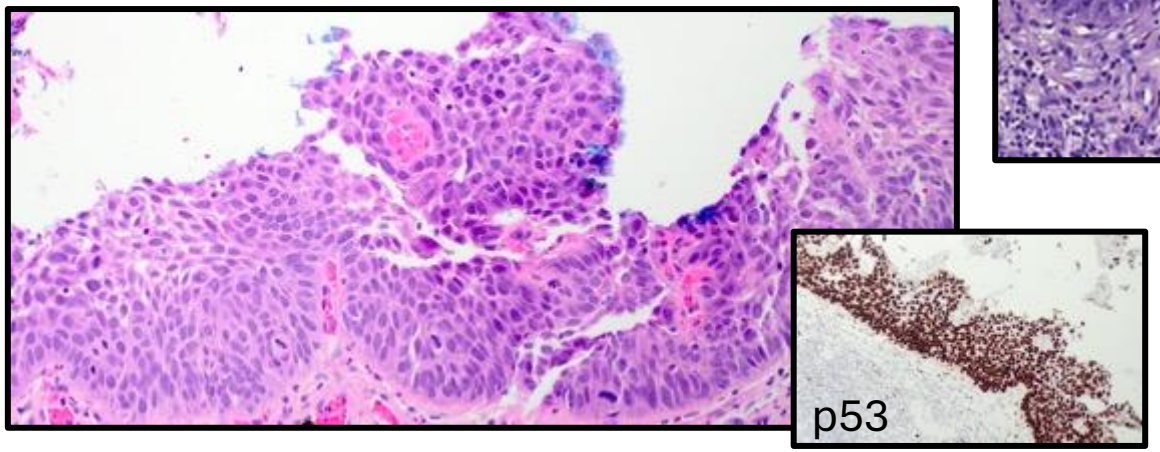



Why this matters: VIN progression risk



Histopathology

Histopathology 2024, 84, 301–314. DOI: 10.1111/his.15050

High-grade vulvar intraepithelial neoplasia: comprehensive characterization and long-term vulvar carcinoma risk

Nikki B Thuijs,[1,2] Marc van Beurden,[3] Sylvia Duin,[1,2] Daniëlle A M Heideman,[1,2,4] Johannes Berkhof,[5] Renske D M Steenbergen[1,2] & Maaike C G Bleeker[1,2]

n=751, p16, p53, ki67, HPV DNA

10-year cancer risk (SCC): **8%** for HPVA HSIL

28% for HPVI p53wt VIN

67% for HPVI p53abn VIN→

74% basaloid
39% differentiated

Median progression time: **6 yrs** for HSIL

5 yrs for HPVI p53wt VIN

1.5 yrs for HPVI p53abn VIN – **0.5 yrs** HSIL-like

Histopathology

Histopathology 2023, 82, 731–744. DOI: 10.1111/his.14860

Vulvar squamous cell carcinoma arising on human papillomavirus-independent precursors mimicking high-grade squamous intra-epithelial lesion: a distinct and highly recurrent subtype of vulvar cancer

Carreras-Dieguez, Rakislova

26 HPVA SCC with HSIL
54 HPVI SCC with dVIN
25 HPVI SCC with “HSIL-like” VIN
p16, p53, HPV DNA
Similar rates margin involvement, LVI+, LN+; mean follow-up 57 mo

HPVI SCC arising in “HSIL-like” / basaloid dVIN more likely to recur *(p=0.01)*

64% recurred vs. 35% HPVI SCC in conventional dVIN, 19% HPVA

? More intensive treatment and surveillance following surgery

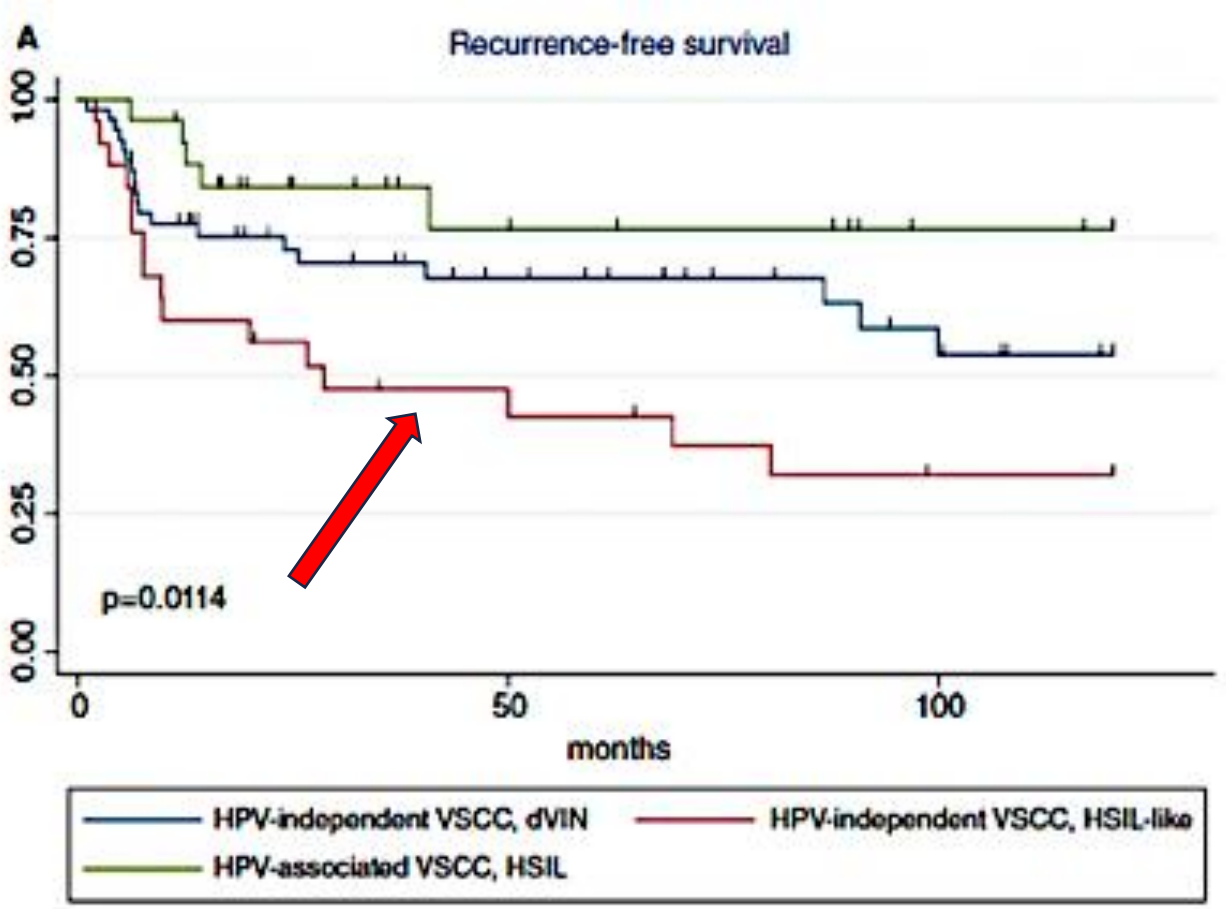

Problematic staining patterns – p16/p53

HPVA VIN/SCC

- **p16 basal**

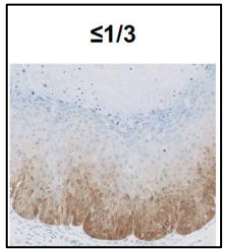

Maturation of squamous epithelium impacts extent of p16; well-differentiated keratinising SCC may see basal staining only
? keratin mask/interferes with p16 signal

- **p16 false negative**

Unexpected absence p16 - *CDKN2A* gene deletion (codes for p16) **or epigenetic silencing.** Approach: HPV ISH / PCR

- **p53 basal sparing**

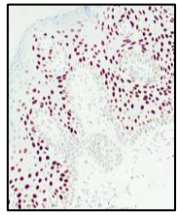

SPECIFIC FOR HPVA LESIONS. Pitfall: Misread as p53abn
? HPV integrates into basal cells, viral E6 degrades p53

- **p53 null-like**

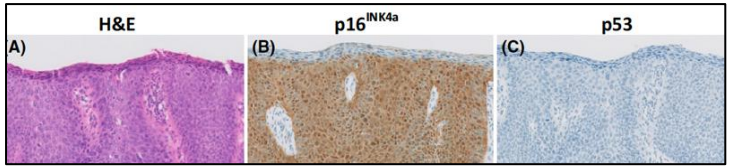

Markedly reduced p53. Pitfall: True null.
?Higher viral load, diffuse viral E6 degradation p53
Approach**:** HRHPV ISH / rpt p53 on another block

HPVI VIN/SCC

- **p16, p53 double positive**

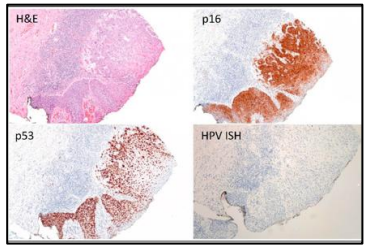

Yang, Mod Path 2023:
5/225 SCCs, <1%; all HRHPV ISH neg, *TP53* mutated on NGS
p16 staining HPV unrelated, mechanisms uncertain
Suggest double positives be classified HPVI p53abn

Histopathol 2024;84:301-14, AdvAP 2024, Diagn Histopath 2020;26:257-277, Thompson Mod Path 2020, Yang Mod Path 2023

Case 2

52yo

Clinical history:

Lichen sclerosus

Warty lesion, ?VIN

Procedure:

Excisional biopsy

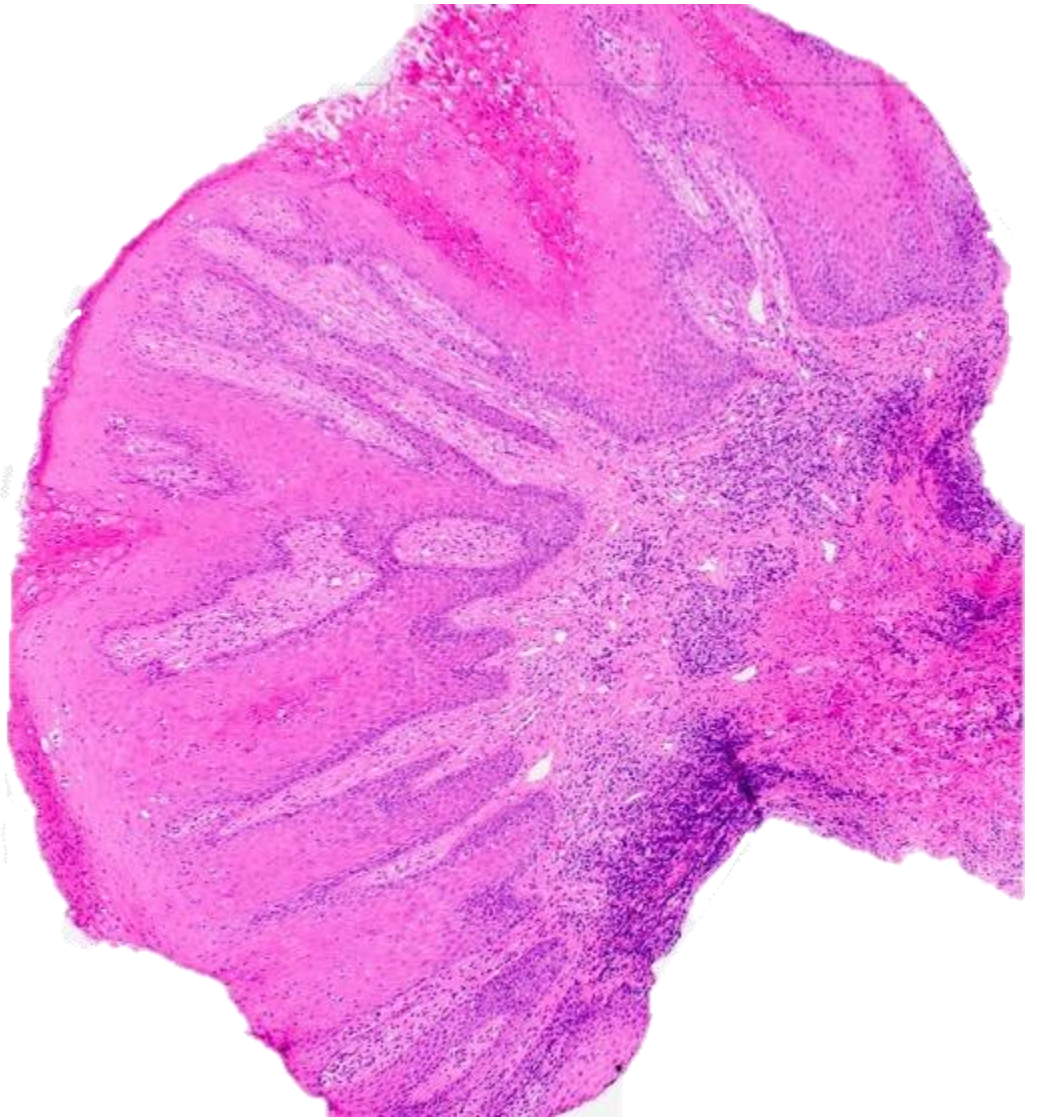


- Wedge-shaped parakeratin
- No granular layer
- Neutrophils in surface keratin

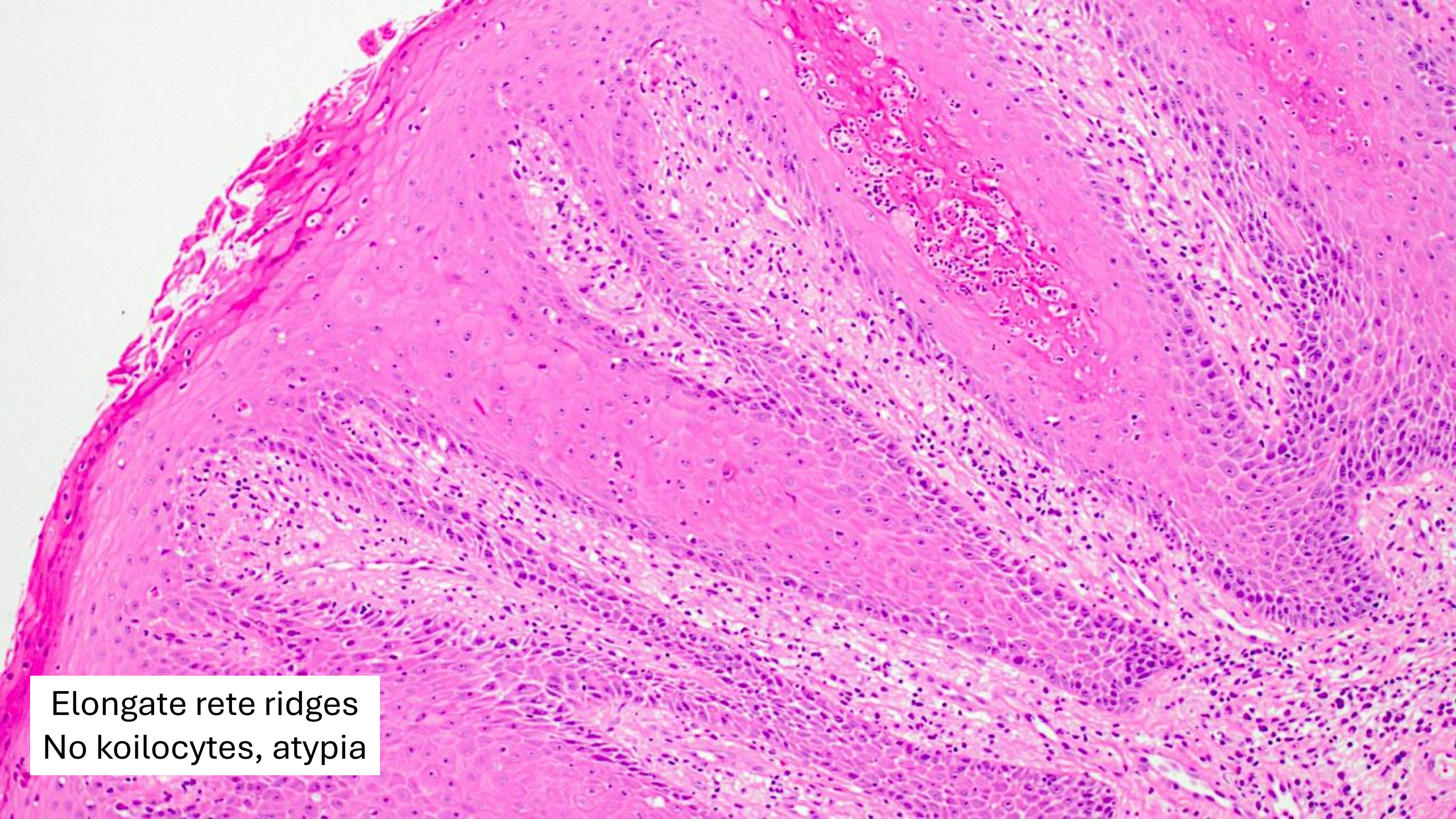
Elongate rete ridges
No koilocytes, atypia

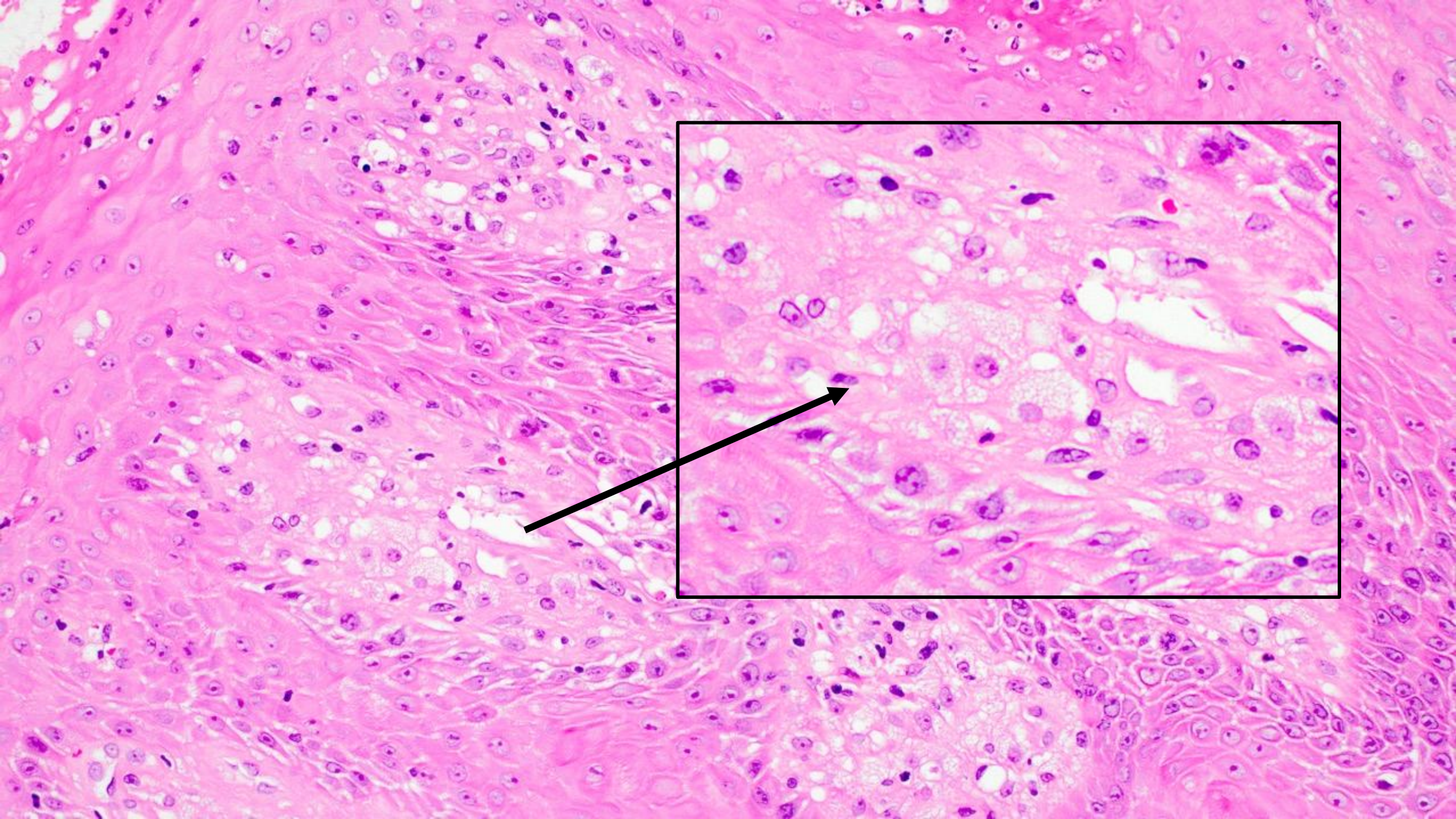

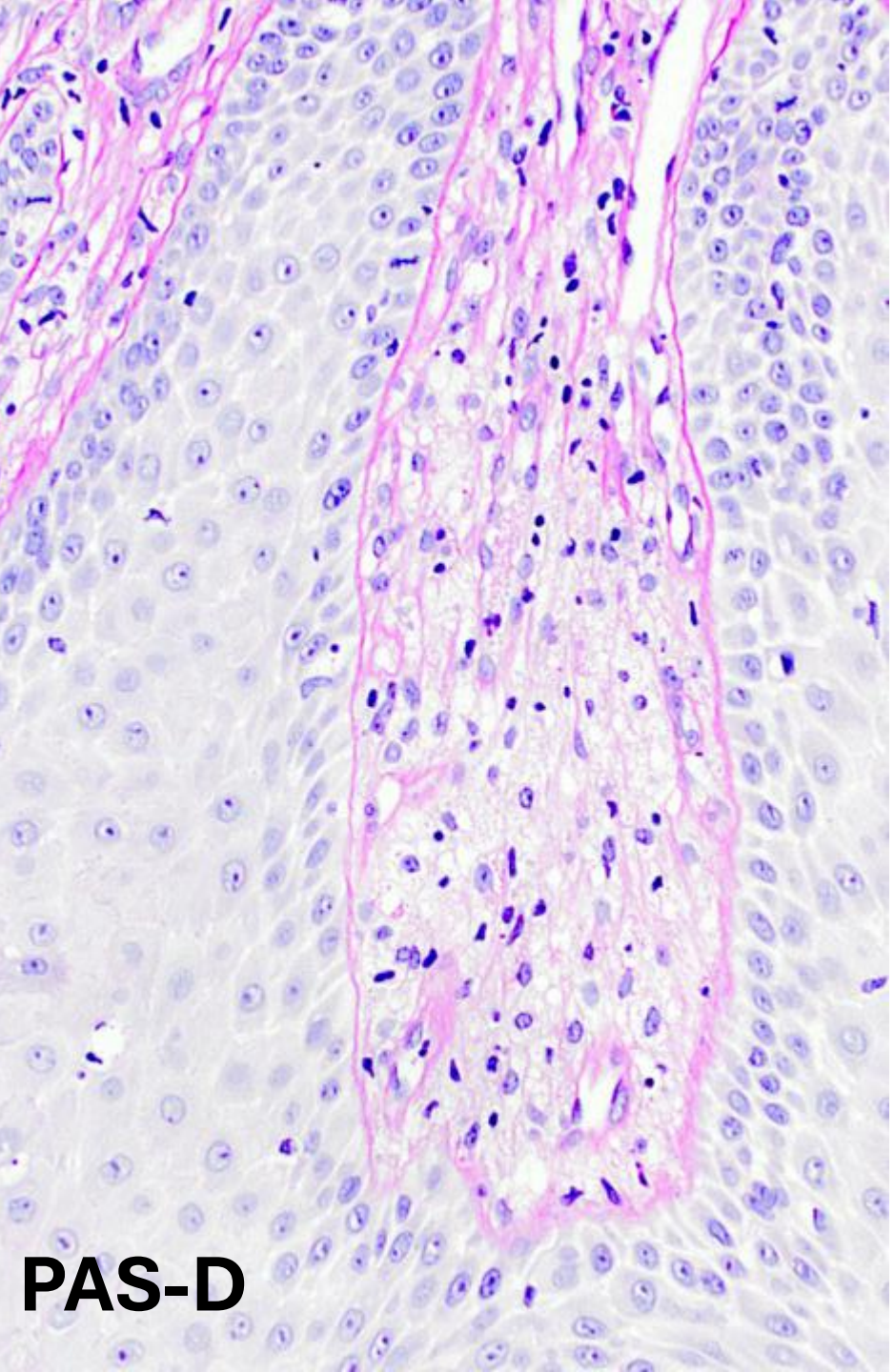
PAS-D

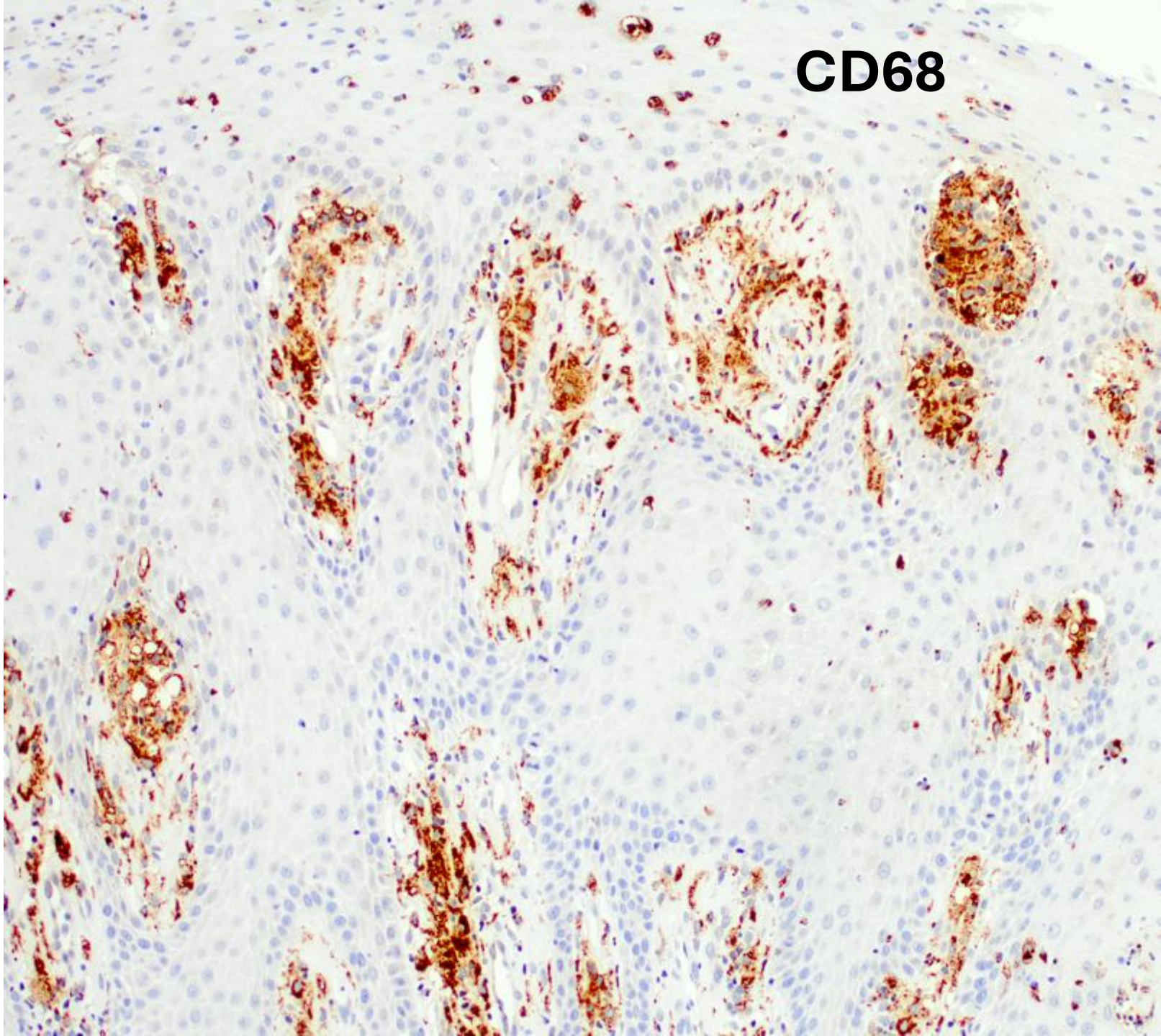
CD68

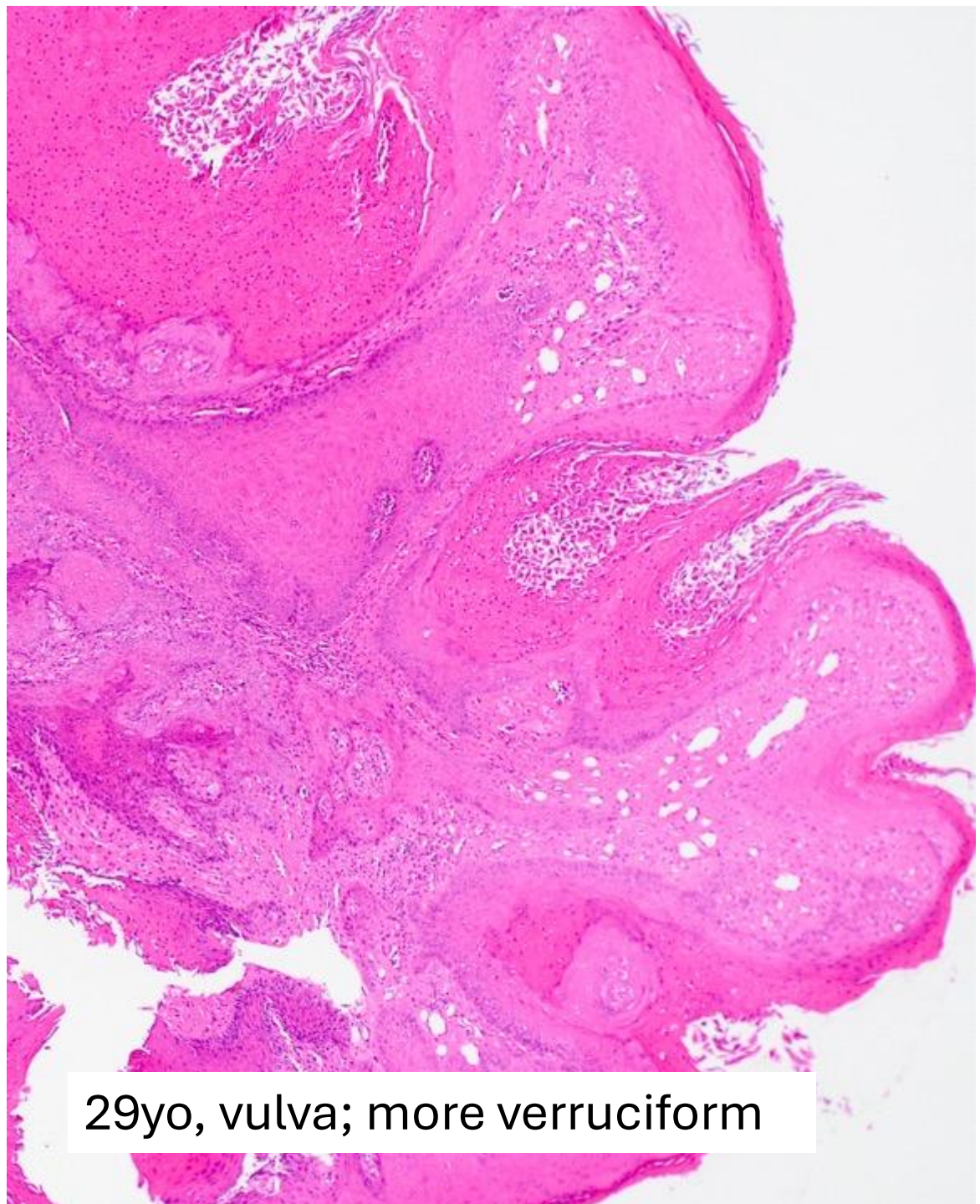
29yo, vulva; more verruciform


Ectatic dermal vessels

Verruciform xanthoma

- **Slow-growing verruciform plaque, pink-yellow**
- Clinically **concerning for wart / SCC**

- First described in **oral cavity** (1971)
  - Also genital and non-genital skin
  - **Labia minora** > clitoris > fourchette groin, buttocks, anus

Aetiology unclear; **usually NOT HPVA**
hyperlipidaemia proposed but only a minority





Source: Arch Dermatol 2011;147:1087-1092

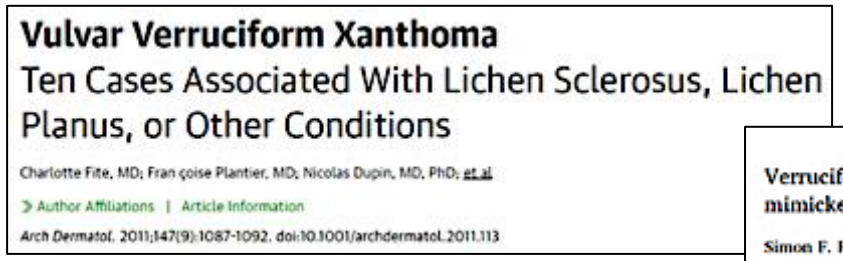

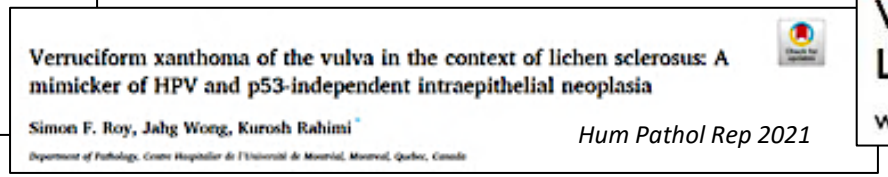

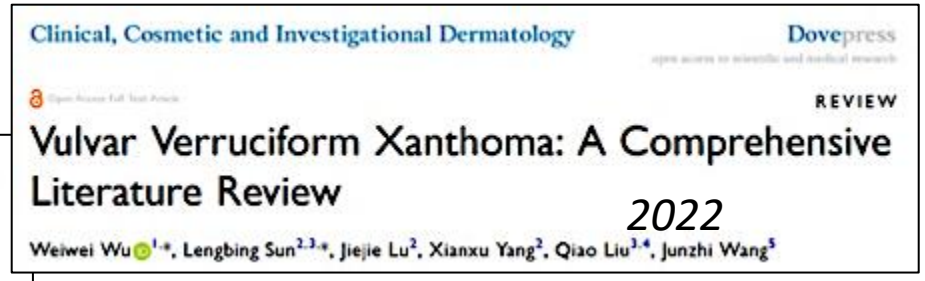

32 vulval cases reported; **mean age 46** (1.5 - 84)

Usually associated with another condition: Mostly **lichen sclerosus**, lichen planus

→ **Important not to mistake for HPVI VIN**

Unlikely to progress to SCC; 1 reported case, penile SCC**; excision suggested to minimise risk**

Proposed pathogenesis:

- Epidermal injury → macrophage phagocytosis damaged keratinocytes → lipid rich foam cells

Most helpful diagnostically:

- Bright pink parakeratin, neutrophil microabscesses, foamy histiocytes in dermal papillae

Case 3

67yo

Clinical history:

Nodule right labium majus, recently enlarging

Procedure:

Wide local excision

Nodule 20 x 18 x 11mm

Macroscopically extends into subcutis

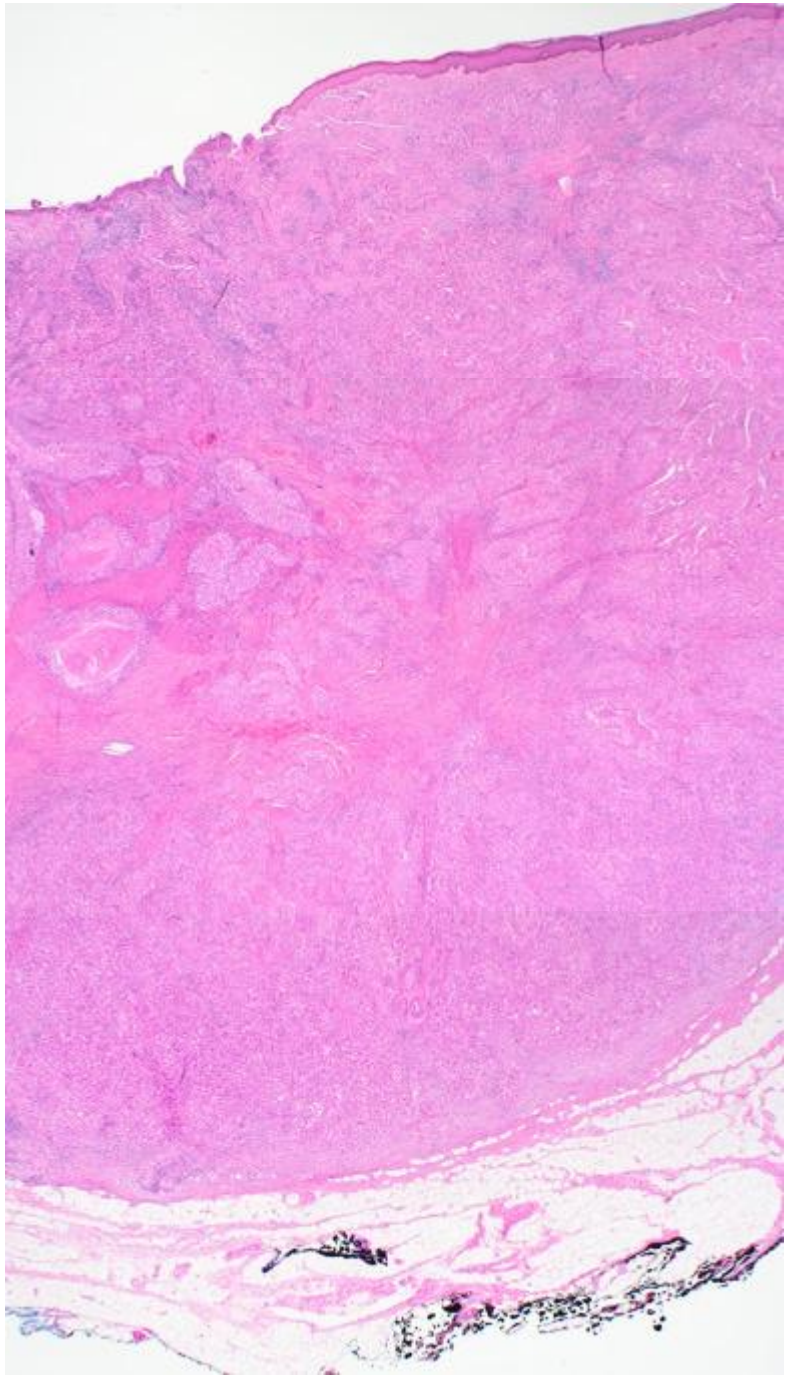

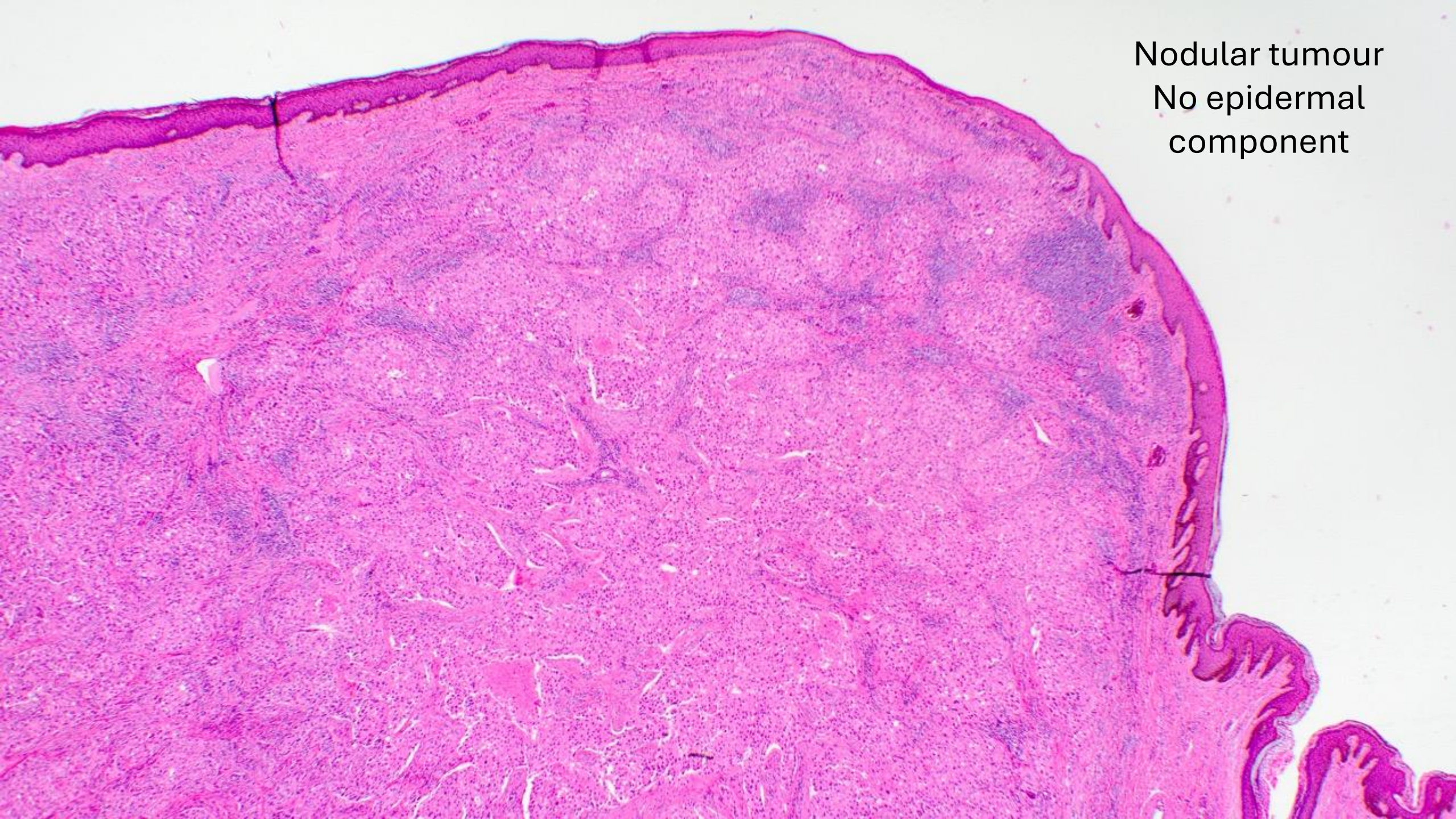
Nodular tumour
No epidermal component

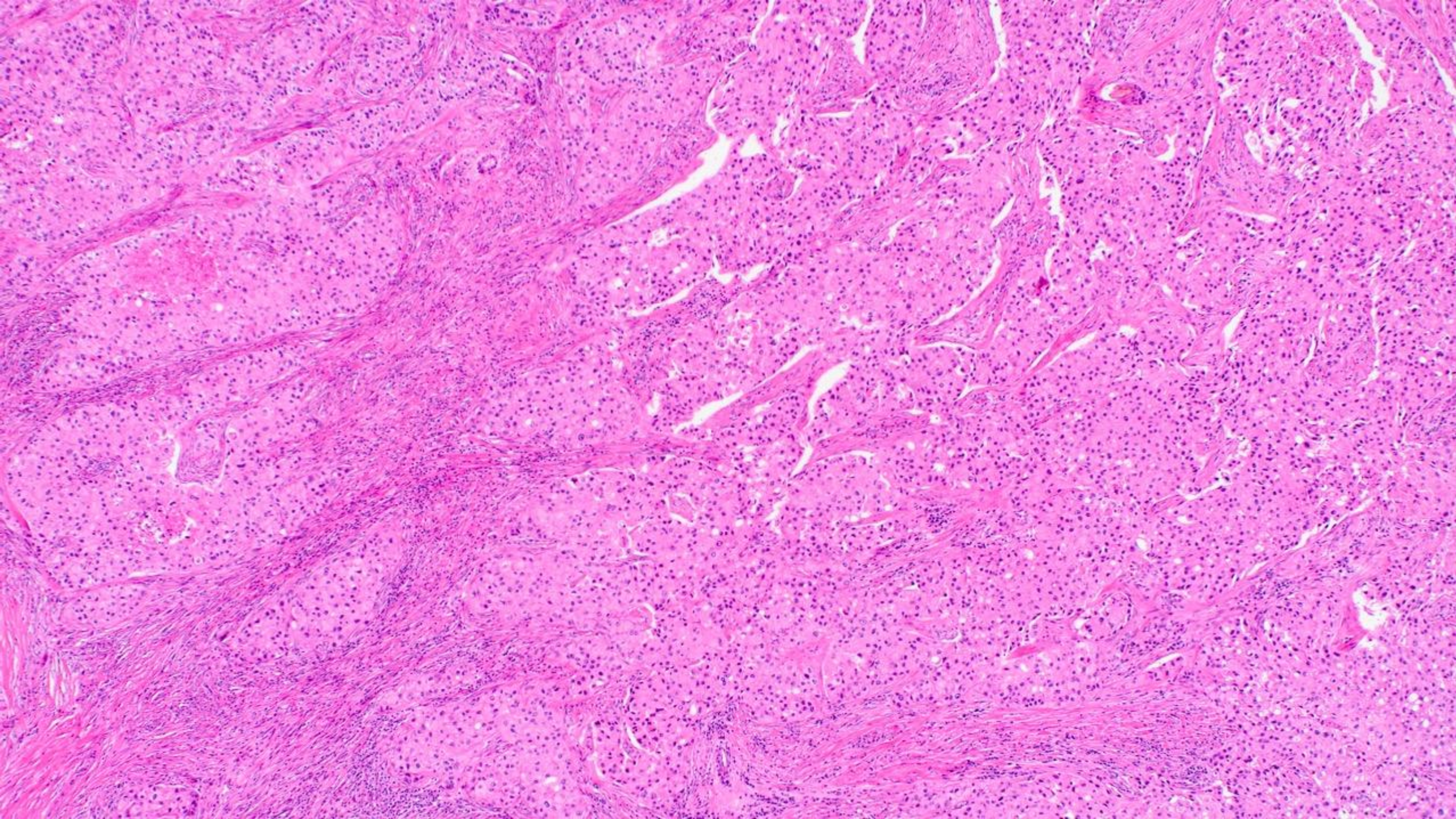

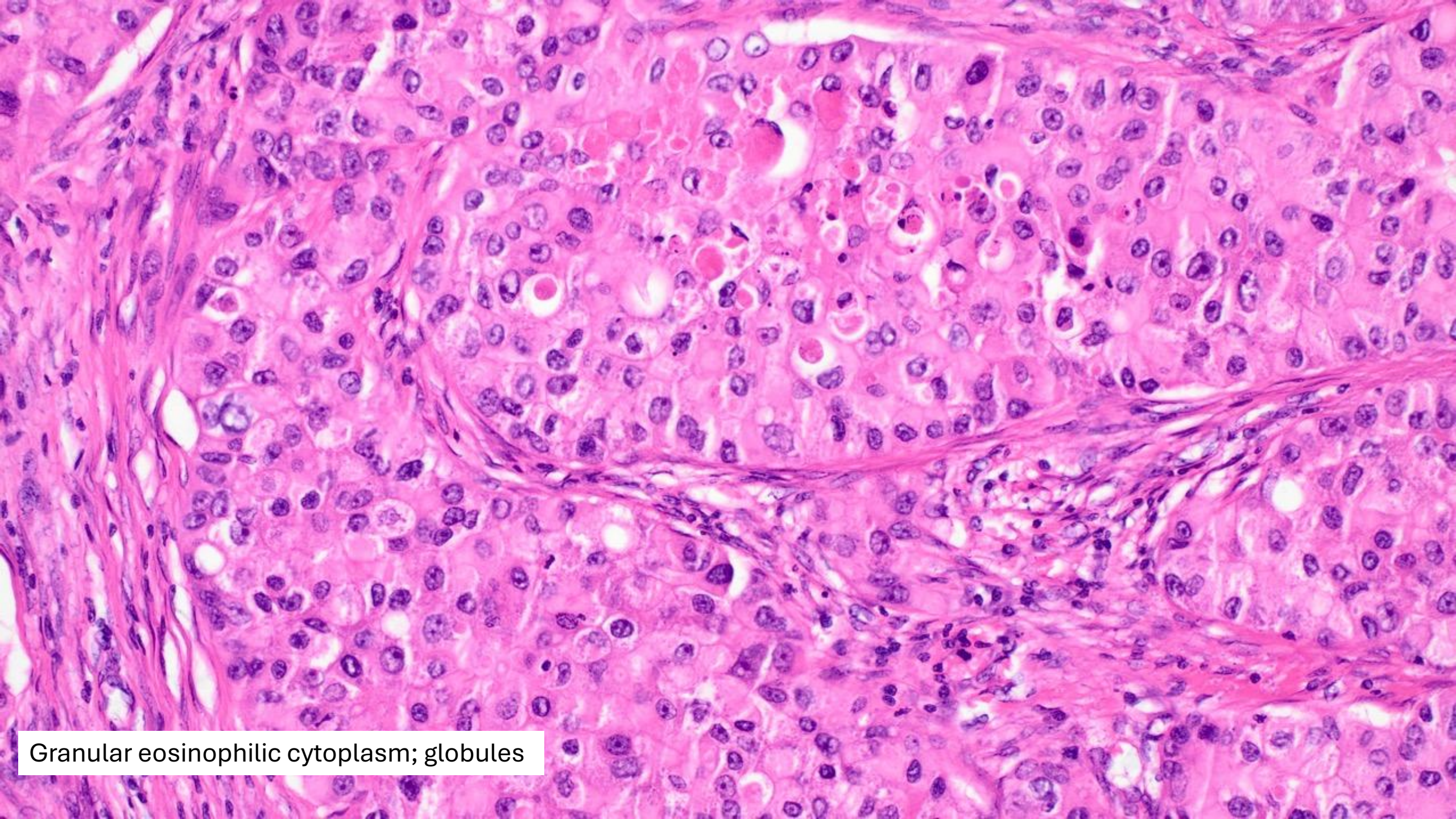
Granular eosinophilic cytoplasm; globules

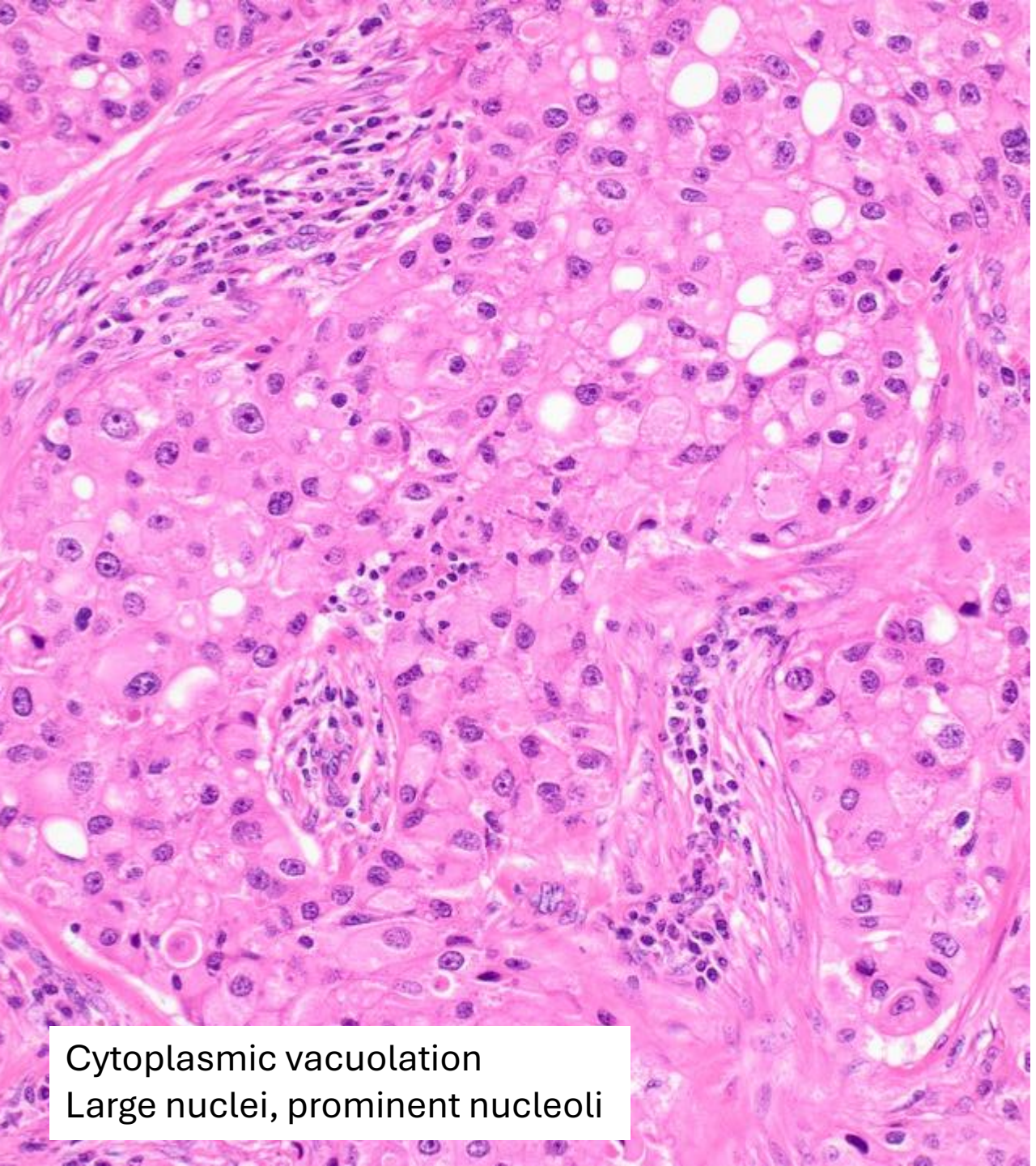
Cytoplasmic vacuolation
Large nuclei, prominent nucleoli

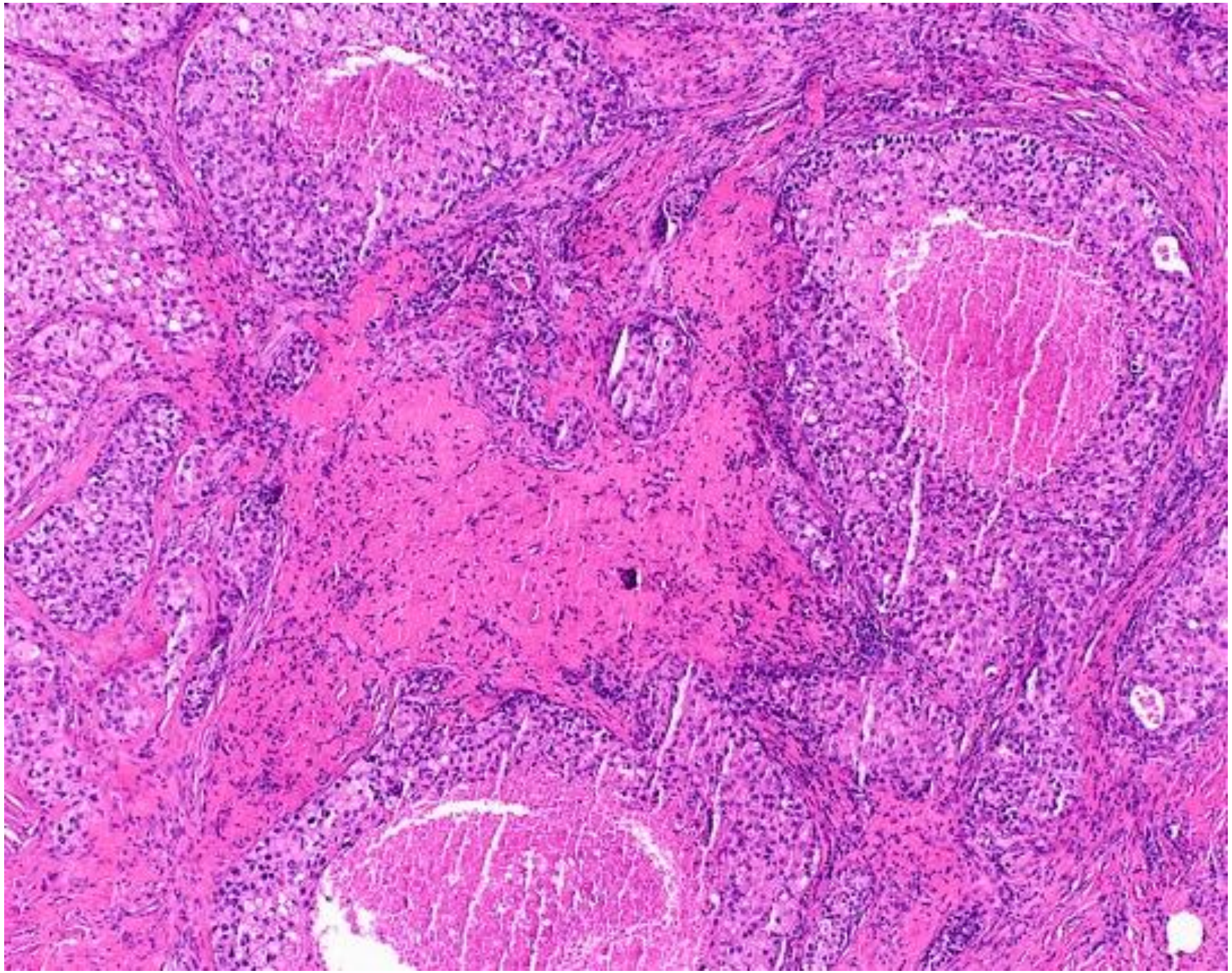

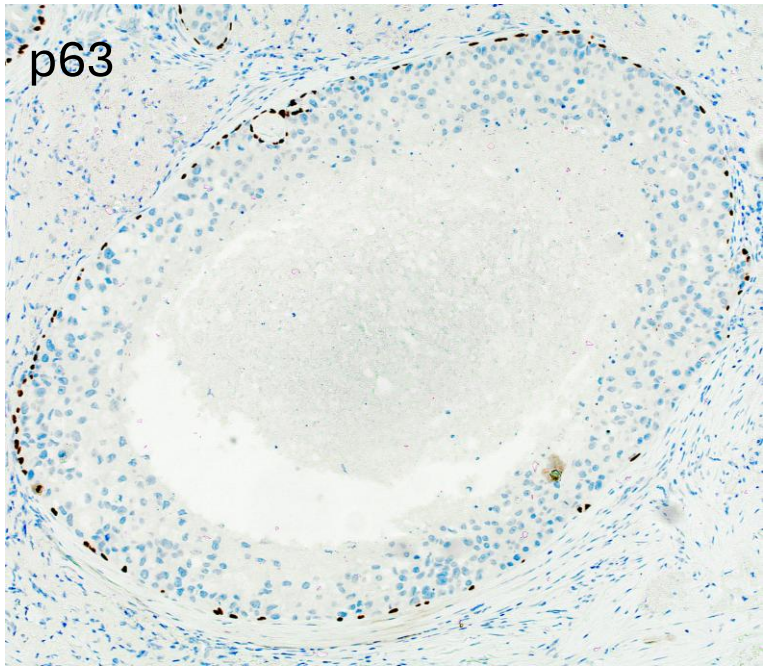
p63

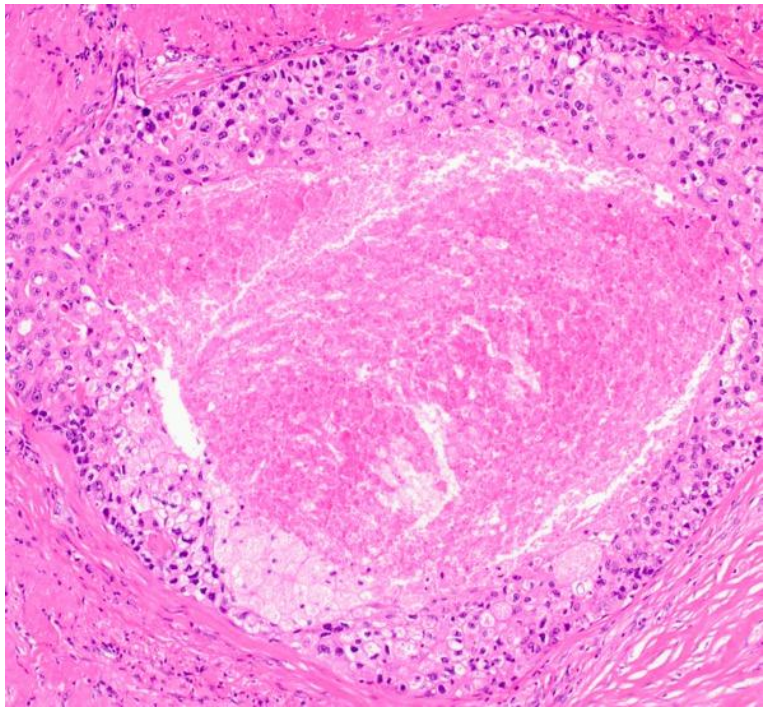

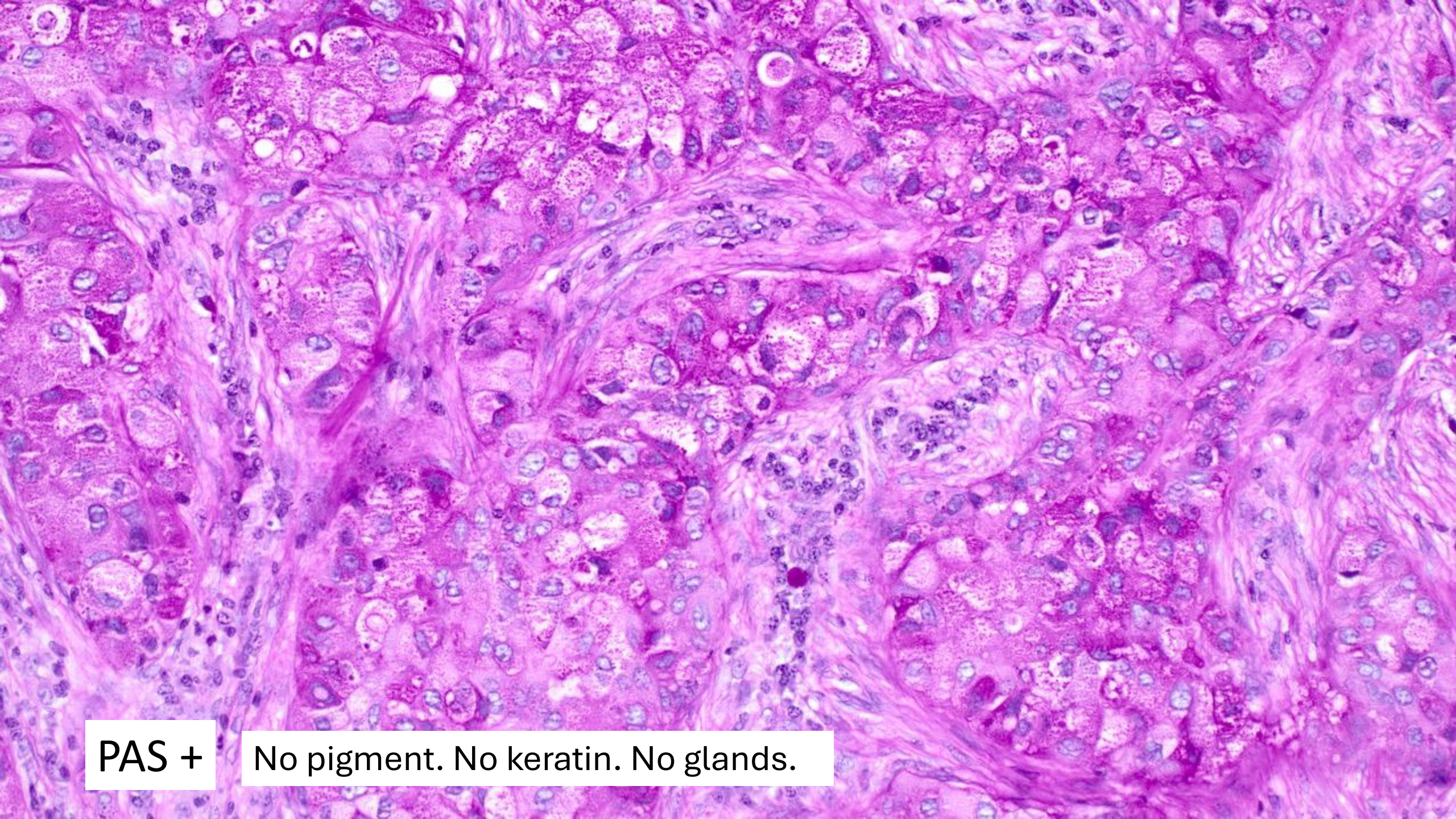
PAS +
No pigment. No keratin. No glands.


CK7

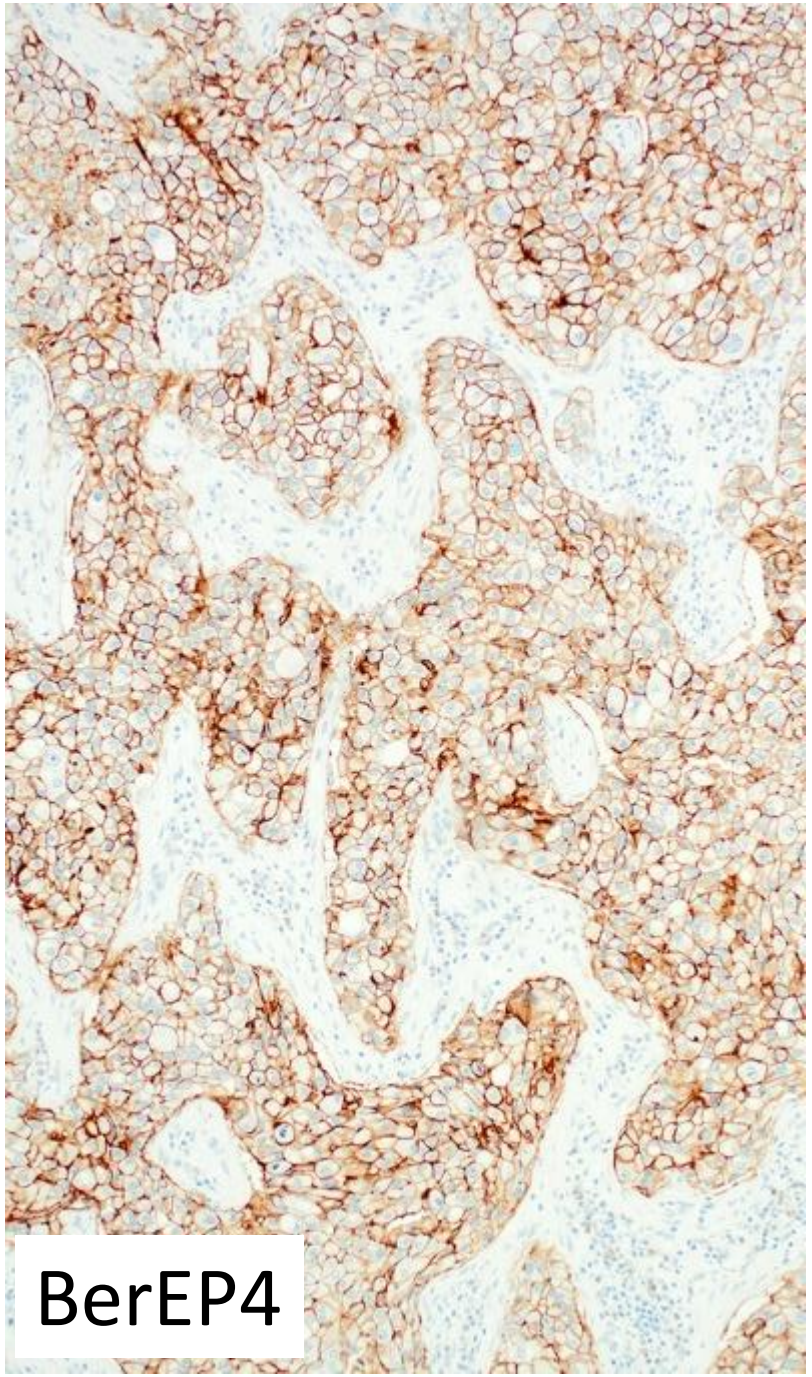
BerEP4

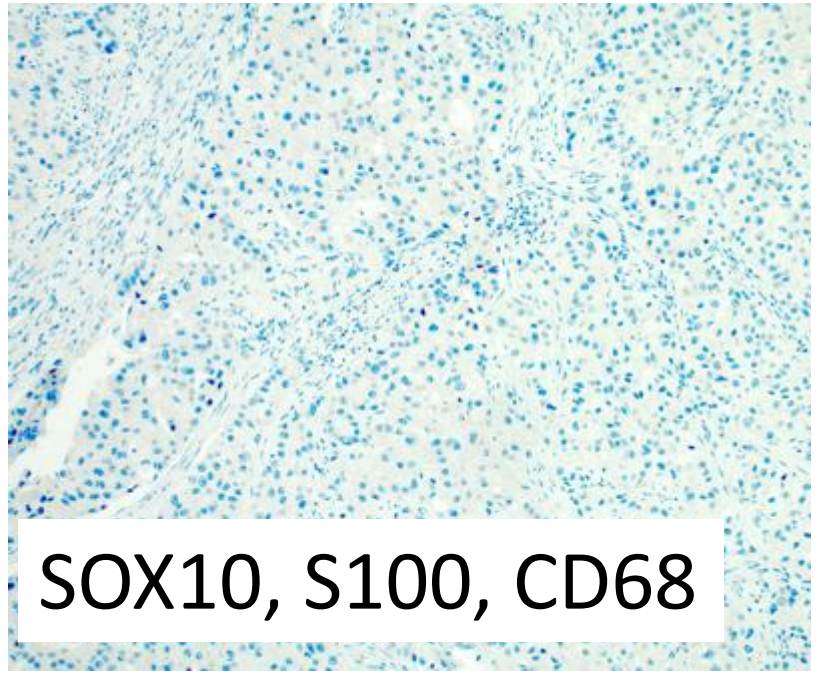
SOX10, S100, CD68

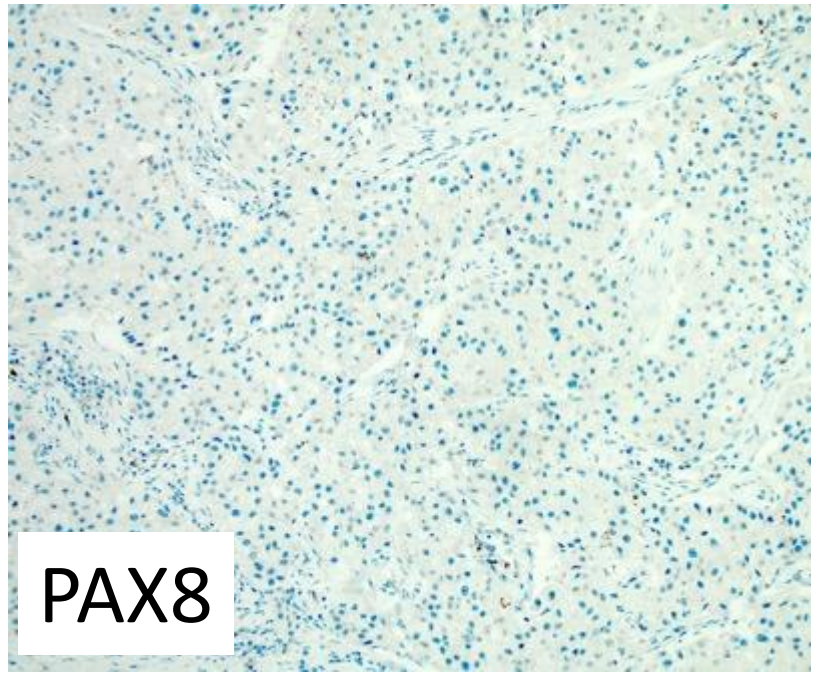
PAX8

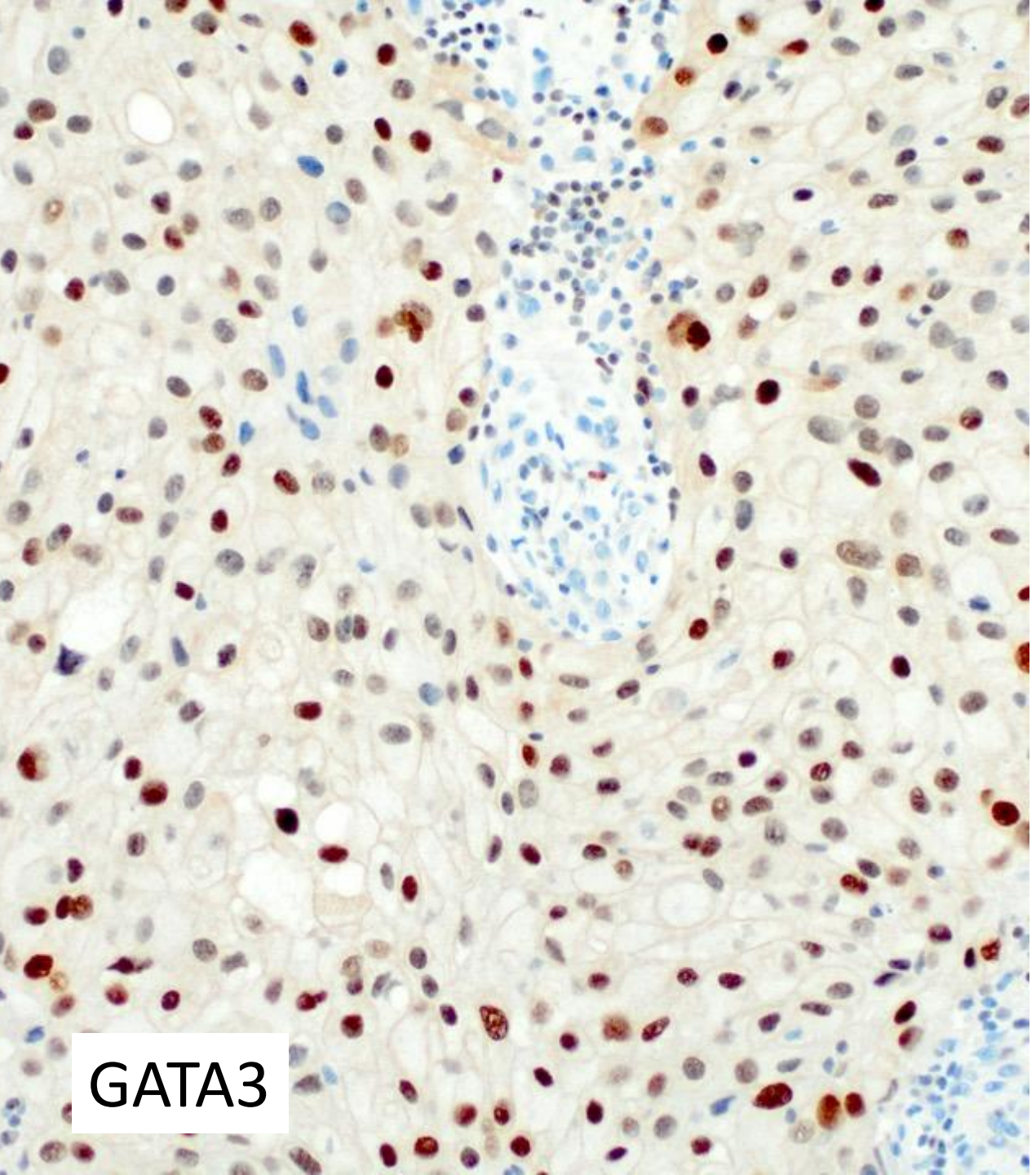
GATA3

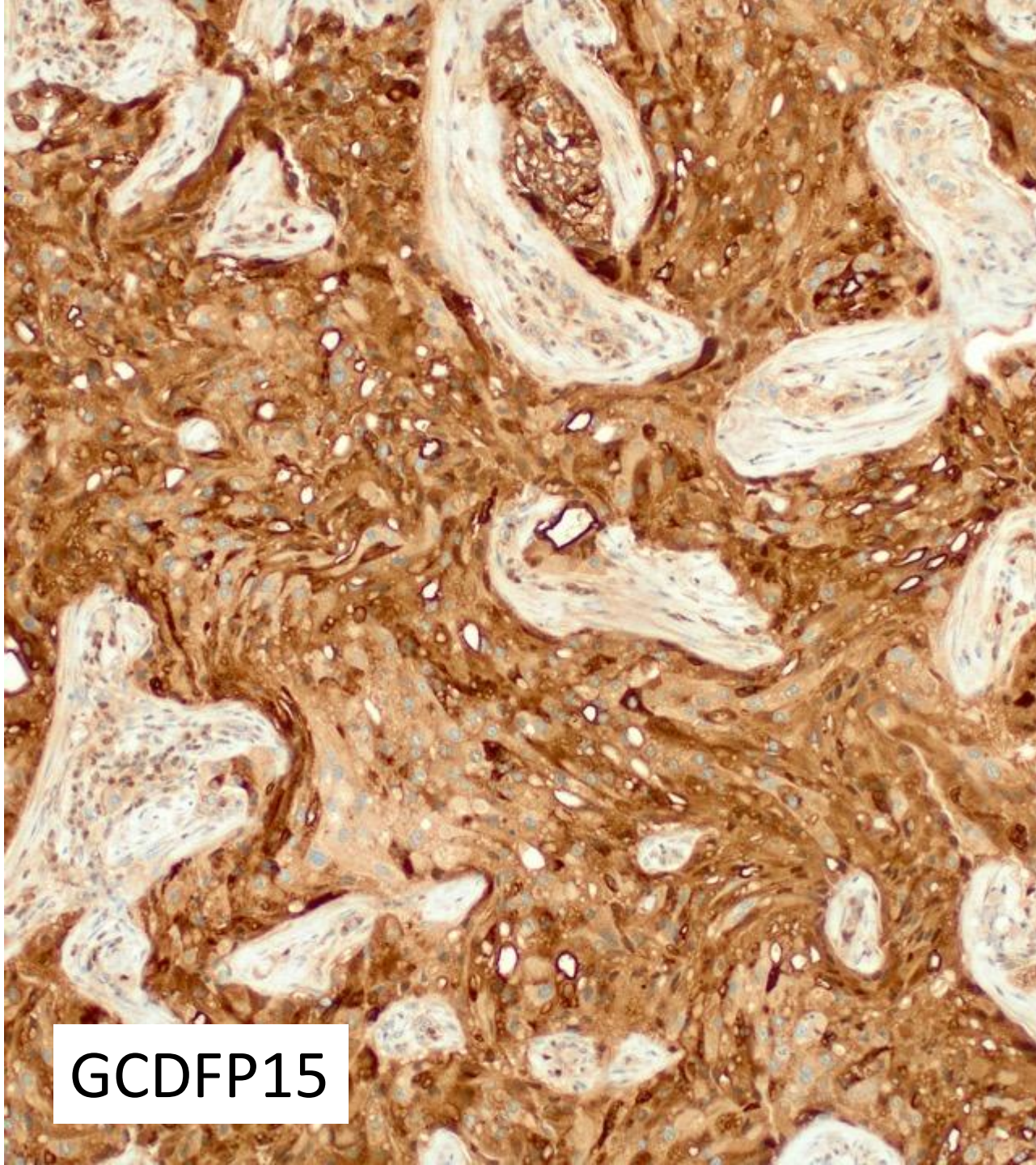
GCDFP15

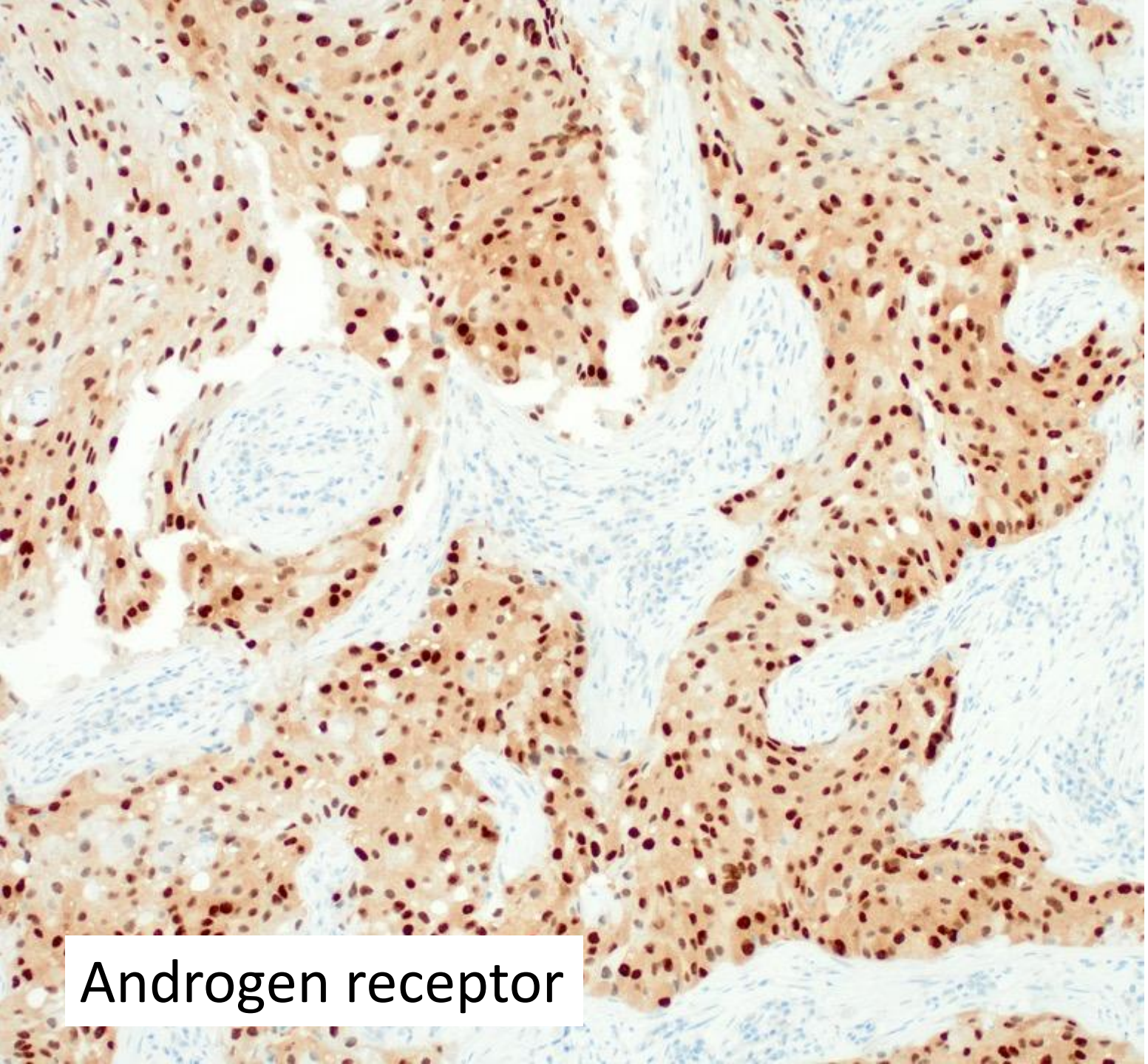
Androgen receptor

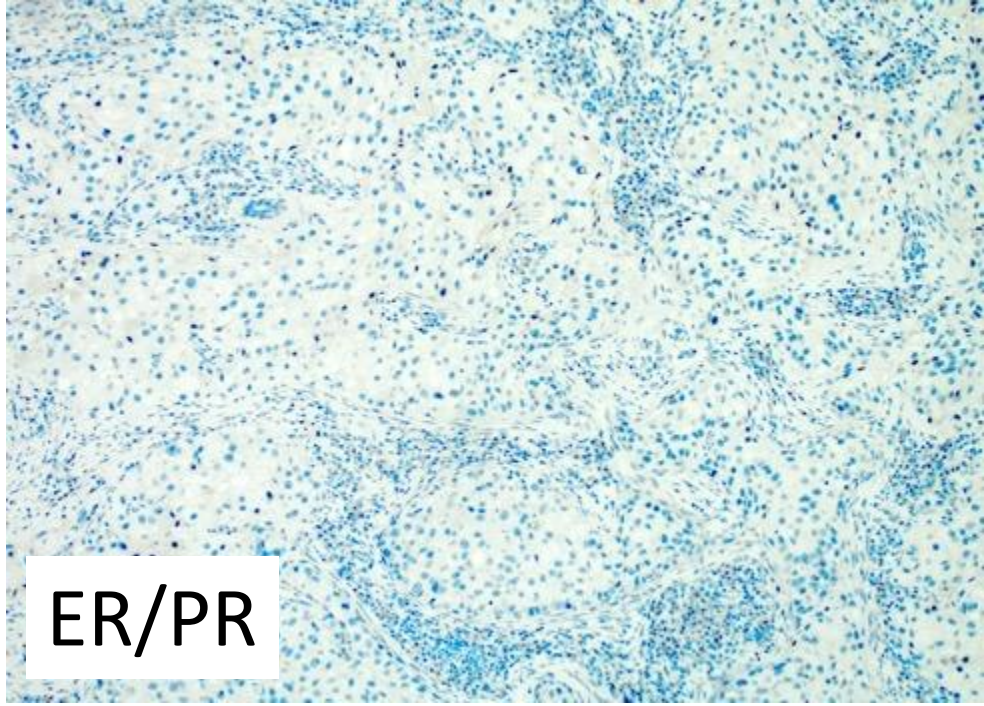
ER/PR

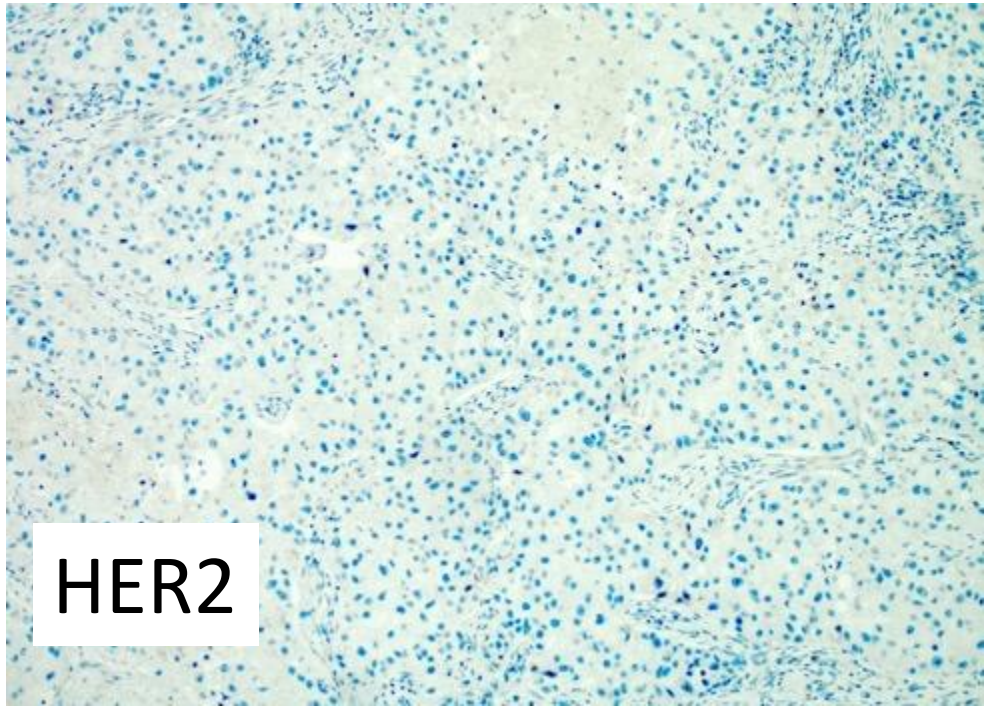
HER2

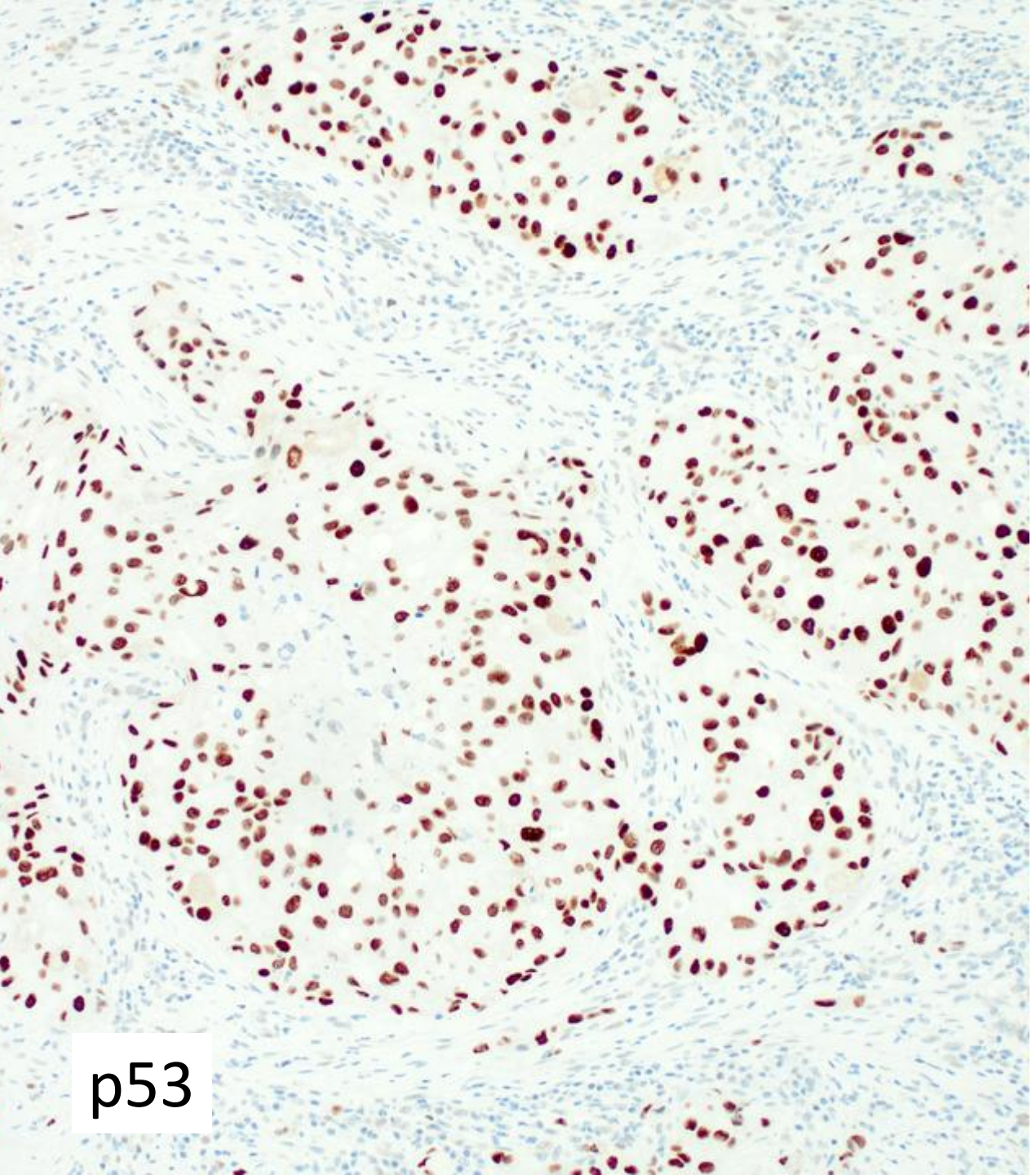
p53

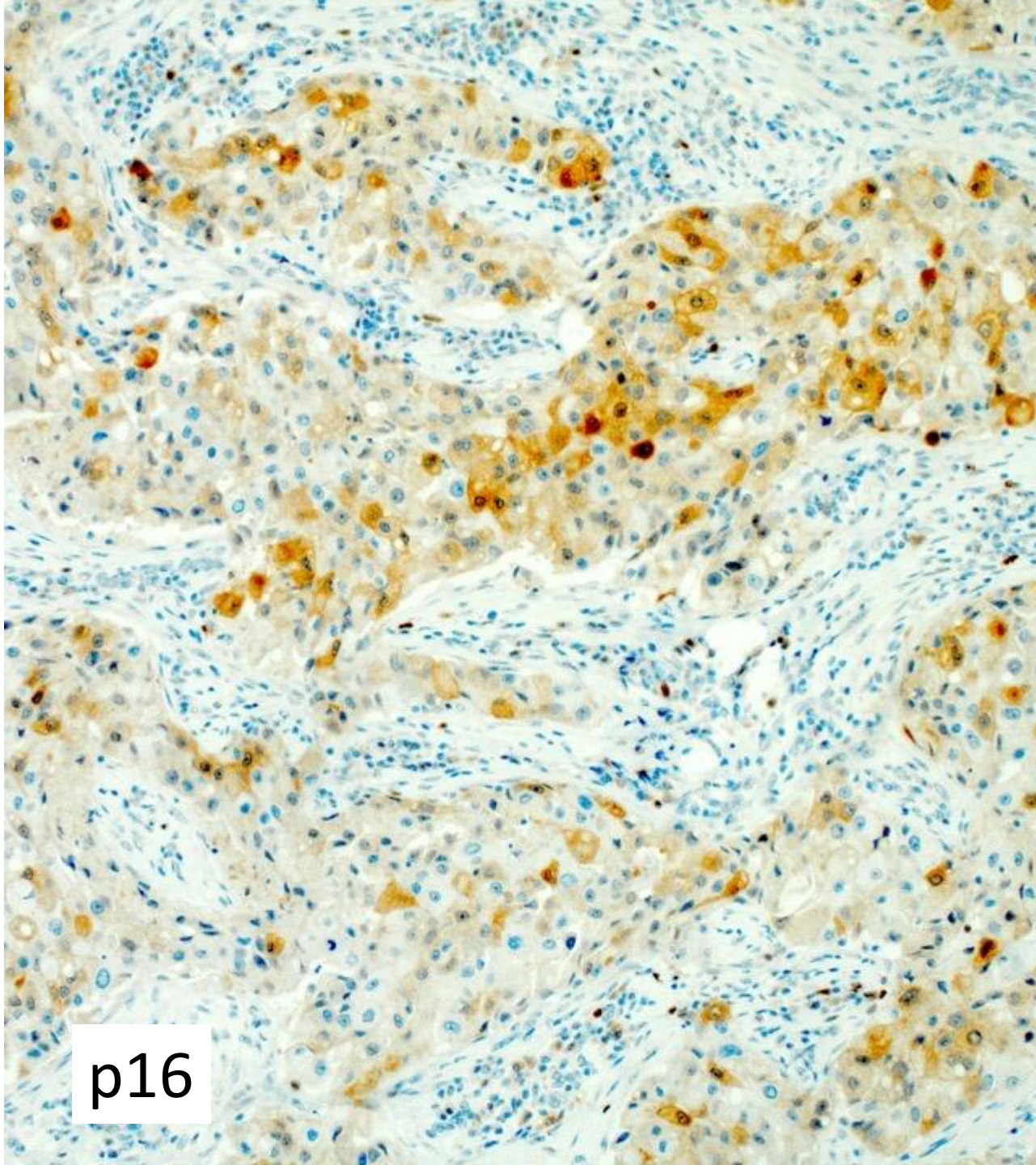
p16

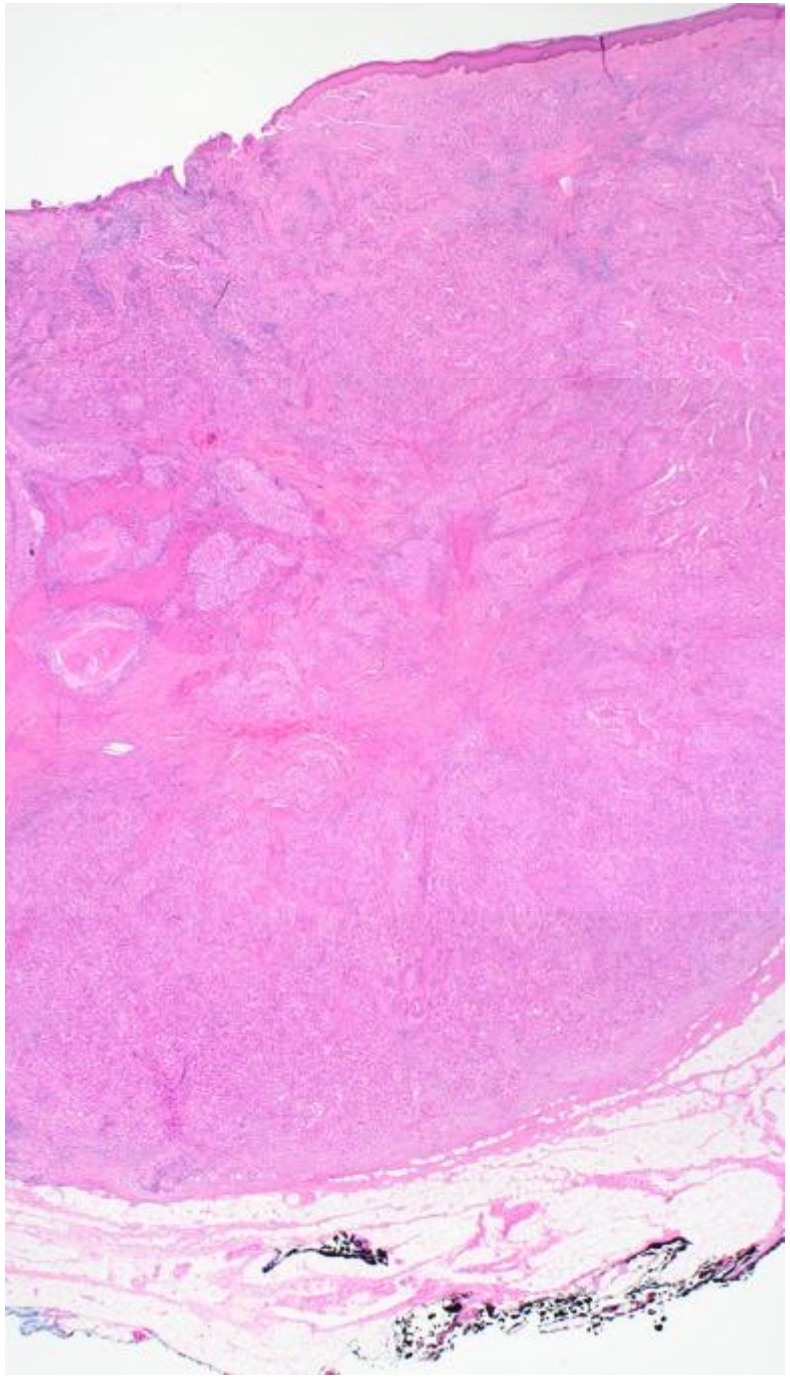

Diagnosis

Poorly differentiated adenocarcinoma
Apocrine carcinoma

Favour mammary-type adenocarcinoma
- DCIS favours primary vulval; no AGMLG
- ER negative, PR negative, AR positive
  - apocrine signature
- Basal-like – ER/PR/HER2 negative

- Carcinoma of sweat gland origin
- Exclude metastasis from breast

Primary vulval adenocarcinoma

Rare; approximately half are secondary

→ Rule out metastasis or direct extension before diagnose 1° adenocarcinoma

Generally HPV-independent

WHO 5th Ed

Glandular tumours and cysts

- Mammary-type glandular lesions
  - Papillary hidradenoma
  - Chondroid syringoma
  - Fibroadenoma
  - Phyllodes tumour
  - → Adenocarcinoma of mammary gland type
- Bartholin gland lesions
  - Bartholin gland cyst
  - Bartholin gland hyperplasia, adenoma, and adenomyoma
  - → Bartholin gland carcinomas
- Other cysts of the vulva

→ *Adenocarcinomas of other types*

- Paget disease
- Carcinomas of sweat gland origin
- Adenocarcinoma of intestinal type

Desouki Sem Diagn Pathol 2021

Anogenital mammary-like glands

Normal anogenital constituent

Modified eccrine glands; apocrine and mammary features, hormonally sensitive

Tumours show striking homology with breast

Historically (pig embryos): Supernumerary breast, remnants of milk line / mammary ridges

Recent (human embryo studies): The “milk line” is a myth; mammary glands don’t extend beyond axilla/pectoral area

Kazakov Adv AP 2011, van der Putte Dermatopathol 1991, IJGP 1994

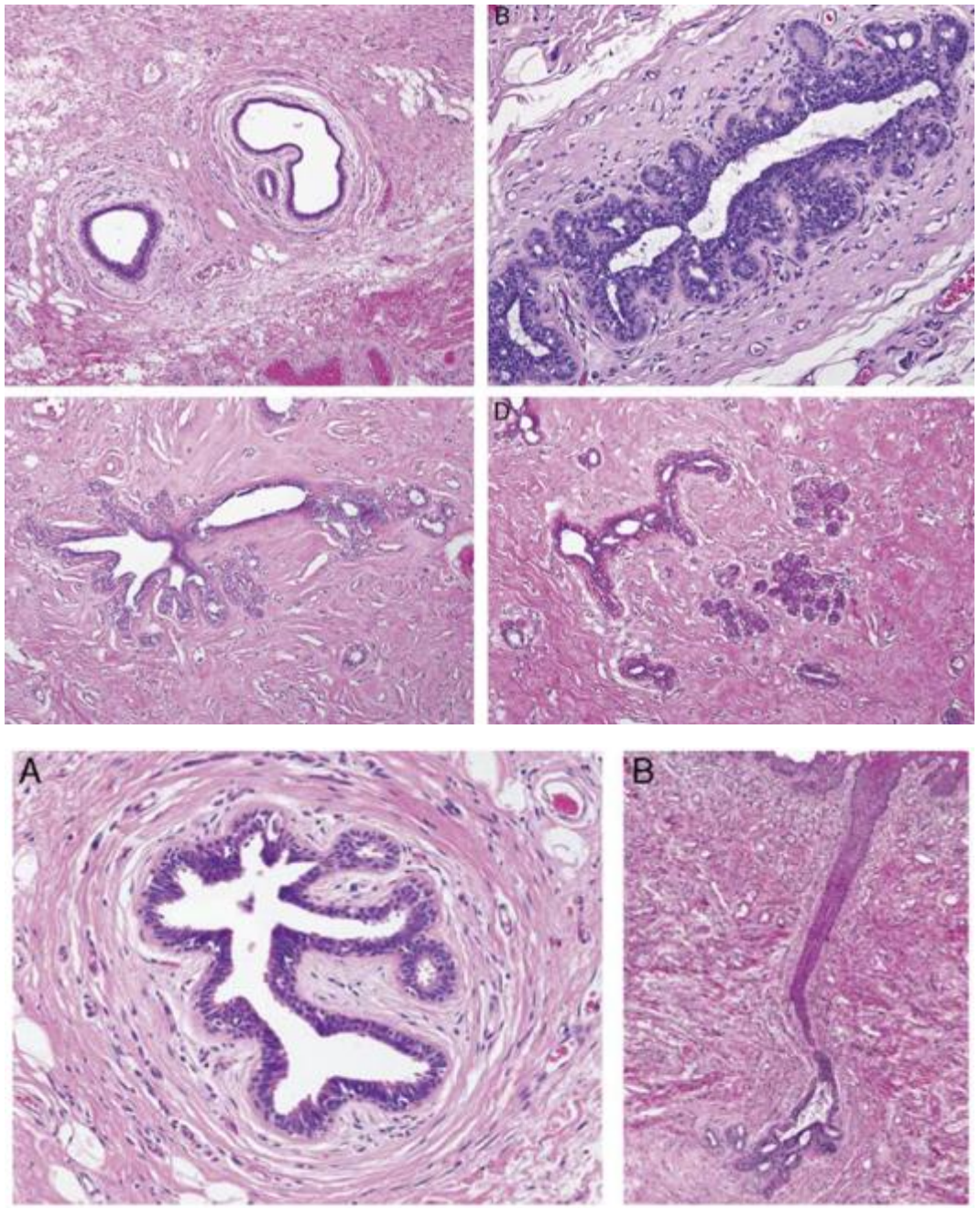

Kazakov Adv AP 2011

Adenocarcinoma of mammary gland type
Diagnostic criteria

Resembles a breast primary morphologically:
Invasive ductal ± DCIS > lobular > tubulolobular, secretory, metaplastic

Same IHC as breast: CK7, ER, PR, HER2, GATA3, mammaglobin

Dermally centred, minimal or no epidermal involvement

Adjacent AGMLG helpful feature but seldom seen

Differentials: Metastasis from breast 1°, invasive Paget disease

Behaviour: Locally aggressive, often metastasise to regional lymph nodes

Shah IJGP 2021, Kazakov Adv AP 2011, Tessier-Cloutier Histopathol 2017, Morais BMJ case Rep 2022, Grewal Cold Spring Harb Mol Case Stud 2017

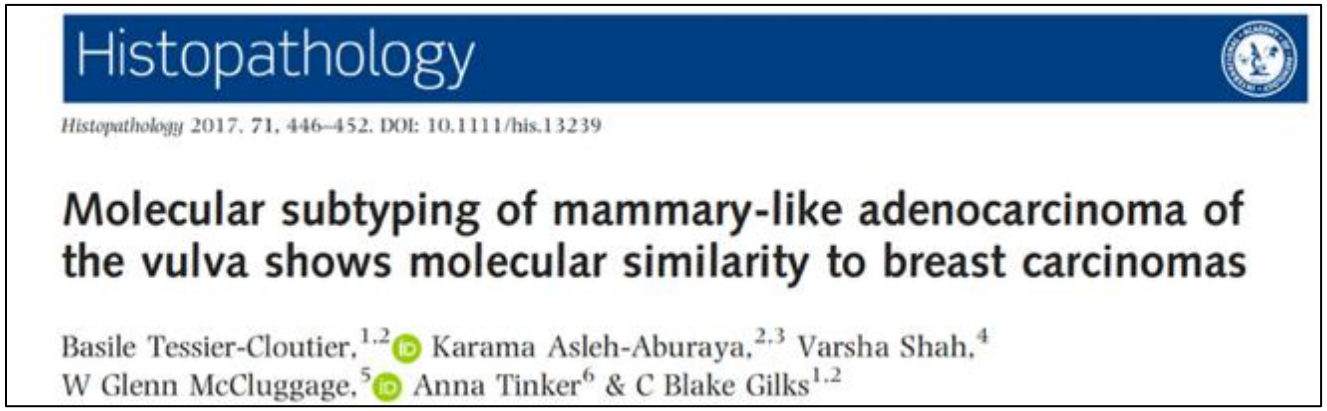

Histopathology

Histopathology 2017, 71, 446–452. DOI: 10.1111/his.13239

Molecular subtyping of mammary-like adenocarcinoma of the vulva shows molecular similarity to breast carcinomas

Basile Tessier-Cloutier,[1,2] Karama Asleh-Aburaya,[2,3] Varsha Shah,[4] W Glenn McCluggage,[5] Anna Tinker[6] & C Blake Gilks[1,2]

7 MLA; 17 vulval EMPD, 7 with invasion

As in breast, MLA groups to 4 molecular categories:

14% Luminal A: ER+, Ki-67 low

43% Luminal B: ER+, Ki-67 high, HER2 +/-

29% HER2-enriched: ER/PR-, HER2 overexpressed/amplified

14% Basal-like: ER/PR-, HER2-, Ki-67 high

Suggested these breast cancer biomarkers be assessed

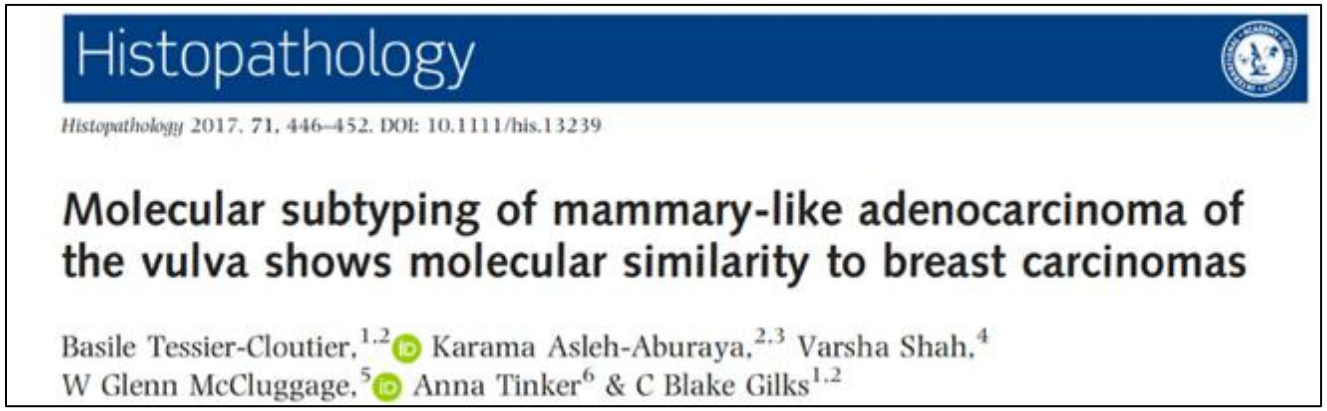

Histopathology

Histopathology 2017, 71, 446–452. DOI: 10.1111/his.13239

Molecular subtyping of mammary-like adenocarcinoma of the vulva shows molecular similarity to breast carcinomas

Basile Tessier-Cloutier,[1,2] Karama Asleh-Aburaya,[2,3] Varsha Shah,[4] W Glenn McCluggage,[5] Anna Tinker[6] & C Blake Gilks[1,2]

7 MLA; 17 vulval EMPD, 7 with invasion

As in breast, MLA groups to 4 molecular categories:

14% Luminal A: ER+, Ki-67 low

43% Luminal B: ER+, Ki-67 high, HER2 +/-

29% HER2-enriched: ER/PR-, HER2 overexpressed/amplified

14% Basal-like: ER/PR-, HER2-, Ki-67 high

Hormone receptor negative does not exclude mammary like carcinoma of vulva

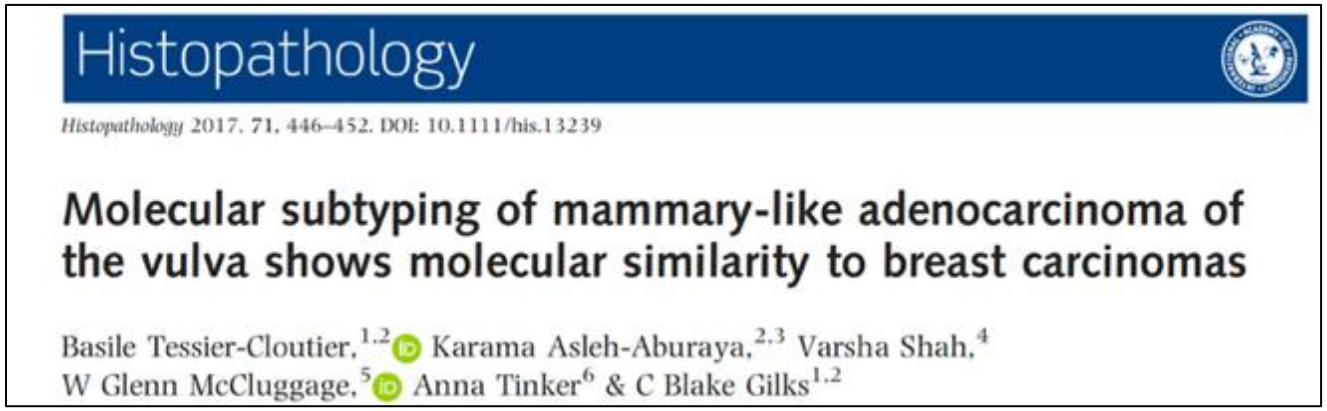

Histopathology

Histopathology 2017, 71, 446–452. DOI: 10.1111/his.13239

Molecular subtyping of mammary-like adenocarcinoma of the vulva shows molecular similarity to breast carcinomas

Basile Tessier-Cloutier,[1,2] Karama Asleh-Aburaya,[2,3] Varsha Shah,[4] W Glenn McCluggage,[5] Anna Tinker[6] & C Blake Gilks[1,2]

7 MLA; 17 vulval EMPD, 7 with invasion

For invasive extra-mammary Paget disease:

29% Luminal A: ER+, Ki-67 low

43% Luminal B: ER+, Ki-67 high, HER2 +/-

14% HER2-enriched: ER/PR-, HER2 overexpressed/amplified

14% Basal-like: ER/PR-, HER2-, Ki-67 high

Relationship between mammary like adenocarcinoma and EMPD unclear; IHC can be identical; both may originate in skin adnexa

Mammary-like adenocarcinoma	Invasive Paget Disease
Less common	**More common**; up to 19% invasive ~9% underlying 1° vulval malignancy
Dermally centred Minimal / no epidermal involvement	May have dermal invasion (superficial) Epidermal component extensive
4 molecular types Luminal B most common	4 molecular types Luminal B most common
	Luminal A more common for in situ than invasive Paget Disease May explain indolent vs. aggressive course of in situ vs. invasive

Preti JLGTD 2022, Tessier-Cloutier Histopathol 2017
Kazakov AdvAP 2011, Shah IJGP 2021

Mammary-like adenocarcinoma	Invasive Paget Disease
Less common	More common; up to 19% invasive ~9% underlying 1° vulval malignancy
Dermally centred **Minimal / no epidermal** involvement	May have dermal invasion (superficial) **Epidermal component extensive**
4 molecular types Luminal B most common	4 molecular types Luminal B most common
	Luminal A more common for in situ than invasive Paget Disease May explain indolent vs. aggressive course of in situ vs. invasive

Preti JLGTD 2022, Tessier-Cloutier Histopathol 2017
Kazakov AdvAP 2011, Shah IJGP 2021

Mammary-like adenocarcinoma	Invasive Paget Disease
Less common	More common; up to 19% invasive ~9% underlying 1° vulval malignancy
Dermally centred Minimal / no epidermal involvement	May have dermal invasion (superficial) Epidermal component extensive
4 molecular types Luminal B most common	**4 molecular types** Luminal B most common
	Luminal A more common for in situ than invasive Paget Disease May explain indolent vs. aggressive course of in situ vs. invasive

Preti JLGTD 2022, Tessier-Cloutier Histopathol 2017
Kazakov AdvAP 2011, Shah IJGP 2021

Mammary-like adenocarcinoma	Invasive Paget Disease
Less common	More common; up to 19% invasive ~9% underlying 1° vulval malignancy
Dermally centred Minimal / no epidermal involvement	May have dermal invasion (superficial) Epidermal component extensive
4 molecular types Luminal B most common	4 molecular types Luminal B most common
	Luminal A more common for in situ than invasive Paget Disease May explain indolent vs. aggressive course of in situ vs. invasive

Preti JLGTD 2022, Tessier-Cloutier Histopathol 2017
Kazakov AdvAP 2011, Shah IJGP 2021

MLA or invasive Paget Disease?

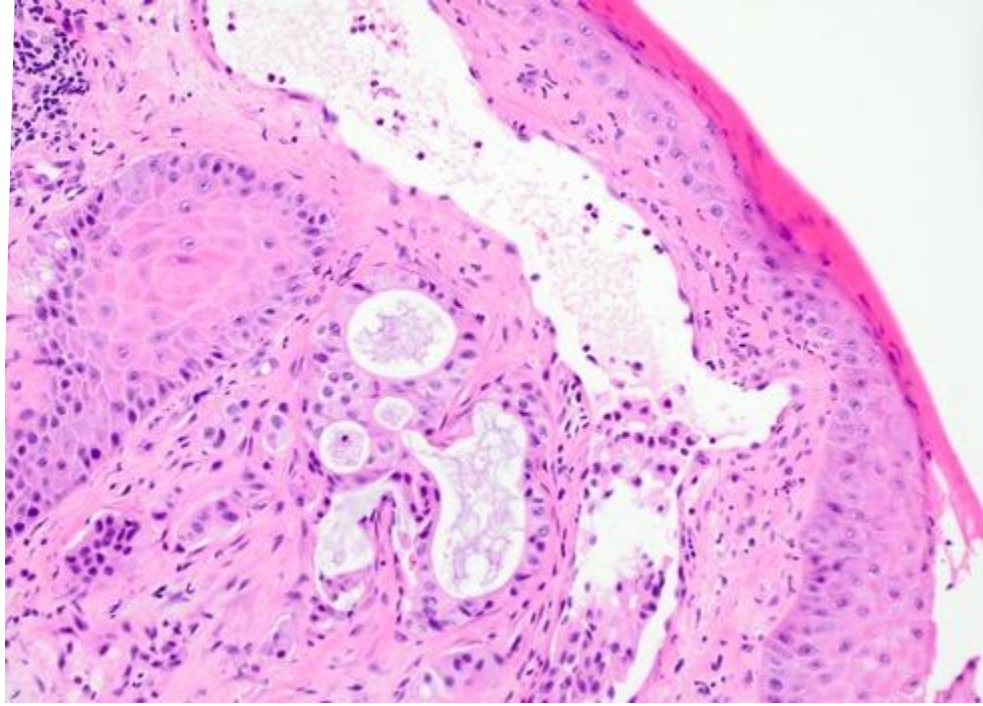

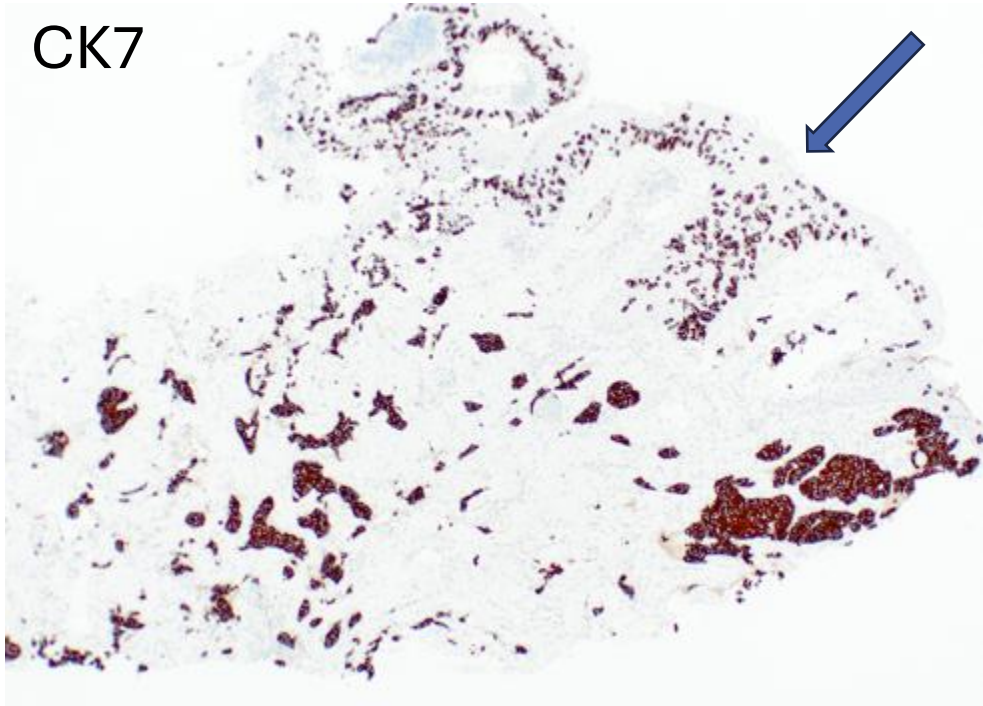

Case 4

82yo

Clinical history:

2 cm “vascular” lesion at introitus

Clinically malignant

Procedure:

Initial biopsy

Wide local excision

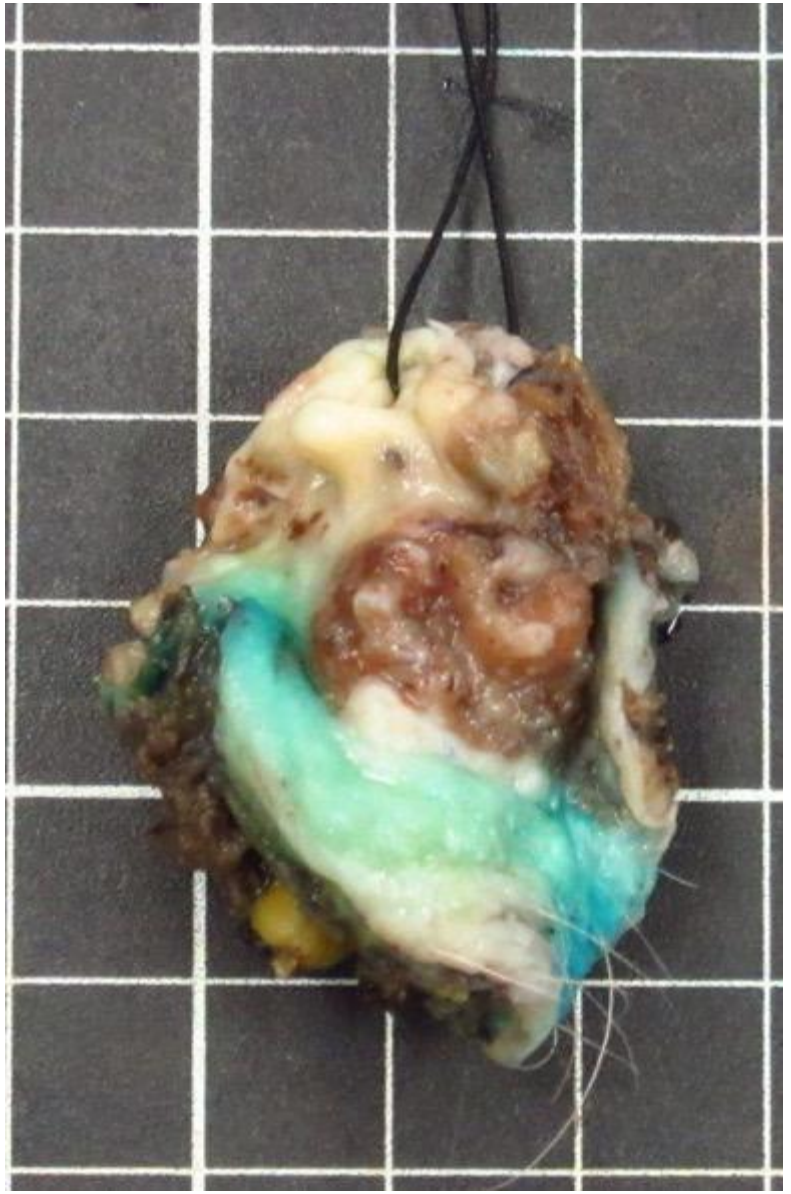

Initial biopsy

Adenocarcinoma

Superficial biopsy, no attached stroma

- **Positive:** CK7, CK20, CEA, CDX2
- **Negative:** PAX8, ER, PR, Vimentin
- p53: Mutation type (diffuse)
- p16: Diffuse positive

Adenocarcinoma with GI phenotype

Consider metastasis from GI tract

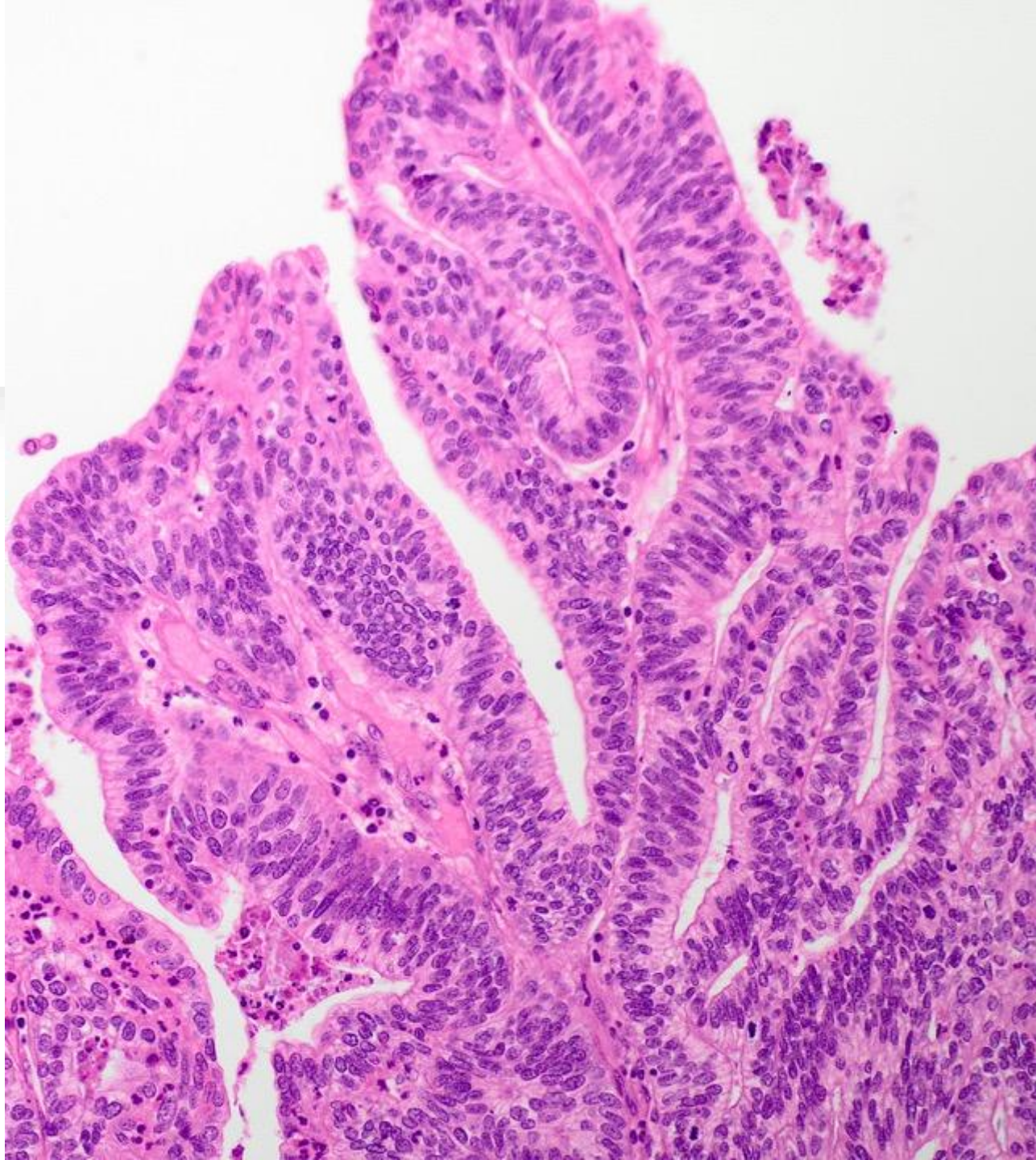

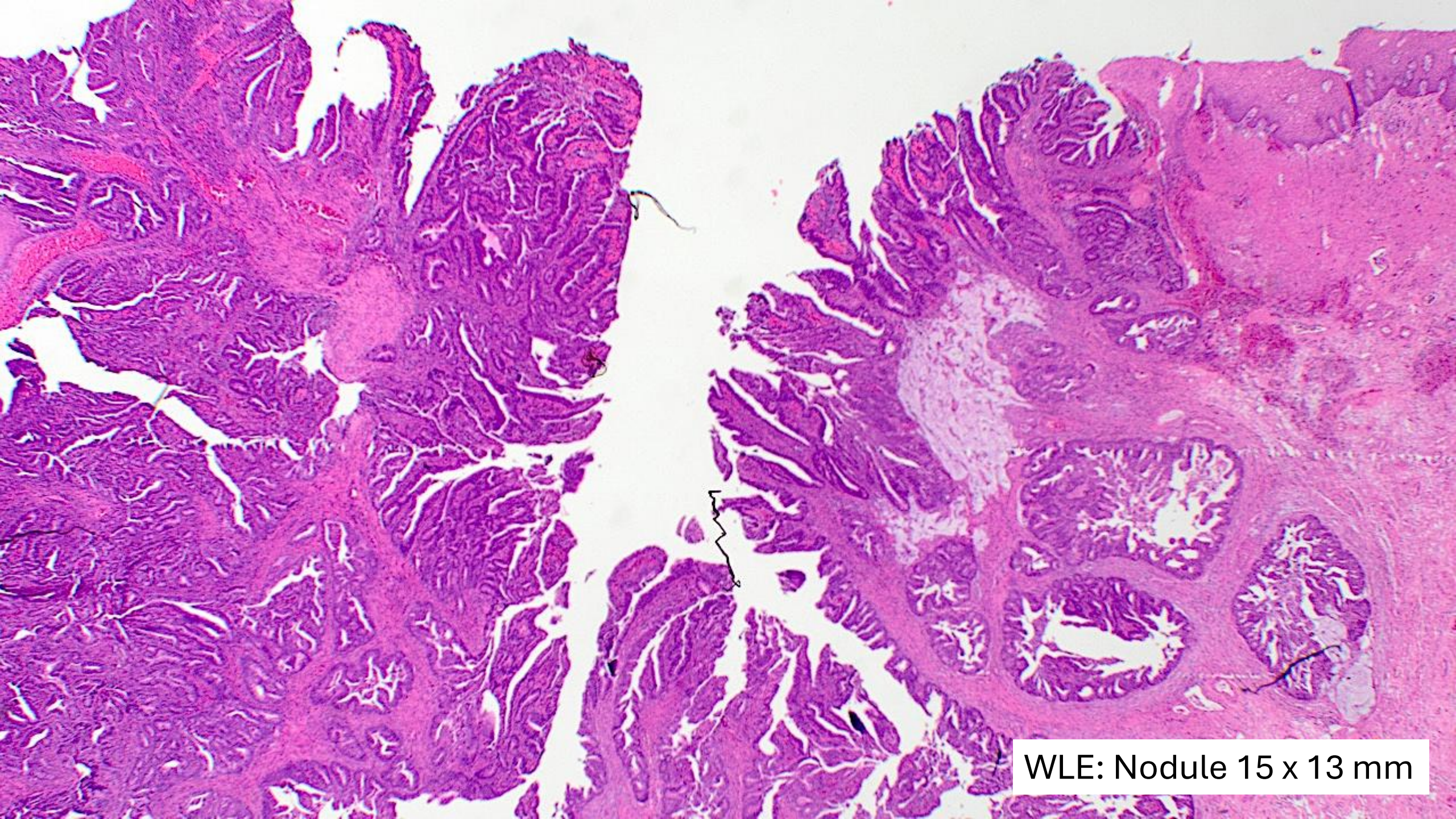
WLE: Nodule 15 x 13 mm

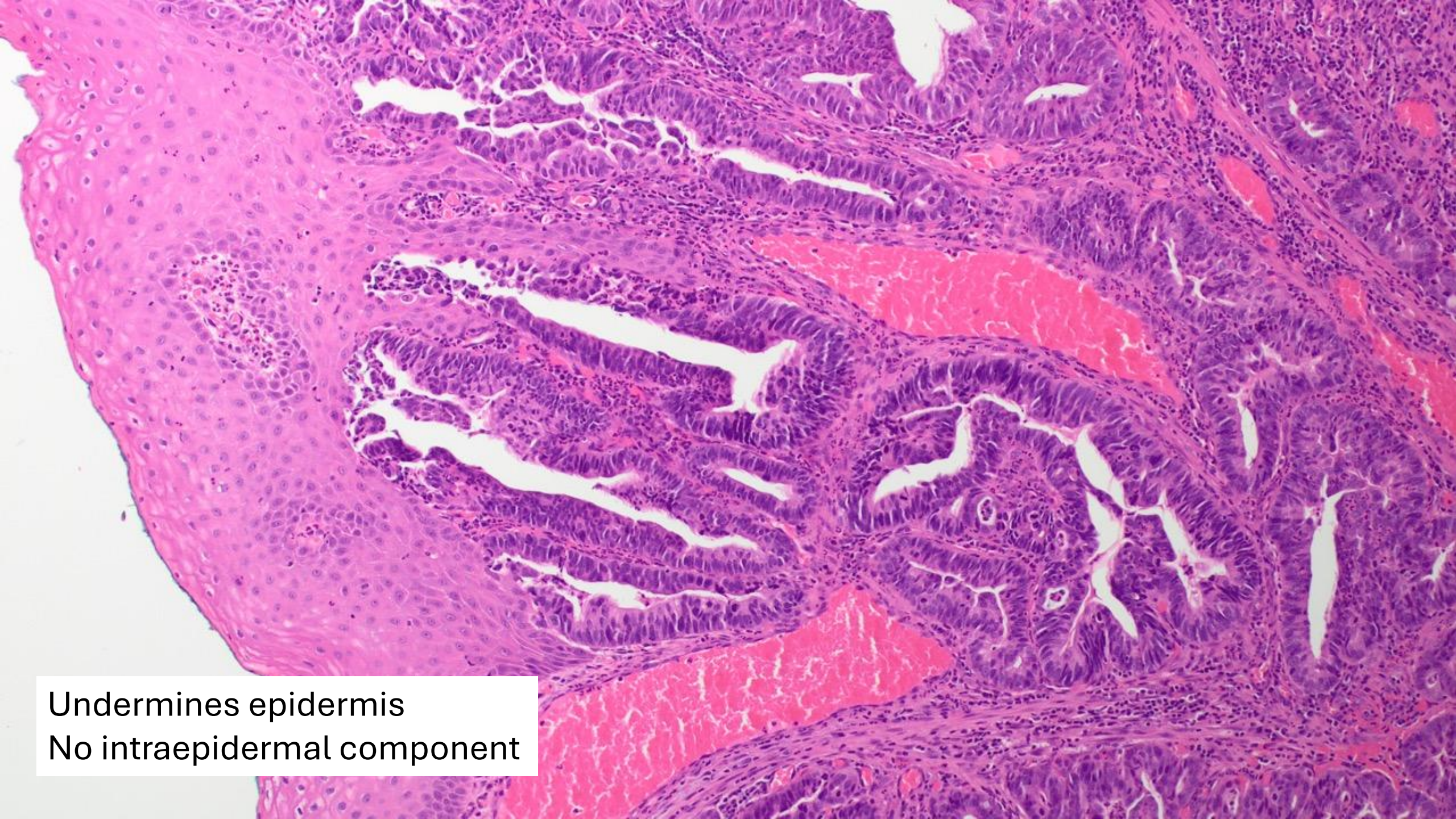
Undermines epidermis
No intraepidermal component

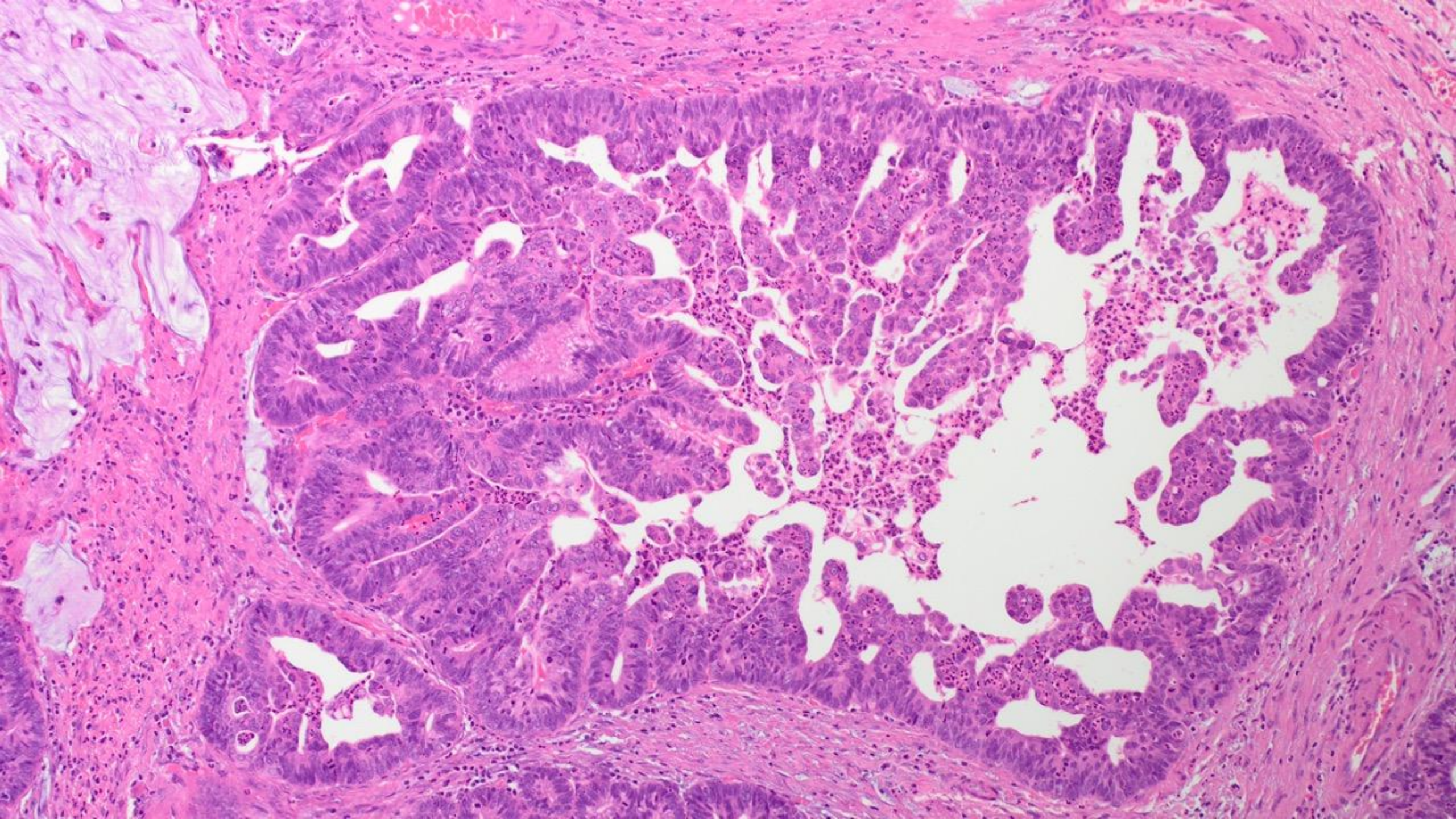

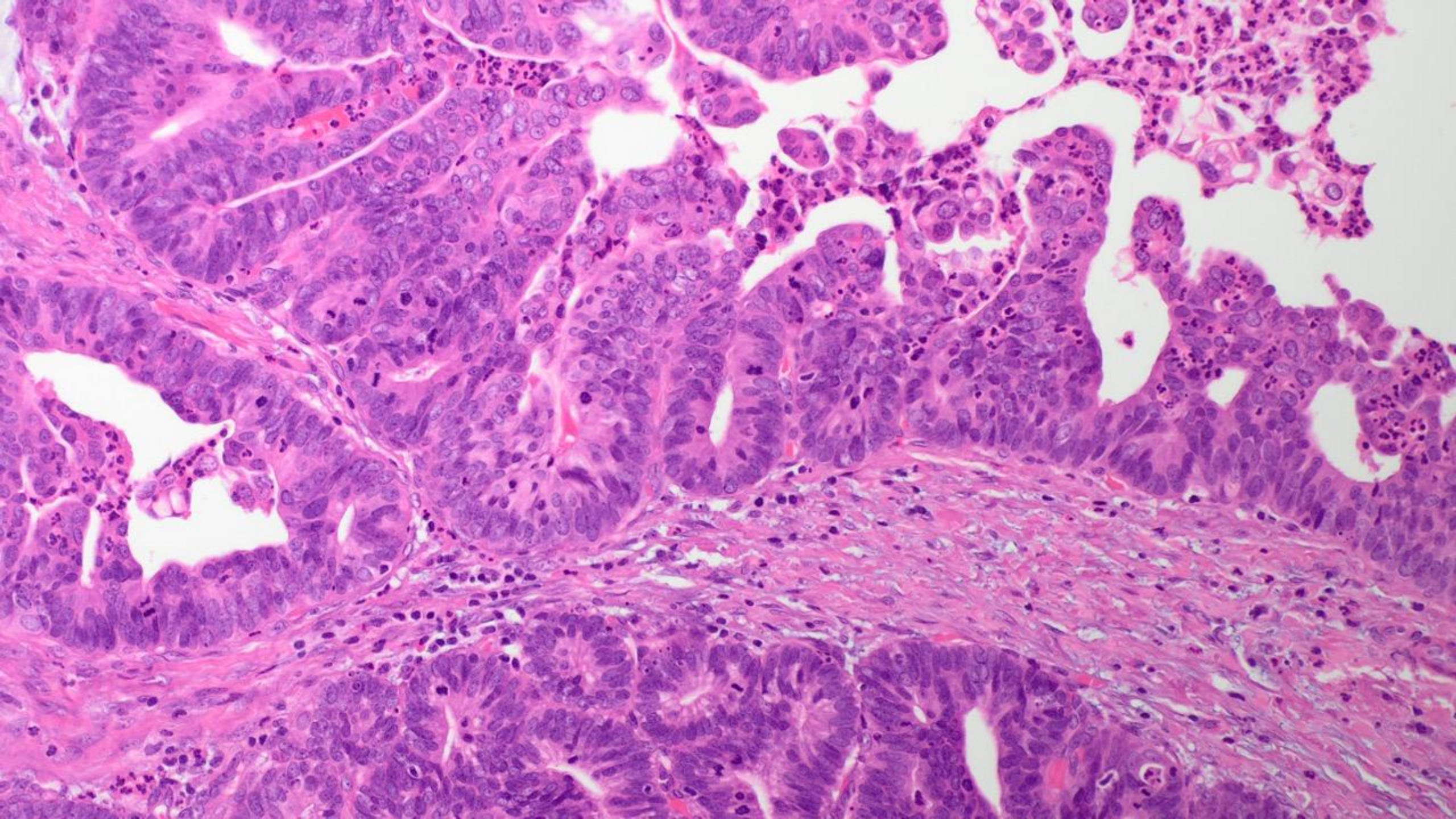

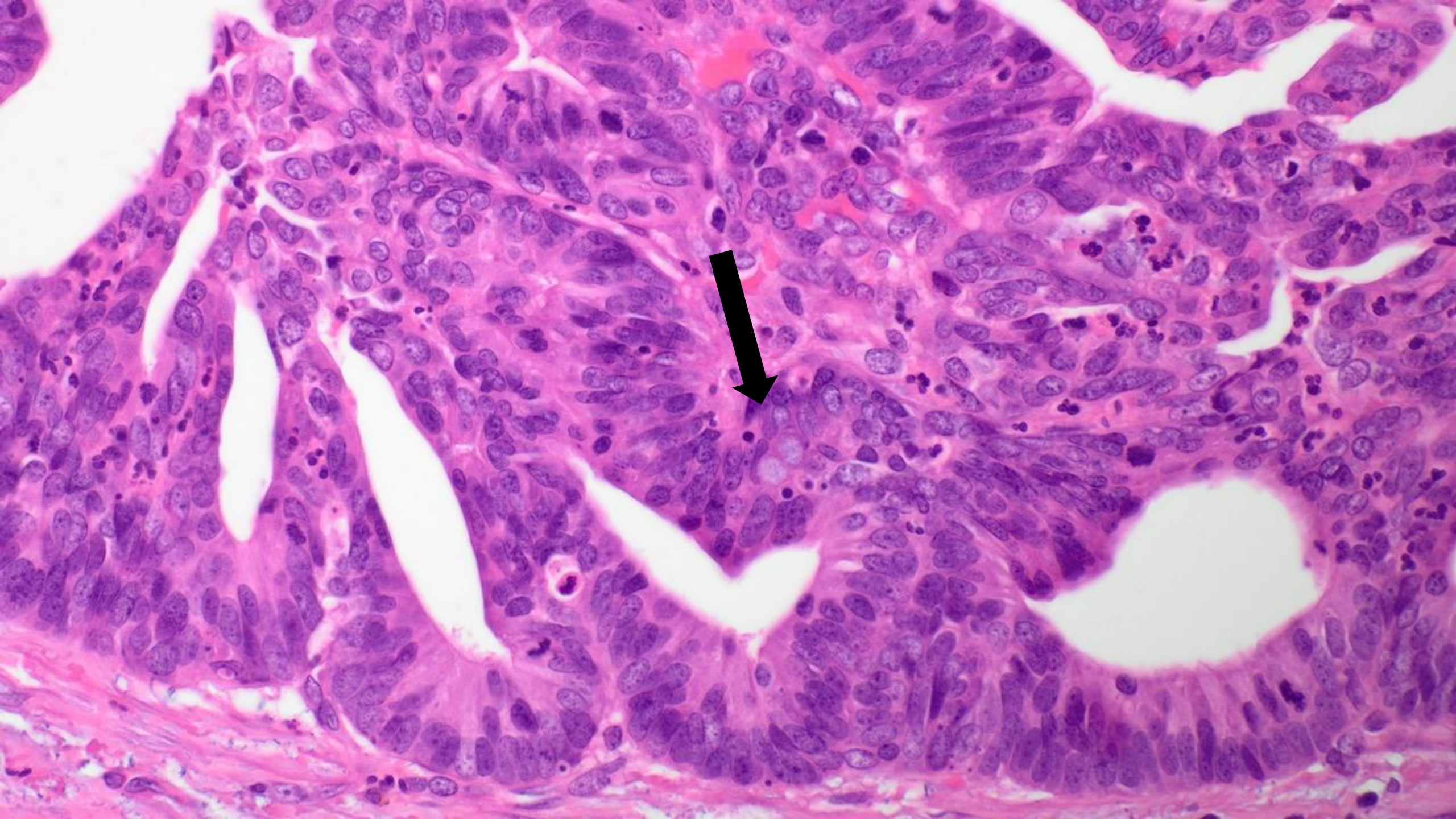

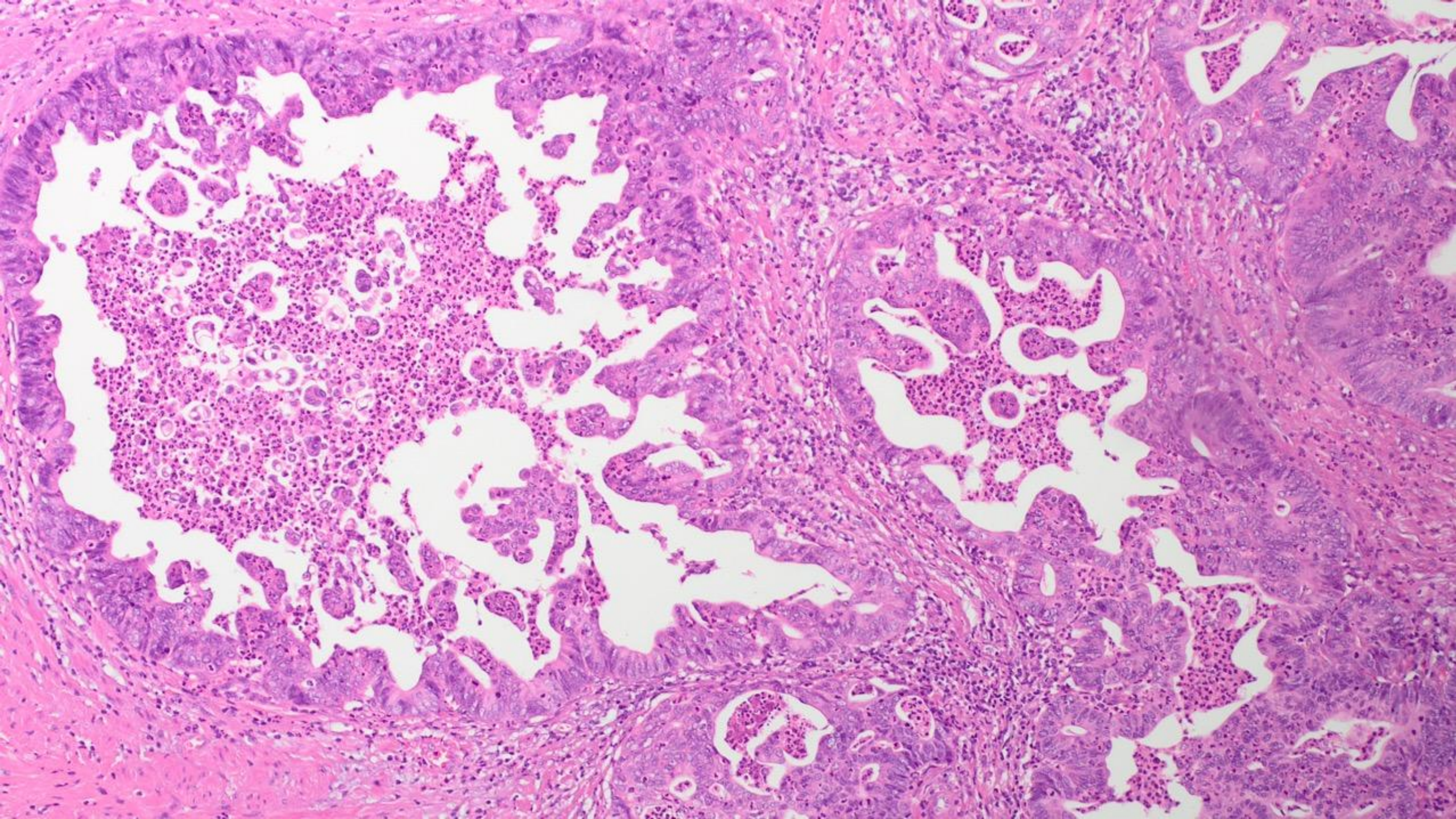

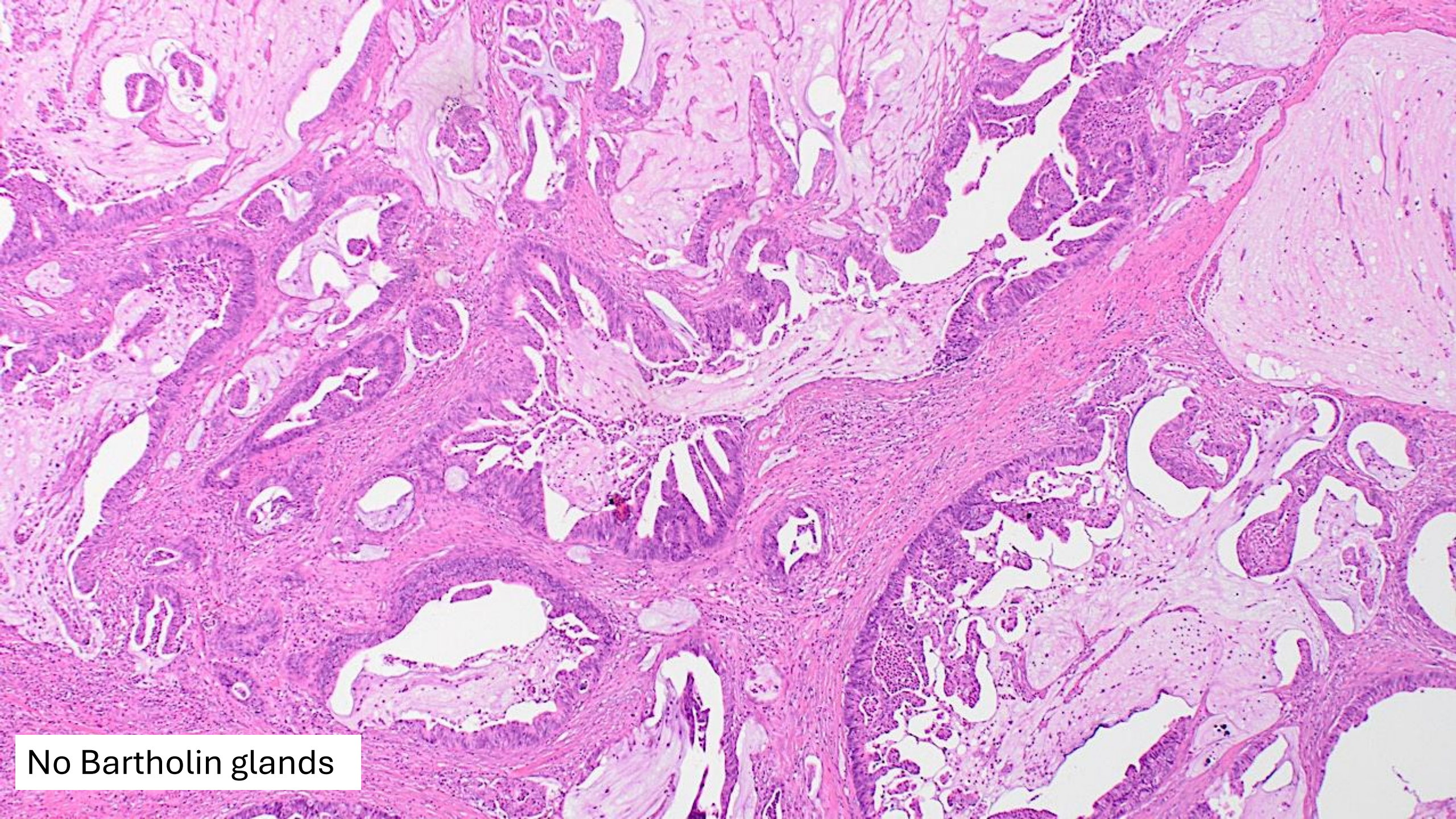
No Bartholin glands

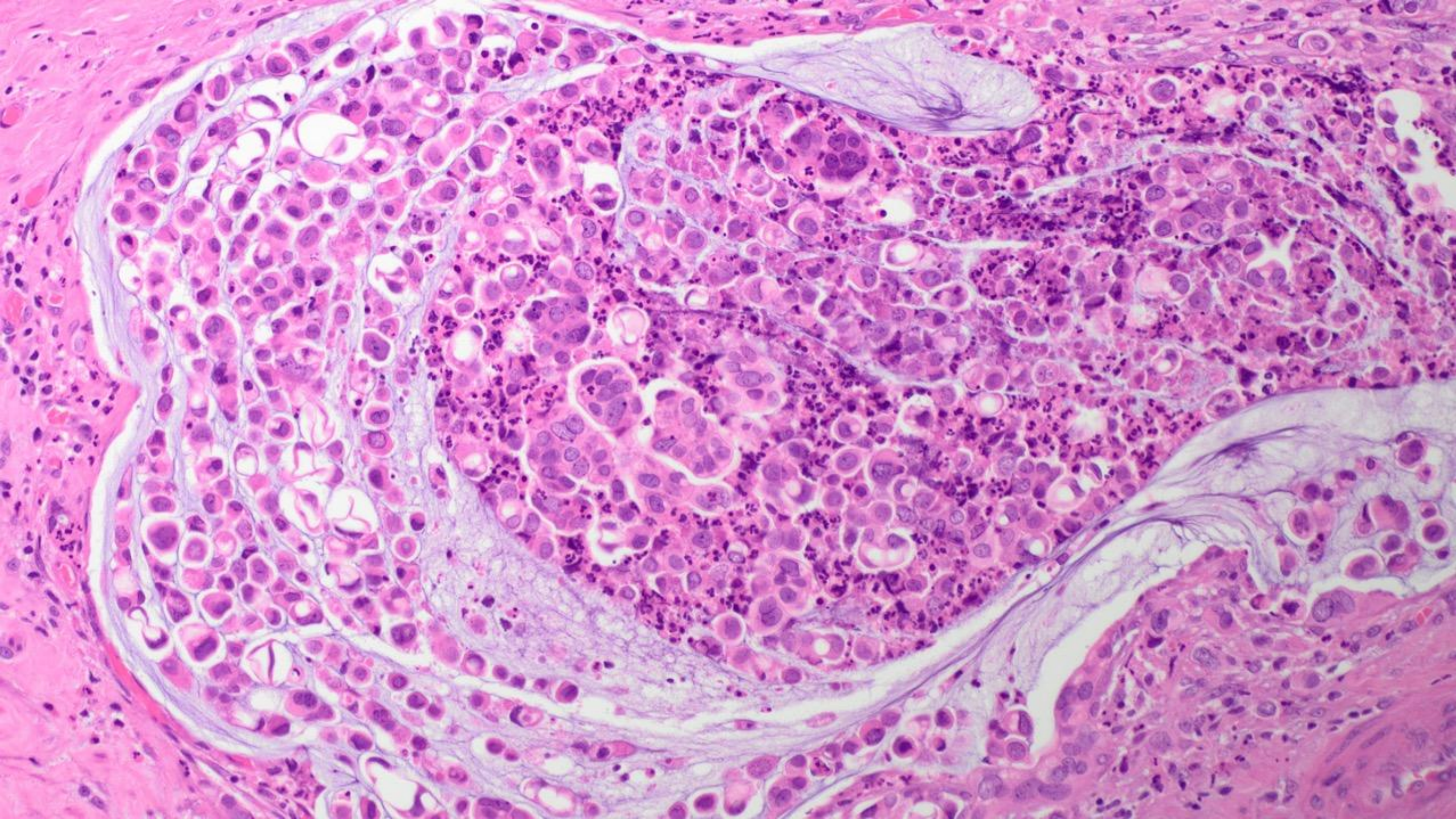

Diagnosis

Adenocarcinoma with intestinal-type morphology

- CK20/CEA/CDX2 positive; PAX8/ER/PR negative
- **No past or current history of GI neoplasia**; **endoscopy normal**
- Location “introitus” but no Bartholin glands identified

Possibilities:

- Bartholin gland adenocarcinoma
- Primary intestinal type adenocarcinoma

Bartholin gland carcinoma

Criteria for a Bartholin gland primary

- In the anatomical region of the Bartholin gland
- Histology compatible with Bartholin gland origin
- No alternative primary site identified
- Ideally, nearby non-neoplastic Bartholin gland tissue

Tumour types arise in Bartholin gland:

Squamous cell carcinoma **most common**

- Usually typical HPVA SCC – often poorly differentiated, basaloid

Adenocarcinoma #2 – usually mucinous NOS but also enteric, signet ring; HPVI

Carcinoma, poorly differentiated

Adenosquamous

Neuroendocrine carcinoma

Salivary - ACC, myoepithelial, epi–myoepithelial carcinoma

Desouki Sem Diagn Pathol 2021, Nazeran IJGP 2018

Adenocarcinoma of intestinal type

Primary **vulvar (and vaginal)** adenocarcinoma exhibiting intestinal differentiation

Superficially located, not in relation to another structure (Bartholin, Skene)

Identical to colorectal carcinoma

- Intestinal differentiation - goblet cells, neuroendocrine cells
- Tubulovillous architecture
- Occasionally serrated, mucinous features, signet ring cells, dirty necrosis
- Diffuse **CK20, CDX2, CEA,** CK7±, ER/PR, p16 negative

Desouki Sem Diagn Pathol 2021, Trecourt Mod Pathol 2025

Adenocarcinoma of intestinal type

Unanswered questions

Origin? Embryological cloacal remnants

Displaced GI epithelium - fistula/perineal laceration after vaginal delivery

Intestinal metaplasia - squamous epithelium / adnexa / Müllerian glands

Histogenesis? Associated tubulovillous adenomas (like colorectal) vulva and vagina - ?adenoma-carcinoma sequence

Unclear histogenesis impacts treatment – female genital or colorectal type therapy?

Desouki Sem Diagn Pathol 2021, Trecourt Mod Pathol 2025

Primary Vulvar and Vaginal Adenocarcinomas of Intestinal Type Are Closer To Colorectal Adenocarcinomas Than To Carcinomas of Müllerian Origin

Alexis Trecourt[a,b], Isabelle Treilleux[c], Daniel Pissaloux[c], Marie Donzel[a,d], Brice Thamphya[c], Franck Thirode[c], Aurélie Houlier[c], Sandrine Paindavoine[c], Tatiana Franceschi[c], Aline Baltrès[c], Witold Gertych[e], Pierre-Adrien Bolze[e], Pierre Antoine Chaix[f], Charlotte Roux-Terrier[g], Françoise Descotes[h], Isabelle Ray-Coquard[i,j], Jonathan Lopez[h,i], Mojgan Devouassoux-Shisheboran[a,b,i,*]

Mod Pathol 2025

4 vulval, 4 vaginal intestinal type adenocarcinoma
IHC, HPV ISH, DNA and RNA sequencing, clustering analysis

AIM: Clarify histogenesis

IHC and molecular analysis of 8 tumours, 4 vulval and 4 vaginal

CK20 100%, **CDX2** 100%, **SATB2** 62.5%, **CK7** 82.5%, CK20 >> CK7 (some focal)

PAX8, ER, PR, p16, SOX17: ALL negative
p53 abn in 75%, **MMR** ALL proficient, **HRHPV ISH:** ALL negative

Pathogenic variants: ***TP53*** (5/7) > ***KRAS*** (3/7), *ATM / STK11 / RAD51D / PTEN* (1 case each)

Clustering analysis:
Closer to colorectal than a range of other tumour types
Don’t cluster with cervical adenocarcinoma mimics (HPVA and HPVI)

Comparing macro, location

- **Vulval** vestibule, near vaginal opening

- **Vaginal** are distal, close to vestibule

- Mucosal based polyp/ulcerated

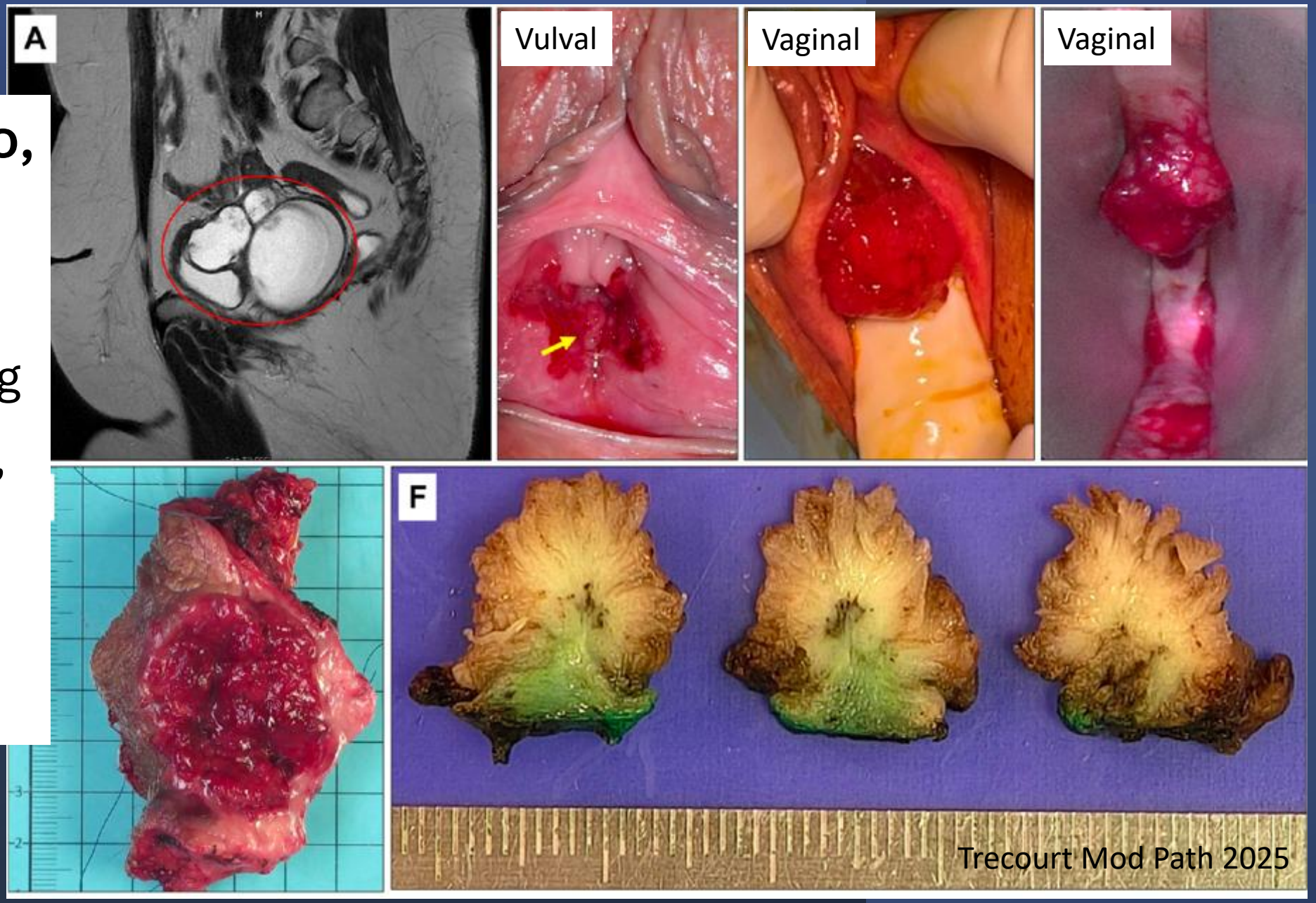

Primary Vulvar and Vaginal Adenocarcinomas of Intestinal Type Are Closer To Colorectal Adenocarcinomas Than To Carcinomas of Müllerian Origin

Alexis Trecourt[a,b], Isabelle Treilleux[c], Daniel Pissaloux[c], Marie Donzel[a,d], Brice Thamphya[c], Franck Thirode[c], Aurélie Houlier[c], Sandrine Paindavoine[c], Tatiana Franceschi[c], Aline Baltrès[c], Witold Gertych[e], Pierre-Adrien Bolze[e], Pierre Antoine Chaix[f], Charlotte Roux-Terrier[g], Françoise Descotes[h], Isabelle Ray-Coquard[i,j], Jonathan Lopez[h,i], Mojgan Devouassoux-Shisheboran[a,b,i,*]

Mod Pathol 2025

4 vulval, 4 vaginal intestinal type adenocarcinoma
IHC, HPV ISH, DNA and RNA sequencing, clustering analysis

Conclusions

Closer to colonic than Müllerian adenocarcinoma

Morphology, immunophenotype identical

Similar gene alterations *TP53* and *KRAS* although no MMRd

Vulval/vaginal likely a single entity, should be grouped together

Must exclude a colorectal primary – colonoscopy, imaging

Mostly indolent behaviour in reported cases

Staats AJSP 2014, Dellino Cancers 2022, He EJGO 2015

Case 5

83yo

Clinical history:

Biopsy-proven SCC vulva

Procedure:

Hemi-vulvectomy

Bilateral inguinal sentinel lymph node dissection

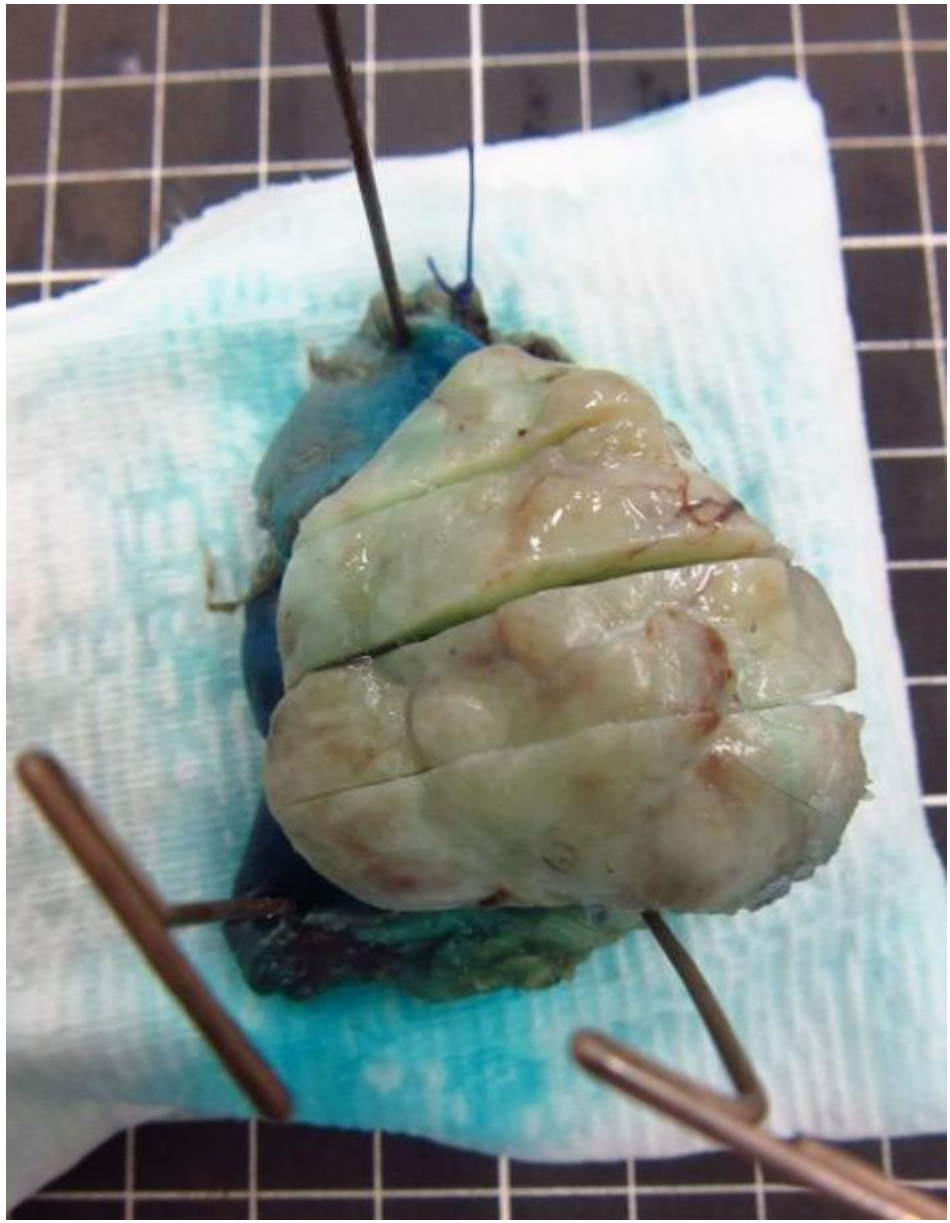

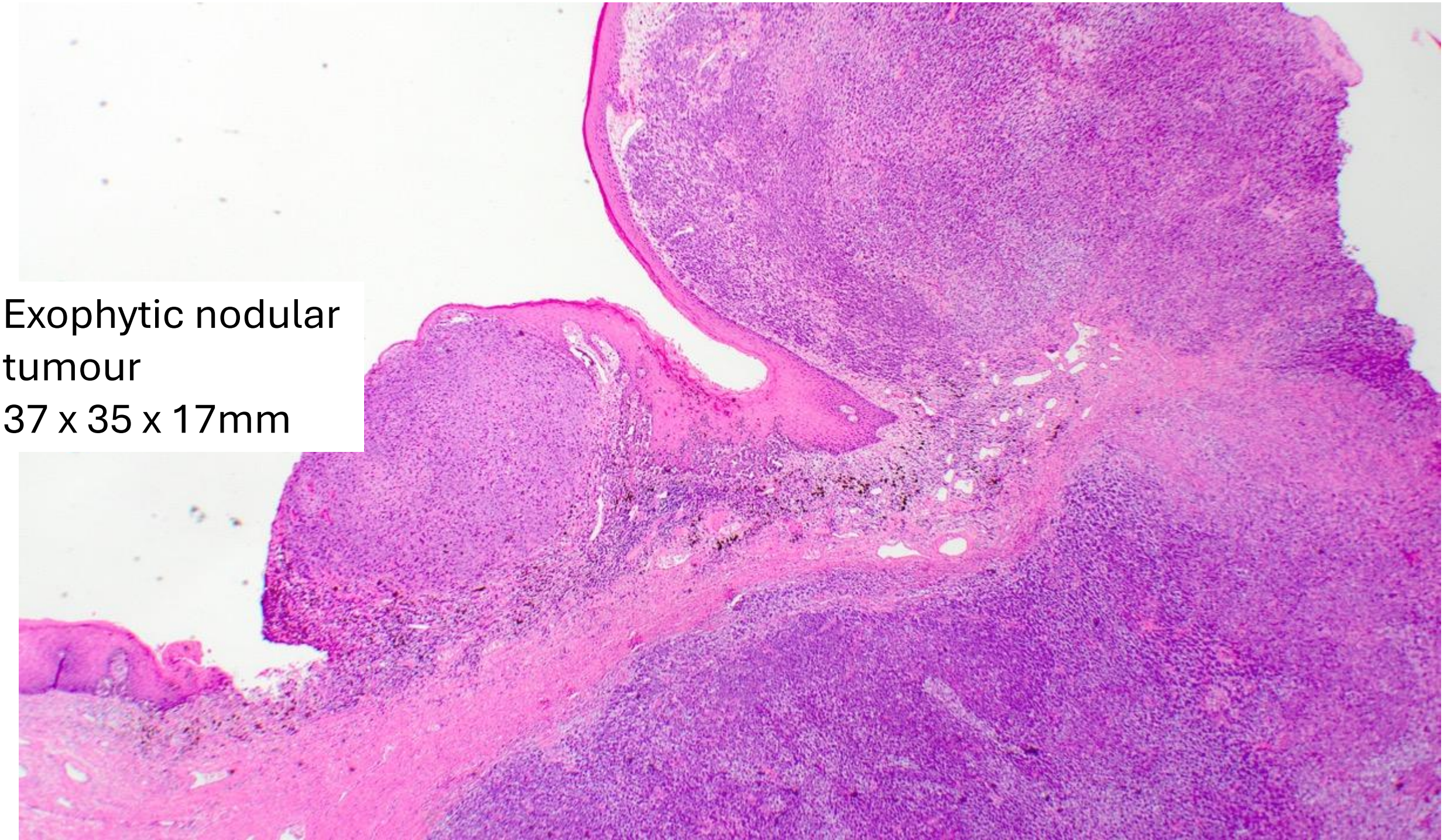
Exophytic nodular tumour
37 x 35 x 17mm

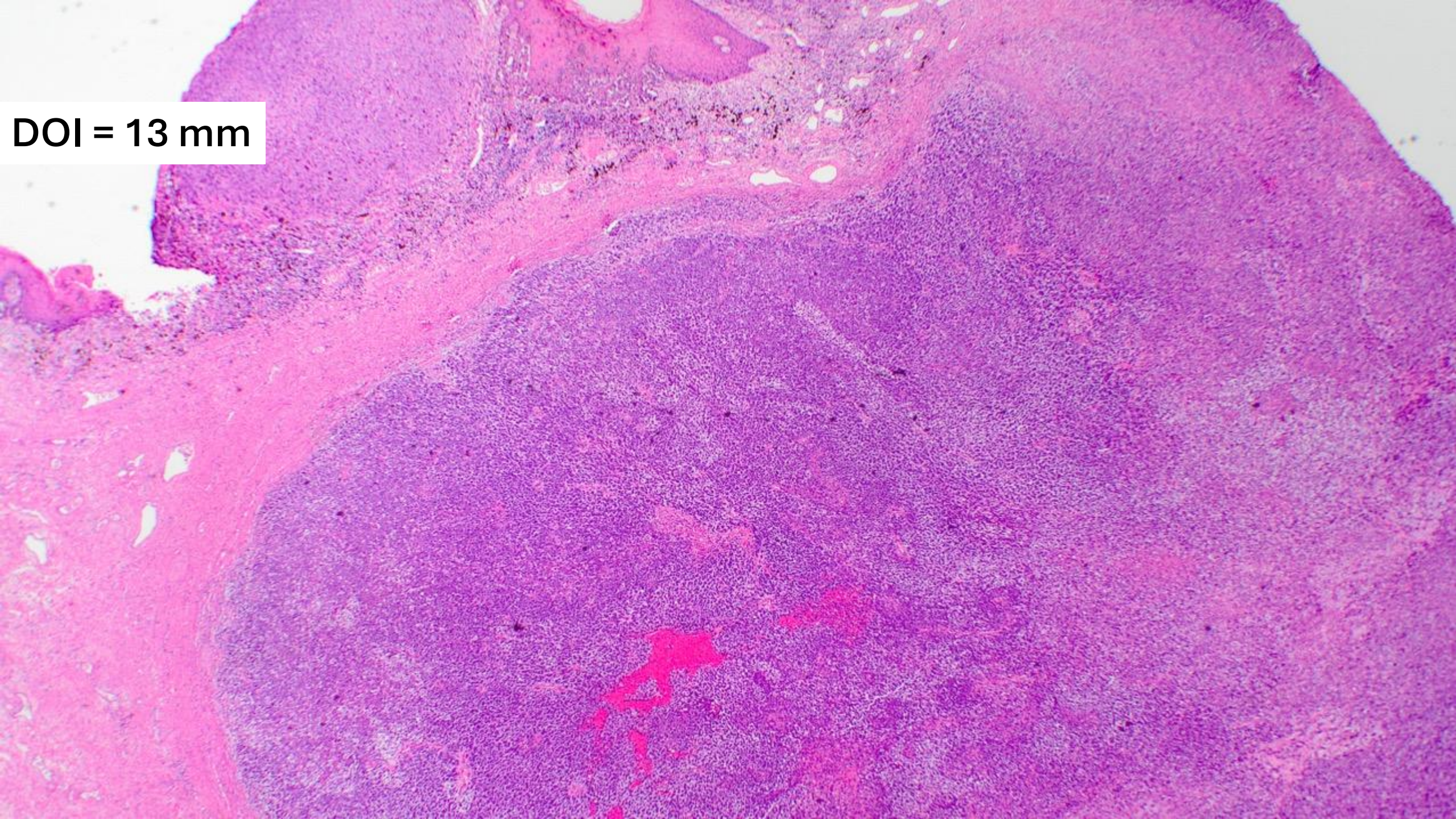
DOI = 13 mm

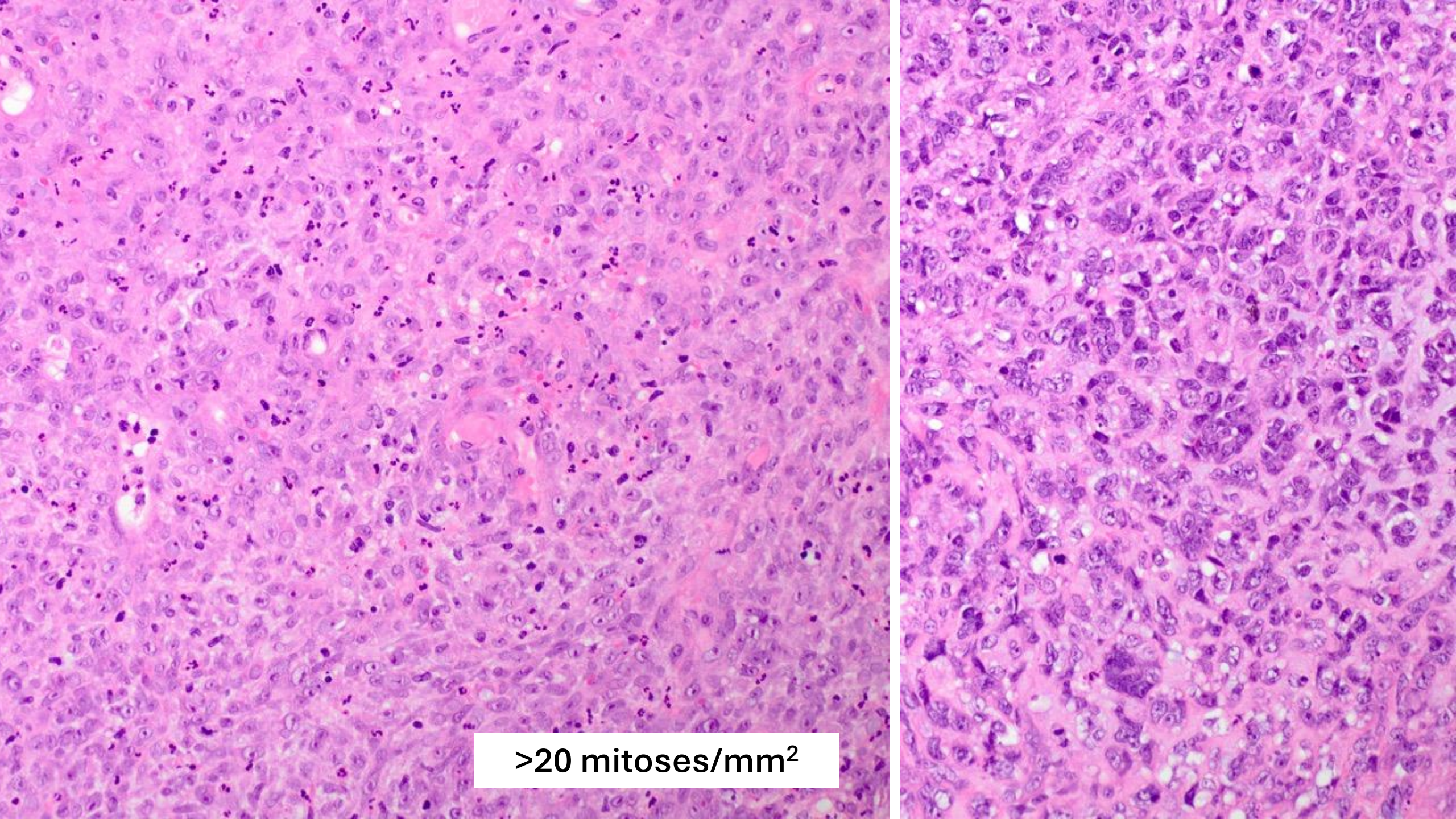
>20 mitoses/mm²

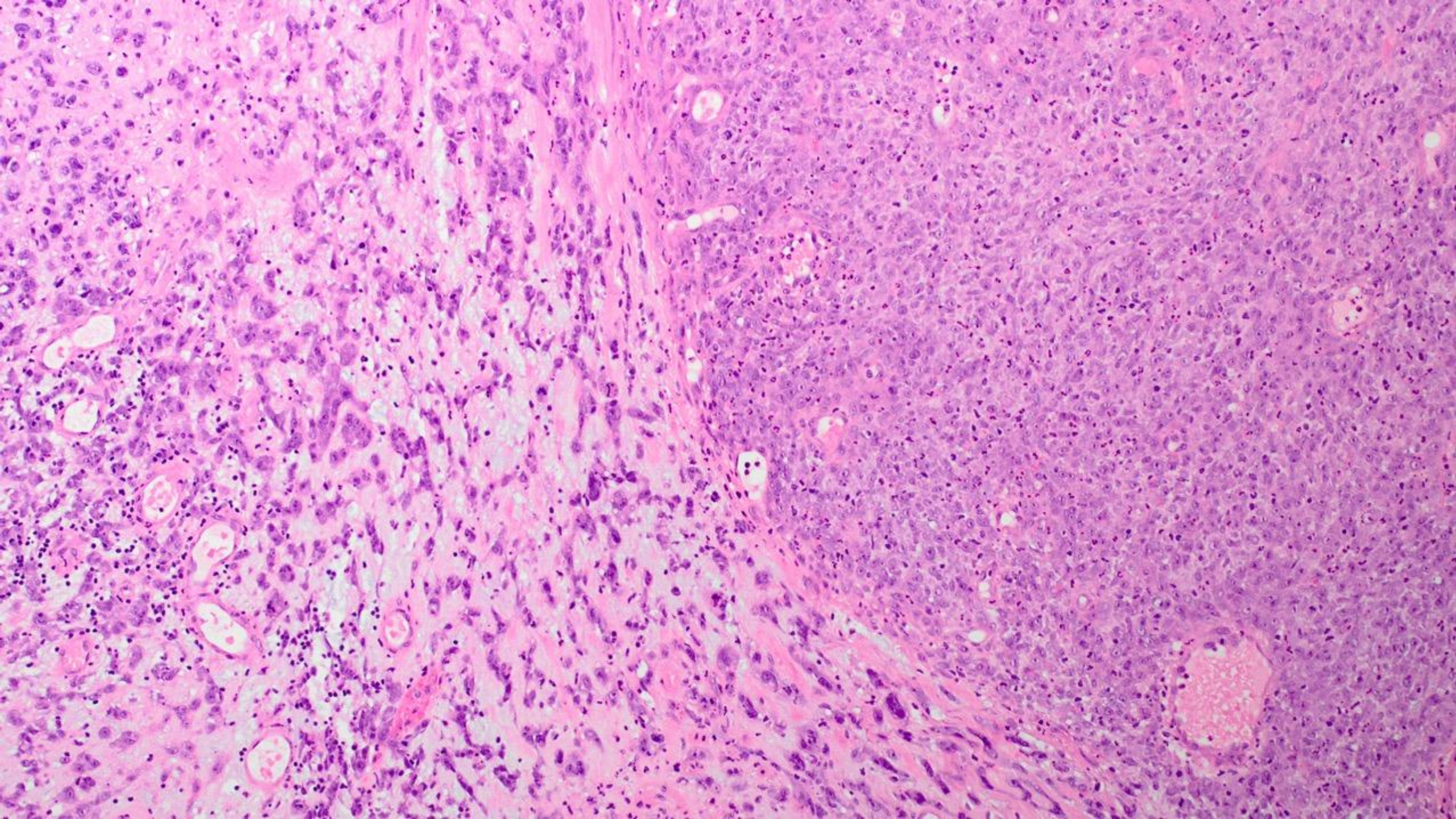

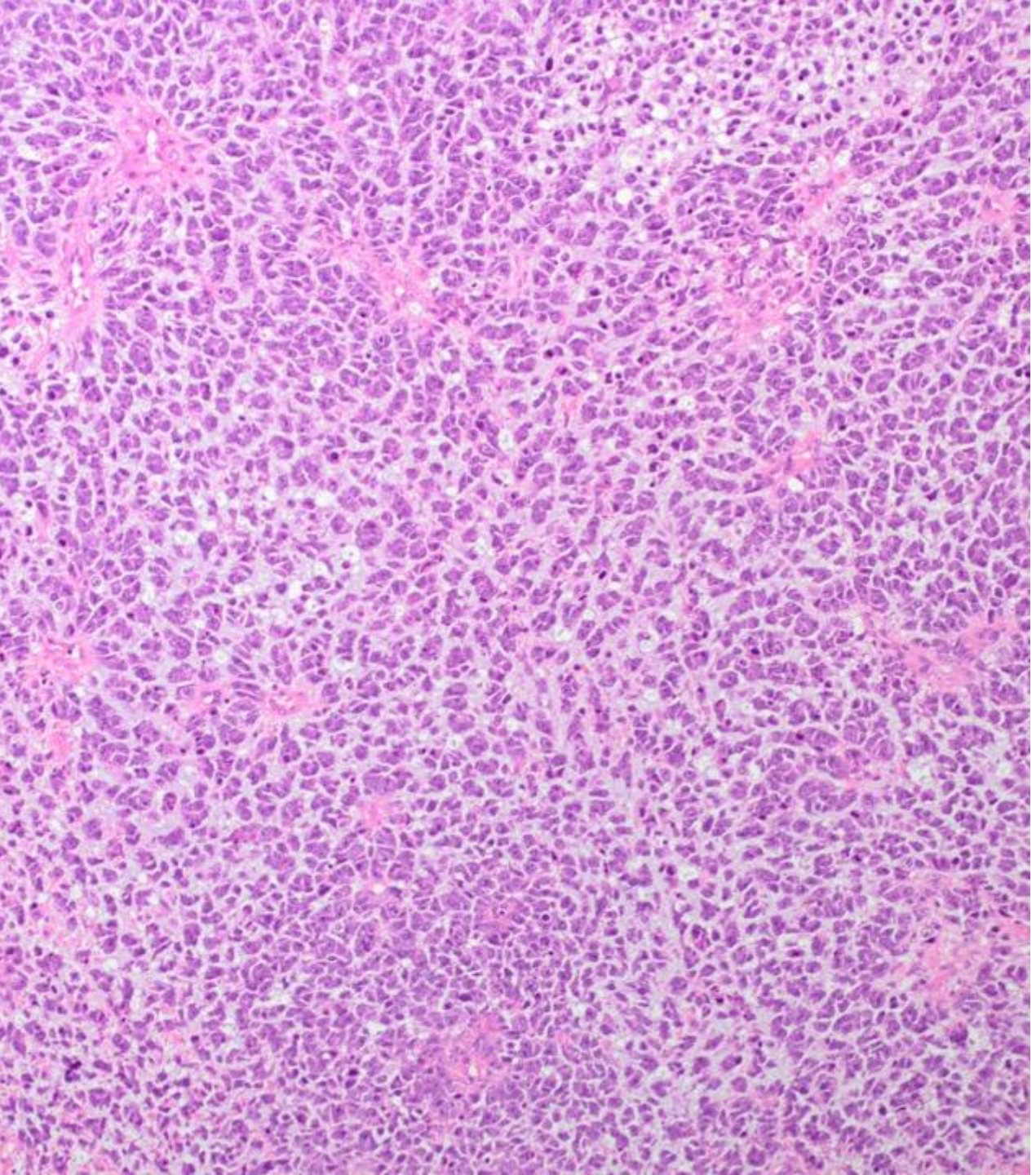

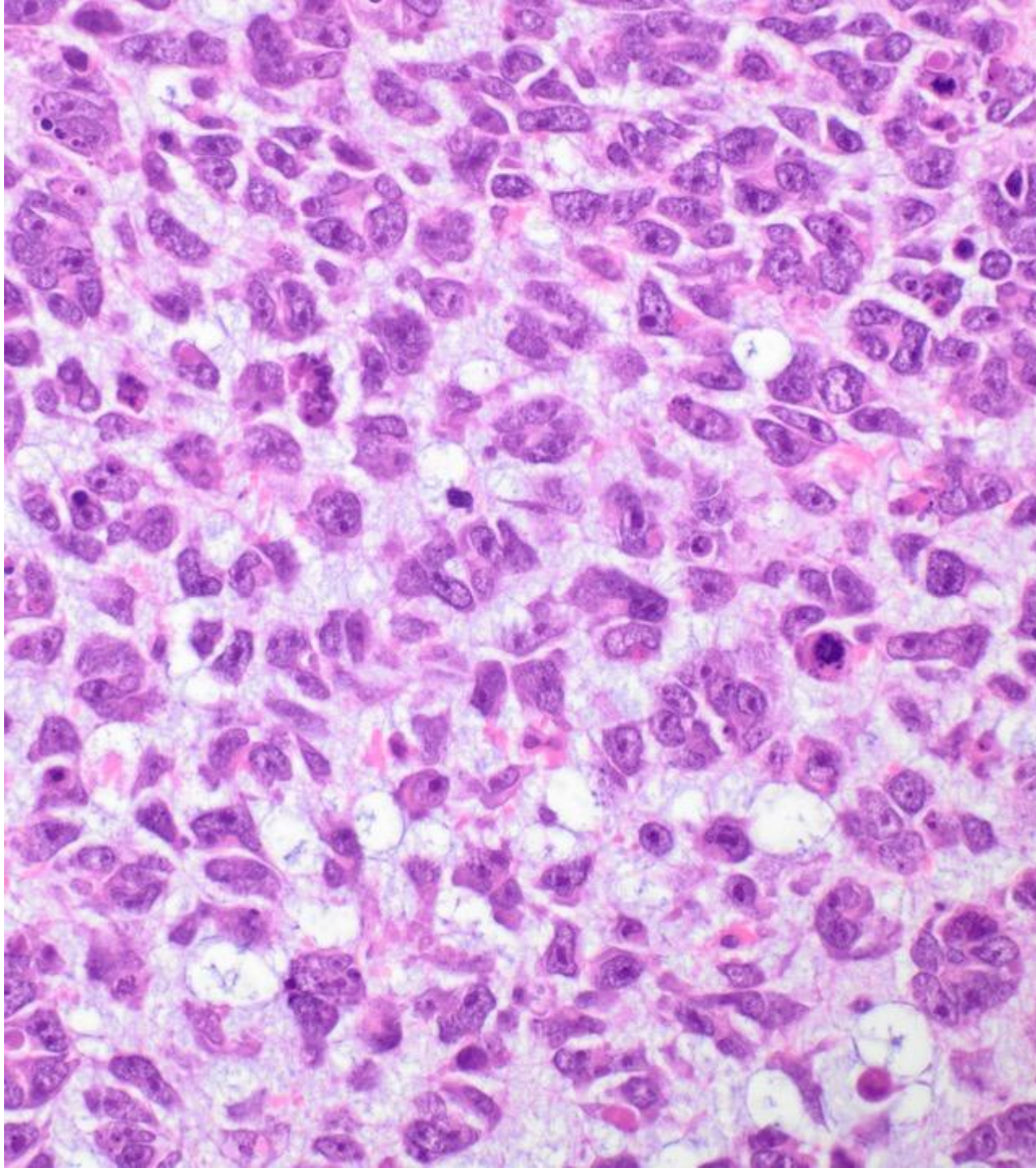

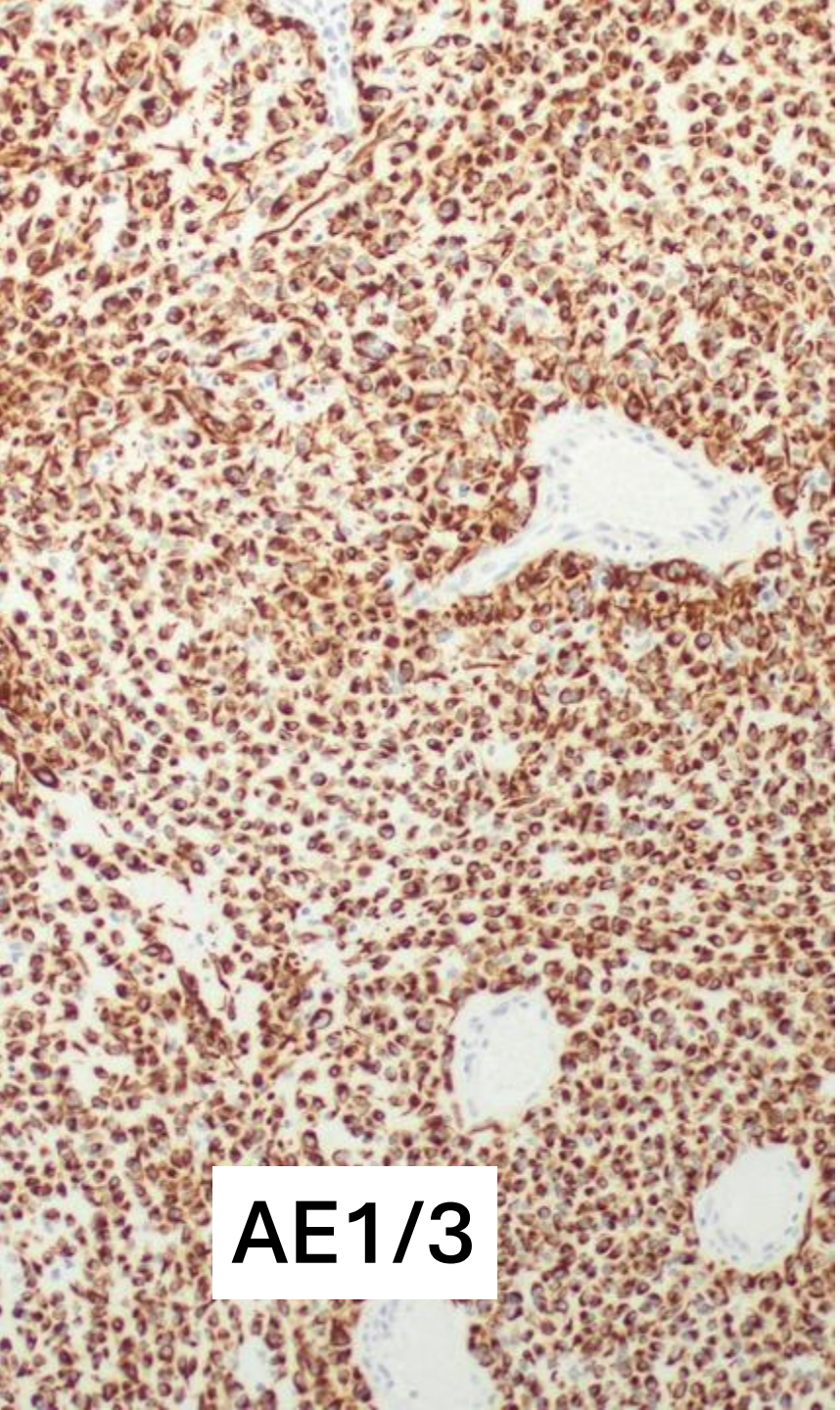
AE1/3

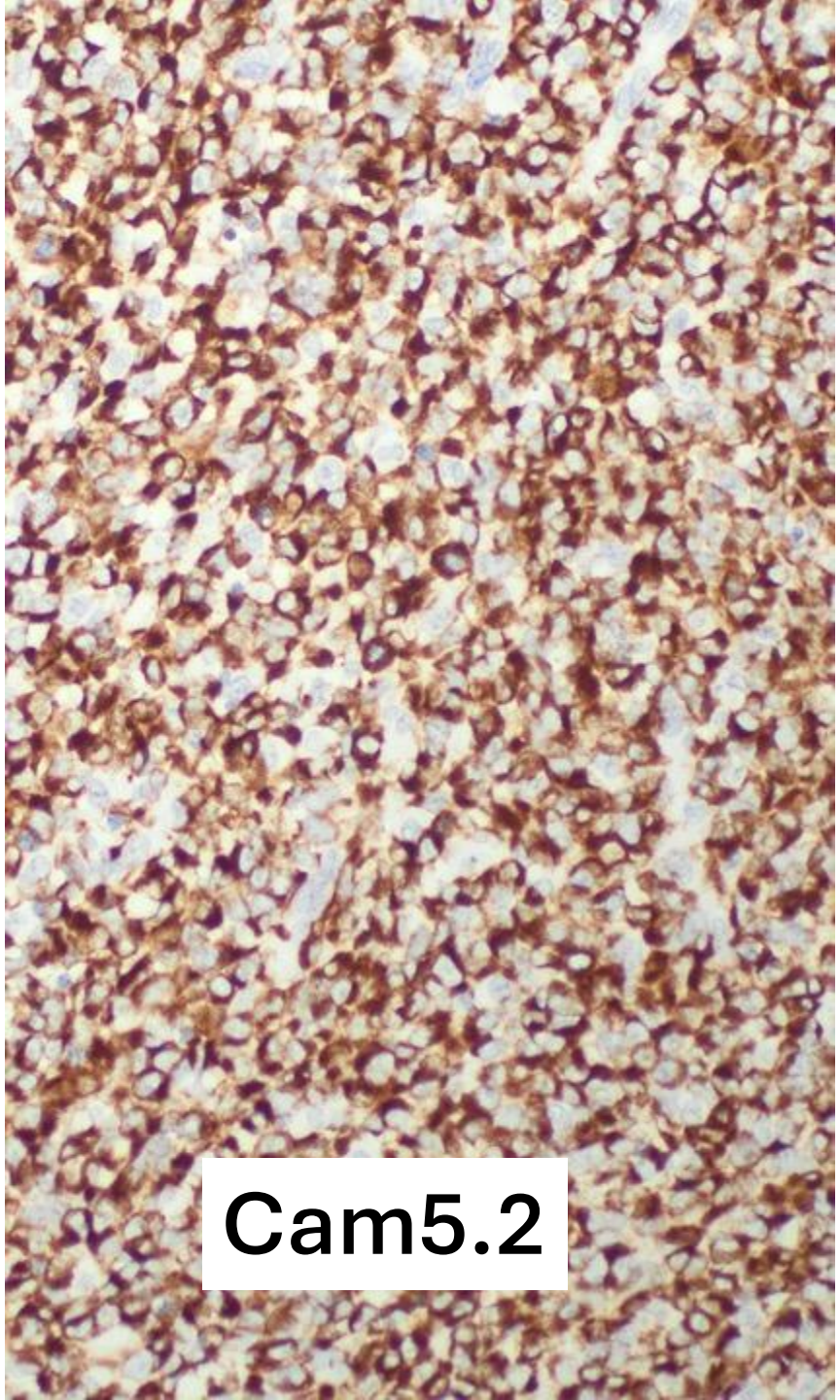
Cam5.2

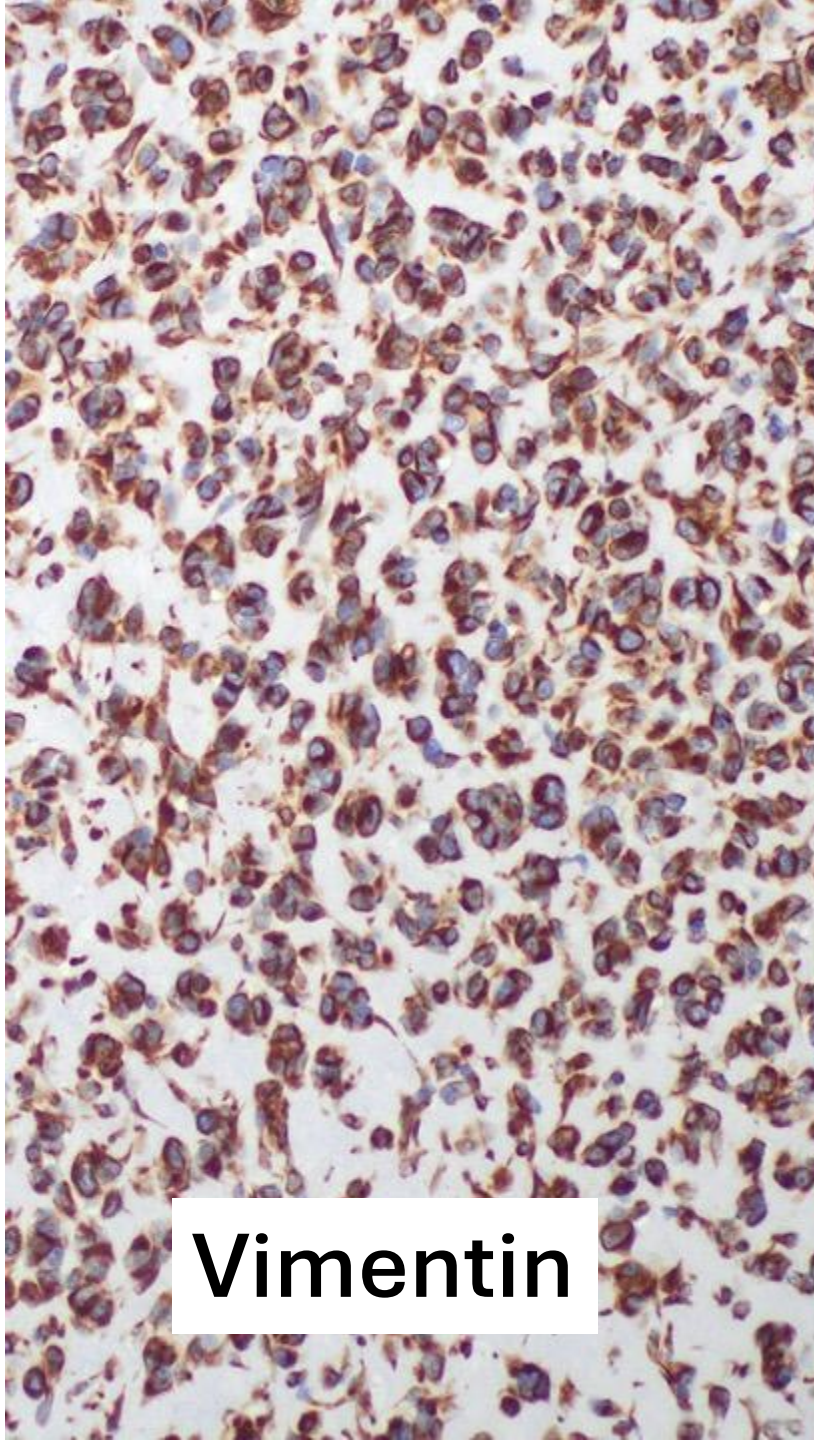
Vimentin

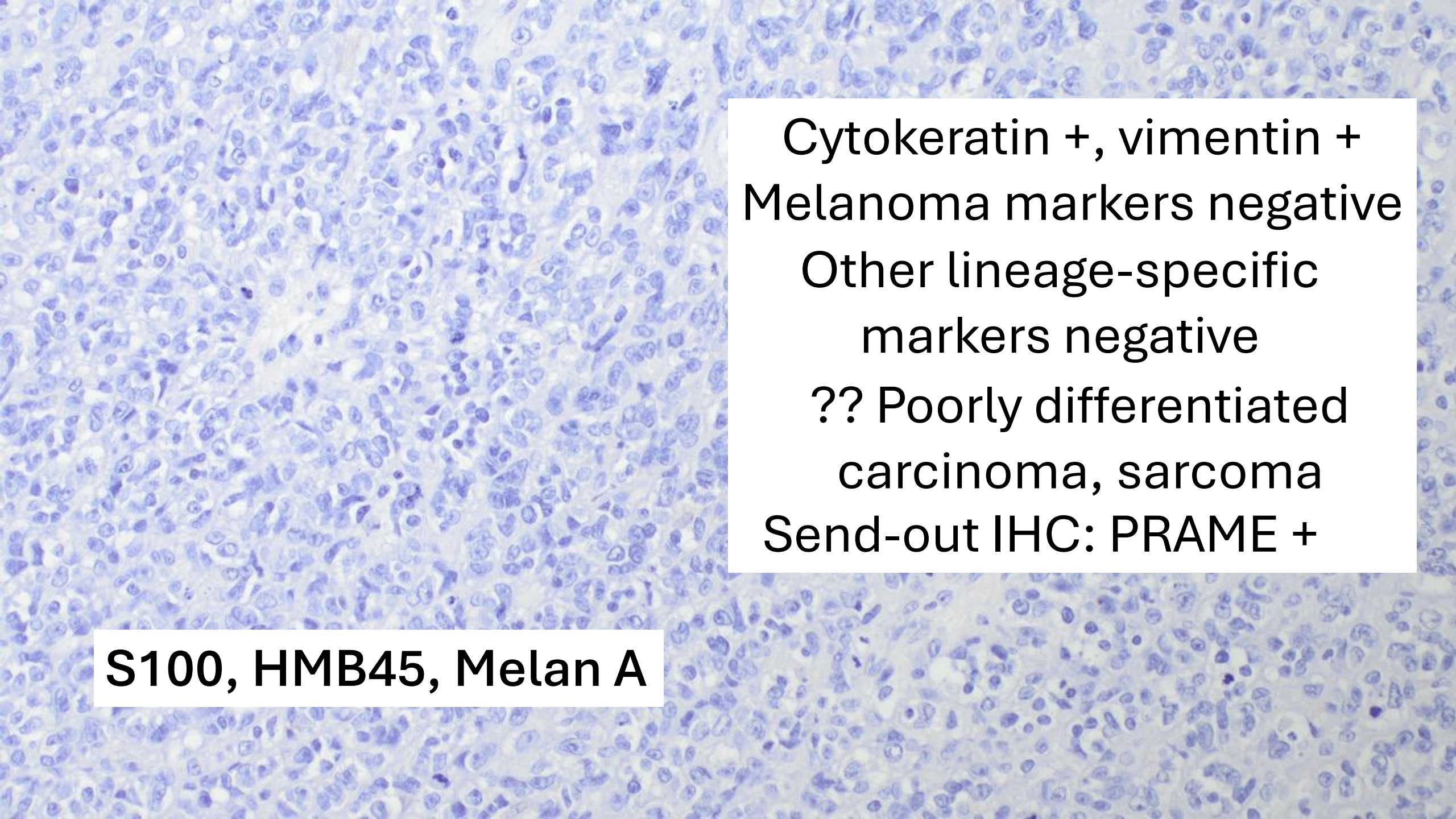
Cytokeratin +, vimentin +
Melanoma markers negative
Other lineage-specific markers negative
?? Poorly differentiated carcinoma, sarcoma
Send-out IHC: PRAME +
S100, HMB45, Melan A

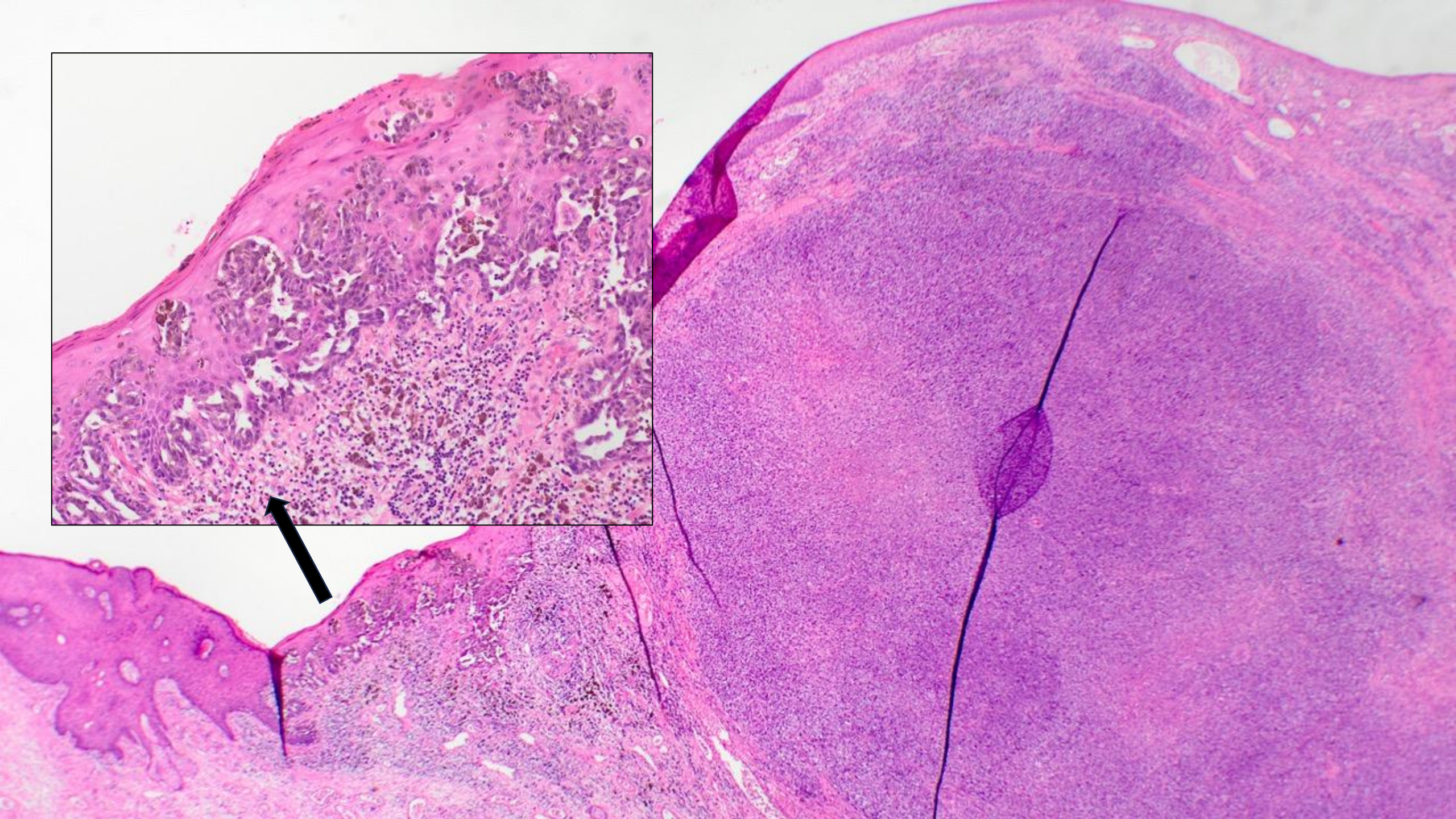

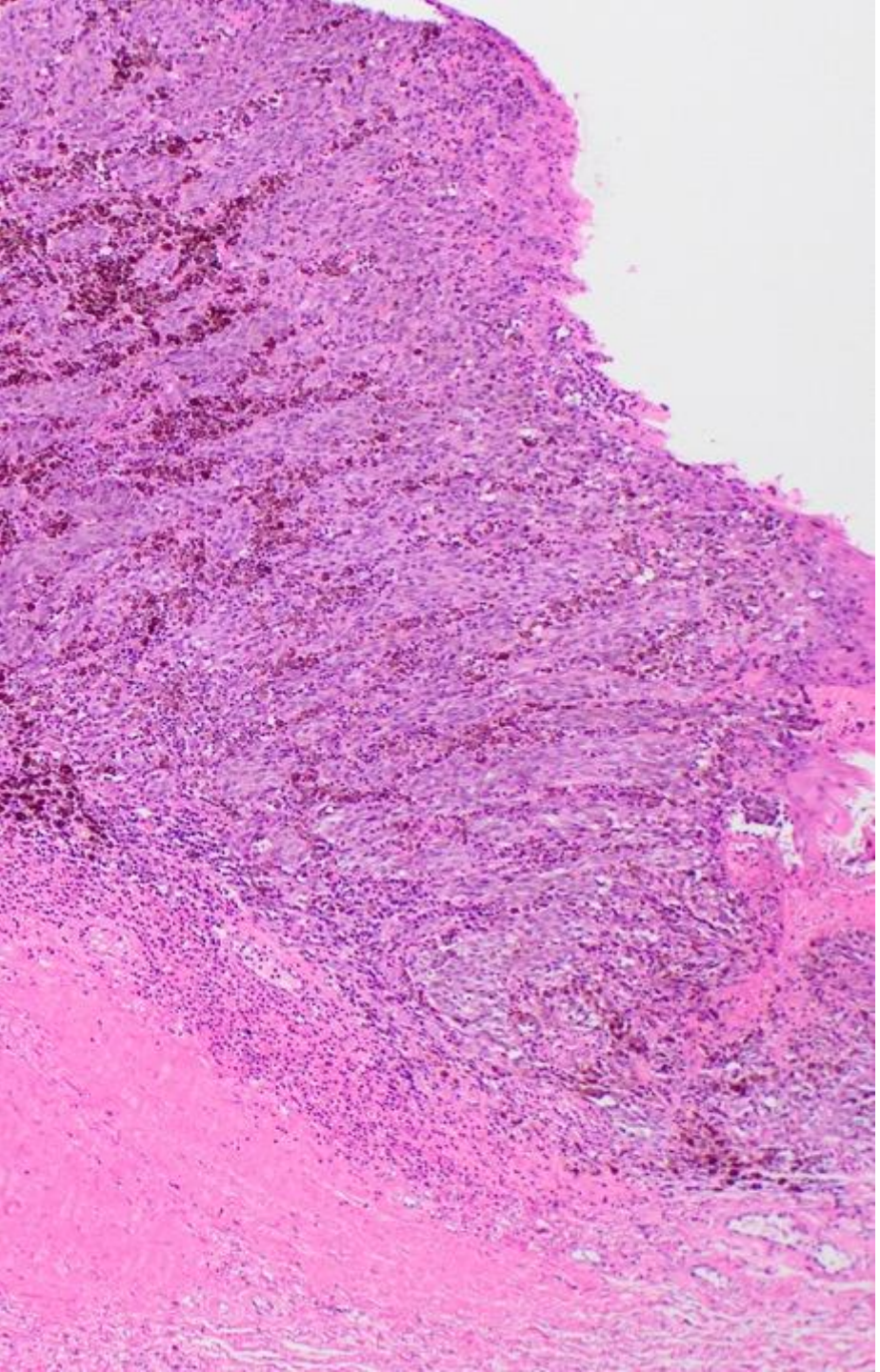

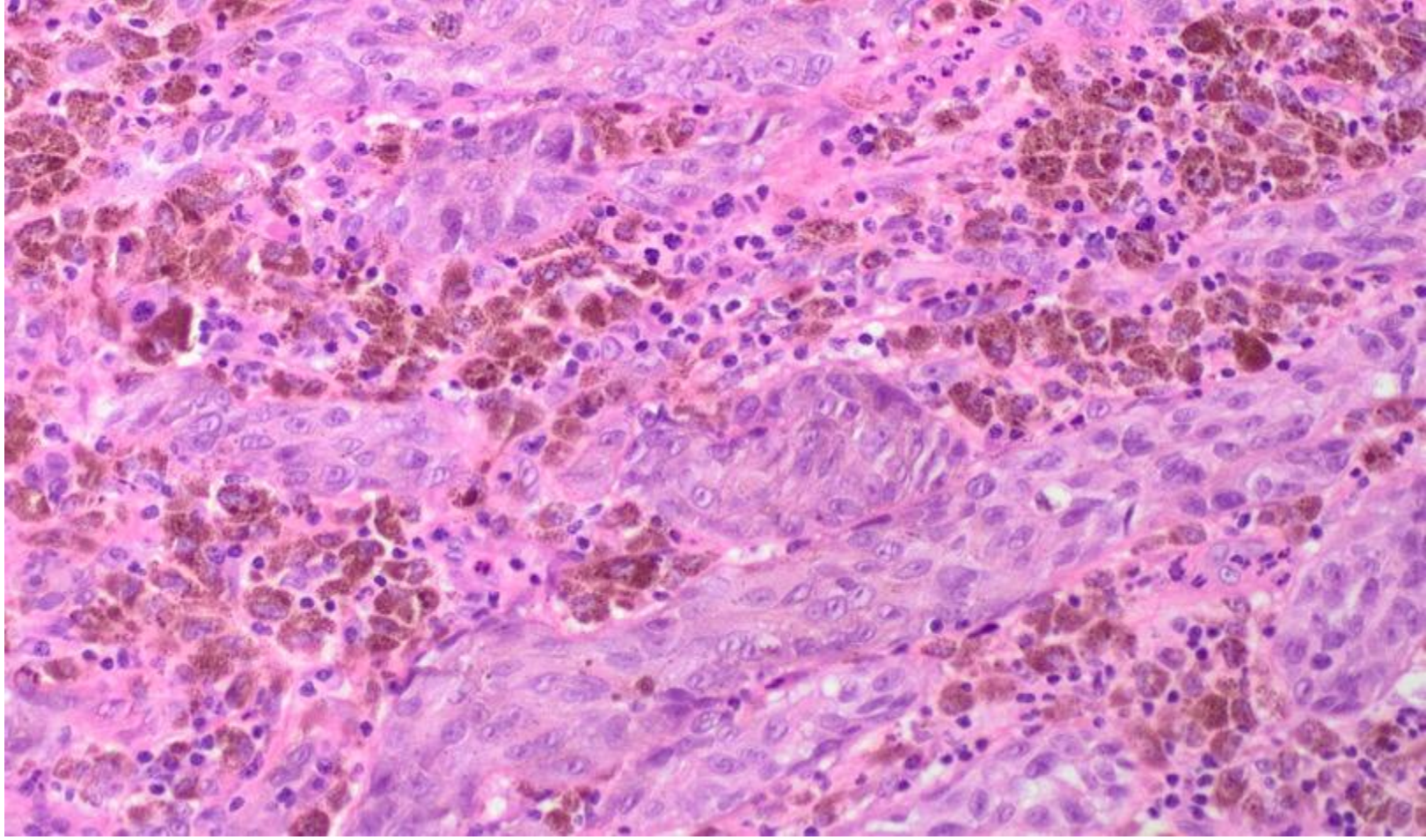

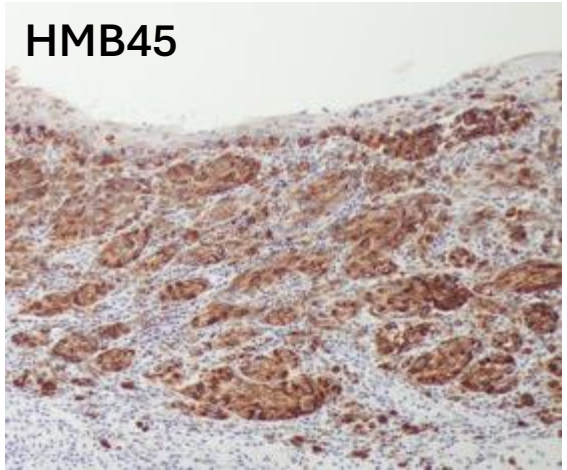
HMB45

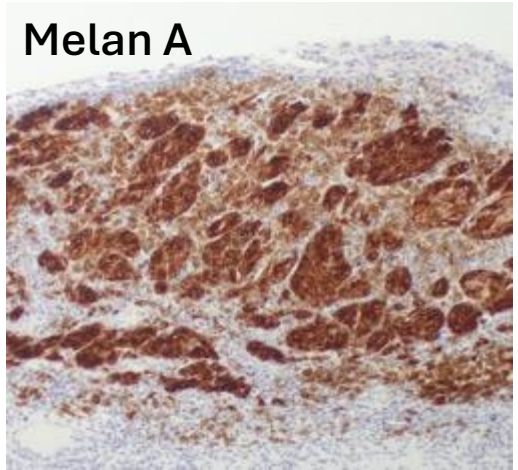
Melan A

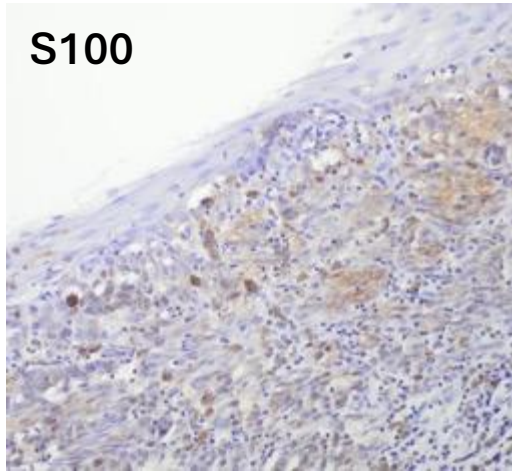
S100

Diagnosis

Conventional melanoma component - in situ and invasive

Dominant undifferentiated melanoma – loss of melanoma markers

→ **Dedifferentiated melanoma**

Mucosal melanoma

- **Vulva, vagina, urethra; rarely cervix**
- Vulval sites: **Labia majora** > minora > clitoris, often multifocal
- Postmenopause; pigmented or amelanotic
- Aetiology unknown; **no link to UV** radiation
- **Distinct molecular profile** cf. cutaneous
  - Low mutational burden; numerous chromosomal variants, copy number changes
  - **Lacks UV signature**
  - Fewer *BRAF* mutations; *NRAS, KIT* common

Survival relatively poor - worst in vagina, urethra, cervix – delayed diagnosis

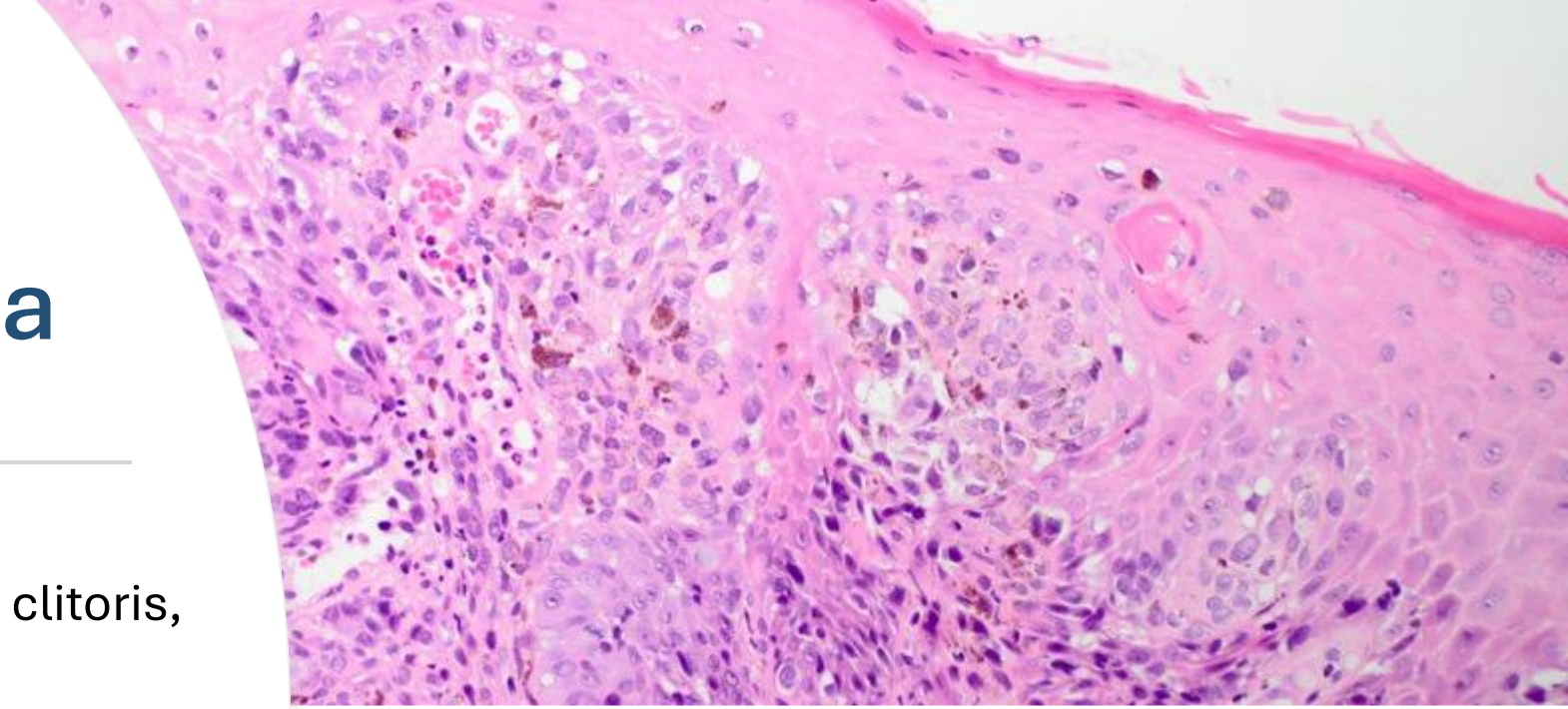

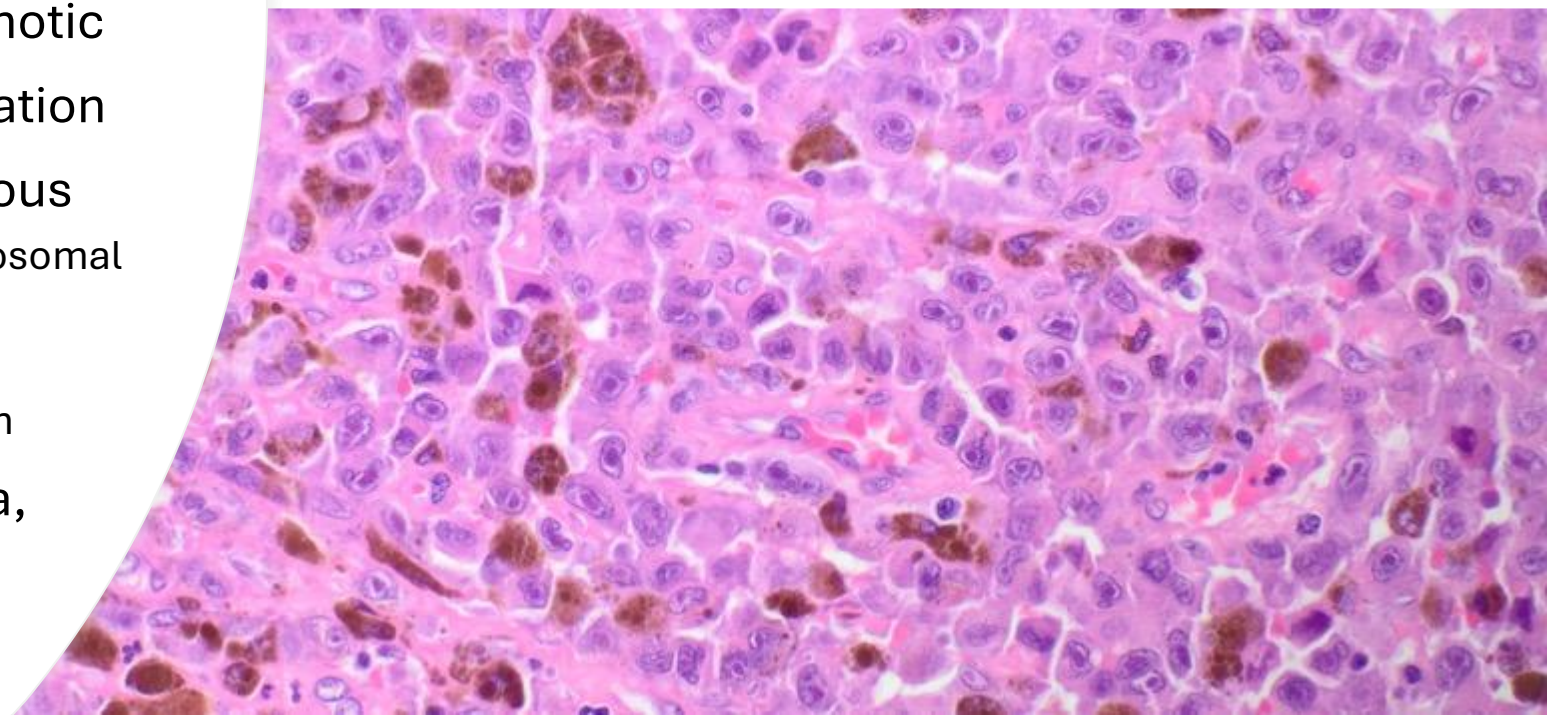

Wilhite Gynecol Oncol 2024, WHO, Roy Pathology 2024

Melanoma – problematic aspects

Great phenotypic diversity – "the great mimicker"

- Heterogeneous morphology
- Aberrant expression of non-melanocytic markers: cytokeratins, neuroendocrine, muscle, other markers

May lose some or all routine melanoma markers – "dedifferentiation/ undifferentiation"

- "Vimentin only" phenotype; misdiagnosed as undifferentiated pleomorphic sarcoma (UPS)
- Transdifferentiation - mimic another lineage eg carcinoma, rhabdomyosarcoma
- Dediff/undifferentiated melanoma significantly under-recognised until recently

Ben-Izhak Am J Dermatopath 1994
Saliba Dermatopathology 2021
Agaimy AJSP 2021
Agaimy AJSP 2016

Dedifferentiated and Undifferentiated Melanomas

Report of 35 New Cases With Literature Review and Proposal of Diagnostic Criteria

Abbas Agaimy, MD, Robert Stoehr, PhD,* Annkathrin Hornung, MD,† Judith Popp, MD,† Michael Erdmann, MD,† Lucie Heinzerling, MD,†‡ and Arndt Hartmann, MD**

AJSP 2021

85 cases - 35 new, 50 previously reported

Definition: Lacks histologic and IHC features of melanoma

Loss of routinely used markers: S100, SOX10, MelanA, HMB45

Requires detection of melanoma-compatible mutations *BRAF, NRAS, NF1*

Occurs as a primary or metastasis, with or without prior melanoma

Dedifferentiated: Conventional and undifferentiated components

Significant phenotypic diversity: UPS-like, heterologous, rhabdoid, giant cell tumour-like, osteochondroblastic, small round cell, LG fibromyxoid sarc-like



Dedifferentiated and Undifferentiated Melanomas

Report of 35 New Cases With Literature Review and Proposal of Diagnostic Criteria

Abbas Agaimy, MD, Robert Stoehr, PhD,* Annkathrin Hornung, MD,† Judith Popp, MD,† Michael Erdmann, MD,† Lucie Heinzerling, MD,†‡ and Arndt Hartmann, MD**

AJSP 2021

85 cases - 35 new, 50 previously reported

Clues to diagnosis:

- A **minimal differentiated component**
- **Prior melanoma**
- Undifferentiated, does not fit any defined entity, no other primary tumour
- At **sites unusual for UPS** (axilla inguinal nodes, GIT)
- Unusual multifocal disease **typical of melanoma spread**
- **Detection of mutation in conventional melanoma driver gene**

PRAME Immunohistochemistry for Distinguishing Vulvar and Vaginal Melanoma From Benign Melanocytic Nevi

IJGP 2023

Spencer D. Martin, M.D., Ph.D., Karina C. Martin, M.D., C. Blake Gilks, M.D., Richard I. Crawford, M.D., and Lien N. Hoang, M.D.

- PRAME highly sensitive and specific for **distinction of vulvovaginal melanoma from benign melanocytic nevi**
- Assists with in situ melanoma margin assessment

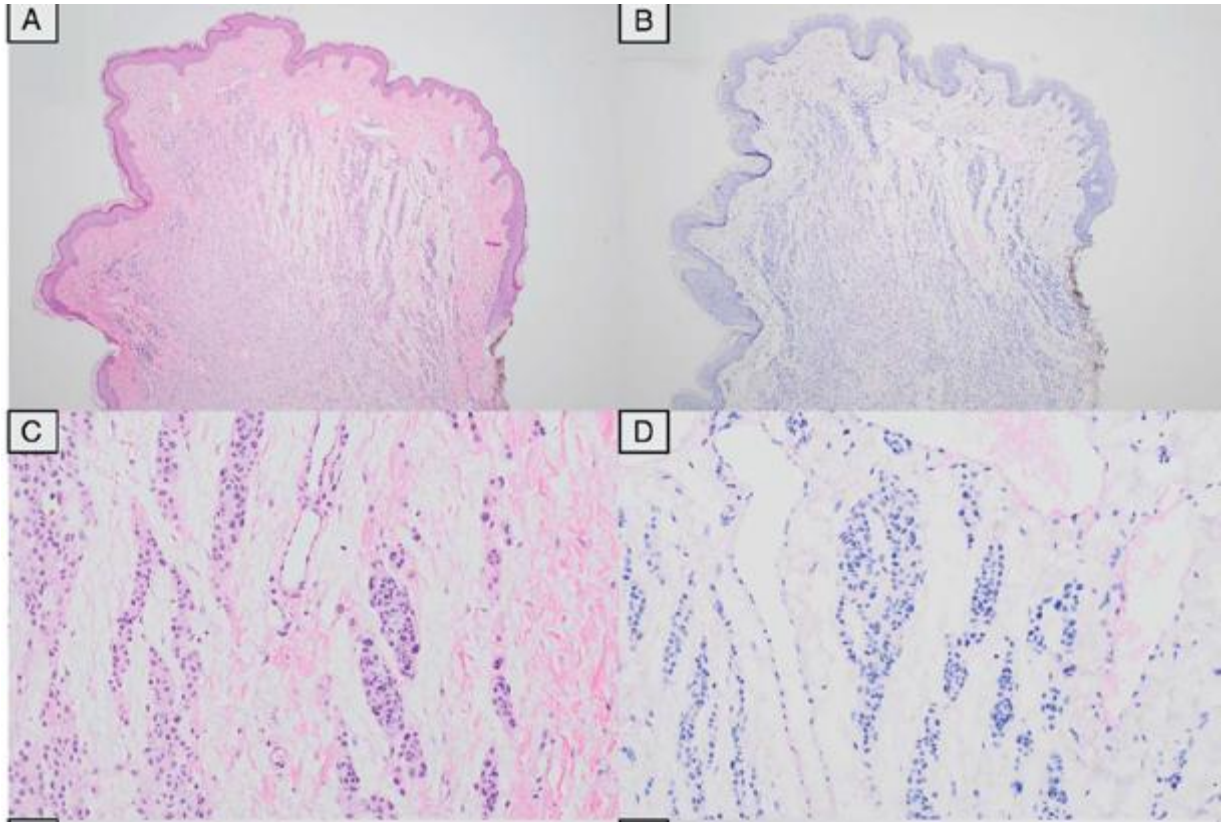

Benign nevus

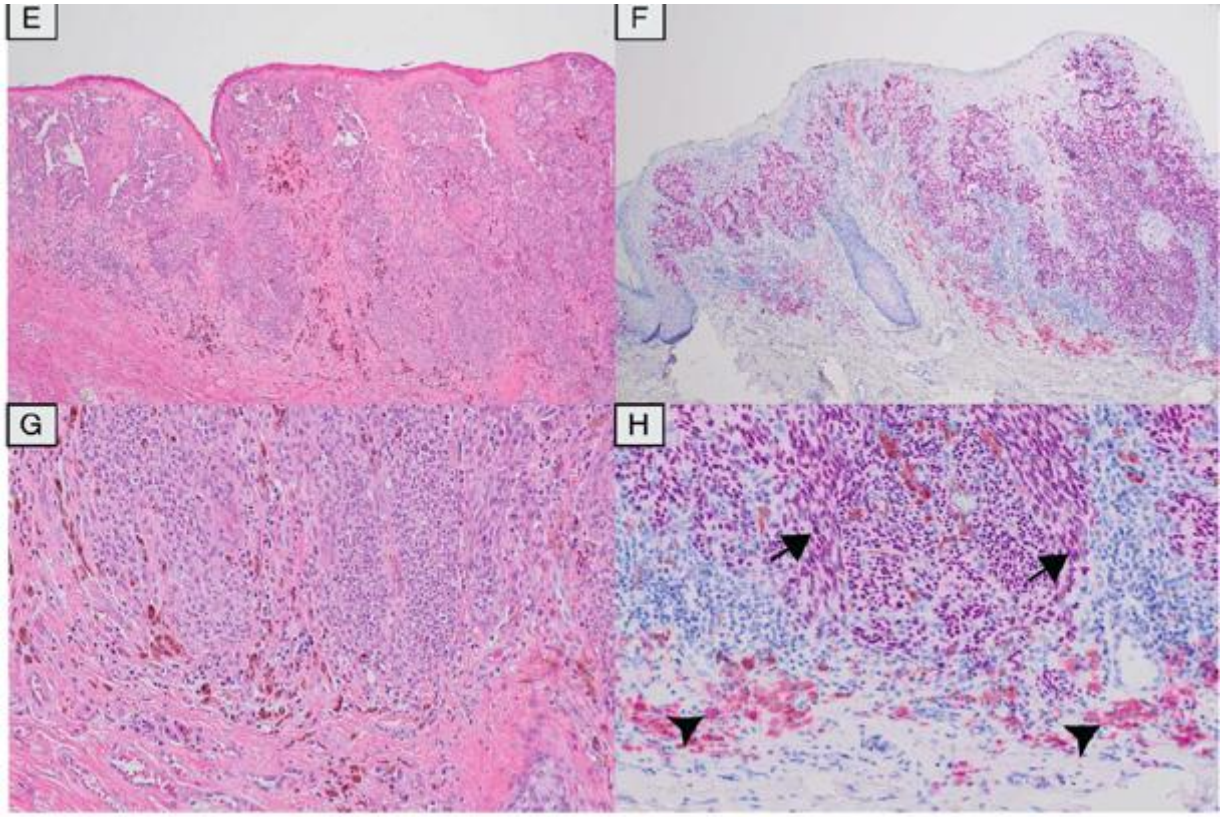

Vulval Melanoma

Summary

- Routine p16 and p53 in work-up of vulval squamous pre/neoplasia
- HPVI p53wt VIN characterized by altered maturation and minimal atypia in most but not all cases
- Mammary-type carcinoma classifies into 4 molecular groups
- Vulvovaginal intestinal type carcinoma more like colorectal than Mullerian carcinoma
- Consider undifferentiated melanoma in the workup of an undifferentiated pleomorphic neoplasm

Thank you!

Acknowledgements:
Sophie Bittinger
Frances Petry
Gayanie Ratnayake
Mila Volchek

