The British Association of Gynaecological Pathologists

Masterclass with the Experts in Collaboration with ISGyP
4th June 2025

- **Title.** Practical Issues of Reporting Molar Cases
- **Speaker.** Pei Hui, MD
- **Affiliation.** Yale University School of Medicine
- **Date.** 6th June 2025

The British Association of Gynaecological Pathologists

Speaker disclosures

I have no relevant financial conflicts of interest to disclose

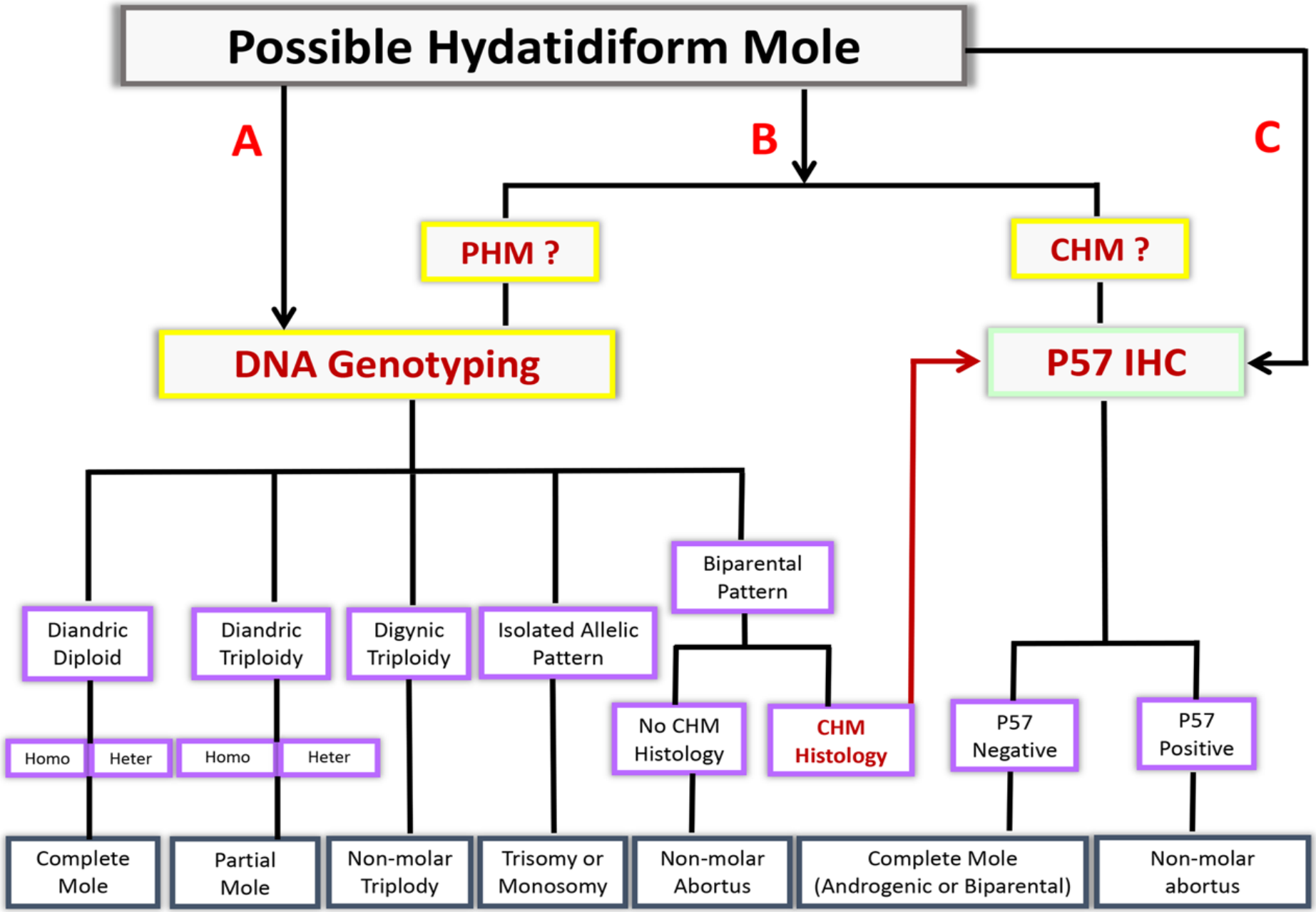
Possible Hydatidiform Mole
A
B
C
PHM ?
CHM ?
DNA Genotyping
P57 IHC
Diandric Diploid
Diandric Triploidy
Digynic Triploidy
Isolated Allelic Pattern
Biparental Pattern
Homo
Heter
Homo
Heter
No CHM Histology
CHM Histology
P57 Negative
P57 Positive
Complete Mole
Partial Mole
Non-molar Triplody
Trisomy or Monosomy
Non-molar Abortus
Complete Mole (Androgenic or Biparental)
Non-molar abortus

Y-GTD Center Experience

- Tertiary Medical Center
- 2006-2024 - 2871 cases
- 99.5% successfully Genotyped
- **Moles - 29.6% (846/2857)**

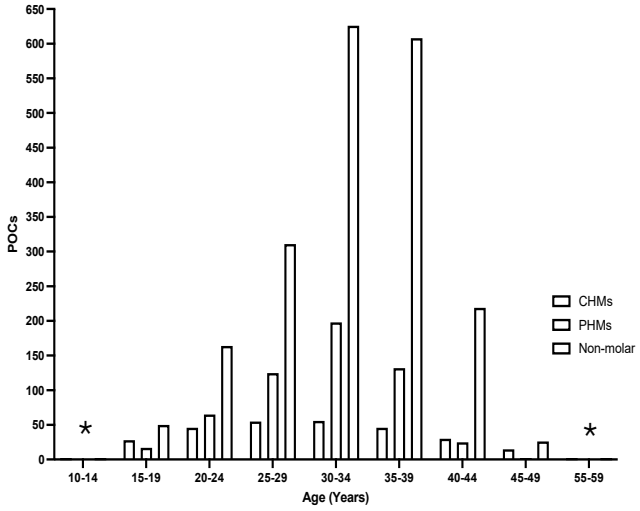

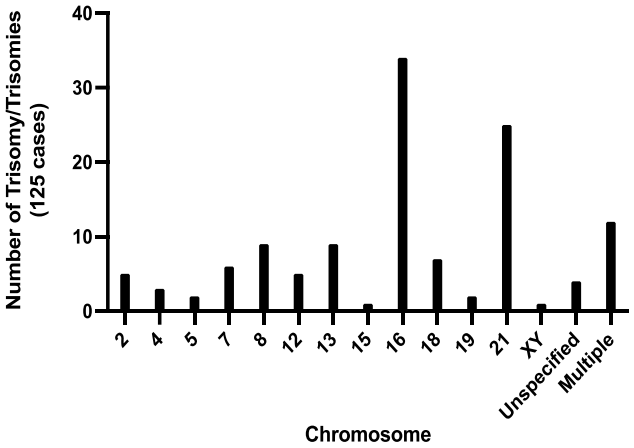

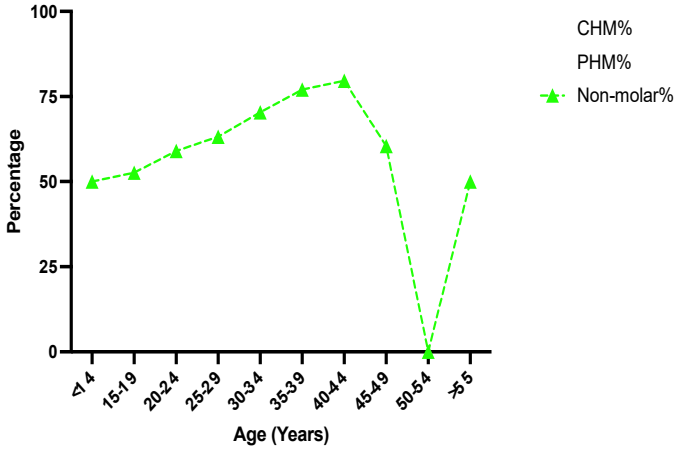

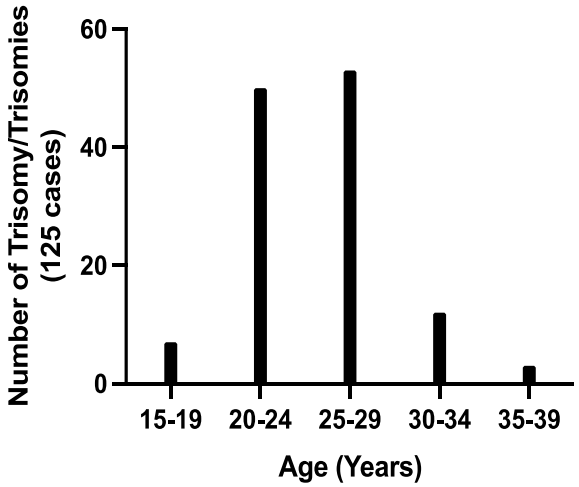

Table 3. Distribution of STR genotyping diagnostic categories in routine in-house and consultation cases.

Diagnostic Categories	In-house	Consultation	Total
CHM	165 (38.6%)	117 (28.0%)	282 (33.3%)
PHM	262 (61.4%	302 (72%)	564 (66.6%)
Non-molar	1255	751	2006
Biparental/Mosaic Androgenetic	1	2	3
Chimeric Gestation	2	0	2
Inconclusive	8	6	14
Total	1693	1178	2871

CHM: complete mole; **PHM:** partial mole.

STR Genotyping

	Yale Direct STR Genotyping Approach (This Study)
Total Study Cohort	2871 cases (41% consults)
Definitive diagnosis achieved	99.5% (14 inconclusive cases)
CHM Exclusively Observed	<14 and >50 years of age
Non-molar	2006 cases (69.8%)
PHM	564 Cases (19.6%)
CHM	282 cases (9.2%)
Androgenetic/ Biparental mosaicism	3 cases
Laser microdissection	138 cases (97% success rate)
Turnaround time	4 business days

Normal Gestation

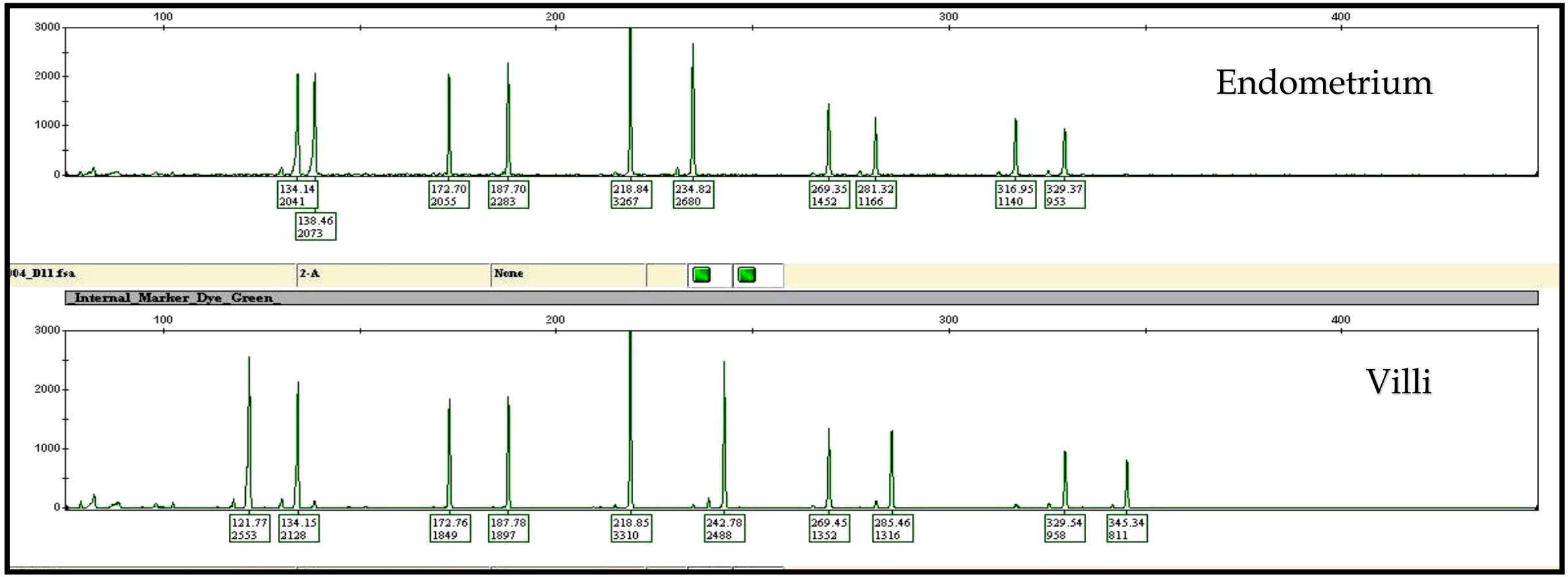

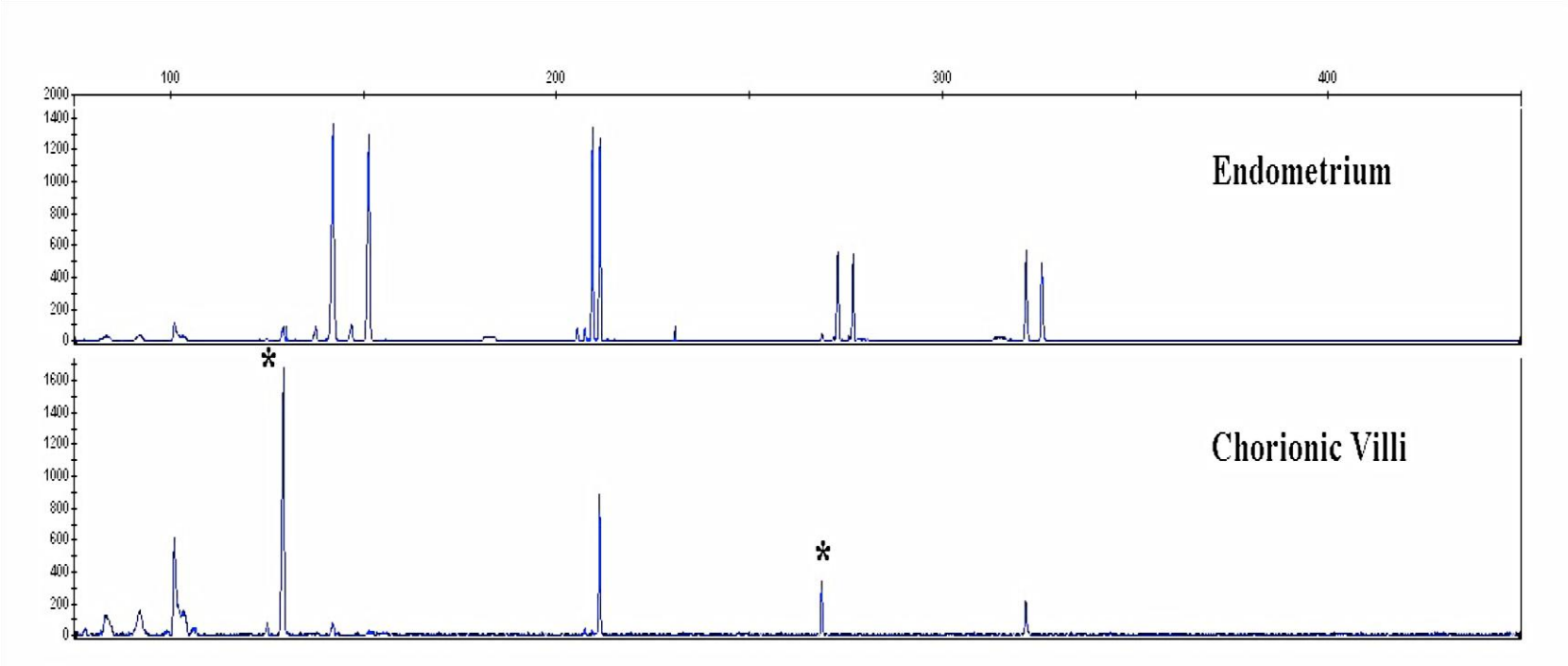

Monospermic (Homozygous) CHM (90%)

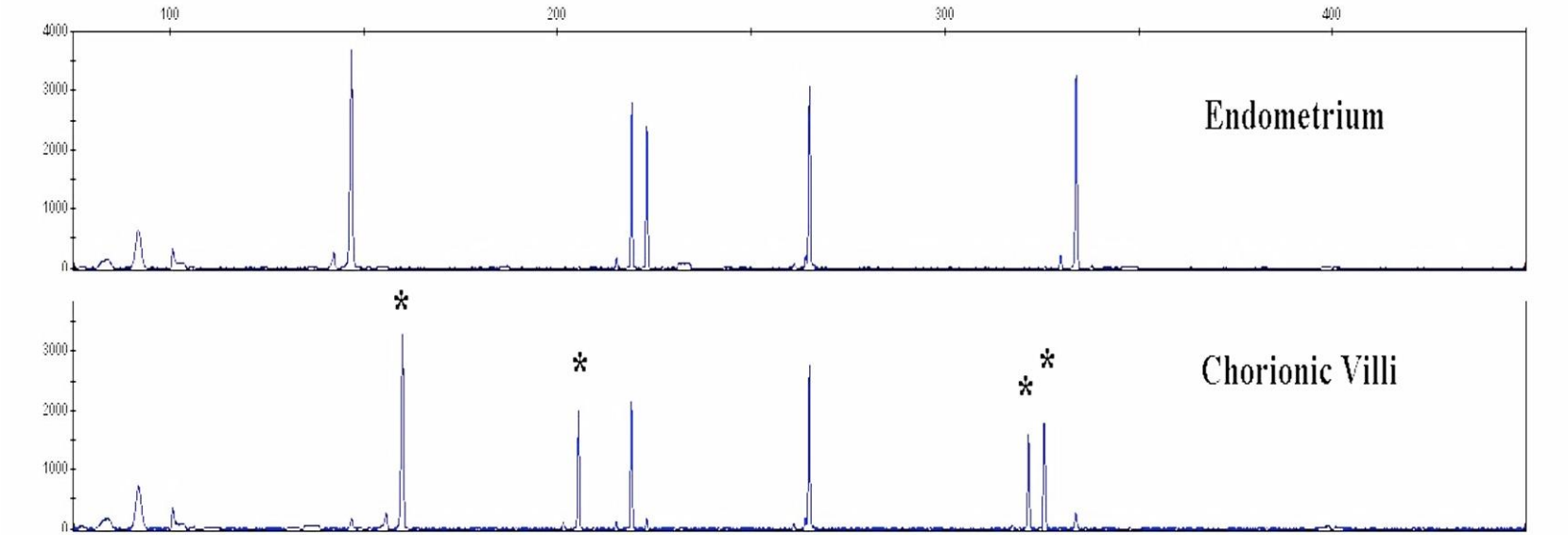

Dispermic (Heterozygous) CHM (10%)

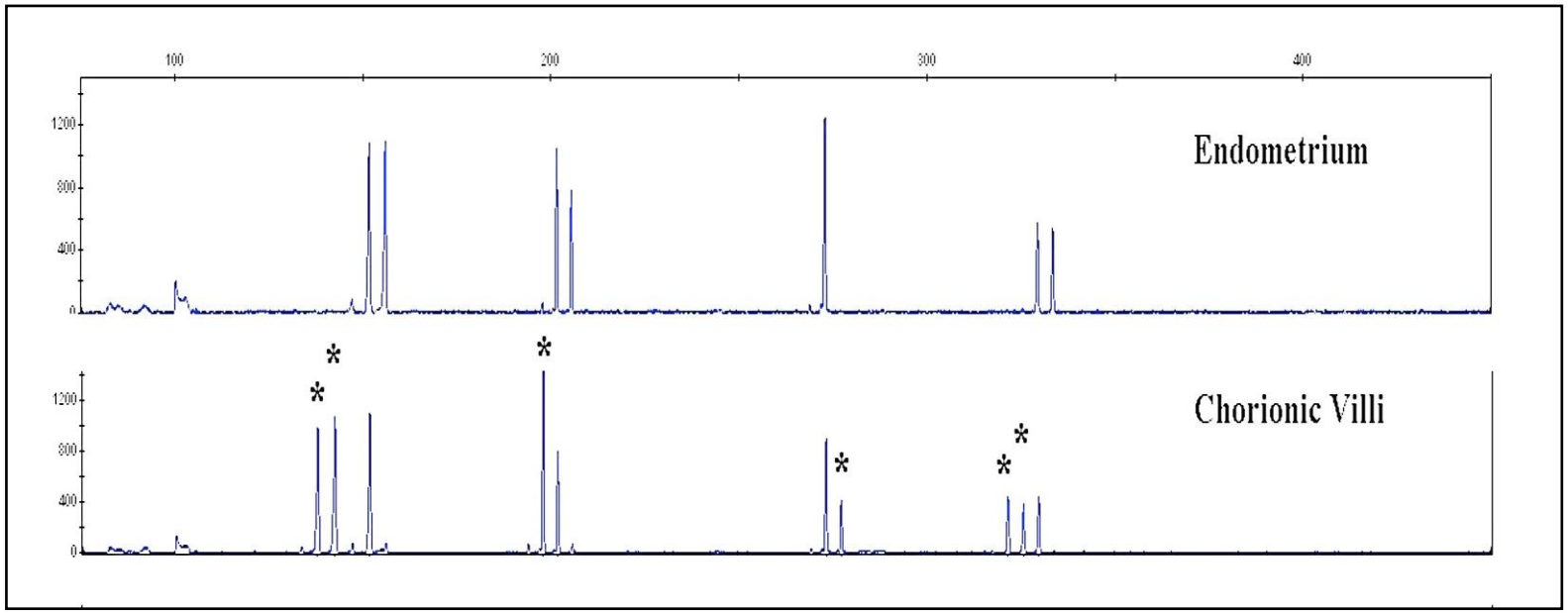

Heterozygous PHM (95%)

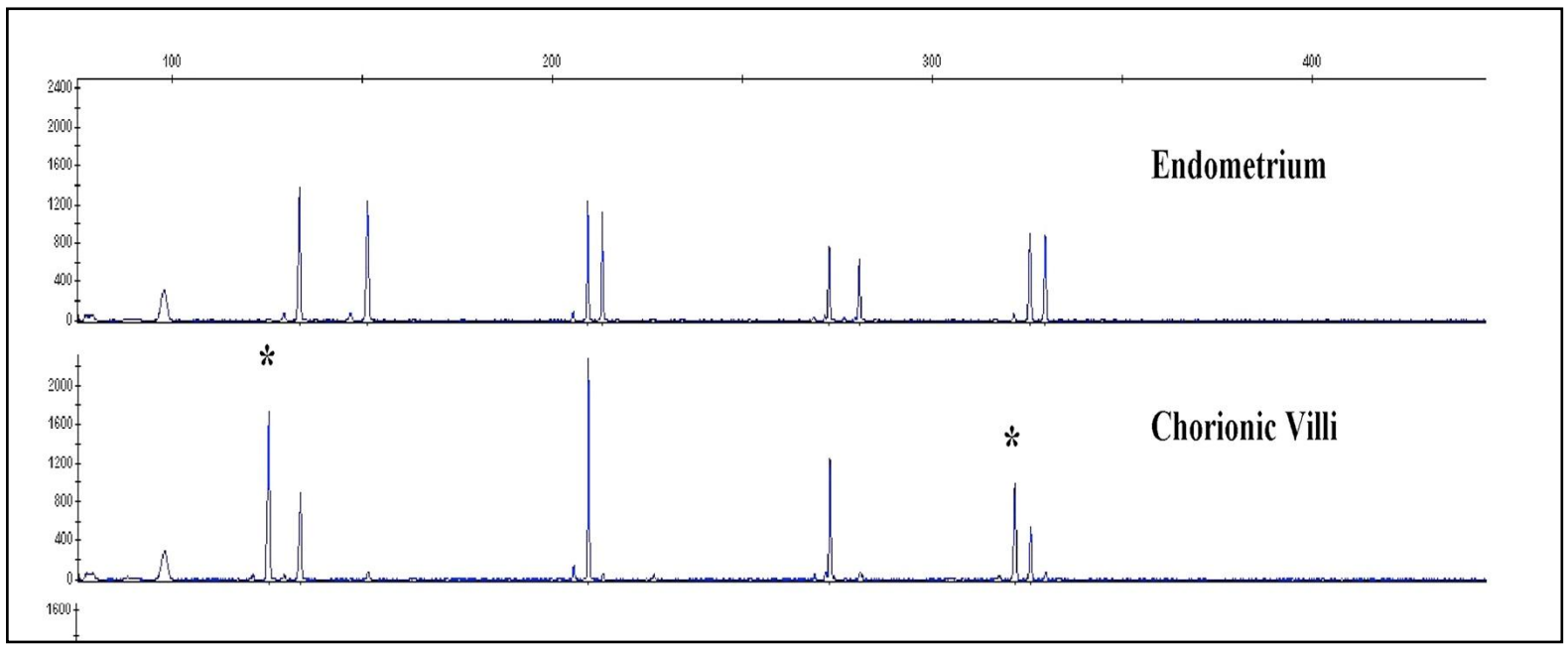

Homonzygoud PHM (5%)

Case 1: 38-year-old woman presented with missed abortion.

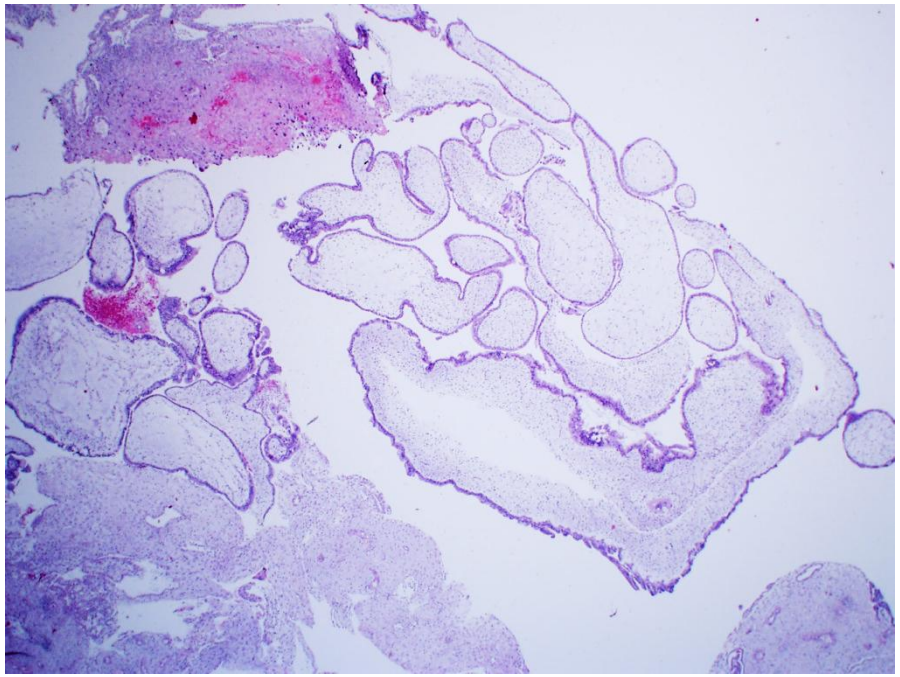

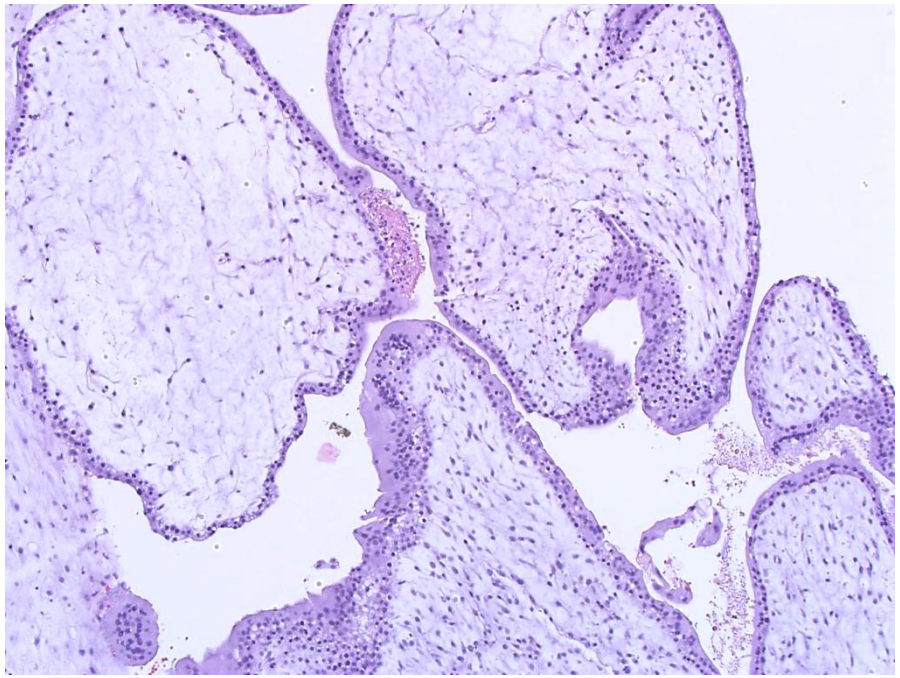

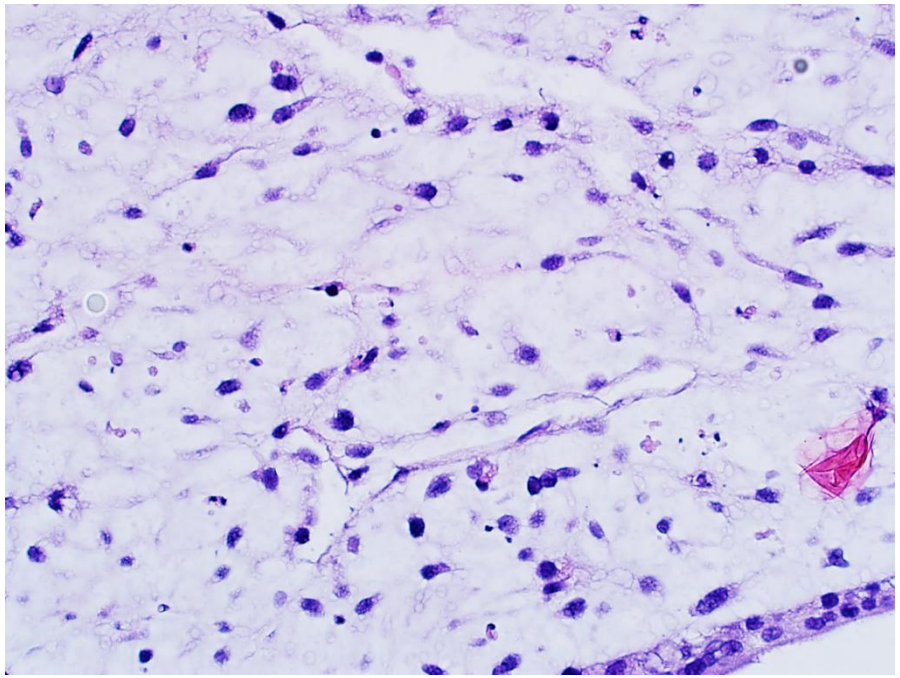

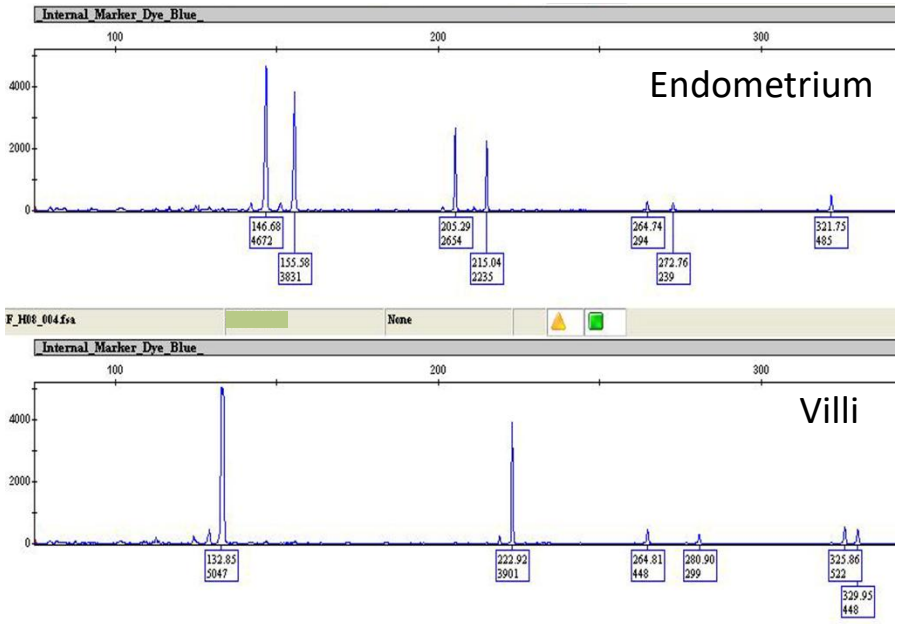
Internal_Marker_Dye_Blue_
100
200
300
4000
2000
0
146.68
4672
155.58
3831
205.29
2654
215.04
2235
264.74
294
272.76
239
321.75
485
Endometrium

F_H08_004.fsa
None
Internal_Marker_Dye_Blue_
100
200
300
4000
2000
0
132.85
5047
222.92
3901
264.81
448
280.90
299
325.86
522
329.95
448
Villi

A: Complete mole
B: Partial mole
D. Non-molar hydropic abortion

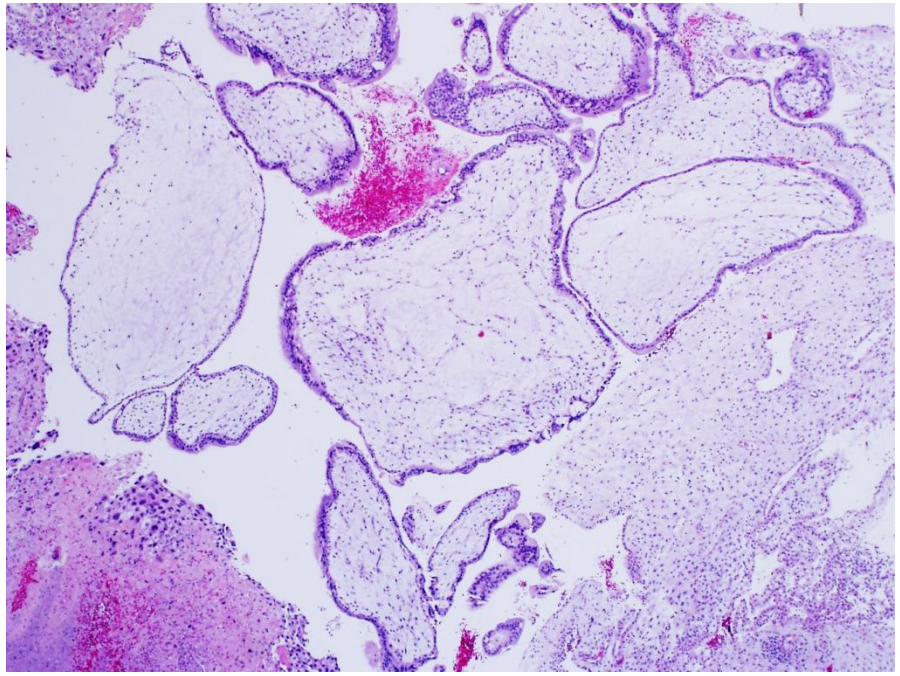

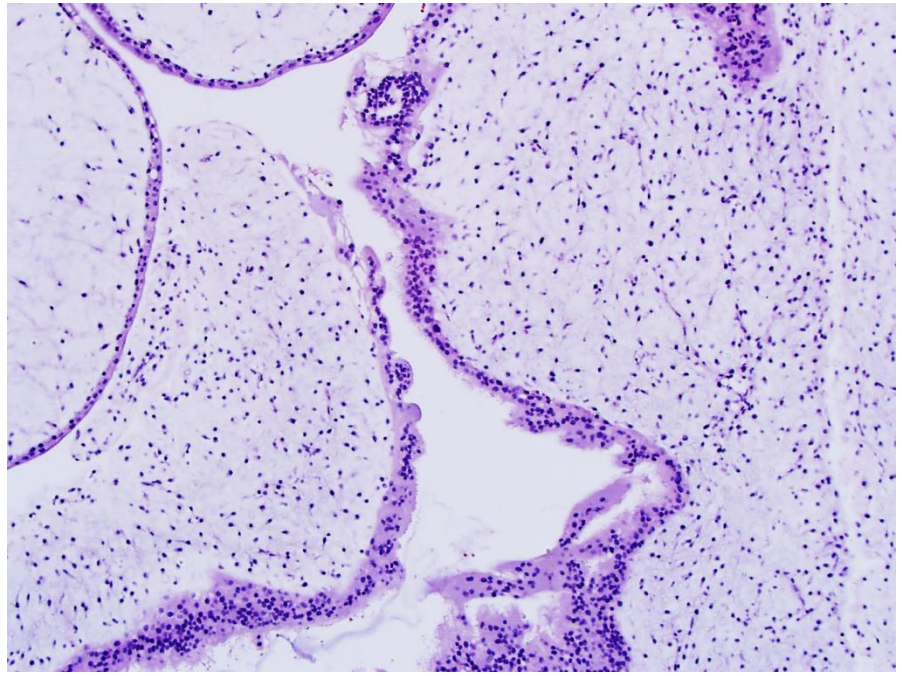

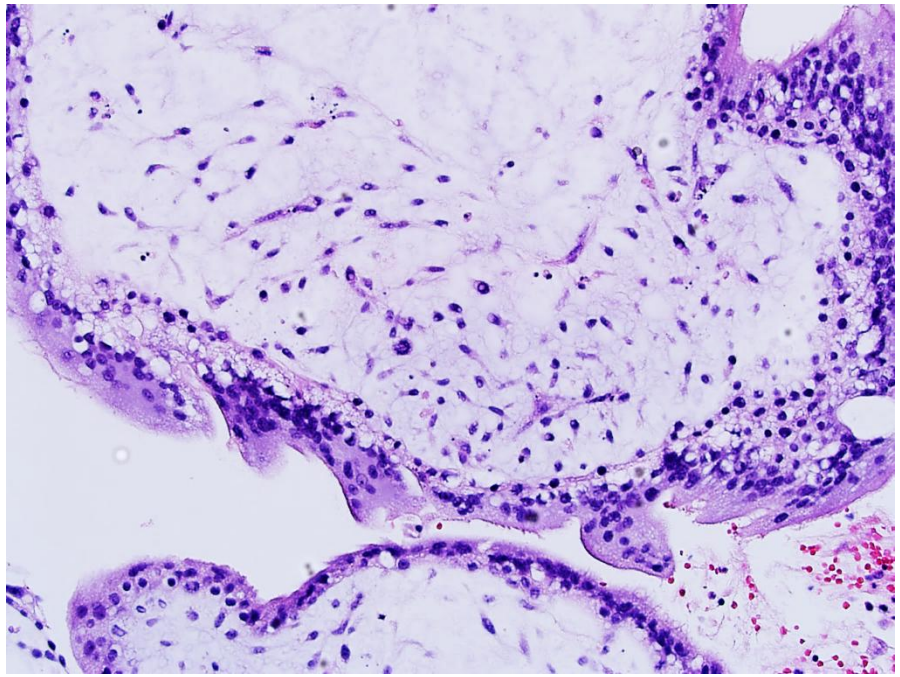

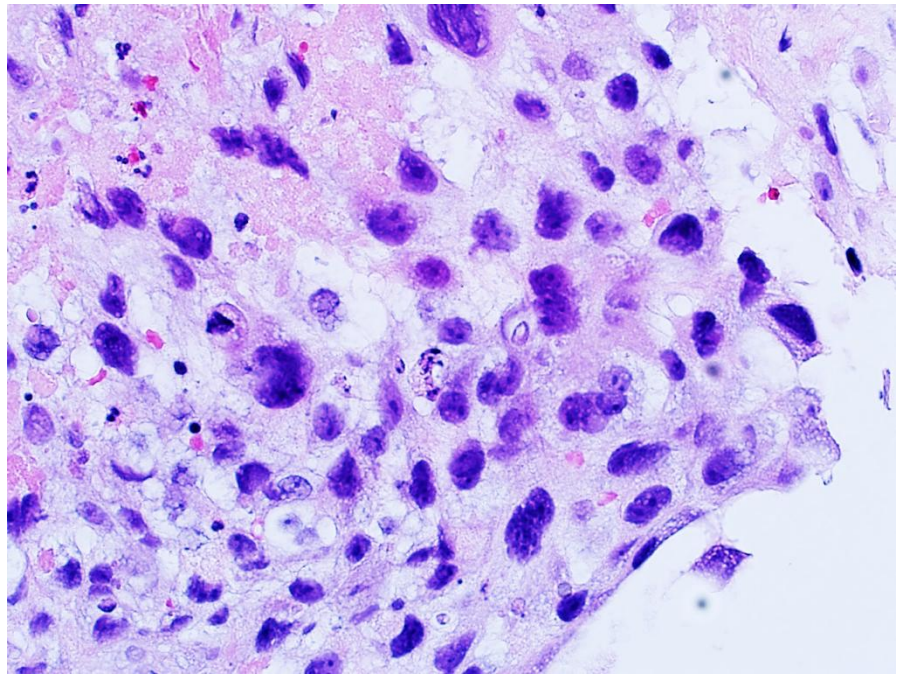

Additional images

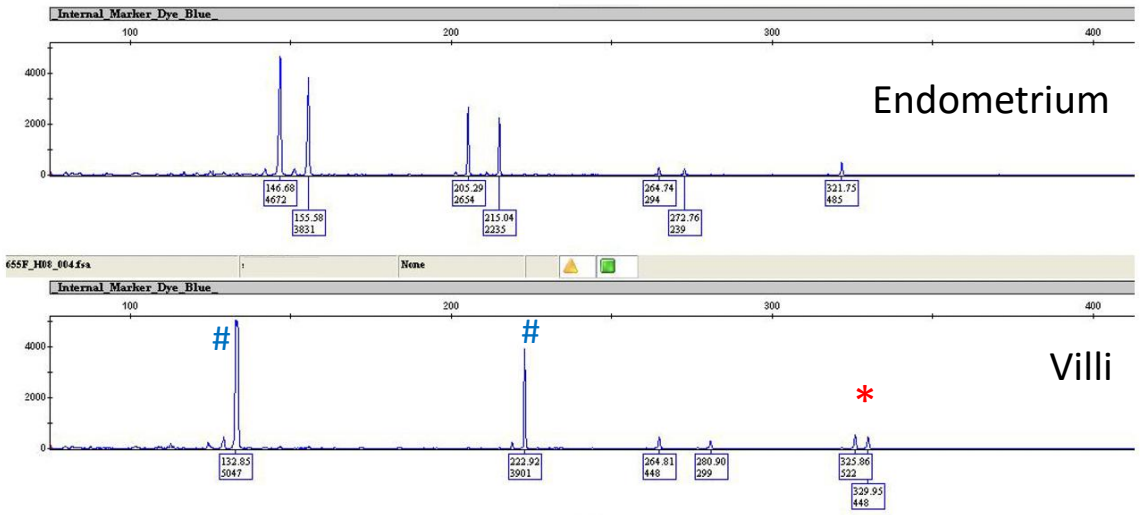



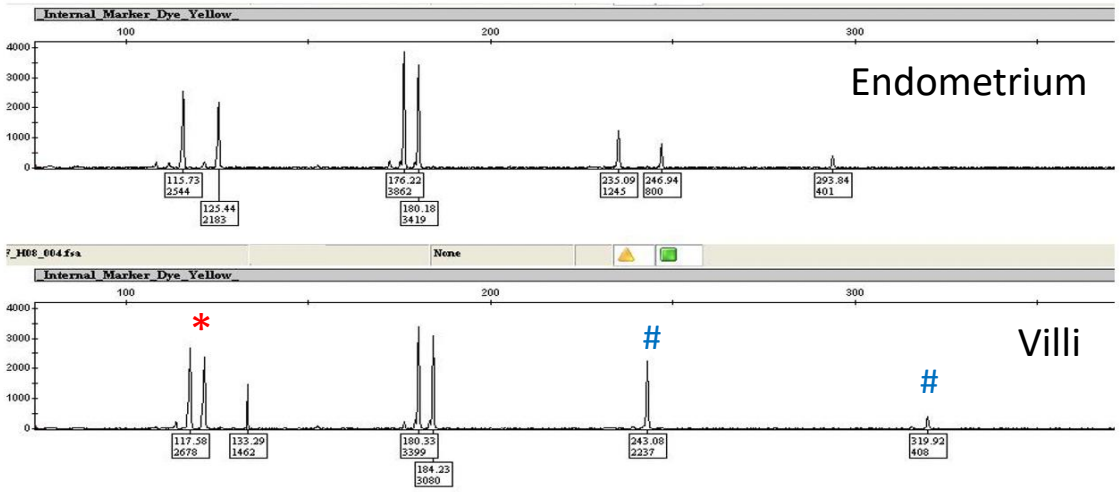

Full STR genotyping panel: The overall allelic pattern at STR loci is diagnostic of dispermic/heterozygous complete mole. Note the presence of two distinct paternal alleles at two STR loci (*) in addition to one paternal allelic pattern at other loci (#).

Case Summary

Chorionic villi: characteristic for VECHM

- Abnormal polypoid configurations
- Hypercellular myxoid stroma and prominent karyorrhectic debris.
- Subtle abnormal, circumferential villous trophoblastic proliferation

STR genotyping: heterozygous paternal-only profile

Final Diagnosis: Heterozygous complete mole

Case 2: 33-year-old woman presenting with missed abortion.

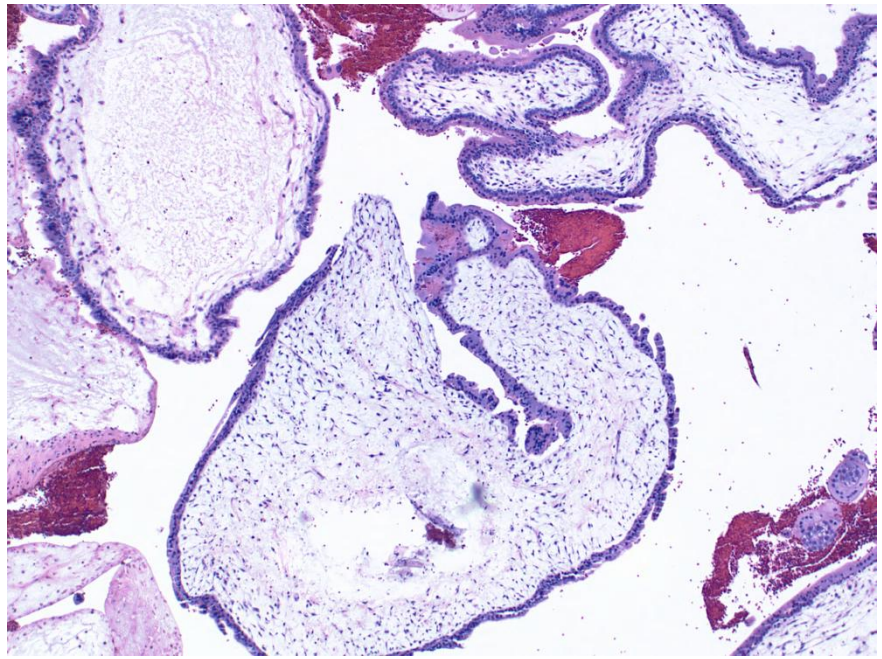

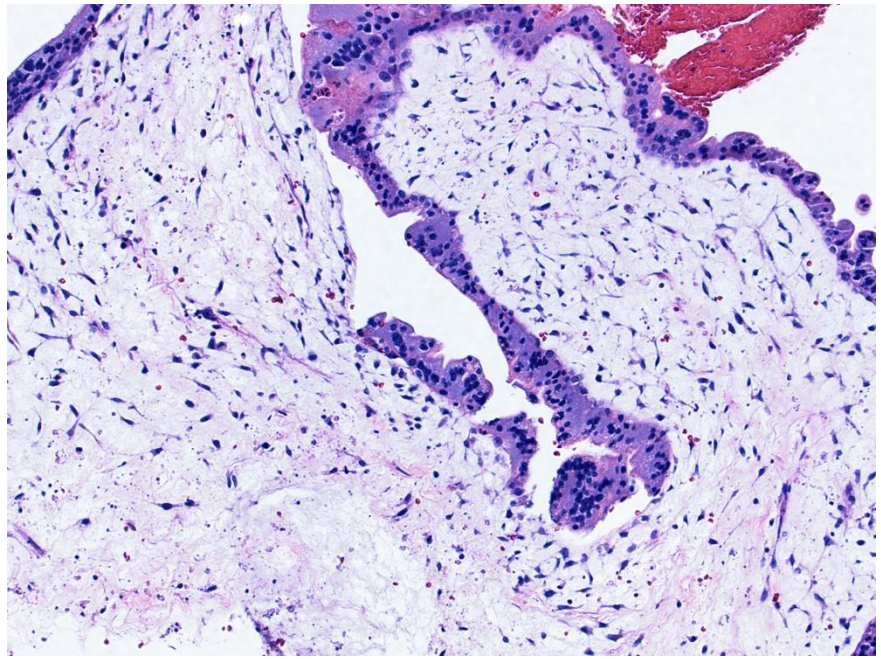

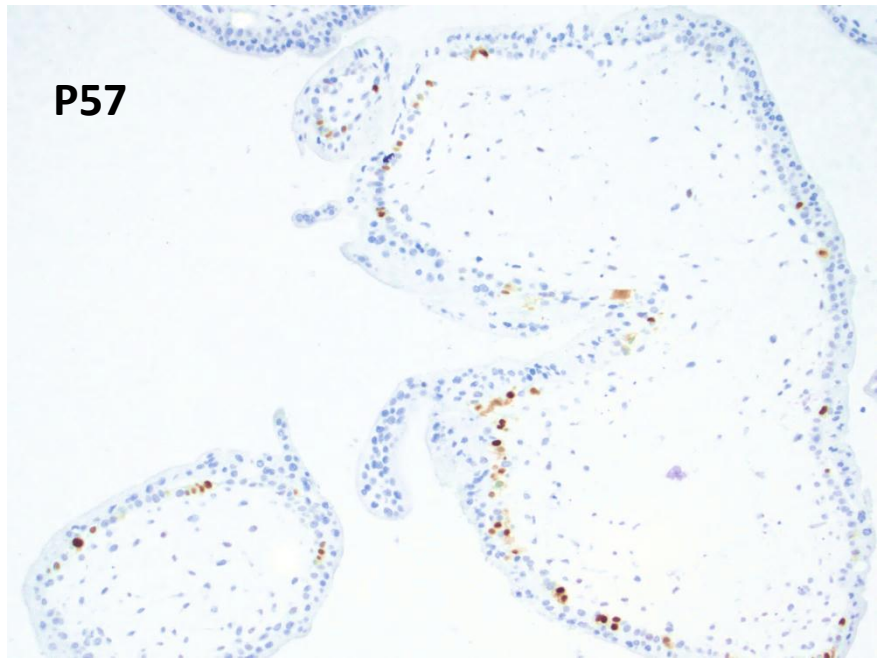
P57

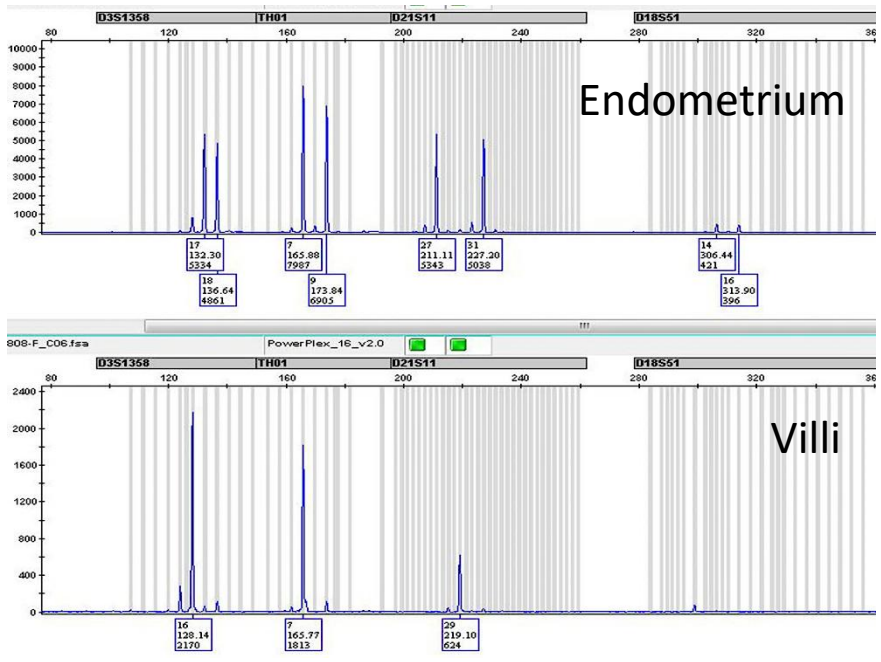
D3S1358
TH01
D21S11
D18S51
Endometrium
Villi
PowerPlex_16_v2.0

- Hydropic Abortion
- Partial Mole
- Complete Mole

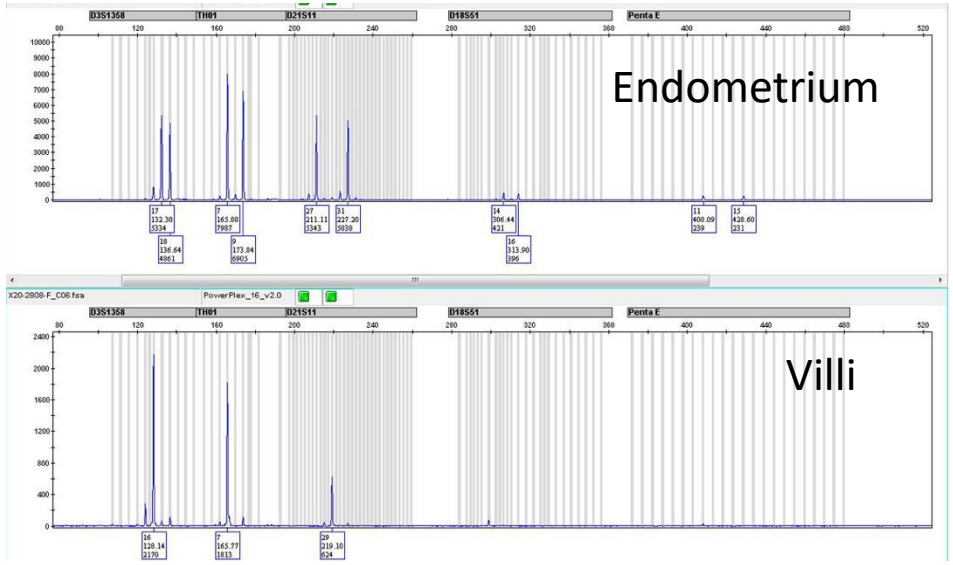

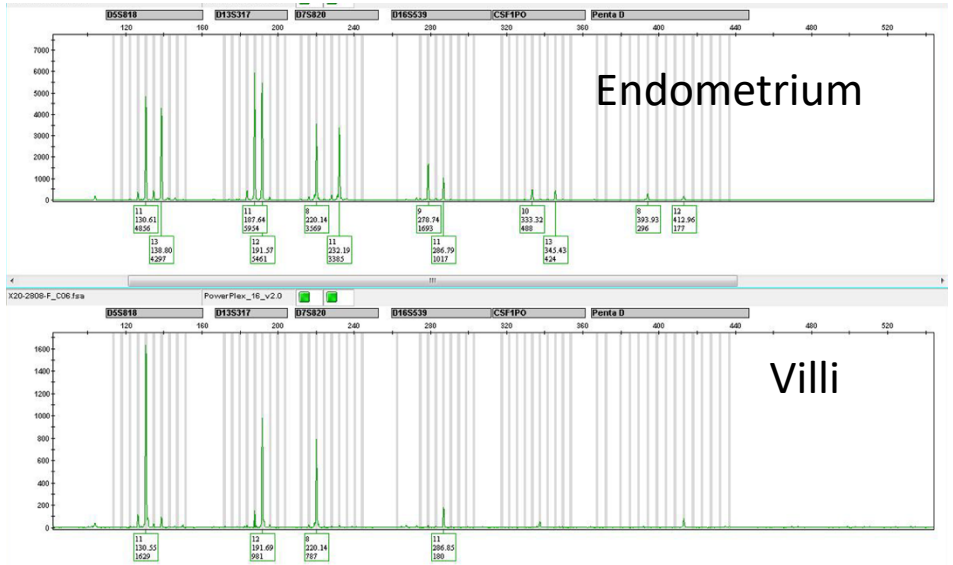

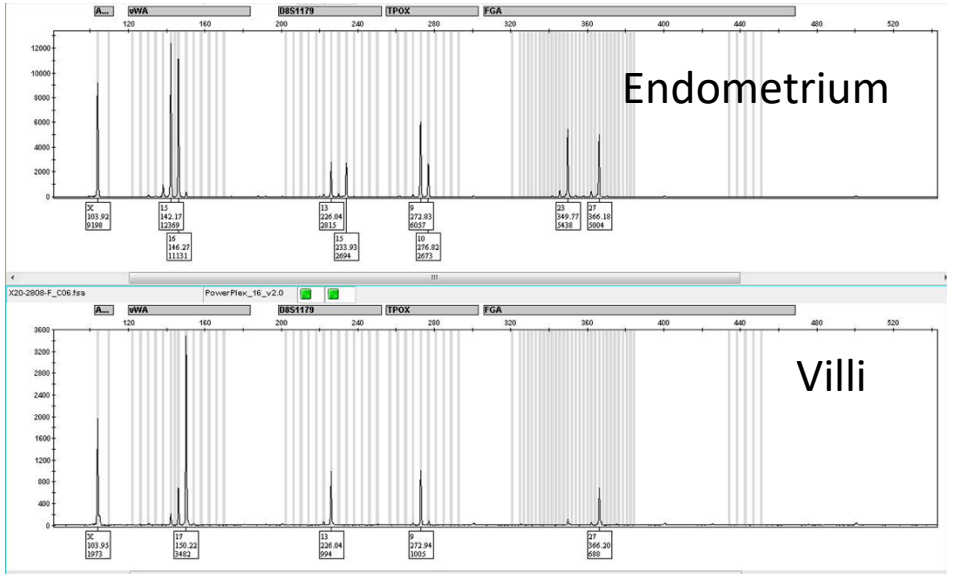

STR Genotyping Data: A homozygous allelic pattern is present at all STR loci, diagnostic of homozygous complete mole.

Diagnostic Summary:

Chorionic villi: characteristic for VECHM

- Abnormal polypoid configurations
- Hypercellular myxoid stroma with prominent karyorrhectic debris.
- Subtle abnormal trophoblastic proliferation
- Unusual nuclear staining of P57 in >10% of cytotrophoblast
- Complete lack of P57 staining in villous stromal cells

STR genotyping: homozygous paternal-only profile

Final Diagnosis: Homozygous very early complete mole

Case 3: 31-year-old P1 with vaginal bleeding and cramping at 13 weeks, followed by passing fetus and intact placenta. Bleeding and pain stopped afterward. CVS diagnosis of triploid gestation by karyotyping.

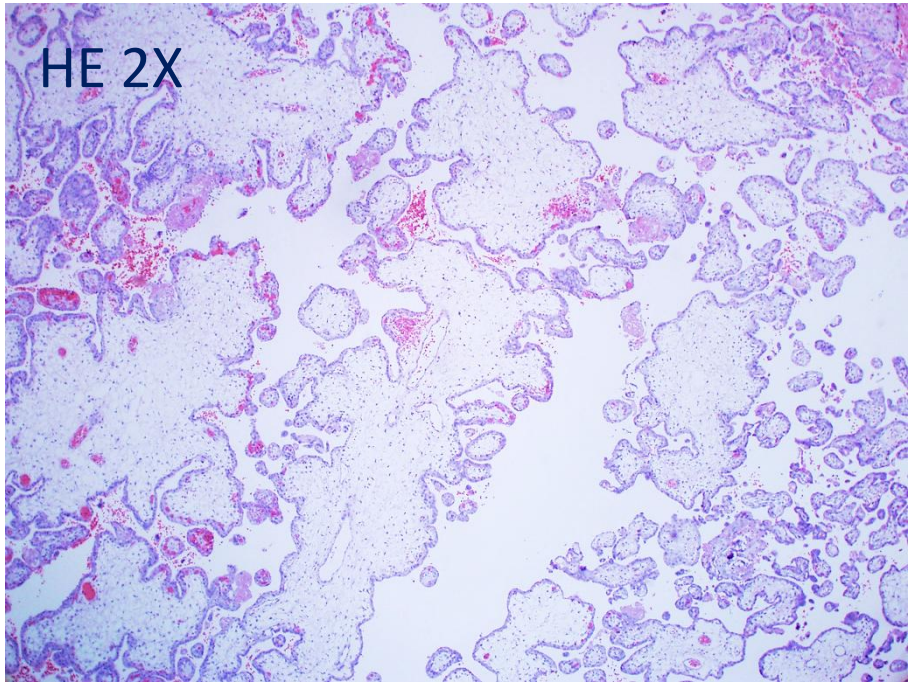
HE 2X

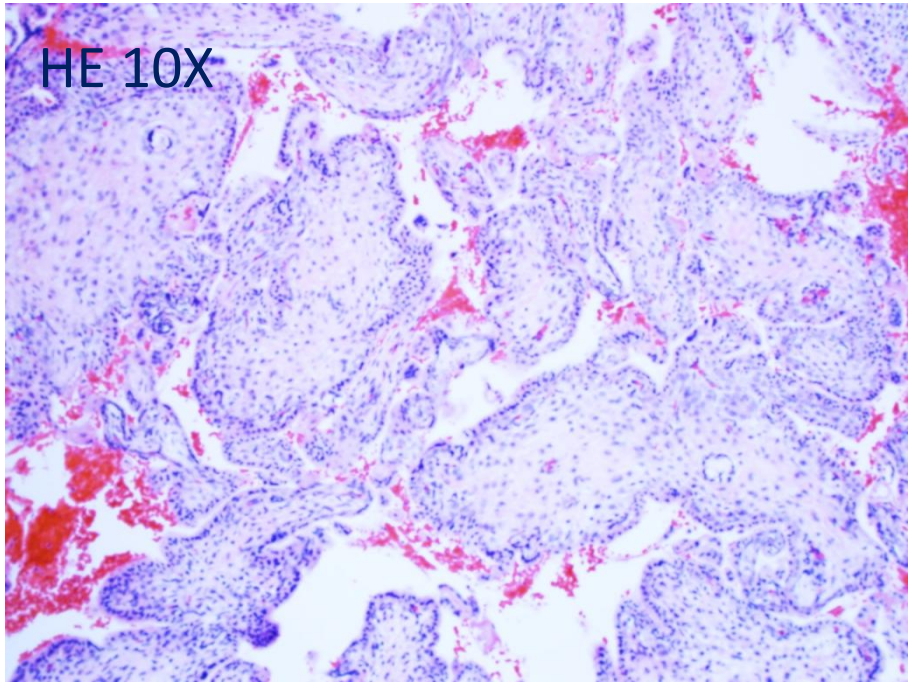
HE 10X

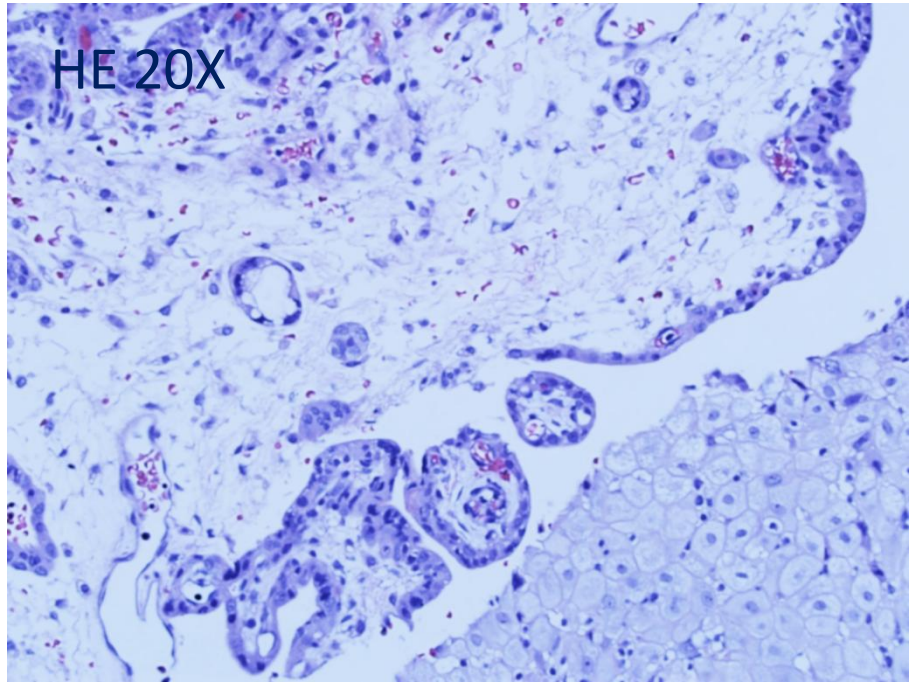
HE 20X


Decidua
Villi
None
al_Marker_Dye_Green_

A: Complete mole
B: Partial mole
D. Non-molar triploid gestation

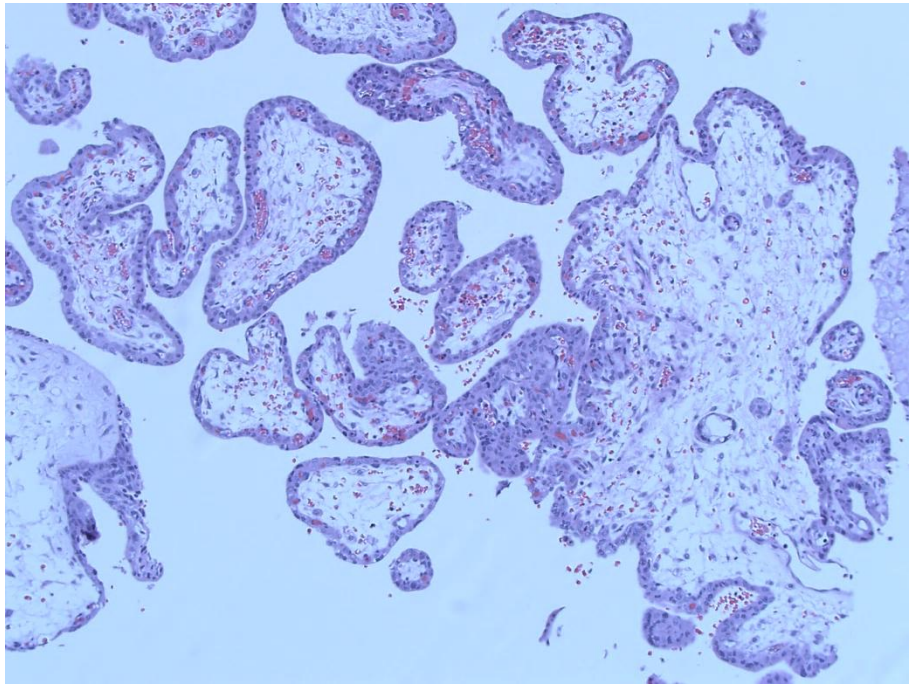

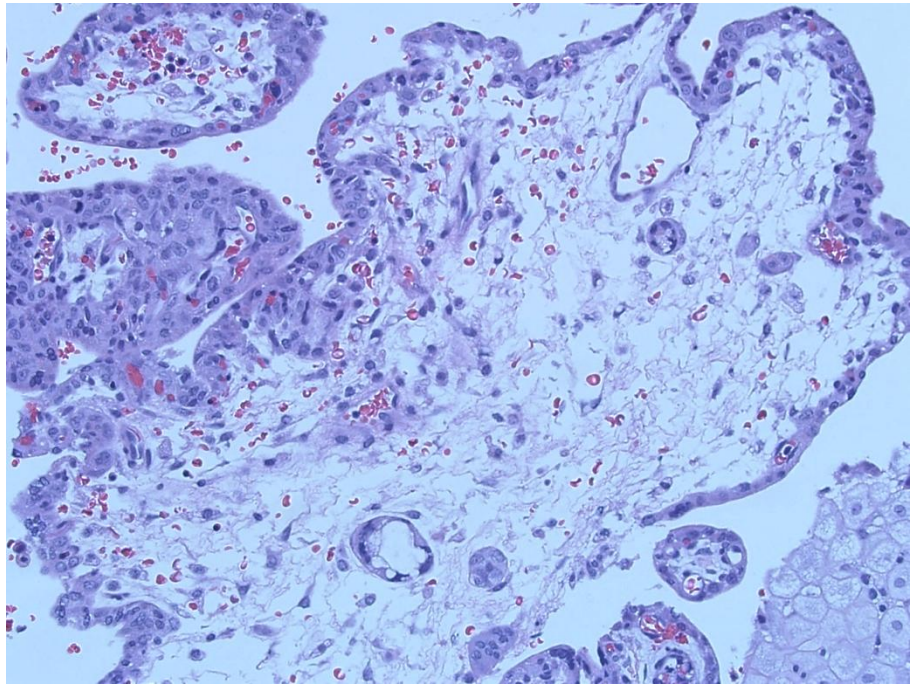

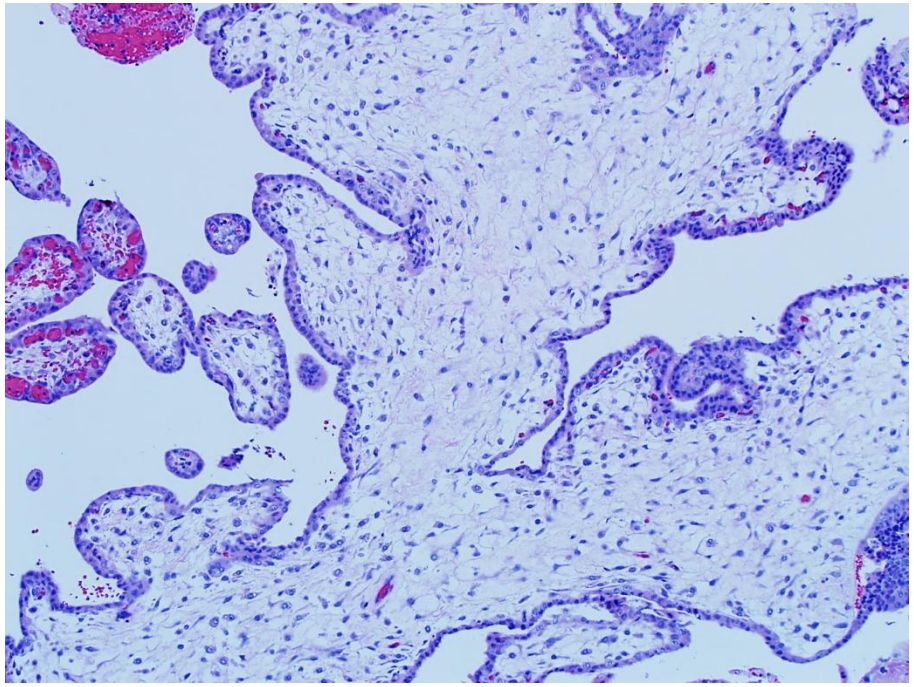

Additional histological images



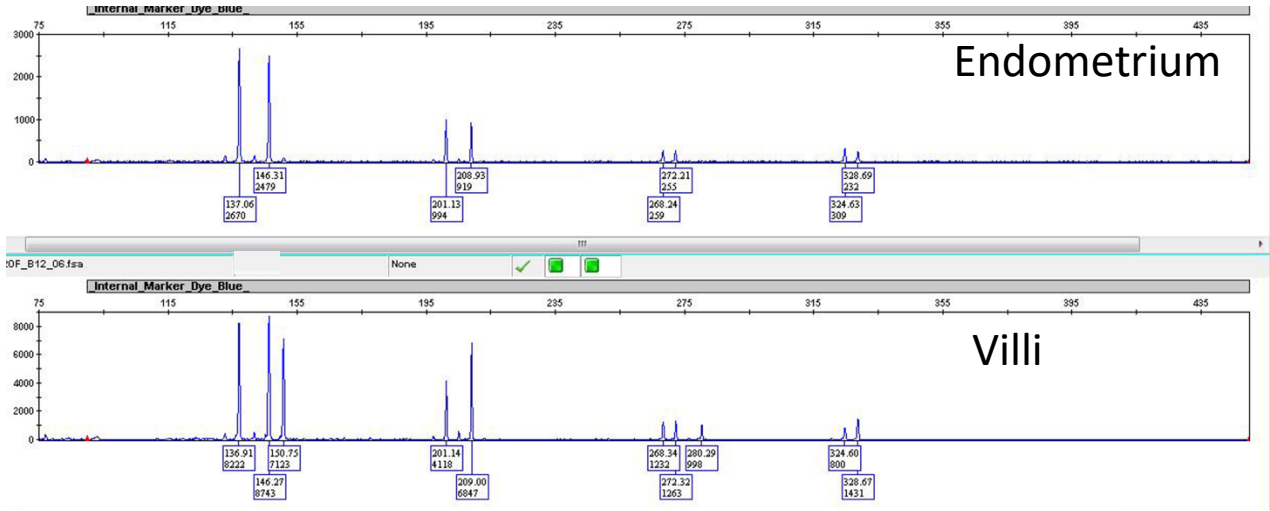

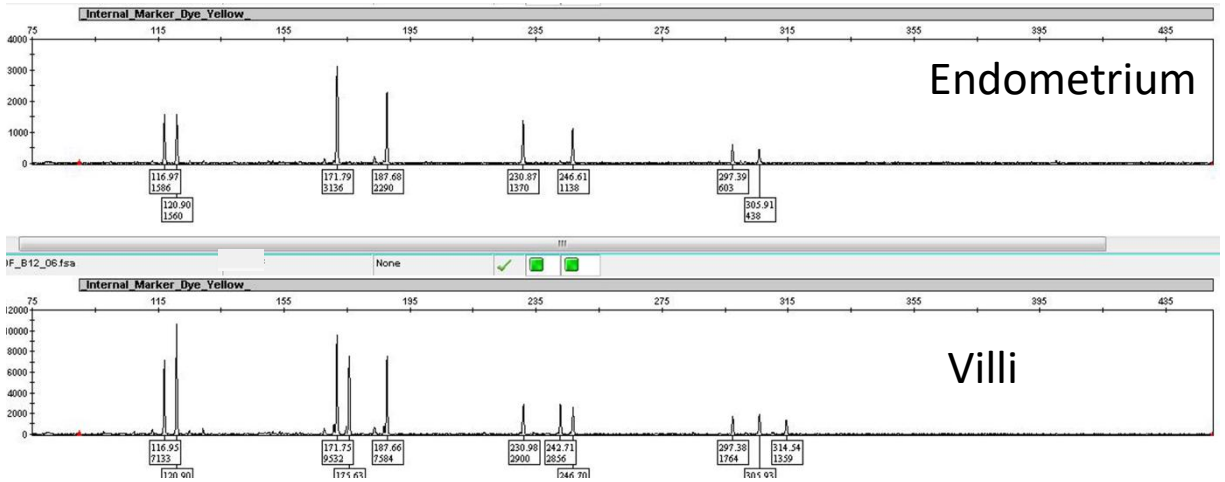

STR Genotyping: Three allelic copies at all informative STR and each locus harboring two matching maternal alleles and one paternal allele

Diagnostic Summary:

Chorionic villi:

- enlarged with abnormal shapes
- trophoblastic pseudoinclusions
- mild villous edema.

CVS karyotyping: triploid gestation

STR genotyping: two matching maternal alleles and one paternal allele at each STR locus (digynic-monoandric triploid)

Final Diagnosis: Digynic Triploid Non-molar Gestation

Case 4: 40-year-old woman with clinical suspicion for molar gestation undergoing uterine D/C.

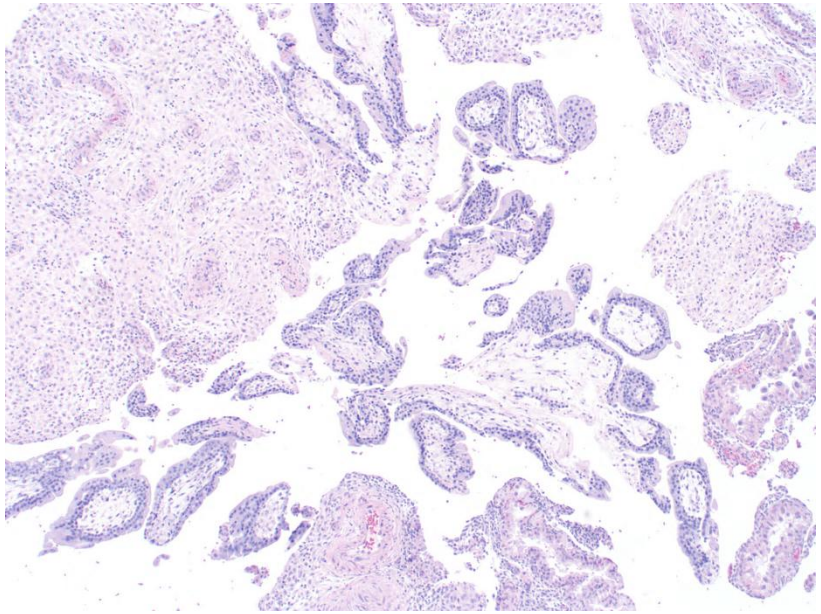

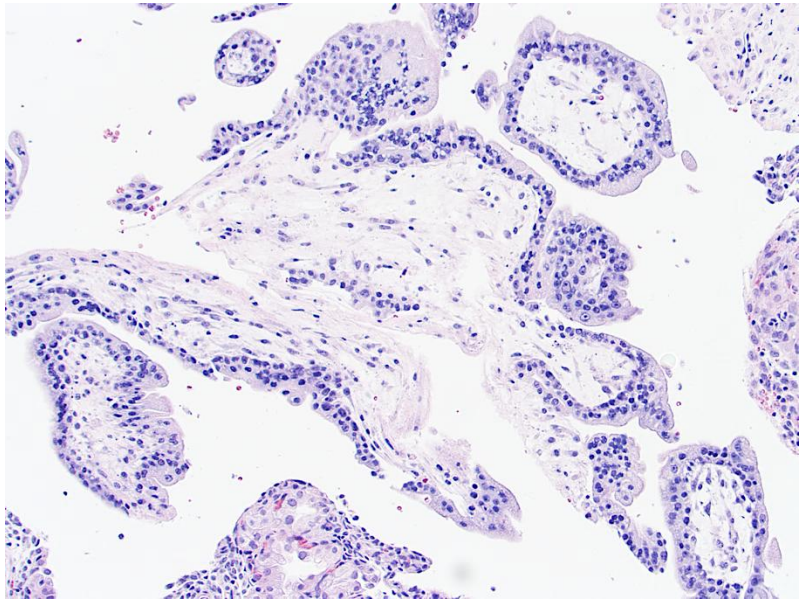

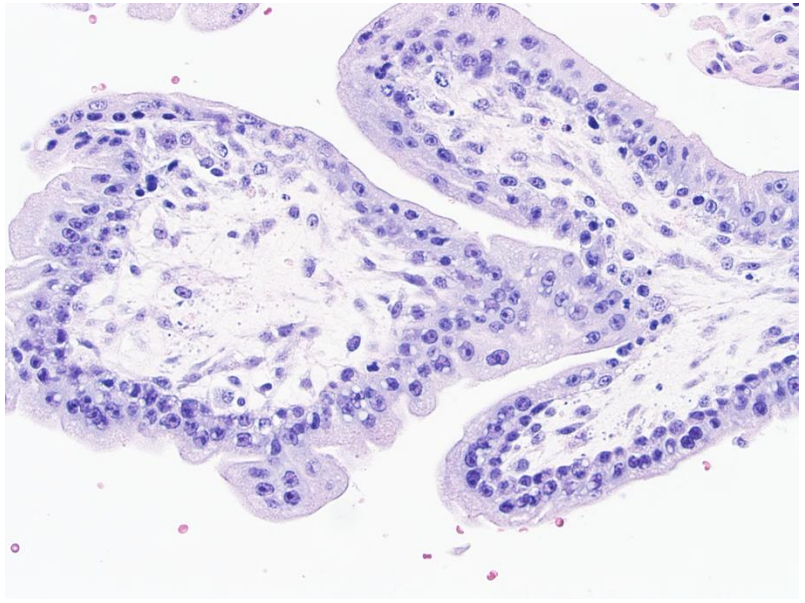

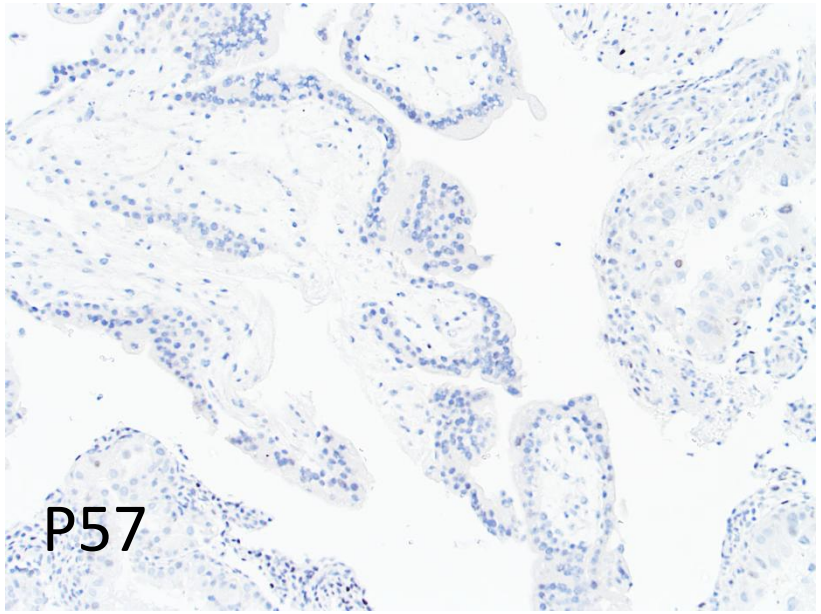
P57

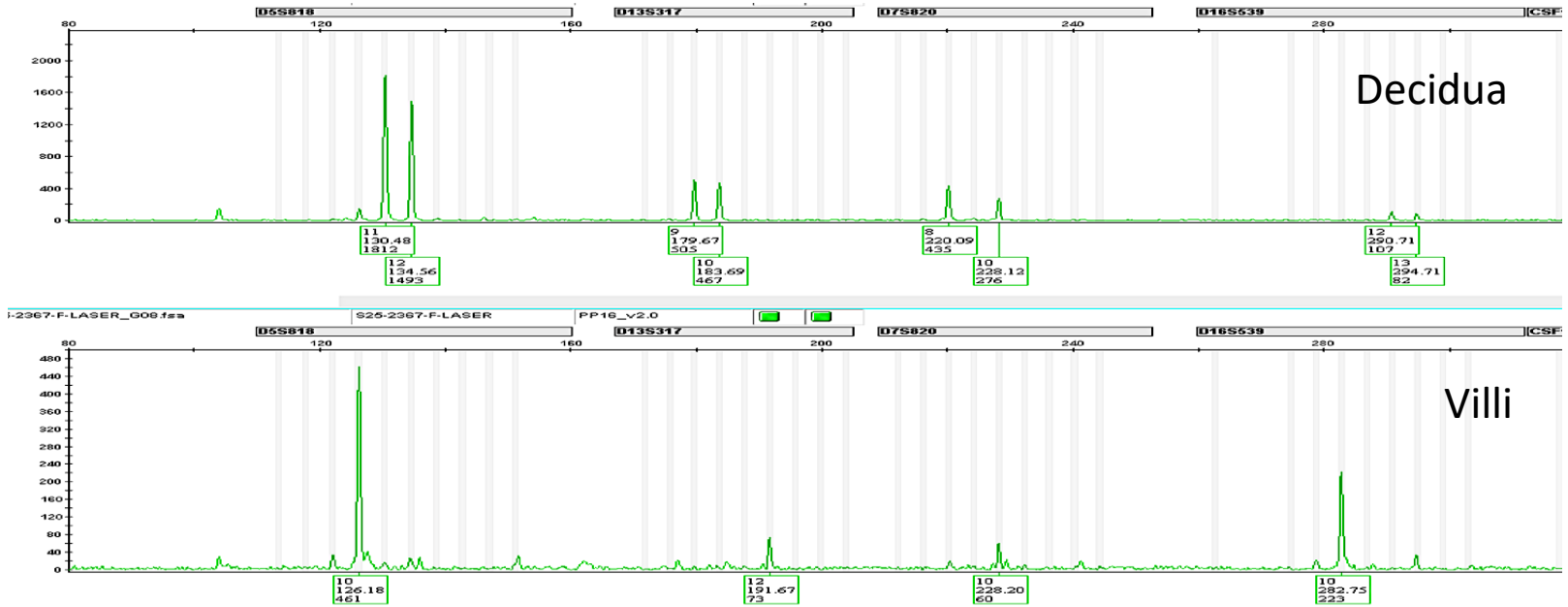
D5S818
D13S317
D7S820
D16S539
Decidua
Villi

A. Hydropic abortus
B. Complete mole
C. Partial mole

Summary: The indication for molar pregnancy was an inappropriately elevated serum hCG level for the gestational age.

The chorionic villi:

- No hydropic changes, abnormal villous shapes, or trophoblastic hyperplasia.
- Only the presence of frequent karyorrhexis.
- Loss of nuclear staining of P57 (negative pattern)

STR genotyping: homozygous paternal-only profile

Final Diagnosis: Very Early Complete Mole

Case 5: 39-year-old woman with clinical suspicion for molar gestation undergoing uterine D/C

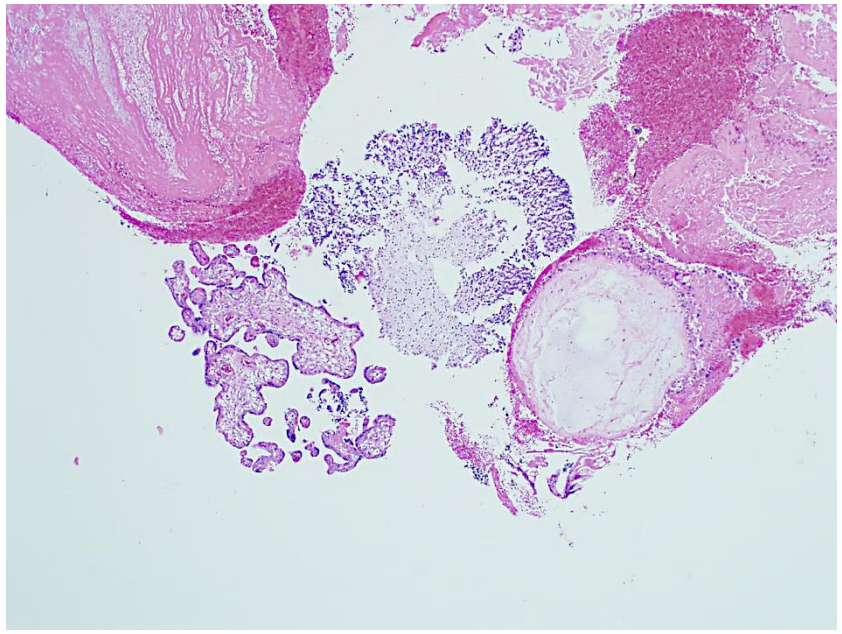
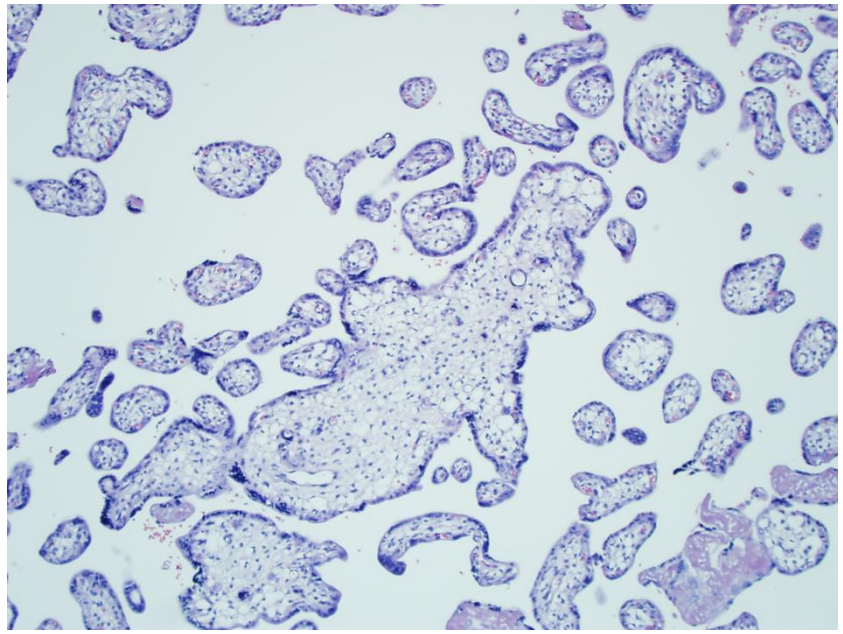
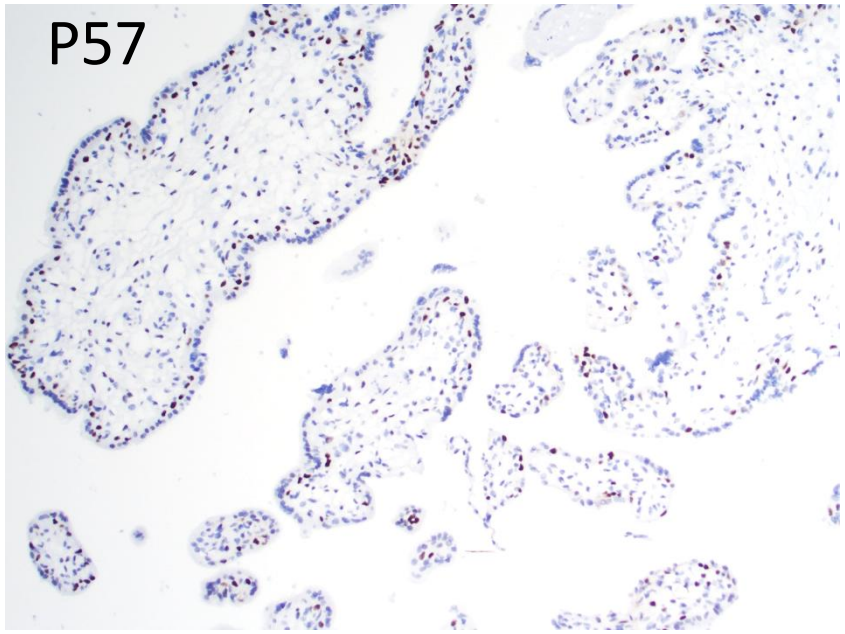
P57
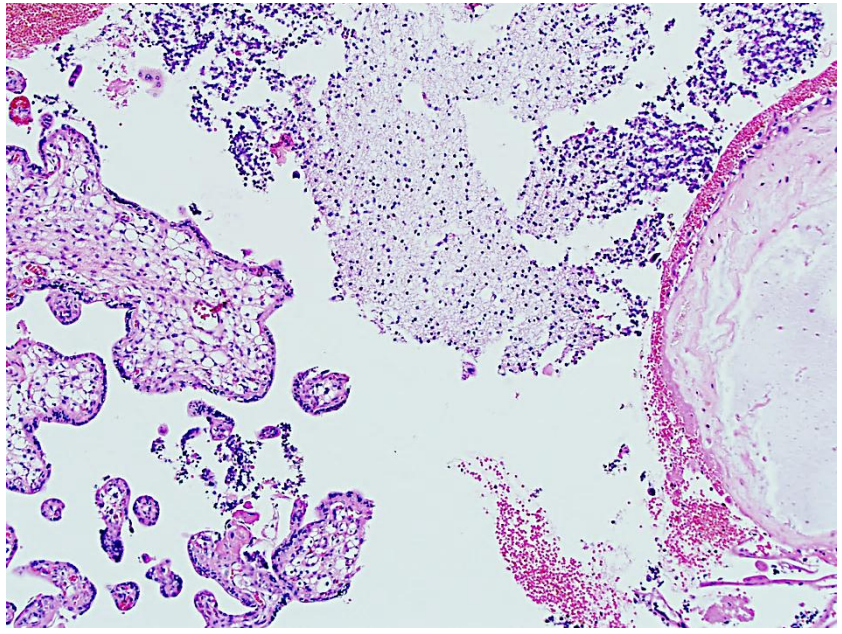
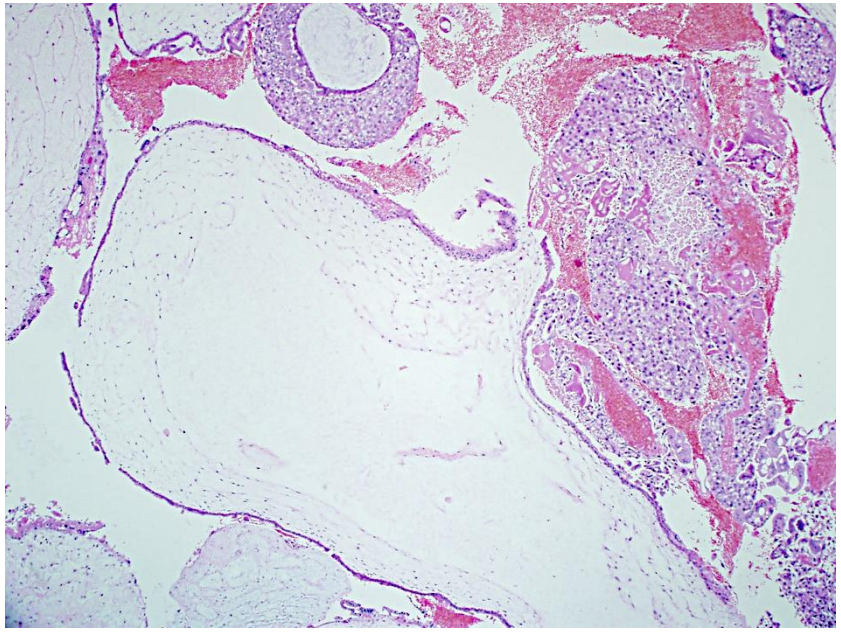
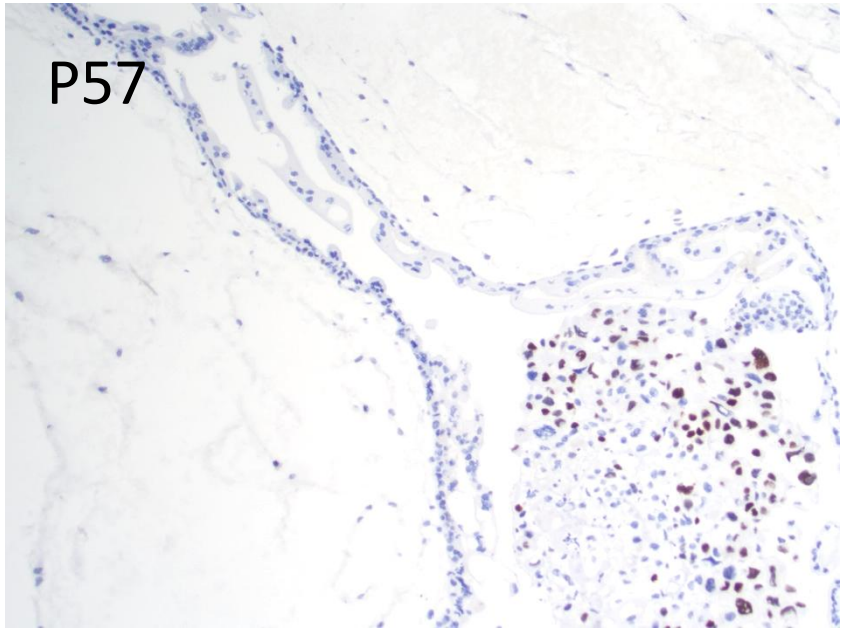
P57

A. Partial mole
B. Complete mole
C. Partial mole in Twin
D. Complete mole in Twin

Additional Histological Images

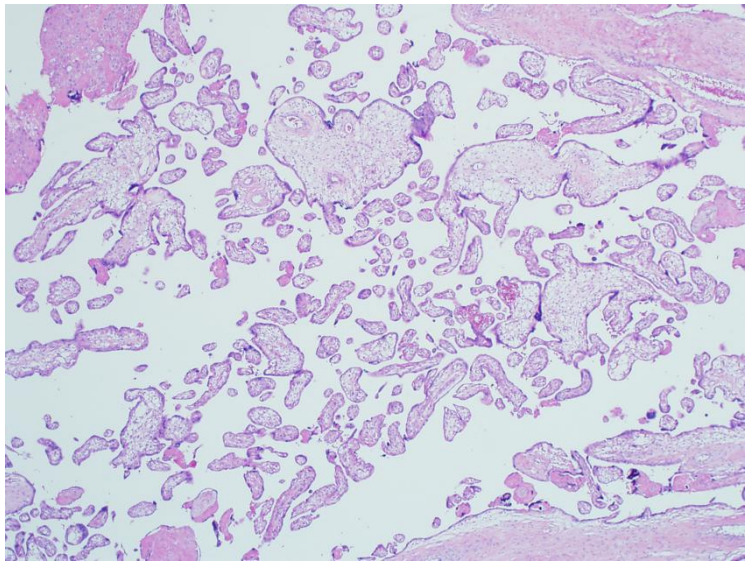

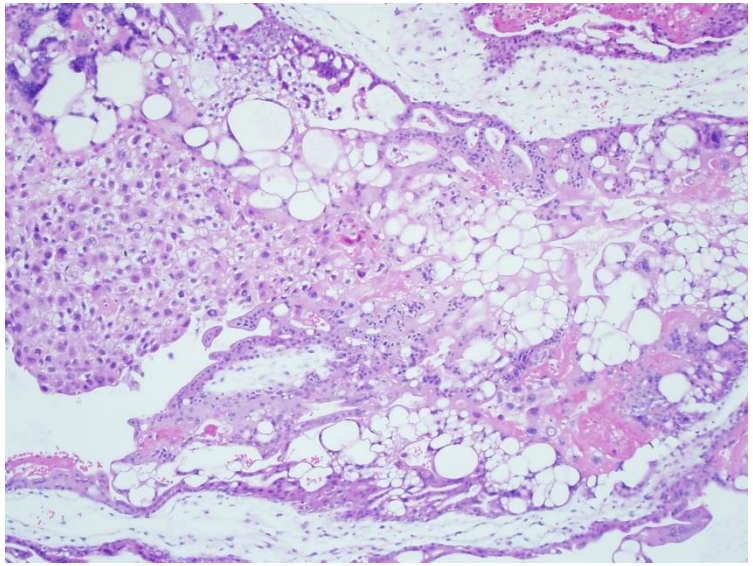

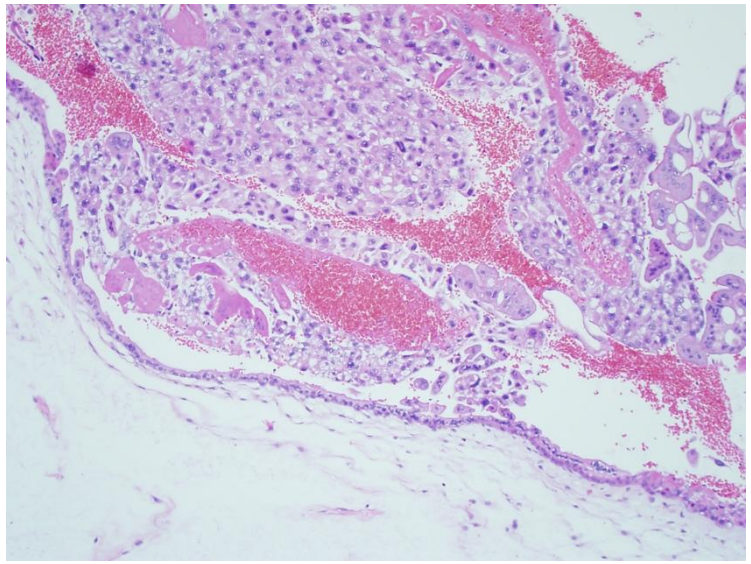

There are admixed two populations of chorionic villi: small sized non-hydropic villi and markedly enlarged hydropic villi with cistern formation, abnormal trophoblastic proliferation and loss of P57 expression in the cytotrophoblast and villous stromal cells.



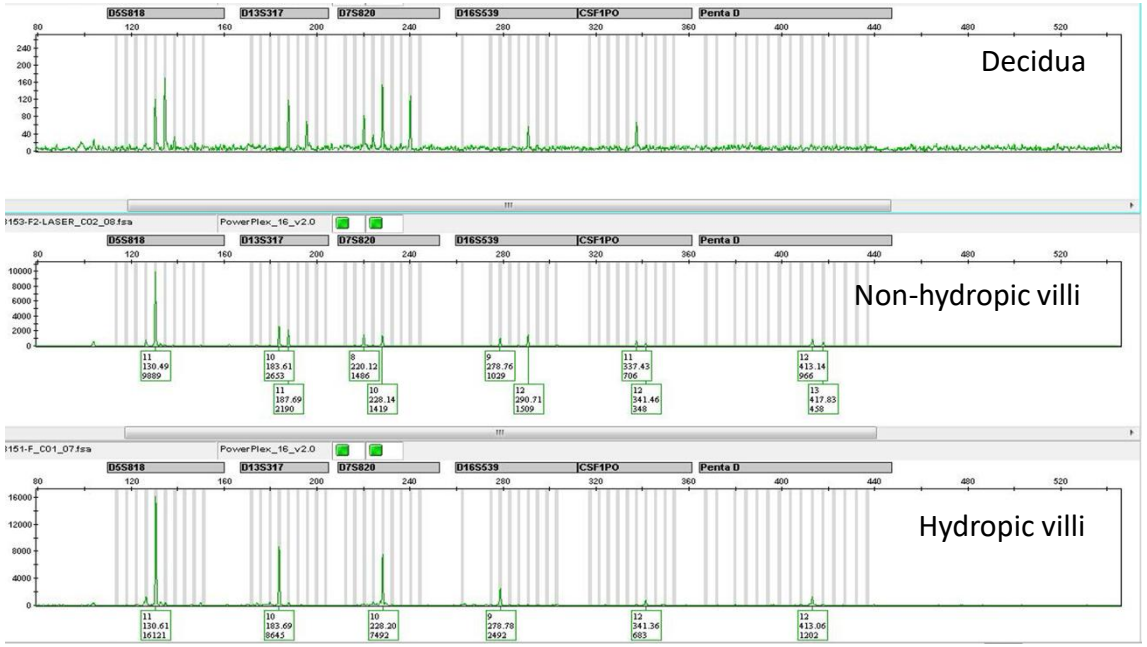



STR genotype: a balanced biparental profile in non-hydropic villi (except three allelic copies at D18S51 locus, asterisk) and a homozygous paternal-only profile in hydropic villi.

Summary

Two villous populations:

- Markedly hydropic villi with cistern formation, abnormal trophoblastic proliferation and negative P57 expression
- Normal size, non-hydropic villi with normal expression of P57

STR genotyping: homozygous paternal-only profile in hydropic villi and balanced biparental profile except three allelic copies at D18S51 locus in non-hydropic villi.

Final Diagnosis: Twin gestation consisting of a complete mole and a non-molar placenta with possible Trisomy 18.

Case 6: 37-year-old woman presented with missed abortion.

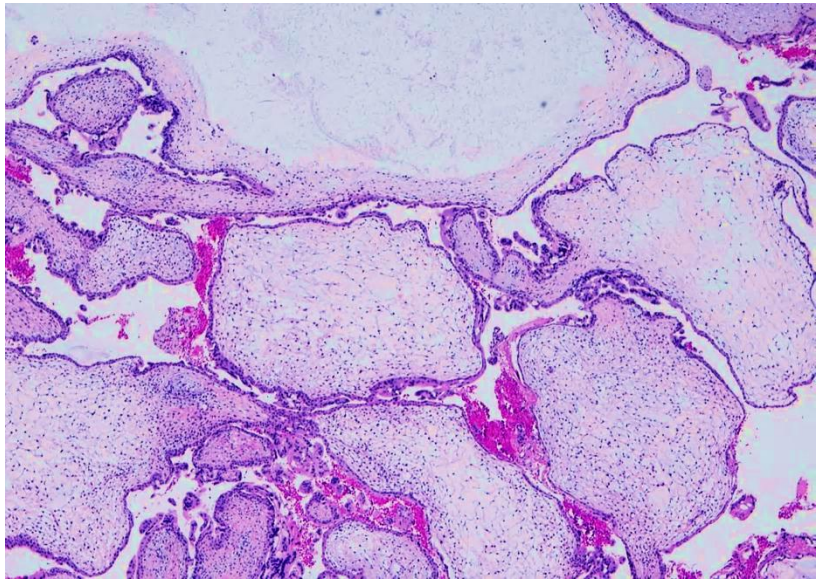

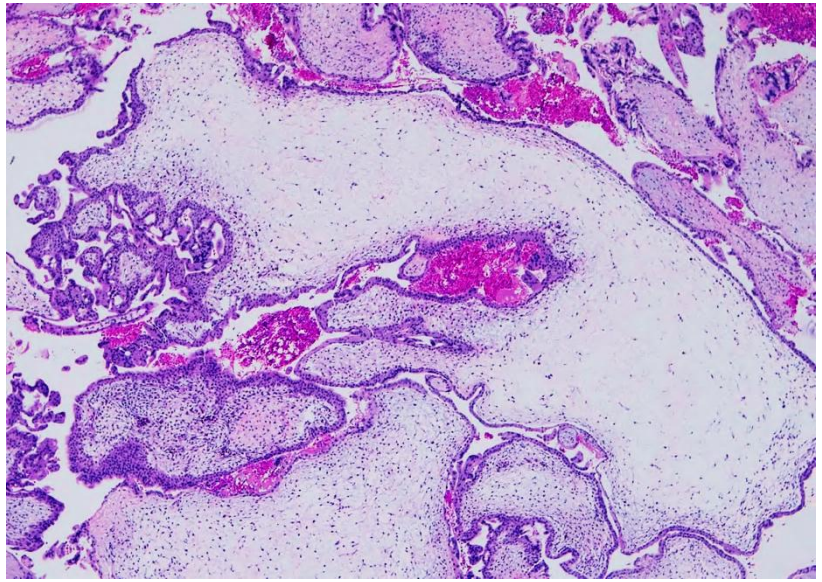

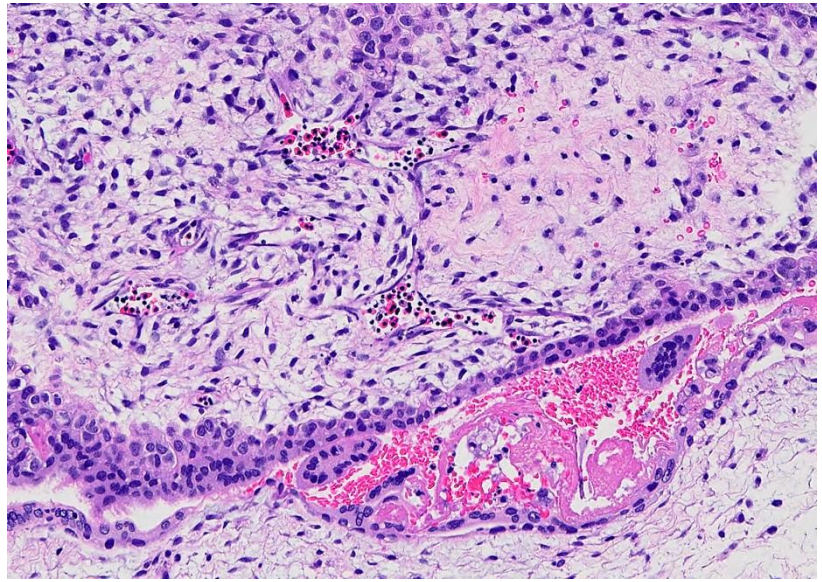

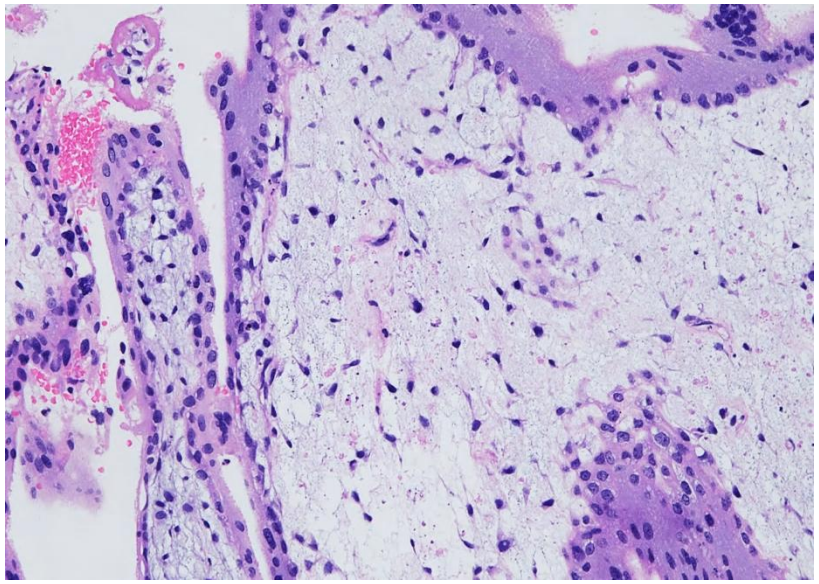

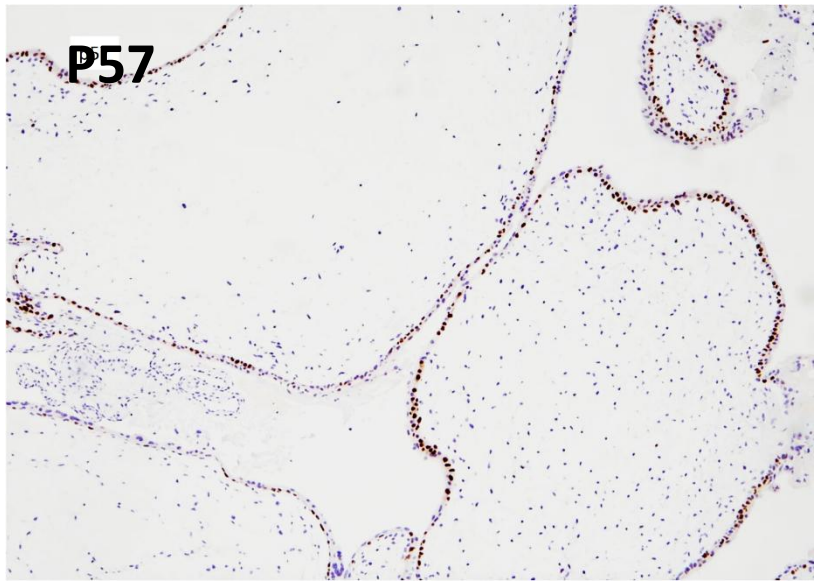
P57

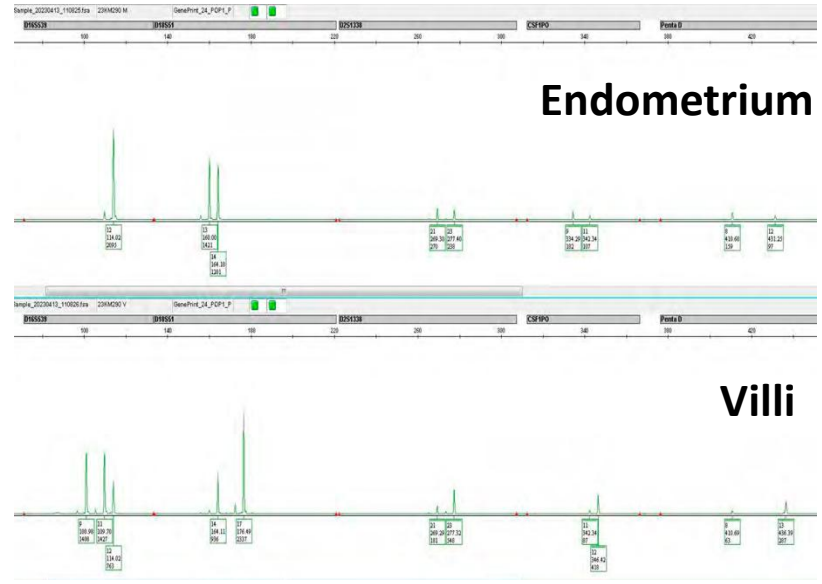
Endometrium
Villi

A: Complete mole
B: Partial mole
C. Androgenetic biparental mosaic
D. CHM arising in androgenetic/biparental mosaic

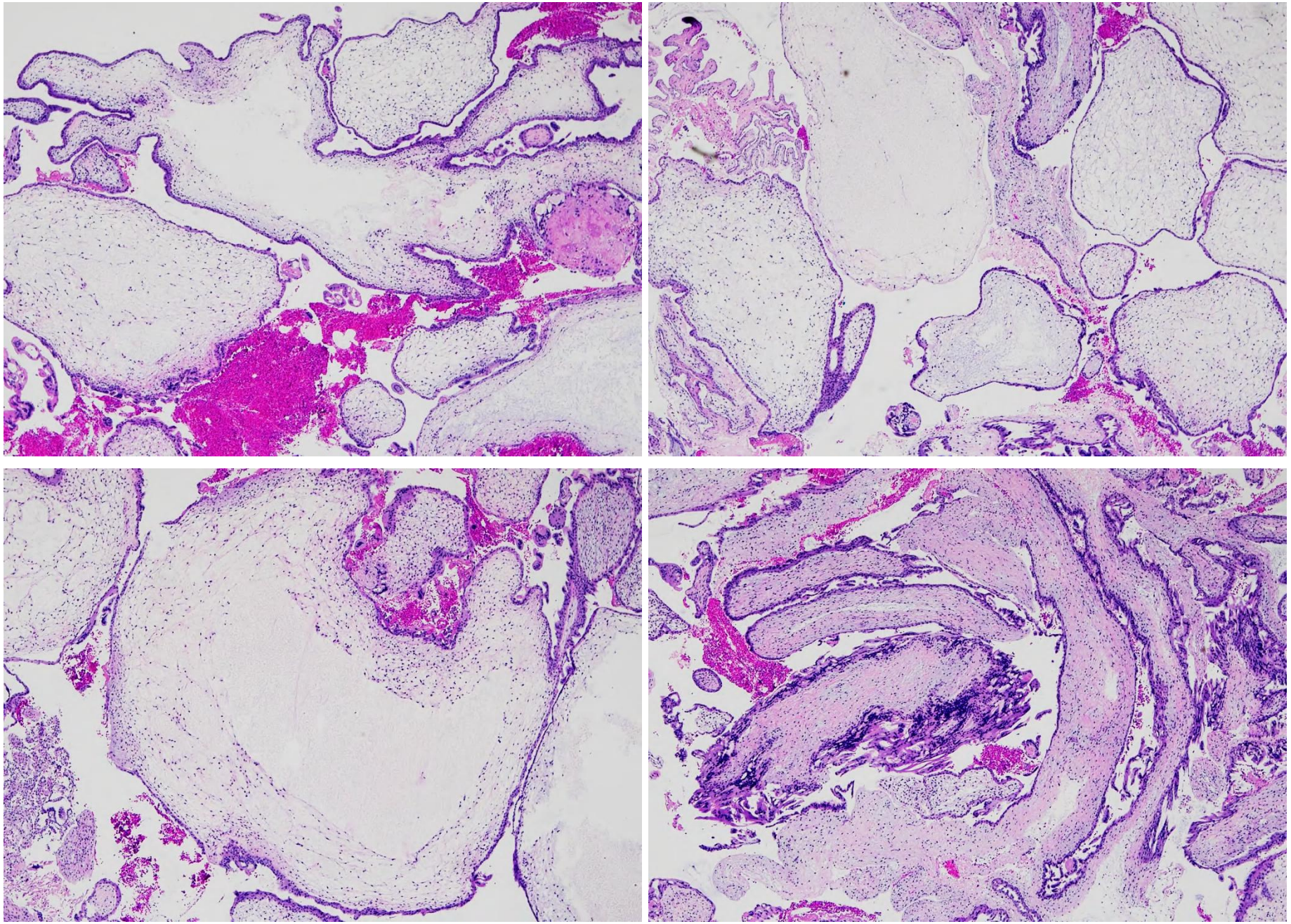

Additional images

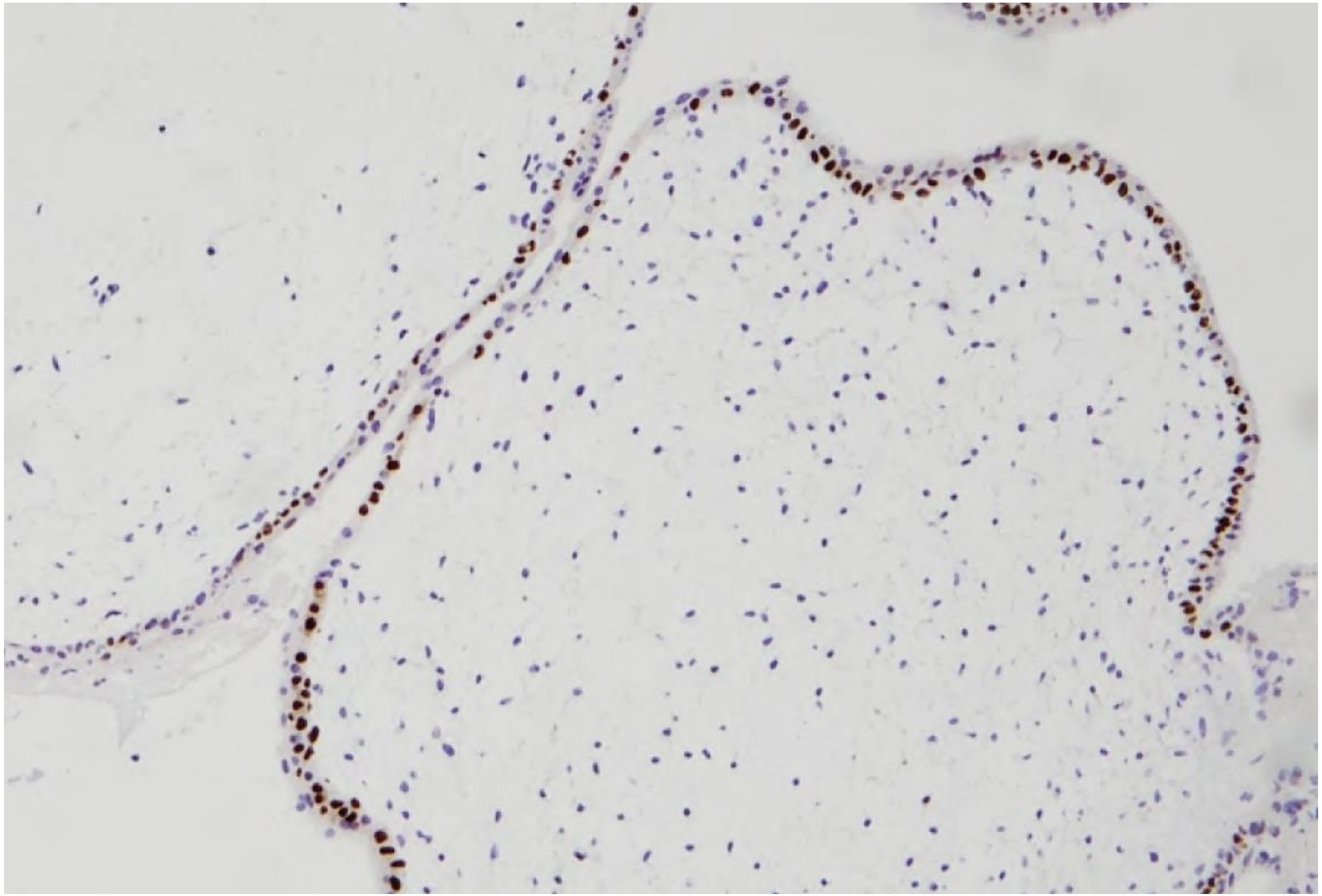

P57 IHC

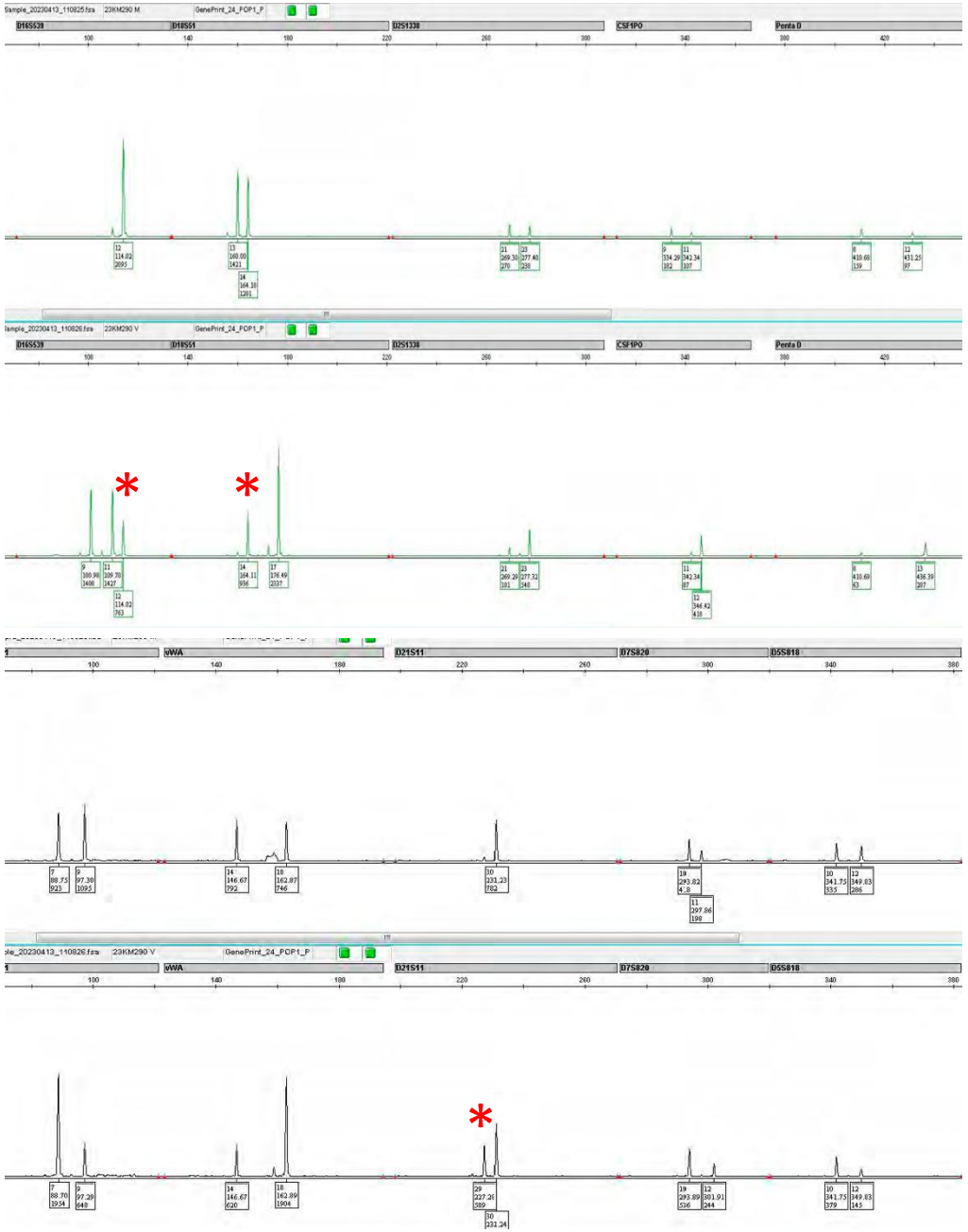
D16S539
D18S51
D2S1338
CSF1PO
Penta D
vWA
D21S11
D7S820
D5S818
*
*
*

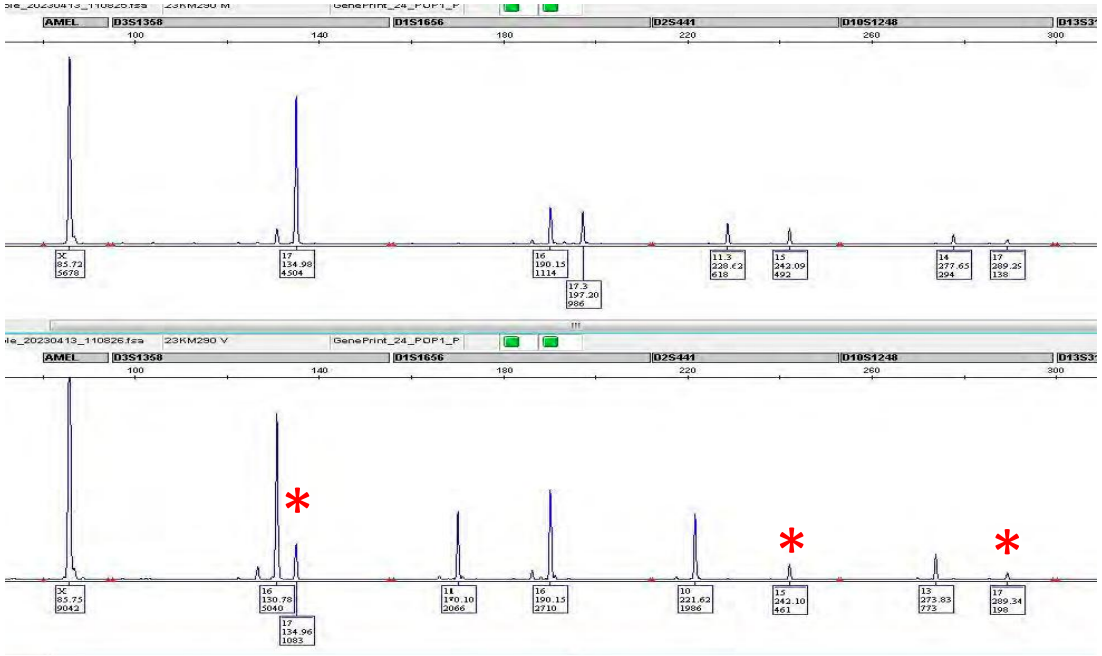
AMEL
D3S1358
D1S1656
D2S441
D10S1248
*
*
*

Case Summary

Most chorionic villi:

- Hydropic changes including cistern formation,
- Abnormal configuration and size.
- Hypercellular and myxoid with prominent karyorrhectic debris.
- Presence of nucleated RBCs.
- Discordant P57 (negative in stromal cells but positive in cytotrophoblast)

STR genotyping: two heterozygous paternal alleles and one maternal allele with paternal:maternal(P:M) ratio of >2:1 at informative loci, indicating admixed androgenetic (villous stroma) and biparental (cytotrophoblast) cells.

Final Diagnosis: Androgenetic/Biparental Mosaic Gestation

Case 7: Missed abortion in a patient in her 30s

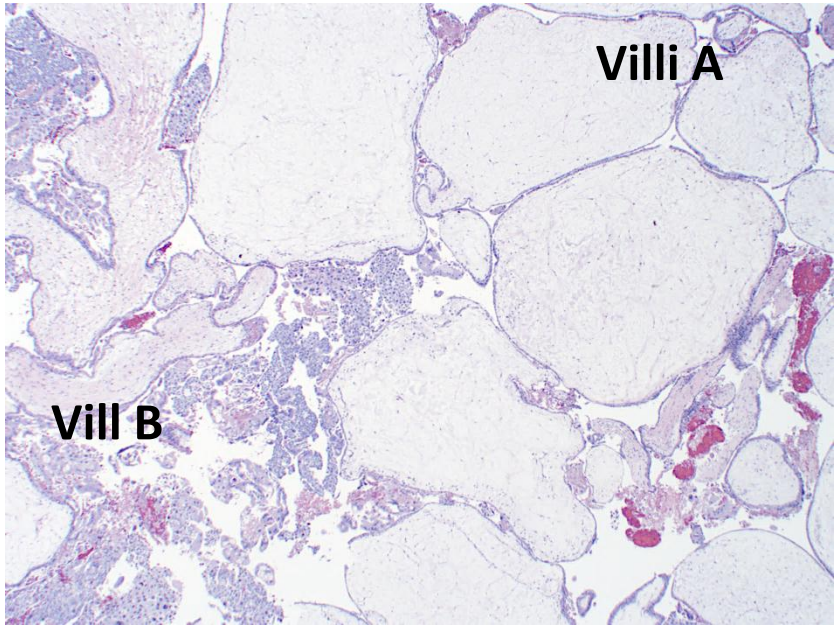

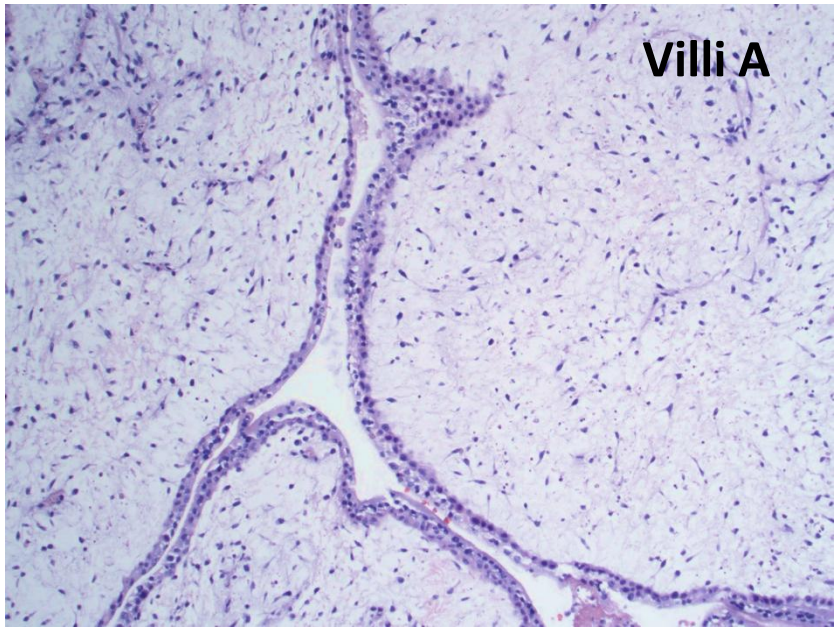

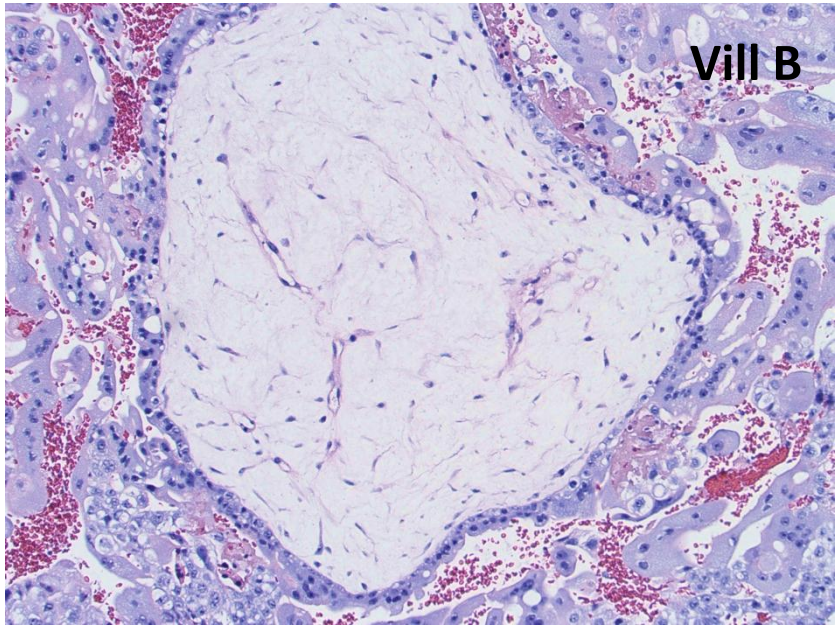

Villi A: without trophoblastic hyperplasia

Villi B: with trophoblastic hyperplasia

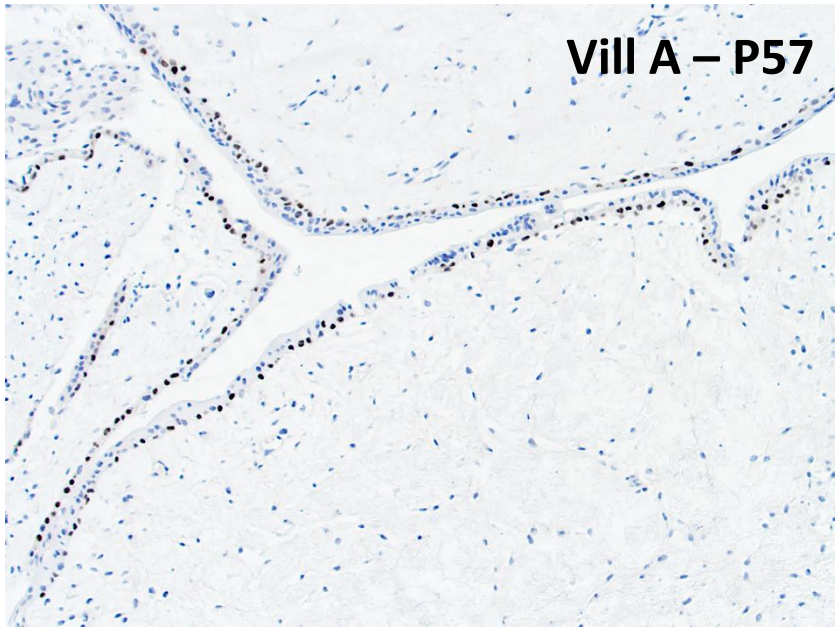

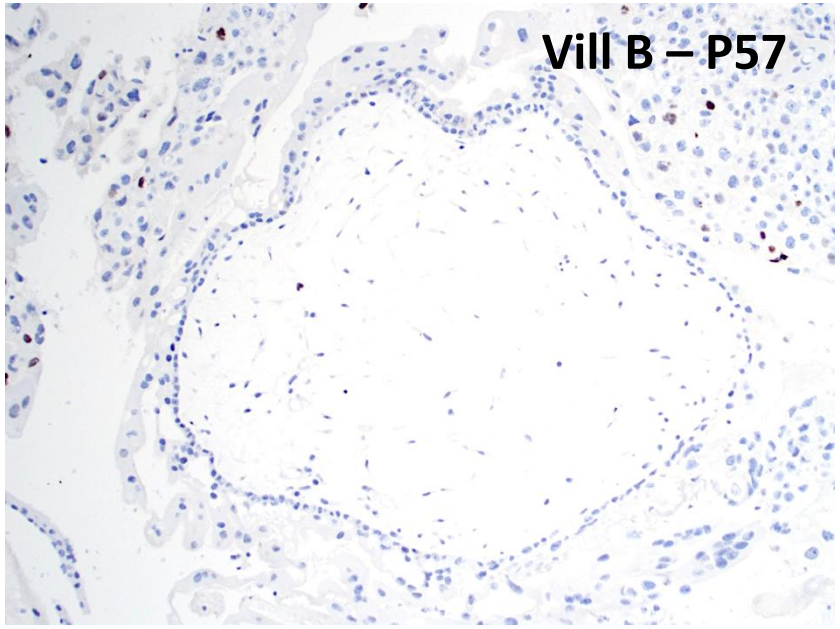



Note a biparental profile with excess homozygous paternal allelic copies at each STR locus in villi without trophoblastic hyperplasia, and a homozygous paternal-only profile in villi with trophoblastic hyperplasia.

A. Partial Mole
B. Complete mole
D. Androgenetic biparental mosaic
C. CHM arising in androgenetic/biparental mosaic

Villi with Trophoblastic Hyperplasia

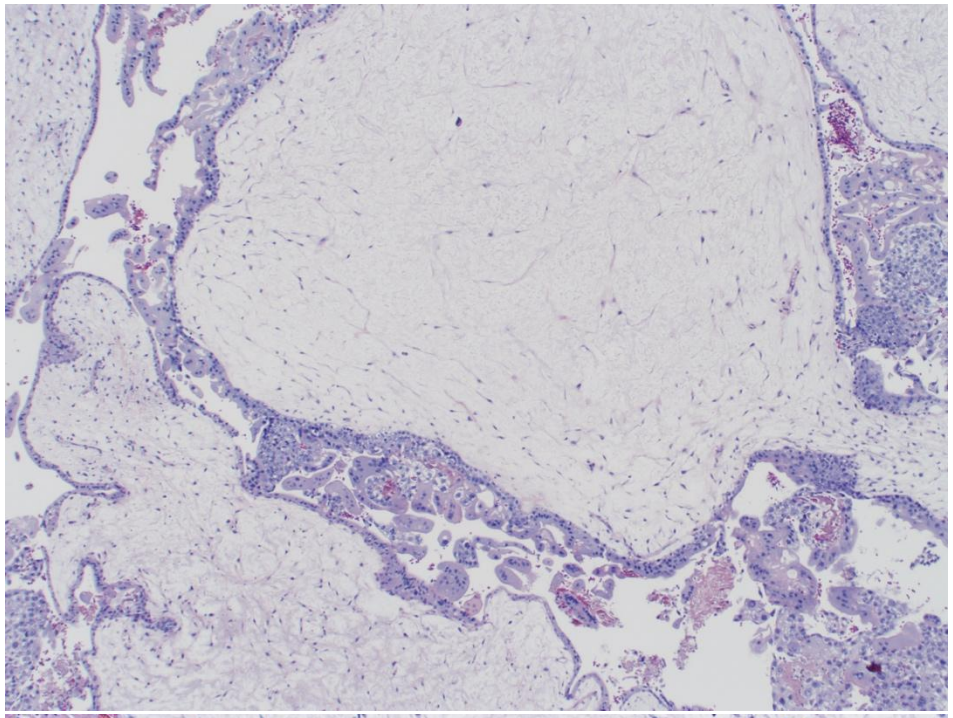

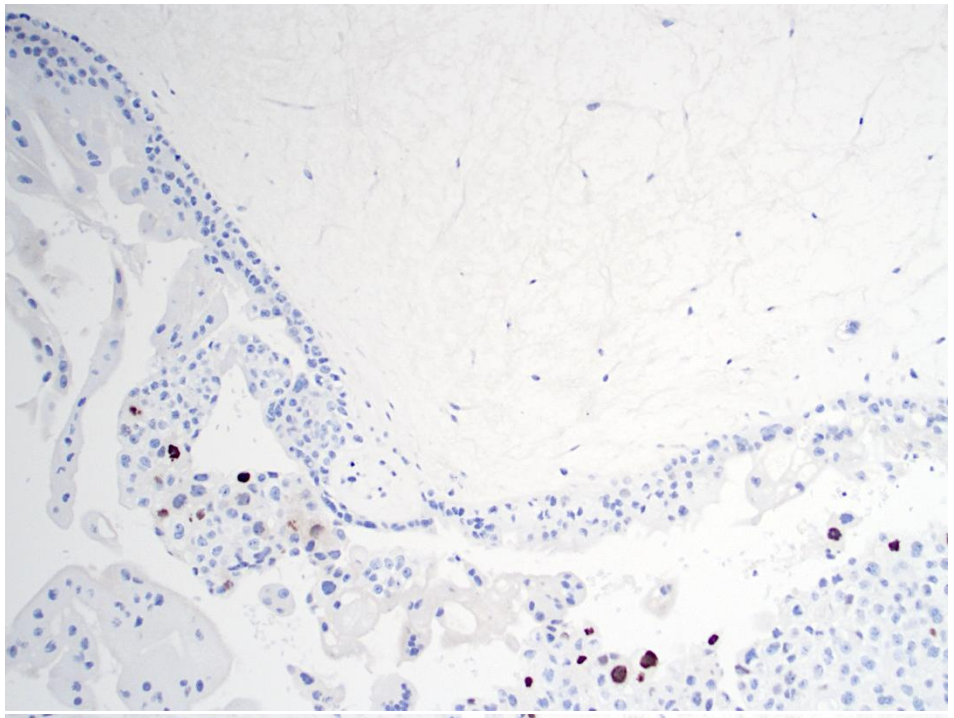

Villi without trophoblastic hyperplasia

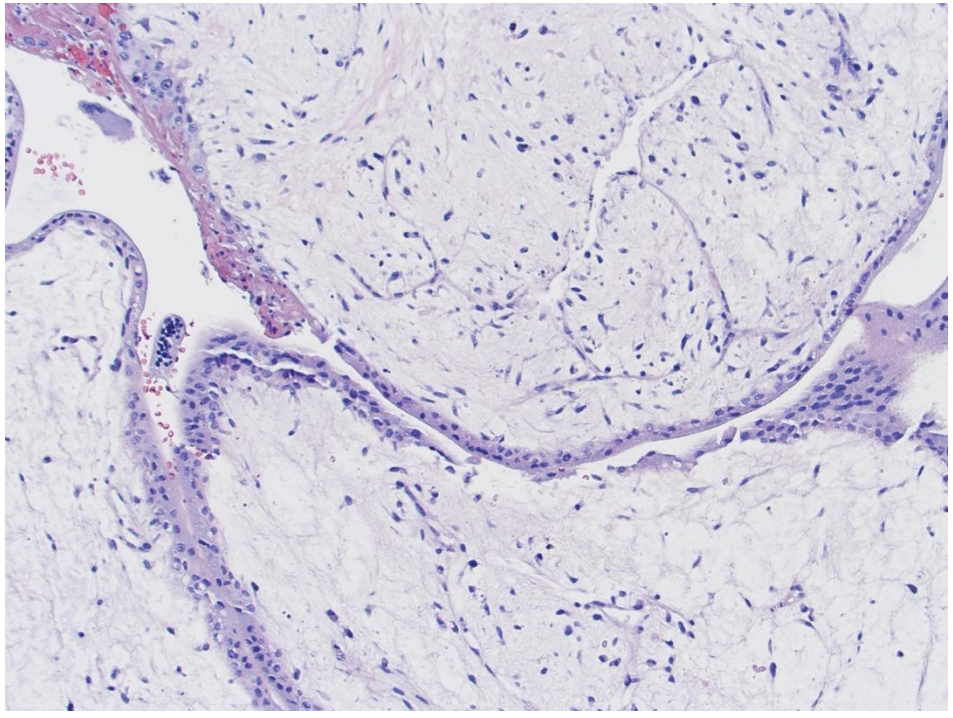

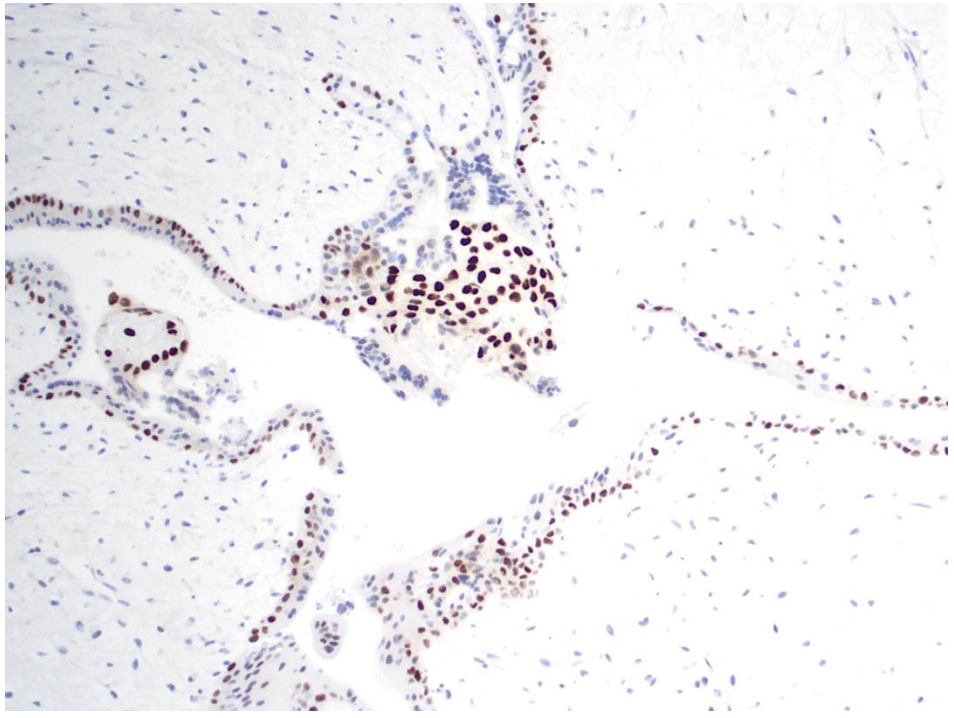

Summary

Chorionic villi:

- Most villi: Marked hydropic changes, including cistern formation and abnormal stroma, and discordant P57 (+cytotrophoblasts and – stromal cells).
- Some villi: Abnormal trophoblastic proliferation and complete loss of p57 expression in both cytotrophoblast and stromal cells(negative P57)

STR genotyping: two heterozygous paternal and one maternal with paternal:maternal ratio of >2:1 in villi with discordant P57, and a homozygous paternal-only profile in villi with marked trophoblastic proliferation and negative P57.

Final Diagnosis: Complete Mole arising from Androgenetic/Biparental Mosaic Gestation

https://medicine.yale.edu/pathology/clinical/precision-medicine-trophoblastic-disease/

About Us

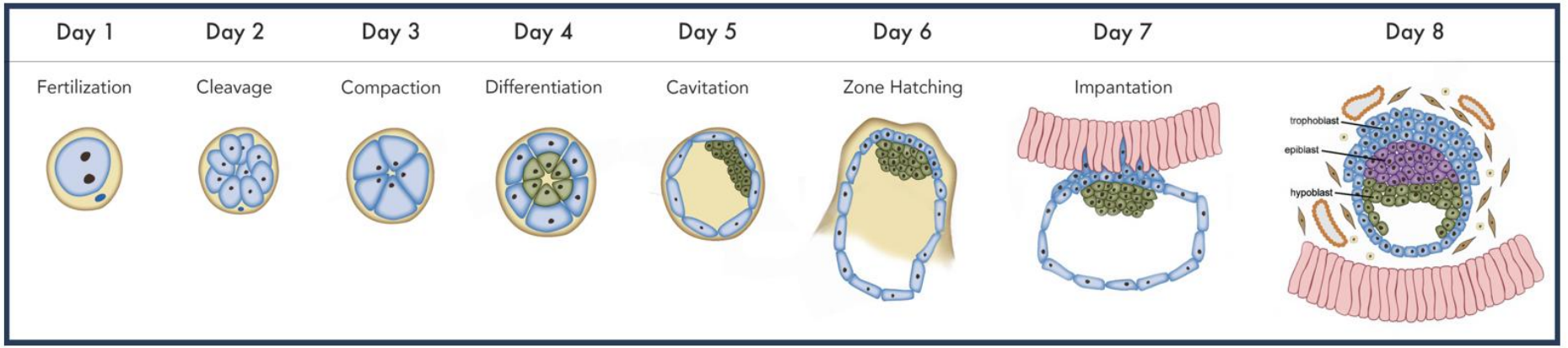

THANK YOU

