The British Association of Gynaecological Pathologists

Masterclass with the Experts in Collaboration with ISGyP
4th June 2025

- Practical issues in endometrial immunohistochemistry interpretation
- Dr Richard Wong
- Department of Pathology, United Christian Hospital, Hong Kong
- 4th June 2025

The British Association of Gynaecological Pathologists

Speaker disclosures

- ❑ I have no financial conflicts of interest to disclose

What will be covered in the session

- 5 cases will be presented
- Digital slides of H&E and selected IHC
- Challenges in diagnosis and IHC interpretation
- Discussion of recent literature related to the topics
- Questions from the audience

Case 1

- 46 years old
- Menorrhagia
- Endometrial biopsy reported as endometrioid carcinoma with mucinous features
- Mismatch repair (MMR) IHC performed

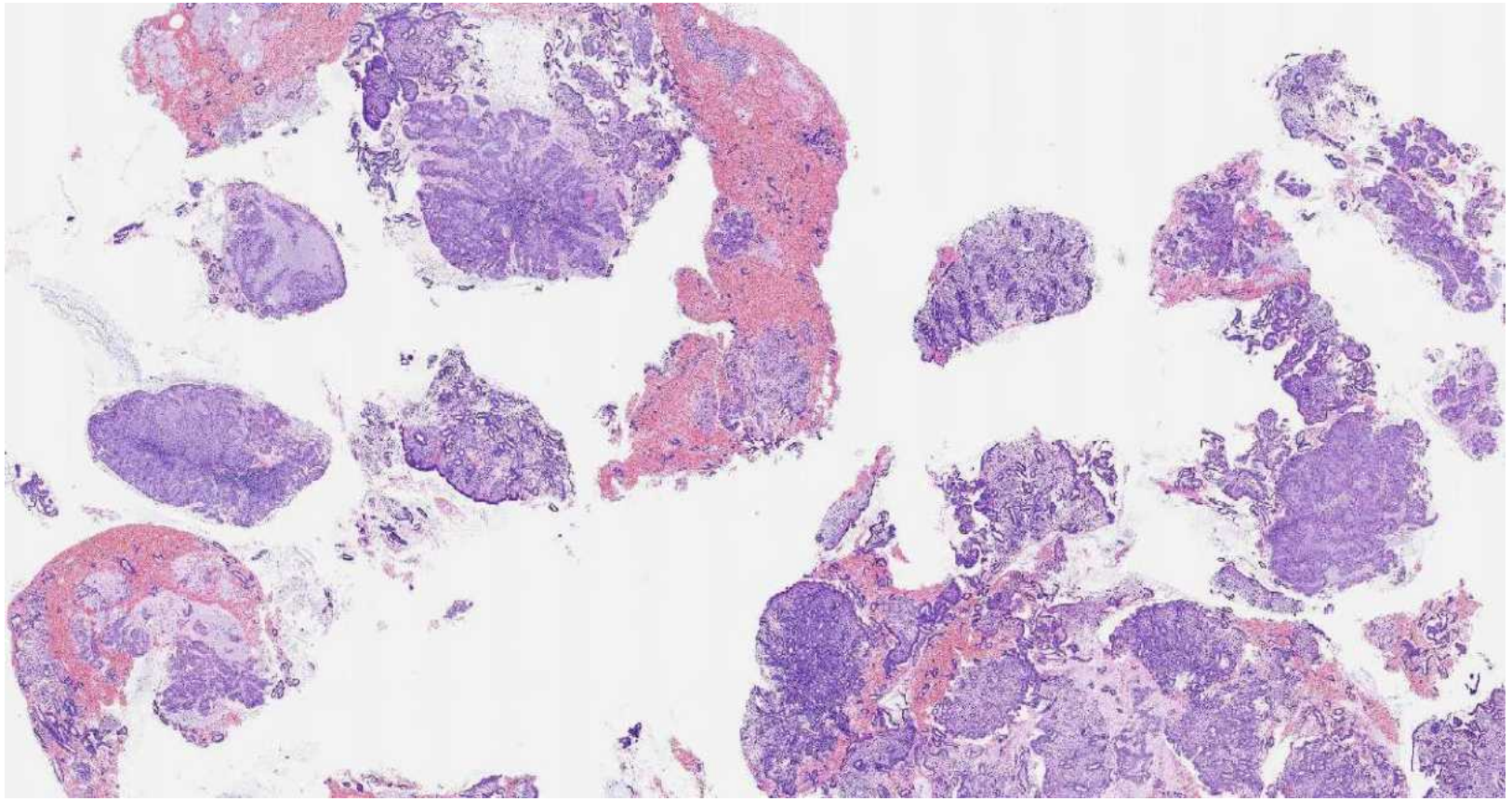

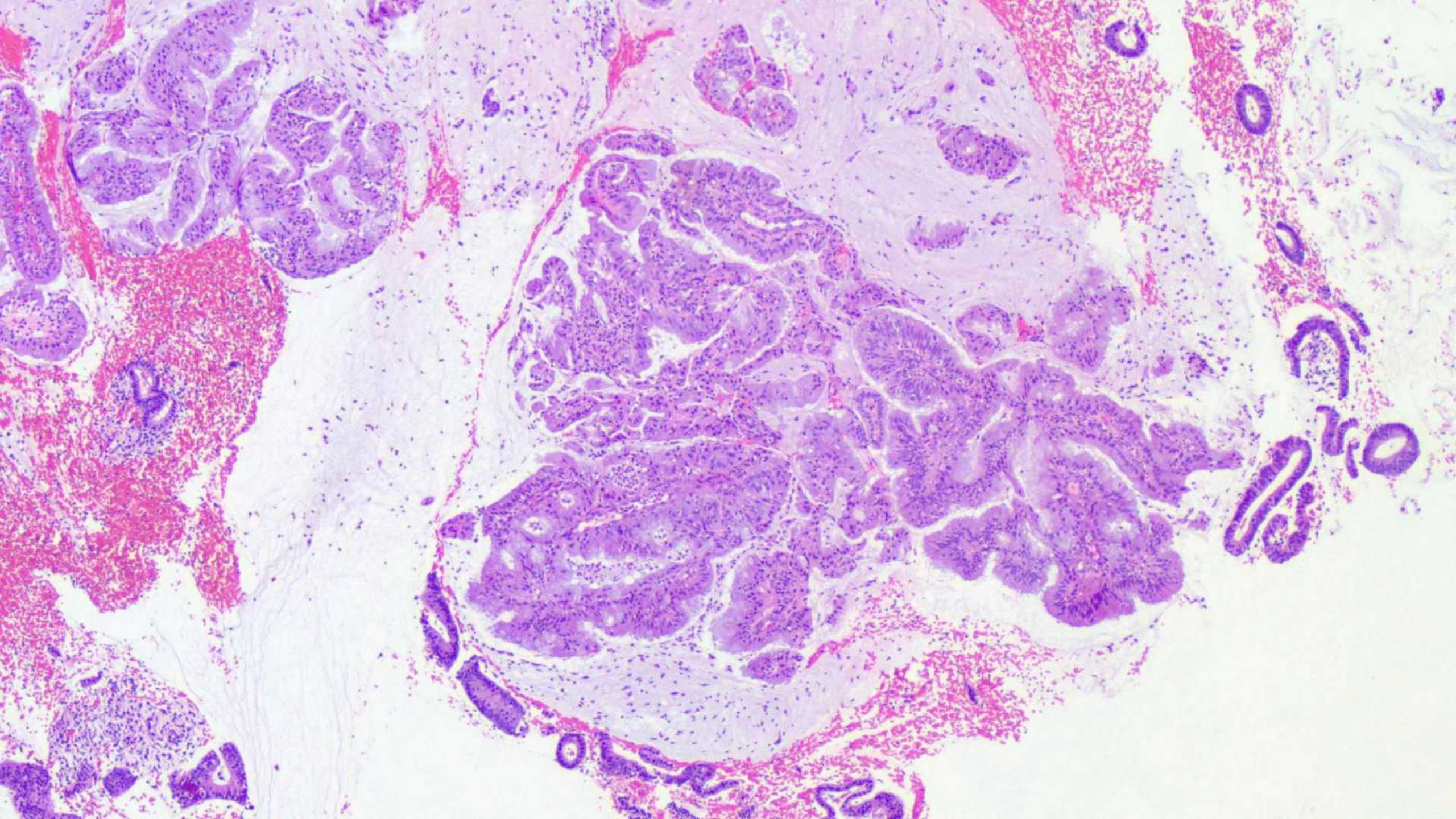

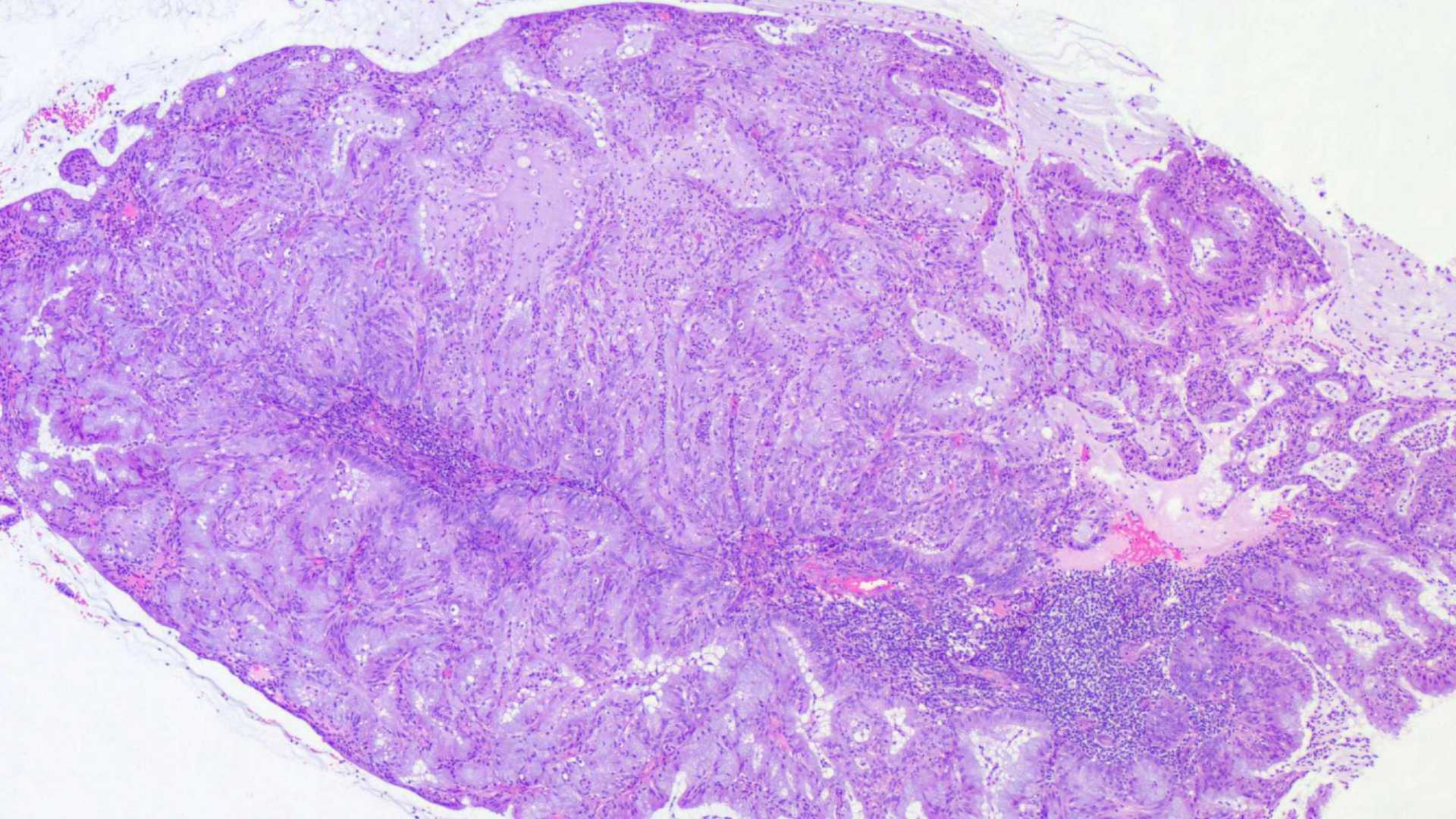

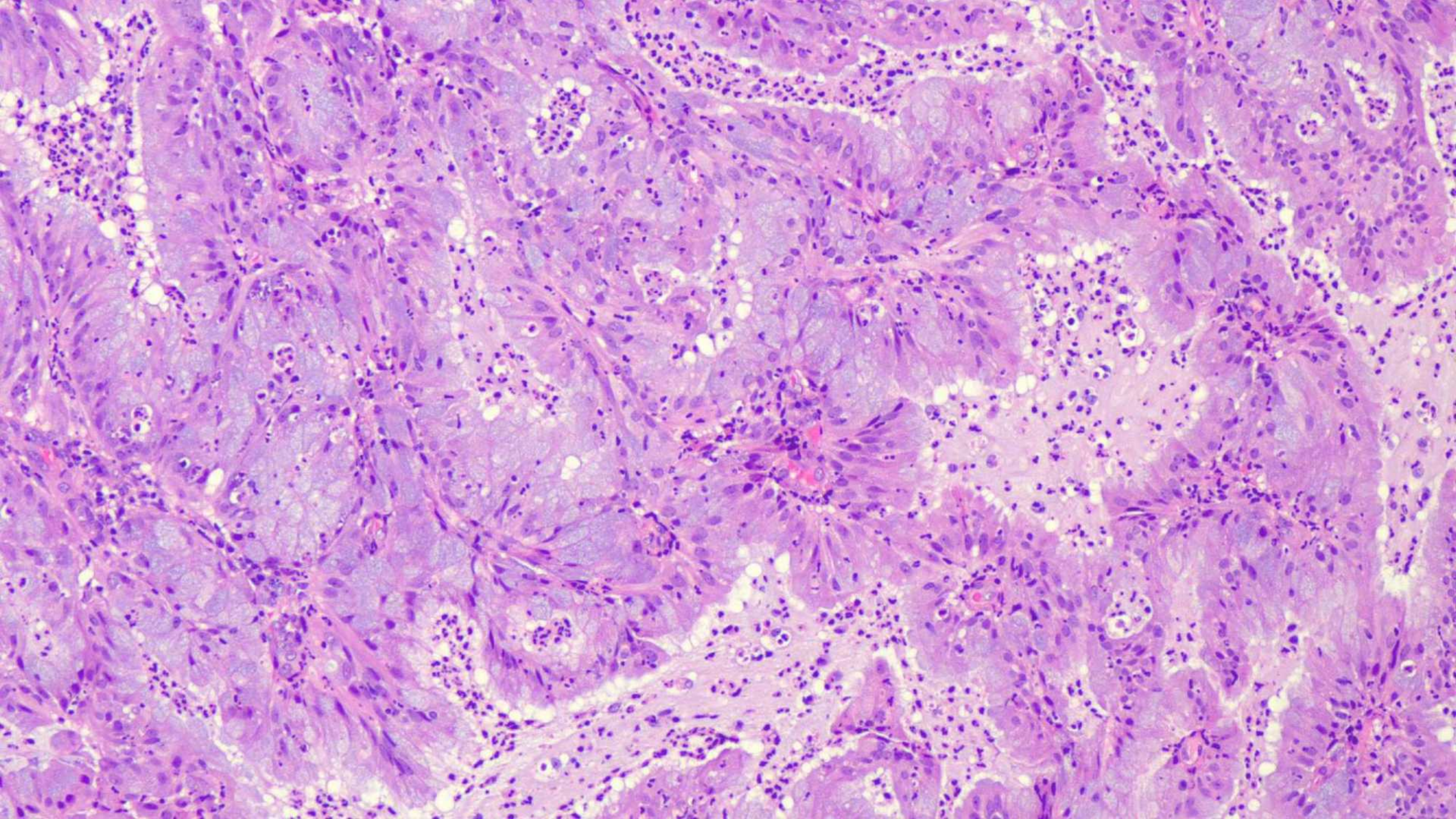

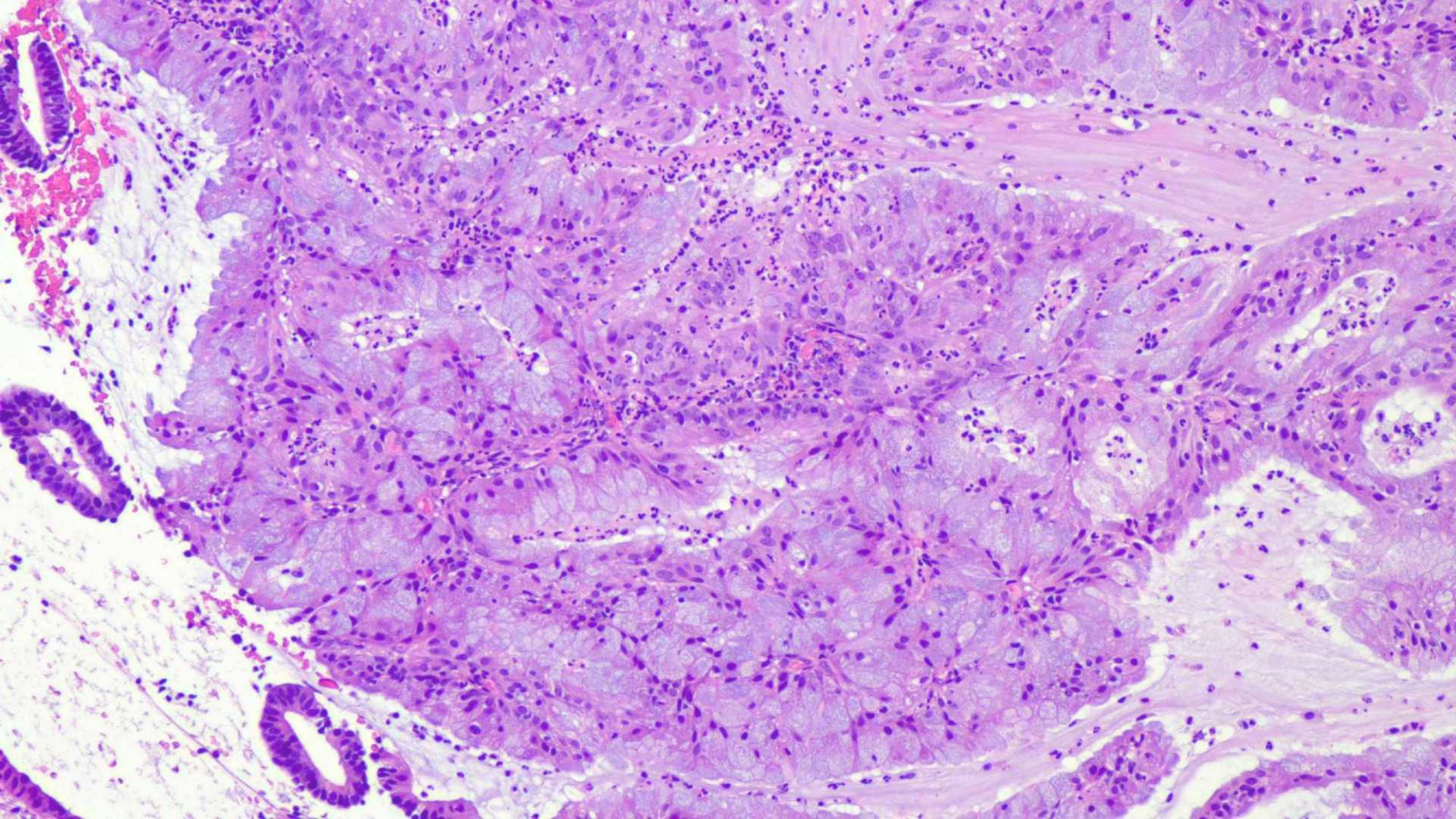

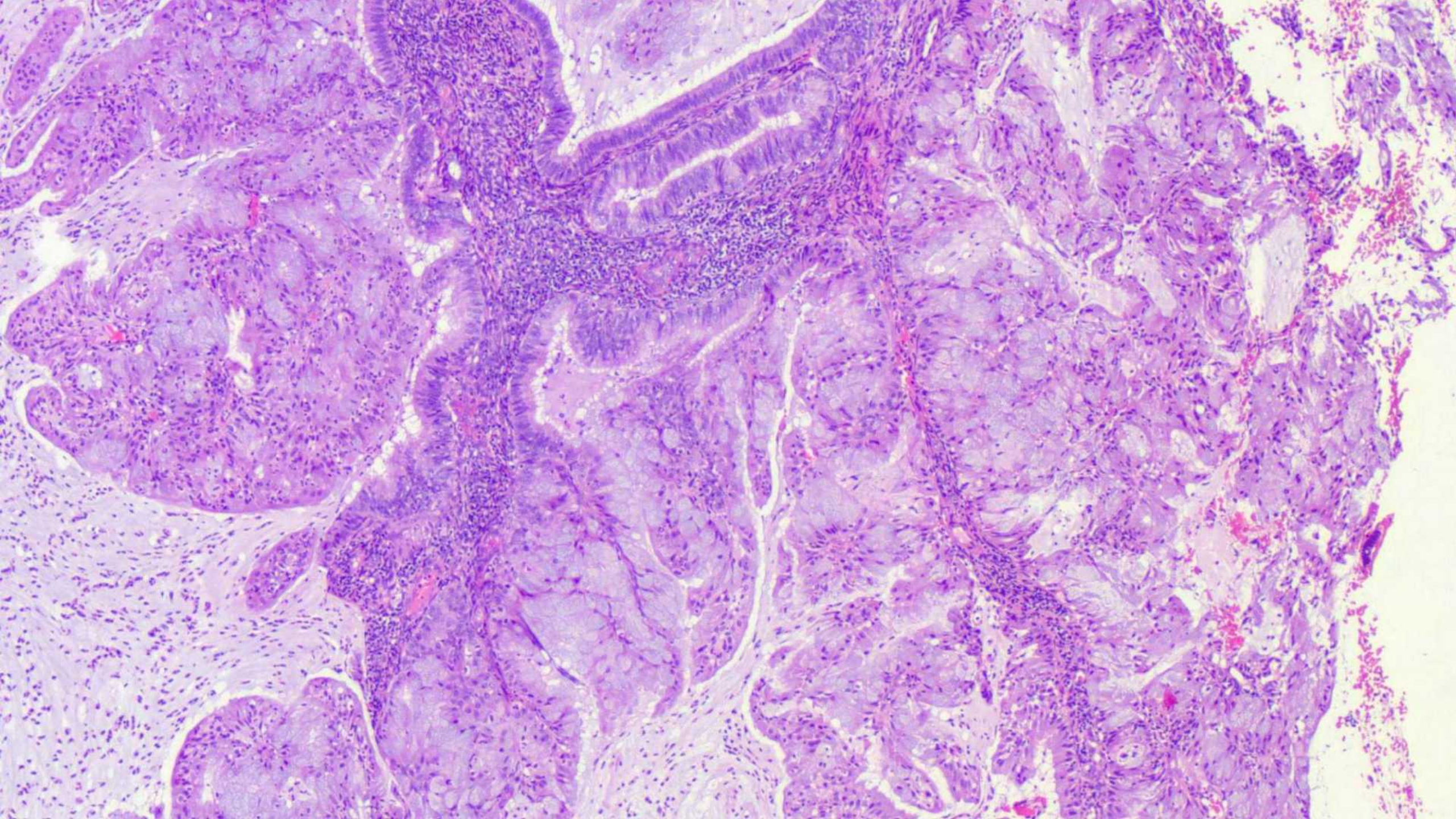

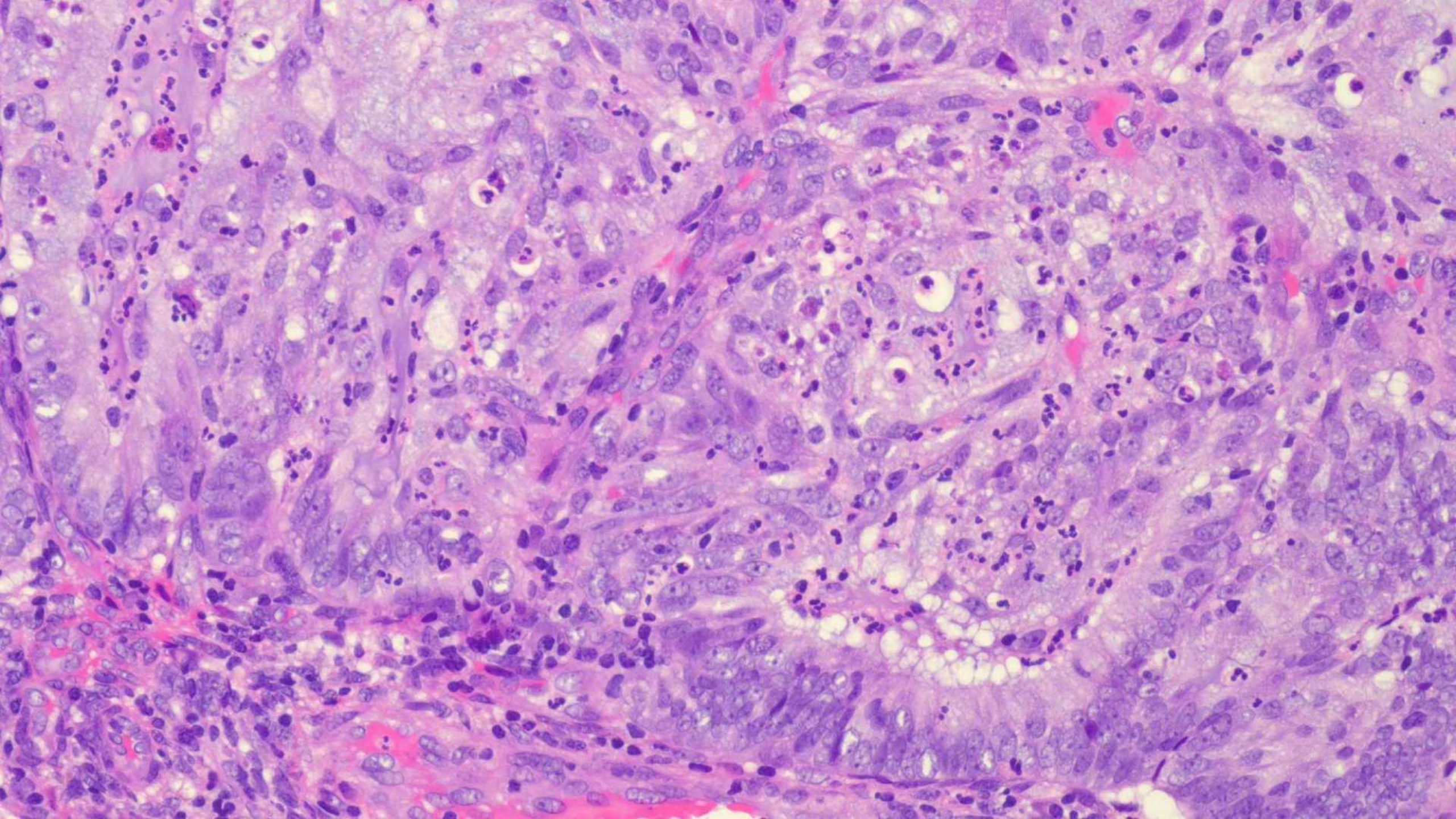

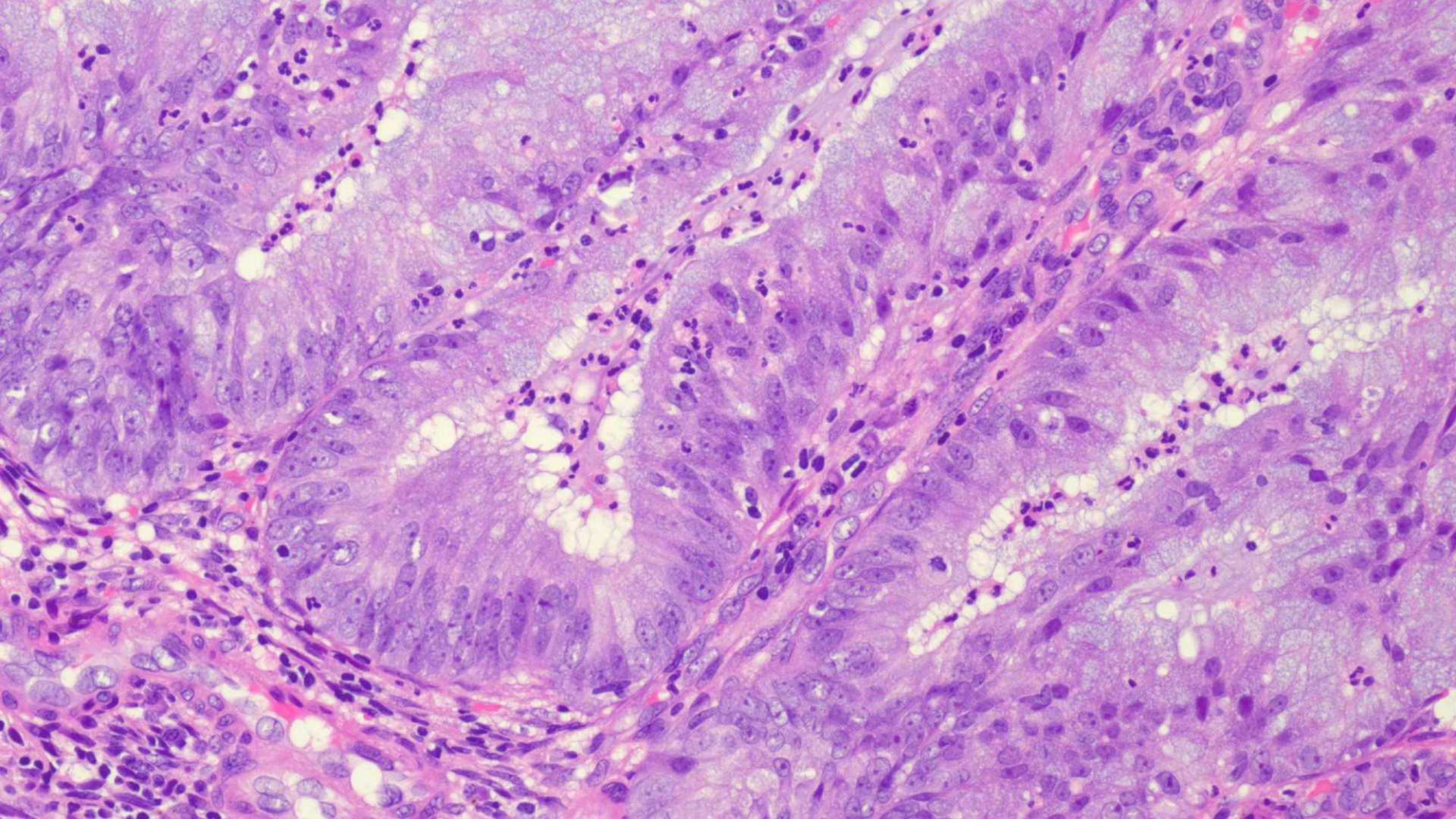

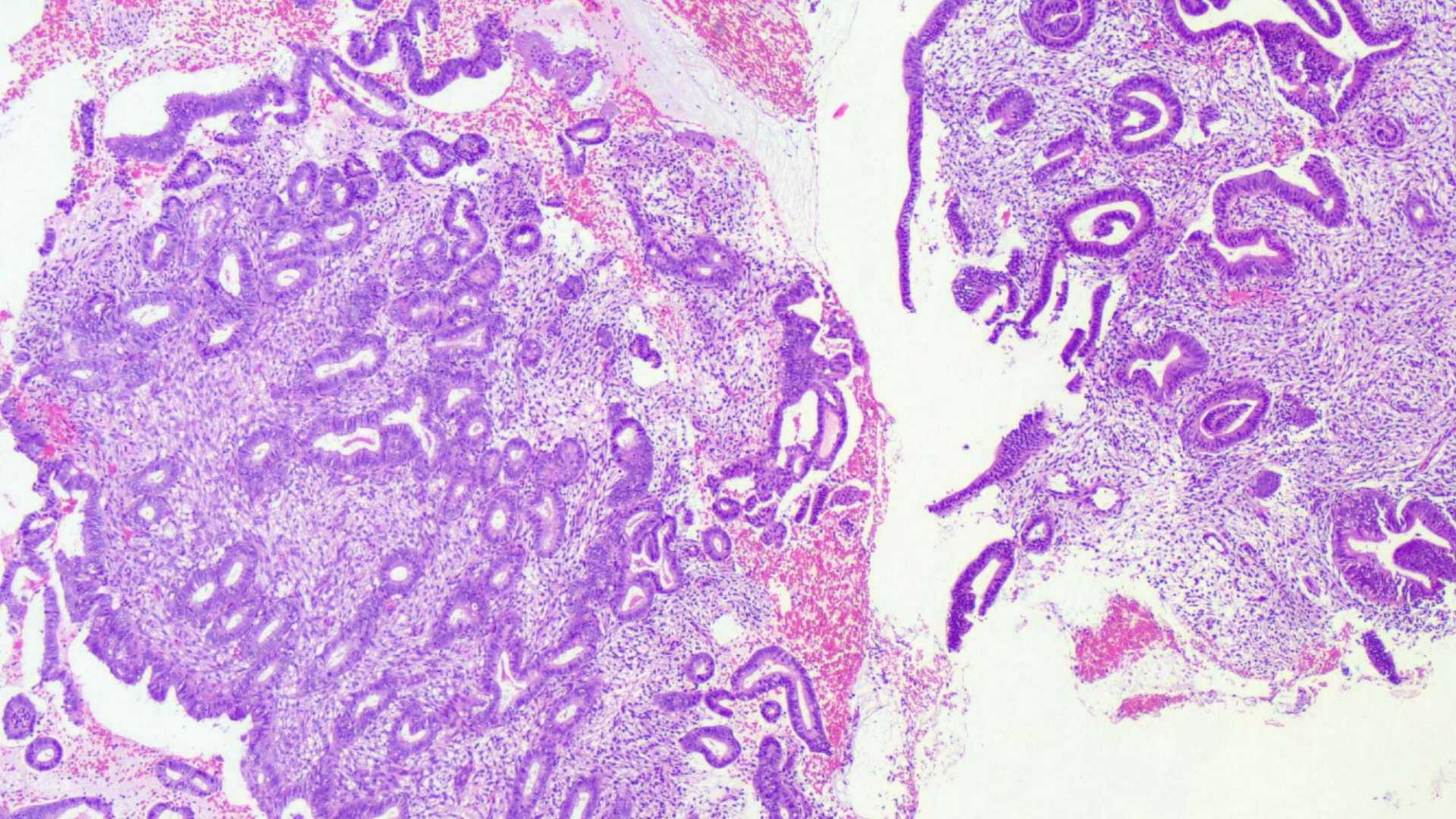

Case 1

- MLH1

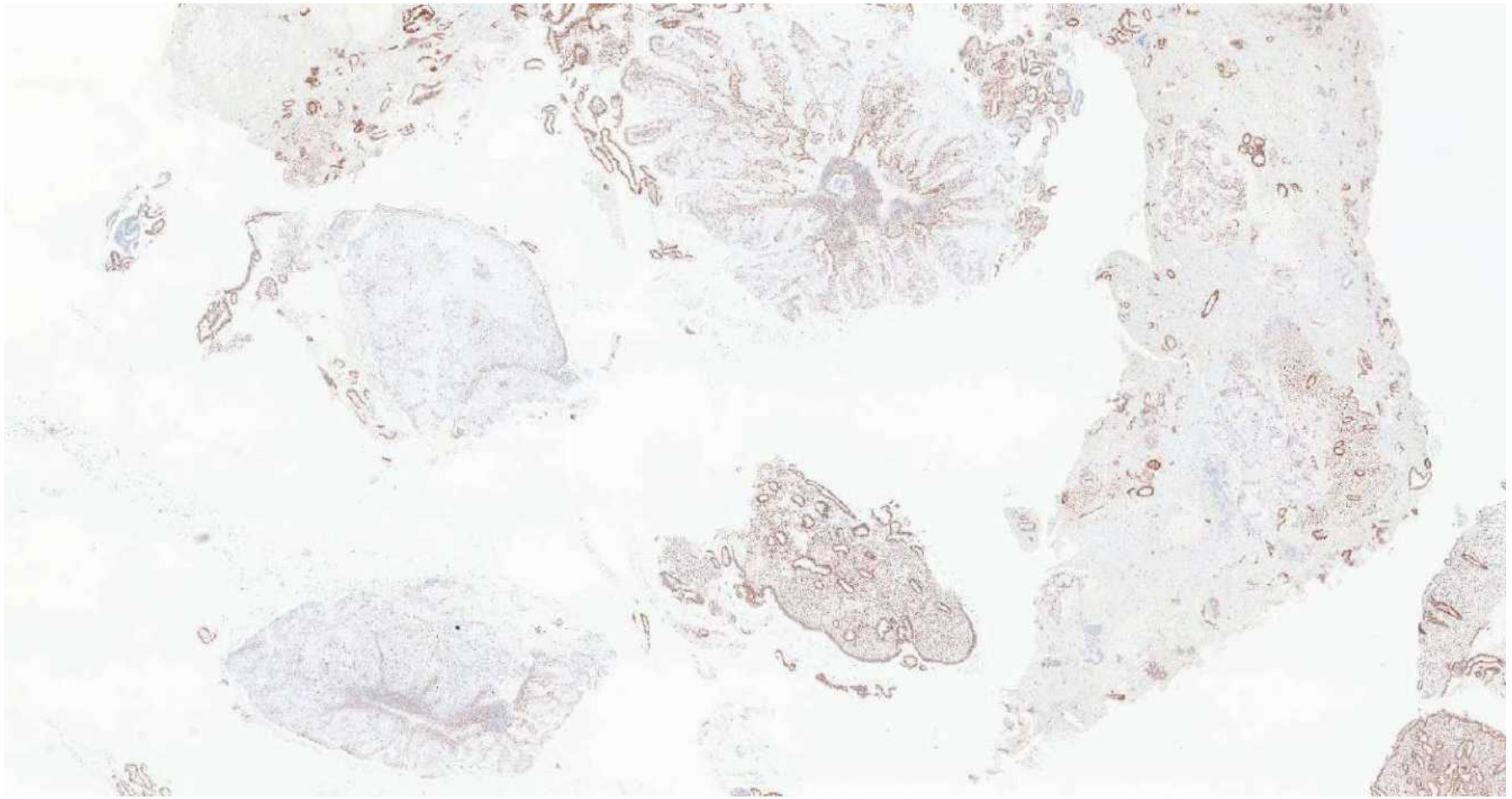

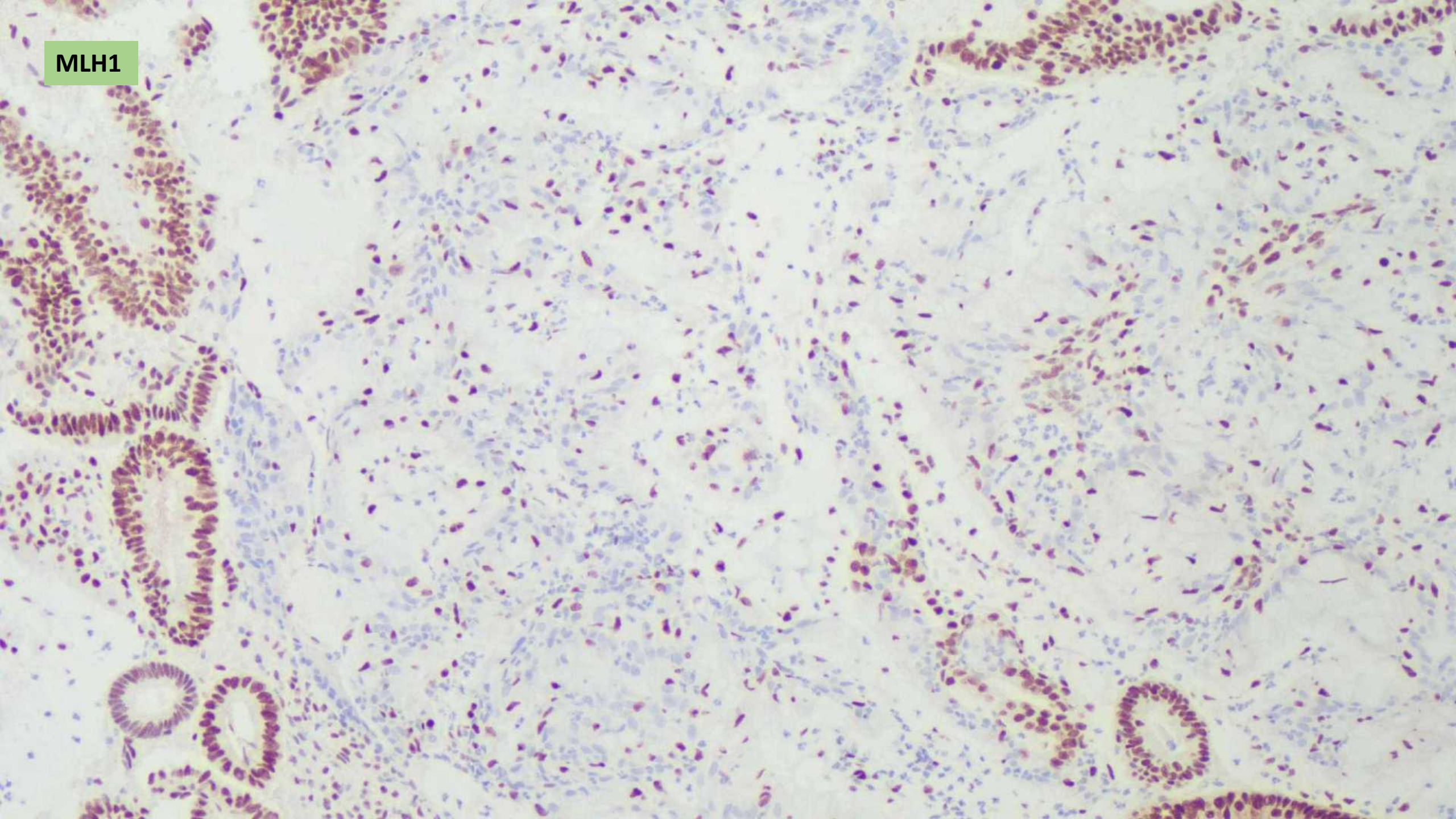
MLH1

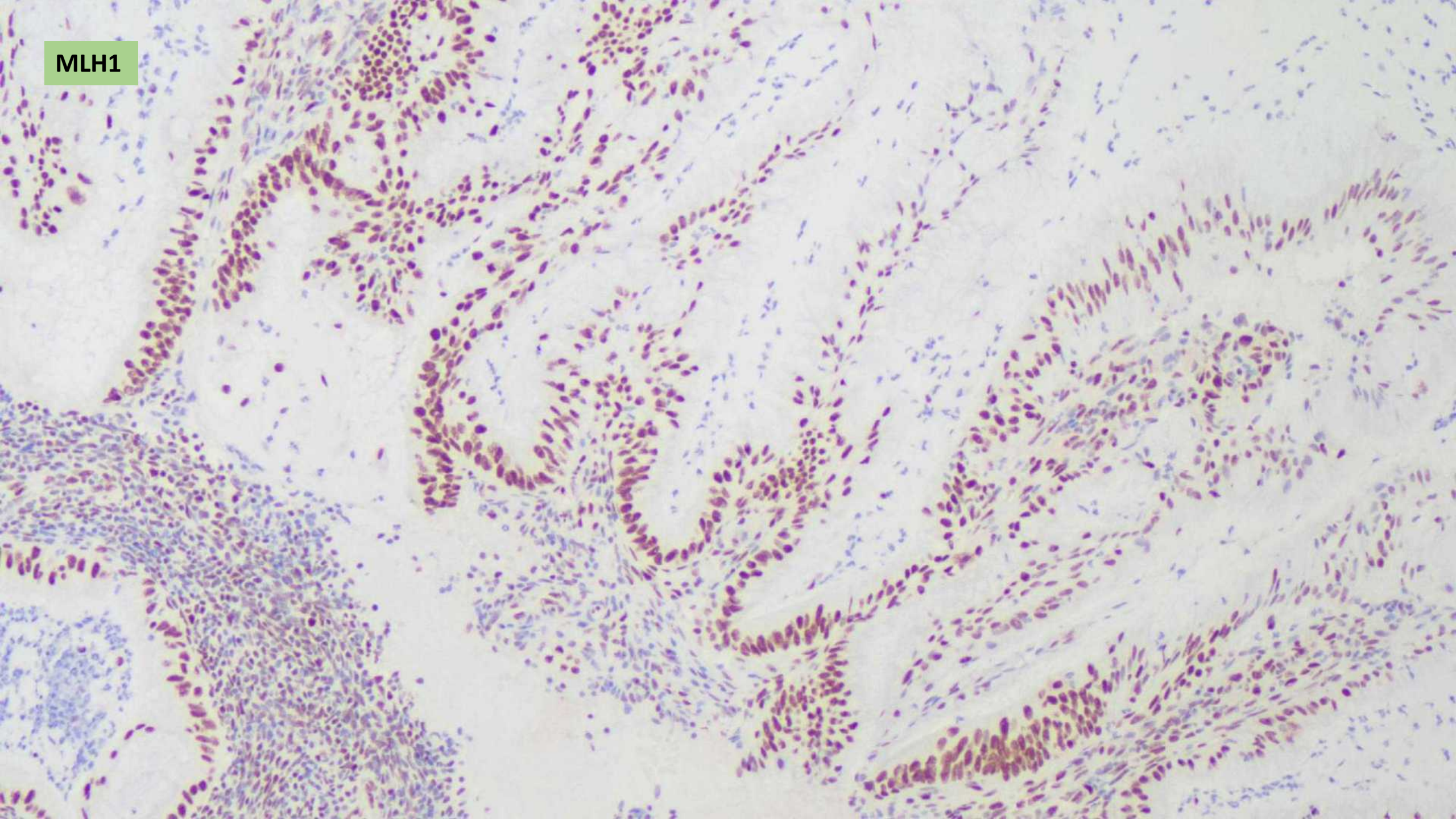
MLH1

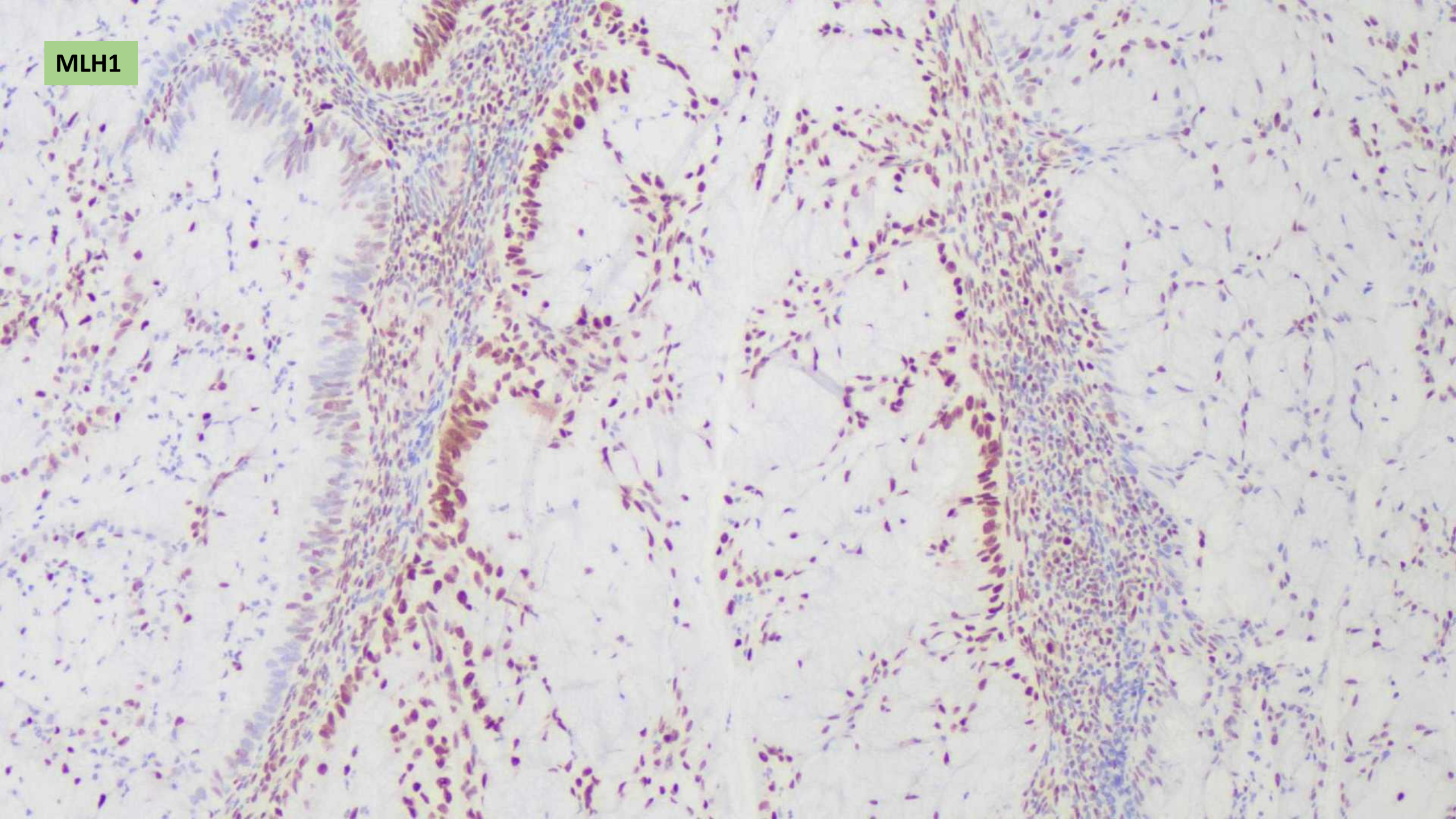
MLH1

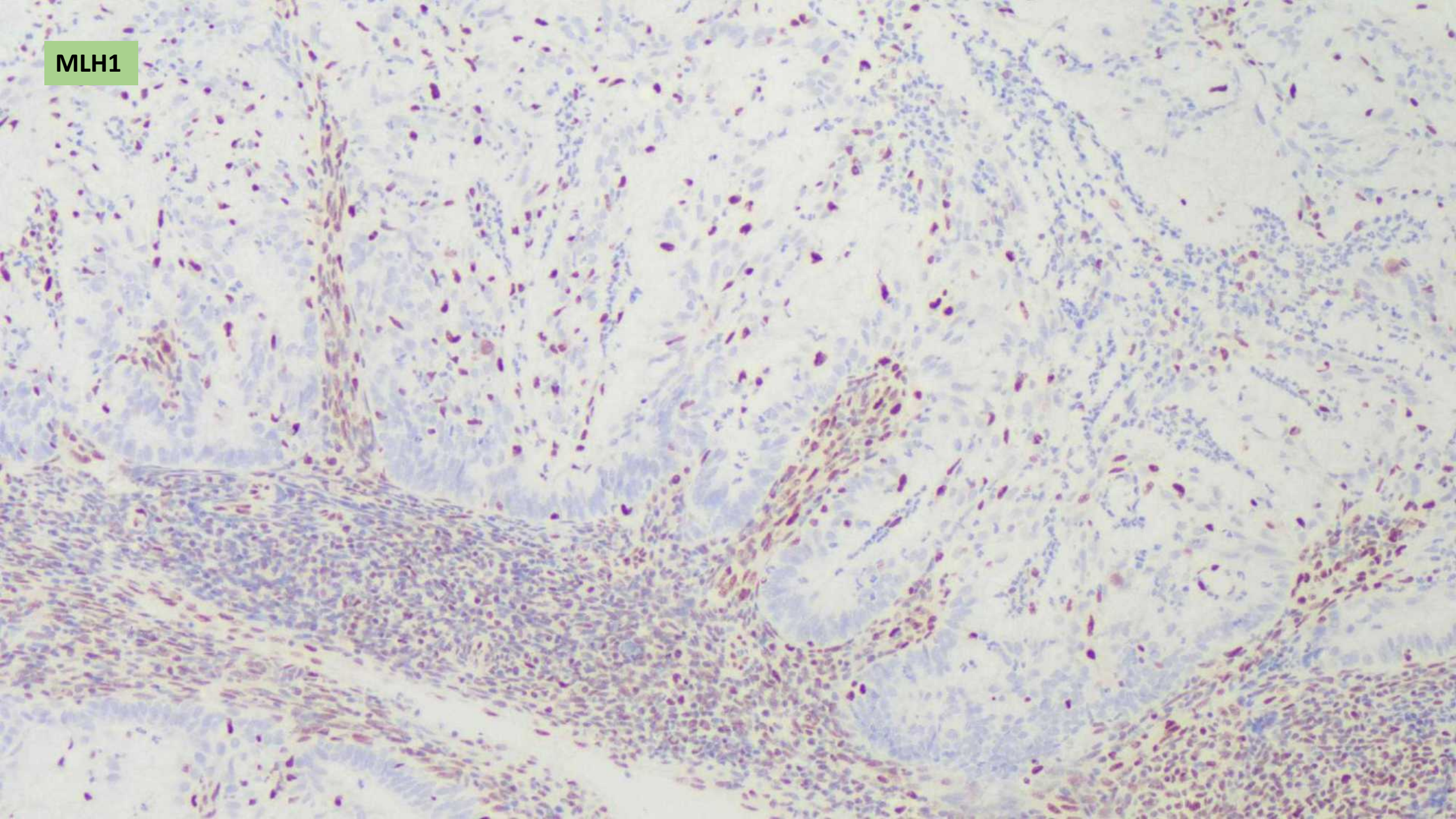
MLH1

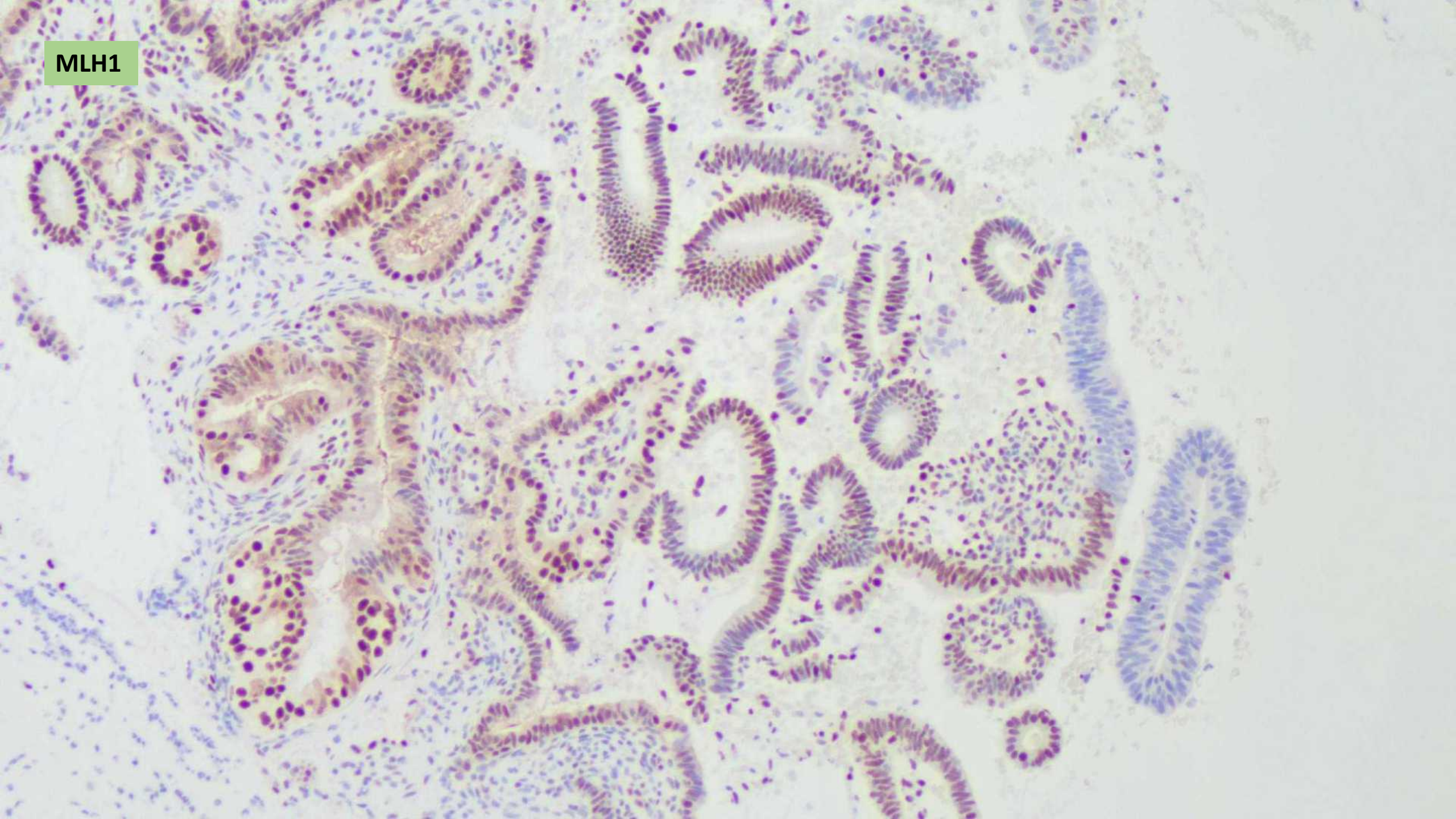
MLH1

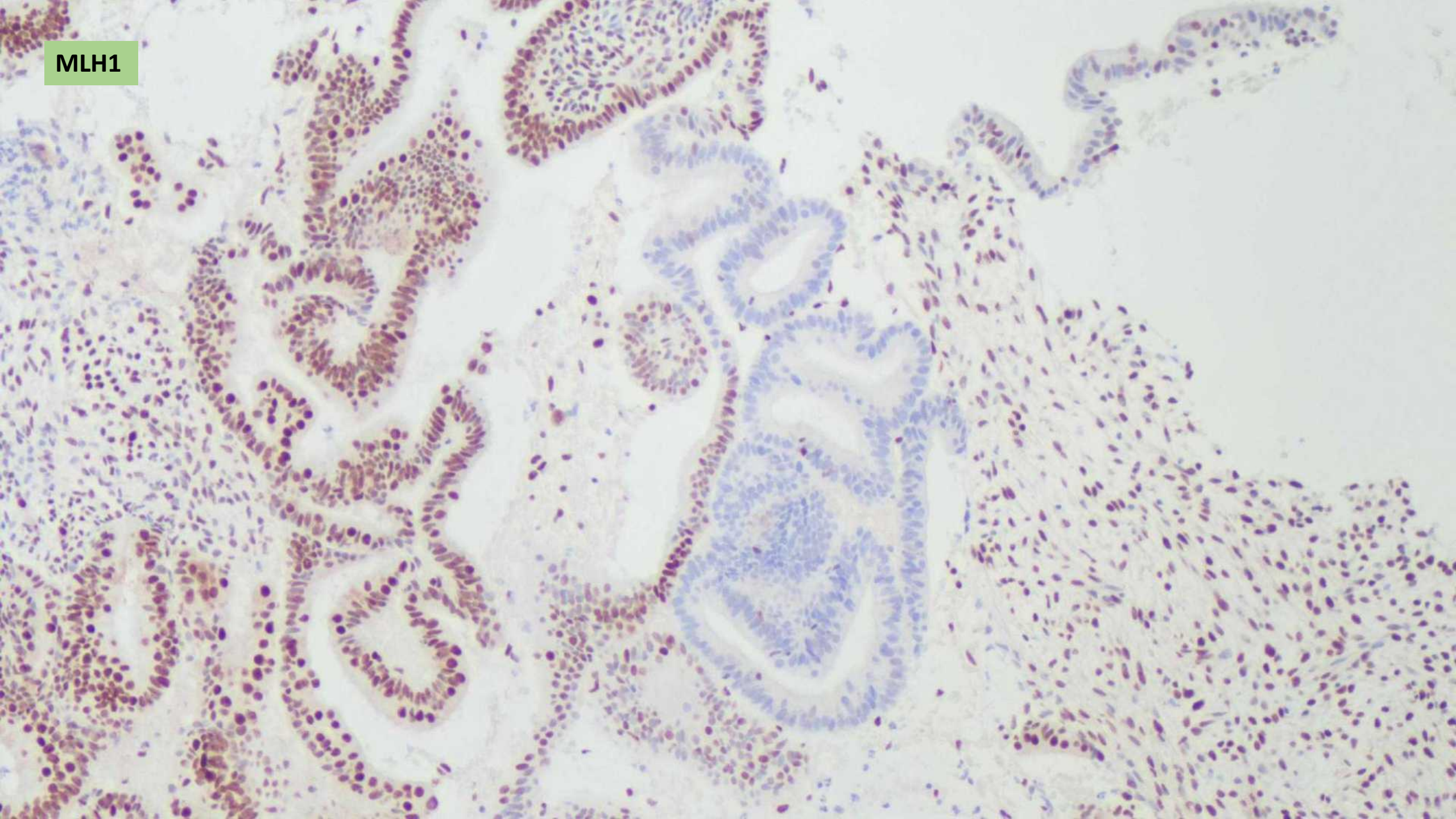
MLH1

Case 1

- PMS2

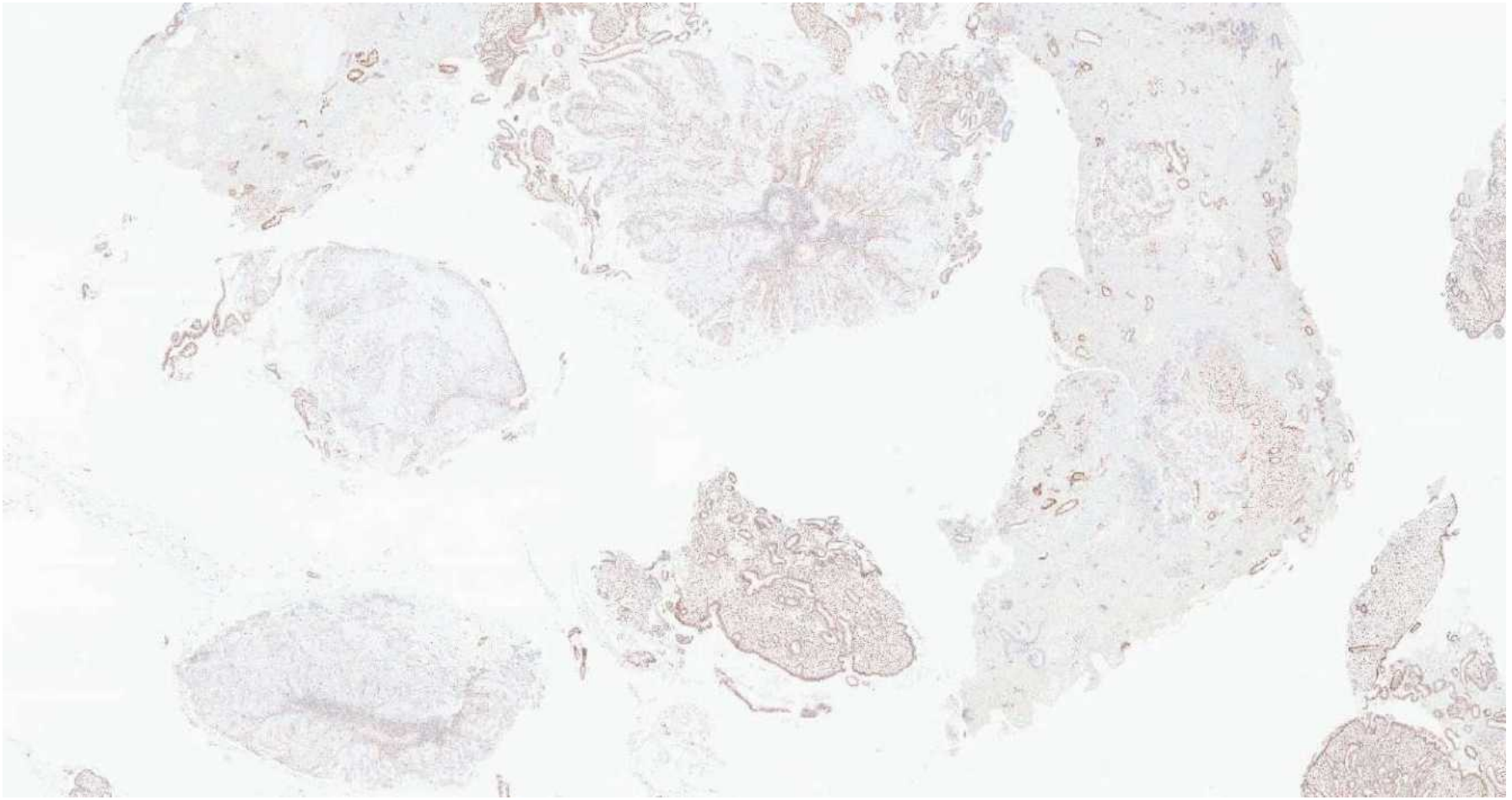

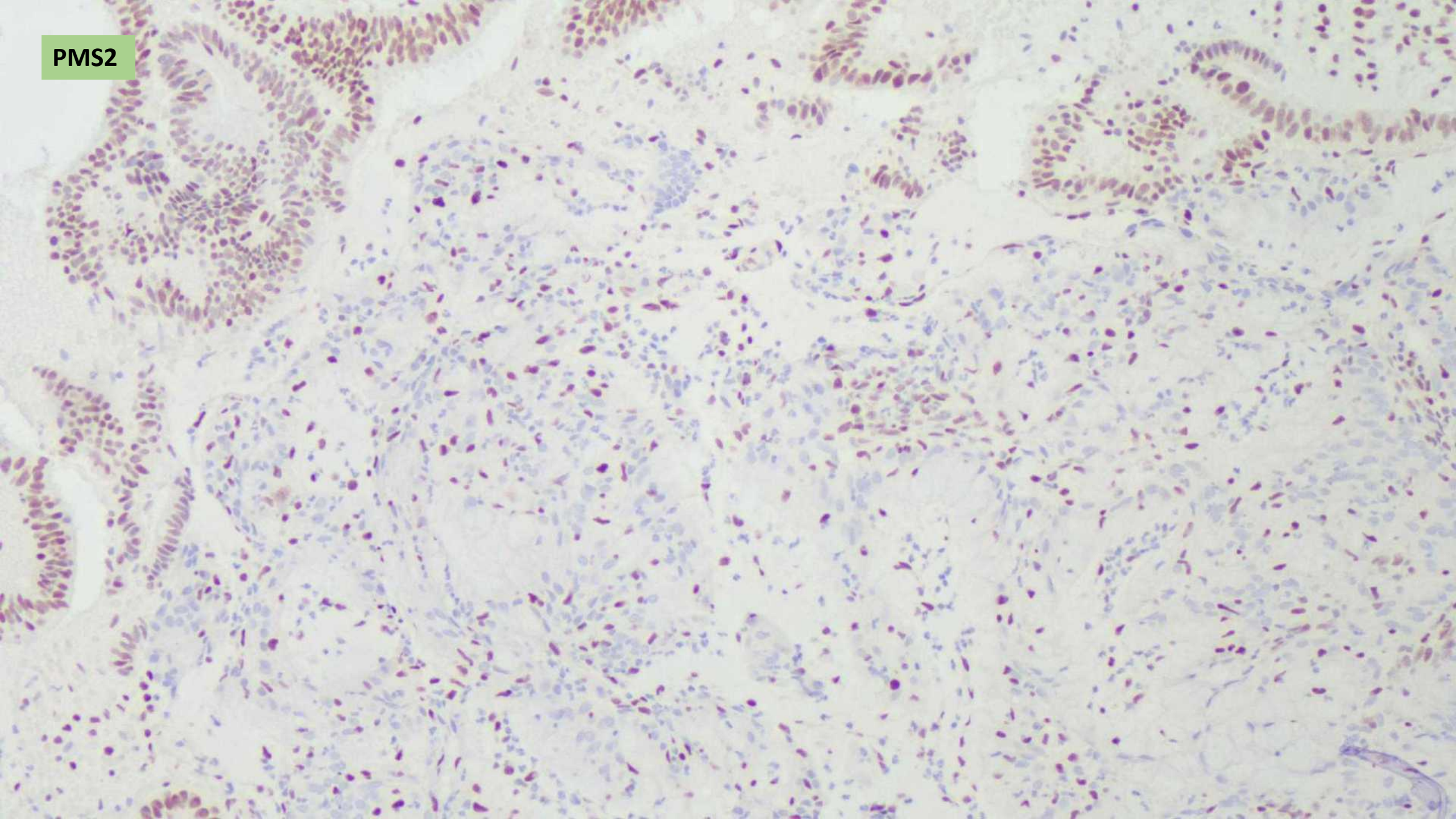
PMS2

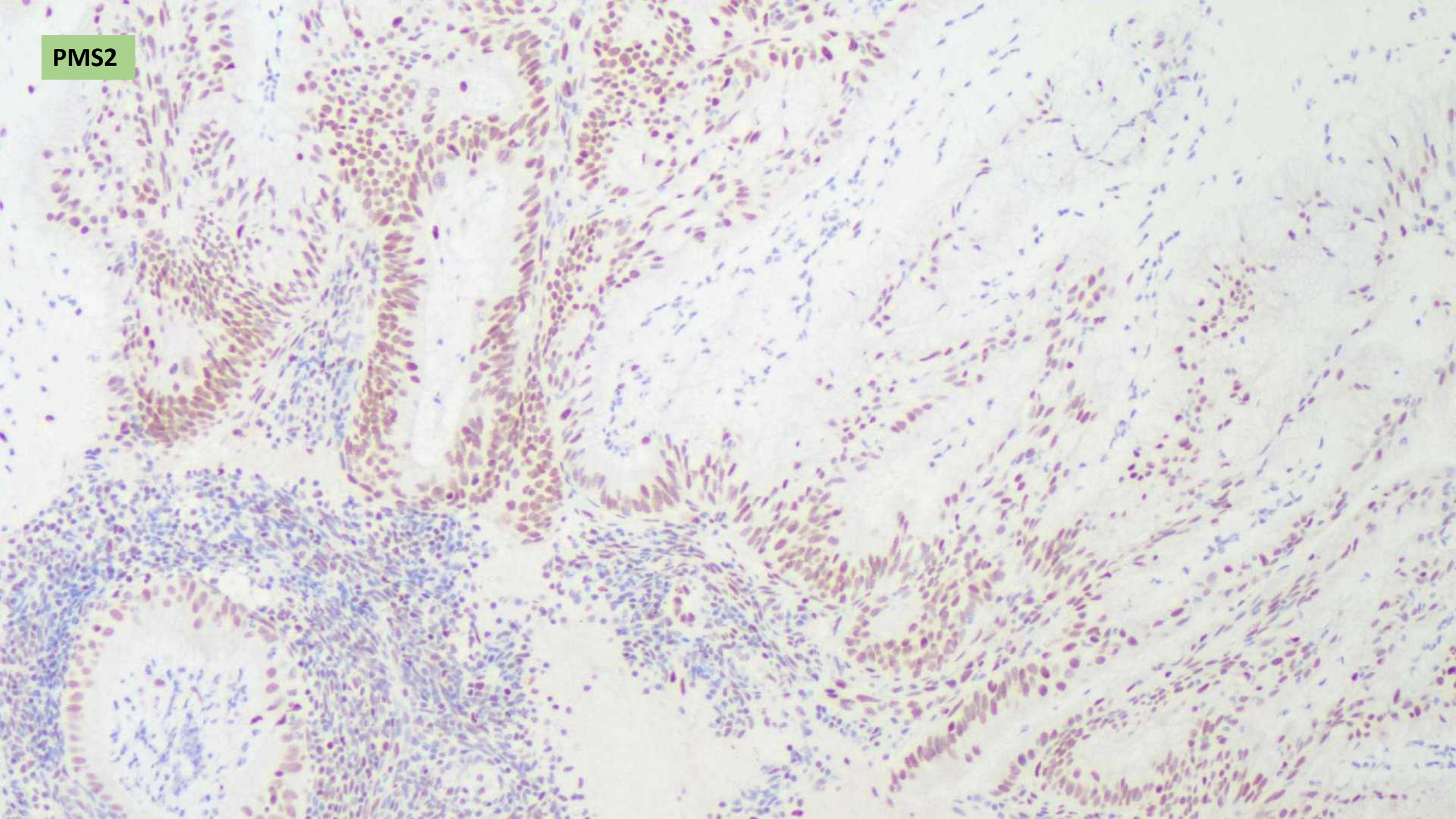
PMS2

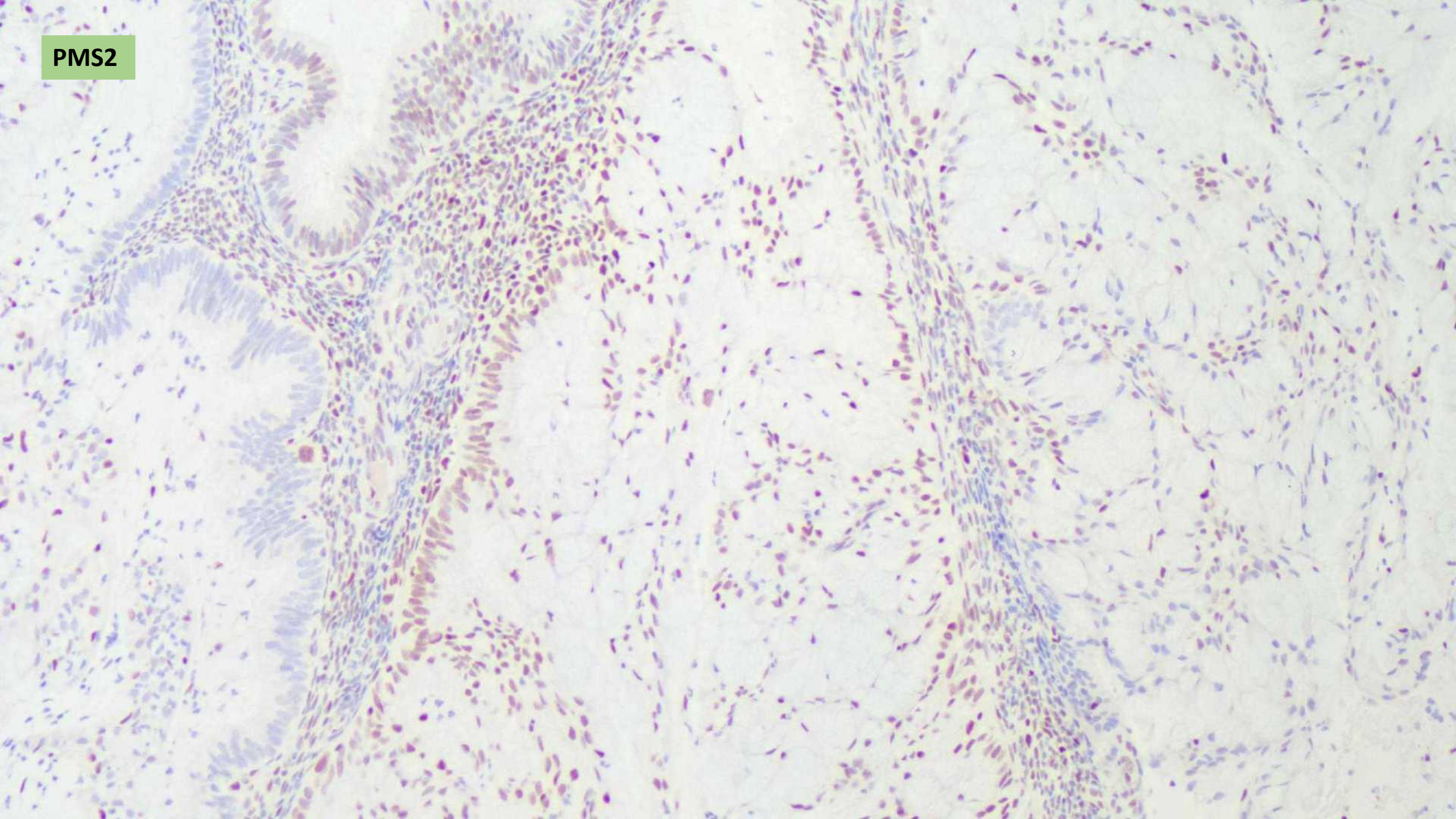
PMS2

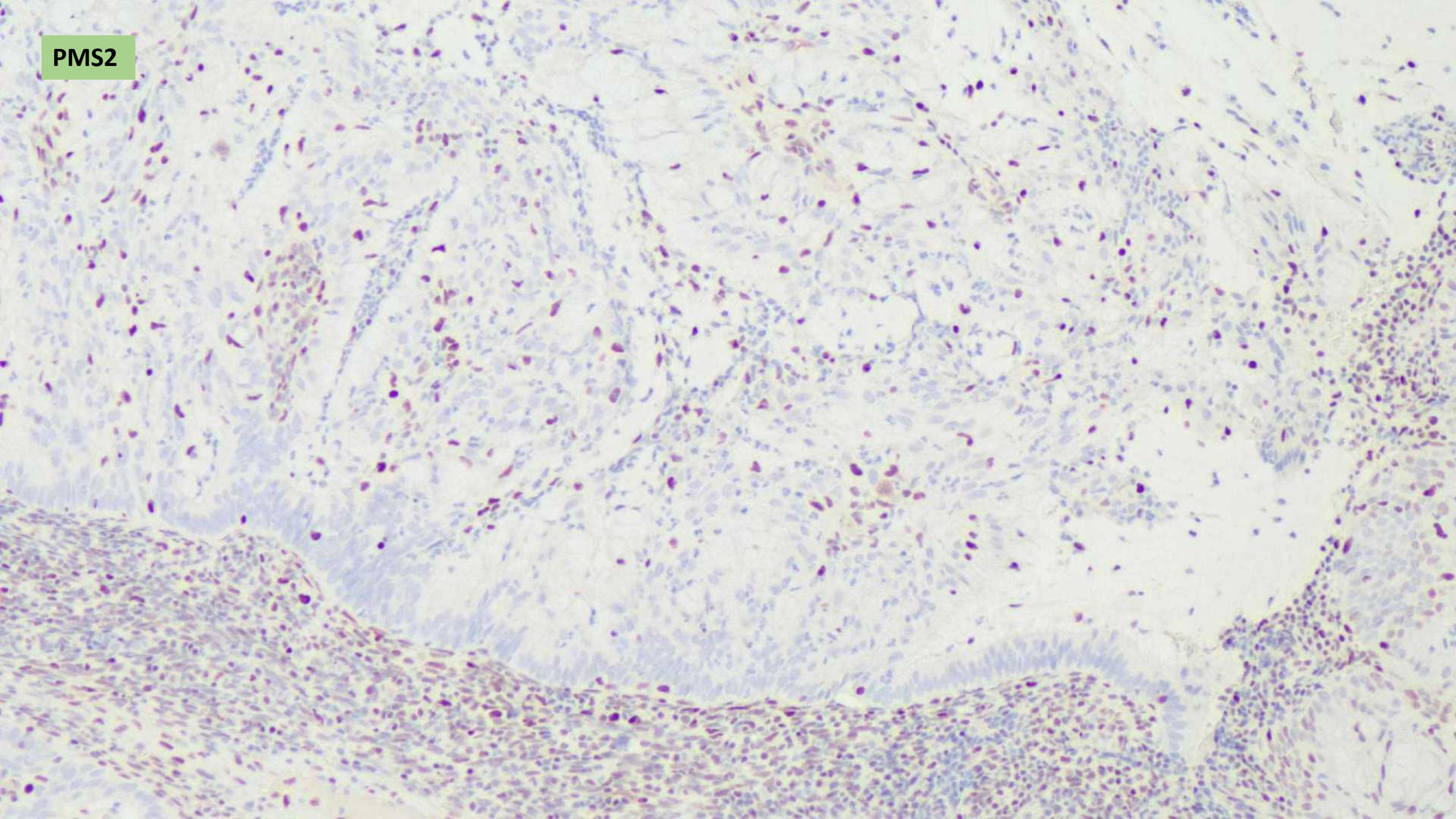
PMS2

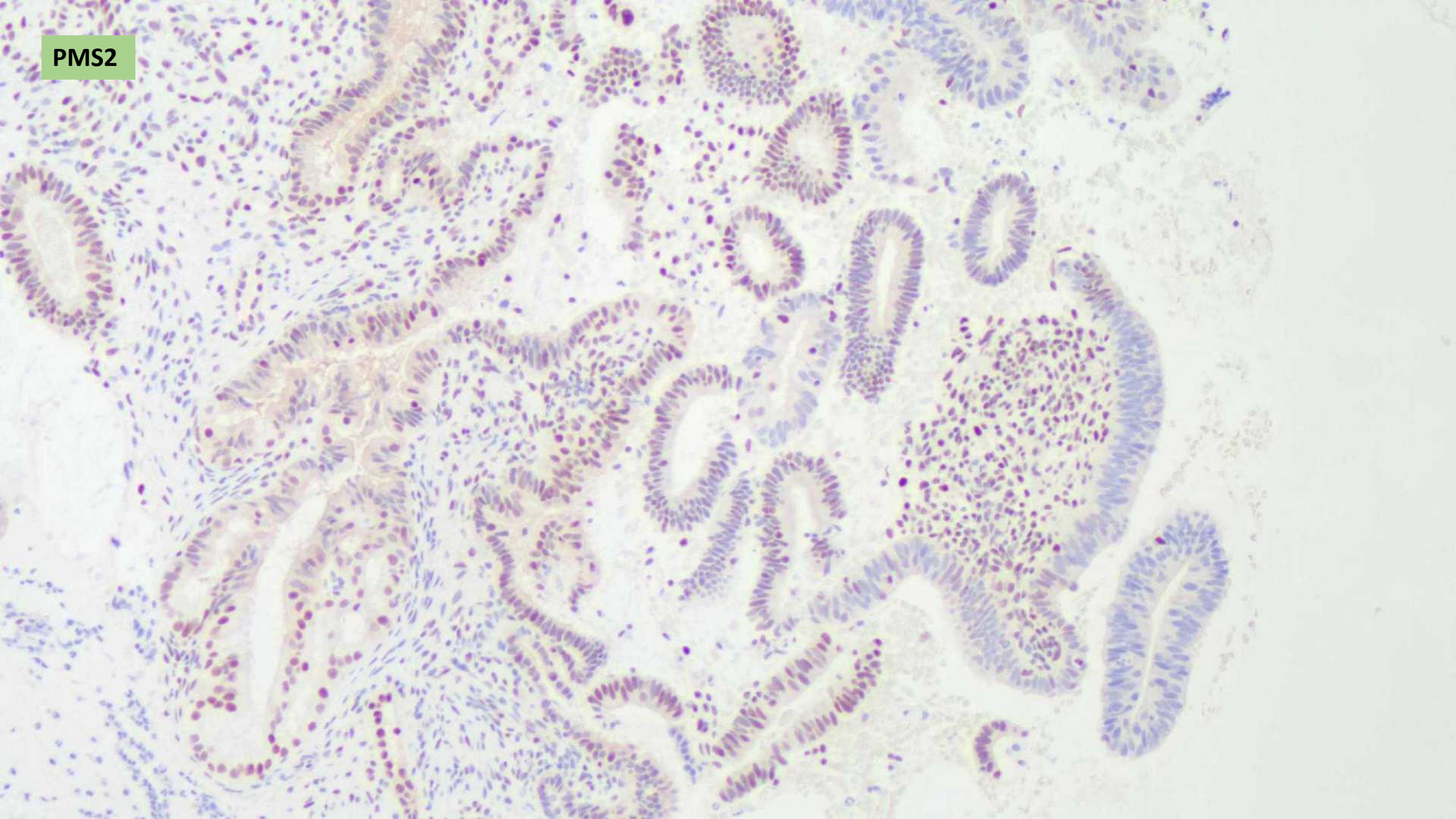
PMS2

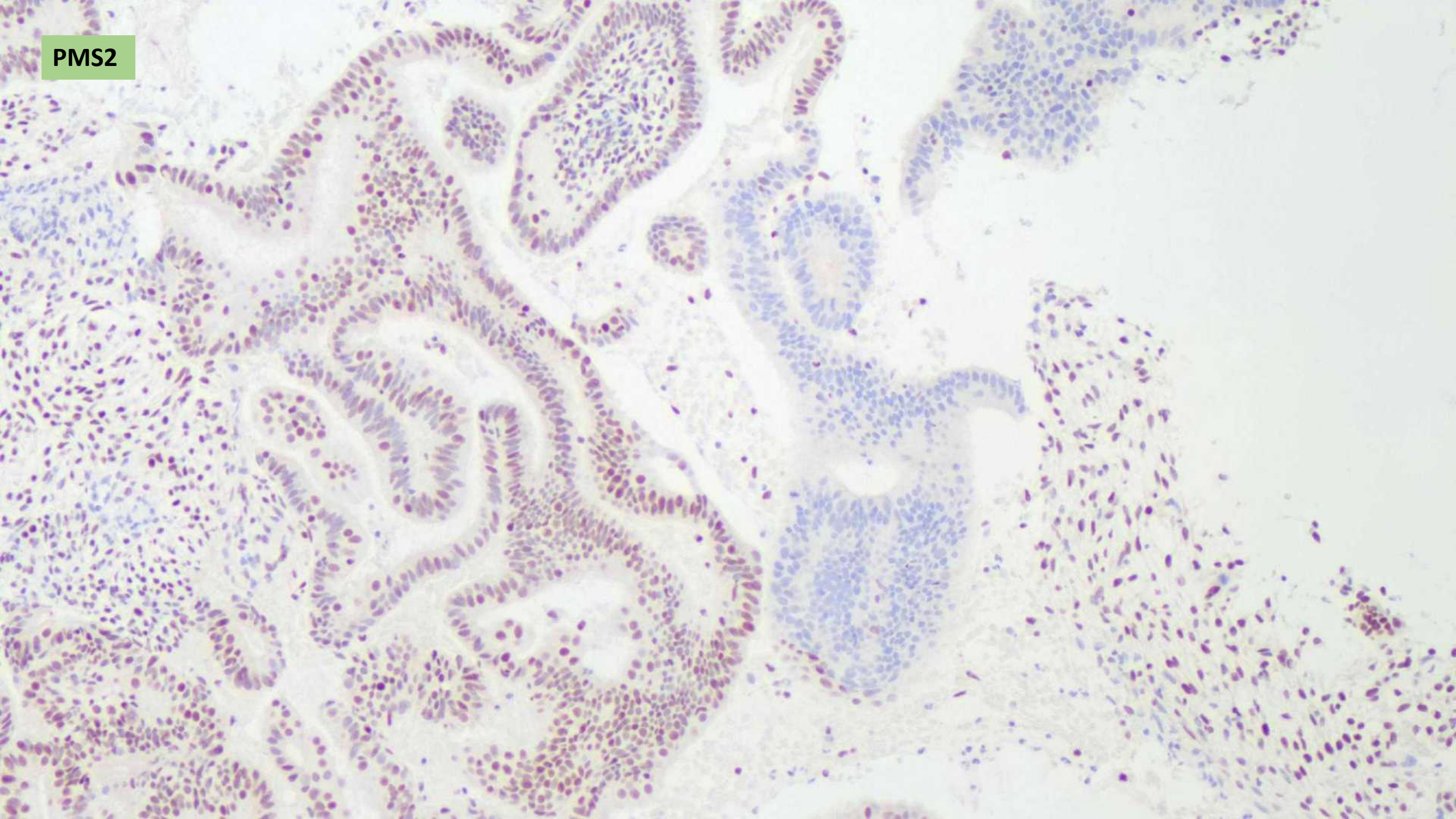
PMS2

Case 1

- MSH2

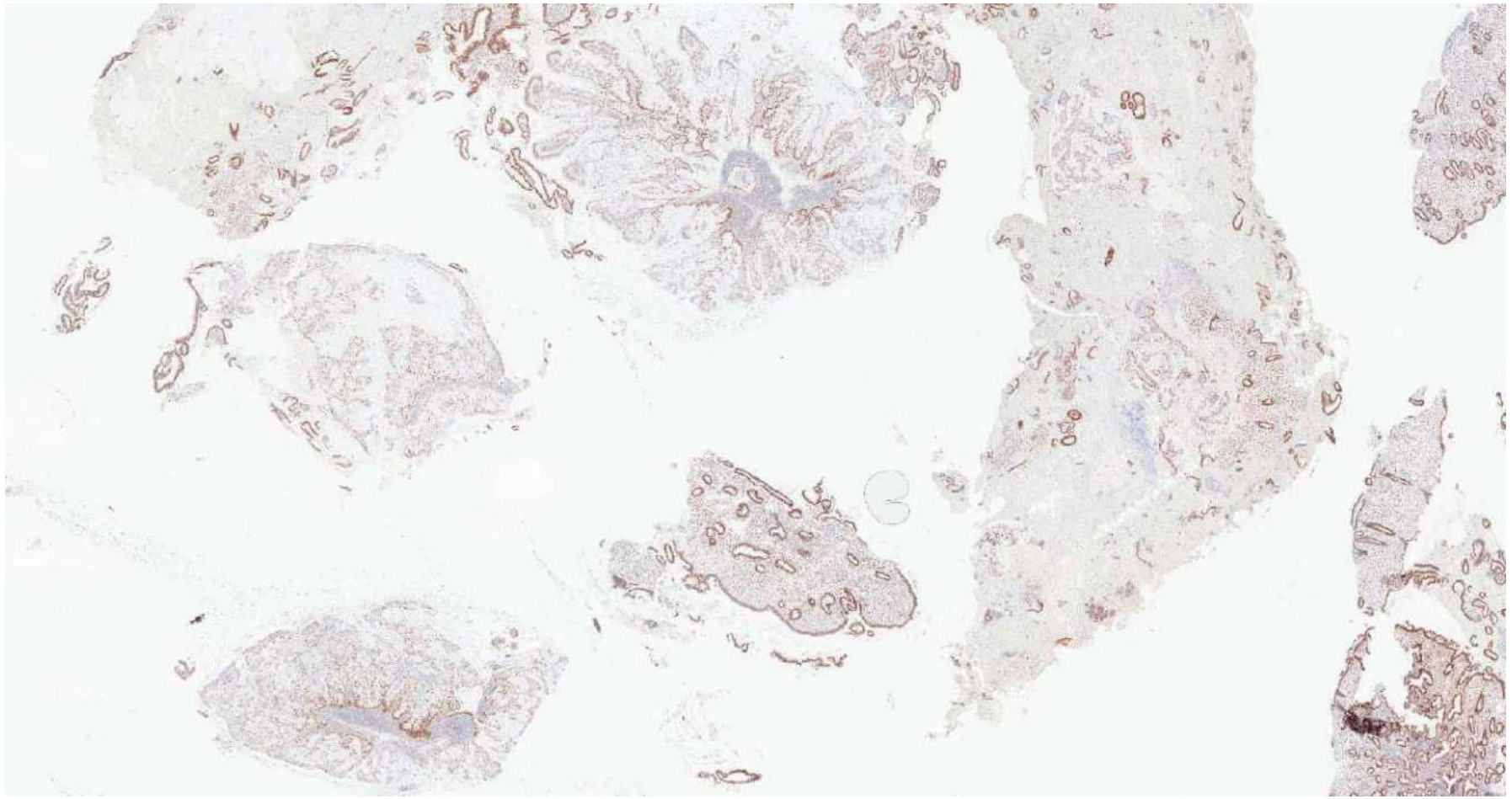

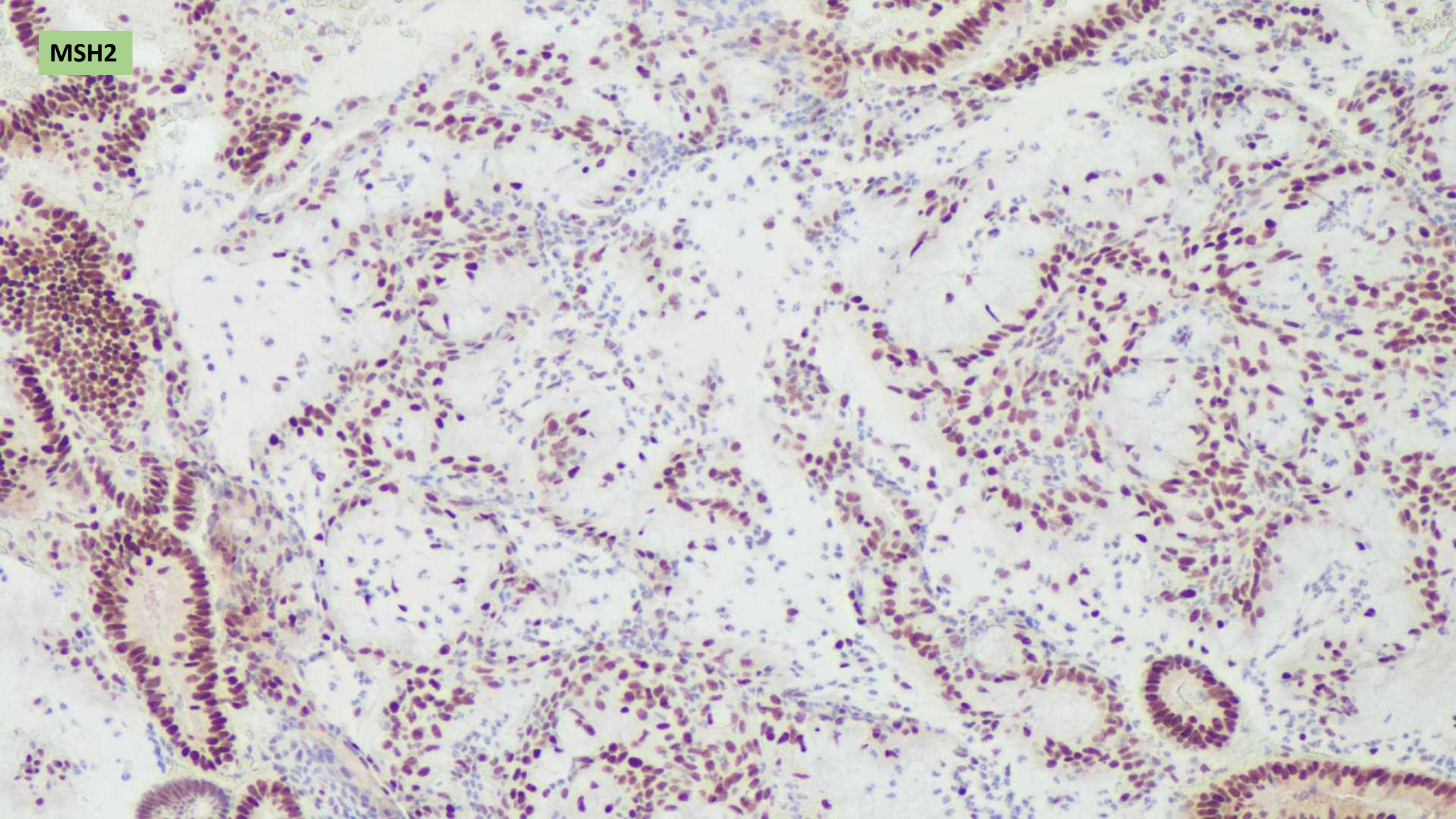
MSH2

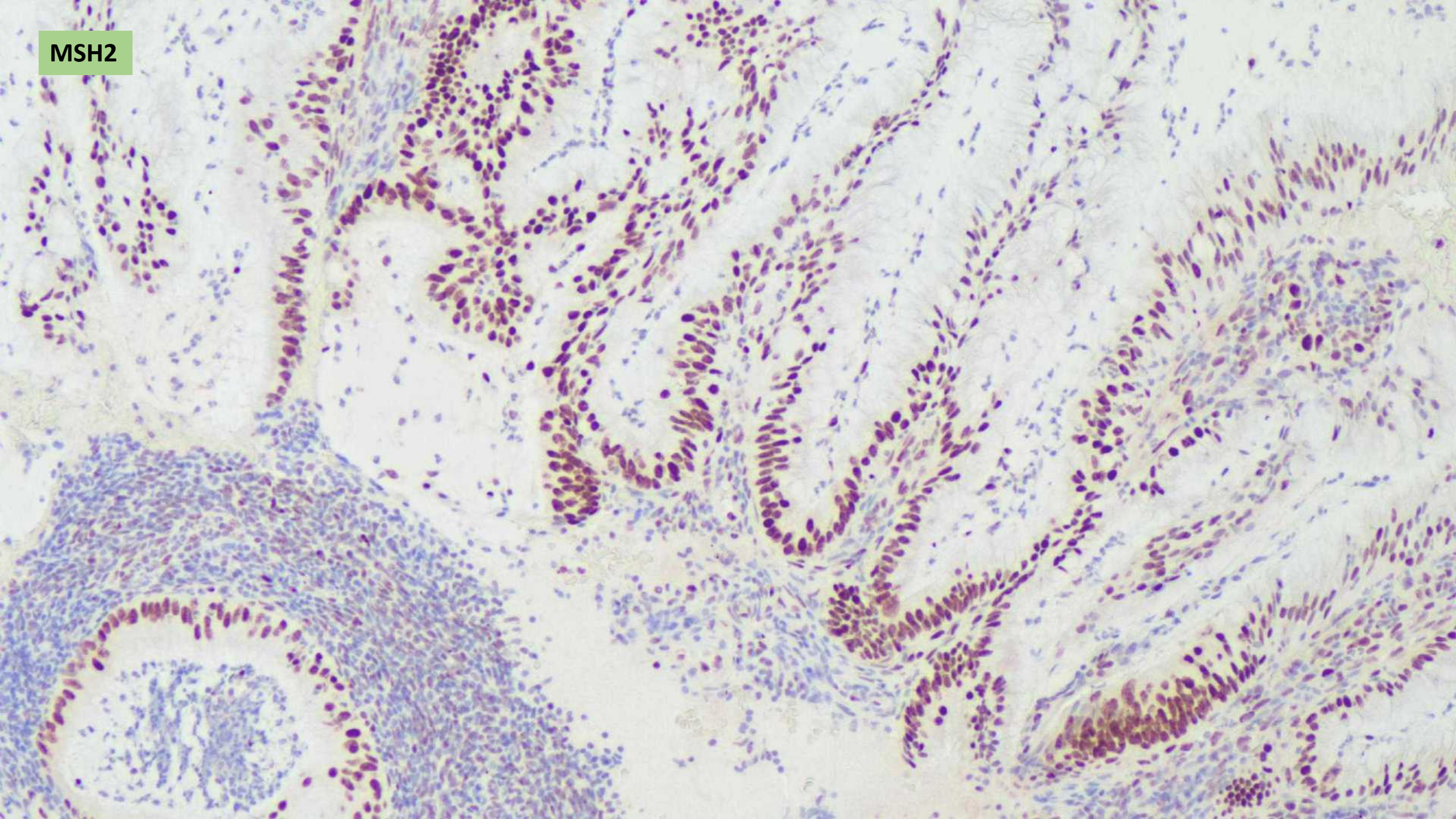
MSH2

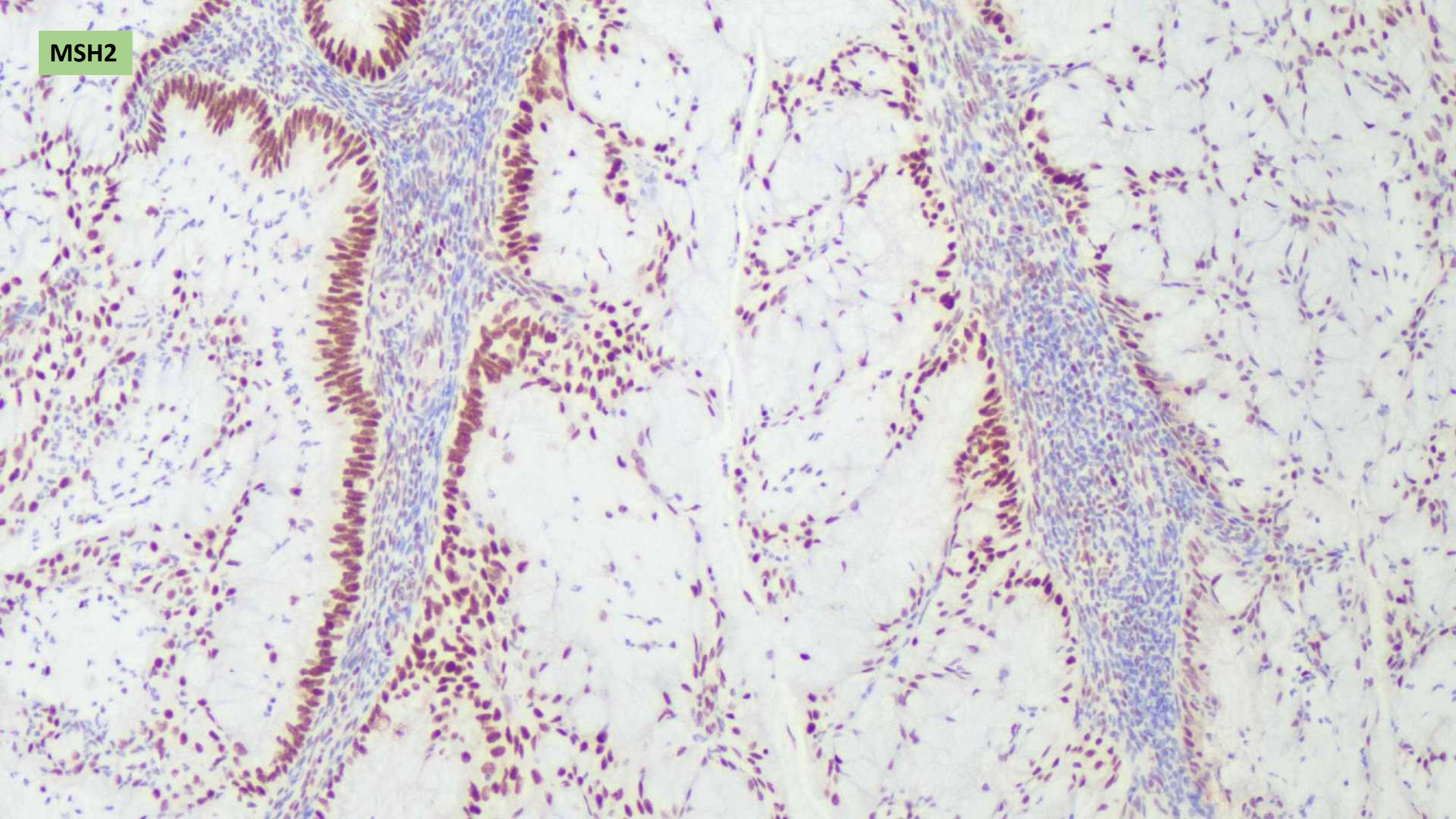
MSH2

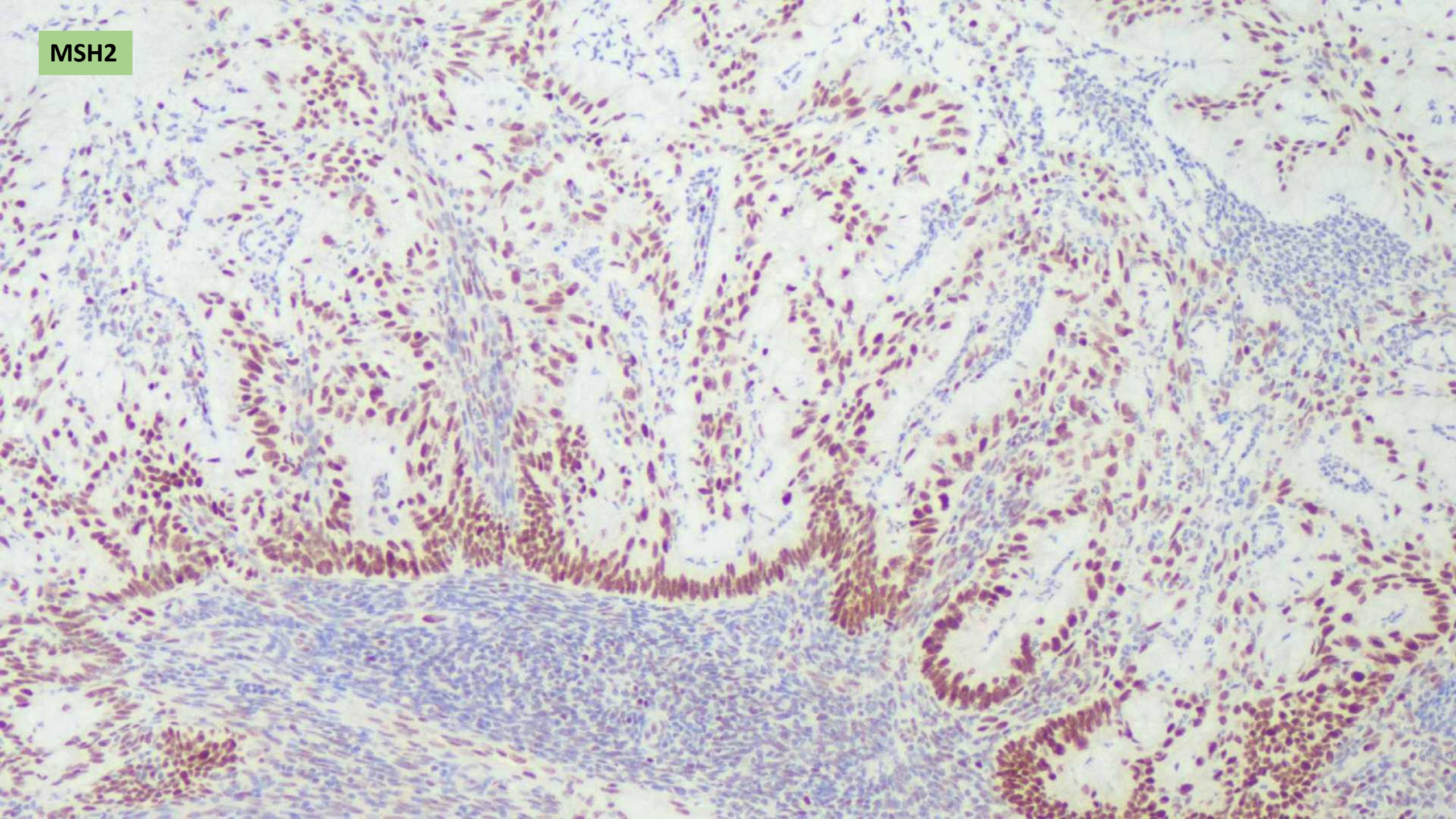
MSH2

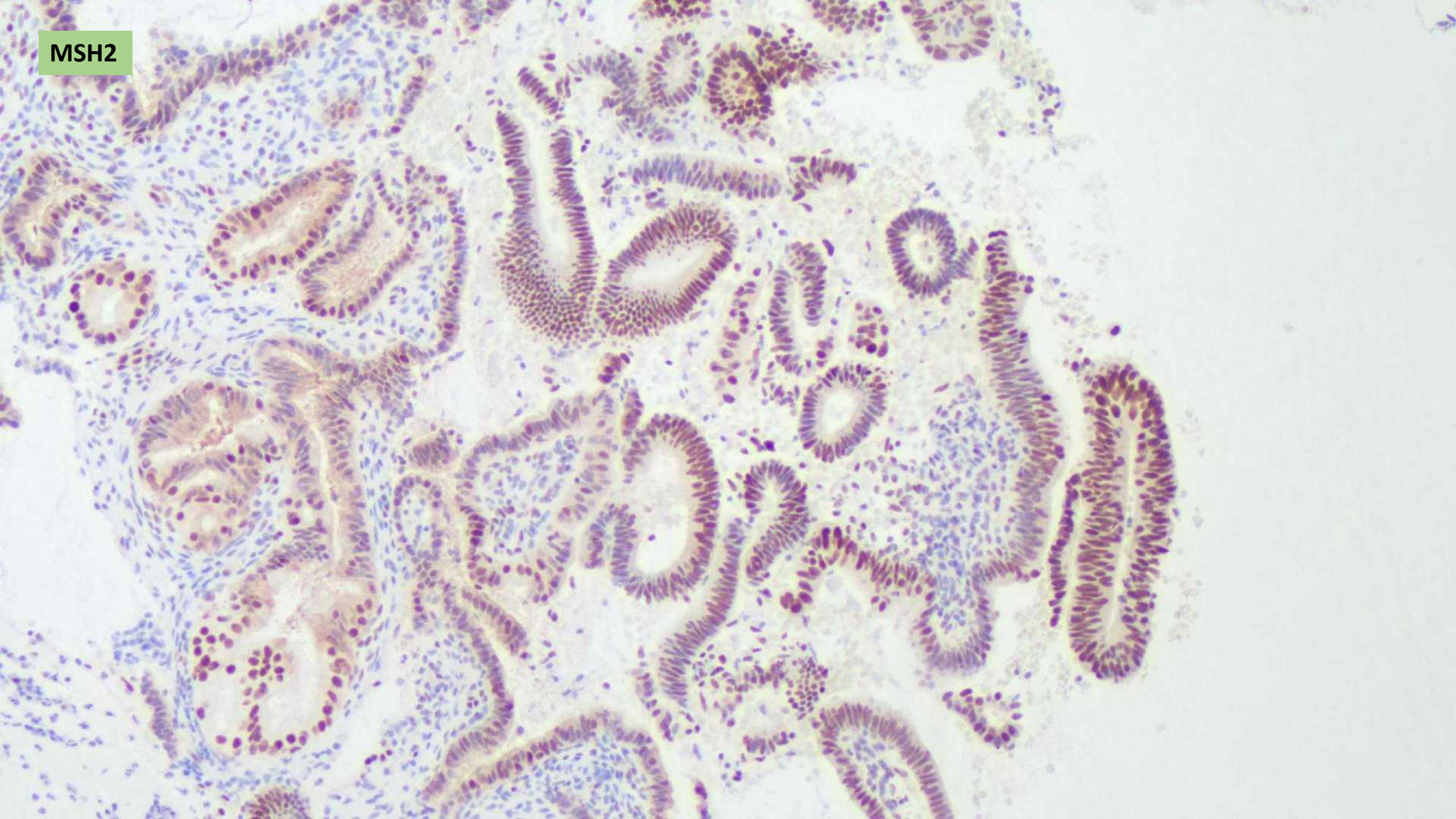
MSH2

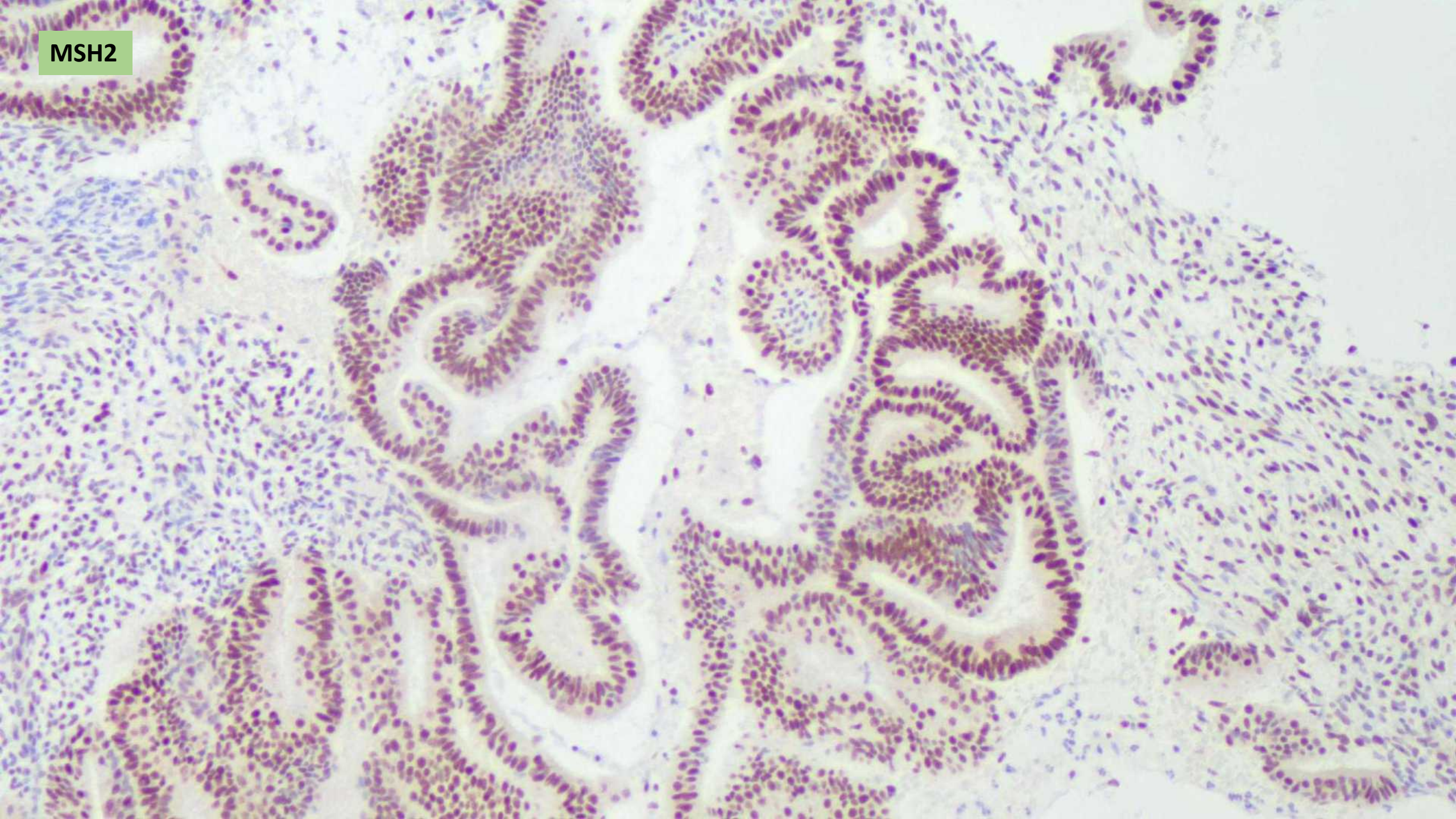
MSH2

Case 1

- MSH6

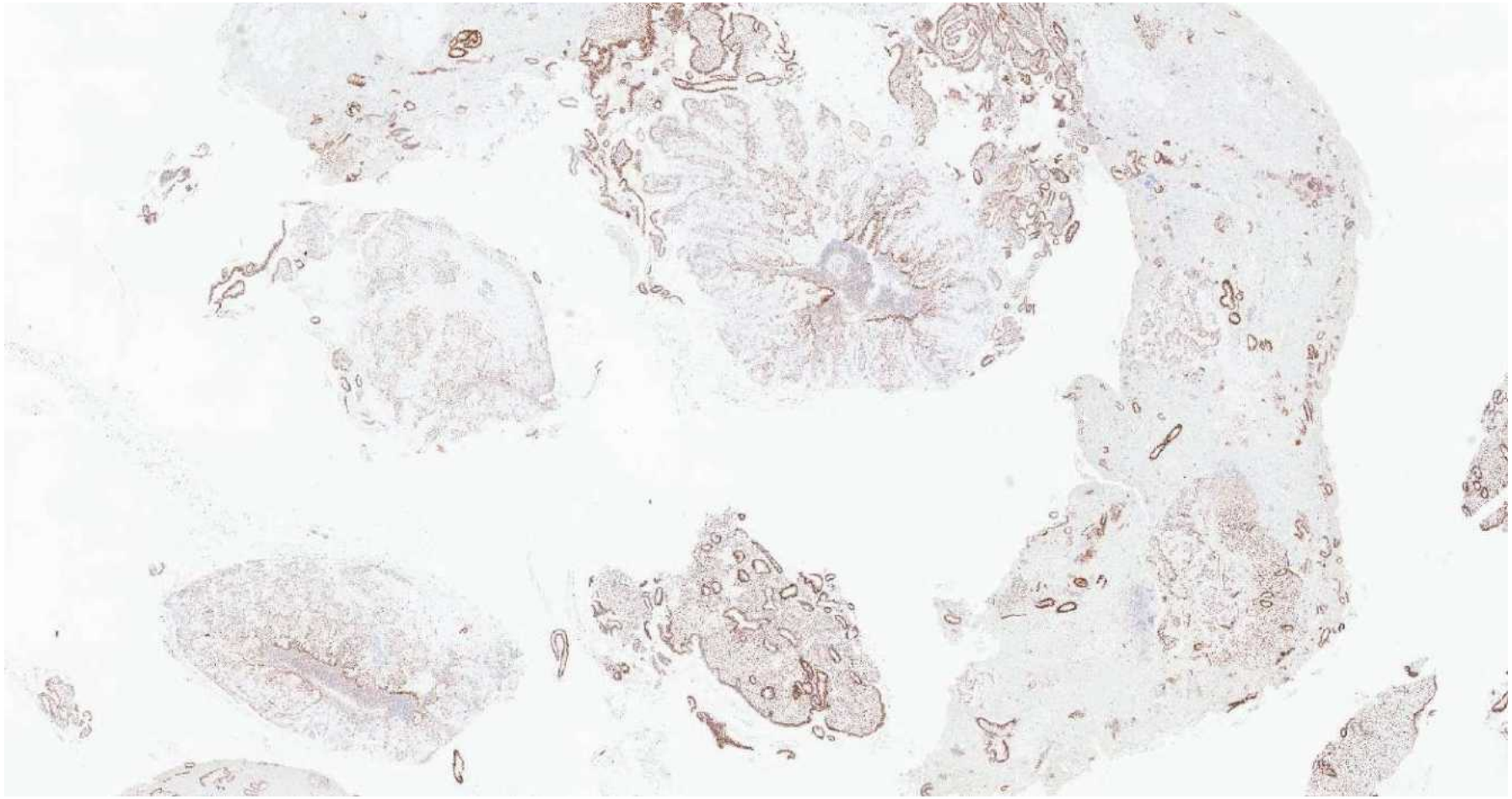

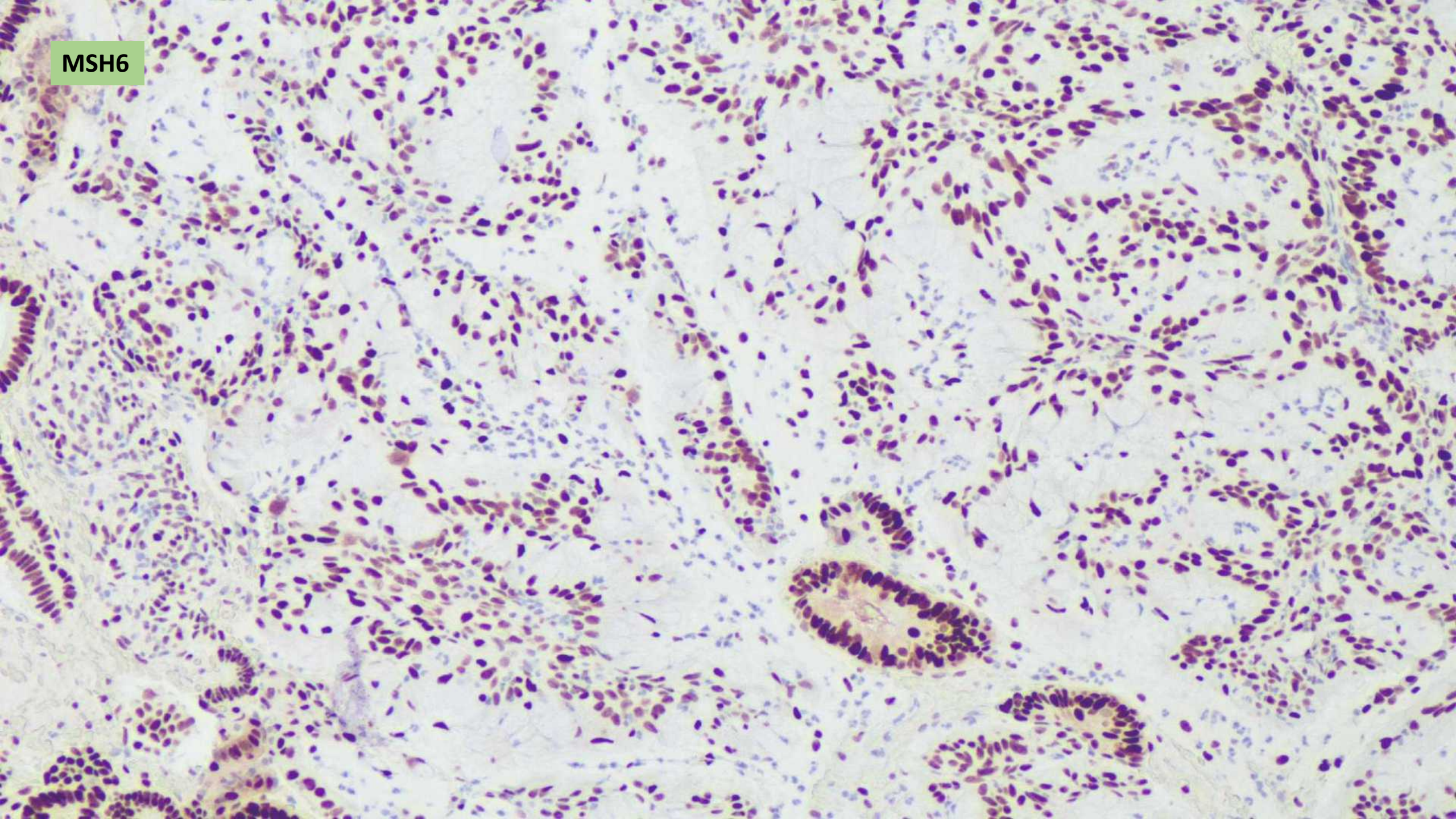
MSH6

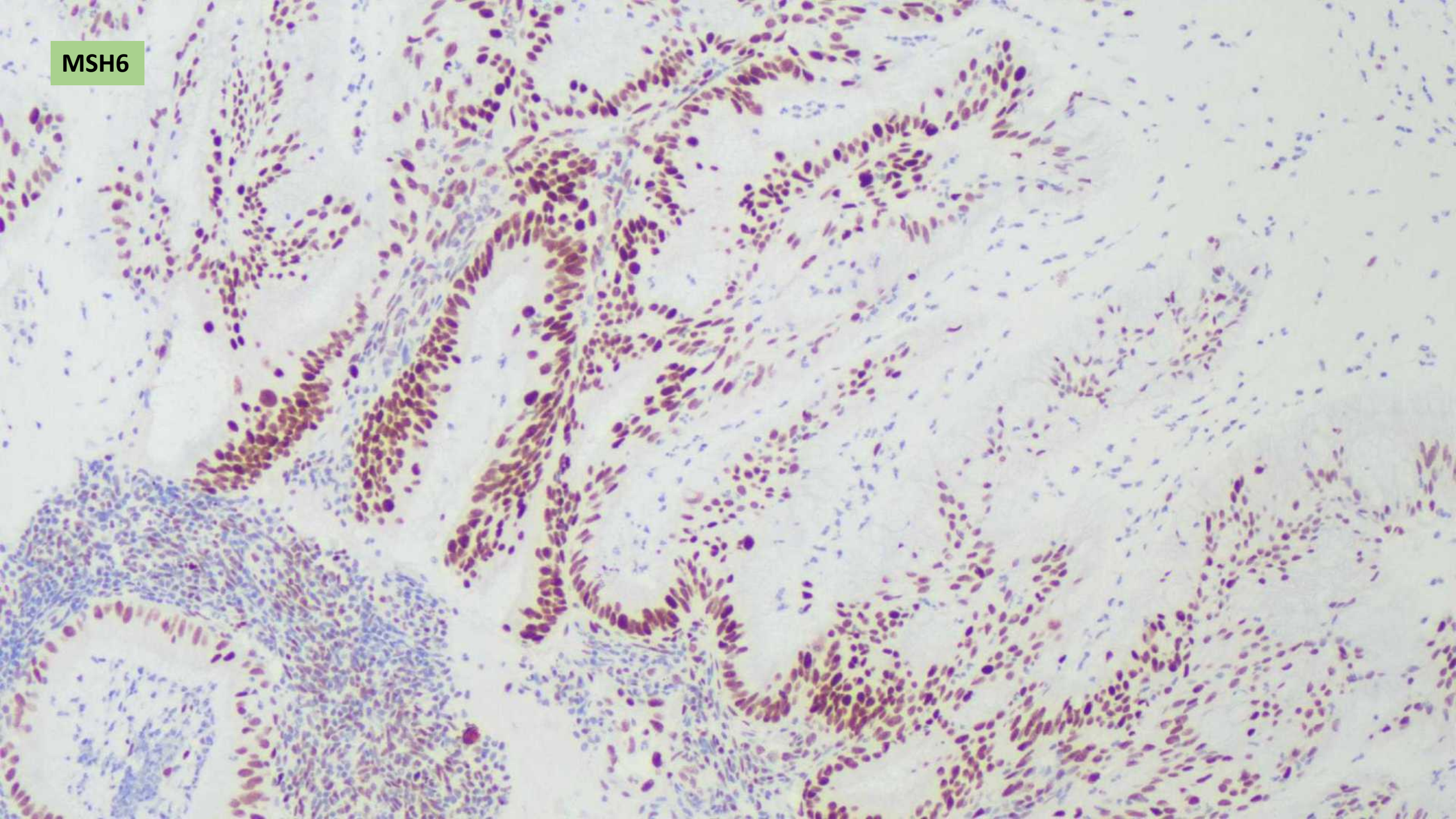
MSH6

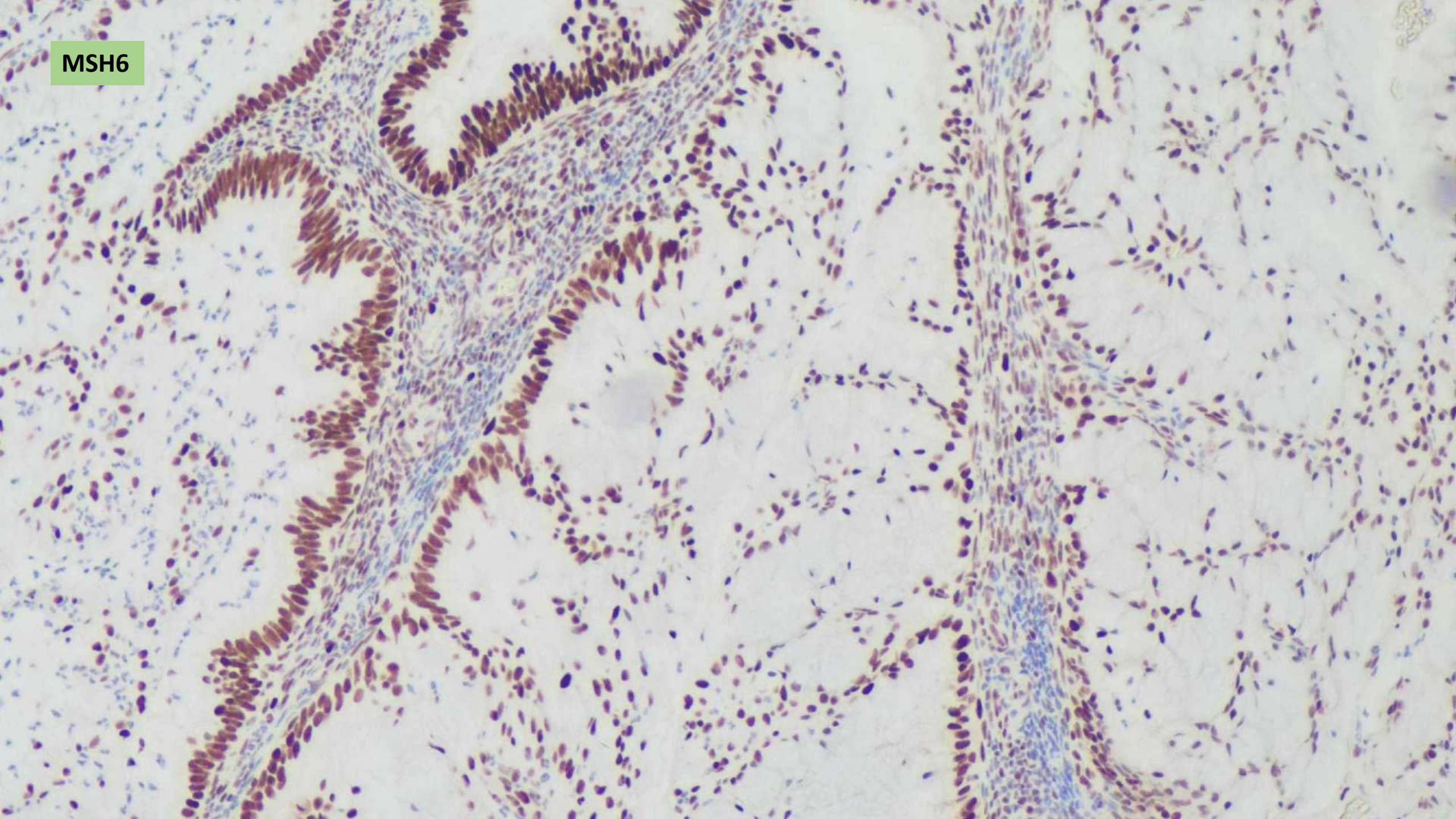
MSH6

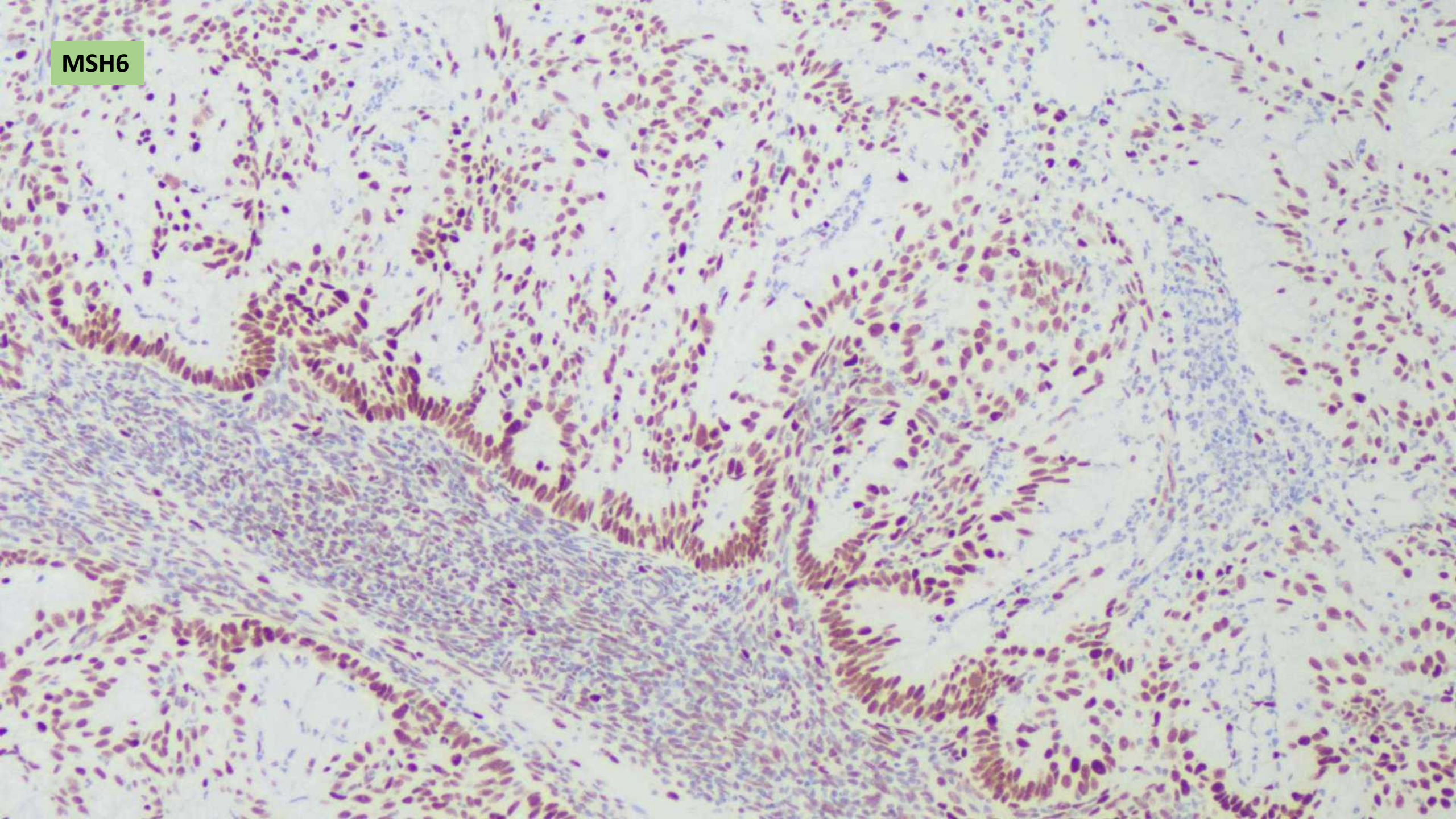
MSH6

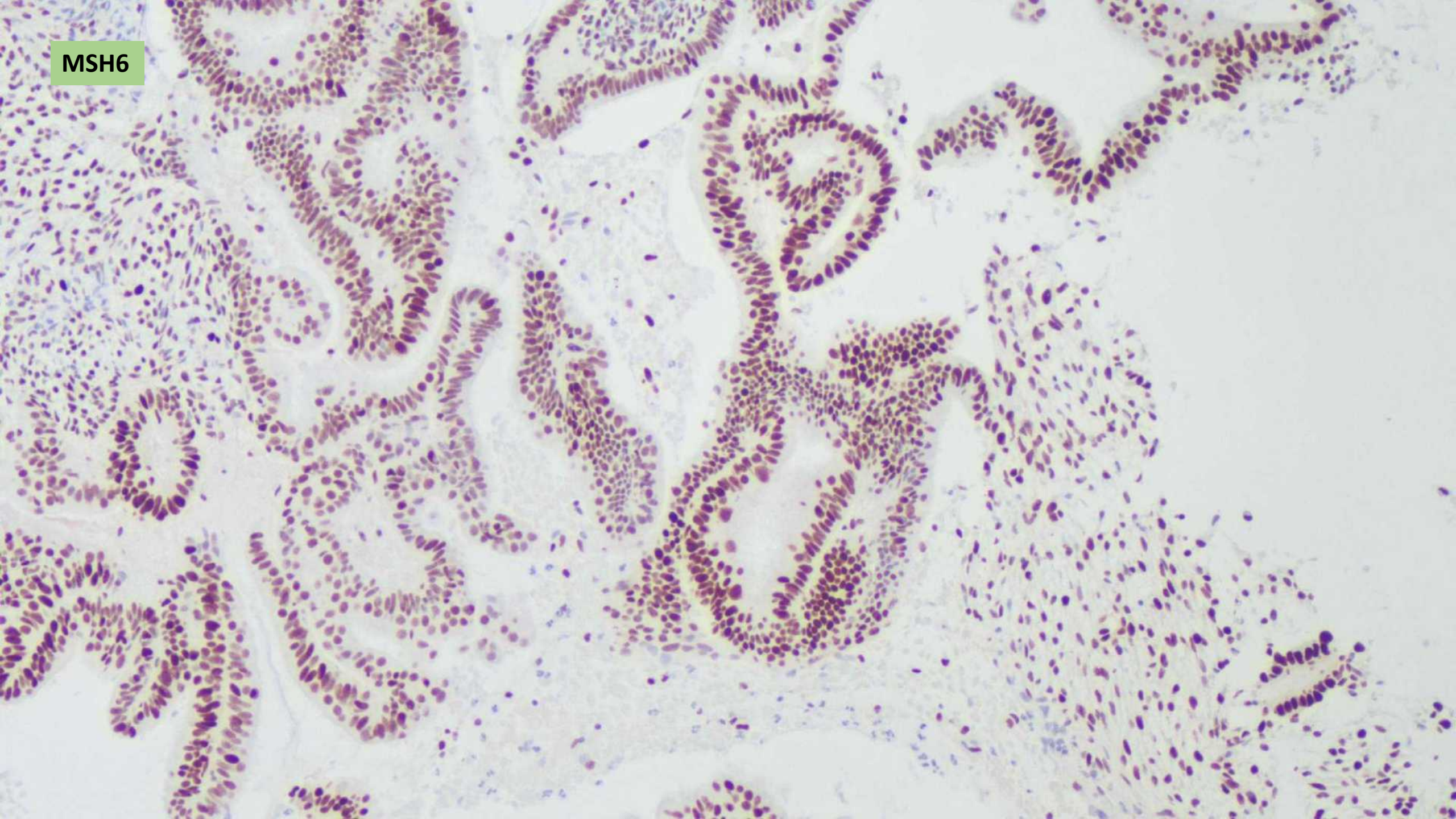
MSH6

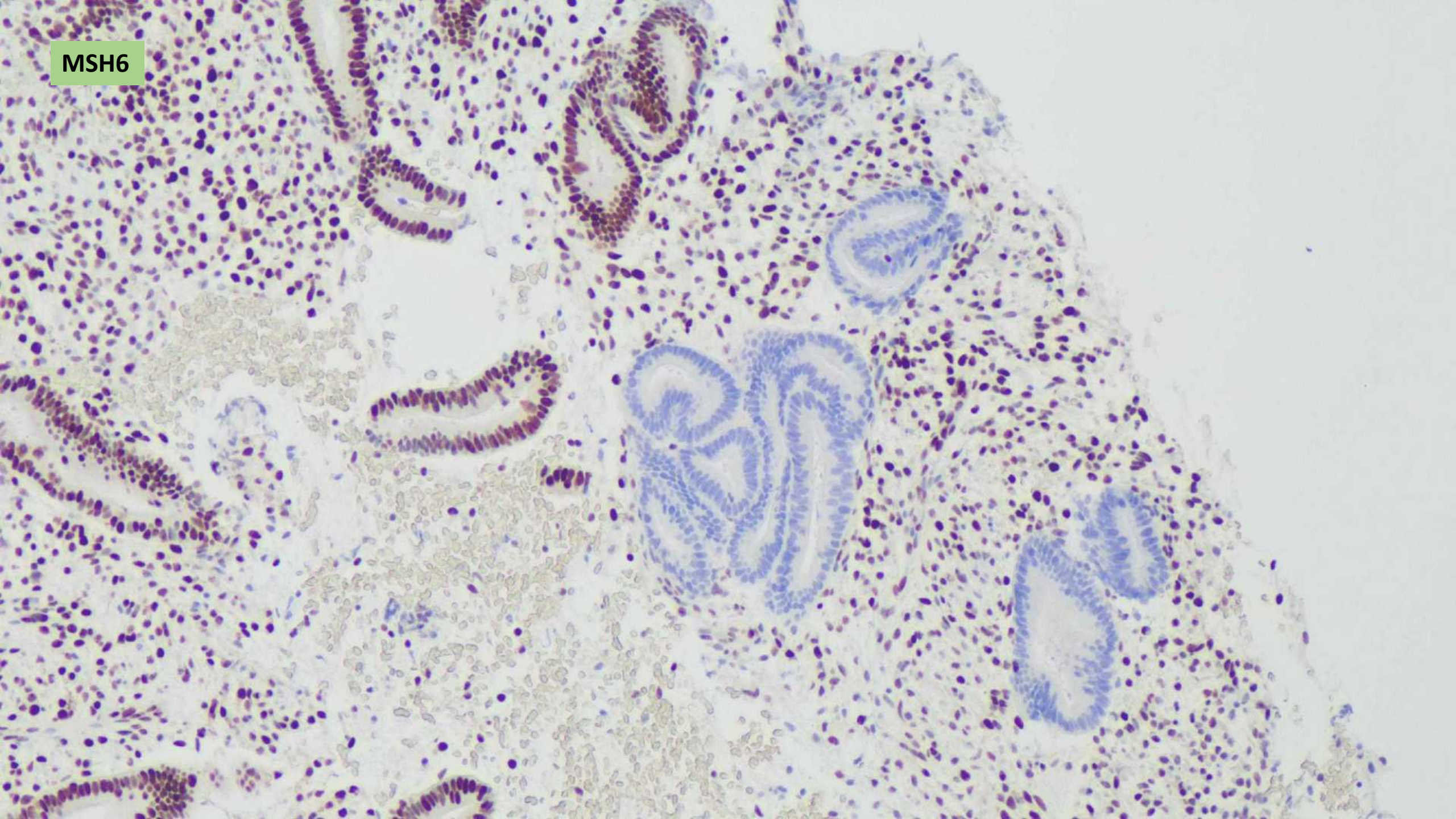
MSH6

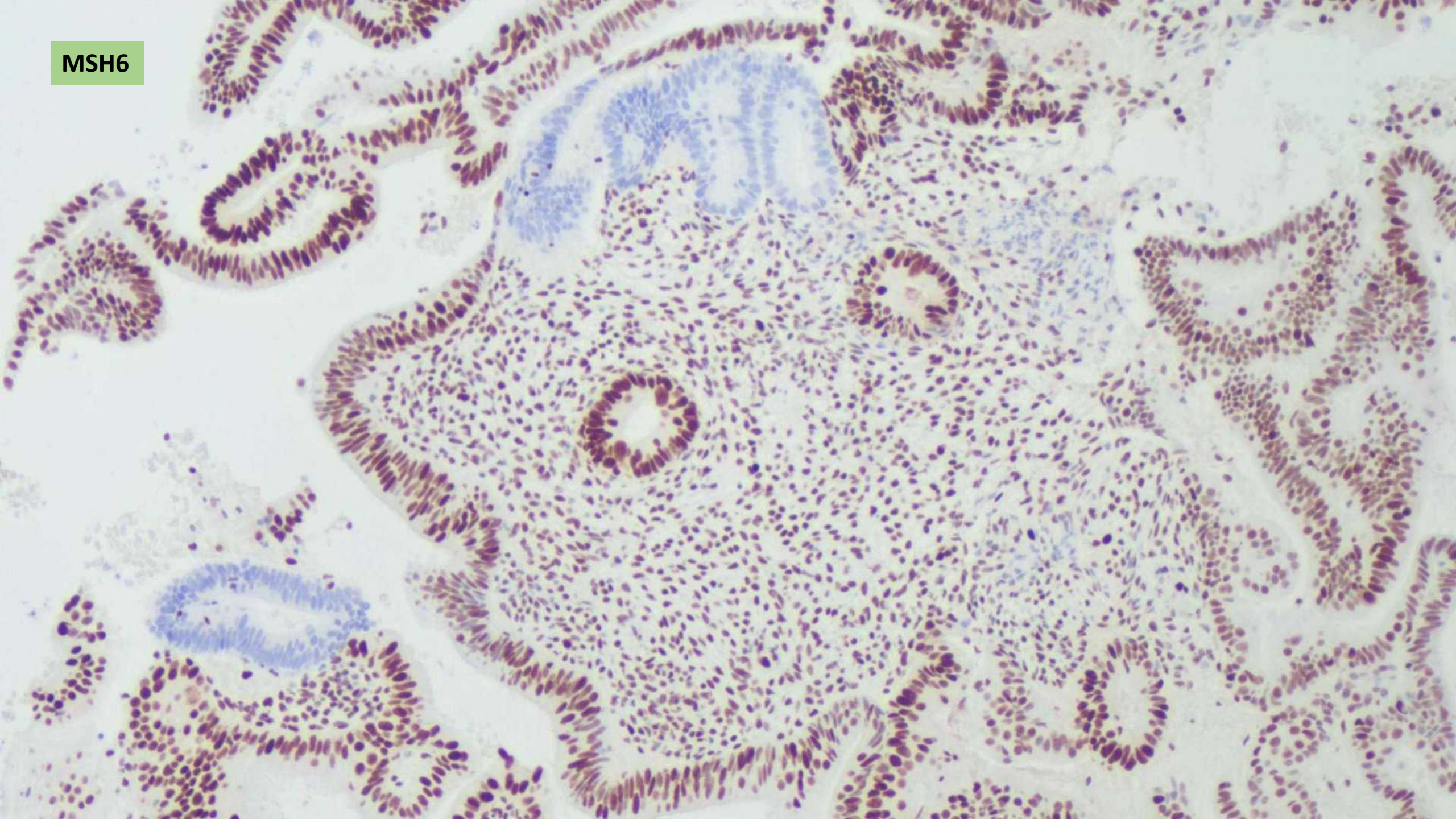
MSH6

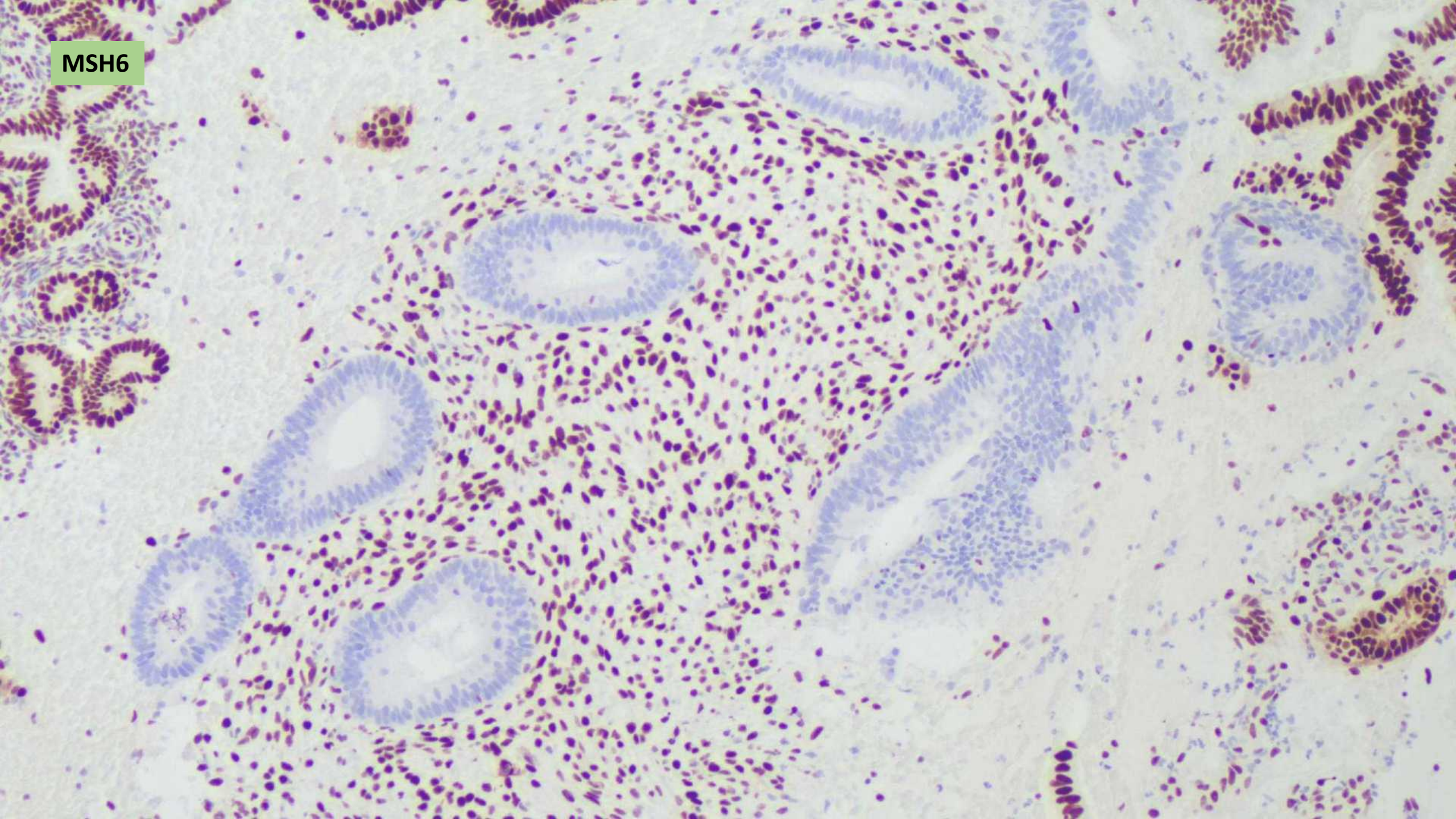
MSH6

Case 1 – MMR IHC findings

	Endometrioid carcinoma	Non-neoplastic endometrial glands
MLH1	Subclonal loss	Scattered glands with MLH1 loss
PMS2	Subclonal loss	Scattered glands with PMS2 loss (same as those with MLH1 loss)
MSH2	Retained	No MSH2 loss
MSH6	Retained	Scattered glands with MSH6 loss (different area from those with MLH1 & PMS2 loss)

Subclonal mismatch repair protein expression in endometrial carcinomas

- Internal control staining must be present in the areas of subclonal loss (to distinguish from fixation problems)
  - An arbitrary cutoff of 10% (tumour area) has been proposed to avoid overdiagnosis of subclonal loss
- Usually due to somatic genetic/epigenetic changes, such as
  - *MLH1* promoter hypermethylation affecting a subclone of tumour cells
  - Bi-allelic mutations in an MMR gene (especially *MSH6*) secondary to MMR deficiency (affecting another MMR gene), or secondary to *POLE* mutation
- Germline MMR gene mutations have been found in some endometrial carcinomas with subclonal MMR expression

  Scheiderer A, Riedinger C, Kimball K, et al. Arch Pathol Lab Med 2022. (PMID: 34979565.)

  Mendoza RP, Wang P, Schulte JJ, et al. Am J Surg Pathol 2023 (PMID: 36866757)

  Riedinger CJ, Esnakula A, Haight PJ, et al. Cancer. 2024. (PMID: 37751191)

- Should be reported as abnormal as the possibility of Lynch syndrome is not excluded

Mismatch repair deficient non-neoplastic endometrial glands as a clue to Lynch syndrome

- **MMR-deficient non-neoplastic endometrial glands** (with mutation-specific loss of MMR expression) are demonstrated in 47 – 70% of endometrial specimens in Lynch syndrome patients

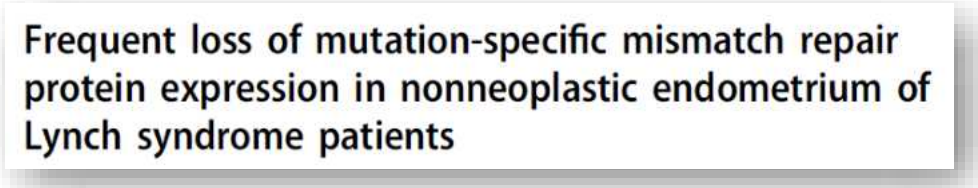

Wong S, Hui P, Buza N. Mod Pathol 2020 (PMID: 31932681)

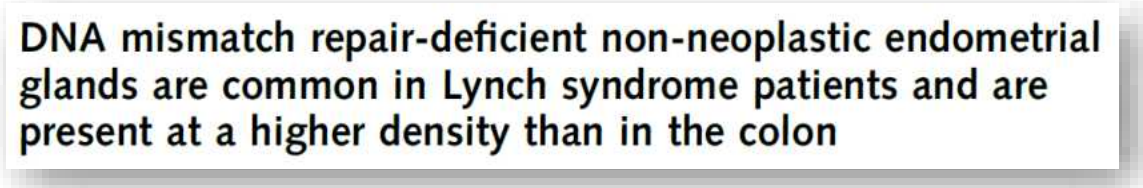

Hegazy S, Brand RE, Dudley B, et al Histopathology 2021 (PMID 33847404)

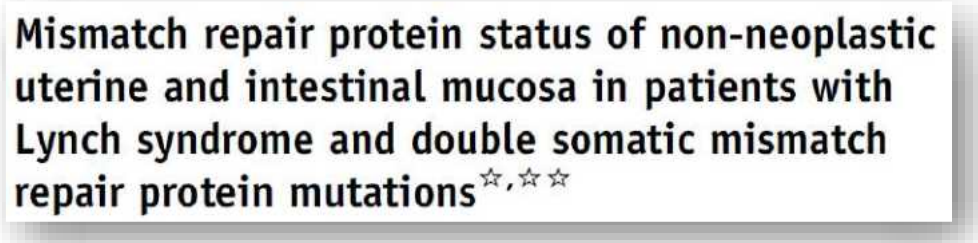

Freitag CE, Chen W, Pearlman R, et al. Hum Pathol 2023 (PMID: 37030500)

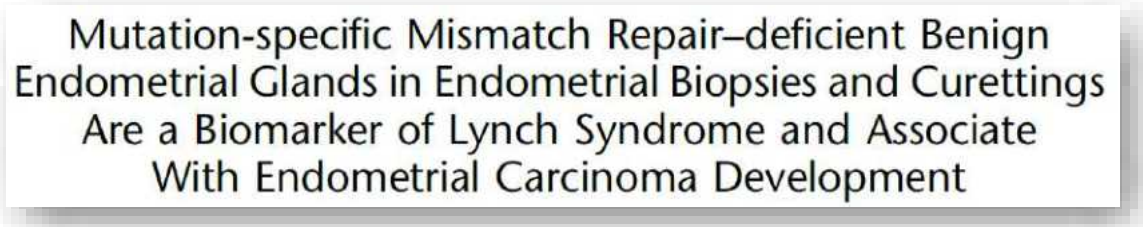

Hegazy S, Brand RE, Dudley B, et al. Am J Surg Pathol 2023 (PMID: 37226842)

Mismatch repair deficient non-neoplastic endometrial glands as a clue to Lynch syndrome

- MMR-deficient non-neoplastic endometrial glands are not identified in the control groups of endometrial specimens in these studies
  - Except for 1 case of endometrial carcinoma with double somatic mutations in *MLH1* (Freitag et al. 2023)
- Lack of established guidance on the reporting of MMR-deficient non-neoplastic endometrial glands

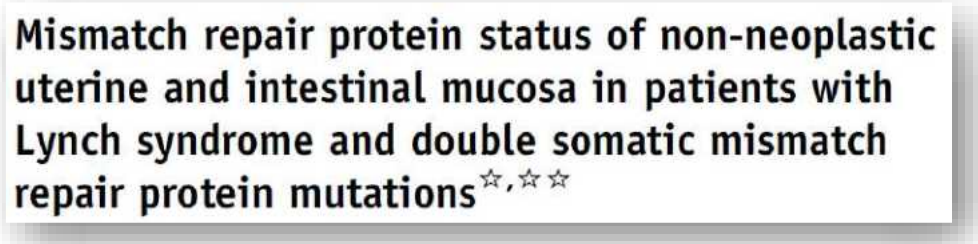
Mismatch repair protein status of non-neoplastic uterine and intestinal mucosa in patients with Lynch syndrome and double somatic mismatch repair protein mutations☆,☆☆

Freitag CE, Chen W, Pearlman R, et al. Hum Pathol 2023 (PMID: 37030500)

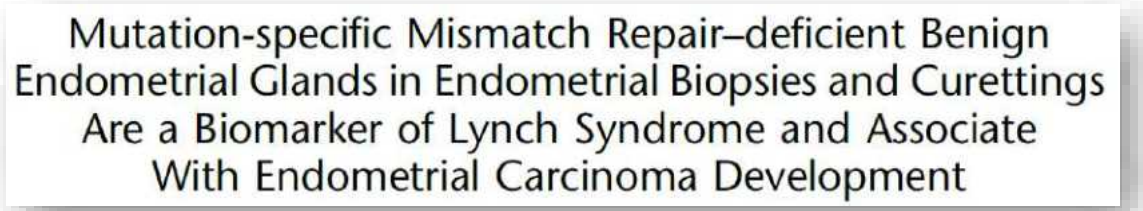
Mutation-specific Mismatch Repair–deficient Benign Endometrial Glands in Endometrial Biopsies and Curettings Are a Biomarker of Lynch Syndrome and Associate With Endometrial Carcinoma Development

Hegazy S, Brand RE, Dudley B, et al. Am J Surg Pathol 2023 (PMID: 37226842)

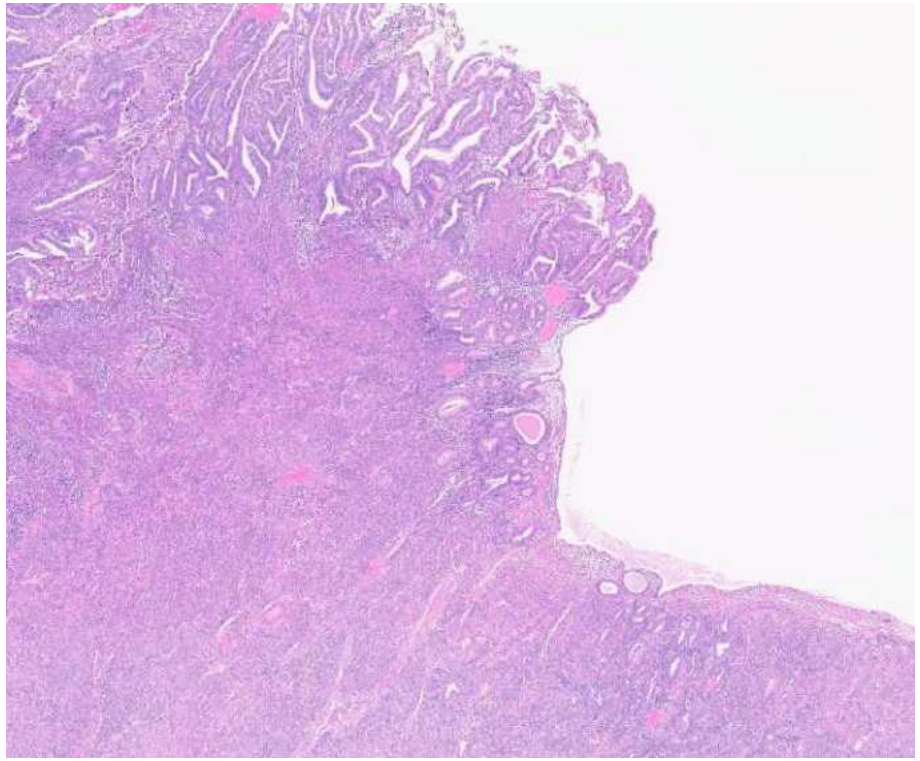

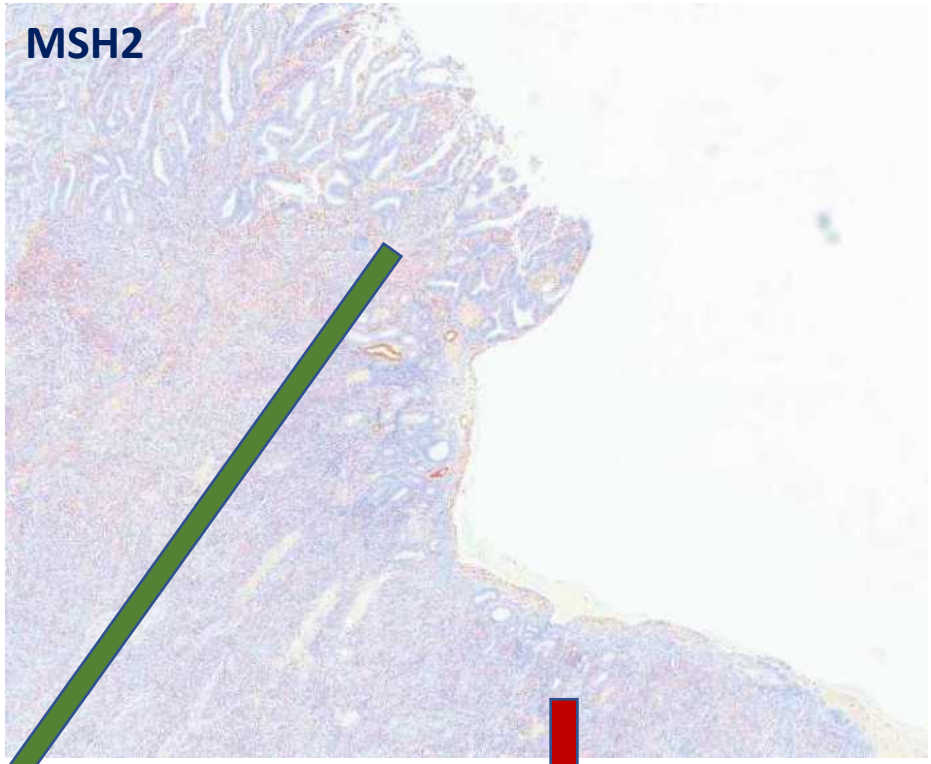

Endometrial carcinoma in Lynch syndrome with germline *MSH2* mutation

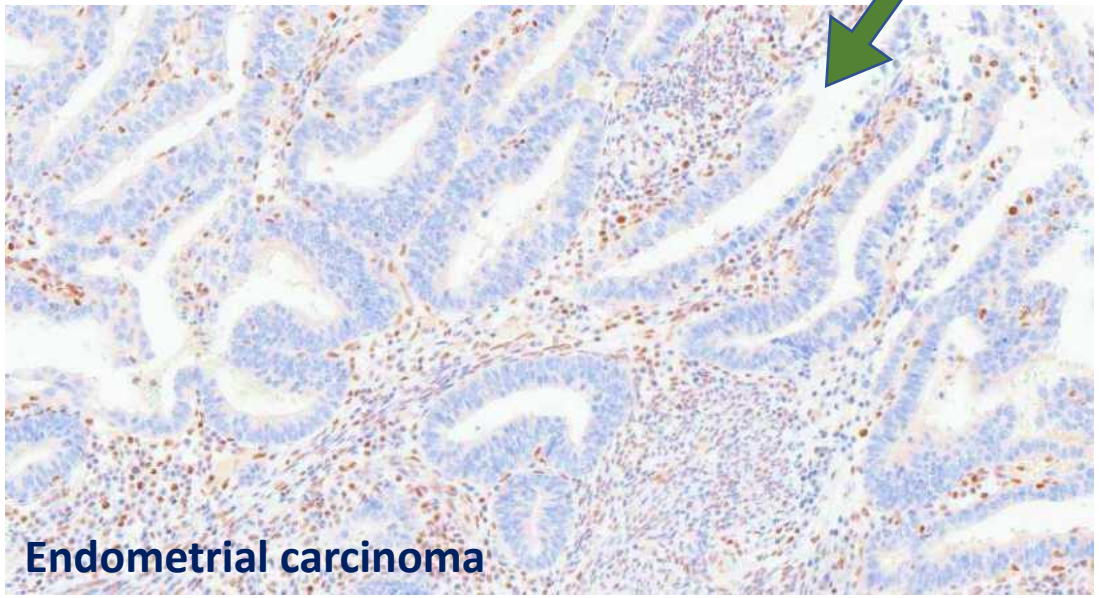

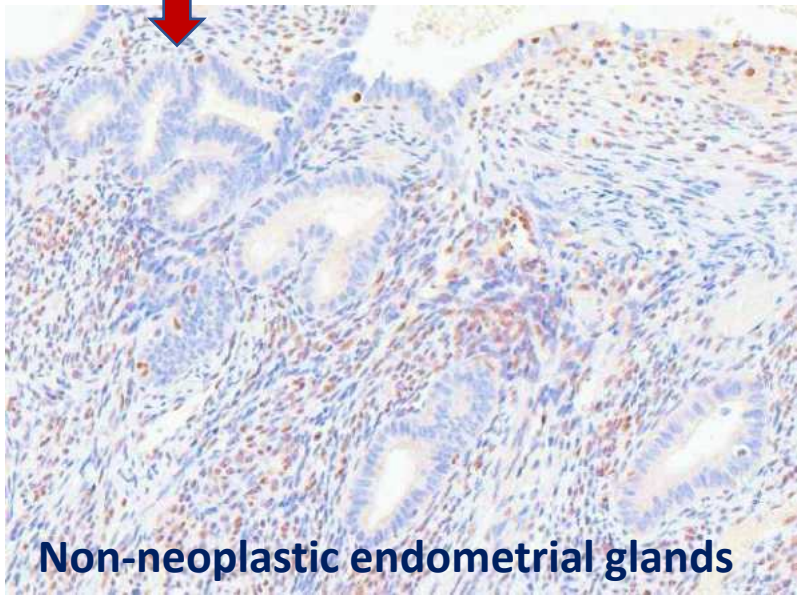

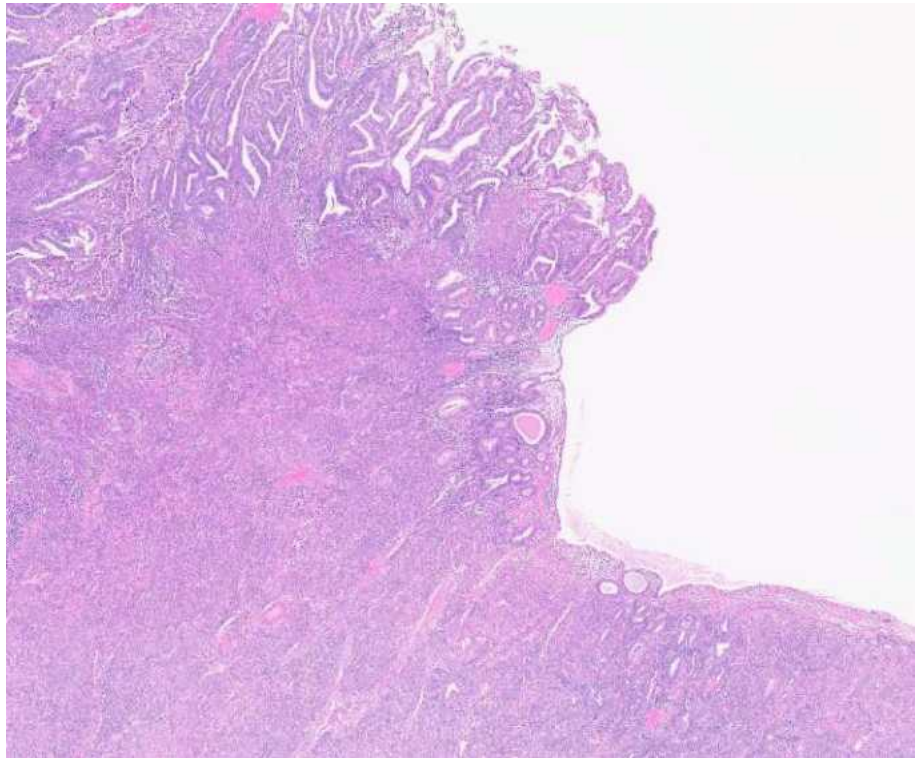

Non-neoplastic glands with mutation-specific MMR deficiency (MSH2/MSH6 loss for *MSH2* mutation)

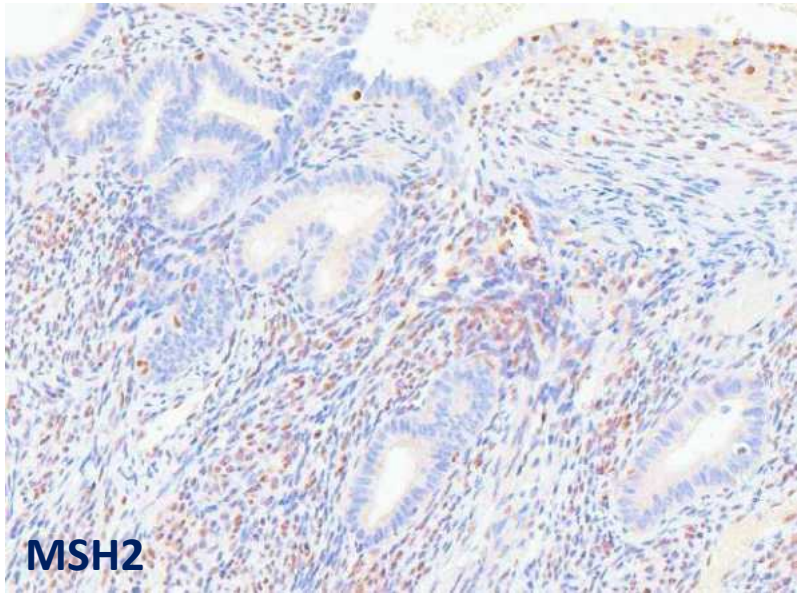

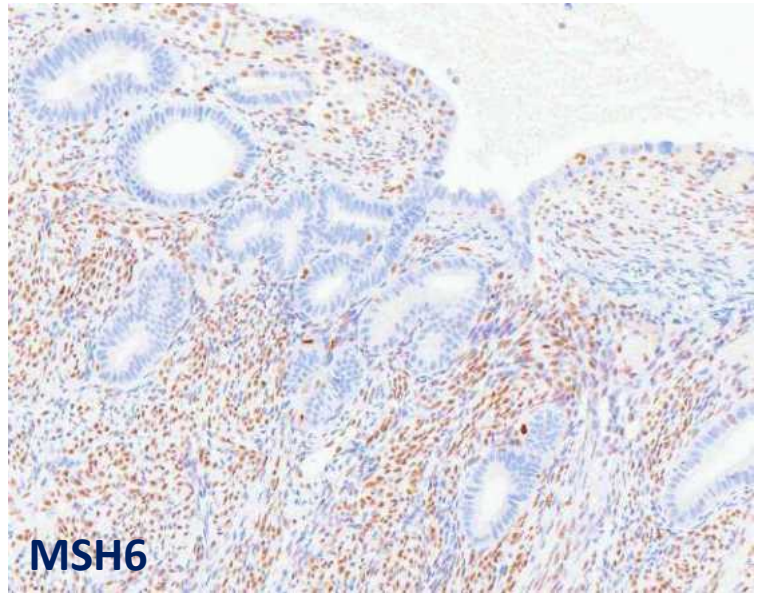

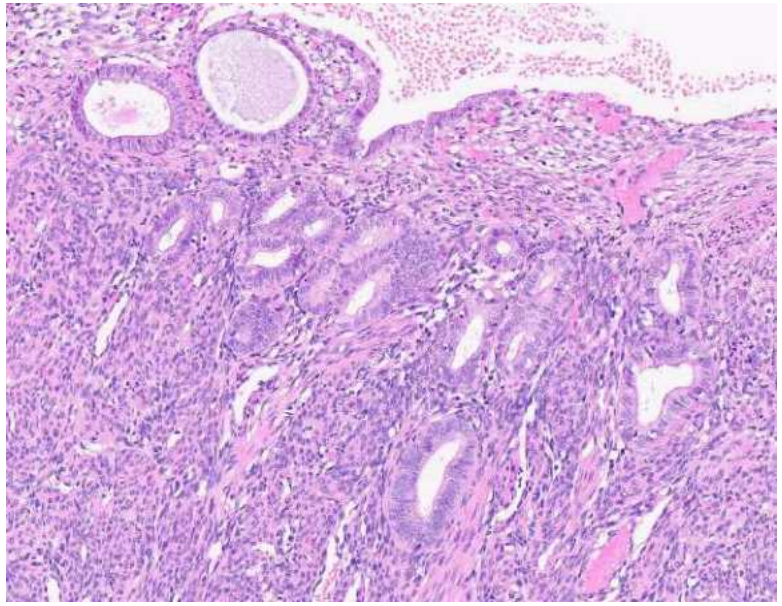



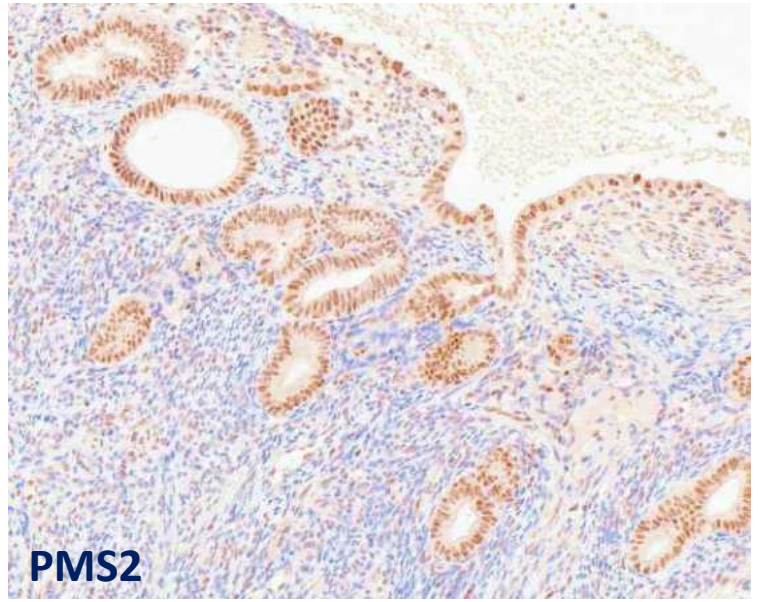

Case 1 – IHC interpretation

- Subclonal MLH1/PMS2 loss in endometrial carcinoma
  - May be related to somatic or germline MLH1 defect
- Non-neoplastic endometrial glands with MLH1/PMS2 loss
  - Lynch syndrome with germline *MLH1* mutation should be considered
- Non-neoplastic endometrial glands with MSH6 loss
  - Lynch syndrome with germline *MSH6* mutation should be considered

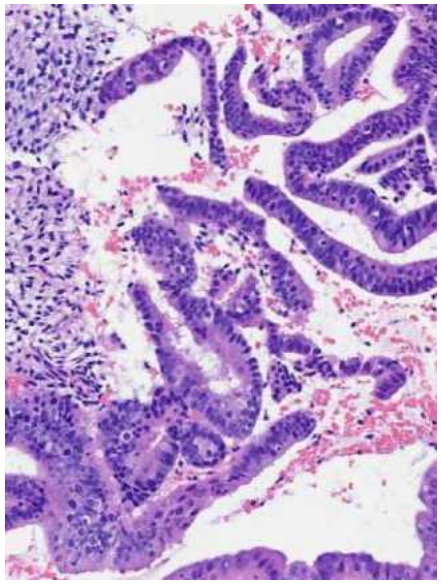



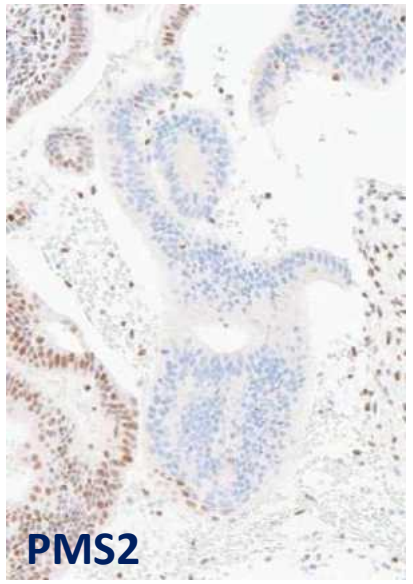

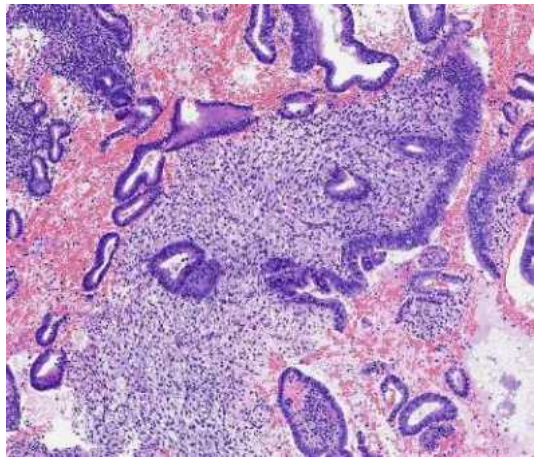

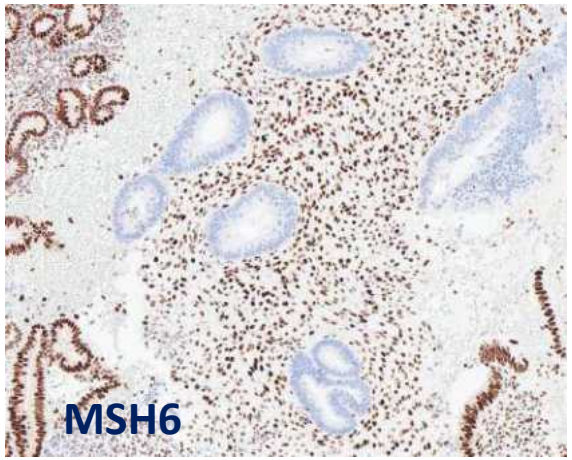

Case 1 – Clinical findings

- Genetic testing for Lynch syndrome showed germline *MLH1* mutation
  - Subclonal MMR expression could be (uncommonly) associated with Lynch syndrome

- No documented germline *MSH6* mutation in this patient
  - Not known whether genetic testing was performed for *MLH1* only (as the tumour IHC profile suggested *MLH1* defect)
  - Germline *MSH6* mutation might have been classified as VUS
  - Potential relevance in cascade testing

Case 2

- 60 years old
- Hysterectomy for suspected endometrial carcinoma
- 6 cm infiltrative tumour involving the entire myometrial thickness

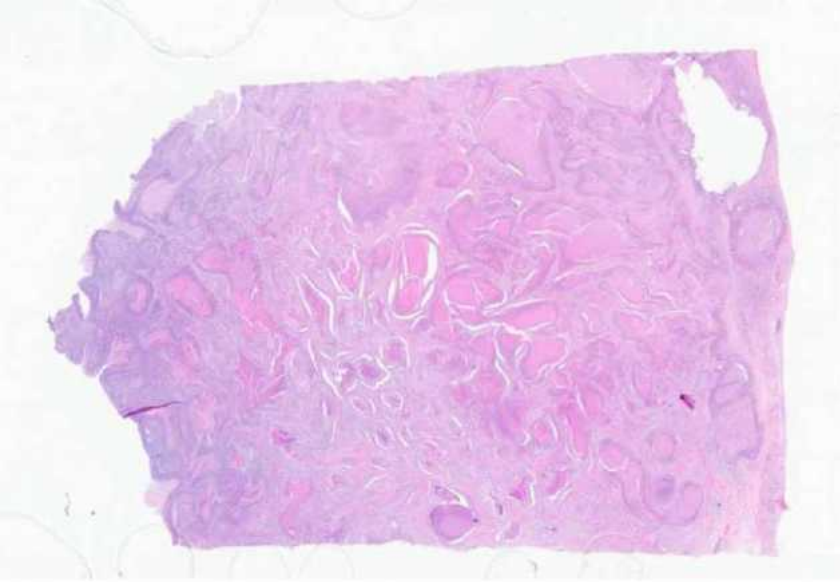

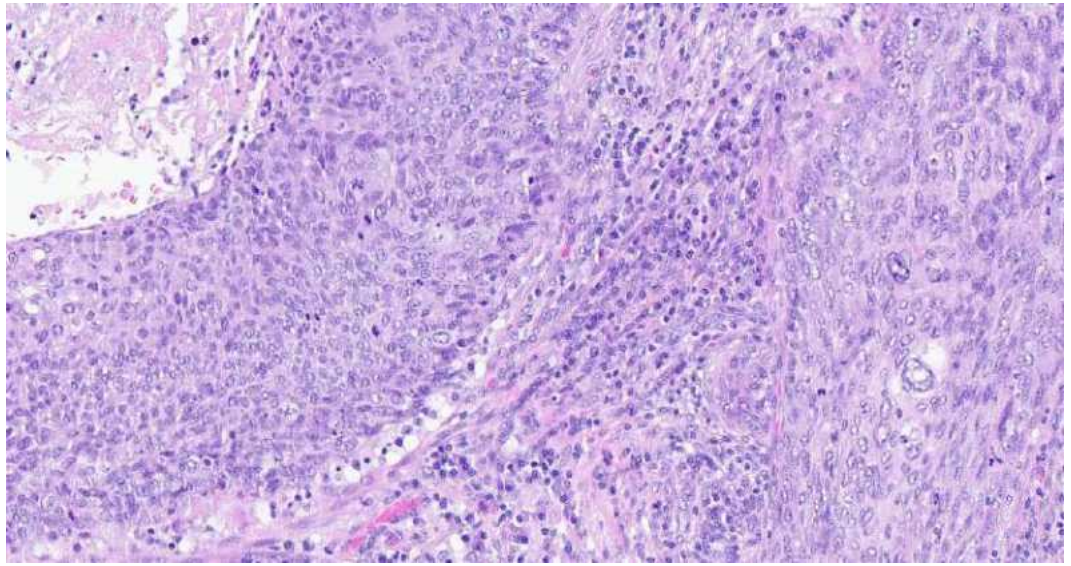

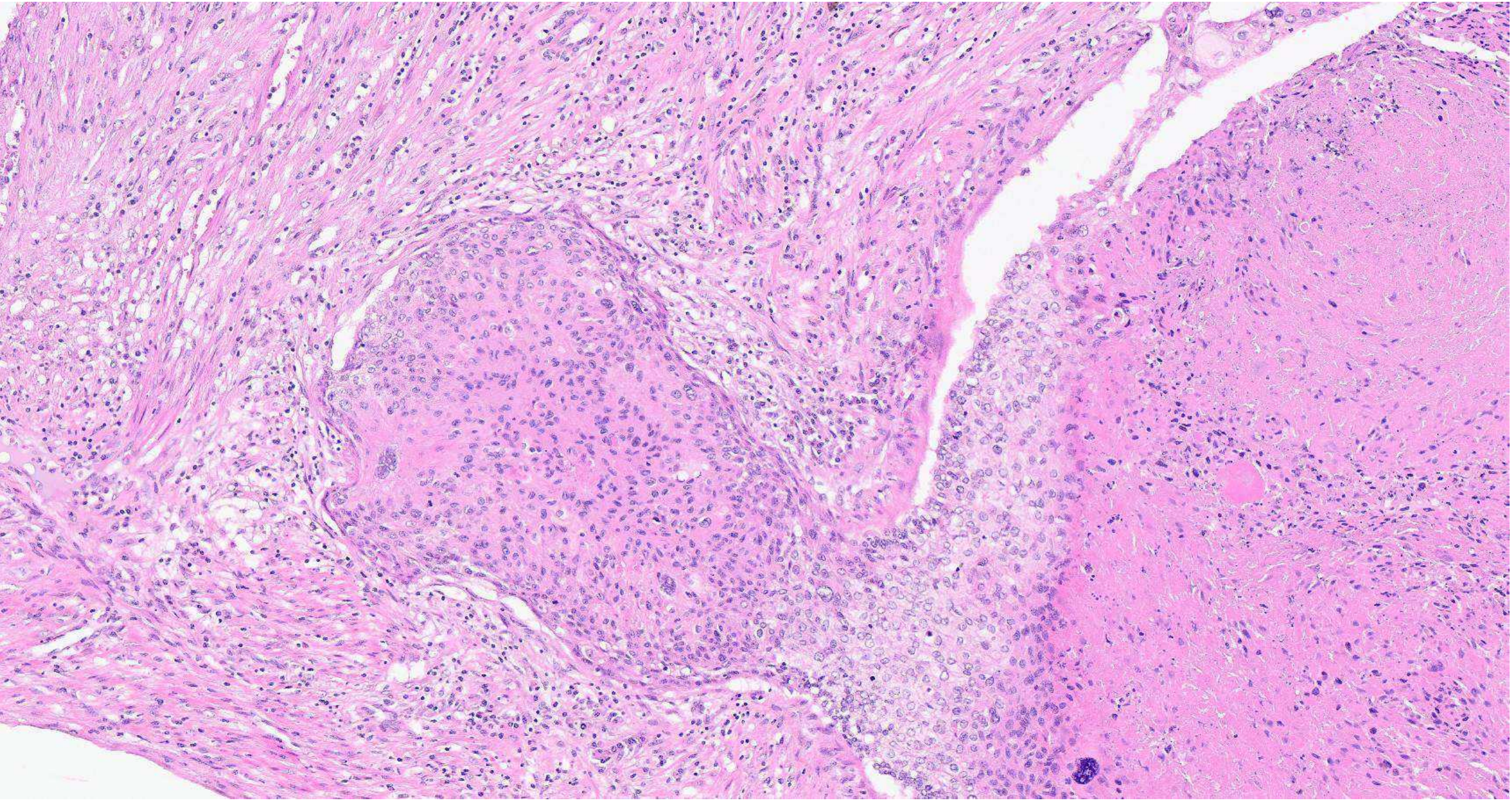

Case 2

- ER

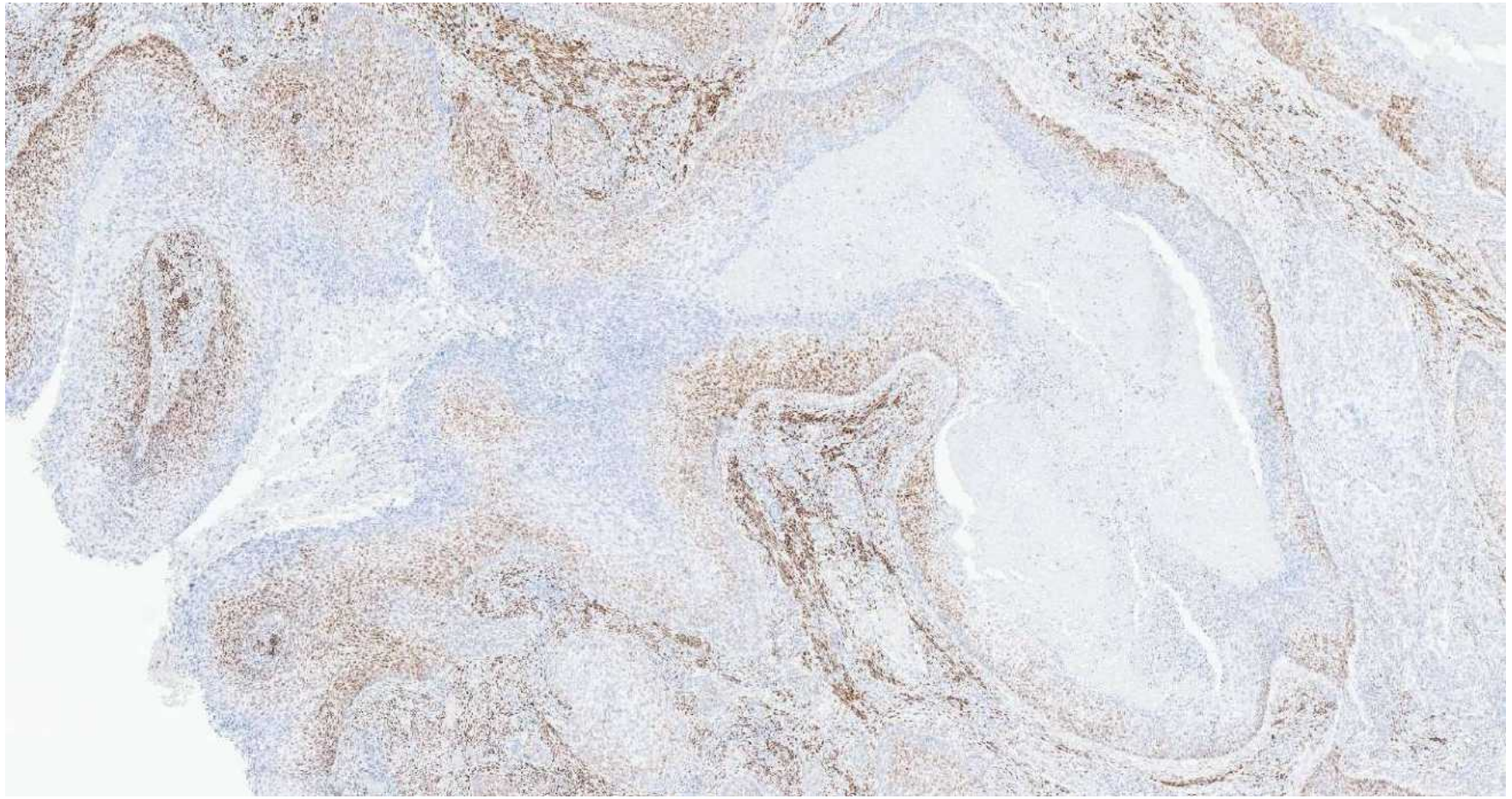

Case 2

- PR

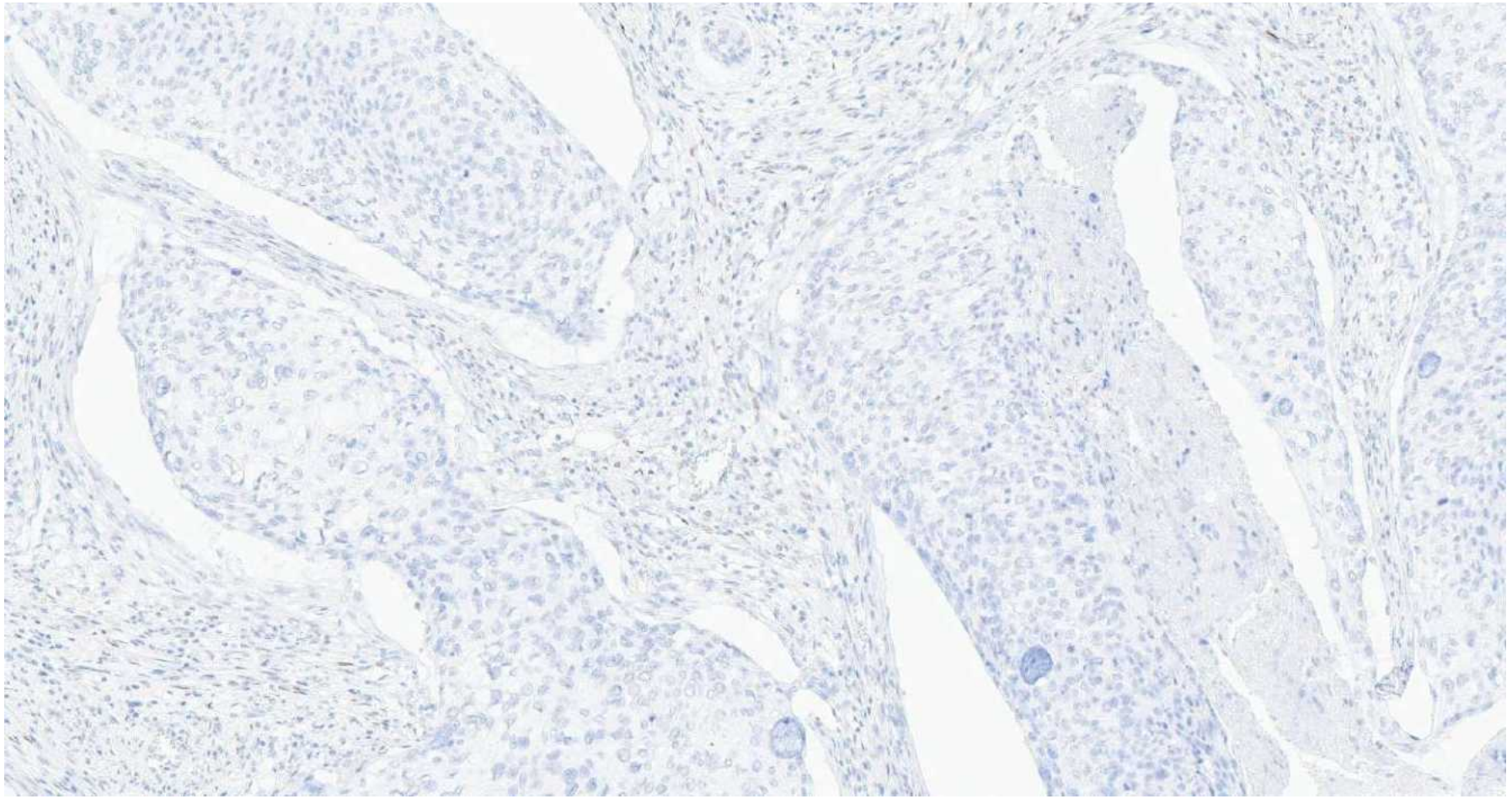

Case 2

- p16



Case 2

- p53

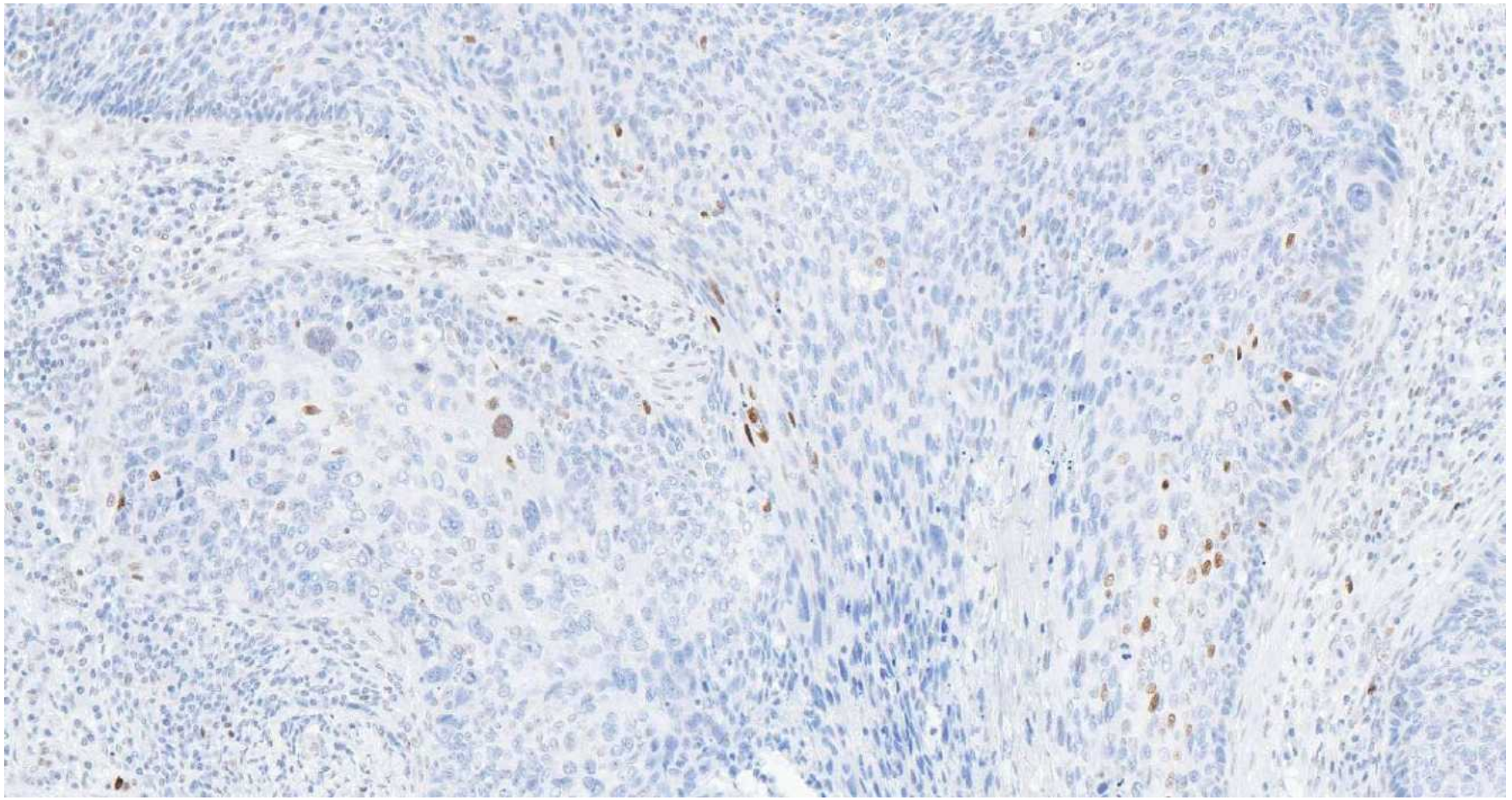

Case 2

- p40

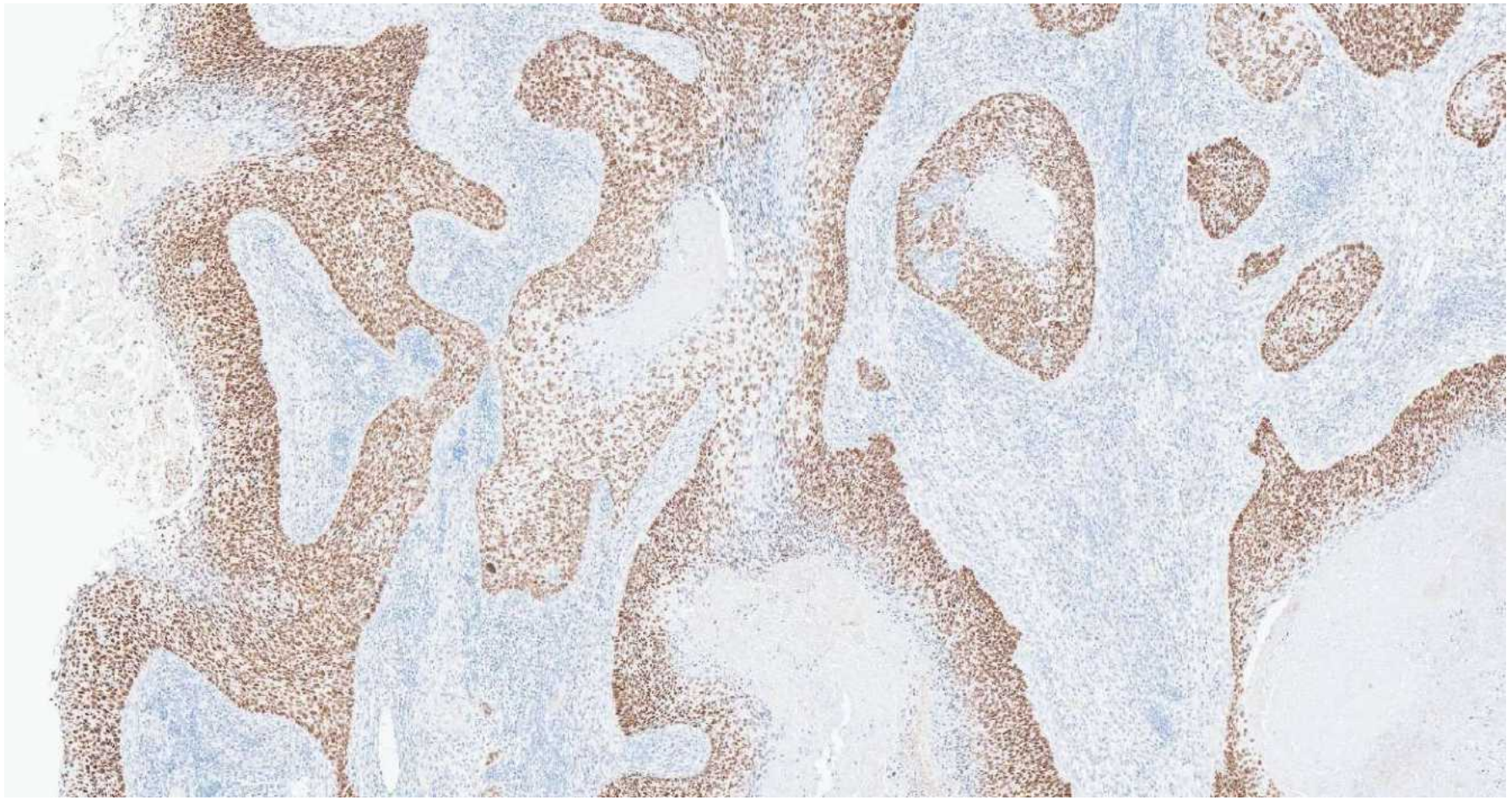

Case 2

- No macroscopic tumour involvement in the uterine cervix

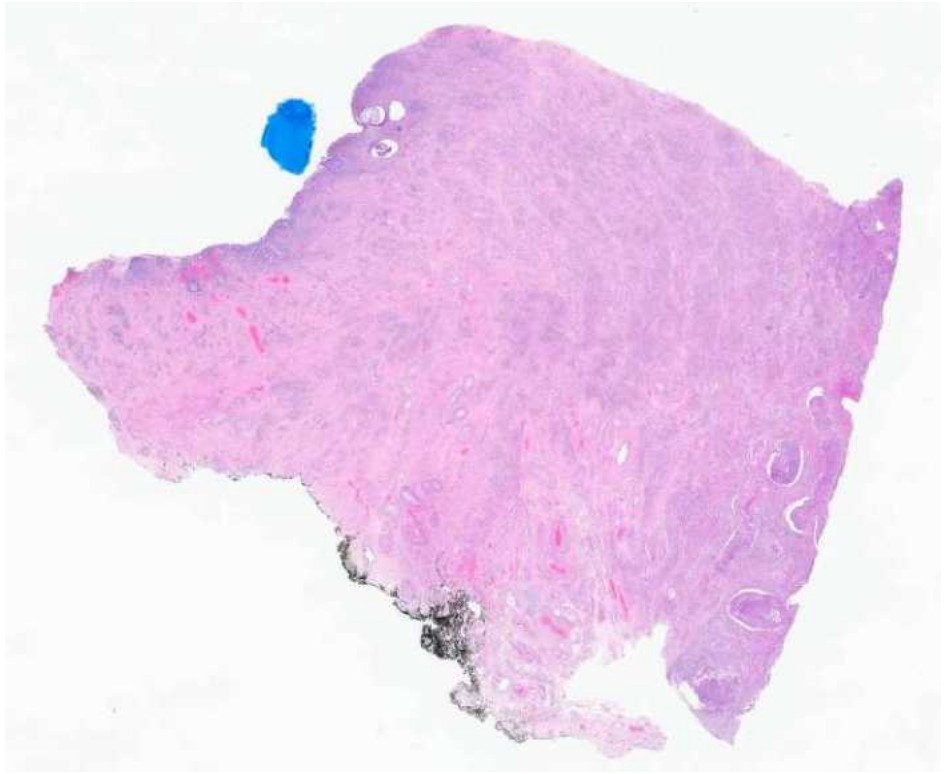

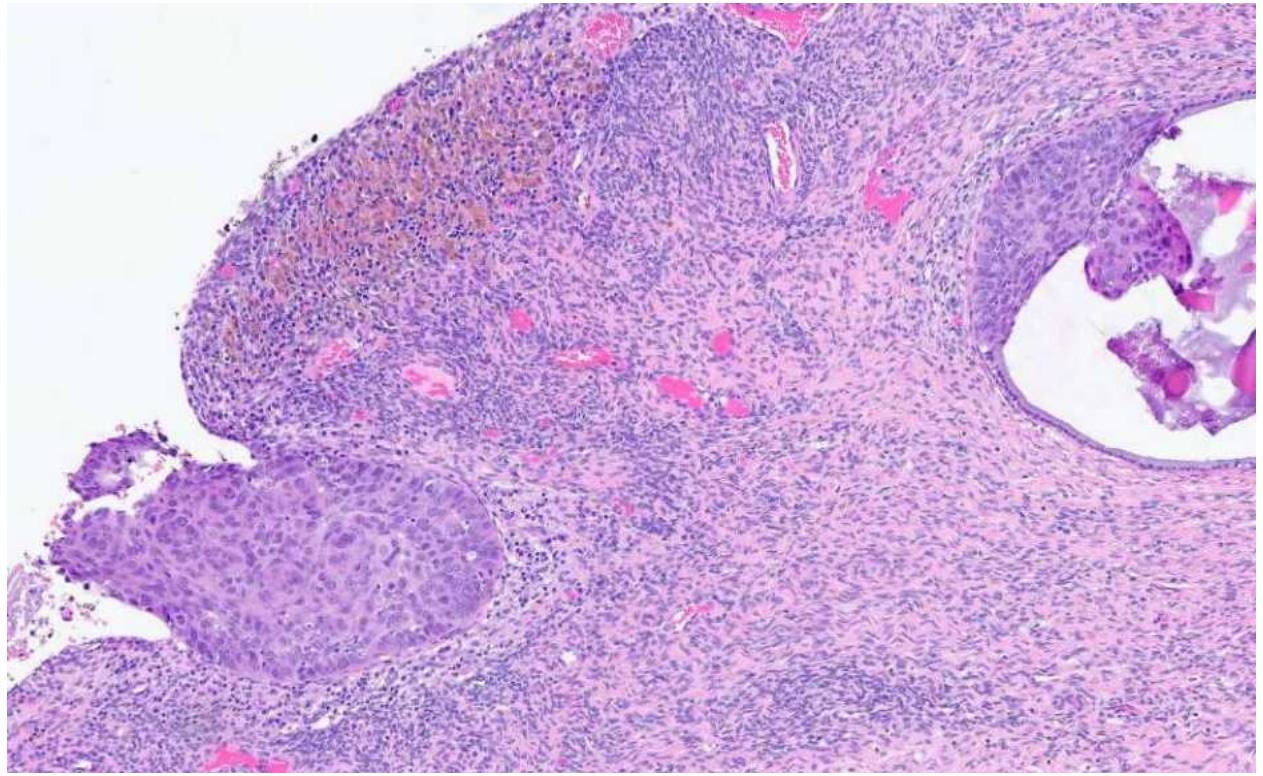

Case 2 – Pathological findings

- Squamous cell carcinoma involving the endometrium and myometrium
  - ER focally positive
  - PR negative
  - p16 block positive
  - p53 wild-type
  - p40 positive
- HSIL (without invasive carcinoma) in the cervix

Case 2 – Differential diagnosis

- Squamous cell carcinoma involving the endometrium and myometrium
  - ER focally positive
  - PR negative
  - p16 block positive
  - p53 wild-type
  - p40 positive
- HSIL (without invasive carcinoma) in the cervix

- Primary endometrial squamous cell carcinoma with concurrent HSIL?
- HPV-associated endometrial squamous cell carcinoma?
- Cervical squamous cell carcinoma with endomyometrial involvement?

Primary endometrial squamous cell carcinoma (PESCC)

- Rare type of endometrial carcinoma displaying exclusive squamous differentiation without endometrioid component
- Mean age 66 – 78 years
- May be associated with uterine prolapse, pelvic irradiation or cervical stenosis, which could predispose to ichthyosis uteri or pyometra
- Most PESCCs are HPV negative
  - It was speculated that reported cases of HPV-associated PESCC might represent cervical SCC with extensive endometrial involvement
- IHC profile: abnormal p53 expression commonly seen and usually negative for p16, ER and PR
- Some cases have *TP53* and *CDKN2A* mutations (Hopkins et al. AJSP 2022)

Hopkins MR, Palsgrove DN, Ronnett BM, et al. Am J Surg Pathol 2022. (PMID: 36069815)

Diagnostic criteria of PESCC

- Discussed in a recent study by Hopkins et al. (PMID 36069815)
- Traditional diagnostic criteria (Fluhmann criteria published in 1928) considered too stringent (cervical involvement not allowed) and relied on morphology alone

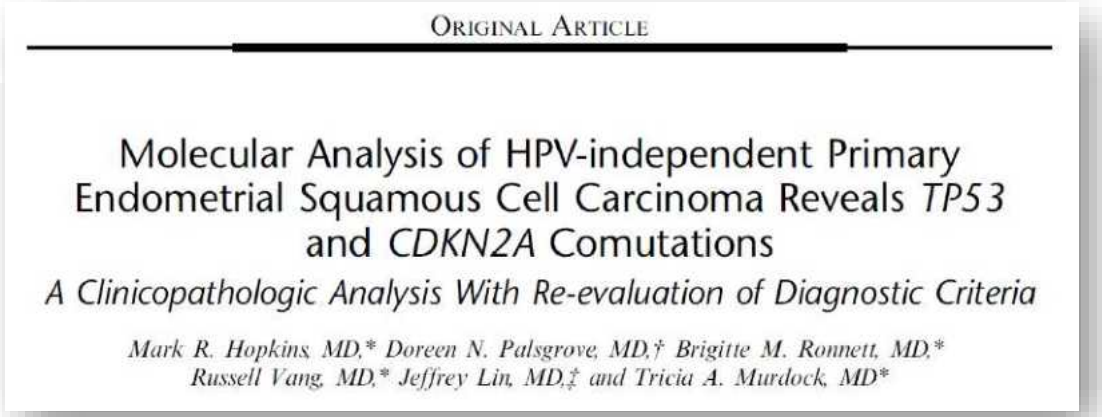

ORIGINAL ARTICLE

Molecular Analysis of HPV-independent Primary Endometrial Squamous Cell Carcinoma Reveals *TP53* and *CDKN2A* Comutations

A Clinicopathologic Analysis With Re-evaluation of Diagnostic Criteria

Mark R. Hopkins, MD, Doreen N. Palsgrove, MD,† Brigitte M. Ronnett, MD,* Russell Vang, MD,* Jeffrey Lin, MD,‡ and Tricia A. Murdock, MD**

Hopkins MR, Palsgrove DN, Ronnett BM, et al. Am J Surg Pathol 2022. (PMID: 36069815)

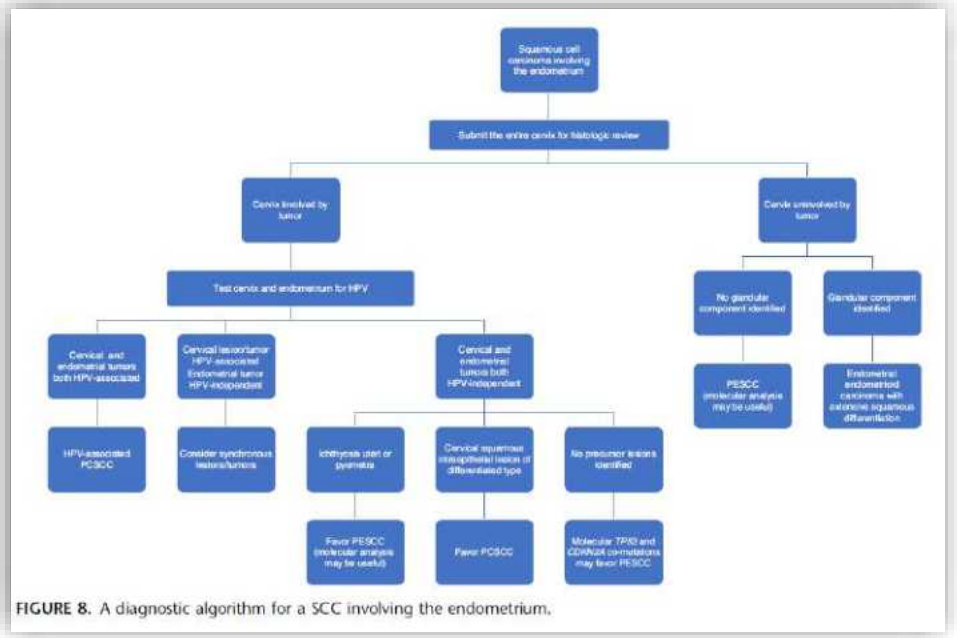

FIGURE 8. A diagnostic algorithm for a SCC involving the endometrium.

Diagnostic criteria of PESCC

- Essential criteria for PESCC include ALL of the following:
  - Proliferation of squamous cells with cytological and/or architectural atypia in the endometrium; AND
  - Absence of glandular differentiation; AND
  - Absence of HPV-associated SCC or HSIL in the cervix upon complete histological sampling
- Cervical involvement by PESCC is possible
  - If there is cervical mucosal involvement by HPV-associated SCC (based on p16 or HPV ISH) or HSIL, a diagnosis of cervical SCC should be made (irrespective of the extent of endomyometrial involvement)
- HPV-associated PESCC might be considered if the tumour is diffusely p16 positive (with HPV demonstrated by molecular studies) and there is no evidence of HSIL or SCC in the cervix upon complete histological sampling

Hopkins MR, Palsgrove DN, Ronnett BM, et al. Am J Surg Pathol 2022. (PMID: 36069815)

Case 2 – Diagnosis

- Squamous cell carcinoma involving the endometrium and myometrium
  - ER focally positive
  - PR negative
  - p16 block positive
  - p53 wild-type
  - p40 positive
- HSIL (without invasive carcinoma) in the cervix

- Diagnosis: **Cervical squamous cell carcinoma with extensive endomyometrial involvement**

- HPV ISH not available but scraping from the tumour was positive for HPV type 16 by PCR-based testing

Case 3

- 80 years old
- Postmenopausal bleeding
- Endometrial biopsy performed

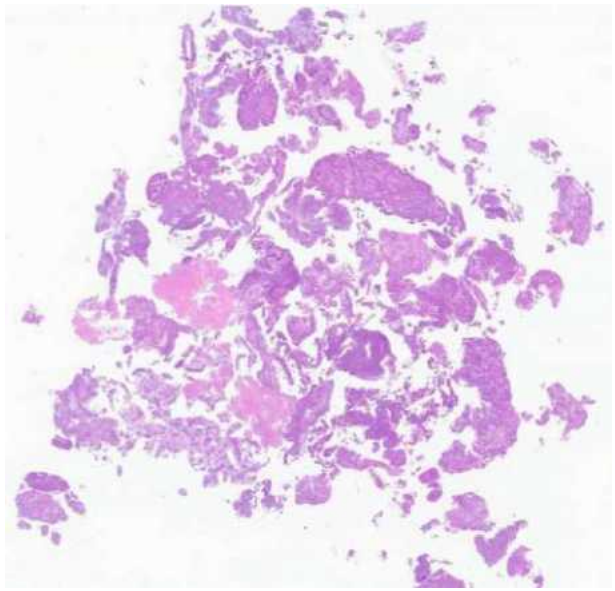
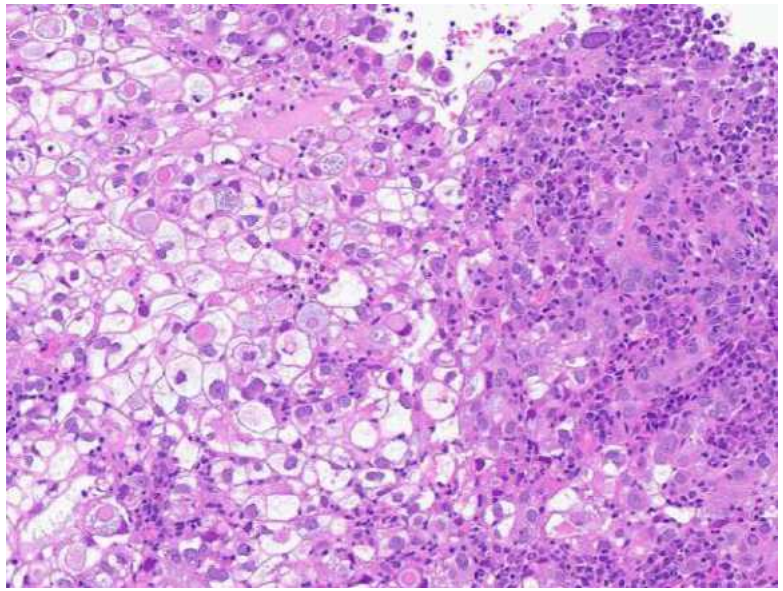
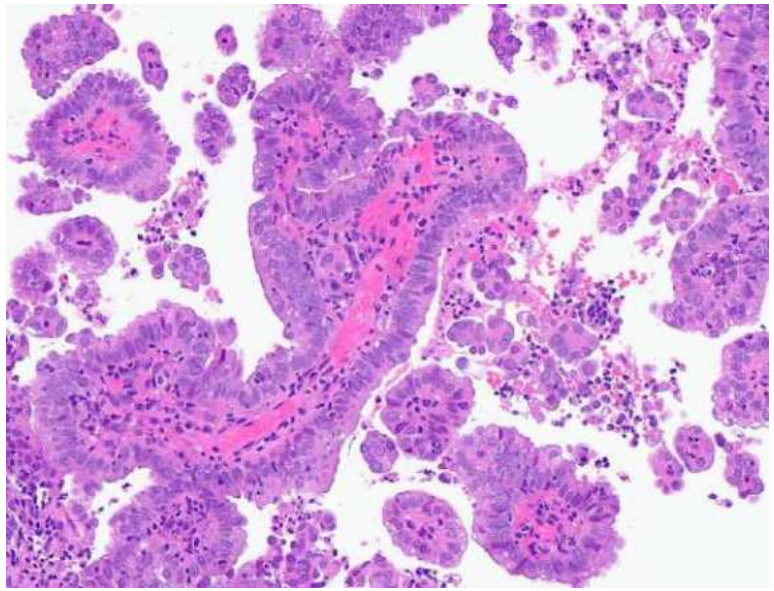

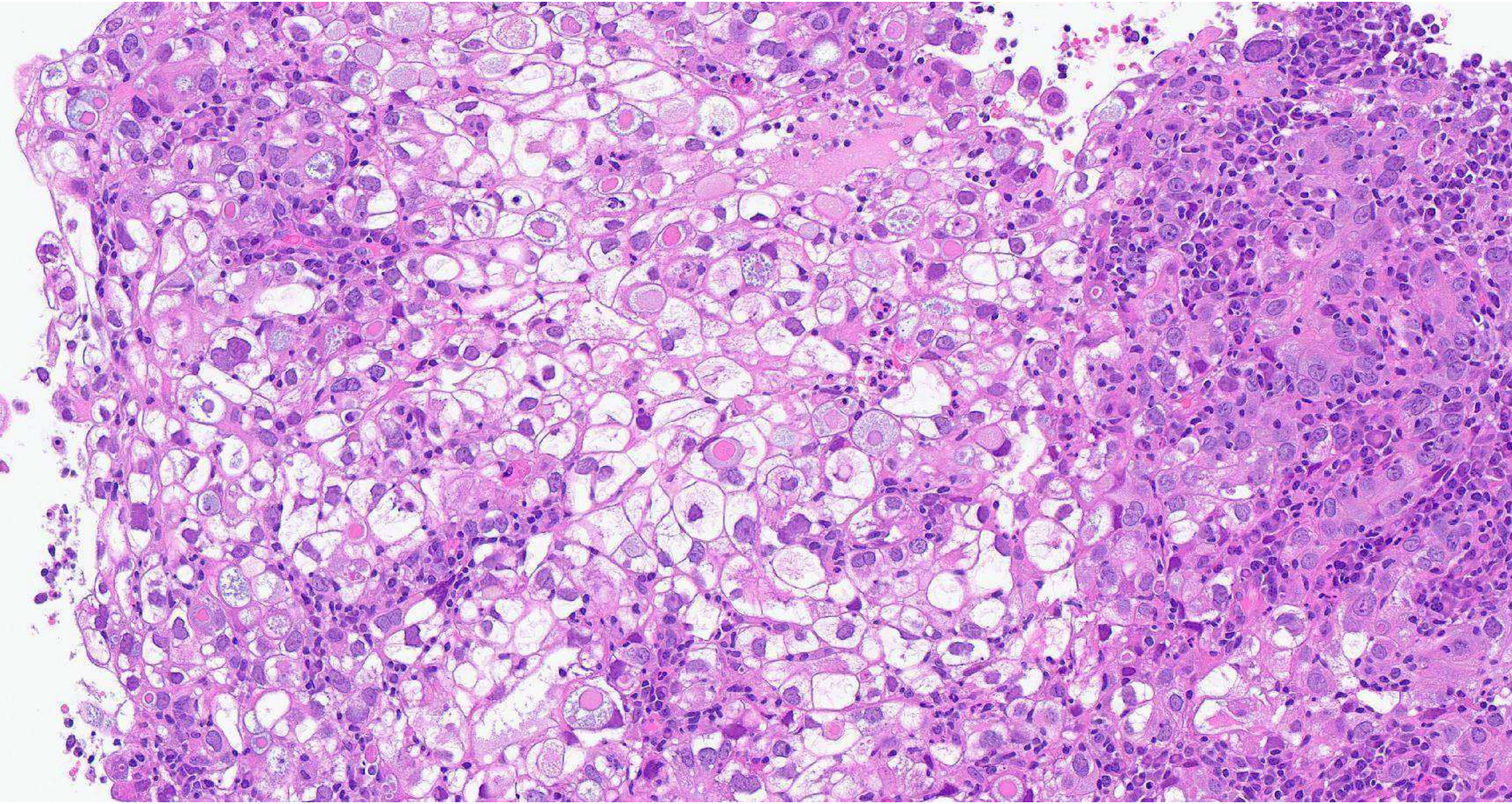

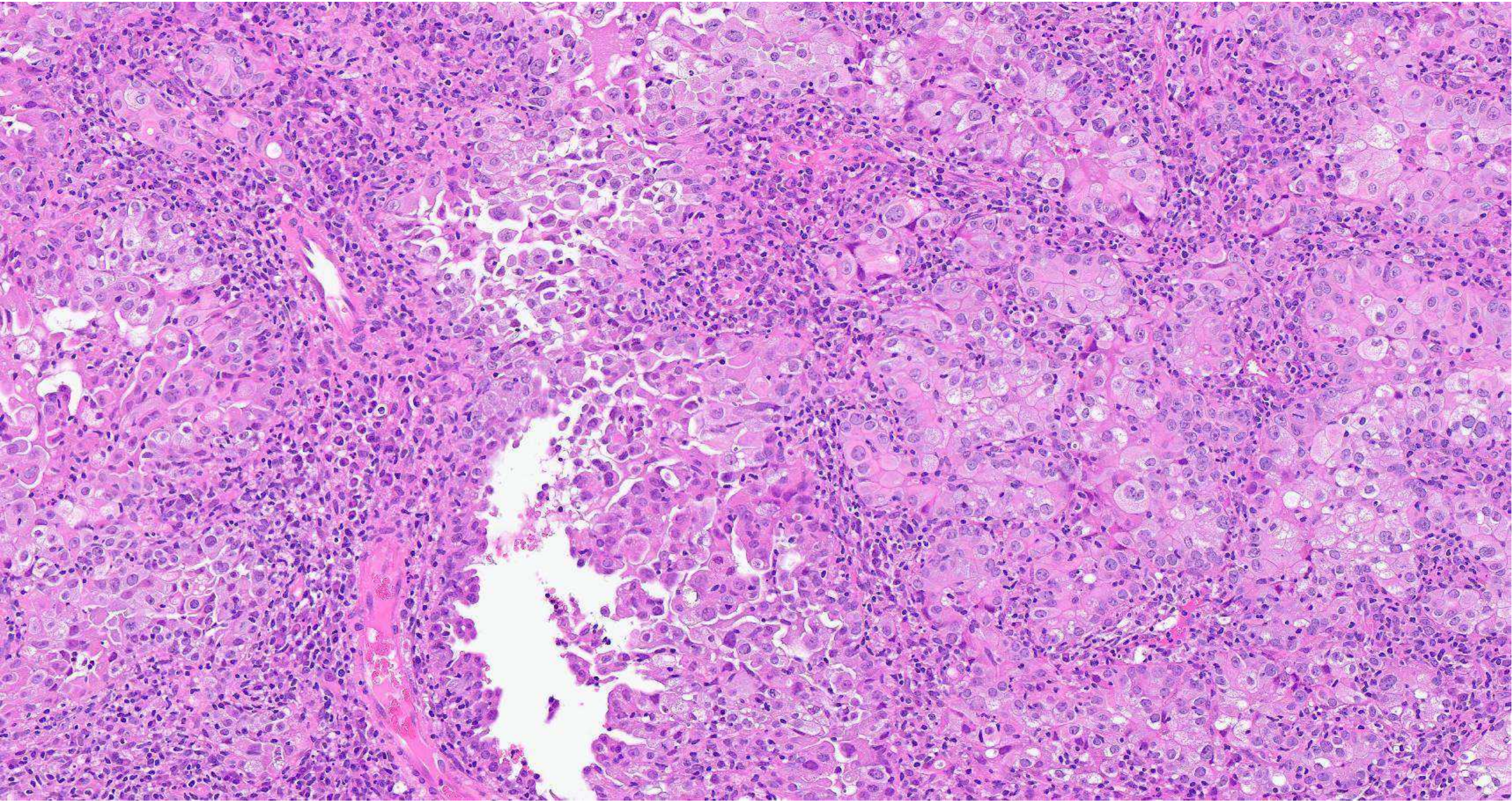

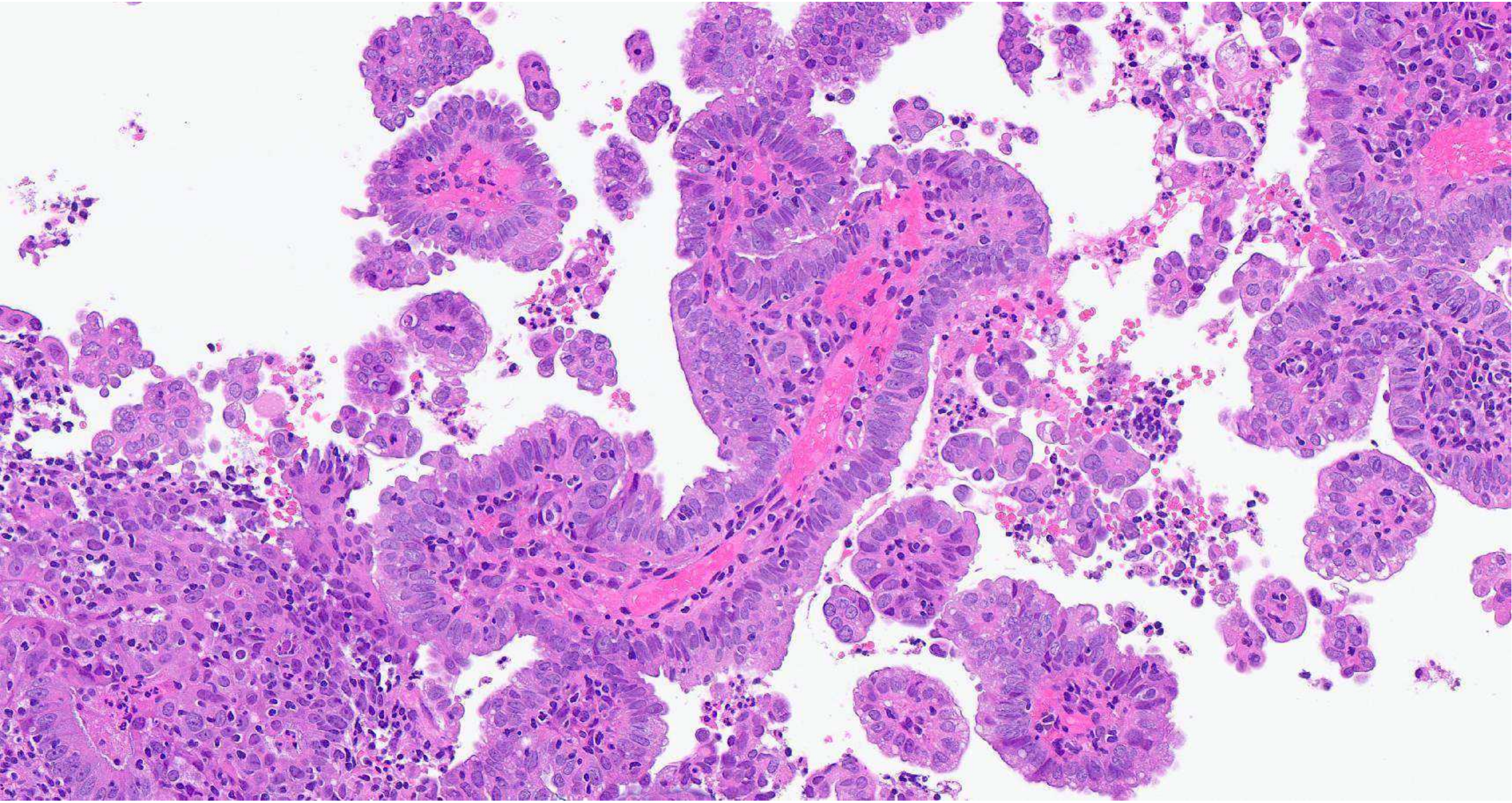

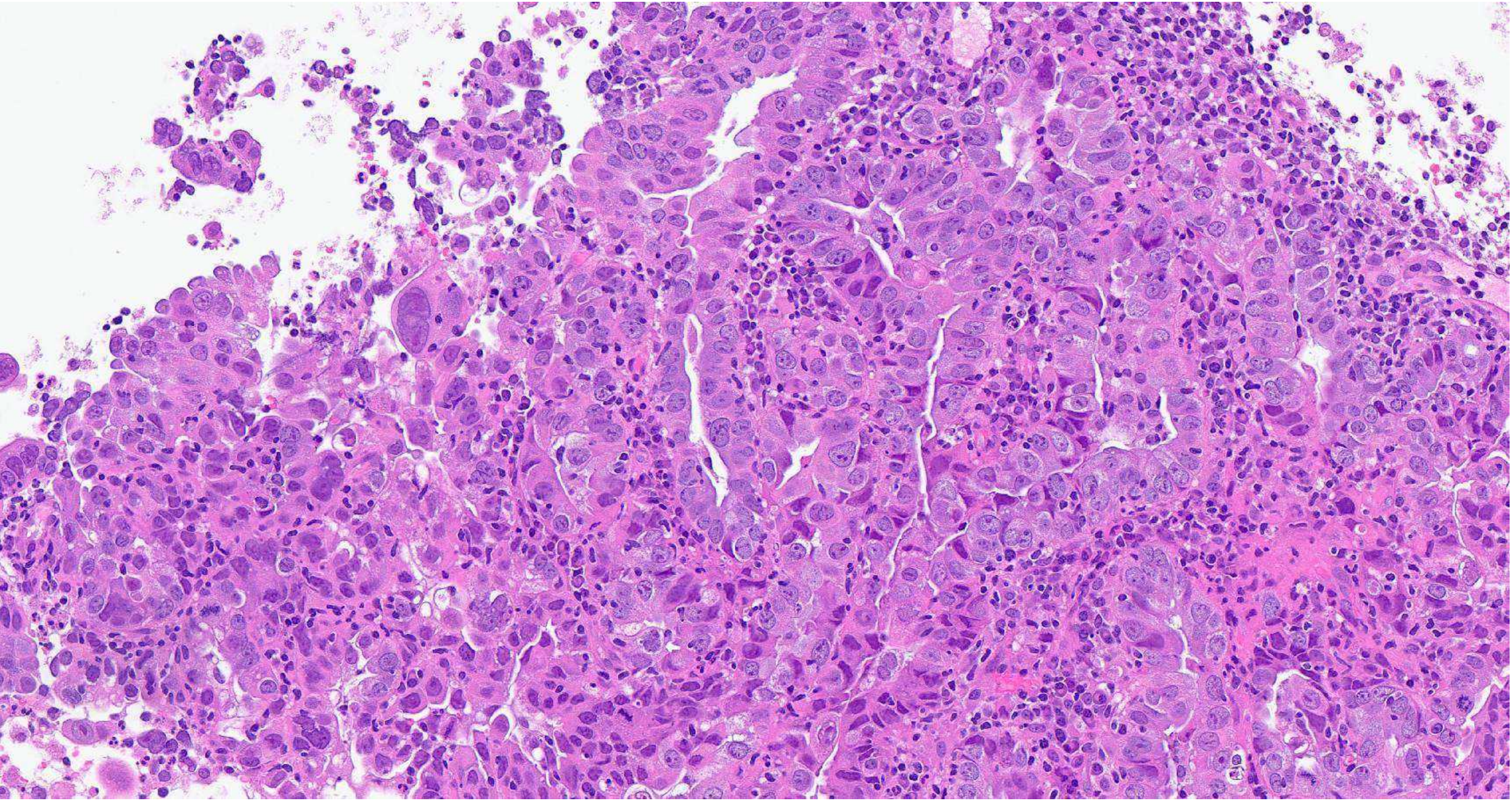

Case 3

- ER

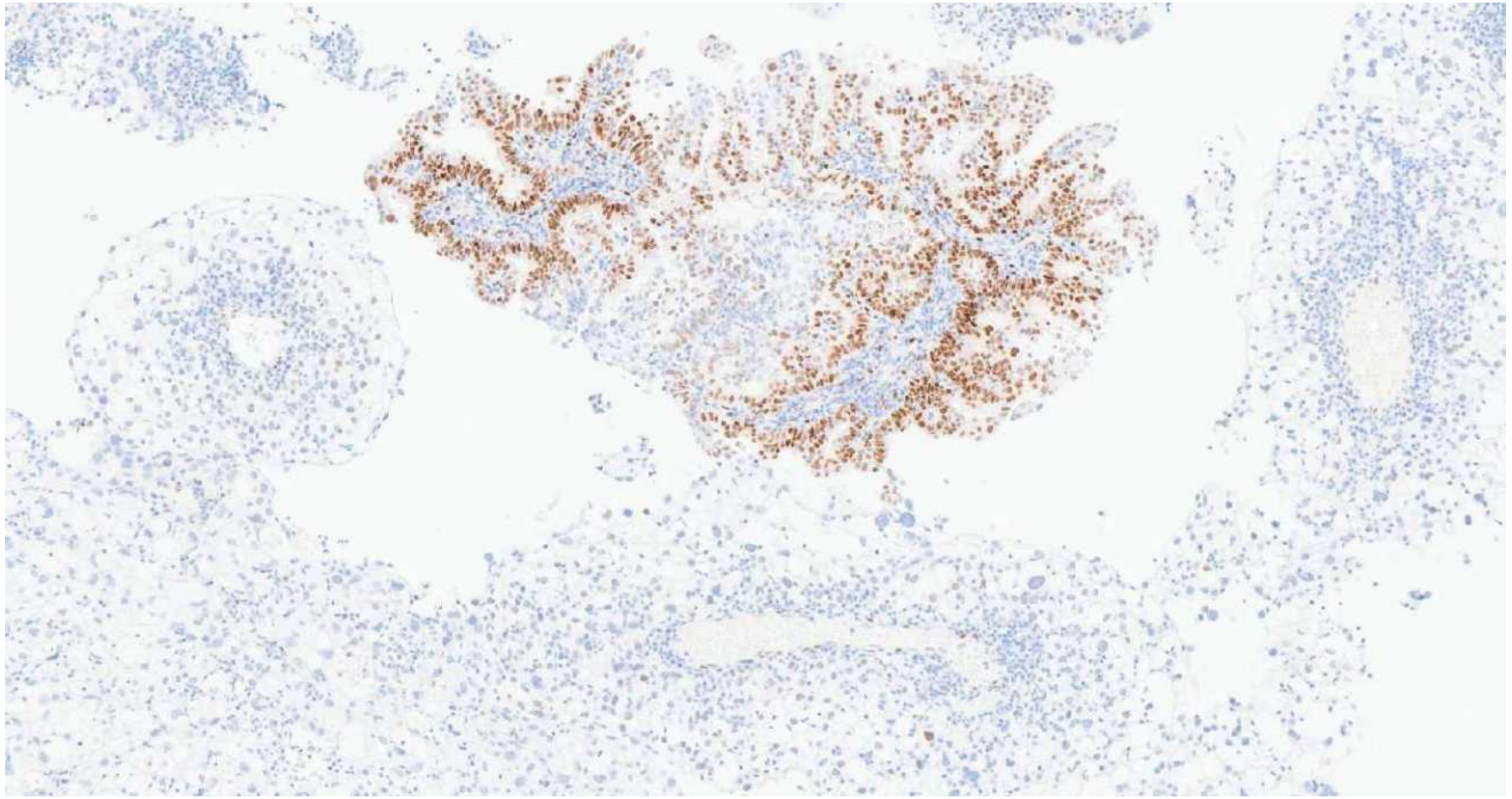

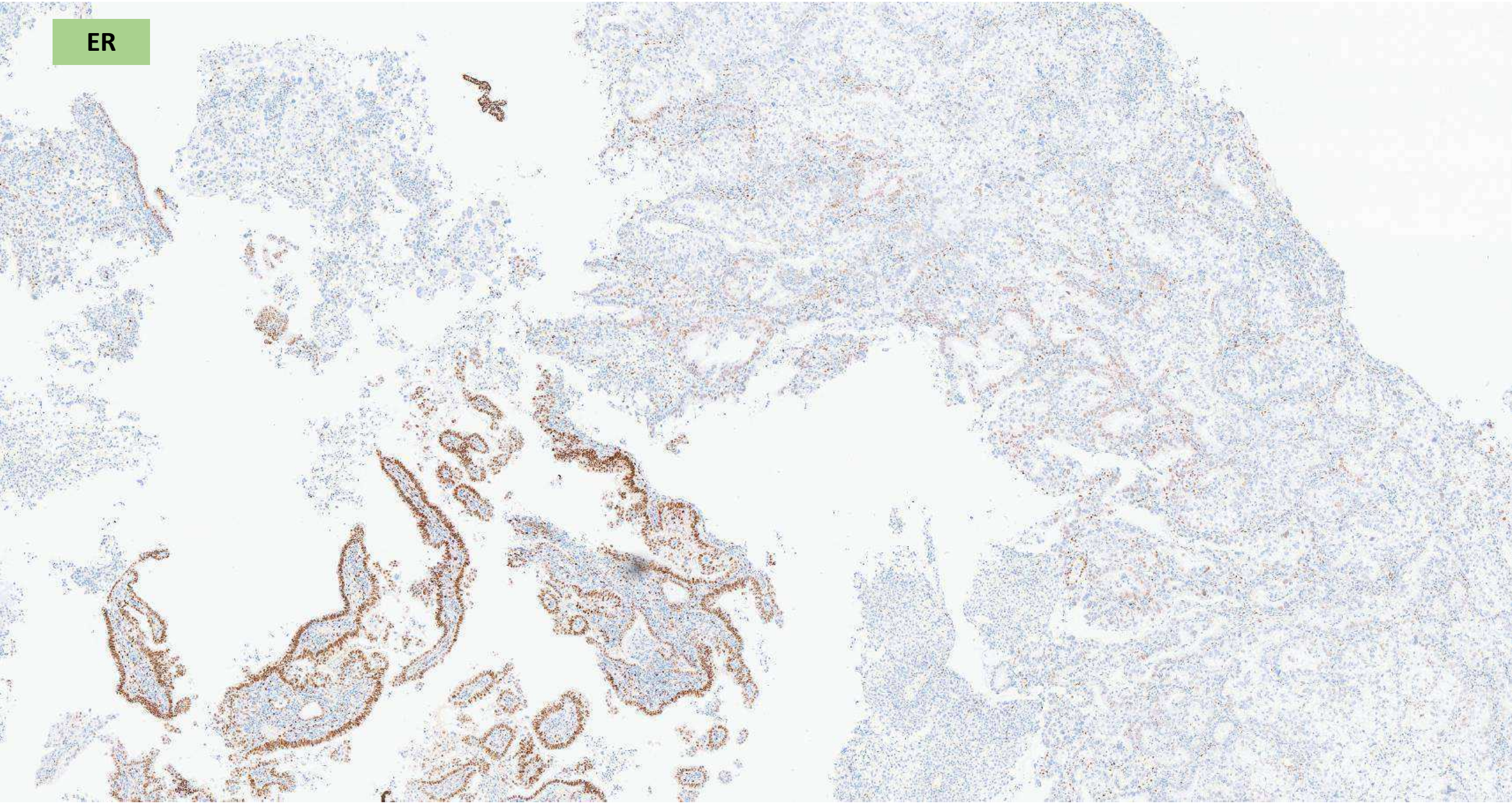
ER

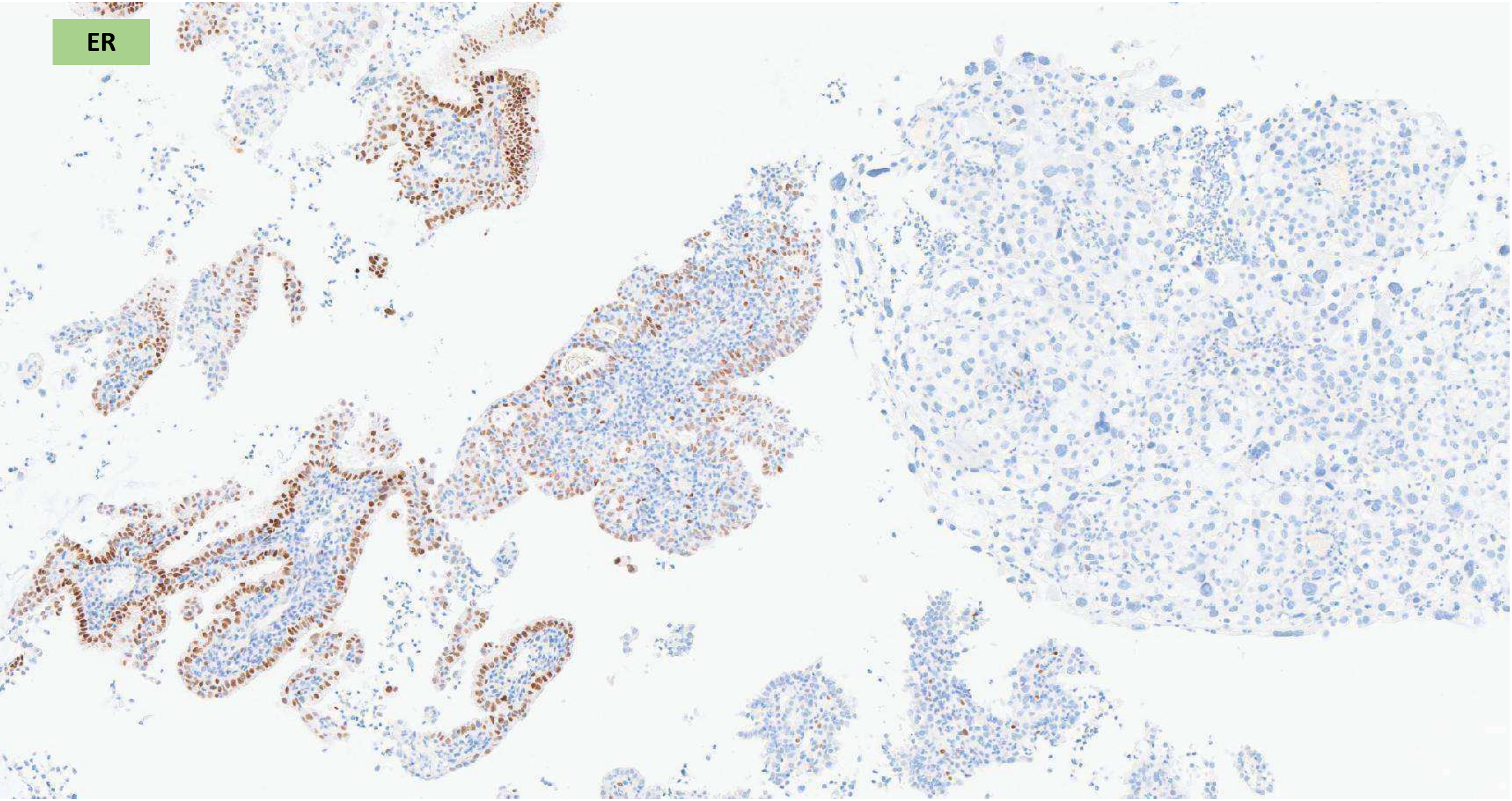
ER

Case 3

- Napsin A

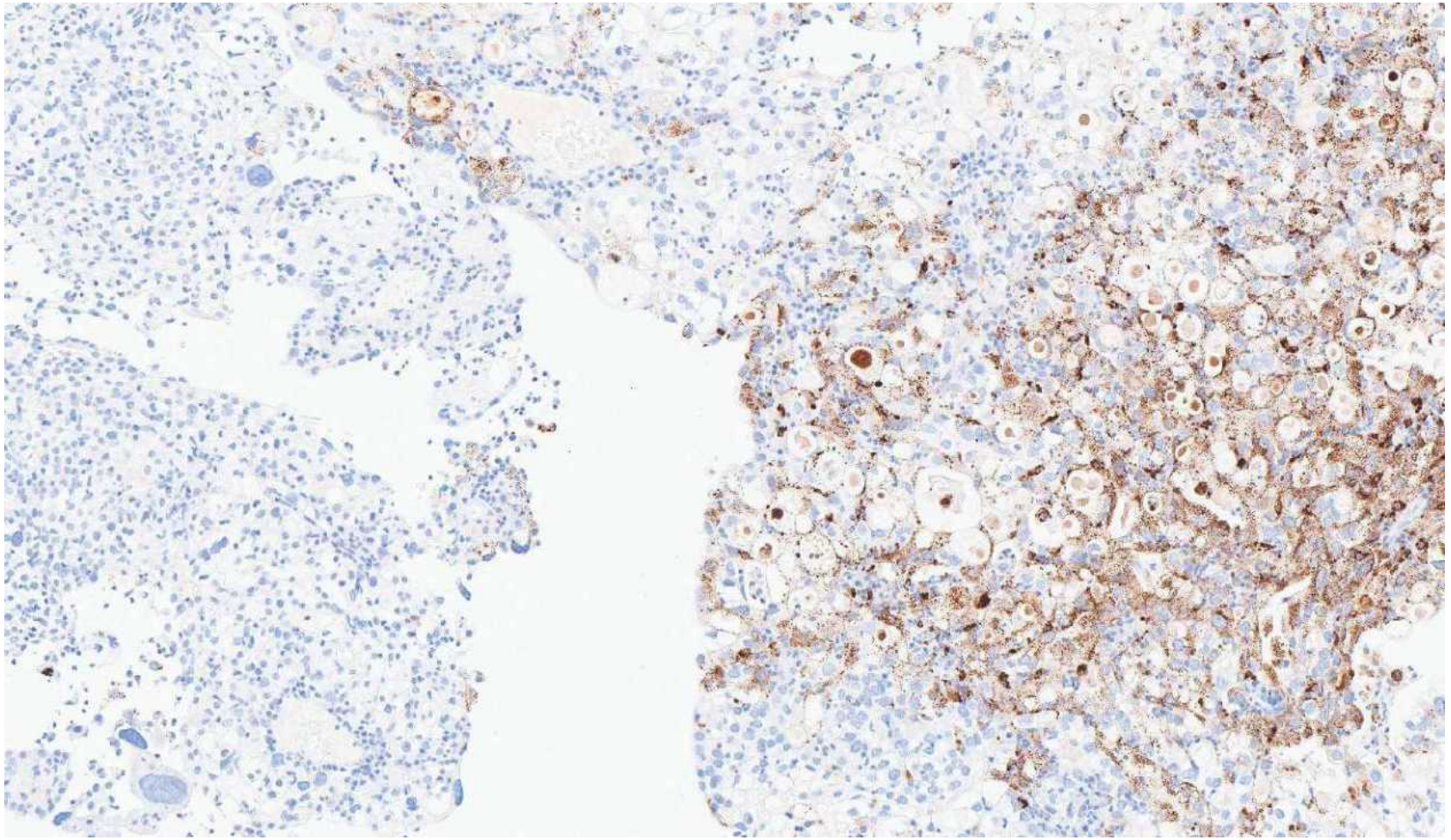

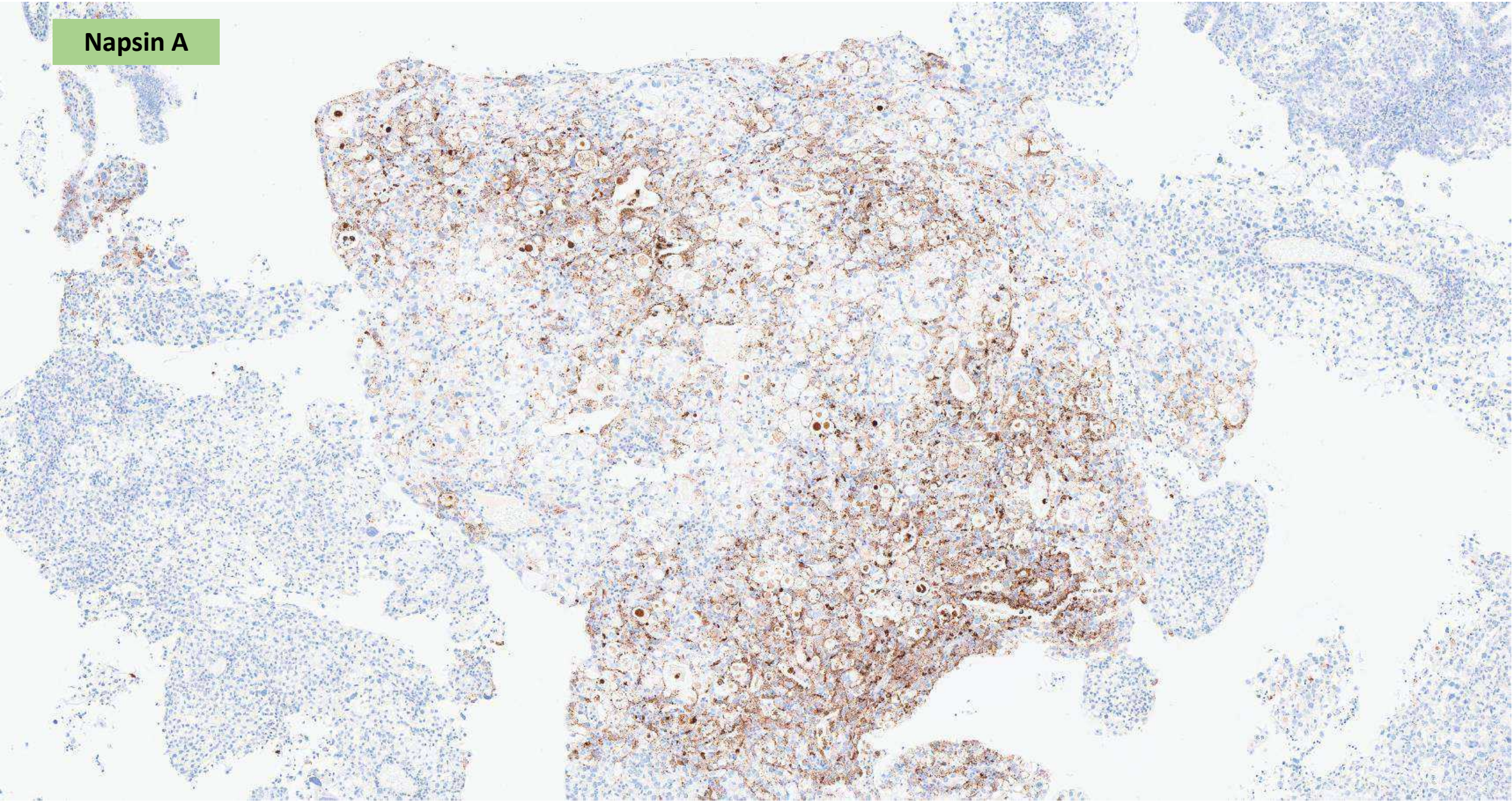
Napsin A

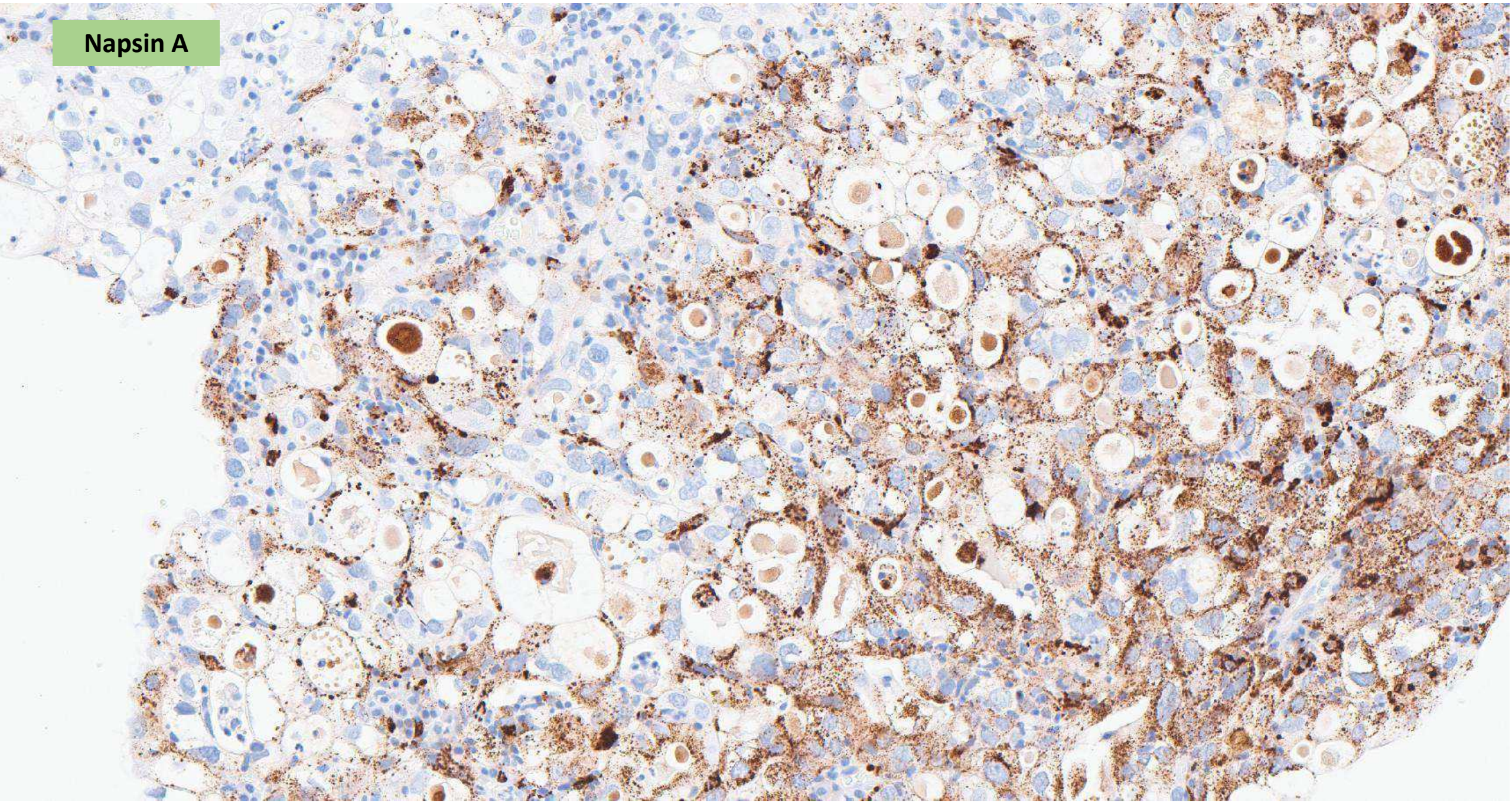
Napsin A

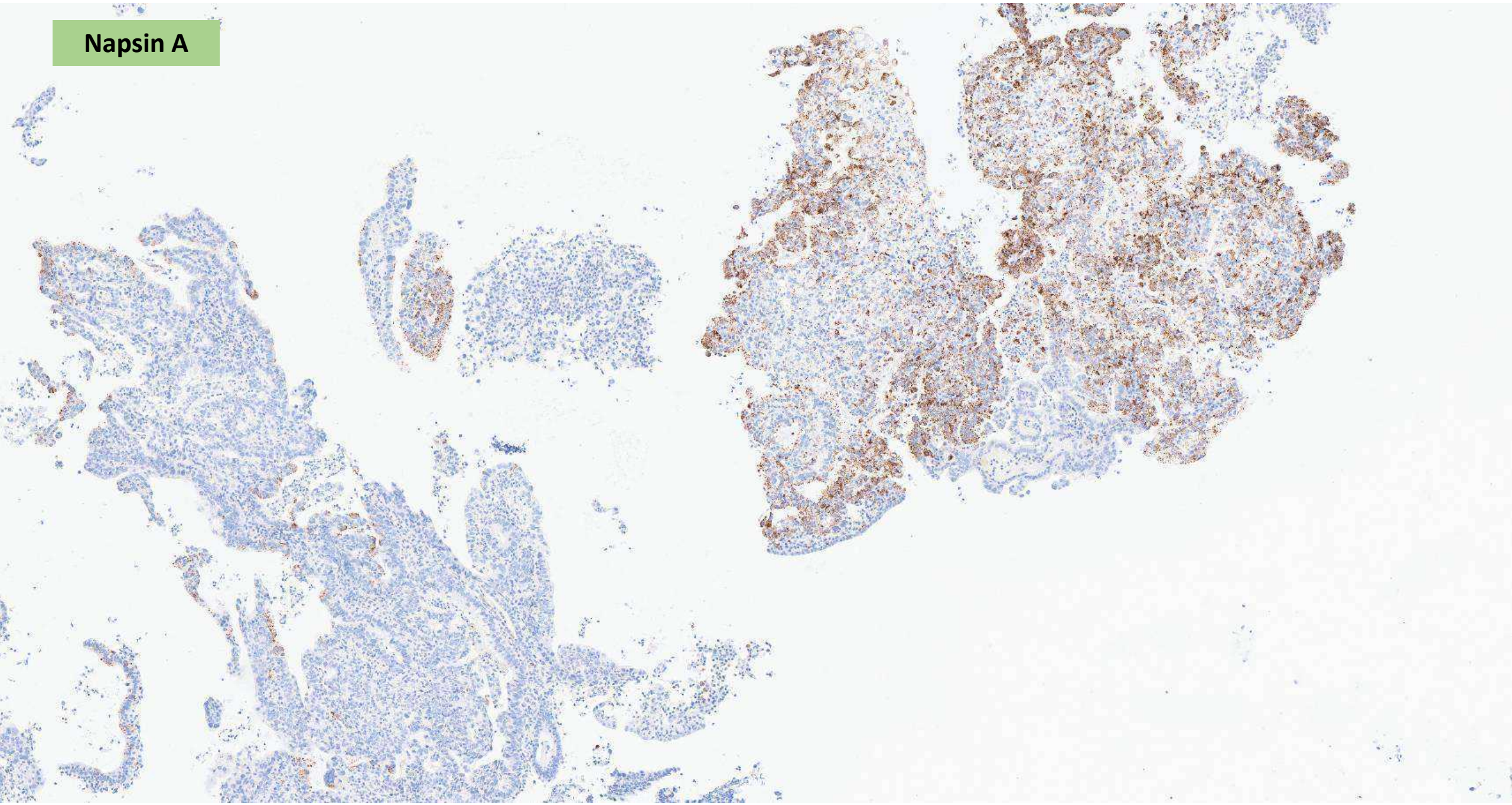
Napsin A

Case 3

- p53

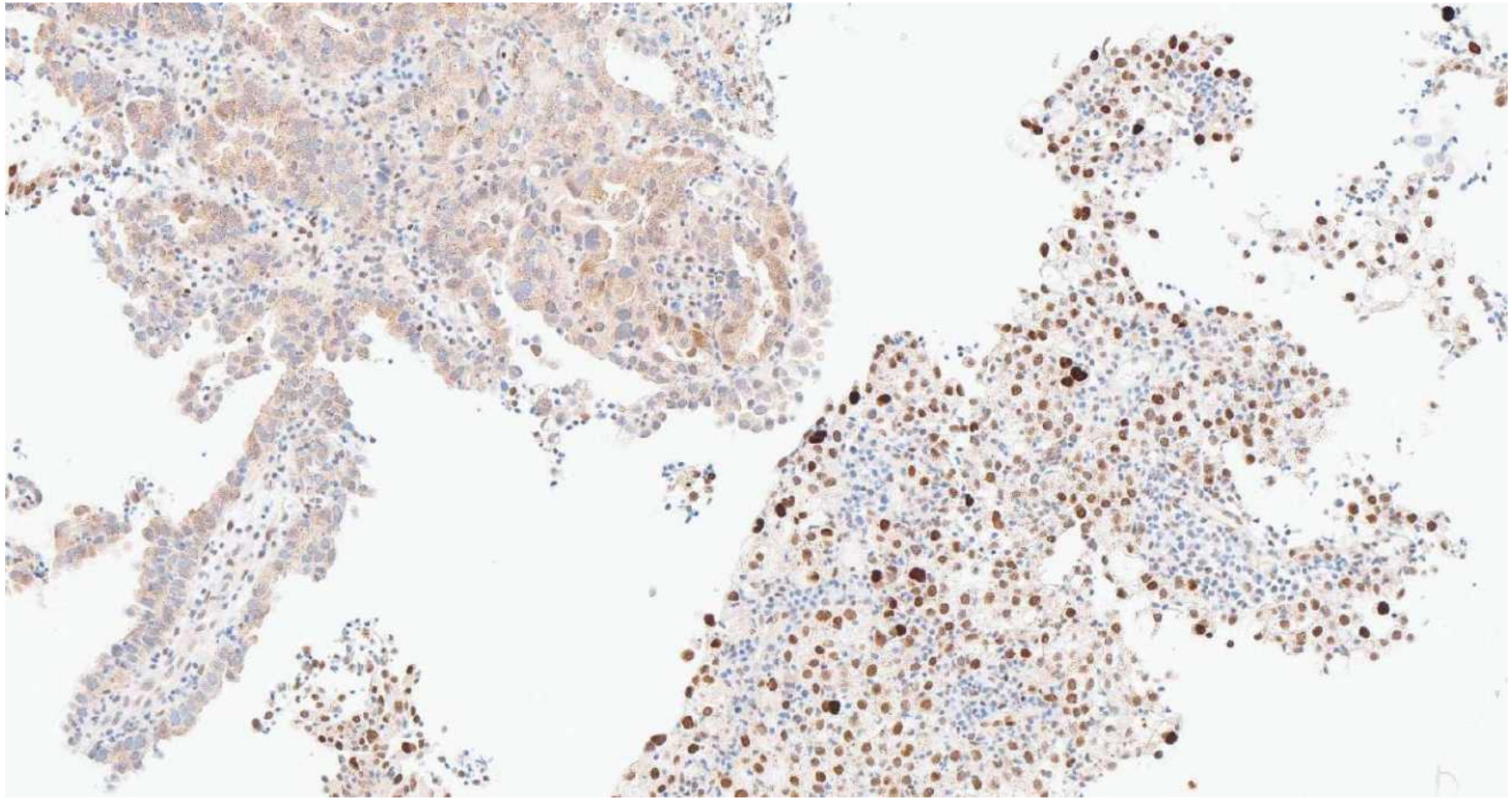

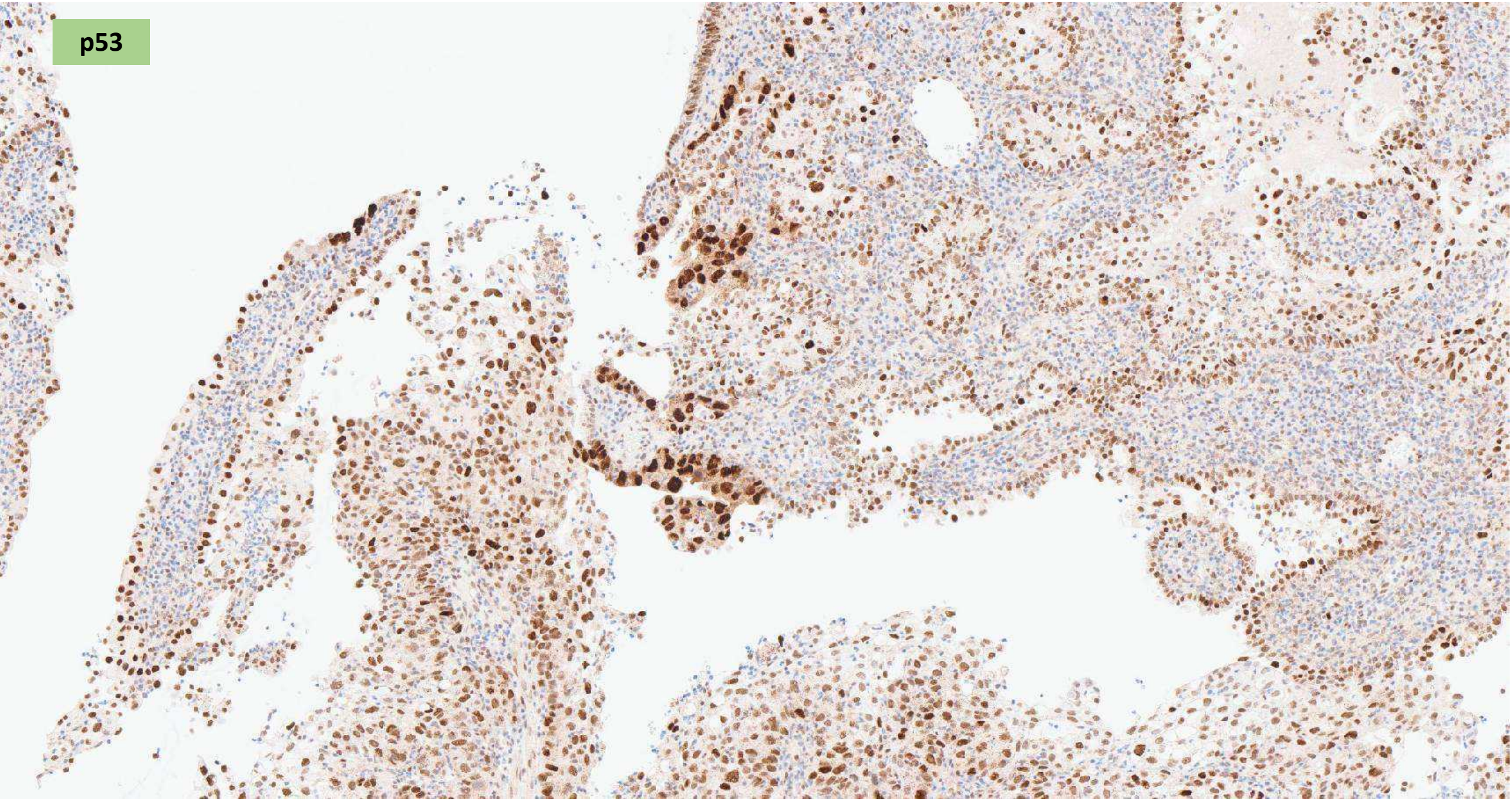
p53

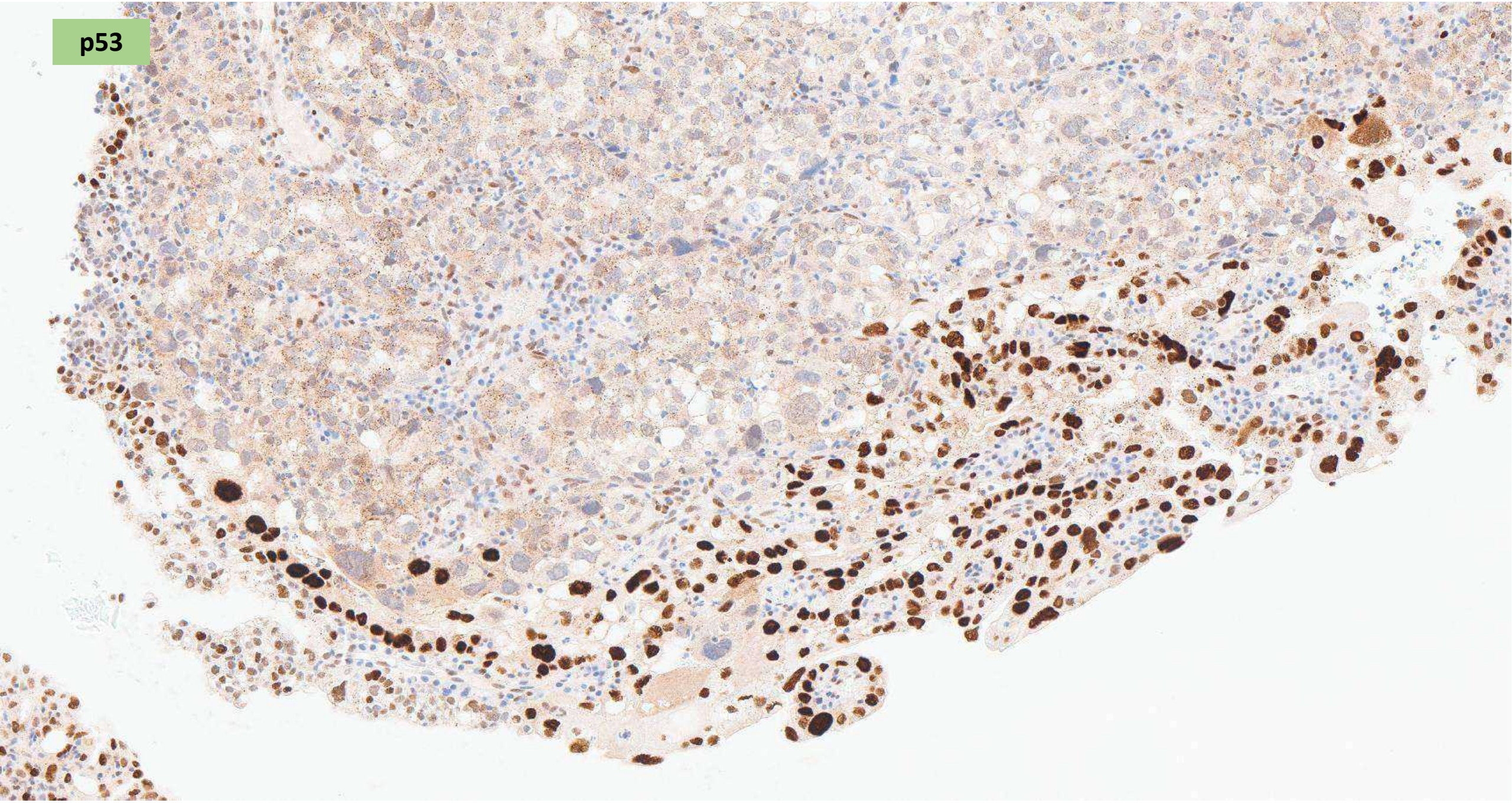
p53

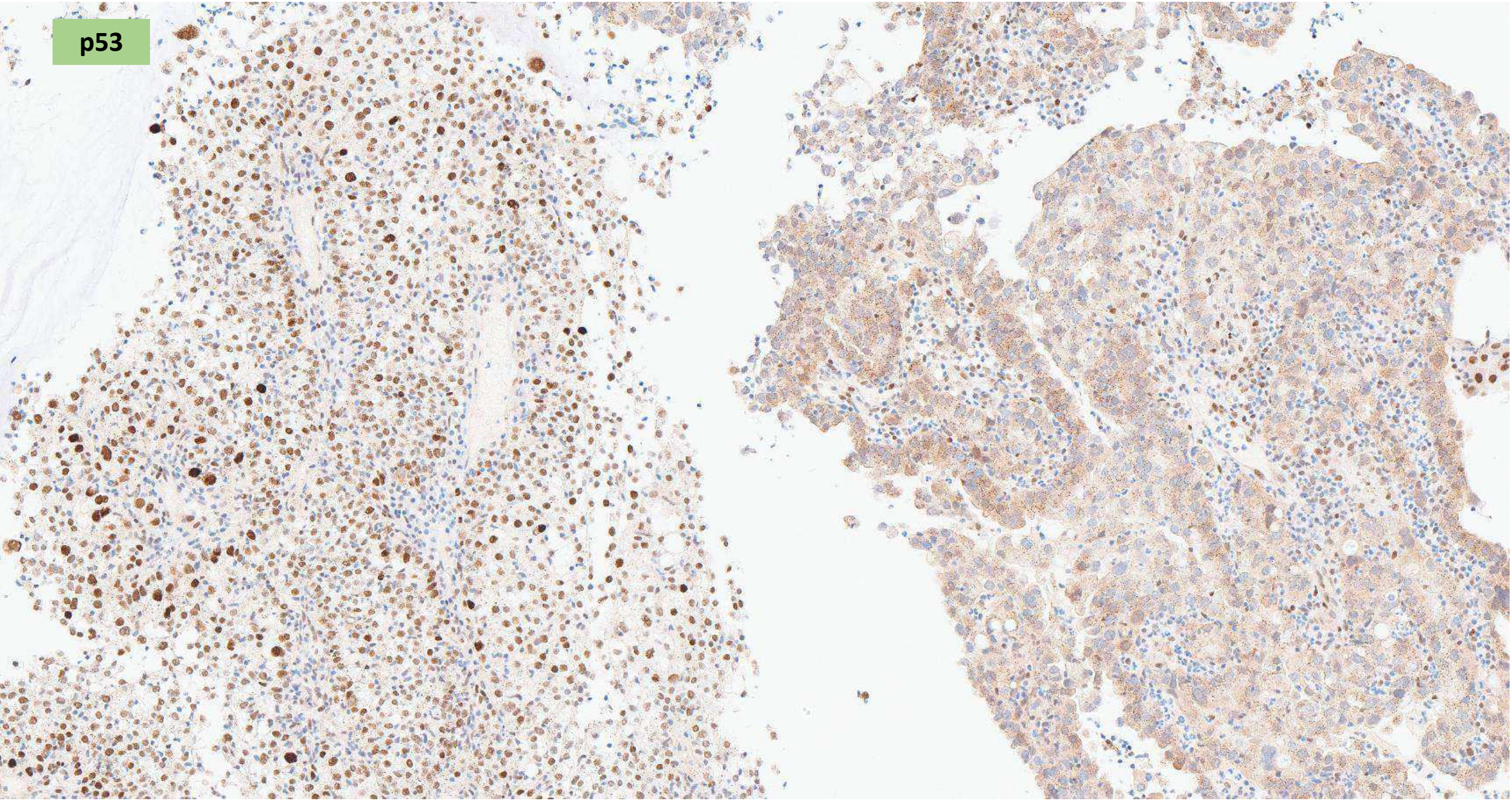
p53

Interpretation of p53 in morphologically heterogenous endometrial carcinomas

- High grade endometrial carcinomas may have areas that suggest different histotypes within the same tumour
- Diagnosis of mixed carcinomas requires 2 or more components that are morphologically and immunohistochemically distinct
- Delineating different components is often difficult especially in the context of endometrial biopsies
- Evaluation of p53 expression patterns could be a real dilemma:
  - Report subclonal/heterogeneous expression in all the tumour areas?
  - Report separate patterns for components of different histotypes?

Most endometrial carcinomas with mixed or ambiguous morphology display uniformly aberrant p53 expression

ORIGINAL ARTICLE

Mixed and Ambiguous Endometrial Carcinomas

A Heterogenous Group of Tumors With Different Clinicopathologic and Molecular Genetic Features

	Dx	Endometriod Component	Nonendometrioid Component	p53	p16
Case 1	Mixed	Grade 1	Low grade (sc)	wt	+
Case 2	Mixed	Grade 1	Low grade (sc)	wt	–
Case 3	Mixed	Grade 2	Grade 3 (sc + sarc)	Aberrant	+
Case 4	Mixed	Grade 1	Grade 3 (un)	wt(end) aberrant(un)	–(end) + (un)
Case 5	Mixed	/	Grade 3 (sc + un)	Aberrant	+
Case 6	Mixed	Grade 3	Grade 3 (sc + sarc + un)	wt(end) aberrant(sc,sarc,un)	–(end) + (sc,sarc,un)
Case 7	Mixed	Grade 3	Grade 3 (sc + sarc)	Aberrant	+
Case 8	Ambiguous	/	/	Aberrant	+
Case 9	Ambiguous	/	/	Aberrant	+
Case 10	Ambiguous	/	/	Aberrant	+
Case 11	Ambiguous	/	/	Aberrant	+
Case 12	Ambiguous	/	/	Aberrant	+
Case 13	Ambiguous	/	/	Aberrant	+
Case 14	Ambiguous	/	/	Aberrant	+
Case 15	Ambiguous	/	/	Aberrant	+
Case 16	Ambiguous	/	/	Aberrant	+
Case 17	Ambiguous	/	/	Aberrant	+
Case 18	Ambiguous	/	/	Aberrant	+
Case 19	Ambiguous	/	/	Aberrant	+
Case 20	Ambiguous	/	/	Aberrant	+

Espinosa I, D'Angelo E, Palacios J, Prat J. Am J Surg Pathol 2016. (PMID: 26975040)

IHC profiles for various components in mixed endometrial carcinomas often do not conform to the expected prototypic staining patterns

Original Article

Despite Diagnostic Morphology, Many Mixed Endometrial Carcinomas Show Unexpected Immunohistochemical Staining Patterns

Case	Diagnosis	Age (yr)	% Components	FIGO Stage	Unexpected IHC
1	G1 EC/SC	59	10% EC, 90% SC	2	p16: diffusely+ in both ER/PR: EC negative
2	G2 EC/SC	57	70% EC, 30% SC	NA	ER/PR: diffusely + in both
3	G2 EC/SC	58	75% EC, 25% SC	3C1	p16: diffusely + in both ER/PR: strongly + in SC Napsin A: weakly + in both
4	G3 EC/SC	54	20% EC, 80% SC	3C2	p16: diffusely + in both ER/PR: strongly + in both
5	G3 EC/SC	81	90% EC, 10% SC	1B	p16: diffusely + in both
6	G3 EC/SC	70	20% EC, 80% SC	3C2	p53: null in both p16: diffusely + in both
7	G1 EC/SC	52	30% EC, 70% SC	2	Expected pattern
8	G2 EC/SC	52	30% EC, 70% SC	3C2	p53: wild-type in both Napsin A: strongly + in SC, very focal + in EC
9	G3 EC/SC	63	90% EC, 10% SC	1A	Expected pattern
10	SC/CC	95	40% SC, 60% CC	4B	p53: diffusely + in both p16: CC negative Napsin A: CC negative
11	SC/CC	83	80% SC; 20% CC	3C1	p53: diffusely + in both p16: negative in CC
12	SC/CC	76	70% SC, 30% CC	4B	p53: diffusely + in both
13	SC/CC	76	50% SC, 50% CC	4B	p53: diffusely + in both Napsin A: patchy + in both
14	G3 EC/CC	71	70% EC, 30% CC	3C1	Napsin A: negative in CC
15	G2 EC/CC	66	60% EC, 40% CC	3A	ER/PR: strong + in CC
16	SC/CC/G1 EC	71	50% SC, 20% EC 30% CC	NA	ER: all positive PR: SC positive Napsin A: all negative
17	SC/CC/G1 EC	88	50% SC, 10% EC 40% CC	NA	p53: CC/SC diffusely + in both p16: SC focal + ER: at least focal + in all Napsin A: all negative
18	SC/CC/G2 EC	81	25% SC, 25% EC 50% CC	3A	p16: SC focal + ER/PR: all negative Napsin A: all negative

Matrai CE, Pirog EC, Ellenson LH. Int J Gynecol Pathol 2018. (PMID: 29019871)

Subclonal p53 expression in endometrial carcinomas

- Definition of subclonal p53 expression (Huvila et al 2023):
  - abrupt transition between wild-type and mutant-pattern staining
- Prevalence of subclonal p53 in endometrial carcinomas: 4.0 – 6.6%

Reference	Cases with subclonal p53	Molecular subtype for cases with subclonal p53
Vermij et al. 2022	27/408 cases (6.6%)	9 POLEmut, 13 MMRd, 2 p53abn, 3 NSMP
Huvila et al. 2023	38/957 cases (4.0%)	9 POLEmut, 13 MMRd, 11 p53abn, 5 NSMP

- A 10% cutoff is recommended for molecular subtype designation:
  - Excluding POLEmut and MMRd cases (i.e. multiple-classifier), a tumour with subclonal p53 $\geq$10% would be classified as p53 abnormal, while one with subclonal p53 <10% would be classified as NSMP
  - Supported by clinical outcome data in the study by Huvila et al.

Vermij L, Léon-Castillo A, Singh N, et al. Mod Pathol 2022. (PMID: 35752743)
Huvila J, Thompson EF, Vanden Broek J, et al. Histopathology 2023. (PMID: 37580913)

Case 3 – Morphological heterogeneity

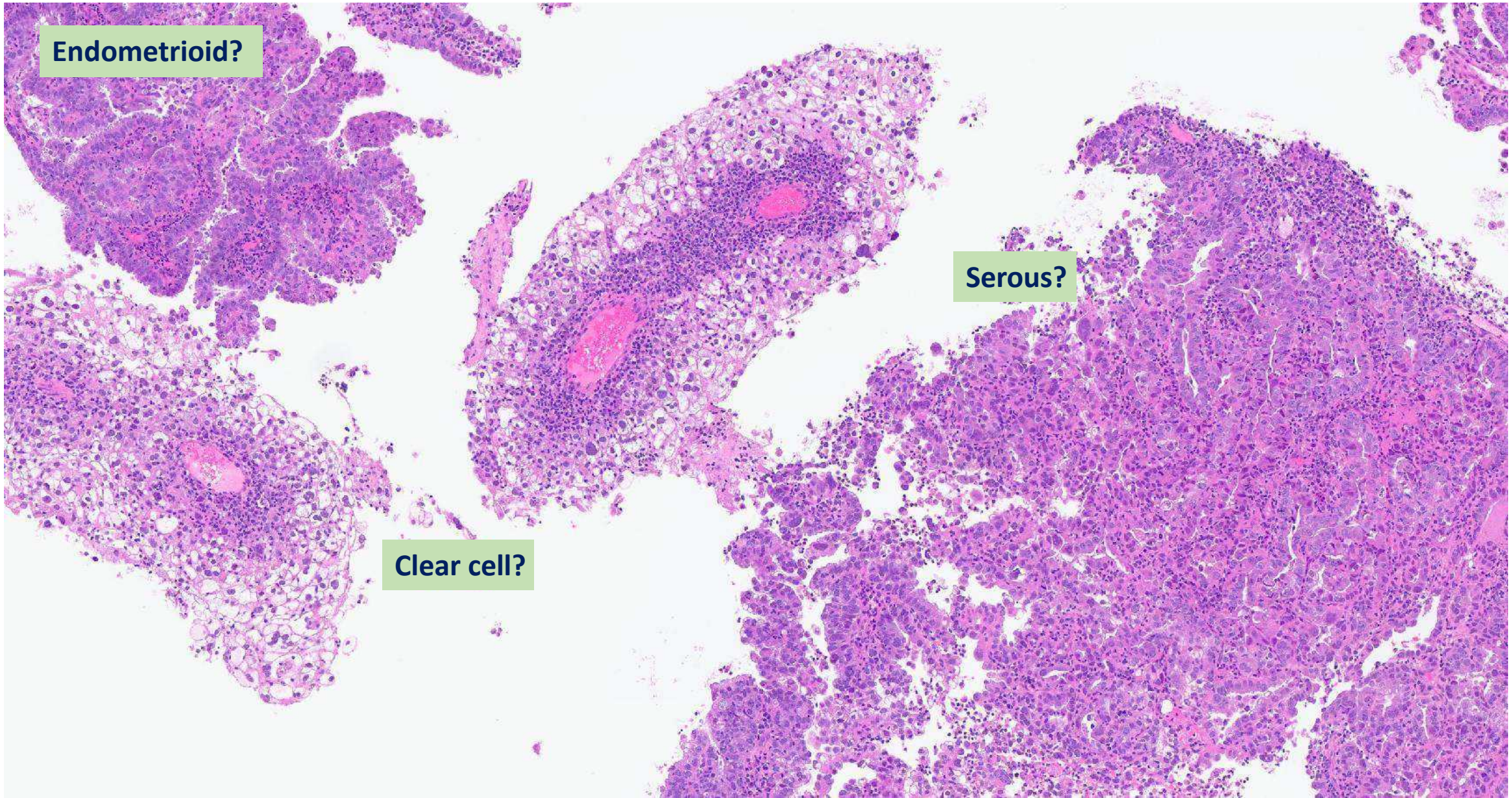

Case 3 – p53 IHC

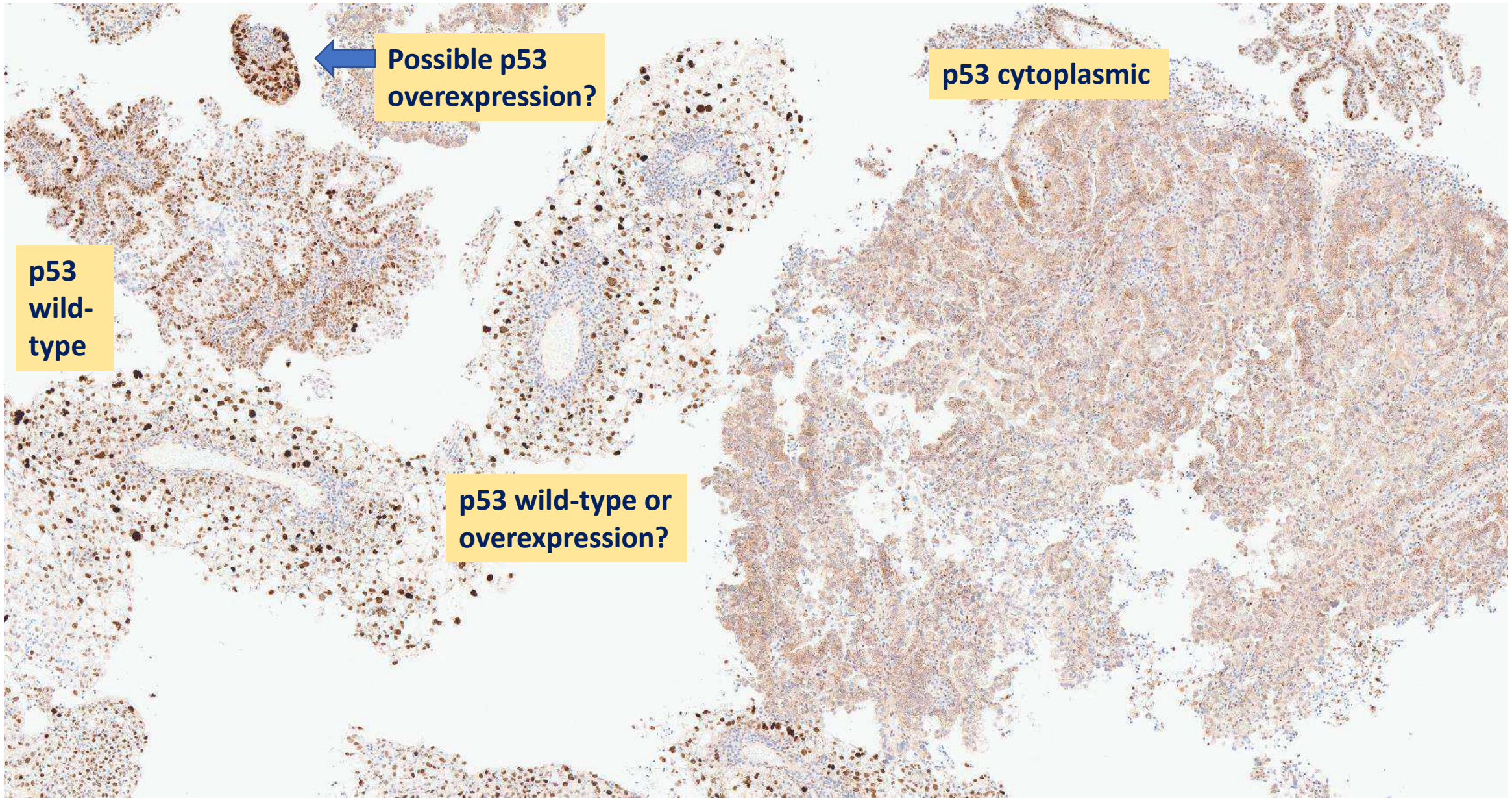

Case 3 – ER IHC

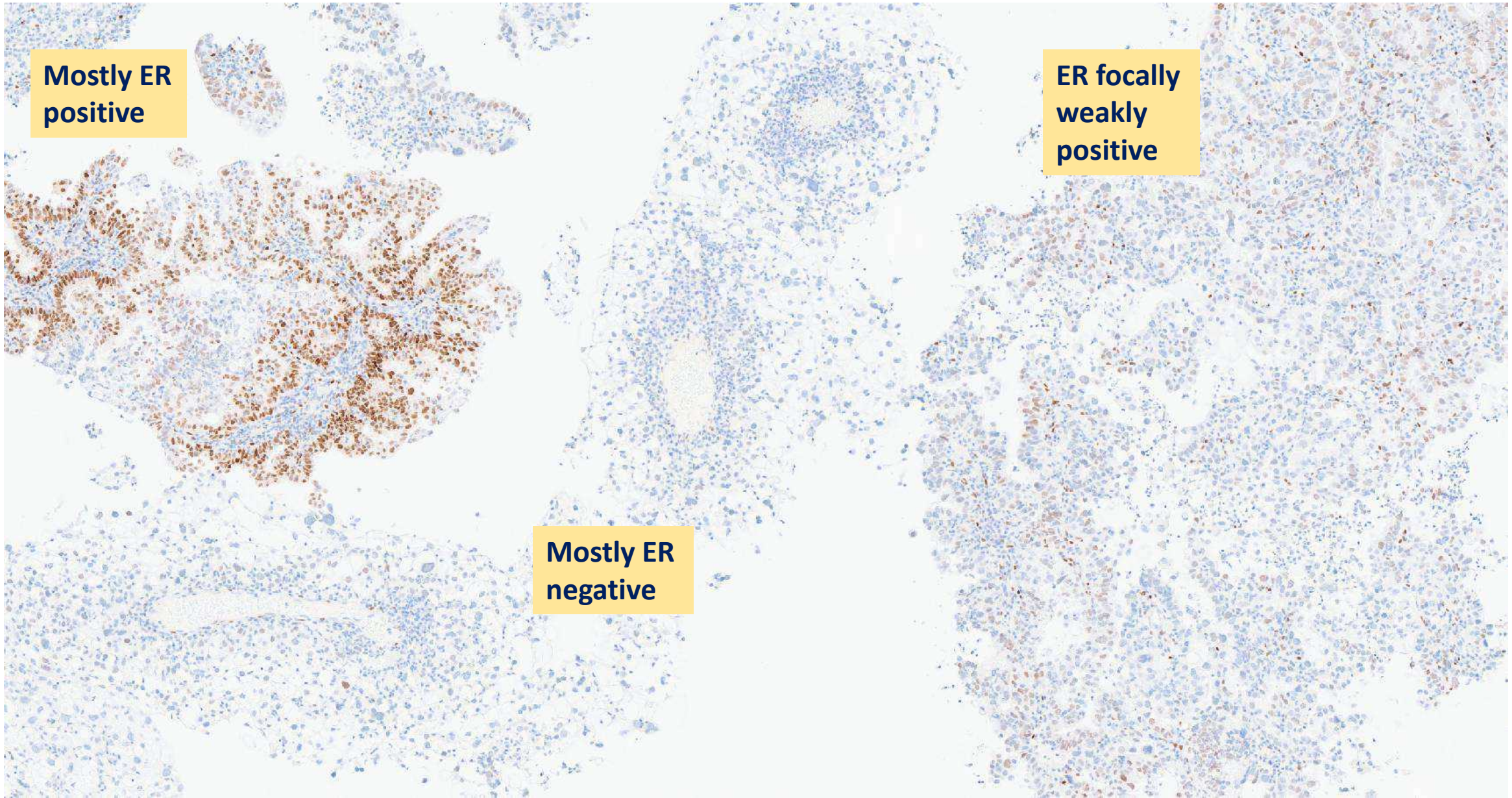
Mostly ER positive
ER focally weakly positive
Mostly ER negative

Case 3 – Napsin A IHC

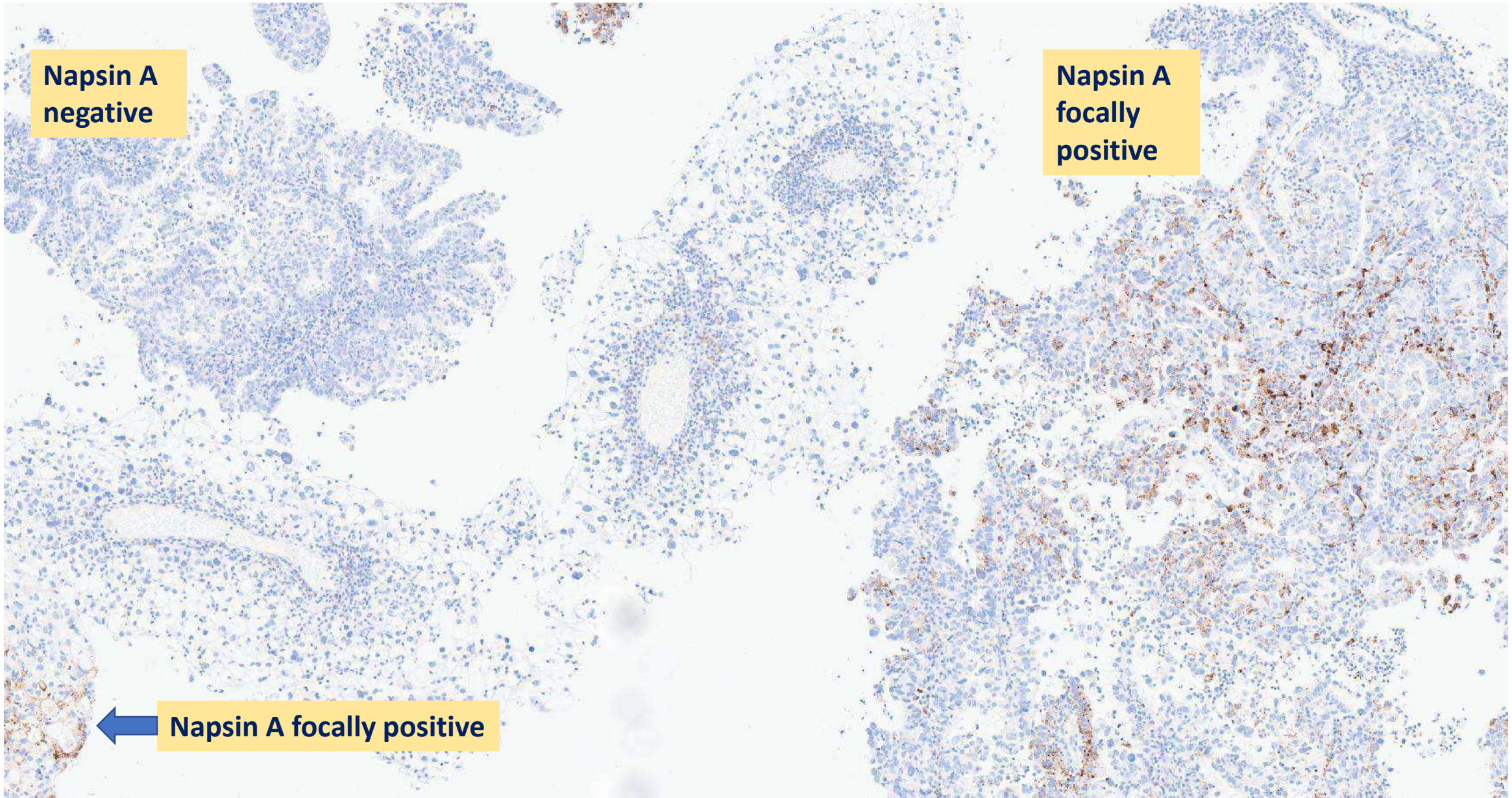

Case 3 – Morphological heterogeneity

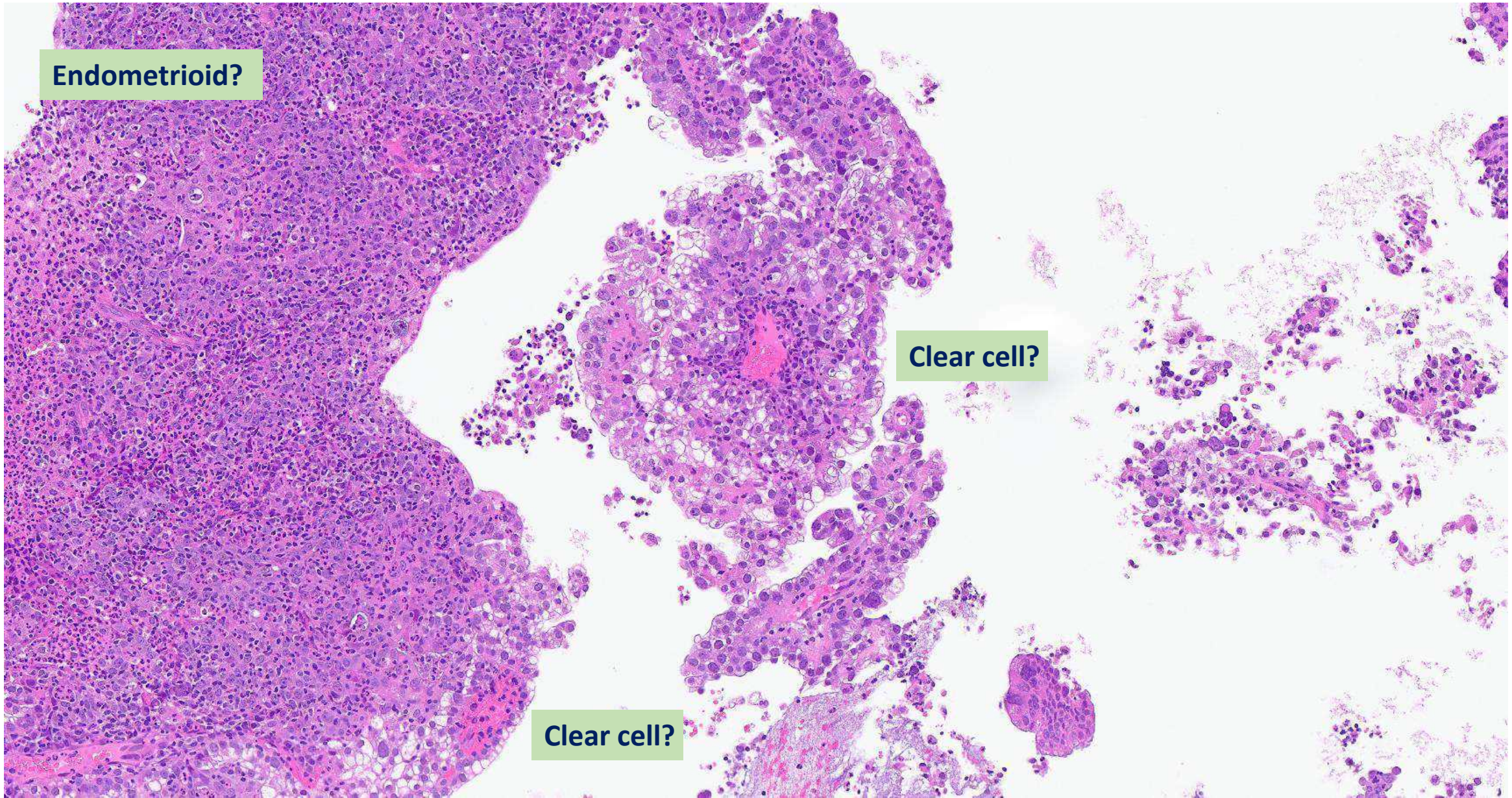

Case 3 – p53 IHC

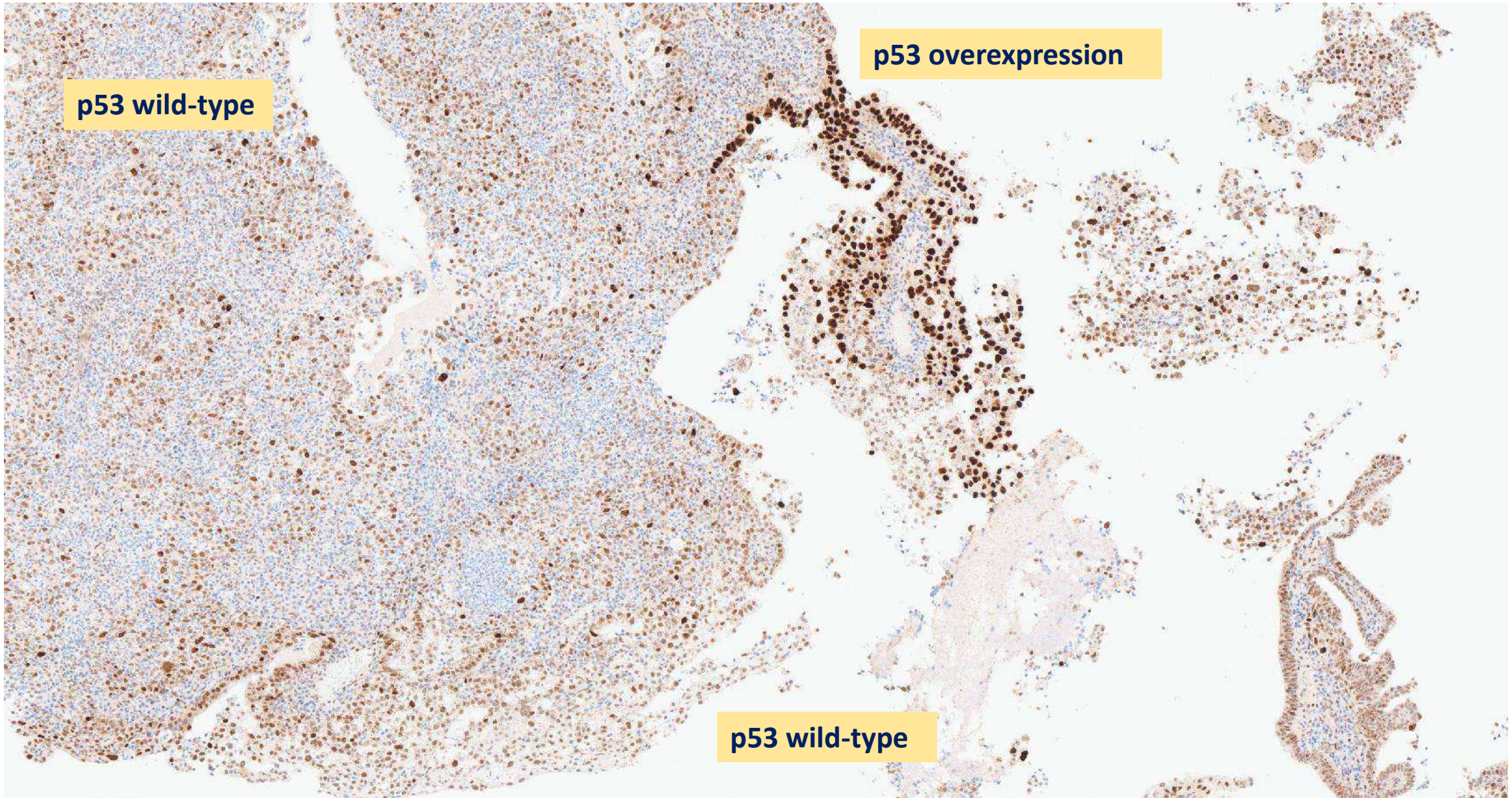

Case 3 – Interpretation

- Heterogenous areas of endometrioid, clear cell and serous morphology
- No clear demarcation of the various components by IHC
- ER and Napsin A focally positive
- p53 shows mostly wild-type expression with subclonal abnormal expression (cytoplasmic and overexpression)
- Diagnosis: High grade endometrial adenocarcinoma
  - p53 subclonal by IHC
  - Molecular subtype designation pending MMR IHC and *POLE* testing

Case 4

- 43 years old
- Abnormal uterine bleeding
- Hysteroscopy and curettage performed

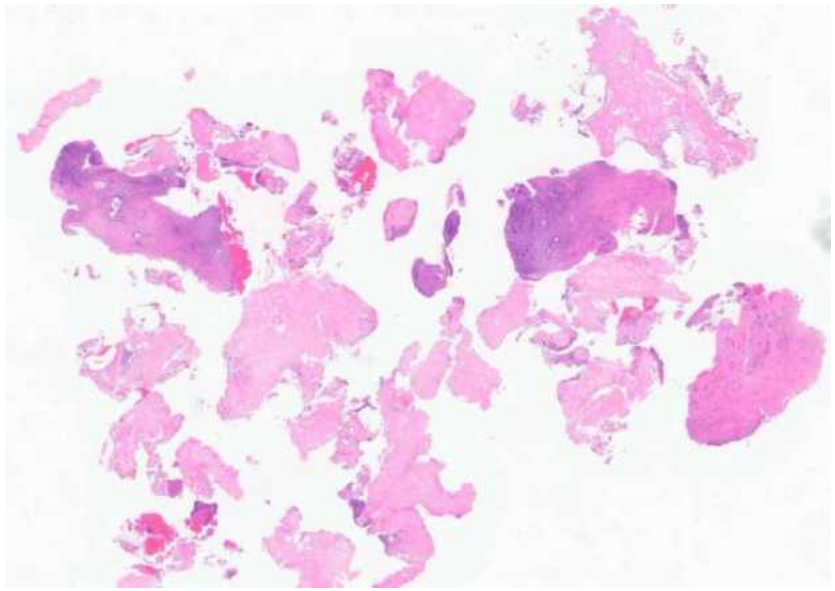
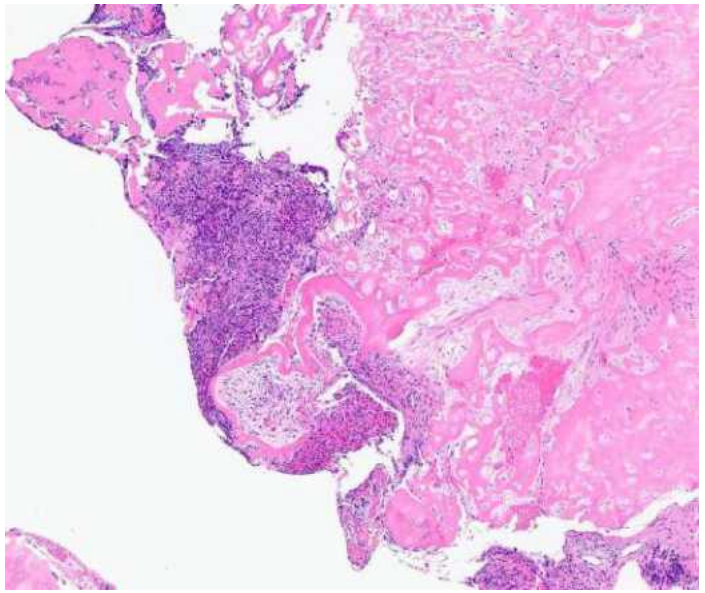
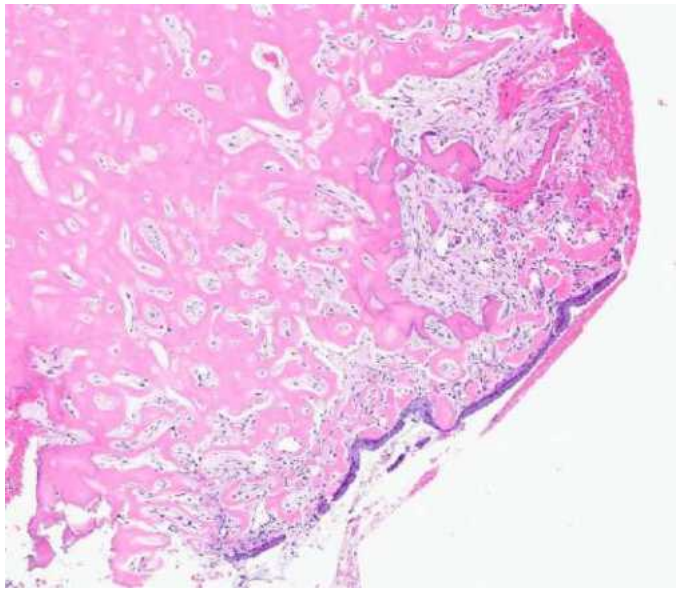

22AH1348-H&E

Case 4

- p53

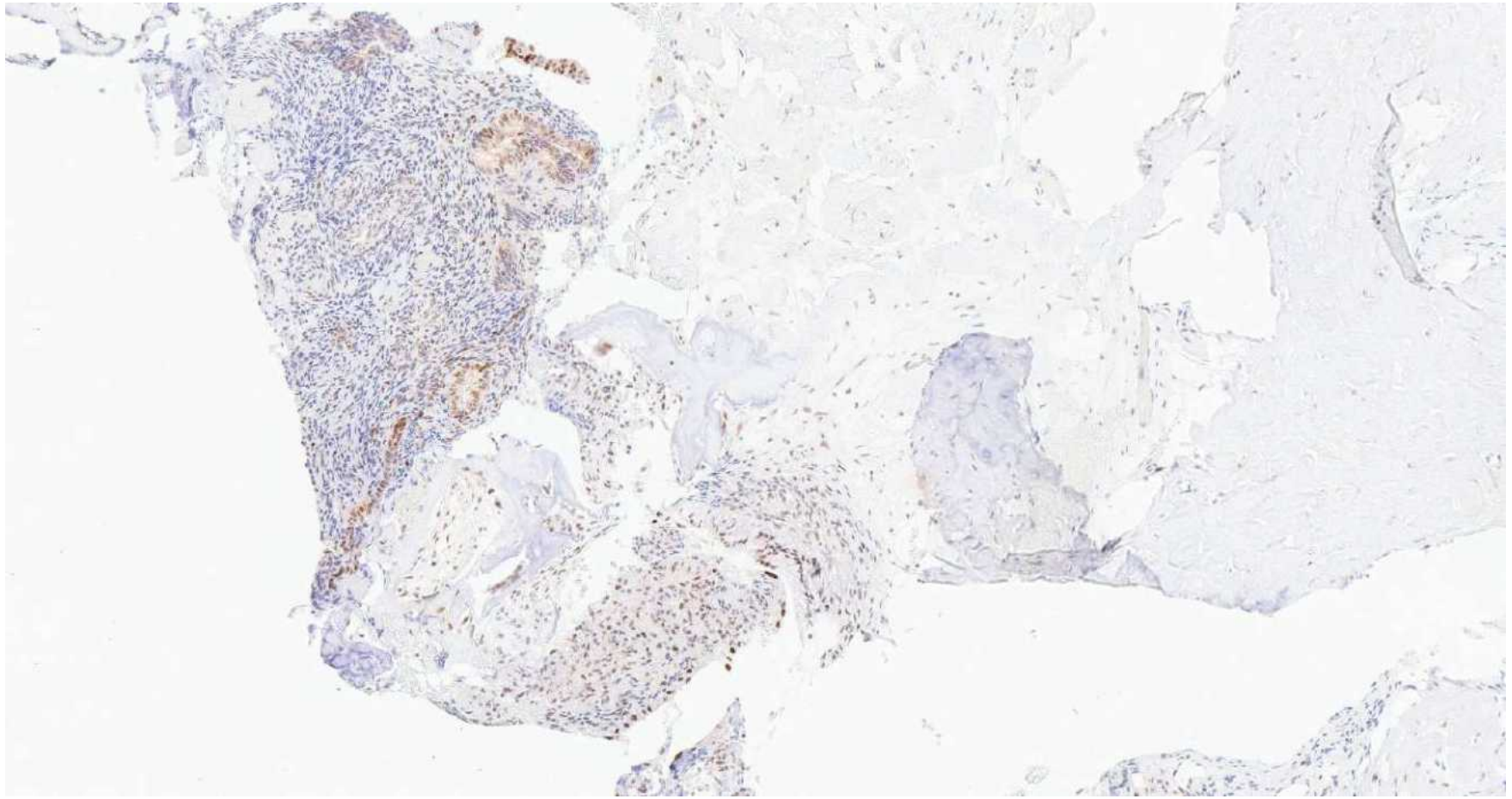

Case 4

- SATB2

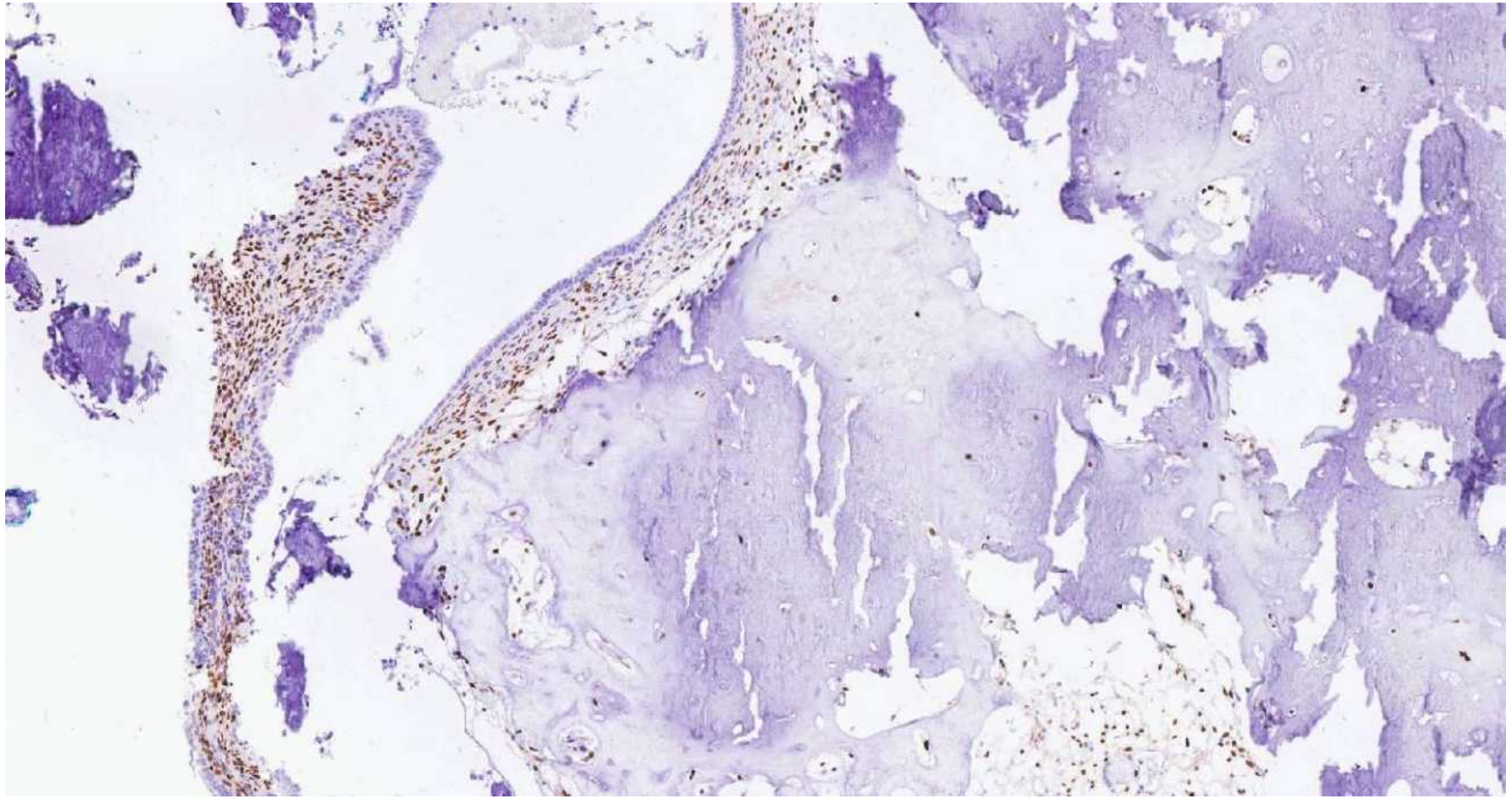

Case 4

- Curettage specimen reported as “bone-forming lesion”, with the differentials including mixed endometrial-endocervical polyp with osseous metaplasia and mesenchymal tumour with heterologous bone formation

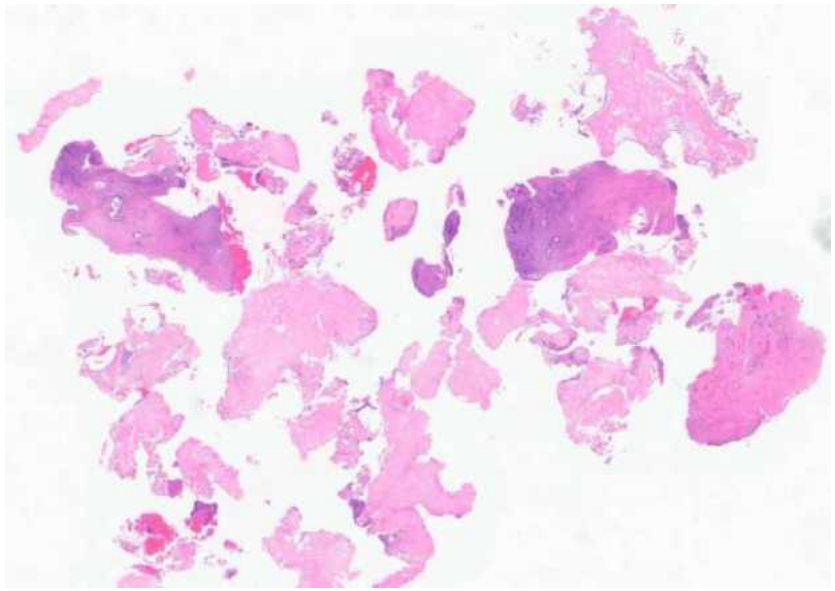
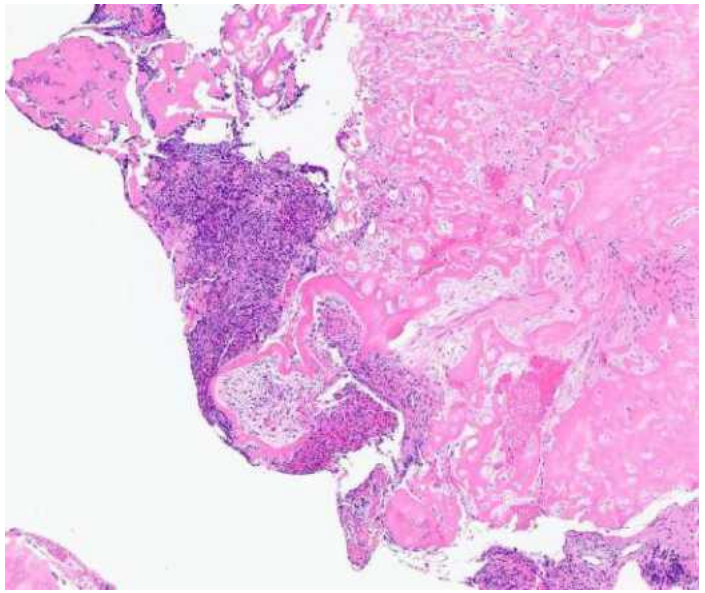
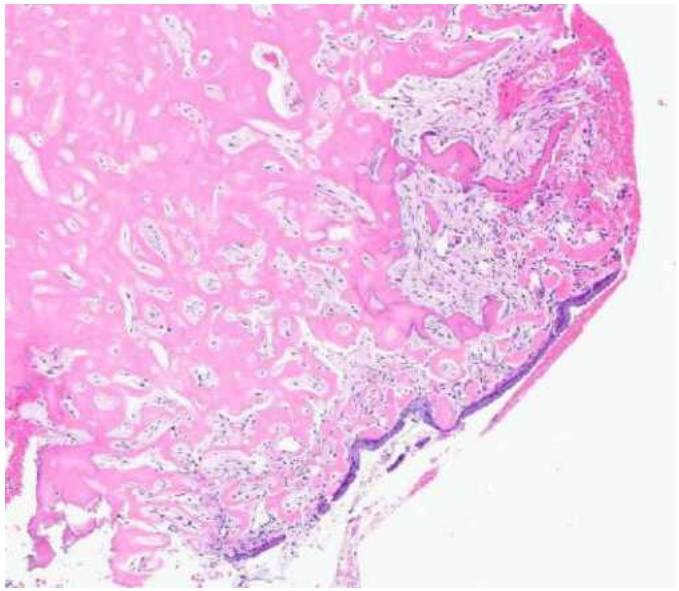

Case 4

- Total hysterectomy and bilateral salpingectomy performed
  - Bony hard mass with irregular surface measuring 3.8 cm, involving the endocervix and lower uterine segment
  - Focal small nodular areas in the endometrium
  - Both tubes appear normal



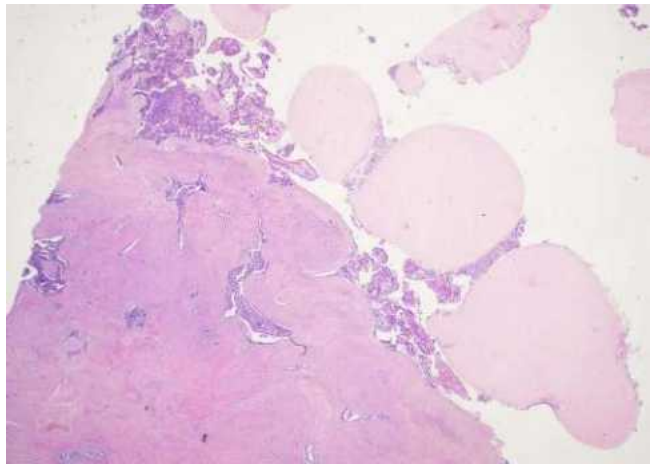
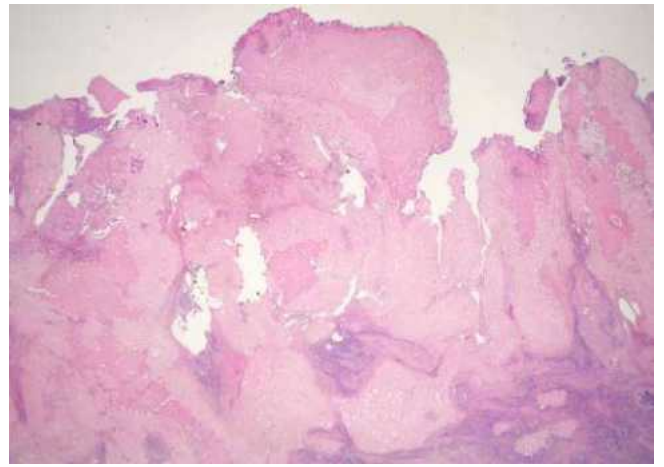

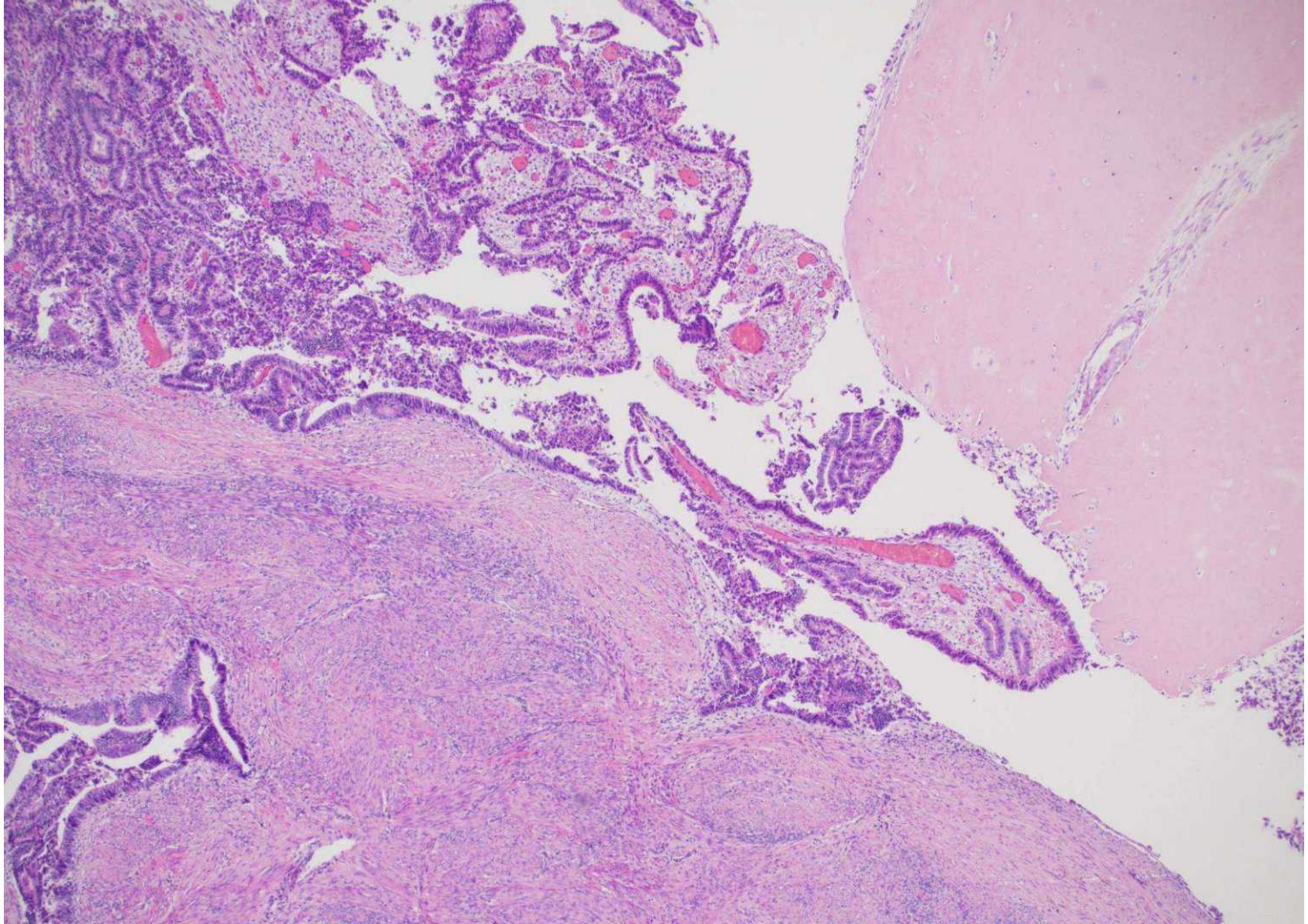

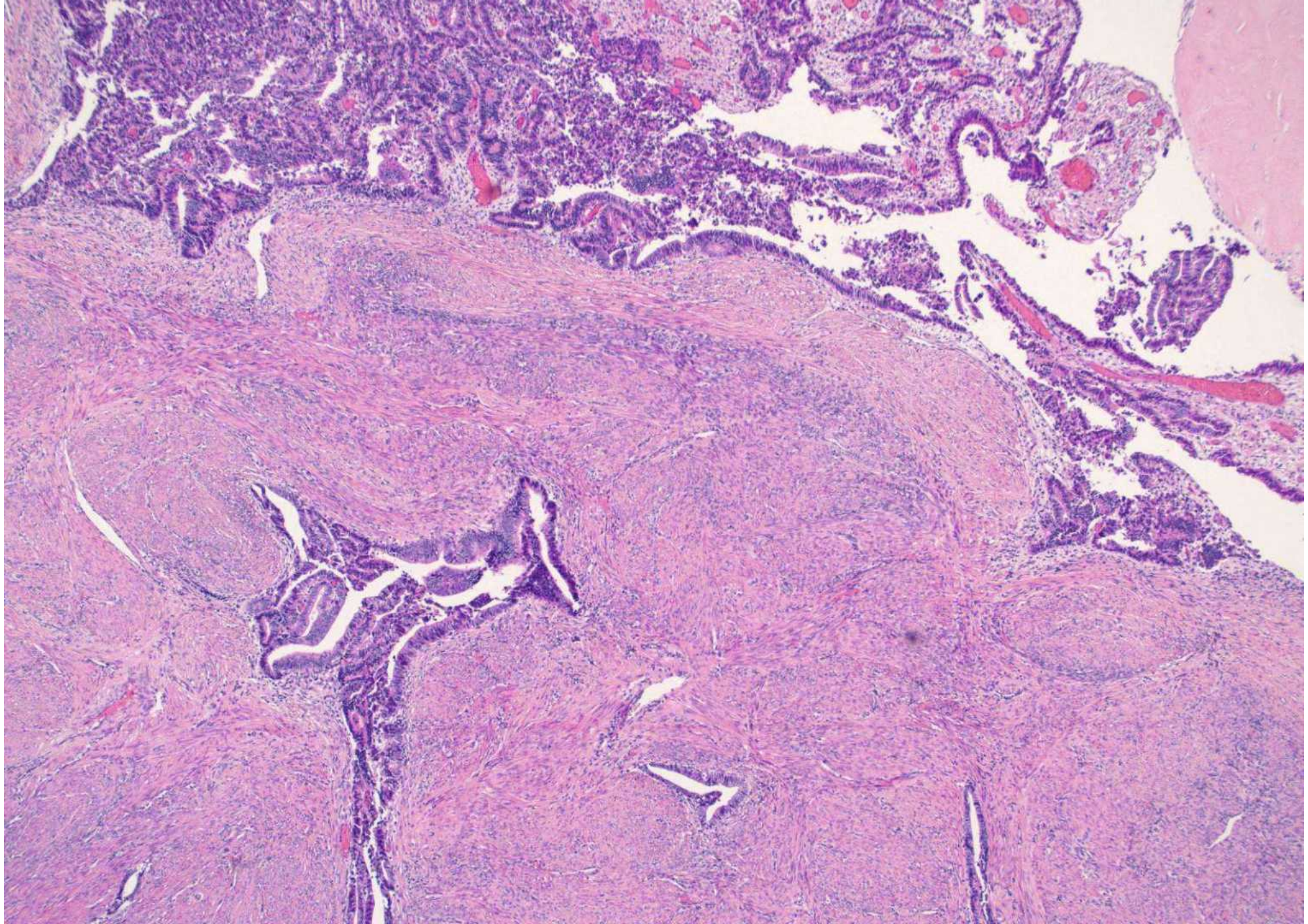

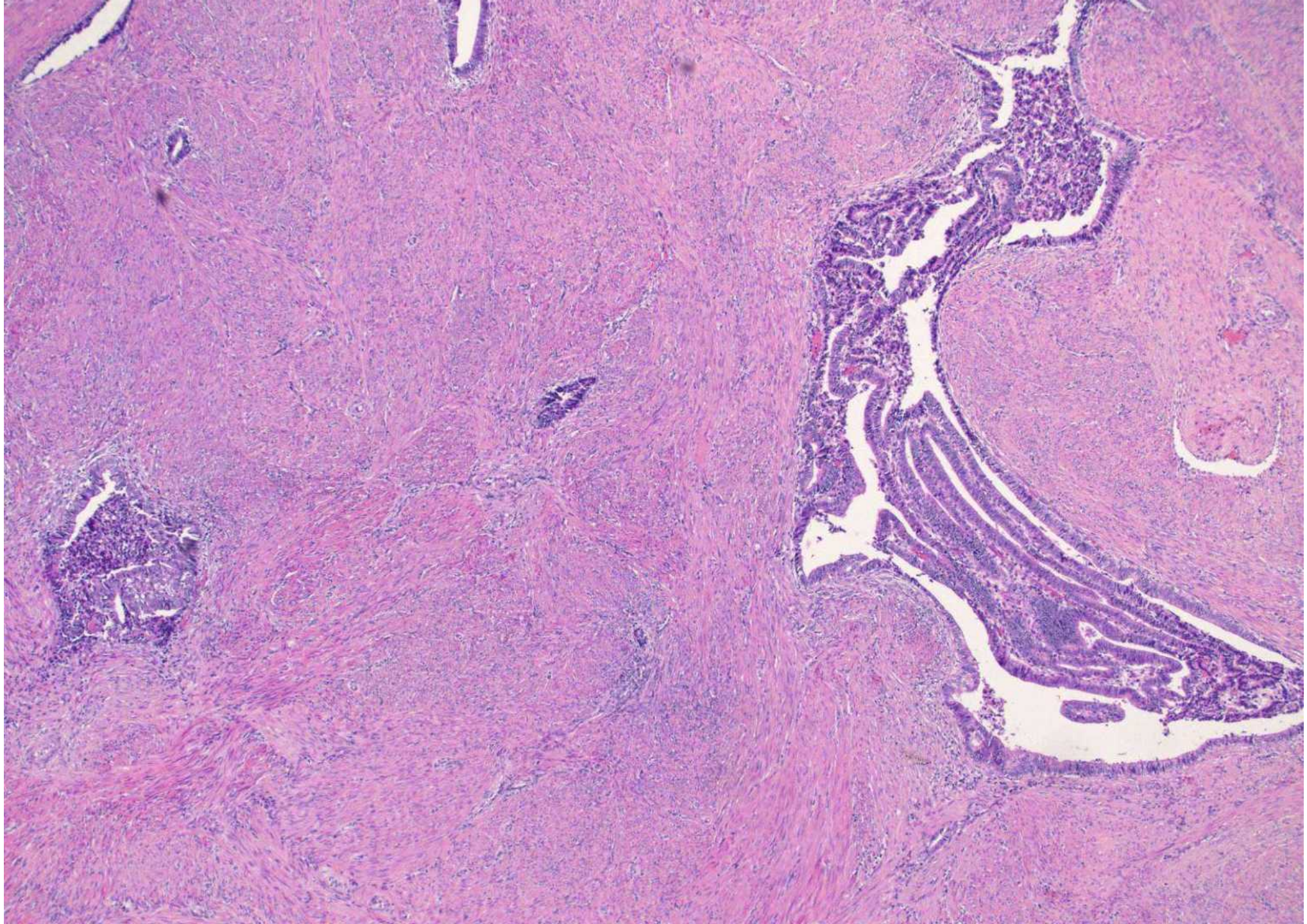

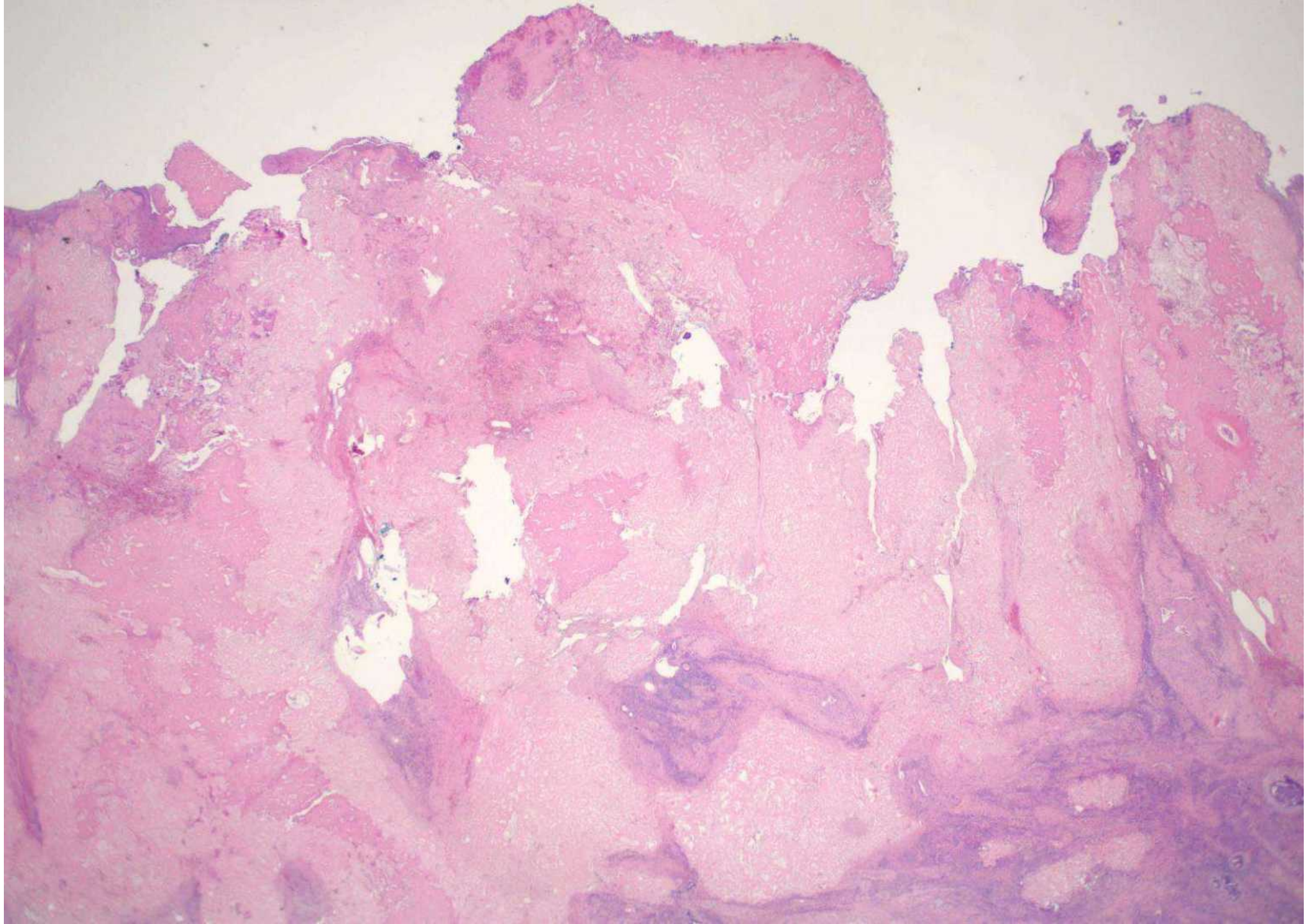

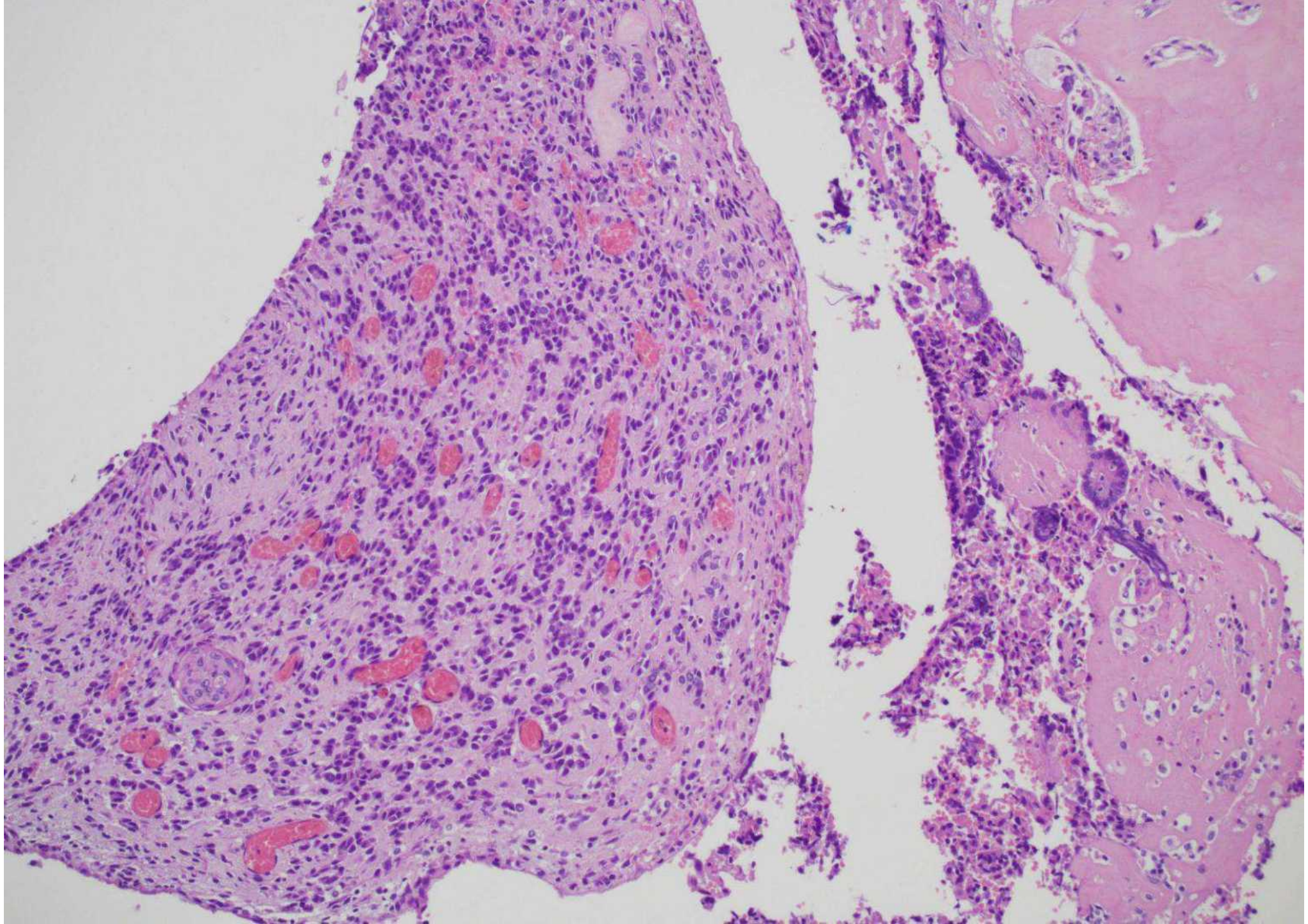

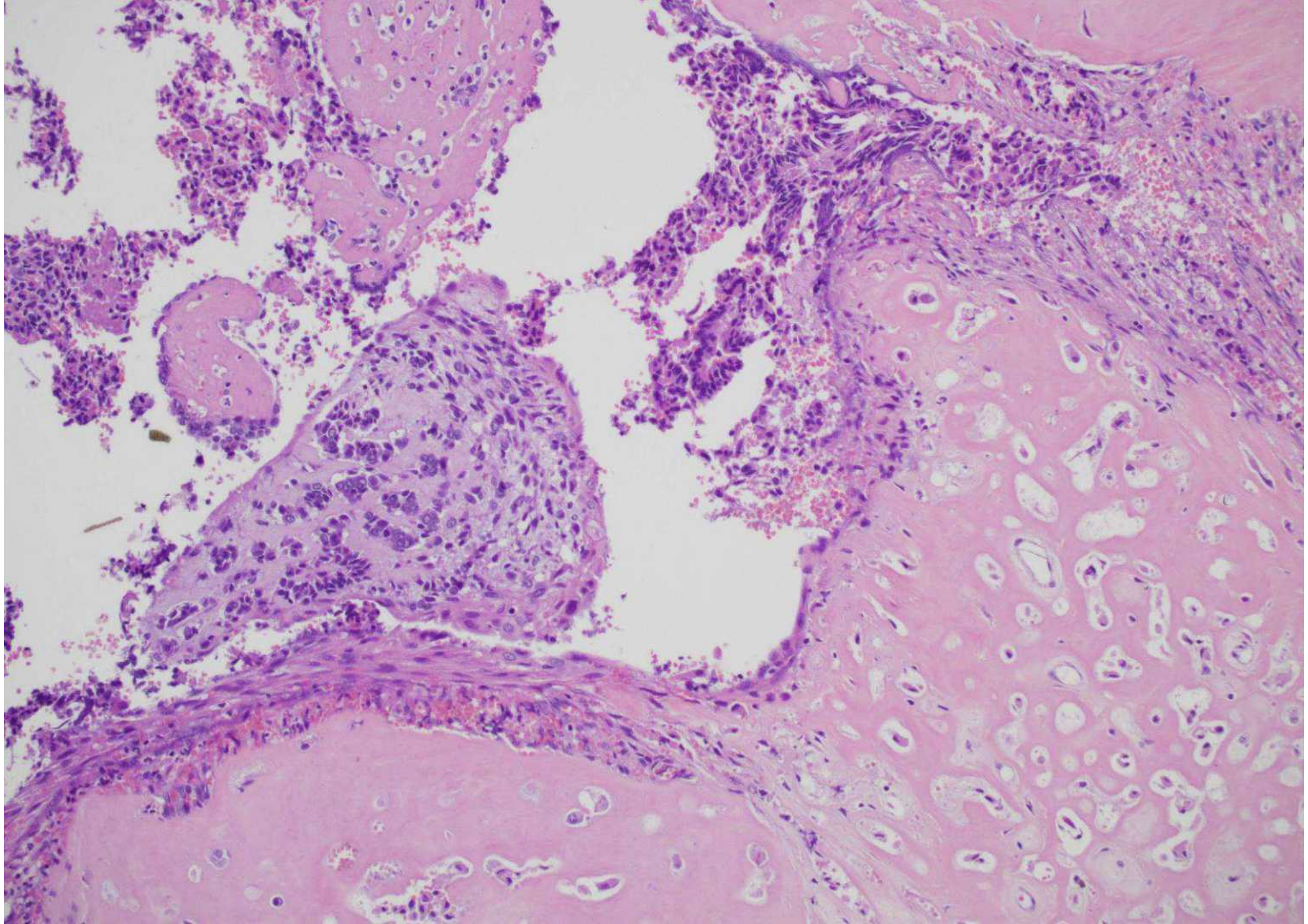

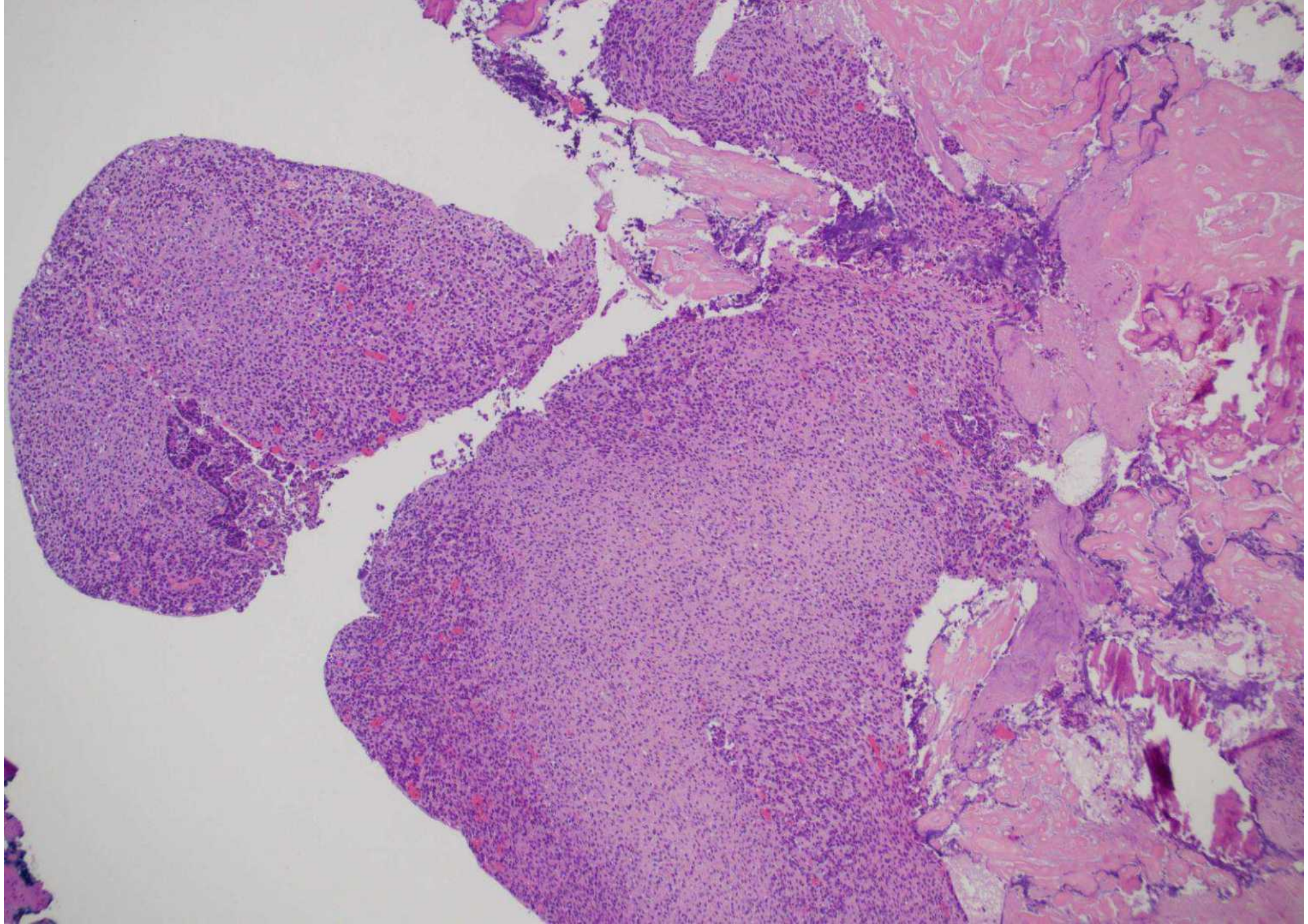

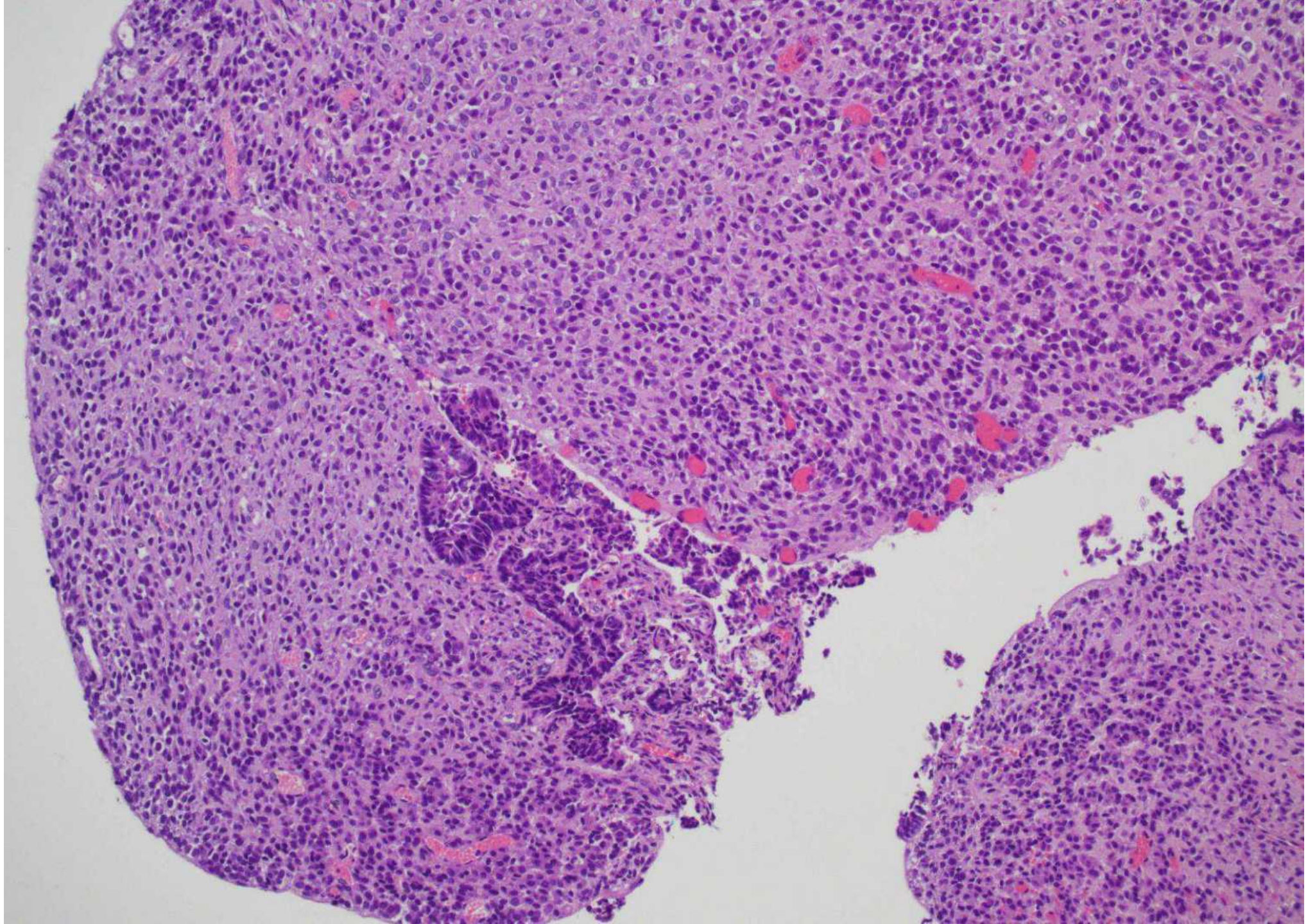

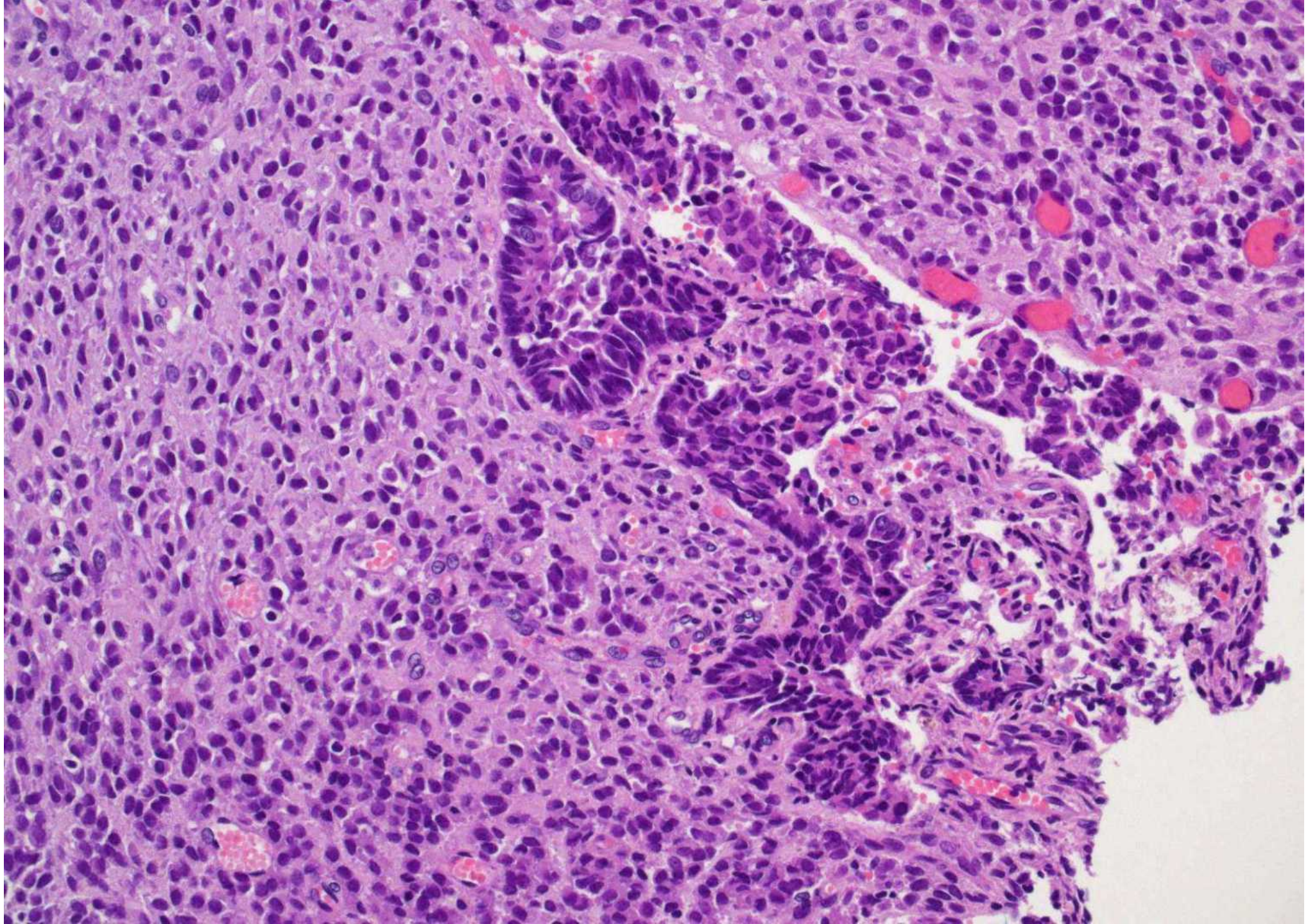

Case 4

- Other areas of the tumour

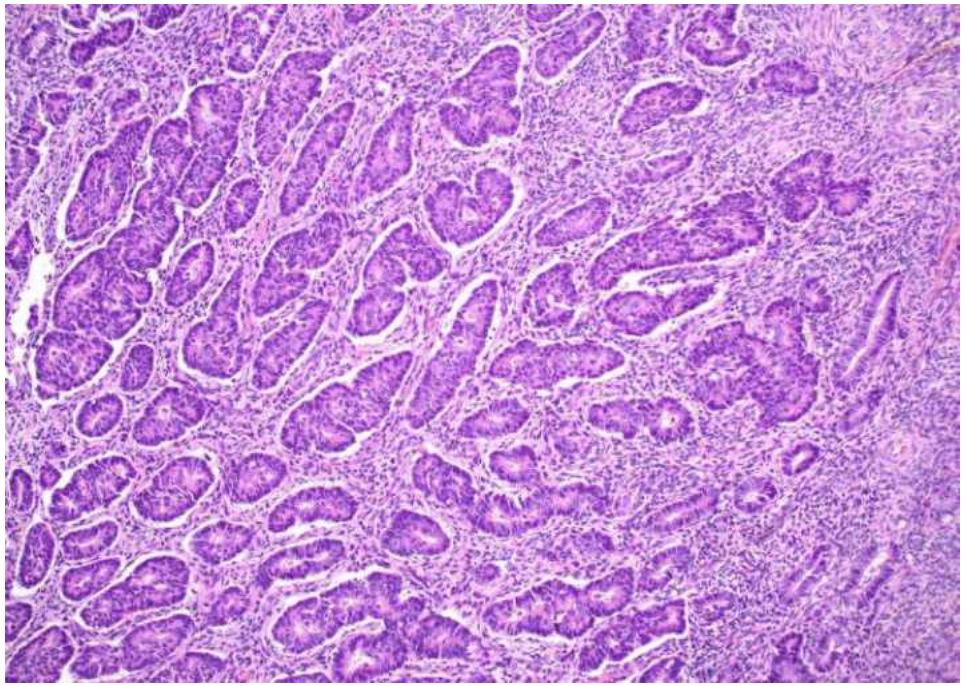

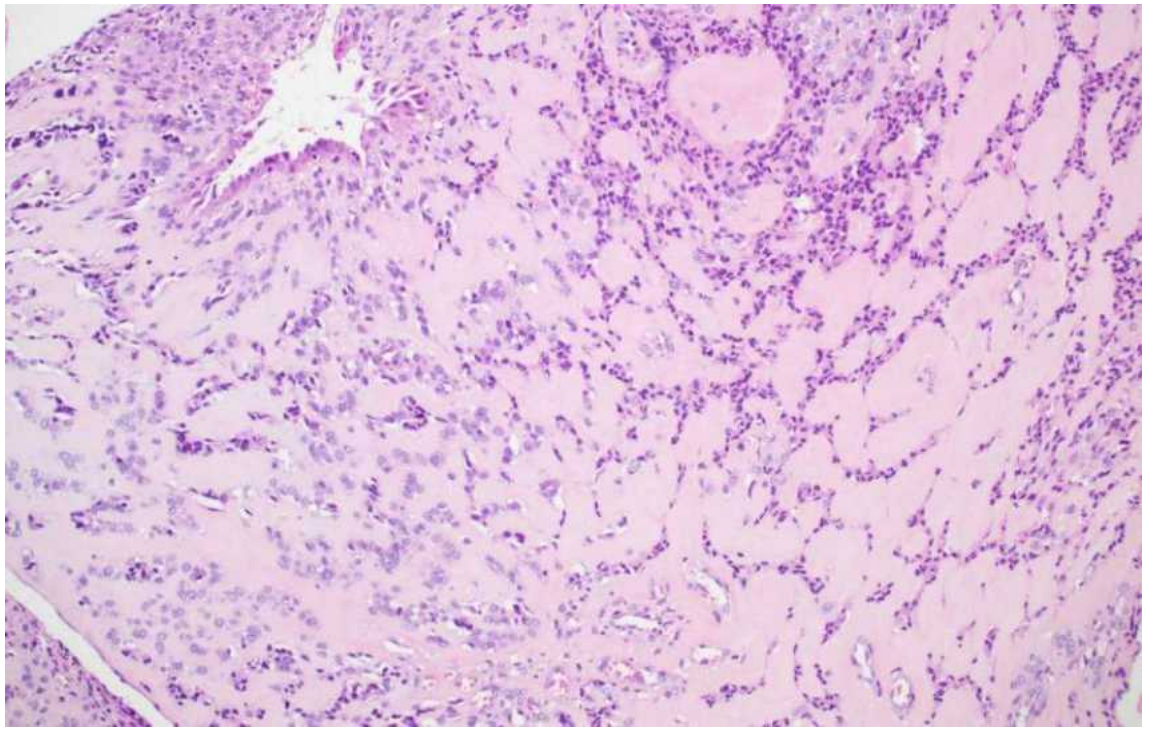

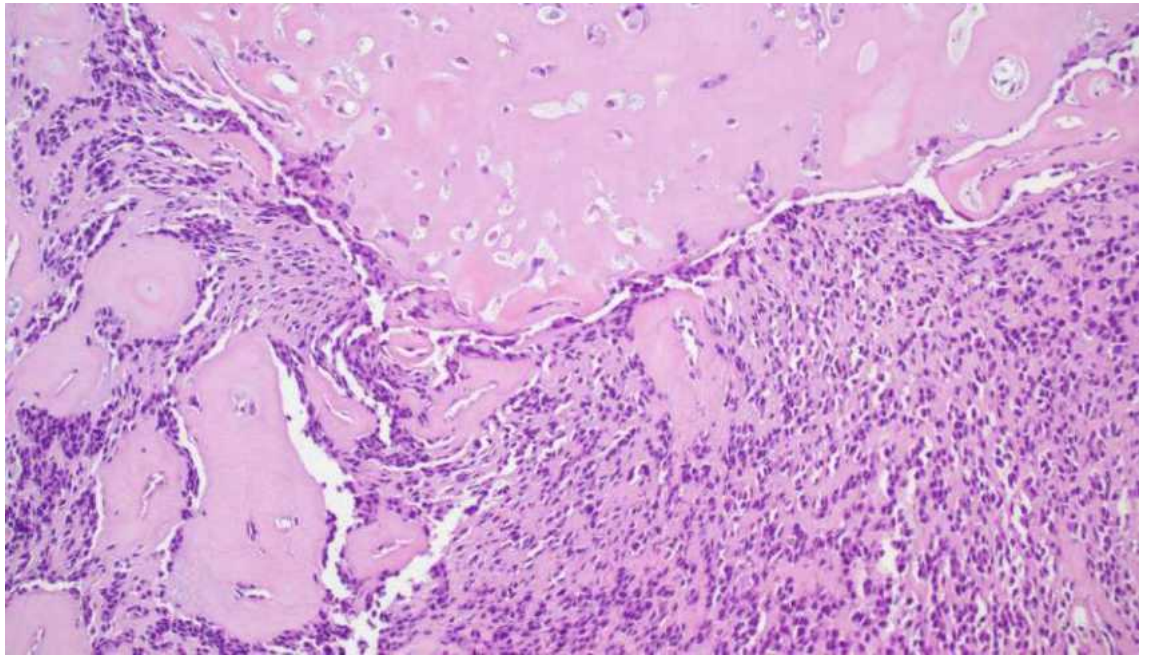

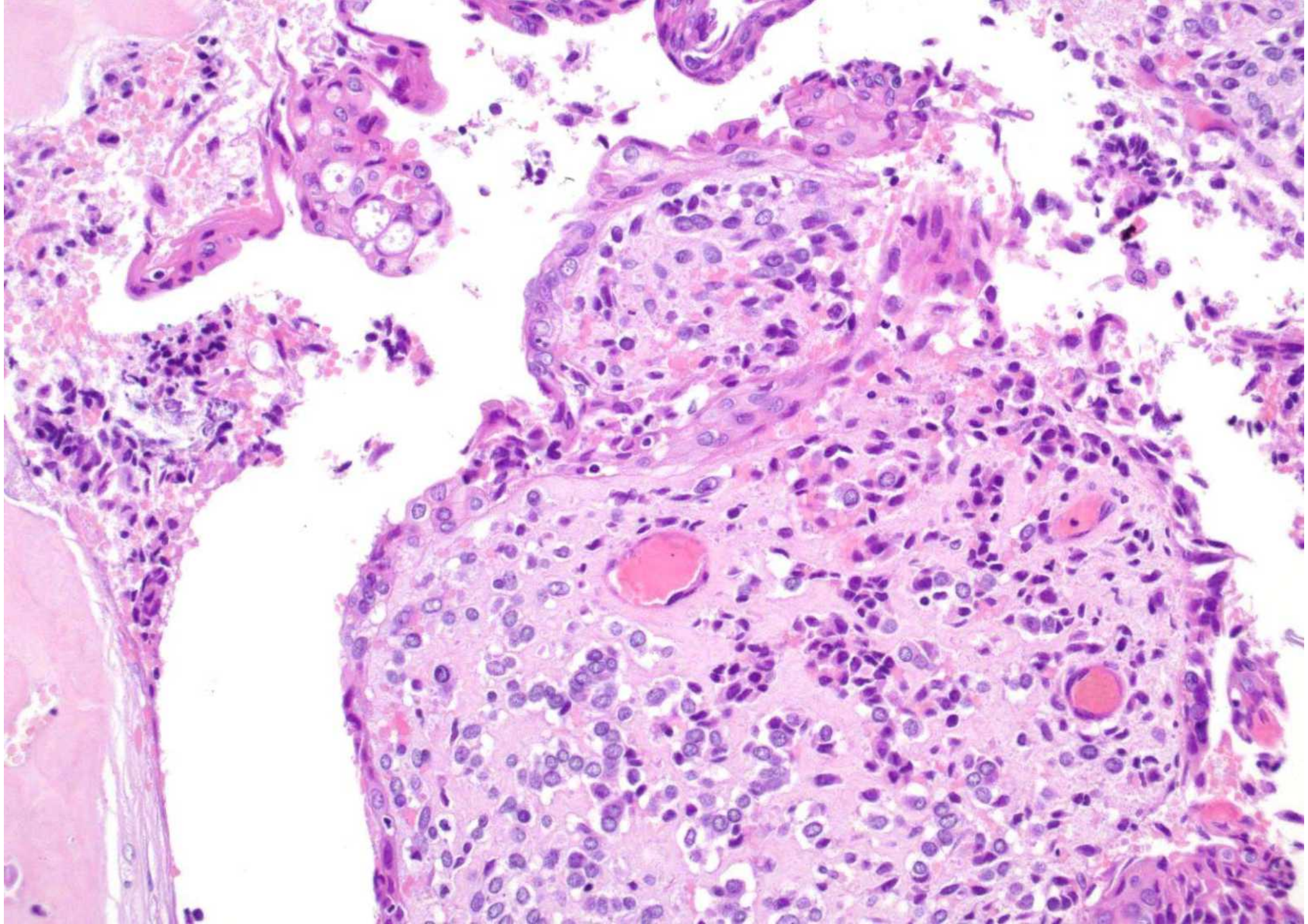

Case 4

- Cytokeratin (AE1/3)

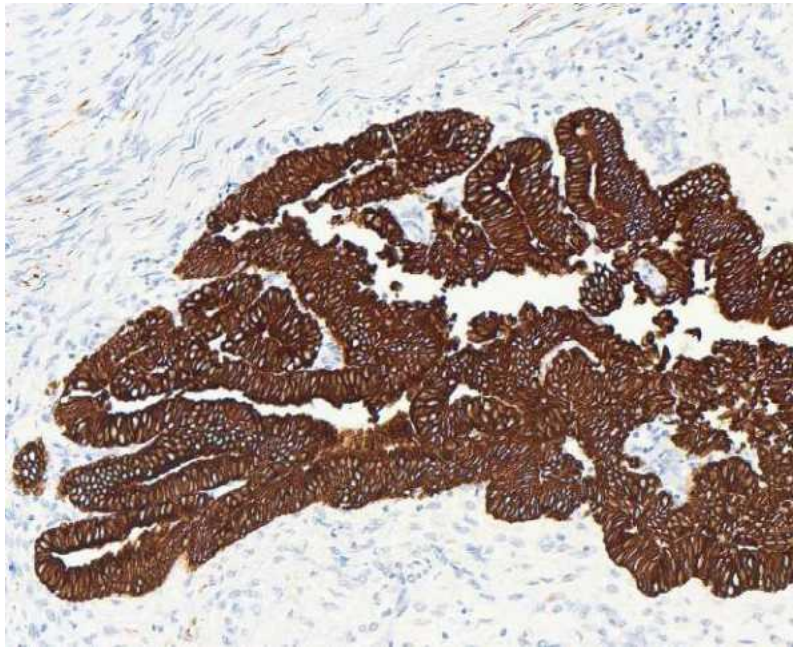

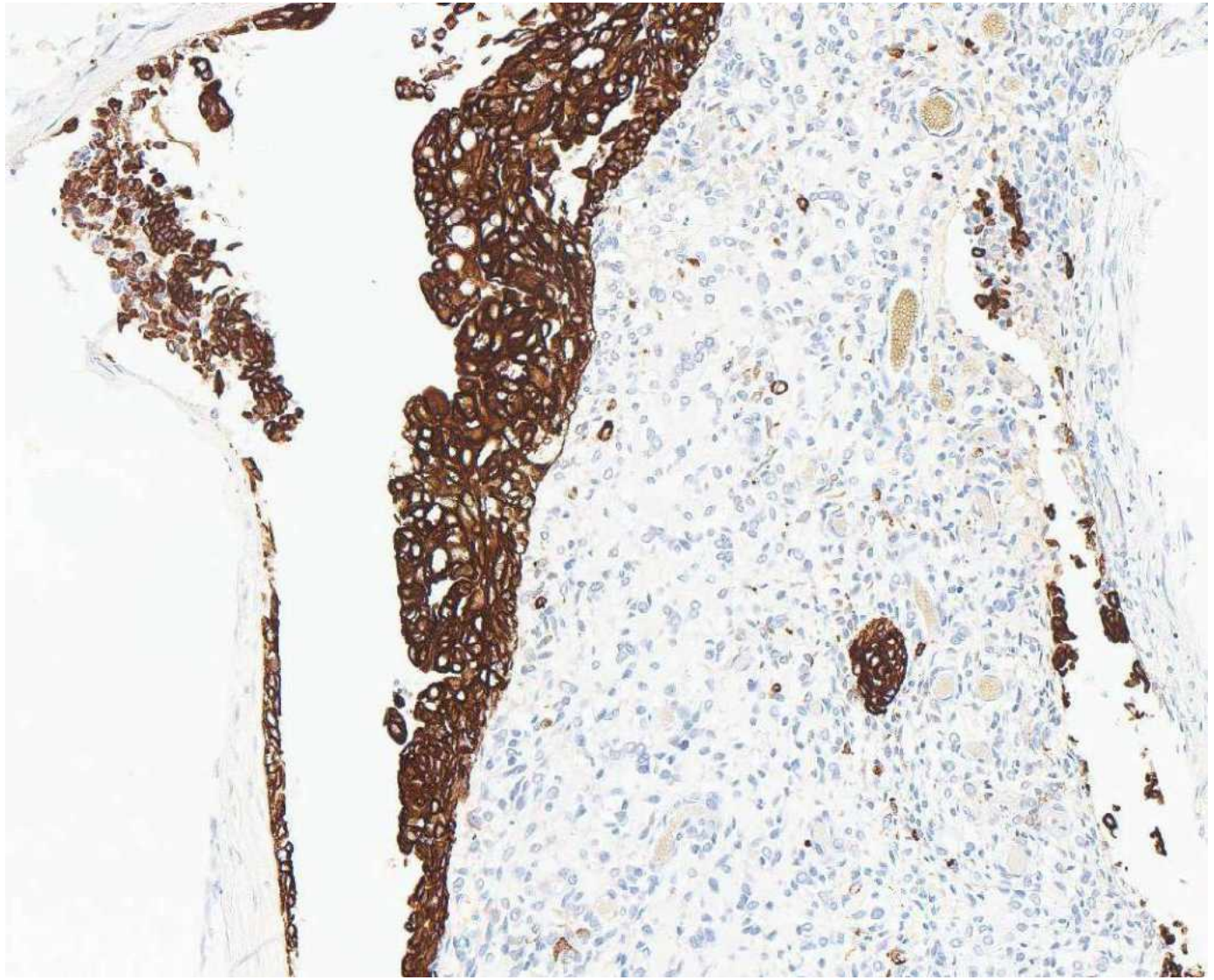

Case 4

- EMA



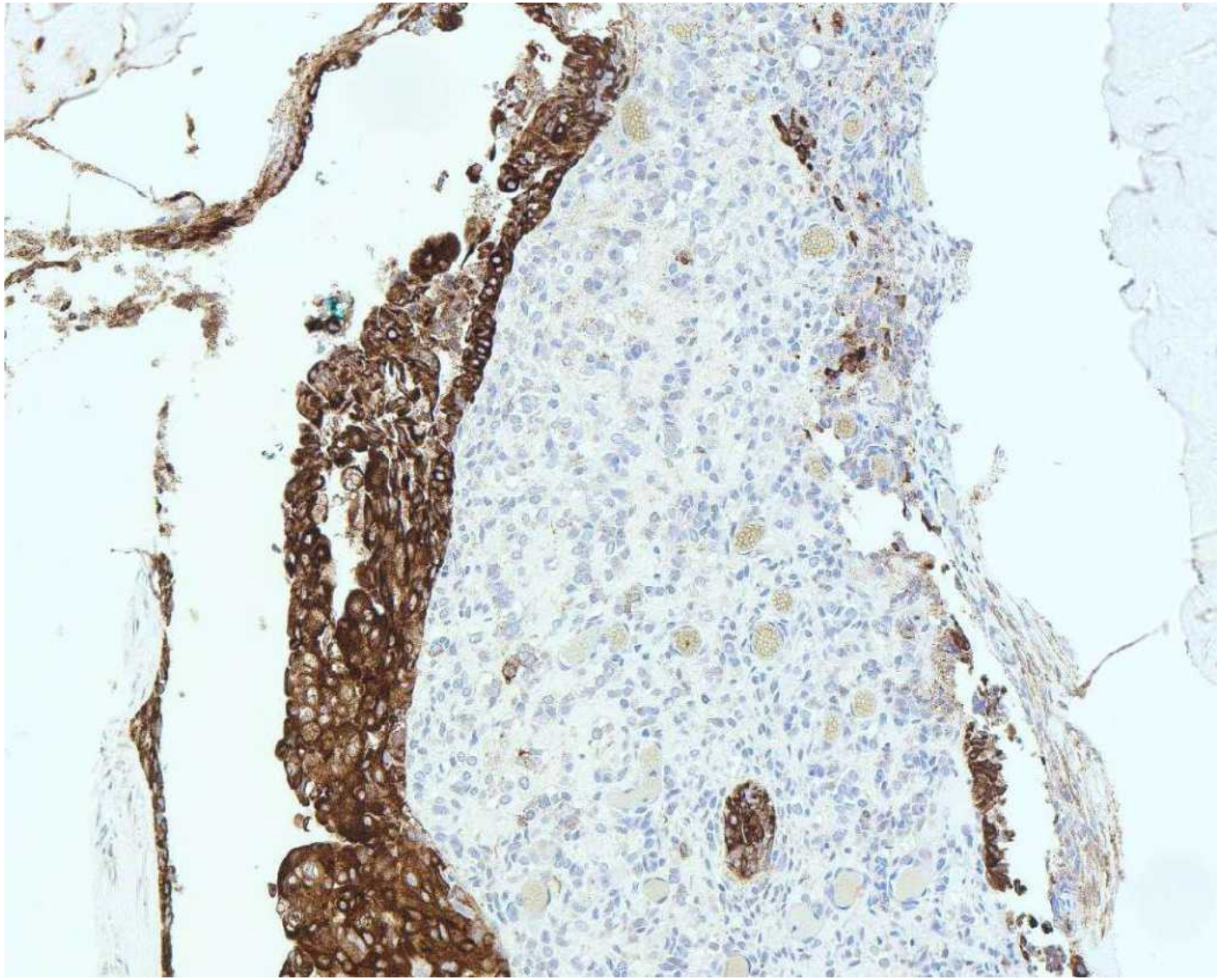

Case 4

- ER

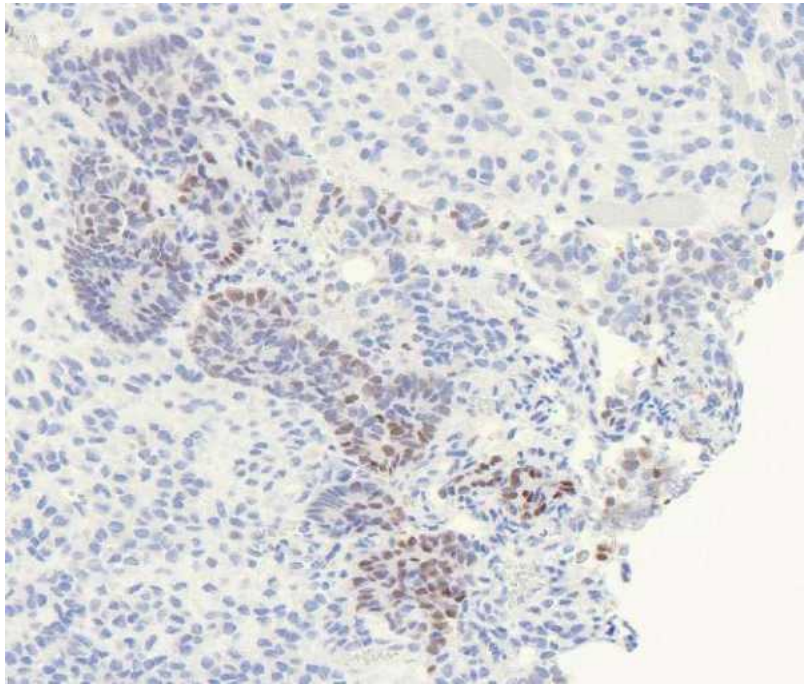

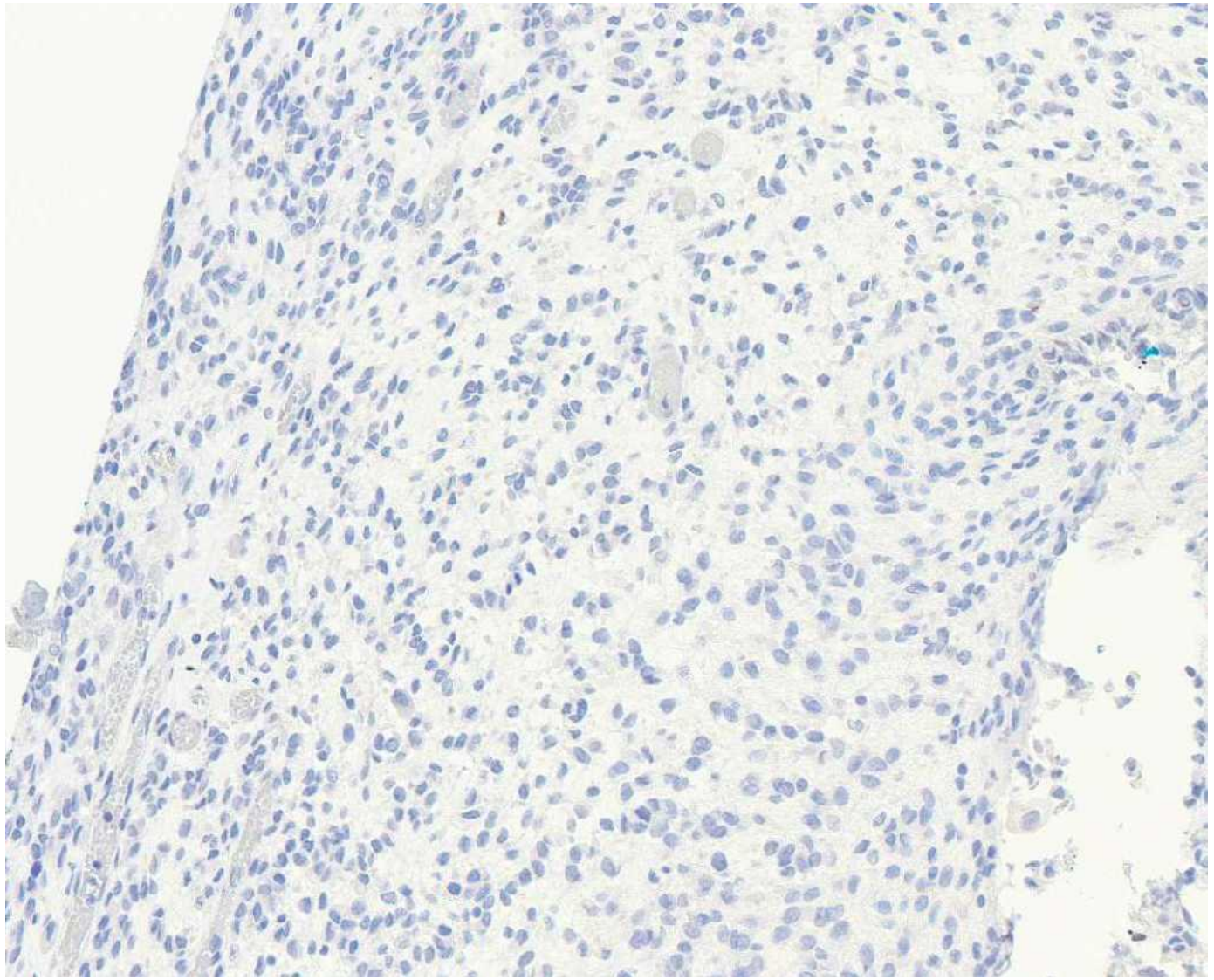

Case 4

- PAX8

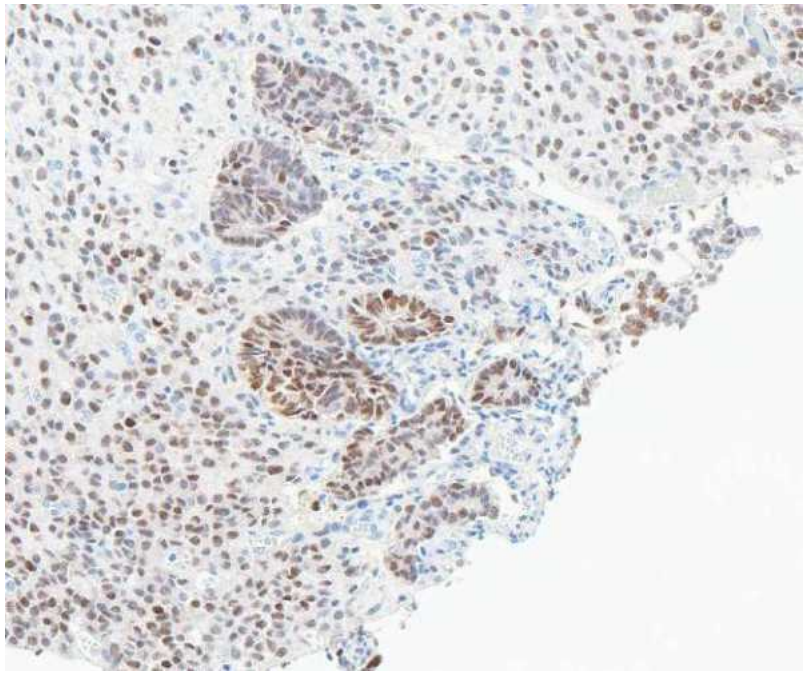

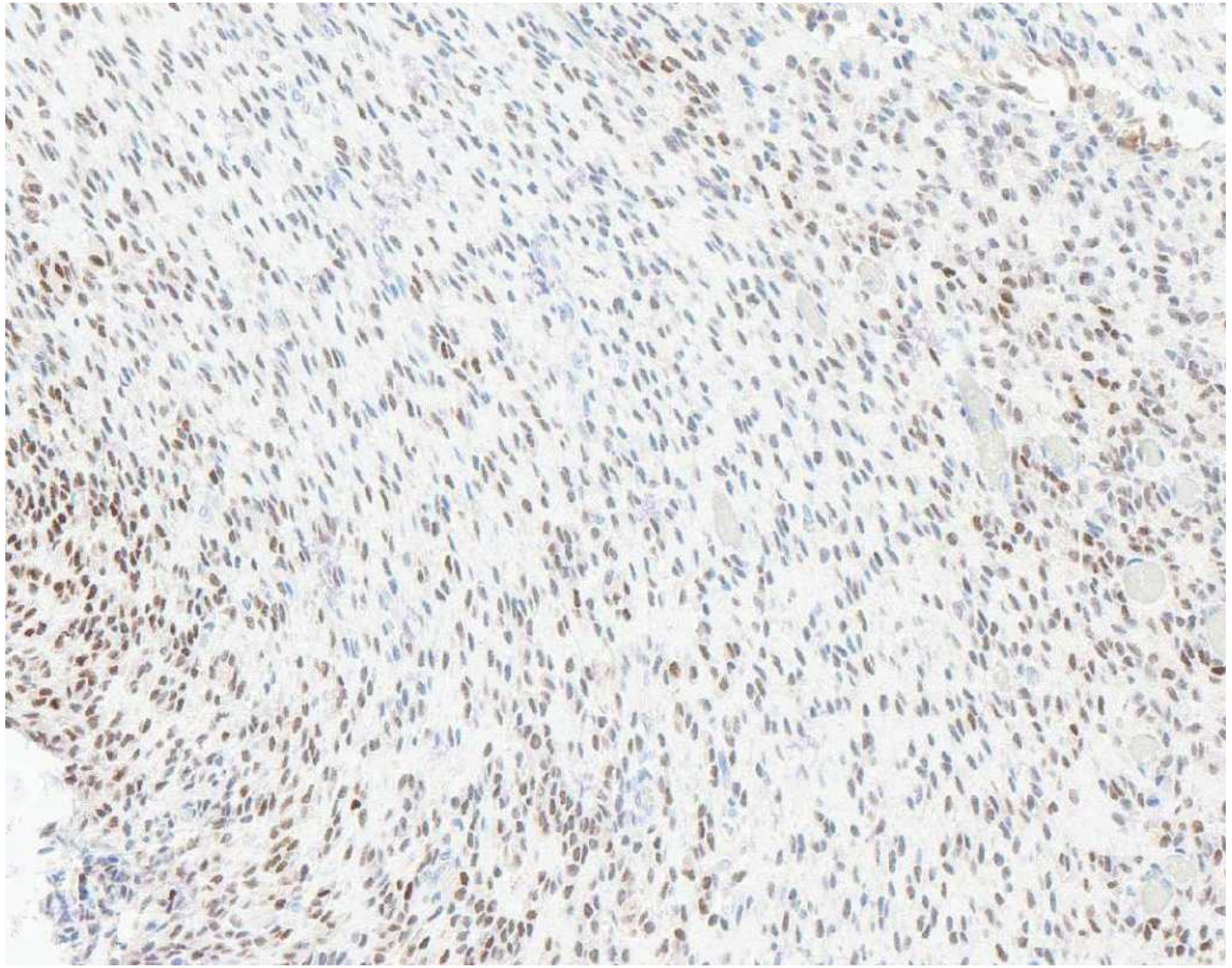

Case 4

- E-cadherin



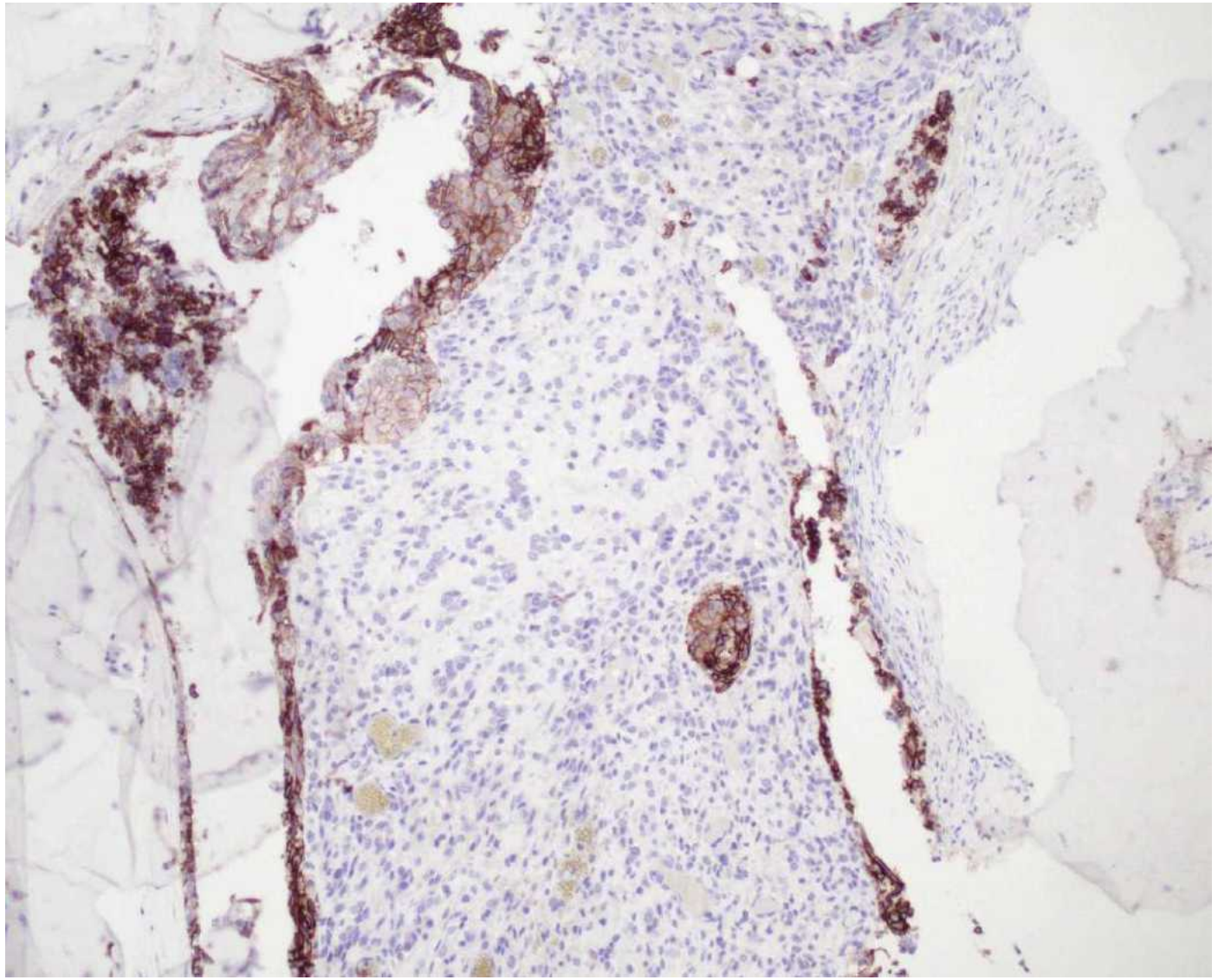

Case 4

- β-catenin

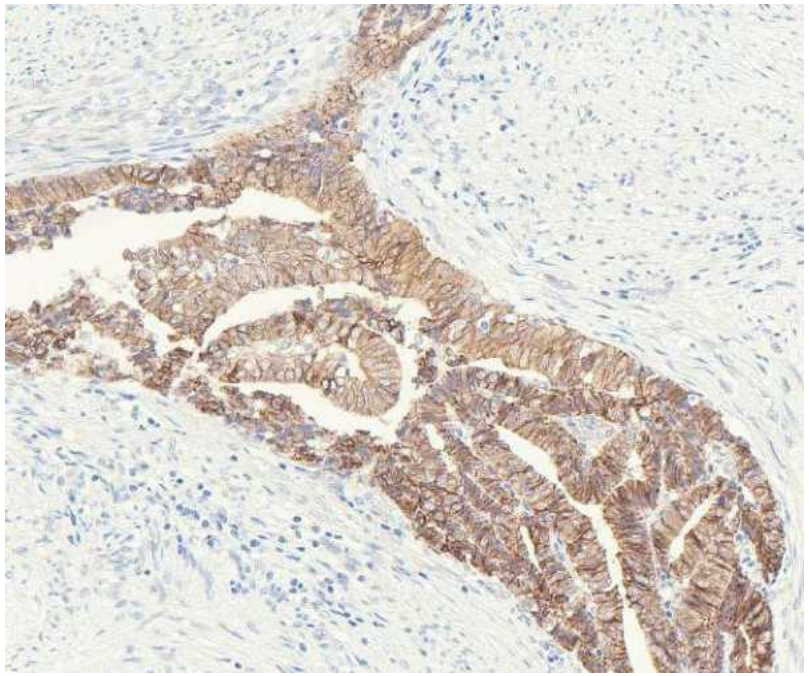

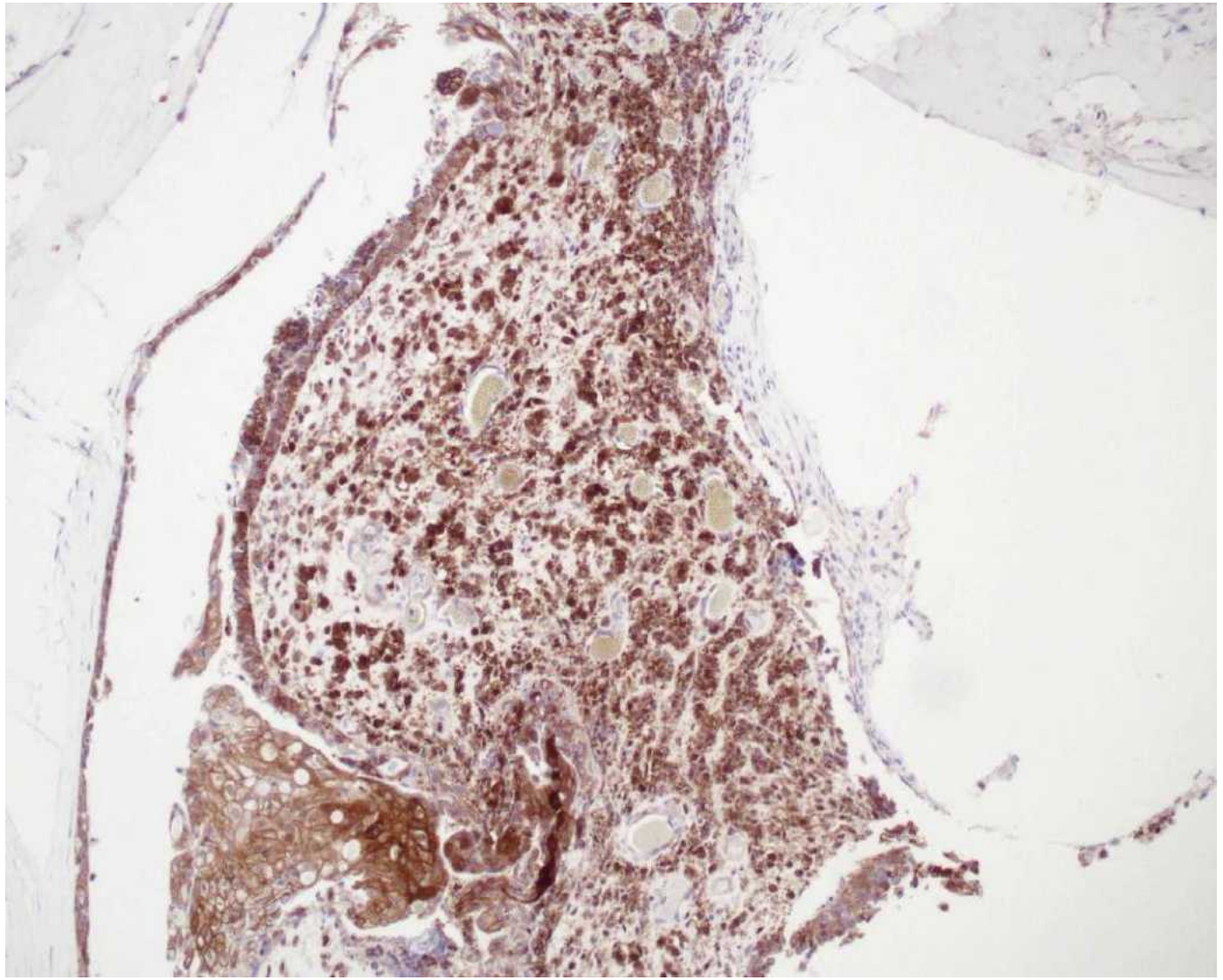

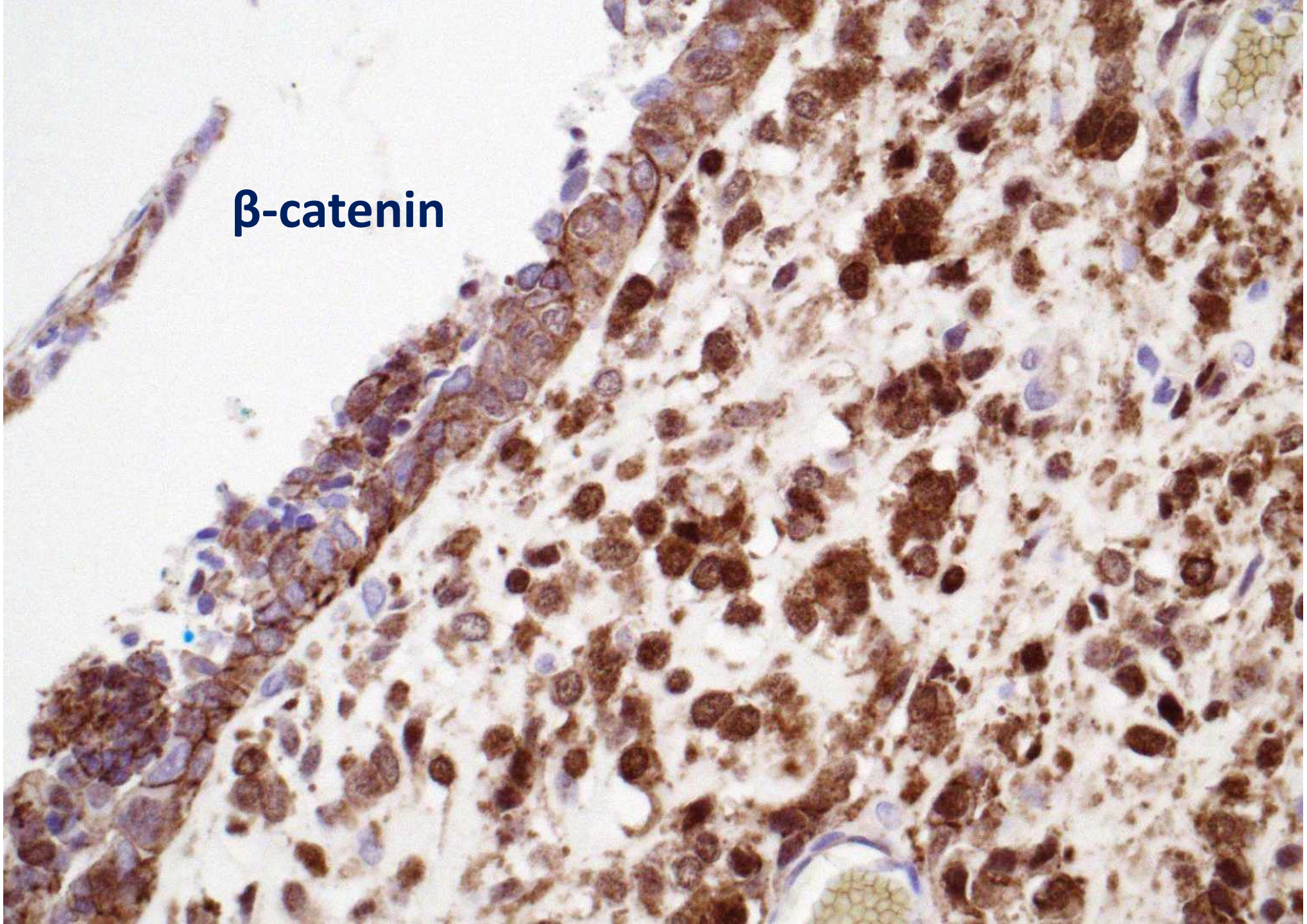
β-catenin

Case 4 – Pathological findings

- Biphasic tumour with endometrioid glands coexisting with cords of cells in hyalinized matrix, associated with osseous metaplasia

	Endometrioid glandular component	Corded and hyalinized component
Cytokeratin (AE1/3), EMA	Positive	**Mostly negative**
ER	Focally positive	**Negative**
PAX8	**Positive**	**Positive**
E-cadherin	Positive	**Negative**
β-catenin	Membrane staining	**Nuclear (and cytoplasmic) staining**
p53 *(not shown)*	Wild-type	Wild-type
CK20, GATA3, TTF1 *(not shown)*	Negative	Negative

Case 4 – Diagnosis

- **Corded and hyalinized endometrioid carcinoma (CHEC)**

	Endometrioid glandular component	Corded and hyalinized component
Cytokeratin (AE1/3), EMA	Positive	**Mostly negative**
ER	Focally positive	**Negative**
PAX8	**Positive**	**Positive**
E-cadherin	Positive	**Negative**
β-catenin	Membrane staining	**Nuclear (and cytoplasmic) staining**
p53 *(not shown)*	Wild-type	Wild-type
CK20, GATA3, TTF1 *(not shown)*	Negative	Negative

Corded and hyalinized endometrioid carcinoma (CHEC)

- A subtype of endometroid carcinoma with characteristic morphology and IHC profile (loss of cytokeratin and E-cadherin, with nuclear β-catenin), associated with *CTNNB1* mutation
- The CHEC component is excluded for grading purpose
- Most CHECs belong to NSMP molecular subtype
- Generally favourable clinical outcomes in the majority of reported cases
- Differential diagnosis of CHEC:
  - Carcinosarcoma
  - Uterine plexiform tumourlet
  - Uterine tumour resembling ovarian sex cord tumour (UTROSCT)
  - Corded and hyalinized endometrial hyperplasia

Murray SK, Clement PB, Young RH. Am J Surg Pathol 2005 (PMID: 15644772)
Ladwig NR, Umetsu SE, Zaloudek C, et al. Int J Gynecol Pathol 2021 (PMID: 32909971)
Safdar NS, Thompson EF, Gilks CB, et al. Am J Surg Pathol 2021 (PMID: 34115671)

Typical histological features of CHEC

- Anastomosing cords, small clusters or scattered epithelioid cells within a hyalinized stroma which may be focally myxoid
- Spindle cells in short fascicles may be seen
- Usually uniform nuclei with minimal or mild cytologic atypia, and low mitotic activity
  - Except for rare cases of “high-grade CHEC” which may have increased nuclear atypia and mitoses (criteria not clearly established)
- Squamous differentiation common
- Osteoid formation (osseous metaplasia) commonly present

Murray SK, Clement PB, Young RH. Am J Surg Pathol 2005 (PMID: 15644772)
Ladwig NR, Umetsu SE, Zaloudek C, et al. Int J Gynecol Pathol 2021 (PMID: 32909971)
Safdar NS, Thompson EF, Gilks CB, et al. Am J Surg Pathol 2021 (PMID: 34115671)

Immunohistochemical features of CHEC (corded and hyalinized component)

- Nuclear expression of **β-catenin** seen in the vast majority of cases
  - Nuclear β-catenin may also be present in the conventional endometrioid component but often more extensive in the corded and hyalinized foci
- **E-cadherin** typically negative or focal weak
- Negative or focal expression of **cytokeratin**
- **EMA** may be diffuse or focal
- **ER** and **PAX8** are variable (may be positive or negative)
- Usually **p53** wild-type and **MMR** proficient

Murray SK, Clement PB, Young RH. Am J Surg Pathol 2005 (PMID: 15644772)
Ladwig NR, Umetsu SE, Zaloudek C, et al. Int J Gynecol Pathol 2021 (PMID: 32909971)
Safdar NS, Thompson EF, Gilks CB, et al. Am J Surg Pathol 2021 (PMID: 34115671)
Travaglino A, Arciuolo D, Santoro A, et al. Pathol Res Pract 2023 (PMID: 37209572)

Recent developments related to CHEC

- Few cases of **high-grade CHEC** have been reported (based on high-grade nuclear features in the endometrioid and/or corded components), some with p53 abnormality
  - Distinction from carcinosarcoma may be difficult
- A case of **corded and hyalinized mesonephric-like carcinoma** of the endometrium has been reported
- Cases of **corded and hyalinized endometrial hyperplasia** (CHEH, with or without atypia) has been reported
  - Endometrial hyperplasia coexisting with sex cord-like growth, stromal hyalinization or spindle cells
  - Nuclear β-catenin present

Ladwig NR, Umetsu SE, Zaloudek C, et al. Int J Gynecol Pathol 2021 (PMID: 32909971)
Travaglino A, Arciuolo D, Santoro A, et al. Virchows Arch 2023 (PMID: 36550216)
Patel V, Kipp B, Schoolmeester JK. Hum Pathol 2019 (PMID: 30172914)
Pors J, Weiel JJ, Ryan E, Longacre TA. Am J Surg Pathol 2023 (PMID: 37493099)

Case 5

- 73 years old
- Hysterectomy for uterine corpus cancer

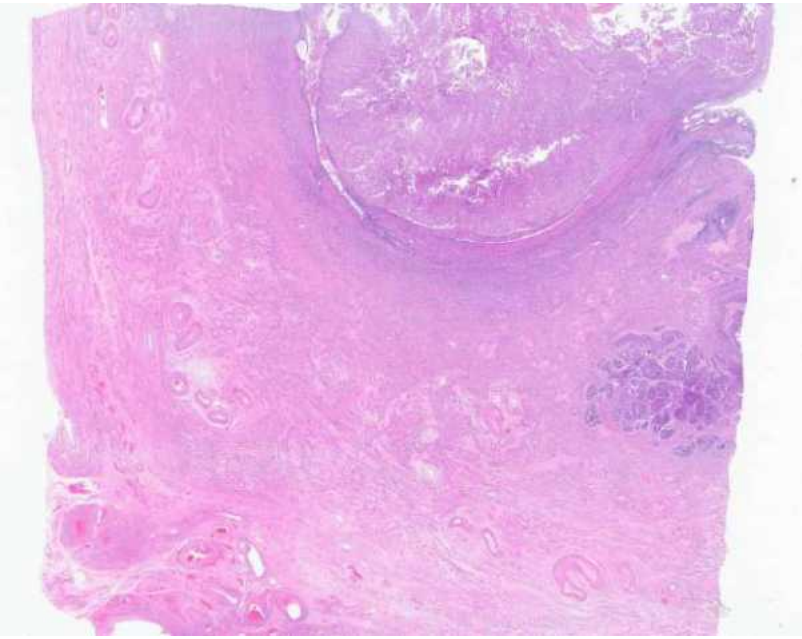
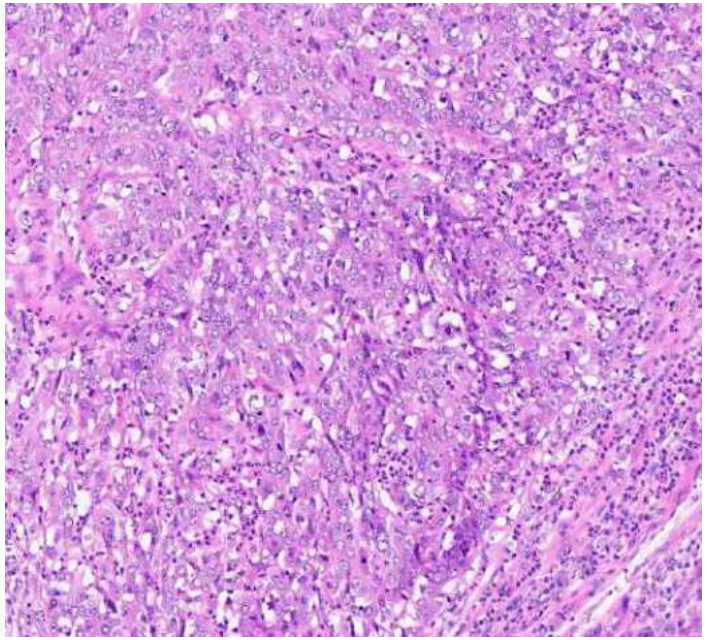
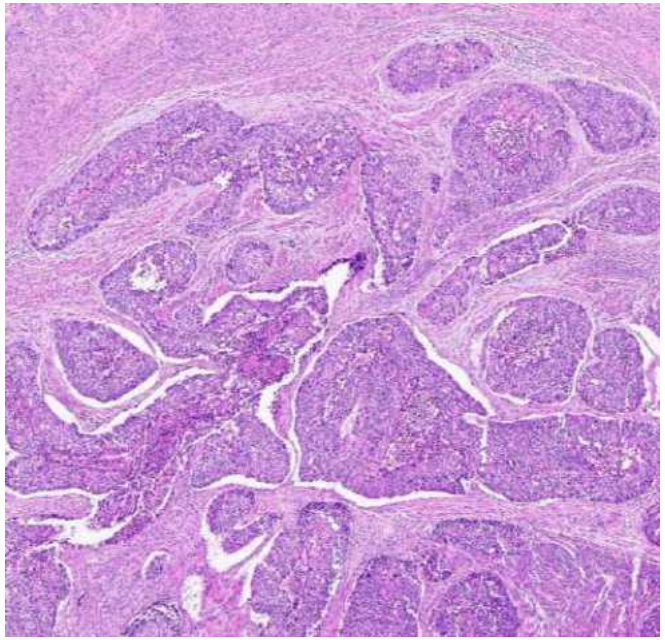

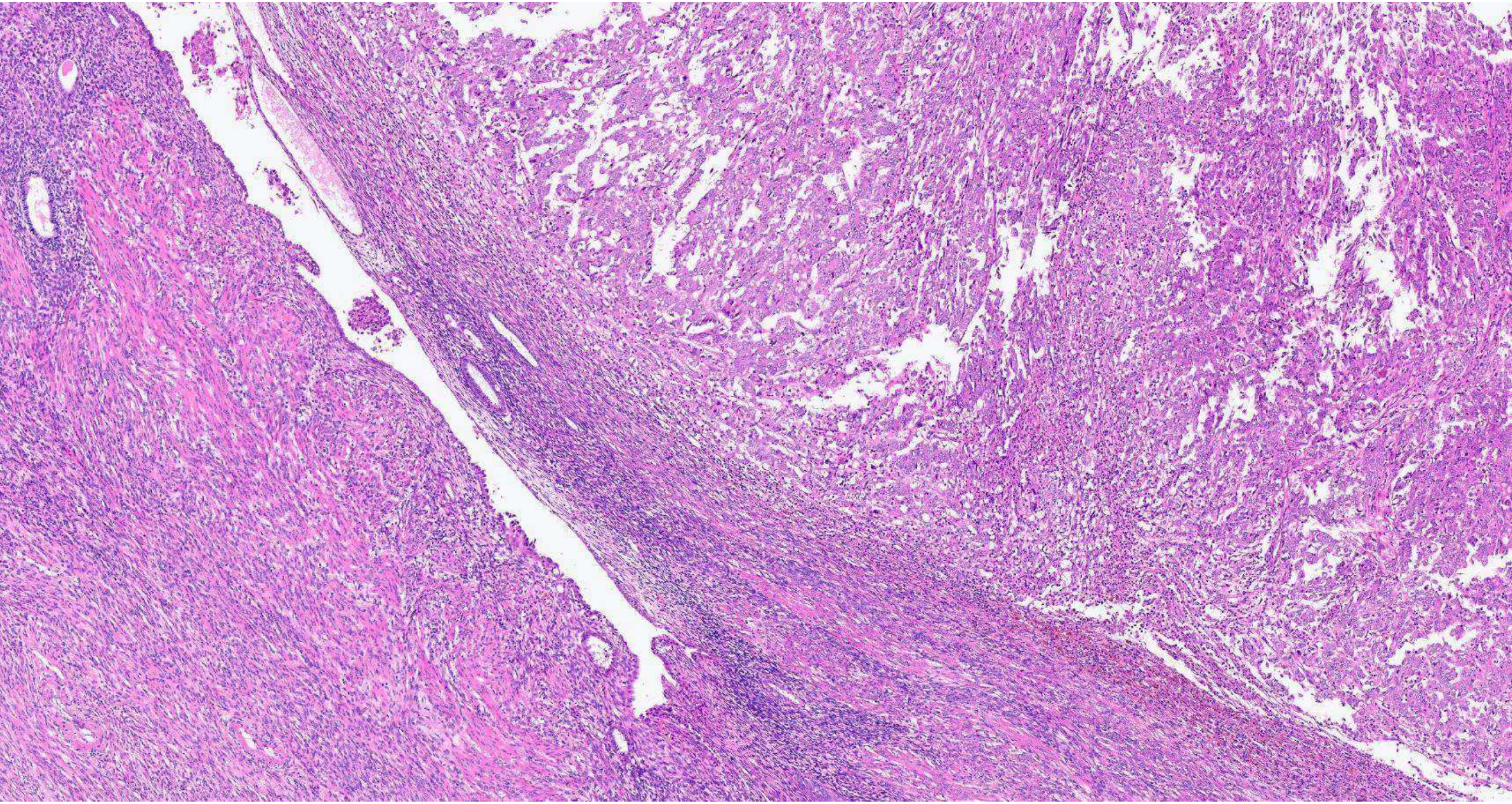

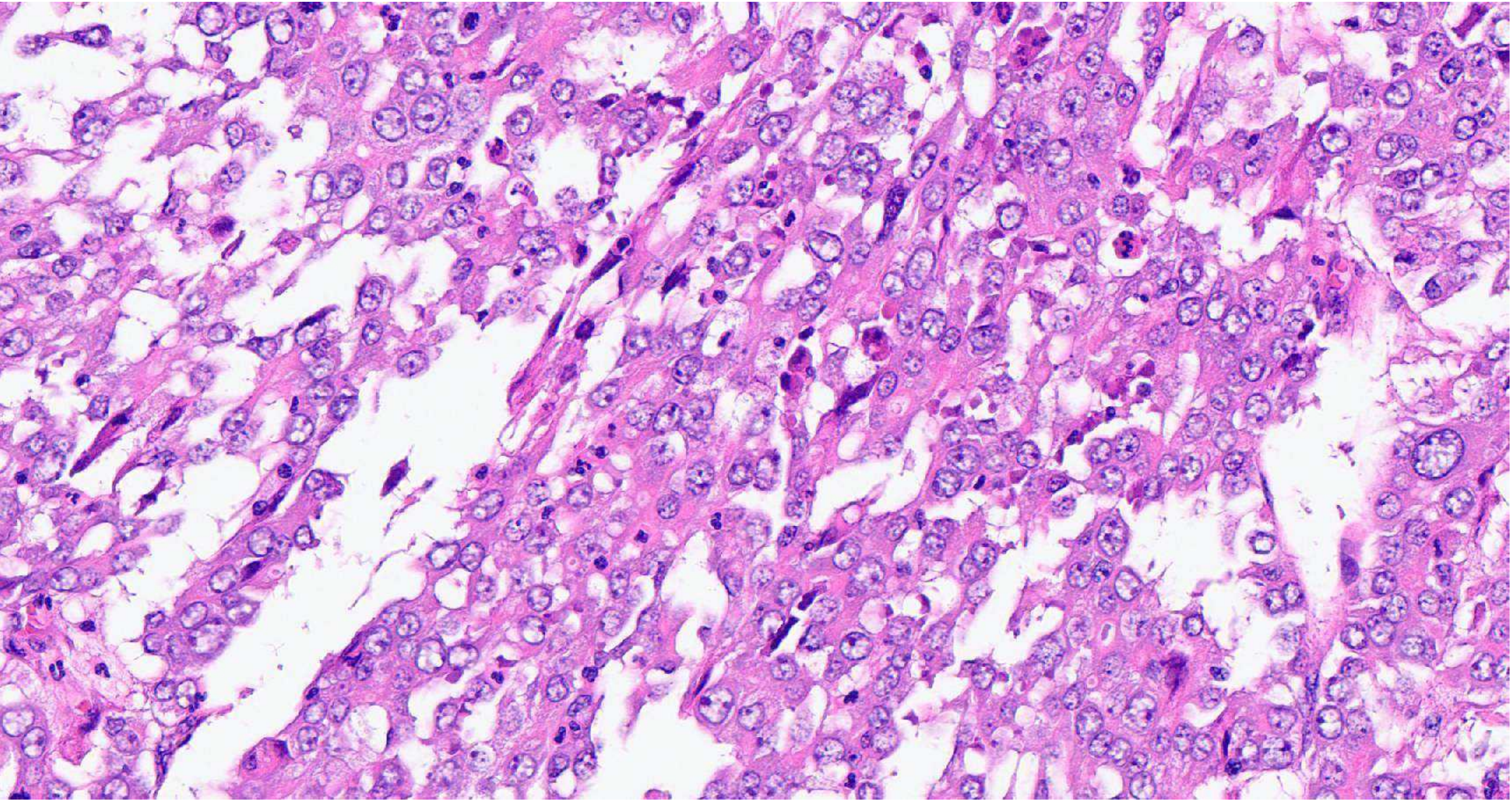

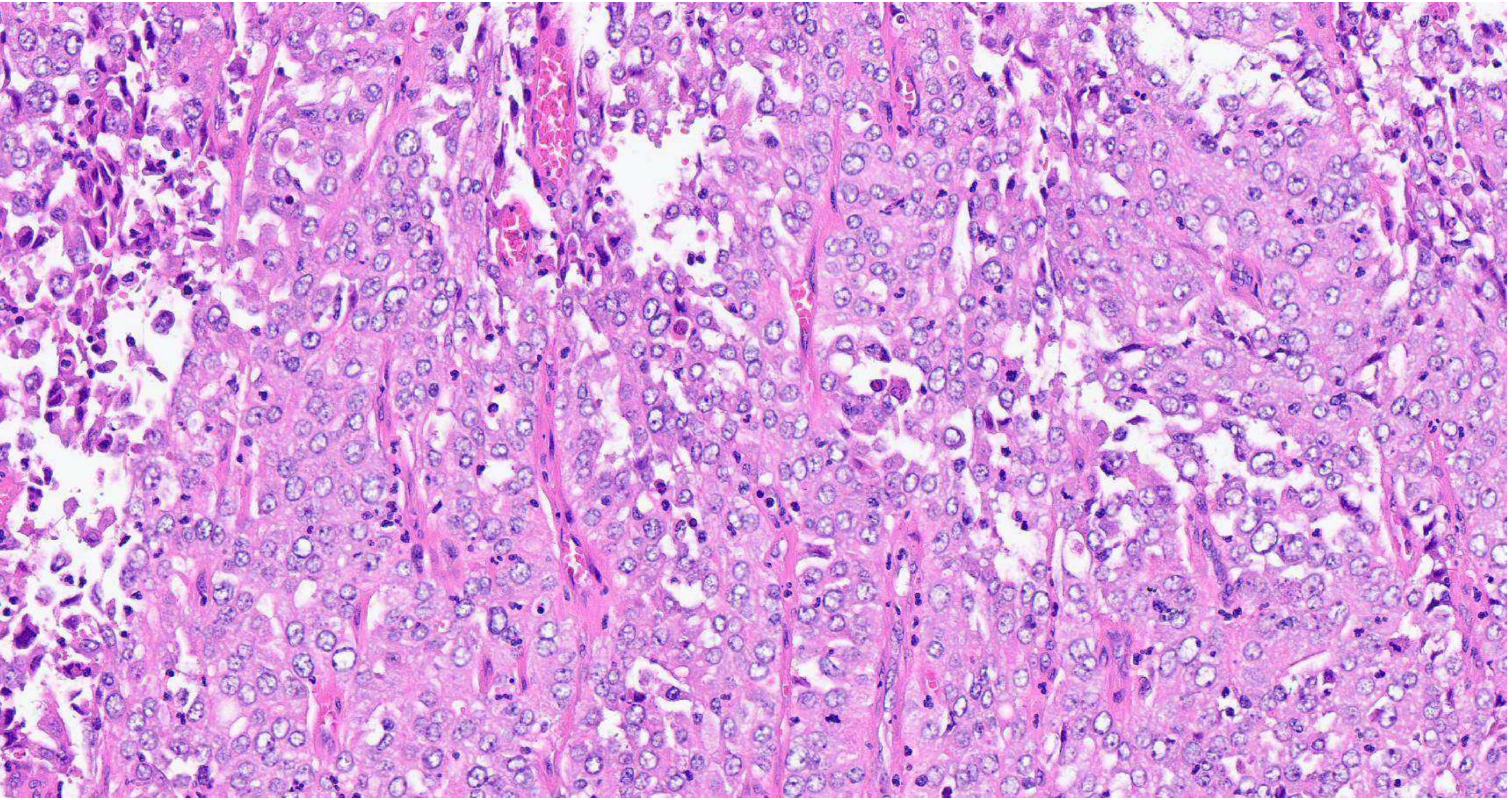

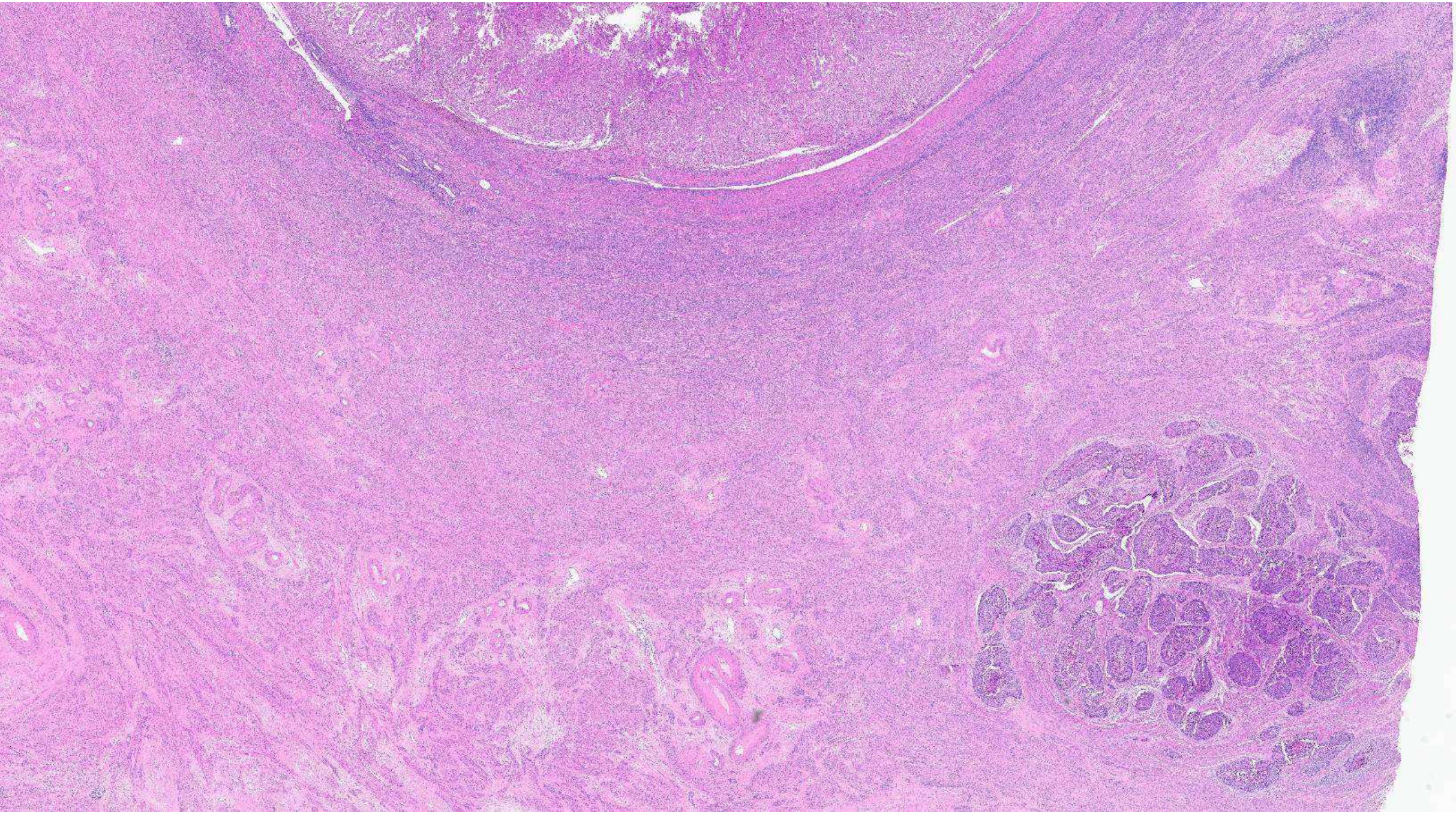

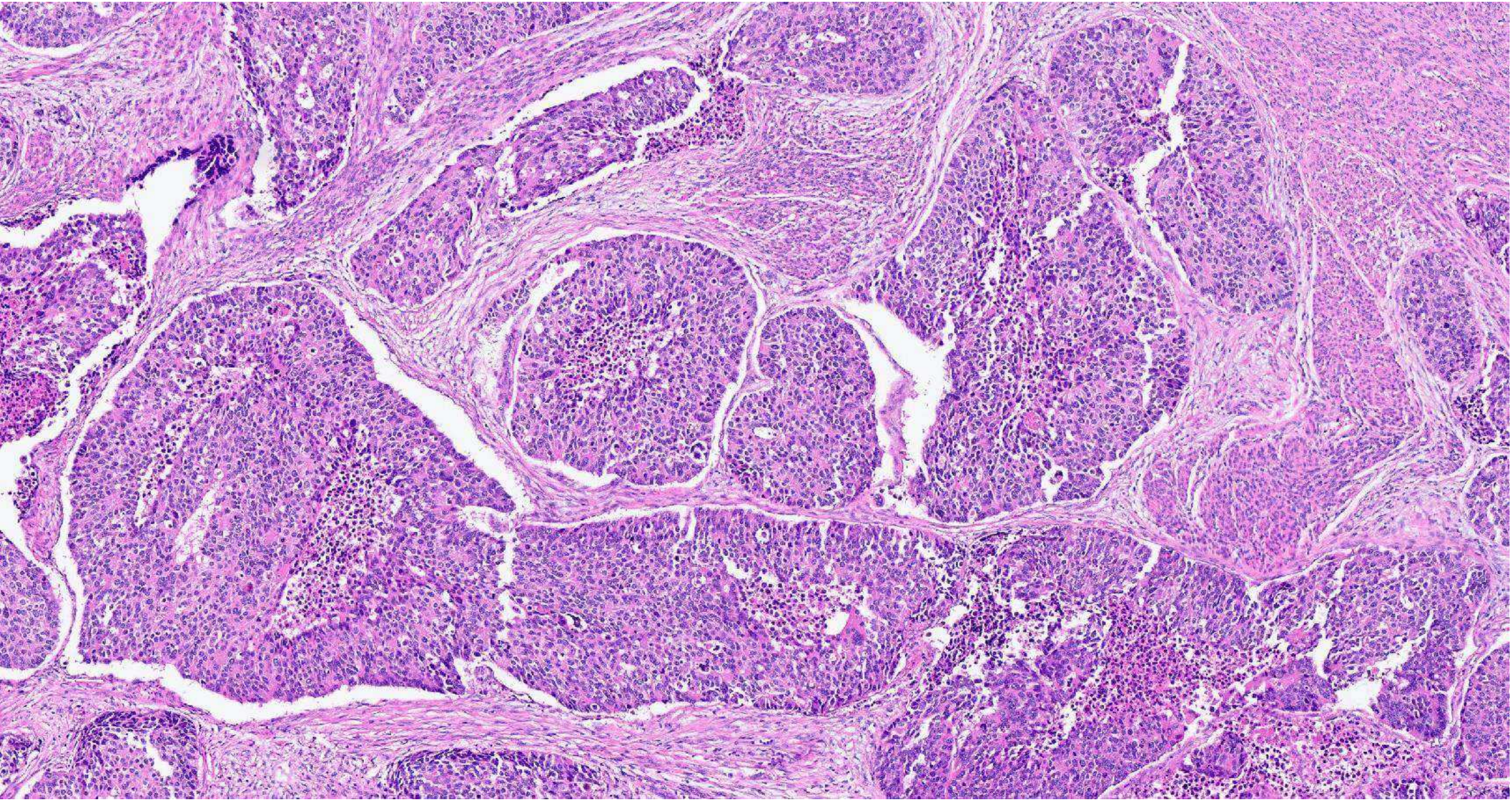

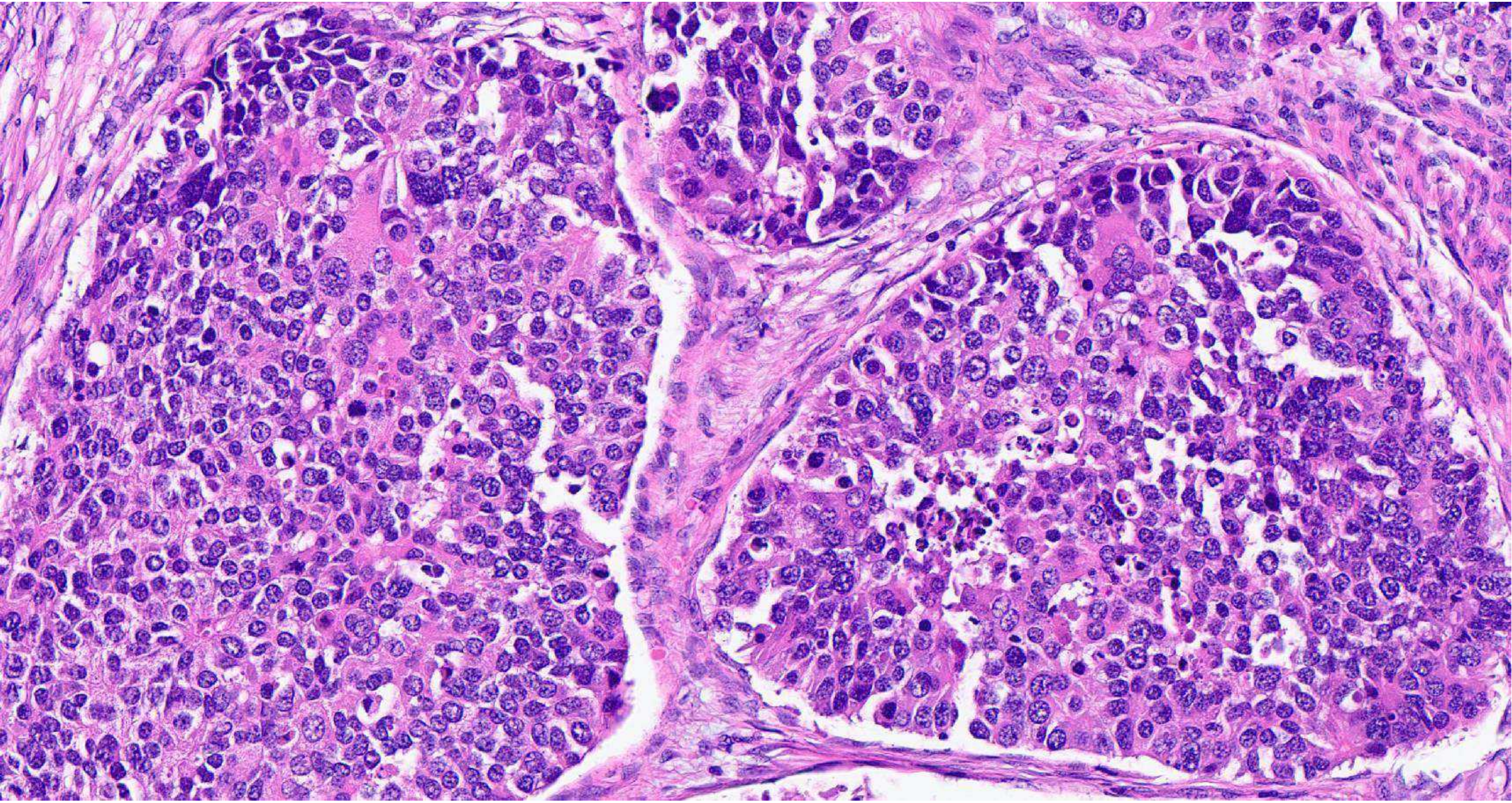

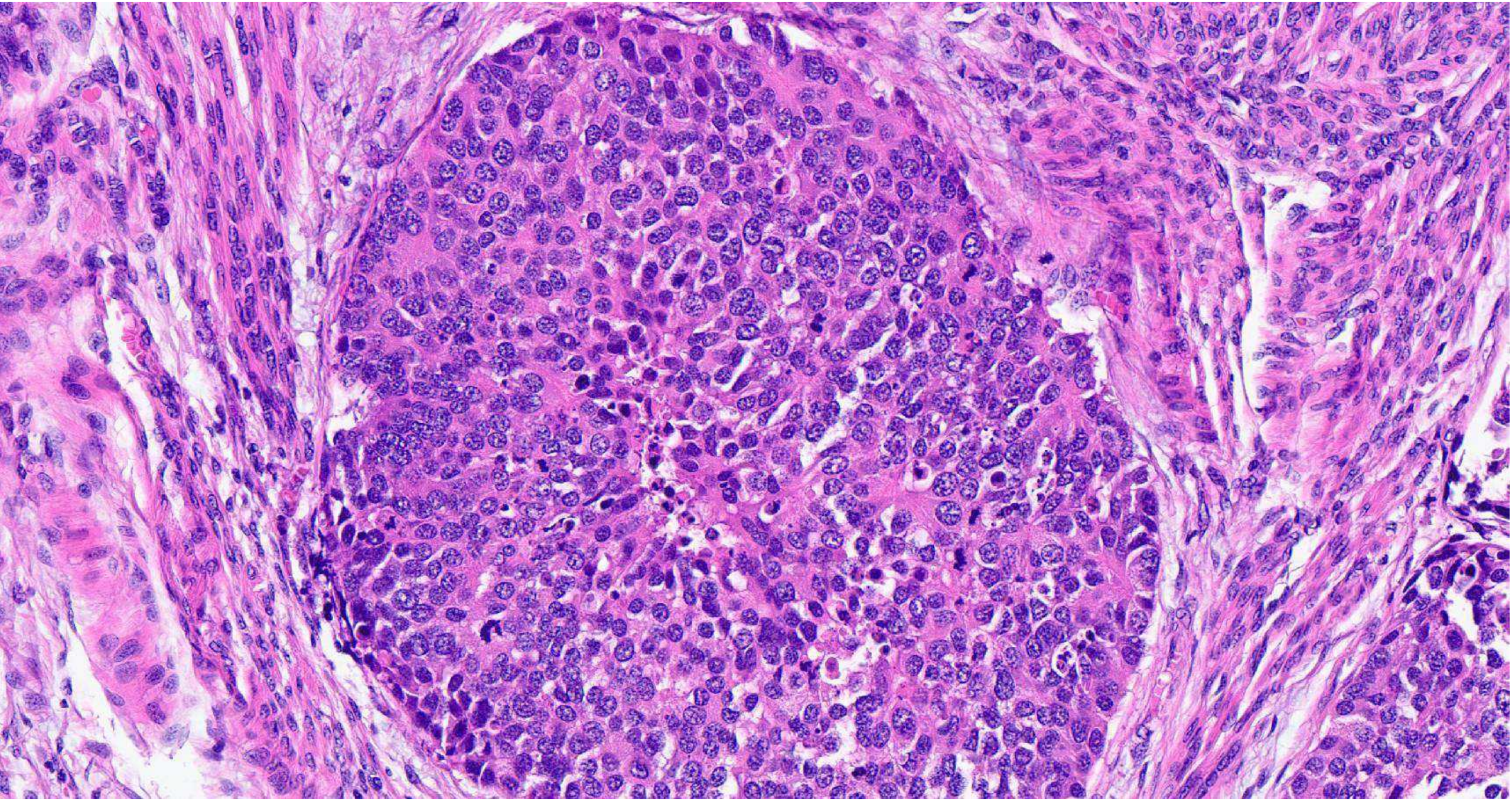

Case 5

- ER

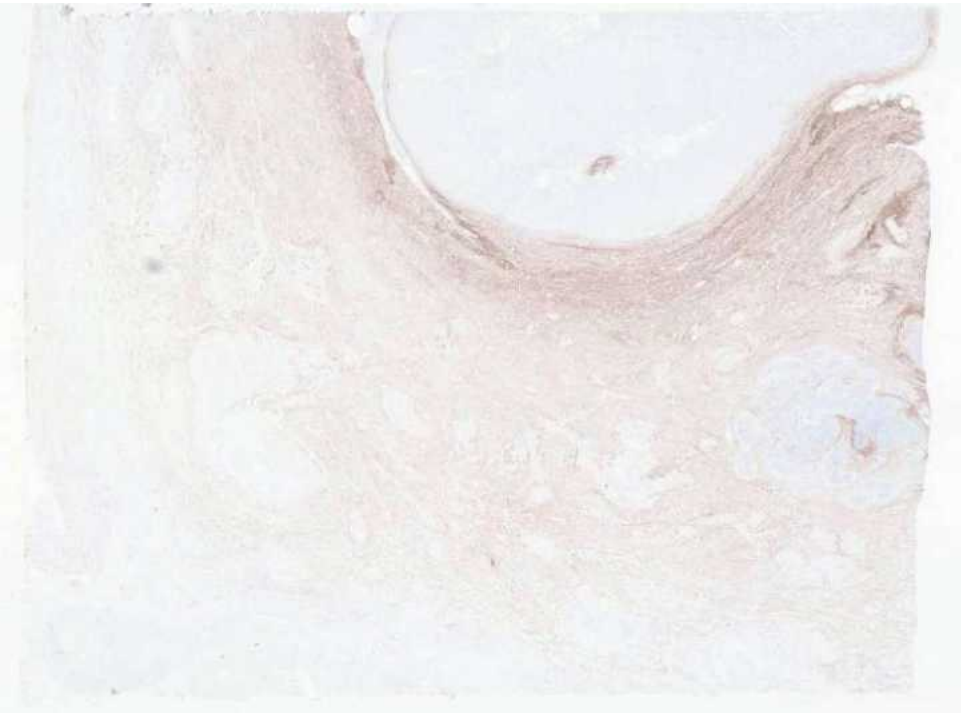

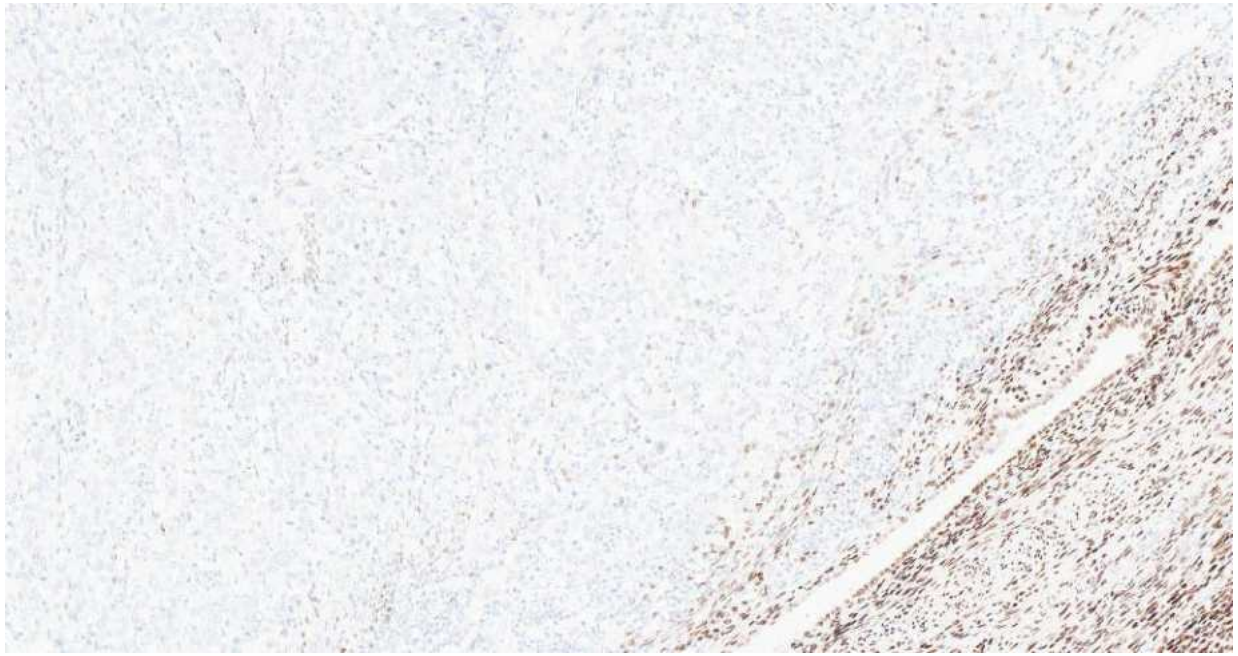

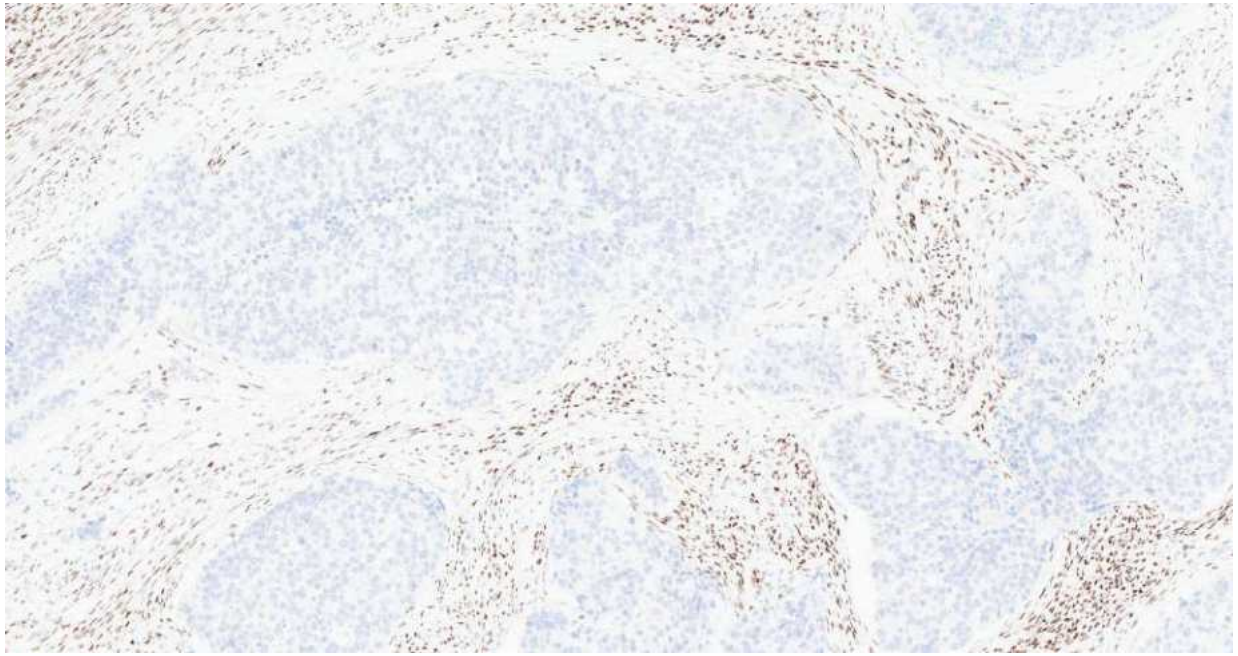

Case 5

- p53

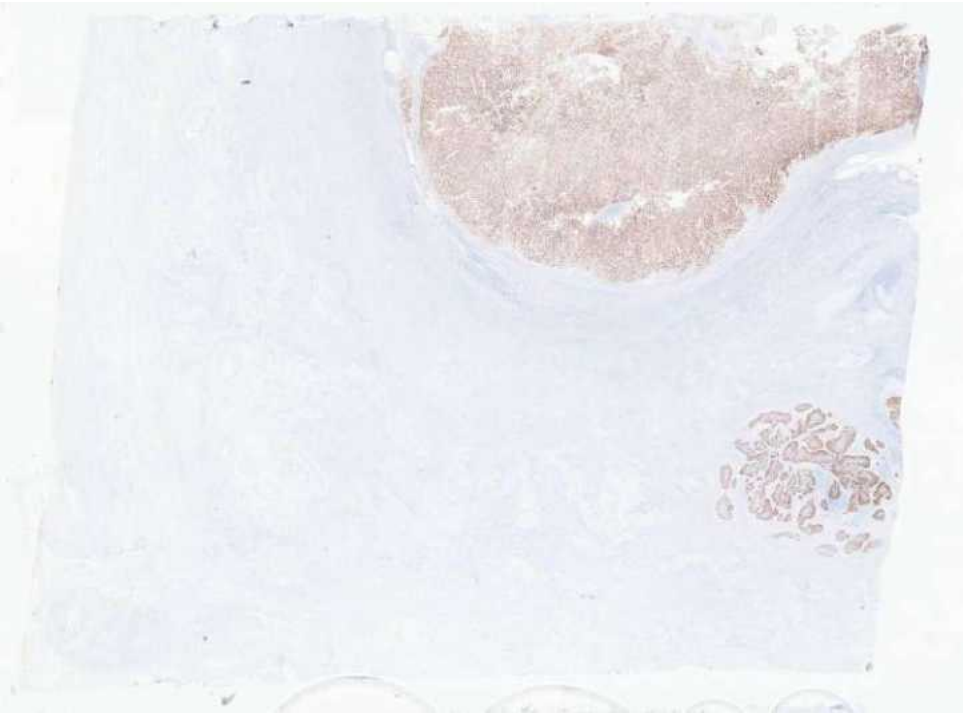

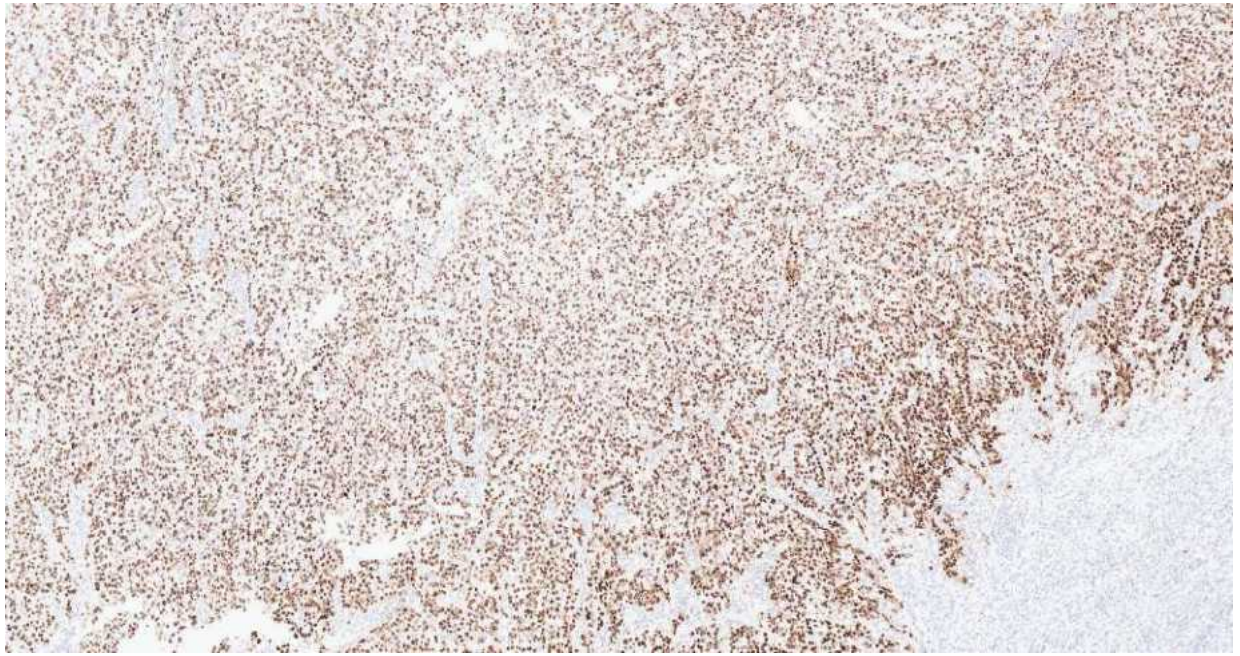

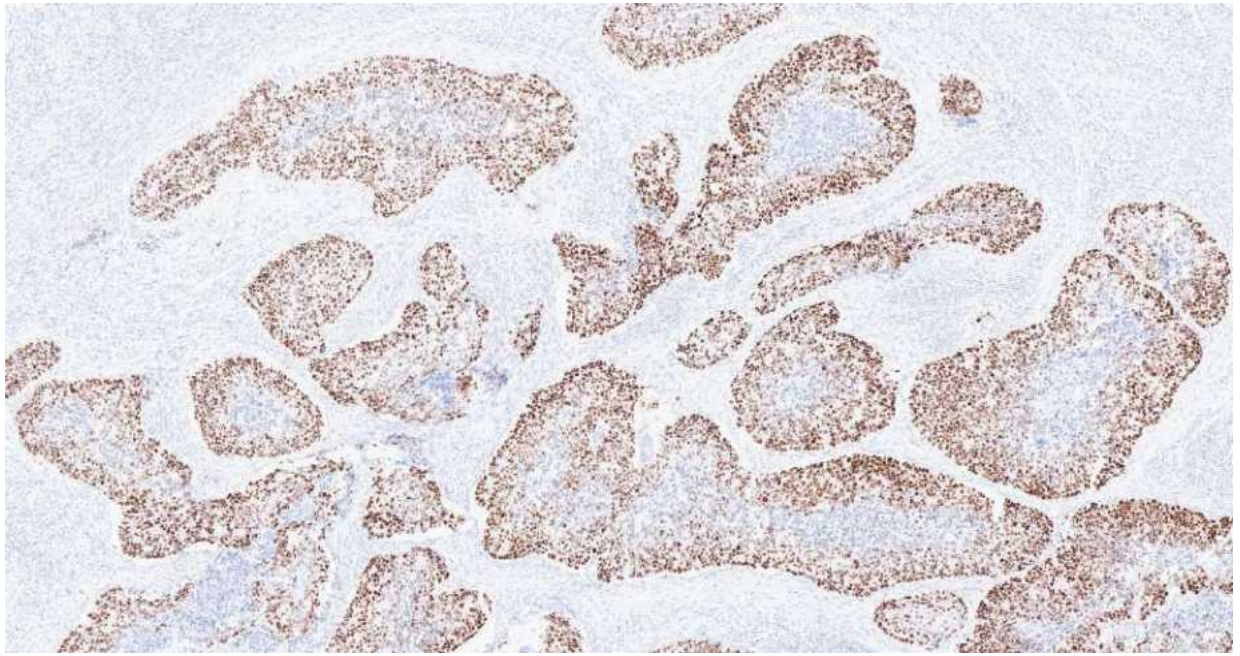

Case 5

- p16



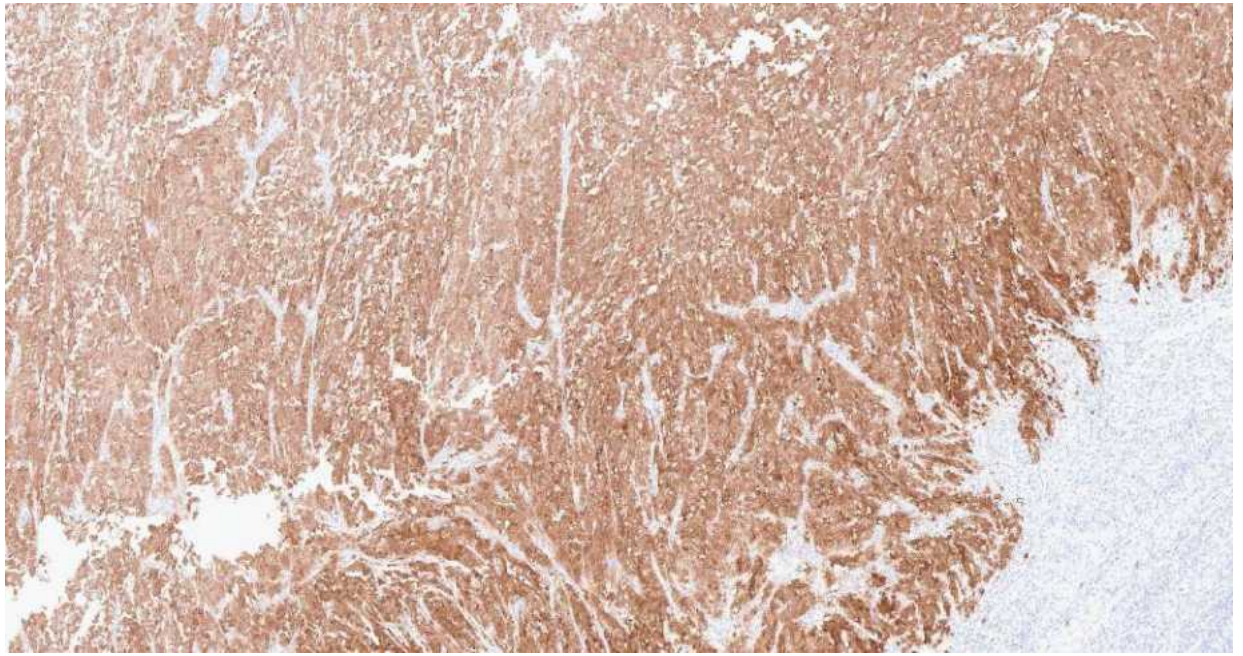

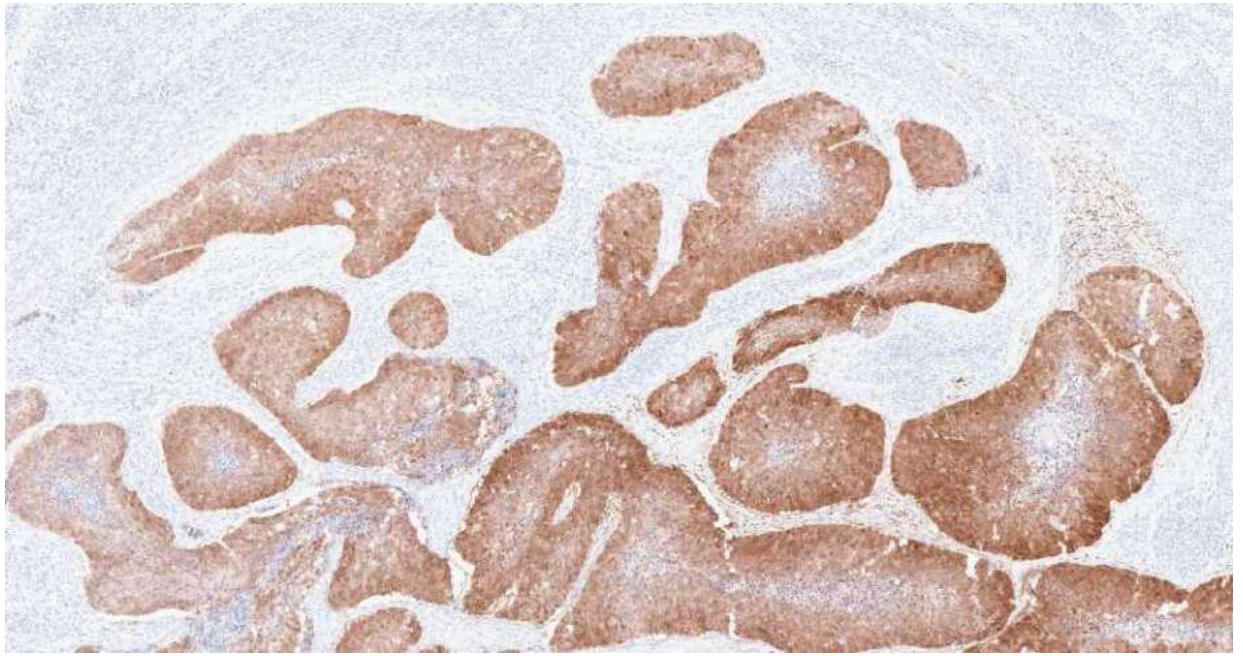

Case 5

- PAX8



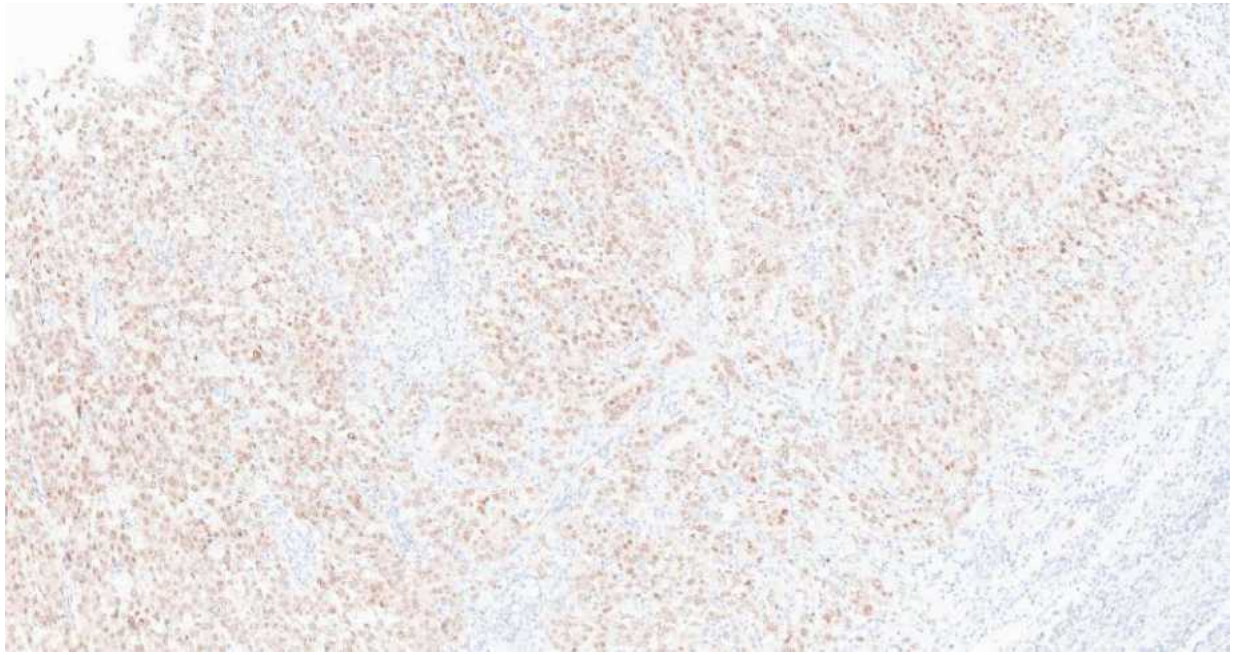

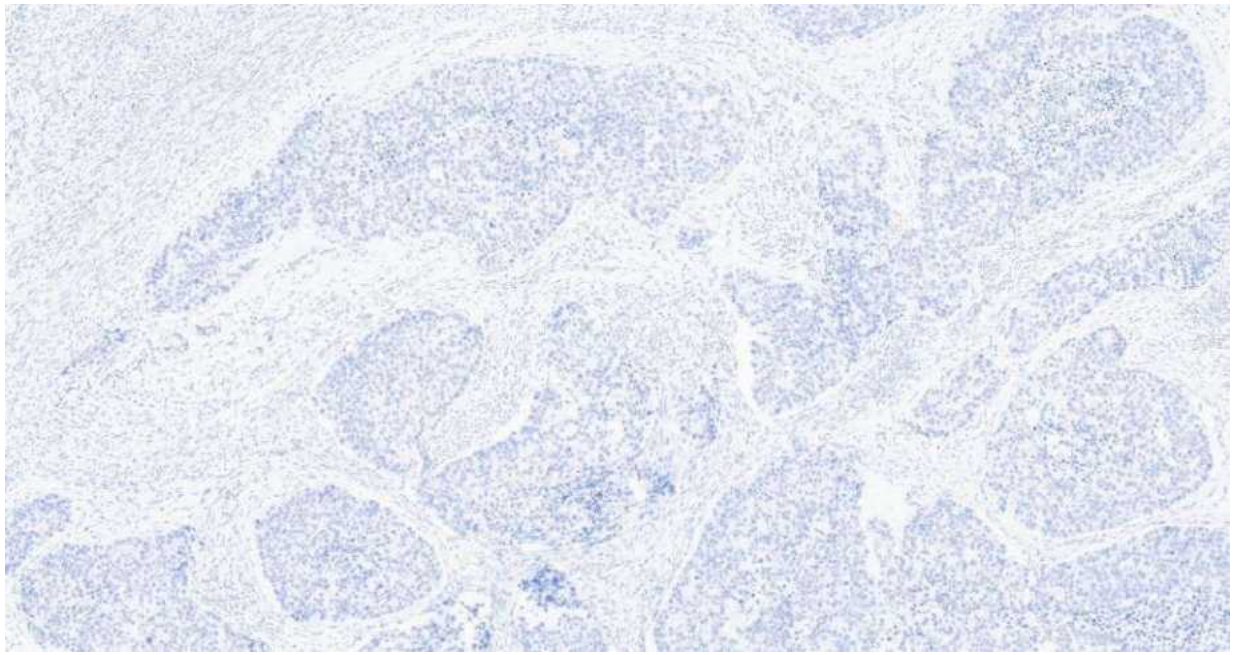

Case 5

- Cytokeratin (MNF116)

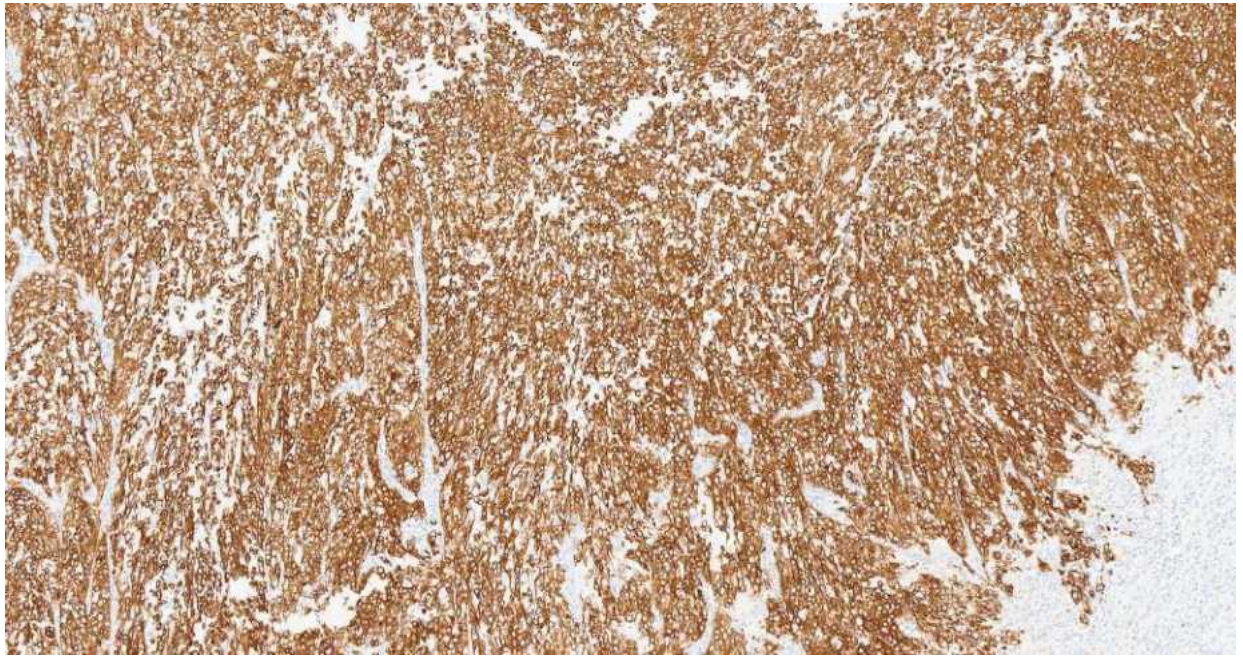

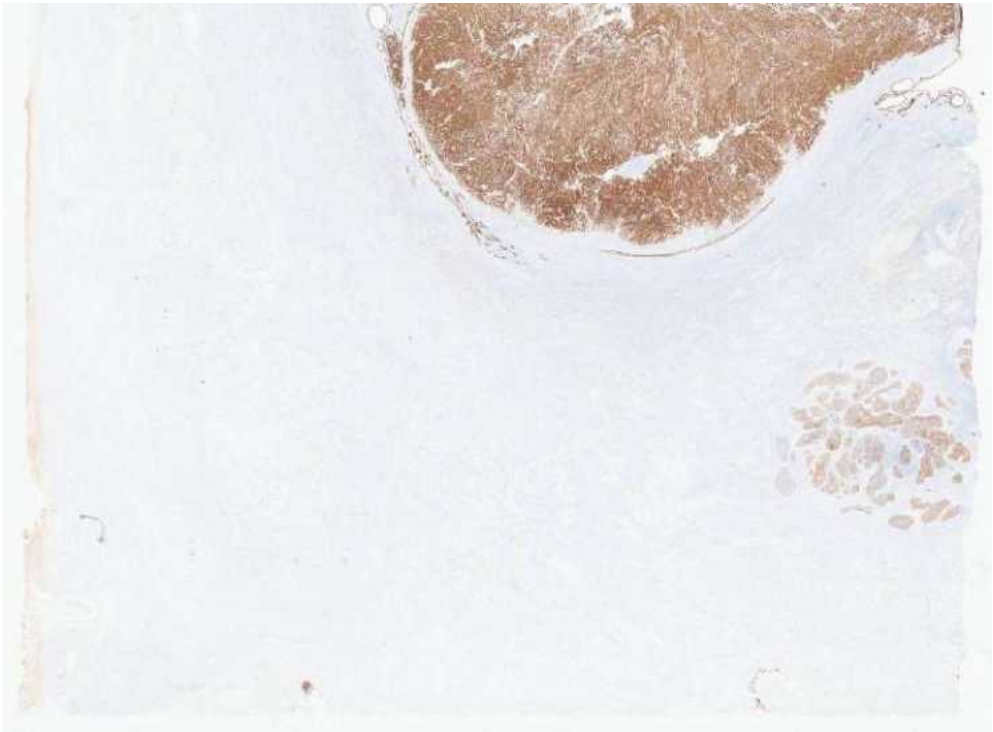

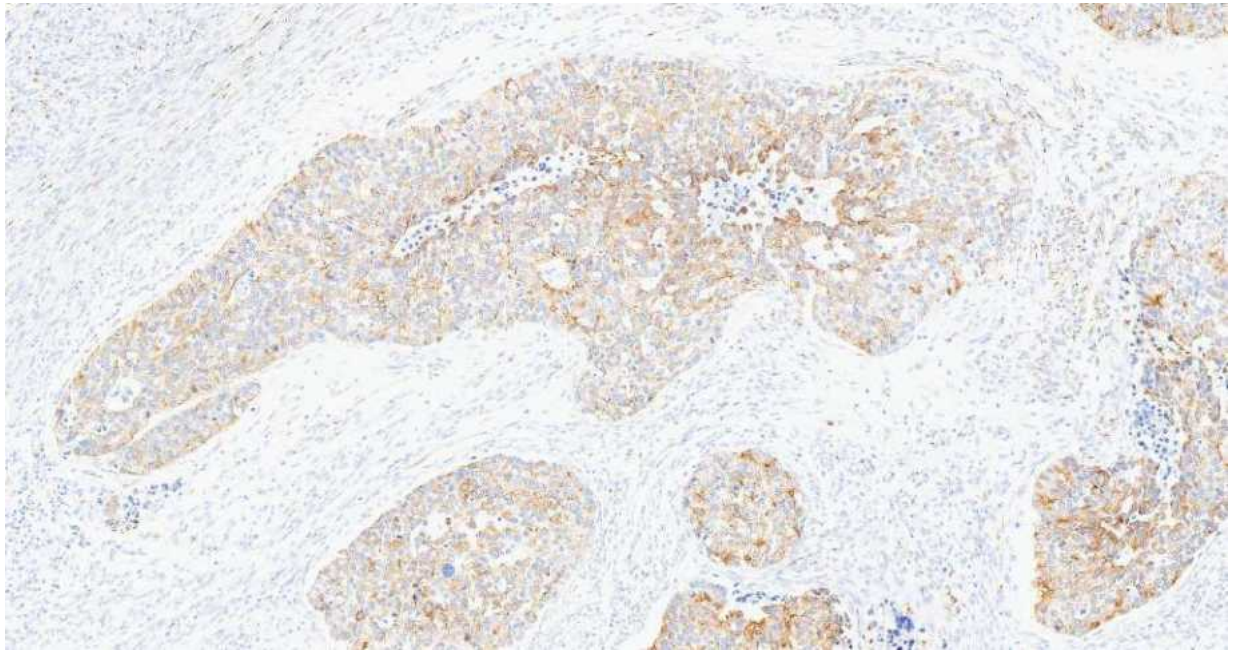

Case 5

- Napsin A

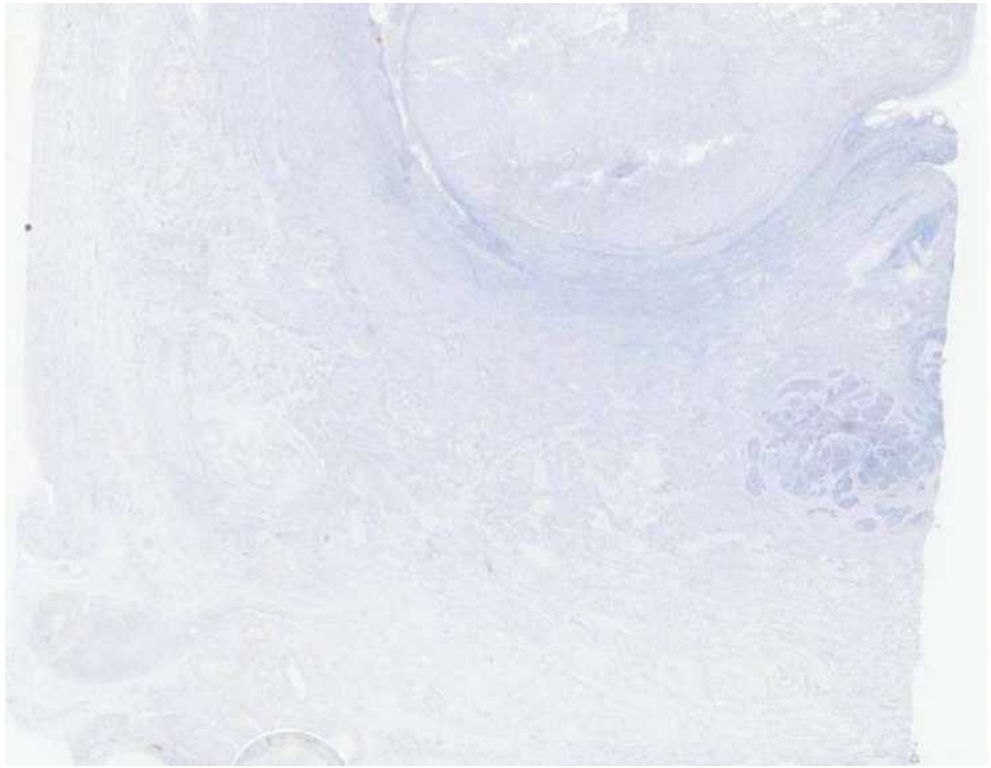



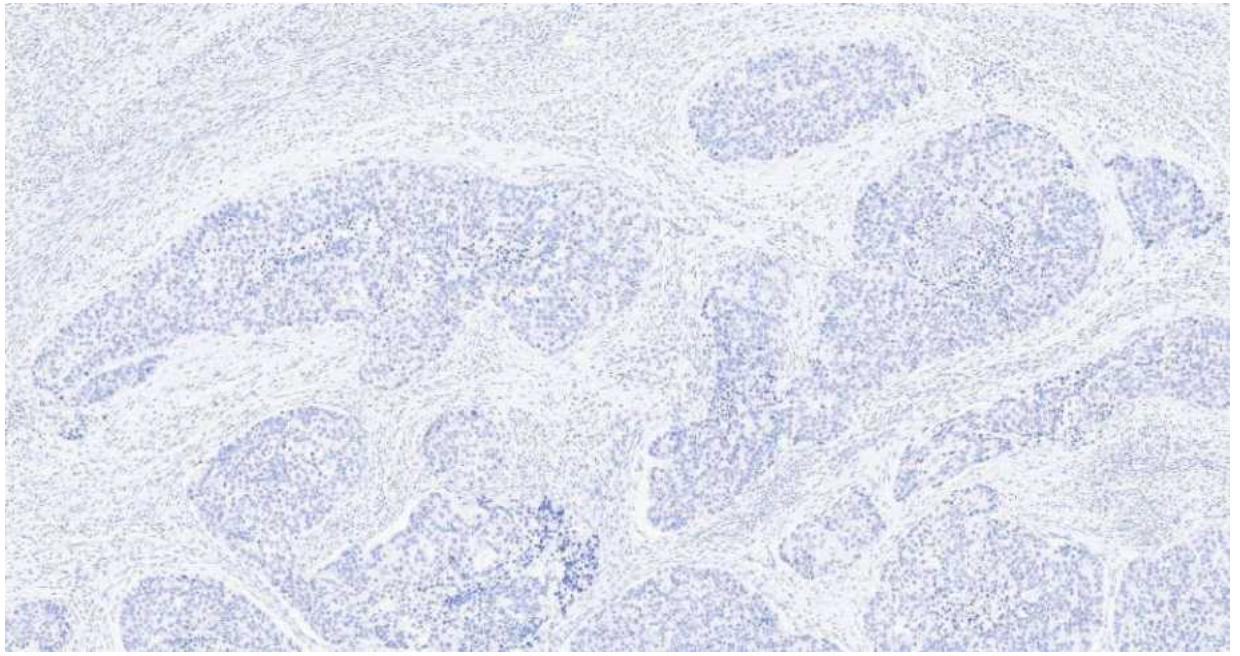

Case 5

- CDX2



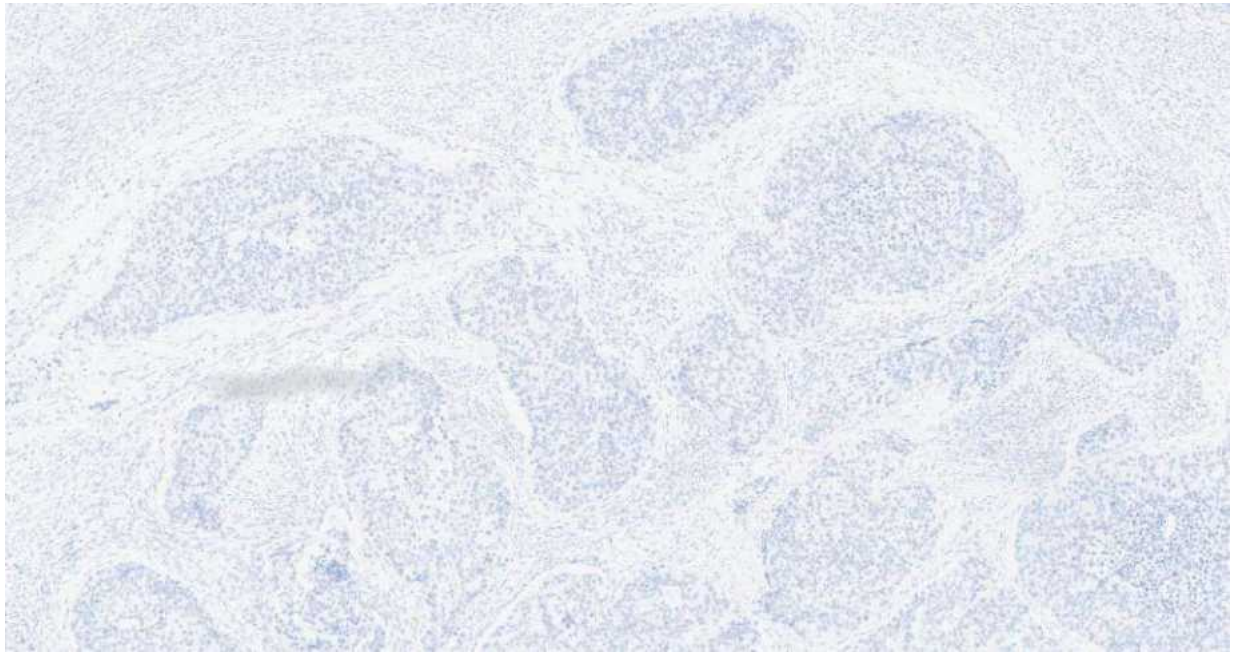

Case 5

- CK20

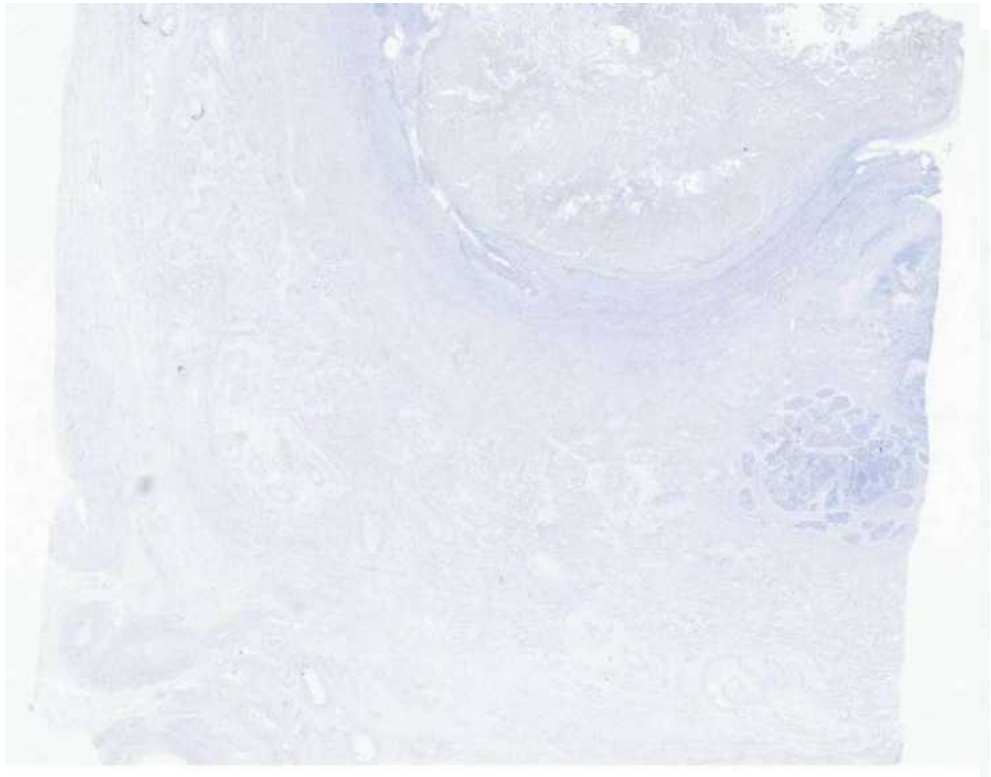

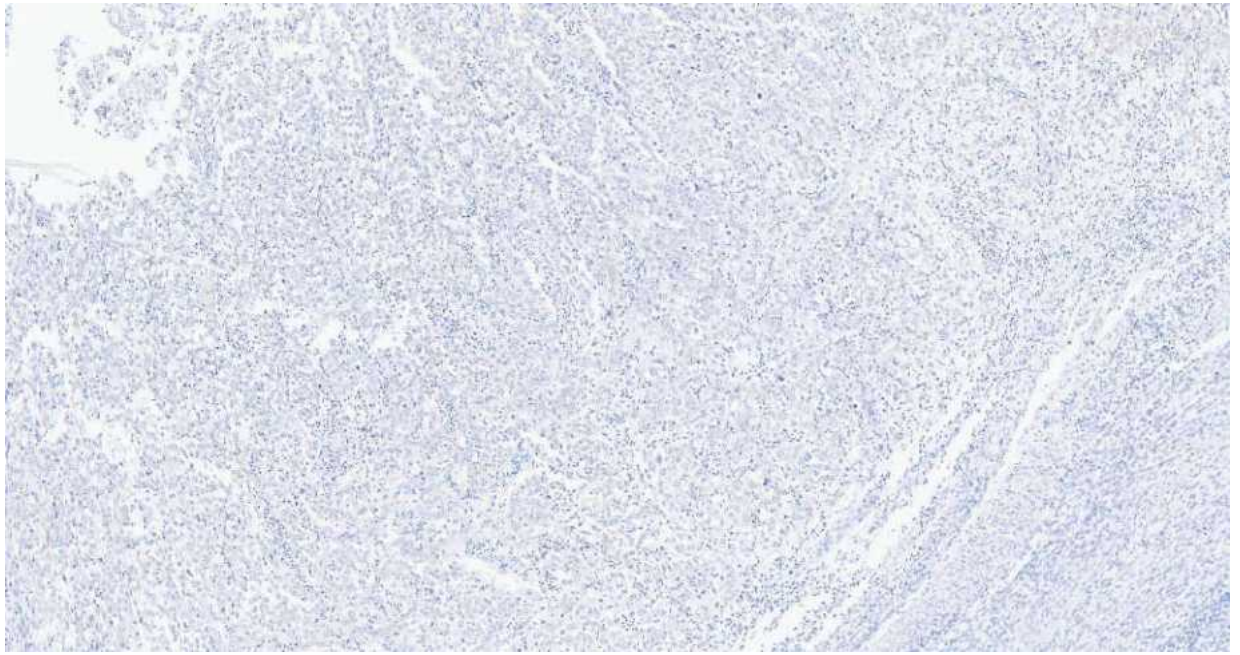

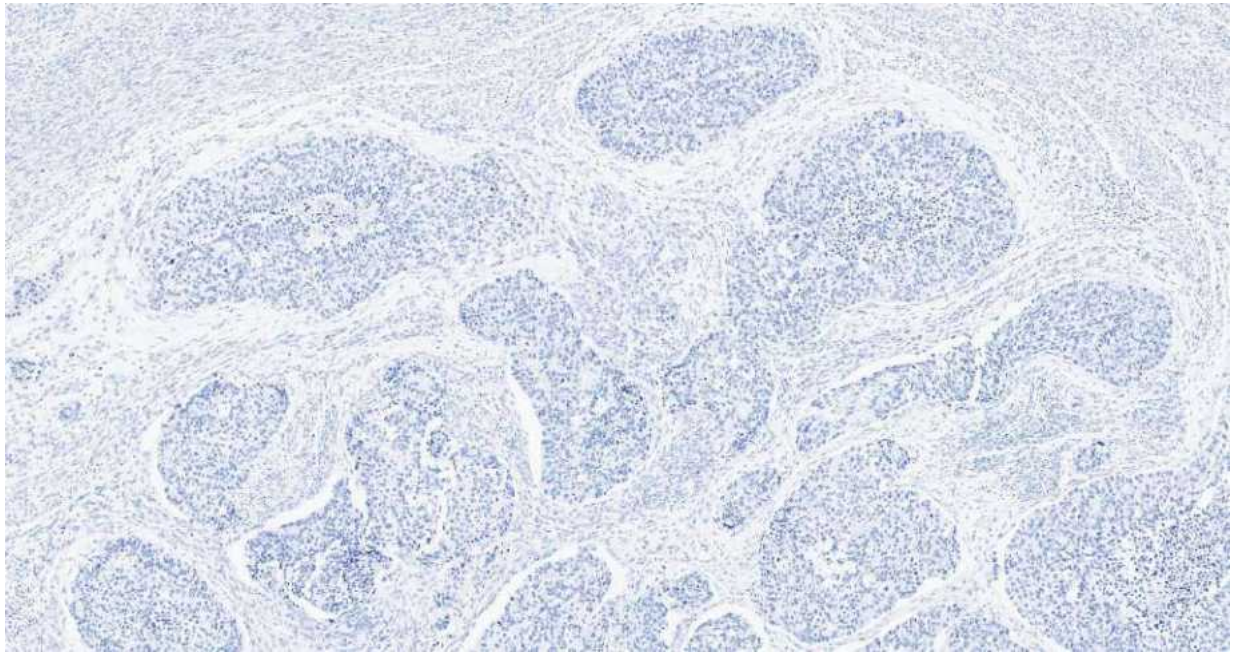

Case 5

- GATA3





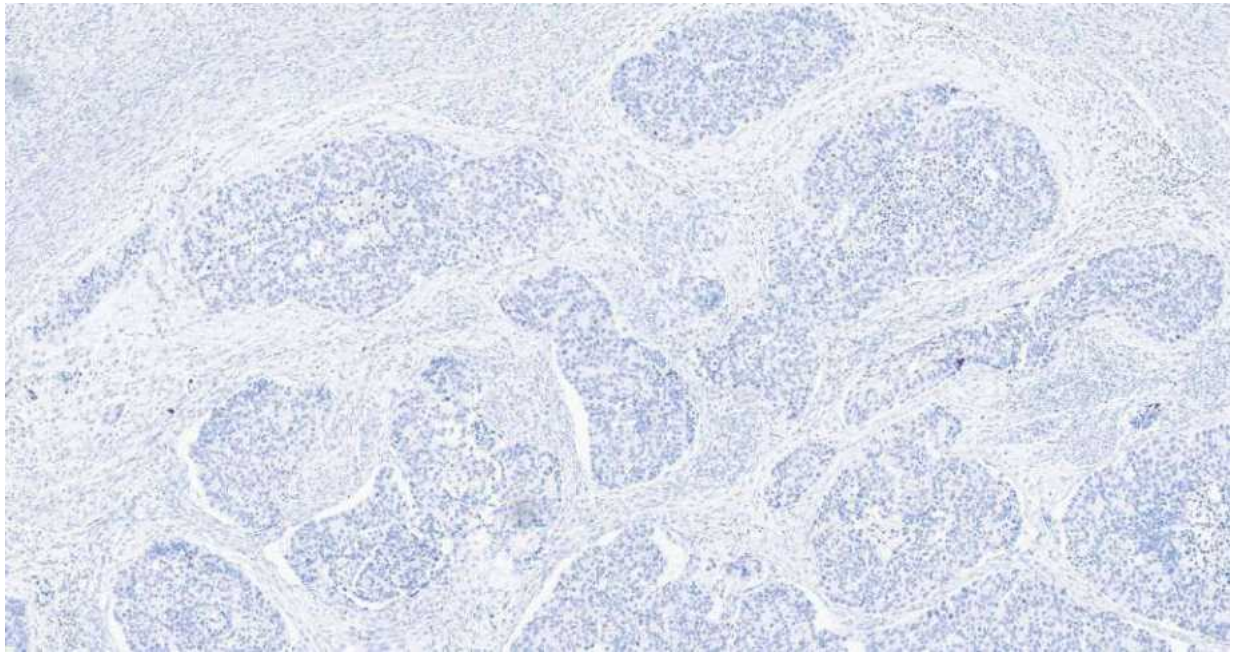

Case 5

- TTF1



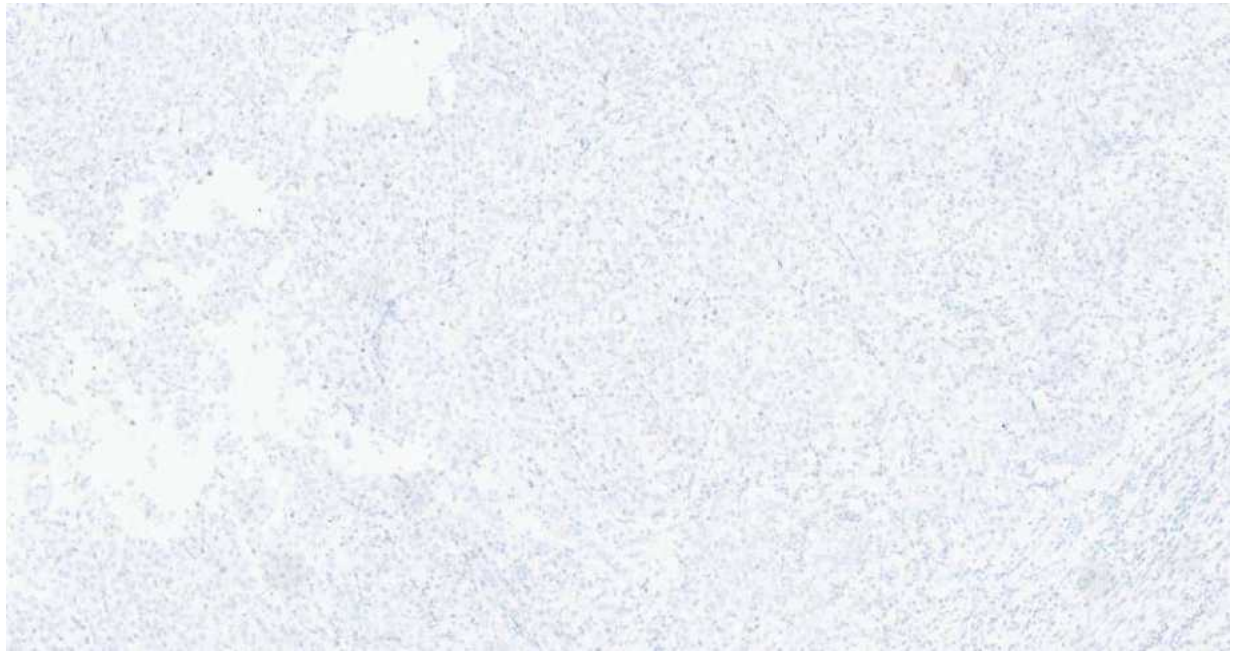

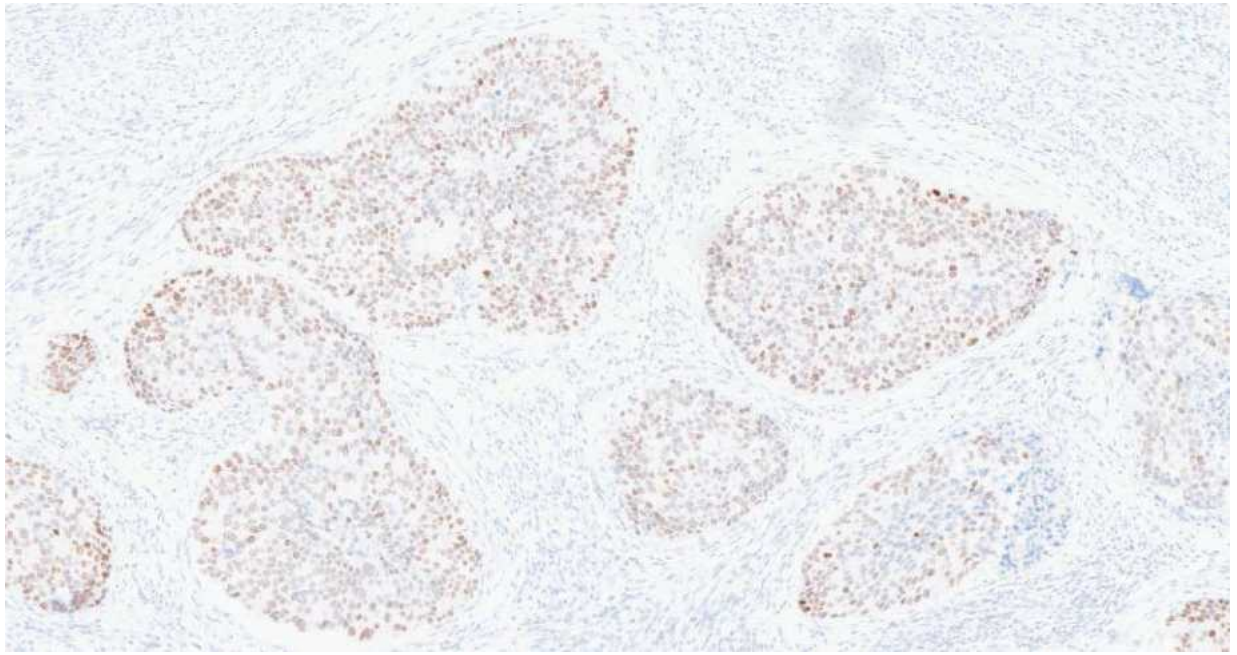

Case 5

- Synaptophysin

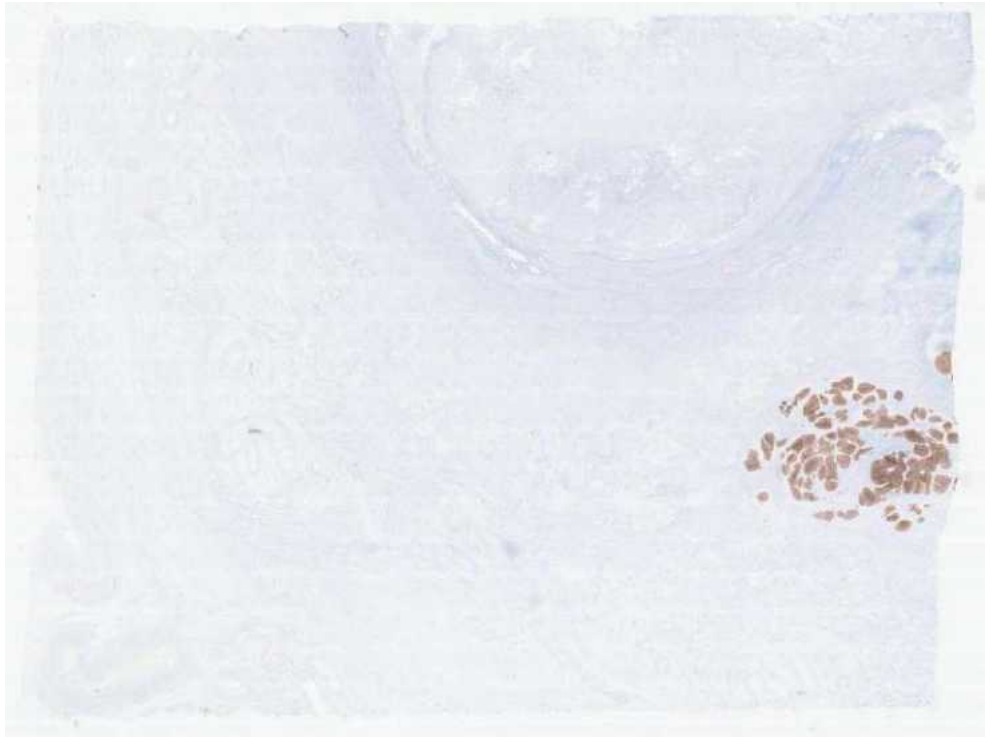



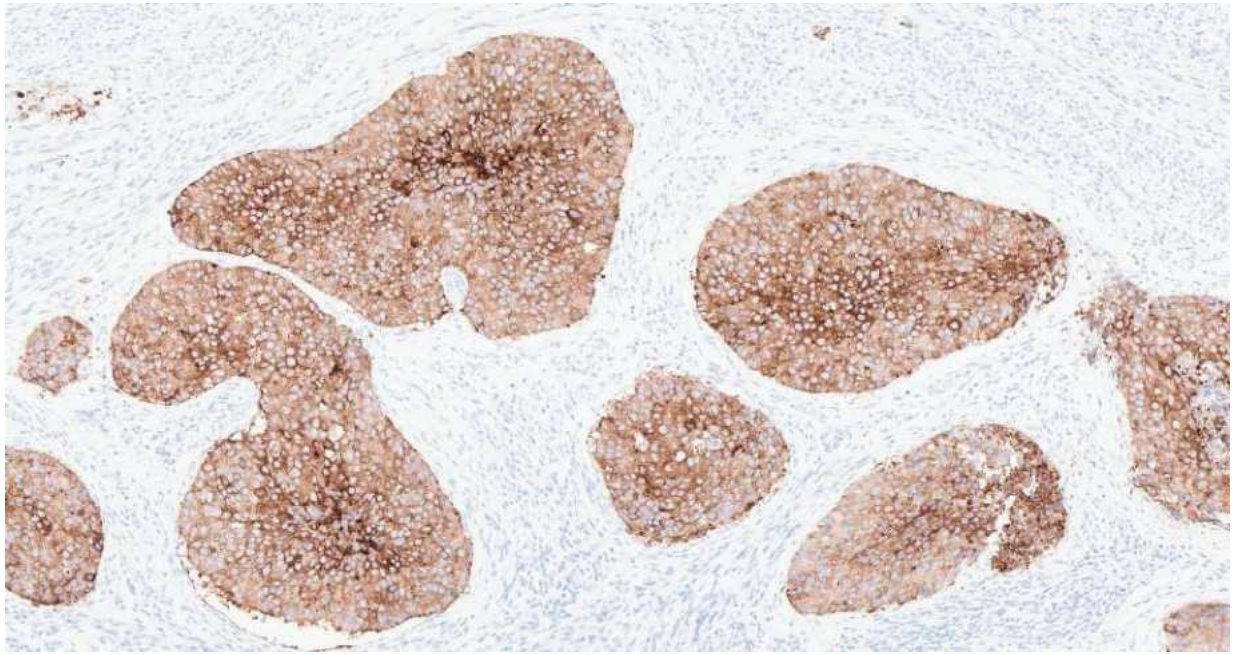

Case 5

- Chromogranin





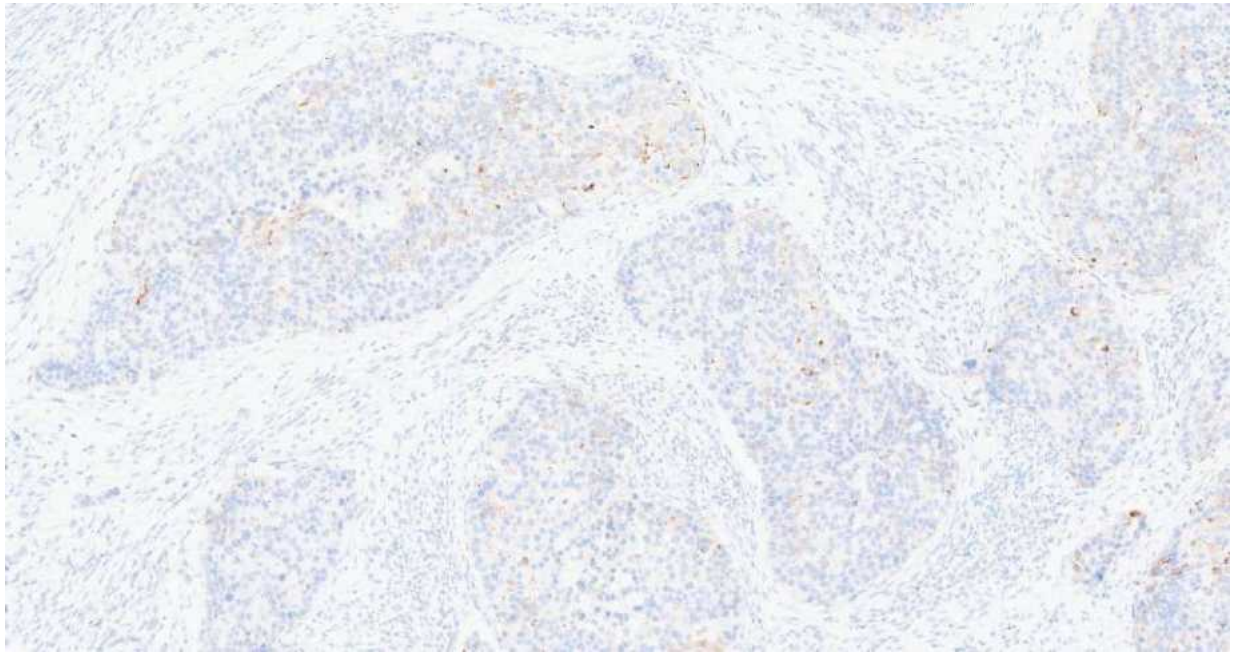

Case 5 – Pathological findings

- Two morphological patterns of cytologically high grade carcinoma cells in the uterine corpus (diffuse sheets and nests with rosette-like arrangement)

	Sheet-like component	Nested component
ER	Negative	Negative
p53	**Mutant (overexpression)**	**Mutant (overexpression)**
p16	**Diffuse**	**Diffuse**
PAX8	**Positive**	Negative
Cytokeratin (MNF116)	**Positive**	**Positive (weak)**
Napsin A, CDX2, CK20, GATA3	Negative	Negative
TTF1, Synaptophysin, Chromogranin	Negative	**Positive**

Case 5 – Diagnosis

- **Mixed serous and large cell neuroendocrine carcinoma**

	Serous carcinoma	Large cell neuroendocrine carcinoma
ER	Negative	Negative
p53	**Mutant (overexpression)**	**Mutant (overexpression)**
p16	**Diffuse**	**Diffuse**
PAX8	**Positive**	Negative
Cytokeratin (MNF116)	**Positive**	**Positive (weak)**
Napsin A, CDX2, CK20, GATA3	Negative	Negative
TTF1, Synaptophysin, Chromogranin	Negative	**Positive**

Neuroendocrine carcinoma of the endometrium

- Commonly associated with another histotype (mostly endometrioid or serous), occasionally as a pure histotype
- Morphology of small cell or large cell neuroendocrine carcinomas (some cases display mixed or overlapping features)
- Diagnosis requires neuroendocrine morphology and positivity for at least 1 neuroendocrine marker in at least 10% of tumour cells (synaptophysin, chromogranin, INSM1)
- TTF1 positivity may be seen
- p16 often diffuse (not useful in distinction from cervical origin)
- Often PAX8 negative
- Differential diagnosis:
  - Neuroendocrine carcinoma of the cervix
  - High grade endometrioid carcinoma
  - Undifferentiated/dedifferentiated carcinoma
  - Primitive neuroectodermal tumour

Pocrnich CE, Ramalingam P, Euscher ED, et al. Am J Surg Pathol 2016 (PMID: 26945341)
Howitt BE, Kelly P, McCluggage WG. Curr Oncol Rep 2017 (PMID: 28735441)

Neuroendocrine carcinomas of the endometrium may show small cell or large cell features (more commonly large cell based on the largest series)

ORIGINAL ARTICLE

Neuroendocrine Carcinoma of the Endometrium

A Clinicopathologic Study of 25 Cases

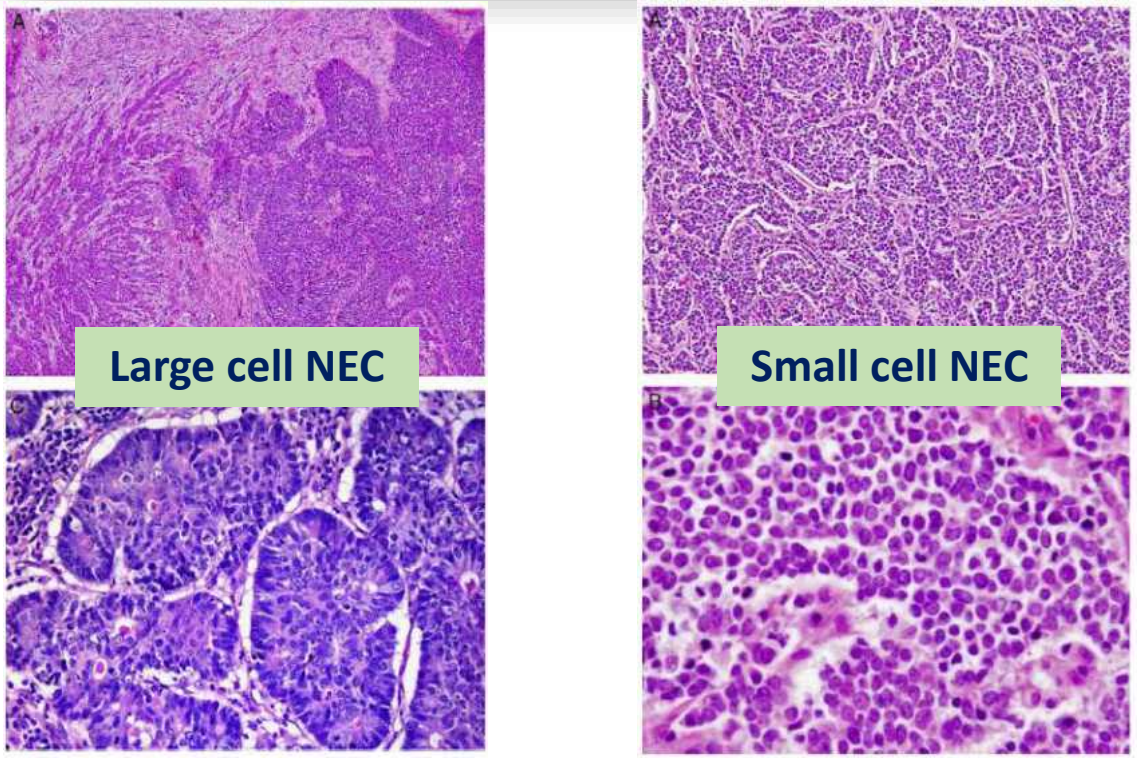

Pocrnich CE, Ramalingam P, Euscher ED, et al. Am J Surg Pathol 2016 (PMID: 26945341)

INSM1 is a sensitive and specific marker for neuroendocrine carcinomas of the female genital tract (24 endometrial cases included in this study)

ORIGINAL ARTICLE

INSM1 Is Less Sensitive But More Specific Than Synaptophysin in Gynecologic High-grade Neuroendocrine Carcinomas

An Immunohistochemical Study of 75 Cases With Specificity Test and Literature Review

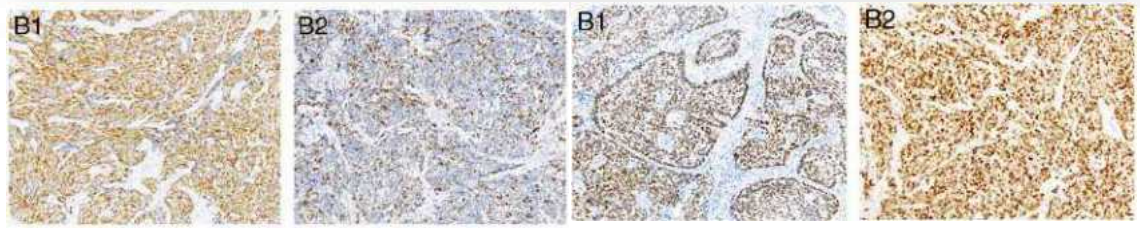

TABLE 4. Sensitivity and Specificity of INSM1, Chromogranin, Synaptophysin, and CD56 for Detecting Primary HGNECs in the Gynecologic Tract

Marker	Sensitivity (%)	Specificity (%)	Positive Predictive Value (%)	Negative Predictive Value (%)
INSM1	92	95	76	99
Chromogranin	81	82	44	96
Synaptophysin	96	81	47	99
CD56	59	75	29	91

Zou Q, Zhang L, Cheng Z, et al. Am J Surg Pathol 2021 (PMID: 33264139)

Neuroendocrine markers may be expressed in conventional types of endometrial carcinoma (usually focal but sometimes more extensive)

ANATOMICAL PATHOLOGY

Expression of neuroendocrine markers in non-neuroendocrine endometrial carcinomas

August W. Moritz[1], Matthew P. Schlumbrecht[2], Mehrdad Nadji[1], Andre Pinto[1]

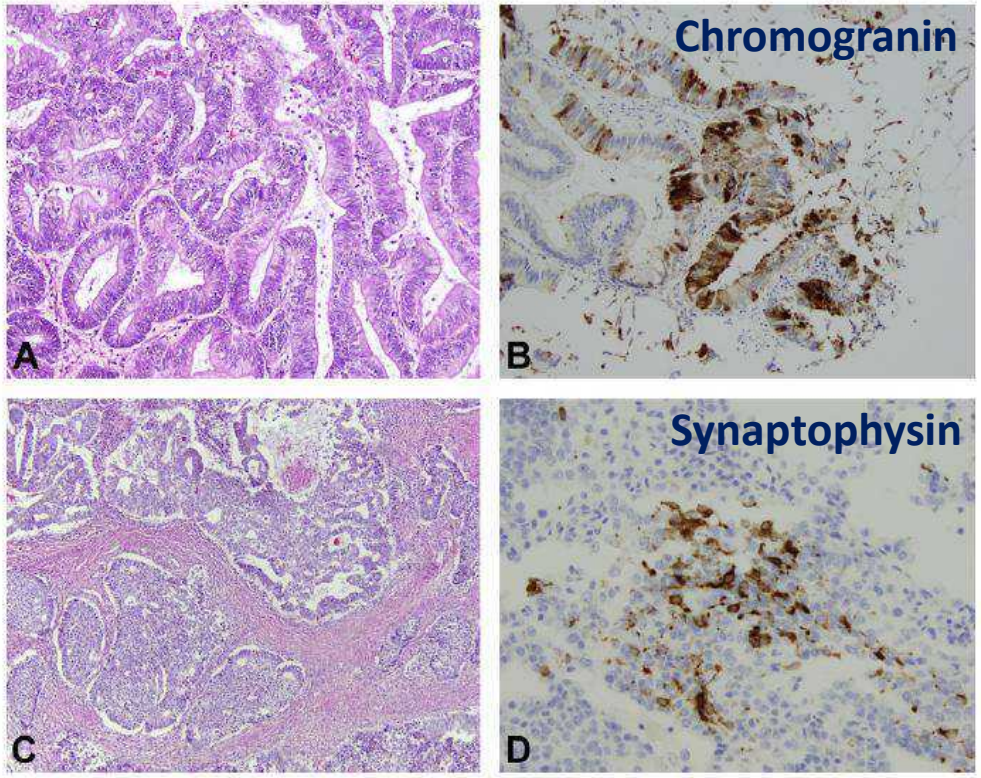

Moritz AW, Schlumbrecht MP, Nadji M, et al. Pathology 2019 (PMID: 31040050)

Undifferentiated carcinomas of the endometrium usually express neuroendocrine markers in a focal manner (<10% of tumour cells)

Endometrial neuroendocrine carcinoma and undifferentiated carcinoma are distinct entities with overlap in neuroendocrine marker expression

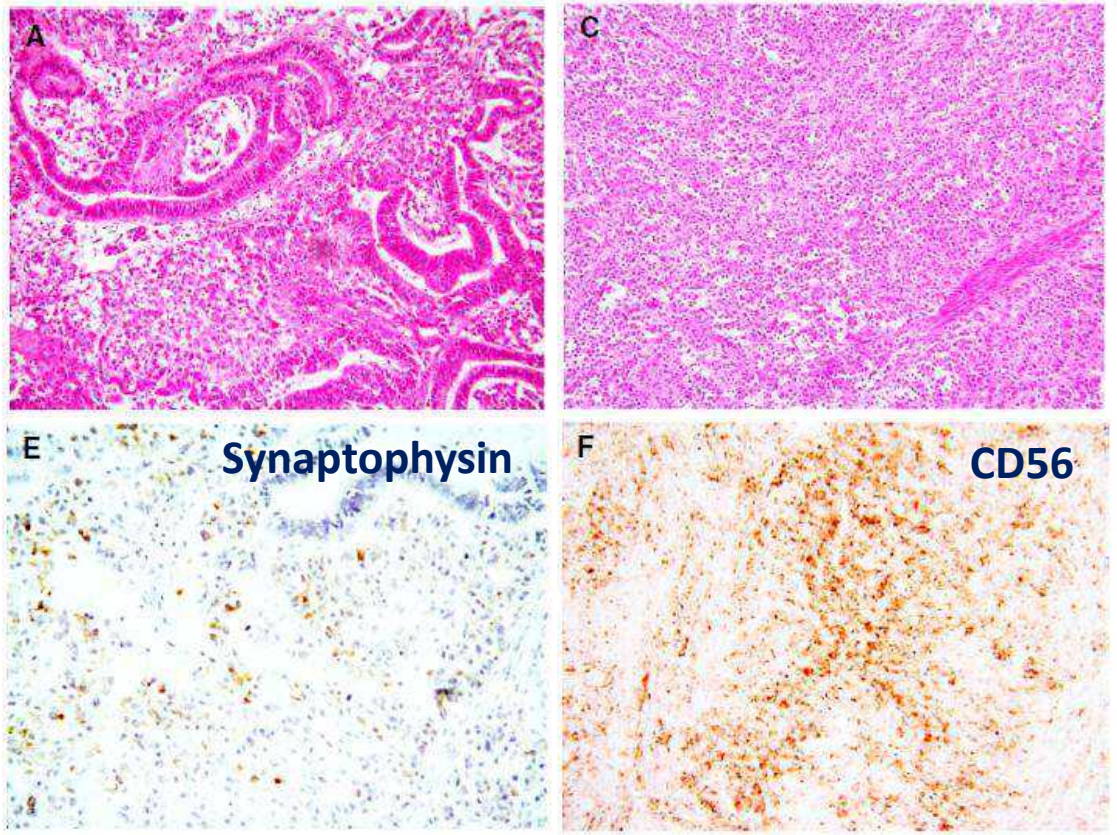

Tessier-Cloutier B, Kang EY, Alex D, et al. Histopathology 2022. (PMID: 35394077)

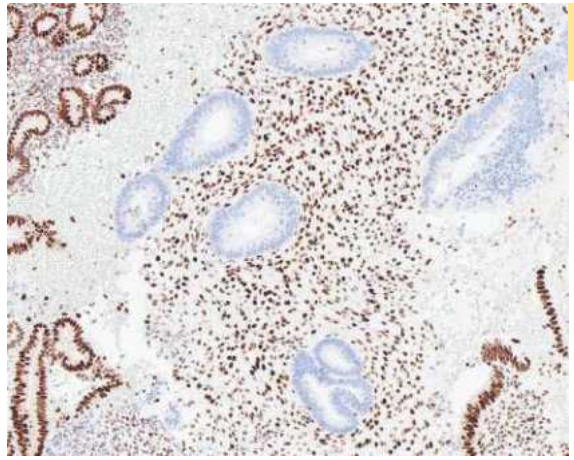

Mismatch repair deficient non-neoplastic endometrial glands

Cervical vs Endometrial squamous cell carcinoma

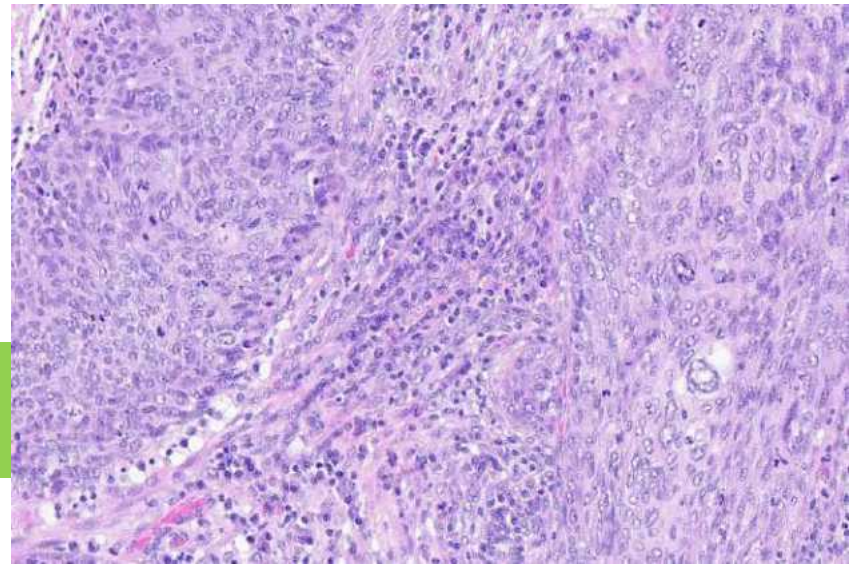

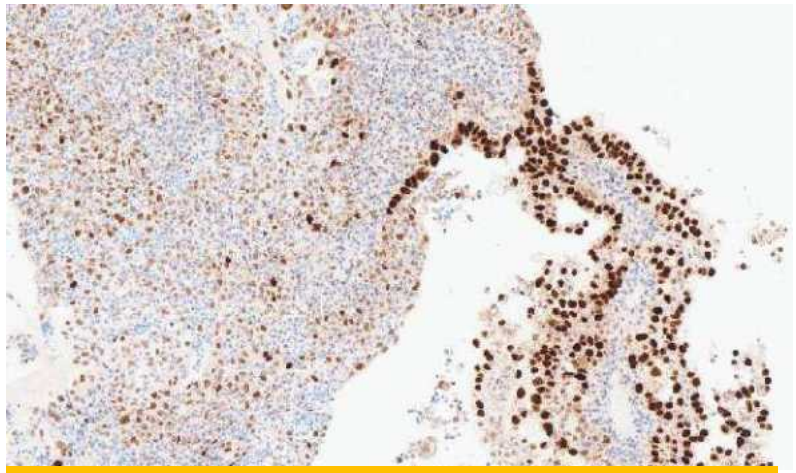

Subclonal p53 and high grade endometrial carcinoma with mixed or ambiguous features

Thank you!

Hope you find the cases interesting and relevant to your daily diagnosis!

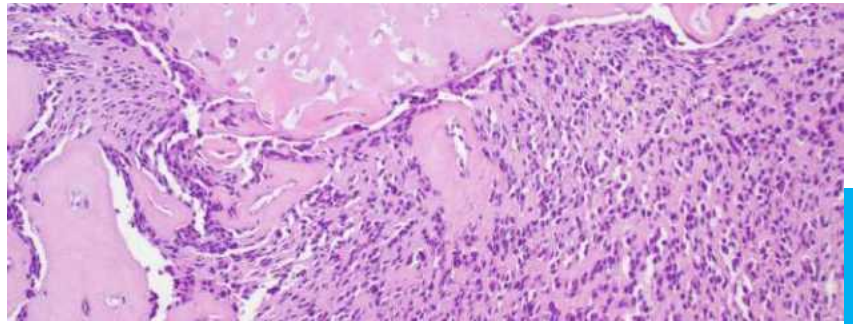

Large cell neuroendocrine carcinoma

Corded and hyalinized endometrioid carcinoma with osseous metaplasia

