The British Association of Gynaecological Pathologists

Lecturer – Prof W Glenn McCluggage



I am a consultant Histopathologist in Belfast Health and Social Care Trust, Belfast and an Honorary Professor in Gynaecological Pathology of Queen's University of Belfast. I have published over 680 papers in peer reviewed journals, including original publications and many invited editorials and reviews. I am on the Editorial Board of several major pathology journals (Modern Pathology, Human Pathology, Advances in Anatomic Pathology, International Journal of Gynecological Pathology, Virchows Archives), a member of the International Advisory Board of Journal of Clinical Pathology and associate editor of Histopathology. I am past President of International Society of Gynecological Pathologists and was previously secretary of this society. Previously I was President of the British Association of Gynaecological Pathologists. I have an extremely busy referral practice and receive numerous consultation cases from all over the world. I have been invited to lecture at numerous national and international meetings. I have authored or coauthored the various Royal College of Pathologists datasets in United Kingdom on reporting of gynaecological malignancies and have chaired the ICCR (International Collaboration on Cancer Reporting) panels developing international guidelines for reporting endometrial, ovarian, cervical, vulval and vaginal carcinomas. I am also the ICCR series champion for gynaecological neoplasms. I have been part of the last four World Health Organization (WHO) groups formulating the classification of Tumours of the Female Genital Tract and am one of the editors on the upcoming 2025/2026 WHO Classification.

The British Association of Gynaecological Pathologists

Practical Aspects of Endometrial Cancer Staging

- W Glenn McCluggage
- Dept of Pathology, Belfast Health and Social Care Trust, Belfast, UK

- 4/6/2025

The British Association of Gynaecological Pathologists

Speaker disclosures

- ❑ I have undertaken paid work for GSK

TO DISCUSS

- Brief history of FIGO staging of endometrial carcinoma
- “Traditional” versus “modern” staging systems
- Major changes in 2023 FIGO update
- Advantages of FIGO 2023
- Disadvantages of FIGO 2023
- What we have recommended in UK
- LVSI in endometrial carcinoma

HISTORY OF FIGO STAGING OF ENDOMETRIAL CARCINOMA

- Older FIGO staging systems for endometrial carcinoma were clinical
- First “surgical/pathological” staging system introduced in 1988
- Last FIGO revision was 2009 (so time for a change); 2009 also included updates to FIGO staging of cervical and vulval carcinomas and a new uterine sarcoma staging system
- FIGO 2009 staging was purely “anatomical”
- Prior revision changes to FIGO 2009 (from 1988) were relatively limited:-
  - Stage IA and IB combined into IA; old IC changed to IB
  - Stage II defined by cervical stromal involvement alone (previously cervical glandular involvement was IIA and stromal involvement IIB)
  - Stage IIIA- uterine serosal or adnexal involvement; IIIB- vaginal and/or parametrial involvement; IIIC- pelvic and/or para-aortic nodes (IIIC1-pelvic nodes; IIIC2- para-aortic nodes)
  - Stage IV (no changes)
  - Peritoneal washings were removed from staging system

INTERACTION BETWEEN FIGO AND TNM (UICC/ AJCC)

- Updates to FIGO are usually incorporated (without change) into TNM UICC and AJCC systems some time later
- UICC and AJCC ensure concordance with each other; some minor differences in terminology sometimes

“TRADITIONAL” VERSUS “MODERN” STAGING SYSTEMS

- Traditional cancer staging is a statement of the anatomical extent of disease at the time of presentation, determined by clinical, pathological, and radiological information; this allows easy comparison between all jurisdictions
- Original stage cannot be altered following treatment
- Globally accepted method is TNM; with gynaecological cancers, also have FIGO
- 6th (2002), 7th (2009) and 8th (2017) editions of the AJCC staging manual have progressively transitioned to staging systems that include histologic prognostic factors, biomarkers and molecular data (for example, breast, head and neck, prostatic carcinomas); currently most staging systems (including gynaecological carcinomas) do not use these non-anatomic parameters
- This new “integrated” approach aims to maintain the clinical relevance of staging by improving its prognostic value and leading to improved clinical decision making

PMID 37593813

J Gynecol Oncol. 2023 Sep;34(5):e85
https://doi.org/10.3802/jgo.2023.34.e85
pISSN 2005-0380·eISSN 2005-0399

JOURNAL OF GYNECOLOGIC ONCOLOGY

FIGO Staging Update

Check for updates

FIGO staging of endometrial cancer: 2023

Jonathan S. Berek,[1] Xavier Matias-Guiu,[2] Carien Creutzberg,[3] Christina Fotopoulou,[4] David Gaffney,[5] Sean Kehoe,[6] Kristina Lindemann,[7] David Mutch,[8] Nicole Concin,[9,10] Endometrial Cancer Staging Subcommittee, FIGO Women's Cancer Committee

MAJOR CHANGES IN FIGO 2023 UPDATE

- Incorporation of non-anatomic parameters (tumour type, tumour grade, LVSI, molecular parameters)
- Major changes to stages I, II, III, IV
- Essentially this could be described as a risk-stratification system rather than a true traditional staging system; this is what authors intend (stated that used ESGO/ ESTRO/ ESP guidelines as a template)

FIGO 2023- STAGE I

Stage I	Confined to the uterine corpus and ovary‡
IA	Disease limited to the endometrium OR non-aggressive histological type, i.e., low-grade endometroid, with invasion of less than half of myometrium with no or focal LVSI OR good prognosis disease
	IA1 Non-aggressive histological type limited to an endometrial polyp OR confined to the endometrium
	IA2 Non-aggressive histological types involving less than half of the myometrium with no or focal LVSI
	IA3 Low-grade endometrioid carcinomas limited to the uterus and ovary‡
IB	Non-aggressive histological types with invasion of half or more of the myometrium, and with no or focal LVSI§
IC	Aggressive histological types‖ limited to a polyp or confined to the endometrium

CHANGES IN STAGE I

FIGO 2009 (AJCC 8TH ED)	FIGO 2023
Stage I *	
Defined as tumour confined to the uterine corpus.	Defined now by a combination of the following features: Histological type, myometrial invasion (presence and extent into inner versus outer half), absent or focal LVSI.
Subdivided as IA (myometrial invasion absent or <50% of the uterine wall) and IB (myometrial invasion ≥50%).	Categorization as IA vs IB as defined in FIGO 2009 now only applies to non-aggressive histological types with no or focal LVSI.
Distinction between absent and <50% myometrial invasion is not necessary.	For non-aggressive histological types with no or focal LVSI, reintroduces distinction between cancer confined to the endometrium (now IA1) versus <50% myometrial invasion (now IA2) vs ≥50% myometrial invasion (IB).
	For aggressive histological types, introduces stage IC (aggressive histological types without myometrial invasion), and considers any myometrial invasion as stage IIC.
	Introduces ovarian involvement as allowed if the following criteria are present: Low grade endometrioid type; absent or superficial myometrial invasion (<50%); absent or focal LVSI; absence of additional metastases; the ovarian tumour is unilateral, limited to the ovary, without capsule invasion/rupture.

FIGO 2023- STAGE II

Stage II	Invasion of cervical stroma without extrauterine extension OR with substantial LVSI OR aggressive histological types with myometrial invasion
IIA	Invasion of the cervical stroma of non-aggressive histological types
IIB	Substantial LVSI[§] of non-aggressive histological types
IIC	Aggressive histological types[‖] with any myometrial involvement

CHANGES IN STAGE II

FIGO 2009 (AJCC 8TH ED)	FIGO 2023
Stage II *	
Defined as tumour confined to the uterus with invasion into the cervical stromal tissue.	Defined now by a combination of the following features: Cervical stromal involvement, substantial LVSI, and aggressive histological tumour type with myometrial invasion.
	Stage II is now subdivided in IIA (cervical stromal invasion by non-aggressive histological type), IIB (substantial LVSI by non-aggressive histological type), and IIC (aggressive histological type with any myometrial invasion).

FIGO 2023- STAGE III

Stage III	Local and/or regional spread of the tumor of any histological subtype
IIIA	Invasion of uterine serosa, adnexa, or both by direct extension or metastasis
	IIIA1 Spread to ovary or fallopian tube (except when meeting stage IA3 criteria)‡
	IIIA2 Involvement of uterine subserosa or spread through the uterine serosa
IIIB	Metastasis or direct spread to the vagina and/or to the parametria or pelvic peritoneum
	IIIB1 Metastasis or direct spread to the vagina and/or the parametria
	IIIB2 Metastasis to the pelvic peritoneum
IIIC	Metastasis to the pelvic or para-aortic lymph nodes or both¶
	IIIC1 Metastasis to the pelvic lymph nodes
	IIIC1i Micrometastasis
	IIIC1ii Macrometastasis
	IIIC2 Metastasis to para-aortic lymph nodes up to the renal vessels, with or without metastasis to the pelvic lymph nodes
	IIIC2i Micrometastasis
	IIIC2ii Macrometastasis

CHANGES IN STAGE III

FIGO 2009 (AJCC 8TH ED)	FIGO 2023
Defined as spread outside of the uterus other than bladder/ intestinal lining, lymph nodes and distant sites.	**Defined as local and/or regional tumour spread.**
Groups tubo-ovarian and serosal tumour involvement as stage IIIA.	Stage IIIA is now subdivided in IIIA1 (spread to ovary or fallopian tube) and IIIA2 (involvement of uterine subserosa or spread through uterine serosa). Introduces the concept of “uterine subserosa”.
Defines vaginal and parametrial tumour involvement as stage IIIB.	Stage IIIB now includes pelvic peritoneum. It is subdivided in IIIB1 (metastasis or direct spread to vagina and/or parametria) and IIIB2 (metastasis to pelvic peritoneum).
Groups nodal micro and macrometastasis as stage IIIC1 (pelvic) and IIIC2 (para-aortic)	Stage IIIC1 (pelvic nodal spread) is now subdivided in IIIC1i (micrometastasis) and IIIC1ii (macrometastasis). Stage IIIC2 (para-aortic nodal spread) is now subdivided in IIIC2i (micrometastasis) and IIIC2ii (macrometastasis).

FIGO 2023- STAGE IV

Stage IV	Spread to the bladder mucosa and/or intestinal mucosa and/or distance metastasis
IVA	Invasion of the bladder mucosa and/or the intestinal/bowel mucosa
IVB	Abdominal peritoneal metastasis beyond the pelvis
IVC	Distant metastasis, including metastasis to any extra-or intra-abdominal lymph nodes above the renal vessels, lungs, liver, brain, or bone

CHANGES IN STAGE IV

FIGO 2009 (AJCC 8TH ED)	FIGO 2023
Groups abdominal peritoneal spread along with lungs, liver, brain, bone and inguinal or extrapelvic lymph nodes above renal vessels (stage IV B).	Separates abdominal peritoneal spread (now IVB) from lungs, liver, brain, bone and inguinal or extrapelvic lymph nodes above renal vessels (stage IVC).

FIGO Staging of Endometrial Carcinoma 2023

Molecular findings in patients with early endometrial cancer (Stages I and II after surgical staging)	Stage designation
POLEmut endometrial carcinoma, confined to the uterine corpus or with cervical extension, regardless of the degree of LVSI or histological type	Stage $IAm_{POLEmut}$
p53abn endometrial carcinoma confined to the uterine corpus with any myometrial invasion, with or without cervical invasion and regardless of the degree of LVSI or histological type	Stage $IICm_{p53abn}$

PMID 37935523

Review



FIGO 2023 endometrial cancer staging: too much, too soon?

W Glenn McCluggage ,[1] Tjalling Bosse,[2] C Blake Gilks ,[3] Brooke E Howitt,[4] Jessica N McAlpine,[5] Marisa R Nucci,[6] Joseph T Rabban,[7] Naveena Singh,[8] Karen L Talia,[9] Carlos Parra-Herran[10]

ADVANTAGES OF FIGO 2023

- Recognition that endometrial carcinoma is not a single disease
- Virtually all parameters needed for prognostication and management in a single system
- Different subcategories of stages will facilitate accrual of information on prognostic value and management
- Subcategorisation of nodal involvement based on size and statement that ITCs do not upstage (brings in line with TNM and some other FIGO systems)
- Separation of pelvic peritoneal involvement (IIIB2) from abdominal peritoneal involvement (IVB) likely to be useful
- Separation of tumours with synchronous uterine corpus and ovarian involvement into favourable and unfavourable prognostic groups (personally I do not think there is a lot of evidence for this)
- More prognostically significant stage by stage compared to FIGO 2009
- More significant differences in prognosis between stage I and II; stage II in FIGO 2009 was not much different than stage I

PMID 37748967

Original Research

Verification of the prognostic precision of the new 2023 FIGO staging system in endometrial cancer patients – An international pooled analysis of three ESGO accredited centres

Richard Schwameis [a], Francesco Fanfani [b,c], Christoph Ebner [d], Naomi Zimmermann [a], Inge Peters [b,c], Camilla Nero [b,c], Christian Marth [d], Robin Ristl [e], Katharina Leitner [d], Christoph Grimm [a], Felicitas Oberndorfer [f], Ilaria Capasso [b,c], Alain G. Zeimet [d], Stephan Polterauer [a], Giovanni Scambia [b,c], Anna Fagotti [b,c], Nicole Concin [d,*]

PMID 37748967

- 519 endometrial carcinoma patients
- Treated at 3 ESGO accredited centres in Austria/ Italy
- Compared staging using FIGO 2009 and FIGO 2023
- Stage shifts in 26.7%
- 23.7% upshifts (mostly stage I to II); 3.9% downshifts (mostly *POLE* tumours)
- Higher prognostic precision in FIGO 2023 compared to FIGO 2009

OLU FADARE- LETTER IN AJSP (PMID: 38117288)

- 1169 cases of endometrial cancer
- 82.3%, 100%, 100%, 100% of cases which were stage I, III, III, IV in FIGO 2009 remain in same stage in FIGO 2023
- Significant number of 2009 FIGO stage I moved to 2023 FIGO stage II
- FIGO stage I (76.7% (FIGO 2009) vs 63.1% (FIGO 2023))
- FIGO stage II (5.8% (FIGO 2009) vs 19.4% (FIGO 2023))
- Negligible impact on number of cases categorised as stage III or IV

DISADVANTAGES OF FIGO 2023

TOO MANY CHANGES

- Many more categories (increase from 9 to 21 compared to FIGO 2009)
- Complicated/ non-intuitive; difficult for clinicians, pathologists, patients to grasp (the more categories, the easier it is to make a mistake)
- This may hinder adoption
- Will make comparisons between old and new patient cohorts extremely difficult and will result in problems in compiling useful data for clinical, epidemiologic and research (particularly clinical trial) purposes

DISADVANTAGES OF FIGO 2023

PREMATURE USE OF EVOLVING AND CONTROVERSIAL VARIABLES

- Definitions are still evolving for some parameters
- Considerable interobserver variability with regard to some parameters
- Examples are:- substantial LVSI; distinction between superficially myoinvasive tumour and one confined to the endometrium
- Lumping of “aggressive” histological types (not all are the same)

SYNCHRONOUS UTERINE CORPUS AND OVARIAN ENDOMETRIOID CARCINOMAS

- Different definitions for “good prognosis” synchronous uterine corpus and ovarian endometrioid carcinomas
- Bilateral ovarian involvement is a criterion of unfavourable outcome in the 2023 FIGO, ICCR and ISGyP Endometrial Cancer Project recommendations but not in the 2020 WHO classification
- LVSI qualifiers (focal vs substantial) are used by 2023 FIGO and WHO but not by ICCR and ISGyP recommendations
- Precursors to endometrioid carcinoma in the endometrium (atypical hyperplasia) and in the ovary (endometriosis, adenofibroma) are among the criteria for classification of favourable outcome by ICCR and ISGyP recommendations but not WHO or 2023 FIGO
- FIGO update fails to provide evidence in favour of their approach rather than the approach used in other recommendations

DISADVANTAGES OF FIGO 2023

MOLECULAR PARAMETERS

- incorporation of molecular parameters essentially precludes staging as proposed in resource-poor settings (even immunohistochemistry may not be available)
- molecular testing sometimes not readily available in good time even in developed countries
- methodology for determining the molecular group is not specified

DISADVANTAGES OF FIGO 2023

UNNECESSARY REDUPLICATION OF RISK STRATIFICATION MODELS

- FIGO 2013 is very similar to ESGO/ ESTRO/ ESP 2021 guidelines (in fact, these were used as a template)
- ? Stage should be an element of “risk-stratification” rather than the “risk-stratification”

DISADVANTAGES OF FIGO 2023

LESS APPLICABILITY AND ADOPTION BY STAKEHOLDERS

- Concern that new FIGO staging system will confuse patients and clinicians
- Potential to frustrate those who are only recently coming to terms with the value added by molecular typing
- Potential to cause frustration and anxiety to those who lack the tools (molecular testing, immunohistochemistry) to implement the staging system as proposed
- In discussing a historical clinical trial with a patient, extensive explanation of stage differences will be required, and it is unlikely that interpretation of treatment efficacy will be possible
- Assigned stage potentially changing at different points during the patient's cancer journey (may cause confusion to patient)

SCENARIO

- a hysterectomy specimen deemed to have a grade 2 endometrioid carcinoma (no substantial LVSI) with invasion into the outer half of the myometrium (stage IB)
- reviewed at a local cancer centre where the tumour is considered grade 3, and therefore assigned FIGO stage IIC
- when molecular classification results become available and a pathogenic *POLE* mutation is identified, the same patient has stage changed to stage IAm$_{POLE\text{mut}}$

ANOTHER SCENARIO

- a hysterectomy specimen deemed to have a grade 2 endometrioid carcinoma (no substantial LVSI) with invasion into the outer half of the myometrium (stage IB)
- reviewed at a local cancer centre where the tumour is considered to exhibit substantial LVSI and therefore assigned FIGO stage IIB
- when molecular classification results become available and a pathogenic *POLE* mutation is identified, the same patient has stage changed to stage IAm$_{POLE\text{mut}}$

DISADVANTAGES OF FIGO 2023

LACK OF CONSULTATION WITH THE PATHOLOGY COMMUNITY (AND OTHERS)

- With new staging updates, a rigorous and formalised process of consultation with appropriate disciplines prior to formal publication should be expected
- Staging parameters in FIGO 2023 are largely pathological in nature (determined and reported by the pathologist); to this end, pathology representation on the committee that developed the 2023 FIGO update appears largely insufficient
- Absence of meaningful contribution by pathology societies (especially ISGyP) in the staging update development, discussion and publication is a major oversight
- Should have been substantial input by ISGyP

UNSETTLING TREND BY FIGO

- unsettling trend by FIGO of limiting and/or omitting pathologist's input in their staging updates
- most recent updates for carcinomas of the uterine cervix and vulva (both 2021) included no gynaecological pathologists

DISADVANTAGES OF FIGO 2023

RADIOLOGIST WILL NOT BE ABLE TO ASSIGN A PREOPERATIVE STAGE IN MANY CASES

- Need to know details about LVSI, molecular testing for full staging

UK BGCS/ BAGP RECOMMENDATIONS OCTOBER 2023

- The BAGP and BGCS recommend continuing to use the 2009 FIGO endometrial cancer staging system in the UK; we do not recommend use of the 2023 FIGO system at the current time
- Only 35% of UK core MDT (tumour board) members want the FIGO 2023 system to be implemented, compared to 41% who do not
- Deferring implementation should have no impact on patient management as the parameters included in the new FIGO 2023 system are already incorporated into current risk stratification and treatment algorithms
- This decision will be reviewed within 12 months when new information, such as availability of *POLE* testing and feedback on the FIGO 2023 system from other learned societies, will be taken into account
- BAGP/BGCS support universal *POLE* testing in endometrial carcinomas

PMID 38937066

Histopathology

Histopathology 2024 DOI: 10.1111/his.15272

REVIEW

Practical guidance for assessing and reporting lymphovascular space invasion (LVSI) in endometrial carcinoma

Elke E M Peters,[1,2] Marisa R Nucci,[3] C Blake Gilks,[4] W Glenn McCluggage[5] & Tjalling Bosse[2]

[1]Department of Pathology, Haaglanden Medical Centre, The Hague, [2]Department of Pathology, Leiden University Medical Center, Leiden, the Netherlands, [3]Division of Women's and Perinatal Pathology, Department of Pathology, Brigham and Women's Hospital/Harvard Medical School, Boston, MA, USA, [4]Department of Pathology and Laboratory Medicine, University of British Columbia, Vancouver, BC, Canada and [5]Department of Pathology, Belfast Health and Social Care Trust, Belfast, UK

PROGNOSTIC SIGNIFICANCE OF LVSI IN ENDOMETRIAL CARCINOMA

- Many studies (old and new) show that it is important; studies are difficult to compare due to markedly different designs
- Independent predictor of pelvic nodal metastasis
- Independent predictor of local recurrence and distant metastasis
- Decisions on adjuvant therapy based on LVSI (sometimes whether present or not; sometimes no/ focal versus substantial/ extensive)
- ESGO/ESTRO/ESP 2020 risk stratification incorporates substantial LVSI
- Evidence that extent of LVSI is more prognostically important in stage I disease rather than just presence or absence

PMID 34392268

International Journal of Gynecological Pathology
41:227–234, Lippincott Williams & Wilkins, Baltimore
Copyright © 2021 by the International Society of Gynecological Pathologists

Original Article

Substantial Lymphovascular Space Invasion Is an Adverse Prognostic Factor in High-Risk Endometrial Cancer

Elke E.M. Peters, M.D., Alicia Léon-Castillo, M.D., Estrid Hogdall, Ph.D., Marie Boennelycke, M.D., Vincent T.H.B.M. Smit, M.D., Ph.D., Claus Hogdall, M.D., Ph.D., Carien L. Creutzberg, M.D., Ph.D., Tjalling Bosse, M.D., Ph.D., Remi A. Nout, M.D., Ph.D., and Gitte Ørtoft, M.D., Ph.D.

PMID 34392268

- Aimed to determine whether extent of LVSI is prognostic in endometrial cancer
- Danish Gynaecological Cancer Database cohort
- 376 patients
- LVSI assessed by 4 pathologists
- Found that in “high-risk” endometrial cancer, substantial LVSI is an independent factor for nodal metastasis, distant metastasis and survival
- Extent of LVSI should be incorporated into reporting and should be used as a factor determining adjuvant treatment

ESGO-ESTRO-ESP Risk Stratification for Endometrial Carcinoma 2021: PMID 33397713, 33604759 , 33712263

Management guidelines

ESGO/ESTRO/ESP guidelines for the management of patients with endometrial carcinoma

Nicole Concin, Xavier Matias-Guiu, Ignace Vergote, David Cibula, Mansoor Raza Mirza, Simone Marnitz, Jonathan Ledermann, Tjalling Bosse, Cyrus Chargari, Anna Fagotti, Christina Fotopoulou, Antonio Gonzalez Martin, Sigurd Lax, Domenica Lorusso, Christian Marth, Philippe Morice, Remi A Nout, Dearbhaile O'Donnell, Denis Querleu,Maria Rosaria Raspollini, Jalid Sehouli, Alina Sturdza, Alexandra Taylor, Anneke Westermann, Pauline Wimberger, Nicoletta Colombo, François Planchamp, Carien L Creutzberg

Prognostic risk groups

Risk group	Molecular classification unknown	Molecular classification known
Low	• Stage IA endometrioid + low-grade + LVSI neg/focal	• Stage I–II POLEmut EC[†] • Stage IA MMRd/NSMP EC + low-grade + LVSI neg/focal
Intermediate	• Stage IB endometrioid + low-grade + LVSI neg/focal • Stage IA endometrioid + high-grade[‡] + LVSI neg/focal • Stage IA non-endometrioid (serous, clear cell, undifferentiated carcinoma, carcinosarcoma, mixed) without myometrial invasion	• Stage IB MMRd/NSMP EC + low-grade + LVSI neg/focal • Stage IA MMRd/NSMP EC + high-grade + LVSI neg/focal • Stage IA p53abn and/or non-endometrioid (serous, clear cell, undifferentiated carcinoma, carcinosarcoma, mixed) without myometrial invasion
High-intermediate	• Stage I endometrioid + substantial LVSI any • Stage IB endometrioid high-grade LVSI any • Stage II	• Stage I MMRd/NSMP EC + substantial LVSI any • Stage IB MMRd/NSMP EC high-grade LVSI any • Stage II MMRd/NSMP EC
High	• Stage III–IVA with no residual disease • Stage I–IVA non-endometrioid (serous, clear cell, undifferentiated carcinoma, carcinosarcoma, mixed)*[†]	• Stage III–IVA MMRd/NSMP EC[†] • Stage I–IVA p53abn EC*[†] • Stage I–IVA NSMP/MMRd serous, undifferentiated carcinoma, carcinosarcoma*[†]
Advanced metastatic	• Stage III–IVA with residual disease • Stage IVB	• Stage III–IVA with residual disease of any molecular type • Stage IVB of any molecular type

ESGO-ESTRO-ESP Risk Stratification

- Presence of substantial LVSI affects adjuvant treatment recommendations in stage I endometrioid carcinoma in MMRd and NSMP groups

PMID 37666529



Original research

Prognostic value of lymphovascular space invasion according to the molecular subgroups in endometrial cancer

Franziska Siegenthaler ,[1] Elisabeth Epstein,[2] Carol A Büchi,[1] Andrea Gmür,[1]
Flurina A C M Saner ,[1] Tilman T Rau,[3] Joseph W Carlson,[4] Michael D Mueller,[1] Sara Imboden[1]

PMID 37666529

- Investigated prognostic value of LVSI in different TCGA molecular groups of endometrial cancer
- 589 patients (**17% exhibited LVSI**) (**25% of *POLE*; 19% of MMRd; 30% of p53 abnormal; 10% NSMP)**
- In whole cohort, significant correlation of lymph node metastasis and tumour stage with LVSI; significant in MMRd, p53 abnormal, NSMP groups (not *POLE*)
- LVSI significantly associated with decreased recurrence free survival in MMRd, p53 abnormal, NSMP groups (not *POLE*)
- LVSI significantly associated with decreased overall survival in p53 abnormal and NSMP groups
- In NSMP group, substantial LVSI remained an independent predictor of recurrence in multivariate analysis; this has also been shown for MMRd endometrial cancers in other studies
- **In stage I endometrioid carcinomas, LVSI remained an independent predictor of recurrence in MMRd and NSMP cancers in multivariate analysis (supports ESGO/ ESTRO/ ESP recommendations)**

HYSTERECTOMY SPECIMENS

- LVSI incorporated into most international guidelines for reporting endometrial carcinoma and risk stratification systems
- LVSI should be classified as NOT IDENTIFIED; FOCAL; SUBSTANTIAL/ EXTENSIVE
- Incoporated into ICCR, WHO 2020, FIGO 2023, NCCN, ISGyP guidelines, ESGO/ESTRO/ESP
- In these guidelines where management is mentioned, it is SUBSTANTIAL/ EXTENSIVE LVSI (as opposed to no/ focal) which results in different management

LVSI IN AN ORGAN SOLELY CONFINED TO VESSELS DOES NOT RESULT IN TUMOUR UPSTAGING

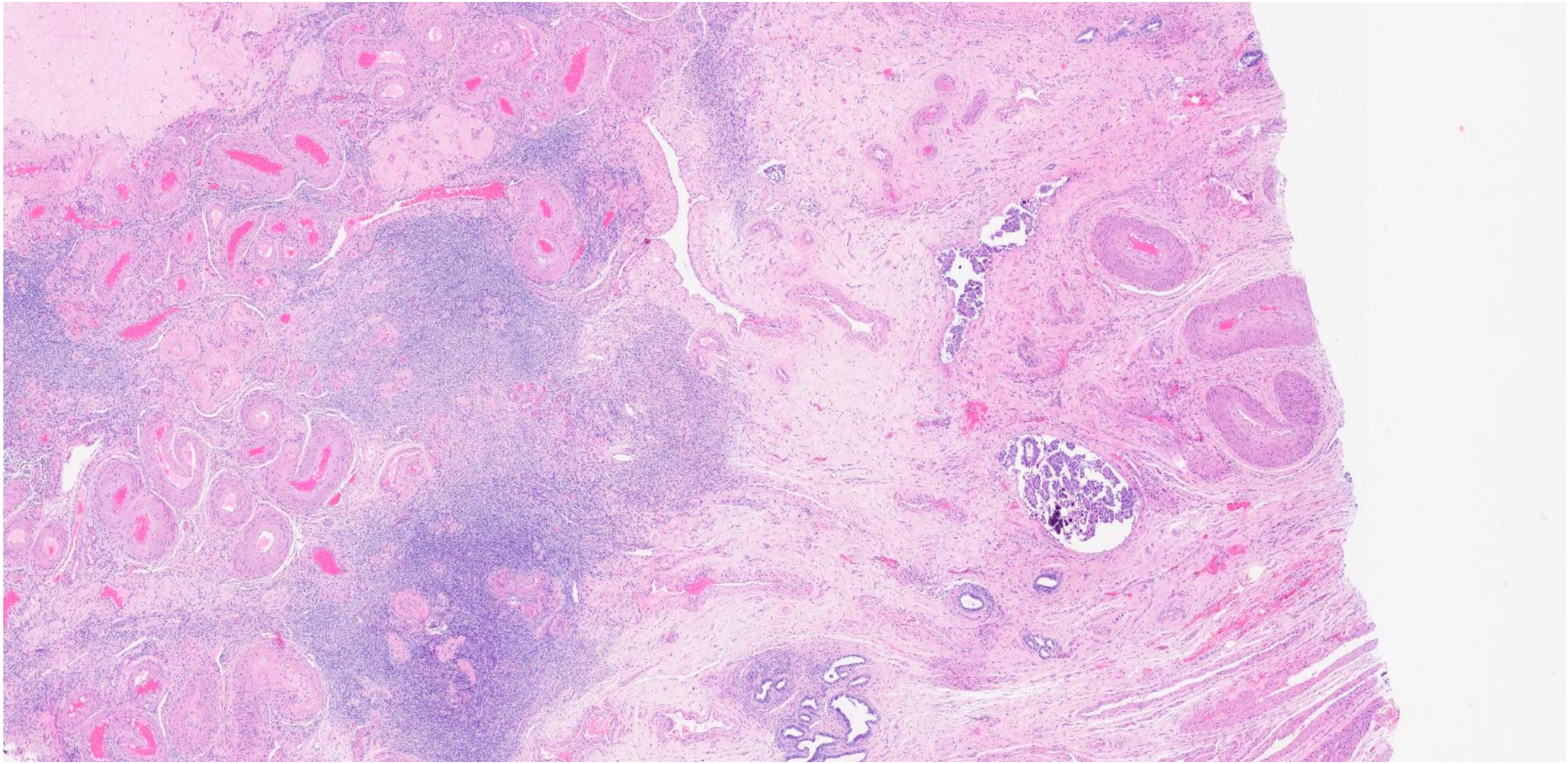

PROBLEMS IN ASSESSING PRESENCE OF AND QUANTIFYING LVSI

- The sometimes subtle and focal nature of LVSI such that it may be overlooked
- Retraction artefact mimicking LVSI
- Artefactual LVSI secondary to autolysis/ spreading artefact
- Vascular pseudoinvasion secondary to use of an intrauterine balloon manipulator mimicking true LVSI
- MELF pattern myometrial invasion mimicking LVSI
- Quantification of LVSI (including distinction between involvement of multiple vessels or multifocal involvement of a single vessel)

CLUES TO RECOGNISING LVSI

- Defined as presence of tumour cells in a vascular space lined by endothelial cells
- Best seen at advancing edge of tumour
- Tumour emboli often smooth and round and conform to contours of vessel
- Tumour cells are viable but typically do not form glands
- Tumour emboli may be attached to vessel wall
- Tumour emboli usually lack stromal elements
- Sometimes altered cytology compared to tumour not in vessels (more abundant eosinophilic cytoplasm)
- Lymphoid aggregates surrounding vessel
- Presence of accompanying venous or arterial vessel is supportive
- MOST OF THESE ARE “SOFT” CLUES

LVSI

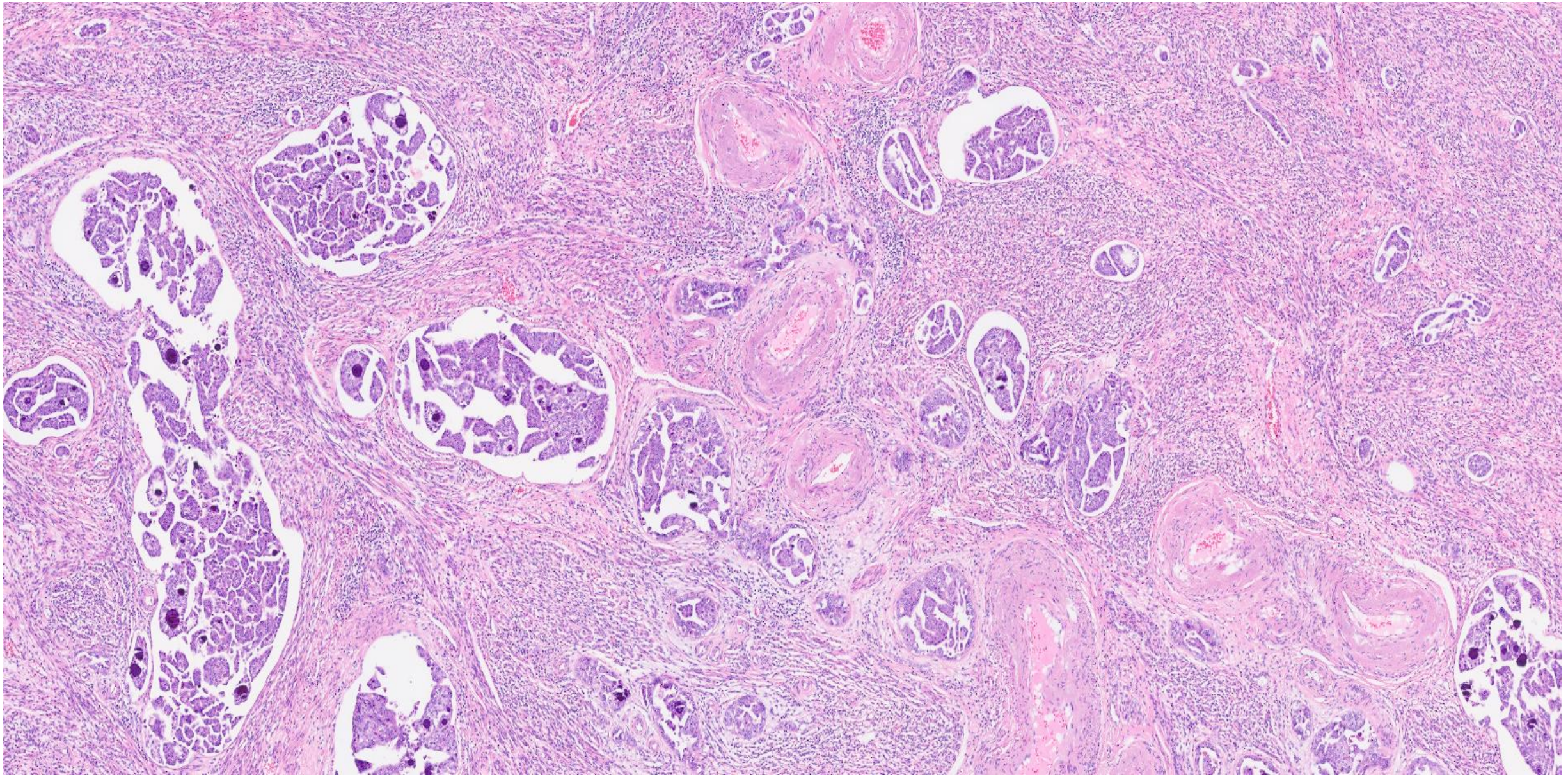

LYMPHOID AGGREGATES

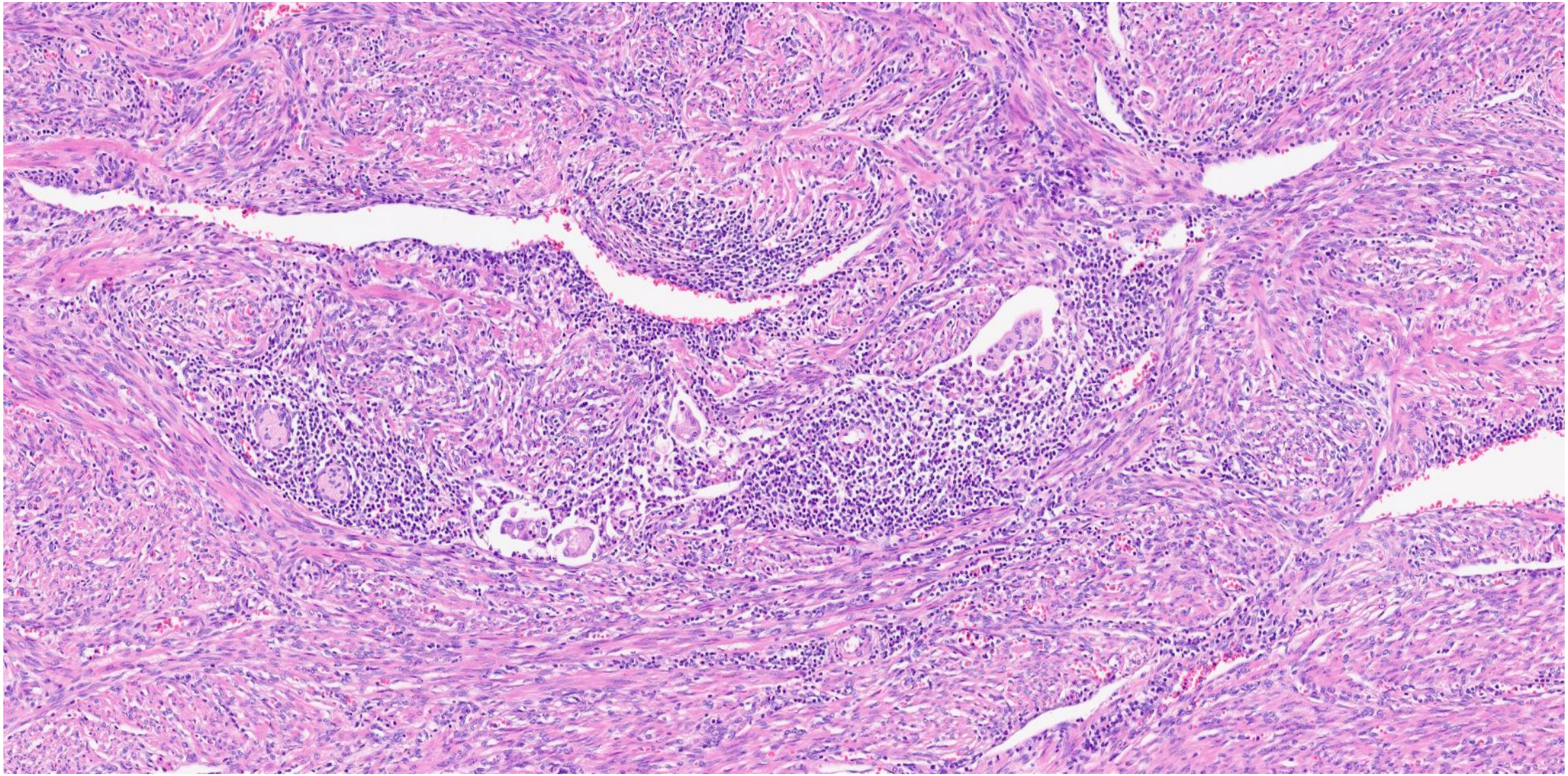

Retraction Artefact Mimicking LVSI

- No endothelial lining but flattened smooth muscle cells can resemble endothelial cells
- Often widespread throughout much of tumour
- May occasionally be strands of cytoplasm attaching the embolus to the putative vessel wall
- May be glandular formation with basally located nuclei which is relatively unusual in true LVSI

Retraction Artefact Mimicking LVSI

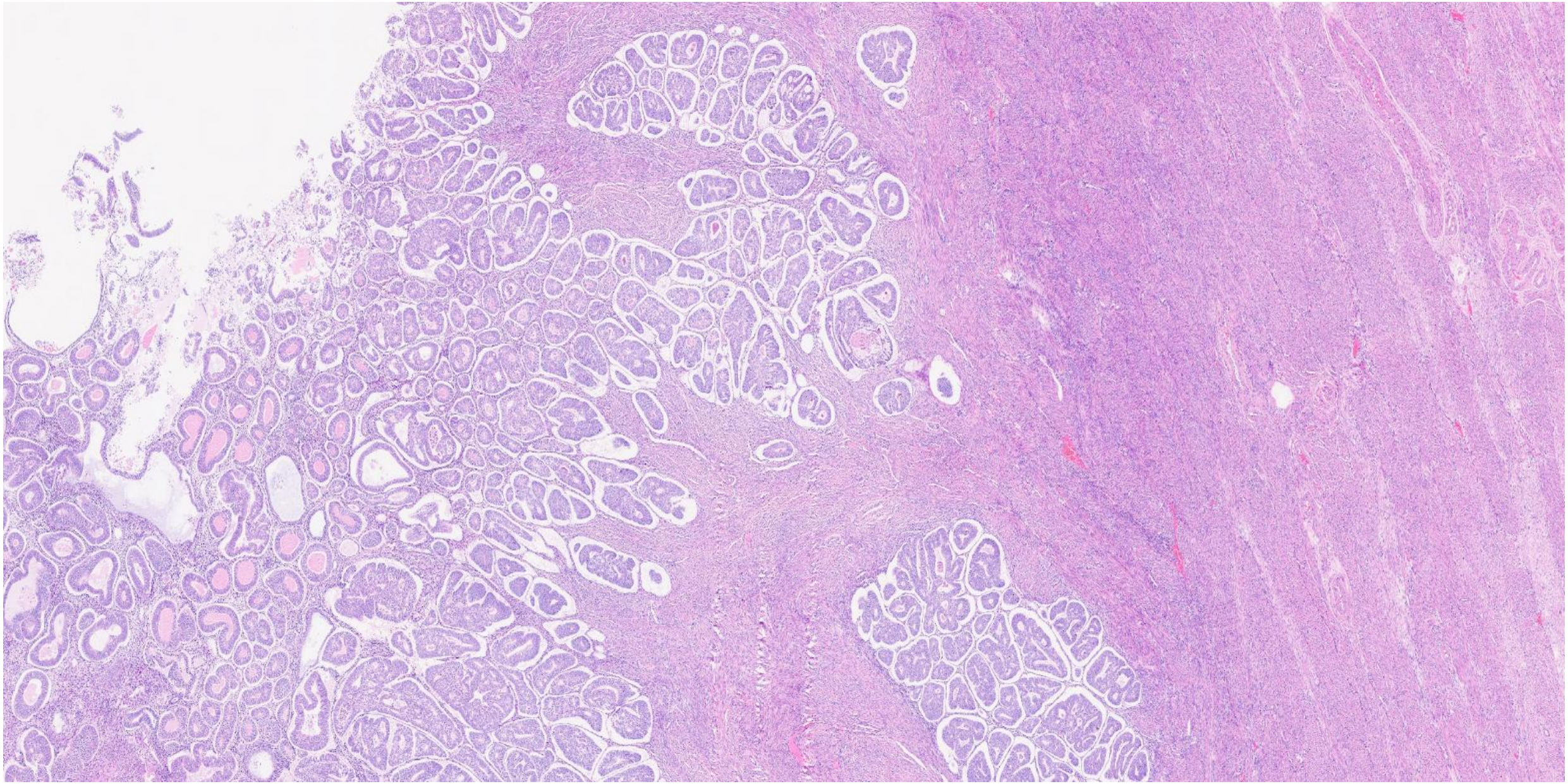

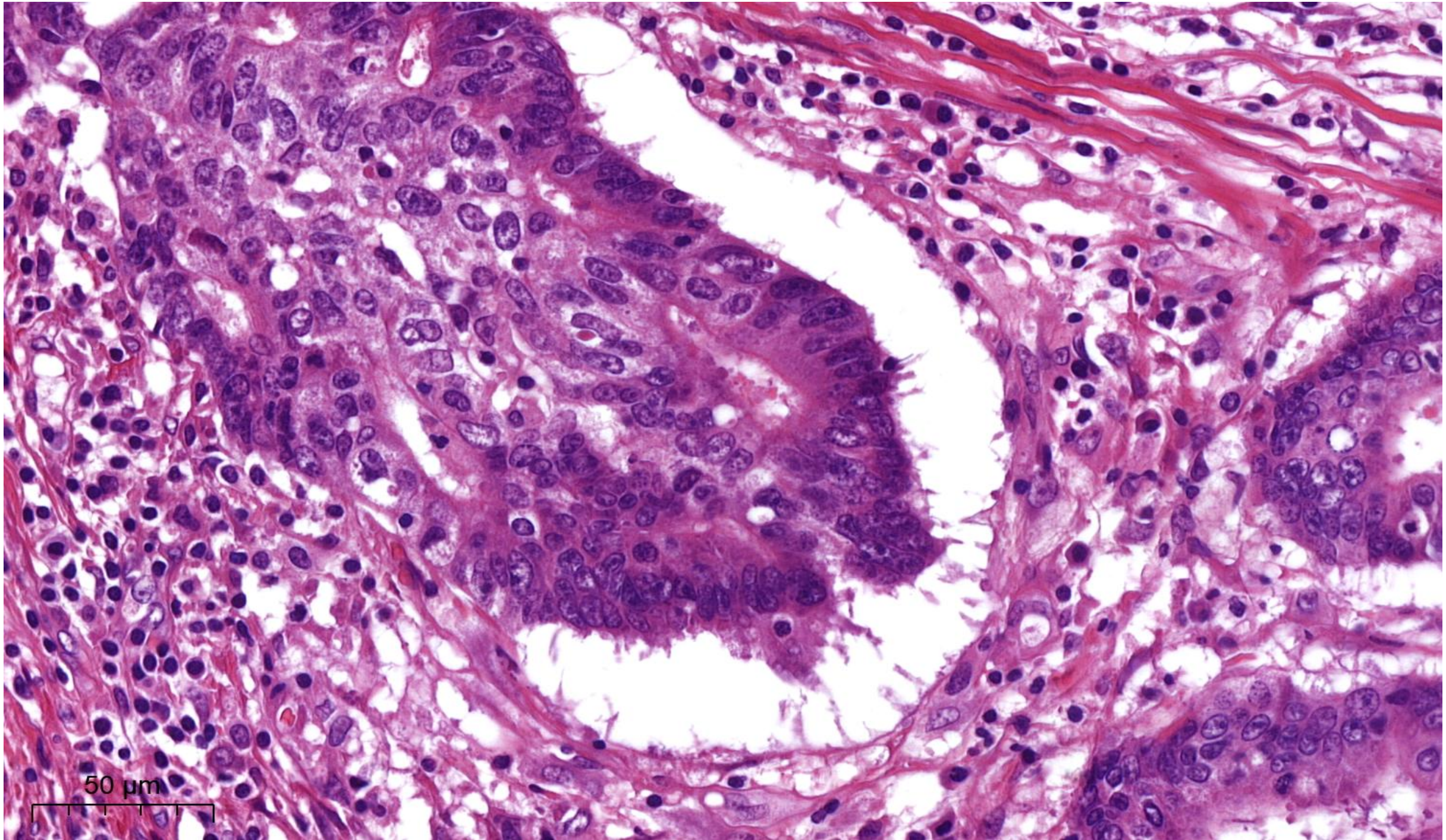
50 µm

Artefactual LVSI Secondary to Autolysis/ Spreading Artefact

- Due to poor fixation and tissue preservation
- Autolytic tumour gets displaced easily during grossing
- Get displaced to cut surfaces, onto serosa or into vessels (sometimes large vessels)
- Get “lytic” artefacted/ crushed tumour fragments

Artefactual LVSI Secondary to Autolysis/ Spreading Artefact

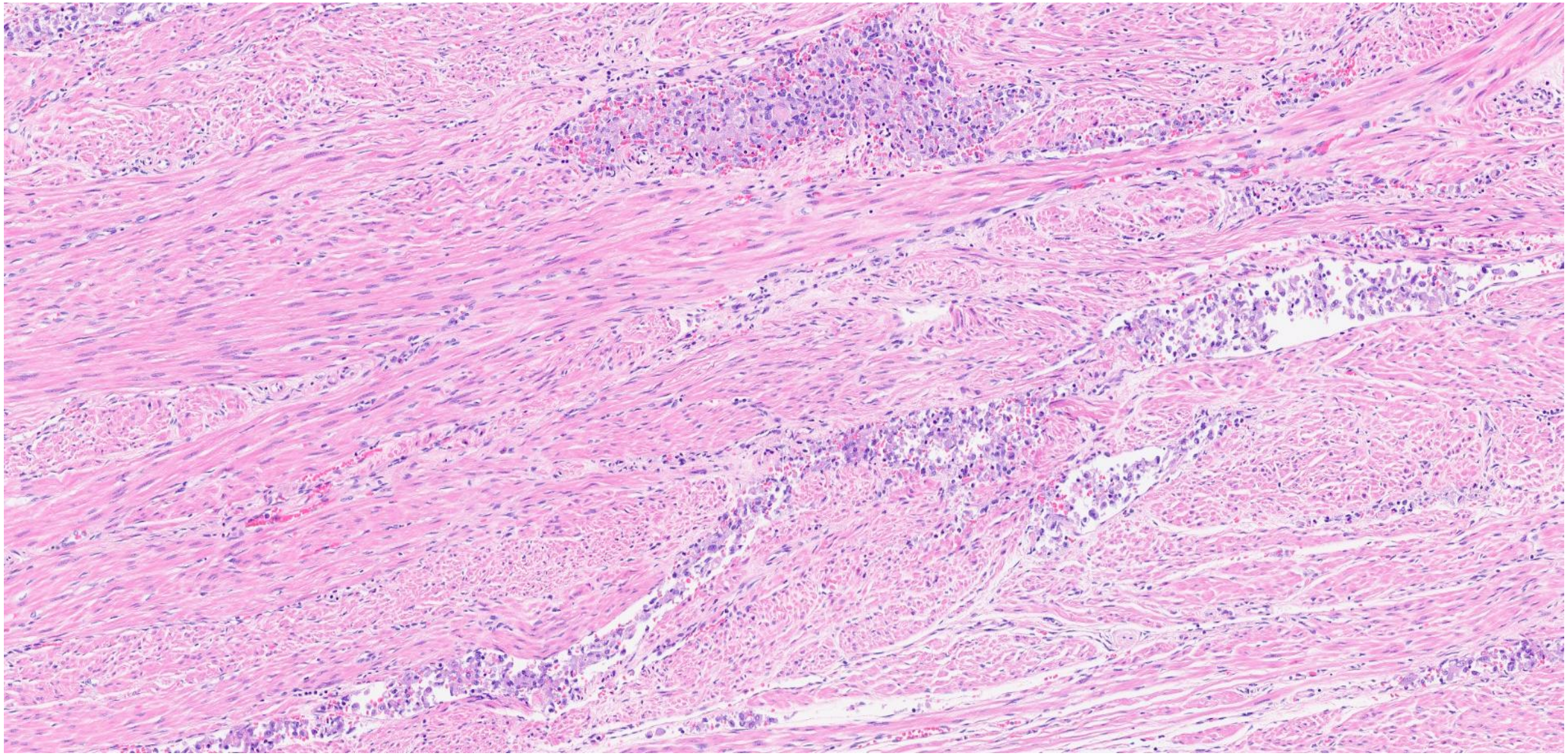

VASCULAR PSEUDOINVASION SECONDARY TO INTRAUTERINE BALLOON MANIPULATOR

- common with laparoscopic hysterectomies and intrauterine balloon manipulators
- more common with polypoid tumours
- benign or malignant tissue displaced into vessels
- typically predominantly thick-walled vessels in outer half of myometrium
- often clue is that degree of vascular invasion inconsistent with low tumour grade and stage
- often crush artefact; associated stroma with glands; inflammatory debris in vessels
- probably no prognostic significance (but unknown) (one study- PMID 24654453- suggests of adverse prognostic significance)

OTHER FEATURES SECONDARY TO BALLOON MANIPULATOR

- disruption of endometrial lining
- myometrial clefts
- floaters in tubal lumina and cervix
- serosal carry-over
- increased incidence of positive peritoneal washings (can be prevented by ligating tubes)

INTRAUTERINE BALLOON MANIPULATORS

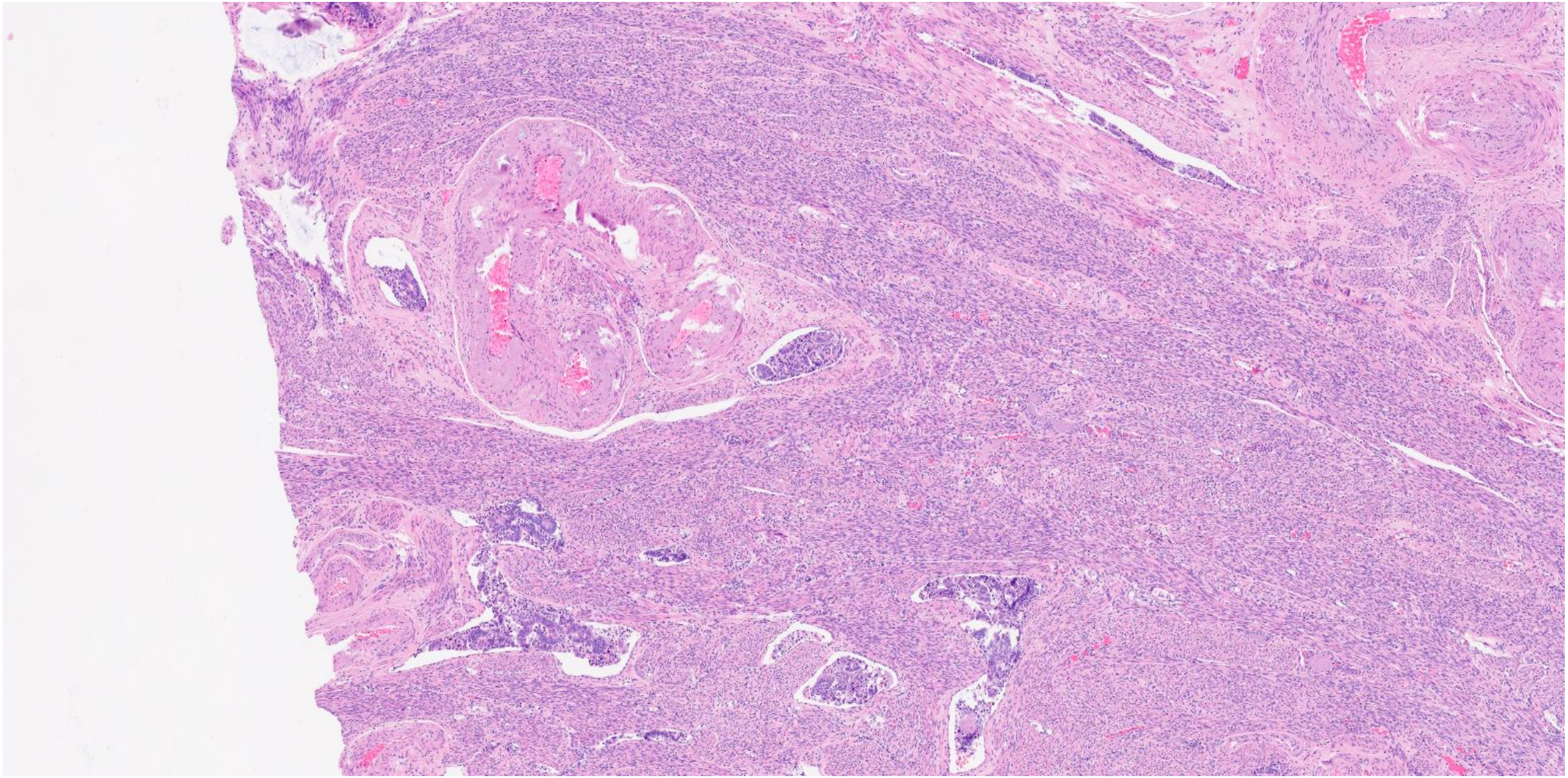

INTRAUTERINE BALLOON MANIPULATORS

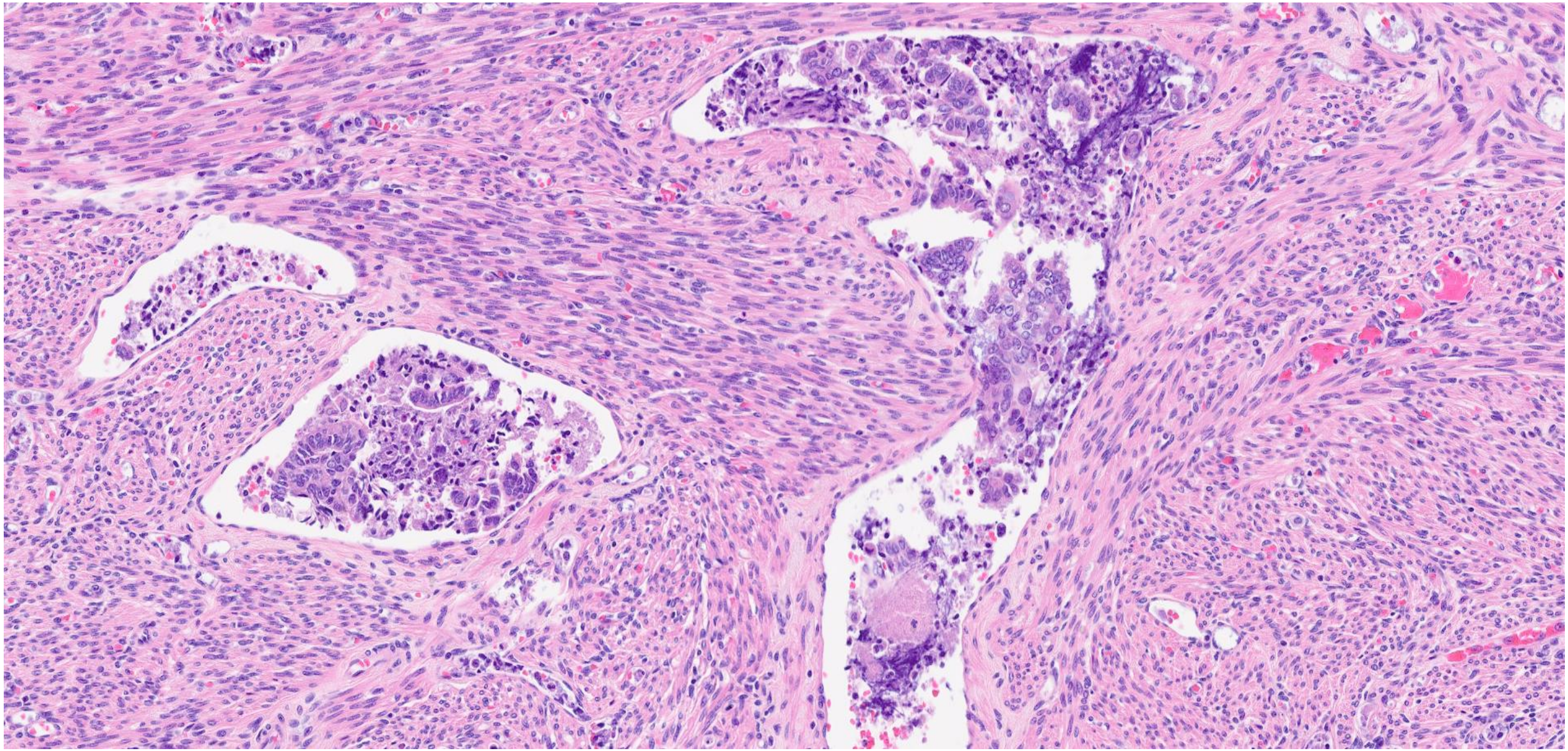

INTRAUTERINE BALLOON MANIPULATORS

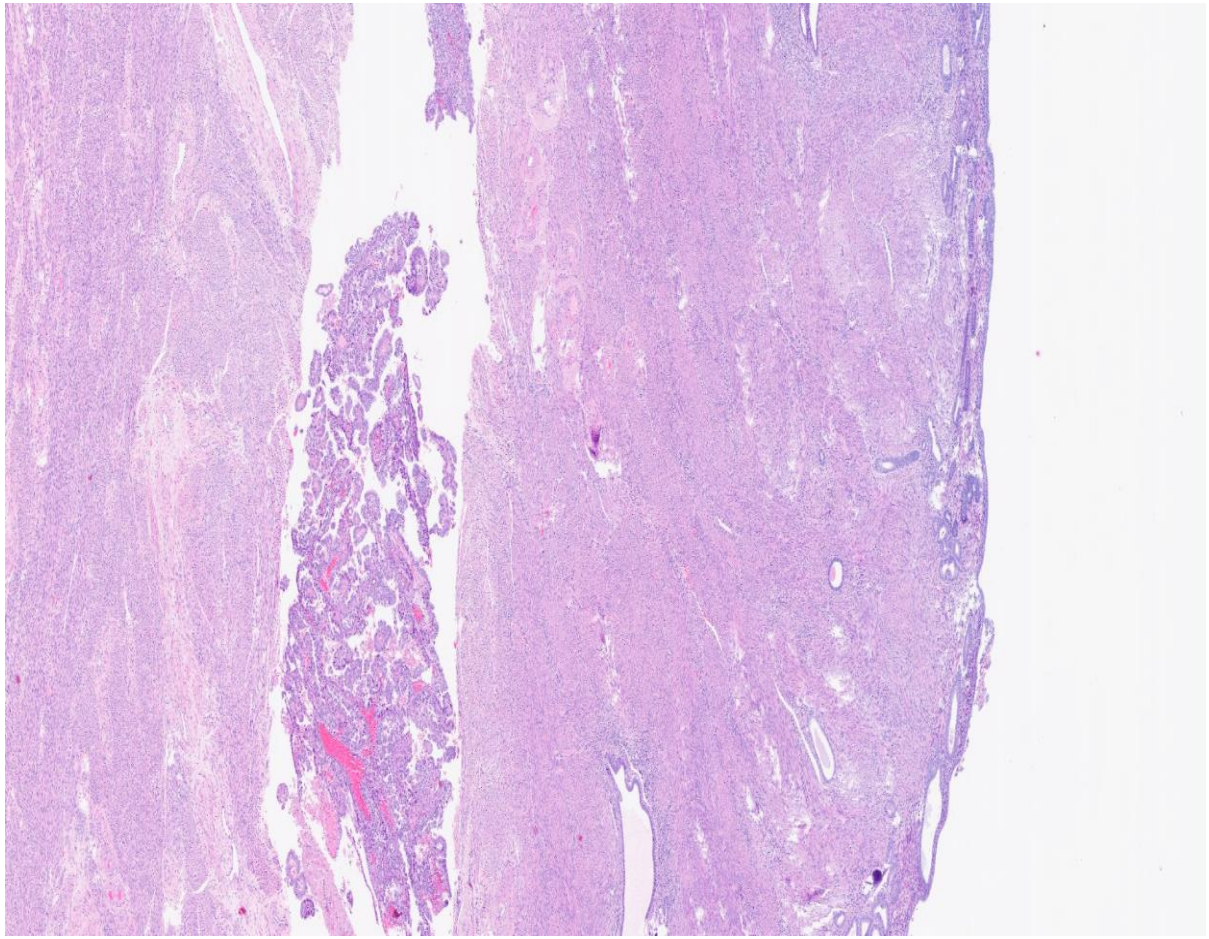

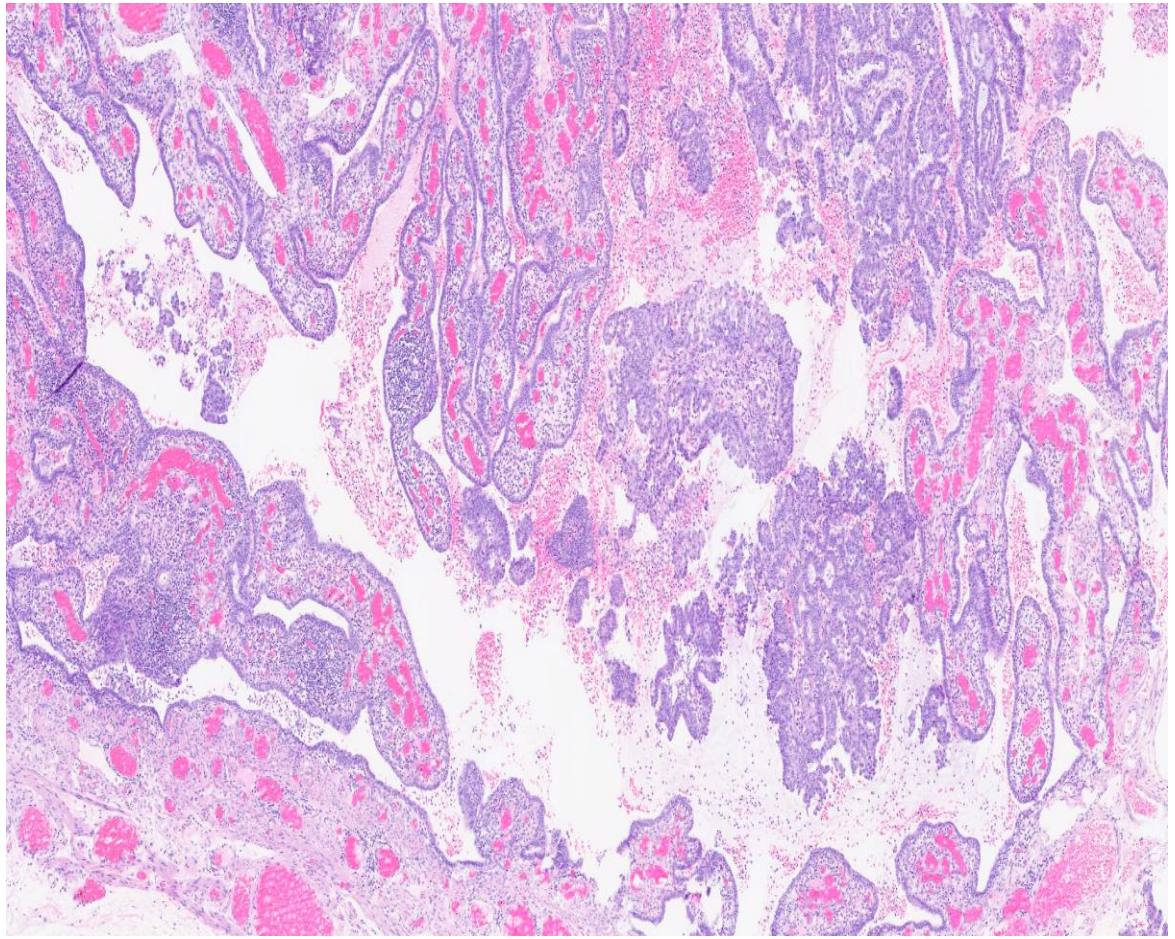

MELF (MICROCYSTIC ELONGATED AND FRAGMENTED) PATTERN OF MYOMETRIAL INVASION

- common pattern of myometrial involvement in low-grade endometrioid carcinomas
- glands associated with fibromyxoid stromal reaction
- out-pouchings from typical invasive glands; flattened epithelium, microcysts; elongation and fragmentation of glands
- **may simulate vascular invasion**
- **often associated with LVSI (search carefully for)**
- may get single or small groups of myoinvasive cells – can underestimate depth of myometrial invasion (CKs may be useful)
- may be poor prognostic feature in low-grade endometrioid carcinomas/ risk of nodal involvement (“histiocyte-like”; isolated tumour cells)
- **SHOULD MENTION ON PATHOLOGY REPORT**

MELF

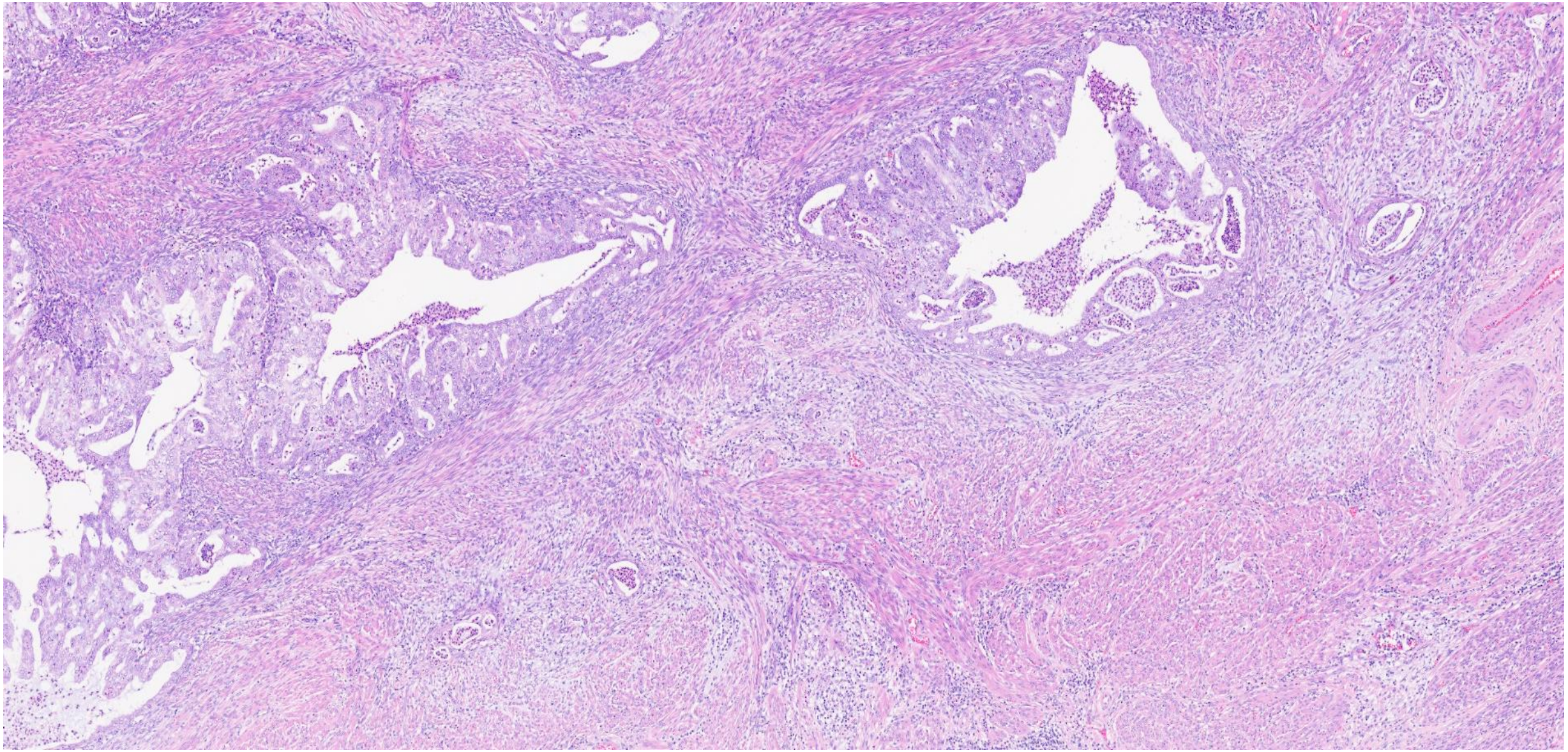

MELF MIMICKING LVSI

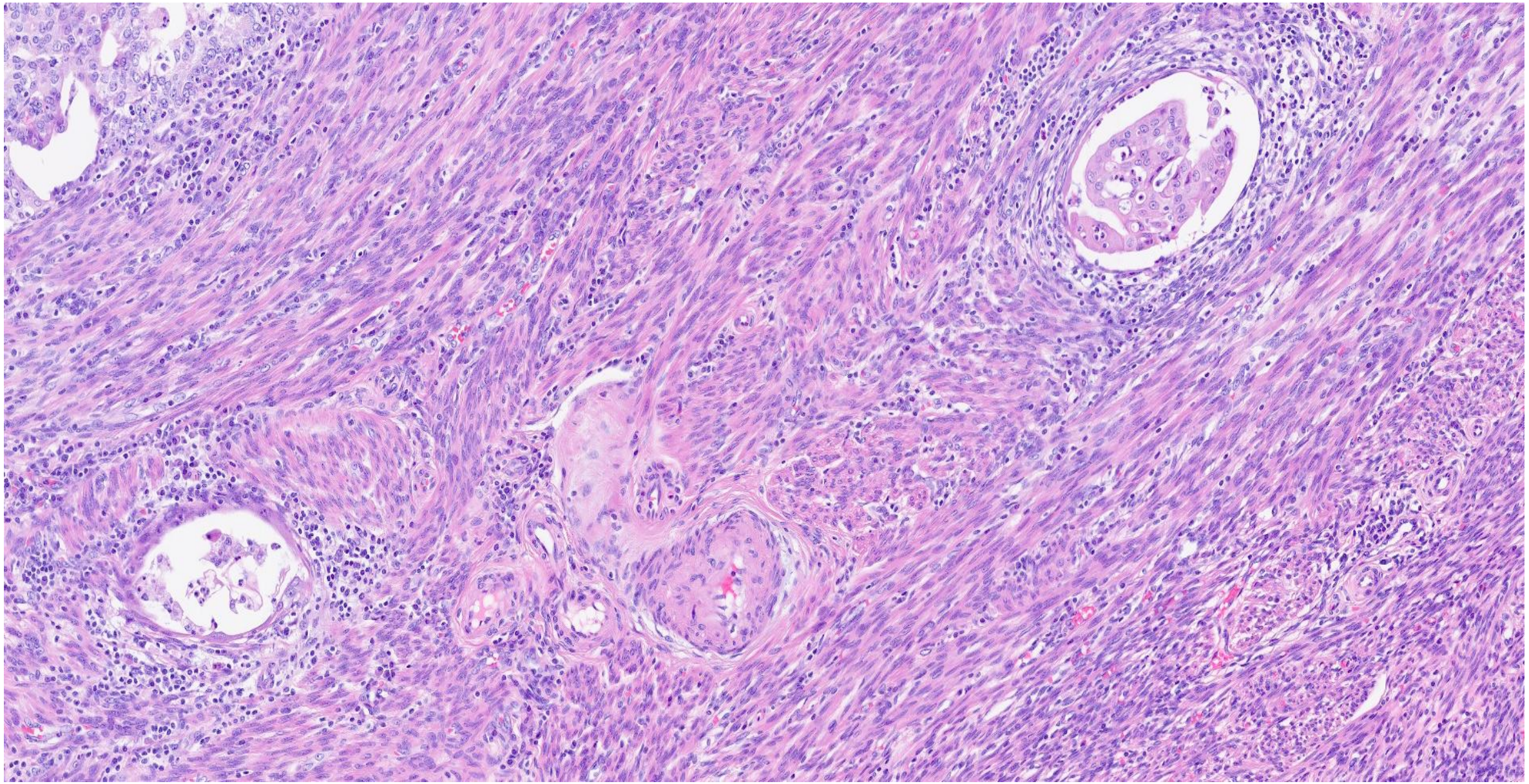

MELF

H/E

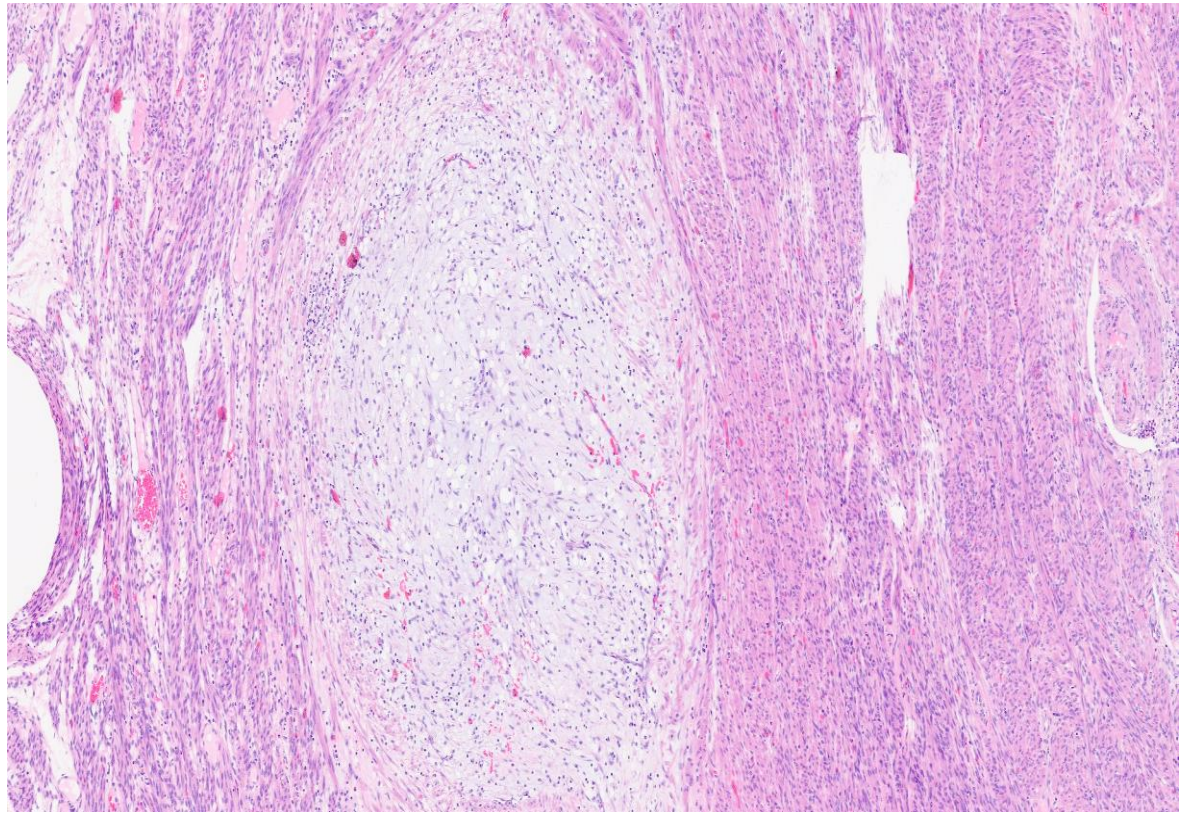

Cytokeratin

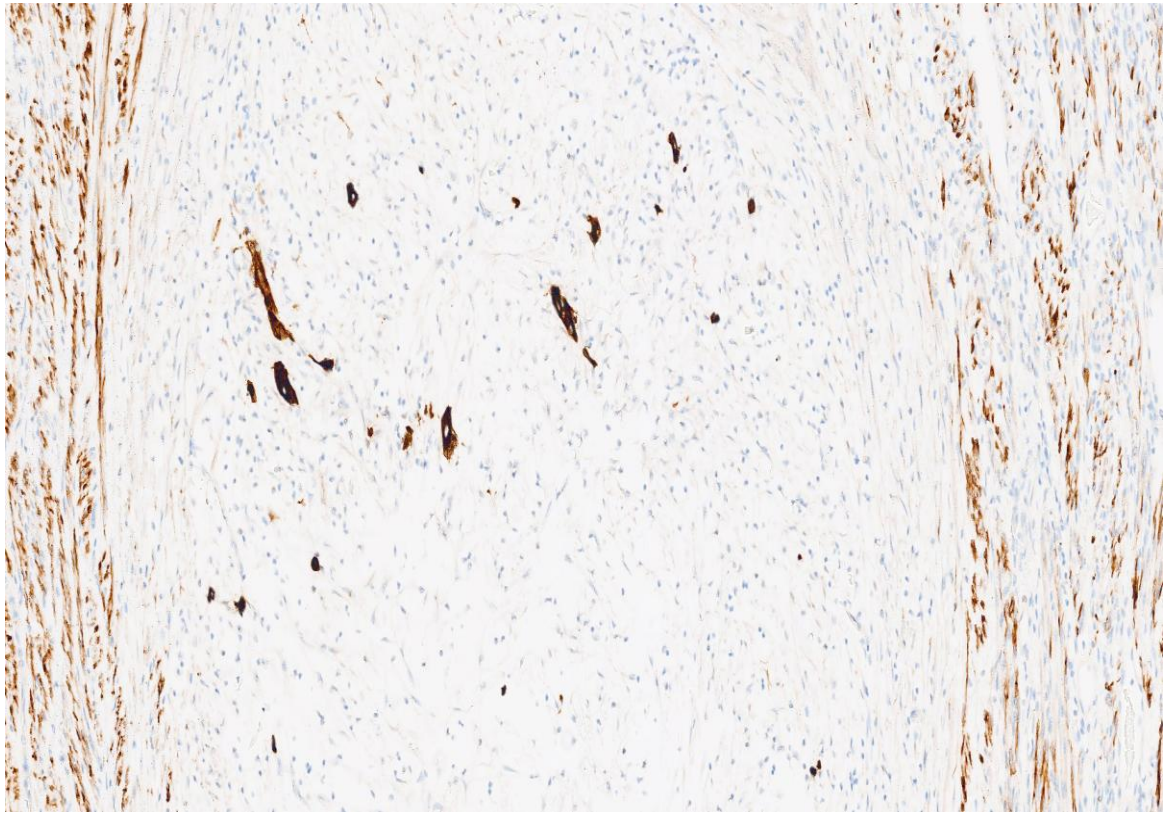

MELF Mimicking LVSI

- MELF spaces lined by cytokeratin positive flattened epithelial cells

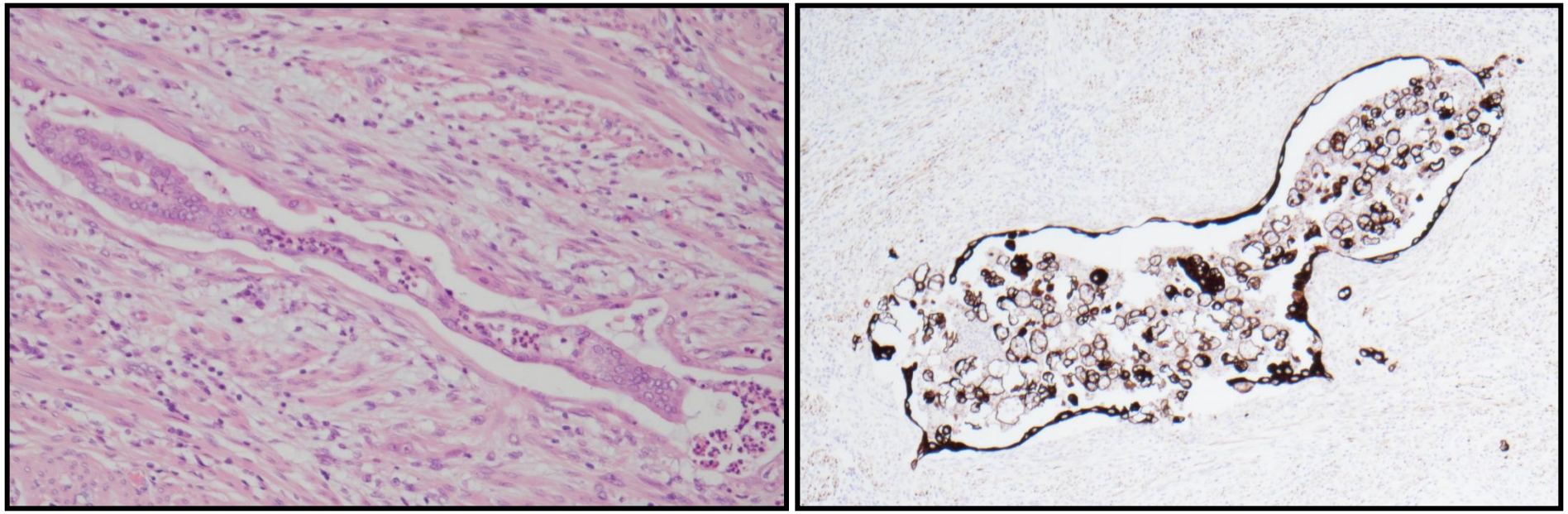

Distinction Between Involvement of Single and Multiple Vessels

- Some guidelines state that should distinguish between involvement of multiple vessels and a single tortuous vessel
- A clue to a single vessel may be the presence of vessels of same caliber in a “line”
- In practice, this is difficult/ impossible

Distinction Between Involvement of Single and Multiple Vessels

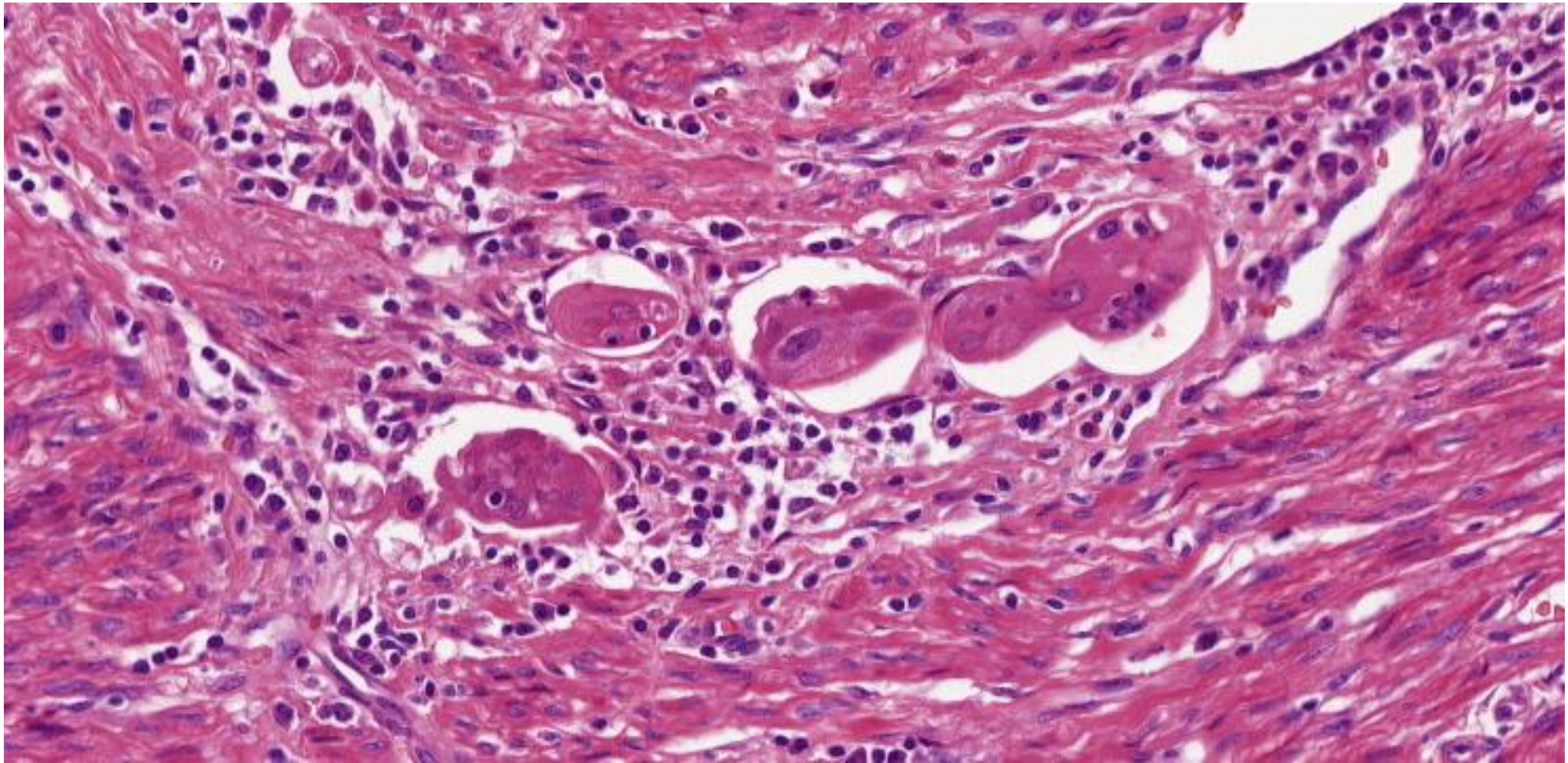

Distinction Between Involvement of Single and Multiple Vessels

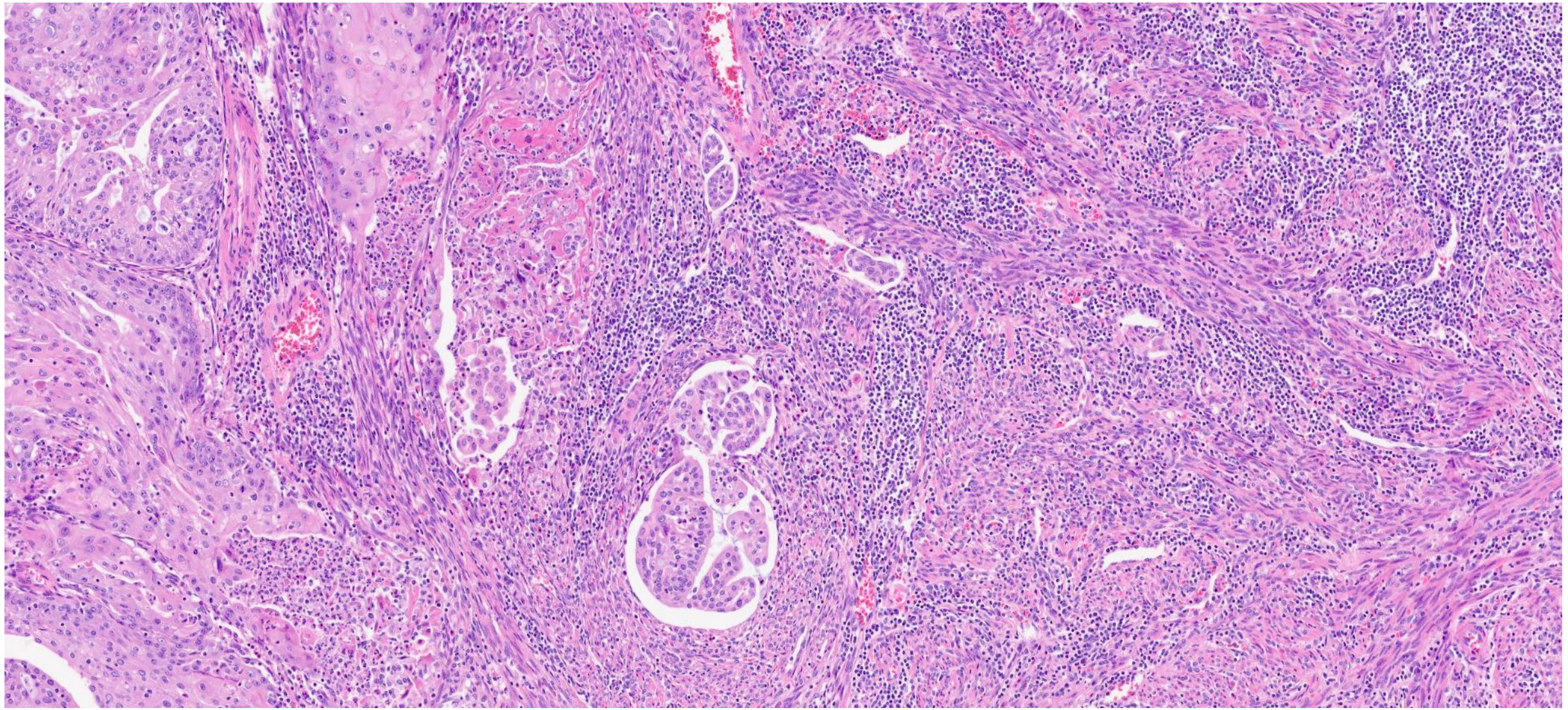

FOCAL VERSUS SUBSTANTIAL SUBSTANTIAL LVSI

- Original definition (PMID 26049688); focal LVSI- a focus of LVSI; substantial LVSI- diffuse or multifocal LVSI beyond advancing edge of tumour; THERE IS A GAP HERE FOR A PROPORTION OF CASES
- FIGO 2023 uses involvement of 5 or more lymphovascular spaces to define substantial (extensive) LVSI, as does WHO 2020 and ESGO/ ESTRO/ ESP
- NCCN guidelines uses 4 or more
- ICCR, CAP, ISGyP 2019 recommendations use 3 or more
- These guidelines do not clarify whether the extent of LVSI is based on the maximum involvement in a single tissue section or on the cumulative extent across all tissue sections
- These guidelines do not clarify whether LVSI should just be counted at the invasive edge of the tumour (not intratumoral)

PMID 34261899

International Journal of Gynecological Pathology
41:220–226, Lippincott Williams & Wilkins, Baltimore
Copyright © 2021 by the International Society of Gynecological Pathologists

Original Article

Defining Substantial Lymphovascular Space Invasion in Endometrial Cancer

Elke E.M. Peters, M.D., Alicia León-Castillo, M.D., Vincent T.H.B.M. Smit, M.D., Ph.D., Marie Boennelycke, M.D., Estrid Hogdall, Ph.D., Claus Hogdall, M.D., Ph.D., Carien Creutzberg, M.D., Ph.D., Ina M. Jürgenliemk-Schulz, Ph.D., Jan J. Jobsen, M.D., Ph.D., Jan Willem M. Mens, M.D., Ludy C.H.W. Lutgens, M.D., Elzbieta M. van der Steen-Banasik, M.D., Gitte Ortoft, M.D., Ph.D., Tjalling Bosse, M.D., Ph.D., and Remi Nout, M.D., Ph.D.

PMID 34261899

- Quantitative analysis between LVSI and risk of pelvic lymph node recurrence in endometrial carcinomas
- PORTEC 1 and PORTEC 2 cases; analysis then repeated in Danish Gynaecological Cancer Database cohort
- Number of spaces involved per H/E slide
- Proposed numeric threshold of $\geq$4 involved vessels in at least 1 H/E stained slide for defining clinically relevant LVSI
- Defined LVSI as tumour embolus in endothelial lined space in the myometrium beyond the invasive front of the tumour
- Recommended to report the number of spaces involved in borderline cases (will facilitate further studies)

PMID 31155736

Histopathology

Histopathology 2019, 75, 128–136. DOI: 10.1111/his.13871

Reproducibility of lymphovascular space invasion (LVSI) assessment in endometrial cancer

Elke E M Peters,[1,2] Carla Bartosch,[3] W Glenn McCluggage,[4] Catherine Genestie,[5] Sigurd F Lax,[6] Remi Nout,[7] Jan Oosting,[1] Naveena Singh,[8] Huub C S H Smit,[9] Vincent T H B M Smit,[1] Koen K Van de Vijver[9] & Tjalling Bosse[1]

[1]*Department of Pathology, Leiden University Medical Center, Leiden, the Netherlands,* [2]*Department of Pathology, Haaglanden Medical Center, The Hague, the Netherlands,* [3]*Department of Pathology, Portuguese Oncology Institute-Porto, Porto, Portugal,* [4]*Department of Pathology, Belfast Health and Social Care Trust, Belfast, Northern Ireland, UK,* [5]*Department of BioPathology, University Paris-Saclay, Gustave-Roussy Cancer Center, Villejuif, France,* [6]*Department of Pathology, Hospital Graz II and Medical University of Graz, Graz, Austria,* [7]*Department of Radiation Oncology, Leiden University Medical Center, Leiden, the Netherlands,* [8]*Department of Cellular Pathology, Barts Health NHS Trust, London, UK, and* [9]*Department of Pathological Anatomy, Ghent University Hospital, Ghent, Belgium*

PMID 31155736

- Evaluated reproducibility in distinguishing LVSI from mimics
- Evaluated reproducibility in quantifying LVSI
- 6 pathologists, 48 endometrioid carcinomas of corpus, single scanned H/E, cases chosen because of possible LVSI
- Apply criteria used in daily practice
- Moderate reproducibility in diagnosing (ICC 0.64) and quantifying (ICC 0.62) LVSI

IS IMMUNOHISTOCHEMISTRY NECESSARY TO DIAGNOSE LVSI OR DOES IT HELP?

- All major recommendations do not mention IHC so presume that mean to assess LVSI on routine H/E stained sections
- ? Should we use on all cases (all slides or single slide)
- ? Only in scenarios where it may affect management
- ? Only in cases where not sure whether true LVSI or mimic
- ? Only in cases where problems in quantifying LVSI
- IHC is not always easy to interpret

IMMUNOHISTOCHEMISTRY

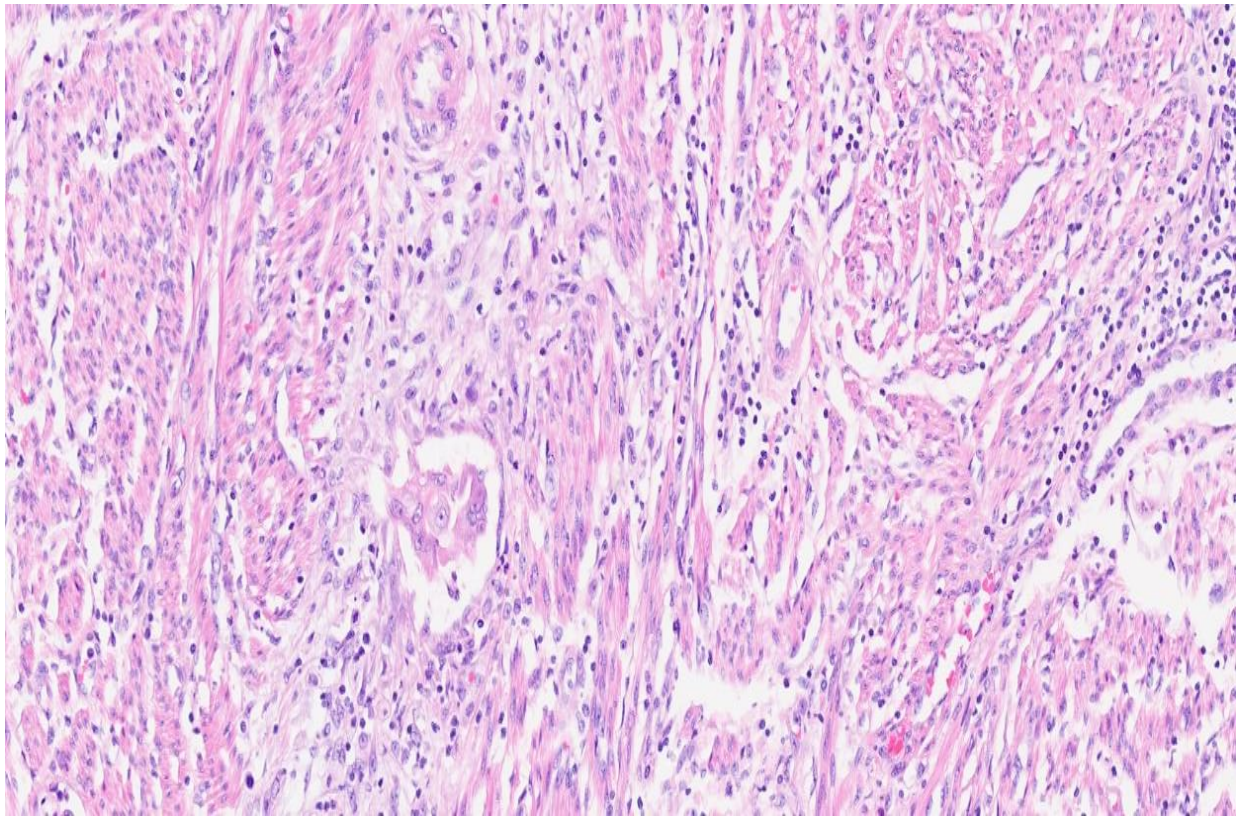

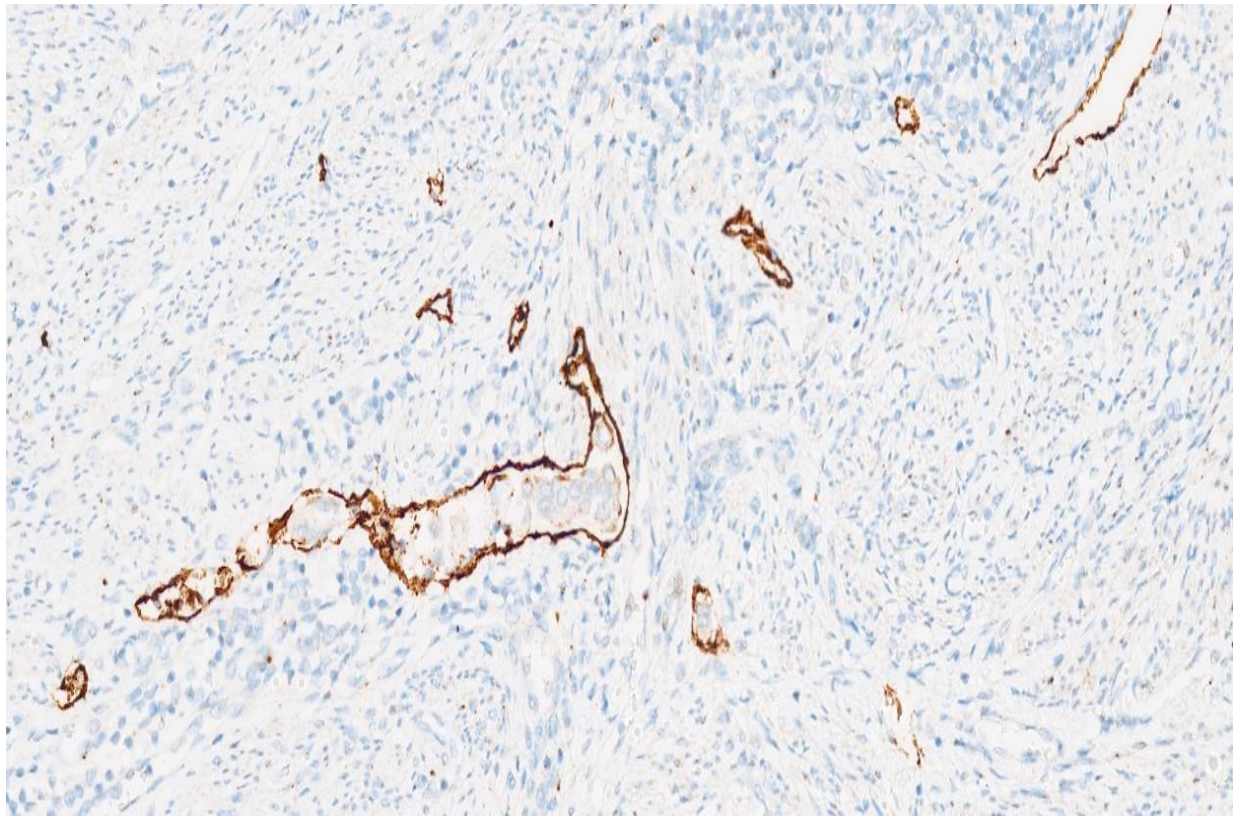

D240

Retraction Artefact Mimicking LVSI

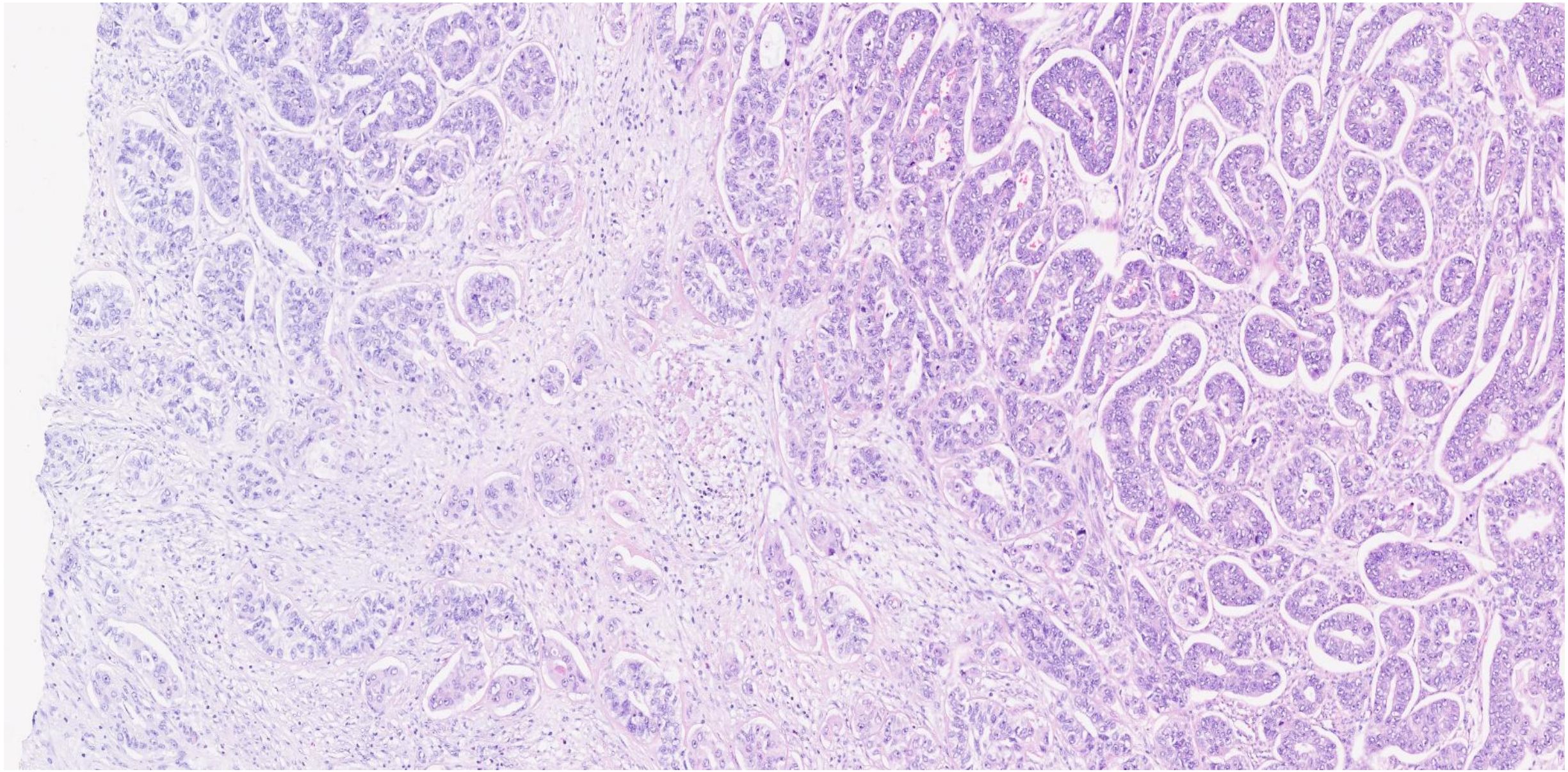

COMBINED D240 AND CAM5.2

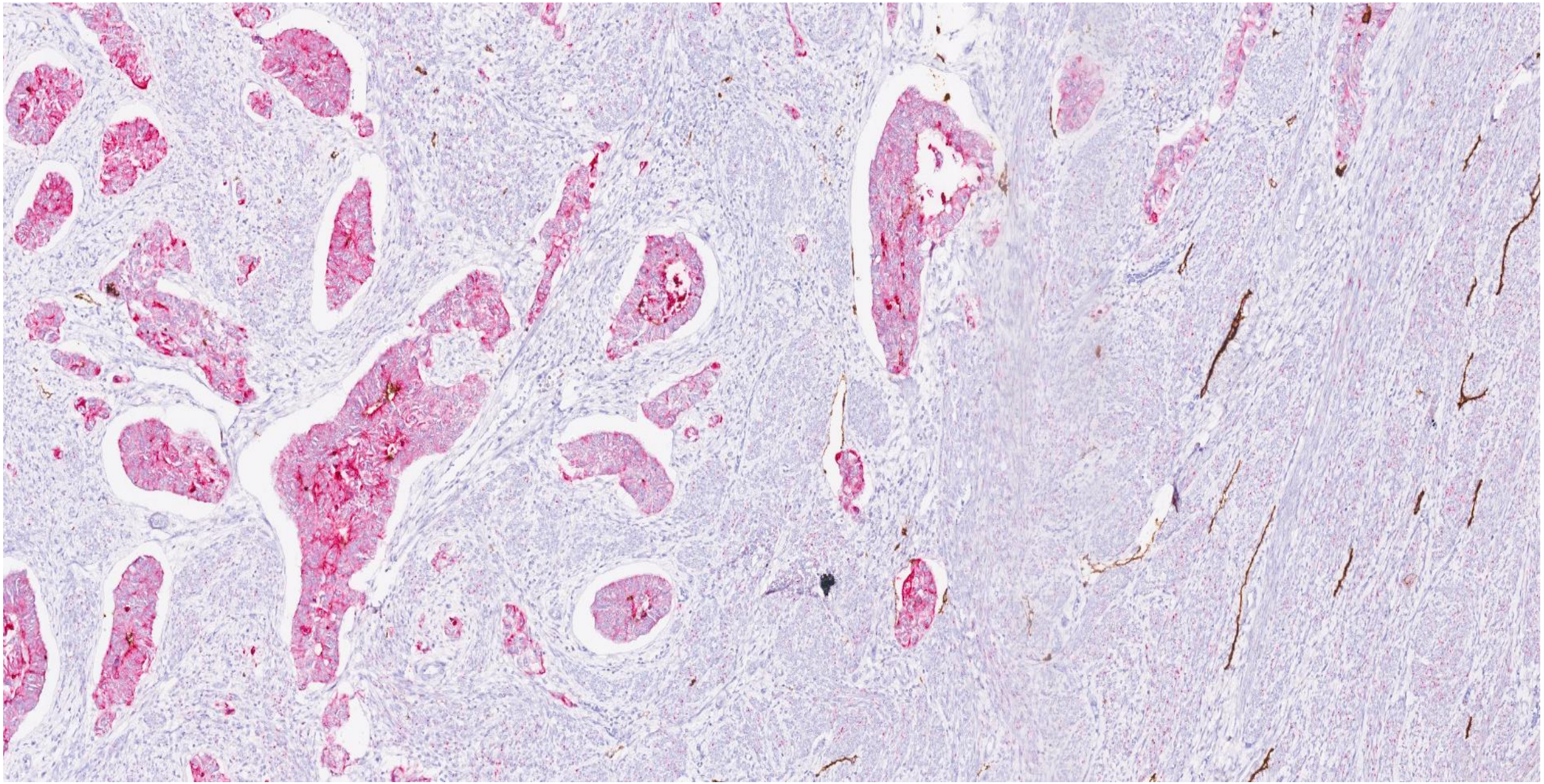

Does IHC Result in Increased Pick-up of LVSI?

- PMID: 28975668 (year 2017). Using IHC (D240 and CD31), vascular invasion increased from 24.6% to 31.6% of cases
- PMID 14766262 (year 2004). H/E - LVSI present in 19% of cases compared to 50% on IHC stained slides (double staining CD31/ CAM5.2). Recurrence free survival was only significant in cases where LVSI was detected by H/E only
- PMID 14514787 (year 2003). Using IHC, detection of LVSI increased 3 fold (double staining CD31/ broad spectrum cytokeratin)

PMID 19207942

Histopathology 2009, **54**, 174–183. DOI: 10.1111/j.1365-2559.2008.03201.x

Importance of tumour cell invasion in blood and lymphatic vasculature among patients with endometrial carcinoma

Monica Mannelqvist,[1] Ingunn Stefansson,[1] Helga B Salvesen[2,3] & Lars A Akslen[1]
[1]*The Gade Institute, Section for Pathology,* [2]*Department of Clinical Medicine, University of Bergen, and* [3]*Department of Gynaecology and Obstetrics, Haukeland University Hospital, Bergen, Norway*

Date of submission 19 June 2008
Accepted for publication 15 August 2008

PMID 19207942

- 276 endometrial cancers; retrospective population-based study
- Used D240 (lymphatic vessel marker) and CD31 (predominantly blood vessel marker but sometimes weak staining in lymphatic vessels)
- 40% exhibited vascular invasion; 31% exhibited lymphatic vessel involvement (LVI); 18% exhibited blood vessel involvement (BVI); 9% exhibited both
- Patients without vascular involvement had best prognosis
- Those with BVI (with or without LVI) had worst prognosis
- Those with LVI had intermediate prognosis
- Multivariate analysis both BVI and LVI were associated with worse prognosis but especially BVI
- 12% of cases negative on H/E had vascular invasion on IHC; 13% positive on H/E could not be confirmed by IHC (only 1 slide per case used for IHC)

PMID 39074932 AND 40055122



Original Research

Oncologic outcomes based on lymphovascular space invasion in node-negative FIGO 2009 stage I endometrioid endometrial adenocarcinoma: a multicenter retrospective cohort study

Christian Dagher ,[1] Pernille Bjerre Trent,[2,3] Rofieda Alwaqfi,[4] Ben Davidson,[3,5] Lora Ellenson,[4] Qin C Zhou,[6] Alexia Iasonos,[6] Jennifer J Mueller ,[1,7] Kaled Alektiar,[8] Vicky Makker,[9,10] Sarah Kim,[1,7] Mario M Leitao Jr ,[1,7] Nadeem R Abu-Rustum ,[1,7] Ane Gerda Z Eriksson[2,3]

PMID: 39074932 AND 40055122

- Surgically staged (FIGO 2009 stage I) node negative endometrioid carcinomas
- 1555 patients (large series); used 5 vessel cut-off on 1 slide to distinguish between focal (<5) and substantial (≥5) LVSI
- 4.2% substantial LVSI; 7.7% focal LVSI; 88.2% no LVSI
- 5-year cumulative incidence failure rates for any recurrence were 6.0% for no LVSI, 19.5% for focal LVSI, and 19.0% for substantial LVSI
- S-LVSI and F-LVSI were independently associated with disease progression/death
- S-LVSI was not associated with different oncologic outcomes compared to F-LVSI
- Does not support grouping F-LVSI and negative into one risk category

SUMMARY

- LVSI is prognostically and sometimes therapeutically important in endometrial carcinomas
- Usually assessment of LVSI is only clinically important in low-grade and low-stage endometrioid carcinomas
- Most cases are straightforward (either obvious negative/ focal or substantial) but in a minority of cases it may be problematic
- There are problems in determining cut-offs for focal versus substantial; in most cases this is not an issue
- We need better standardization of definitions so all recommendations are concordant: ? How many vessels; ? Single slide; ? Just at advancing edge of tumour
- Beware of mimics of LVSI
- We should probably just do on H/E since most studies have not used ancillary markers (although IHC may help to exclude mimics)

PMID 38937066

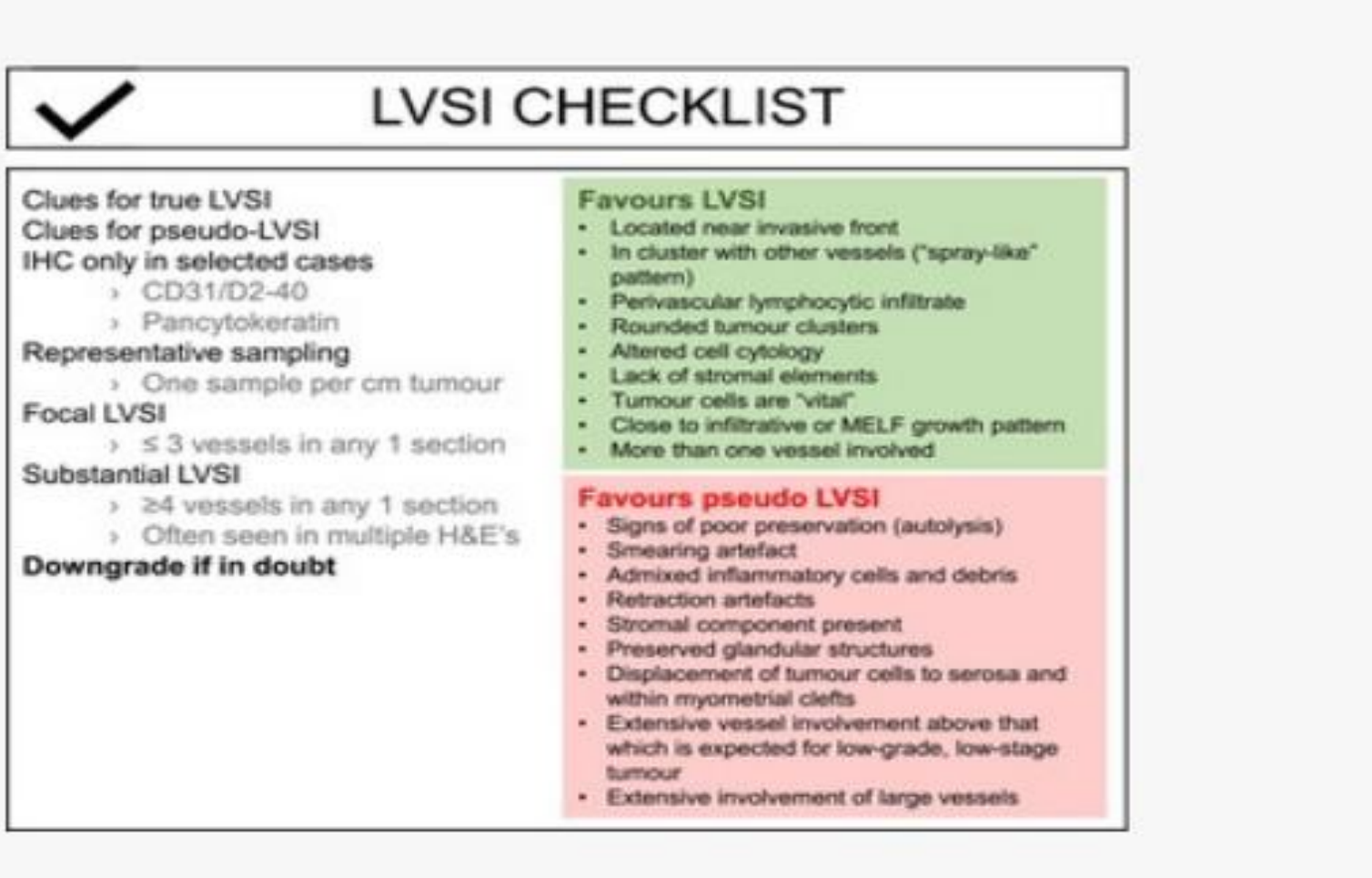

LVSI CHECKLIST

Clues for true LVSI
Clues for pseudo-LVSI
IHC only in selected cases
- CD31/D2-40
- Pancytokeratin

Representative sampling
- One sample per cm tumour

Focal LVSI
- ≤ 3 vessels in any 1 section

Substantial LVSI
- ≥4 vessels in any 1 section
- Often seen in multiple H&E's

Downgrade if in doubt

Favours LVSI
- Located near invasive front
- In cluster with other vessels ("spray-like" pattern)
- Perivascular lymphocytic infiltrate
- Rounded tumour clusters
- Altered cell cytology
- Lack of stromal elements
- Tumour cells are "vital"
- Close to infiltrative or MELF growth pattern
- More than one vessel involved

Favours pseudo LVSI
- Signs of poor preservation (autolysis)
- Smearing artefact
- Admixed inflammatory cells and debris
- Retraction artefacts
- Stromal component present
- Preserved glandular structures
- Displacement of tumour cells to serosa and within myometrial clefts
- Extensive vessel involvement above that which is expected for low-grade, low-stage tumour
- Extensive involvement of large vessels