The British Association of Gynaecological Pathologists

21st Annual Meeting in Collaboration with ISGyP

5th and 6th June 2025

- **Practical Evaluation of Vulval Neoplasia**
- **Carlos Parra-Herran**
- **Brigham and Women's Hospital, Boston MA United States**
- **June 6, 2025**

The British Association of Gynaecological Pathologists

Speaker disclosures

Choose one

- ❑ I have no financial conflicts of interest to disclose

VULVAL CANCER

- <5% of gynecologic cancers
- 14% increase in incidence in developed countries (specially in patients <60 y/o)
- Prognostic factors
  - *Tumor size* *Depth of invasion*
  - *Multifocality* *Lymph node involvement*

Int J Gynecol Obstet 2021;155(Suppl 1):7–18
Am J Surg Pathol 2008;32:765-772
Am J Surg Pathol 2015;39:1226-1233
Int J Cancer 2017;141:2174-2186
Am J Surg Pathol 2015;39:1070-1074
Hum Pathol 2016;56:22-30

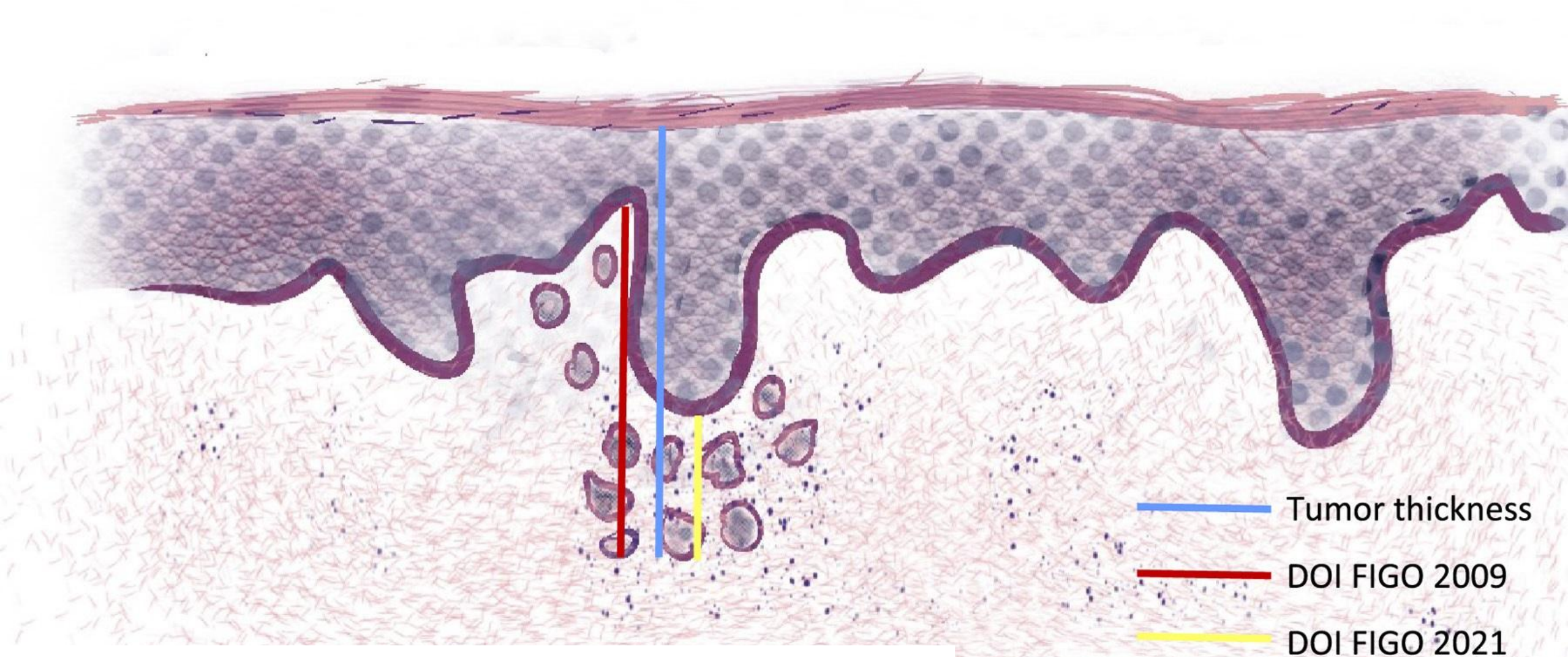

Does "One Size Fits All"? Rethinking FIGO Depth of Invasion Measurements in Vulvar Cancer

Maaike C.G. Bleeker, M.D., Tjalling Bosse, M.D., Koen K. van de Vijver, M.D., Joost Bart, M.D., Hugo Horlings, M.D., Trudy G.N. Jonges, M.D., Nicole C.M. Visser, M.D., Loes F.S. Kooreman, M.D., Johan Bulten, M.D., and Patricia C. Ewing-Graham, M.B.Ch.B.

Conventional method (FIGO 2009)

Alternative method (FIGO 2021)

Int J Gynecol Pathol 2024;43(5):457-463

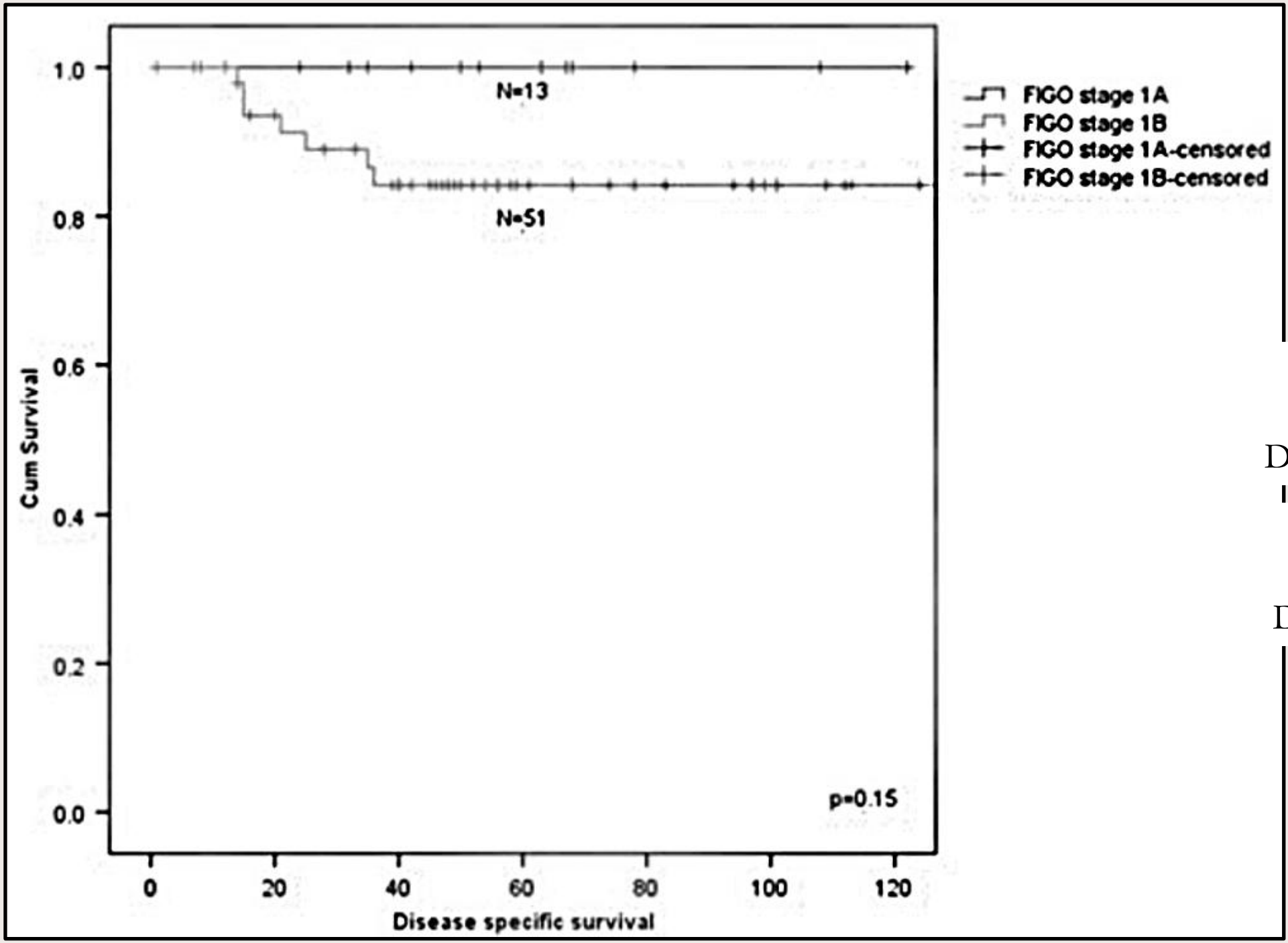

Stage IB

Stage IA

13 with new stage IA

Recurrence 15%

Disease specific survival 100%

51 with confirmed stage IB

Recurrence 39%

Disease specific survival 84%

Mod Pathol 2015;28(2):295-302

Results: Depending on the measurements used (conventional vs alternative depth, clinical lesion size vs cumulative extent of invasive component), between 1 and 18 cases were downstaged to pT1a. All such cases were pN0, without lymphovascular or perineural invasion. Infiltrative cords carcinoma showed separation ($P = 0.038$). Alternative depth was slightly more predictive of groin recurrence than conventional depth (AUC = 0.74 vs 0.70). Kaplan-Meier curves for local recurrence-free survival based on stage did not show significant separation regardless of method.

Conventional method (FIGO 2009)

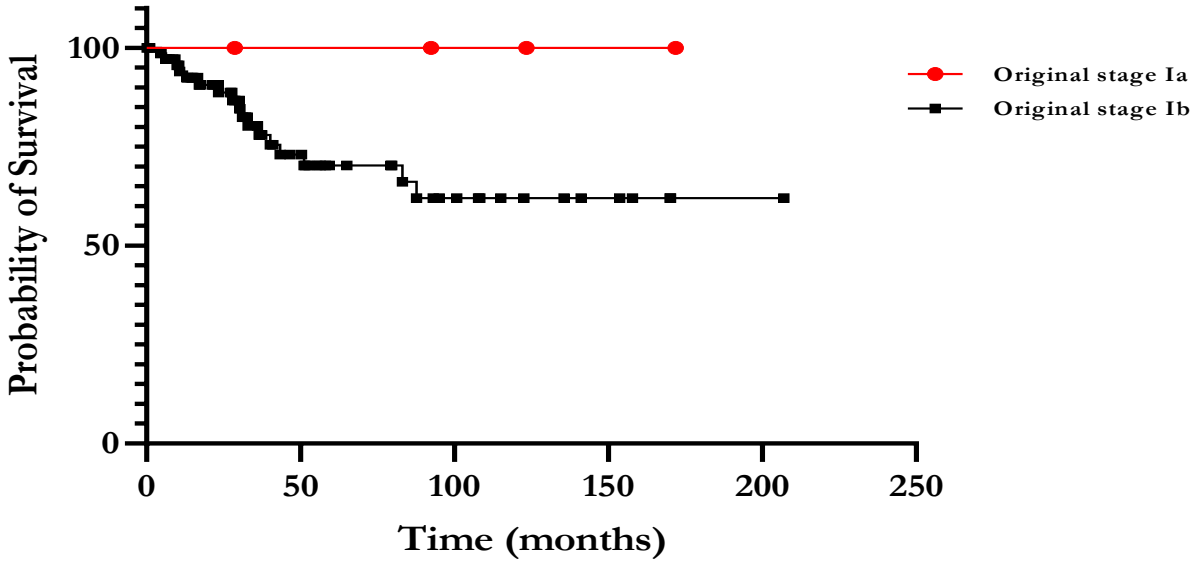

Alternative method (FIGO 2021)

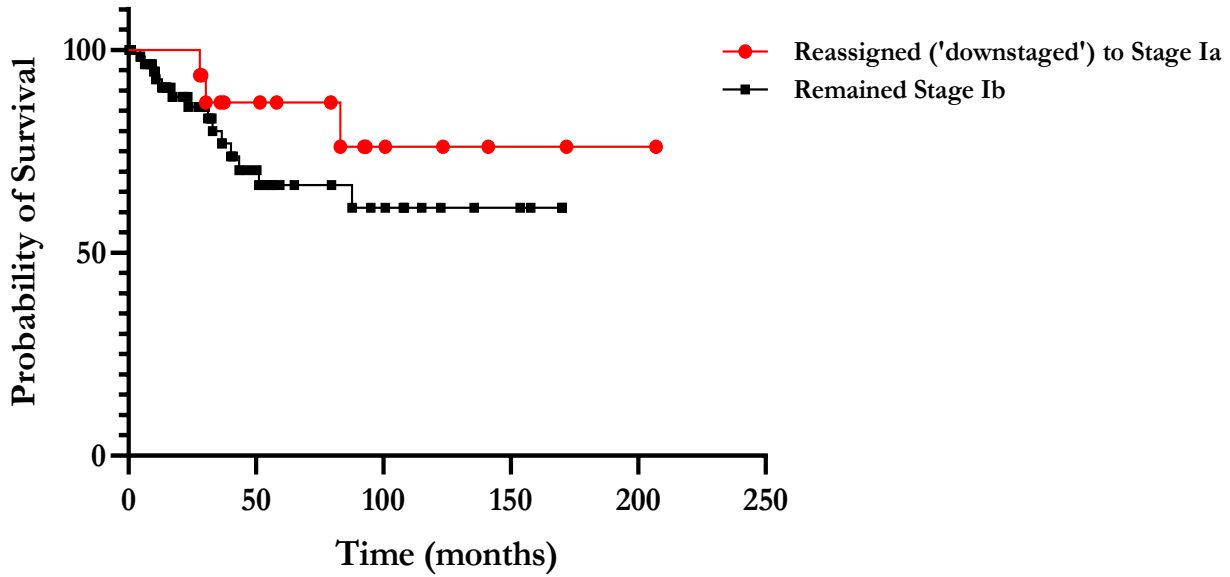

Lab Invest 2023;103(suppl 1): 976-978, abstract 968
Int J Gynecol Pathol 2024;43(5):457-463

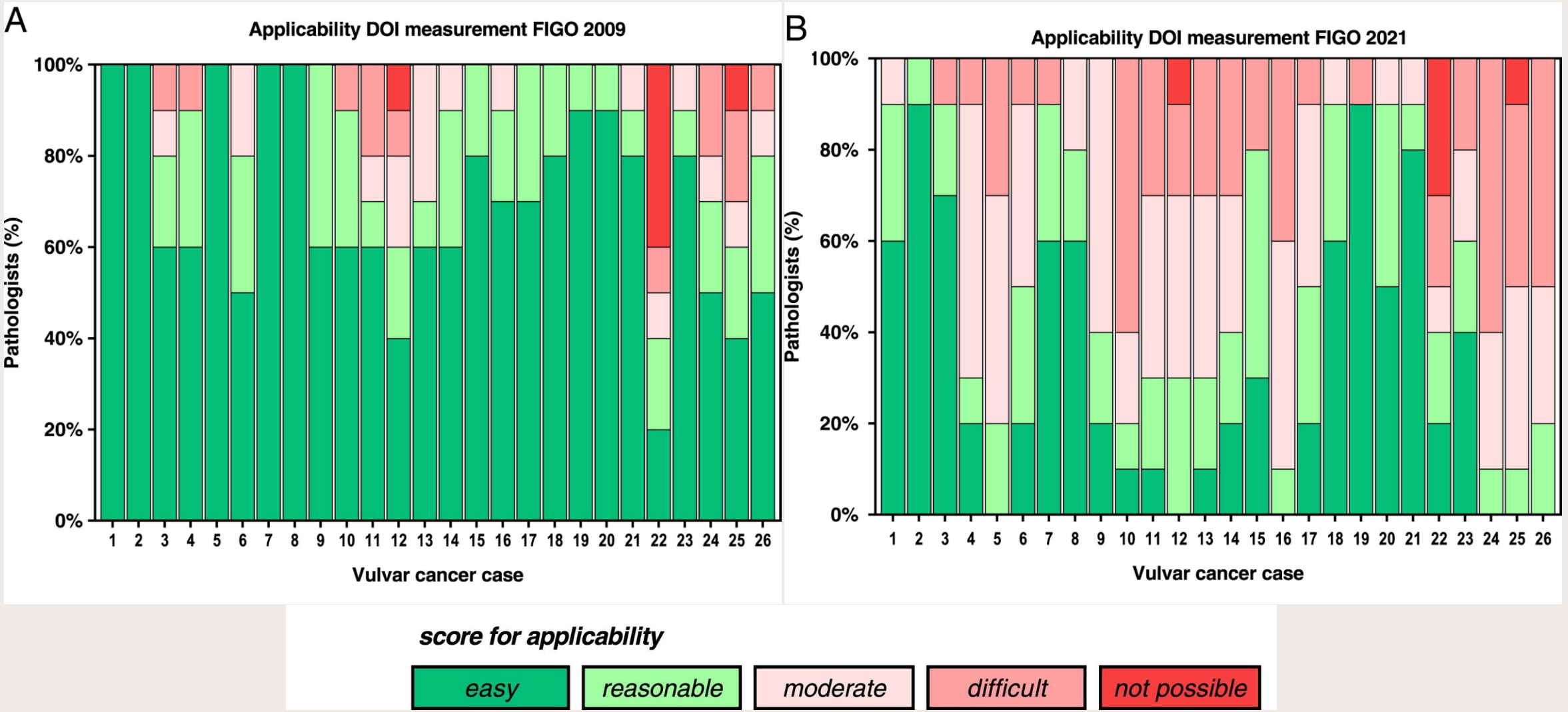

Int J Gynecol Pathol 2024;43(5):457-463

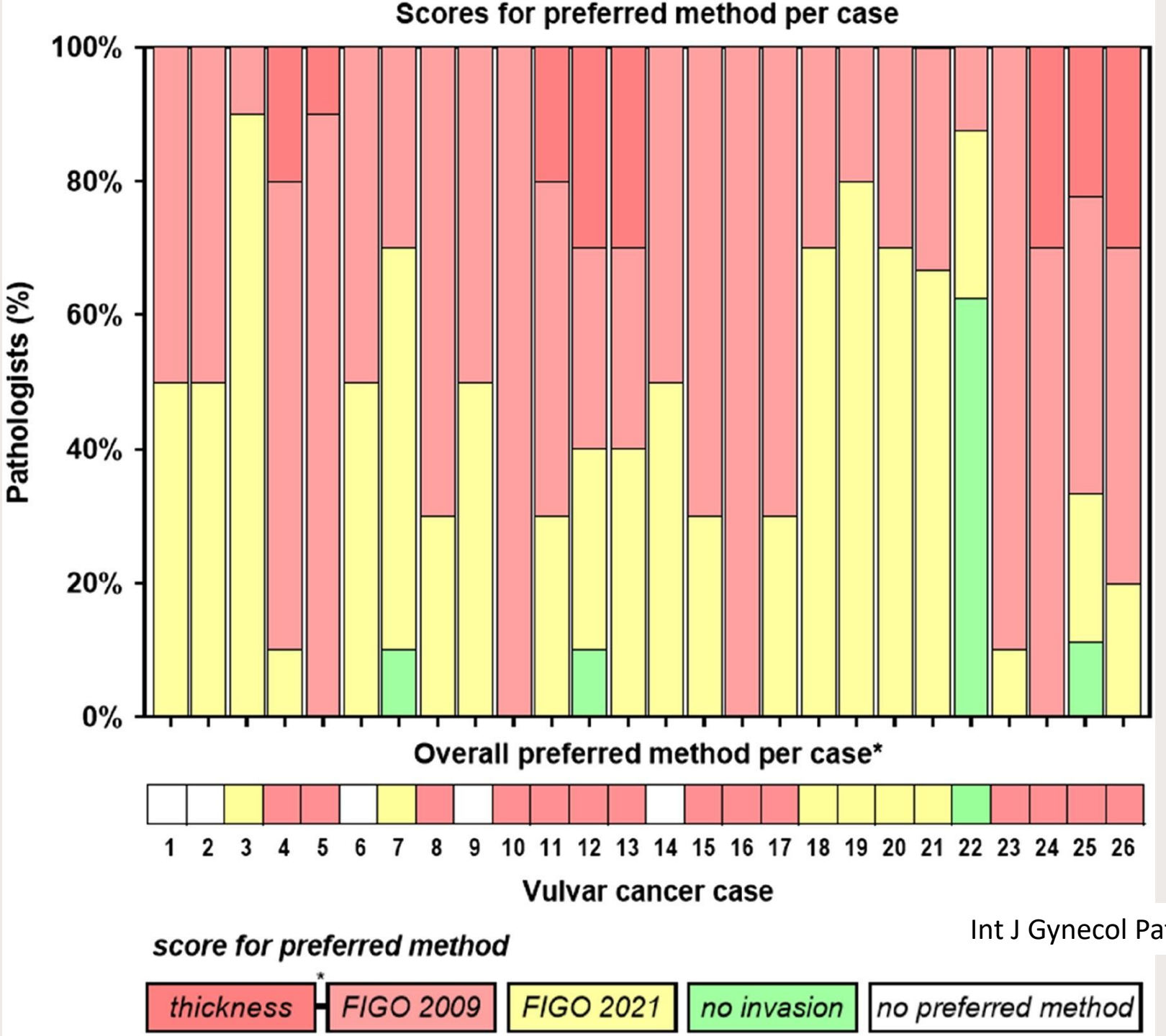

Int J Gynecol Pathol 2024;43(5):457-463

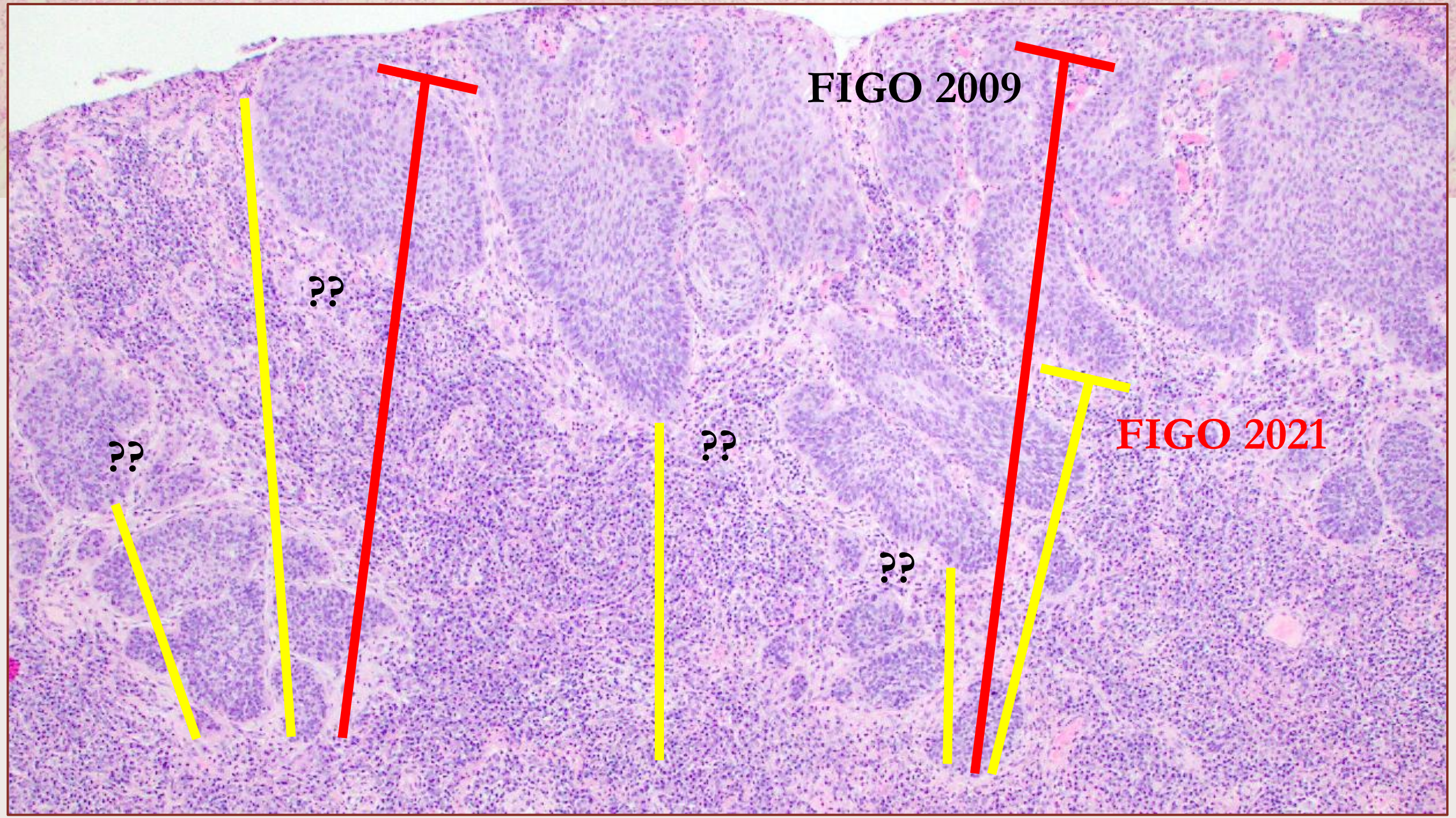
FIGO 2009
??
??
??
??
FIGO 2021

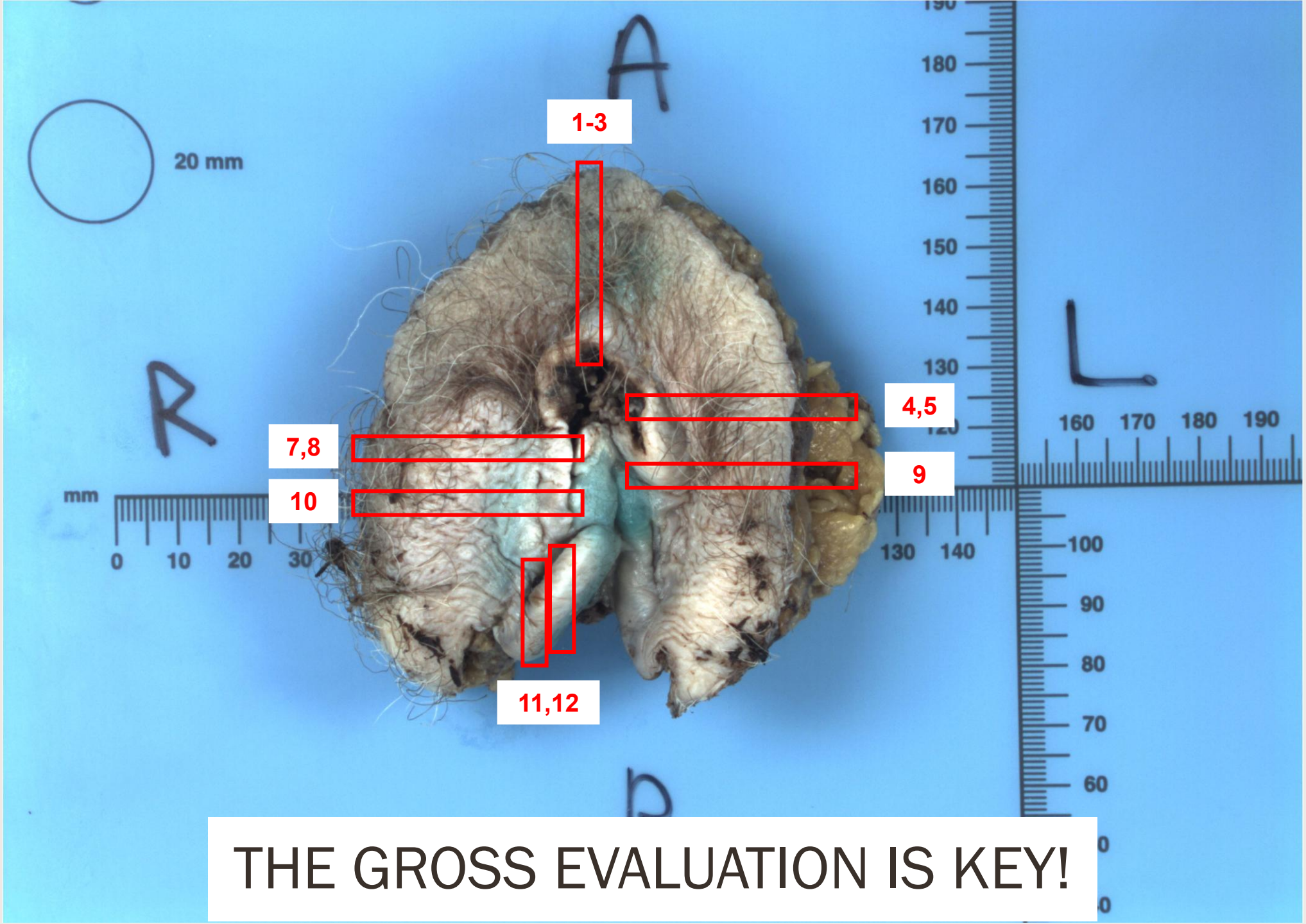

THE GROSS EVALUATION IS KEY!


10
7
8
11,12
6
5
4
1-3
9
THE GROSS EVALUATION IS KEY!

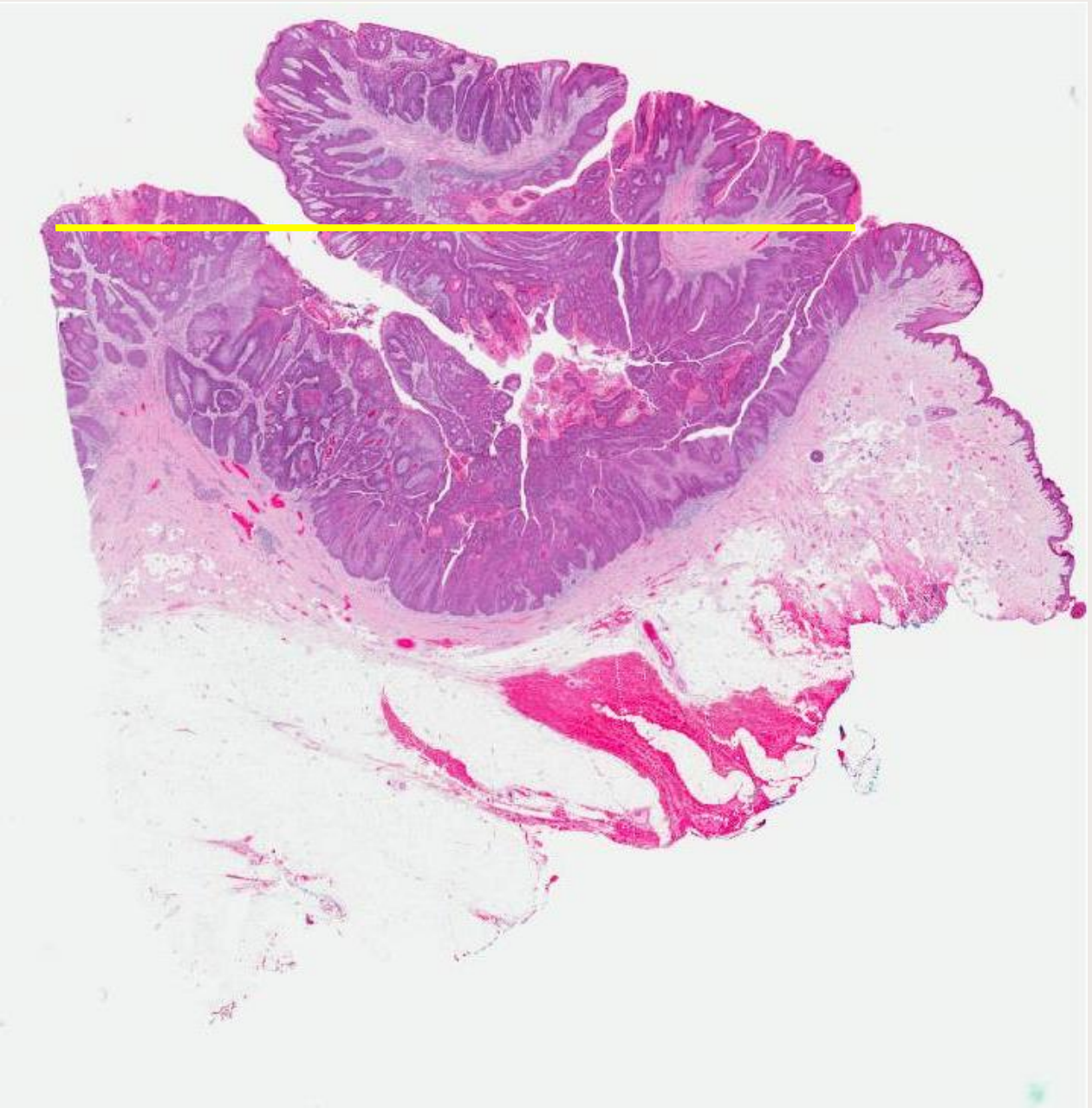

- Tumor size (parallel to the surface)

  AJCC 8th ed: it includes in-situ disease

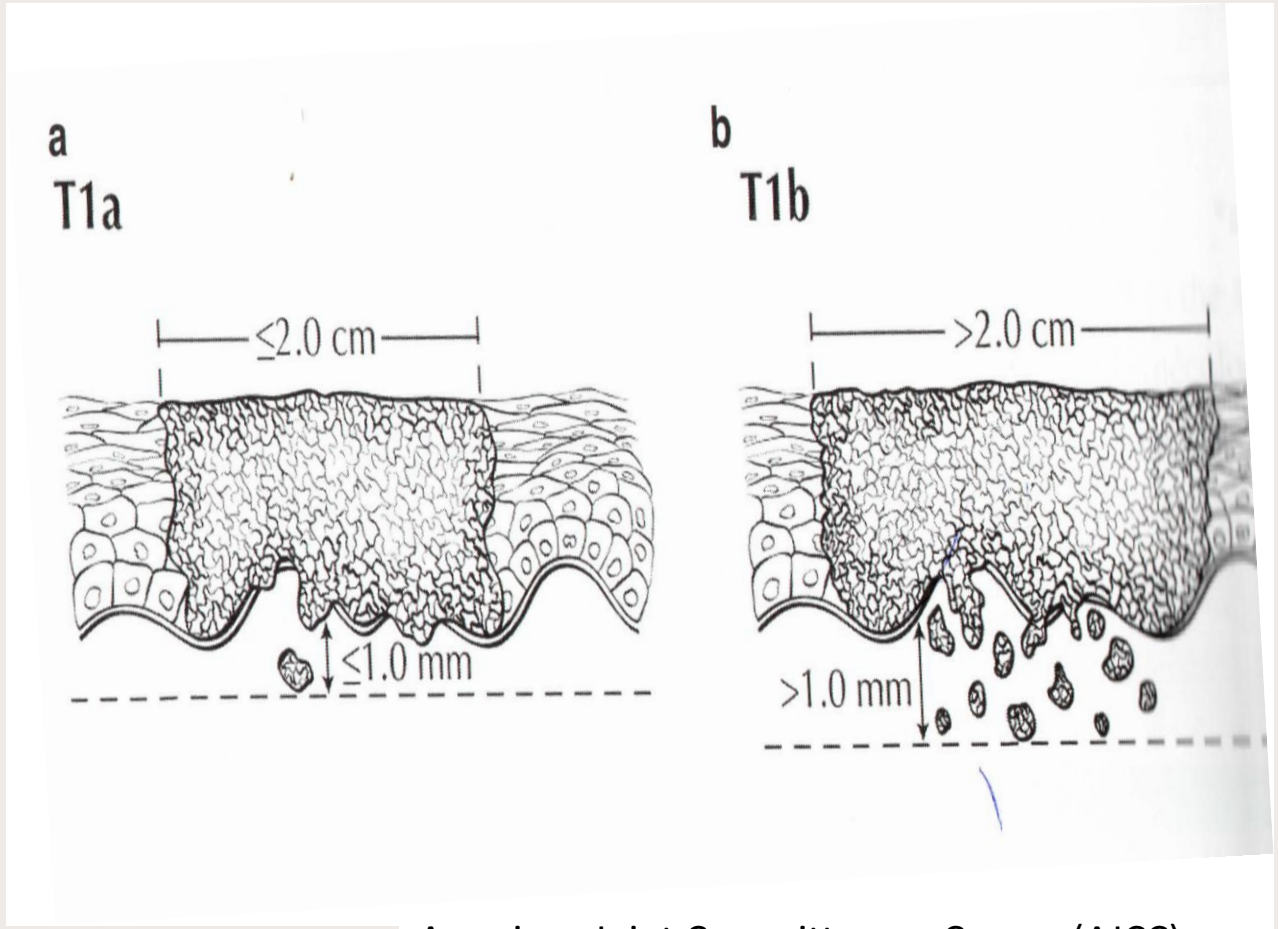

American Joint Committee on Cancer (AJCC) Staging Manual, 8th ed, 2017, Page 646

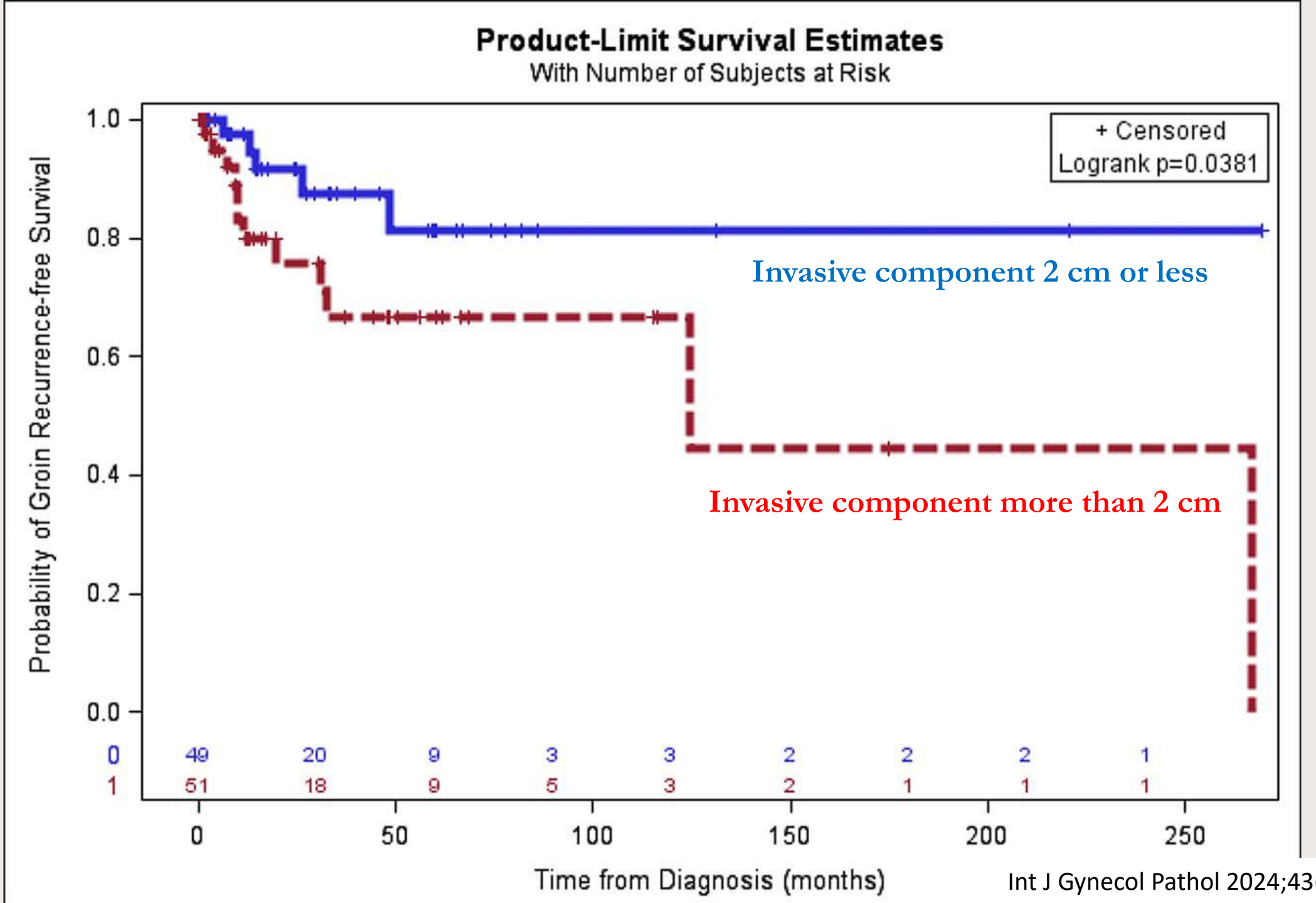

Int J Gynecol Pathol 2024;43(5):457-463

RECOMMENDATIONS

- Reporting tumor size
  - *Correlate invasive tumor size with gross tumor size*
  - *If widely discrepant, report both in a note*
- Reporting depth of invasion
  - *> 1 mm (both FIGO 2009 & 2021 staging systems)*
  - *≤ 1 mm (both FIGO 2009 & 2021 staging systems)*
  - *1.2 mm (FIGO 2009 method); 0.8 mm (FIGO 2021 method)*

International Agency for Research on Cancer

World Health Organization

Female Genital Tumours

Squamous cell tumours and precursors

- Squamous intraepithelial lesions, HPV-associated, of the vulva
- Vulvar intraepithelial neoplasia, HPV-independent
- Squamous cell carcinoma, HPV-associated, of the vulva
- Squamous cell carcinoma, HPV-independent, of the vulva
- Squamous cell carcinoma NOS of the vulva
- Basal cell carcinoma

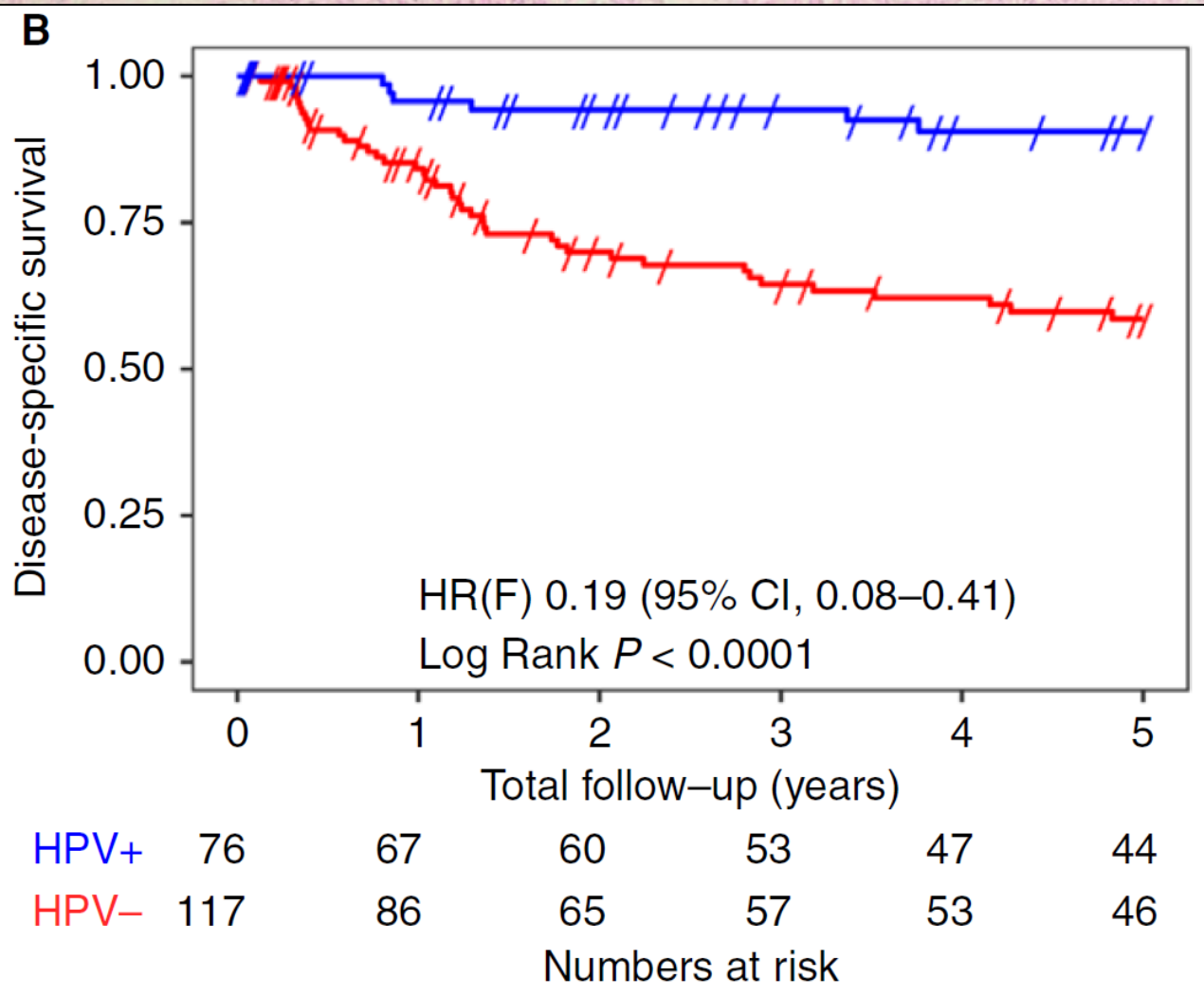

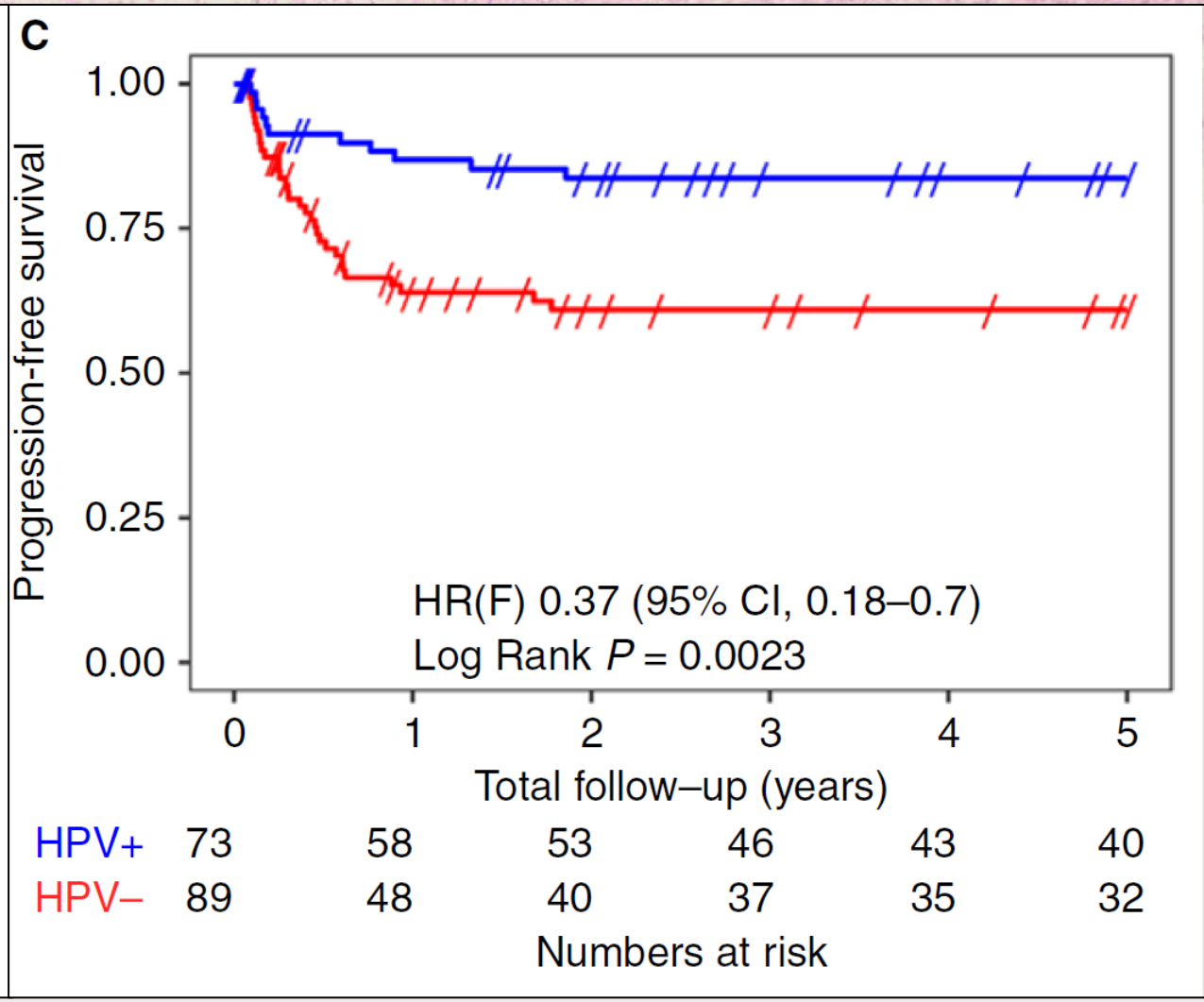

* P16 IHC used as surrogate for HPV status

Histopathol 2017;71:238-246

A

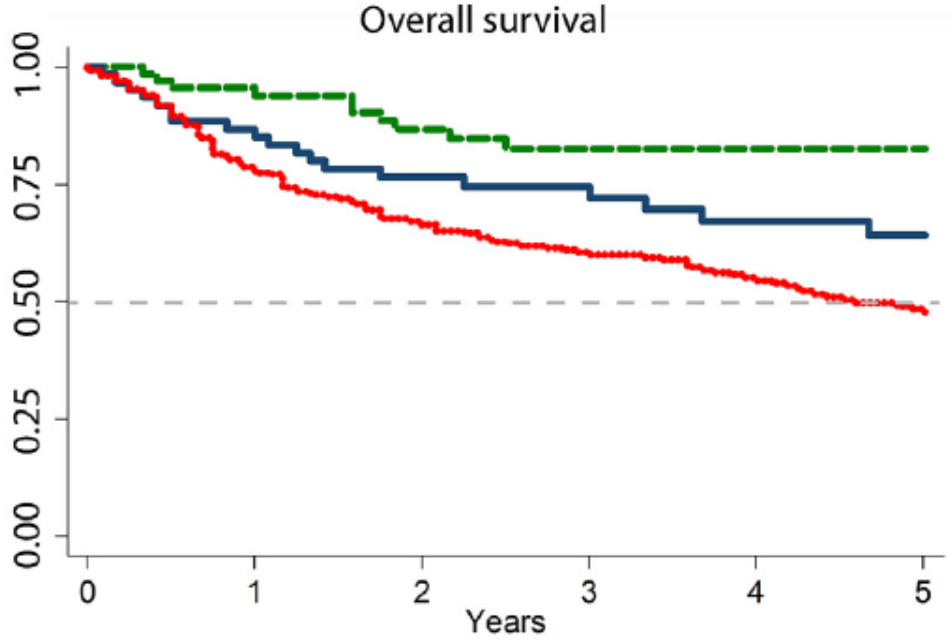

Number at risk						
HPVpos VSCC	75	59	46	35	26	23
HPVneg/p53wt VSCC	63	51	44	32	27	21
HPneg/p53mut VSCC	275	201	161	123	97	72

HPVpos VSCC (REF) versus HPVneg/p53wt VSCC	HR 2.16 (1.00-4.64); p=**0.049**
HPVpos VSCC (REF) versus HPVeg/p53mut VSCC	HR 3.43 (1.80-6.53); p<**0.001**
HPVneg/p53wt VSCC (REF) versus HPVneg/p53mut VSCC	HR 0.63 (0.39-1.02); p=0.06

B

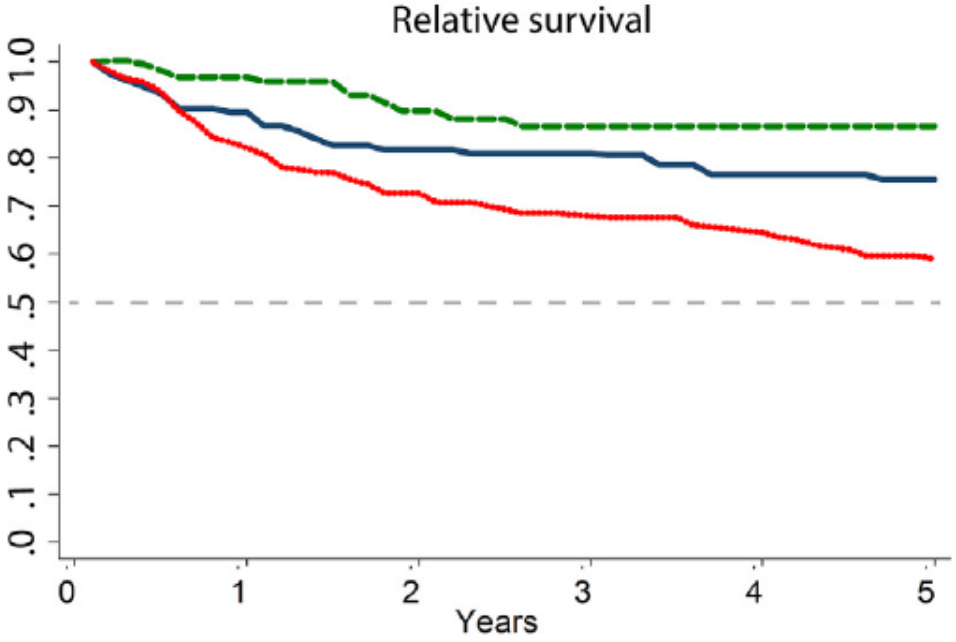

HPVpos VSCC (REF) versus HPVneg/p53wt VSCC	RER 2.26 (0.69-7.37); p=0.18
HPVpos VSCC (REF) versus HPVeg/p53mut VSCC	RER 4.02 (1.48-10.90); p=**0.006**
HPVneg/p53wt VSCC (REF) versus HPVneg/p53mut VSCC	RER 0.56 (0.28-1.15); p=0.11

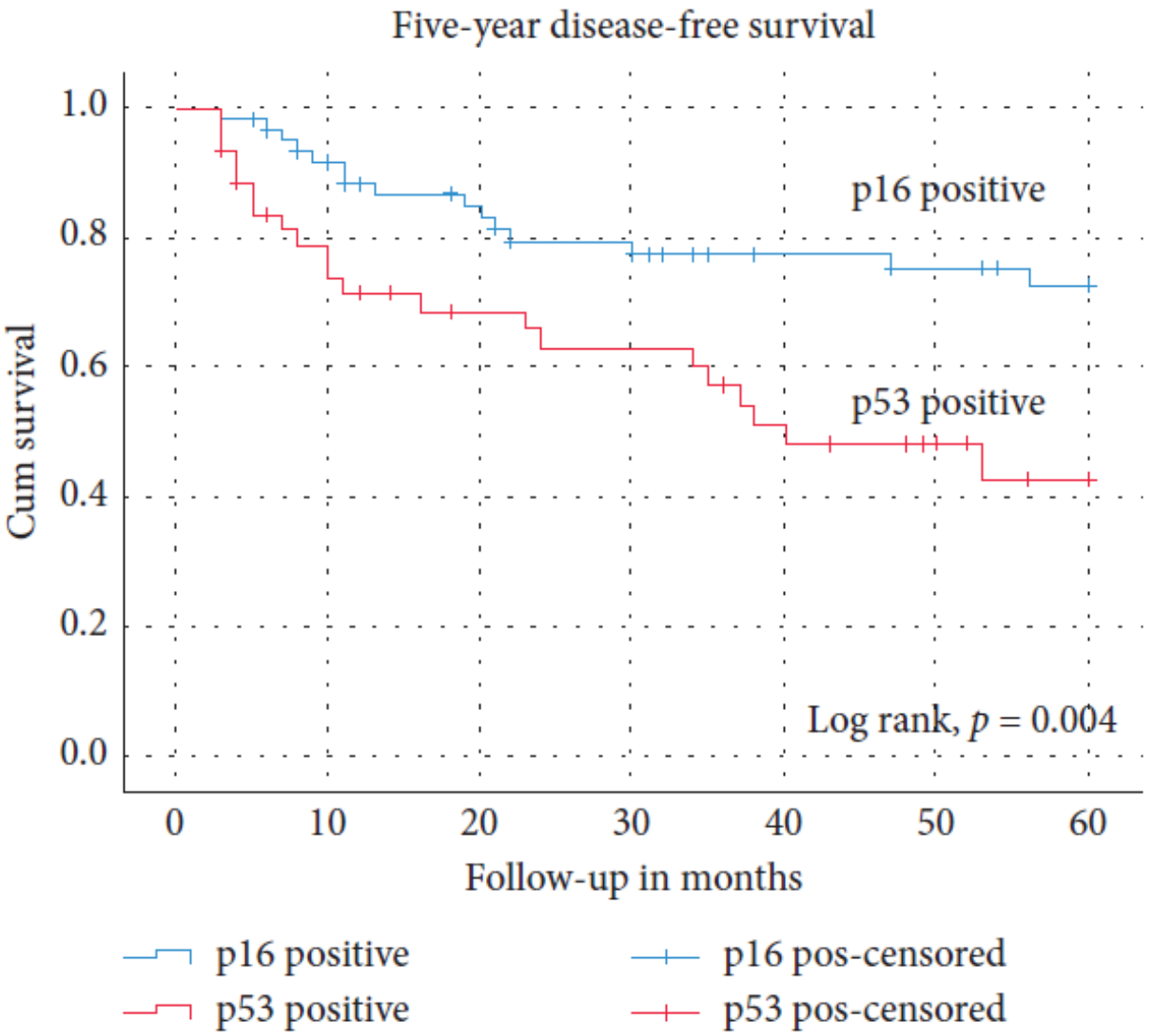

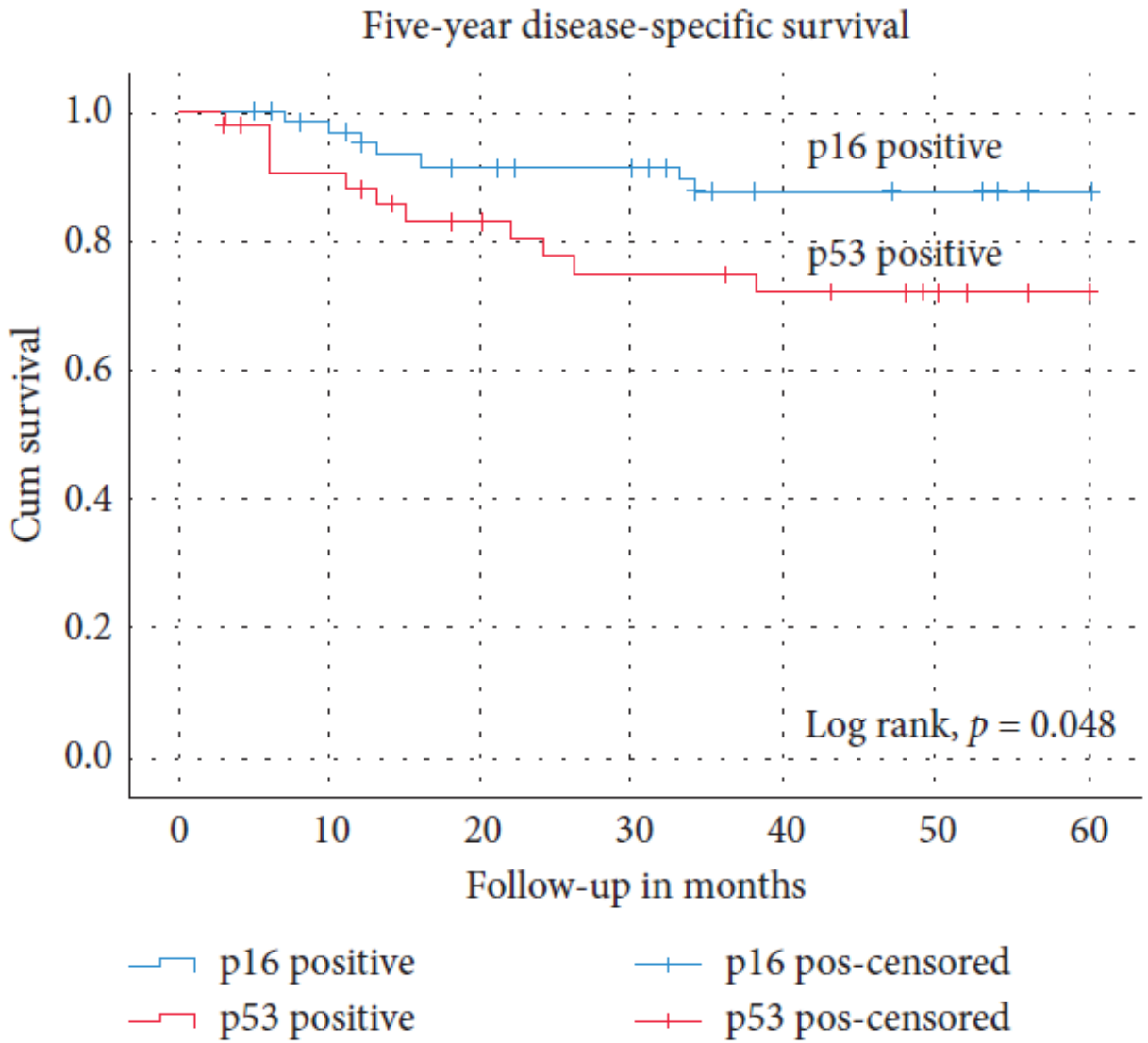

J Oncol 2020;2020:3739075. PMID: 32280343

VULVAR CANCER CLASSIFICATION

- WHO 2025 (draft)
  - *HPV-associated*
  - *HPV-independent*
    - p53-abnormal subtype
    - p53-wildtype subtype
- Subtyping requires p16 & p53 immunohistochemistry

J Low Genit Tract Dis 2016;20:252-256
Mod Pathol 2017;30(S2):293A
Int J Gynecol Pathol 2017;36:507-516
Histopathol 2017;71:238-246

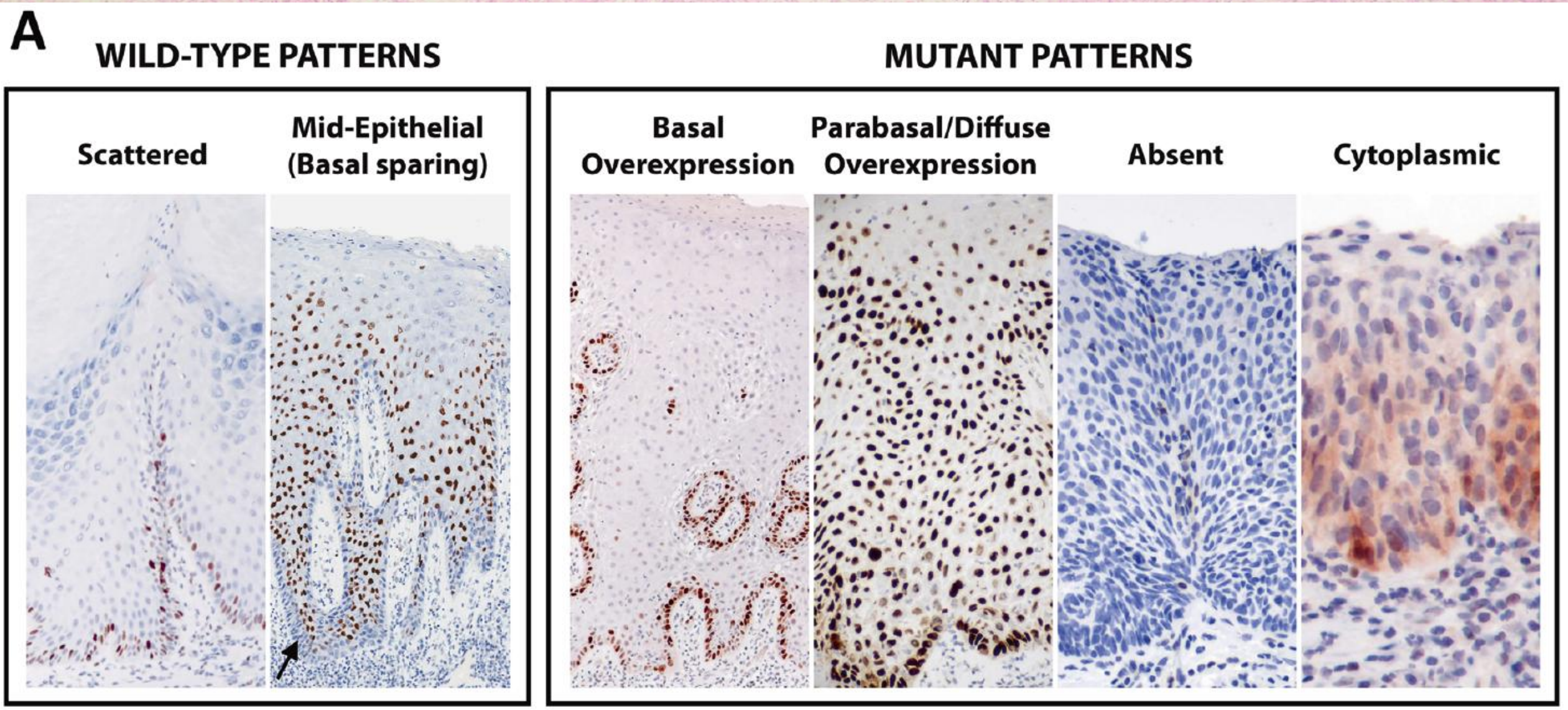

Mod Pathol 2020 PMID: 32203095

MODERN PATHOLOGY

USCAP UNITED STATES AND CANADIAN ACADEMY OF PATHOLOGY
Creating a Better Pathologist

Journal homepage: https://modernpathology.org/

Research Article

Classification of Vulvar Squamous Cell Carcinoma and Precursor Lesions by p16 and p53 Immunohistochemistry: Considerations, Caveats, and an Algorithmic Approach

Hang Yang[a], Noorah Almadani[b], Emily F. Thompson[a], Basile Tessier-Cloutier[c], Julia Chen[d], Julie Ho[a,e], Janine Senz[f], Melissa K. McConechy[g], Christine Chow[e], Monica Ta[e], Angela Cheng[e], Anthony Karnezis[h], Jutta Huvila[i], Jessica N. McAlpine[j], Blake Gilks[a,e], Amy Jamieson[j], Lynn N. Hoang[a,e,*]

Mod Pathol 2023;36:100145

Inusual results

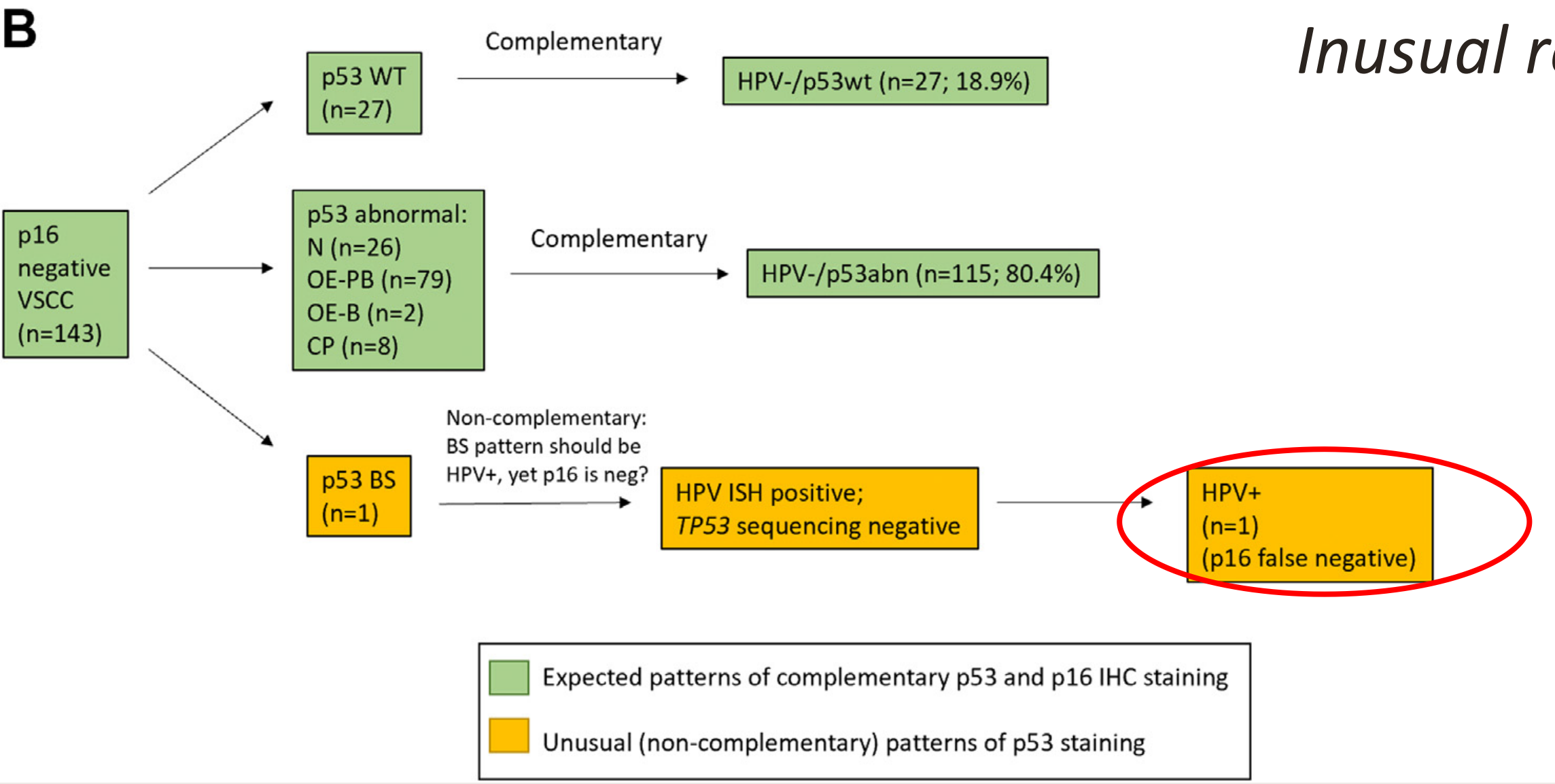

Mod Pathol 2023;36:100145

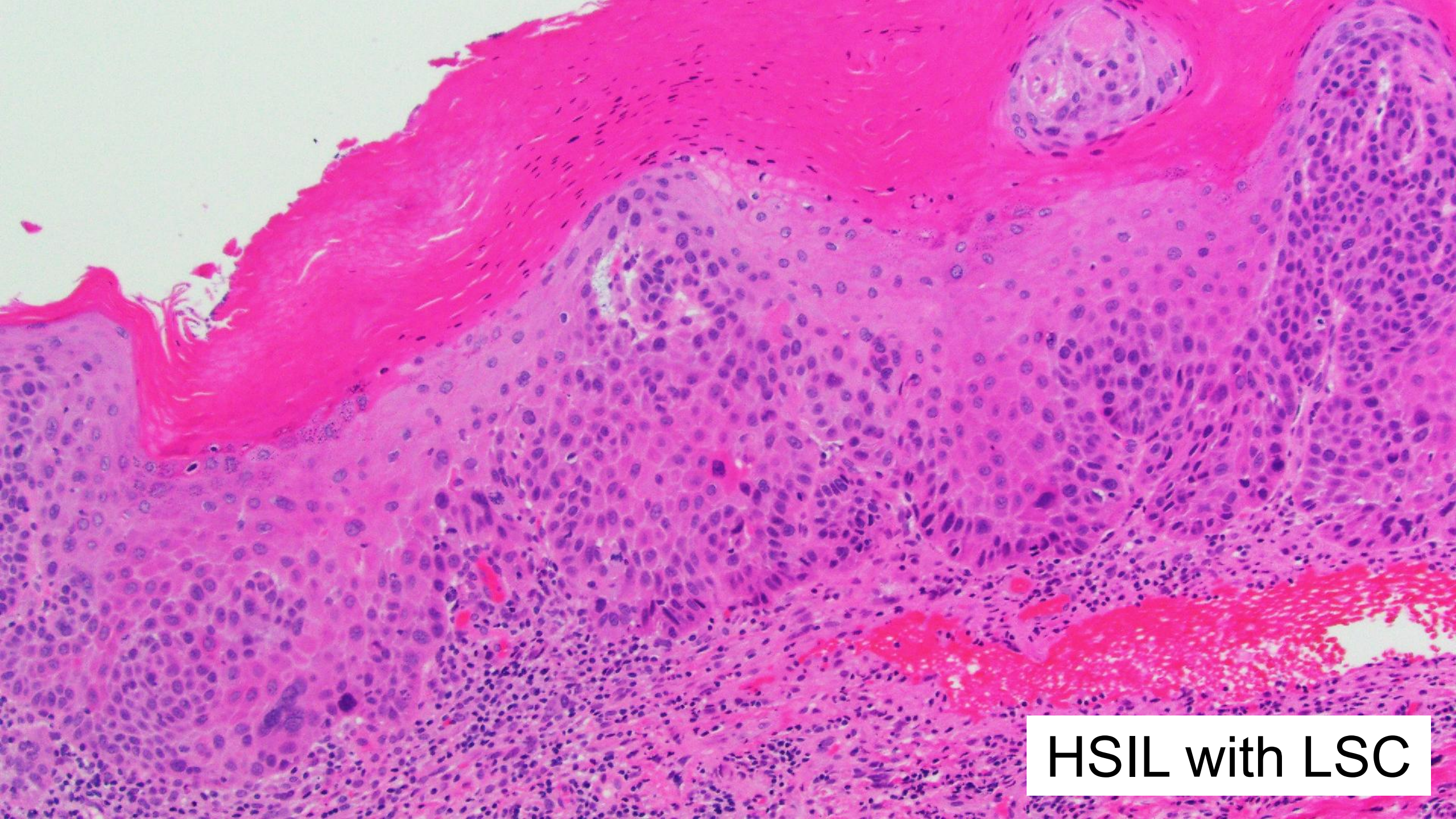
HSIL with LSC

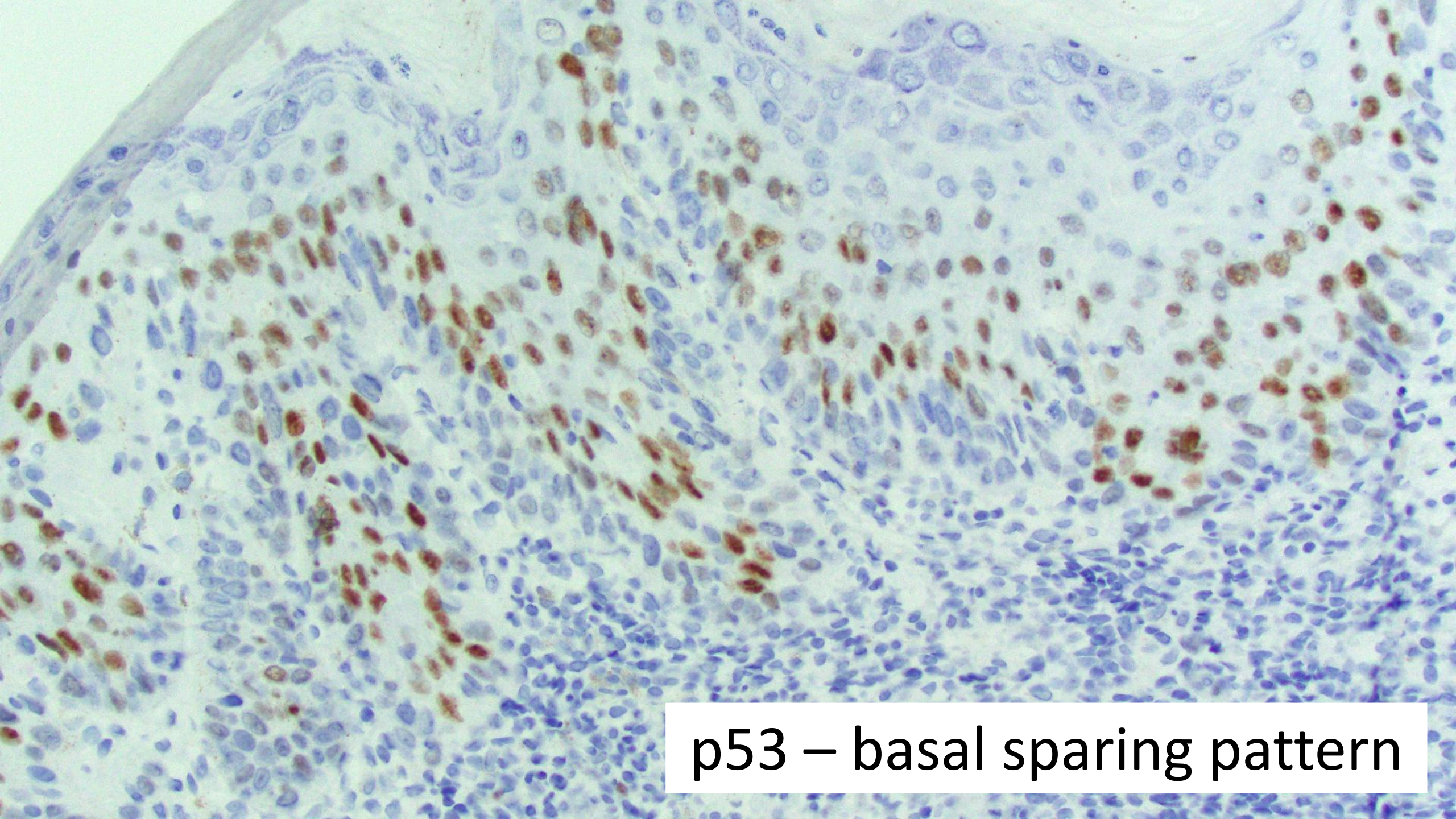
p53 – basal sparing pattern

Inusual results

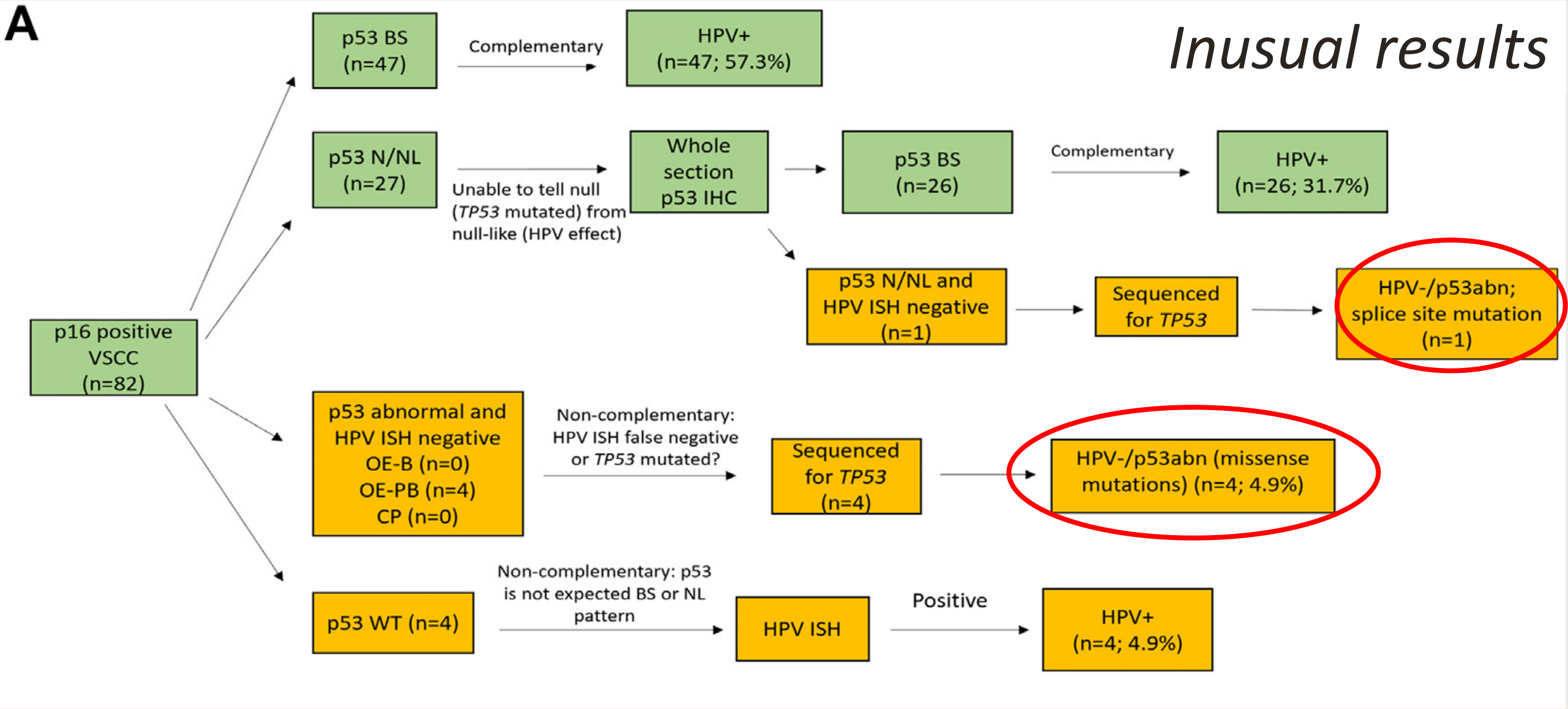

Mod Pathol 2023;36:100145

International Agency for Research on Cancer

World Health Organization

Female Genital Tumours

Squamous cell tumours and precursors

- Squamous intraepithelial lesions, HPV-associated, of the vulva
  - Vulvar intraepithelial neoplasia, HPV-independent
- Squamous cell carcinoma, HPV-associated, of the vulva
- Squamous cell carcinoma, HPV-independent, of the vulva
- Squamous cell carcinoma NOS of the vulva
- Basal cell carcinoma

VULVAR SQUAMOUS PRECURSORS

- HPV-associated Vulvar Intraepithelial Lesion
- HPV-independent Vulvar Intraepithelial Neoplasia
  - WHO 2020
    - Differentiated type
    - Differentiated exophytic vulvar intraepithelial lesion
  - WHO 2025 (draft)
    - p53-abnormal subtype
    - p53-wildtype subtype

VULVAR PRECURSOR CLASSIFICATION

MORPHOLOGY BASED

- Squamous intraepithelial lesion
- Differentiated VIN
- Verruciform acanthotic VIN

BIOMARKER BASED

- HPV-associated
- HPV-independent p53 mutant
- HPV-independent p53 wild type

WHO CLASSIFICATION

Histopathology

Histopathology 2024, **84**, 301–314. DOI: 10.1111/his.15050

High-grade vulvar intraepithelial neoplasia: comprehensive characterization and long-term vulvar carcinoma risk

Nikki B Thuijs,[1,2] Marc van Beurden,[3] Sylvia Duin,[1,2] Daniëlle A M Heideman,[1,2,4] Johannes Berkhof,[5] Renske D M Steenbergen[1,2] & Maaike C G Bleeker[1,2]

- 751 high-grade VINs
- Re-classified based on histopathology + immunohistochemistry (p16, p53, Ki-67) and HPV DNA
- 46 HPV-independent VIN
  - *30 (65%) p53mut* *16 (35%) p53 wt*
  - *59% differentiated*
  - *41% nondifferentiated ('HPV associated-like')*

Histopathology 2024;84:301-14

Table 1. Categorization of vulvar lesions after reassessment in relation to the original diagnosis and age at baseline

	Original diagnosis			Age, years
	HSIL	DVIN	Total (%)	Median (range)
	743	8	751 (100)	45.0 (16–92)
Final categorization				
HPV-associated	663	1	664 (88.4)	44.0 (17–91)
HSIL	578	0	578 (77.0)	45.0 (17–90)
LSIL	81	1	82 (10.9)	39.0 (19–91)
VSCC	3	0	3 (0.4)	39.0 (37–48)
HPV-independent	75	7	82 (10.9)	67.0 (16–92)
HPV-independent VIN	39	7	46 (6.1)	72.0 (35–92)
Nondysplastic	35	0	35 (4.7)	58.0 (16–79)
VSCC	1	0	1 (0.1)	67.0 (NA)
Inconclusive	6	0	6 (1.1)	75.0 (46–88)

Histopathology 2023;84:301–314

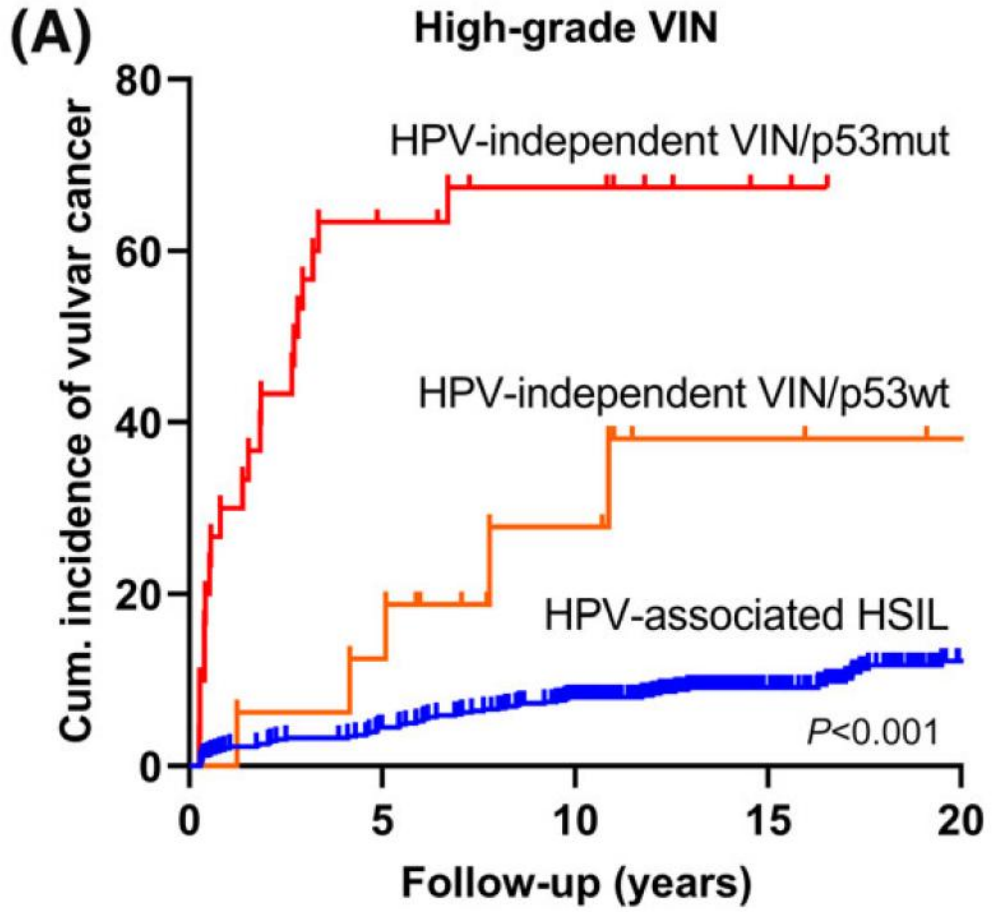

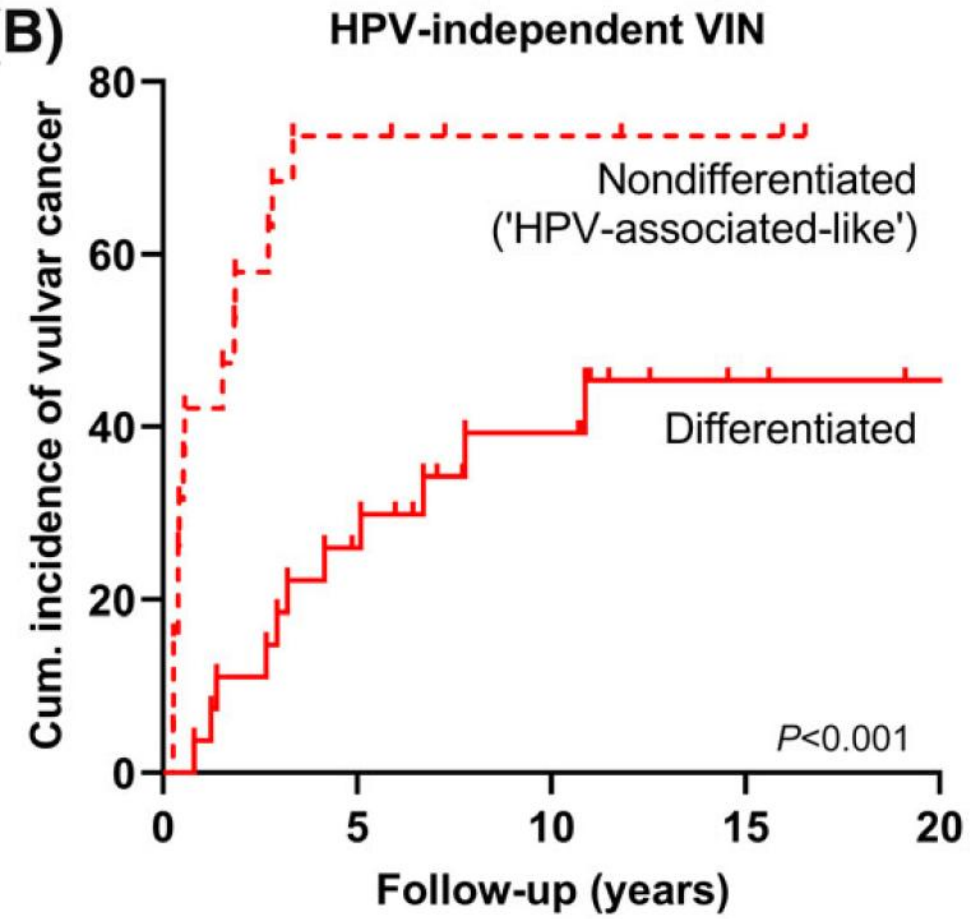

HPV-ind/p53mut	30	10	7	2	0
HPV-ind/p53wt	16	14	8	4	2
HPV-ass HSIL	578	548	496	303	174

Nondiff.	19	5	3	2	0
Diff.	27	19	12	4	2

Histopathology 2024;84:301-14

Table 4. Risk of vulvar squamous cell carcinoma (VSCC), including time to VSCC, per disease category

	Absolute VSCC risk	Cumulative incidence of VSCC (95% CI)			Median time to VSCC,
	No. (%)	1 year	5 years	10 years	years (range)
HPV-associated HSIL	61/578 (10.6)	2.1 (0.9–3.3)	4.5 (2.7–6.3)	8.0 (5.8–10.2)	6.0 (0.3–24.2)
HPV-independent VIN	25/46 (54.3)	19.6 (8.2–31.0)	45.7 (31.4–60.0)	53.6 (38.7–68.5)	1.8 (0.3–10.9)
HPV-ind VIN/p53 mutant	20/30 (66.7)	30.0 (13.5–46.5)	63.3 (46.1–80.5)	67.4 (50.3–84.5)	1.5 (0.3–6.7)
HPV-ind VIN/p53 wildtype	5/16 (31.3)	0.0 (NA)	12.5 (0.0–28.8)	27.8 (3.9–51.7)	5.1 (1.2–10.9)
HPV-ind VIN/ differentiated	11/27 (40.7)	3.7 (0.0–10.8)	25.9 (9.4–42.4)	39.3 (19.9–58.7)	3.2 (0.8–23.3)
HPV-ind VIN/ nondifferentiated	14/19 (73.7)	42.1 (20.0–64.2)	73.7 (53.9–93.5)	73.7 (53.9–93.5)	0.5 (0.3–16.5)

HSIL, High-grade squamous intraepithelial lesion; HPV-independent VIN, Human papillomavirus-independent vulvar intraepithelial neoplasia; NA, Not applicable.

Histopathology 2024;84:301-14



Is p16/HPV and p53 available?

- Squamous intraepithelial lesion
- Differentiated HPV-independent VIN
- Verruciform acanthotic HPV-independent VIN

HPV-INDEPENDENT VIN

- Usually in post-menopausal women (70-80 years)
- Chronic inflammatory conditions
  - *Mainly, lichen sclerosus*
  - *Rarely, lichen planus & lichen simplex chronicus*

J Clin Pathol 2014;67(4):290-4
Mod Pathol 2010;23:404-12
Mod Pathol 2011;24(2):297-305
Int J Gynecol Cancer 2003;89:2249-53

HPV-INDEPENDENT DIFFERENTIATED VIN

- Rare (5-10% of all VINs)
- Median time to progression to VSCC: 9–23 months
- 10-year cumulative VSCC risk: 50%
  - *Compared to 10% for HSIL*
- Absolute risk for primary SCC: 33-86%
  - *Compared to 3-10% cancer risk for HSIL*

Cancers 2021;13:6170
Int. J. Cancer 2020;148:90–98

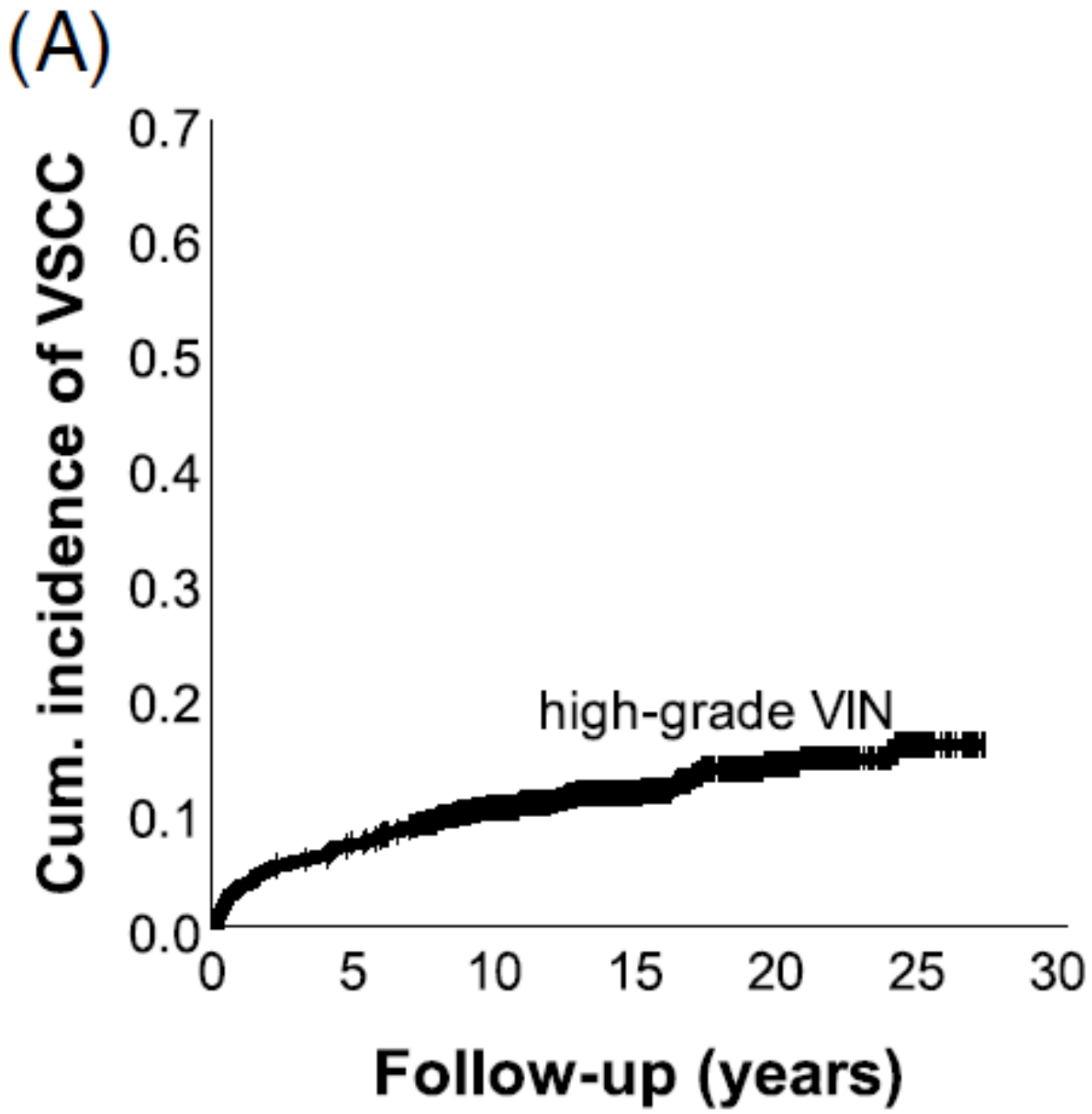

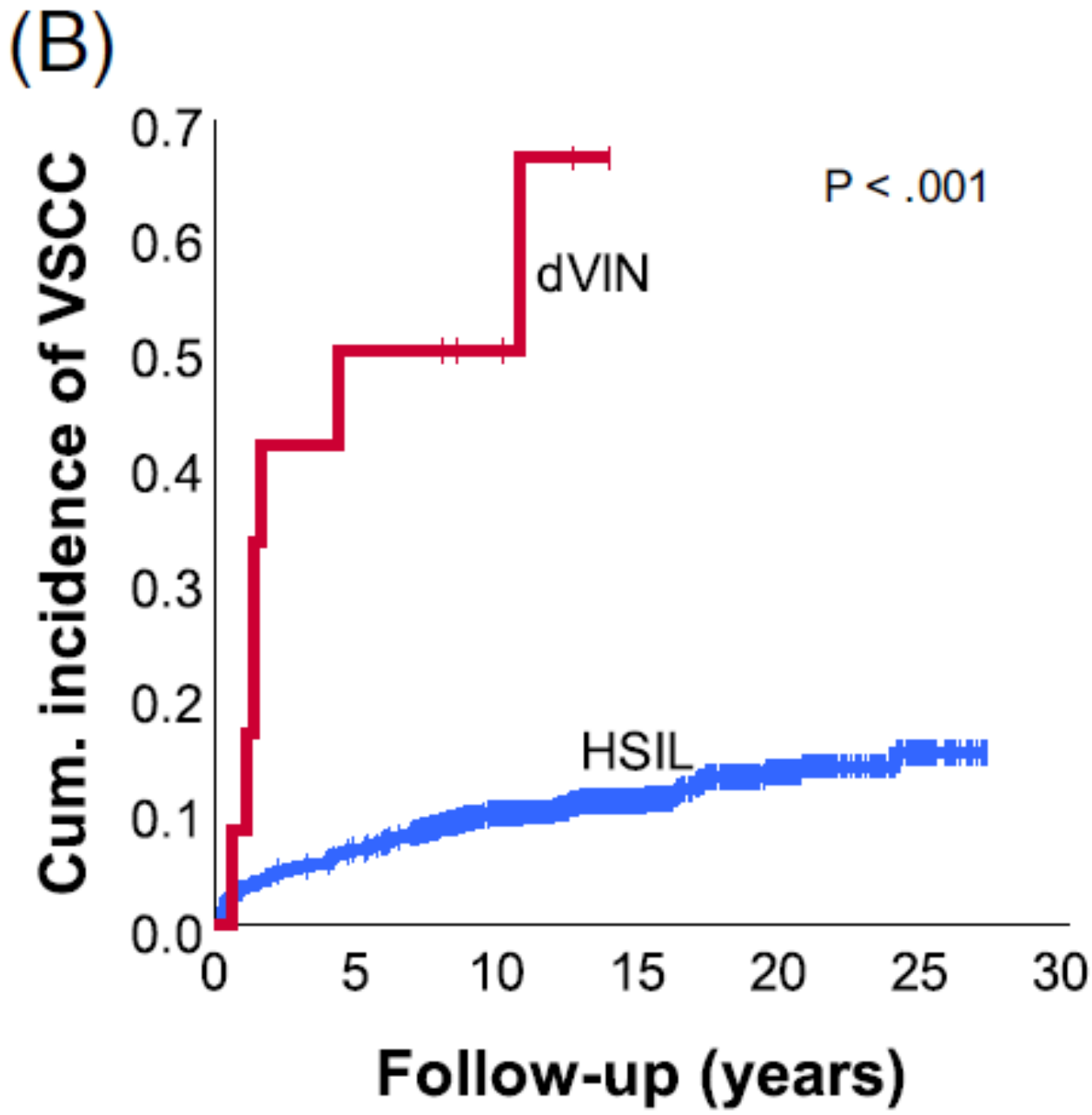

Int. J. Cancer 2020;148:90–98

Interobserver Agreement Across Subspecialties for Diagnosis of Differentiated Vulvar Intraepithelial Neoplasia and Predictive Values of 20 Histologic Features

Shula A. Schechter, MD; May P. Chan, MD; Selvaraj Muthusamy, MBBS, PhD; Stephanie L. Skala, MD; Grace Y. Wang, MD

Table 1. Logistic Regression for Prediction of Differentiated Vulvar Intraepithelial Neoplasia (dVIN) and Progression to Squamous Cell Carcinoma (SCC)

	Coefficient[a]	*P* Value[a]	Coefficient[b]	*P* Value[b]
Keratin pearls	1.95	<.001	1.96	<.001
Basal pleomorphism	1.97	<.001	1.20	<.001
Basal layer disarray	0.91	<.001	1.08	<.001
Parakeratosis	0.67	<.001	0.83	<.001
Epidermal thickness	0.76	.002	1.05	<.001
Hypergranulosis	0.39	.05	0.67	<.001
Lichenoid inflammation	0.63	.20	0.69	.002
Anastomosing rete	0.20	.35	−0.04	.84
Elongated rete	0.07	.78	0.26	.42
Homogenized dermal collagen	−0.87	<.001	−0.78	.003

[a] Coefficient and *P* values for prediction of dVIN.
[b] Coeffcient and *P* values for prediction of progression to SCC.

Arch Pathol Lab Med 2023;147(12):1431-1437

Retained overall organization and maturation

Atypia discernable under × 100

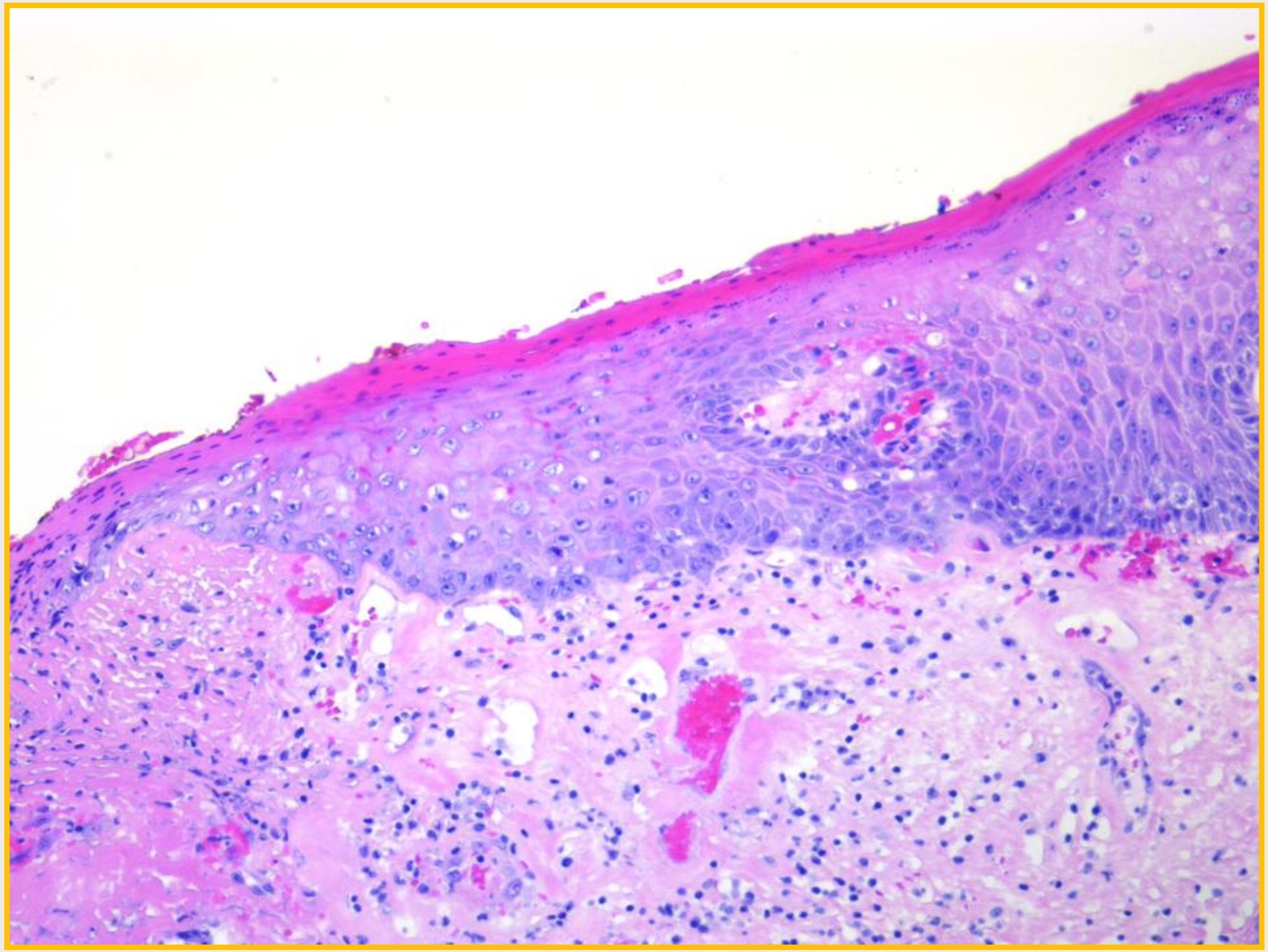

- Basal cell atypia
  - Nuclear enlargement
  - Prominent nucleoli
- Basal layer disarray

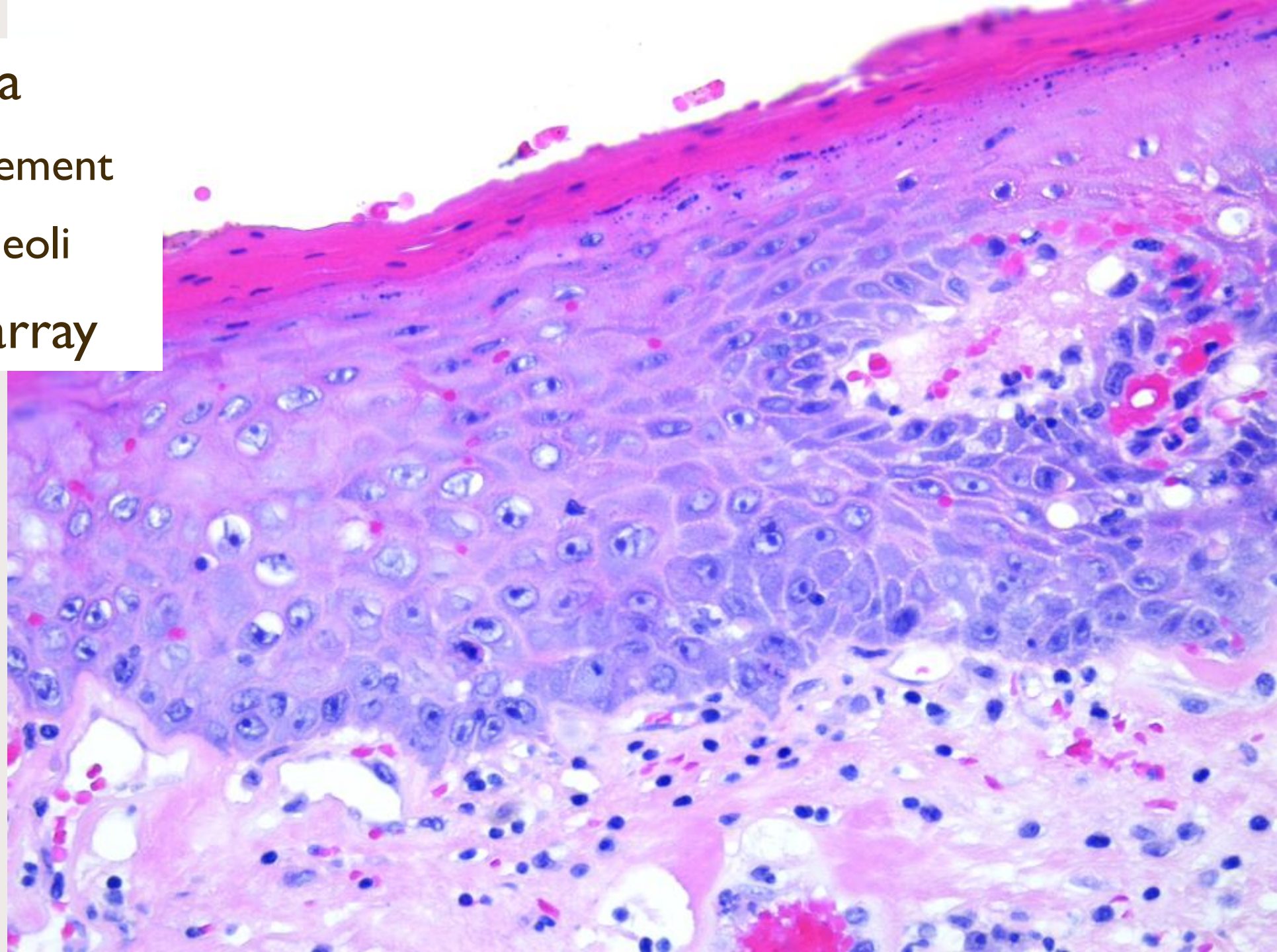

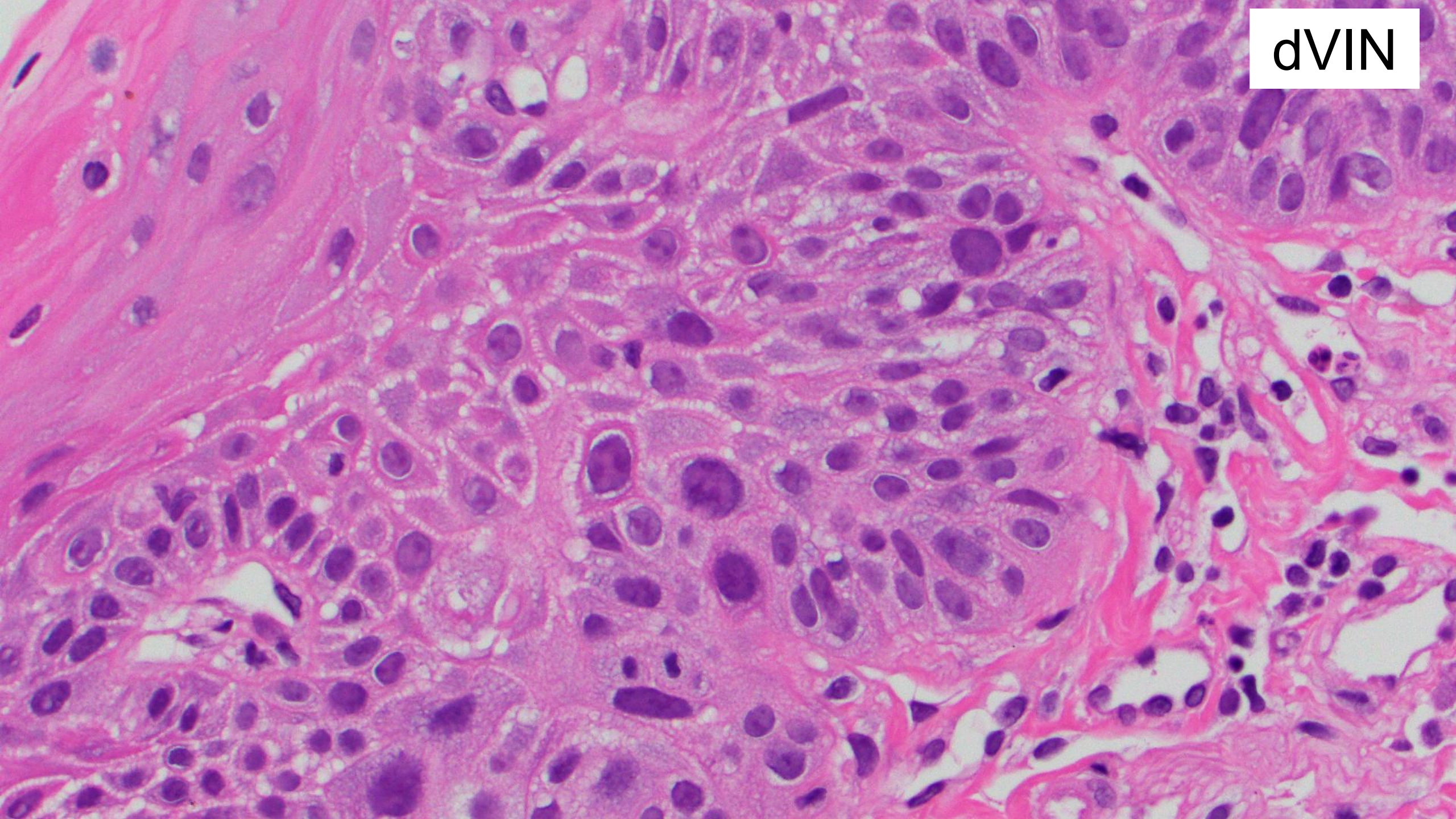
dVIN

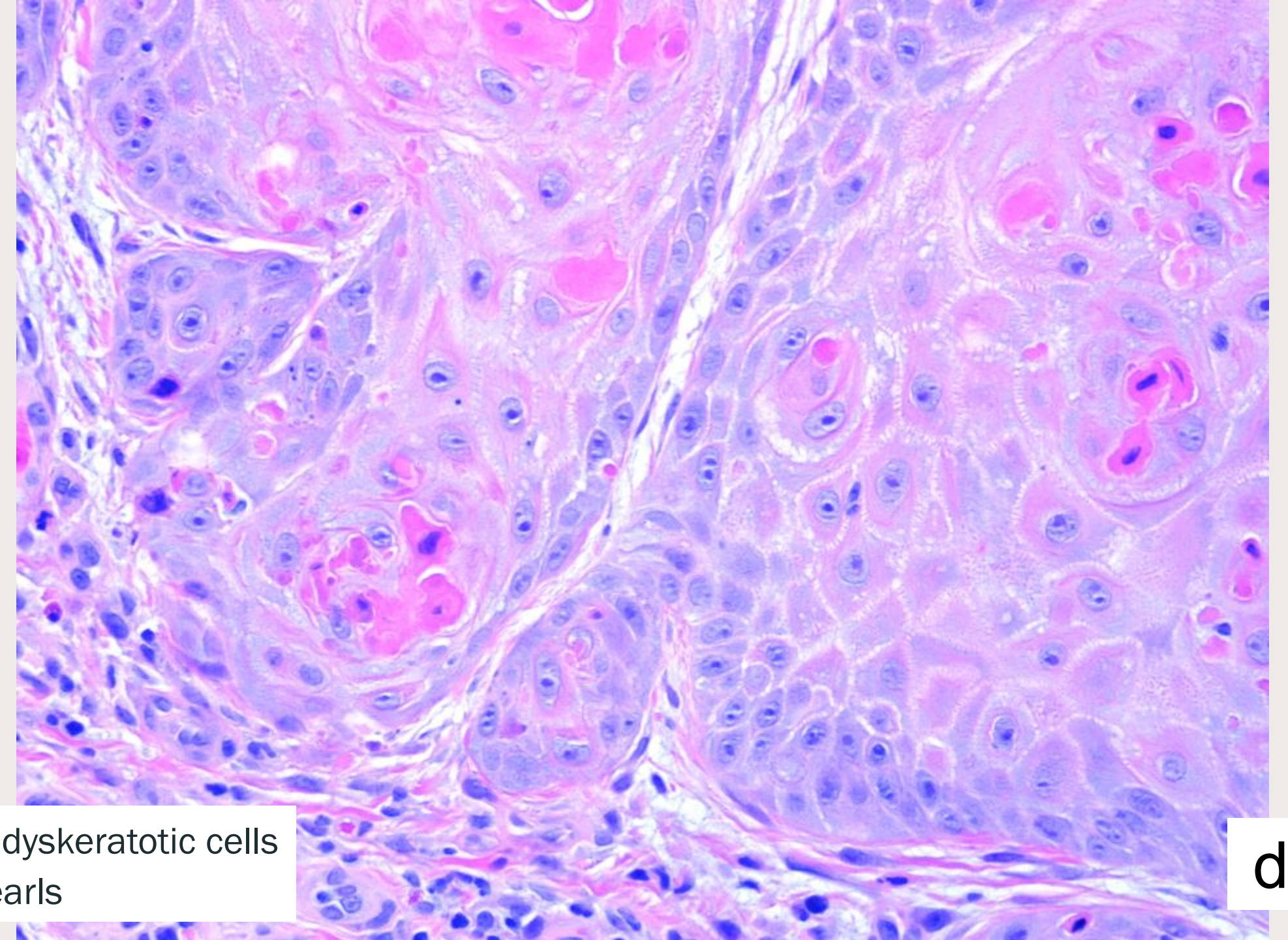

Individual dyskeratotic cells
Keratin pearls

dVIN

Spongiosis and acantholysis (basal and parabasal)

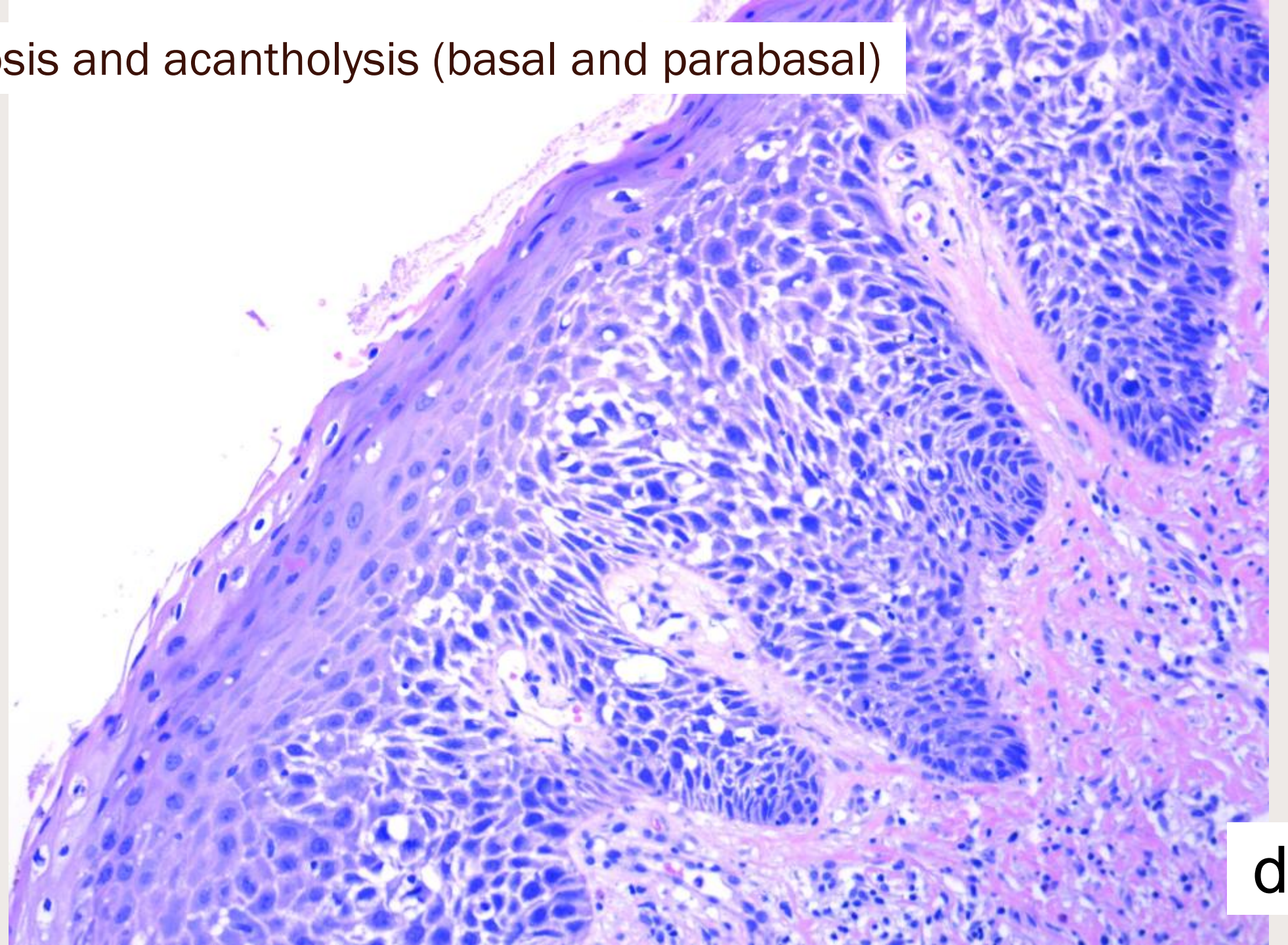

dVIN

Basal cell expansion

- Hypercellularity
- Elongation and anastomosis of the rete pegs

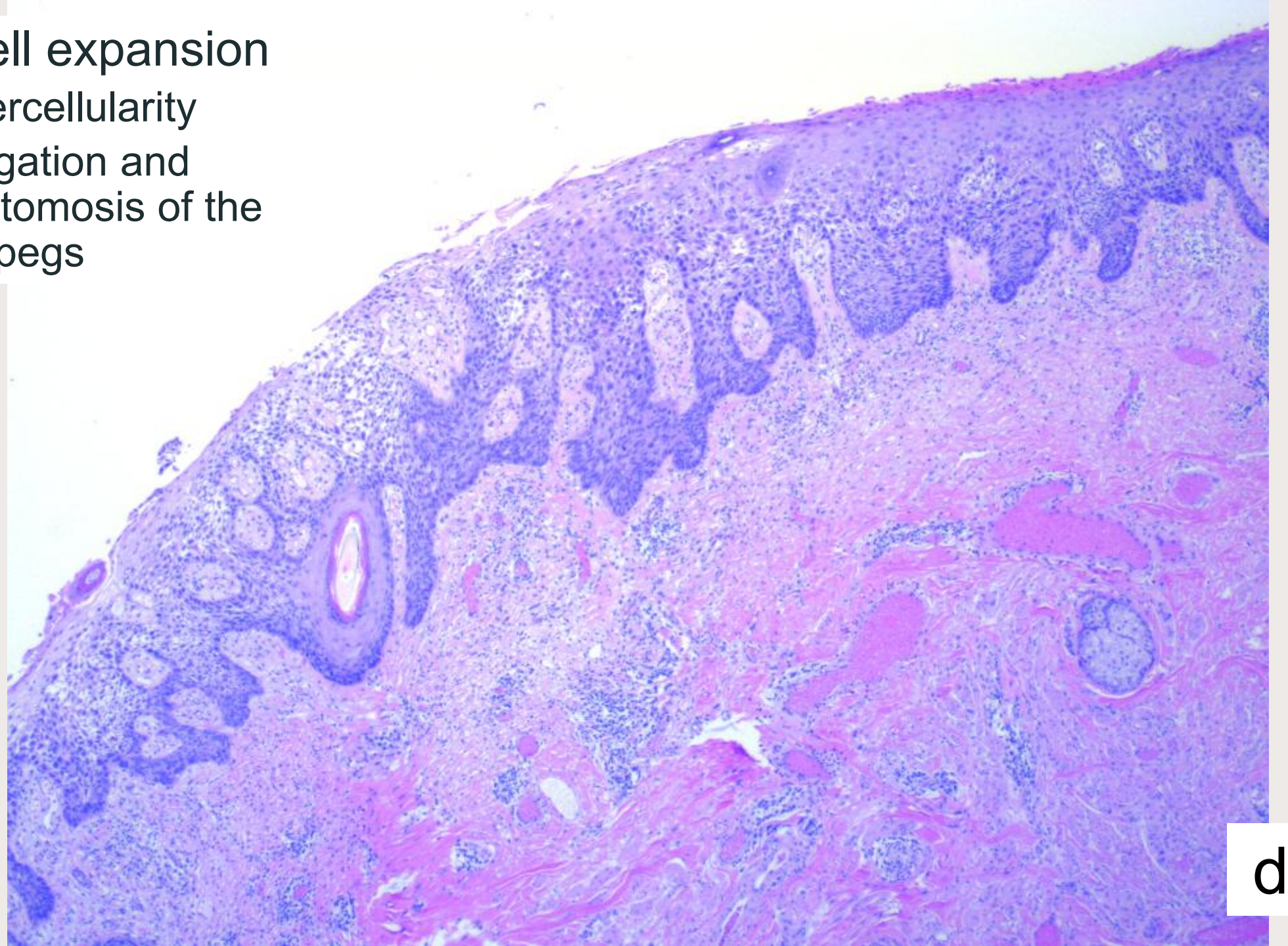

dVIN

HPV-INDEPENDENT VIN

- HSIL-like / Basaloid HPV-I VIN
  - *Less frequent (10-20% of HPV-I VIN cases)*
  - *Immature appearance*
  - *Overlap with HSIL*

Am J Surg Pathol 2009;33(11):1659-65
Am J Surg Pathol 2020;44:1506–1514

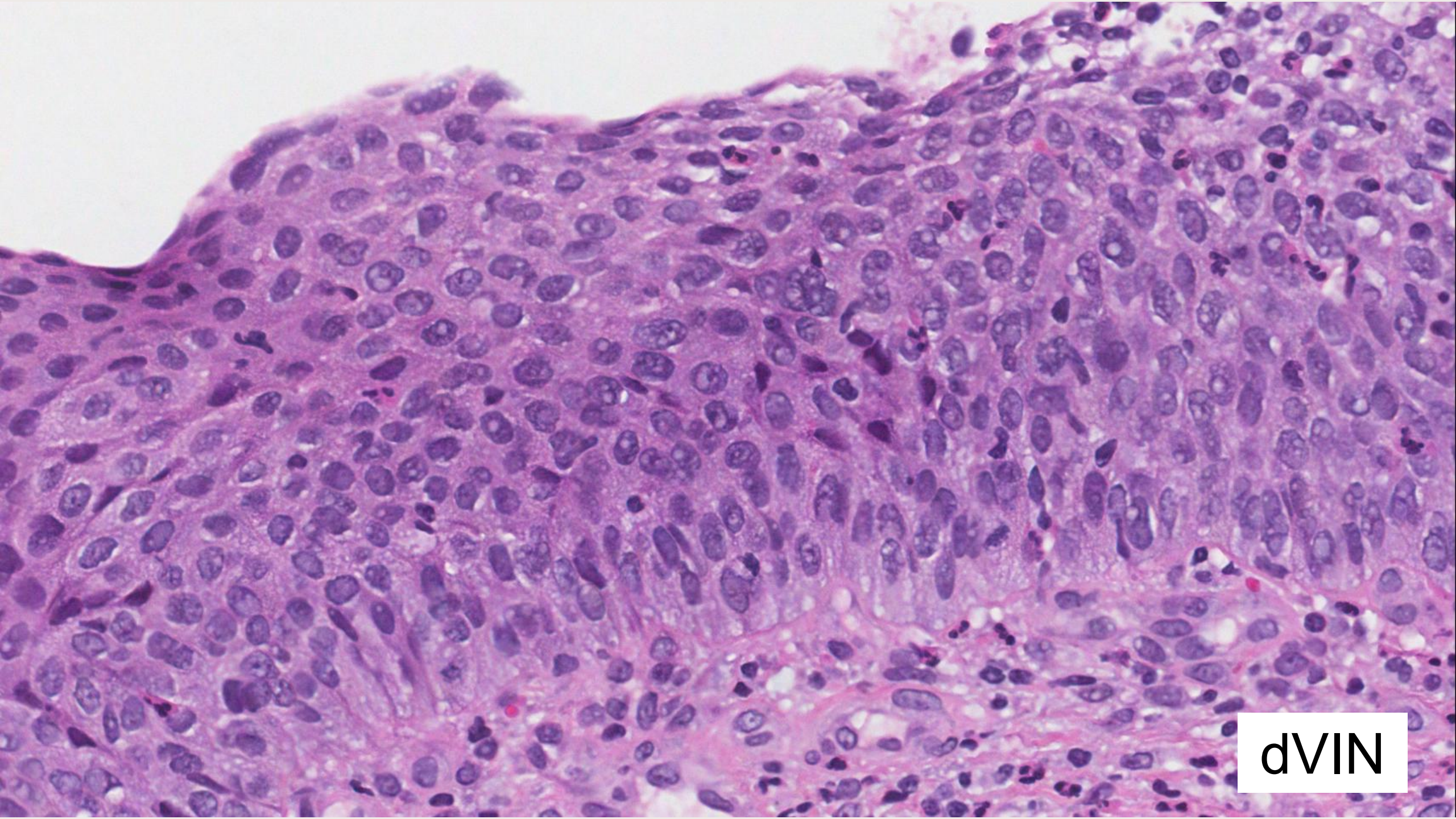
dVIN

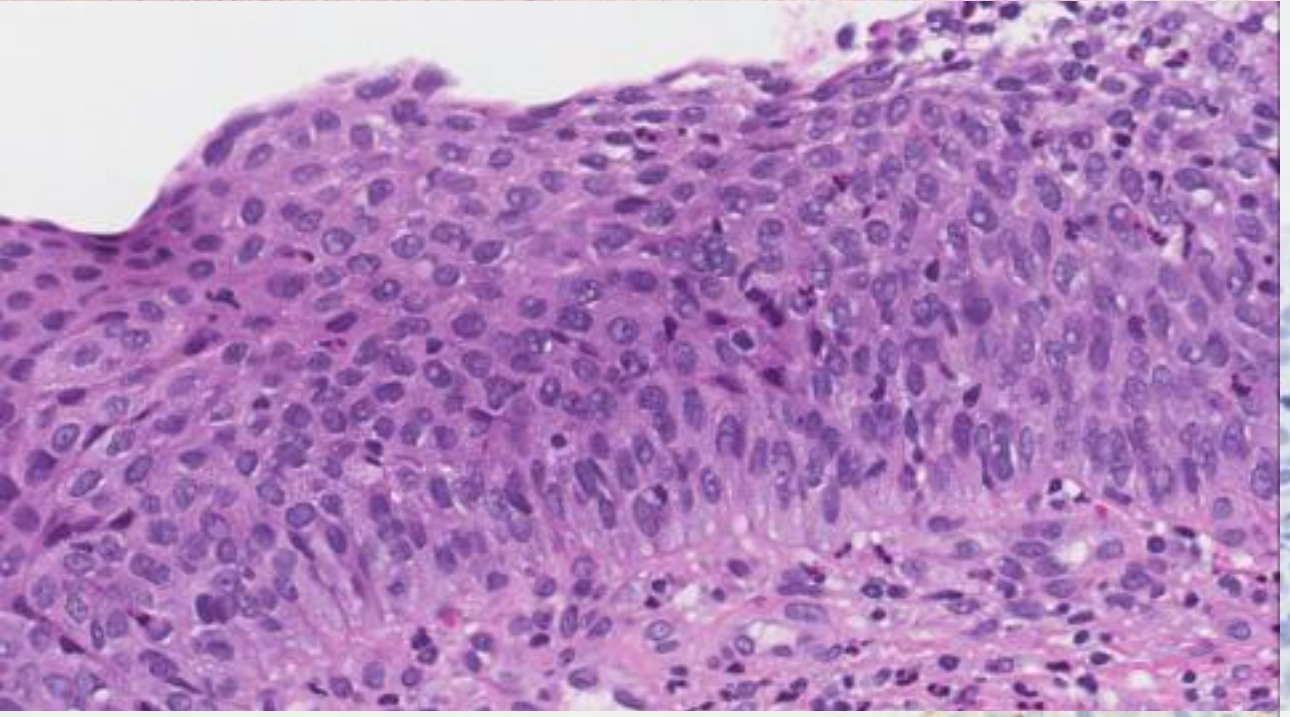

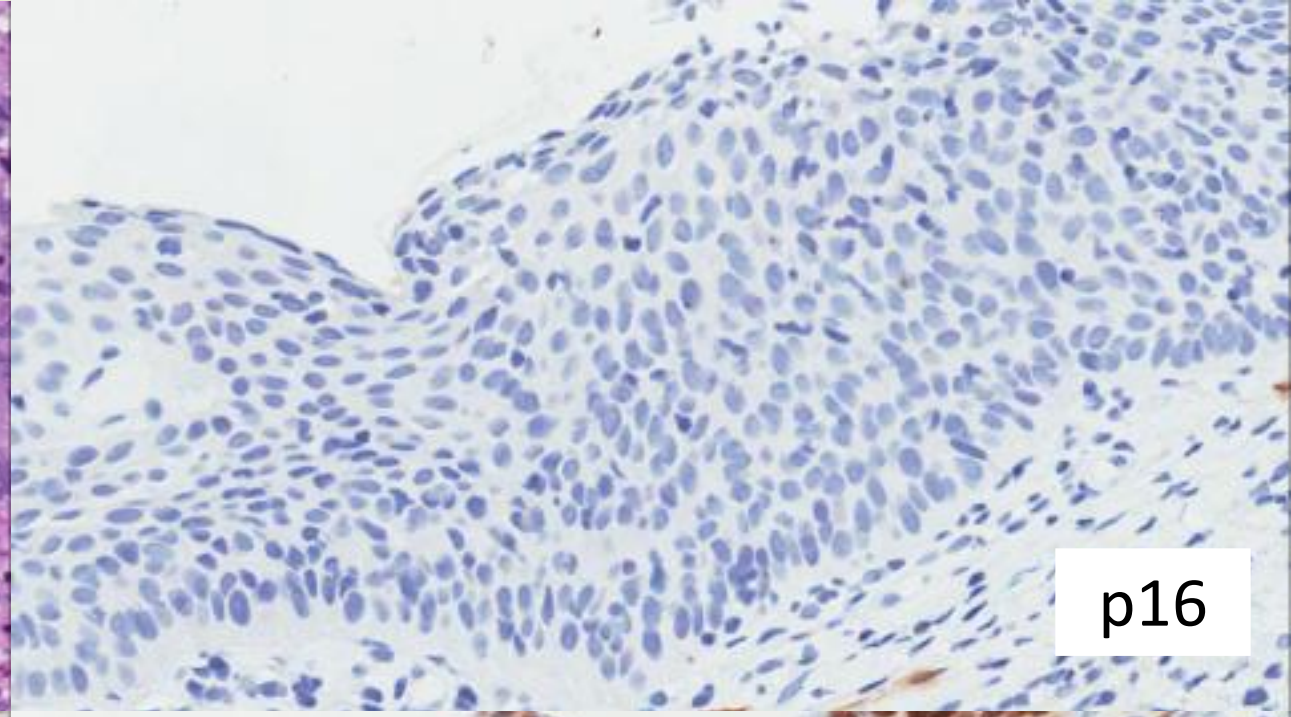
p16

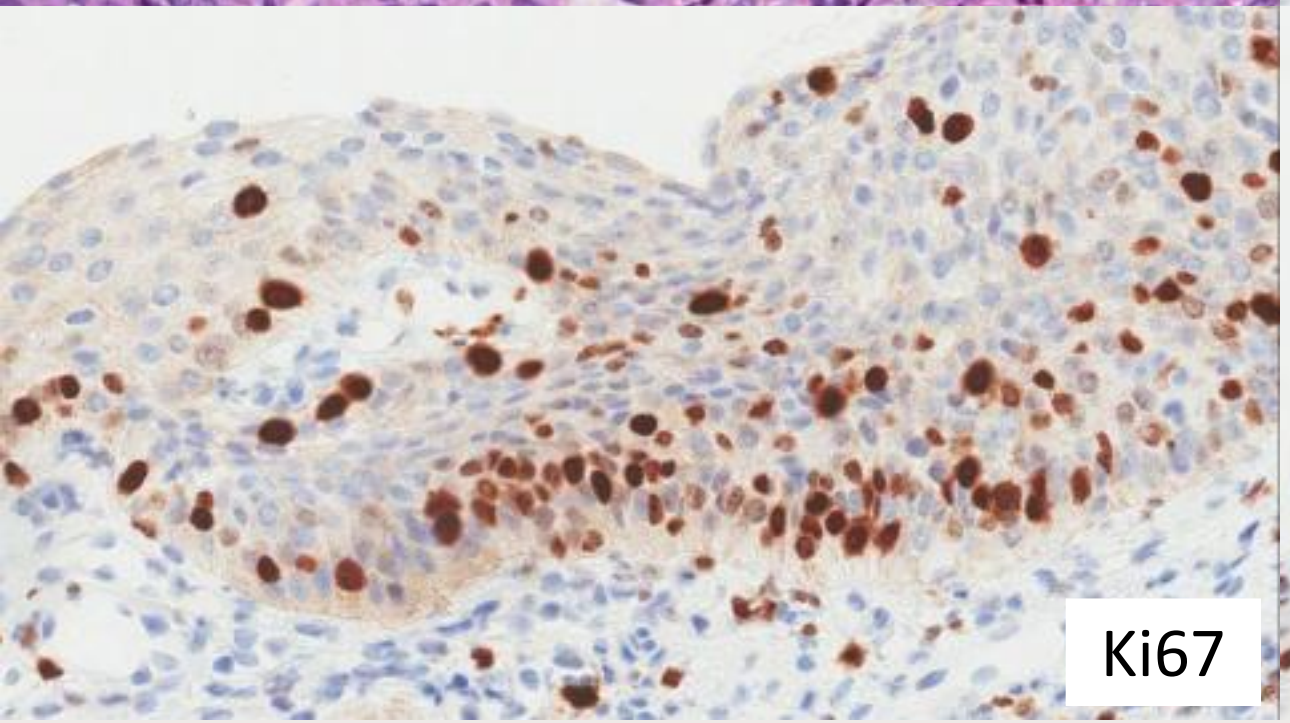
Ki67

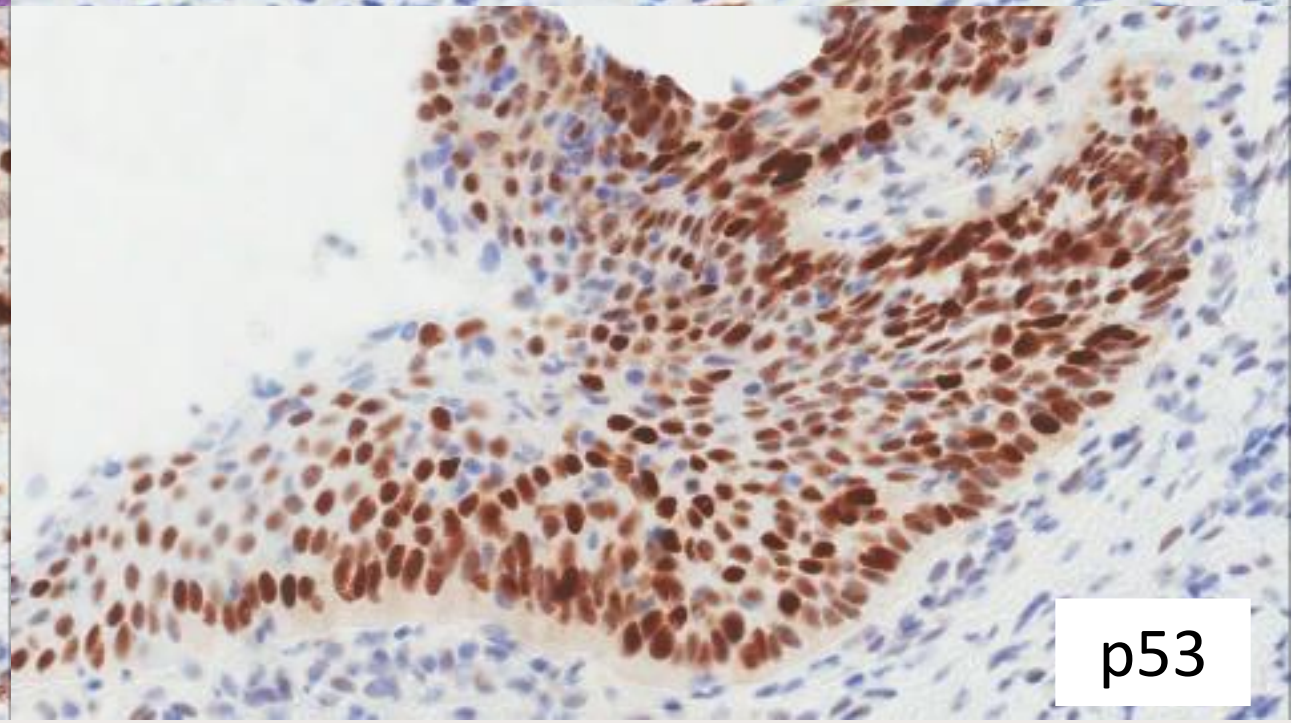
p53

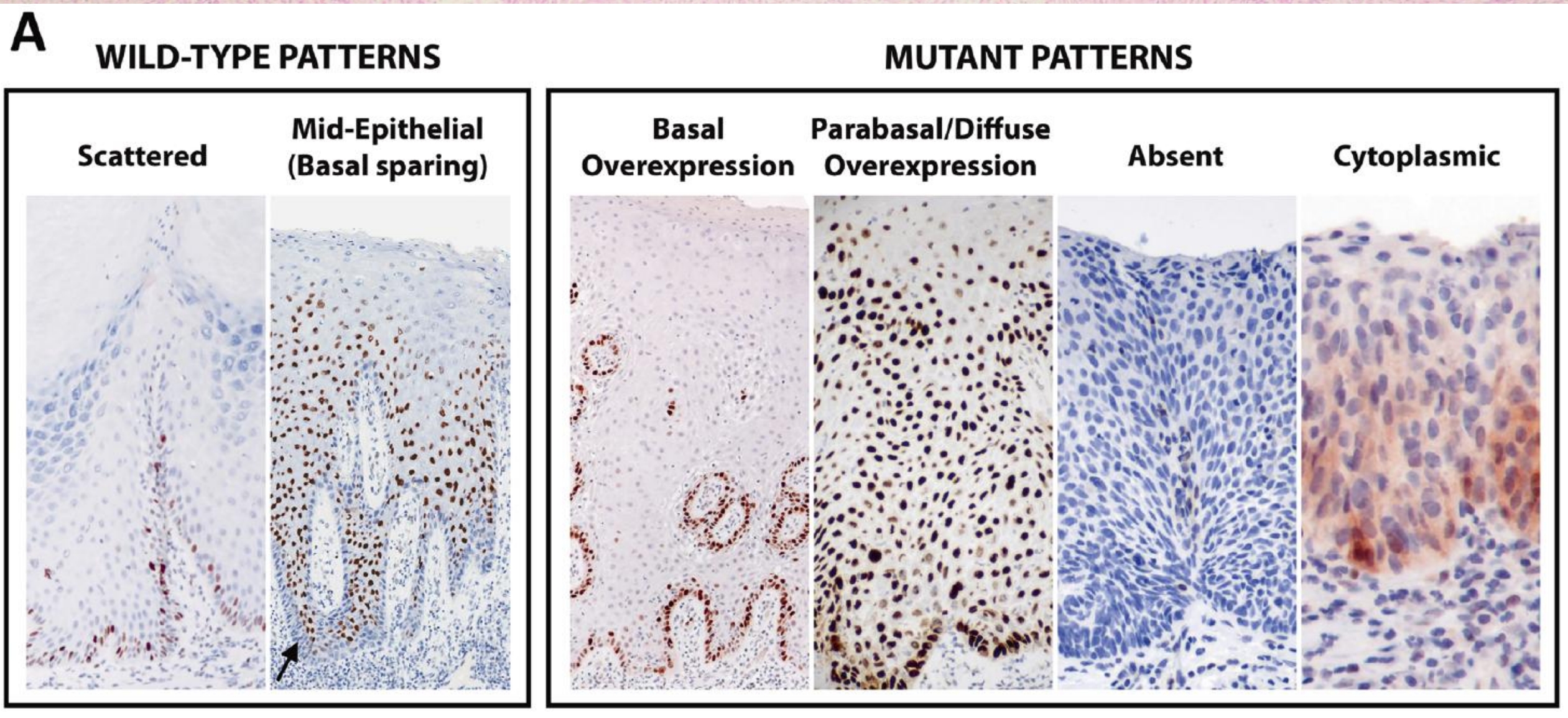

Mod Pathol 2020 PMID: 32203095

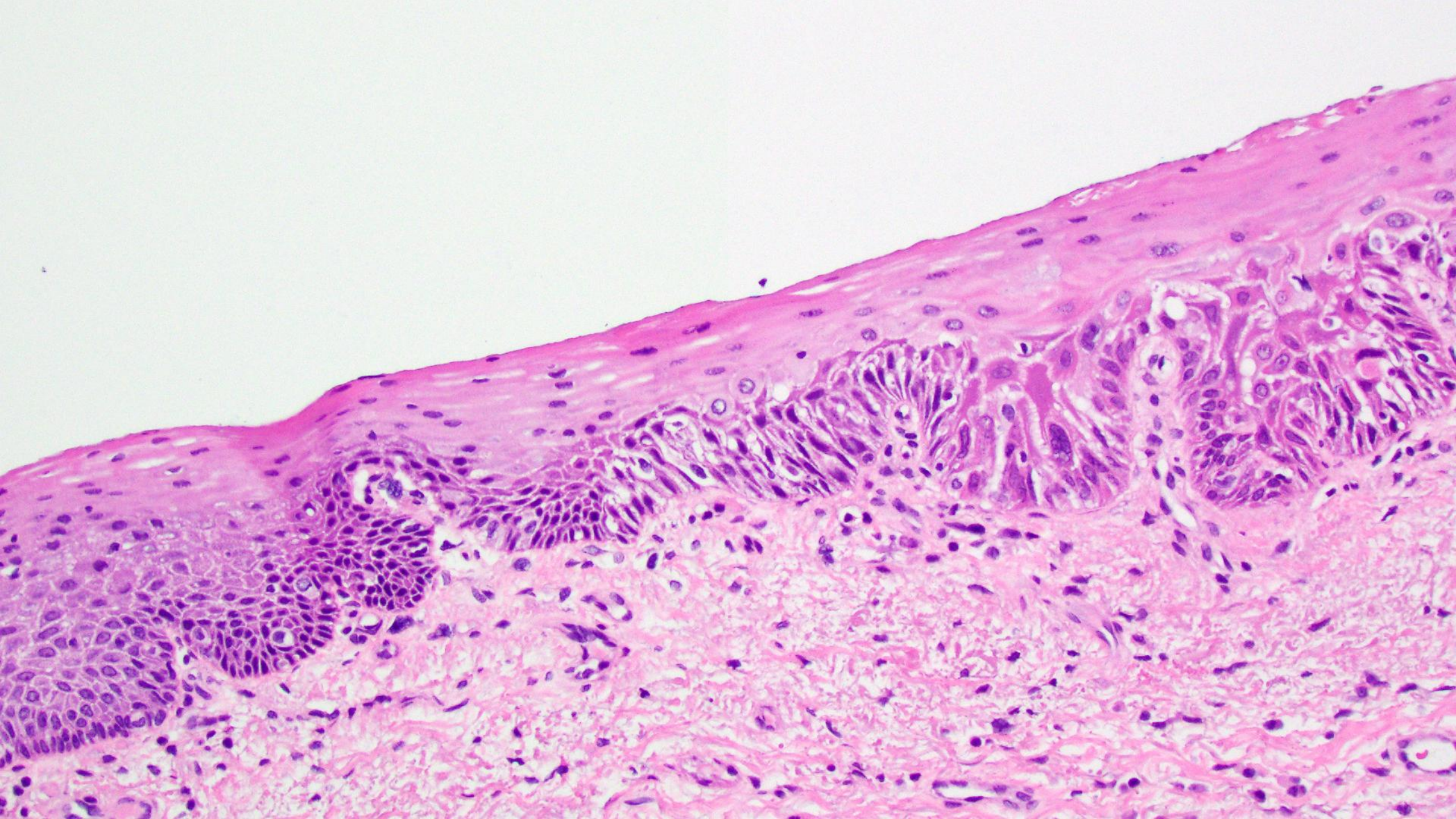

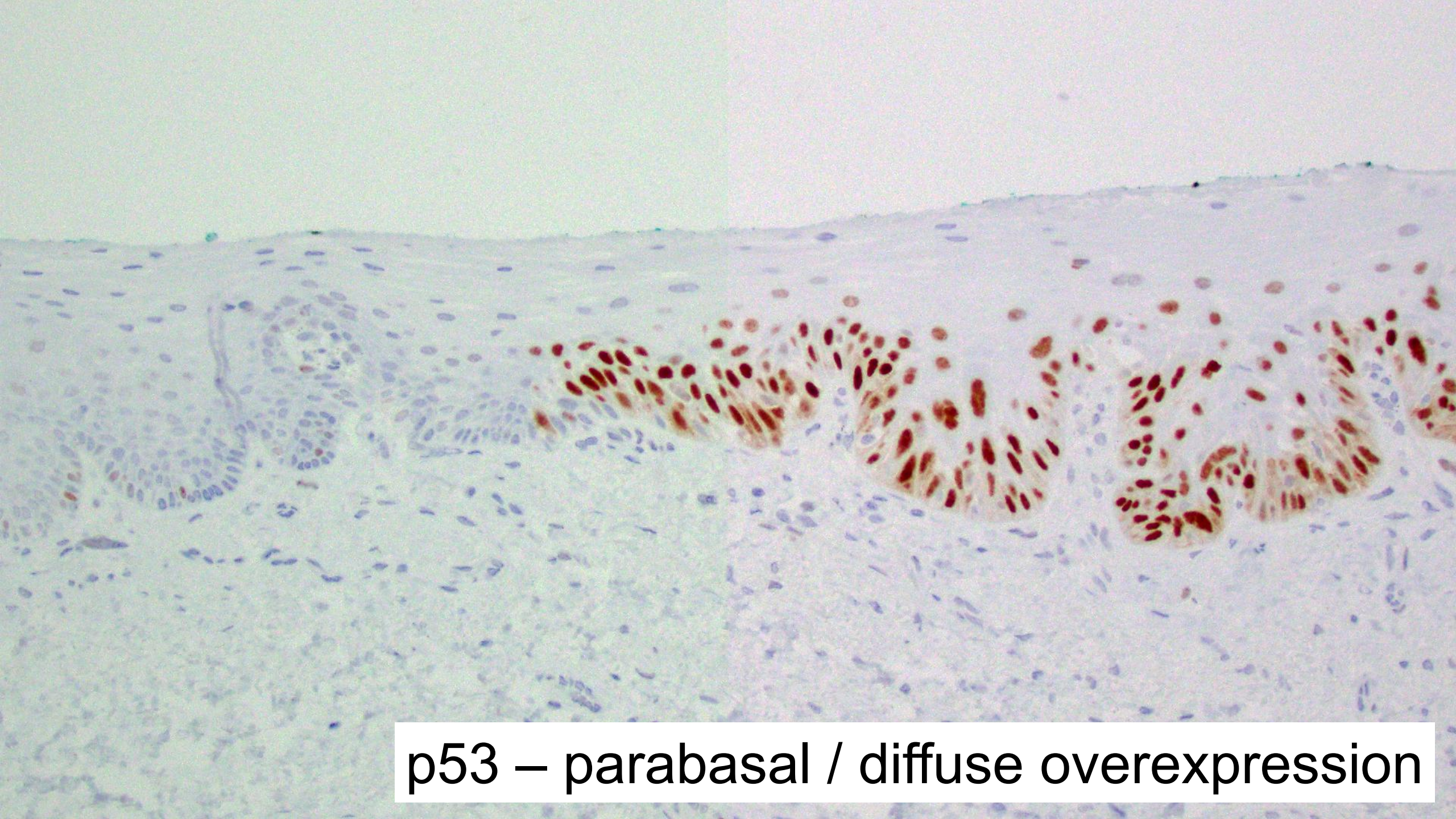
p53 – parabasal / diffuse overexpression

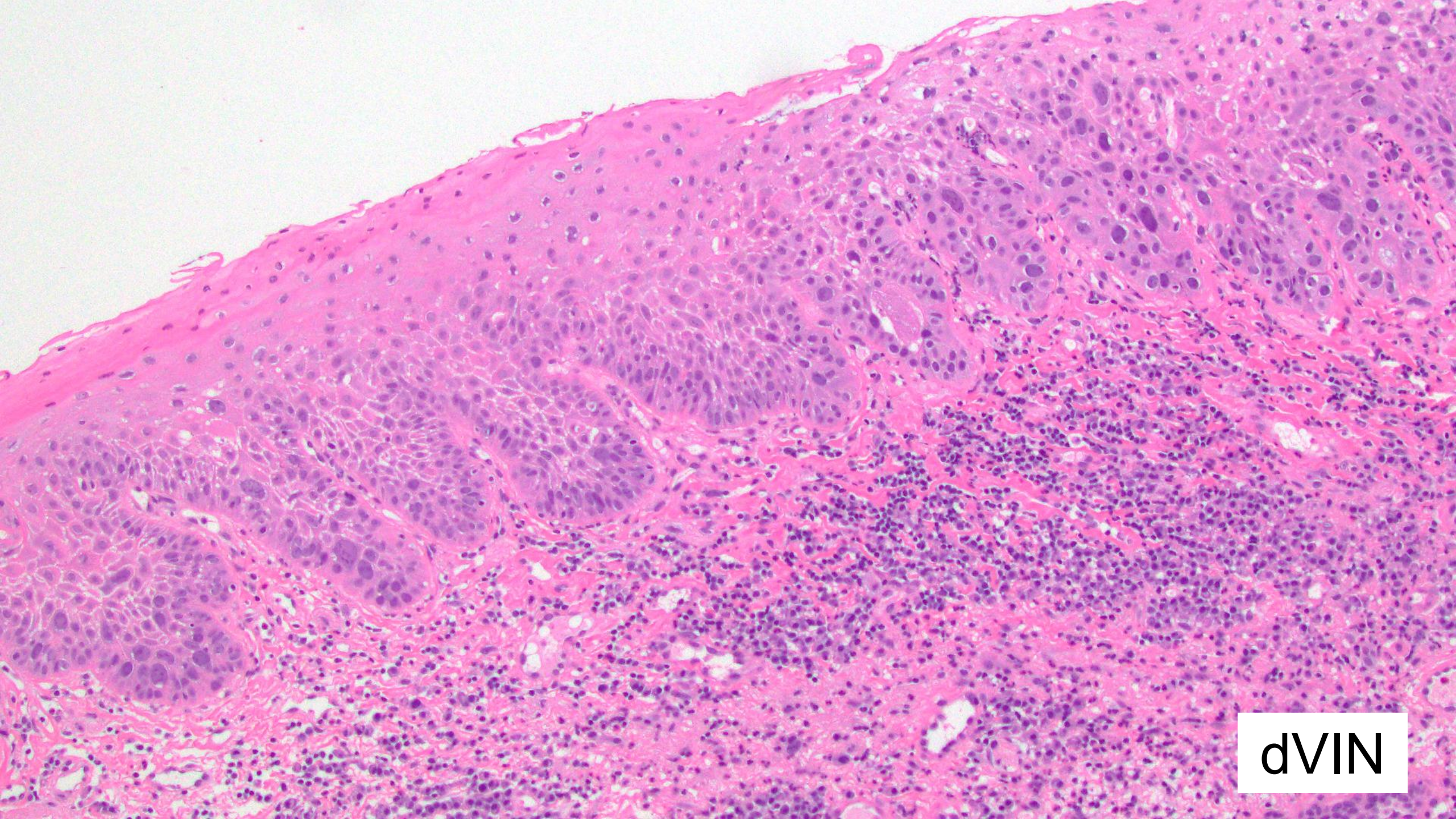
dVIN

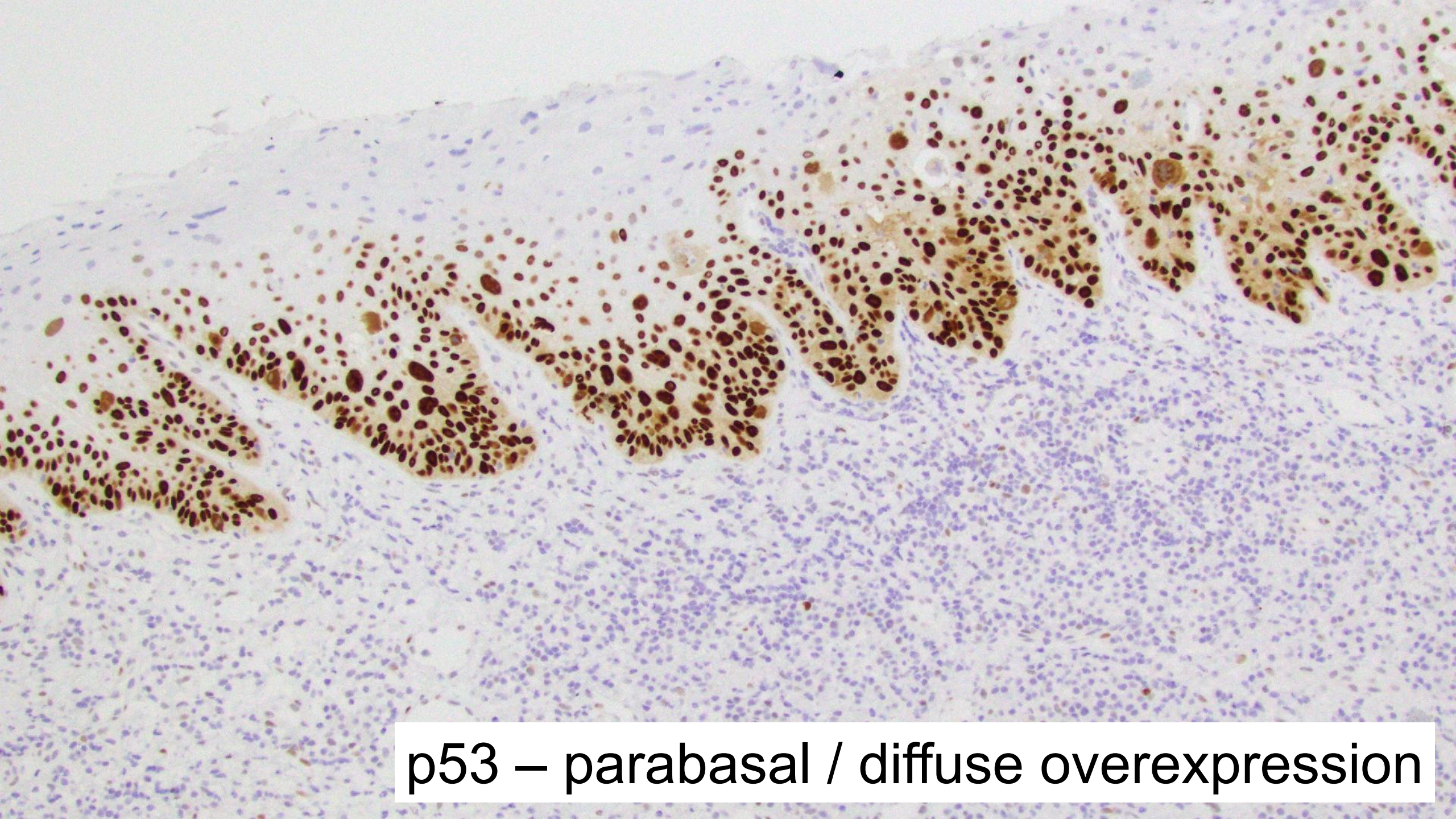
p53 – parabasal / diffuse overexpression

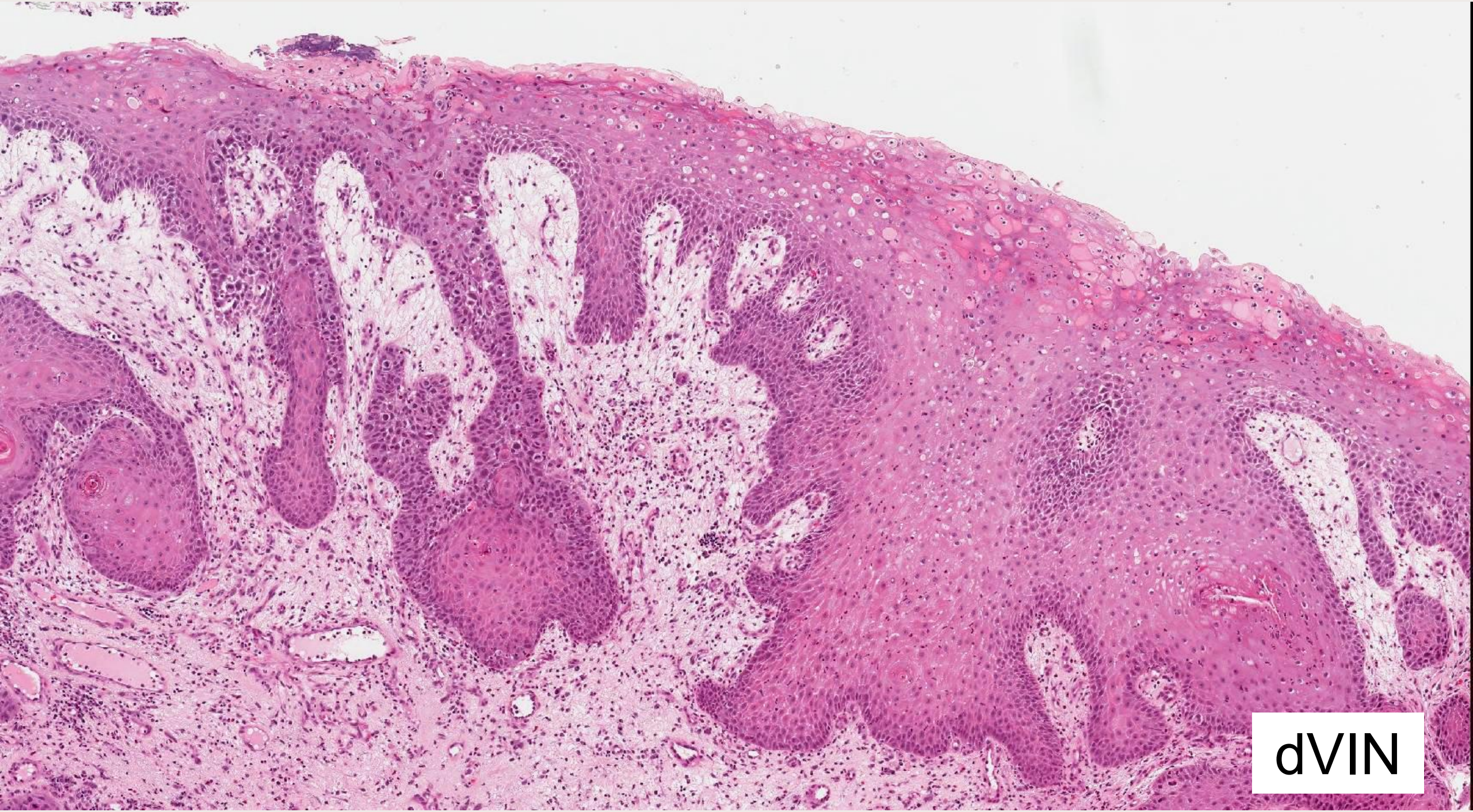
dVIN

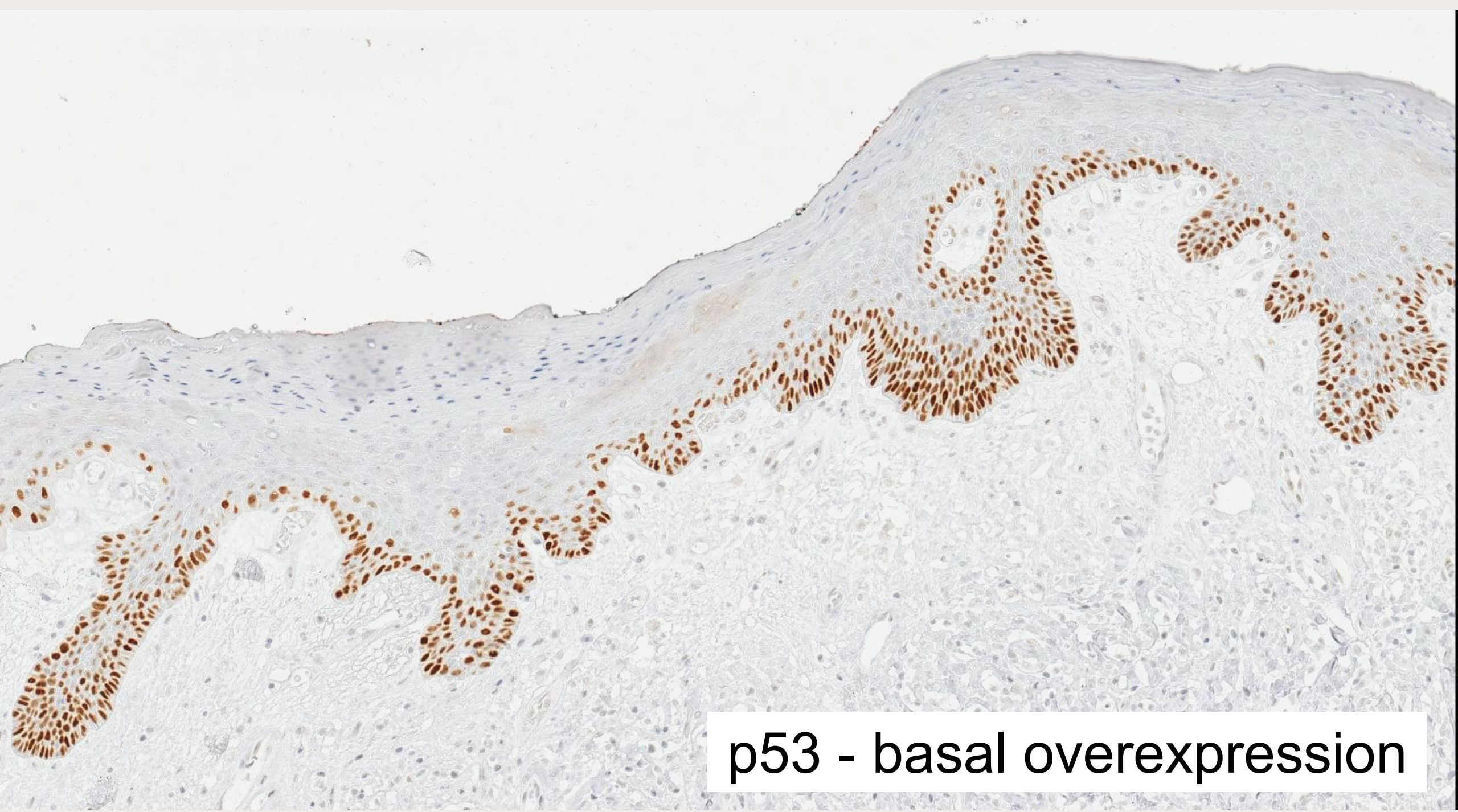
p53 - basal overexpression

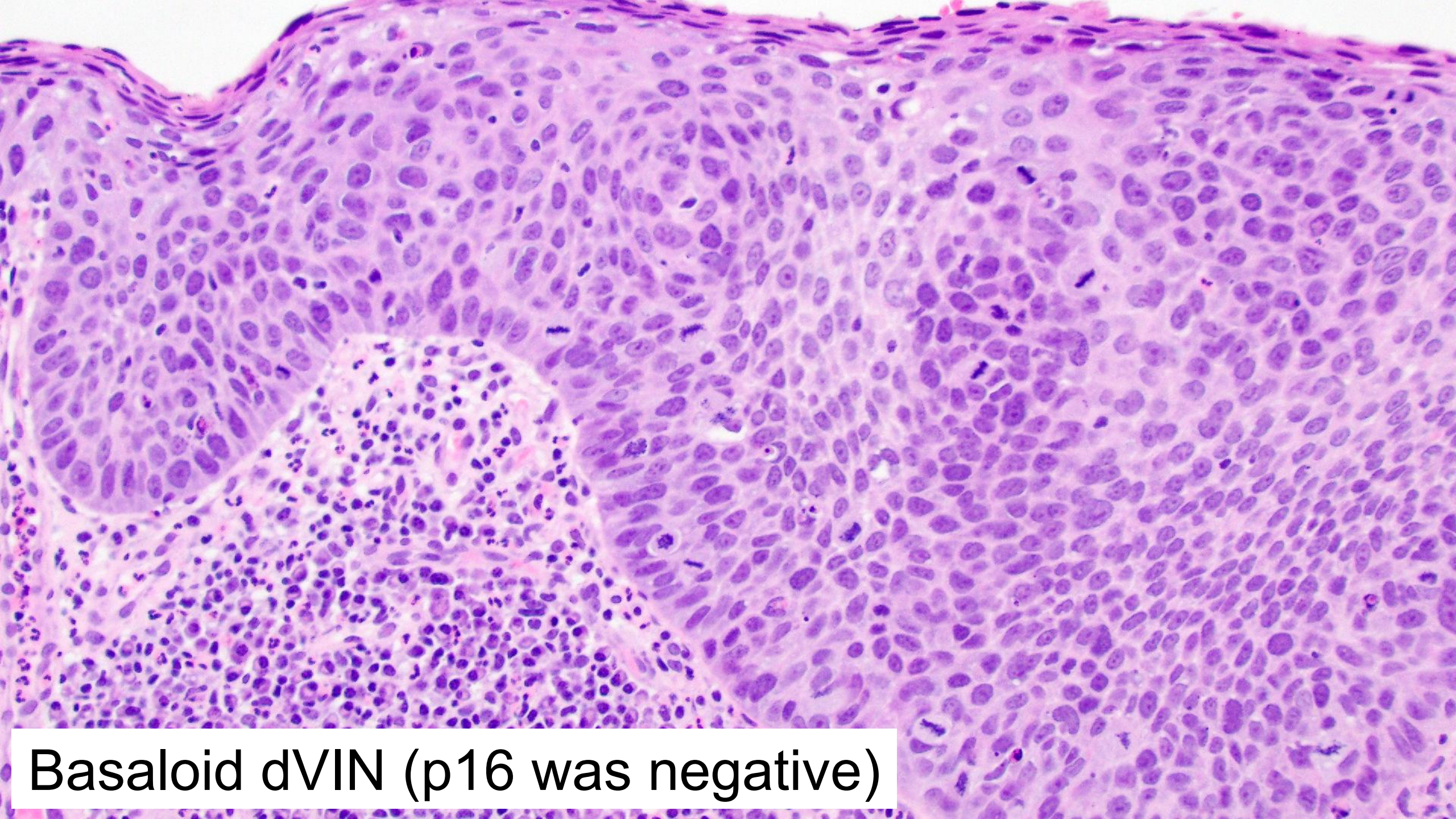
Basaloid dVIN (p16 was negative)

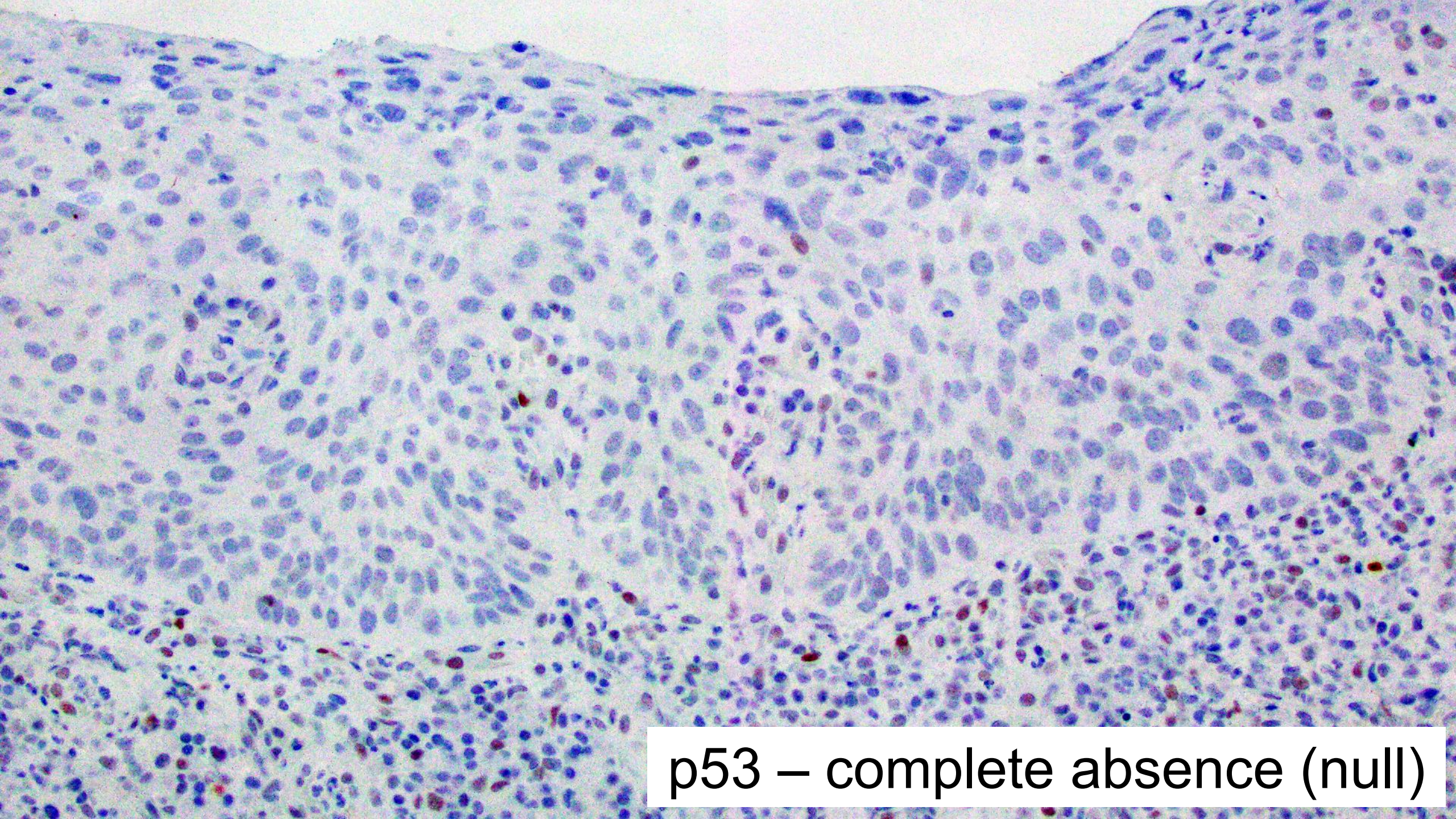
p53 – complete absence (null)

Can VIN with atypia (differentiated or HSIL-like) be p53-wild type?

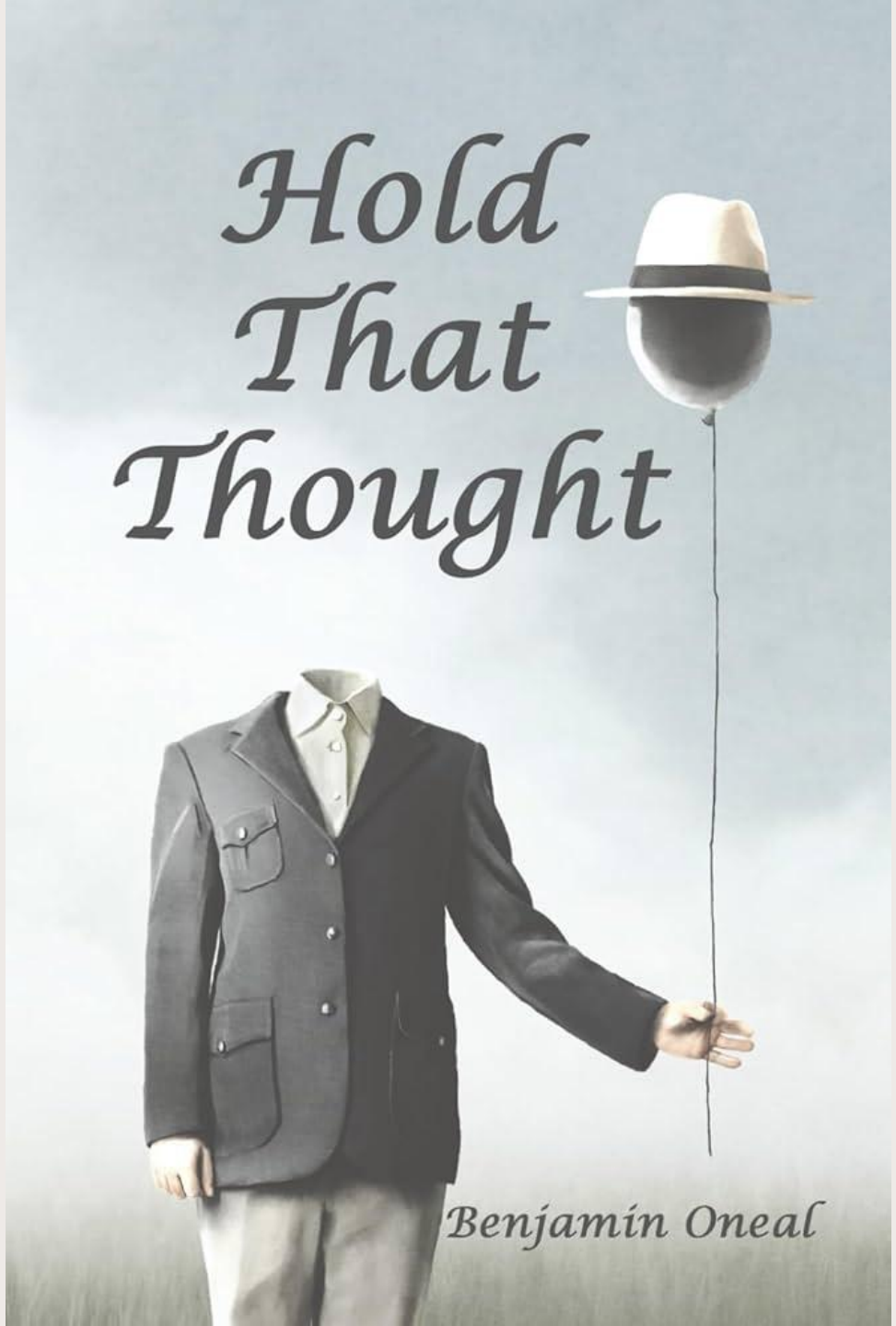

HPV-INDEPENDENT p53 WT VIN

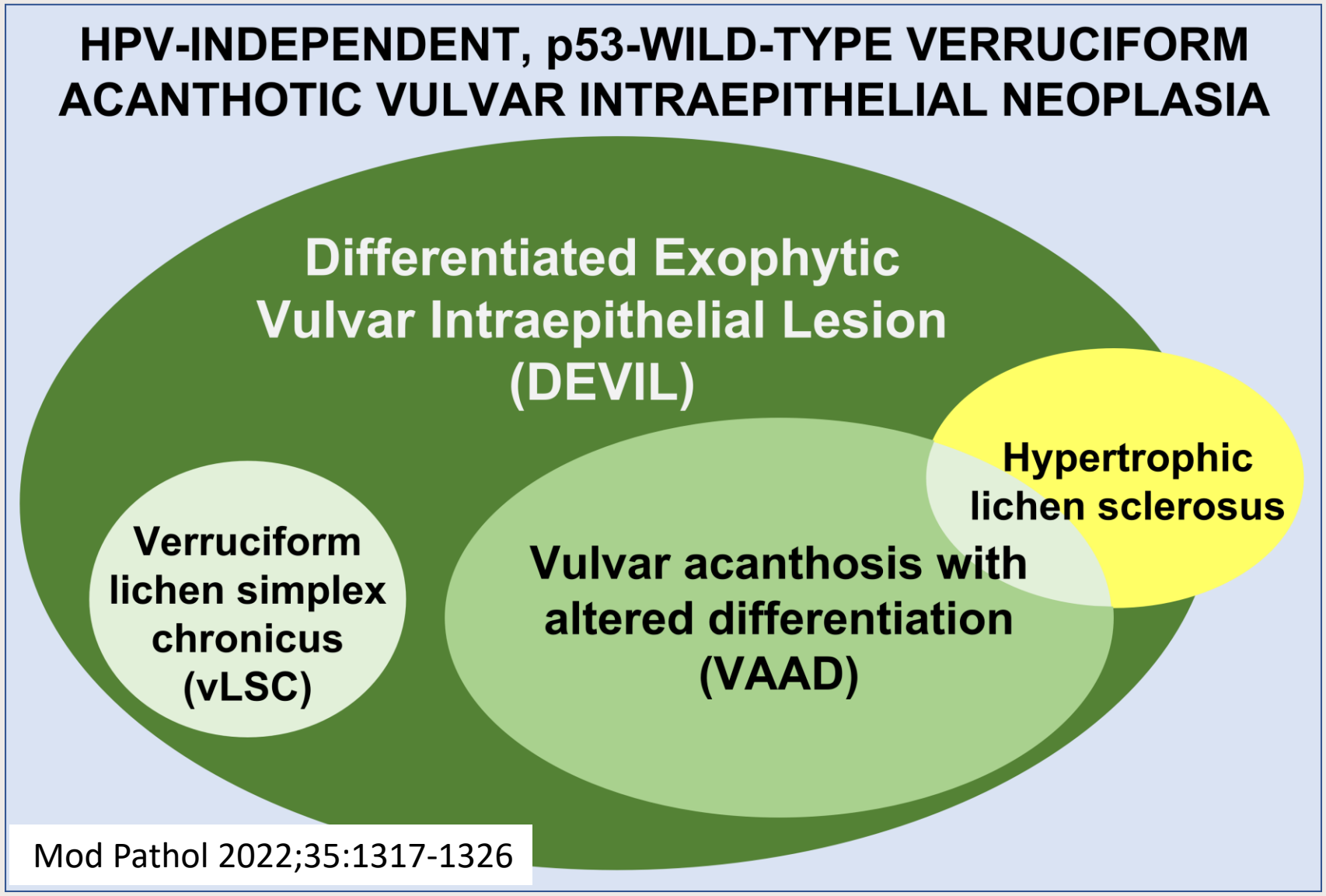

Mod Pathol 2022;35:1317-1326

- Association with HPVI SCC
  - Verrucous
  - Conventional
- Negative p16 staining and HPV testing
- Wild-type p53 expression
- Absence of cytologic atypia

Am J Surg Pathol 2004;28:638-643
Mod Pathol 2017;30:448-458
Mod Pathol 2020;33(S2):1004-1005

Histopathology 2021, 79, 975–988. DOI: 10.1111/his.14451

DEVIL, VAAD and vLSC constitute a spectrum of HPV-independent, p53-independent intra-epithelial neoplasia of the vulva

Simon F Roy,[1,2] Jahg Wong,[1,2] Cécile Le Page,[1] Danh Tran-Thanh,[1] Maroie Barkati,[3] Annick Pina,[4] Vincent Quoc-Huy Trinh[5] & Kurosh Rahimi[1,2]

Table 3. Outcomes of patients with verruciform precursor lesions without invasive carcinoma at initial diagnosis.

	VAAD (n = 11)	DEVIL (n = 5)	Verruciform lichen simplex chronicus (n = 11)	Total (n = 27)	P-value
Median follow-up (months, IQR)	30.2 (14.6–79.4)	28.1 (11.9–41.7)	41.1 (10–82.7)	33 (14.6–61.6)	0.804
Recurrence of verruciform lesion	7 (64%)	3 (60%)	2 (18%)	12 (44%)	0.074
Median recurrence of verruciform lesion time (months, 95% CI)*	9.6 (0–42.1)	7.5 (6.2–8.8)	67.1 (48.2–86.0)**	36.0 (24.2–47.8)	0.082***
Progression to SCC	5 (46%)	2 (40%)	3 (27%)	10 (37%)	0.669
Median progression to squamous cell carcinoma time (months, 95% CI)	63.7 (1.5–125.8)	42.5 (17.7–53.0)	56.9 (34.3–79.5)**	42.5 (18.6–66.3)	0.782***

* IQR not calculable, 95% confidence interval shown instead.

** Media not calculable, mean shown instead.

*** Log-Rank P-value.

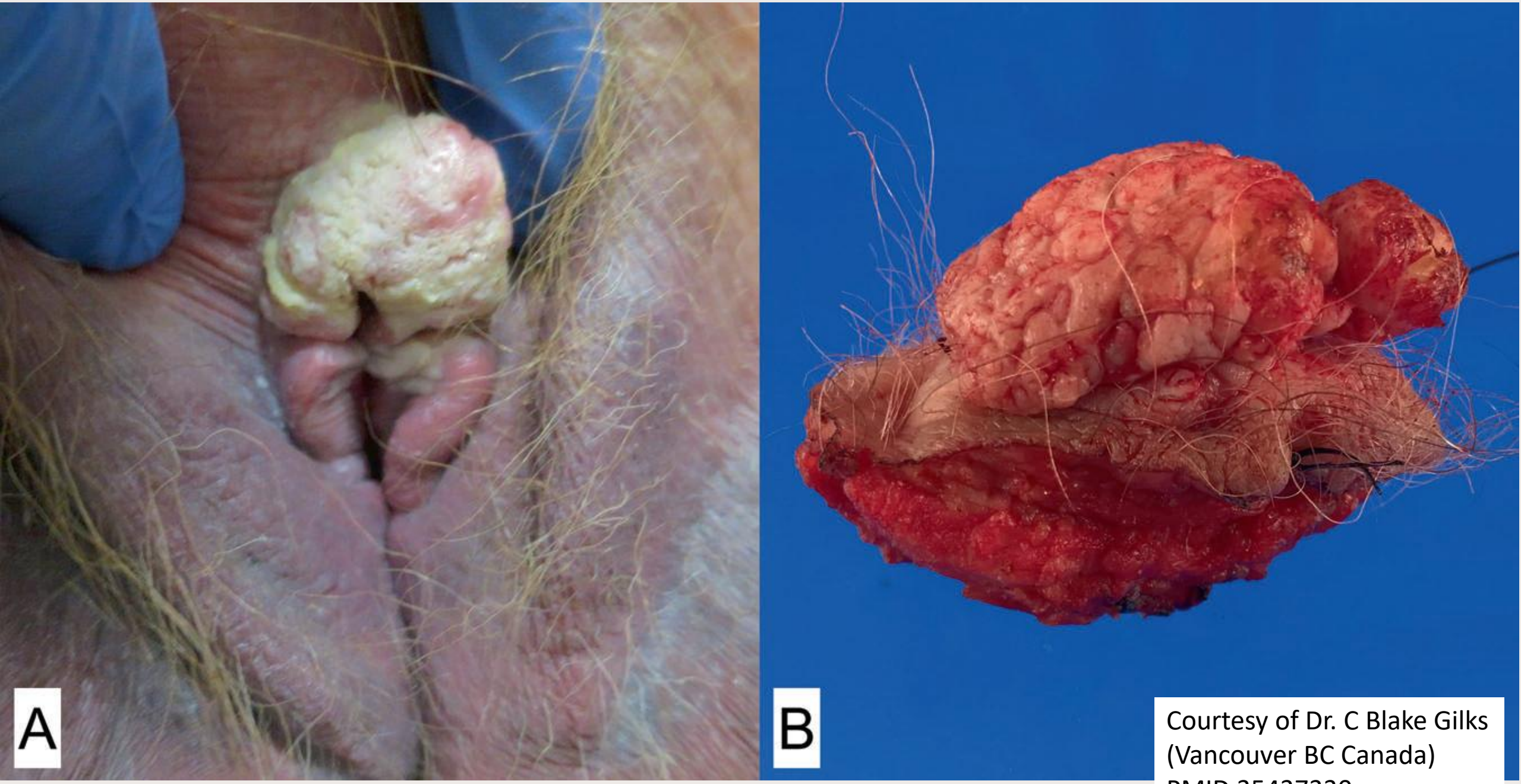

Courtesy of Dr. C Blake Gilks
(Vancouver BC Canada)
PMID 35437330

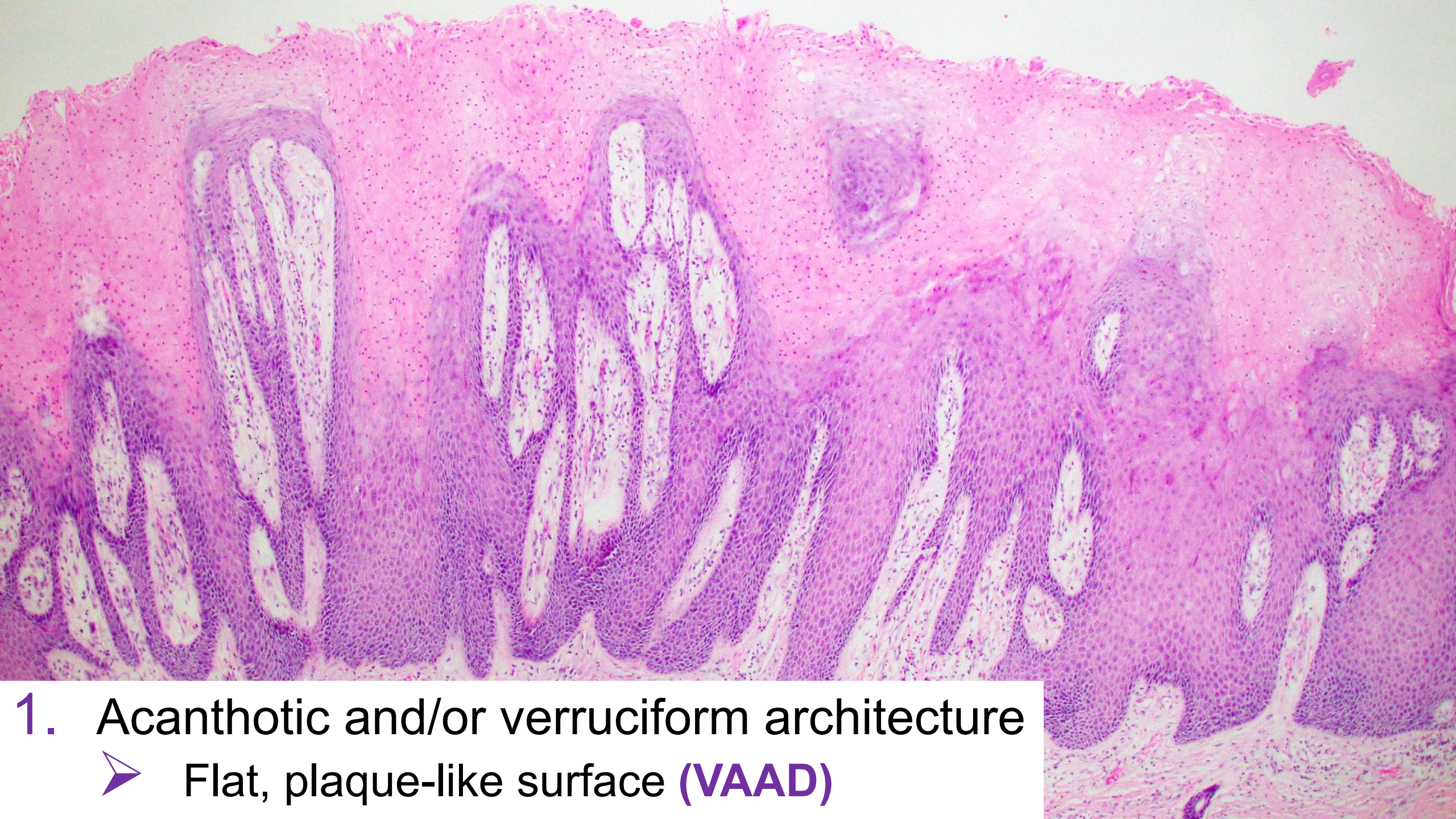

1. Acanthotic and/or verruciform architecture
   - Flat, plaque-like surface **(VAAD)**

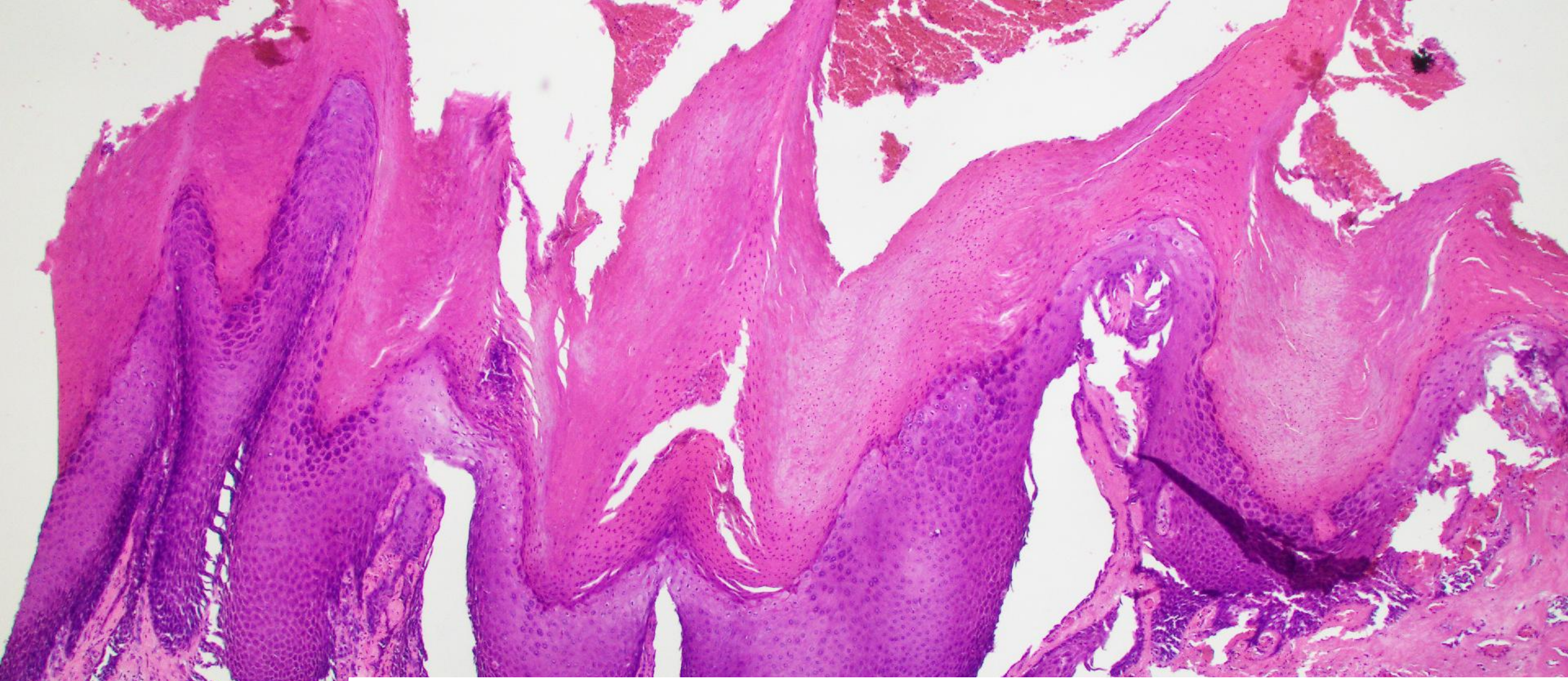

1. Acanthotic and/or verruciform architecture
   - Exophytic **(DEVIL)** = projections with squared, bulbous, or pointed “church spire” shapes

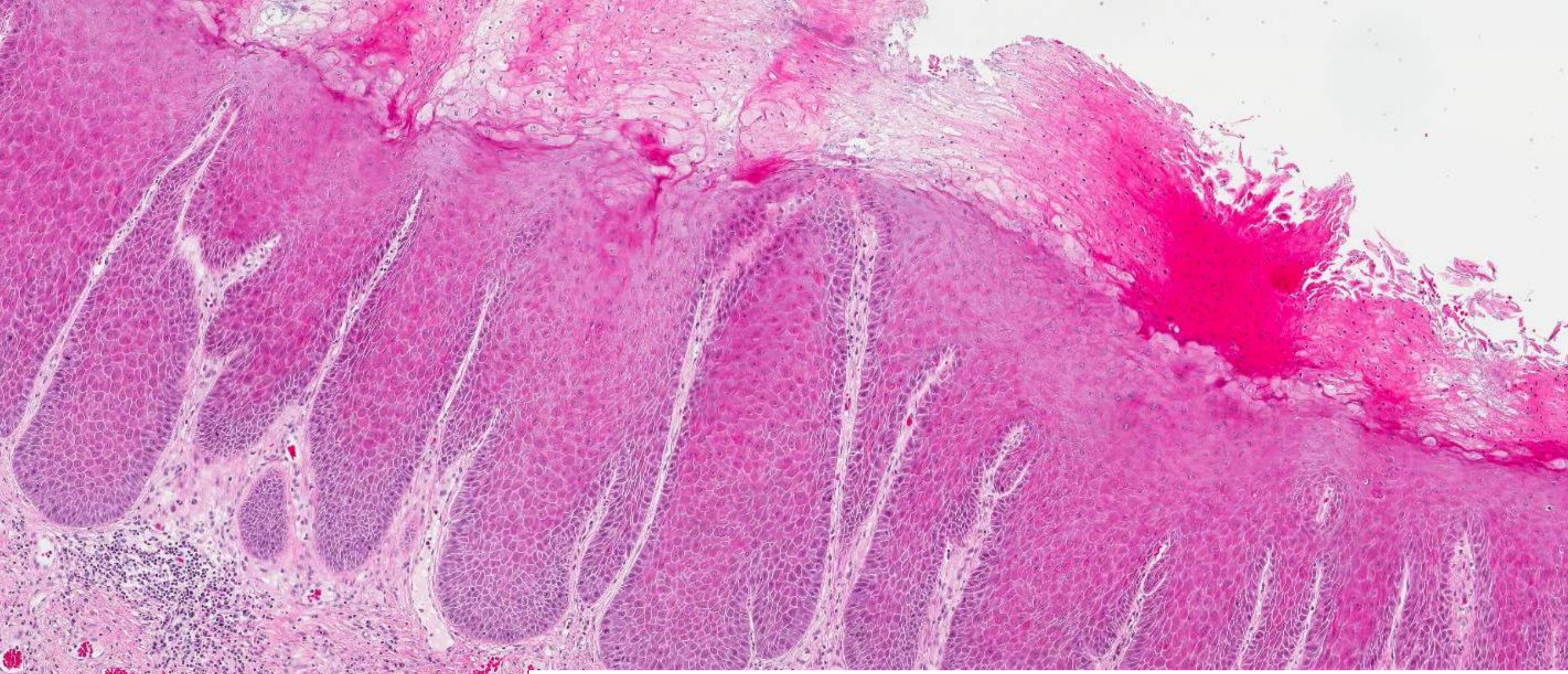

2. Altered squamous differentiation
   - Partial or complete hypogranulosis **(VAAD)**
   - Cytoplasmic pallor

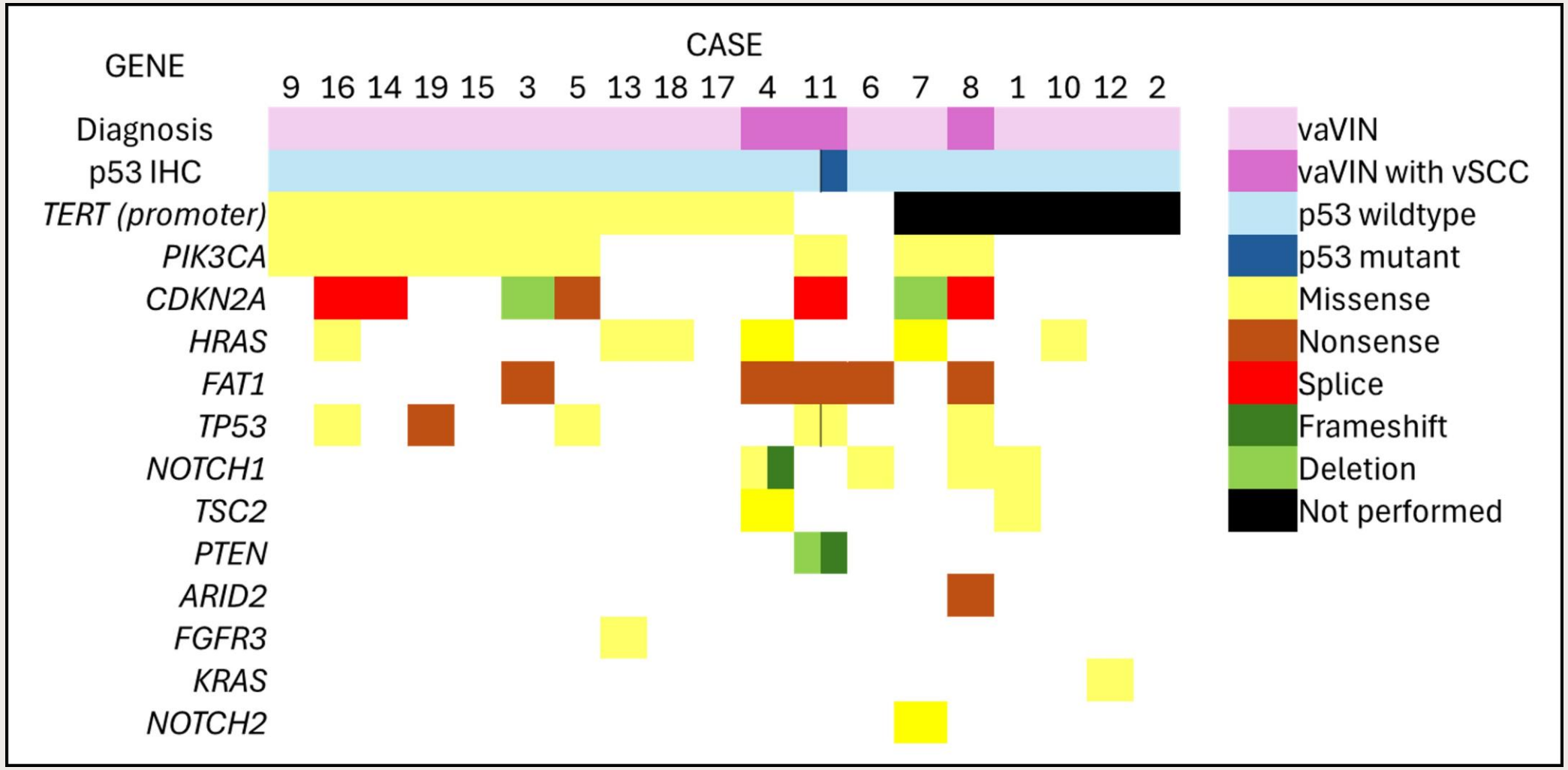

Int J Gynecol Pathol 2025 PMID 39868730

vaVIN = DIFFERENTIAL DIAGNOSIS

NEOPLASTIC

- VIN, HPV-associated (HSIL)
- VIN, HPV-independent p53 mutant (dVIN)
- Squamous cell carcinoma
  - *Verrucous*
  - *Conventional*

NON-NEOPLASTIC

- Lichen simplex chronicus
- Psoriasis
- Verruciform xanthoma
- Keratoacanthoma
- Pseudoepitheliomatous hyperplasia
  - *Granular cell tumor*
  - *Syphilis*

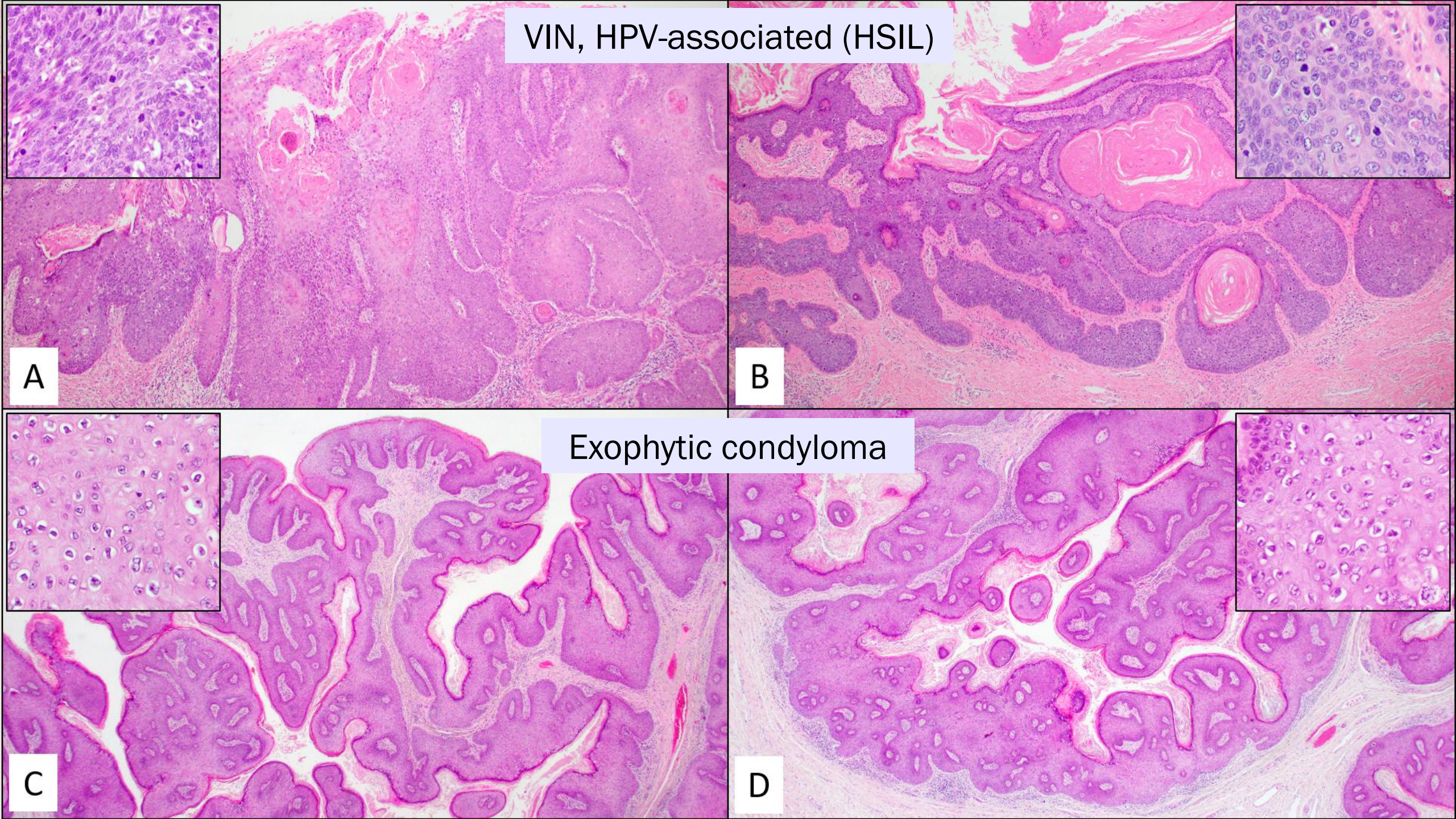
VIN, HPV-associated (HSIL)
A
B
Exophytic condyloma
C
D

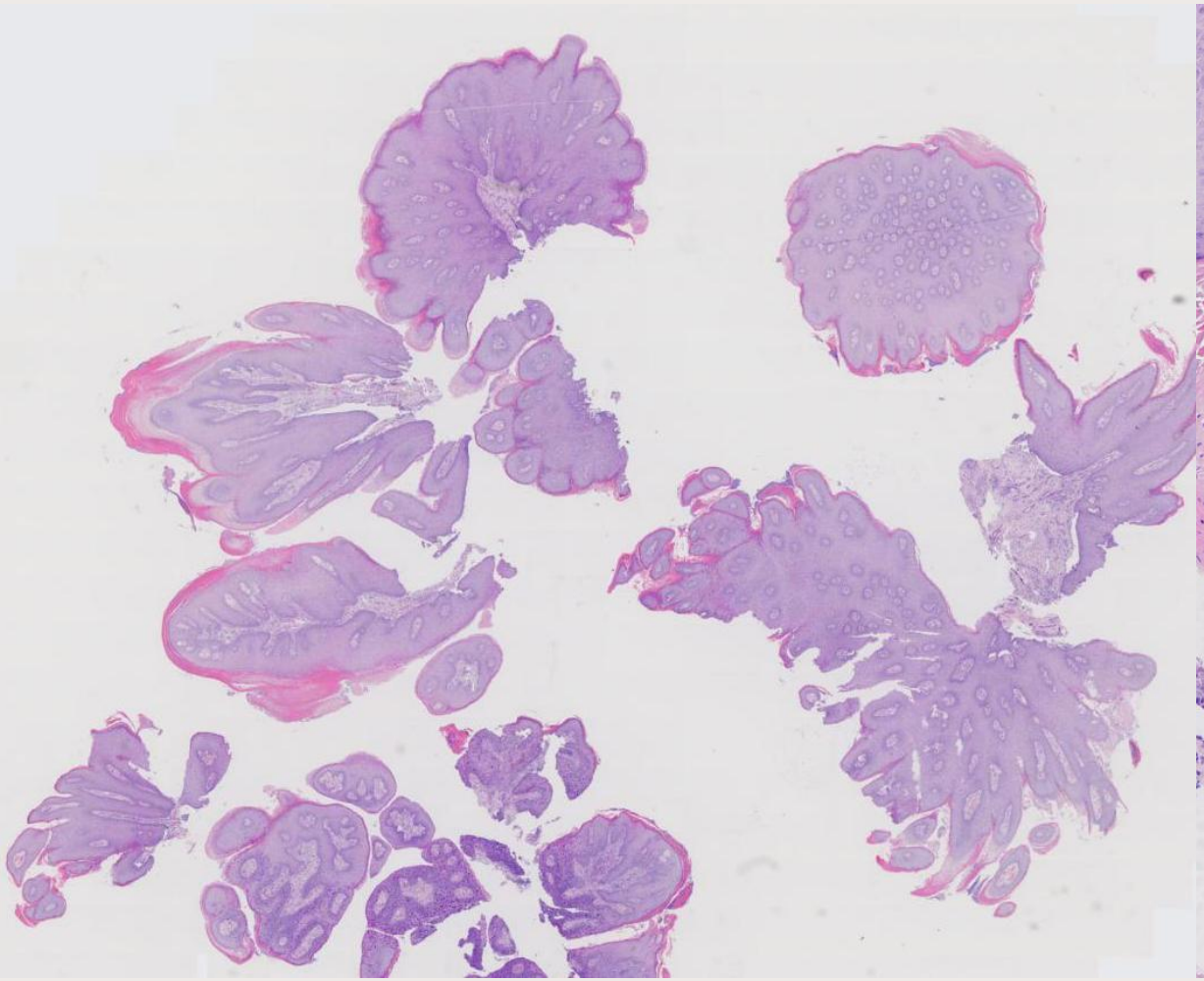

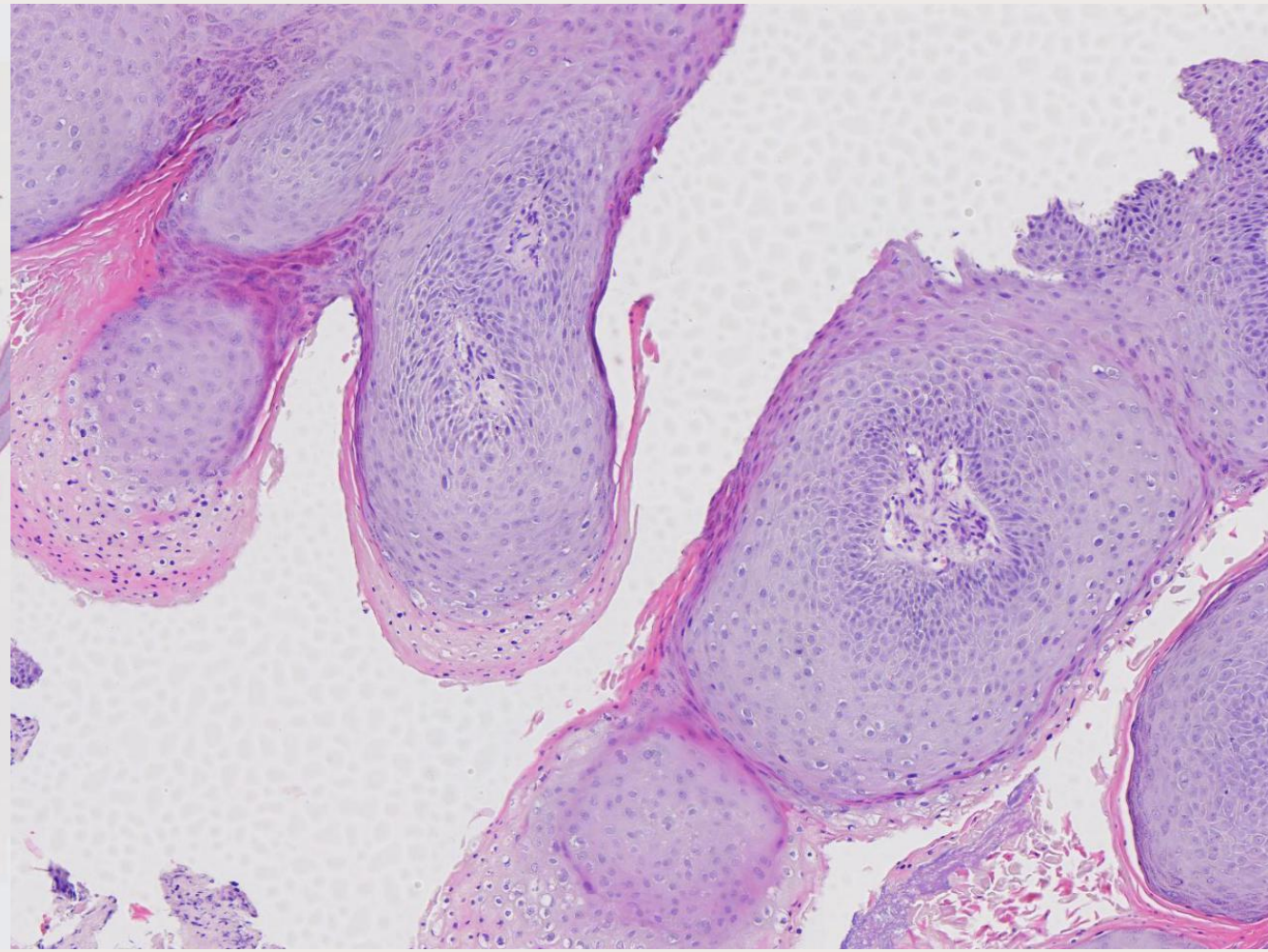

Exophytic condyloma

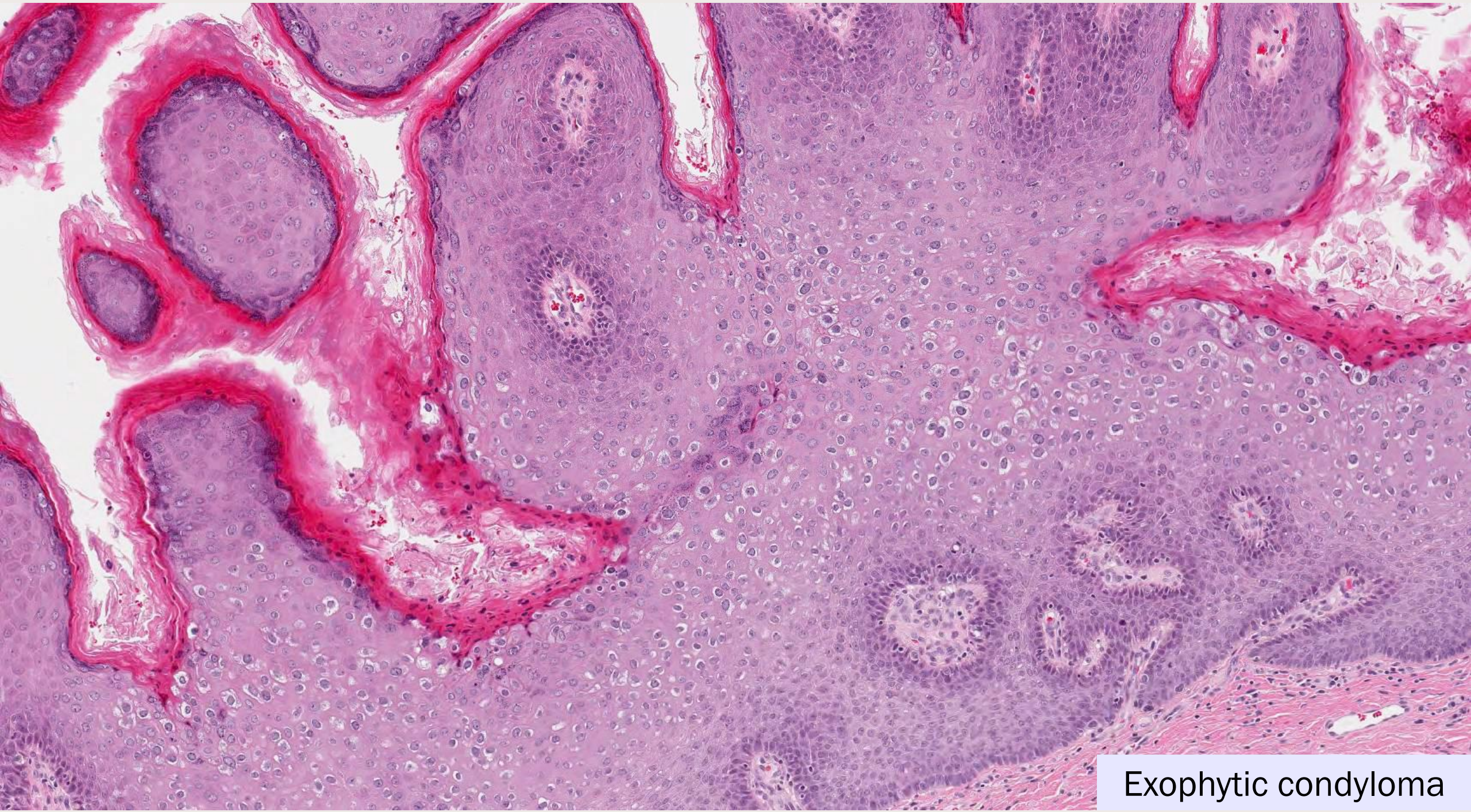

Exophytic condyloma

VERRUCOUS CA

- Postmenopausal
- 7th-8th decade
- Exophytic growth
- Expansile blunt interface
- No metastatic potential

…. Like vaVIN

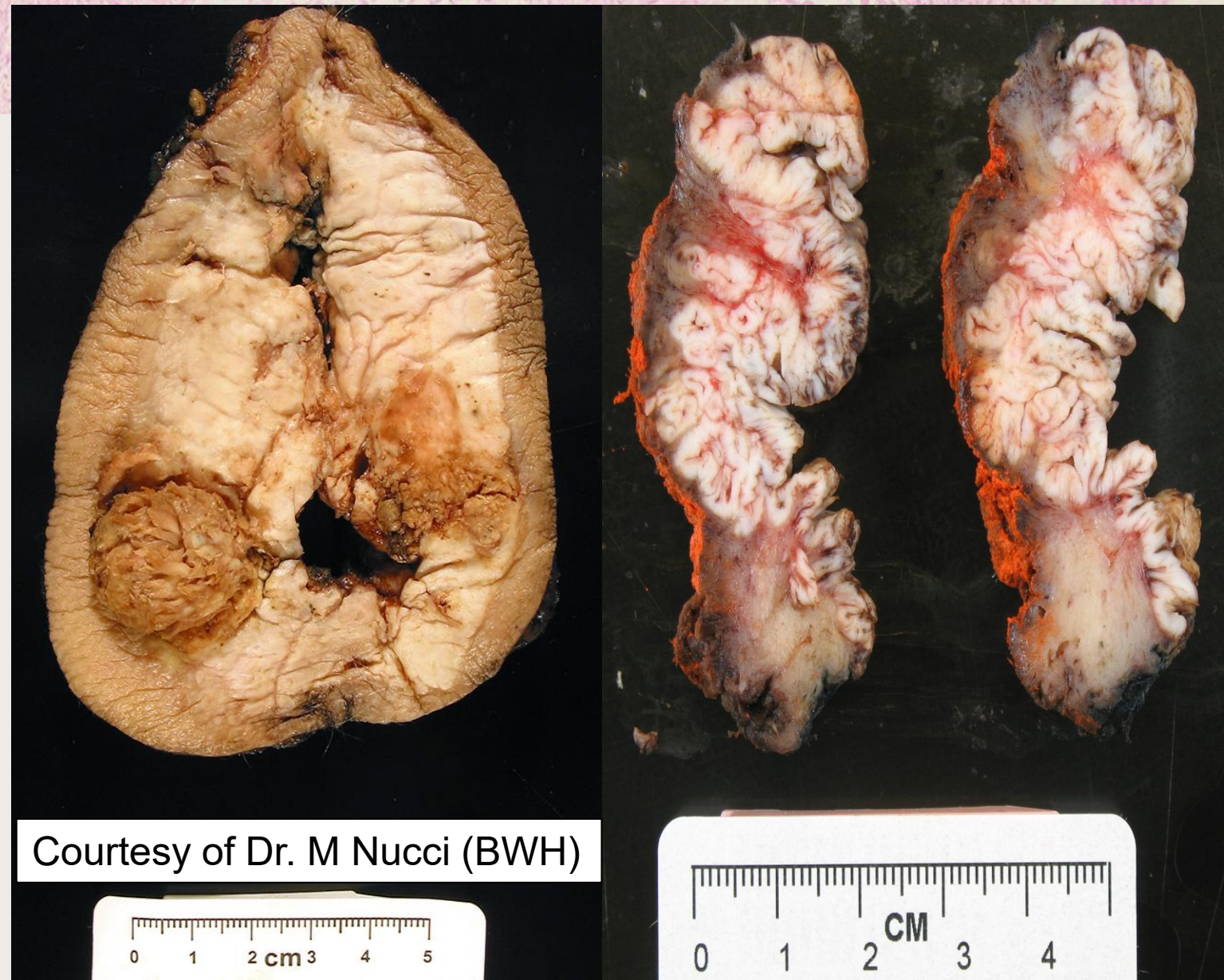

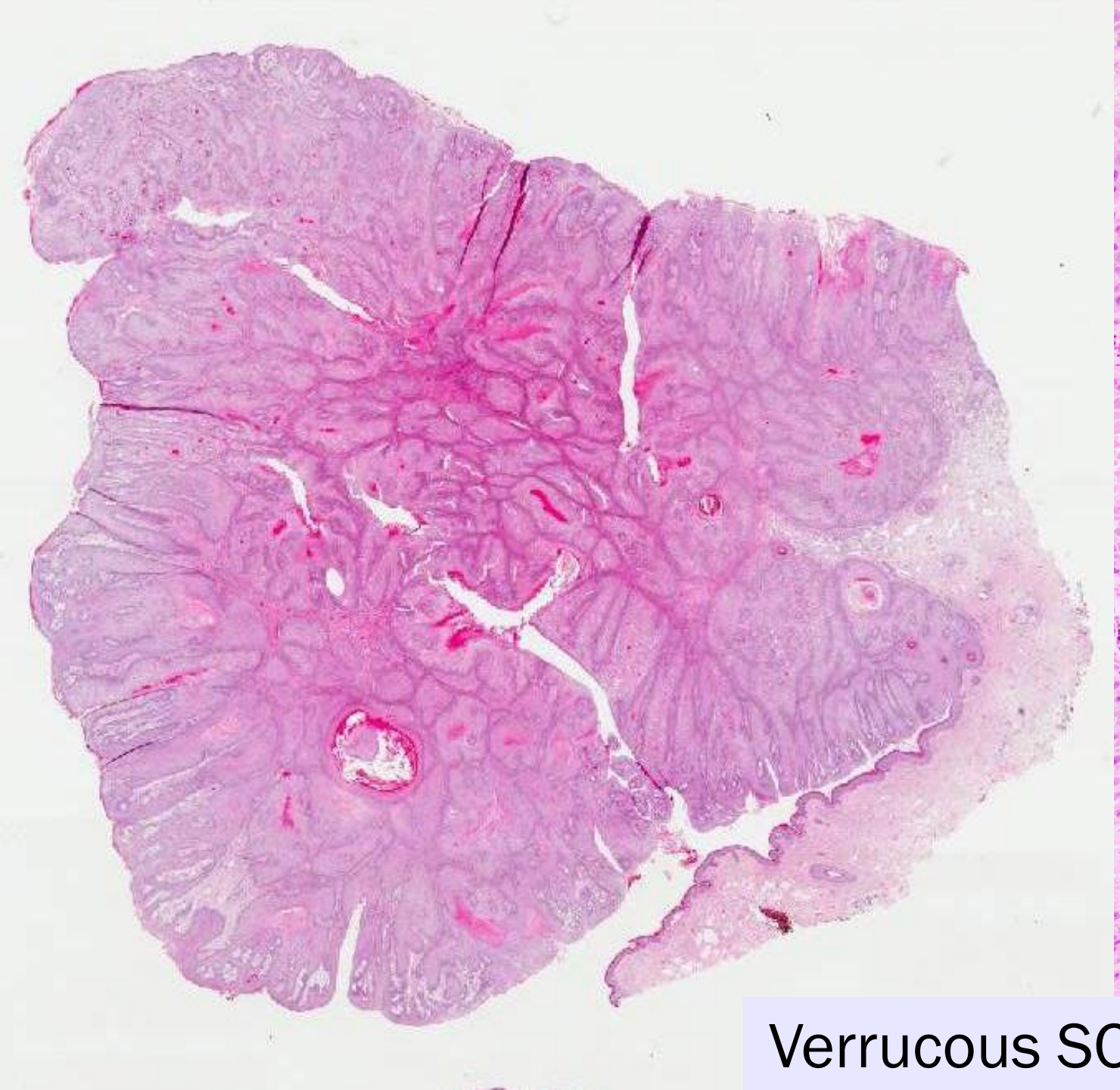

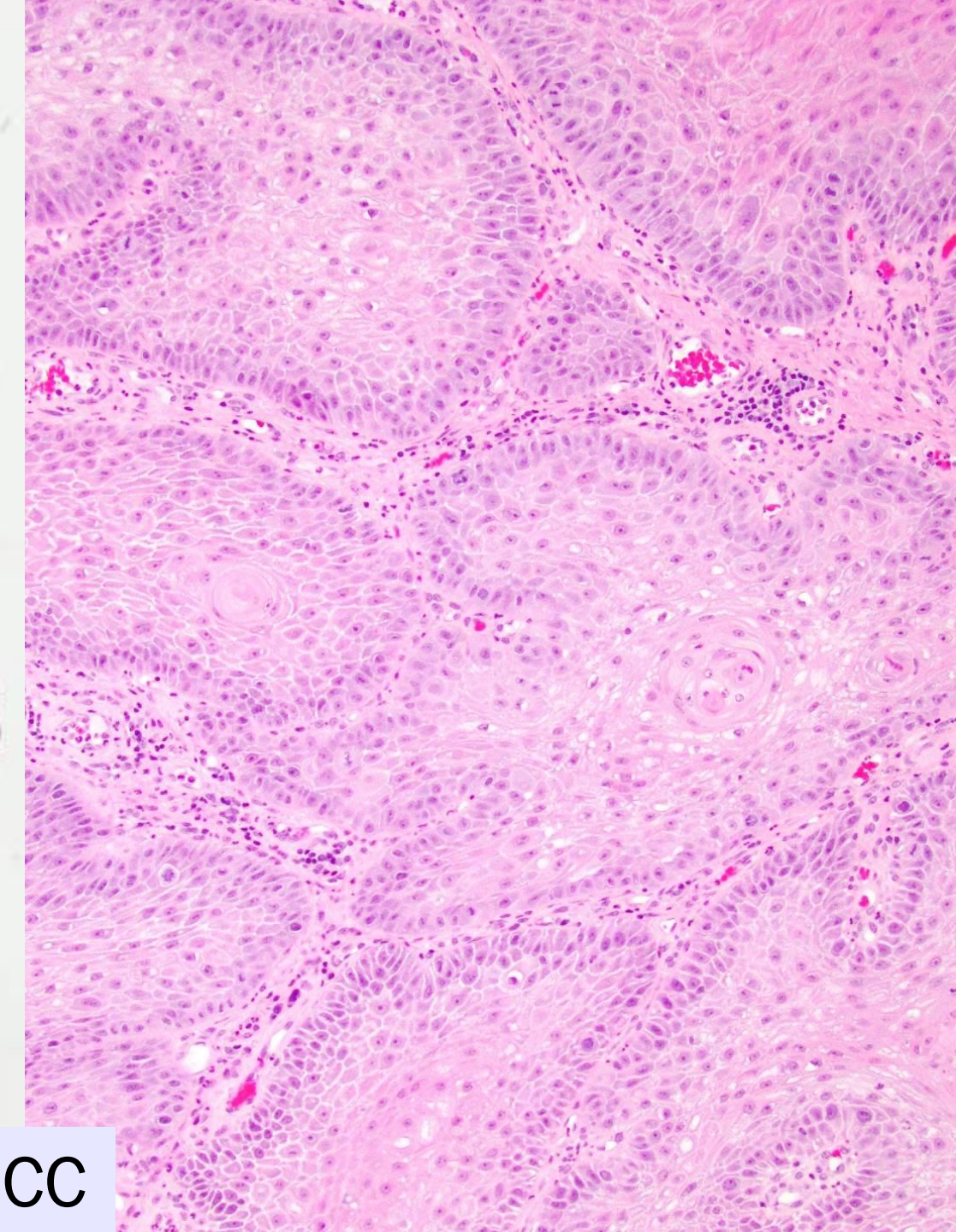

Verrucous SCC

Psoriasis

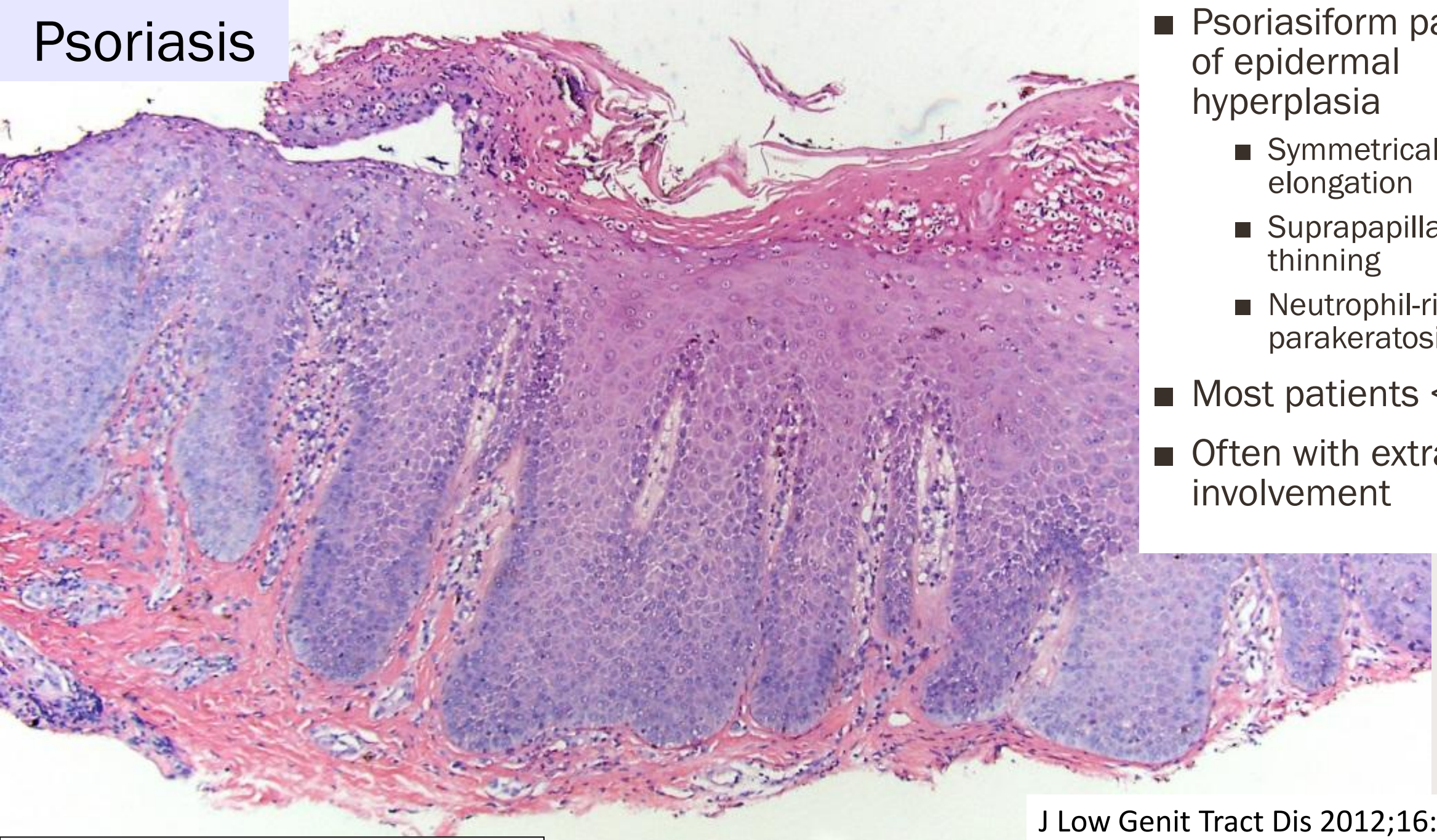

- Psoriasiform pattern of epidermal hyperplasia
  - Symmetrical rete elongation
  - Suprapapillary plate thinning
  - Neutrophil-rich parakeratosis
- Most patients <30 y/o
- Often with extra-vulvar involvement

Courtesy of Dr. C. Matt Quick (UAMS)

J Low Genit Tract Dis 2012;16:364–371
Eur J Dermatol 2020;30:267–278

Verruciform xanthoma

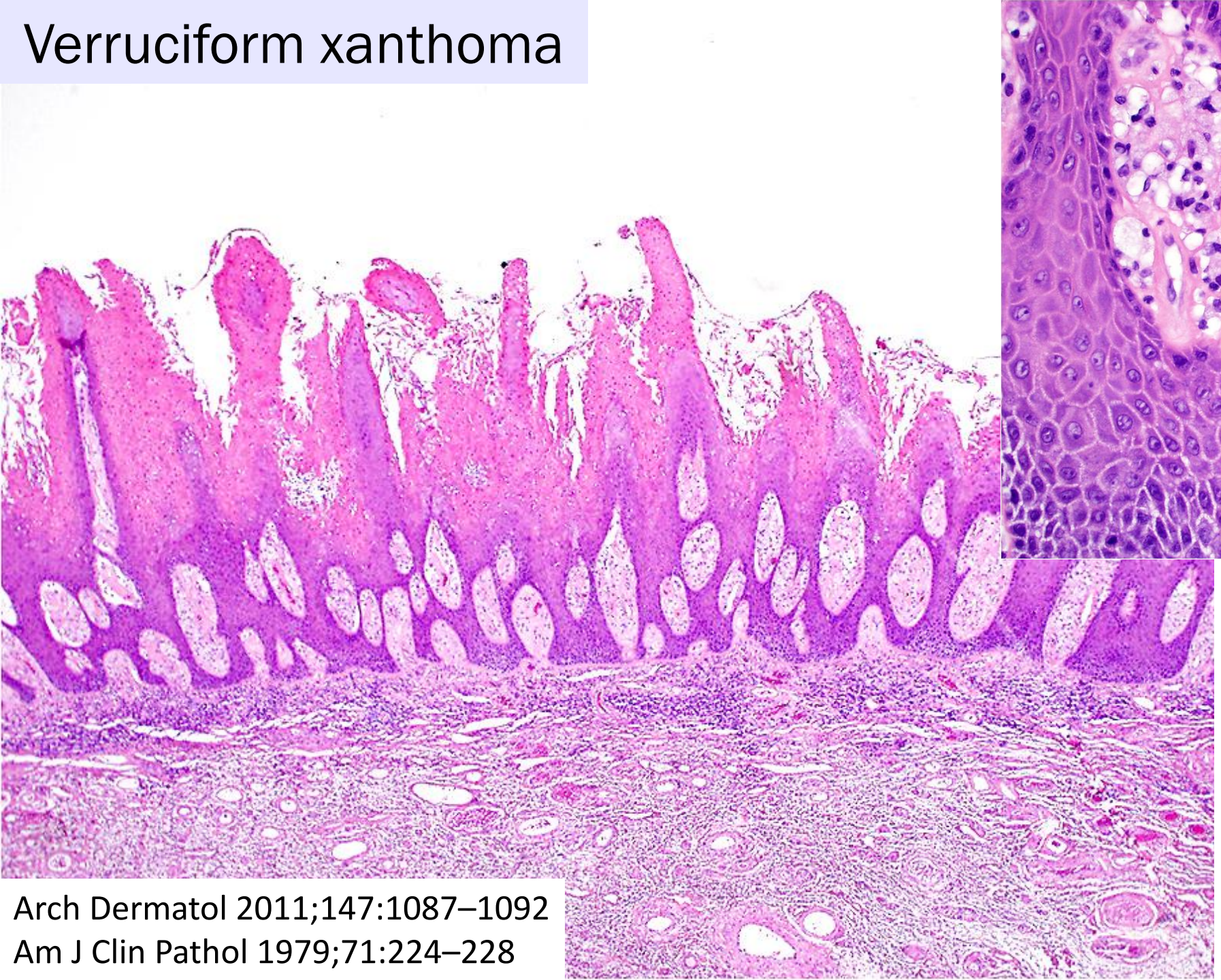

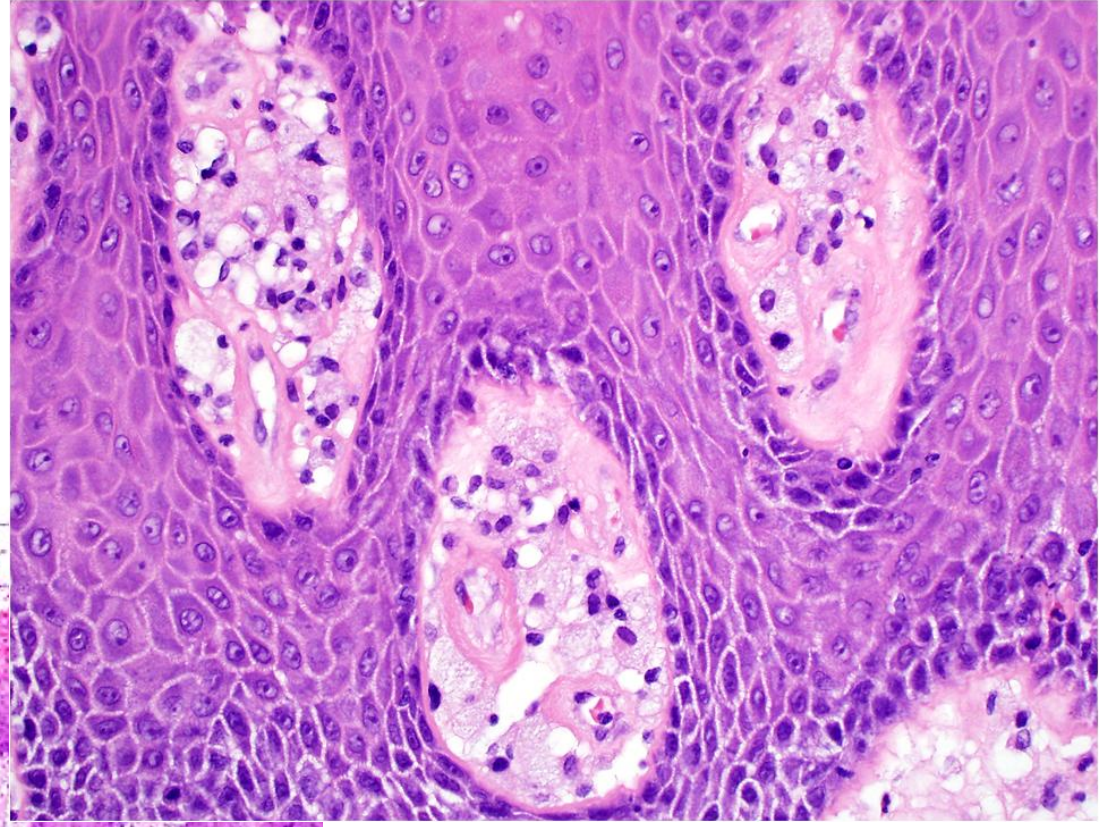

- Small (<2 cm) slow-growing mass
- Young, pre-menopausal women
- Foamy histiocytes in superficial dermis
  - *CD68, PU1 IHC*

Arch Dermatol 2011;147:1087–1092
Am J Clin Pathol 1979;71:224–228

Pseudoepitheliomatous hyperplasia

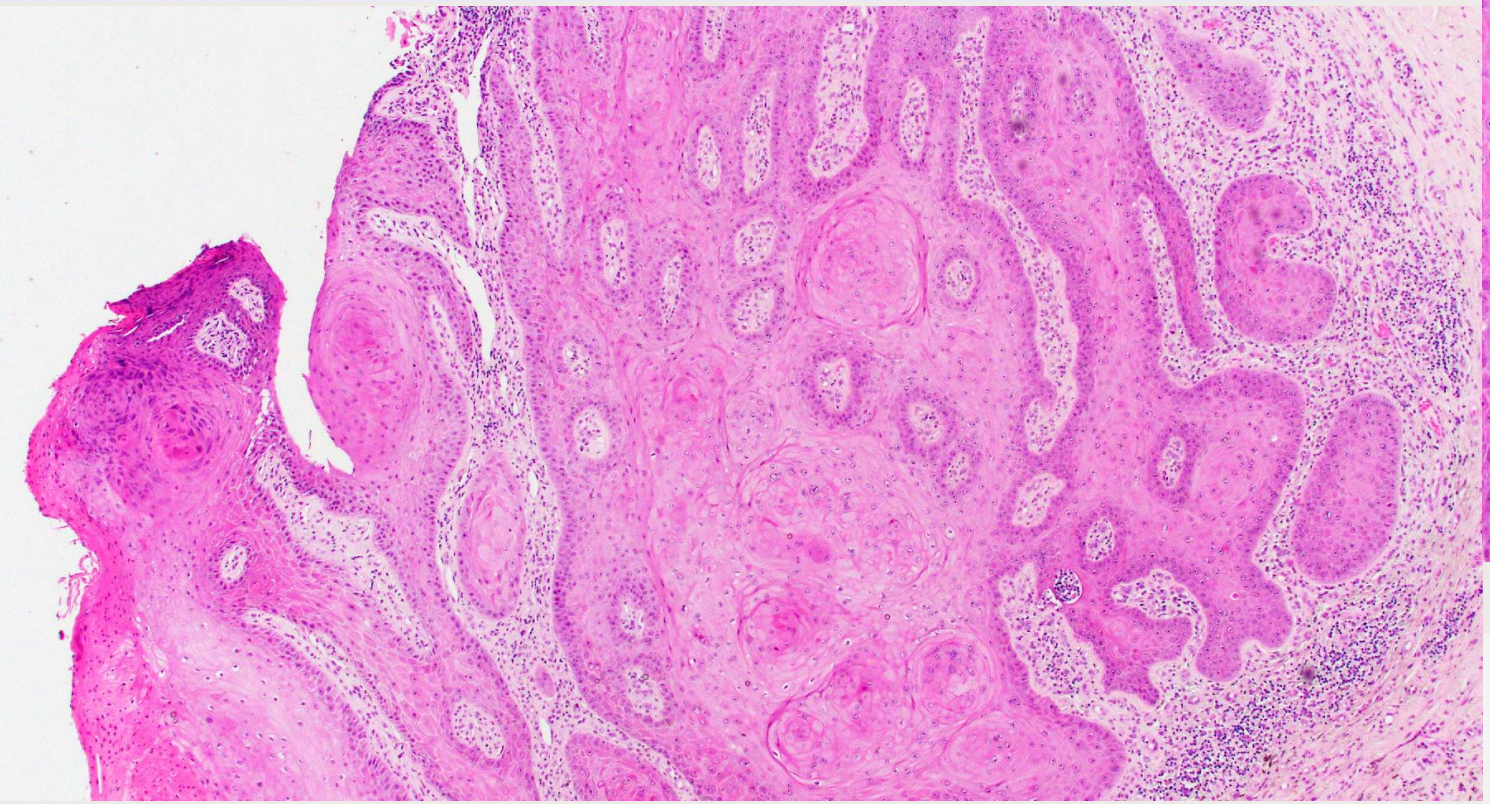

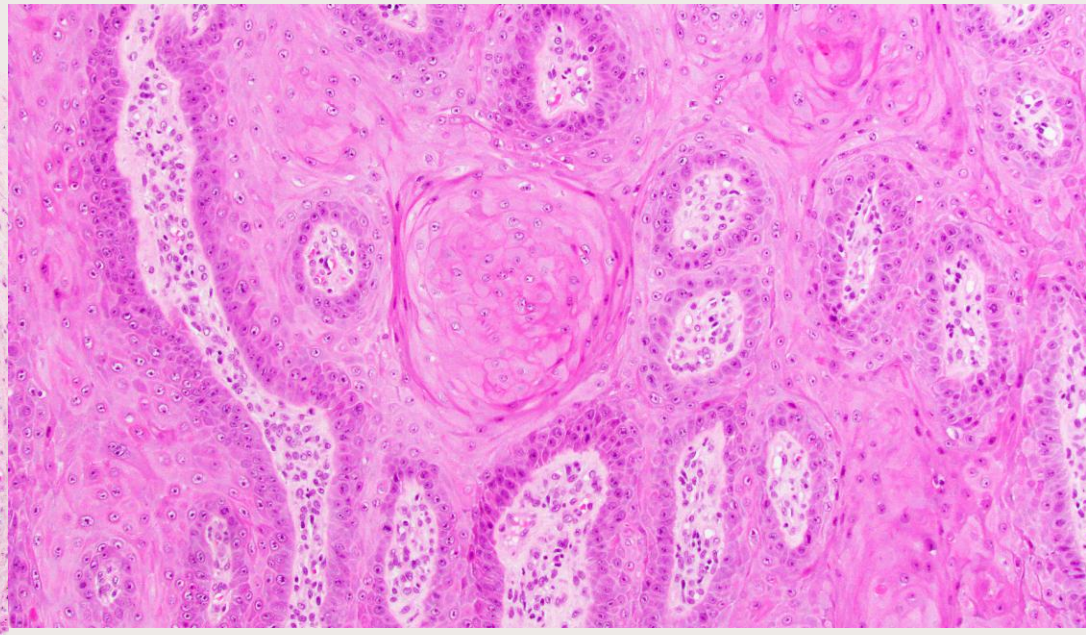

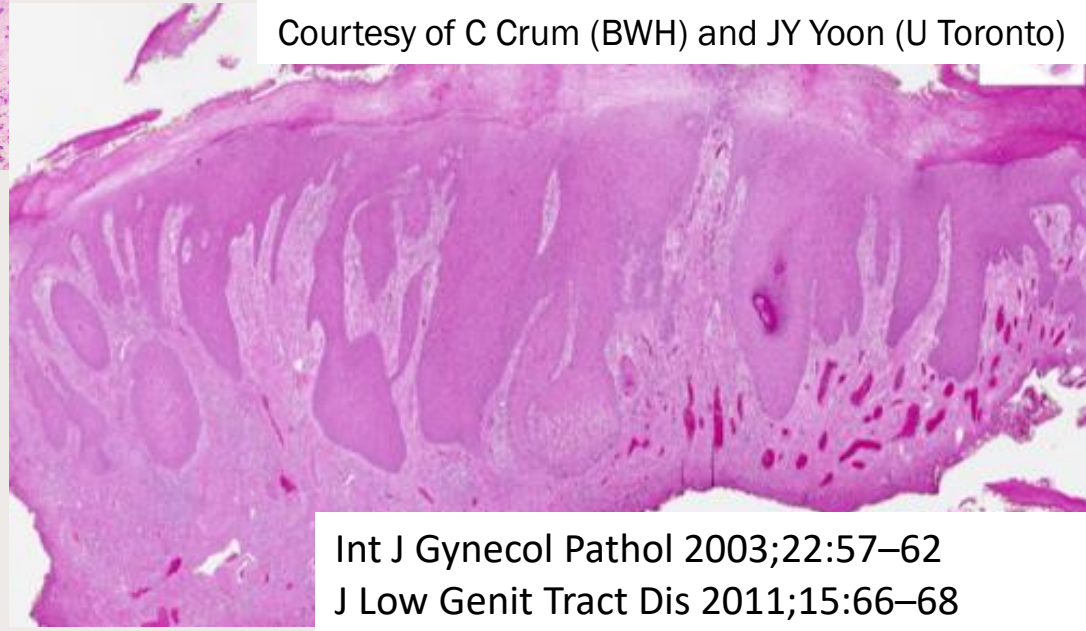

Courtesy of C Crum (BWH) and JY Yoon (U Toronto)

- Acanthosis with irregular rete elongation
- Often related to infection (HSV, syphilis), neoplasia (granular cell tumor) or inflammation (lichen sclerosus)
- Absence of well-developed verruciform surface

Int J Gynecol Pathol 2003;22:57–62
J Low Genit Tract Dis 2011;15:66–68
J Oral Maxillofac Pathol 2014;18:437–441

DDx: LICHEN SIMPLEX CHRONICUS

- Hypergranulosis
- Lack of well-developed verruciform growth
- Is there an explanation?
  - *Another dermatosis (LS, LP)*
  - *Fungal infection*
- Clinical context (age, size)

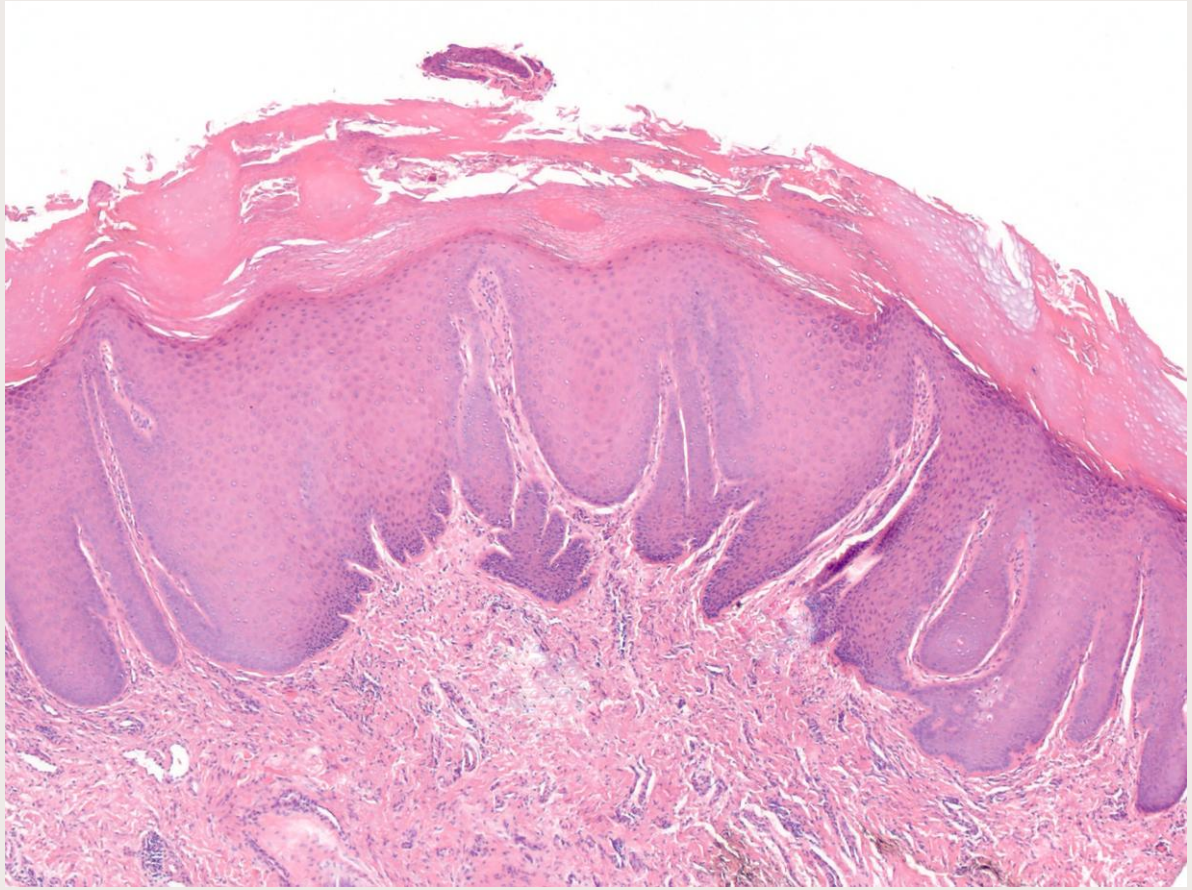

Hoang L, Kinloch M. Inflammatory Diseases of the Vulva. In Gynecologic Pathology. Foundations in Diagnostic Pathology Elsevier 2020.

What if Dx is inconclusive (e.g. small Bx)?

- Vulvar Aberrant Maturation. See note.

NOTE: The differential diagnosis includes a variety of hyperplasias as well as lesions associated with HPV-independent, p53 wild type squamous cell carcinoma, namely verruciform acanthotic VIN. Close observation and consideration for further sampling is recommended.

J Low Genit Tract Dis 2021;25: 57–70

Can VIN with atypia (differentiated or HSIL-like) be p53-wild type?

- *Rare, but documented*
- In the setting of wild type p53, consider HPV-I if H&E is convincing
  - Severe atypia not explained by inflammation, radiation or other

Histopathology

Histopathology 2024, **84**, 301–314. DOI: 10.1111/his.15050

High-grade vulvar intraepithelial neoplasia: comprehensive characterization and long-term vulvar carcinoma risk

Nikki B Thuijs,[1,2] Marc van Beurden,[3] Sylvia Duin,[1,2] Daniëlle A M Heideman,[1,2,4] Johannes Berkhof,[5] Renske D M Steenbergen[1,2] & Maaike C G Bleeker[1,2]

- 751 high-grade VINs
- 46 HPV-independent VIN
  - *59% differentiated*
  - *41% HSIL-like*
  - *65% p53mut*
  - *35% p53 wt*



Is p16/HPV and p53 available?



- Squamous intraepithelial lesion
- HPV-independent VIN (Differentiated pattern)
- HPV-independent VIN (verruciform acanthotic pattern)

VIN, NOS
Suspicious for VIN

- HSIL (HPV-associated)
- HPV-independent p53-mut VIN
  - Differentiated
  - HSIL-like / basaloid
- HPV-independent p53-wt VIN
  - Verruciform acanthotic
  - With atypia

IHC

- CK17
- SOX2
- GATA3

Article

Evaluation of Immunohistochemical Markers, CK17 and SOX2, as Adjuncts to p53 for the Diagnosis of Differentiated Vulvar Intraepithelial Neoplasia (dVIN)

Shatavisha Dasgupta [1,*], Senada Koljenović [1], Thierry P. P. van den Bosch [1], Sigrid M. A. Swagemakers [1,2], Nick M. A. van der Hoeven [3,4], Ronald van Marion [1], Peter J. van der Spek [1,2], Helena C. van Doorn [4], Folkert J. van Kemenade [1,†] and Patricia C. Ewing-Graham [1,†]

Pharmaceuticals 2021;14;324

Differential expression patterns of GATA3 in usual and differentiated types of vulvar intraepithelial neoplasia: potential diagnostic implications

Abha Goyal[1] · Gloria Zhang[2] · Bin Yang[2]

Mod Pathol 2018;31(7):1131-1140

GATA3 immunohistochemistry as a diagnostic adjunct for differentiated vulvar intraepithelial neoplasia: utility and limitations☆,☆☆

Somaye Y. Zare MD, Elmira Vaziri Fard MD, MPH, Oluwole Fadare MD*

Hum Pathol 2023;139:55-64

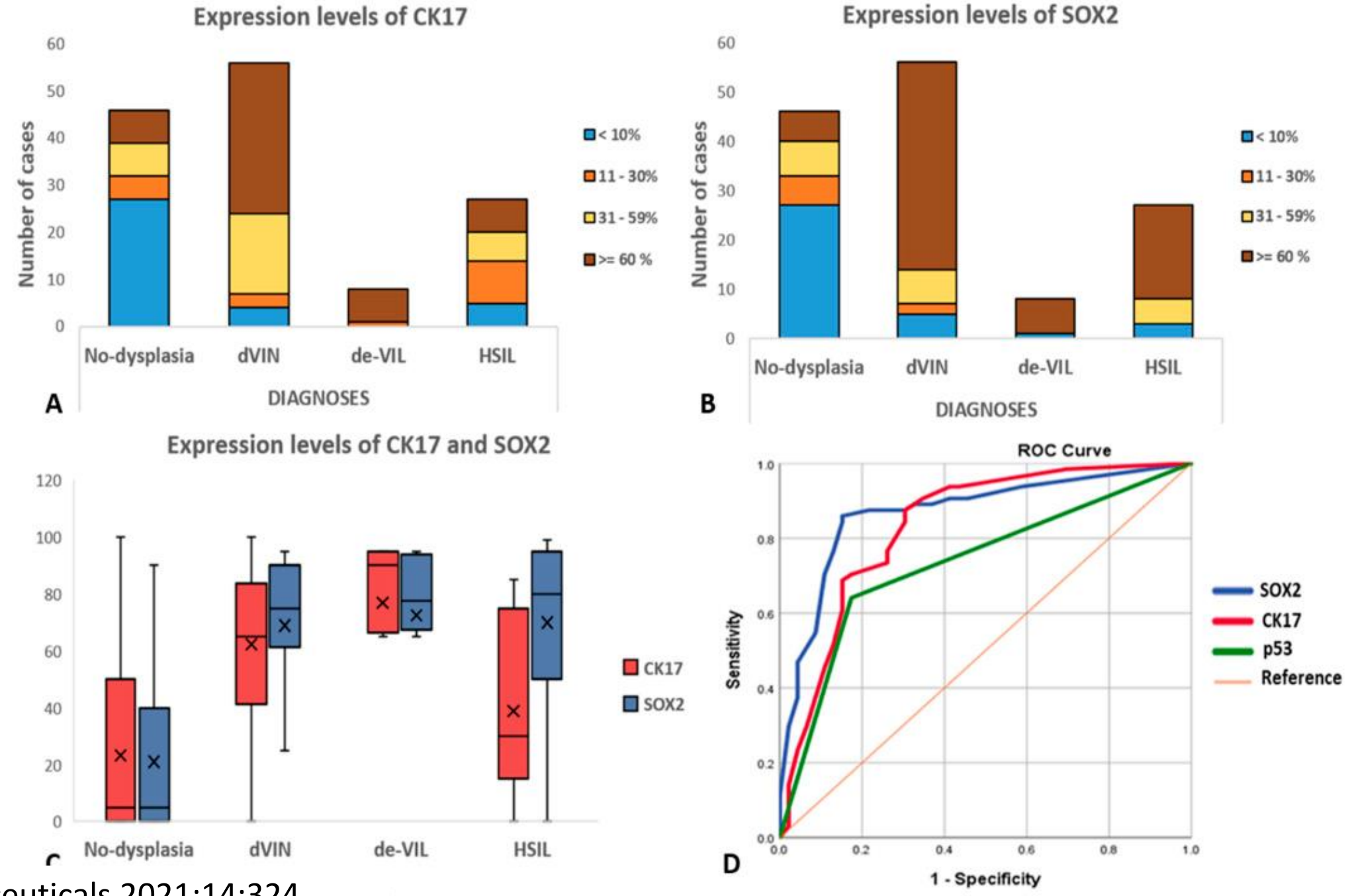

Pharmaceuticals 2021;14;324

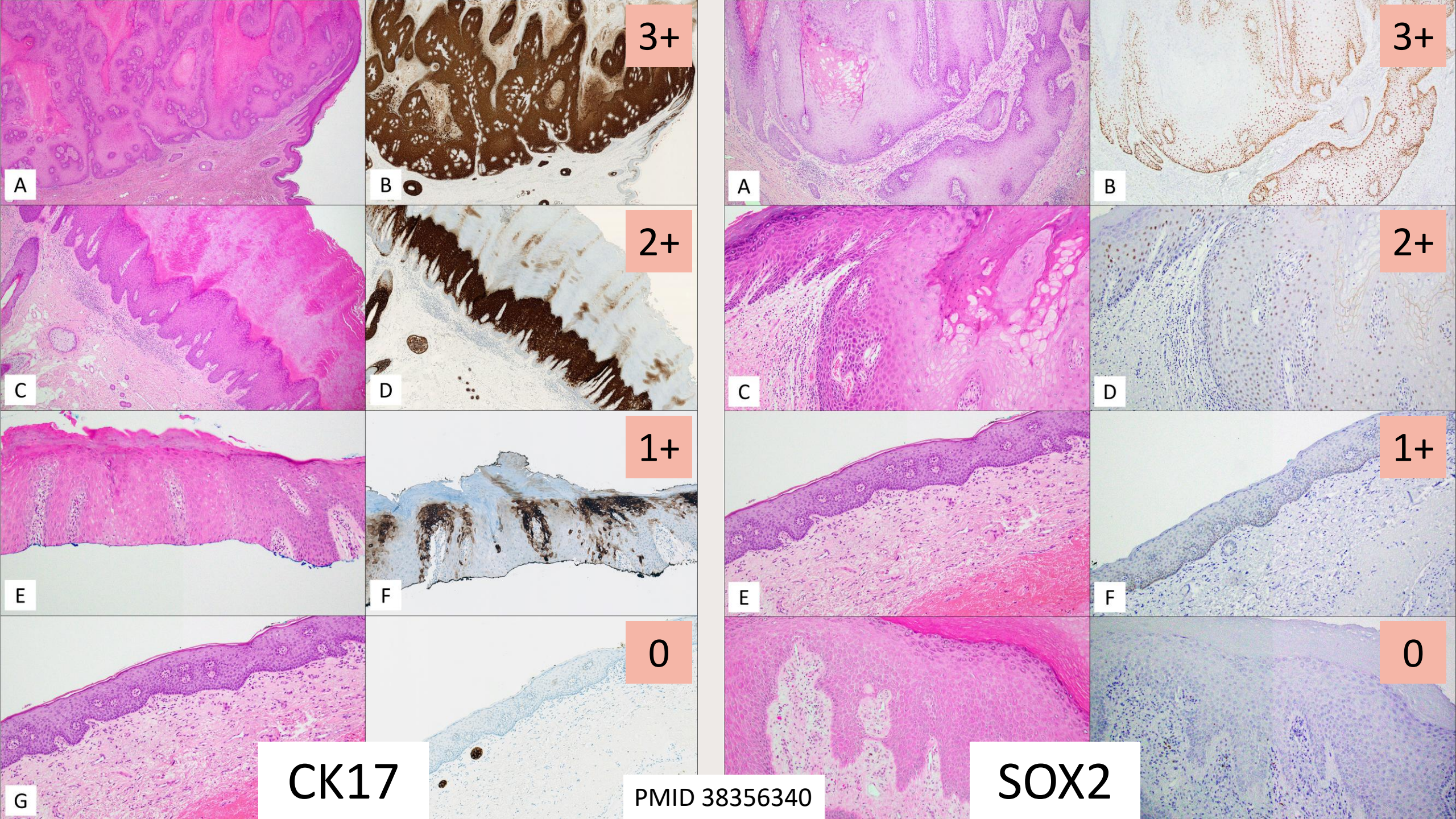
A
3+
B
A
3+
B
C
2+
D
C
2+
D
E
1+
F
E
1+
F
G
0
0
CK17
PMID 38356340
SOX2

Pattern 0: Loss of expression in <25% basal cells (focal)

Pattern 1: Loss of expression in 25-75% basal cells (extensive)

Pattern 2: Loss of expression in >75% basal cells (diffuse)

	GATA3 staining patterns			p53 IHC results	
	Pattern 0	Pattern 1	Pattern 2	Wild type	Abnormal
VULVAR EPIDERMIS IN PATHOLOGIC STATES					
Dysplastic and precancerous lesions (number of cases)					
Differentiated VIN	2	3	16	1	20
Vulvar aberrant maturation	1	7	2	9	1 (strong basal)
VIN III	37	1	6	44	0
Non-neoplastic lesions (number of cases)					
Lichen sclerosus	23	1	1	23	2 (strong basal)
Lichen simplex chronicus	6	0	0	6	0
Spongiotic dermatitis	13	0	0	13	0
Lichen planus	2	0	0	2	0
Nonspecific interface dermatitis	3	0	0	3	0
NORMAL VULVAR EPIDERMIS	75	0	0	75	0

Hum Pathol 2023;139:55-64

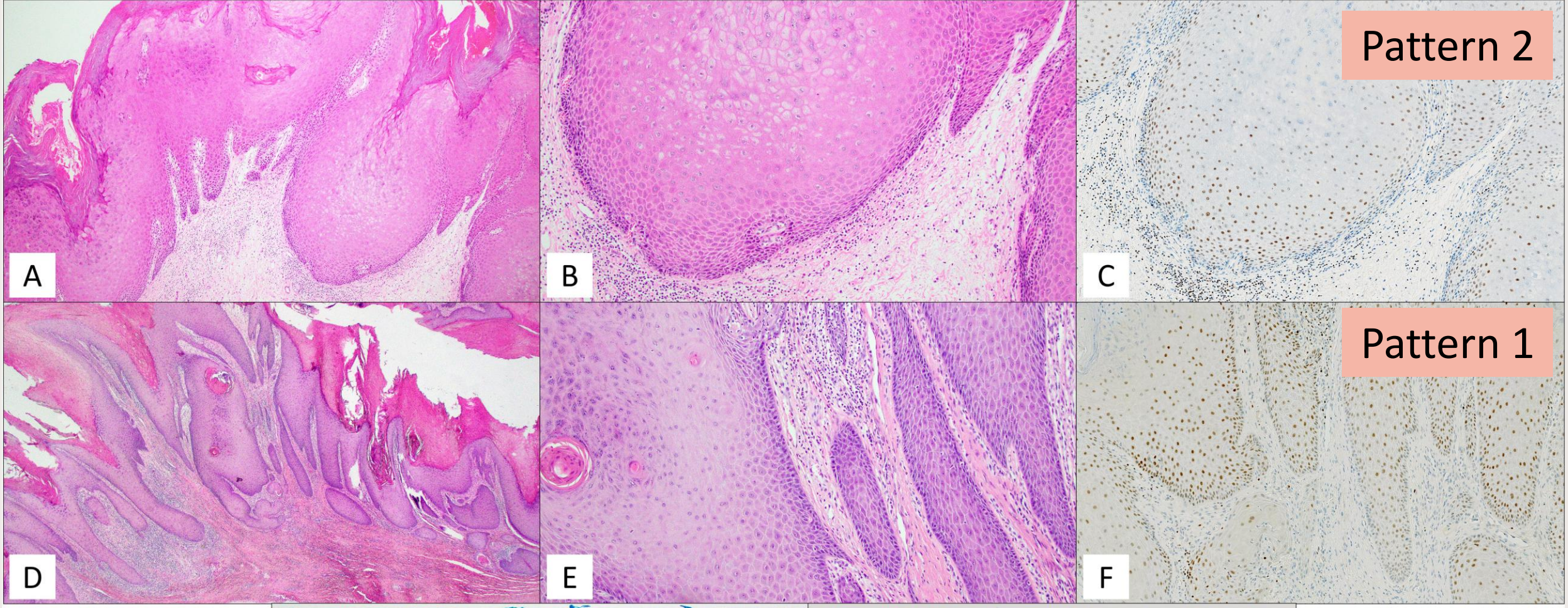

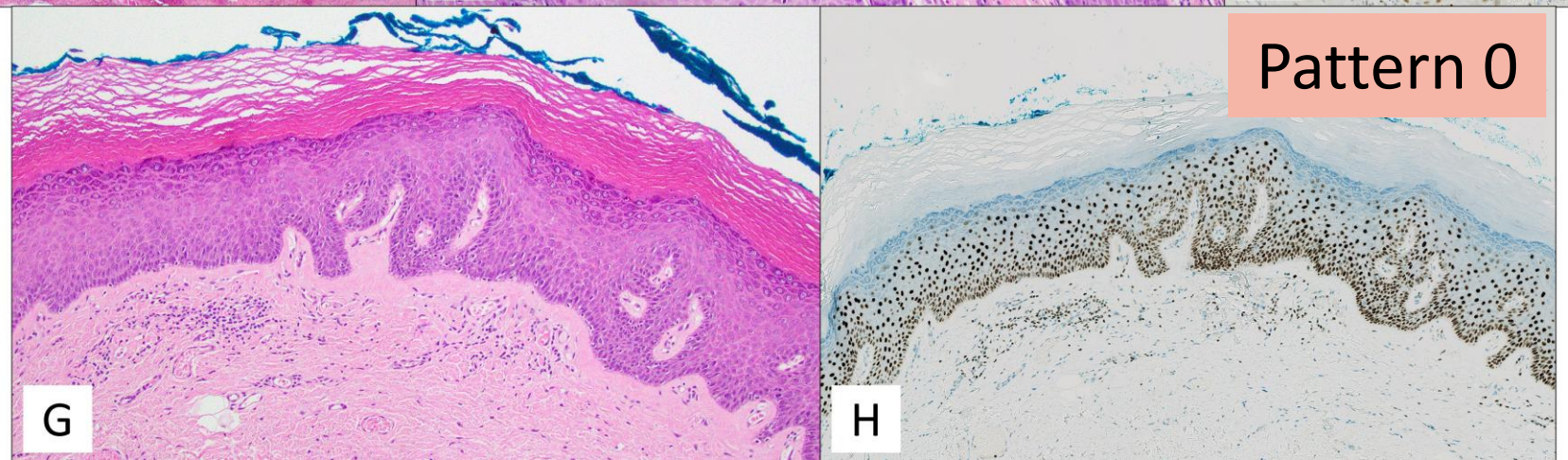

GATA3

PMID 38356340

Table 5. Sensitivity, specificity and predictive values for CK17, SOX2 and GATA3 in the diagnosis of verruciform/acanthotic vulvar intra-epithelial neoplasia (vaVIN)

Differential	Statistic	CK17 positivity (3+ score) (%)	SOX2 positivity (3+ score) (%)	GATA3 positivity (pattern 1 or 2) (%)	2 or 3 positive markers (%)
vaVIN versus acanthotic/ verruciform mimicker	Sensitivity	81	75	58	83
	Specificity	68	83	78	88
	Pos predictive value[a]	54	64	50	71
	Neg predictive value[a]	88	89	83	93
	Accuracy	72	81	73	86
vaVIN versus normal mucosa	Sensitivity	81	69	58	83
	Specificity	100	50	75	86
	Pos predictive value[a]	100	69	78	91
	Neg predictive value[a]	79	50	55	75
	Accuracy	89	62	65	84

PMID 38356340

Positive: CK17 = 3+ SOX2 = 3+ GATA3 = patterns 1 & 2

Negative: CK17 = 2+/1+/0 SOX2 = 2+/1+/0 GATA3 = pattern 0

THANK YOU!

cparra-herran@bwh.harvard.edu