The British Association of Gynaecological Pathologists

21st Annual Meeting in Collaboration with ISGyP

5th and 6th June 2025

- Title: Evaluation of Non-Smooth Muscle Uterine Mesenchymal Lesions on Biopsy
- Carlos Parra-Herran
- Brigham and Women's Hospital, Boston MA United States
- June 5, 2025

The British Association of Gynaecological Pathologists

Speaker disclosures

Choose one

- ❑ I have no financial conflicts of interest to disclose

Evaluation of Non-Smooth Muscle Uterine Mesenchymal Lesions on Biopsy

CARLOS PARRA-HERRAN MD
Pathologist – Brigham and Women's Hospital
Associate Professor - Harvard Medical School
cparra-herran@bwh.harvard.edu





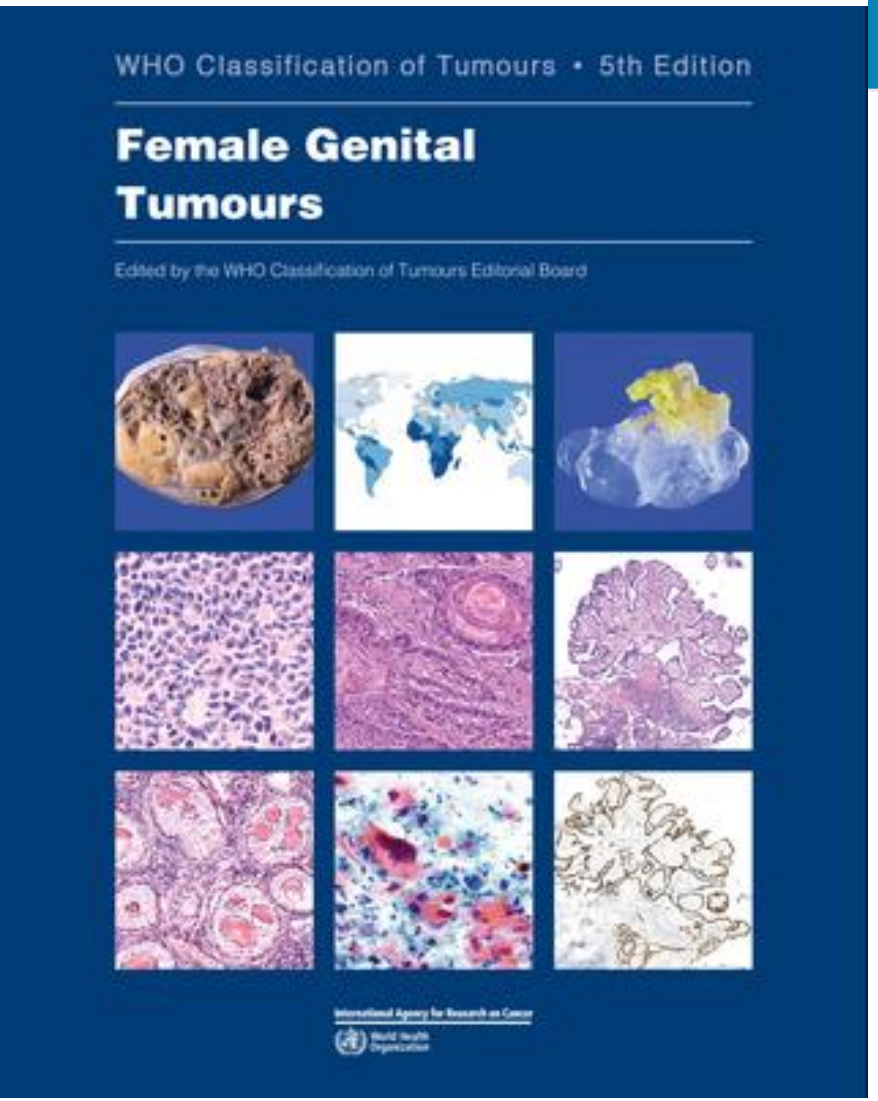

International Agency for Research on Cancer

World Health Organization

WHO Classification of Female Genital Tumours. 5th Ed. 2020. IARC

Female Genital Tumours

Mesenchymal tumours of the uterus

Smooth muscle tumours

- Uterine leiomyoma
- Intravenous leiomyomatosis
- Smooth muscle tumour of uncertain malignant potential of the uterine corpus
- Metastasizing leiomyoma
- Uterine leiomyosarcoma

Defined by morphology

Endometrial stromal and related tumours

- Endometrial stromal nodule
- Low-grade endometrial stromal sarcoma
- High-grade endometrial stromal sarcoma
- Undifferentiated uterine sarcoma

Miscellaneous mesenchymal tumours

- Uterine tumour resembling ovarian sex cord tumour
- Perivascular epithelioid cell tumour (PEComa)
- Inflammatory myofibroblastic tumour
- Other mesenchymal tumours of the uterus

Defined by morphology & molecular substrate

DIAGNO

- Inmunohi
- In Situ Hy
- DNA & RN



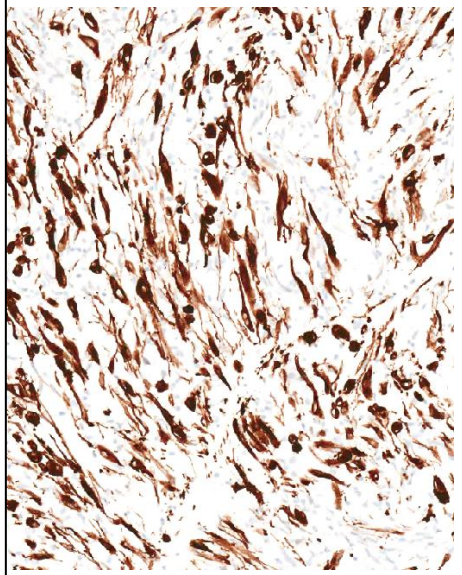

ARCHER™
Now part of
Integrated DNA Technologies

SIONPlex®
oma v2

OUTLINE

- Differential diagnosis based on morphology
- Initial categorization (benign vs malignant)
- Reporting suggestions

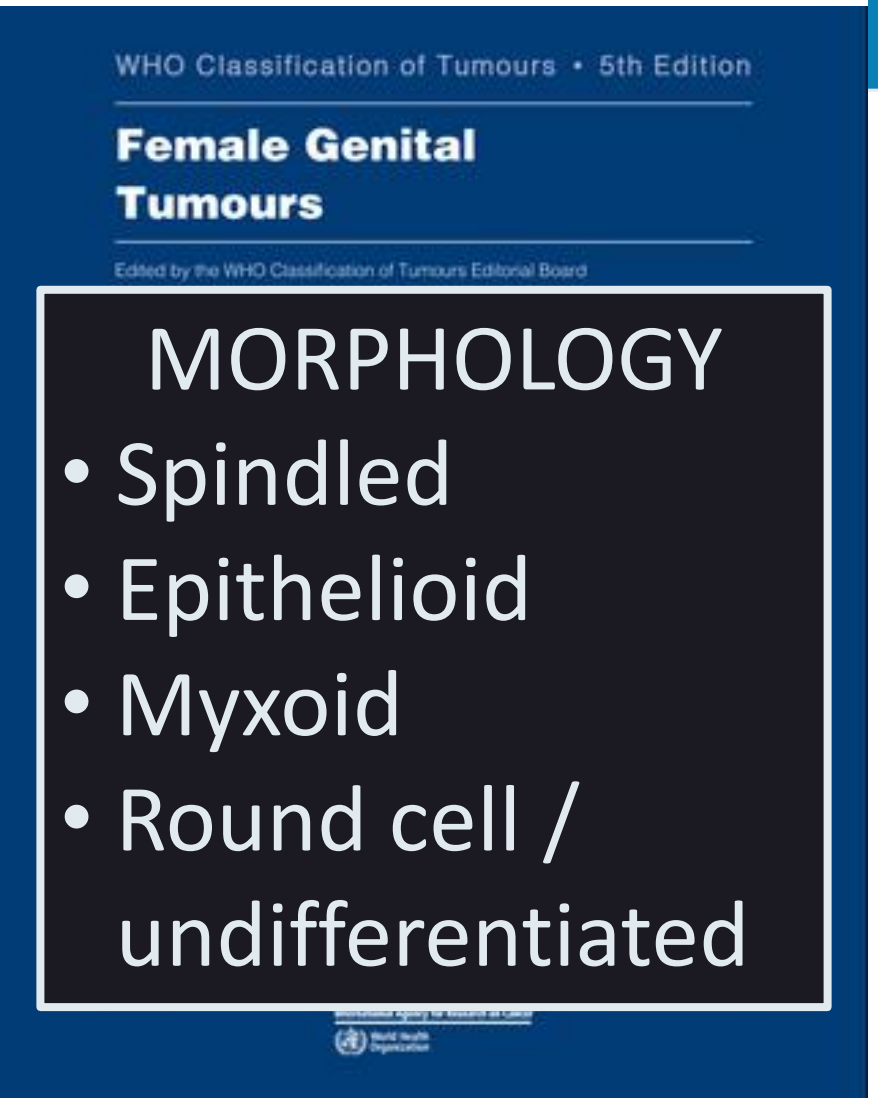

International Agency for Research on Cancer

World Health Organization

WHO Classification of Female Genital Tumours. 5th Ed. 2020. IARC

Female Genital Tumours

Mesenchymal tumours of the uterus

Smooth muscle tumours

- Uterine leiomyoma
- Intravenous leiomyomatosis
- Smooth muscle tumour of uncertain malignant potential of the uterine corpus
- Metastasizing leiomyoma
- Uterine leiomyosarcoma

Endometrial stromal and related tumours

- Endometrial stromal nodule
- Low-grade endometrial stromal sarcoma
- High-grade endometrial stromal sarcoma
- Undifferentiated uterine sarcoma

Miscellaneous mesenchymal tumours

- Uterine tumour resembling ovarian sex cord tumour
- Perivascular epithelioid cell tumour (PEComa)
- Inflammatory myofibroblastic tumour
- Other mesenchymal tumours of the uterus

SPINDLE CELL PATTERN – MONOMORPHIC

- Benign tumours (**most often**)
  - Leiomyoma (conventional y variants)
  - Endometrial stromal nodule
- Tumors with malignant potential
  - Low-grade endometrial stromal sarcoma
  - Inflammatory myofibroblastic tumour
  - *NTRK*-rearranged sarcoma
  - Malignant peripheral nerve sheath tumour
  - Solitary fibrous tumour

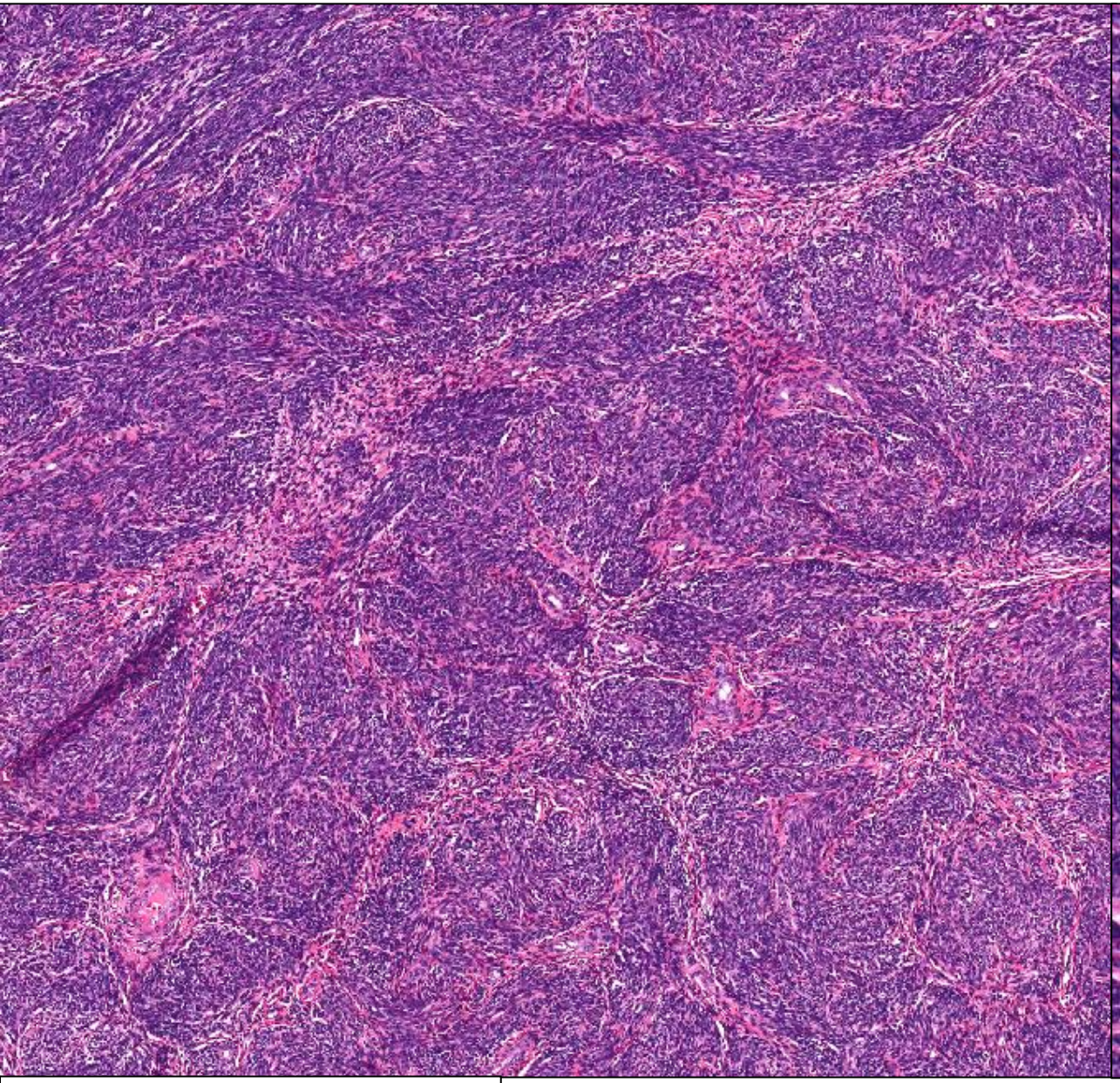

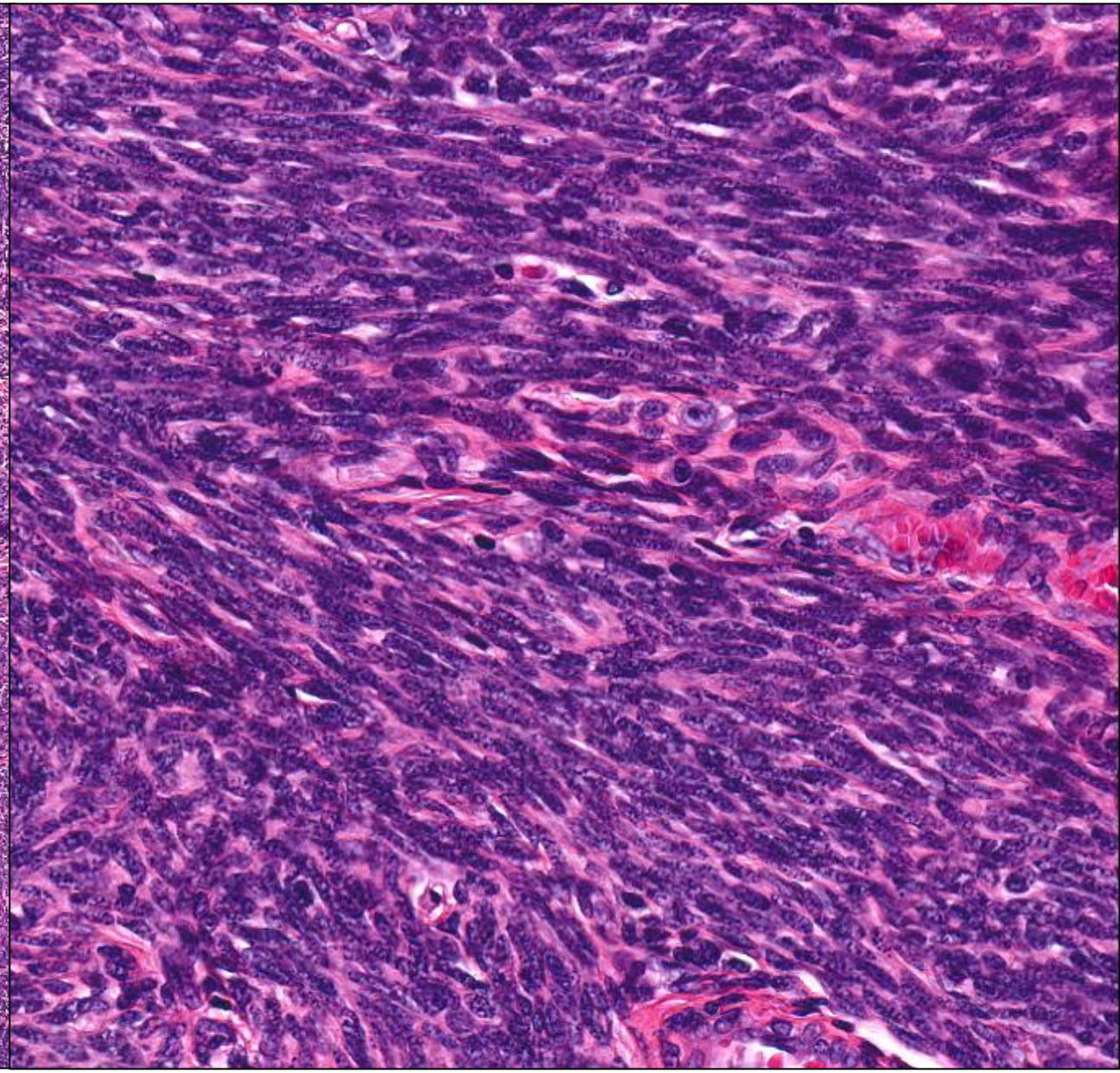

Cellular leiomyoma

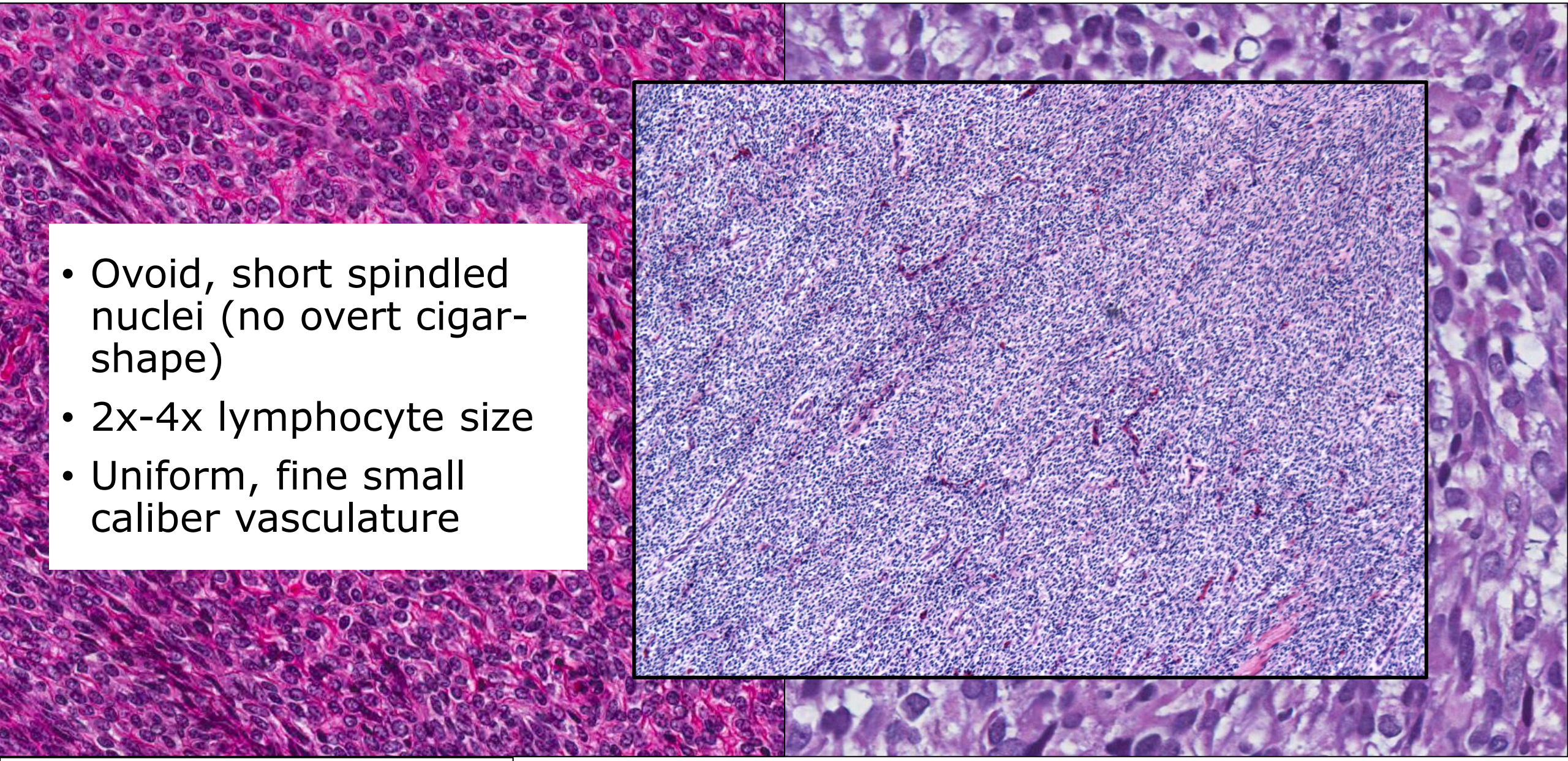

- Ovoid, short spindled nuclei (no overt cigar-shape)
- 2x-4x lymphocyte size
- Uniform, fine small caliber vasculature

Endometrial stromal nodule

Endometrial stromal markers:

CD10 Sensitive, non-specific

IFITM1 Sensitive, better specificity, not widely available

Smooth muscle markers:

SMA Sensitive, non-specific

Desmin Sensitive, non-specific

Caldesmon Non-sensitive, specific

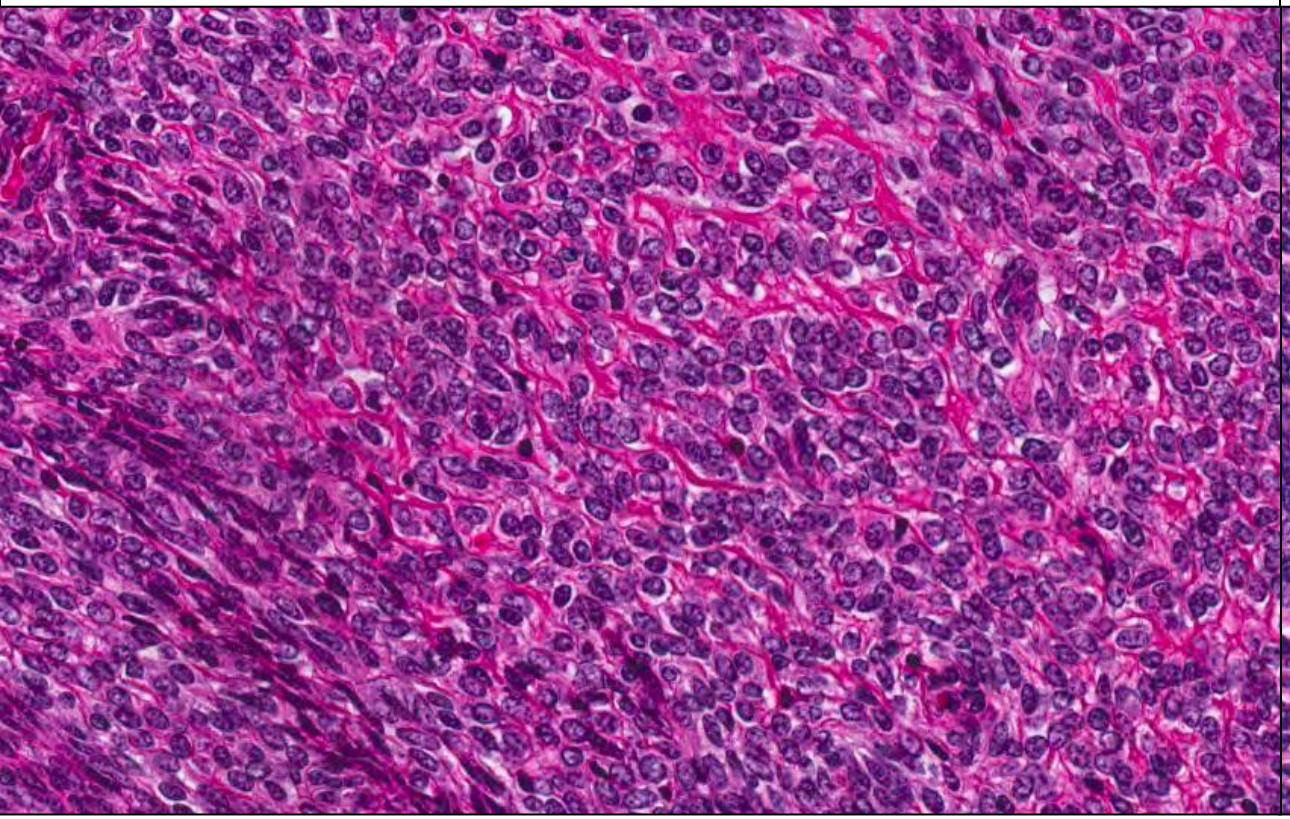

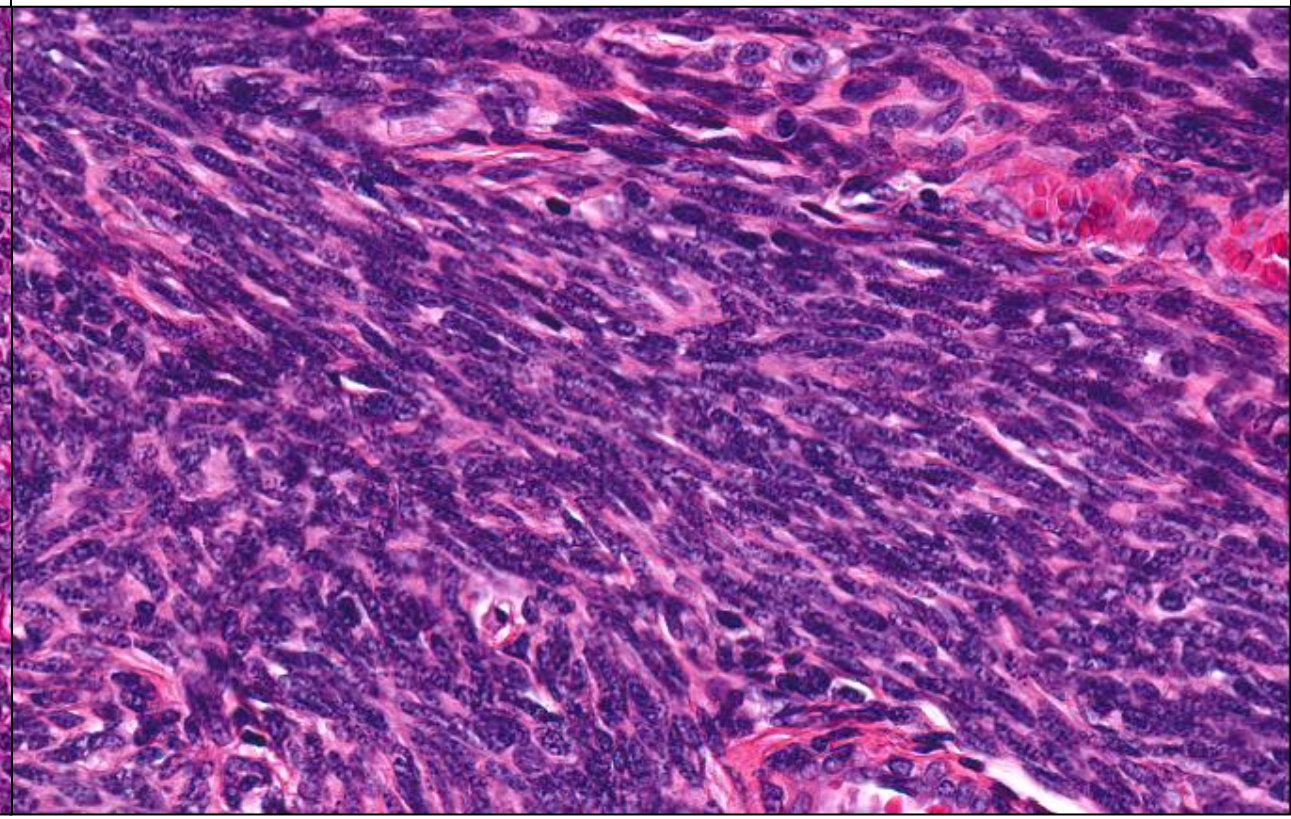

LG-ESS

Cellular leiomyoma

Low-grade mesenchymal tumour
- High celullarity
- No significant atypia
- No necrosis
- Low mitotic count (<10/2.4 mm^2)
- ER y PR +++

Smooth muscle tumour
Cigar-shaped elongated nuclei
Desmin, SMA, H-caldesmon +++
Think and variably distributed vessels

Endometrial stromal tumour
Short ovoid nuclei
CD10, IFITM1 +++
Think and uniformly distributed vessels

Still don't know!



Tumor border

Smooth, non-infiltrative
Absent or minimal projections *
No vascular invasion

BENIGN
Cellular leiomyoma

BENIGN
Endometrial stromal nodule

Other possibilities (rare):
Inflammatory myofibroblastic tumour
Solitary fibrous tumour
PEComa

Invasive, myo-permeative type
Satellite lesions
Vascular invasion

BENIGN
Dissecting leiomyoma / with Intravascular extension

Very rare scenario
Nodules with convex and smooth outline

MALIGNANT
Low-grade endometrial stromal sarcoma

Nodules have smooth outline but with irregular (puzzle-like) shapes

Invasive, destructive type

MALIGNANT
Not a low-grade mesenchymal tumour

* In continuity with the main mass, 3 or less, <3 mm

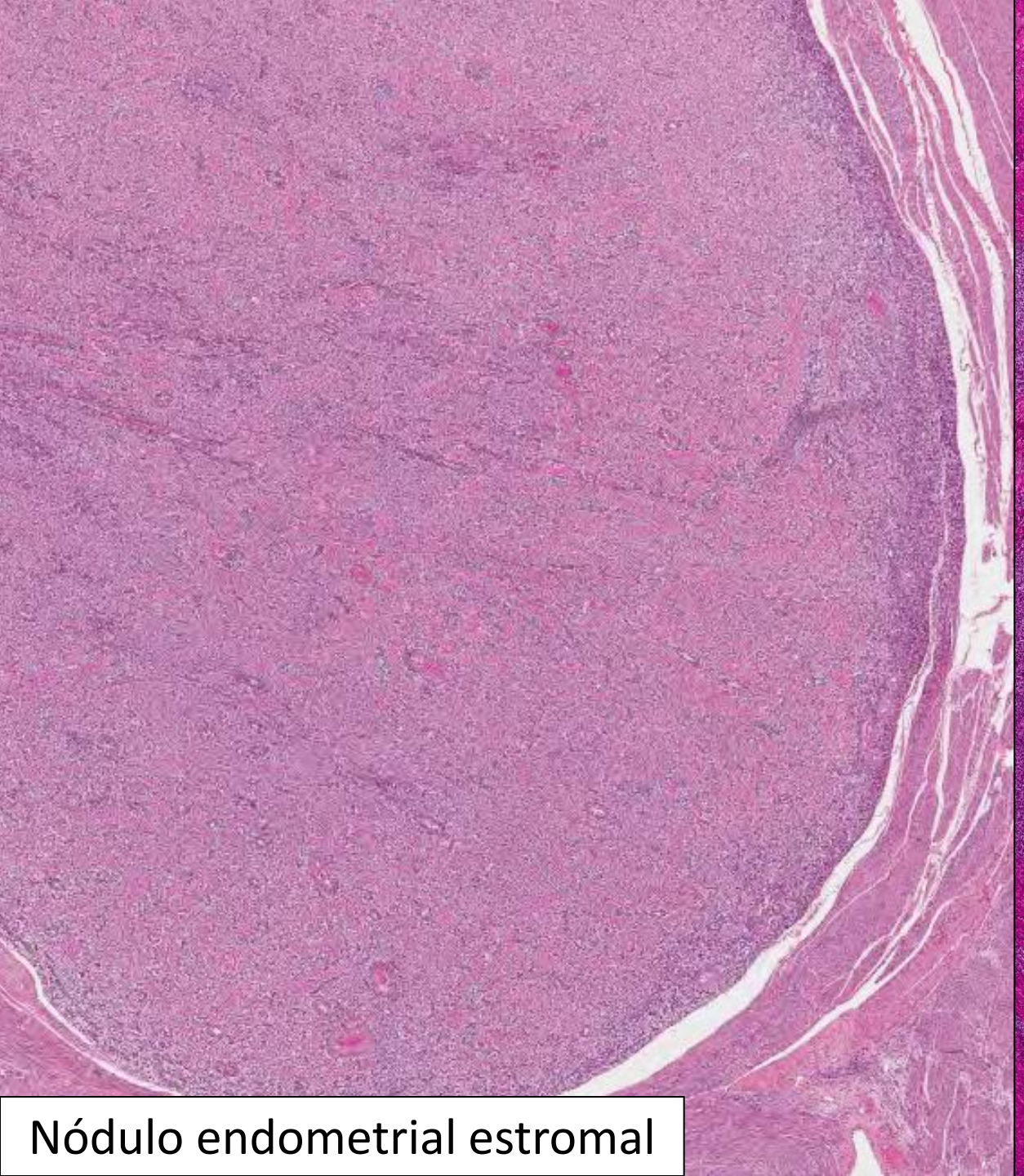

Nódulo endometrial estromal

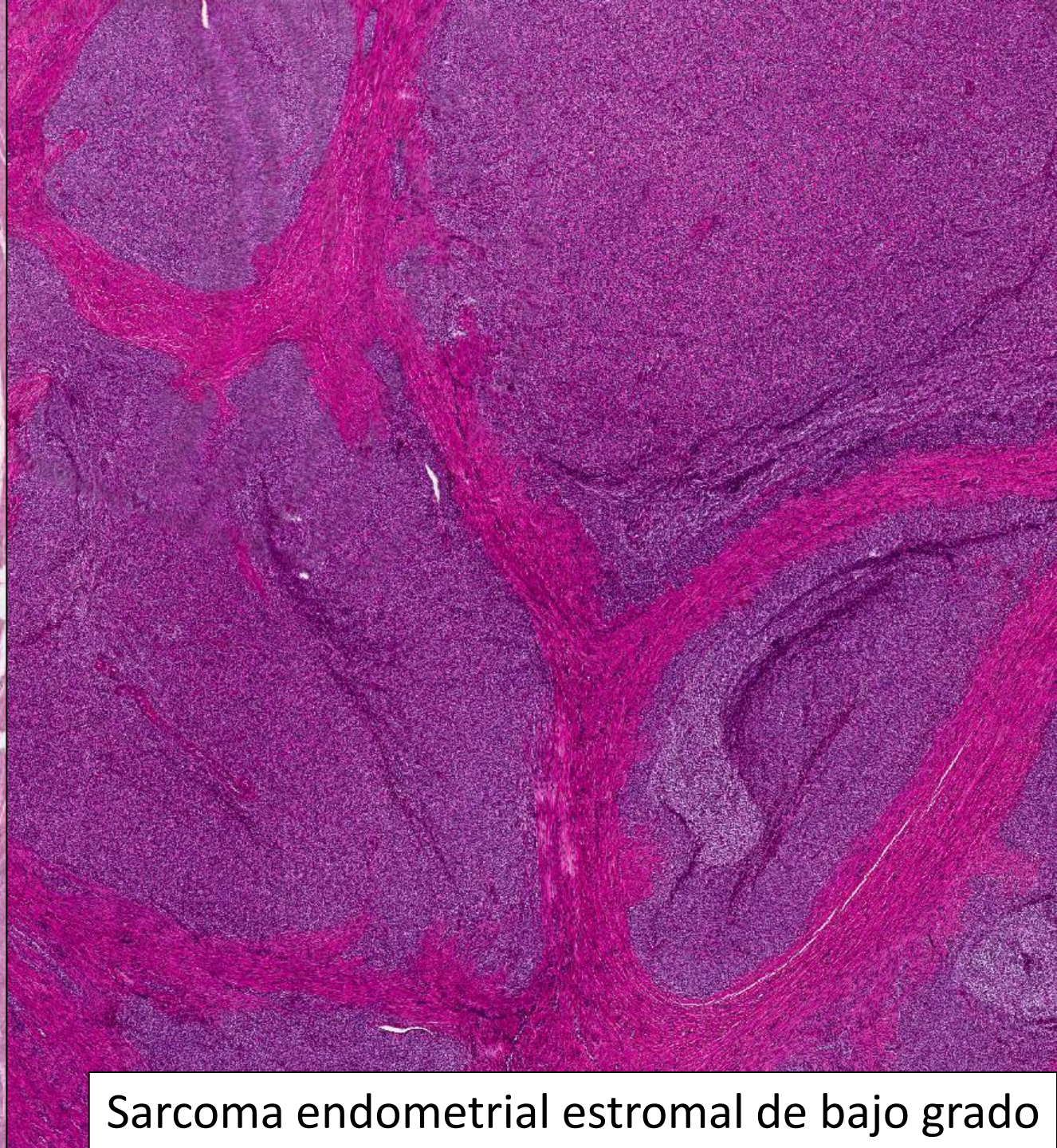

Sarcoma endometrial estromal de bajo grado

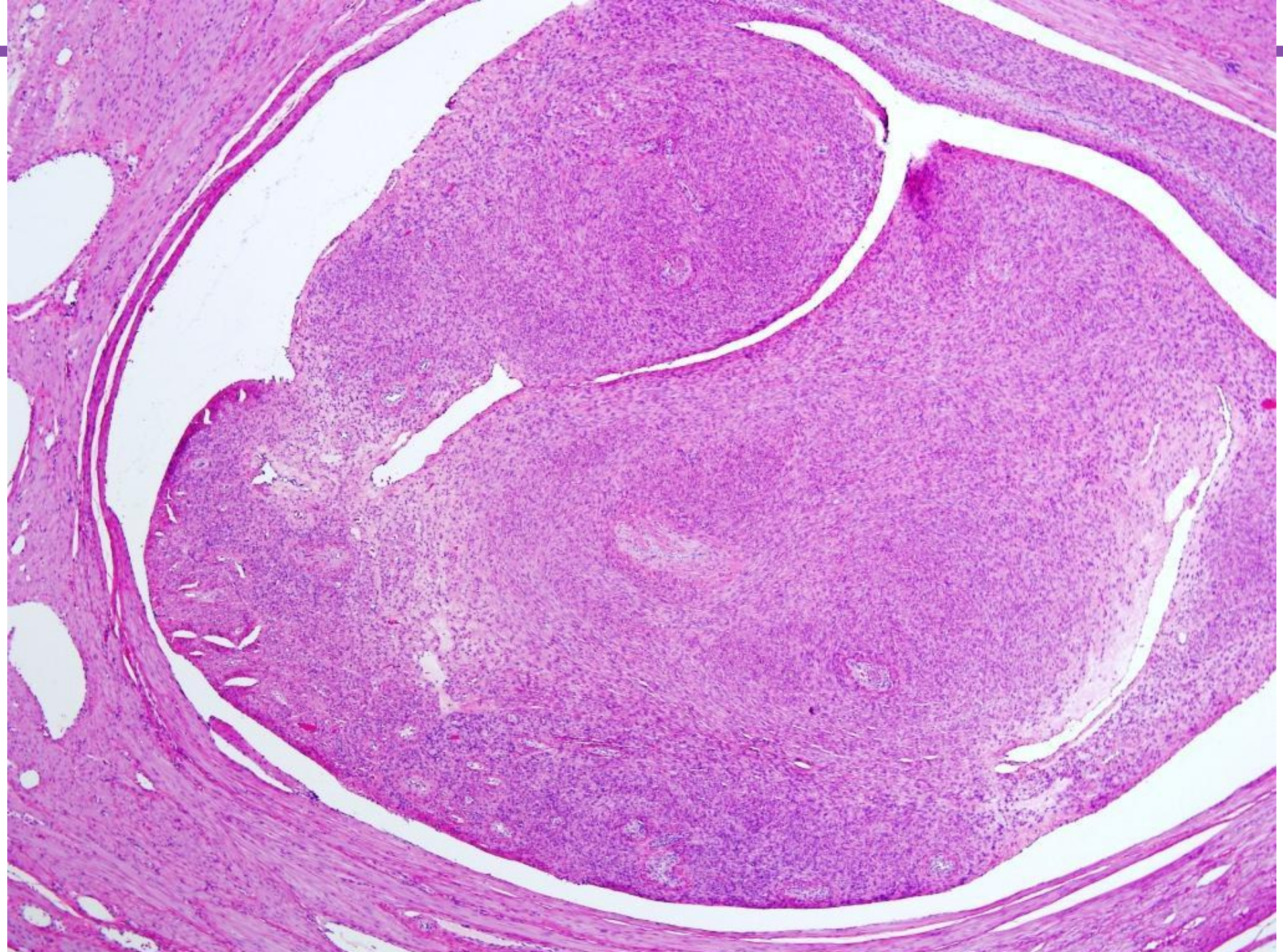

Low-grade mesenchymal tumour
- High celullarity
- No significant atypia
- No necrosis
- Low mitotic count (<10/2.4 mm^2)
- ER y PR +++

Smooth muscle tumour
Cigar-shaped elongated nuclei — Think, variably distributed vessels
Desmin, SMA, H-caldesmon +++

Endometrial stromal tumour
Short ovoid nuclei — Think, uniformly distributed vessels
CD10, IFITM1 +++

In Bx material

- *Low-grade spindle cell neoplasm*
- *LG-ESS cannot be excluded*
- Recommend:
  - Correlation with imaging
  - Close surveillance & monitor for regrowth

Inflammatory myofibroblastic tumour

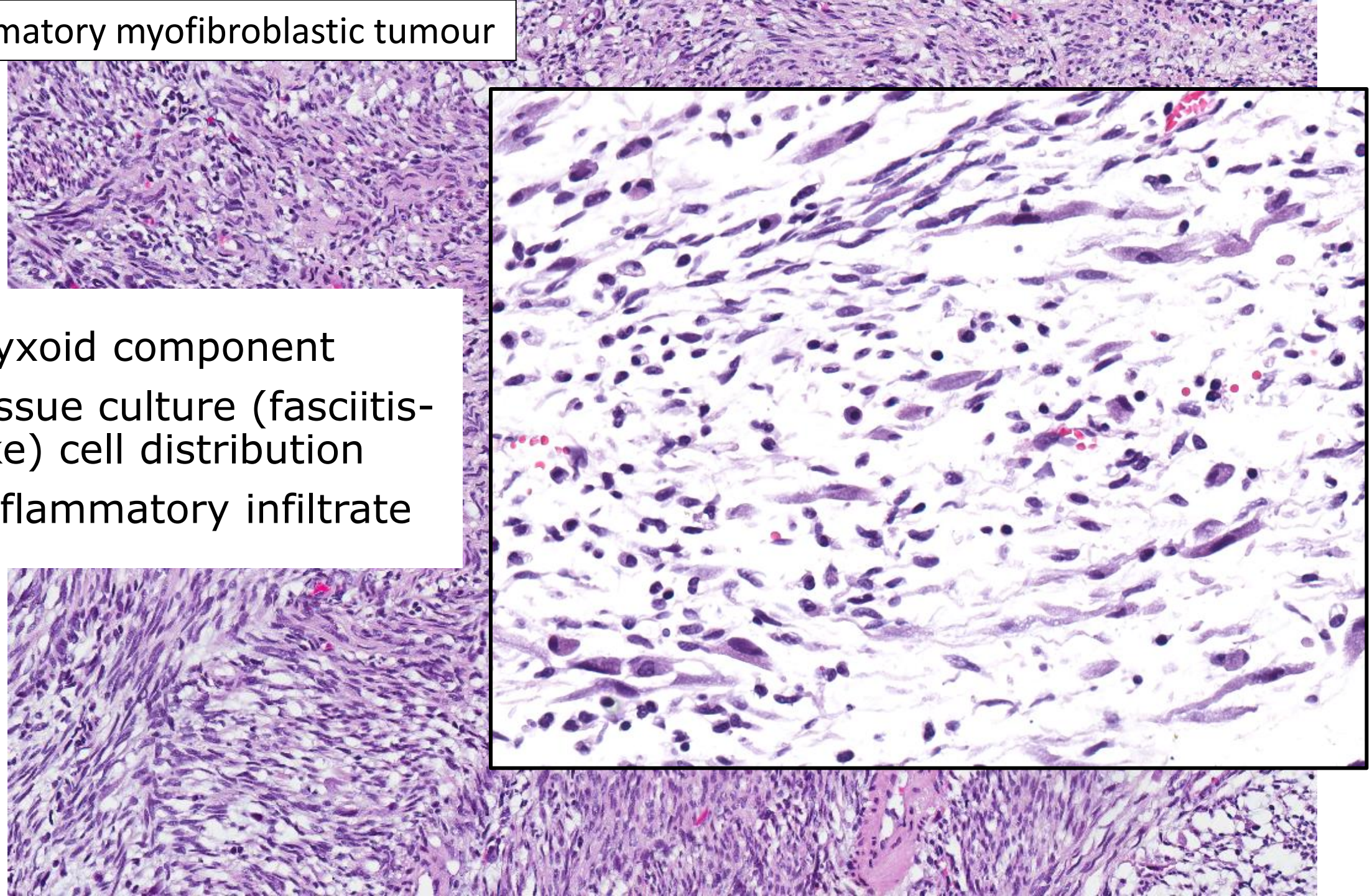

- Myxoid component
- Tissue culture (fasciitis-like) cell distribution
- Inflammatory infiltrate

NTRK-rearranged sarcoma

- Usually cervical
- Variable atypia
- Predominantly monomorphic spindle cell population

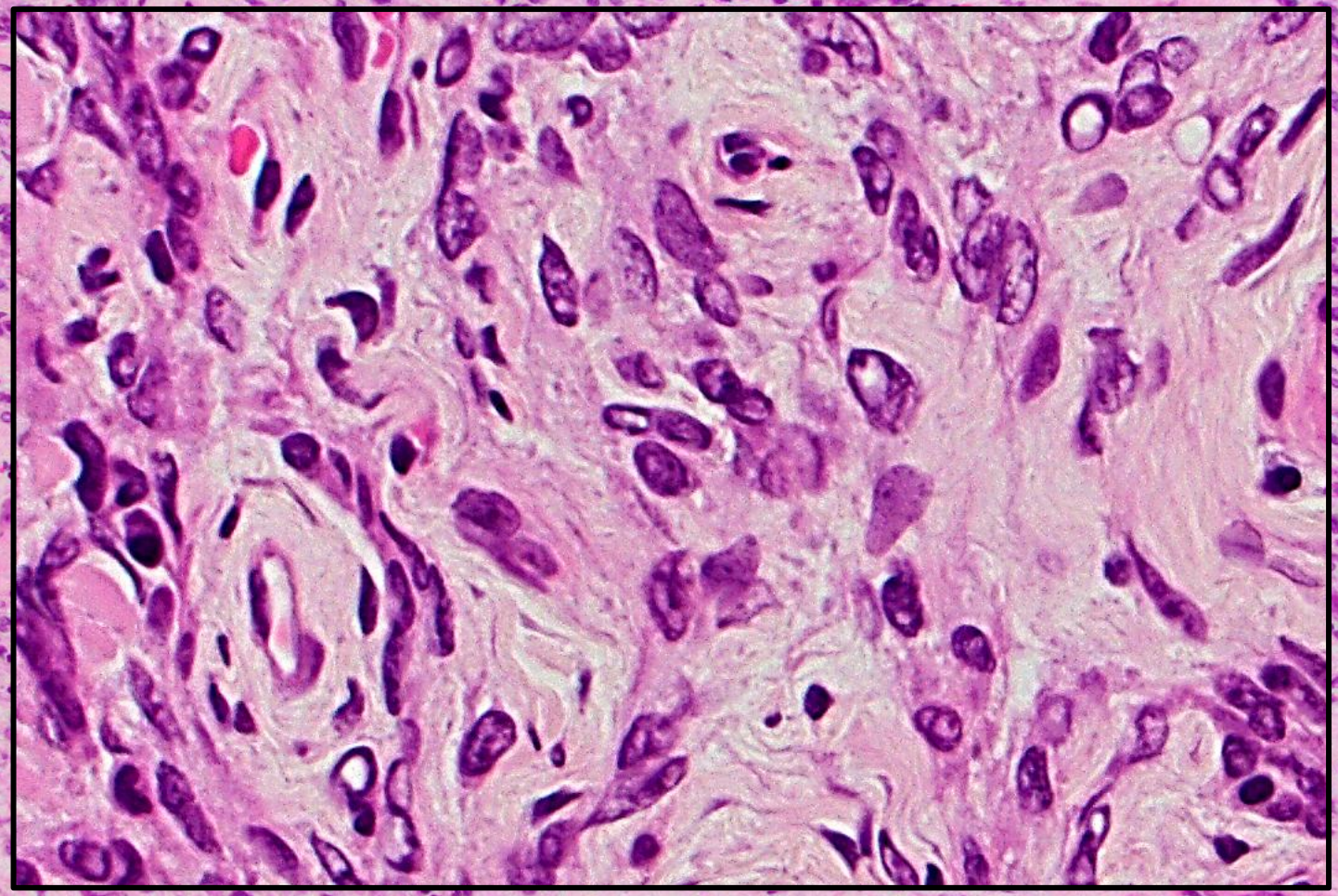

SPINDLE CELL PATTERN – PLEOMORPHIC

* *Usually a sign of malignancy*

- Leiomyosarcoma (conventional)
- Dedifferentiated leiomyosarcoma
- Undifferentiated uterine sarcoma
- Less frequently:
  - Rhabdomyosarcoma
  - Inflammatory myofibroblastic tumour
  - *NTRK*-rearranged sarcoma

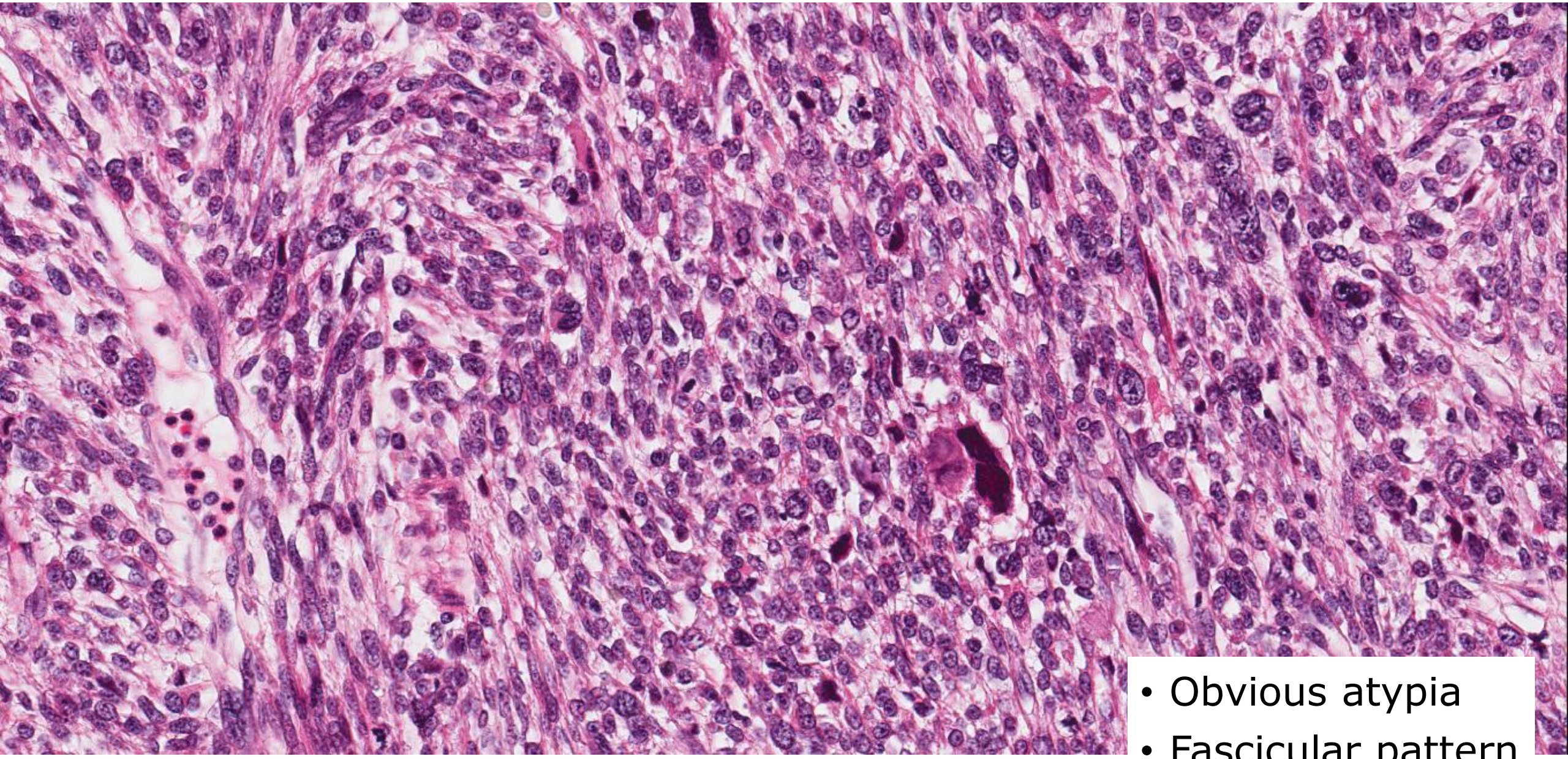

- Obvious atypia
- Fascicular pattern

Leiomyosarcoma

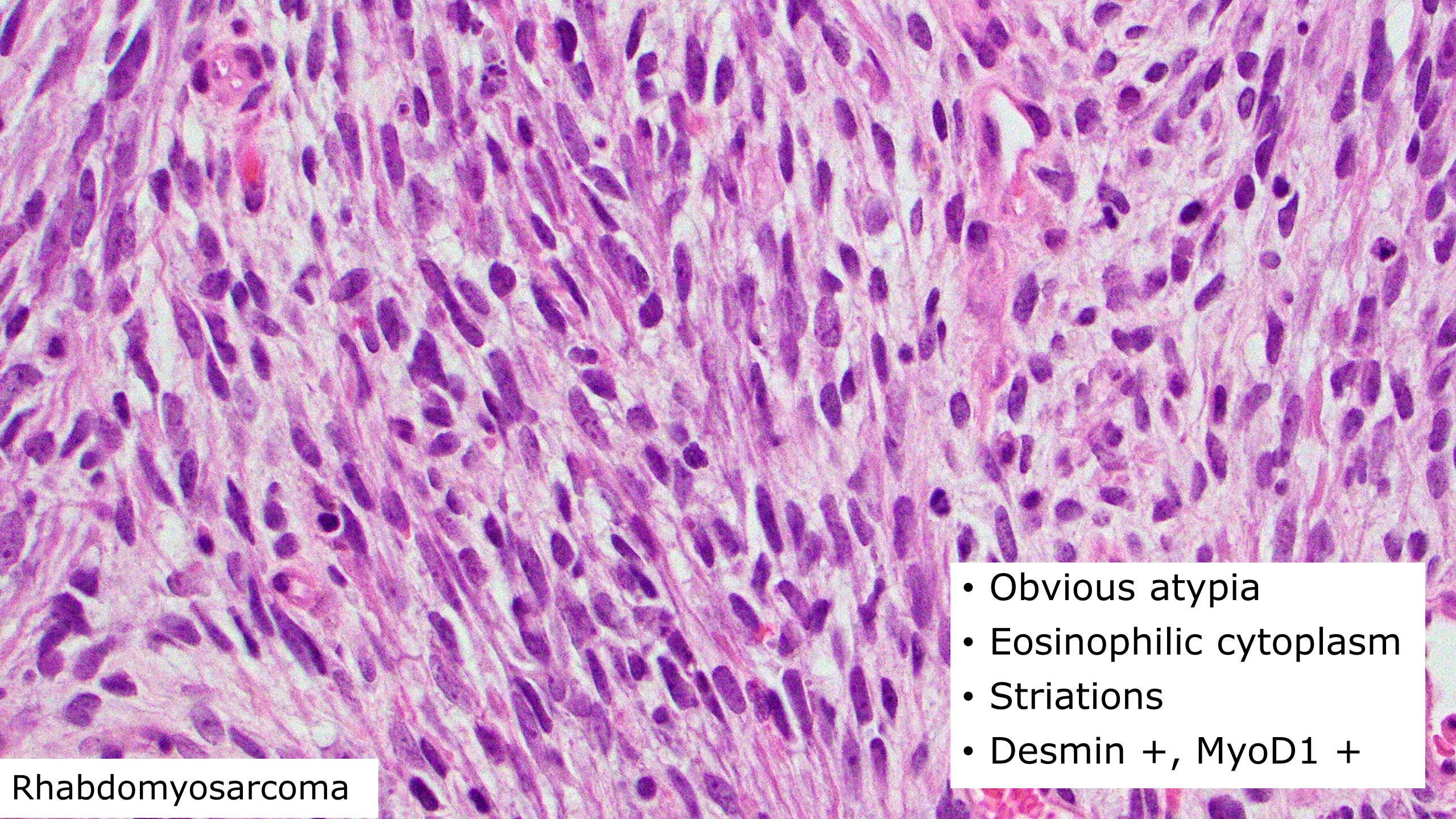

- Obvious atypia
- Eosinophilic cytoplasm
- Striations
- Desmin +, MyoD1 +

Rhabdomyosarcoma

MYXOID TUMOURS

* *Usually with a spindle cell cellular morphology*

- Myxoid (Alcian blue positive) extracellular matrix

- Myxoid leiomyosarcoma
- Endometrial stromal sarcoma
  - Low-grade, fibromyxoid
  - High-grade, with *BCOR* alterations
- Inflammatory myofibroblastic tumour

MYXOID TUMOURS

* *Usually with a spindle cell cellular morphology*

- Myxoid (Alcian blue positive) extracellular matrix

- Myxoid leiomyosarcoma
- **Endometrial stromal sarcoma**
  - **Low-grade, fibromyxoid**
  - **High-grade, with *BCOR* alterations**
- **Inflammatory myofibroblastic tumour**

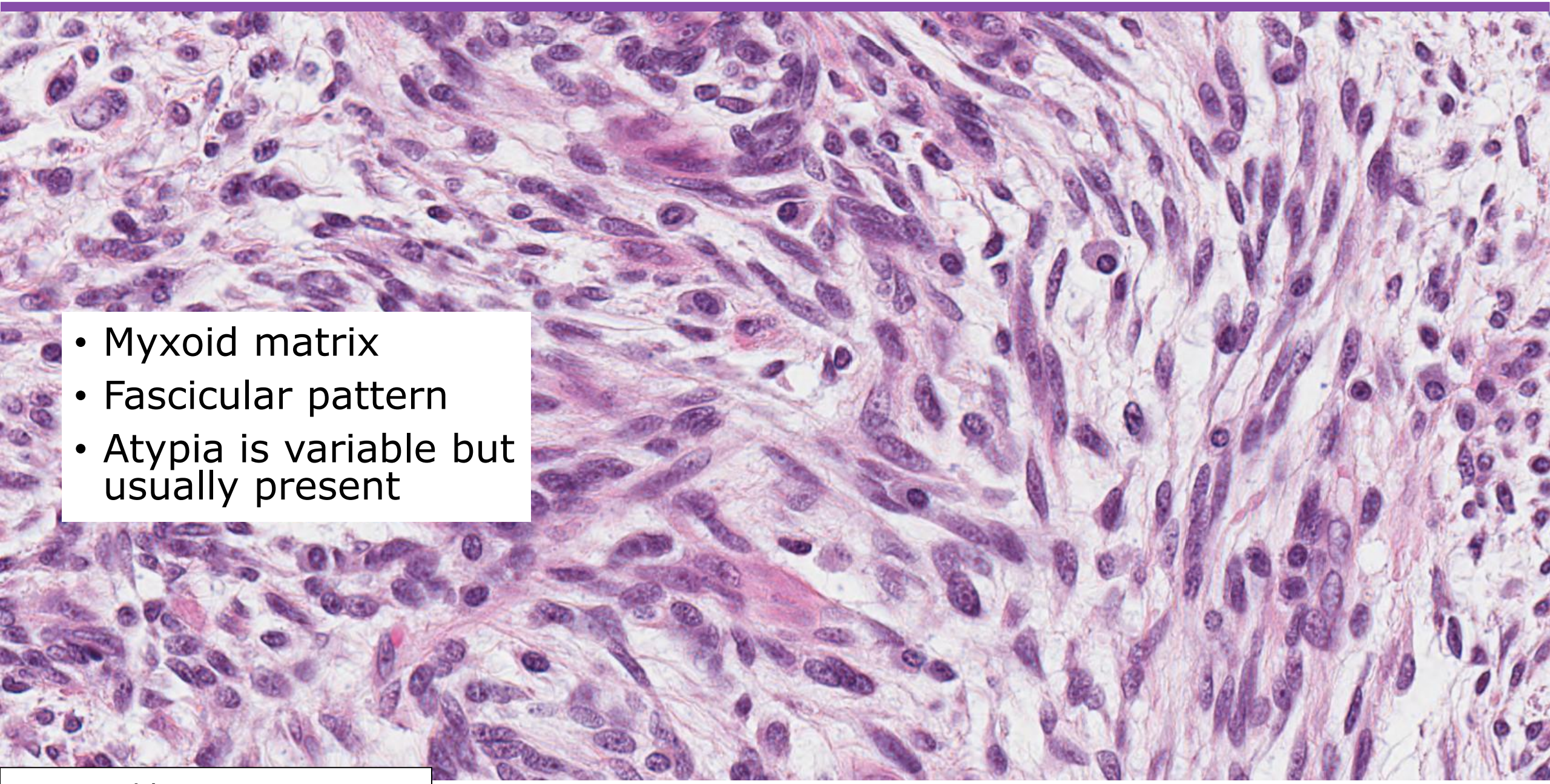

Myxoid leiomyosarcoma

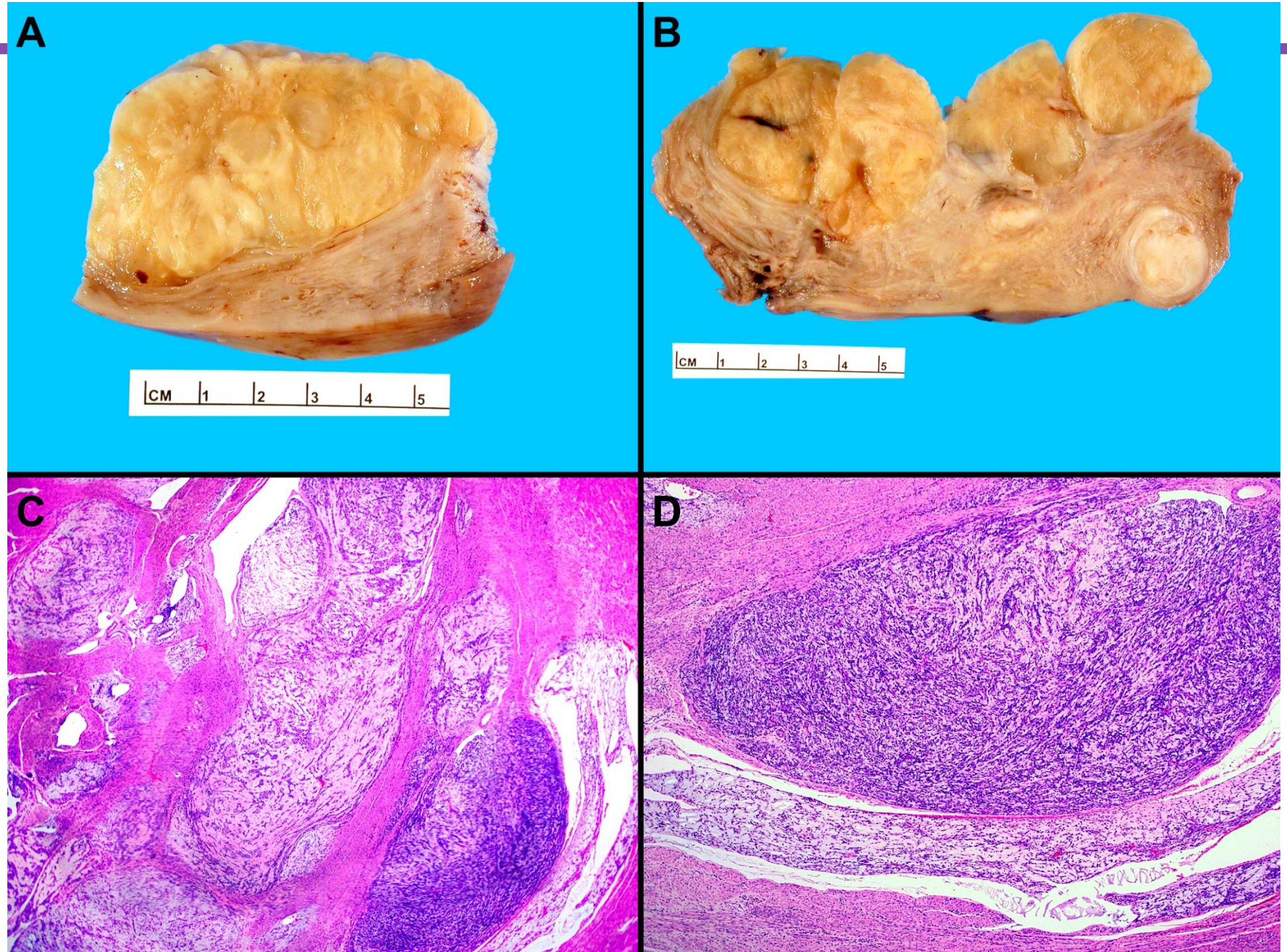
A
CM 1 2 3 4 5
B
CM 1 2 3 4 5
C
D

LG ESS fibromyxoid

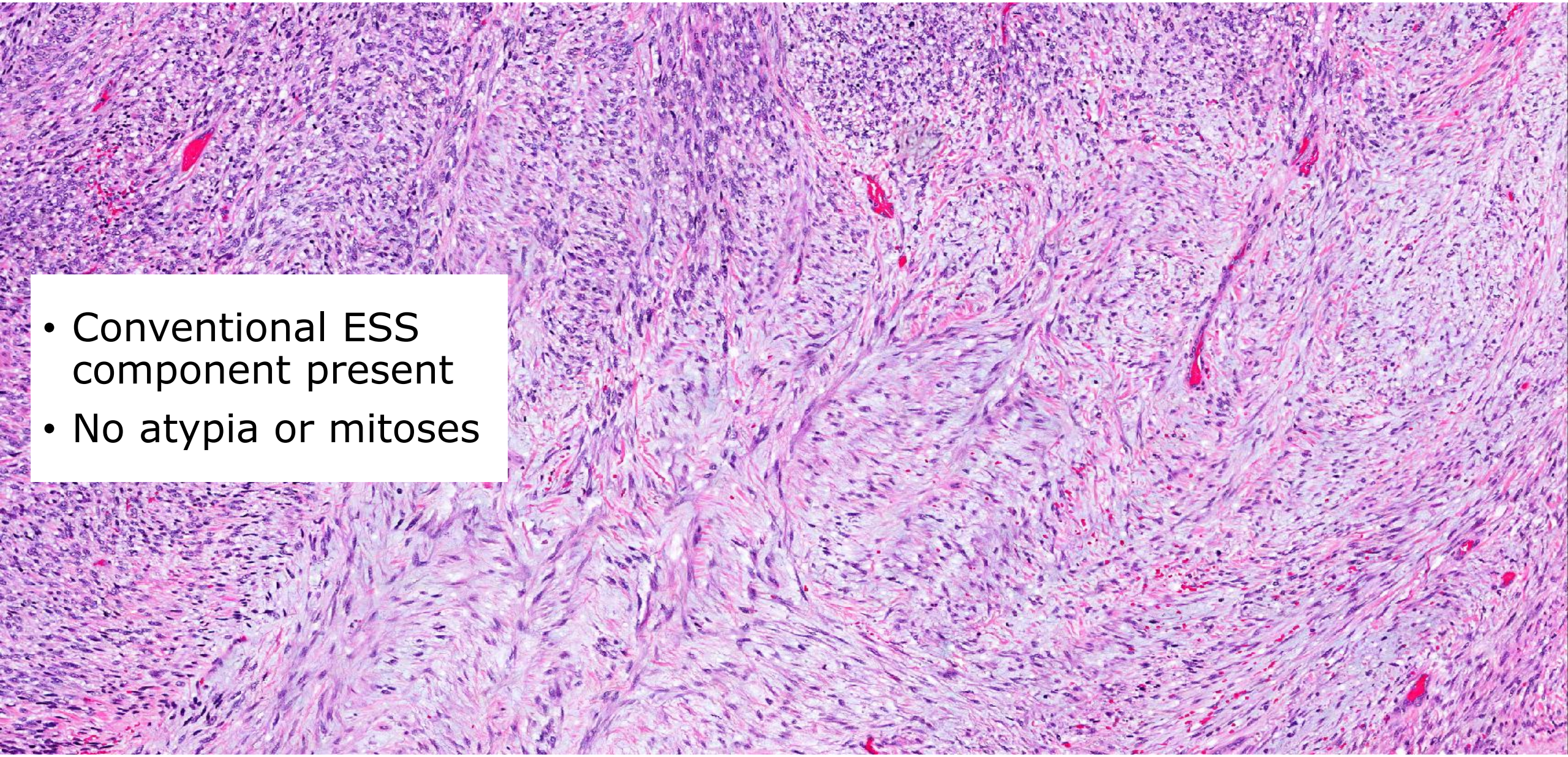

BCOR uterine sarcoma

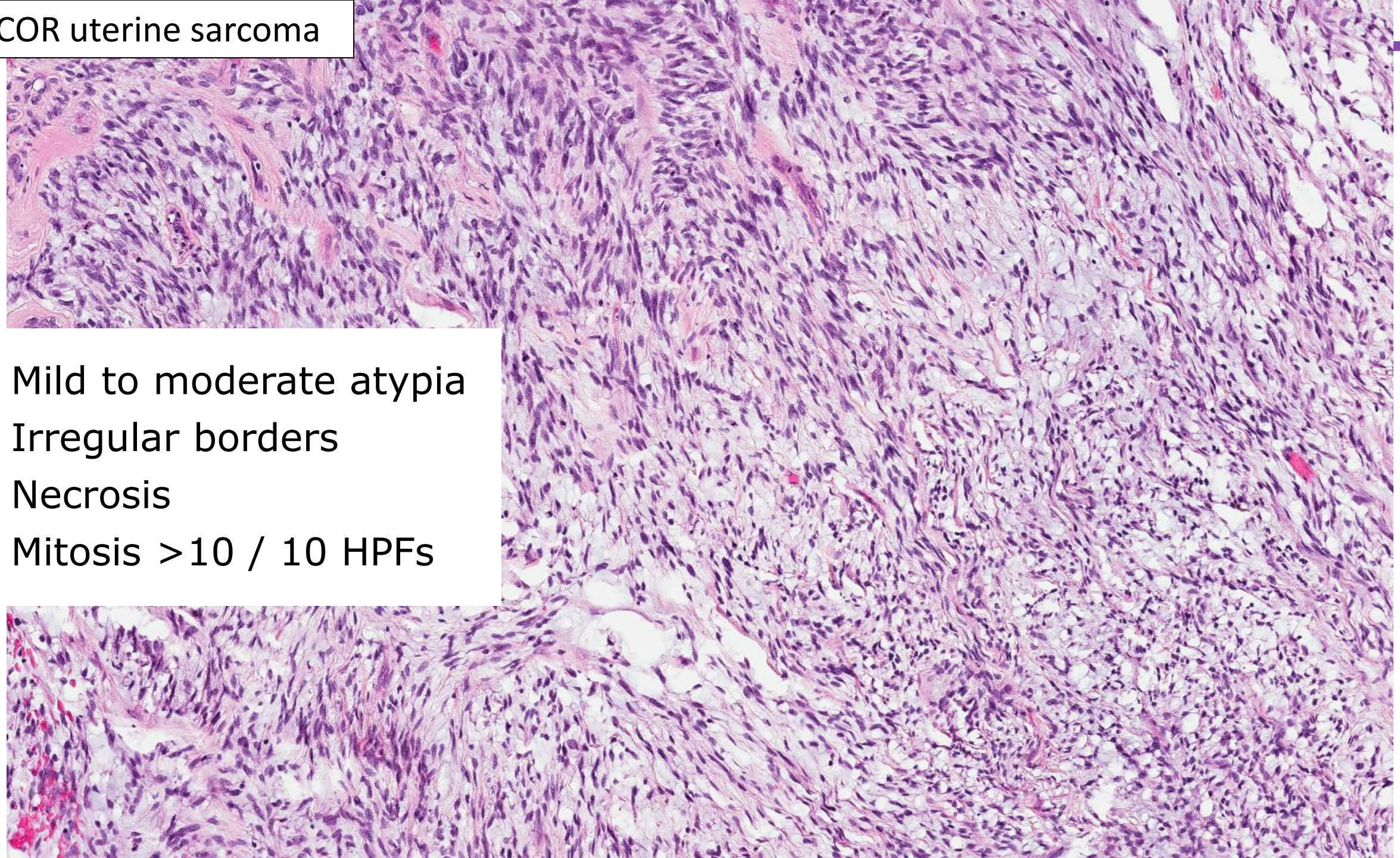

- Mild to moderate atypia
- Irregular borders
- Necrosis
- Mitosis >10 / 10 HPFs

BCOR uterine sarcoma

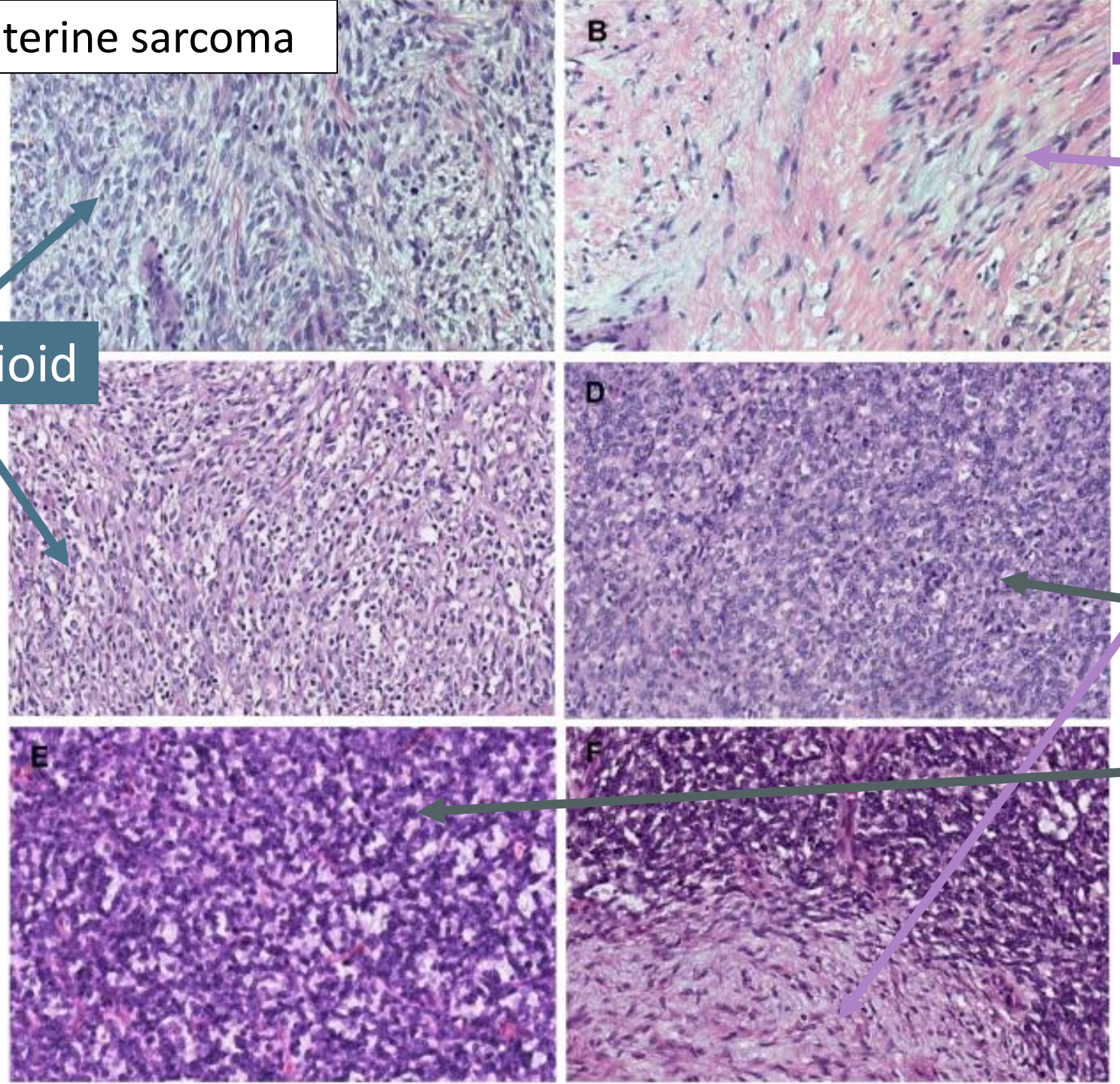

Epithelioid

Fibromyxoid

Round cell

Gynecol Oncol 2020;157:357-366
Cortesía del Dr. D Lin (Foundation Medicine, Cambridge MA)

Inflammatory myofibroblastic tumour

- Myxoid component
- Tissue culture (fasciitis-like) cell distribution
- Inflammatory infiltrate

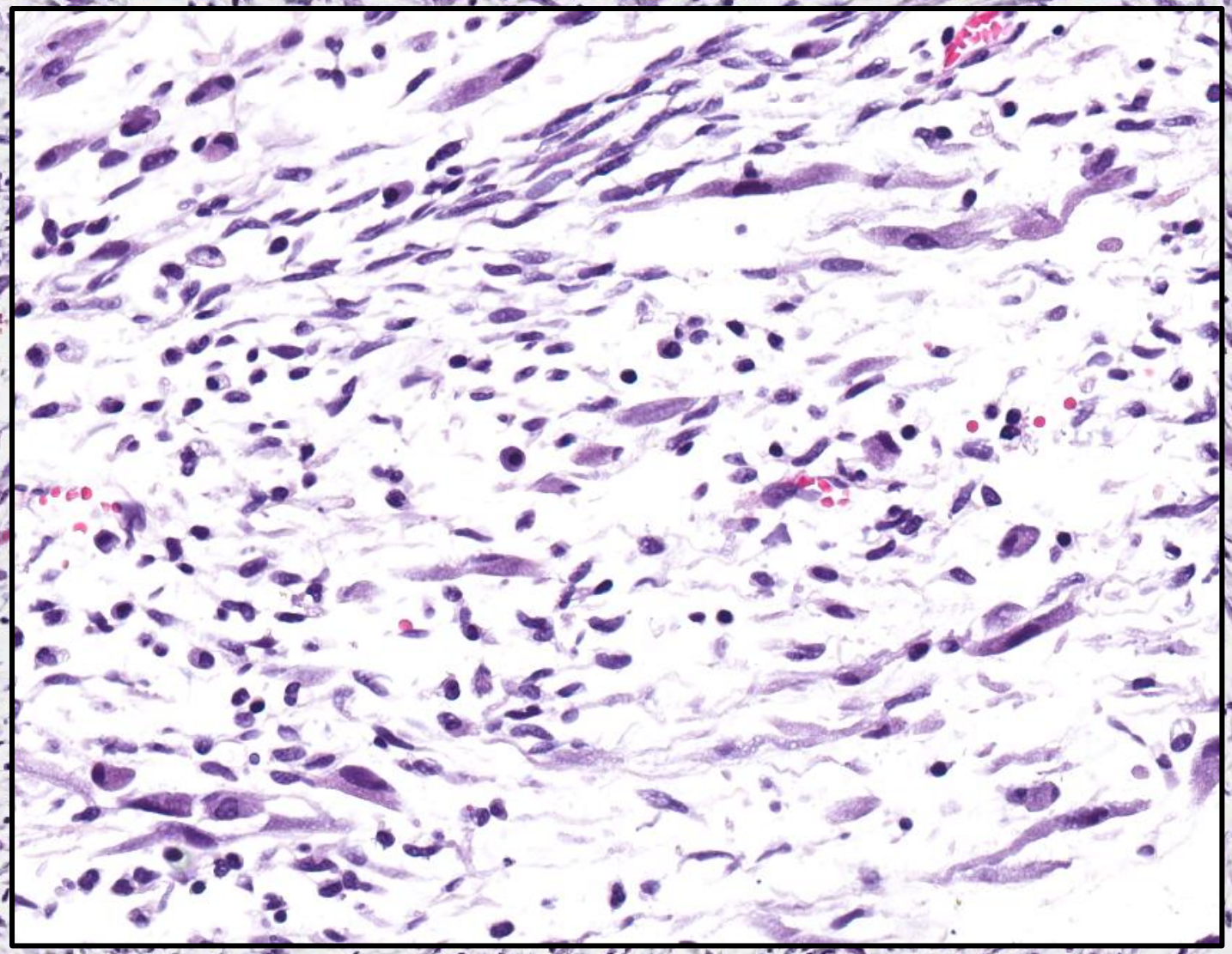

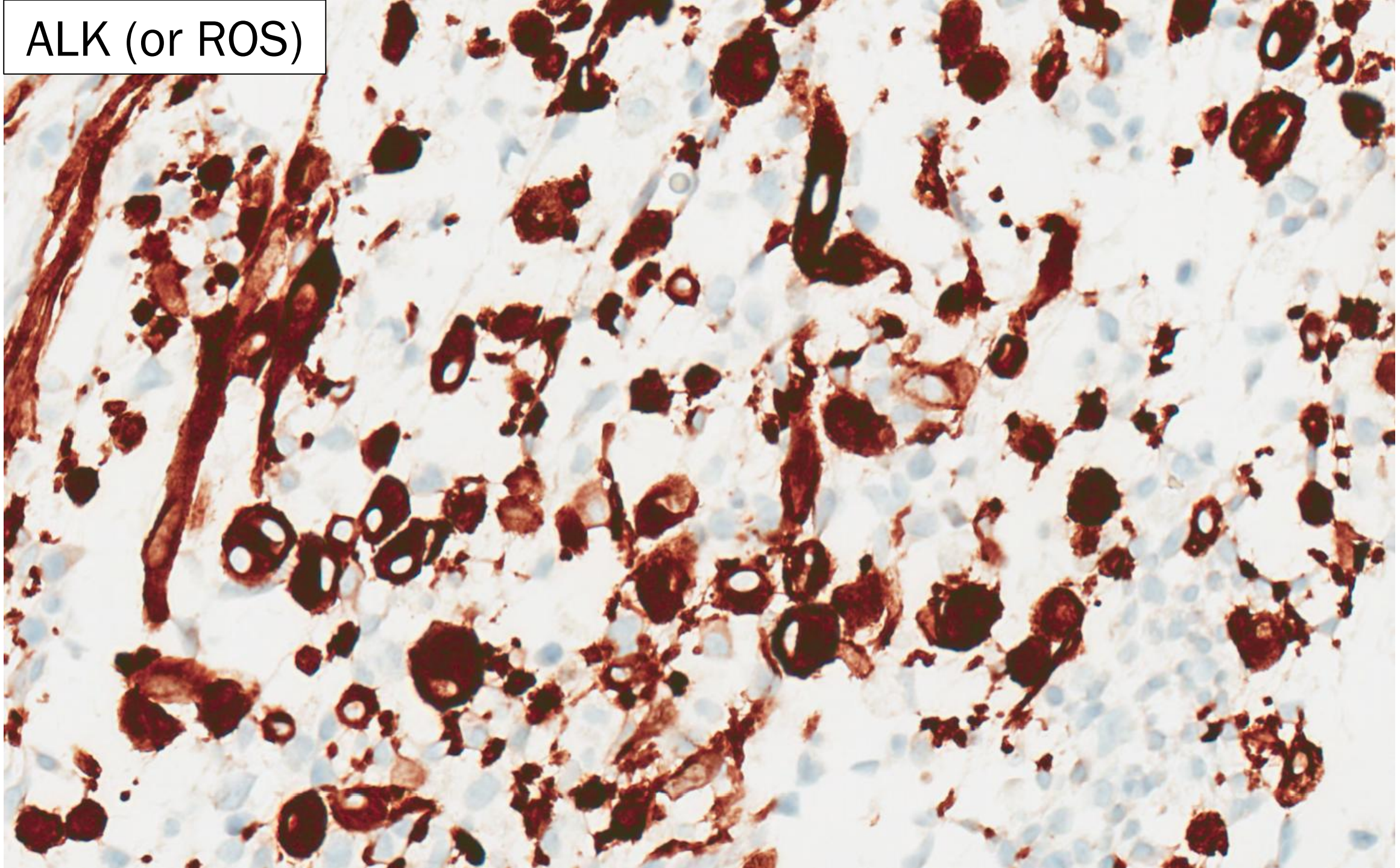
ALK (or ROS)

EPITHELIOID TUMOURS

* *Usually admixed with spindle cell components*

- Cells with round shape, noticeable eosinophilic cytoplasm, and round to ovoid nuclei

- Epithelioid leiomyosarcoma
- Undifferentiated uterine sarcoma
- Perivascular epithelioid tumour (PEComa)
- Uterine tumour resembling ovarian sex cord stromal tumour (UTROSCT)

EPITHELIOID TUMOURS

* *Usually admixed with spindle cell components*

- Cells with round shape, noticeable eosinophilic cytoplasm, and round to ovoid nuclei

- Epithelioid leiomyosarcoma
- **Undifferentiated uterine sarcoma**
- **Perivascular epithelioid tumour (PEComa)**
- **Uterine tumour resembling ovarian sex cord stromal tumour (UTROSCT)**

Epithelioid leiomyosarcoma

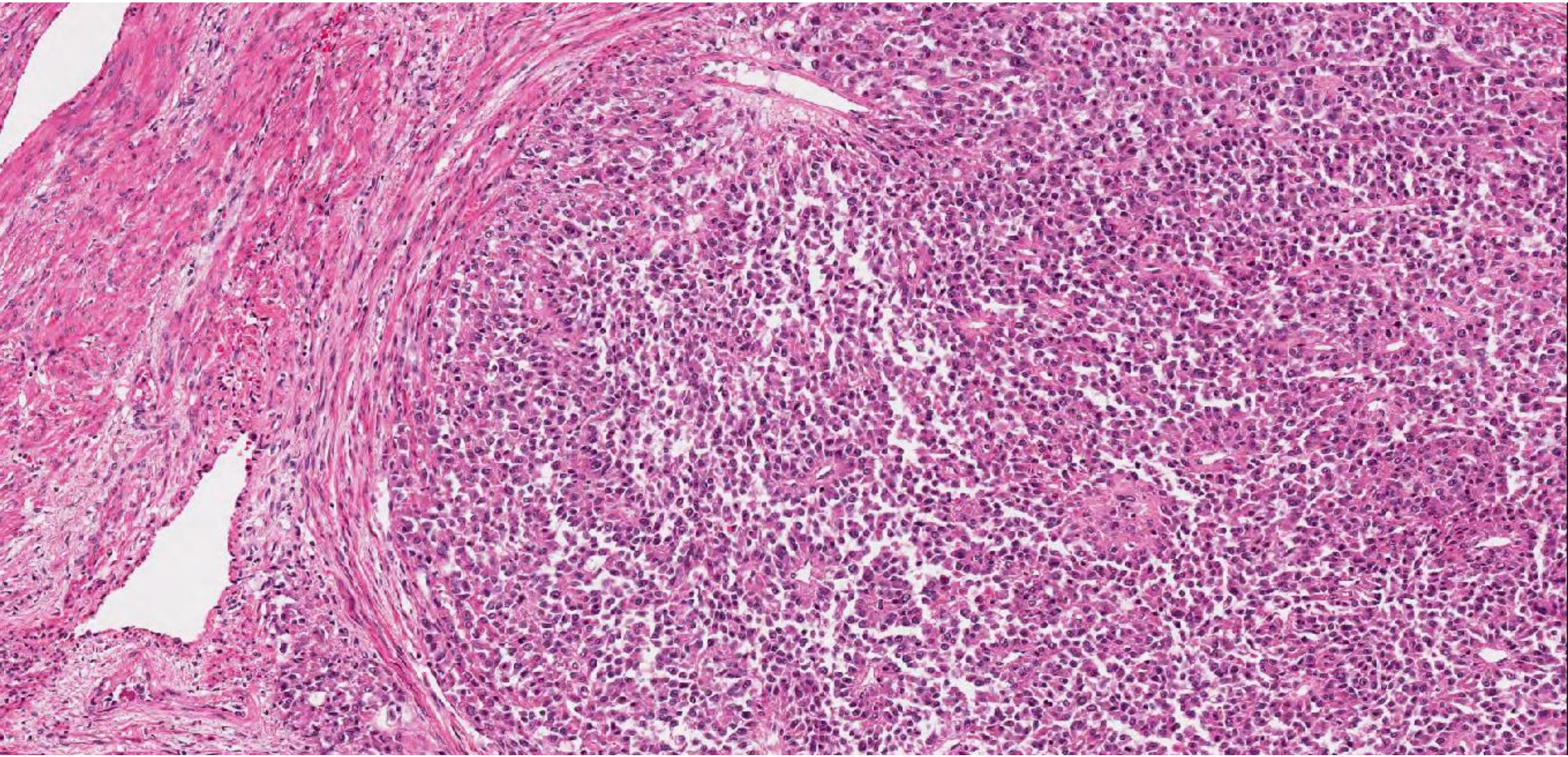

Epithelioid leiomyosarcoma

- Often with a fascicular component
- Usually markedly atypical

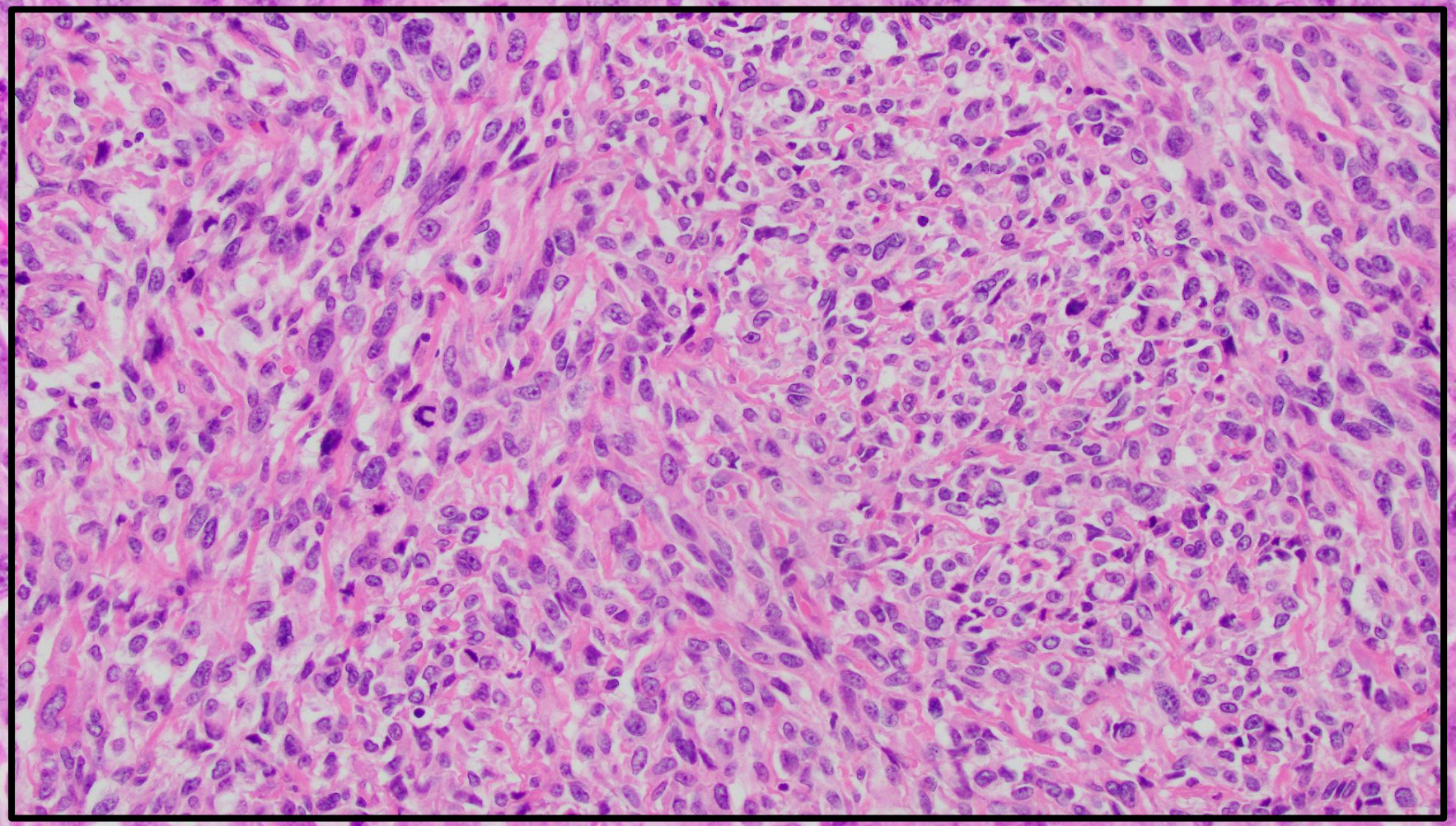

PEComa

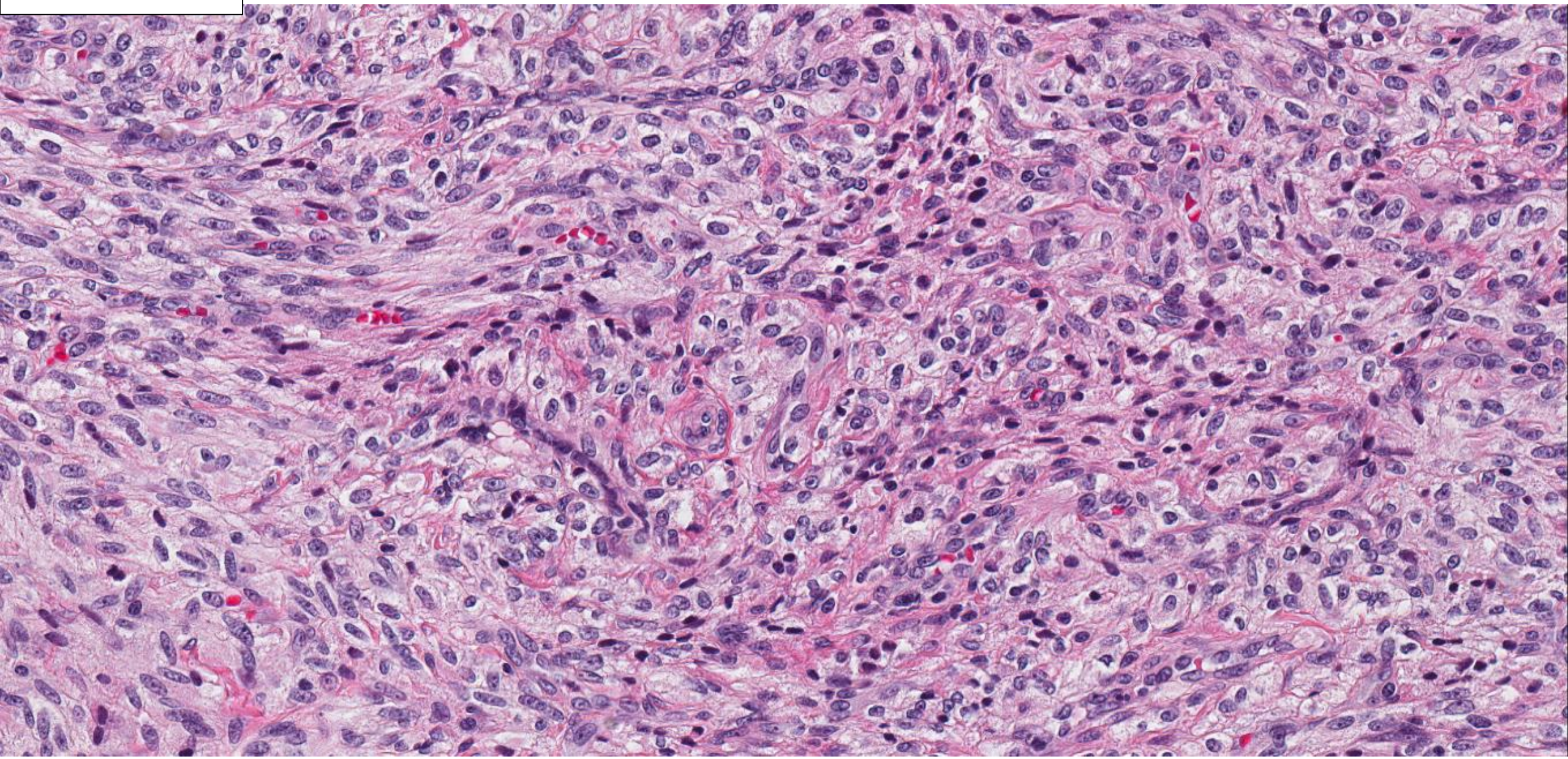

PEComa

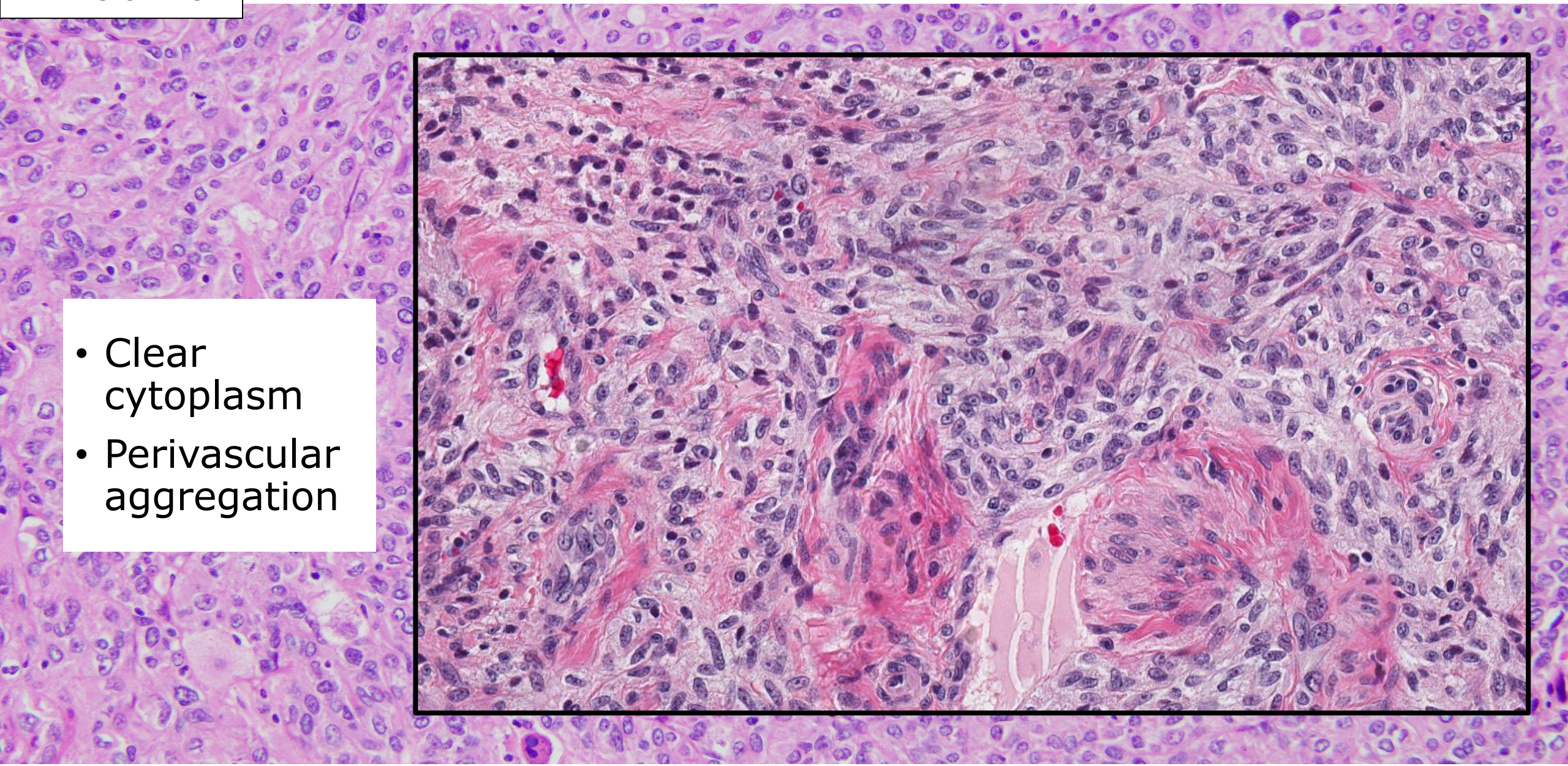

- Clear cytoplasm
- Perivascular aggregation

PECOMA - INMUNOHISTOCHEMISTRY

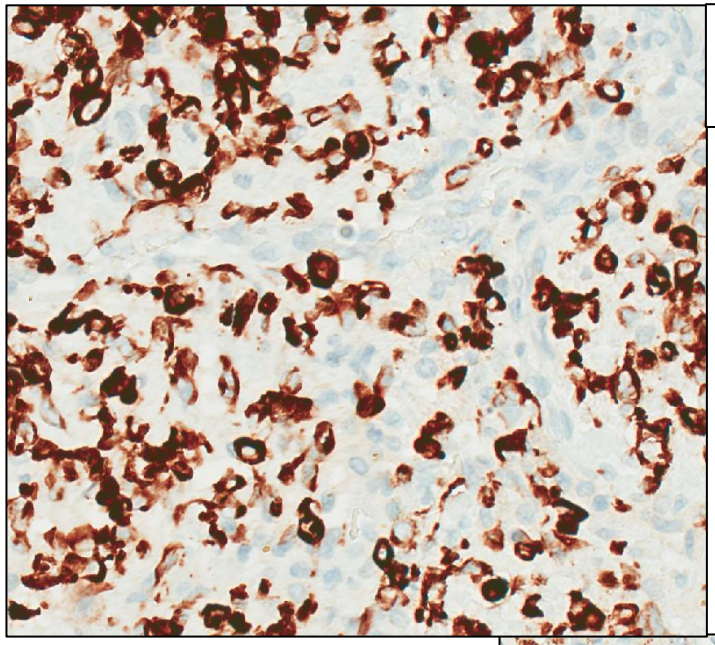

Desmin

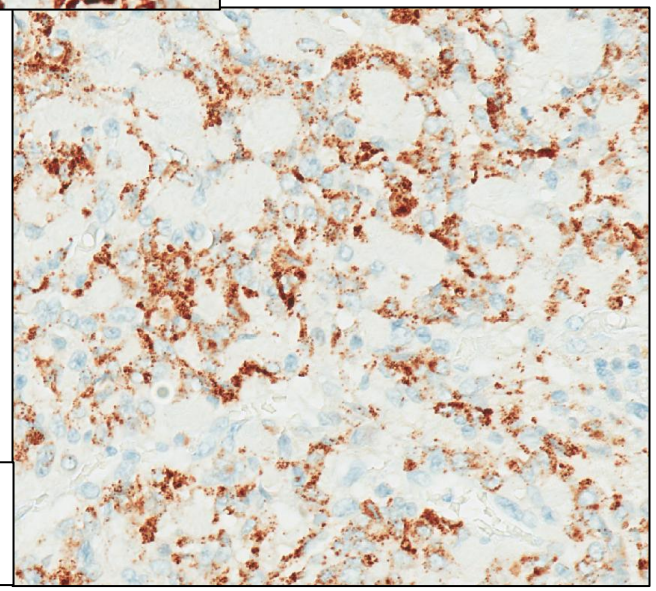

HMB45

Table 2 Expression of myoid and melanocytic immunohistochemical markers in uterine corpus PEComas

Immunohistochemistry result			Extent of positivity		
IHC	n	Positive (%)	n	<50% of cells (%)	≥50% of cells (%)
HMB-45	72	71/72 (99)	57	31/57 (54)	26/57 (46)
Melan-A	46	21/46 (46)	20	13/20 (65)	7/20 (35)
MiTF	21	14/21 (66)	12	5/12 (42)	7/12 (58)
S100	48	5/48 (10)			
Tyrosinase	3	0/3 (0)			
SMA	68	53/68 (80)	39	16/39 (41)	23/39 (59)
Desmin	62	39/62 (63)	18	7/18(39)	11/18 (61)
Caldesmon	22	17/22 (77)	5	3/5 (60)	2/5 (40)
Cathepsin	12	12/12 (100)			
Myosin/MSA	4	2/4 (50)			

IHC, immunohistochemical; MiTF, microphthalmia-associated transcription factor; PEComas, perivascular epithelioid tumours.

J Clin Pathol 2015;68:418–426

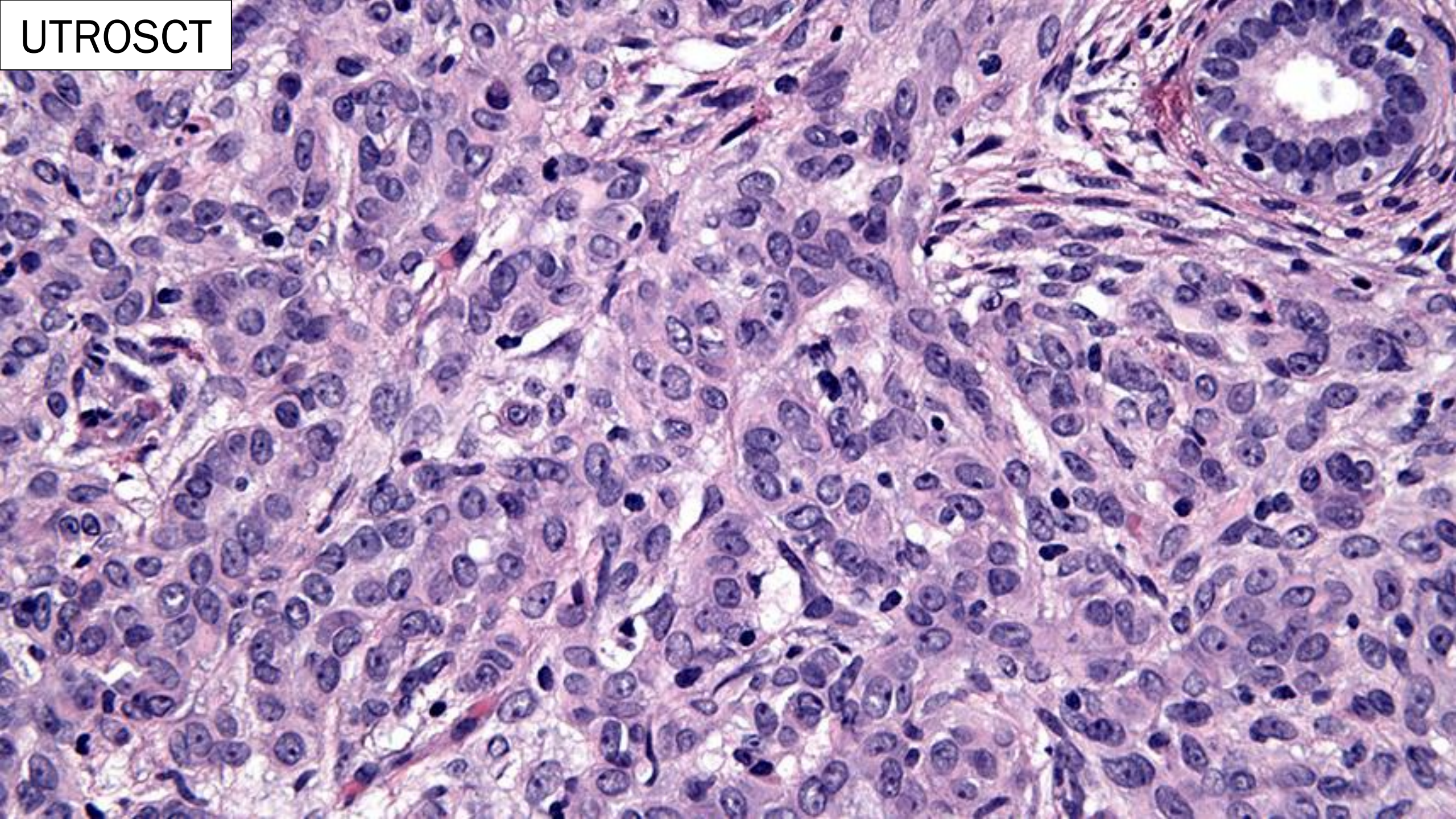
UTROSCT

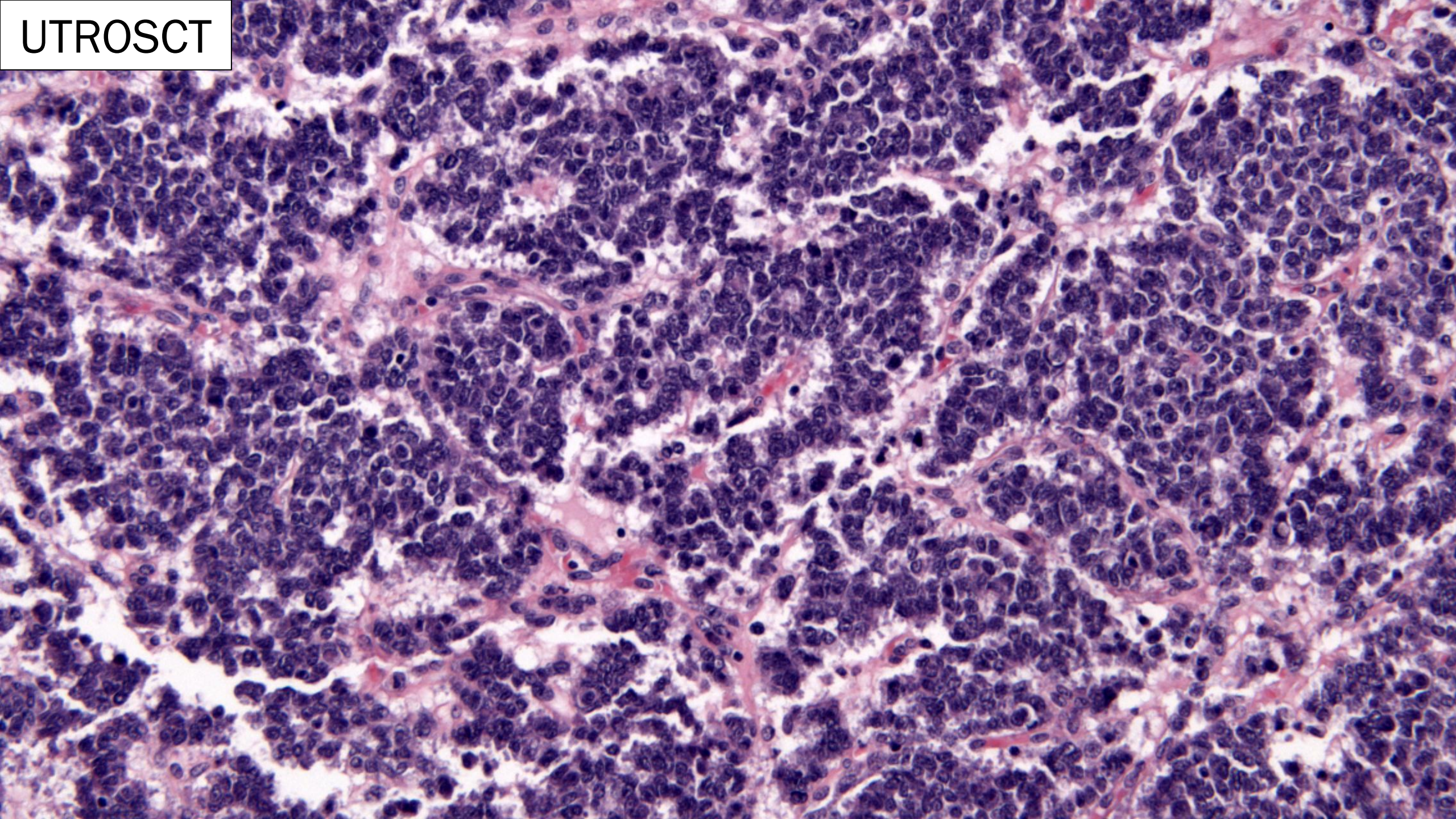
UTROSCT

UTROSCT & *GREB* sarcomas

- Poliphenotypic appearance
- Epithelioid
- Spindle cell
- Cord-like / trabecular

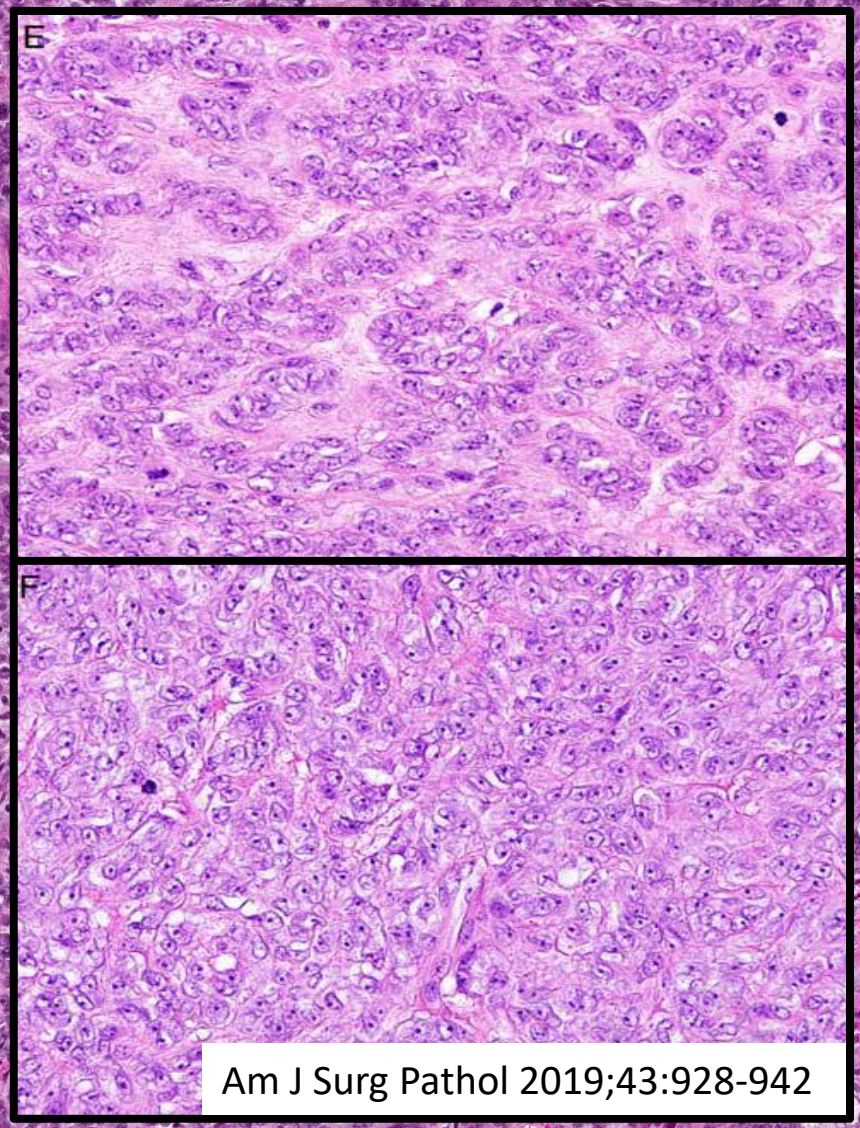

Am J Surg Pathol 2019;43:928-942

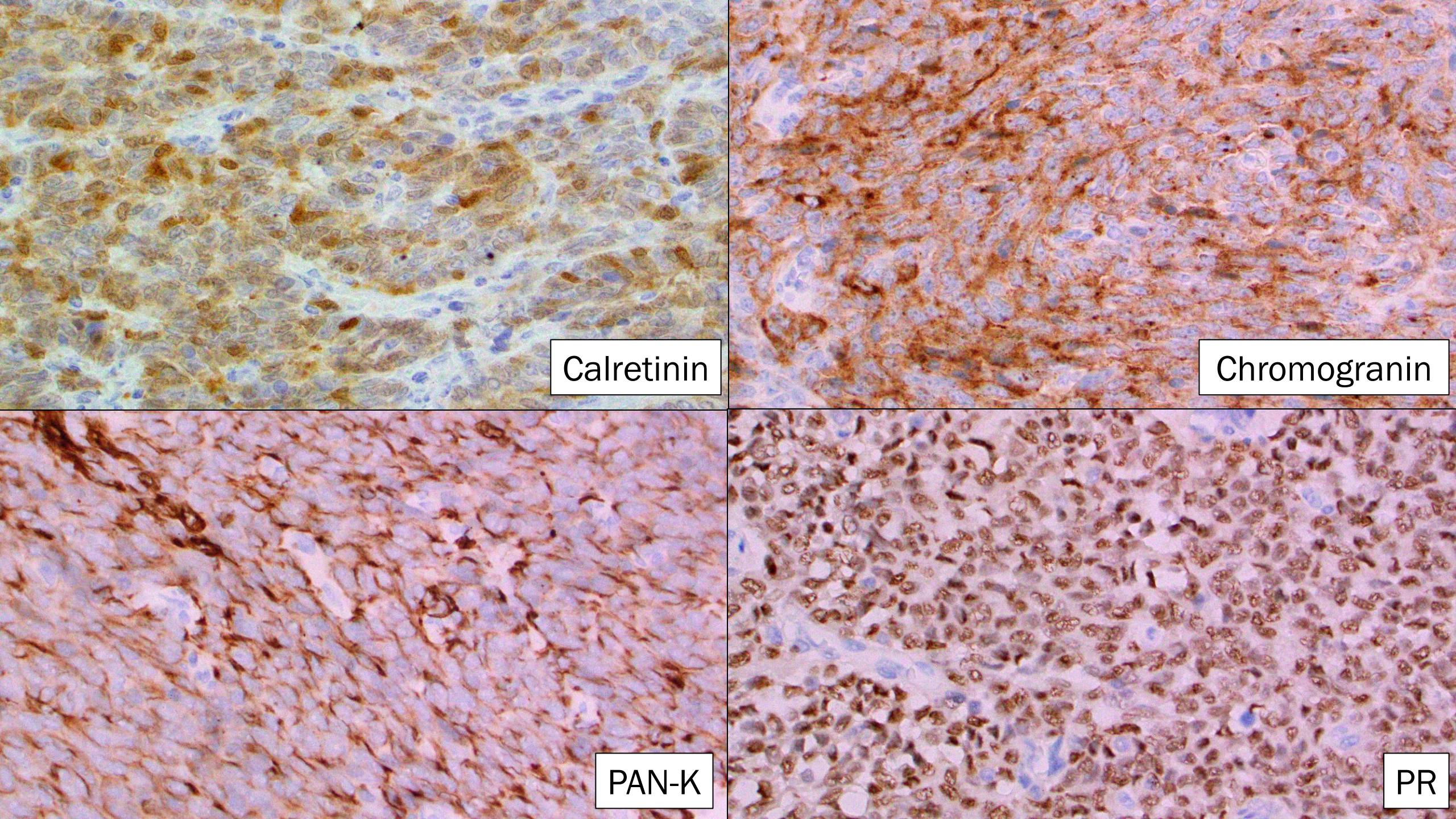
Calretinin
Chromogranin
PAN-K
PR

UNDIFFERENTIATED / ROUND CELL PATTERN

- Large atypical cells, relatively uniform, with scant cytoplasm and round nuclear shape

- Dedifferentiated leiomyosarcoma
- Undifferentiated uterine sarcoma
- Endometrial stromal sarcoma
  - High-grade with *YWHAE::NUTM2A/B* fusions
  - High-grade with *BCOR* alterations
- Rhabdomyosarcoma

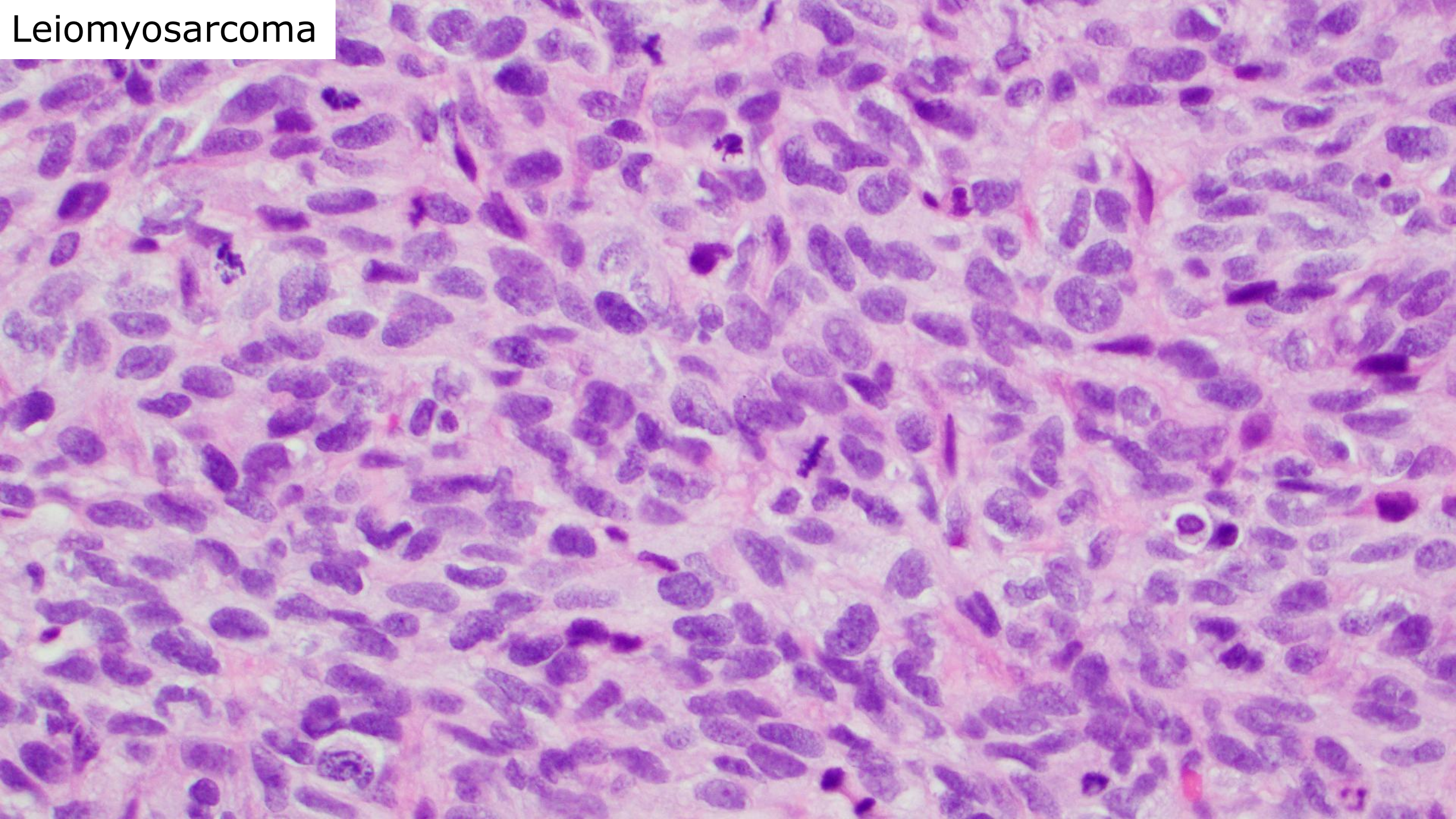
Leiomyosarcoma

Undifferentiated uterine sarcoma

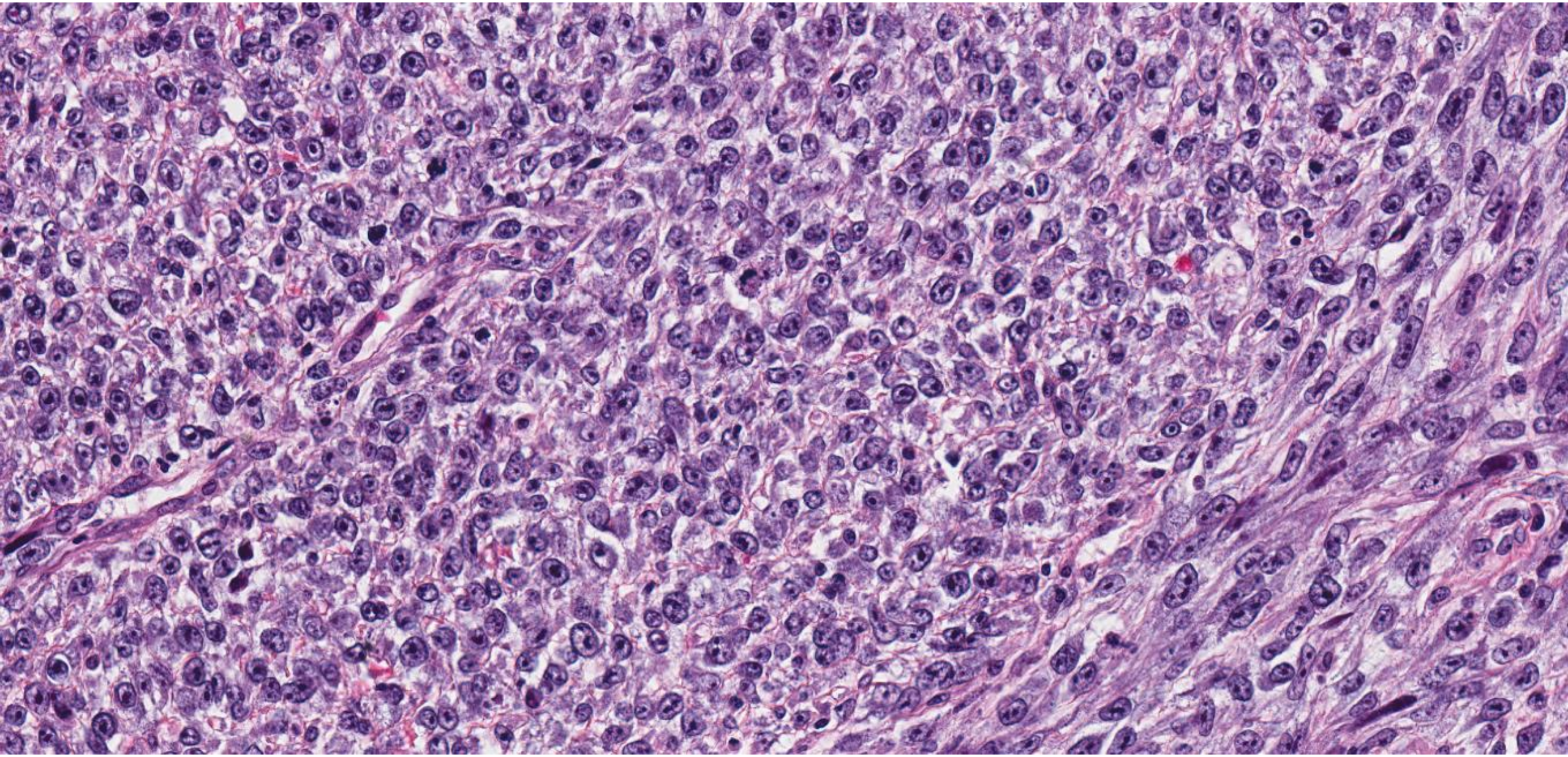

High-grade ESS with YWHAE::NUTM2A/B fusions

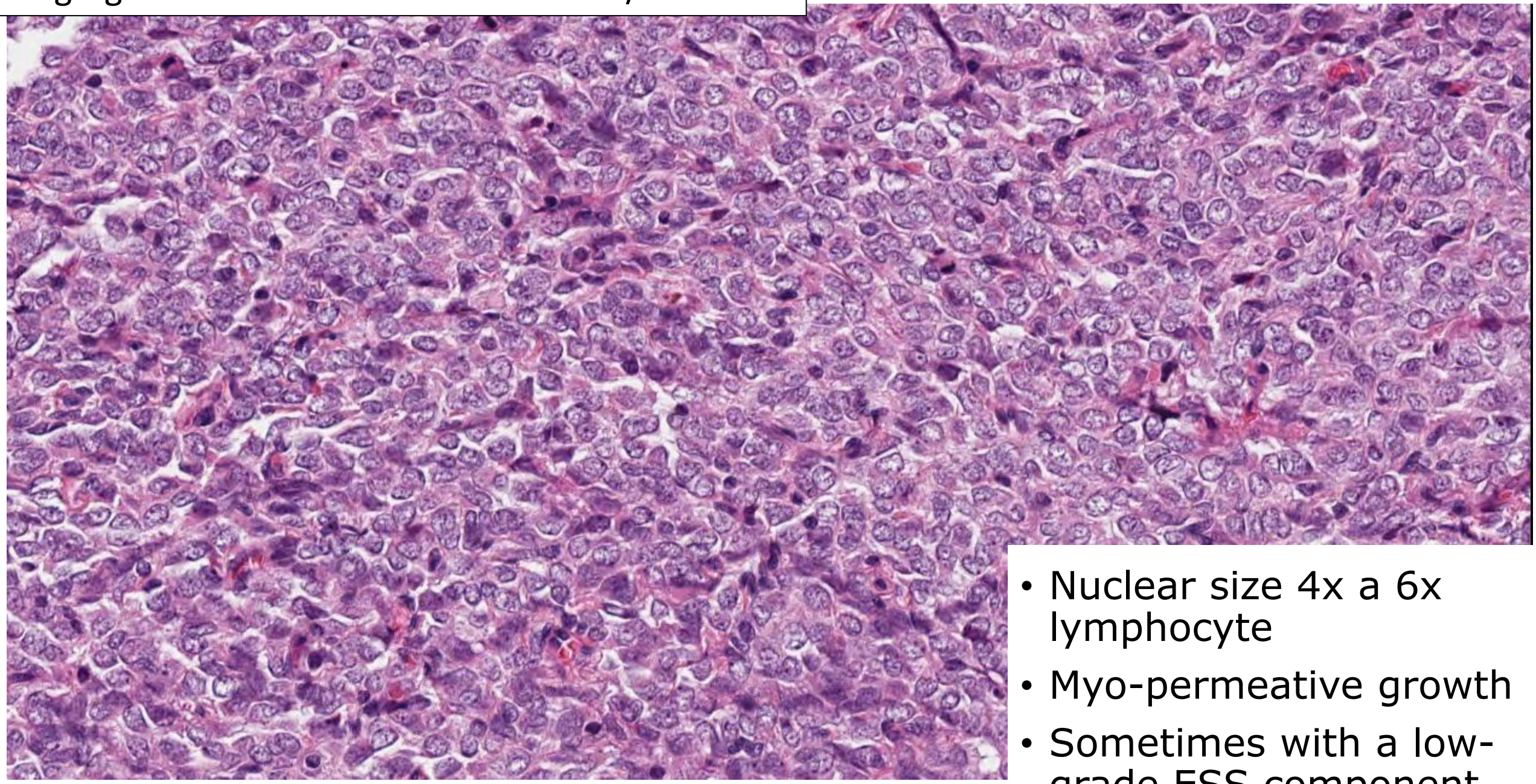

- Nuclear size 4x a 6x lymphocyte
- Myo-permeative growth
- Sometimes with a low-grade ESS component

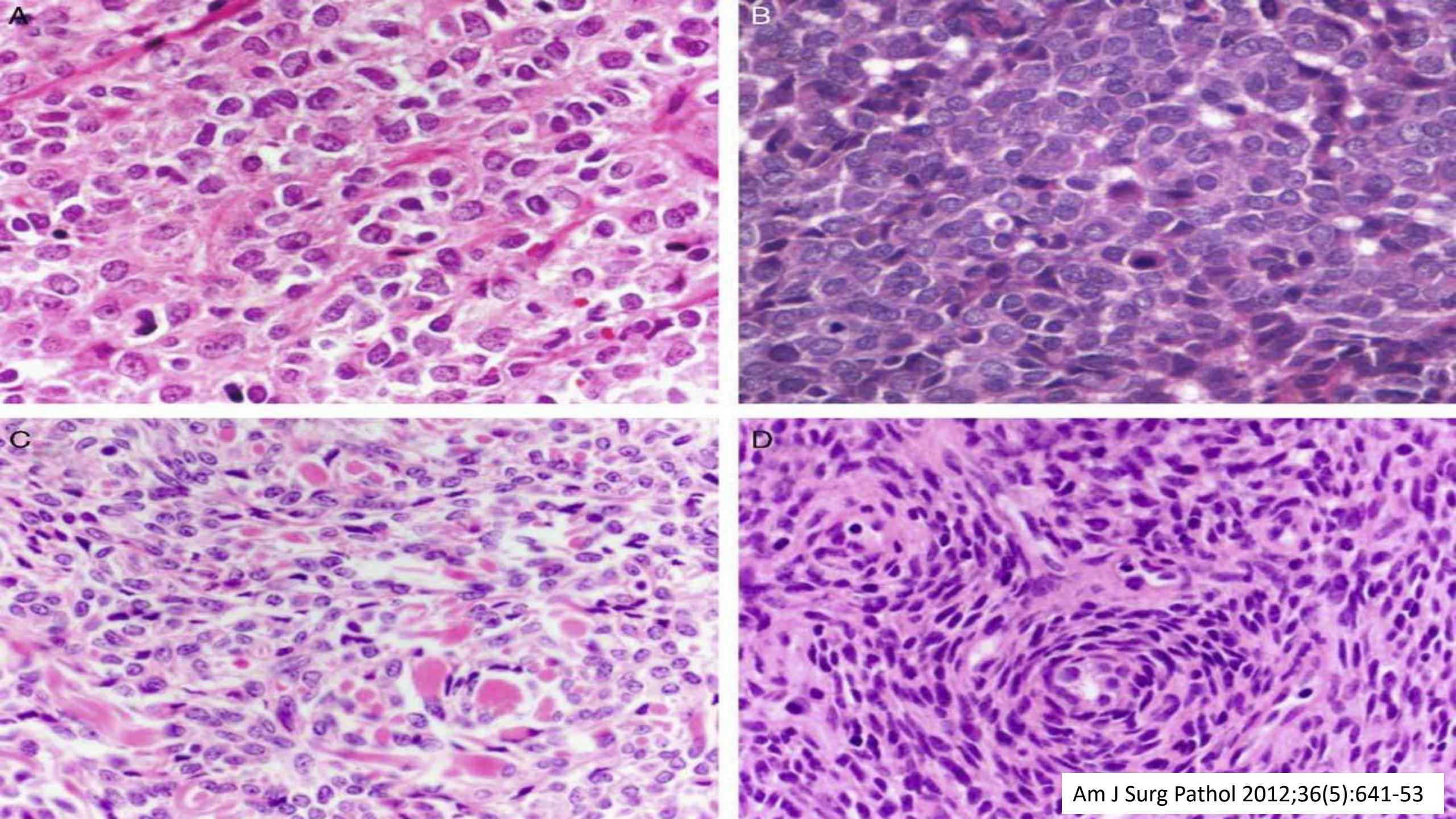

Am J Surg Pathol 2012;36(5):641-53

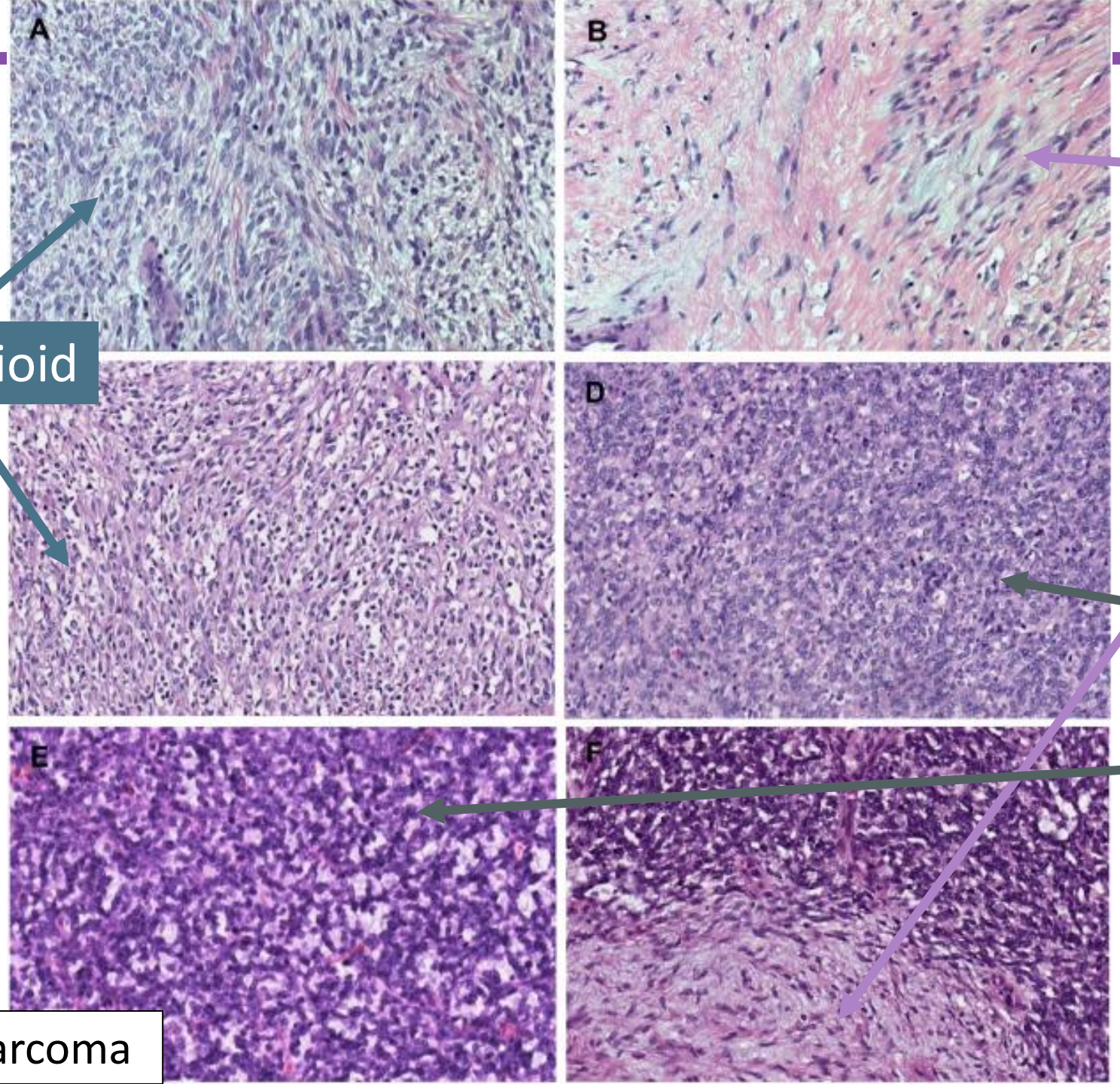

Epithelioid

Fibromyxoid

Round cell

BCOR sarcoma

Gynecol Oncol 2020;157:357-366
Cortesía del Dr. D Lin (Foundation Medicine, Cambridge MA)

IMMUNOHISTOCHEMISTRY

MARKER	LG-ESS	HG-ESS *YWHAE-NUTM2*	HG-ESS *BCOR*
ER / PR	+++ (>90%)	- / débil	+ (30%)
CD10	+++ (< in smooth muscle areas)	- (+ in <5%)	+++ (100%)
IFITM1	+++ (>90%)	++ (60%)	?
Desmin, SMA, H-caldesmon	+/- (++ in smooth muscle areas)	+/- (++ in smooth muscle areas)	+/- (focal)
Cyclin D1	+	+++ (>70%)	+++ (80%)
BCOR	- / weak (<5%)	+++ (>95%)	++(70%)
C-KIT	-/+	+++	?
Ki67 index	<5%	>5%	>5%

Mod Pathol 2017;30:1251-61
Mod Pathol 2018;31:674-684
Am J Surg Pathol 2002 26(4):403-12
Mod Pathol 2014;27(4):569-79
Histopathol 2001 39(3):273-8
Mod Pathol 2001 14(5):465-71

Very often, a precise diagnosis is not possible



OUTLINE

- Differential diagnosis based on morphology
- **Initial categorization (benign vs malignant)**
- **Reporting suggestions**

BENIGN OR MALIGNANT?

- Start by assessing features attributed to malignant behaviour
  - 2+/3+ nuclear atypia, multifocal or diffuse
  - Coagulative (geographic) necrosis
  - High mitotic count (>10 mitosis / 10 CAAs)
  - If present, irregular or frankly infiltrative borders
- Situations in which criteria change
  - Myxoid tumours (mLMS, *BCOR* sarcoma)
  - Epithelioid tumours (eLMS, PEComa)

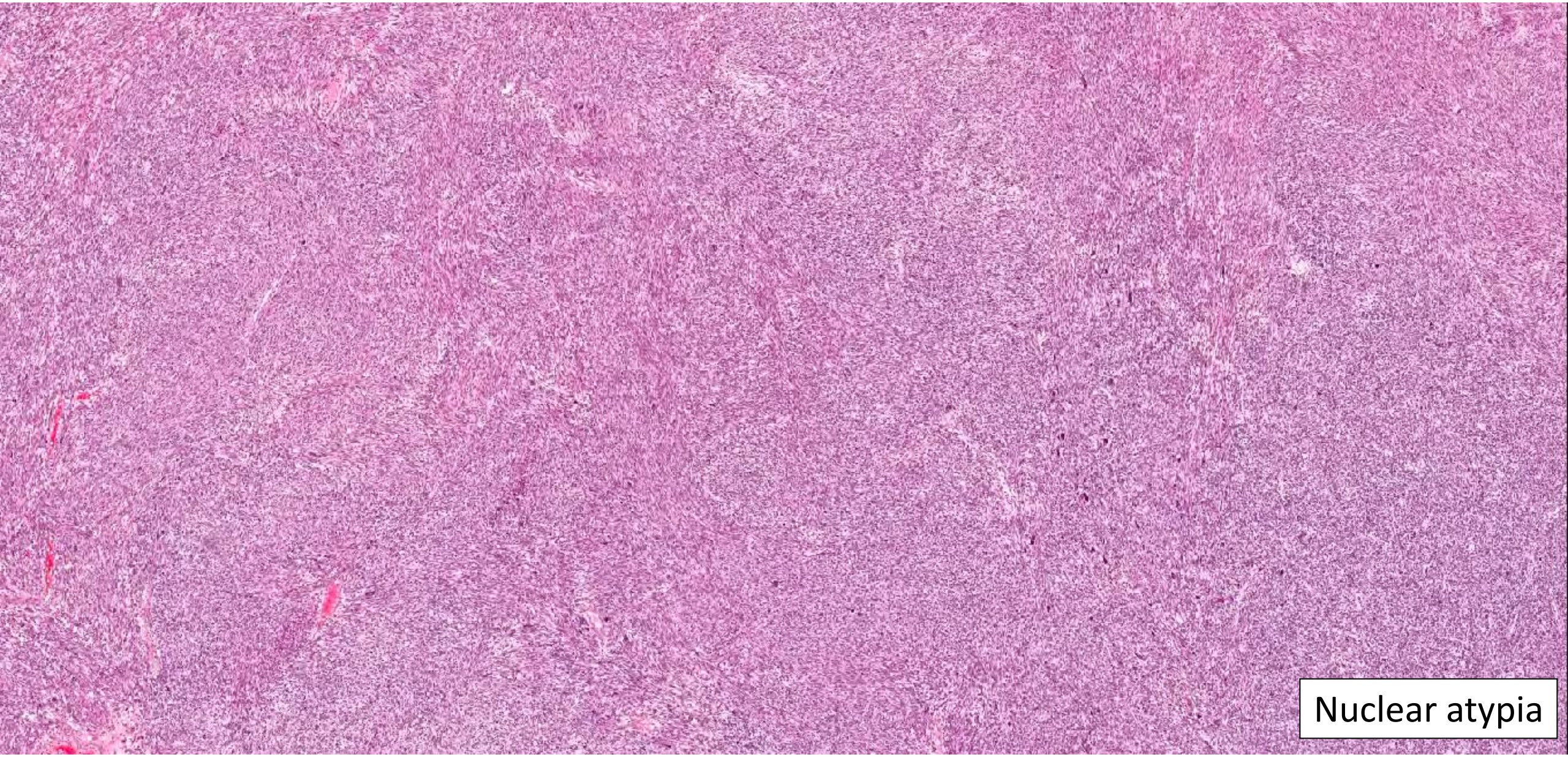
Nuclear atypia

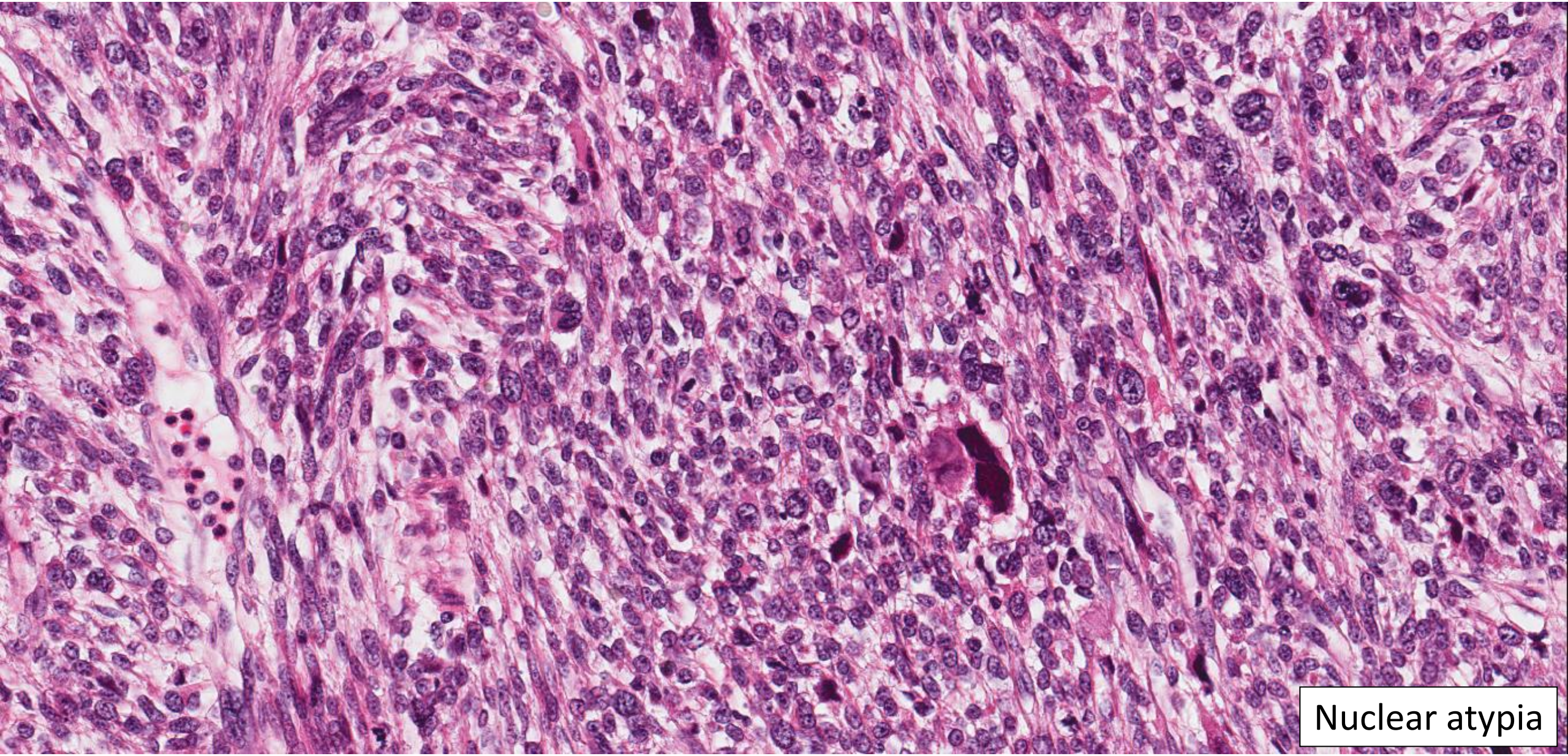
Nuclear atypia

NUCLEAR ATYPIA

- Broders system
- Mild (1+): Uniform nuclei, 2x normal myocyte nucleus
- Moderate (2+): >2x normal myocyte nucleus, minimal pleomorphism
- Severe: Marked (3+) o diffuse (4+) pleomorphism

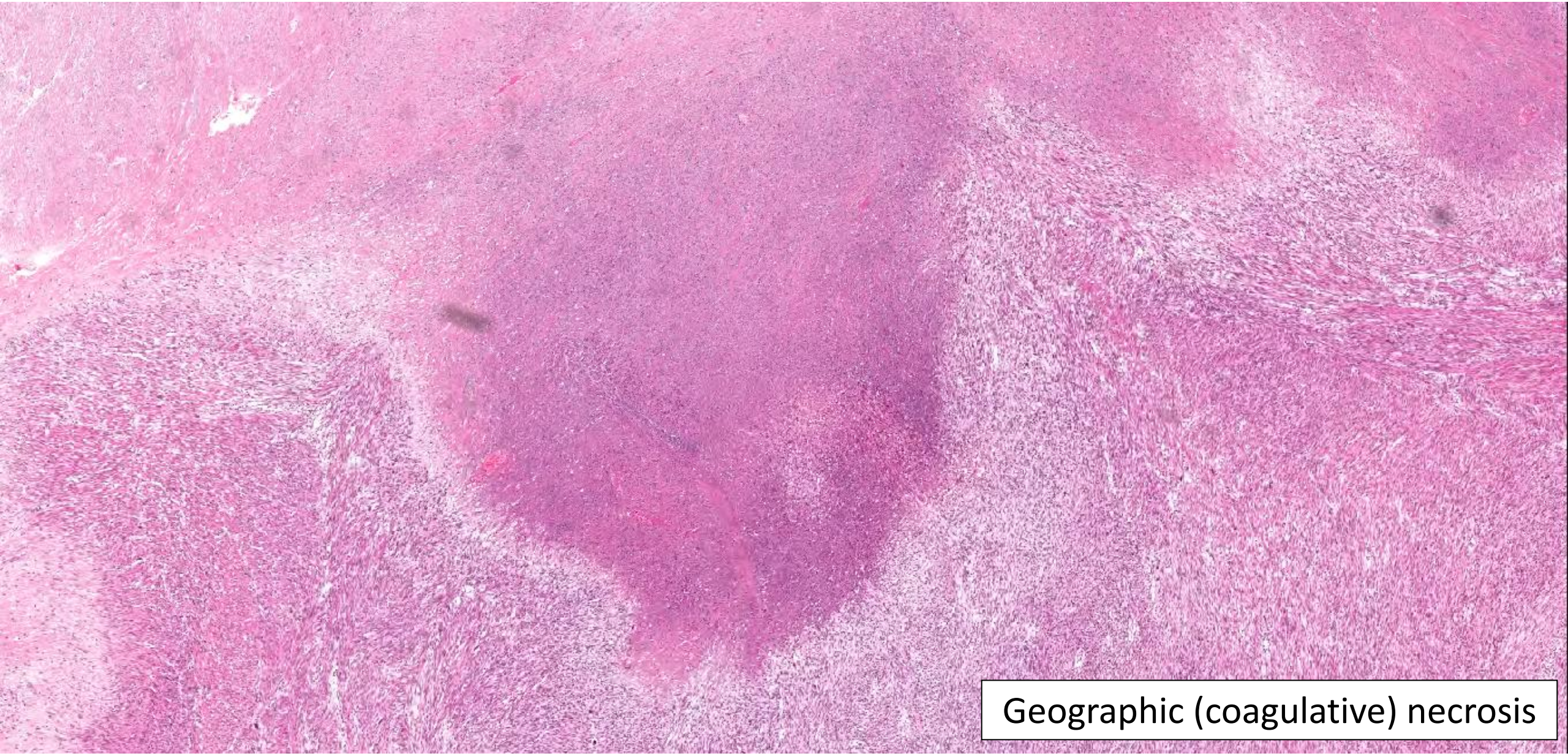
Geographic (coagulative) necrosis

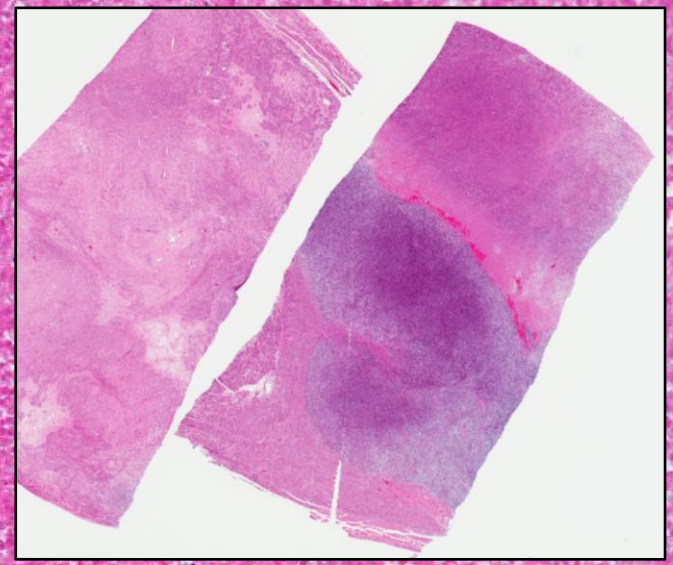

Geographic (coagulative) necrosis

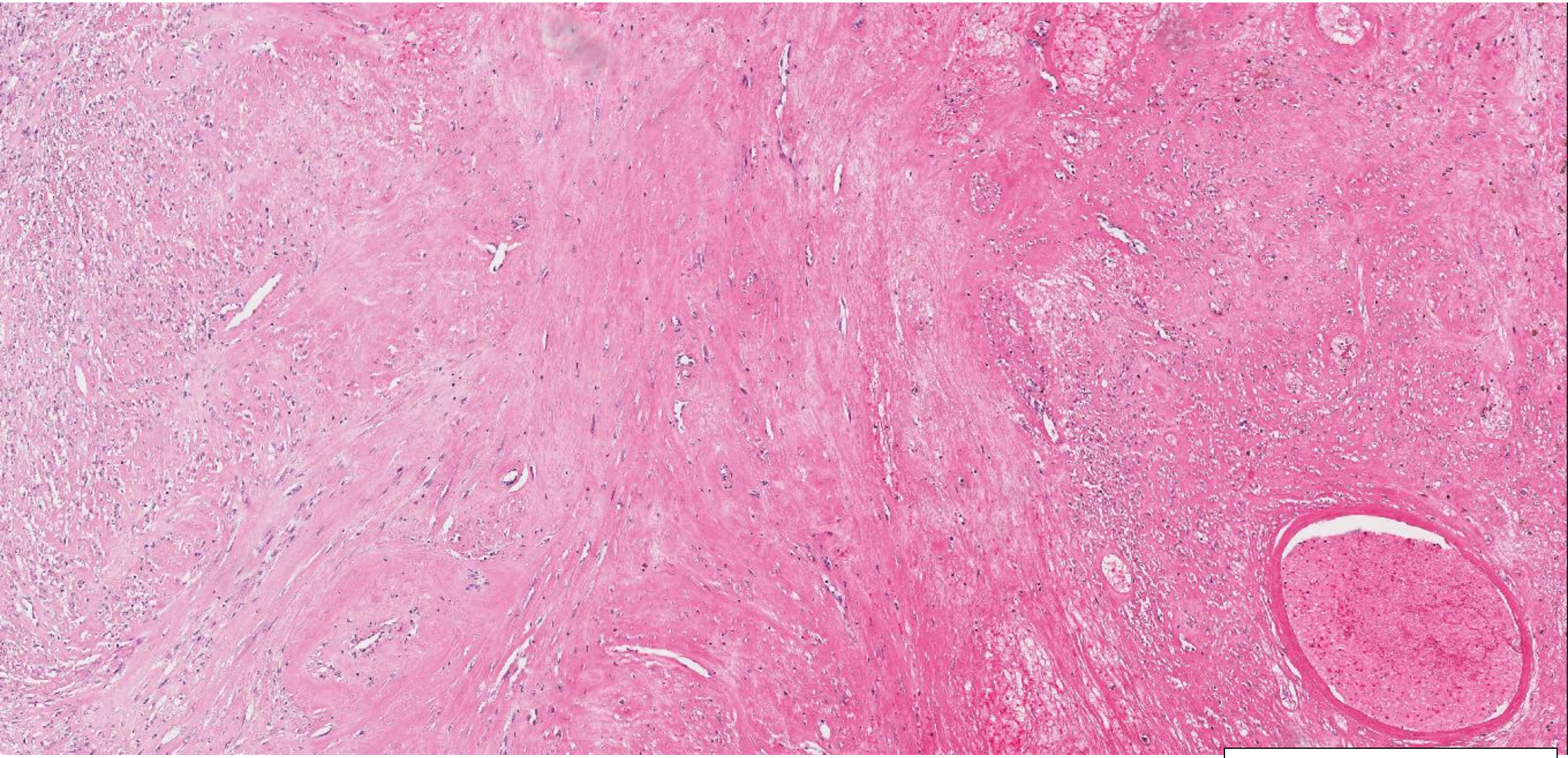

Ischemic necrosis

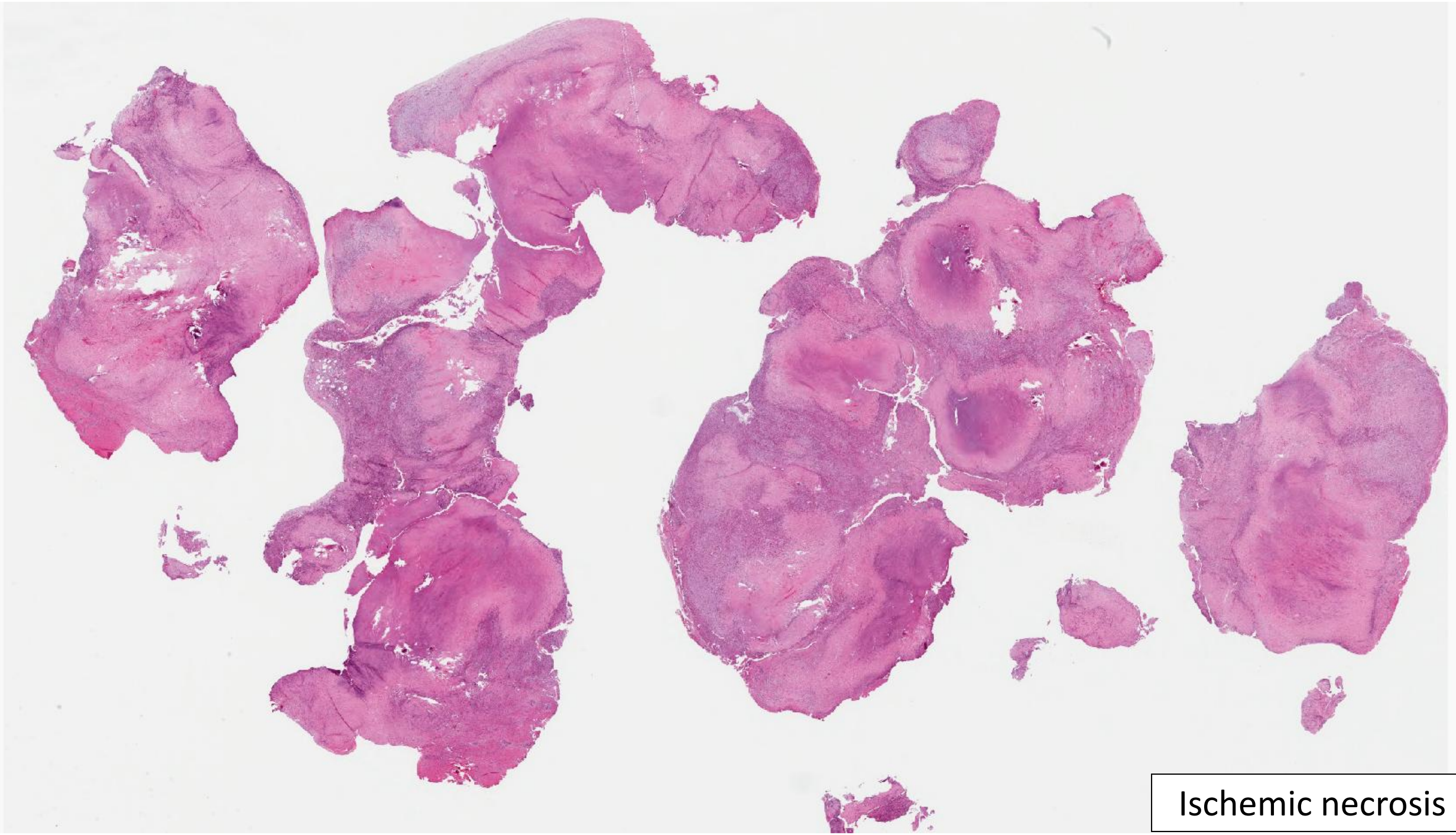
Ischemic necrosis

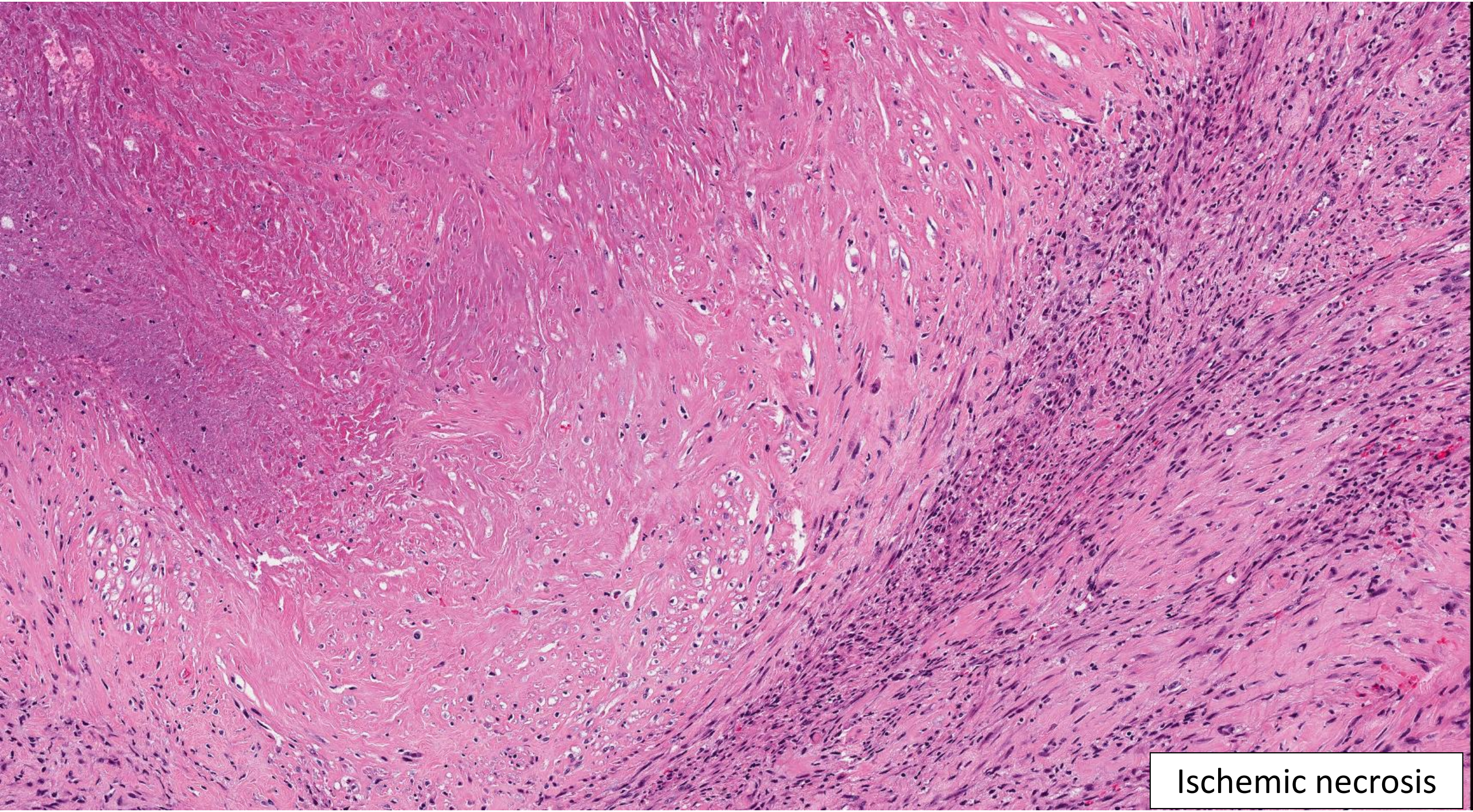
Ischemic necrosis

BENIGN OR MALIGNANT?

- Start by assessing features attributed to malignant behaviour
  - 2+/3+ nuclear atypia, multifocal or diffuse
  - Coagulative (geographic) necrosis
  - High mitotic count (>10 mitosis / 10 CAAs)
  - If present, irregular or frankly infiltrative borders
- Situations in which criteria change
  - Myxoid tumours (mLMS, *BCOR* sarcoma)
  - Epithelioid tumours (eLMS, PEComa)

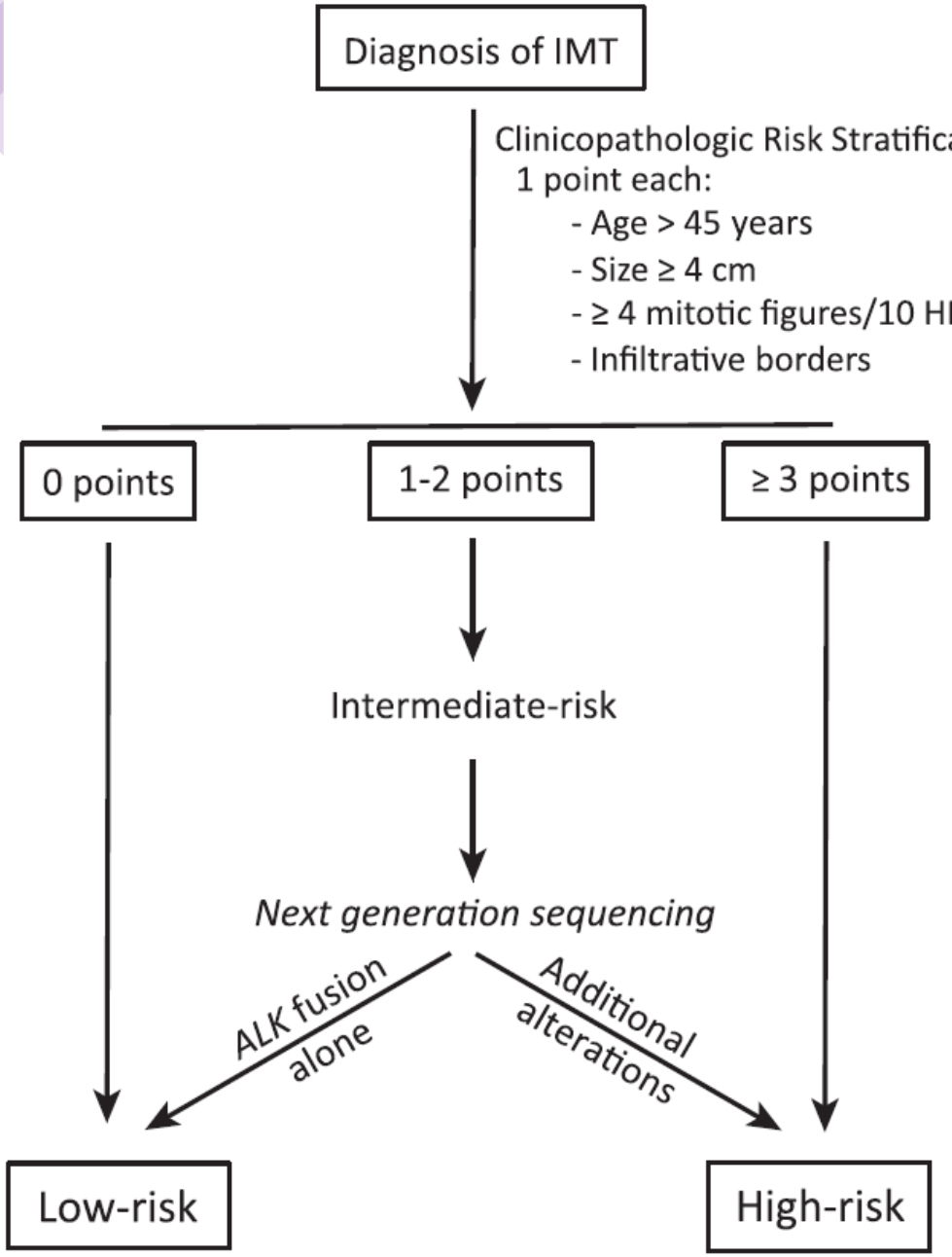

TABLE 5. Clinicopathologic Risk Stratification Score Versus Outcome

Clinicopathologic Risk Stratification Score	Outcome	
	No Aggressive Behavior	Aggressive Behavior
0	11	0
1	15	1
2	4	3
3	0	12
4	0	6

Am J Surg Pathol 2023;47:157-171

PECOMA – CRITERIA FOR MALIGNANCY

WHO (2020 & 2025)	
Unknown Malignant Potential	<3 features: Size ≥5 cm Severe atypia Necrosis Vascular invasion Mitosis ≥1/50 HPFs
Malignant	≥3 features

Surg Pathol Clin 2019;12(2):363-396

REPORTING SUGGESTIONS

- Benign mesenchymal neoplasia
- Low-grade mesenchymal neoplasia
  - Favour **benign** / **malignant**
  - Of unknown malignant potential
- High-grade **spindle cell** / **epithelioid** / **myxoid** sarcoma
- **Undifferenciated** / **round cell** sarcoma

- NOTE: Differential diagnosis includes x, y, z. Ancillary studies (DNA / RNA sequencing, fusion testing) can be contributory
- Final classification requires examination of the lesion in a resection (e.g. hysterectomy) specimen

THANK YOU!

cparra-herran@bwh.harvard.edu



