The British Association of Gynaecological Pathologists

21st Annual Meeting in Collaboration with ISGyP

5th and 6th June 2025

- Title: Practical Evaluation of Endometrial Hyperplasia
- Carlos Parra-Herran
- Brigham and Women's Hospital, Boston MA United States
- June 5, 2025

The British Association of Gynaecological Pathologists

Speaker disclosures

Choose one

- ❑ I have no financial conflicts of interest to disclose

ENDOMETRIAL HYPERPLASIA

- Hyperplasia: Increase in number of cells in a tissue
- Endometrial hyperplasia
  - WHO: Increase in the epithelial compartment (# of glands) in comparison to stroma
  - Gland to stroma ratio greater than 1 (>50% of surface area)

ENDOMETRIOID CANCER PRECURSORS

- **WHO 2003**
- 
- Endometrial intraepithelial neoplasia (EIN)

- **Since 2014**
- Endometrial hyperplasia without atypia
- Atypical endometrial hyperplasia / Endometrioid intraepithelial neoplasia (AH/EIN)

Semin Diagn Pathol 2010;27:215-25
Obstet Gynecol 2022;140:1061-75
Gynecol Oncol 2023:175:15-19

Genetic (e.g. Lynch syndrome)
Obesity
Chronic anovulation (e.g. PCOS)

Unopposed estrogen stimulation

Disordered proliferative endometrium	Non-atypical endometrial hyperplasia	EIN/ Atypical endometrial hyperplasia	Endometrial endometroid adenoCA
• Increased glandular density (gland to stroma ratio < 1) • Abnormal glandular shape - Branching - Dilation - Scalloping	• Increased glandular density (gland to stroma ratio ≥ 1) • No atypia (cells are similar to non-crowded areas)	• Increased glandular density • Atypia / altered cytology (nuclei are different from non-crowded areas) • No confluence or complex architecture	• Increased glandular density with confluence and complex architecture - Cribriform - Papillary

Disordered proliferative endometrium

- Increased glandular density (gland to stroma ratio < 1)
- Abnormal glandular shape

- Branching
- Dilation
- Scalloping

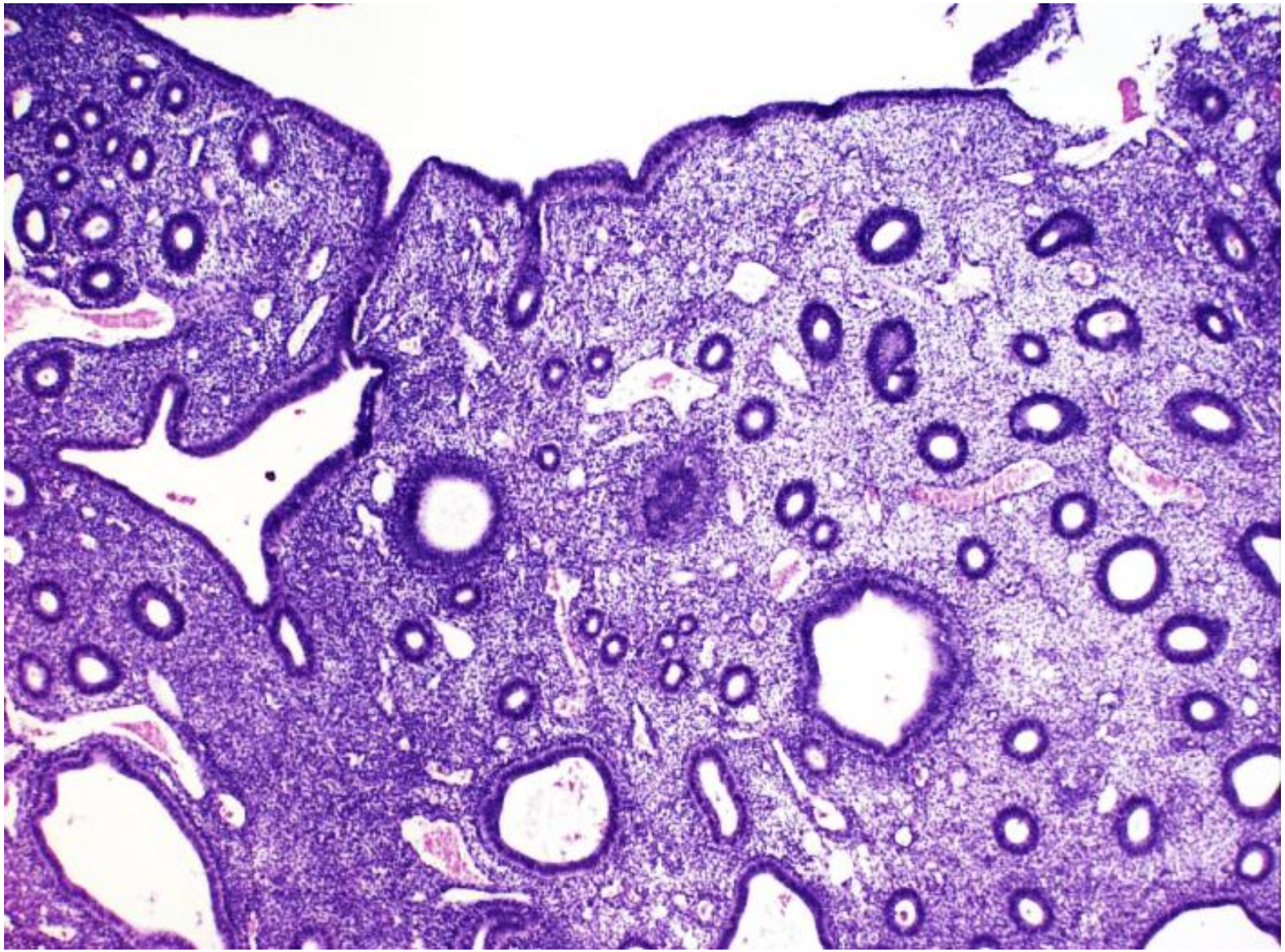

Glandular heterogeneity (shape & size)

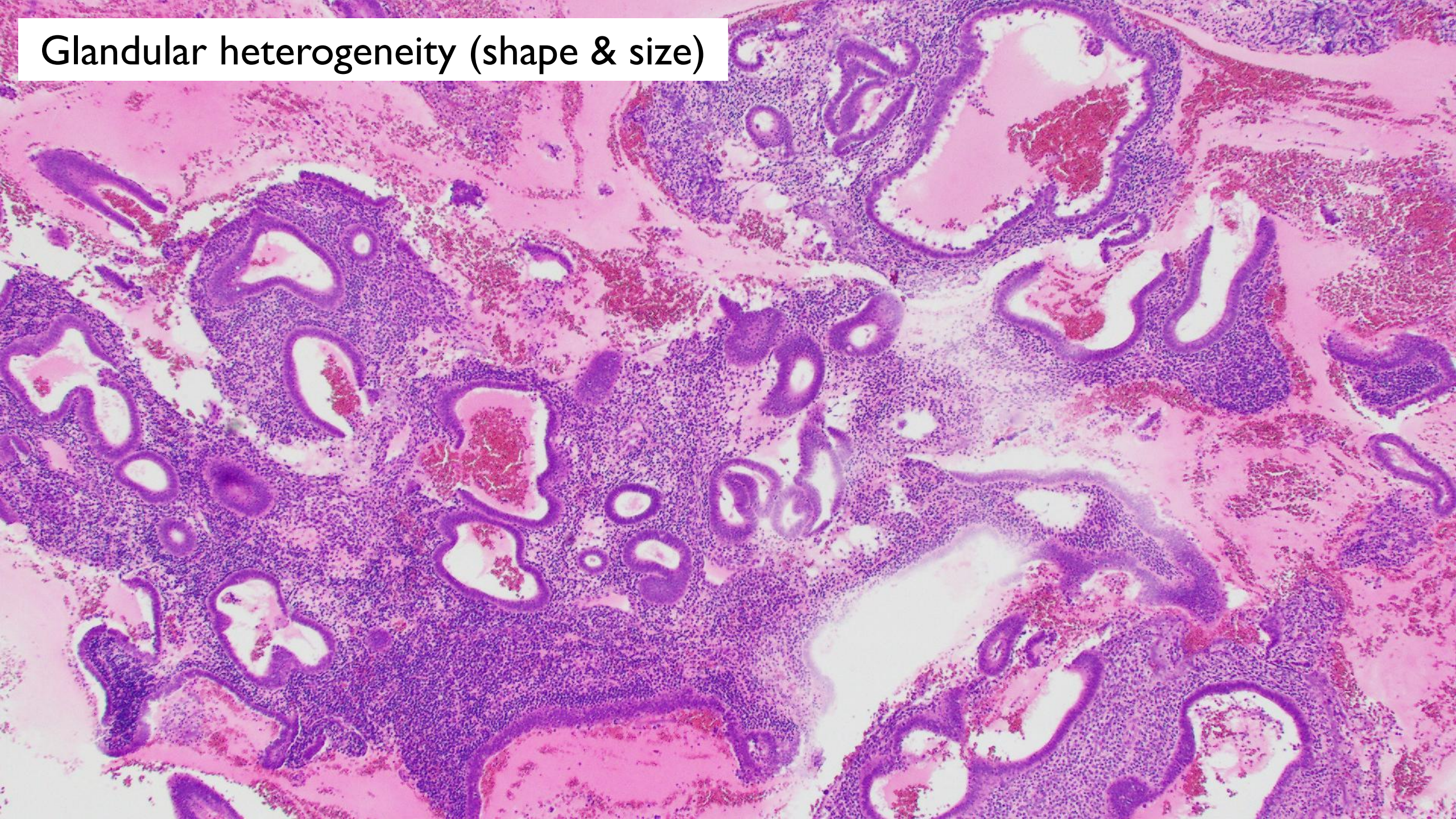



Glandular irregularity (animal crackers*)
Epithelial metaplasia (usually tubal)

* As elegantly described by Brad Quade (BWH)

Non-atypical endometrial hyperplasia

- Increased glandular density (gland to stroma ratio ≥ 1)
- No atypia (cells are similar to non- crowded areas)
- Prognosis
  - 20-year progression to carcinoma: less than 5%

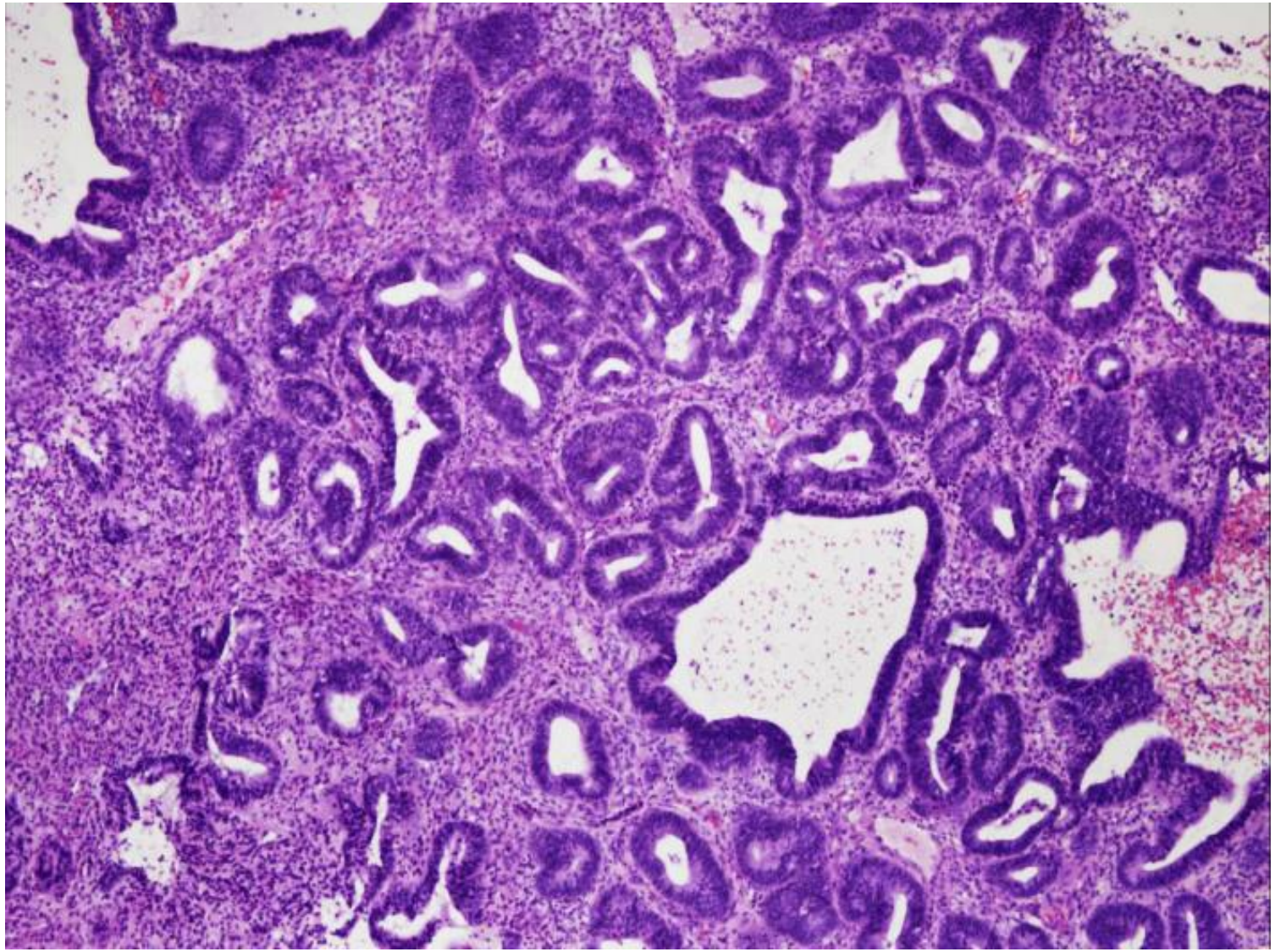

J Clin Oncol 2010;28:788-92
PLoS One 2020;28;15(4):e023223

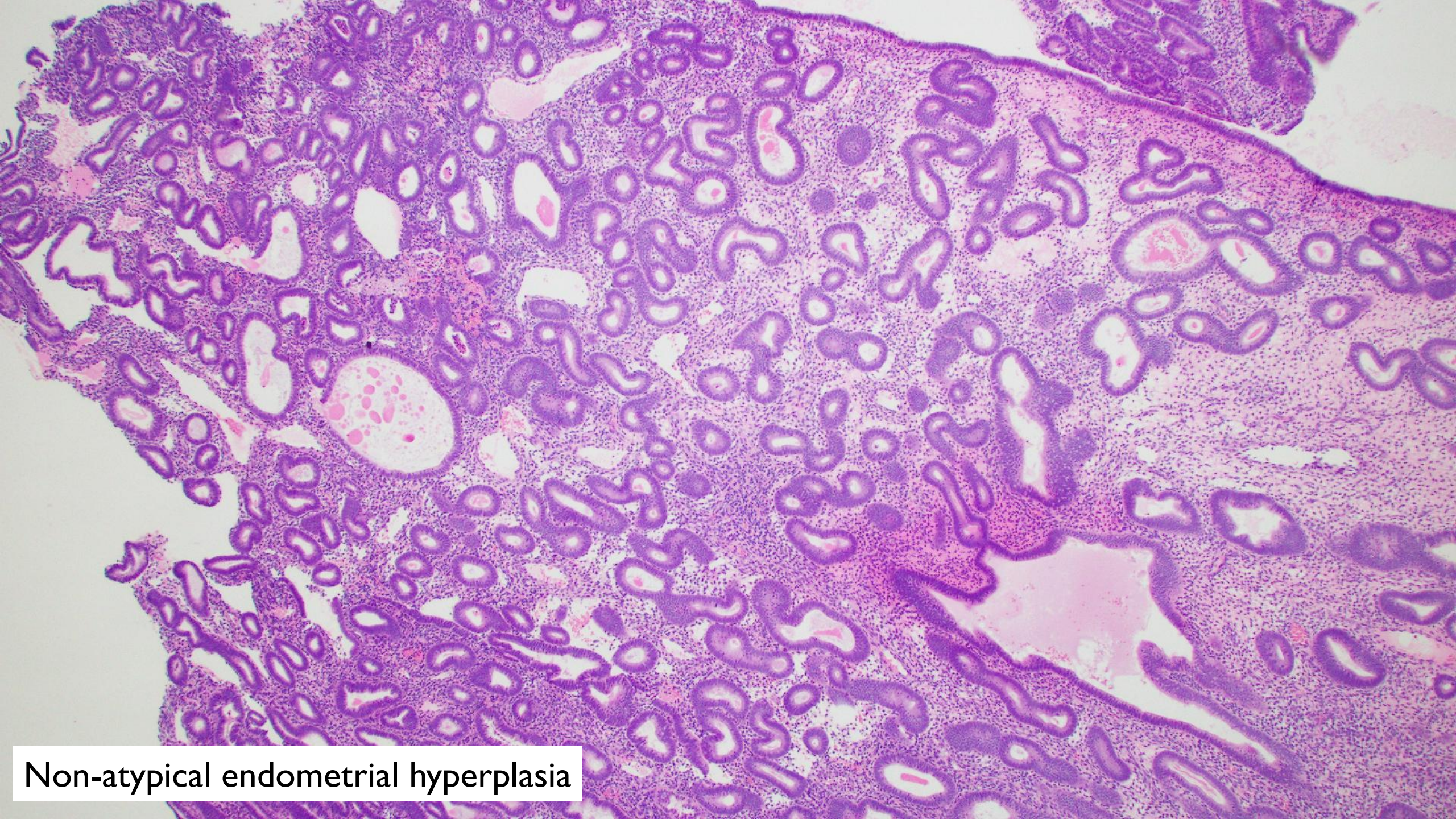

Non-atypical endometrial hyperplasia

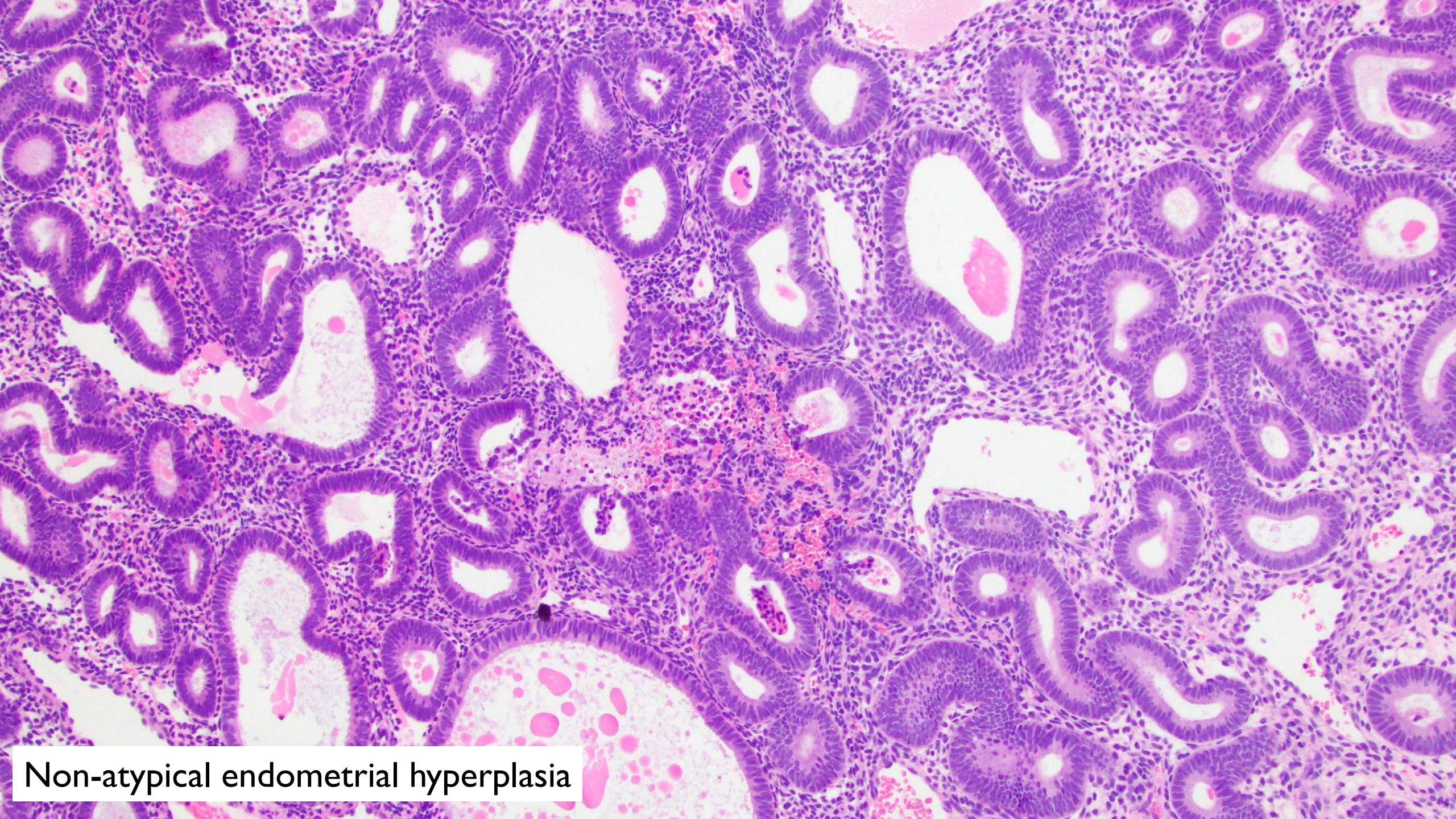
Non-atypical endometrial hyperplasia

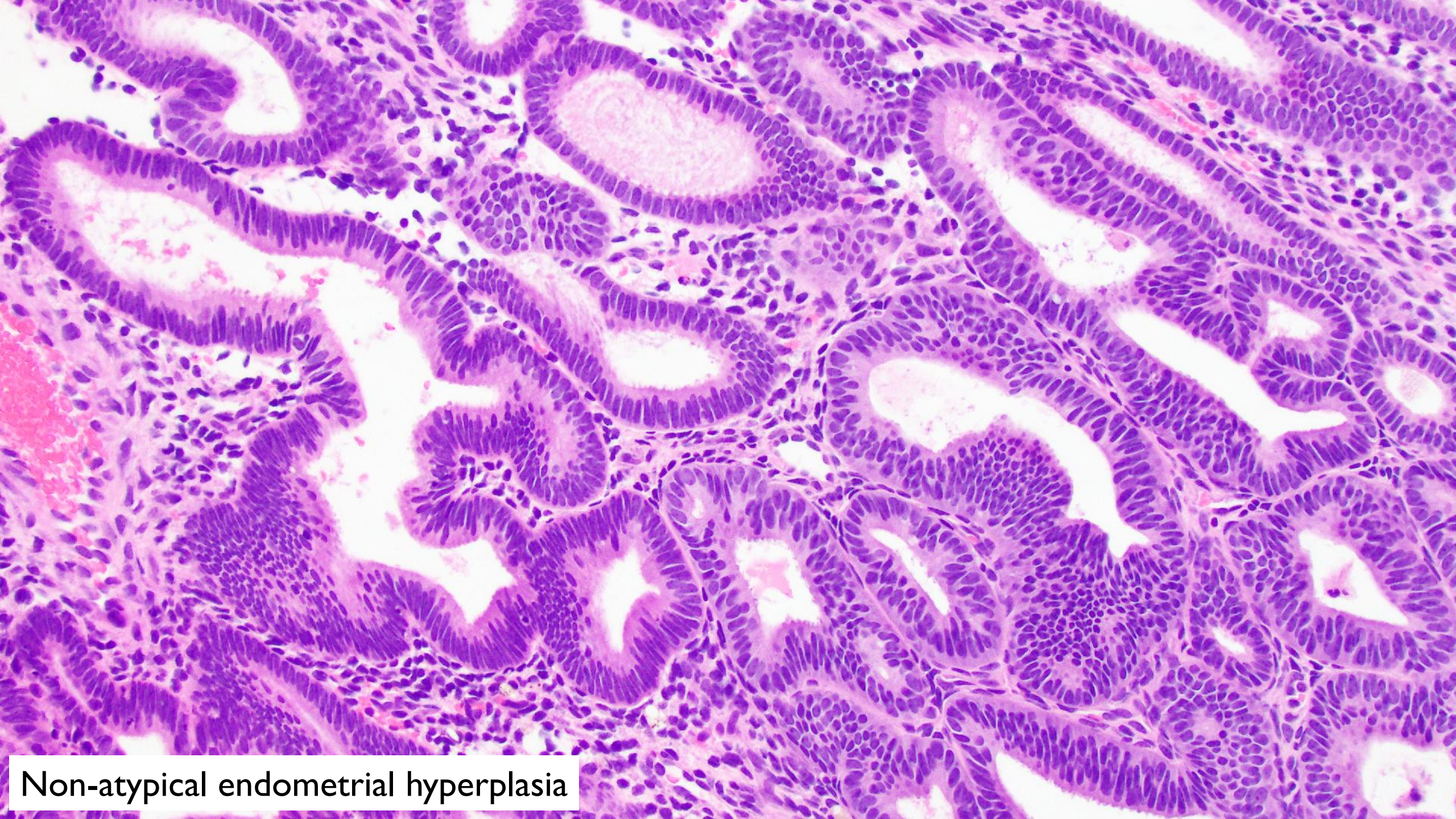

Non-atypical endometrial hyperplasia

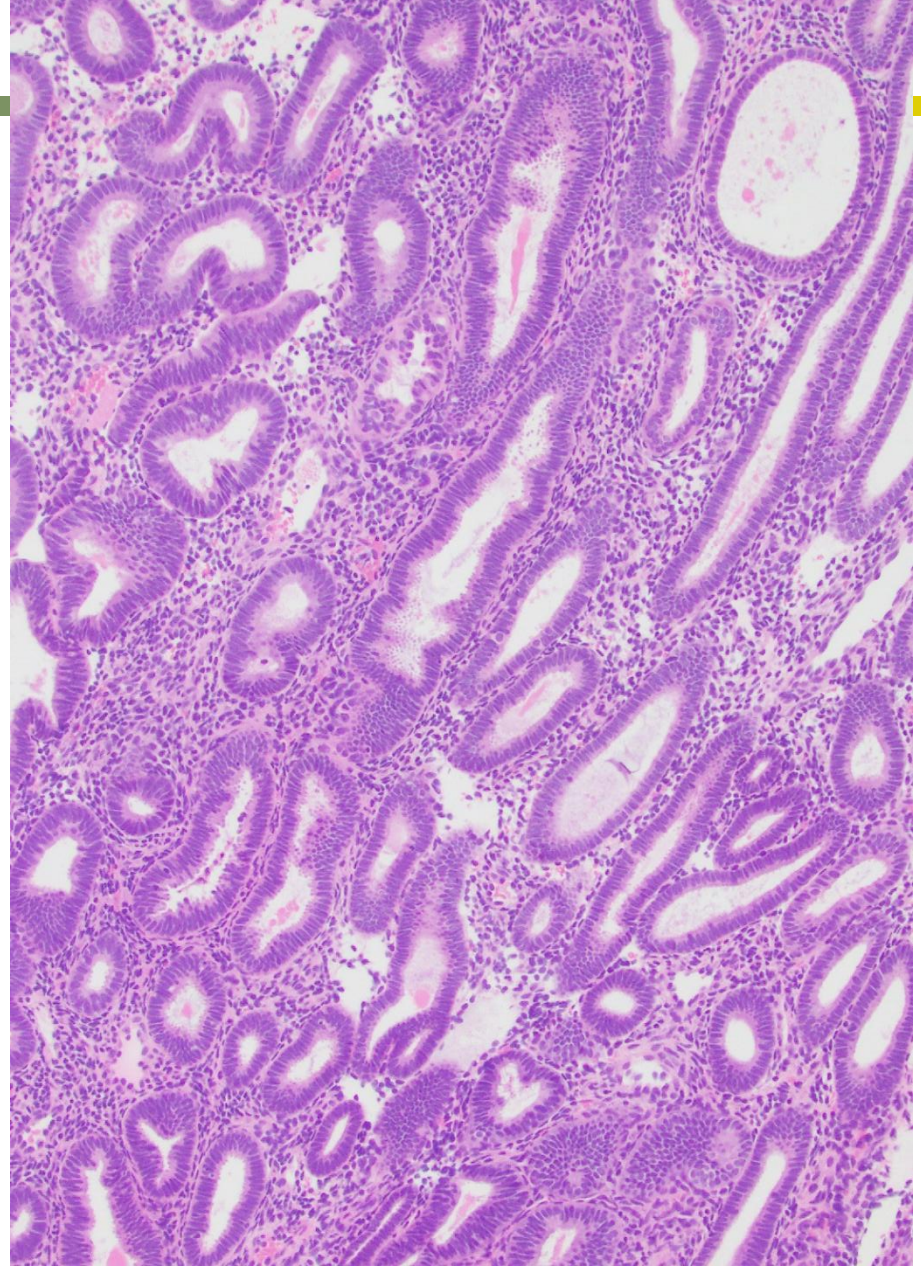

Non-atypical endometrial hyperplasia

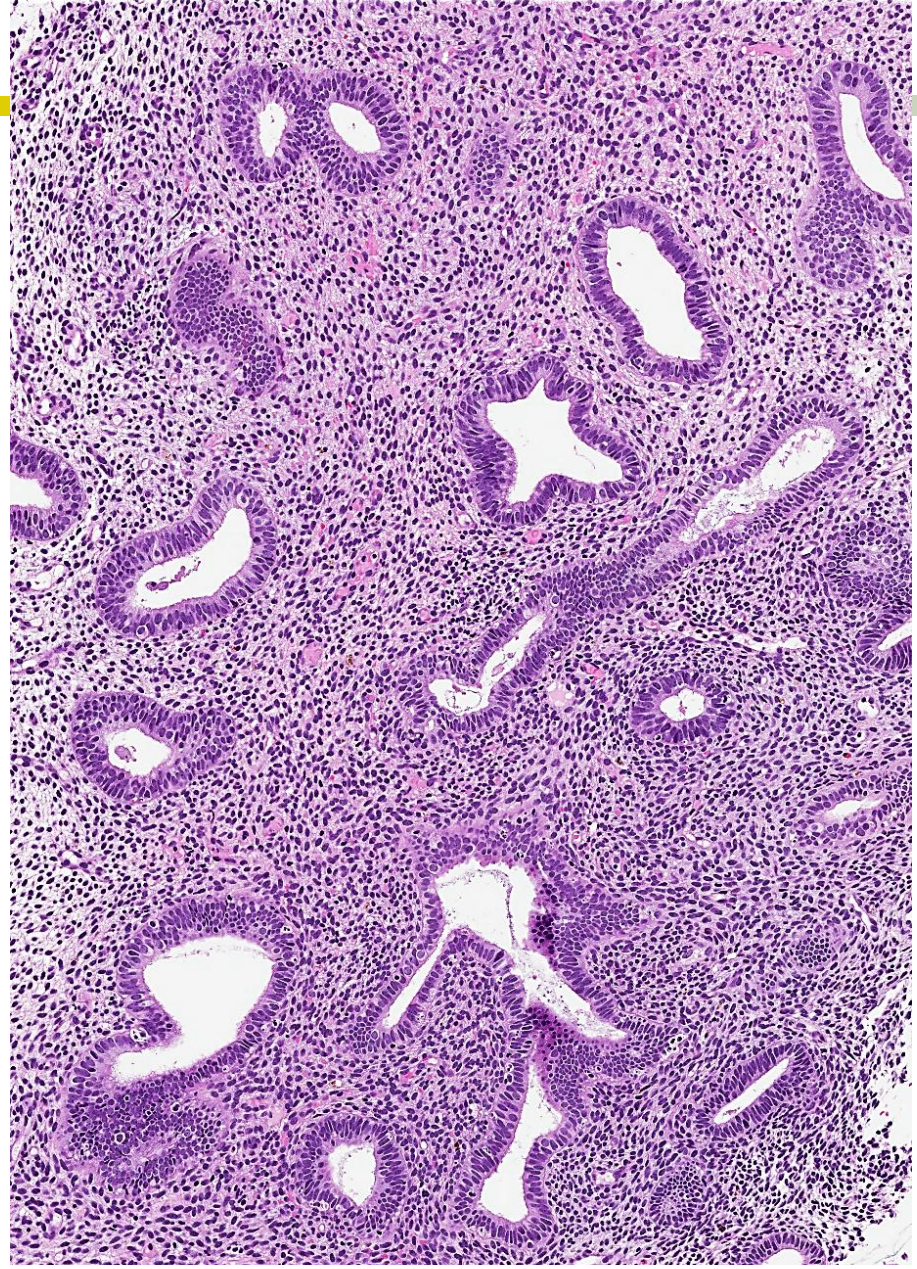

Disordered proliferative endometrium

EIN/ Atypical endometrial hyperplasia

- Increased glandular density
- Atypia / altered cytology (nuclei are different from non-crowded areas)
- No confluence or complex architecture
- Prognosis
  - 45-fold lifetime risk of CA
  - 33% risk of concurrent carcinoma in hysterectomy
  - Annual CA incidence rate 8%

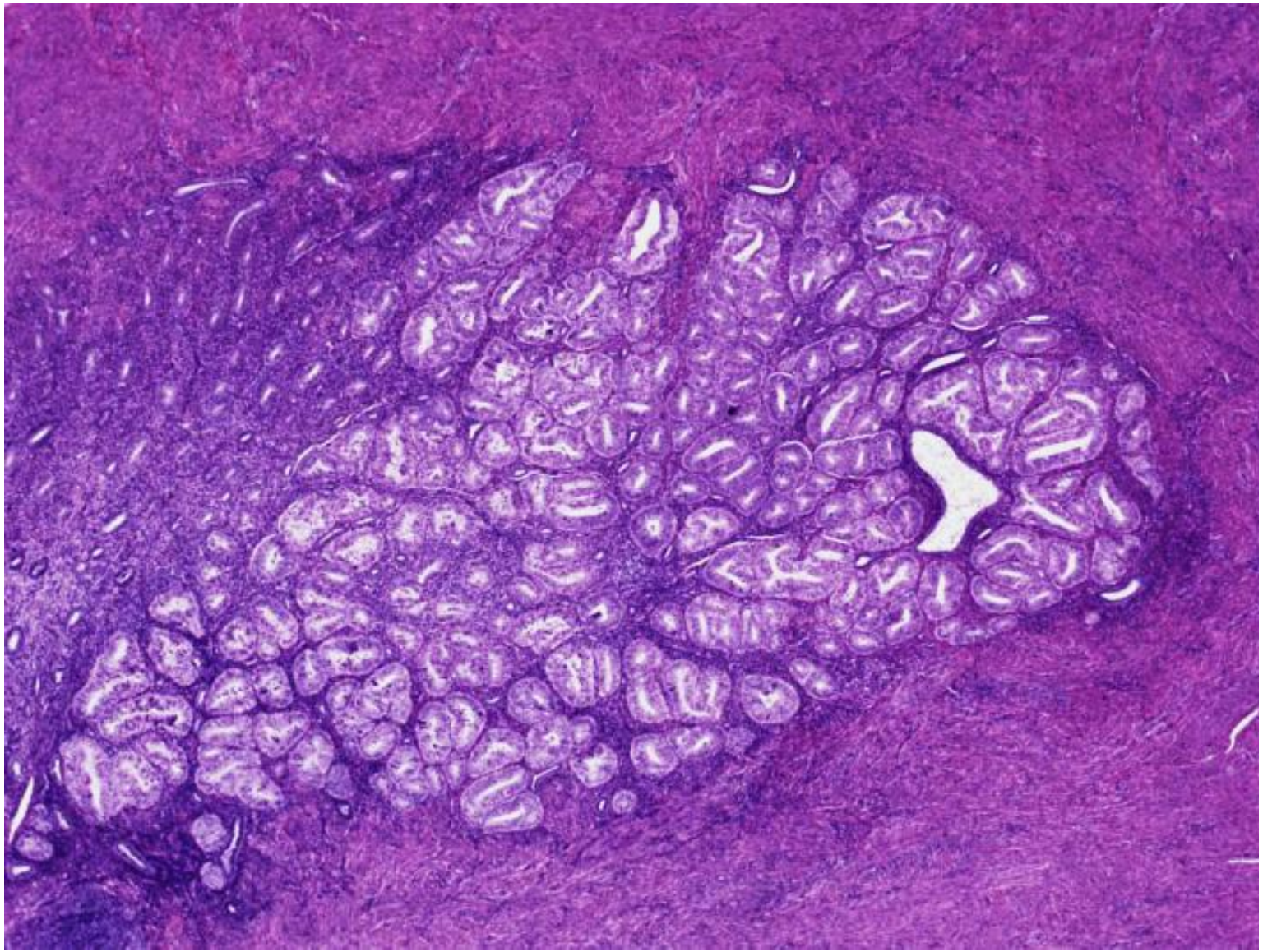

Semin Diagn Pathol 2010;27:215-25
PLoS One 2020;28;15(4):e023223

ATYPICAL HYPERPLASIA (EIN/AH)

- Nuclear atypia
  - Nuclear enlargement
  - Pleomorphism
  - Rounding
  - Loss of polarity
  - Nucleoli
- Nuclear atypia is variable!
- Poor intraobserver & interobserver agreement

THE EIN APPROACH

- Crowded glands (gland : stroma ratio > 1)
- Cytologic demarcation
- Exclude mimickers that feature crowding
  - Endometrial polyp
  - Secretory endometrium
- >1 mm in largest linear dimension

THE EIN APPROACH

- Crowded glands (gland : stroma ratio > 1)
- Cytologic demarcation
- Exclude mimickers that feature crowding
  - Endometrial polyp
  - Secretory endometrium
- >1 mm in largest linear dimension

The EIN (Endometrioid Intraepithelial Neoplasia) Approach

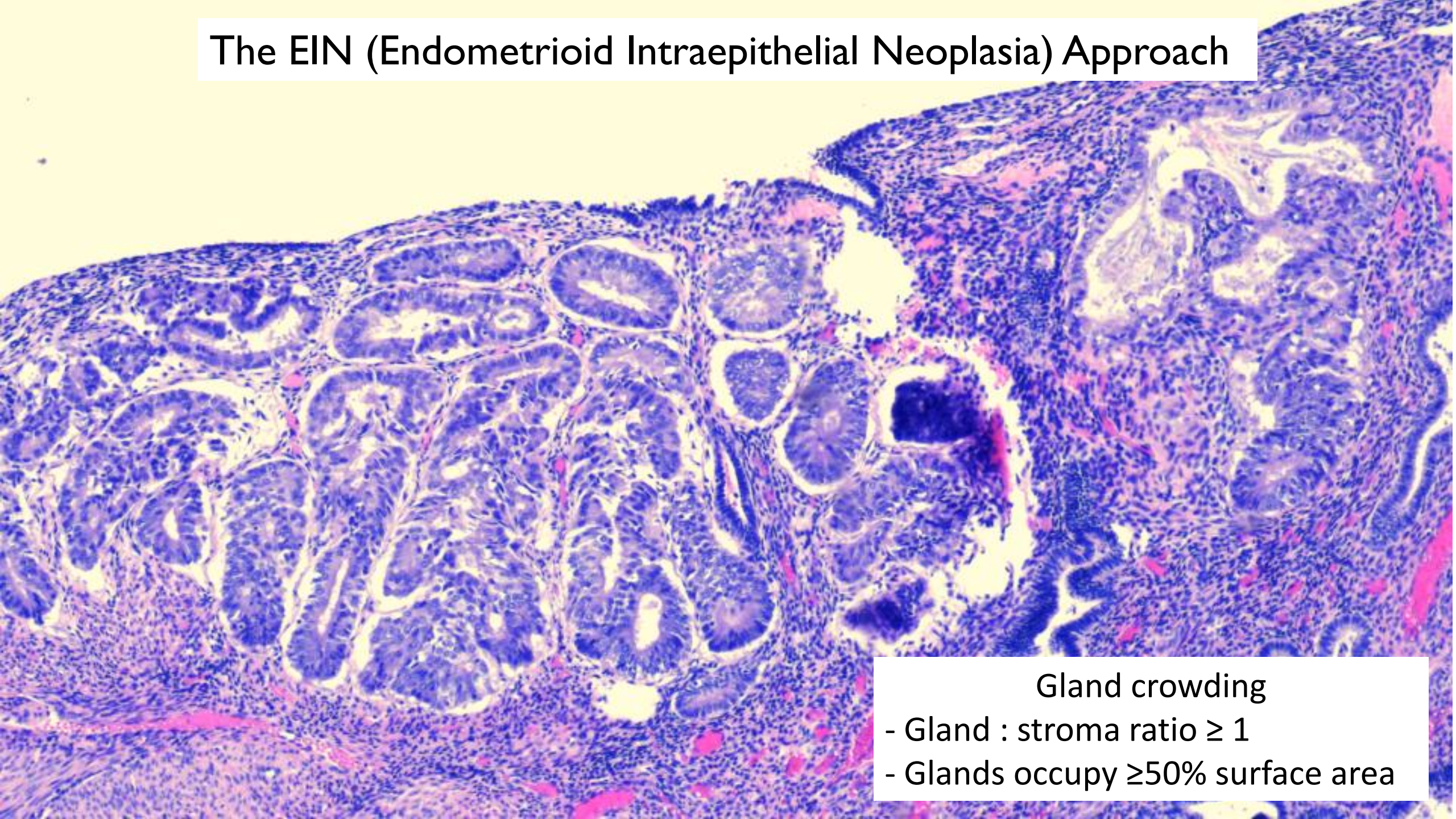

Gland crowding

- Gland : stroma ratio ≥ 1
- Glands occupy ≥50% surface area

The EIN (Endometrioid Intraepithelial Neoplasia) Approach

"Atypia" = cytologically different (demarcated)
Contrast with background endometrium

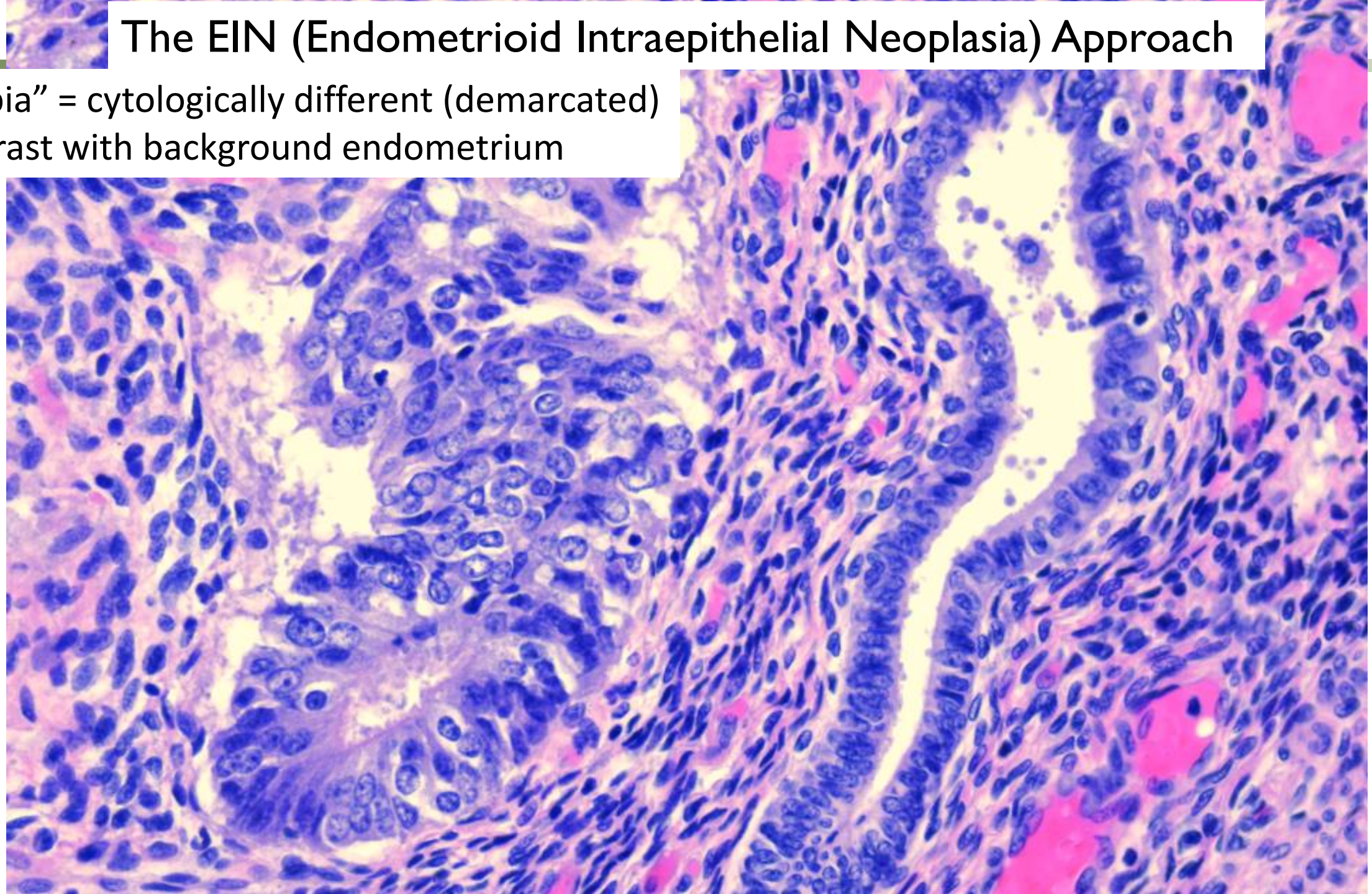

THE EIN APPROACH

- Crowded glands (gland : stroma ratio > 1)
- Cytologic demarcation
- Exclude mimickers that feature crowding
  - Endometrial polyp
  - Secretory endometrium



Absence of cytologic demarcation

- >1 mm in largest linear dimension

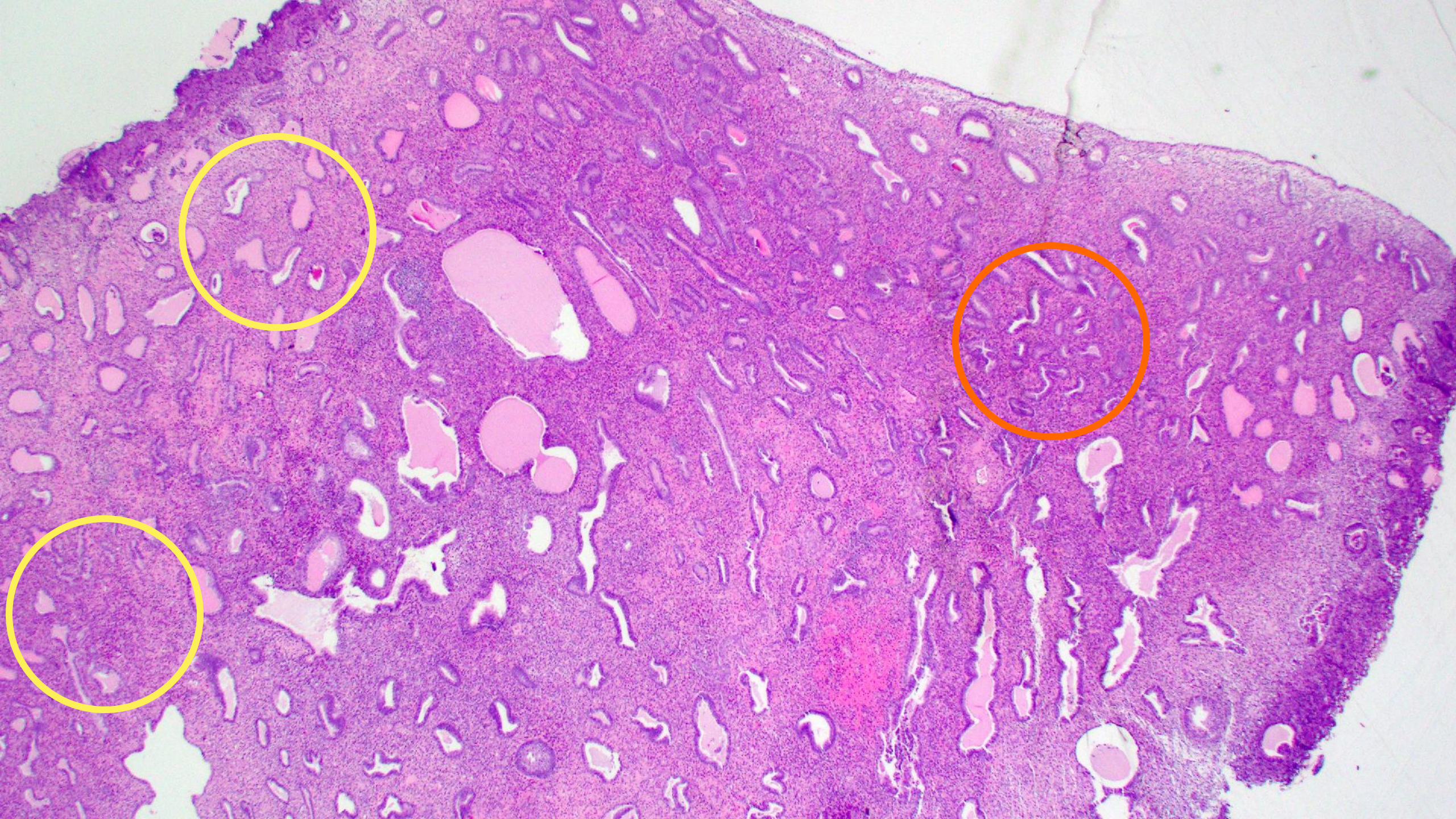

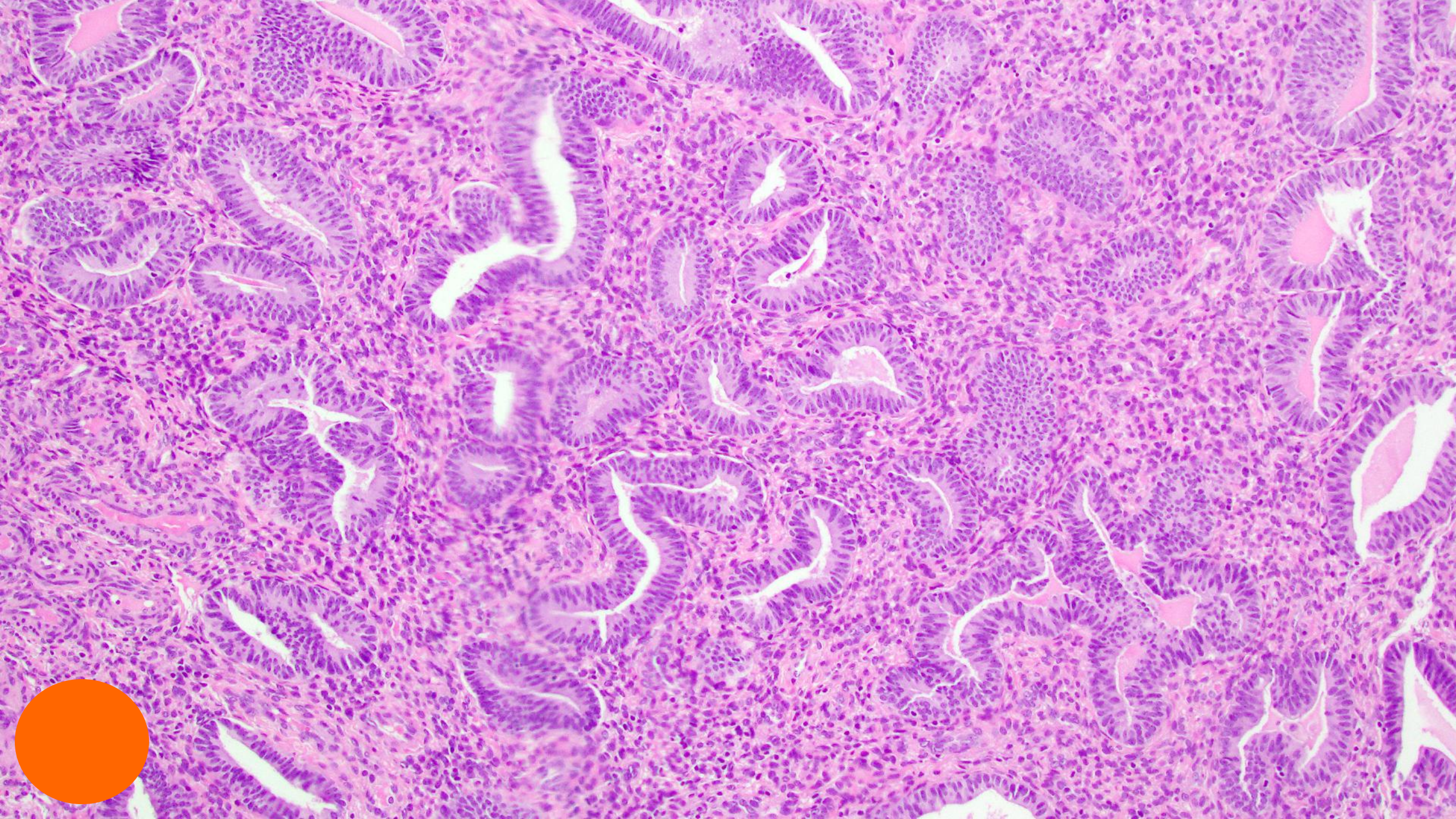

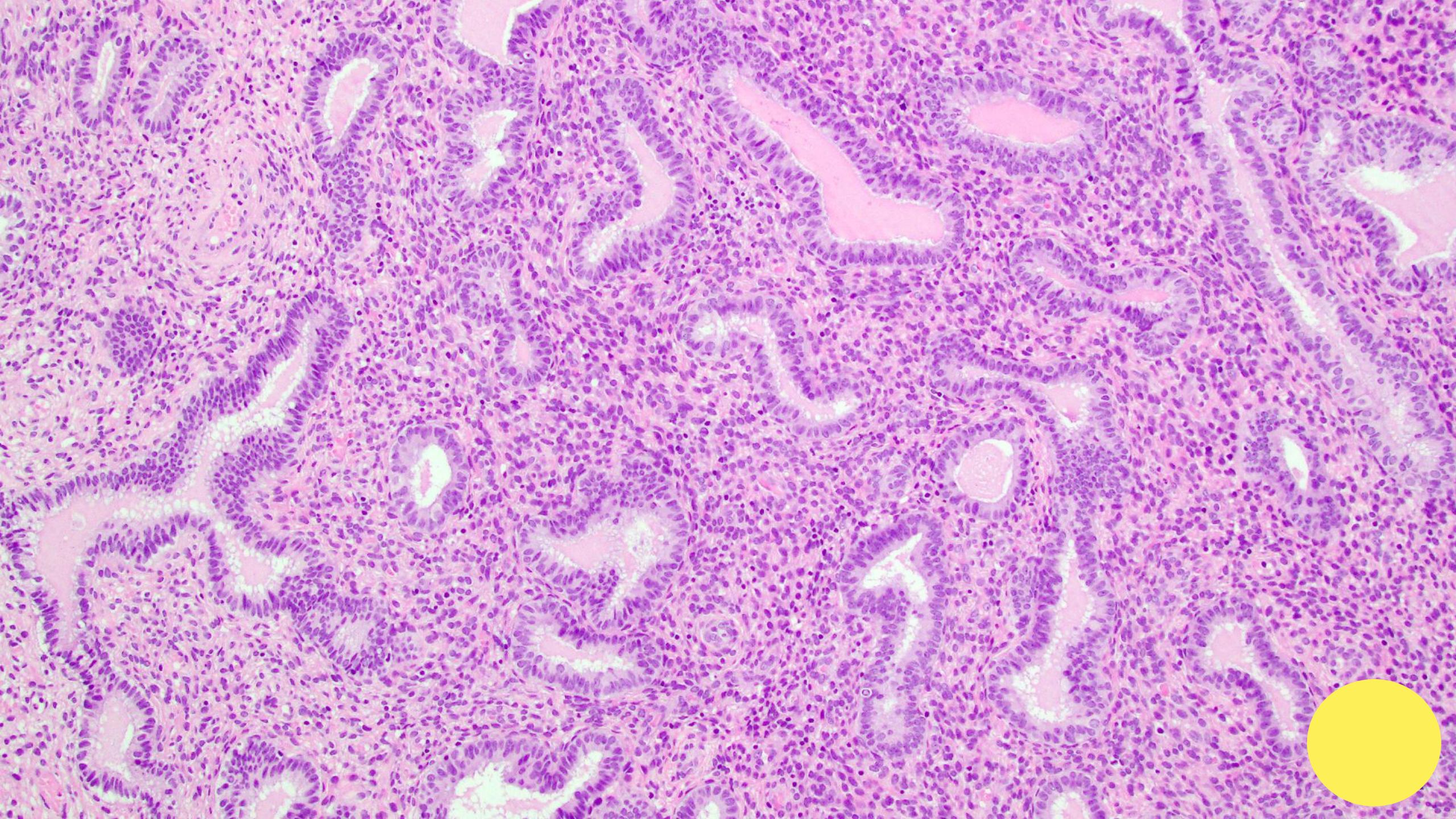

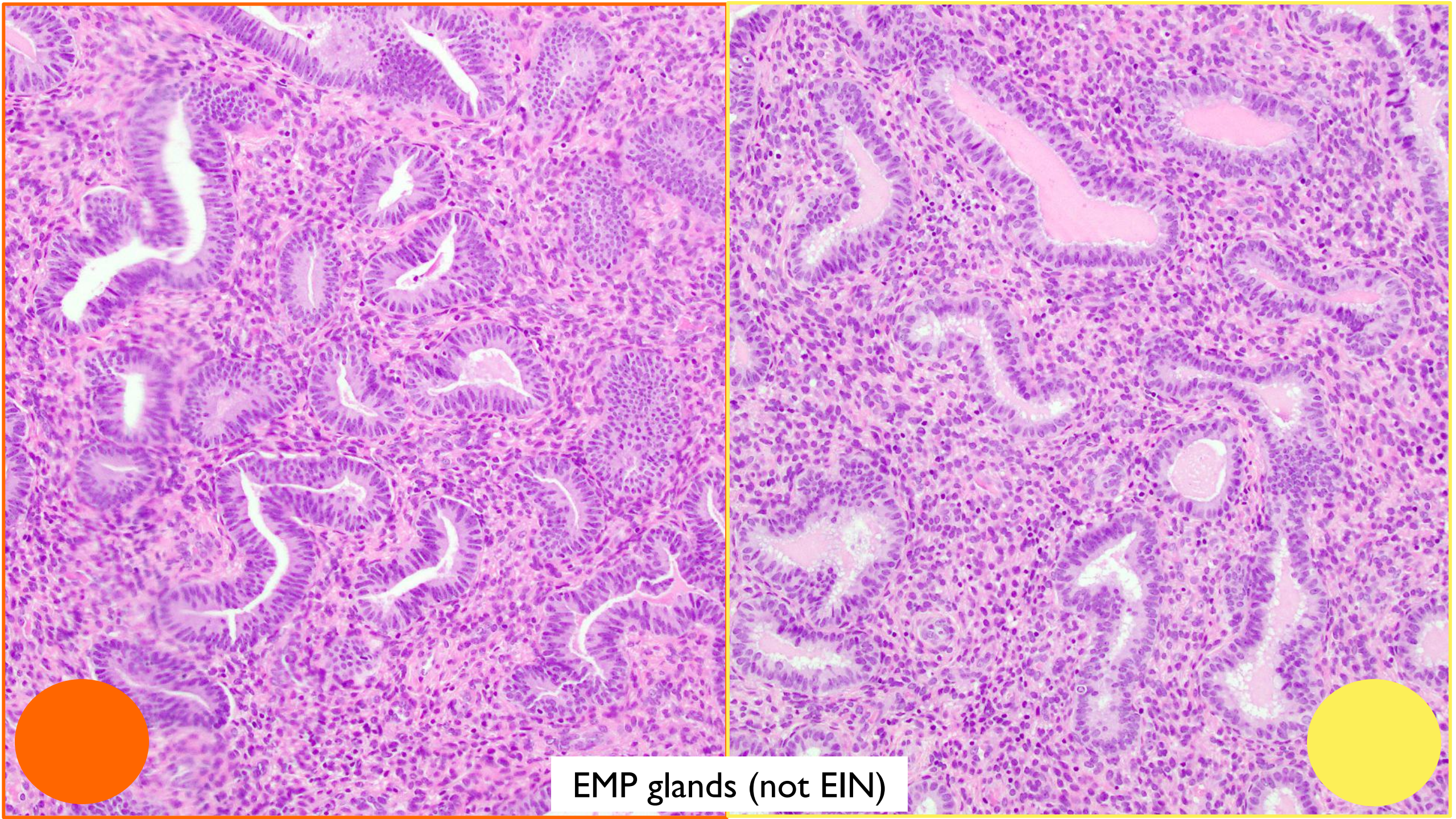
EMP glands (not EIN)

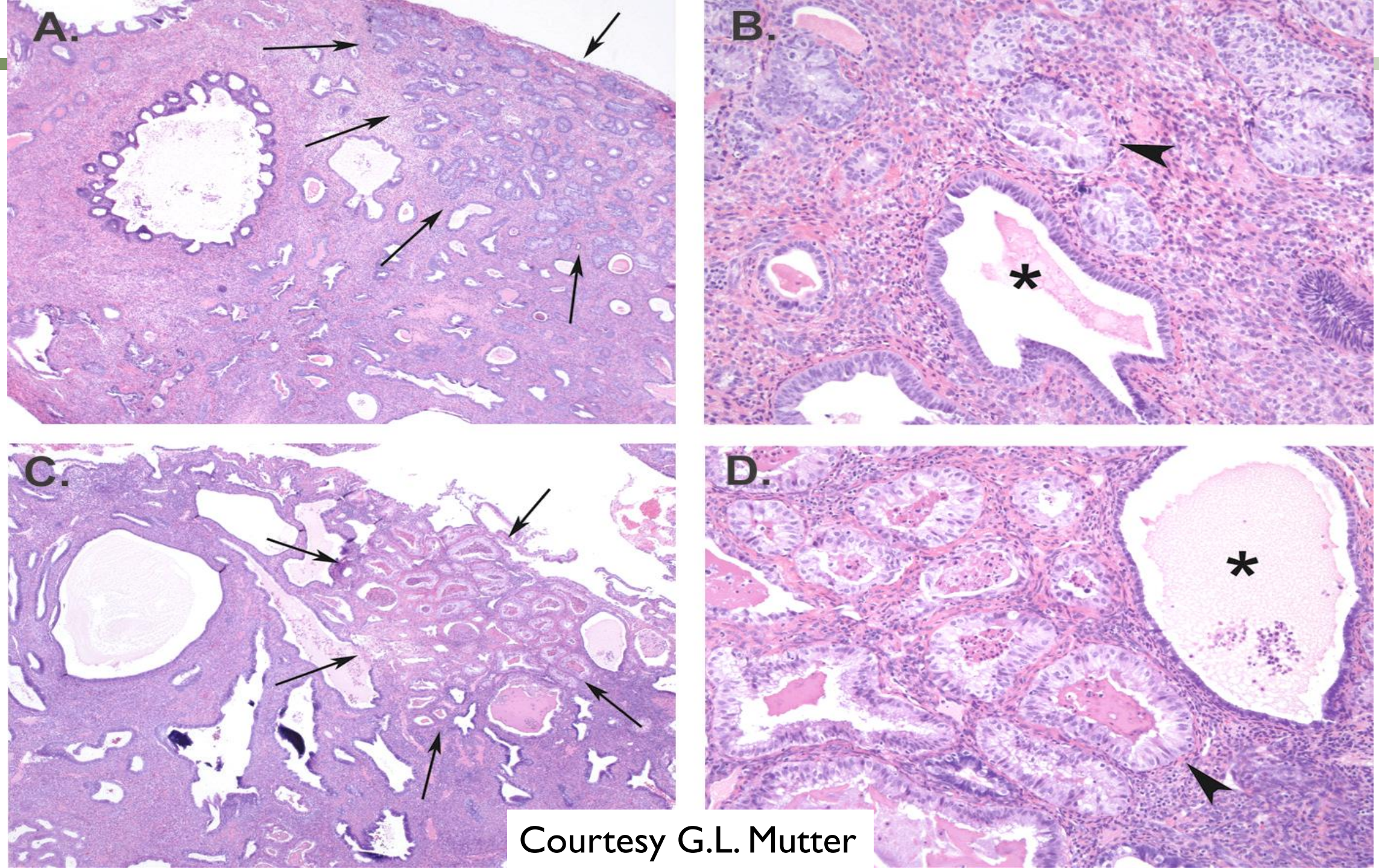

Courtesy G.L. Mutter

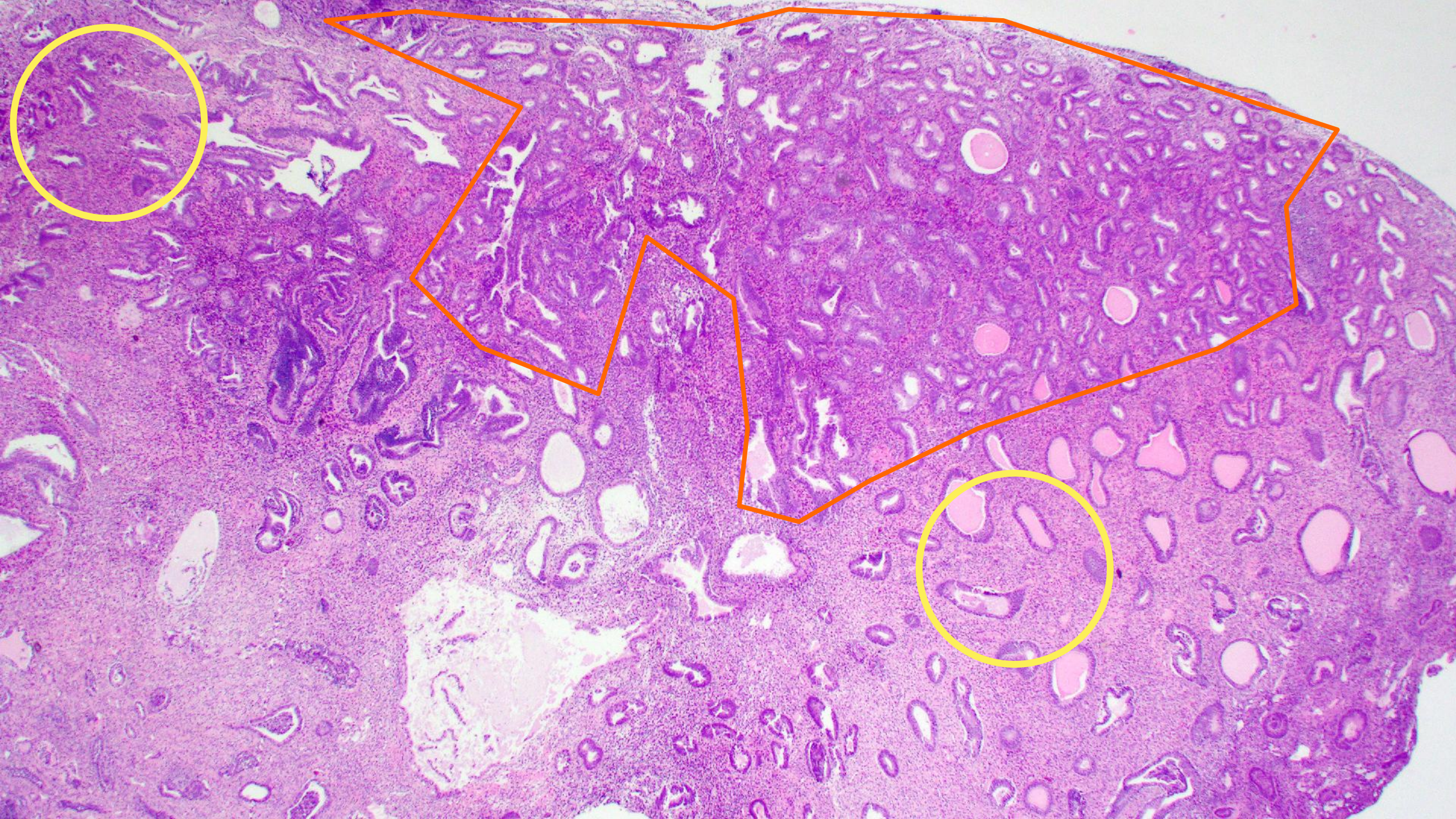

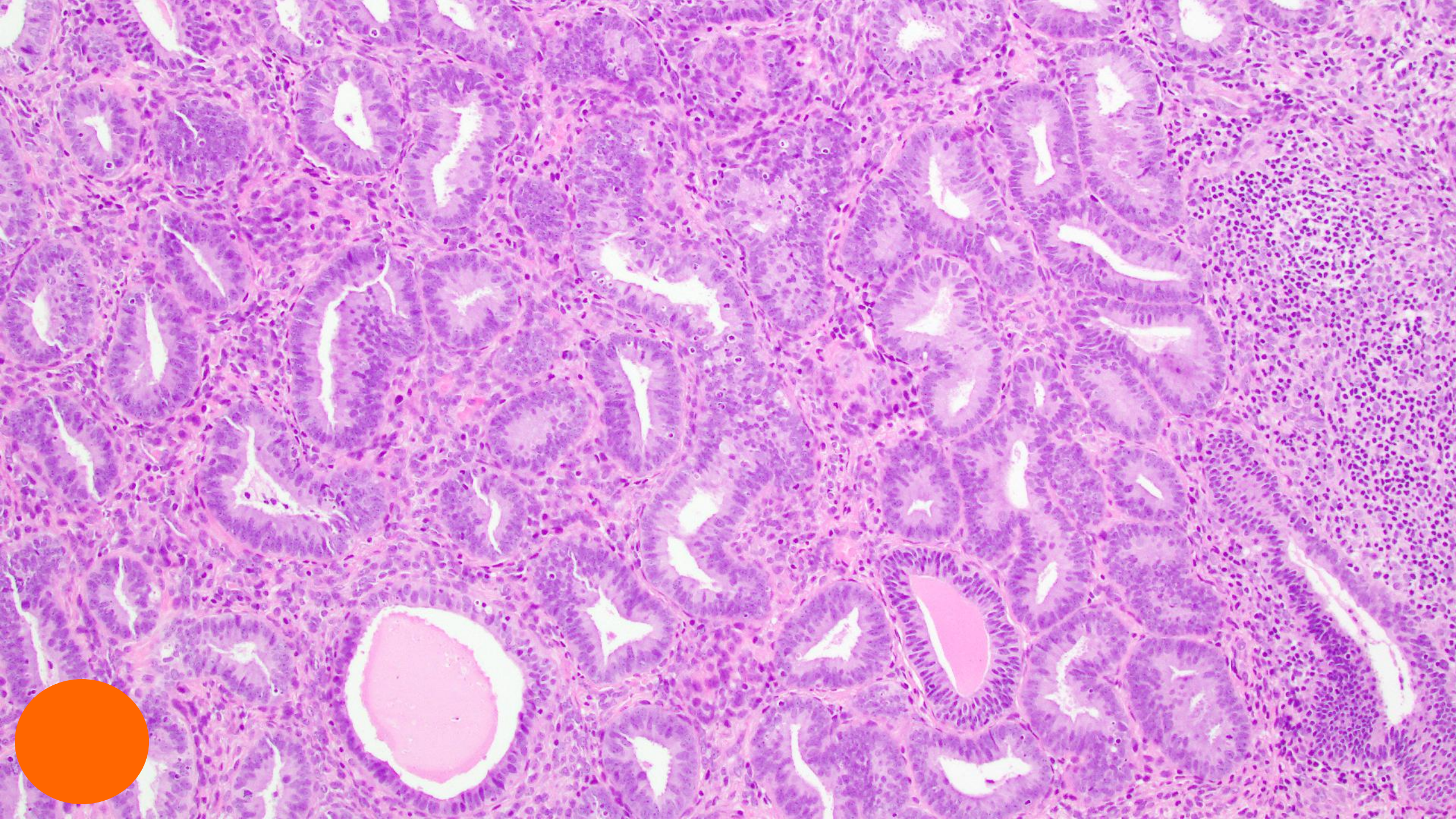

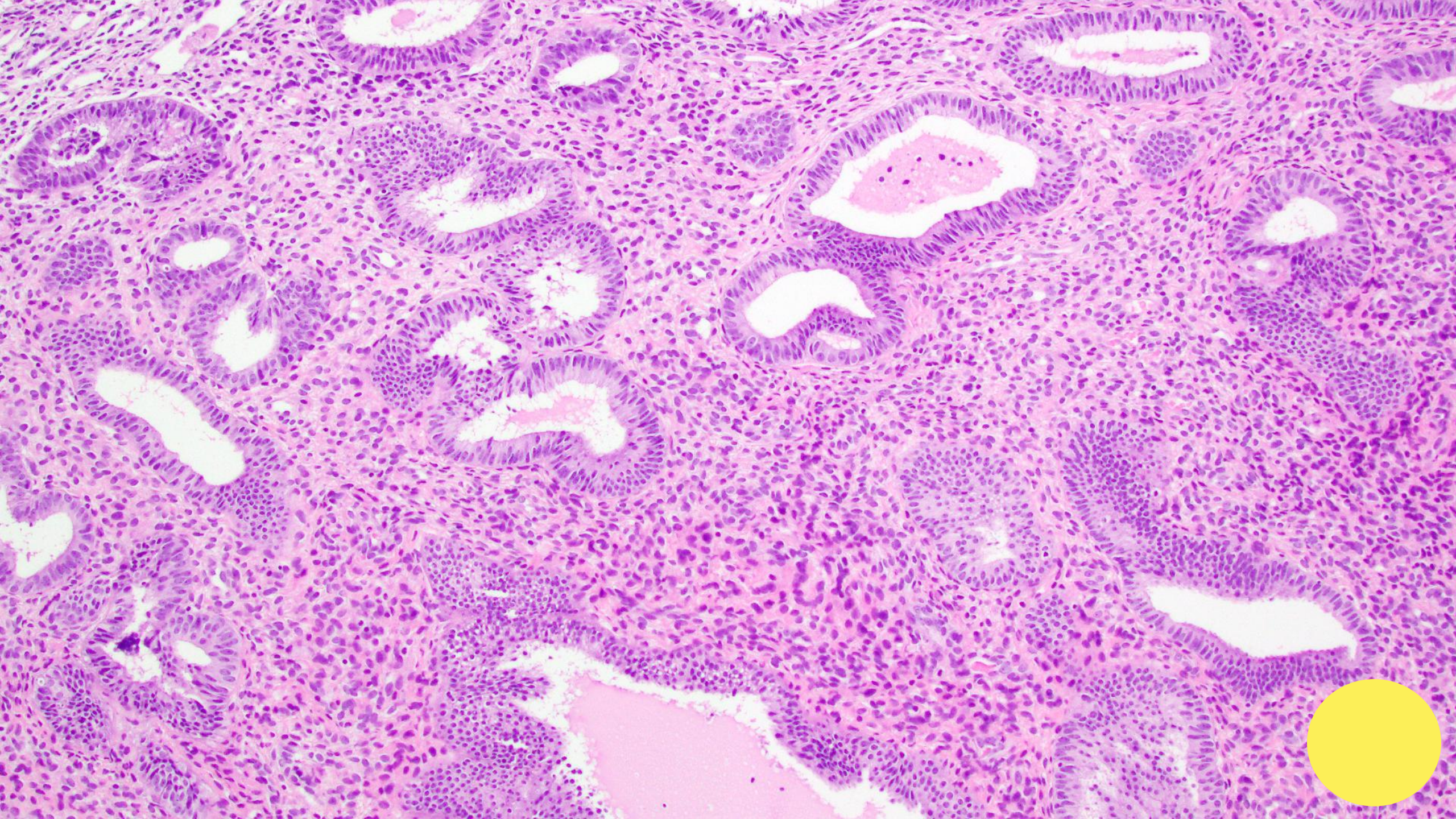

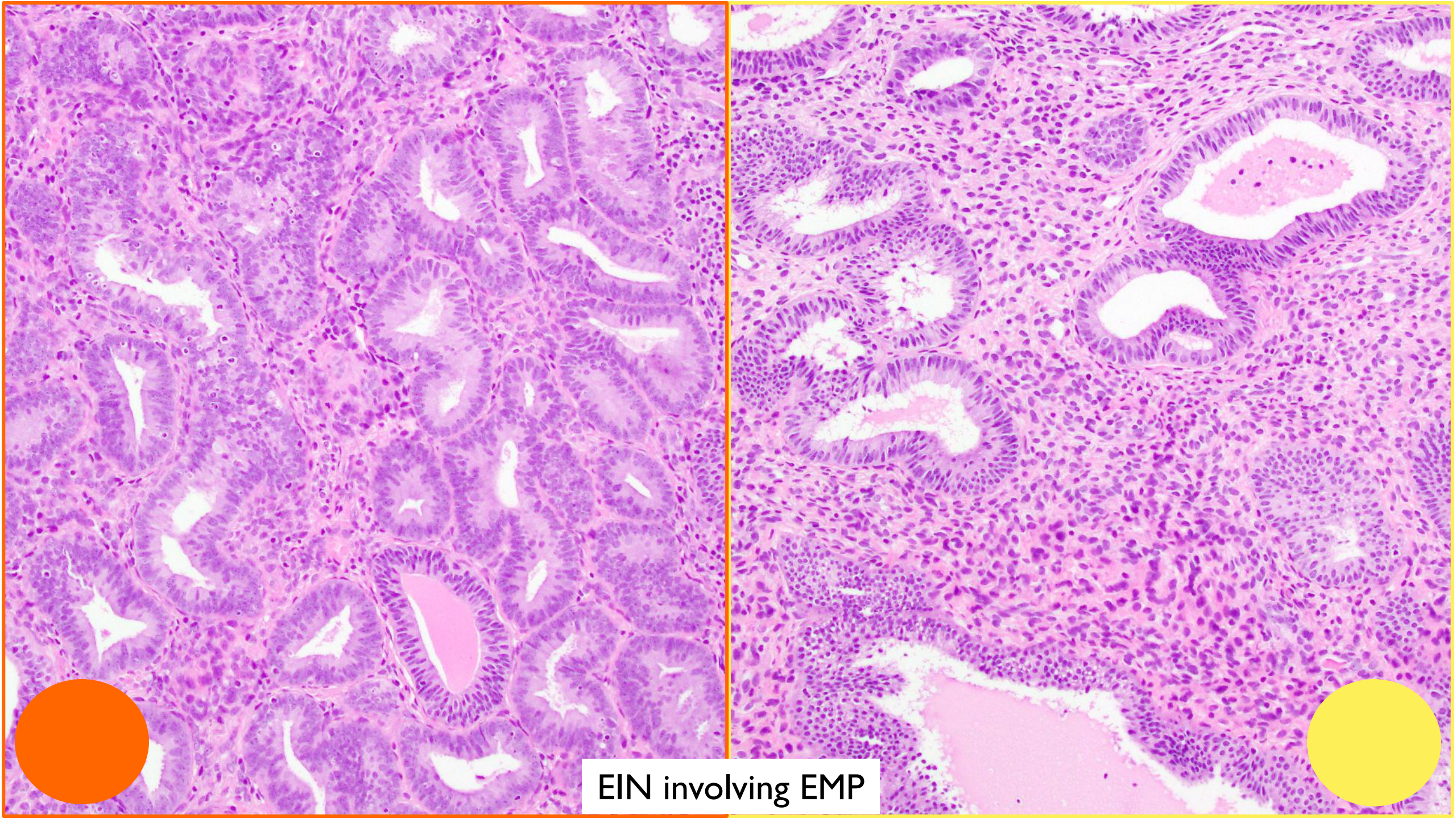
EIN involving EMP

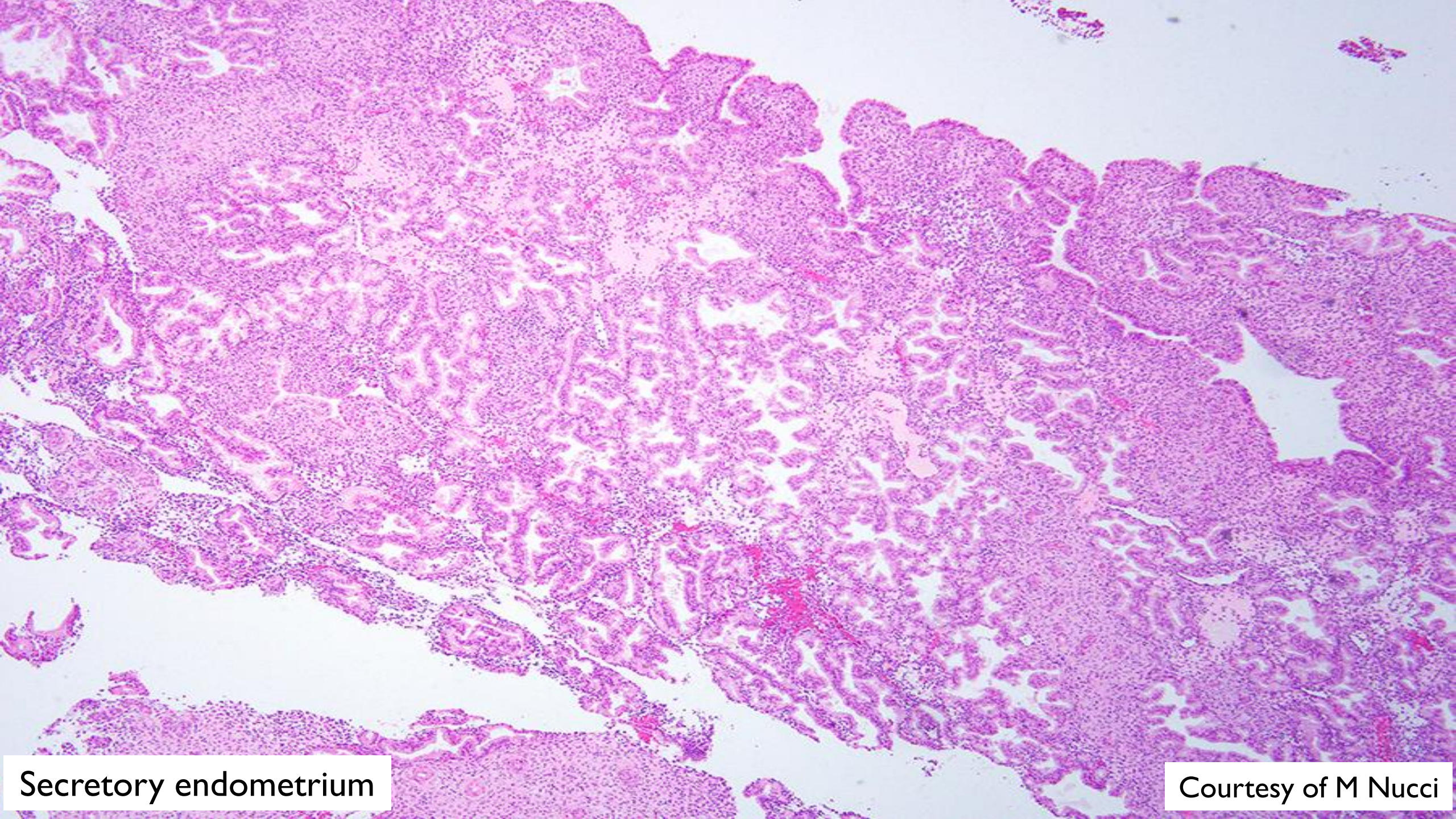

Secretory endometrium

Courtesy of M Nucci

SECRETORY VS NEOPLASTIC

- Diffusely crowded
- Orderly distribution
- Uniform cytologic appearance
- Minimal mitotic activity

- Typically localized (with exceptions)
- Haphazard / irregular orientation
- Divergent cytology
- Mitoses & apoptosis

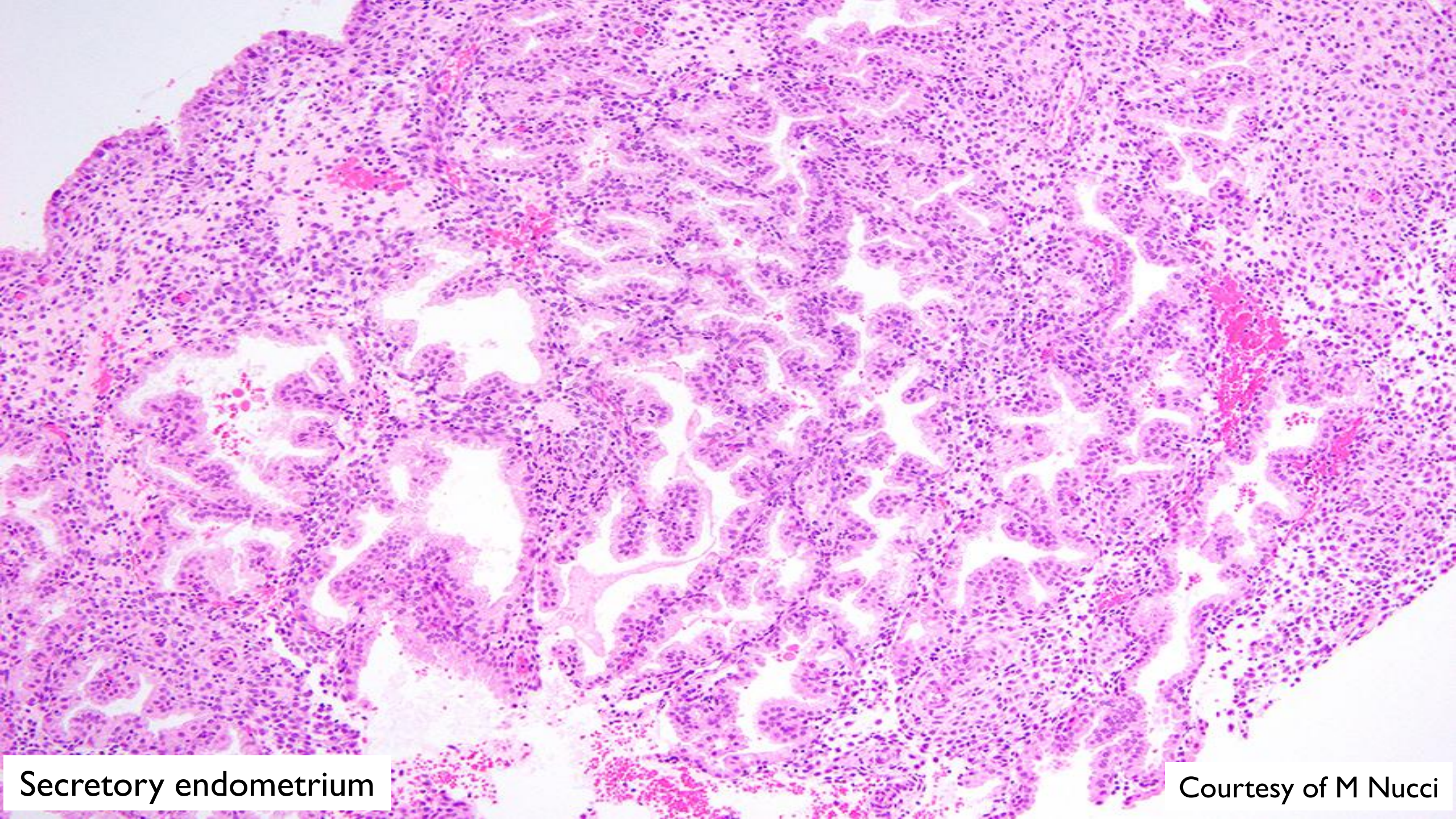

Secretory endometrium

Courtesy of M Nucci

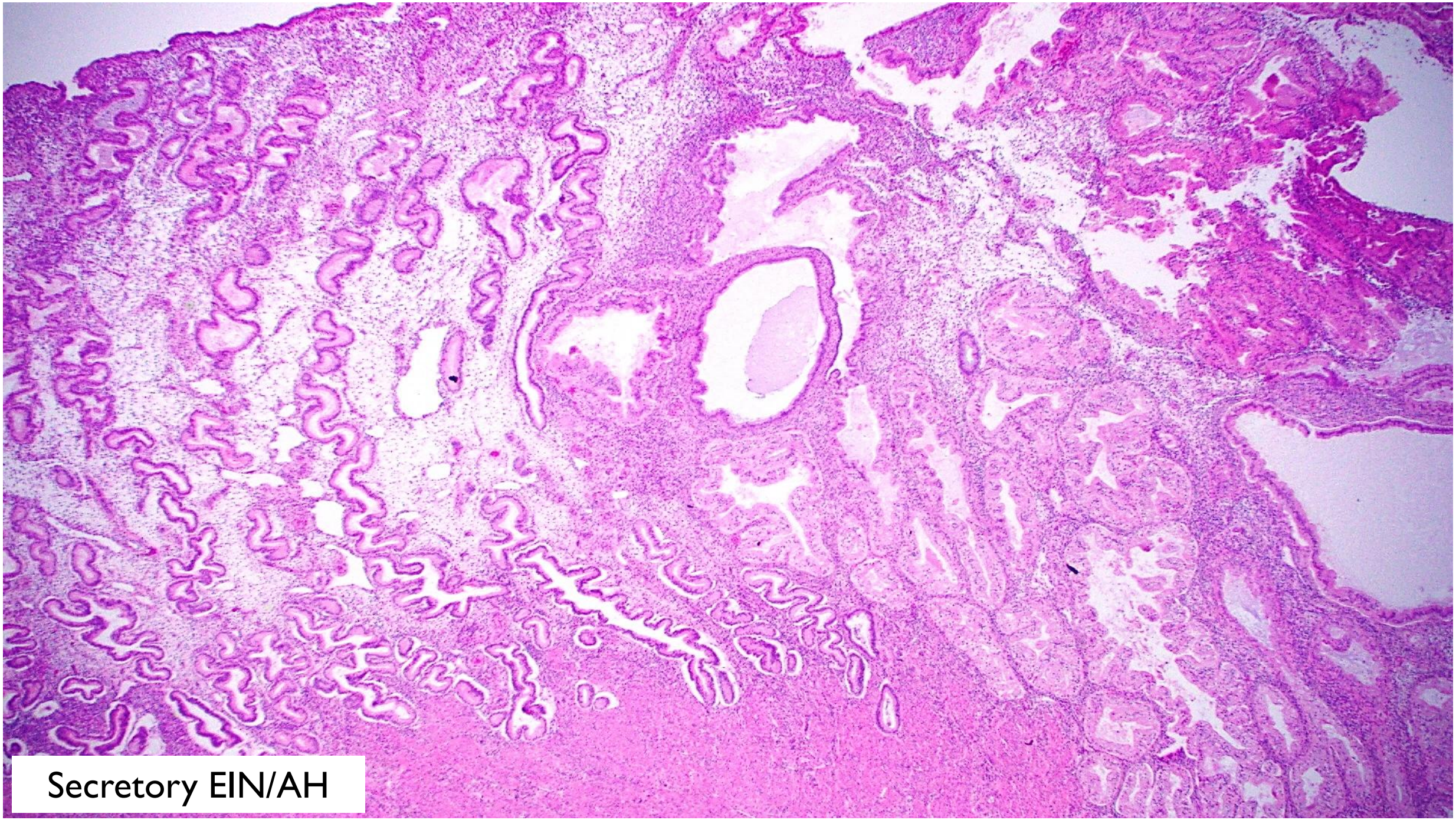
Secretory EIN/AH

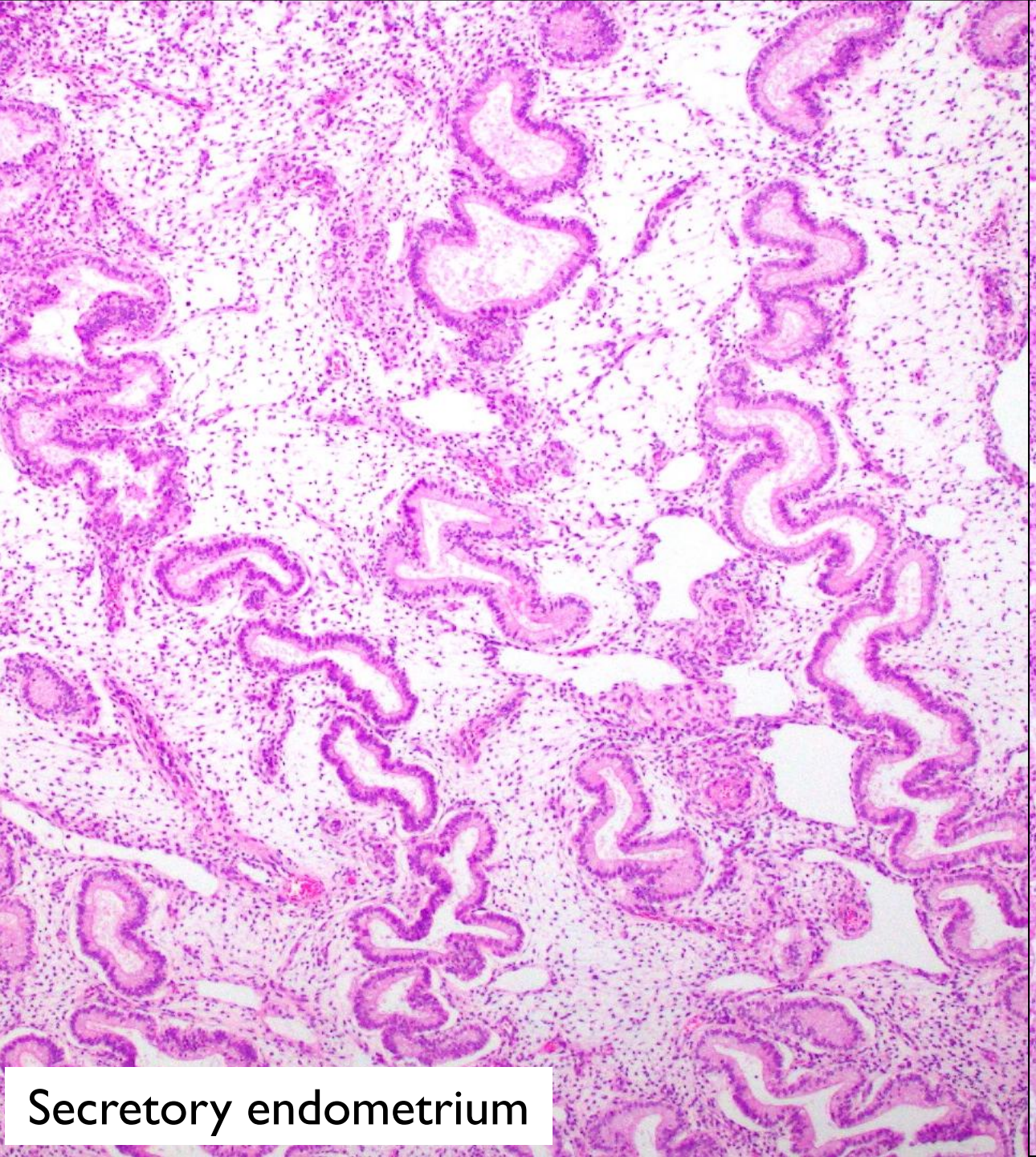
Secretory endometrium

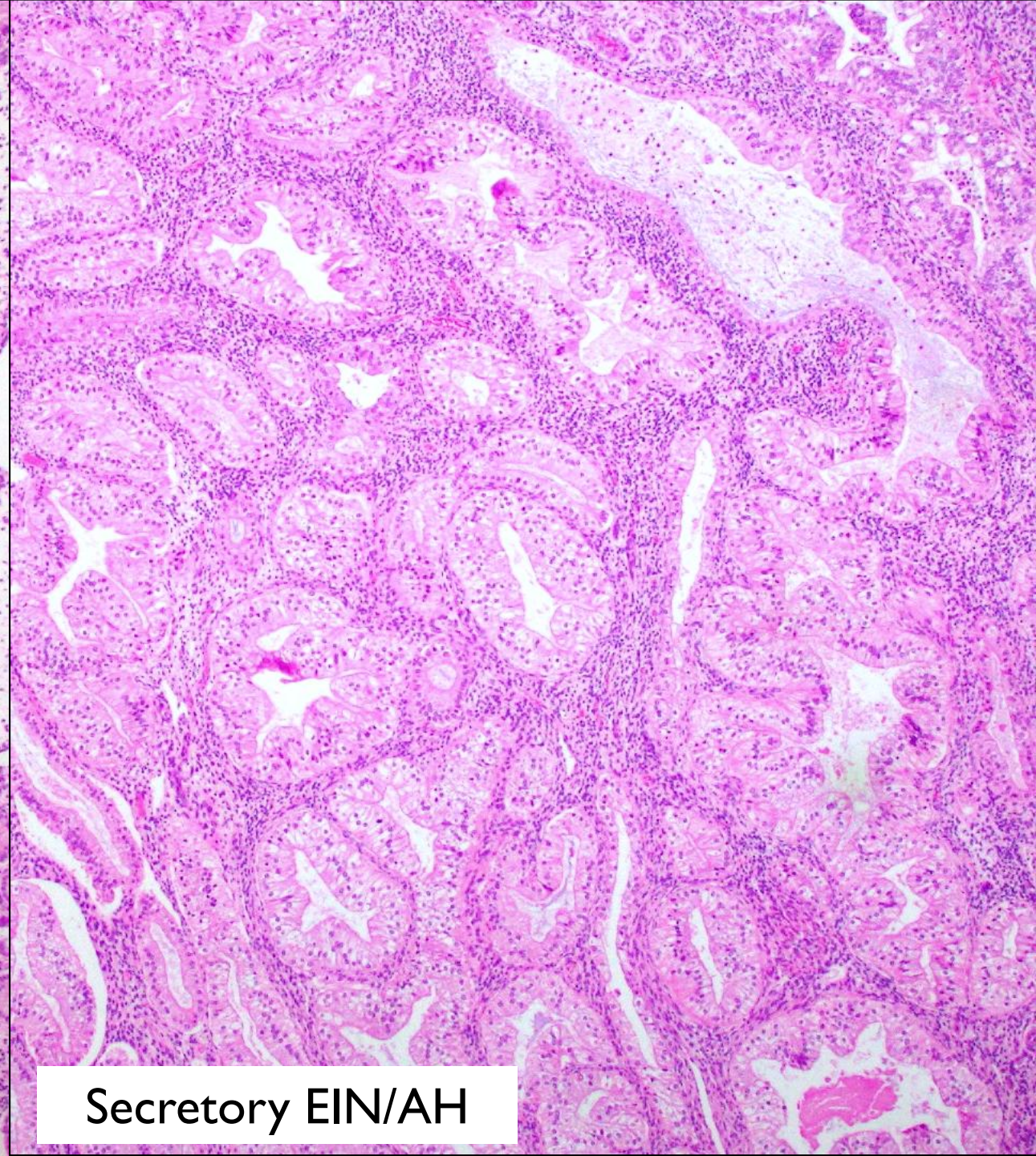
Secretory EIN/AH

DO NOT CONFUSE BASALIS WITH BACKGROUND

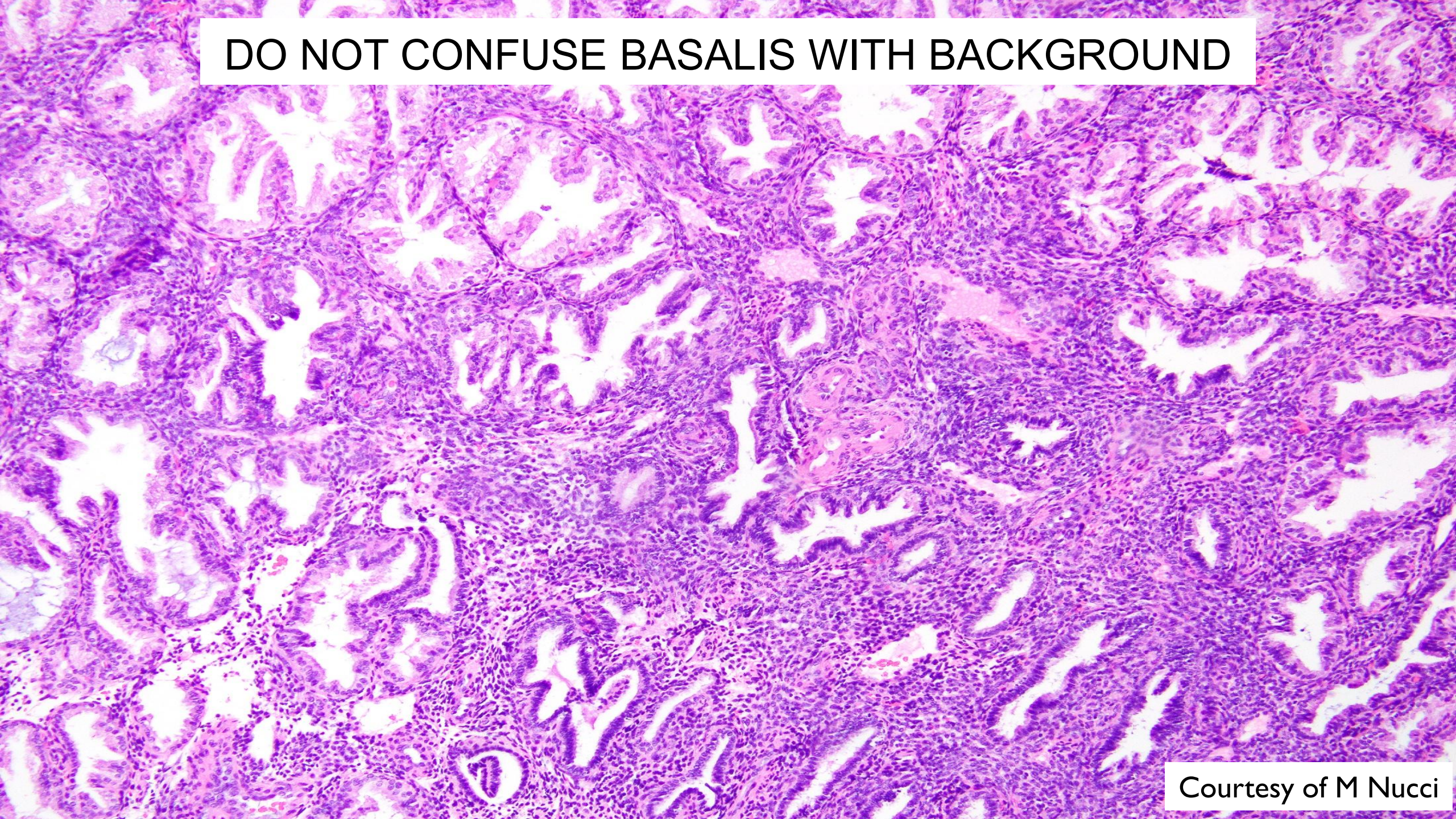

Courtesy of M Nucci

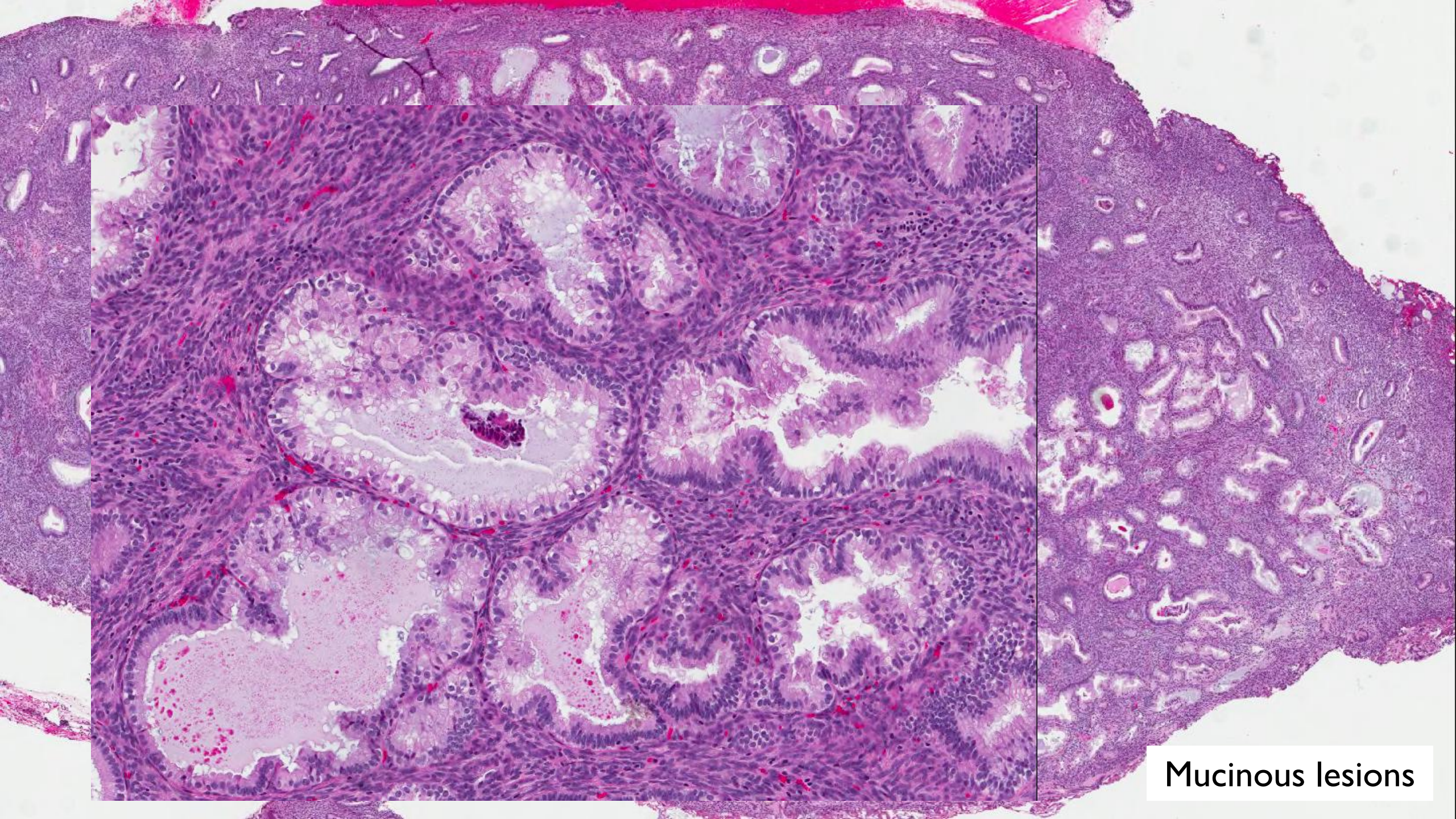

Mucinous lesions

THE EIN APPROACH

- Crowded glands (gland : stroma ratio > 1)
- Cytologic demarcation
- Exclude mimickers that feature crowding
  - Endometrial polyp
  - Secretory endometrium
- >1 mm in largest linear dimension

The EIN (Endometrioid Intraepithelial Neoplasia) Approach

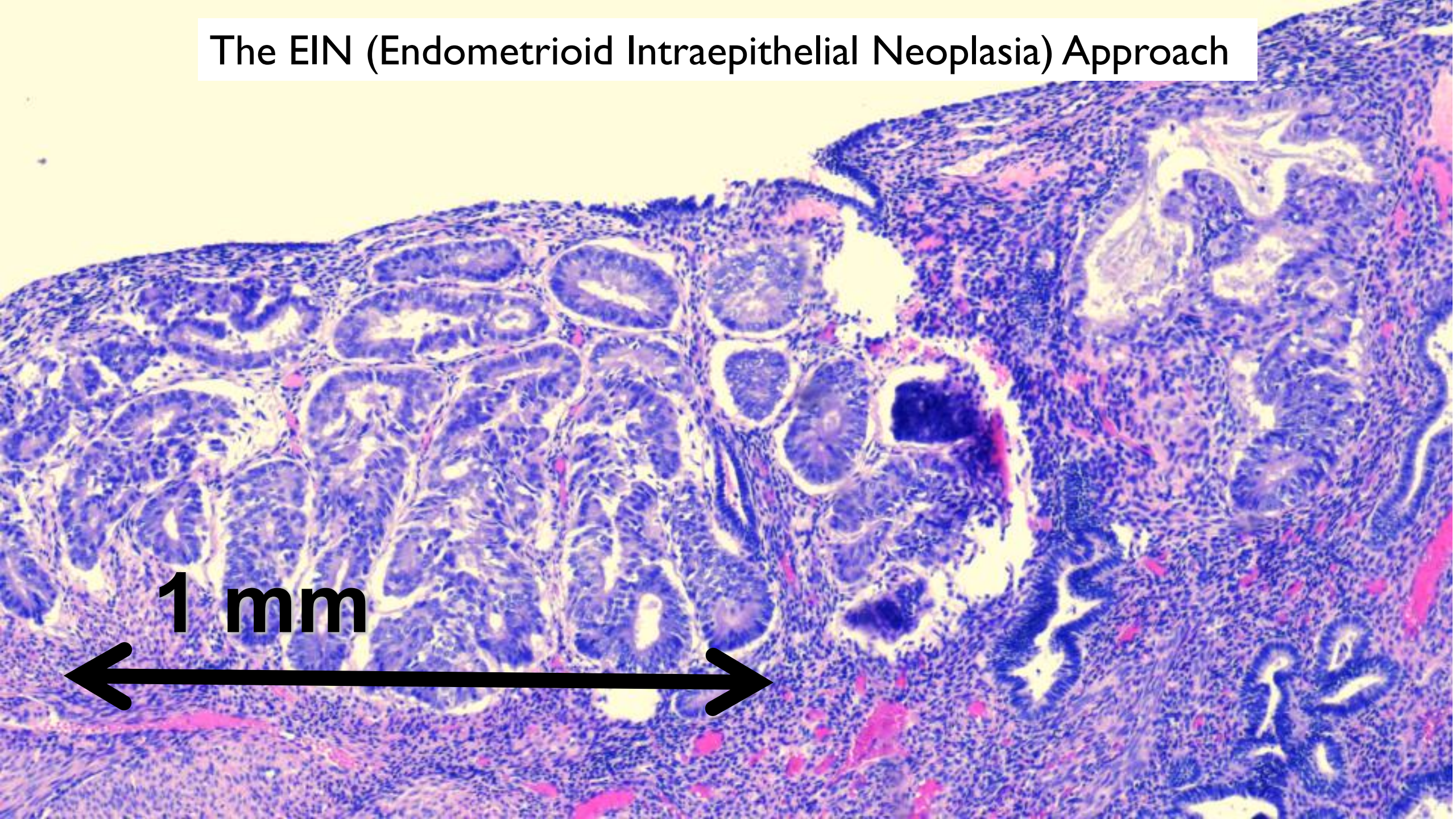

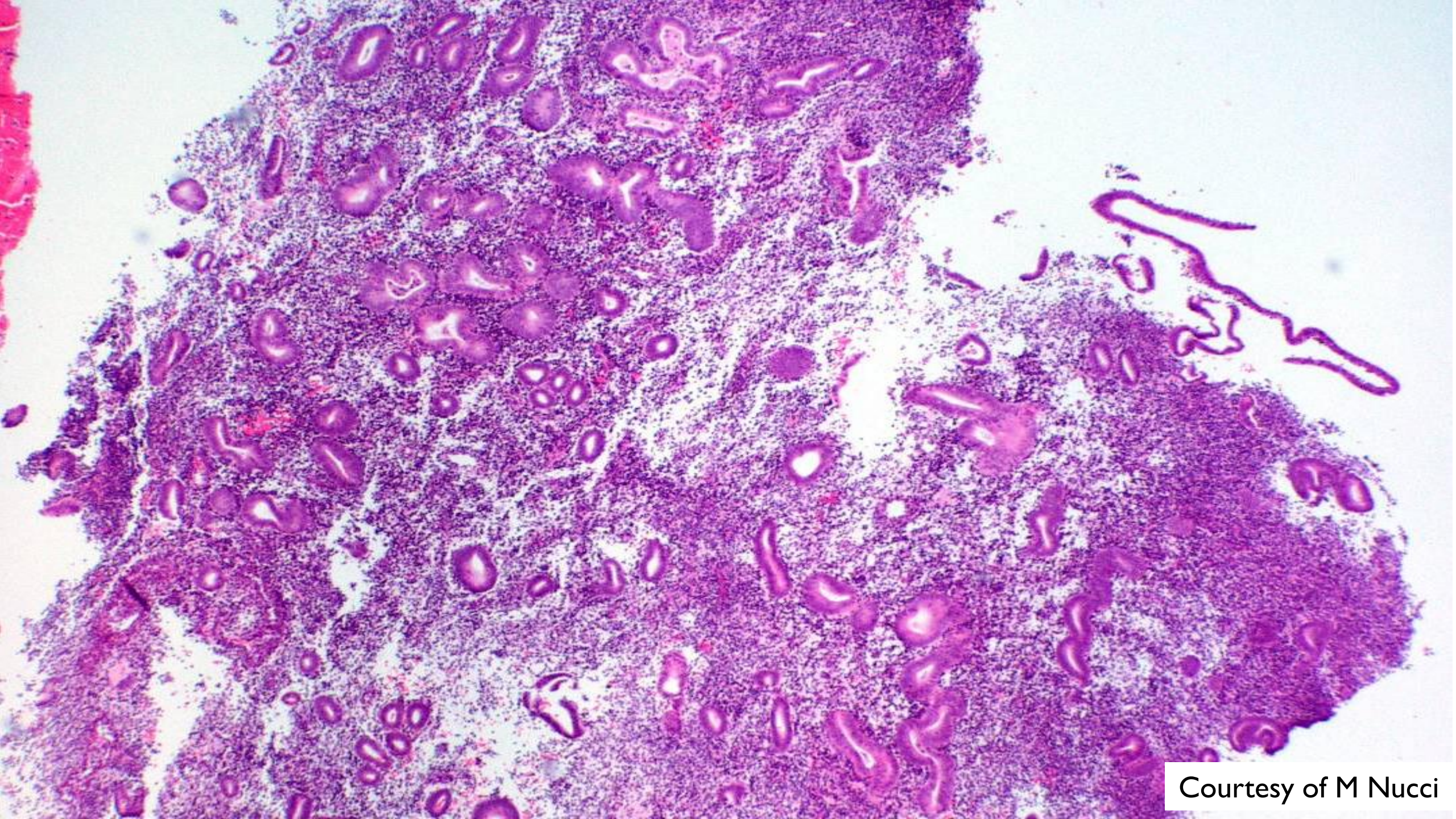

Courtesy of M Nucci

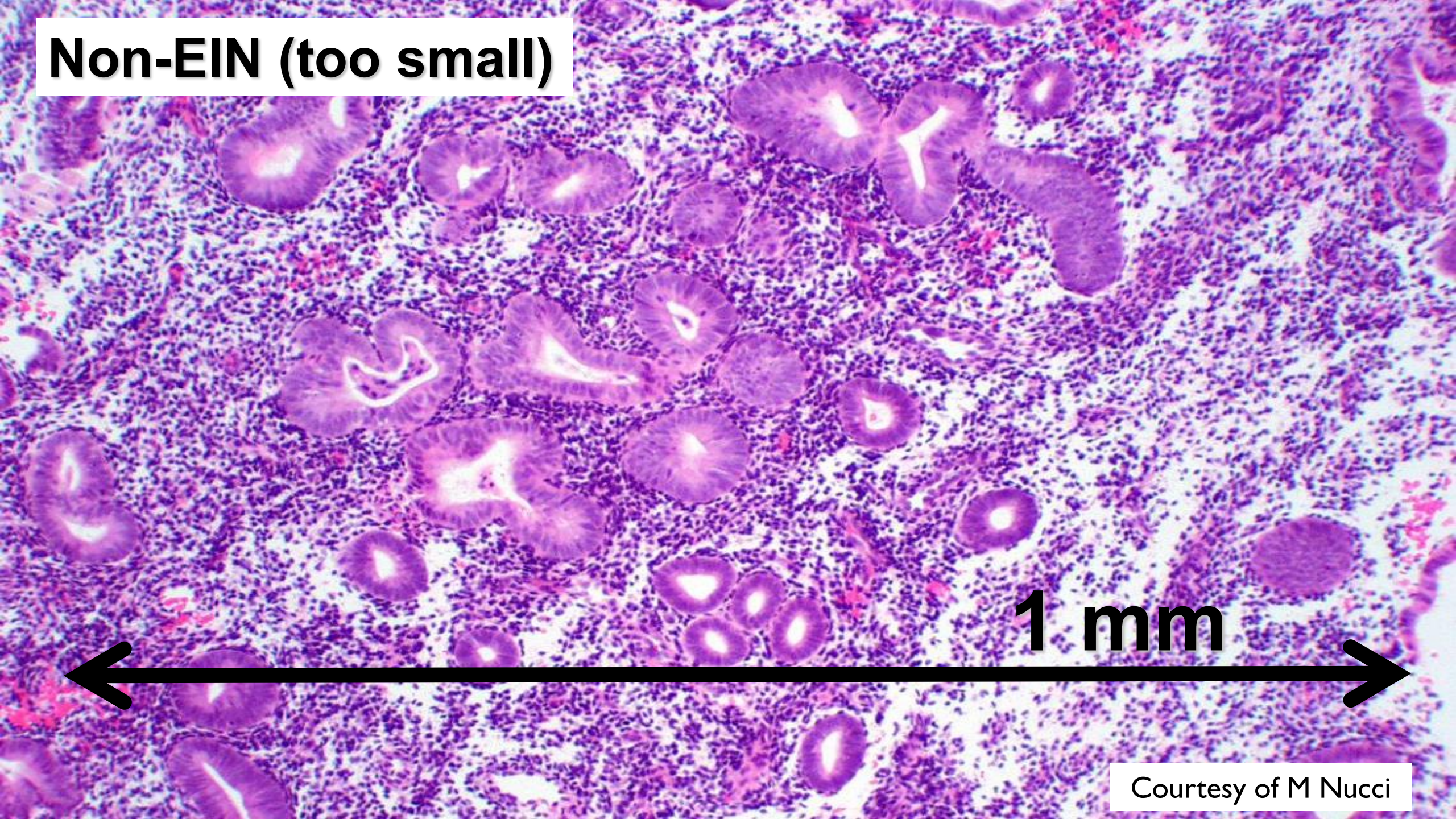
Non-EIN (too small)
1 mm
Courtesy of M Nucci

GLAND CROWDING ON EMBx

Mod Pathol. 2010 Nov;23(11):1486-91. doi: 10.1038/modpathol.2010.140. Epub 2010 Jul 30.

Clinical outcome in diagnostically ambiguous foci of 'gland crowding' in the endometrium

Eric C Huang [1], George L Mutter, Christopher P Crum, Marisa R Nucci

Affiliations + expand

PMID: 20676062 DOI: 10.1038/modpathol.2010.140

- Uncommon scenario = 206 out of 71,579 EMBx in 10 years (0.3%)
- 143 (69%) with follow-up biopsy (one or more)

GLAND CROWDING ON EMBX

- 16-19% have subsequent EIN or carcinoma
  - Most cases diagnosed within 1 year
  - Median time to Dx of endometrioid neoplasia: 8 months
- Recommend follow-up sampling
  - Usually 3-9 months

Mod Pathol 2010;23:1486-91
Histopathology 2024;85:579-589

AN APPROACH TO GLAND CROWDING

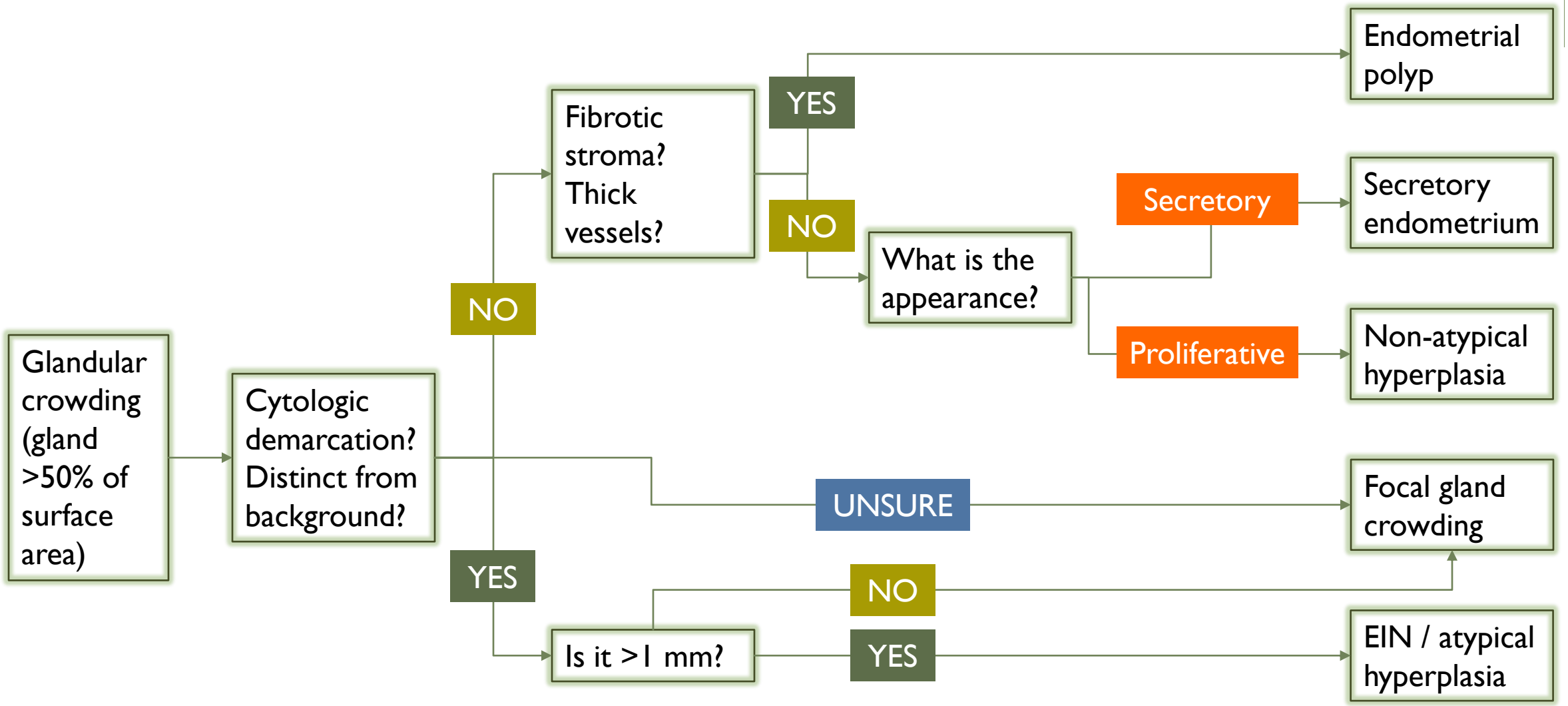

CAN IMMUNOHISTOCHEMISTRY HELP?



"The honest package you will never see."



IHC IN EIN/AH DIAGNOSIS

- EIN cases (n = 111)
- PAX2, PTEN, B-Catenin, MLH1, ARID1A, p53
- Most cases showed aberrant expression of ≥2 markers
- Sensitivity 93%

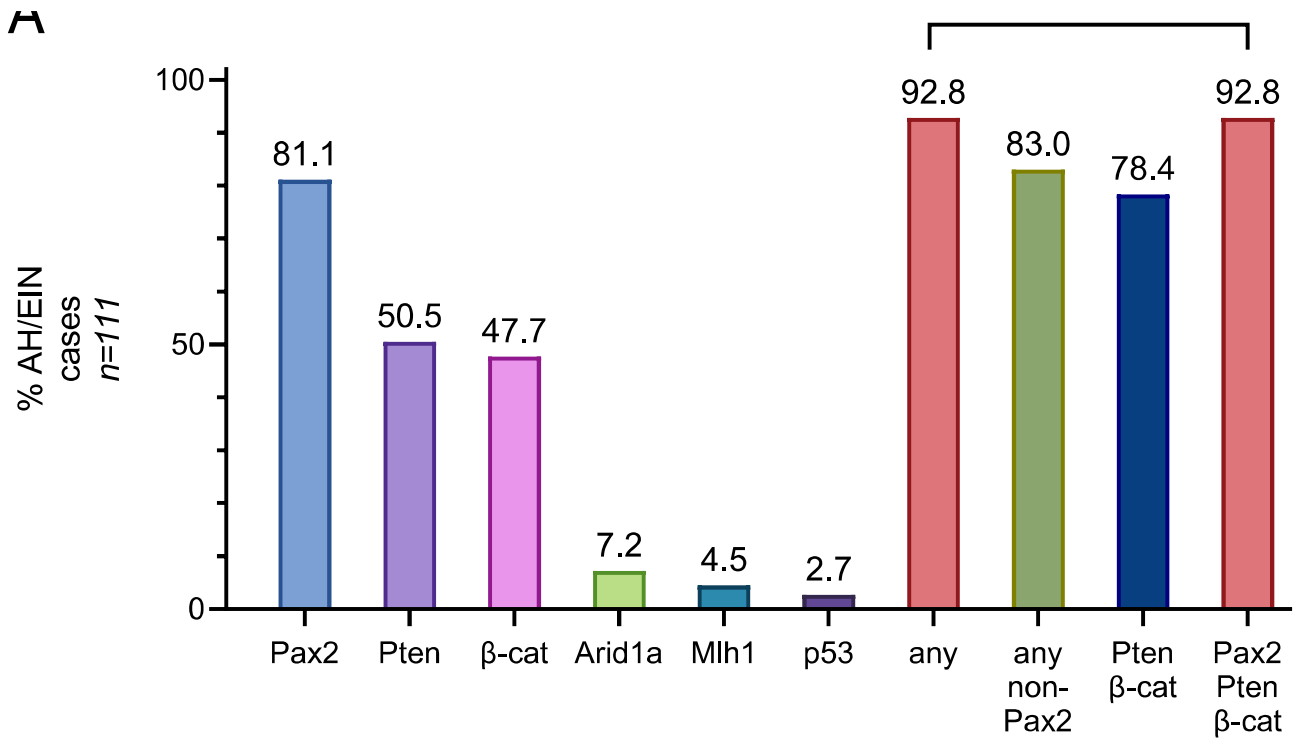

Am J Surg Pathol 2022;46:404-414

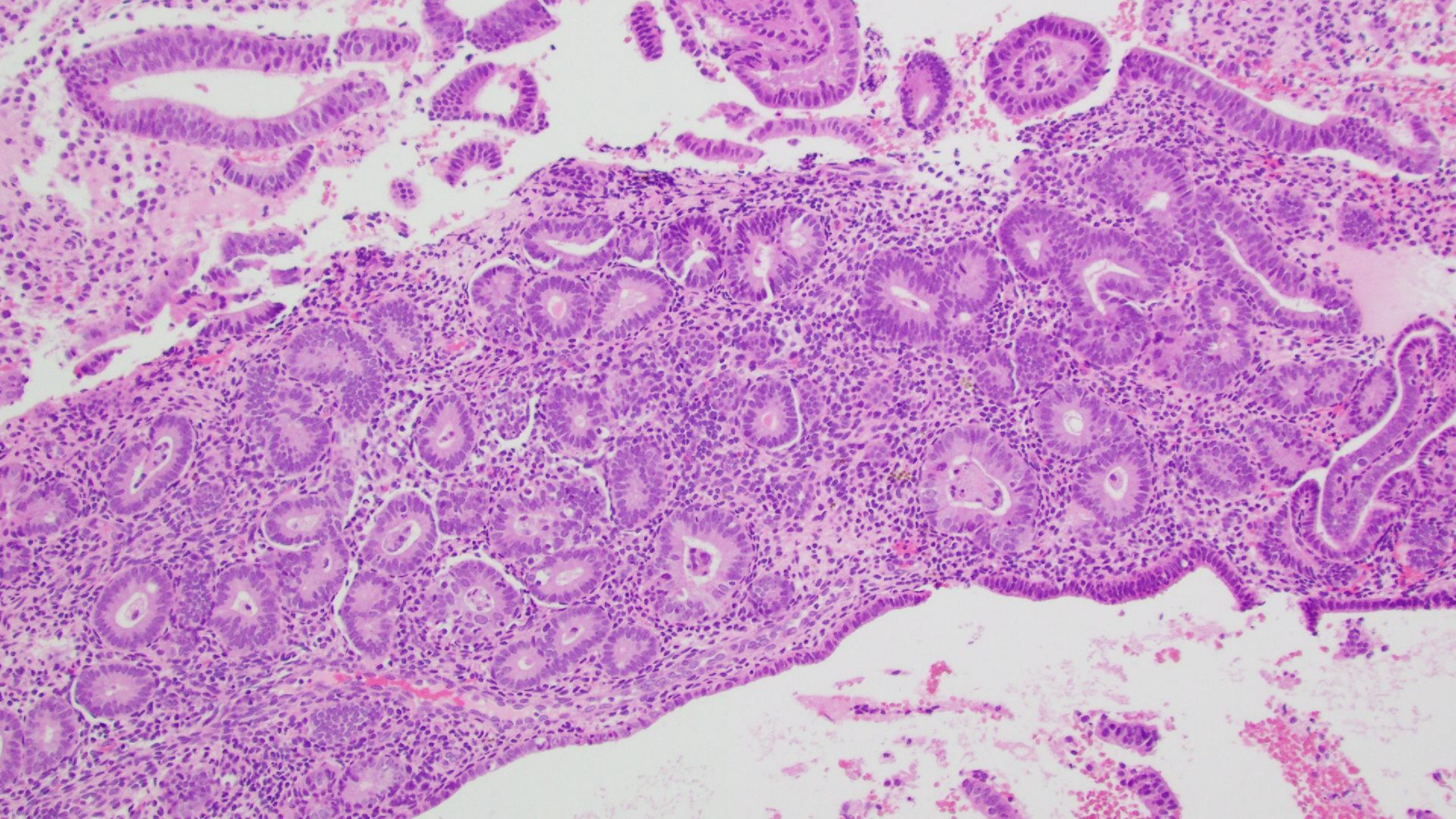

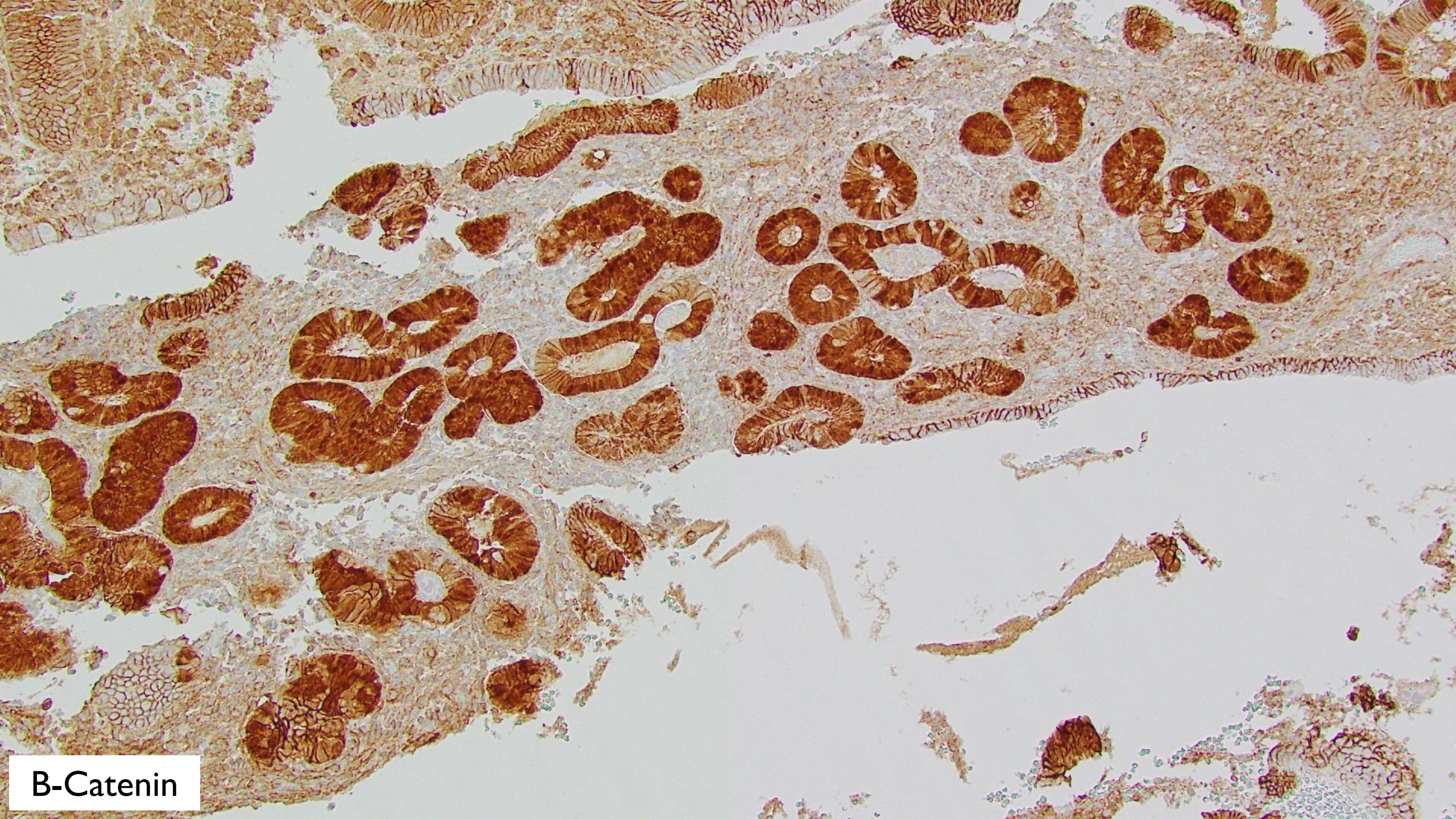
B-Catenin

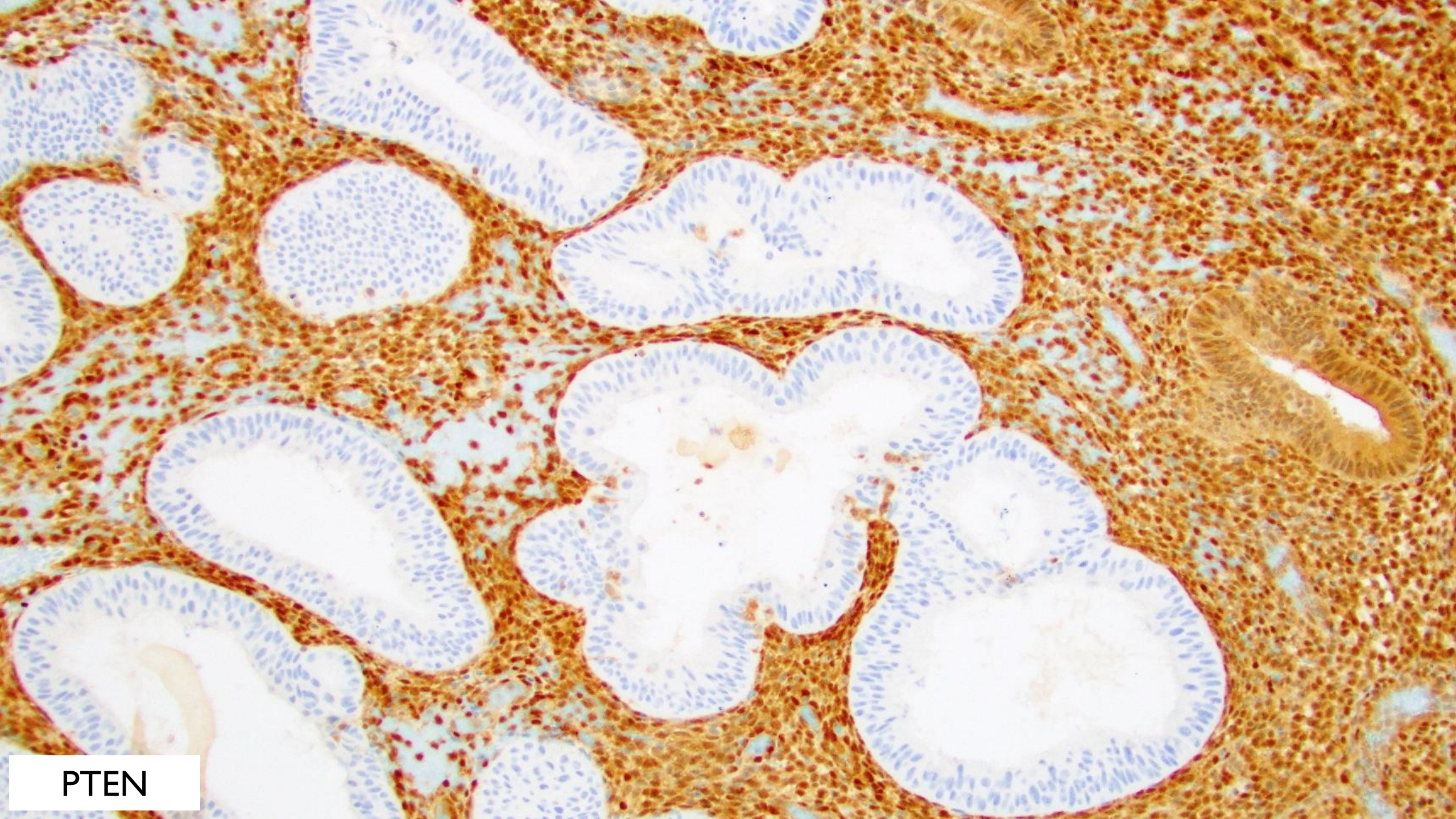
PTEN

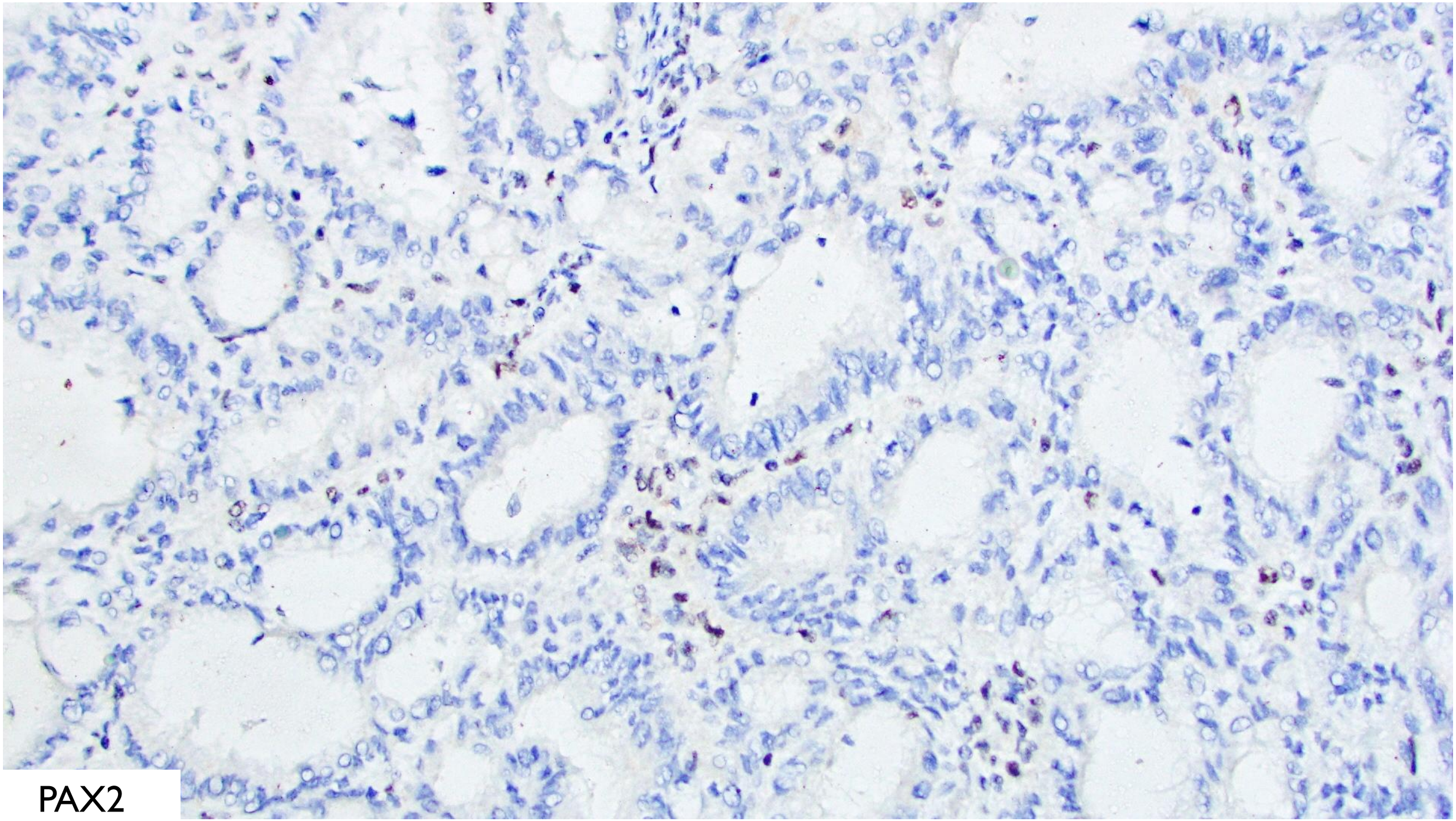
PAX2

CAN IMMUNOHISTOCHEMISTRY HELP?

- Tested in bona fide EIN/AH cases
- What happens in sub-diagnostic cases (gland crowding)?
- *What's the outcome of "gland crowding" with abnormal IHC?*

β-catenin, Pax2, and Pten Panel Identifies Precancers Among Histologically Subdiagnostic Endometrial Lesions

Mitzi Aguilar, BS, Hao Chen, MD, PhD,* Subhransu S. Sahoo, PhD,* Wenxin Zheng, MD,*†‡ Jessica Grubman, MD, MAS,† Jeffrey A. SoRelle, MD,*§ Elena Lucas, MD,*‡ and Diego H. Castrillon, MD, PhD*†‡*

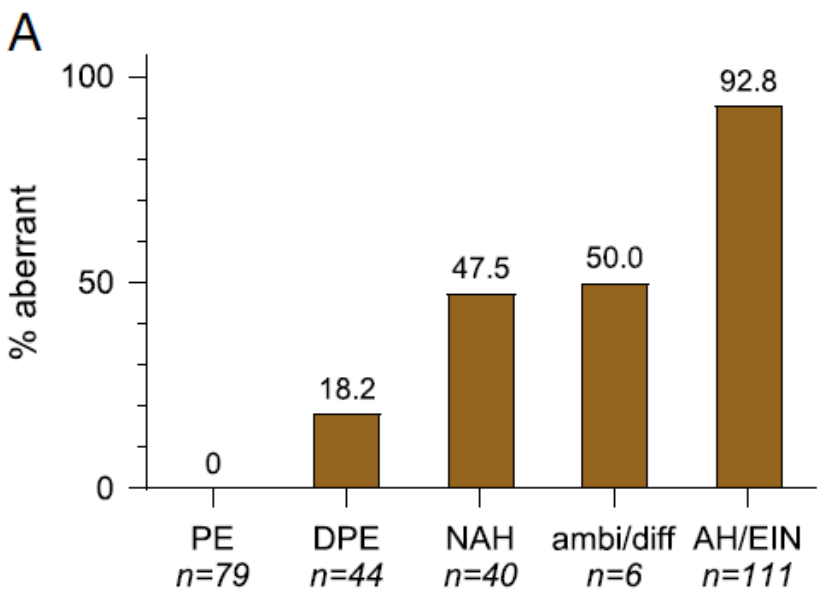

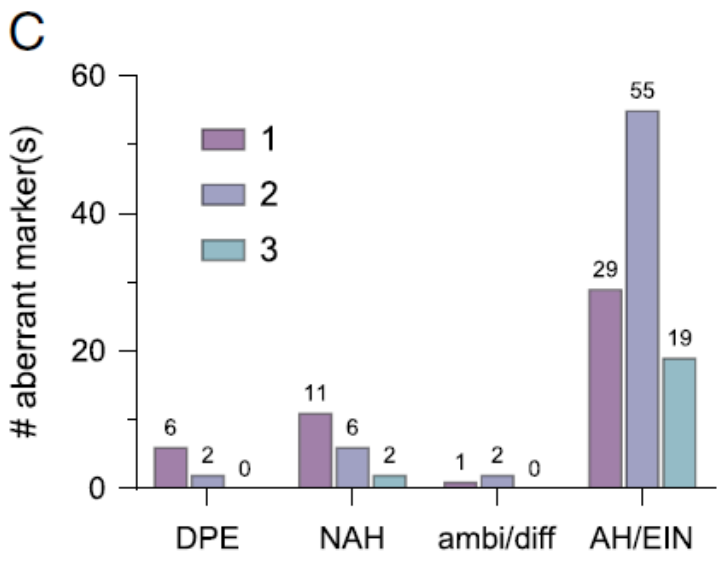

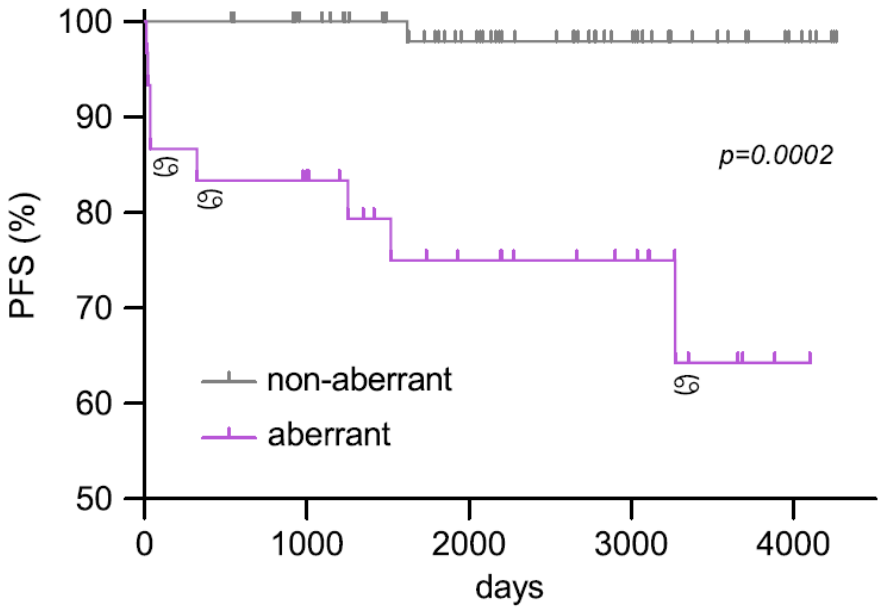

Am J Surg Pathol 2023 PMID 36939046

Gland crowding with neoplastic follow-up

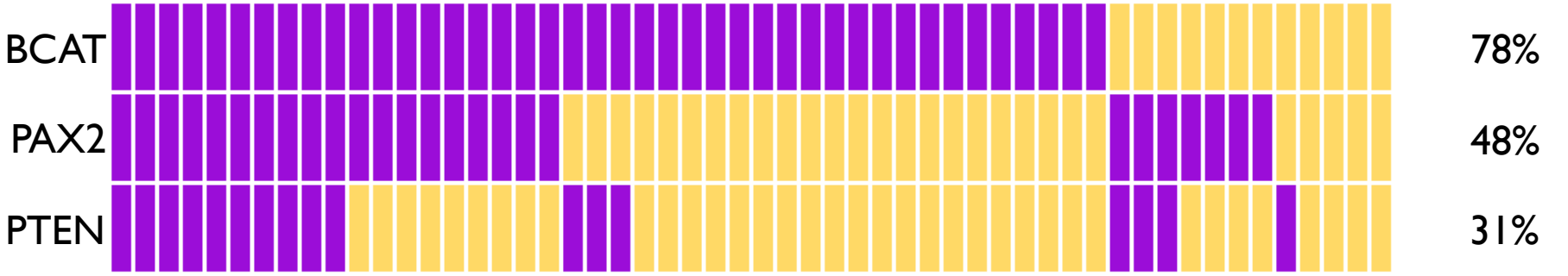

- Sensitivity: 93%
- Specificity: 39%

Gland crowding with benign follow-up



- PPV = 23%
- NPV = 96%

- Non-aberrant IHC is reassuring (very low prob of EIN/CA follow-up)
- Aberrant IHC is non-informative

Histopathology 2024;85:579-589

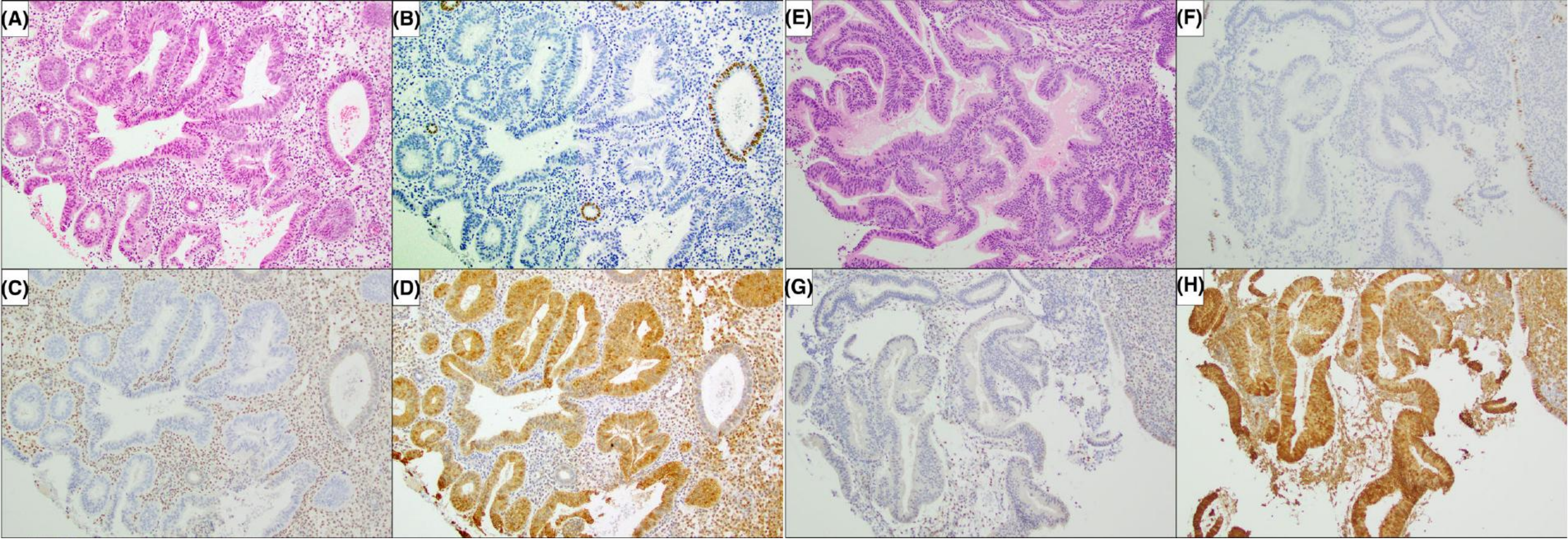

- Loss of PAX2
- Loss of PTEN
- Nuclear & cytoplasmic B-catenin
- EIN Dx 15 months later

- Loss of PAX2
- Markedly reduced PTEN
- Nuclear & cytoplasmic B-catenin
- Alive and well 26 months later

Histopathology 2024;85:579-589

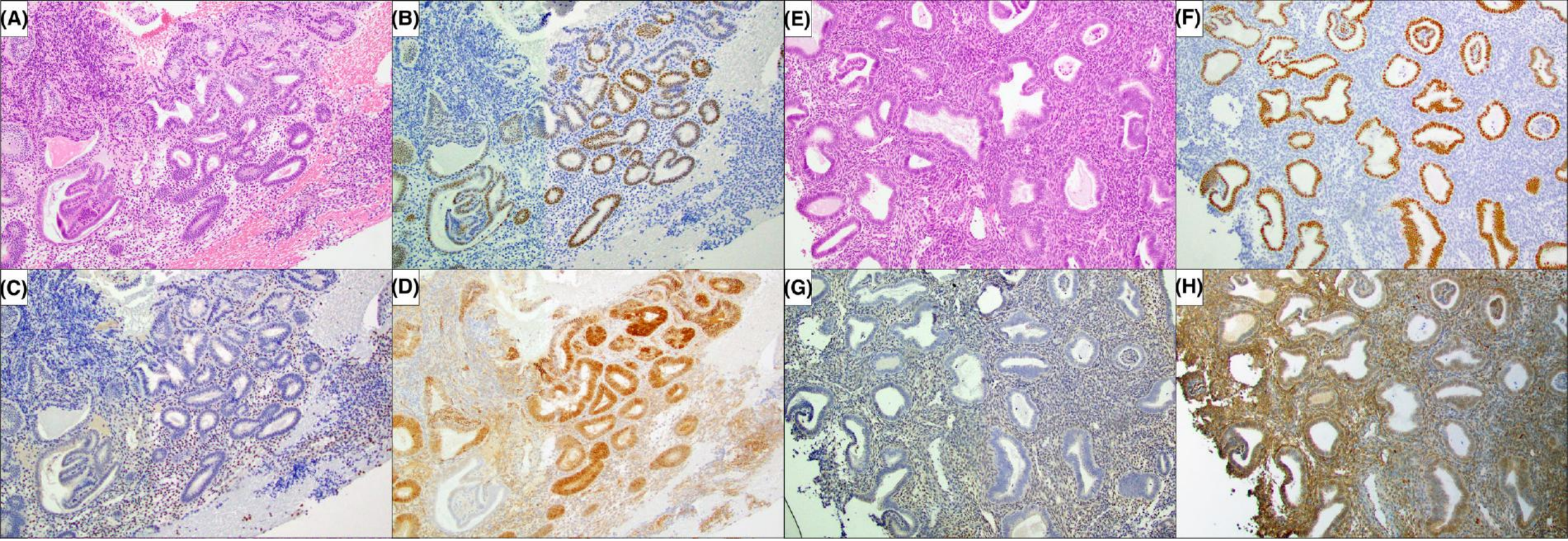

- Retained PAX2
- Loss of PTEN
- Nuclear & cytoplasmic B-catenin
- Alive and well 112 months later

- Loss of PAX2
- Loss of PTEN
- Membranous B-catenin
- Alive and well 105 months later

Histopathology 2024;85:579-589

IMMUNOHISTOCHEMISTRY IN EIN DX

- Still controversial
- WHO 2025 (draft): IHC *NOT* listed as essential criterion
- Do not perform routinely
- Helpful if normal staining patterns (excludes EIN)

Endometrial endometroid adenoCA

- Increased glandular density with confluence and complex architecture
  - Cribriform
  - Papillary

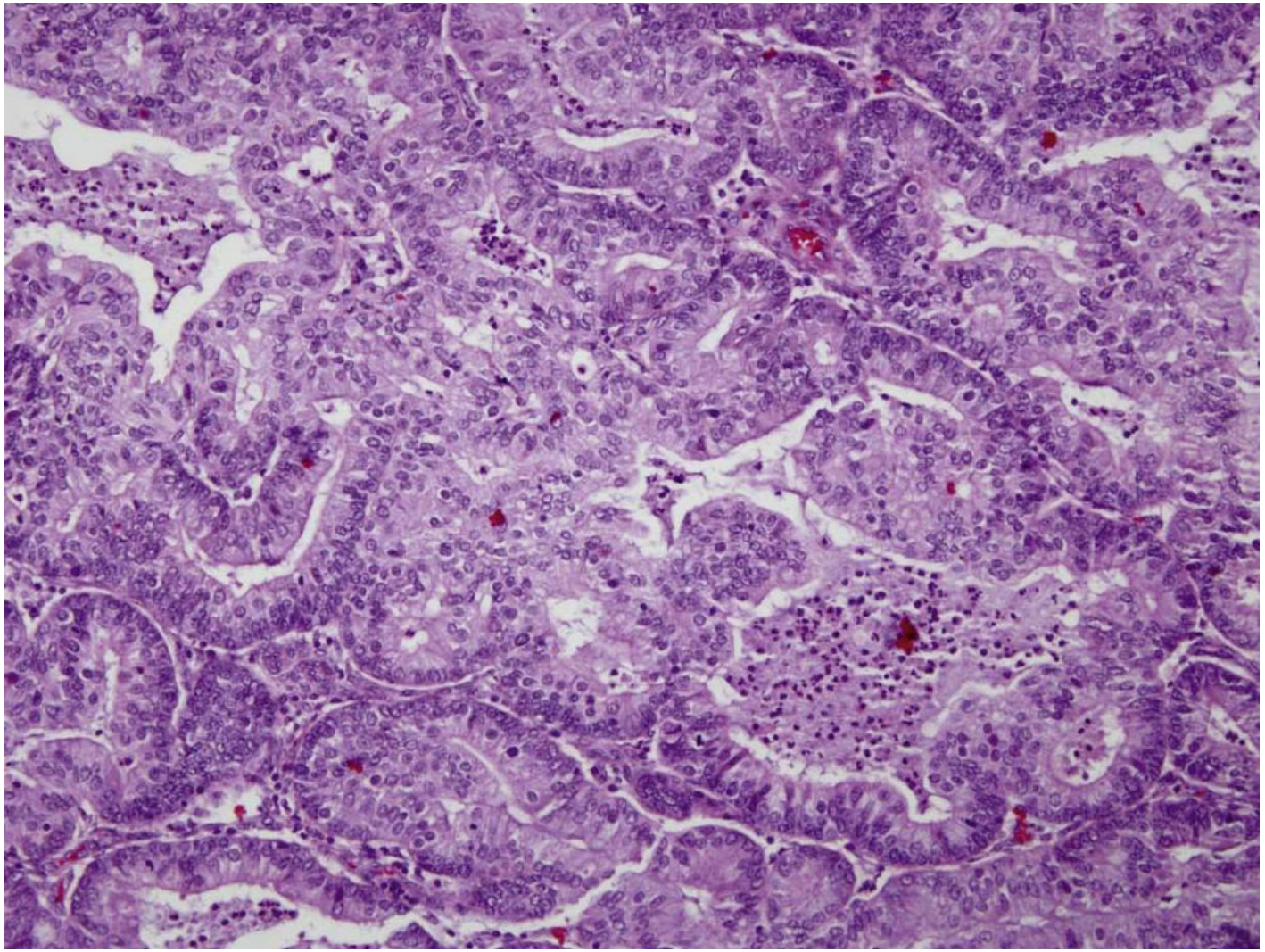

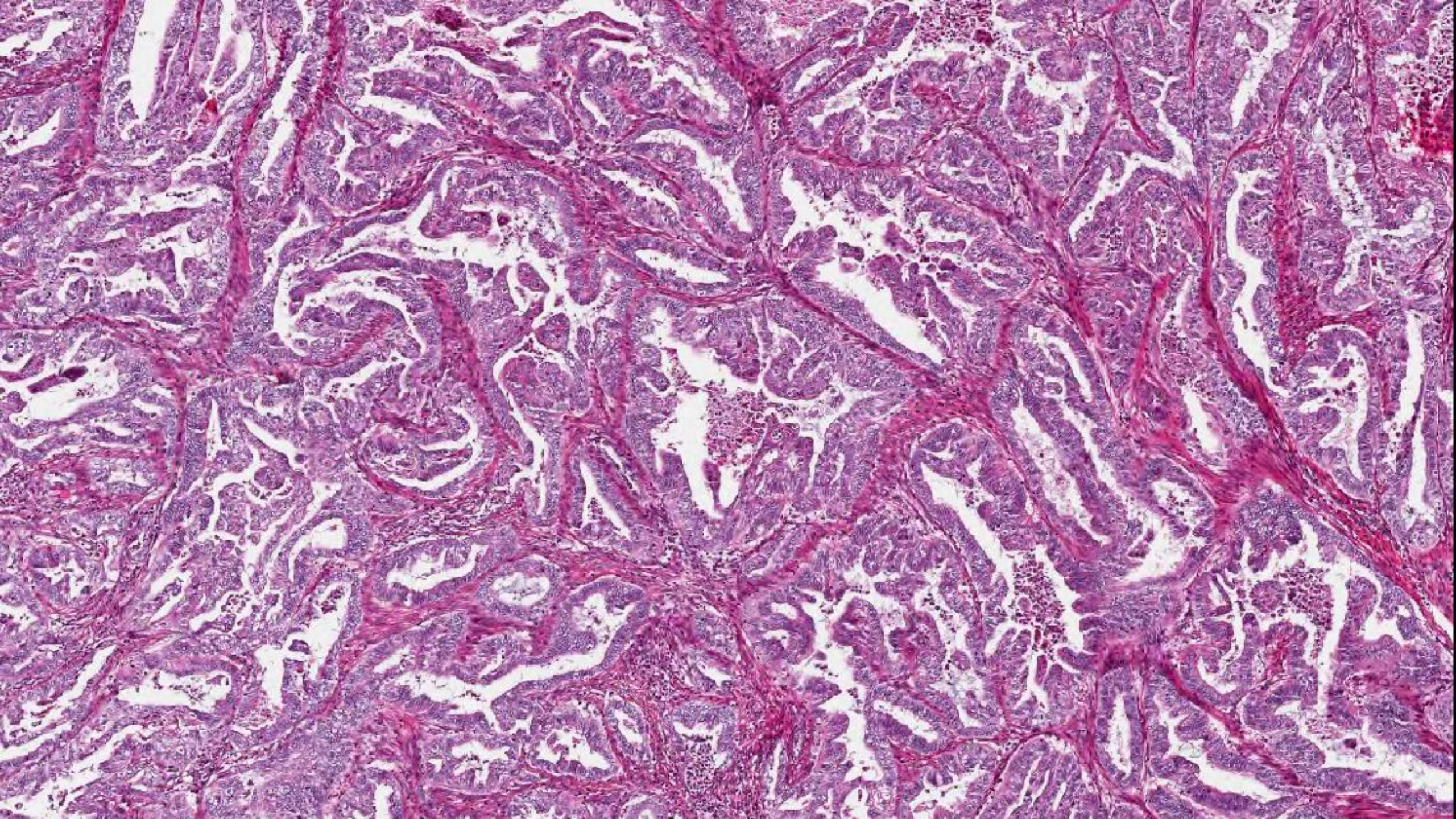

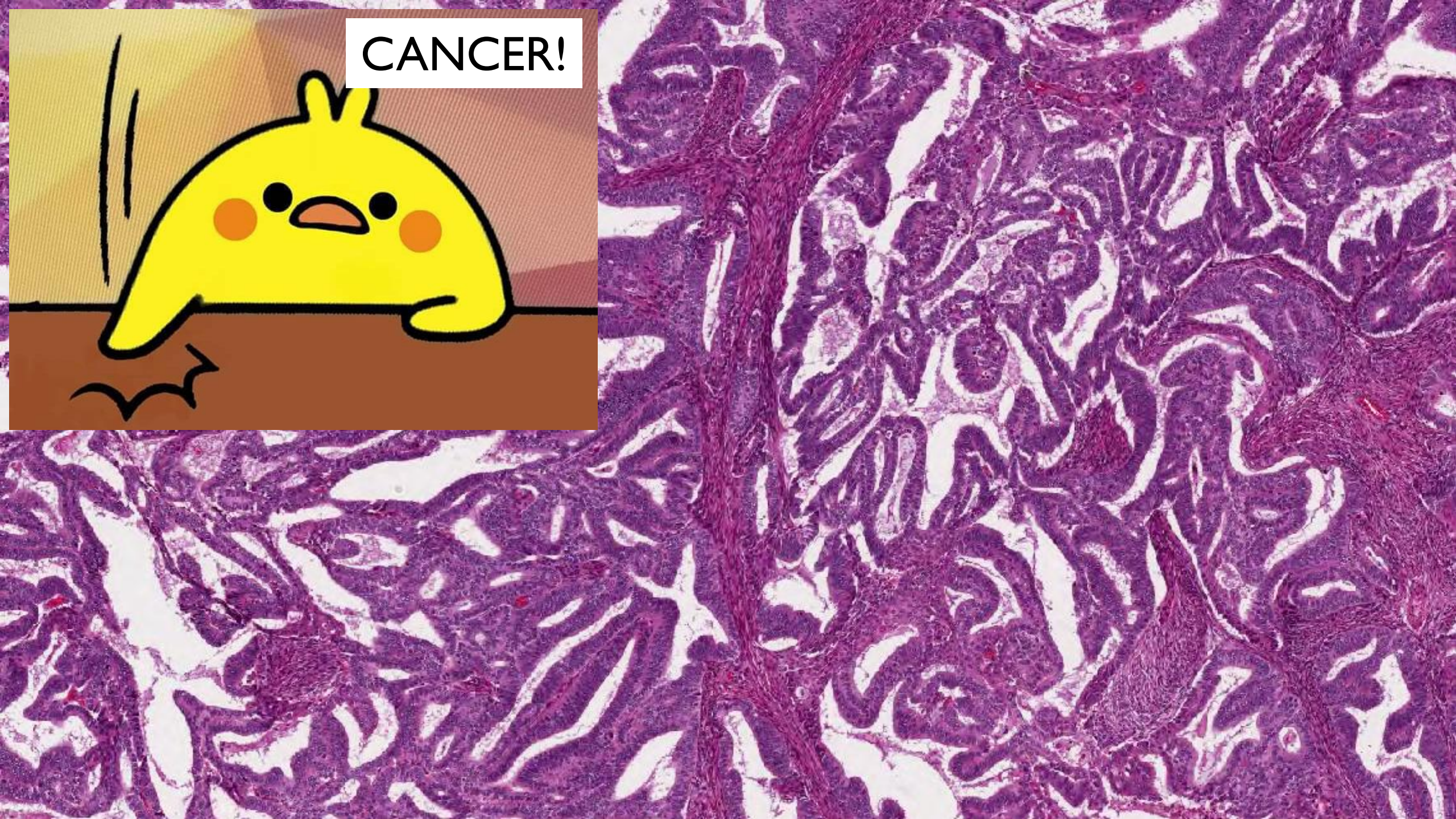
CANCER!

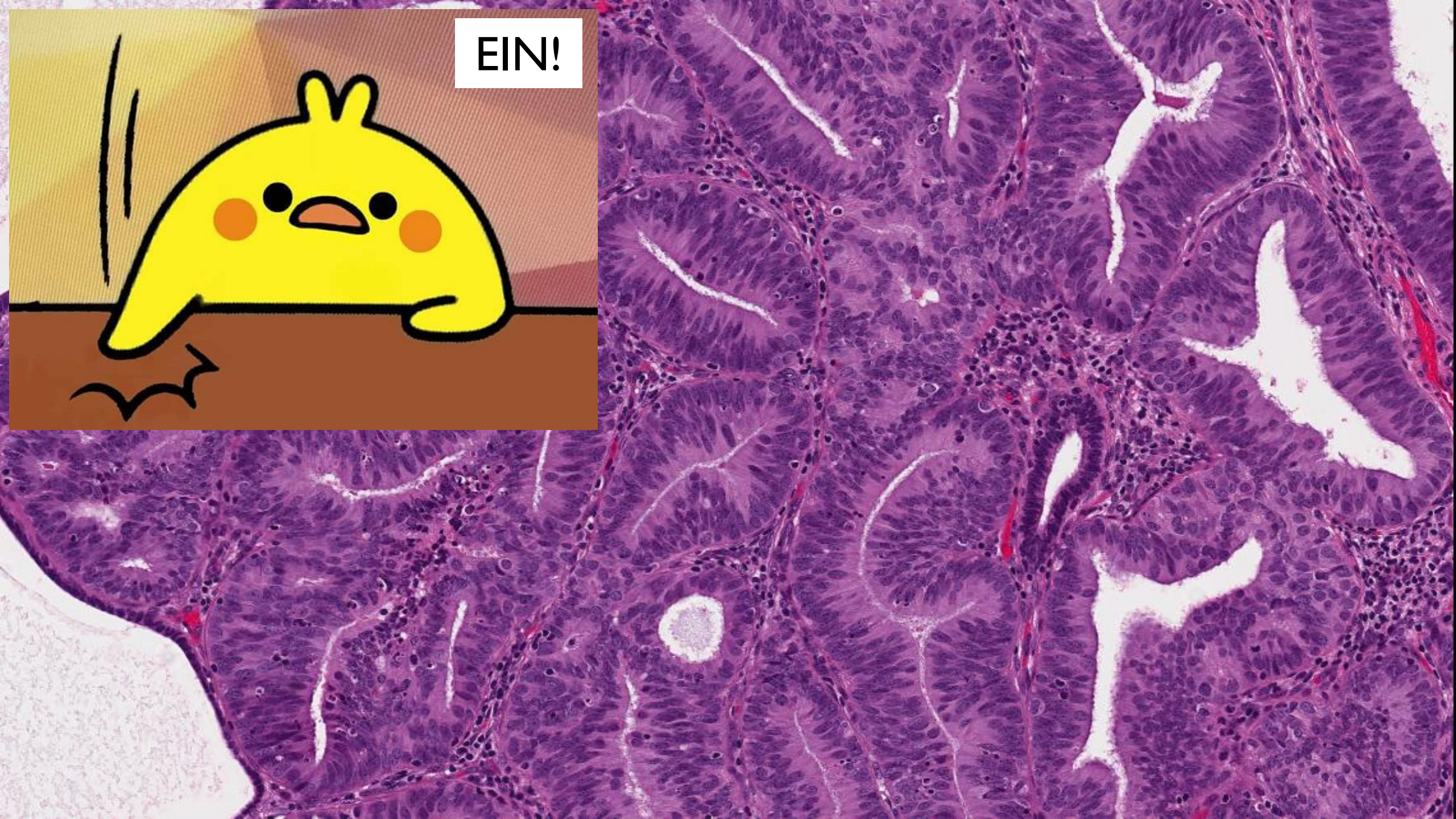
EIN!

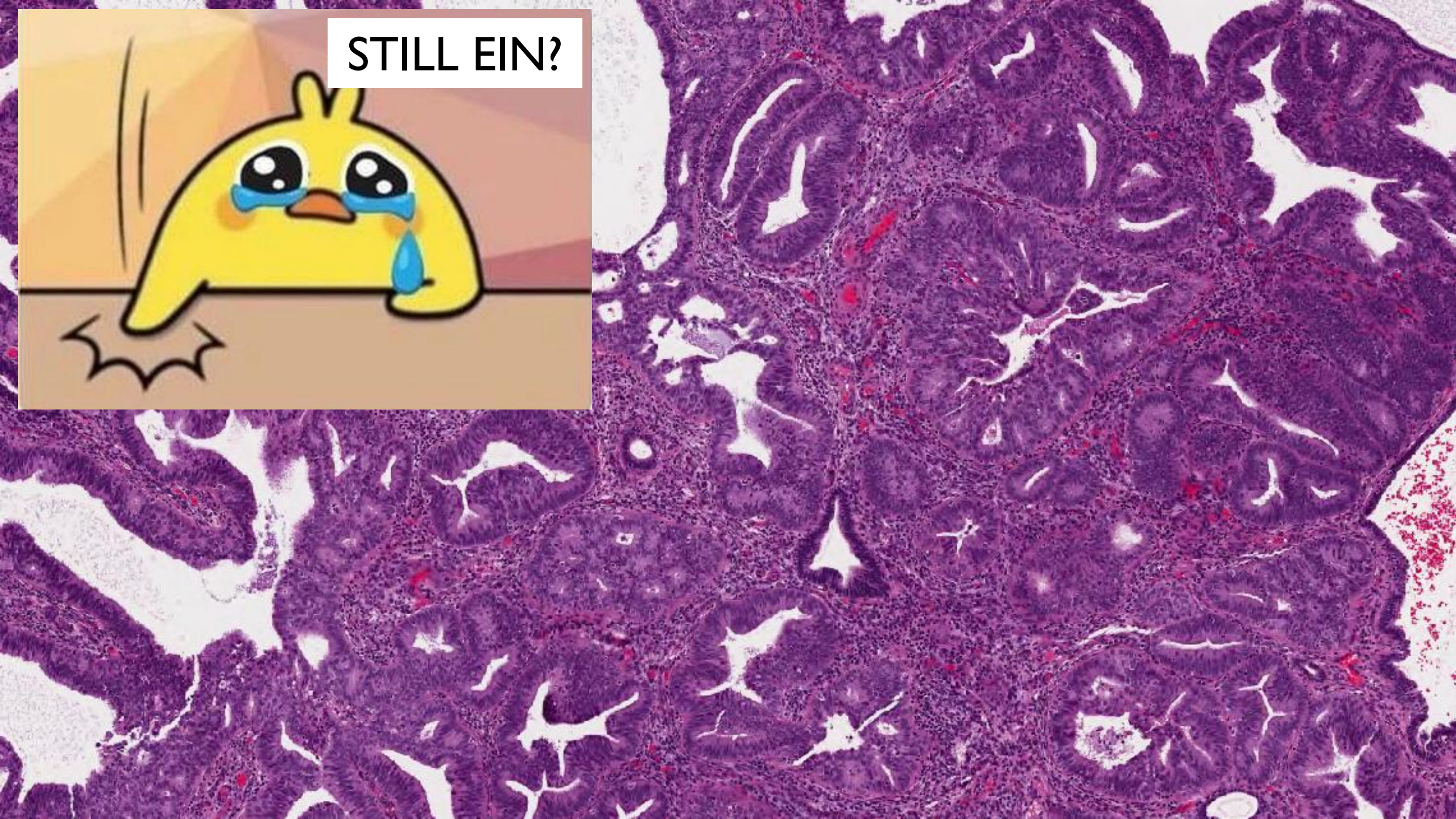
STILL EIN?

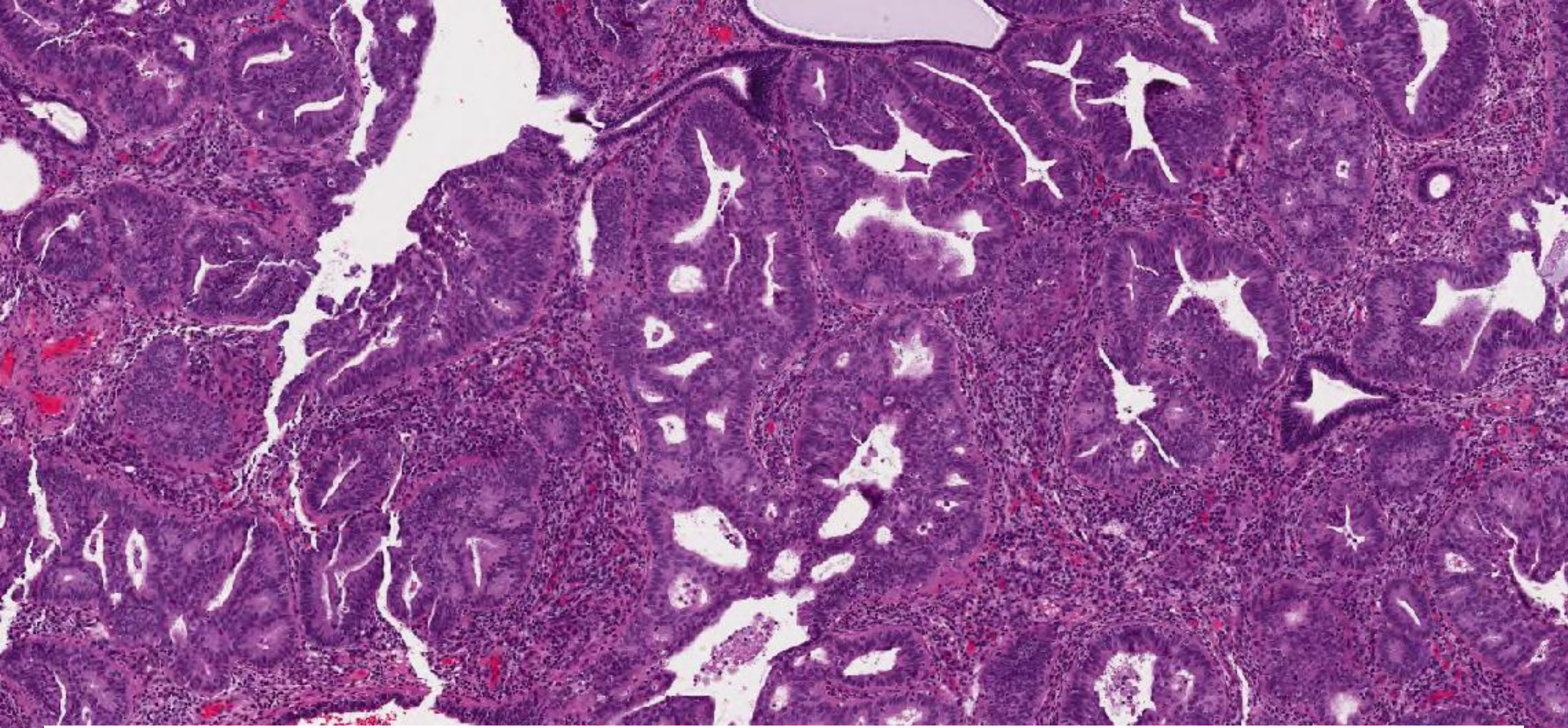

EIN with foci bordering on Endometrioid Carcinoma FIGO grade 1.
or At least EIN. See note.

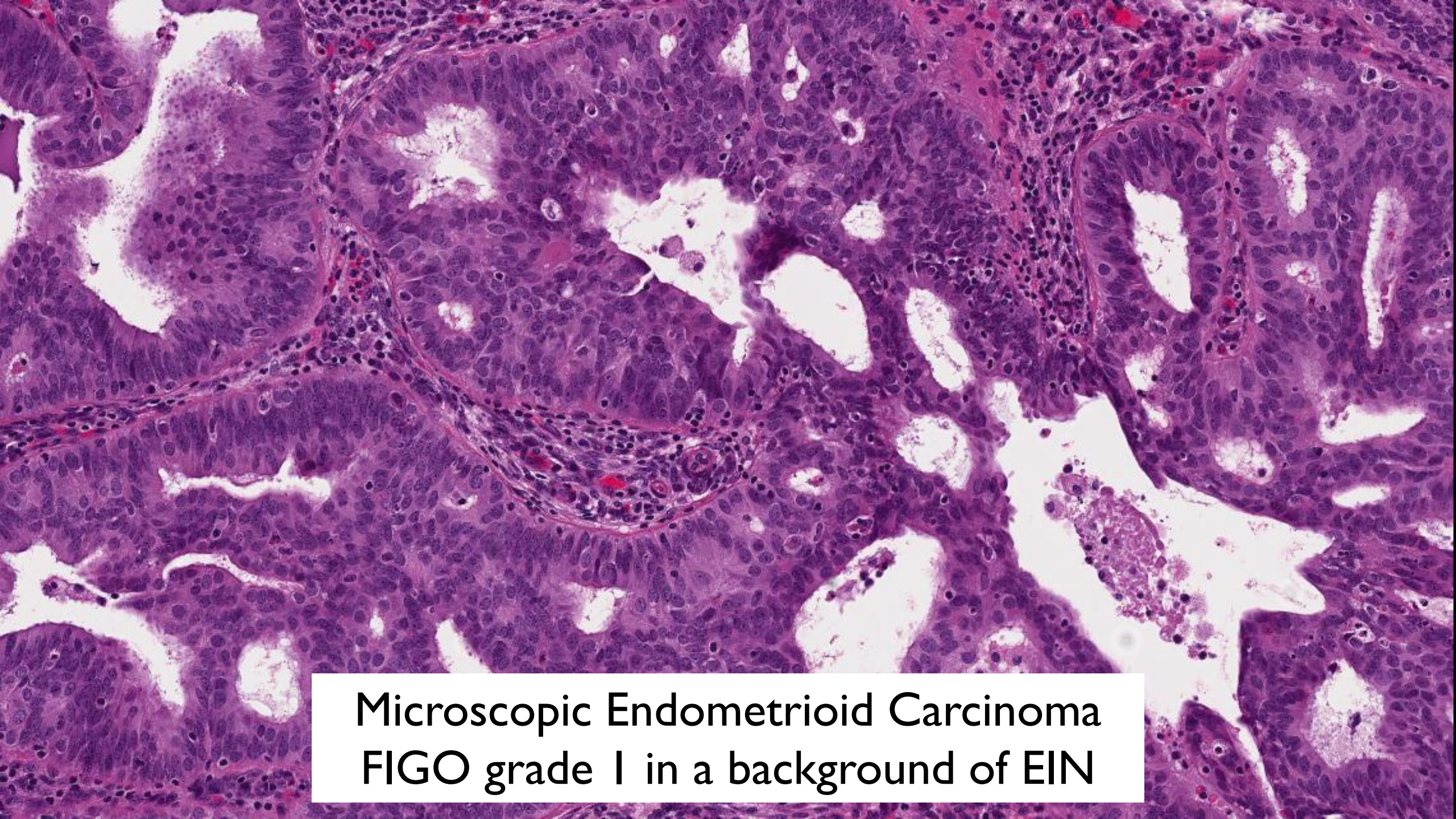

Microscopic Endometrioid Carcinoma
FIGO grade 1 in a background of EIN

FERTILITY SPARING TREATMENT

- Surveillance after EIN/AH or endometrial CA Dx
  - Endometrial curettage or directed biopsy
  - 3-month intervals
- Apply conventional criteria
- But keep in mind that
  - Cytology of the lesion has likely changed
  - The background endometrium has changed

Am J Surg Pathol 2007;31(7):988-98
Am J Clin Pathol 2012;138:524-34

PROGESTIN THERAPY: PATHOLOGY

- Architectural changes
  - Decrease in volume of disease
    - Number of involved fragments
  - Decreased glandular crowding
  - Decreased cellularity
- Cytologic changes
  - Decreased N:C ratio
  - Decreased nuclear size
  - Cytoplasmic eosinophilia
  - Nuclear rounding
- Metaplasia (secretory, squamous, mucinous)

Am J Surg Pathol 2007;31(7):988-98
Am J Clin Pathol 2012;138:524-34
Gynecol Oncol 2014;132:33-37

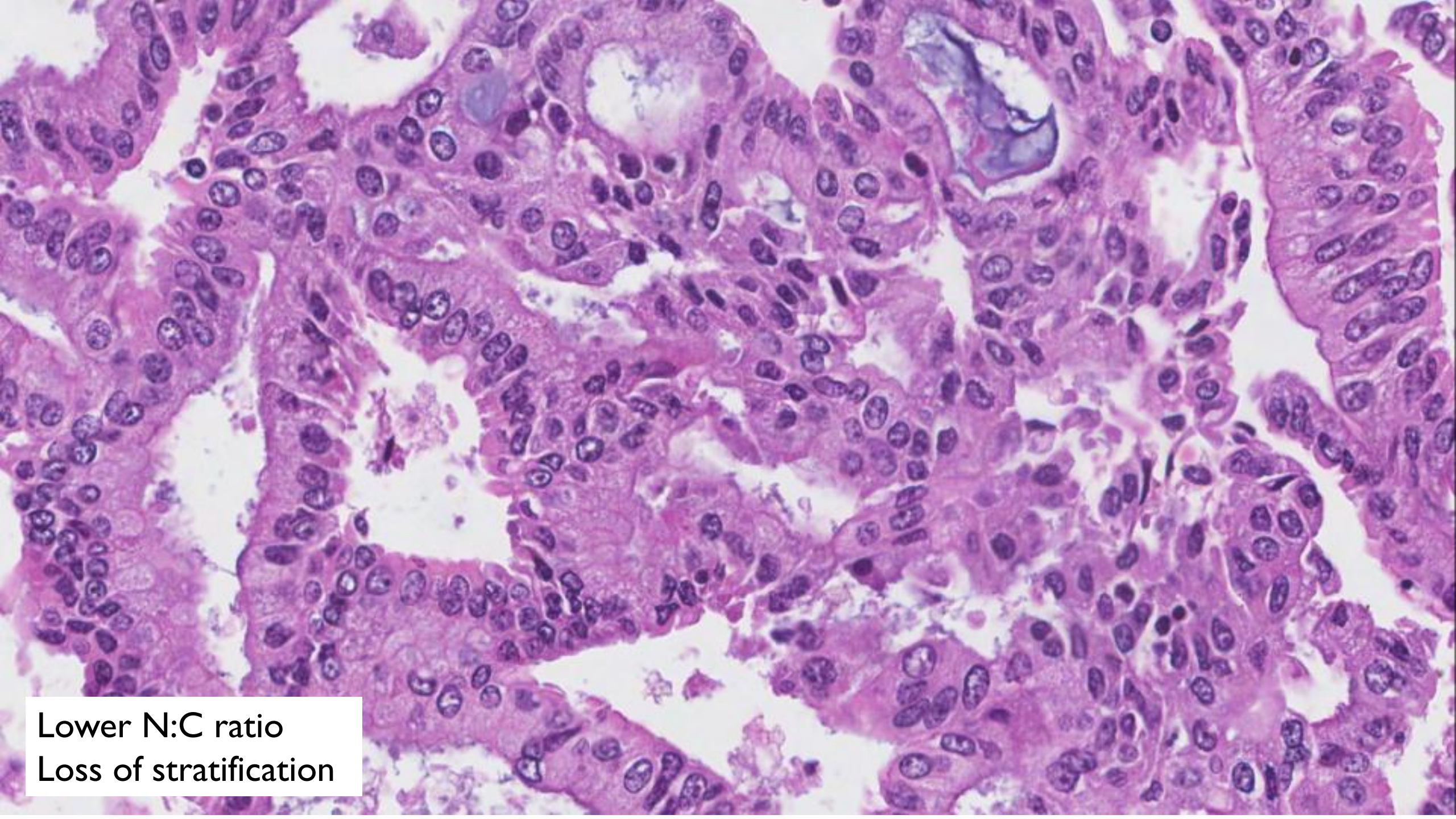
Lower N:C ratio
Loss of stratification

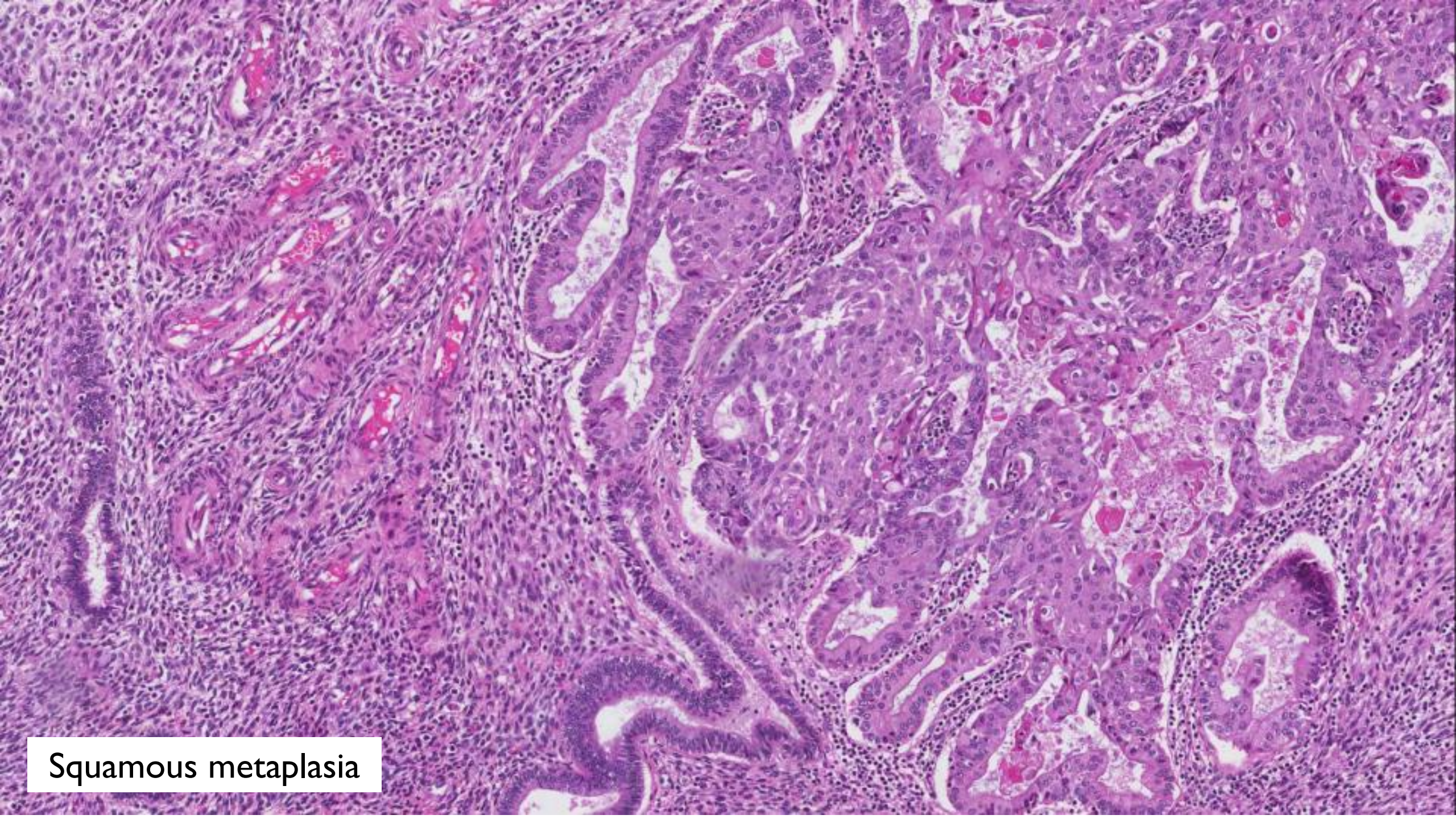
Squamous metaplasia

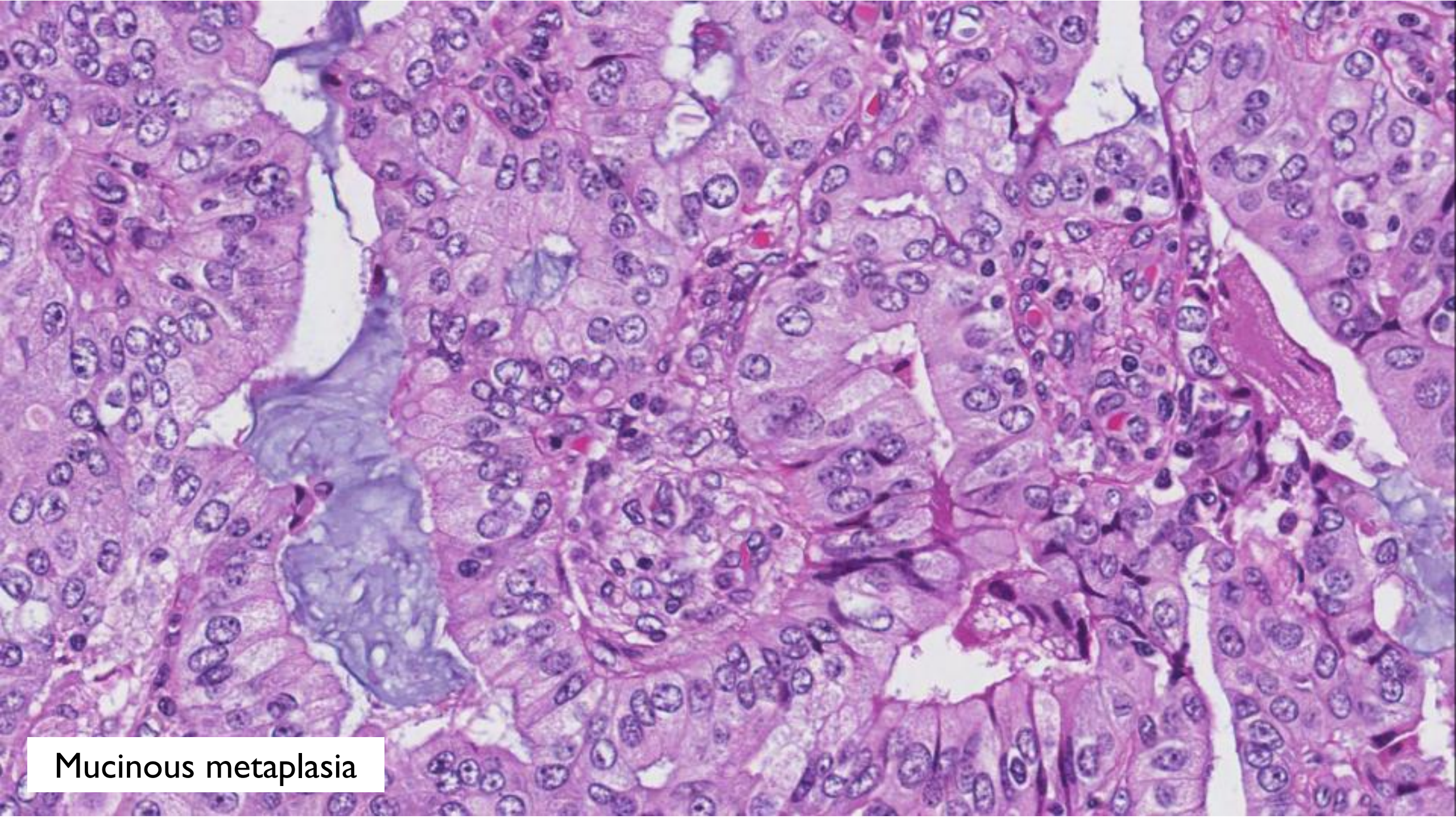
Mucinous metaplasia

DIAGNOSTIC WORK-UP

- Time interval between Dx and follow-up Bx
- Comparison between initial and follow-up samples
  - Assessment is WAY EASIER if you compare with index biopsy
- Look at the background endometrium
  - Progestin changes indicate compliance to Tx
  - Cytologic atypia can be difficult to assess

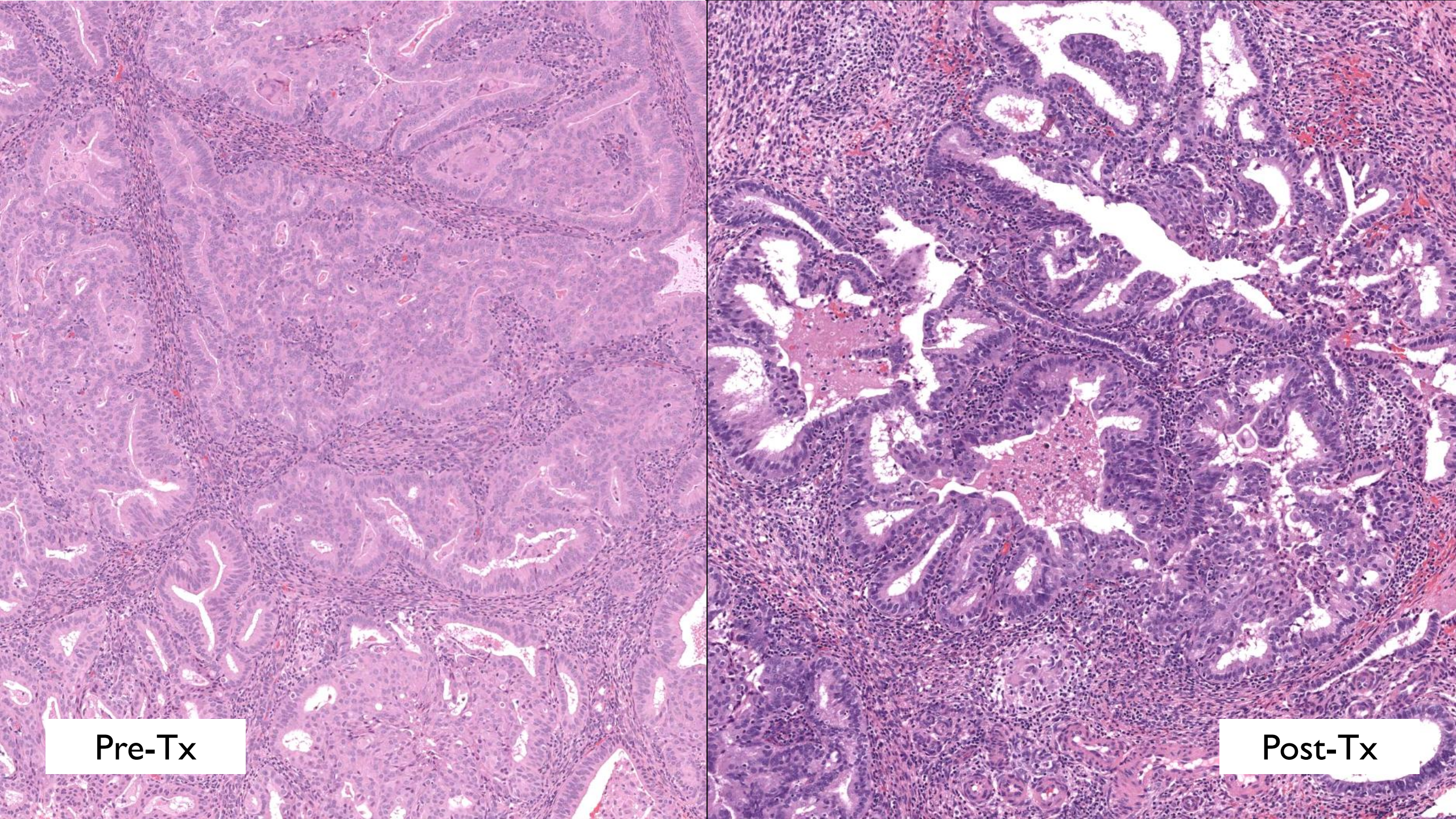
Pre-Tx
Post-Tx

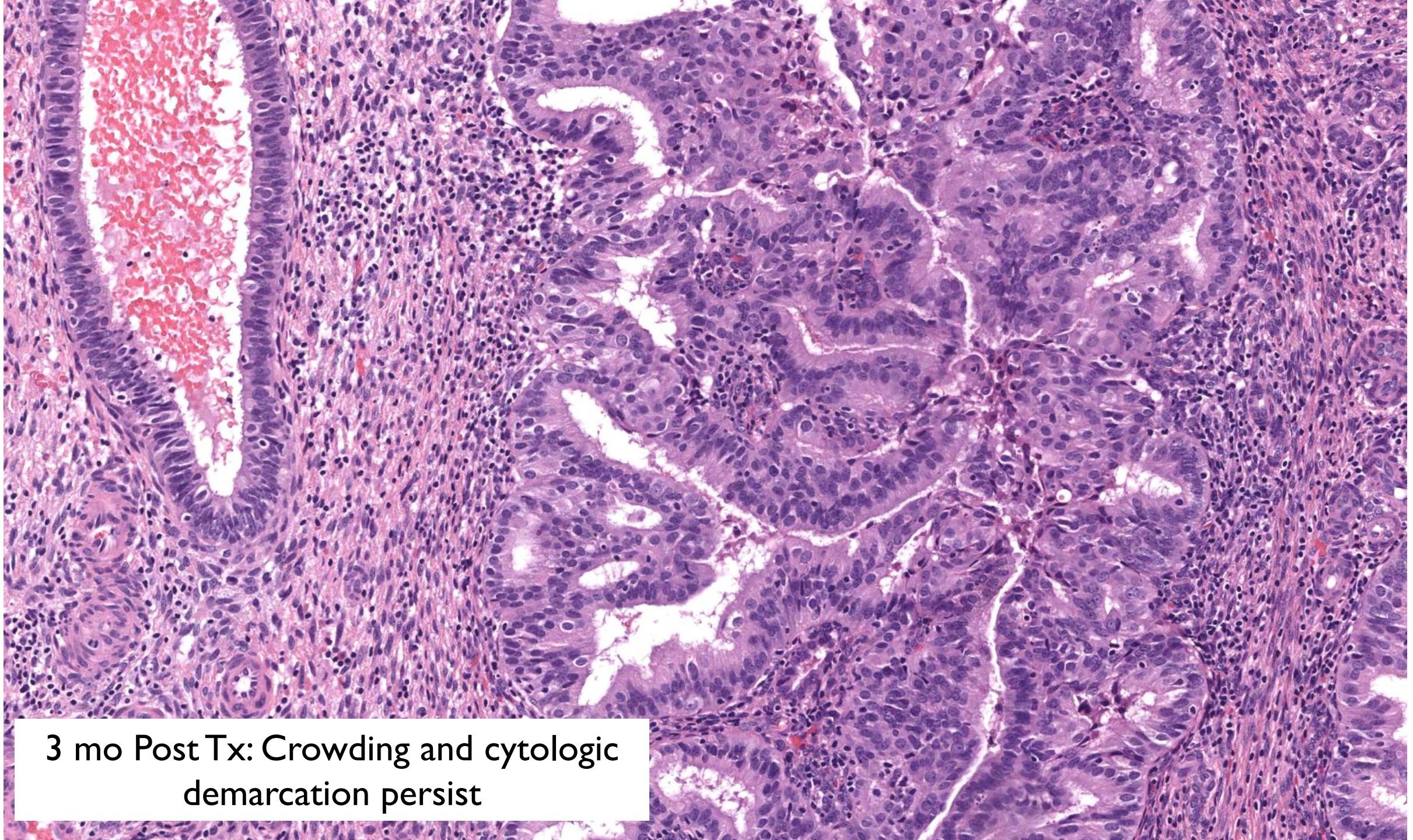

3 mo Post Tx: Crowding and cytologic demarcation persist

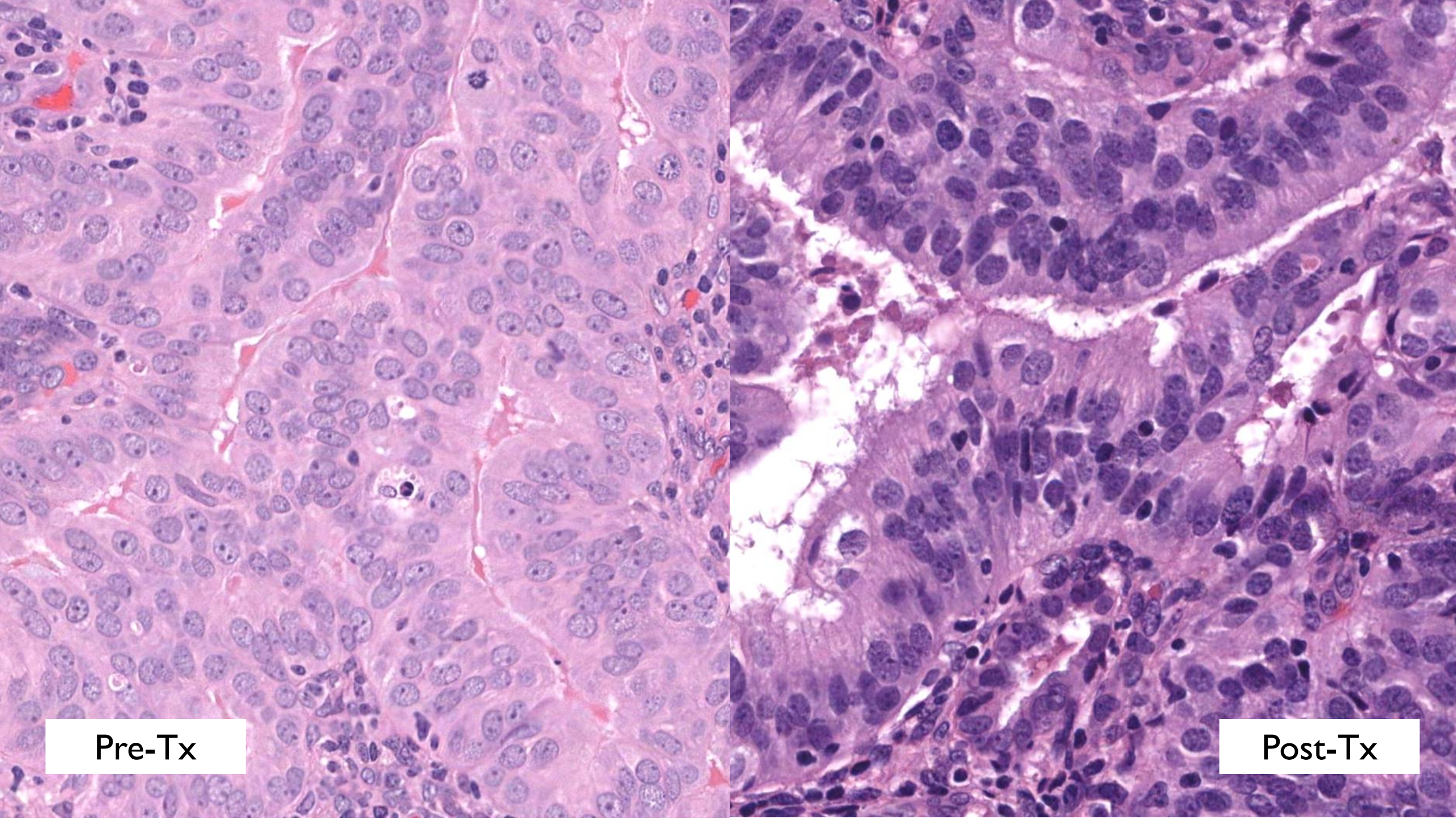
Pre-Tx
Post-Tx

TABLE 2. *Morphologic features and treatment implications of the categories provided in the survey*

Category	Morphologic features: glands	Morphologic features: stroma	Treatment implications
Negative for residual hyperplasia/carcinoma	Well-separated, inactive glands Minor glandular Irregularity or dilatation Focal nuclear enlargement that appears reactive or degenerative No cytologic atypia	Stromal decidual change	Treatment has been effective, and can end Follow-up to ensure that there is no recurrence
Residual hyperplasia with treatment effects	Foci of crowded glands and/or papillary architecture. Squamous metaplasia may be prominent No cytologic atypia	Stromal decidual change	Treatment is working but further treatment is needed
Residual atypical hyperplasia with treatment effects	Foci of crowded glands and/or papillary architecture Cytologic atypia present*	Stromal decidual change	Treatment is working but further treatment is needed
Atypical hyperplasia/ endometrioid carcinoma without treatment effects	Atypical hyperplasia/endometrioid carcinoma without stromal decidual change	No stromal decidual change at the site of gland crowding†	The atypical hyperplasia/ endometrioid carcinoma is not responding to progesterone treatment‡
None of the above (describe changes)			

Int J Gynecol Pathol 2022;41(2):142-150

NEGATIVE FOR RESIDUAL HYPERPLASIA / CARCINOMA

TABLE 2. *Morphologic features and treatment implications of the categories provided in the survey*

Category	Morphologic features: glands	Morphologic features: stroma	Treatment implications
Negative for residual hyperplasia/carcinoma	Well-separated, inactive glands Minor glandular irregularity or dilatation Focal nuclear enlargement that appears reactive or degenerative No cytologic atypia	Stromal decidual change	Treatment has been effective, and can end Follow-up to ensure that there is no recurrence
Residual hyperplasia with treatment effects	Foci of crowded glands and/or papillary architecture. Squamous metaplasia may be prominent No cytologic atypia	Stromal decidual change	Treatment is working but further treatment is needed
Residual atypical hyperplasia with treatment effects	Foci of crowded glands and/or papillary architecture Cytologic atypia present*	Stromal decidual change	Treatment is working but further treatment is needed
Atypical hyperplasia/ endometrioid carcinoma without treatment effects	Atypical hyperplasia/endometrioid carcinoma without stromal decidual change	No stromal decidual change at the site of gland crowding†	The atypical hyperplasia/ endometrioid carcinoma is not responding to progesterone treatment‡
None of the above (describe changes)			

Int J Gynecol Pathol 2022;41(2):142-150

RESIDUAL HYPERPLASIA WITH TREATMENT EFFECT

TABLE 2. *Morphologic features and treatment implications of the categories provided in the survey*

Category	Morphologic features: glands	Morphologic features: stroma	Treatment implications
Negative for residual hyperplasia/carcinoma	Well-separated, inactive glands Minor glandular Irregularity or dilatation Focal nuclear enlargement that appears reactive or degenerative No cytologic atypia	Stromal decidual change	Treatment has been effective, and can end Follow-up to ensure that there is no recurrence
Residual hyperplasia with treatment effects	Foci of crowded glands and/or papillary architecture. Squamous metaplasia may be prominent No cytologic atypia	Stromal decidual change	Treatment is working but further treatment is needed
Residual atypical hyperplasia with treatment effects	Foci of crowded glands and/or papillary architecture Cytologic atypia present*	Stromal decidual change	Treatment is working but further treatment is needed
Atypical hyperplasia/ endometrioid carcinoma without treatment effects	Atypical hyperplasia/endometrioid carcinoma without stromal decidual change	No stromal decidual change at the site of gland crowding†	The atypical hyperplasia/ endometrioid carcinoma is not responding to progesterone treatment‡
None of the above (describe changes)			

Int J Gynecol Pathol 2022;41(2):142-150

RESIDUAL EIN / ATYPICAL HYPERPLASIA WITH TX EFFECT

TABLE 2. *Morphologic features and treatment implications of the categories provided in the survey*

Category	Morphologic features: glands	Morphologic features: stroma	Treatment implications
Negative for residual hyperplasia/carcinoma	Well-separated, inactive glands Minor glandular irregularity or dilatation Focal nuclear enlargement that appears reactive or degenerative No cytologic atypia	Stromal decidual change	Treatment has been effective, and can end Follow-up to ensure that there is no recurrence
Residual hyperplasia with treatment effects	Foci of crowded glands and/or papillary architecture. Squamous metaplasia may be prominent No cytologic atypia	Stromal decidual change	Treatment is working but further treatment is needed
Residual atypical hyperplasia with treatment effects	Foci of crowded glands and/or papillary architecture Cytologic atypia present*	Stromal decidual change	Treatment is working but further treatment is needed
Atypical hyperplasia/endometrioid carcinoma without treatment effects	Atypical hyperplasia/endometrioid carcinoma without stromal decidual change	No stromal decidual change at the site of gland crowding†	The atypical hyperplasia/endometrioid carcinoma is not responding to progesterone treatment‡
None of the above (describe changes)			

Int J Gynecol Pathol 2022;41(2):142-150

EIN(AH) OR CARCINOMA WITHOUT TX EFFECT

TABLE 2. *Morphologic features and treatment implications of the categories provided in the survey*

Category	Morphologic features: glands	Morphologic features: stroma	Treatment implications
Negative for residual hyperplasia/carcinoma	Well-separated, inactive glands Minor glandular Irregularity or dilatation Focal nuclear enlargement that appears reactive or degenerative No cytologic atypia	Stromal decidual change	Treatment has been effective, and can end Follow-up to ensure that there is no recurrence
Residual hyperplasia with treatment effects	Foci of crowded glands and/or papillary architecture. Squamous metaplasia may be prominent No cytologic atypia	Stromal decidual change	Treatment is working but further treatment is needed
Residual atypical hyperplasia with treatment effects	Foci of crowded glands and/or papillary architecture Cytologic atypia present*	Stromal decidual change	Treatment is working but further treatment is needed
Atypical hyperplasia/ endometrioid carcinoma without treatment effects	Atypical hyperplasia/endometrioid carcinoma without stromal decidual change	No stromal decidual change at the site of gland crowding†	The atypical hyperplasia/ endometrioid carcinoma is not responding to progesterone treatment‡
None of the above (describe changes)			

Int J Gynecol Pathol 2022;41(2):142-150

PROGESTIN THERAPY: PATHOLOGY

- Apply conventional criteria for Dx of EIN/AH and carcinoma
  - EIN/AH with/without changes related to progestin therapy
  - Endometrioid carcinoma with/without changes related to progestin therapy
- Some cases are difficult to classify
  - Changes consistent with residual endometrioid neoplasia. See note.
  - NOTE: Previous material was reviewed for comparison. In this sample, residual [EIN or carcinoma] is favored.

Am J Surg Pathol 2007;31(7):988-98
Am J Clin Pathol 2012;138:524-34

SUMMARY

- Endometrial gland crowding = *think EIN/AH* (but not only EIN)
- The hallmark of EIN/AH is *crowding + cytologic alteration* (atypia)
- Sub-diagnostic gland crowding requires clinical *surveillance*
- Use ancillary testing judiciously
- In the setting of fertility-sparing Tx, clinical context and review of prior material are helpful aides

THANK YOU!

cparra-herran@bwh.harvard.edu



