The British Association of Gynaecological Pathologists

21st Annual Meeting in Collaboration with ISGyP

5th and 6th June 2025

Title. Endometrial Polyp and Minimal Uterine Serous Carcinoma

- **Speaker.** Pei Hui, MD
- **Affiliation.** Yale University School of Medicine
- **Date.** 5th June 2025

The British Association of Gynaecological Pathologists

Speaker disclosures

I have no relevant financial conflicts of interest to disclose

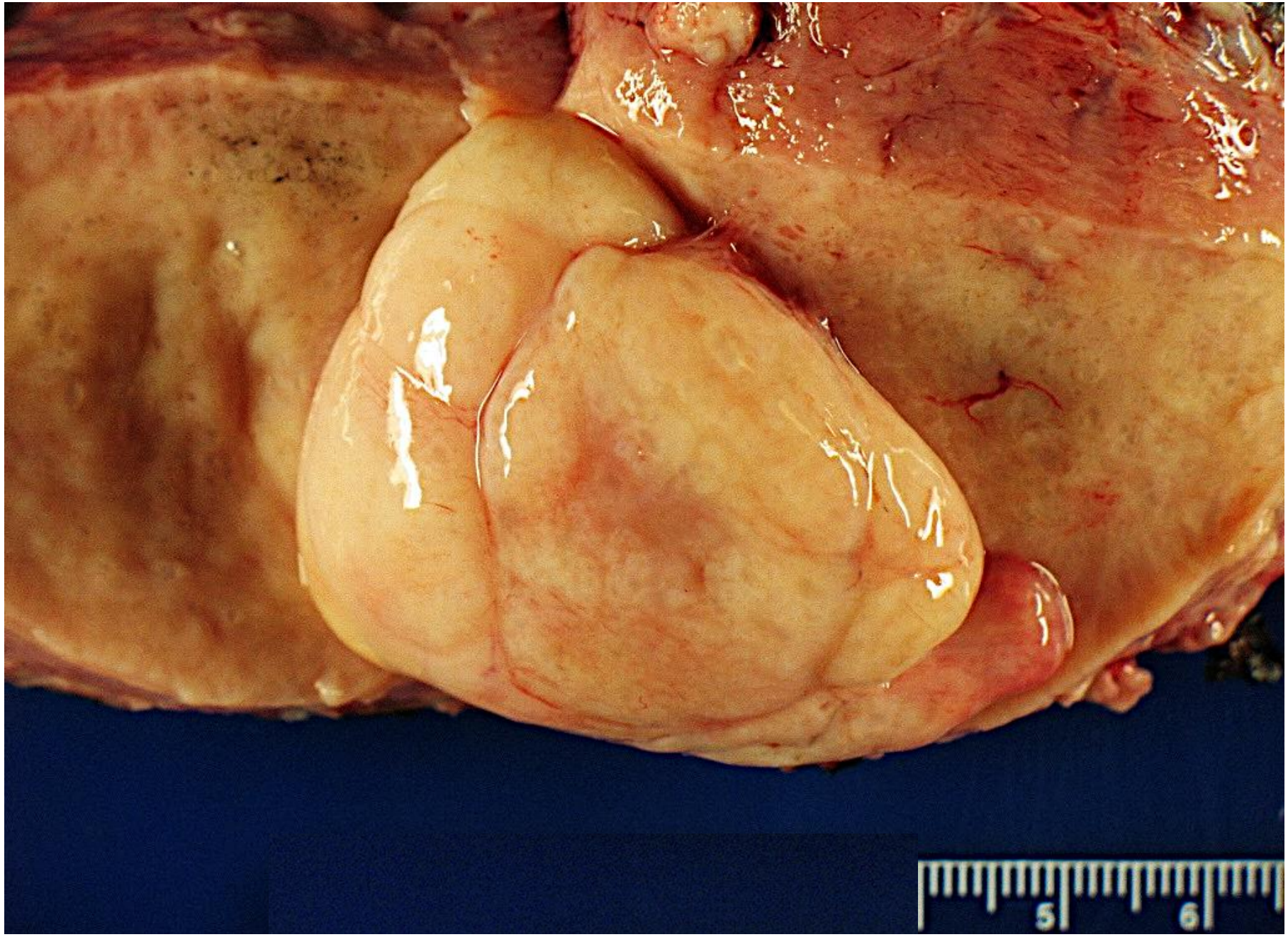
5
6

Endometrial Polyp

- Endometrial polyps are found in 13 to 51% of women in the general population.
- Endometrial polyps are particularly common in patients undergoing tamoxifen therapy for breast cancer.

Endometrial Polyp

- Concurrent or subsequent hyperplasia and carcinoma occur in 11-30% and 0.5–3% of patients, respectively
- Early endometrial adenocarcinomas - serous, endometrioid, clear cell carcinoma, and carcinosarcoma - incidences of 4.5% in symptomatic and 1.5% in asymptomatic patients

Lee SC, Kaunitz AM, Sanchez-Ramos L, Rhatigan RM. The oncogenic potential of endometrial polyps: a systematic review and meta-analysis. *Obstet Gynecol.* 2010;116(5):1197–205.

- Largest meta-analysis
- Premalignant or malignant polyps of 5.42% (214 of 3,946) in postmenopausal
- Endometrial neoplasia with uterine bleeding: 4.15% (195 of 4,697) and 2.16% (85 of 3,941) for those without bleeding
- Malignancy of 4.47% (88 of 1,968) in symptomatic cases vs. 1.51% (25 of 1,654) in asymptomatic cases

Lee SC, et al: The oncogenic potential of endometrial polyps: a systematic review and meta-analysis. Obstet Gynecol. 2010: 116:1197

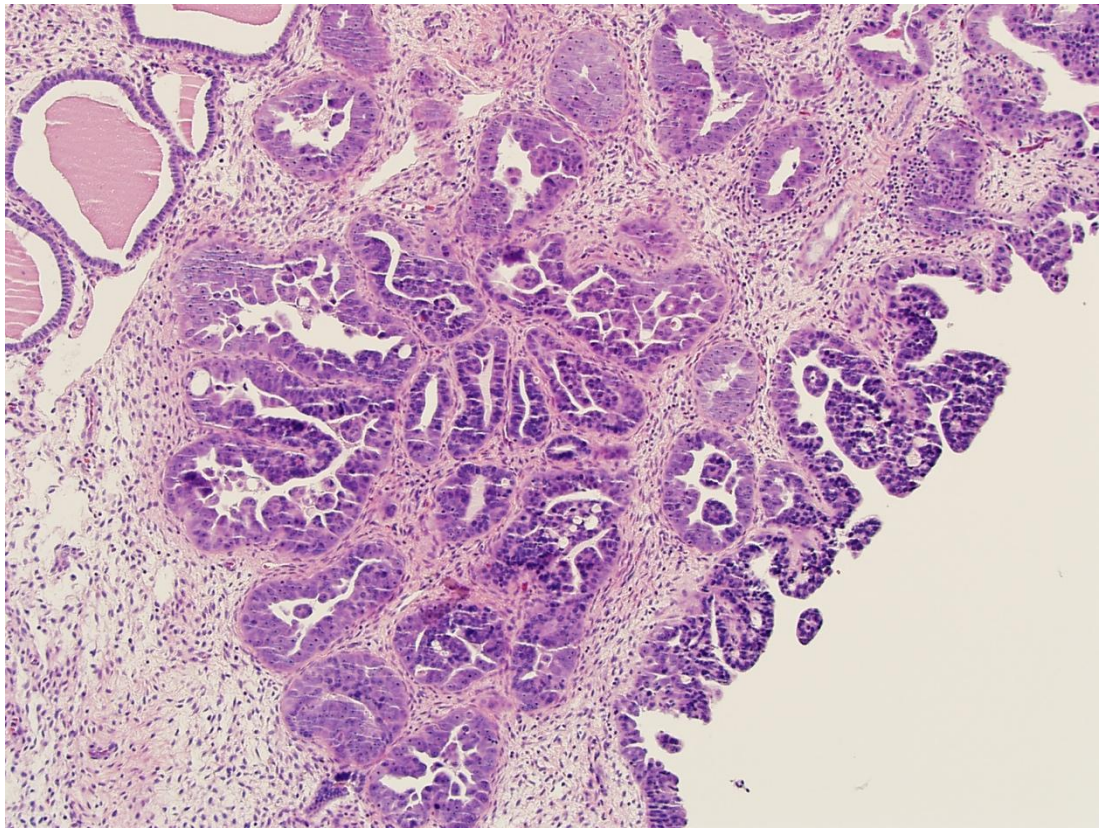

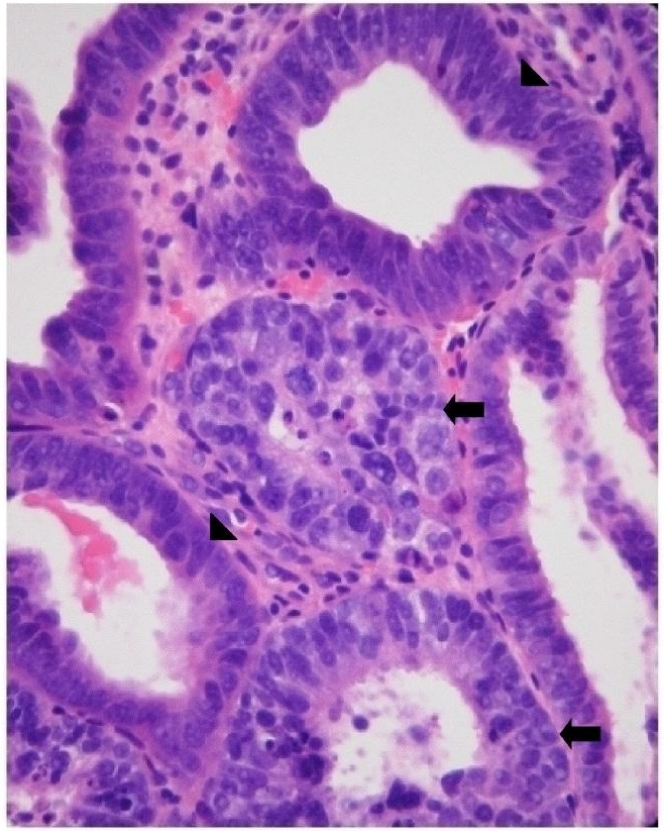

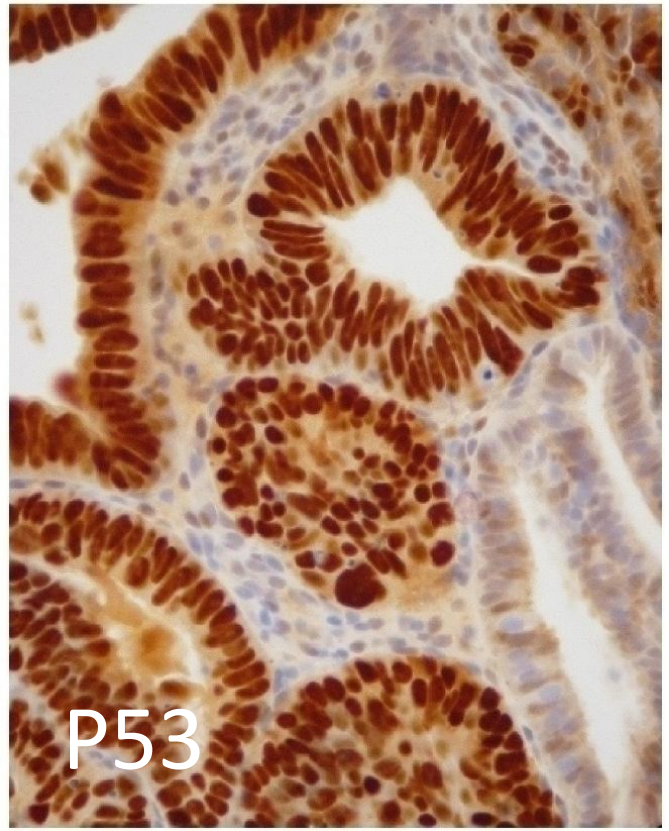
P53

- Endometrial Intraepithelial Carcinoma (EIC)
- Endometrial carcinoma in-situ (ECIS)
- Minimal uterine serous carcinoma (MUSC)
- Minute focus of serous carcinoma
- Serous endometrial intraepithelial carcinoma (SEIC)

Endometrial Intraepithelial Carcinoma or EIC

TABLE 5. *Presence of intraepithelial carcinoma in adjacent endometrium and extrauterine sites according to composition of tumor*

	UPSC-mixed (n = 19)	UPSC-polyp (n = 9)	UPSC-pure (n = 13)
Endometrium	17/19 (89%)	9/9 (100%)	8/10 (80%)
Endocervix	4/17 (24%)	1/8 (12%)	4/11 (36%)
Fallopian tube	2/17 (12%)	0/8 (—)	0/13 (—)
Peritoneal or serosal surfaces[a]	2/17 (12%)	3/8 (38%)	5/11 (56%)
Ovarian surface	3/17 (18%)	1/8 (12%)	0/13 (—)

UPSC = uterine papillary serous carcinoma.
[a] Serosal surface of uterus, fallopian tube, intestine, etc.

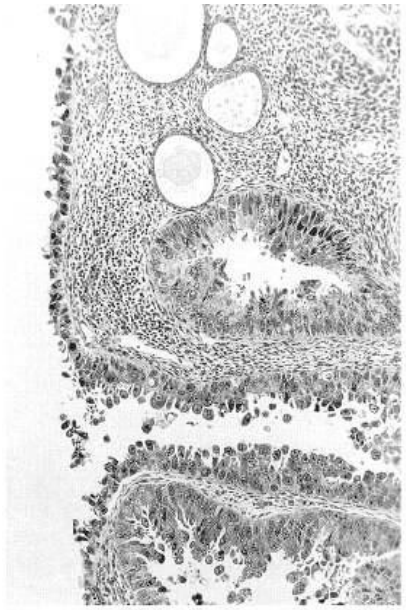



Uterine serous carcinoma. A morphologically diverse neoplasm with unifying clinicopathologic features.

Sherman ME, Bitterman P, Rosenshein NB, Delgado G, Kurman RJ.

Am J Surg Pathol. 1992 Jun;16(6):600-10. doi: 10.1097/00000478-199206000-00008.

Endometrial Intraepithelial Carcinoma – EIC represents a form of intraepithelial tumor growth characteristic of serous carcinoma and serous MMMT

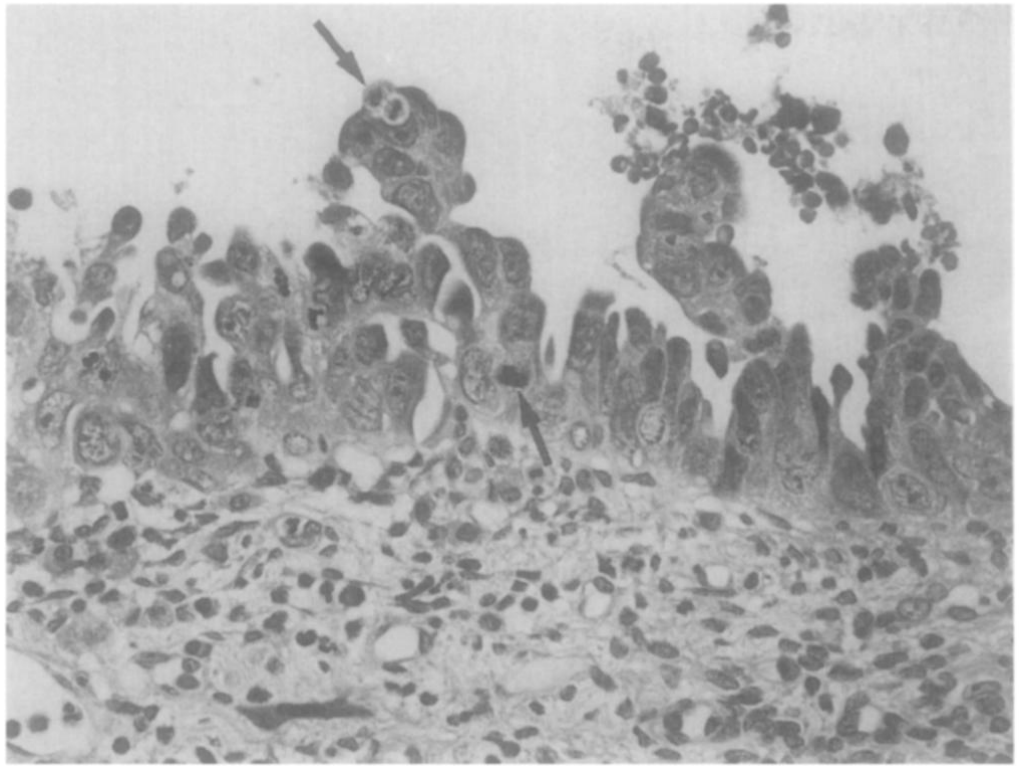

› Hum Pathol. 1995 Nov;26(11):1260-7. doi: 10.1016/0046-8177(95)90203-1.

Endometrial intraepithelial carcinoma: a distinctive lesion specifically associated with tumors displaying serous differentiation

R A Ambros [1], M E Sherman, C M Zahn, P Bitterman, R J Kurman

Serous Endometrial Intraepithelial Carcinoma (WHO 2014/2020)

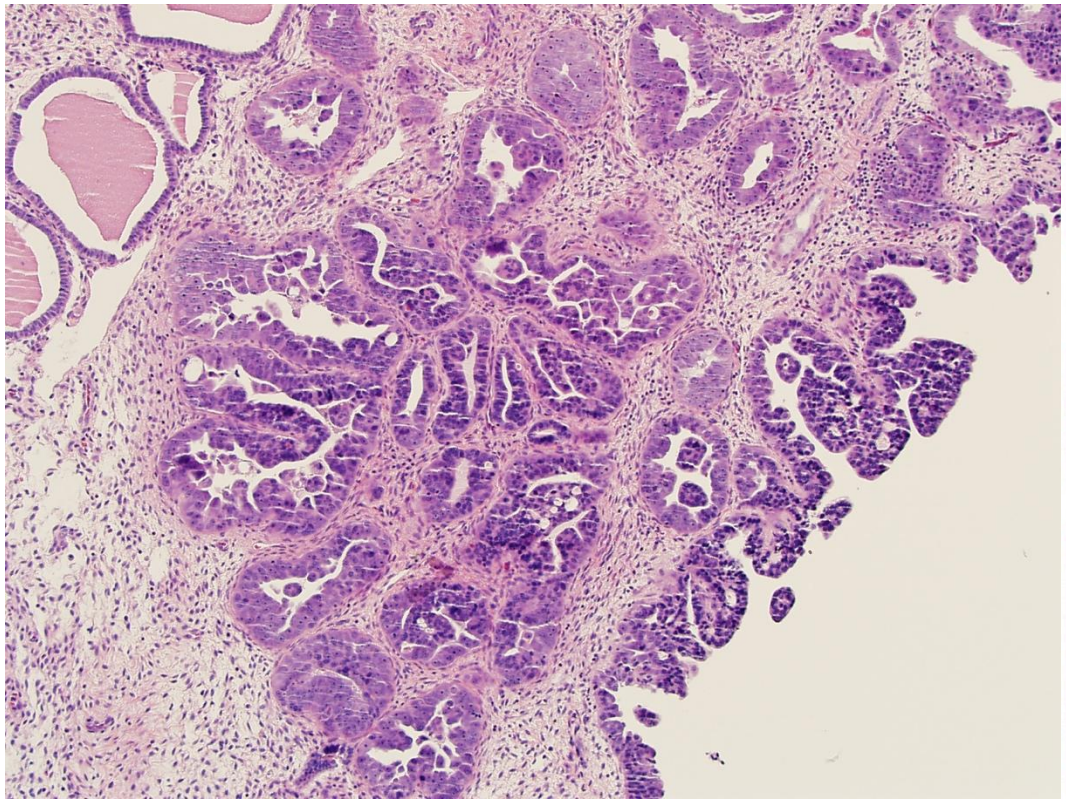

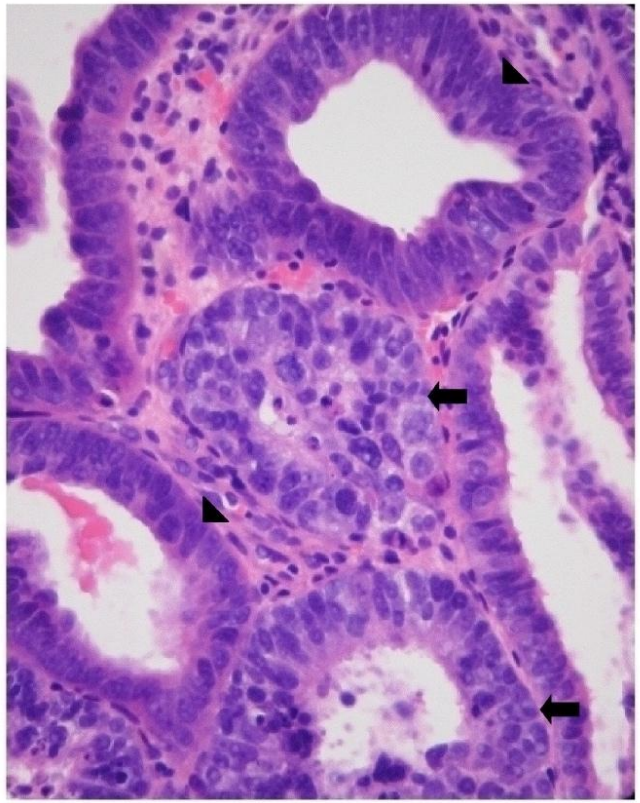

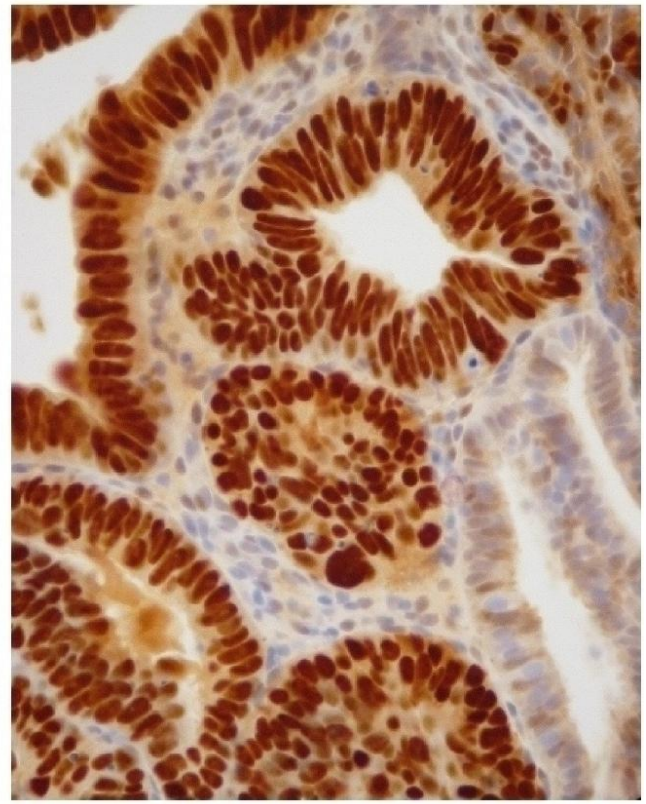

Minimal Uterine Serous Carcinoma (MUSC)

- Serous endometrial intraepithelial carcinoma (SEIC)
- Superficial invasive serous carcinoma

  - < 1 cm in size
  - No myometrial invasion
  - No lymphovascular invasion

- Similar clinical outcome of both lesions

Comparative Study > Am J Surg Pathol. 2000 Jun;24(6):797-806.
doi: 10.1097/00000478-200006000-00004.

Minimal uterine serous carcinoma: diagnosis and clinicopathologic correlation

D T Wheeler [1], K A Bell, R J Kurman, M E Sherman

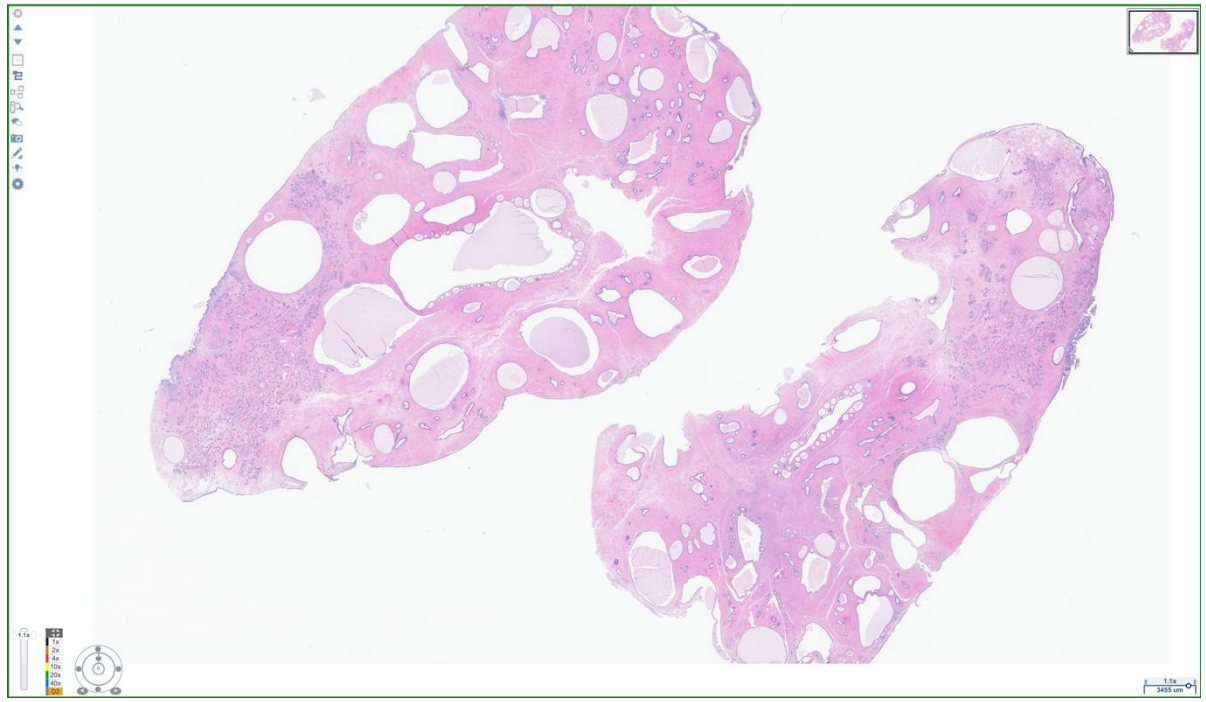

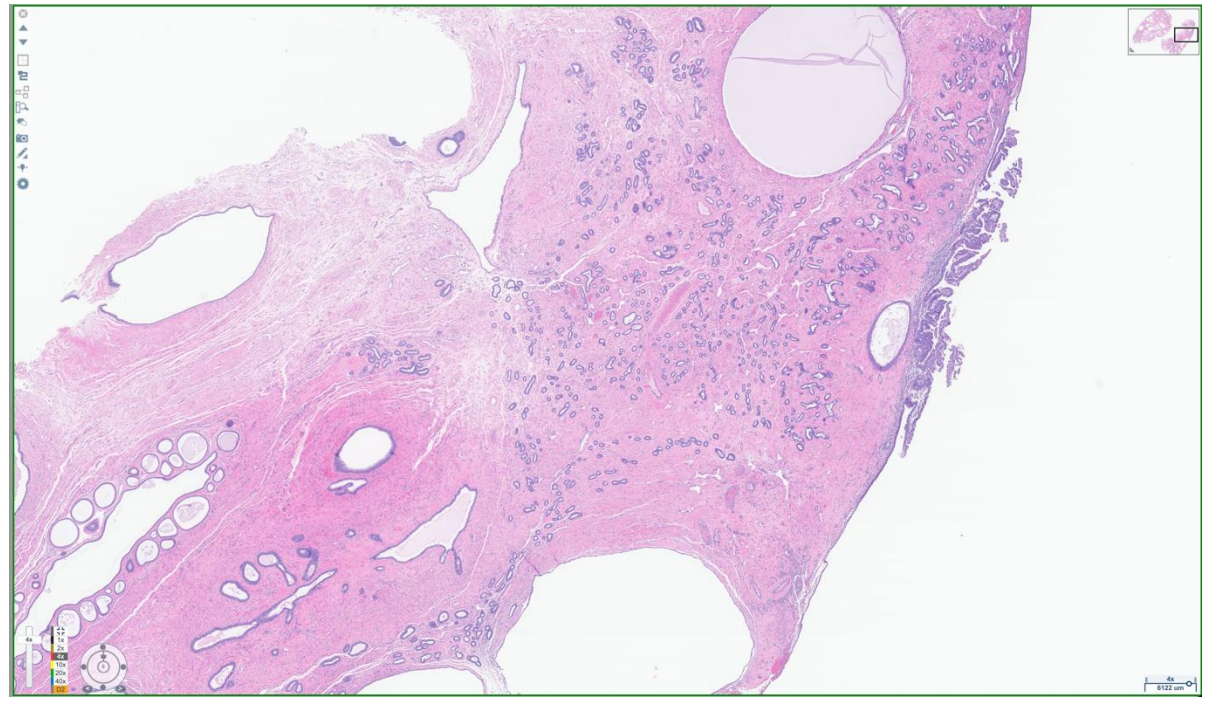

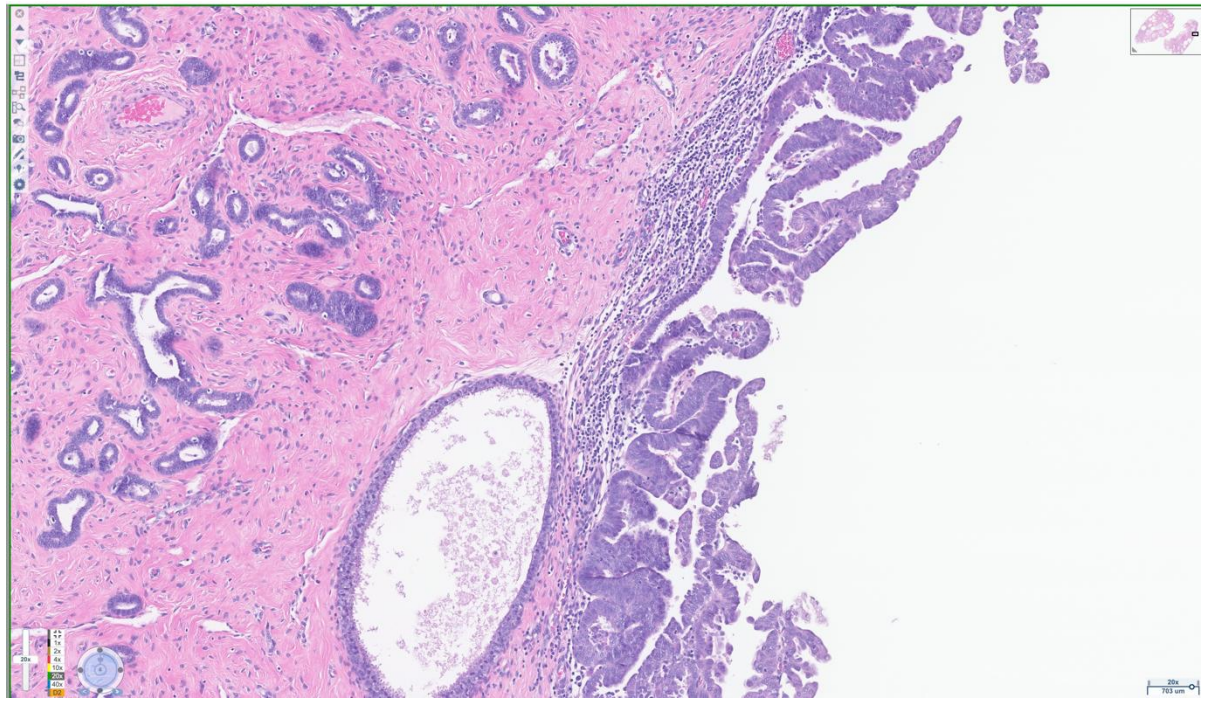

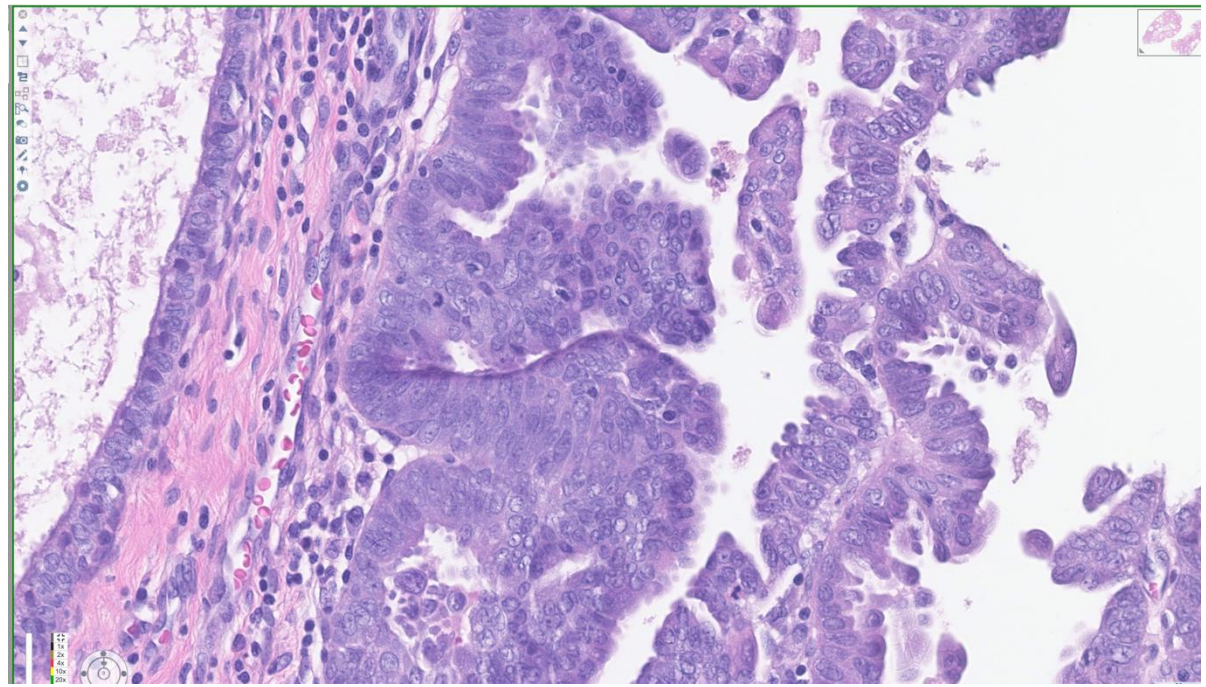

MUSC In EMP

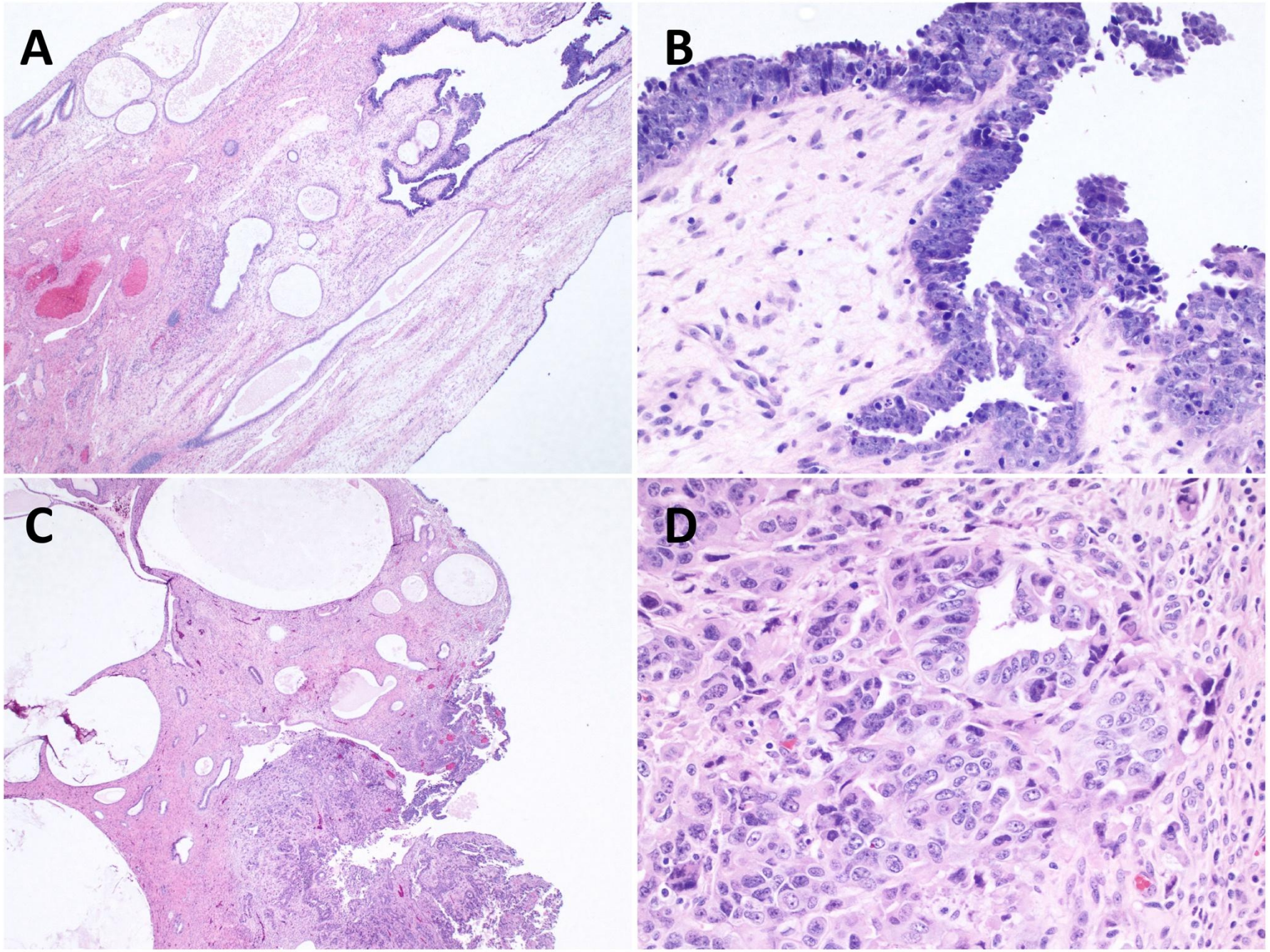

Serous Carcinoma and Endometrial Polyp

MODERN PATHOLOGY

Institution: YALE MEDICAL LIB || Sign In as Member/Individual (Non-Member) || Contact Subscription Administrator at your institution || FAQ

Modern Pathology, Vol 3, Issue 2 120-128, Copyright © 1990 by United States and Canadian Academy of Pathology

Similar articles found in:
Modern Pathology Online
PubMed
PubMed Citation
Search Medline for articles by:
Silva, E. || Jenkins, R
Alert me when:
new articles cite this article
Download to Citation Manager

ARTICLES

Serous carcinoma in endometrial polyps

EG Silva and R Jenkins
Department of Pathology, University of Texas M.D. Anderson Cancer Center, Houston.

Sixteen patients who had serous carcinoma involving endometrial polyps and who demonstrated rare or absent myometrial or lymphovascular invasion are reported. Six of these patients had clinical manifestations of extrauterine disease at presentation. Of the ten patients who presented with clinical stage I disease, six eventually developed extrauterine recurrence, and four of these six were dead of disease within 19 mo of recurrence. Similarities between the patients who presented with extrauterine disease and the patients who presented with clinical stage I disease, including high percentages of patients with hyperplasia of ovarian epithelium surface and of fallopian tube epithelium, suggest that serous carcinoma involving endometrial polyps may represent one aspect of a multicentric disease. In such multicentricity, the entire female genital tract and the abdominal peritoneal surfaces would be at high risk for concurrent or subsequent involvement by serous carcinoma even in the absence of myometrial or lymphovascular invasion.

16 serous carcinomas involving endometrial polyps without myoinvasion or LVSI: 6 had extrauterine spread at surgery and 6 others developed extrauterine recurrence.

Serous Carcinomas Involving Endometrial Polyp

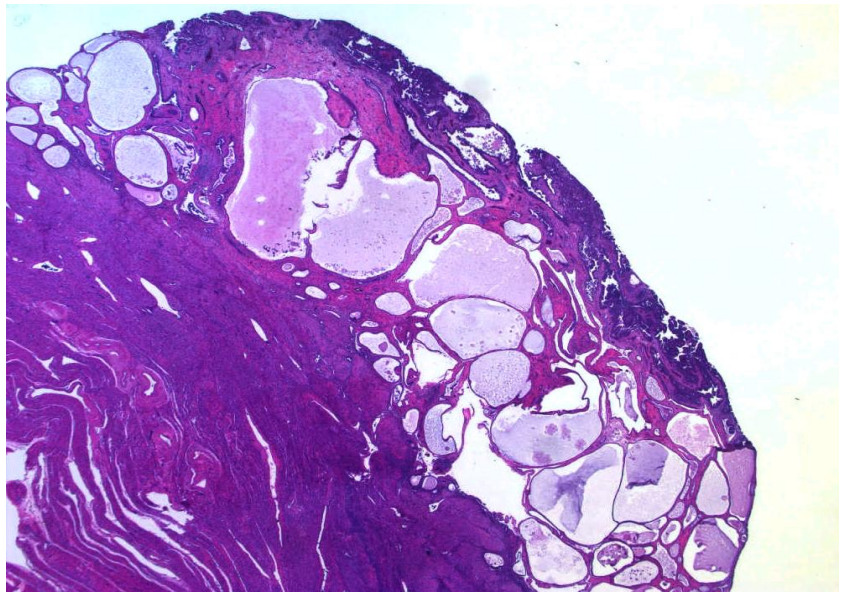

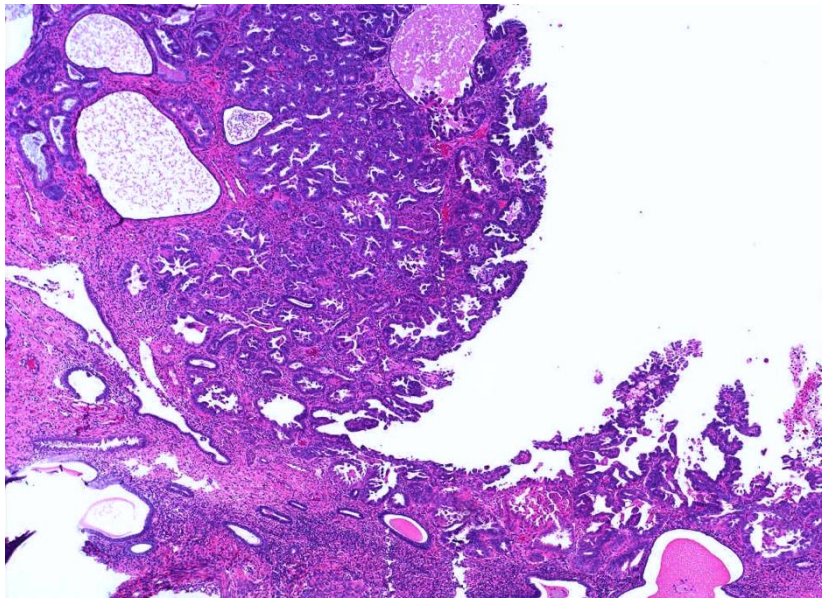

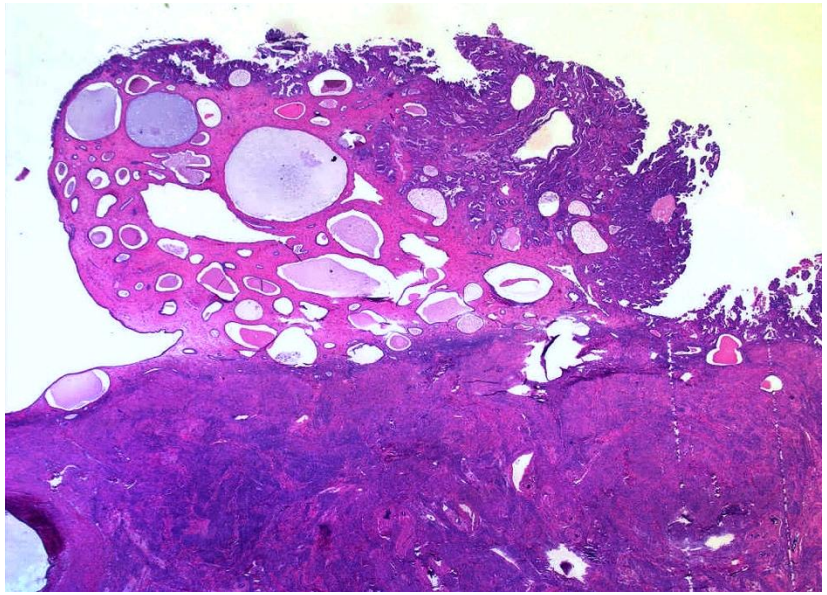

19/21(90%) MUSC involving EMP

- 10 confined to endometrial polyp
- 9 involving both endometrial polyp and endometrium

Age (yrs)	Clinical presentation	Endometrial tumor distribution		Extrauterine disease	FIGO stage	Postoperative therapy	Follow up
		Polyp	Non-polyp area				
62	Postmenopausal bleeding	EIC	EIC and atrophy	None	IA	None	NED, 4 mos
52	Abnormal cervical smear*	No polyp	EIC and atrophy	None	IA	None	NED, 14 mos
65	Abnormal cervical smear*	EIC	Atrophy	None	IA	None	DOC, 52 mos
69	Abnormal cervical smear*	EIC	Simple hyperplasia	None	IA	None	NED, 22 mos
62	Postmenopausal bleeding	EIC	Atrophy	None	IA	None	NED, 41 mos
62	Postmenopausal bleeding	EIC	Atrophy	None	IIA	Chemotherapy	NED, 20 mos
58	Abnormal cervical smear*	EIC	EIC and atrophy	IC–Ovary (<1 mm)	IIIA	WAPRT	AWD, 10 mos
65	Postmenopausal bleeding	EIC	EIC and atrophy	IC–Ovary (4 mm)	IIIA	Chemotherapy	AWD, 8 mos

AWD, alive with disease; DOC, dead of other causes; DOD, dead of disease; IC, intraepithelial carcinoma; NED, no evidence of disease; WAPRT, whole abdomen and pelvic radiotherapy.
* Abnormal cervical smear was interpreted as one with malignant endometrial cells.

Age (yrs)	Clinical presentation	Endometrial tumor distribution		Extrauterine disease	FIGO stage	Postoperative therapy	Follow up
		Polyp	Non-polyp area				
79	Postmenopausal bleeding	SSC	Atrophy	None	IA	None	NED, 42 mos
65	Postmenopausal bleeding	SSC	Atrophy	None	IA	None	NED, 63 mos
67	Postmenopausal bleeding	SSC + EIC	EIC and atrophy	None	IA	None	NED, 50 mos
63	Abnormal cervical smear*	SSC	Atrophy	None	IA	None	NED, 50 mos
72	Postmenopausal bleeding	SSC + EIC	EIC and atrophy	None	IA	None	NED, 9 mos
65	Postmenopausal bleeding	SSC + EIC	EIC and atrophy	None	IA	None	NED, 49 mos
77	Abnormal cervical smear*	SSC + EIC	EIC and atrophy	None	IIA	Chemotherapy	NED, 12 mos
60	Postmenopausal bleeding	SSC + EIC	EIC and atrophy	None	IIA	None	NED, 54 mos
60	Postmenopausal bleeding	No tumor†	SSC, EIC, and atrophy	SC–Fallopian tube lumen (16 mm)	IIIA	Chemotherapy	AWD, 5 mos
62	Postmenopausal bleeding	SSC	Simple hyperplasia	IC–ovary (2 mm)	IIIA	Chemotherapy	DOC, 38 mos
63	Postmenopausal bleeding	SSC + EIC	Atrophy	SC–bowel (6 mm)	IVA	Chemotherapy	DOD, 13 mos
76	Postmenopausal bleeding	SSC + EIC	Simple hyperplasia	SC–Omentum (multiple 2 mm foci)	IVB	Chemotherapy	DOD, 2 mos
62	Abdominal distension	SSC	EIC and atrophy	SC–Omentum (gross)	IVB	Chemotherapy	DOD, 11 mos

AWD, alive with disease; DOD, dead of disease, EIC, endometrial intraepithelial carcinoma; IC, intraepithelial carcinoma; NED, no evidence of disease; SC, metastatic serous carcinoma.
* Abnormal cervical smear was interpreted as one with malignant endometrial cells.
† Benign endometrial polyp that did not contain EIC or SSC.

Am J Surg Pathol. 2000 Jun;24(6):797-806.

Minimal uterine serous carcinoma: diagnosis and clinicopathologic correlation.

Wheeler DT, Bell KA, Kurman RJ, Sherman ME.

TABLE I: Clinicopathological Features of Minimal Uterine Serous Carcinoma (n = 40 cases)

#	Age	Presentation	Pap	Biopsy/Curettage	Uterus cm	Polyp Size cm	Tumor Endometrial Polyp	Tumor Endometrium p roper	Extrauterine Dis	Stage	P53 Score	Survival F/U (mo)	Status
1	49	Cervical HPV	HPV	EMB+	6.5		Benign polyp	ISC	NO	IA	0	64	alive/NED
2	64	PMB	ND	EMC+	12	2.7, 2.3	ISC	NO	NO	IA	9	1	alive/NED
3	61	PMB	ND	EMC+	5.5	0.4, 0.9, 4.5	ISC	NO	NO	IA	9	5	alive/NED
4	68	PMB	ND	EMC+		6.5,3.5	ISC	NO	NO	IA	9	9	alive/NED
5	73	Pap(+)	NEG	EMB+	6	1.7	ISC	NO	NO	IA	0	27	alive/NED
6	72	PMB	NEG	EMC+	5		No polyp	ISC	NO	IA	7	41	alive/NED
7	56	ABD	ND	ABD BX+	9.2	0.9	Benign polyp	ISC	YES	IVB	7*	22	alive/with dis ease
8	71	Pap(+)	POS	EMB+	8.2	2.9	ISC	NO	YES	IVB	8	26	dead of disease
9	76	ABD	ND	No prior specimen	10		No polyp	ISC	YES	IVB	7*	62	dead of disease
10	67	PMB	NEG	EMB+	7	1.5, 1.2	ISC, SSC	NO	NO	IA	9	55	alive/NED
11	68	PMB	ND	EMC+	5	2.5	ISC,SSC	NO	NO	IA	7	13	alive/NED
12	73	PMB	ND	EMB+	6.5	3	ISC,SSC	ISC	NO	IA	9	25	alive/NED
13	54	PMB	POS	EMC+	7.5	1.7	ISC,SSC	ISC	NO	IA	9	8	alive/NED
14	56	PMB	ND	EMB+	7		ISC,SSC	NO	NO	IA	5	51	alive/NED
15	57	PMB	ND	EMC+	4.5	1.2	ISC,SSC	NO	NO	IA	0	67	alive/NED
16	58	Unknown	ND	EMB+	9.5		ISC,SSC	NO	NO	IA	ND	34	alive/NED
17	58	PMB	ND	EMC+	7		ISC,SSC	NO	NO	IA	ND	47	alive/NED
18	71	Pap(+)	POS	EMB+	8	2.9	ISC,SSC	NO	NO	IA	7	25	alive/NED
19	72	PMB	ND	EMC+	10	3	ISC,SSC	NO	NO	IA	7	26	lost/NED
20	75	PMB	ND	EMC+	9	2	ISC,SSC	NO	NO	IA	3	26	alive/NED
21	83	Unknown	ND	EMB+	7.7	1.5	ISC,SSC	NO	NO	IA	8		lost follow-up
22	63	Pap(+)	POS	EMC+			ISC/SSC	ISC	NO	IA	ND	14	alive/NED
23	69	PMB	ND	EMC+	7.5		SSC	ISC	NO	IA	8		lost follow-up
24	52	Unknown	ND	EMC+	8.5	2.5	ISC,SSC	ISC	NO	IIA	3	27	lost/NED
25	68	PMB	ND	EMC+	8	5.5	ISC,SSC	ISC	NO	IIA	0	23	dead of disease
26	80	PMB	ND	EMB+	8		ISC,SSC	NO	YES	IVB	7*	12	alive/NED
27	70	PMB	ND	EMC+	7	2.7	ISC,SSC	ISC	YES	IIIA	9	17	alive/NED
28	70	Pap(+)	POS	EMC+	9.3	1	ISC,SSC	ISC,SSC	YES	IIIA	8	8	alive/NED
29	67	ABD	ND	No prior specimen	8.5	1	ISC,SSC	NO	YES	IVB	9	7	lost/NED
30	72	PMB	ND	No prior specimen	7.5		No polyp	ISC,SSC	YES	IIIA	0	16	dead of disease
31	52	Pap(+)	POS	EMC+	9		ISC,SSC	NO	YES	IIIC	6	60	alive/NED
32	64	ABD	ND	No prior specimen	7.5	5	ISC	ISC,SSC	YES	IVB	9	13	dead of disease
33	63	Pap(+)	POS	EMB+	7	5.2	ISC,SSC	ISC	YES	IVB	9	8	alive with disease
34	65	ABD	ND	EMC+	8	1.3	ISC,SSC	ISC	YES	IVB	0	19	dead of disease
35	68	PMB	ND	EMC+	7.5	1	ISC,SSC	ISC,SSC	YES	IVB	8	19	dead of disease
36	74	ABD	ND	FNA/omentum+	10	2	ISC,SSC	ISC,SSC	YES	IVB	0	14	dead of disease
37	62	ABD	NEG	No prior specimen	9.5	1.4	ISC,SSC	NO	YES	IVB	0	27	alive with disease
38	69	ABD	NEG	Paracentisis+	8	7.5	ISC,SSC	NO	YES	IVB	7*	1.5	alive with disease
39	72	PMB	ND	EMC+	8.5	1.5	ISC,SSC	NO	YES	IVB	7	3	dead another cause
40	77	Unknown	ND	EMB+	7.2		ISC,SSC	NO	YES	IVB	8	36	dead of disease

Abbreviations: PMB-postmenopausal bleeding; HPV-human papilloma virus; ABD- abdominal distension; ISC: intraepithelial serous carcinoma; SSC- superficial serous carcinoma; ND- not done; LN- lymph node; NED- no evidence of disease; EMB- endometrial biopsy; EMC- endometrial curettage; FNA- fine needle aspiration; *- p53 score is 7 or above. Pap (+)- papanicolau smear is positive for malignant cells.

Minimal uterine serous carcinomas involving an endometrial polyp in 88 % of the cases (35/40) and being confined to the polyp in 53% (21/40).

Minimal uterine serous carcinoma: a clinicopathological study of 40 cases.

Hui P, Kelly M, O'Malley DM, Tavassoli F, Schwartz PE.

Mod Pathol. 2005 Jan;18(1):75-82. doi: 10.1038/modpathol.3800271.

Multicenter Study > Am J Clin Oncol. 2019 May;42(5):472-480.
doi: 10.1097/COC.0000000000000541.

Uterine Papillary Serous Carcinoma Arising in a Polyp: A Multicenter Retrospective Analysis on 75 Patients

Vincenzo D Mandato [1], Federica Torricelli [2], Stefano Palomba [1], Stefano Uccella [3] [4], Debora Pirillo [1], Gino Ciarlini [5], Pierandrea De Iaco [6], Emilio Lucia [7], Giorgio Giorda [7], Antonino Ditto [8], Fabio Ghezzi [3], Francesca Sanseverino [9], Massimo Franchi [10], Giuseppe Bifulco [11], Valentina Mastrofilippo [5], Martino Abrate [5], Lorenzo Aguzzoli [5], Giovanni B La Sala [1]

75 serous carcinomas involving a polyp: 56 (75%) polyp-confined cases and 19 cases with concurrent involvement of both the endometrial polyp and the background endometrial mucosa

Human Pathology (2021) **118**, 1–8



Human PATHOLOGY

www.elsevier.com/locate/humpath

Original contribution

Minimal uterine serous carcinoma and endometrial polyp: a close clinicopathological relationship ☆



Hisham Assem MD [a], Douglas Rottmann MD [a], Alexander Finkelstein MD [b], Minhua Wang MD,PhD [a], Elena Ratner MD [c], Alessandro D. Santin MD [c], Natalia Buza MD [a], Pei Hui MD,PhD [a,*]

77 fully staged MUSCs involving endometrial polyp

- 53 MUSCs confined to polyp
- 24 non-polyp confined tumors

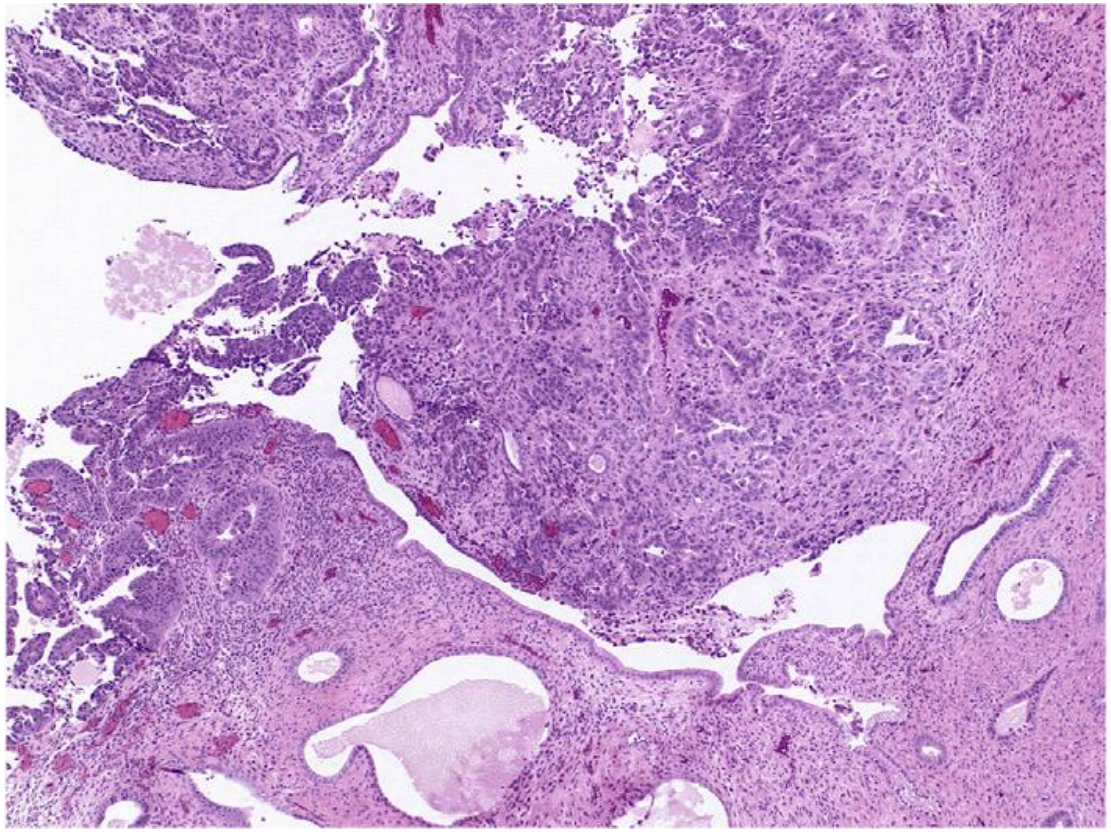

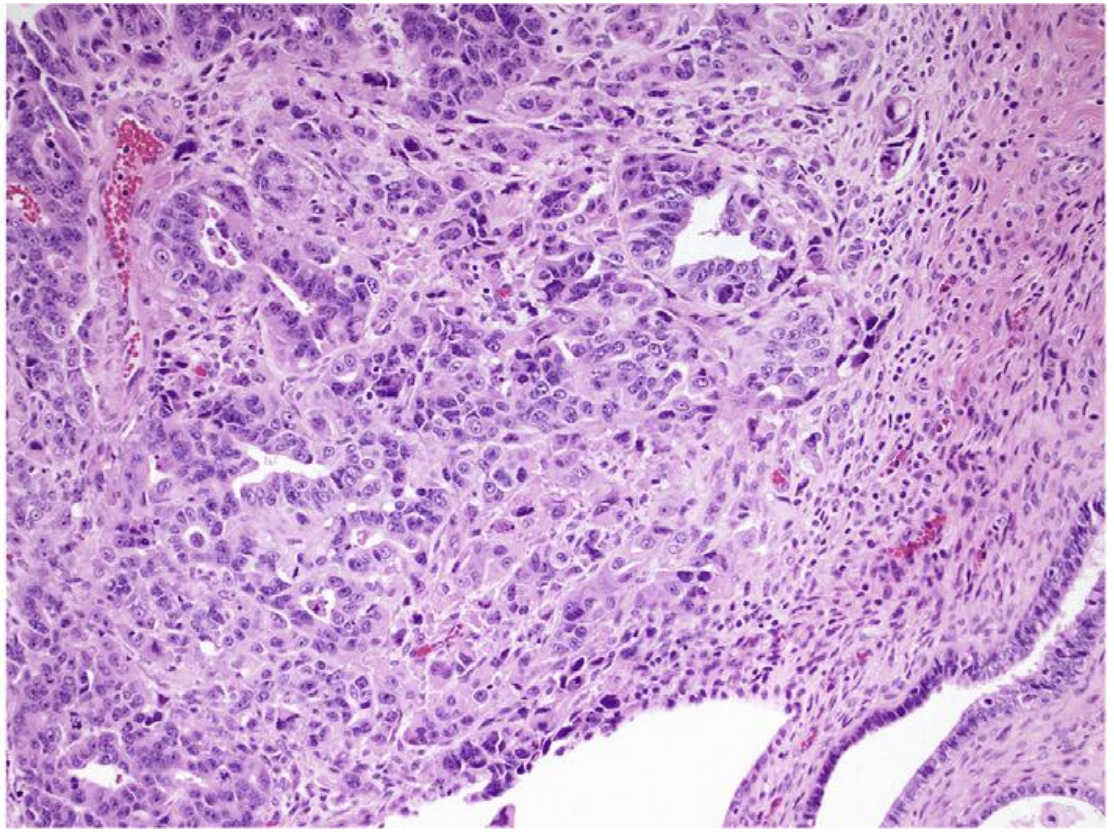

Assem H et al. Hum Pathol. 2021 Dec;118:1-8.

Observational Study > Int J Gynecol Cancer. 2023 Jun 5;33(6):905-914.
doi: 10.1136/ijgc-2023-004281.

Serous endometrial intra-epithelial carcinoma: an observational study

Ciska Slaager [1 2], Ward Hofhuis [3], Klaas J Hoogduin [4], Patricia C Ewing-Graham [5], Heleen J van Beekhuizen [2 6]

Affiliations + expand

PMID: 37130624 DOI: 10.1136/ijgc-2023-004281

Results: A total of 23 patients from 13 medical centers were included, of whom 15 (65.2%) presented with post-menopausal blood loss. In 17 patients (73.9%) the intra-epithelial lesion was present in an endometrial polyp. All patients underwent hysterectomy, of whom 12 patients (52.2%) were surgically staged. None of the staged patients showed extra-uterine disease. Two patients received adjuvant brachytherapy. There were no recurrences of disease (median follow-up duration of 35.6 months (range 1.0-108.6) and no disease-related deaths in this cohort.

The earliest recognition of a strong relationship between endometrial polyp and endometrial serous carcinoma was reported in 16 cases, of which 6 patients (37.5%) presented with concurrent extrauterine disease. Silva EG, Jenkins R. Serous carcinoma in endometrial polyps. *Mod Pathol.* 1990;3(2):120-128.

13 stage IA serous carcinomas, 6 tumors were solely identified within an endometrial polyp and additional 4 tumors involved both the endometrial polyp and background endometrium. Carcangiu ML. Stage IA uterine serous carcinoma: a study of 13 cases. *Am J Surg Pathol.* 1997;21(12):1507-1514.

21 cases of MUSC of which 10 were confined to an endometrial polyp and an additional 9 involved both the endometrial polyp and background endometrium. Wheeler DT, Bell KA, Kurman RJ, Sherman ME. Minimal uterine serous carcinoma: diagnosis and clinicopathologic correlation. *Am J Surg Pathol.* 2000;24(6):797-806.

5 cases of uterine serous carcinoma involving an endometrial polyp, two of which were confined to the endometrial polyp. McCluggage WG, Sumathi VP, McManus DT. Uterine serous carcinoma and endometrial intraepithelial carcinoma arising in endometrial polyps: report of 5 cases, including 2 associated with tamoxifen therapy. *Hum Pathol.* 2003;34(9):939-943.

13 cases of non-myometrial invasive uterine serous carcinoma involving an endometrial polyp, all except one were limited to the polyp. Trahan S, Tetu B, Raymond PE. Serous papillary carcinoma of the endometrium arising from endometrial polyps: a clinical, histological, and immunohistochemical study of 13 cases. *Hum Pathol.* 2005;36(12):1316-1321.

40 cases of MUSC, of which 35 tumors involved an endometrial polyp (88%) and 21 tumors (53%) were confined to an endometrial polyp. Hui P, Kelly M, O'Malley DM, Tavassoli F, Schwartz PE. Minimal uterine serous carcinoma: a clinicopathological study of 40 cases. *Mod Pathol.* 2005;18(1):75-82.

8 MUSC involved an endometrial polyp, 4 tumors were confined to the polyp. Yasuda M, Katoh T, Hori S, et al. Endometrial intraepithelial carcinoma in association with polyp: review of eight cases. *Diagn Pathol.* 2013;8:25.

44 patients with stage IA endometrial serous carcinoma including MUSC and those beyond the size limit of MUSC, the tumor was confined to an endometrial polyp in 17 cases (30.9%). Semaan A, et al. Clinical and pathologic characteristics of serous carcinoma confined to the endometrium: a multi-institutional study. *Int J Gynecol Pathol.* 2013;32(2):181-187.

37 polypoid SEIC. Trinh et al. Distinct Histologic, Immunohistochemical and Clinical Features Associated With Serous Endometrial Intraepithelial Carcinoma Involving Polyps. IJGP, 2019;39:128-135

A multi-institutional series 75 serous carcinomas involving a polyp, including 56 (75%) polyp-confined cases and 19 cases with concurrent involvement of both the endometrial polyp and the background endometrial mucosa. Mandato , et al. Uterine Papillary Serous Carcinoma Arising in a Polyp: A Multicenter Retrospective Analysis on 75 Patients. *Am J Clin Oncol.* 2019;42(5):472-480.

In the largest series of MUSC of 77 consecutive, fully staged pure serous carcinomas without myometrial invasion, 77 MUSCs (76%, 77/101) involved an endometrial polyp, of which 68.8% (53/77) confined to the polyp. Assem H, et al. Minimal uterine serous carcinoma and endometrial polyp: a close clinicopathological relationship. *Hum Pathol.* 2021;118:1-8.

- Significant number of study series over the years
- 90% of MUSCs involving an endometrial polyp
- 40 to 70 % of MUSCs confined to a polyp at the time of staging surgery

Review > Arch Pathol Lab Med. 2023 Apr 1;147(4):413-417. doi: 10.5858/arpa.2021-0557-RA.

Endometrial Polyp in Postmenopausal Women: An Epicenter for the Development of Endometrial Serous Carcinoma

Pei Hui [1]

CLINICAL BEHAVIOR OF MINIMAL UTERINE SEROUS CARCINOMA

Prognosis of SEIC:

- A unique feature of SEIC is that although not invading the stroma, it is frequently associated with disseminated pelvic serous carcinoma

- Clinically and Biologically it is not an “in-situ carcinoma”

MODERN PATHOLOGY

Institution: YALE MEDICAL LIB || Sign In as Member/Individual (Non-Member) || Contact Subscription Administrator at your institution || FAQ

Modern Pathology, Vol 3, Issue 2 120-128, Copyright © 1990 by United States and Canadian Academy of Pathology

Similar articles found in:
Modern Pathology Online
PubMed
PubMed Citation
Search Medline for articles by:
Silva, E. || Jenkins, R
Alert me when:
new articles cite this article
Download to Citation Manager

ARTICLES

Serous carcinoma in endometrial polyps

EG Silva and R Jenkins
Department of Pathology, University of Texas M.D. Anderson Cancer Center, Houston.

Sixteen patients who had serous carcinoma involving endometrial polyps and who demonstrated rare or absent myometrial or lymphovascular invasion are reported. Six of these patients had clinical manifestations of extrauterine disease at presentation. Of the ten patients who presented with clinical stage I disease, six eventually developed extrauterine recurrence, and four of these six were dead of disease within 19 mo of recurrence. Similarities between the patients who presented with extrauterine disease and the patients who presented with clinical stage I disease, including high percentages of patients with hyperplasia of ovarian epithelium surface and of fallopian tube epithelium, suggest that serous carcinoma involving endometrial polyps may represent one aspect of a multicentric disease. In such multicentricity, the entire female genital tract and the abdominal peritoneal surfaces would be at high risk for concurrent or subsequent involvement by serous carcinoma even in the absence of myometrial or lymphovascular invasion.

Endometrial polyp with serous carcinoma was reported in 16 cases, of which 6 patients (37.5%) presented with concurrent extrauterine disease and 6 more developed extrauterine recurrence.

Age (yrs)	Clinical presentation	Endometrial tumor distribution		Extrauterine disease	FIGO stage	Postoperative therapy	Follow up
		Polyp	Non-polyp area				
62	Postmenopausal bleeding	EIC	EIC and atrophy	None	IA	None	NED, 4 mos
52	Abnormal cervical smear*	No polyp	EIC and atrophy	None	IA	None	NED, 14 mos
65	Abnormal cervical smear*	EIC	Atrophy	None	IA	None	DOC, 52 mos
69	Abnormal cervical smear*	EIC	Simple hyperplasia	None	IA	None	NED, 22 mos
62	Postmenopausal bleeding	EIC	Atrophy	None	IA	None	NED, 41 mos
62	Postmenopausal bleeding	EIC	Atrophy	None	IIA	Chemotherapy	NED, 20 mos
58	Abnormal cervical smear*	EIC	EIC and atrophy	IC–Ovary (<1 mm)	IIIA	WAPRT	AWD, 10 mos
65	Postmenopausal bleeding	EIC	EIC and atrophy	IC–Ovary (4 mm)	IIIA	Chemotherapy	AWD, 8 mos

AWD, alive with disease; DOC, dead of other causes; DOD, dead of disease; IC, intraepithelial carcinoma; NED, no evidence of disease; WAPRT, whole abdomen and pelvic radiotherapy.
* Abnormal cervical smear was interpreted as one with malignant endometrial cells.

Age (yrs)	Clinical presentation	Endometrial tumor distribution		Extrauterine disease	FIGO stage	Postoperative therapy	Follow up
		Polyp	Non-polyp area				
79	Postmenopausal bleeding	SSC	Atrophy	None	IA	None	NED, 42 mos
65	Postmenopausal bleeding	SSC	Atrophy	None	IA	None	NED, 63 mos
67	Postmenopausal bleeding	SSC + EIC	EIC and atrophy	None	IA	None	NED, 50 mos
63	Abnormal cervical smear*	SSC	Atrophy	None	IA	None	NED, 50 mos
72	Postmenopausal bleeding	SSC + EIC	EIC and atrophy	None	IA	None	NED, 9 mos
65	Postmenopausal bleeding	SSC + EIC	EIC and atrophy	None	IA	None	NED, 49 mos
77	Abnormal cervical smear*	SSC + EIC	EIC and atrophy	None	IIA	Chemotherapy	NED, 12 mos
60	Postmenopausal bleeding	SSC + EIC	EIC and atrophy	None	IIA	None	NED, 54 mos
60	Postmenopausal bleeding	No tumor†	SSC, EIC, and atrophy	SC–Fallopian tube lumen (16 mm)	IIIA	Chemotherapy	AWD, 5 mos
62	Postmenopausal bleeding	SSC	Simple hyperplasia	IC–ovary (2 mm)	IIIA	Chemotherapy	DOC, 38 mos
63	Postmenopausal bleeding	SSC + EIC	Atrophy	SC–bowel (6 mm)	IVA	Chemotherapy	DOD, 13 mos
76	Postmenopausal bleeding	SSC + EIC	Simple hyperplasia	SC–Omentum (multiple 2 mm foci)	IVB	Chemotherapy	DOD, 2 mos
62	Abdominal distension	SSC	EIC and atrophy	SC–Omentum (gross)	IVB	Chemotherapy	DOD, 11 mos

AWD, alive with disease; DOD, dead of disease, EIC, endometrial intraepithelial carcinoma; IC, intraepithelial carcinoma; NED, no evidence of disease; SC, metastatic serous carcinoma.
* Abnormal cervical smear was interpreted as one with malignant endometrial cells.
† Benign endometrial polyp that did not contain EIC or SSC.

7 of 21 MUSC (33%) presenting with extrauterine spread

Am J Surg Pathol. 2000 Jun;24(6):797-806.

Minimal uterine serous carcinoma: diagnosis and clinicopathologic correlation.

Wheeler DT, Bell KA, Kurman RJ, Sherman ME.

TABLE I: Clinicopathological Features of Minimal Uterine Serous Carcinoma (n = 40 cases)

#	Age	Presentation	Pap	Biopsy/Curettage	Uterus cm	Polyp Size cm	Tumor Endometrial Polyp	Tumor Endometrium proper	Extrauterine Dis	Stage	P53 Score	Survival F/U (mo)	Status
1	49	Cervical HPV	HPV	EMB+	6.5		Benign polyp	ISC	NO	IA	0	64	alive/NED
2	64	PMB	ND	EMC+	12	2.7, 2.3	ISC	NO	NO	IA	9	1	alive/NED
3	61	PMB	ND	EMC+	5.5	0.4, 0.9, 4.5	ISC	NO	NO	IA	9	5	alive/NED
4	68	PMB	ND	EMC+		6.5,3.5	ISC	NO	NO	IA	9	9	alive/NED
5	73	Pap(+)	NEG	EMB+	6	1.7	ISC	NO	NO	IA	0	27	alive/NED
6	72	PMB	NEG	EMC+	5		No polyp	ISC	NO	IA	7	41	alive/NED
7	56	ABD	ND	ABD BX+	9.2	0.9	Benign polyp	ISC	YES	IVB	7*	22	alive/with disease
8	71	Pap(+)	POS	EMB+	8.2	2.9	ISC	NO	YES	IVB	8	26	dead of disease
9	76	ABD	ND	No prior specimen	10		No polyp	ISC	YES	IVB	7*	62	dead of disease
10	67	PMB	NEG	EMB+	7	1.5, 1.2	ISC, SSC	NO	NO	IA	9	55	alive/NED
11	68	PMB	ND	EMC+	5	2.5	ISC,SSC	NO	NO	IA	7	13	alive/NED
12	73	PMB	ND	EMB+	6.5	3	ISC,SSC	ISC	NO	IA	9	25	alive/NED
13	54	PMB	POS	EMC+	7.5	1.7	ISC,SSC	ISC	NO	IA	9	8	alive/NED
14	56	PMB	ND	EMB+	7		ISC,SSC	NO	NO	IA	5	51	alive/NED
15	57	PMB	ND	EMC+	4.5	1.2	ISC,SSC	NO	NO	IA	0	67	alive/NED
16	58	Unknown	ND	EMB+	9.5		ISC,SSC	NO	NO	IA	ND	34	alive/NED
17	58	PMB	ND	EMC+	7		ISC,SSC	NO	NO	IA	ND	47	alive/NED
18	71	Pap(+)	POS	EMB+	8	2.9	ISC,SSC	NO	NO	IA	7	25	alive/NED
19	72	PMB	ND	EMC+	10	3	ISC,SSC	NO	NO	IA	7	26	lost/NED
20	75	PMB	ND	EMC+	9	2	ISC,SSC	NO	NO	IA	3	26	alive/NED
21	83	Unknown	ND	EMB+	7.7	1.5	ISC,SSC	NO	NO	IA	8		lost follow-up
22	63	Pap(+)	POS	EMC+			ISC/SSC	ISC	NO	IA	ND	14	alive/NED
23	69	PMB	ND	EMC+	7.5		SSC	ISC	NO	IA	8		lost follow-up
24	52	Unknown	ND	EMC+	8.5	2.5	ISC,SSC	ISC	NO	IIA	3	27	lost/NED
25	68	PMB	ND	EMC+	8	5.5	ISC,SSC	ISC	NO	IIA	0	23	dead of disease
26	80	PMB	ND	EMB+	8		ISC,SSC	NO	YES	IVB	7*	12	alive/NED
27	70	PMB	ND	EMC+	7	2.7	ISC,SSC	ISC	YES	IIIA	9	17	alive/NED
28	70	Pap(+)	POS	EMC+	9.3	1	ISC,SSC	ISC,SSC	YES	IIIA	8	8	alive/NED
29	67	ABD	ND	No prior specimen	8.5	1	ISC,SSC	NO	YES	IVB	9	7	lost/NED
30	72	PMB	ND	No prior specimen	7.5		No polyp	ISC,SSC	YES	IIIA	0	16	dead of disease
31	52	Pap(+)	POS	EMC+	9		ISC,SSC	NO	YES	IIIC	6	60	alive/NED
32	64	ABD	ND	No prior specimen	7.5	5	ISC	ISC,SSC	YES	IVB	9	13	dead of disease
33	63	Pap(+)	POS	EMB+	7	5.2	ISC,SSC	ISC	YES	IVB	9	8	alive with disease
34	65	ABD	ND	EMC+	8	1.3	ISC,SSC	ISC	YES	IVB	0	19	dead of disease
35	68	PMB	ND	EMC+	7.5	1	ISC,SSC	ISC,SSC	YES	IVB	8	19	dead of disease
36	74	ABD	ND	FNA/omentum+	10	2	ISC,SSC	ISC,SSC	YES	IVB	0	14	dead of disease
37	62	ABD	NEG	No prior specimen	9.5	1.4	ISC,SSC	NO	YES	IVB	0	27	alive with disease
38	69	ABD	NEG	Paracentisis+	8	7.5	ISC,SSC	NO	YES	IVB	7*	1.5	alive with disease
39	72	PMB	ND	EMC+	8.5	1.5	ISC,SSC	NO	YES	IVB	7	3	dead another cause
40	77	Unknown	ND	EMB+	7.2		ISC,SSC	NO	YES	IVB	8	36	dead of disease

Abbreviations: PMB-postmenopausal bleeding; HPV-human papilloma virus; ABD- abdominal distension; ISC: intraepithelial serous carcinoma; SSC- superficial serous carcinoma; ND- not done; LN- lymph node; NED- no evidence of disease; EMB- endometrial biopsy; EMC- endometrial curettage; FNA- fine needle aspiration; *- p53 score is 7 or above. Pap (+)- papanicolau smear is positive for malignant cells.

45% MUSC present with extrauterine tumors in our study

Minimal uterine serous carcinoma: a clinicopathological study of 40 cases.
Hui P, Kelly M, O'Malley DM, Tavassoli F, Schwartz PE.
Mod Pathol. 2005 Jan;18(1):75-82. doi: 10.1038/modpathol.3800271.

SEIC has a 40% (31/81 cases) of extrauterine disease at time of staging surgery

Ronsini C, et al. Critical overview of serous endometrial intraepithelial caner treatment: systematic review of adjuvant options. Life 2023,13-1429: 1-11.

OVARY

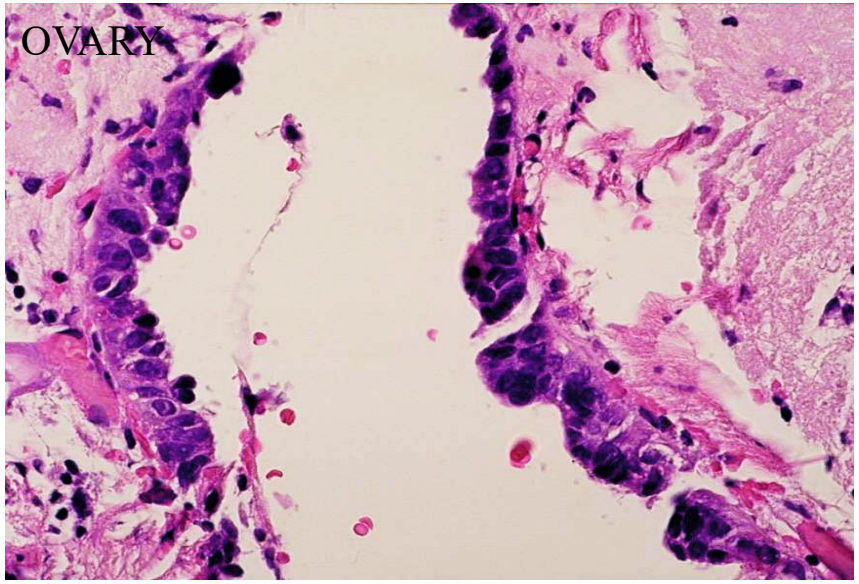

FALLOPAIN TUBE

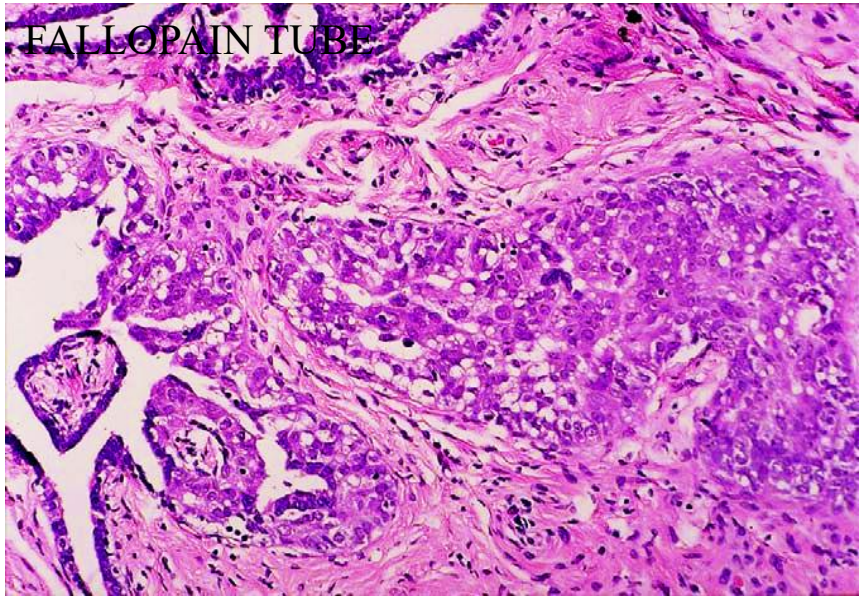

OMENTUM

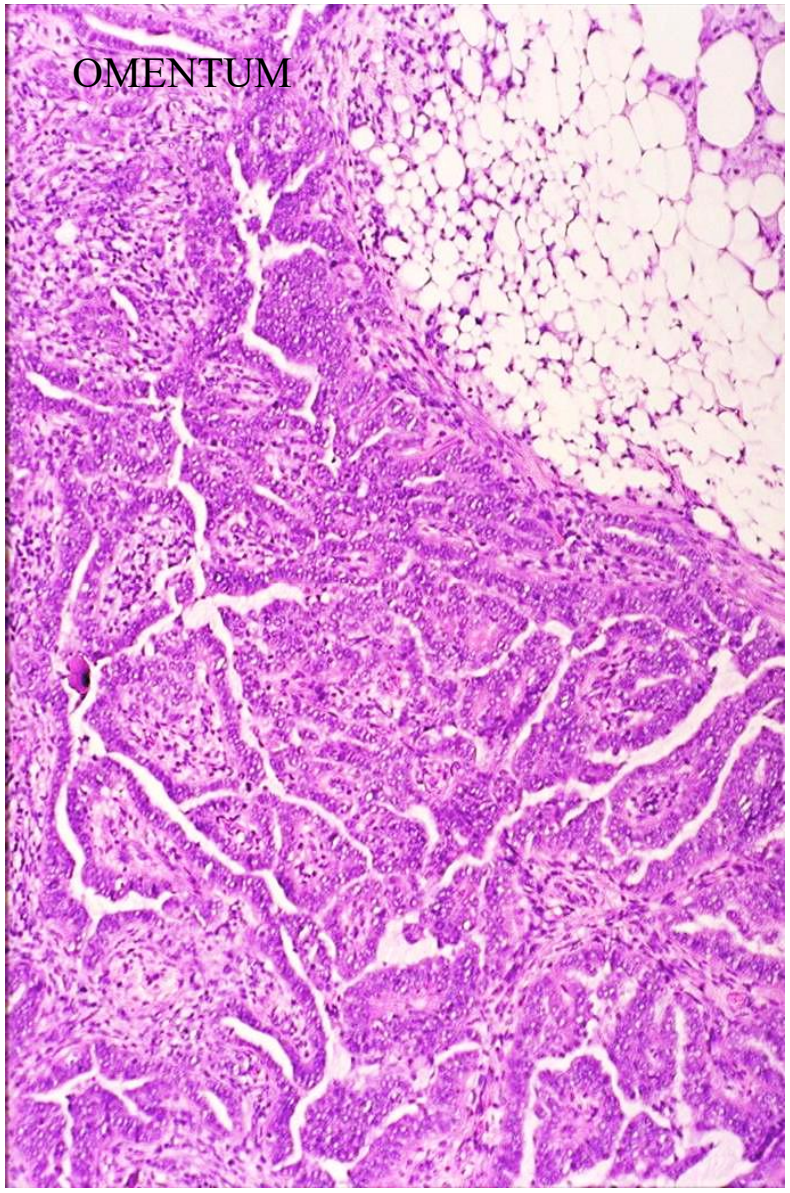

Int J Gynecol Pathol. 2001 Jul;20(3):214-9. doi: 10.1097/00004347-200107000-00002.

Early uterine serous carcinoma: clonal origin of extrauterine disease

R N Baergen [1], C D Warren, C Isacson, L H Ellenson

In all 4 MUSCs, the primary tumors and the associated extrauterine tumor foci had identical p53 mutations

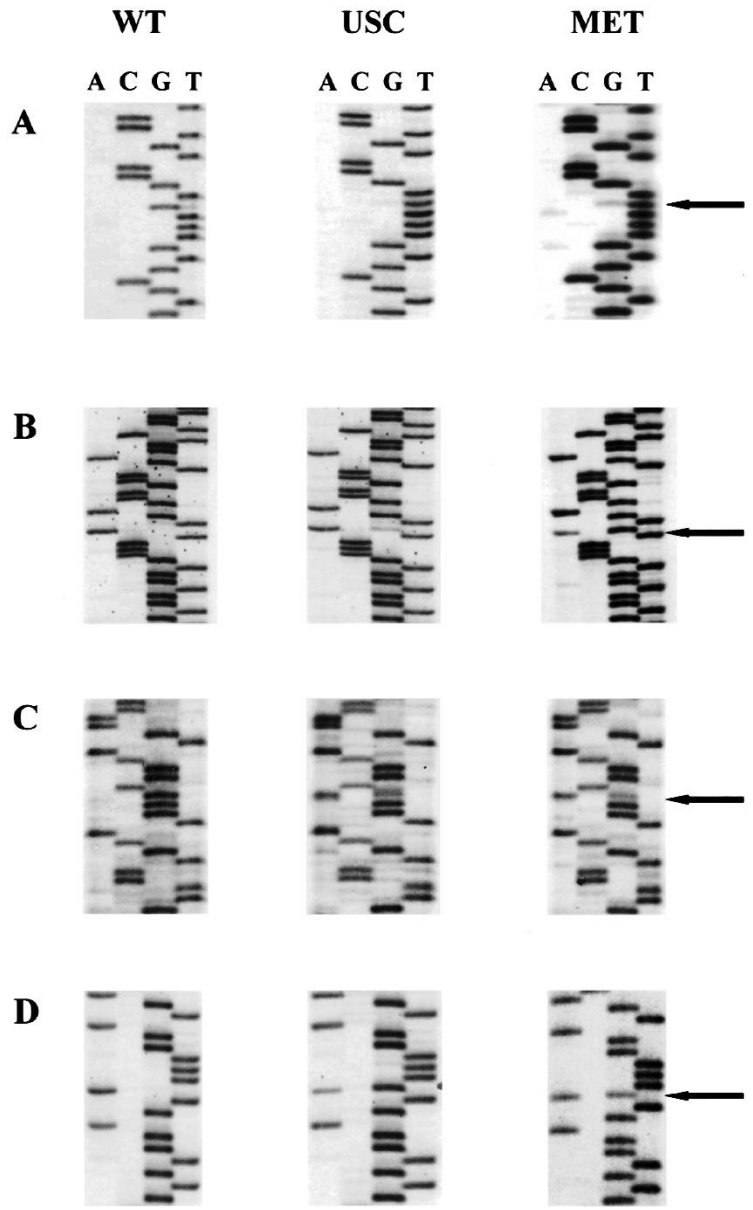

Int J Gynecol Pathol. 2006 Apr;25(2):155-60. doi: 10.1097/01.pgp.0000179614.47838.82.

Transtubal spread of serous adenocarcinoma of the endometrium: an underrecognized mechanism of metastasis

Matthew J Snyder [1], Rex Bentley, Stanley J Robboy

Table 2 Clinicopathological presentation of minimal uterine serous carcinoma (N = 77).

		MUSC confined to EMP	MUSC unconfined to EMP	Total	Chi-Square (p value)
No. Cases (n)		53	24	77	
Average age at presentation (years)		67.38	69.96	68.38	0.16
FIGO Stage (n)	I or II	44	14	58	0.02
	III or IV	9	10	19	
Positive Pelvic Cytology (n)		4 (stage IA)		19	0.078
		6 (stage III or IV)	9 (stage III or IV)		
LVI (n)		2	6	8	0.047
Lymph node metastasis ## (n)		6	7	13	0.058
Follow-up range, median (months)		1.3–134.1, 35.8	3.6–159.7, 42.8		0.89
Tumor recurrence (n)		10	9	19	0.08
Dead of Disease (n)		5	7	12	0.03

MUSC: minimal uterine serous carcinoma; EMP: endometrial polyp; LVI - Lymphovascular invasion.
Involving either pelvic and/or periaortic lymph nodes.

Assem H et al. Hum Pathol. 2021 Dec;118:1-8.

Are all MUCS the same ?

Significant percentage (up to 71%) of MUSCs and (27%) endometrial serous carcinomas in general express WT-1

› Appl Immunohistochem Mol Morphol. 2010 Jan;18(1):75-9. doi: 10.1097/PAI.0b013e3181b1d10e.

Minimal uterine serous carcinoma with extrauterine tumor of identical morphology: an immunohistochemical study of 13 cases

Zhijie Yan [1], Pei Hui

Review › Diagnostics (Basel). 2020 Aug 26;10(9):637. doi: 10.3390/diagnostics10090637.

Diagnostic and Prognostic Role of WT1 Immunohistochemical Expression in Uterine Carcinoma: A Systematic Review and Meta-Analysis across All Endometrial Carcinoma Histotypes

Giuseppe Angelico [1], Angela Santoro [1], Patrizia Straccia [1], Frediano Inzani [1], Federica Cianfrini [1], Saveria Spadola [1], Damiano Arciuolo [1], Michele Valente [1], Nicoletta D'Alessandris [1], Antonino Mulè [1], Gian Franco Zannoni [1] [2]

WT1 is differentially expressed in serous, endometrioid, clear cell, and mucinous carcinomas of the peritoneum, fallopian tube, ovary, and endometrium.

Acs G, Pasha T, Zhang PJ.

Int J Gynecol Pathol. 2004 Apr;23(2):110-8. doi: 10.1097/00004347-200404000-00004.
PMID: 15084838

Comparative Study > Am J Surg Pathol. 2005 Aug;29(8):1074-8.

Differential expression of WT-1 in serous carcinomas in the peritoneum with or without associated serous carcinoma in endometrial polyps

Elizabeth D Euscher [1], Anais Malpica, Michael T Deavers, Elvio G Silva

92% of ovarian serous carcinomas and 80% of peritoneal serous carcinomas without serous carcinoma involving an endometrial polyp expressed WT-1. 12% of peritoneal serous carcinomas with serous carcinoma in an endometrial polyp expressed WT-1 with the serous carcinoma in the endometrial polyp staining concordantly. For uterine serous carcinoma without an endometrial polyp, 11% expressed WT-1.

- The difference in WT-1 expression among serous carcinomas suggests a difference in biology based on the site of origin.

- Difference in WT-1 expression between peritoneal serous carcinomas with and without coexistent serous carcinoma in endometrial polyps suggests that peritoneal serous carcinoma may have different pathogenetic pathways.

Expression of WT-1 in endometrial serous carcinoma predicates a worse disease-free survival in a study of 77 cases

› Hum Pathol. 2014 Sep;45(9):1879-84. doi: 10.1016/j.humpath.2014.05.009. Epub 2014 Jun 4.

The frequency and significance of WT-1 expression in serous endometrial carcinoma

Catherine Hedley [1], Ruethairat Sriraksa [2], Rania Showeil [3], Susan Van Noorden [4], Mona El-Bahrawy [5]

Low level Endometrial Cancer Driver Gene Mutations
Changes in the Epithelial Compartment of EMP

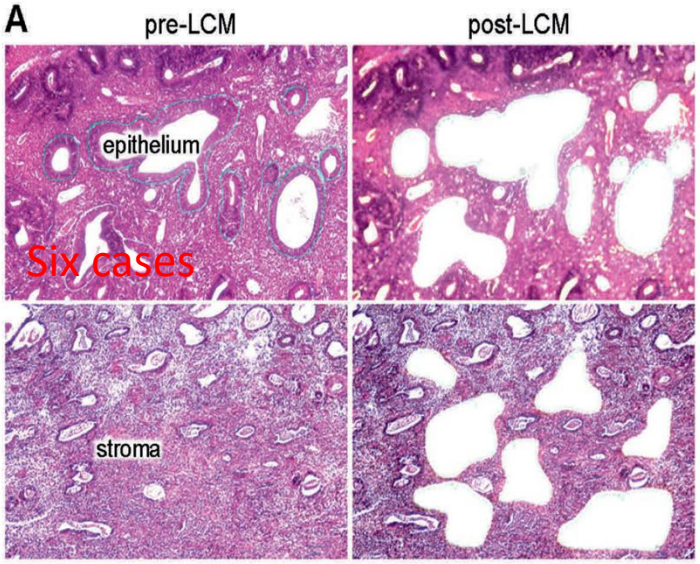

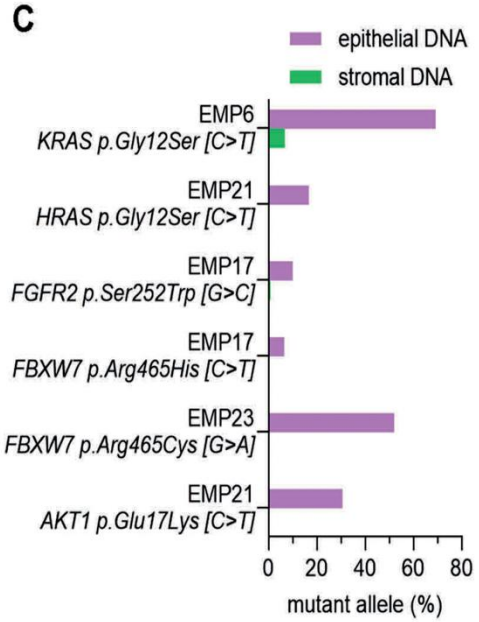

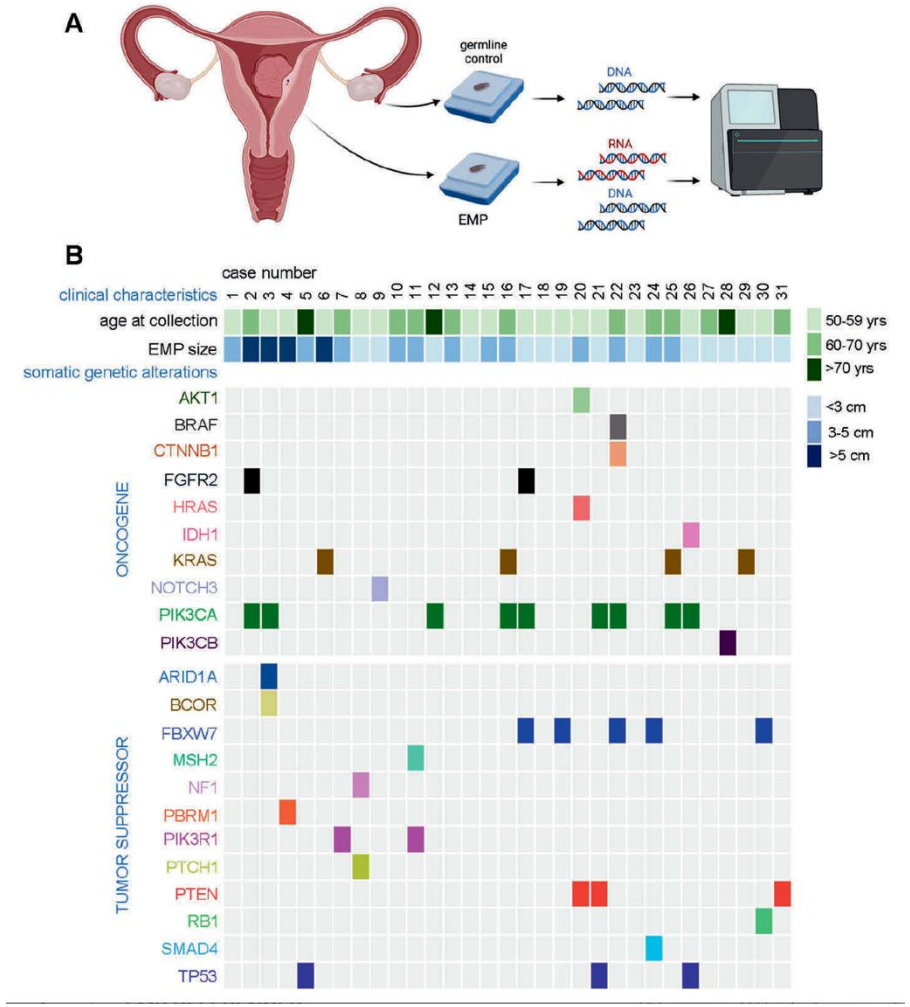

Endometrial polyps are non-neoplastic but harbor epithelial mutations in endometrial cancer drivers at low allelic frequencies.

Sahoo SS, Aguilar M, Xu Y, Lucas E, Miller V, Chen H, Zheng W, Cuevas IC, Li HD, Hitrys D, Wachsmann MB, Bishop JA, Cantarell B, Gagan J, Koduru P, SoRelle JA, Castrillon DH.

Mod Pathol. 2022 Nov;35(11):1702-1712. doi: 10.1038/s41379-022-01124-5. Epub 2022 Jul 7.

- MUSC is strongly associated with endometrial polyps: >2/3 involving a polyp and > 48% confined to one {10843281; 15389257; 34508766}.
- MUSCs extending to the background endometrium more likely associated with high stage disease {34508766}
- SEIC involving a polyp may spread to extrauterine sites in up to 40% of cases {10843281; 11444195; 15389257; 37511804}.
- Timely diagnosis of MUSC can not be overemphasized – Endometrial polyps in postmenopausal patients – **DON'T MISS**

Take Home Message

Endometrial Polyp in Postmenopausal Patient is *an Epic Center* of the Development of Endometrial Serous Carcinoma

THANK YOU!

