Practical evaluation of cervical malignancies

Professor Raji Ganesan

Birmingham Women's Hospital

United Kingdom

Outline of topics

- Squamous lesions
  - Invasion or not
    - 'Pseudoinvasion'
    - Pleomorphic CIN3
  - Patterns of invasion
    - CIN3 like carcinoma
  - Unusual low grade lesions
  - HPV independent squamous lesions
- General
  - Measurements
  - Vascular invasion

Features of invasion in cervical squamous carcinoma

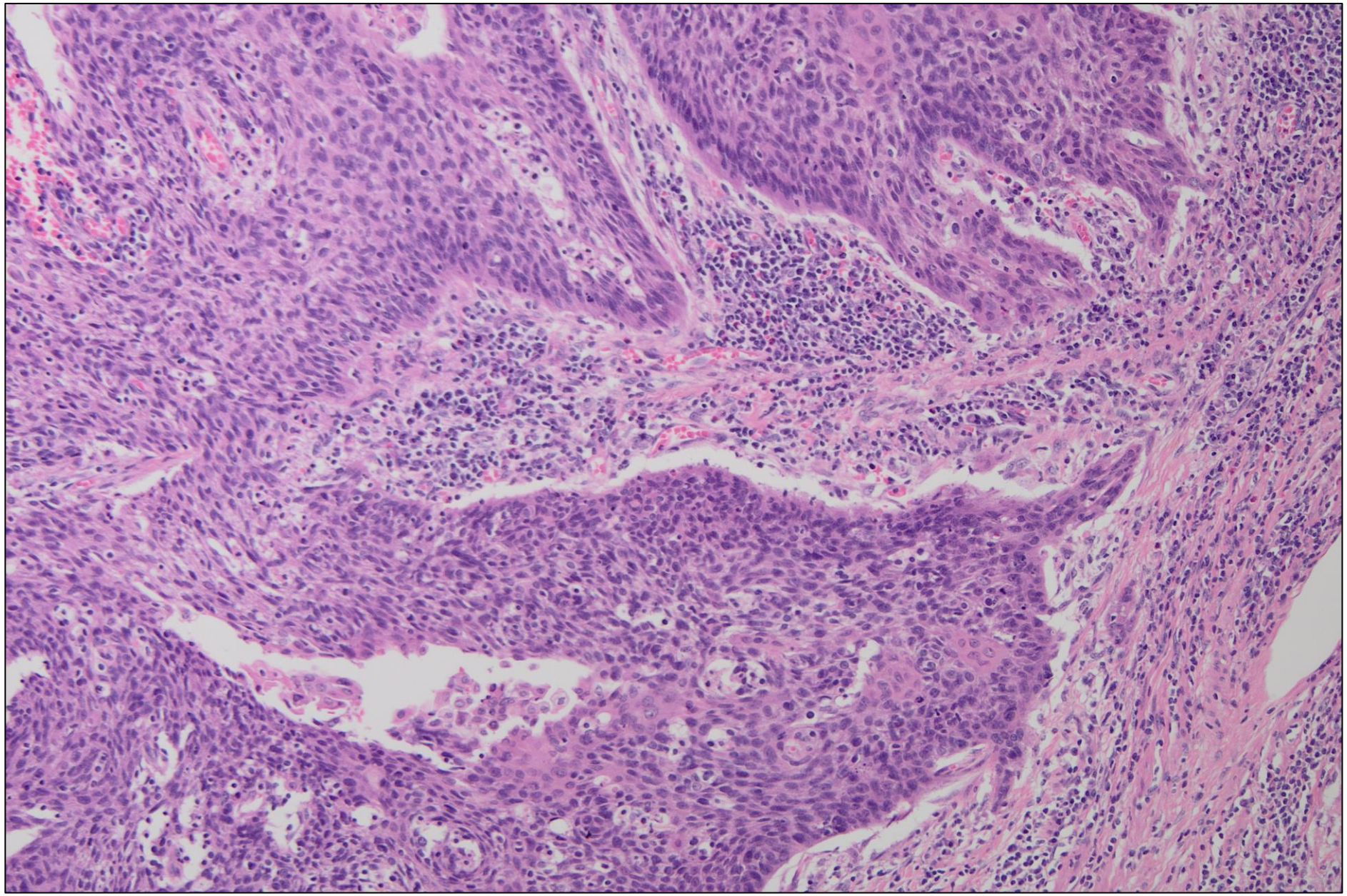

Irregular epithelial-stromal interface

Angulated and irregular tumour nests and buds

Loss of polarity

Loss of basal palisade

Paradoxical maturation

Desmoplastic response

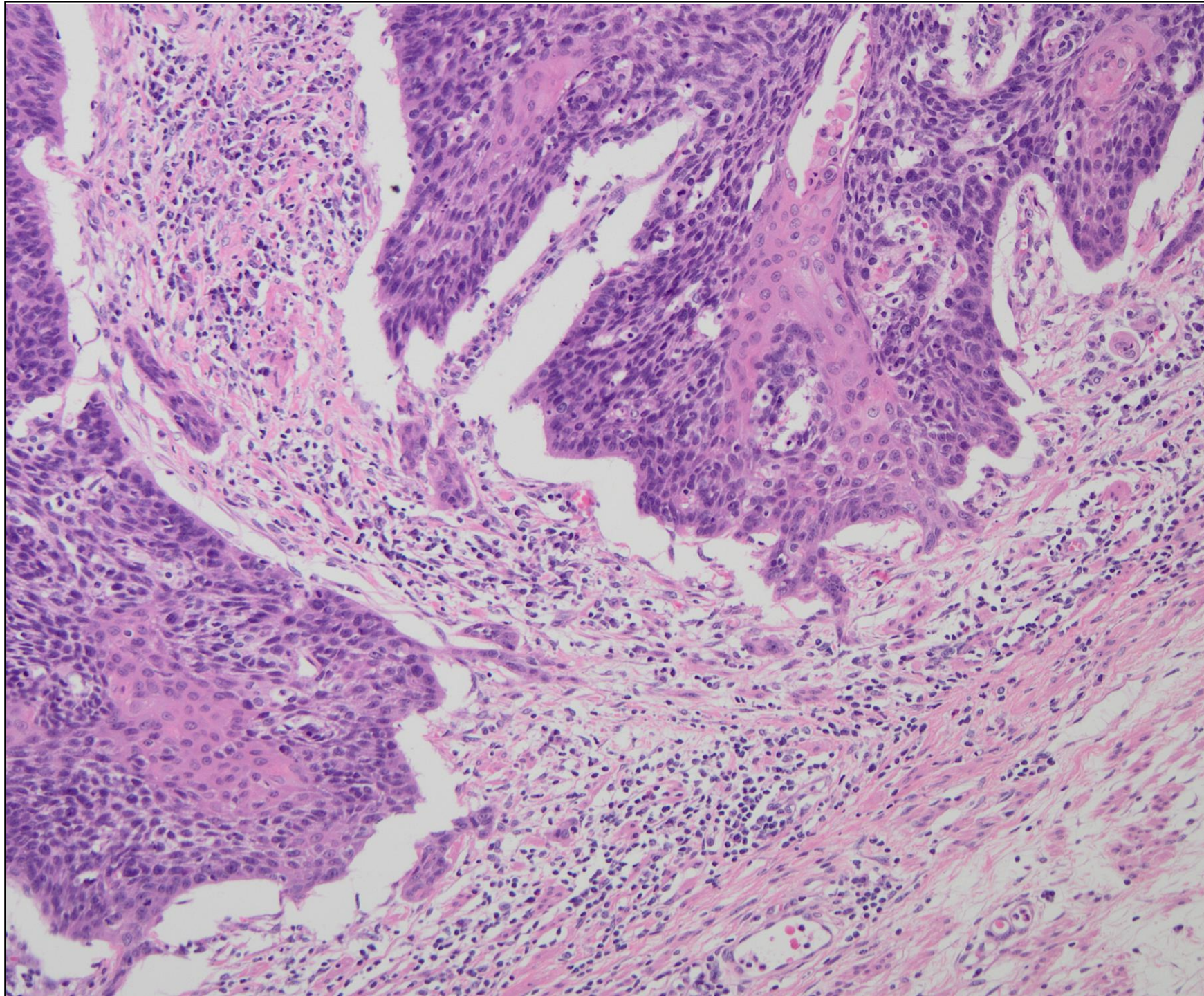

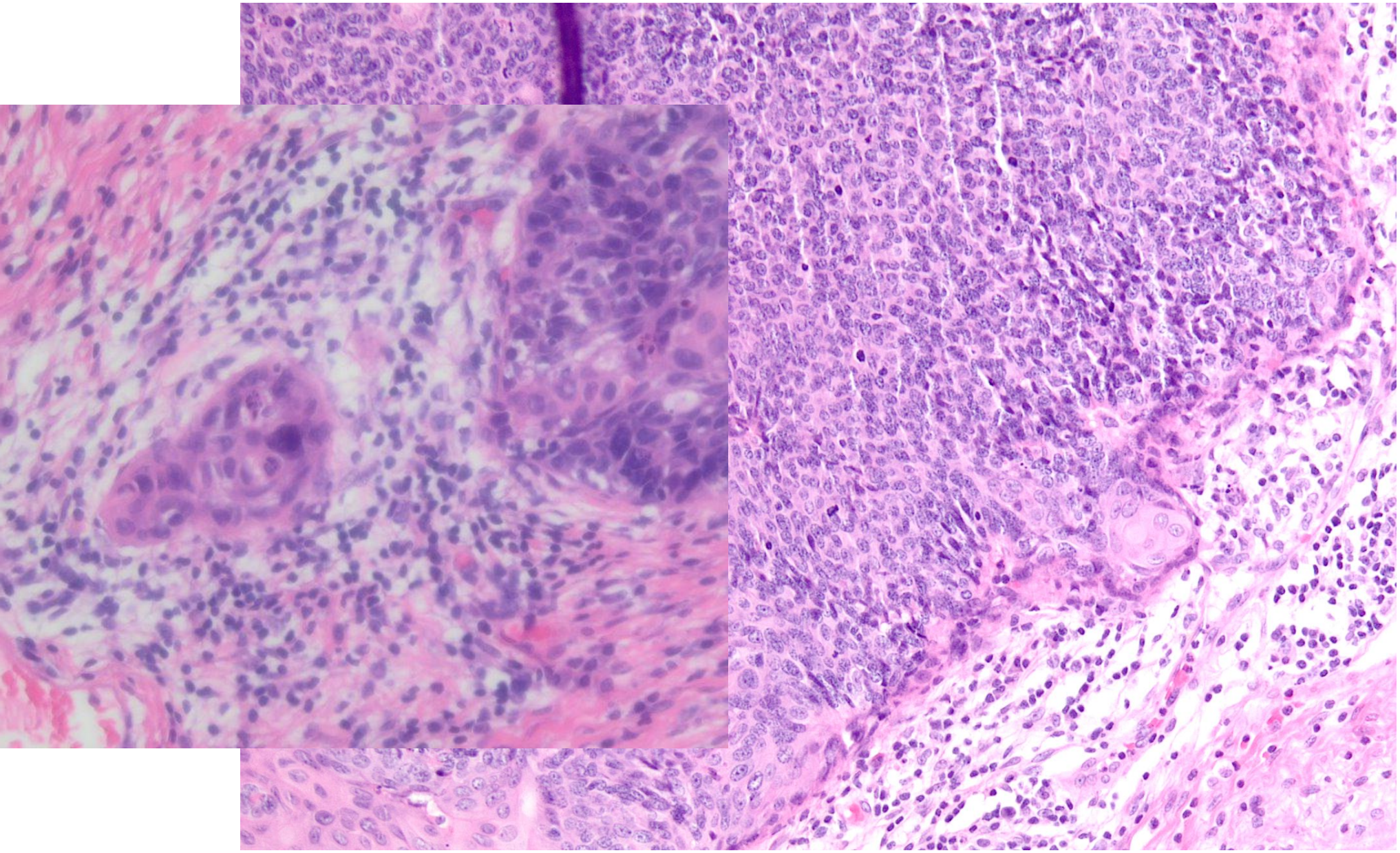

Is this invasion?

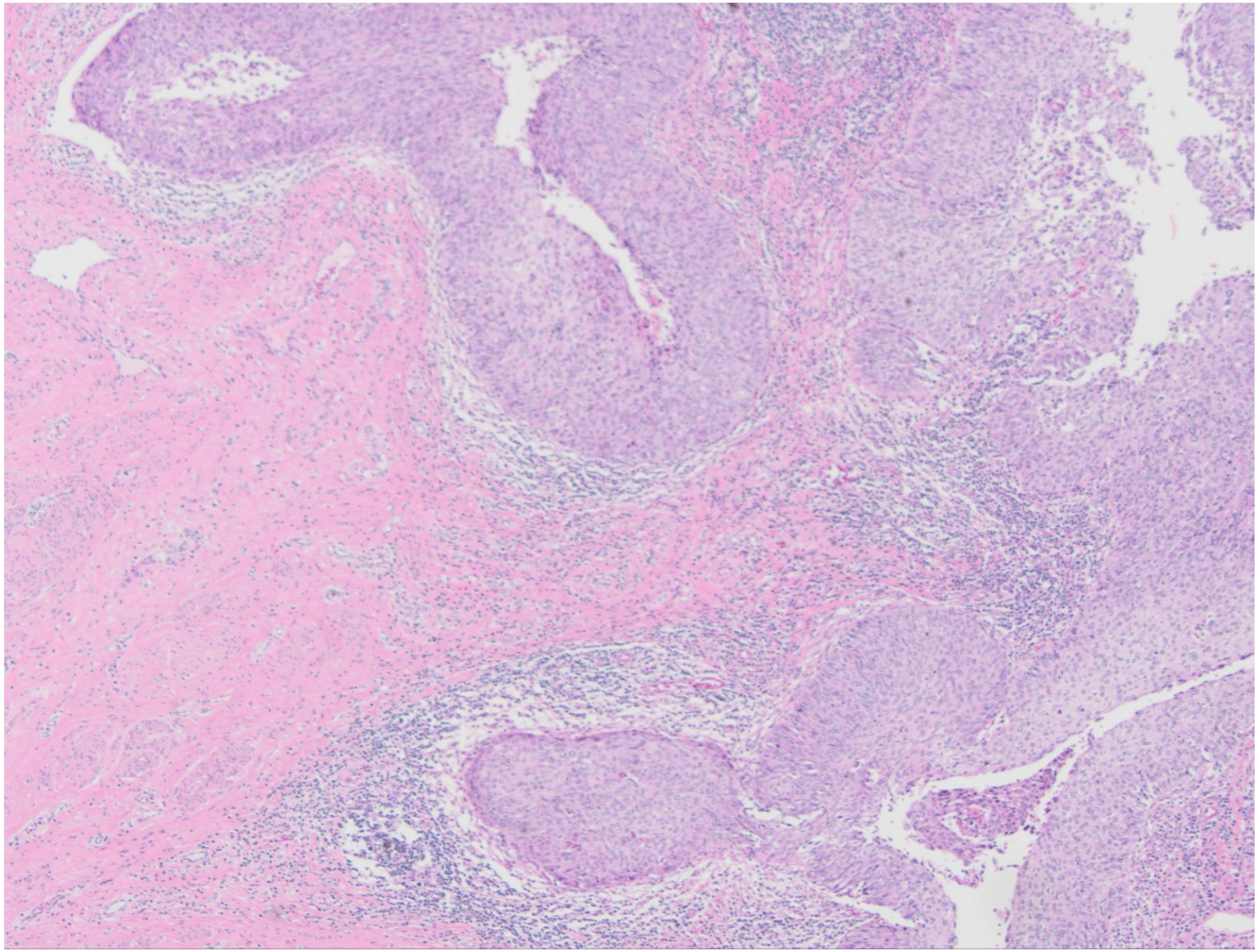

Is this invasion?

Mimics of invasion: Psuedoinvasion

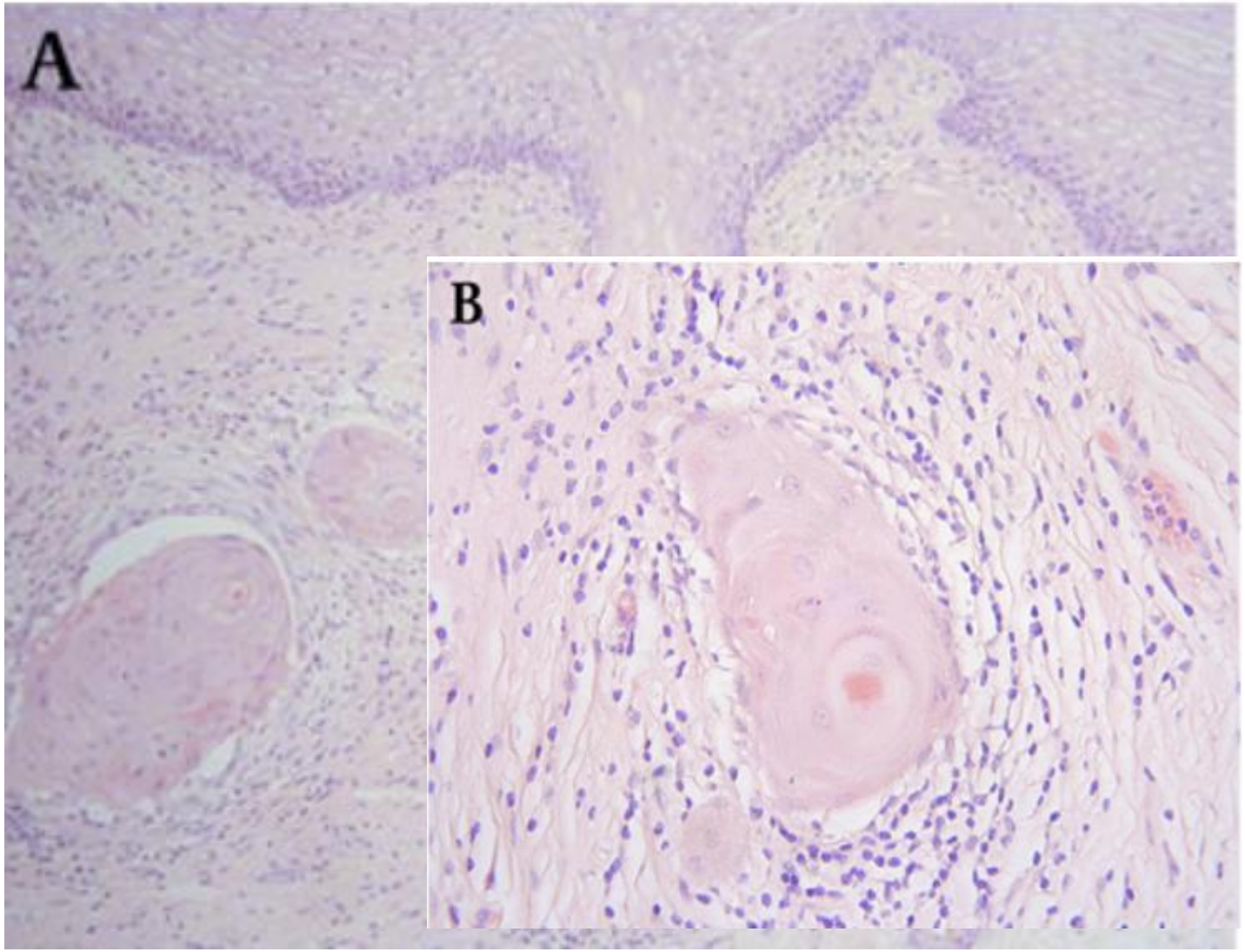

Pseudoinvasion of benign squamous epithelium following cervical biopsy: a pseudoneoplastic phenomenon mimicking invasive squamous carcinoma

David P Boyle, W Glenn McCluggage

Features:

- History of LLETZ / biopsy
- Hypereosinophilic appearance with abundant eosinophilic cytoplasm, no mitosis, no atypia
- Squamous epithelium immediately overlying the nests generally no evidence of CIN
- p16 non-block, Ki67 zero to low.

Mimics of invasion: Psuedoinvasion

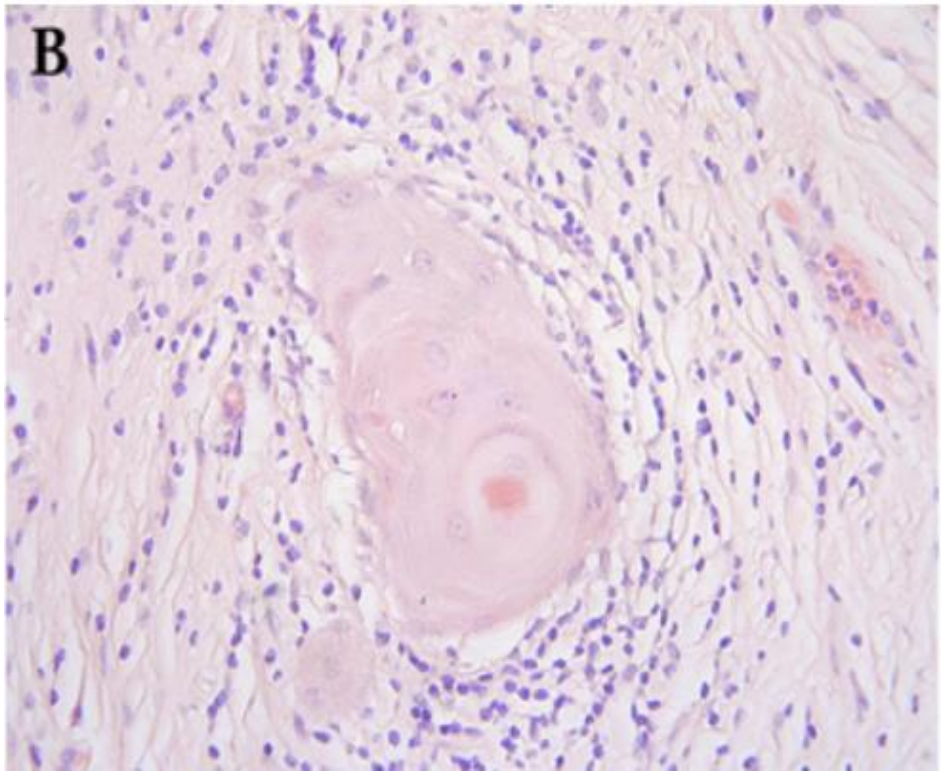

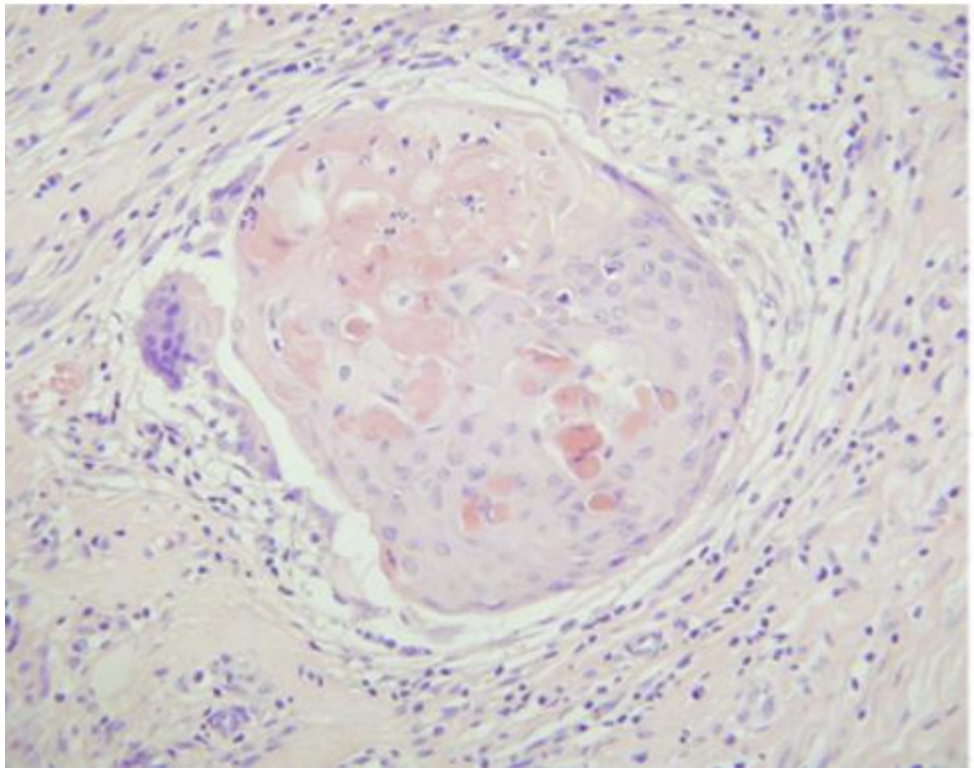

Fibrotic, inflamed and often oedematous stroma surrounded by inflammatory cells

Presence of inflammatory cells, including multinucleate giant cells,

Mimics of invasion: Pleomorphic high grade CIN

Pathology (August 2017) **49(5)**, pp. 465–470

ANATOMICAL PATHOLOGY

High-grade squamous intraepithelial lesion (HSIL) of the cervix with bizarre cytological appearances ('pleomorphic HSIL'): a review of 19 cases

COLIN J. R. STEWART[1,2]

[1]*Department of Pathology King Edward Memorial Hospital, and* [2]*School of Women's and Infants' Health, University of Western Australia, Perth, WA, Australia*

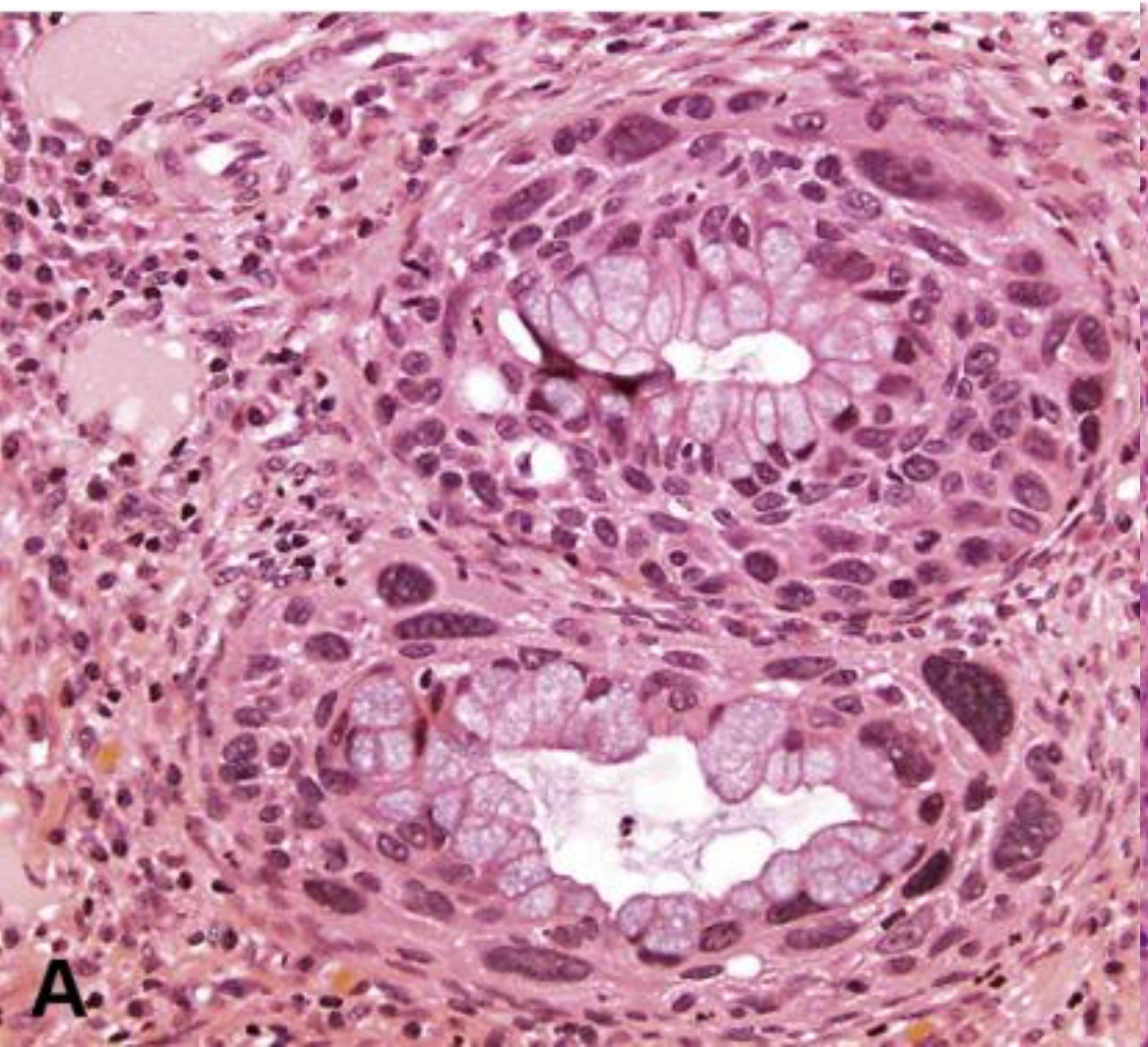

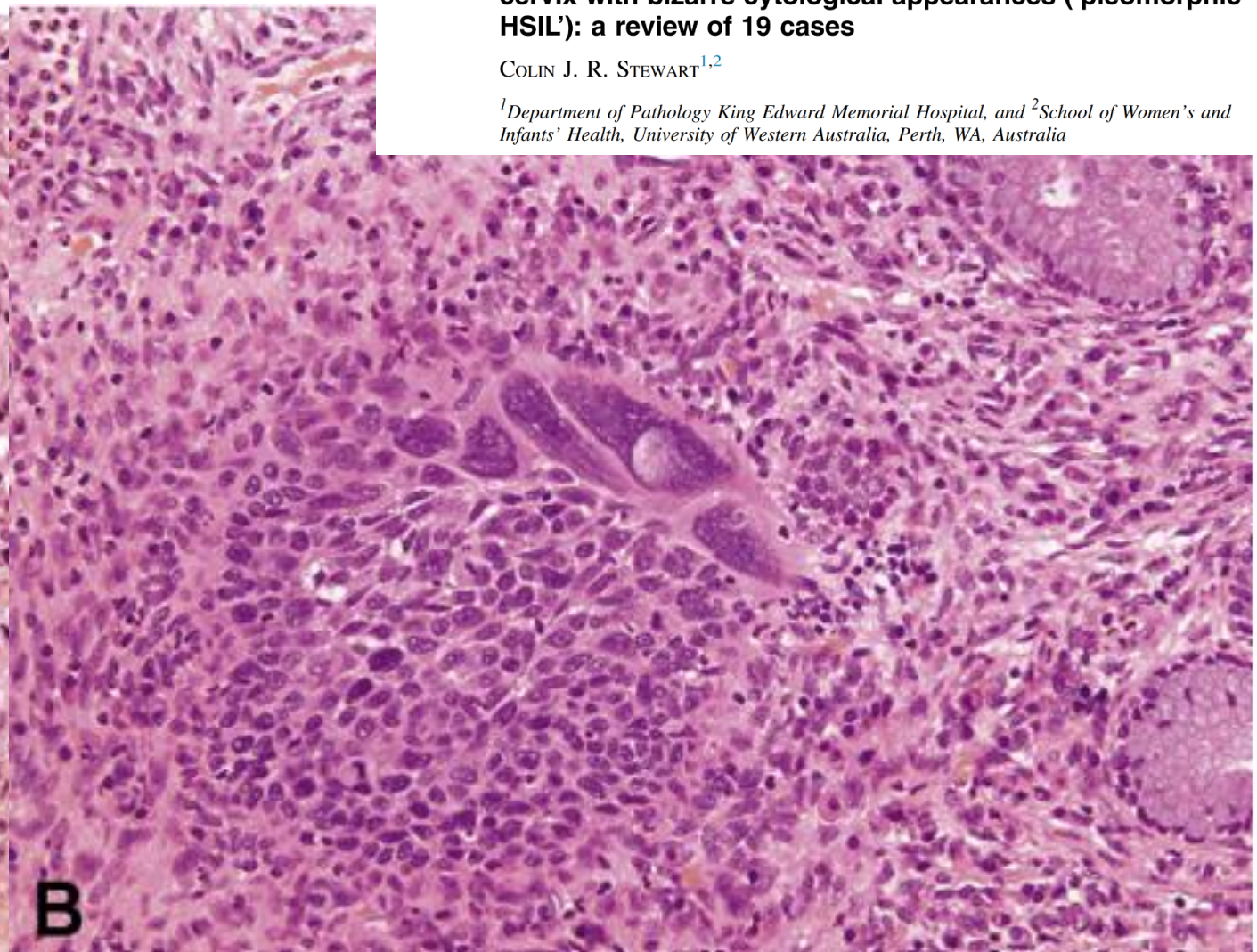

Mimics of invasion: Pleomorphic high grade CIN

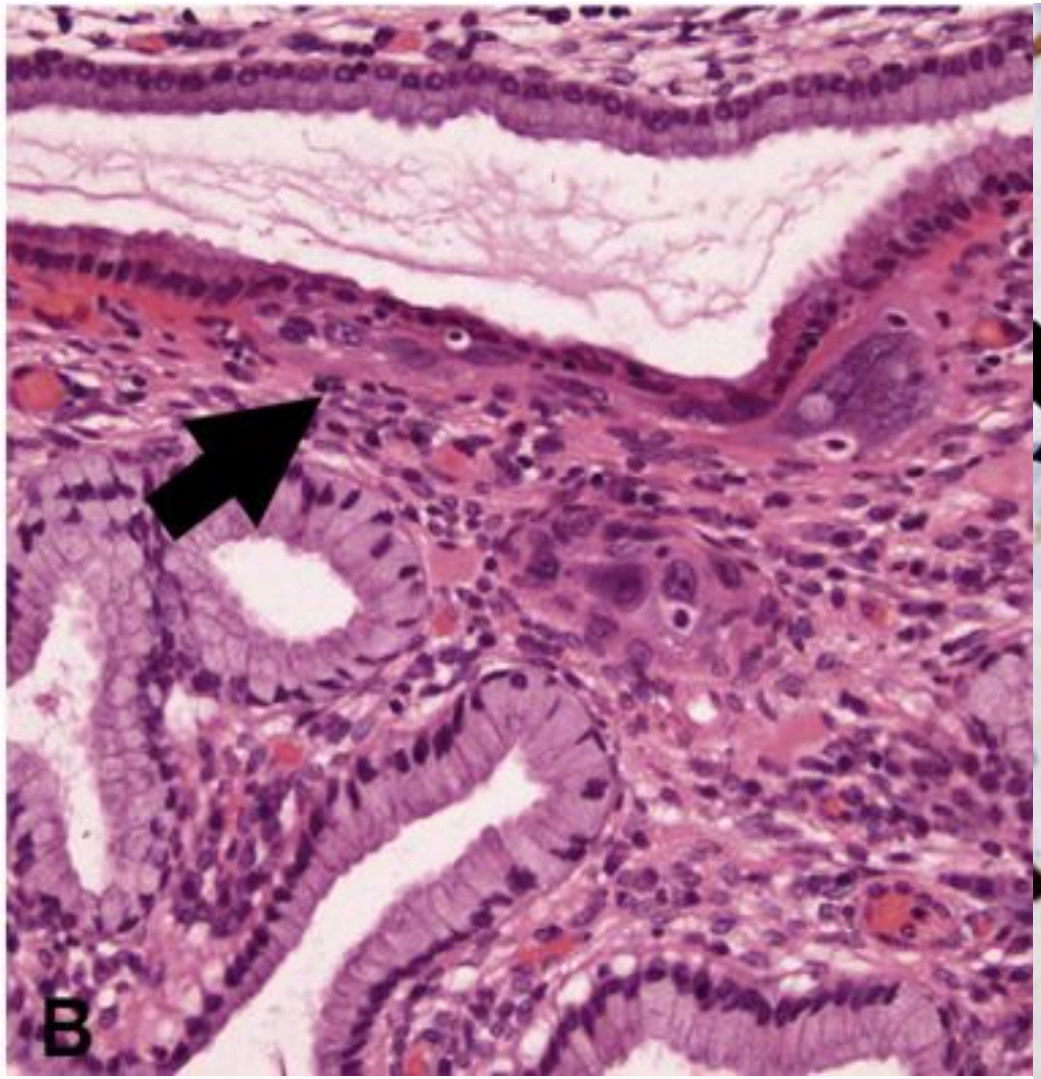

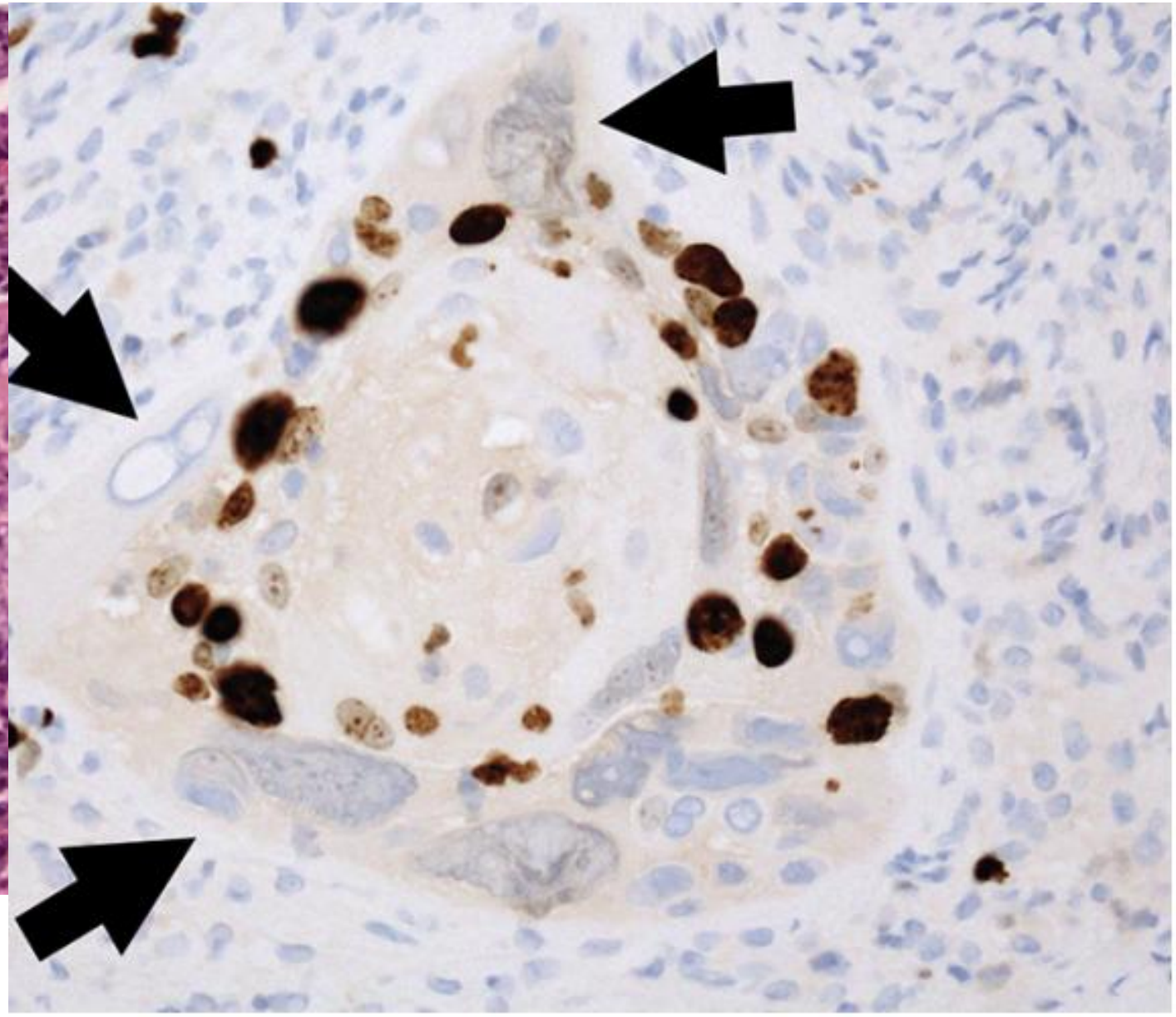

Mimics of invasion: CIN3 with intraepithelial maturation

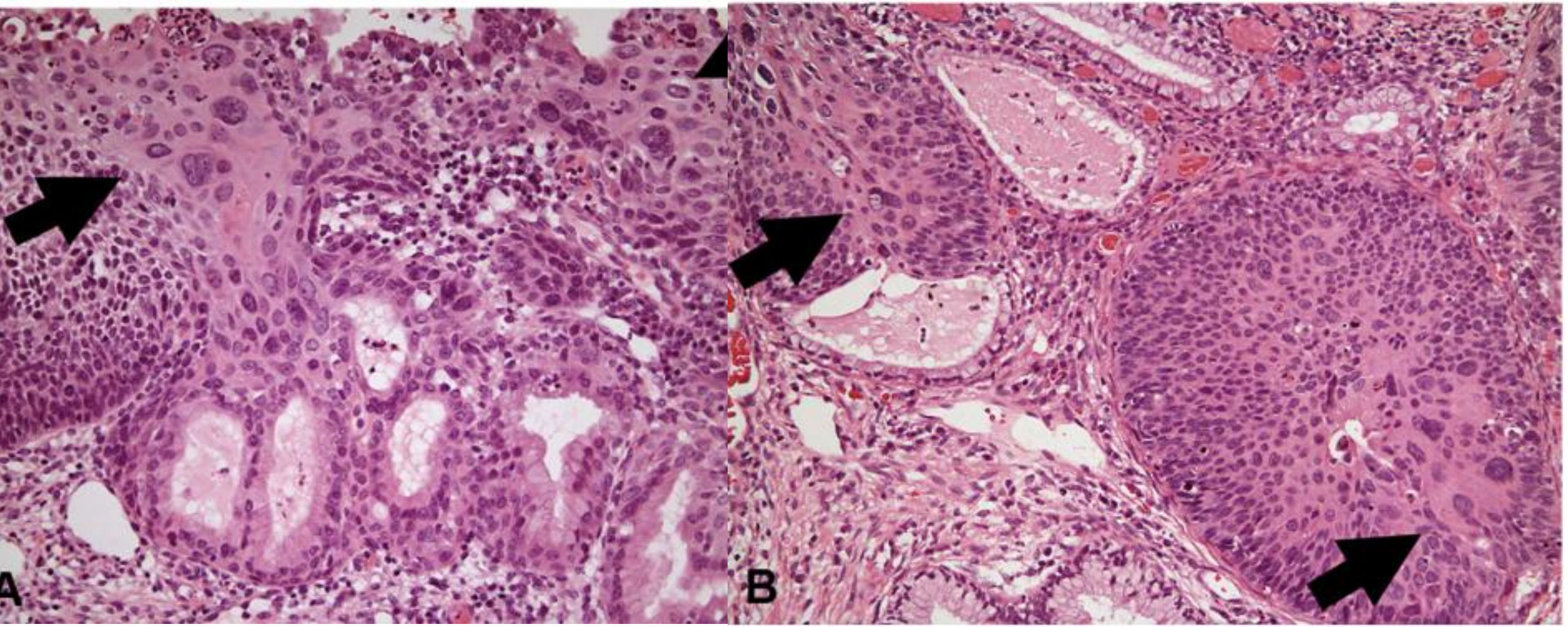

CIN3-like carcinoma

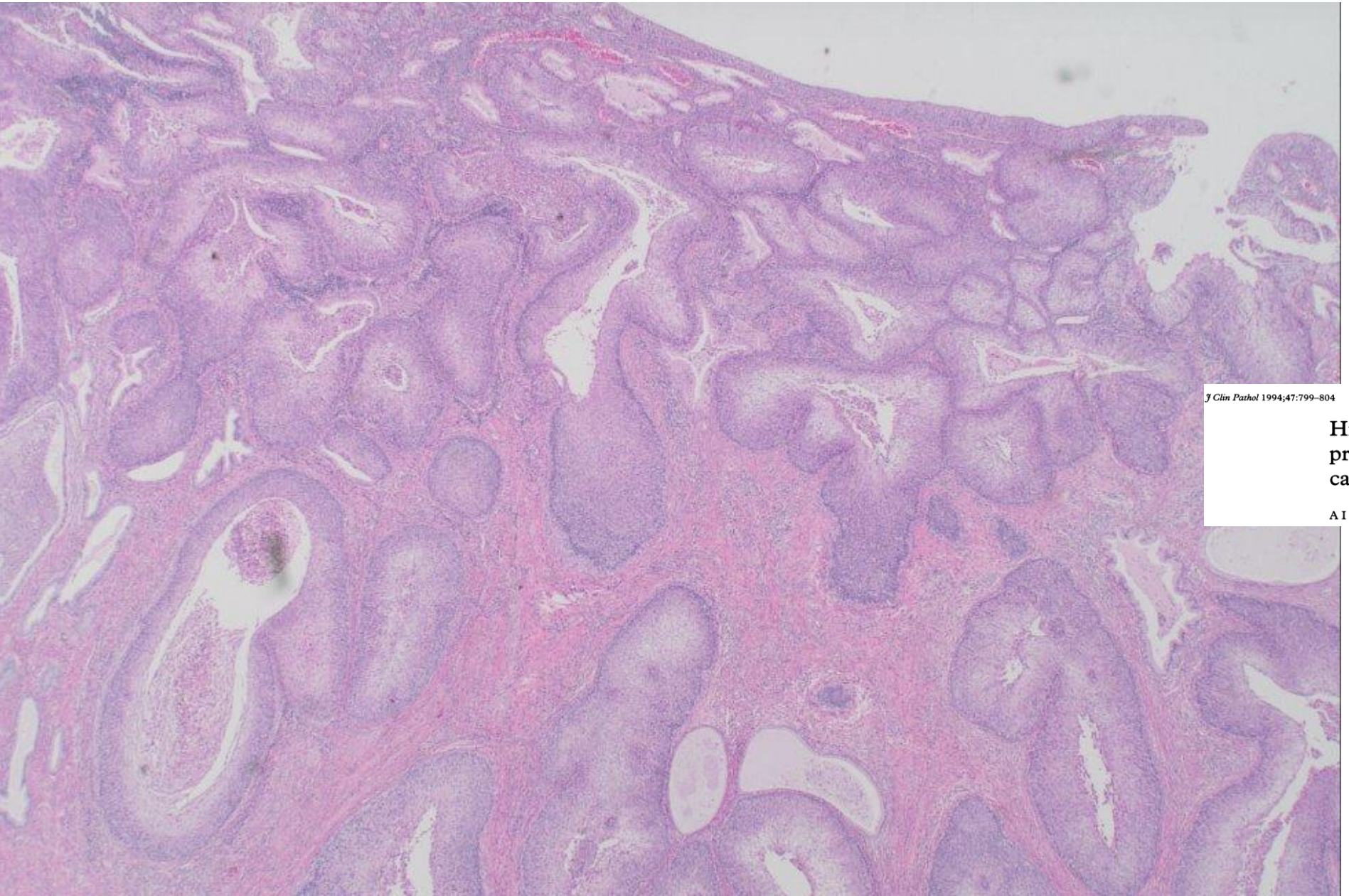

J Clin Pathol 1994;47:799–804

Histological features of CIN3 and their value in predicting invasive microinvasive squamous carcinoma

A I Al-Nafussi, D E Hughes

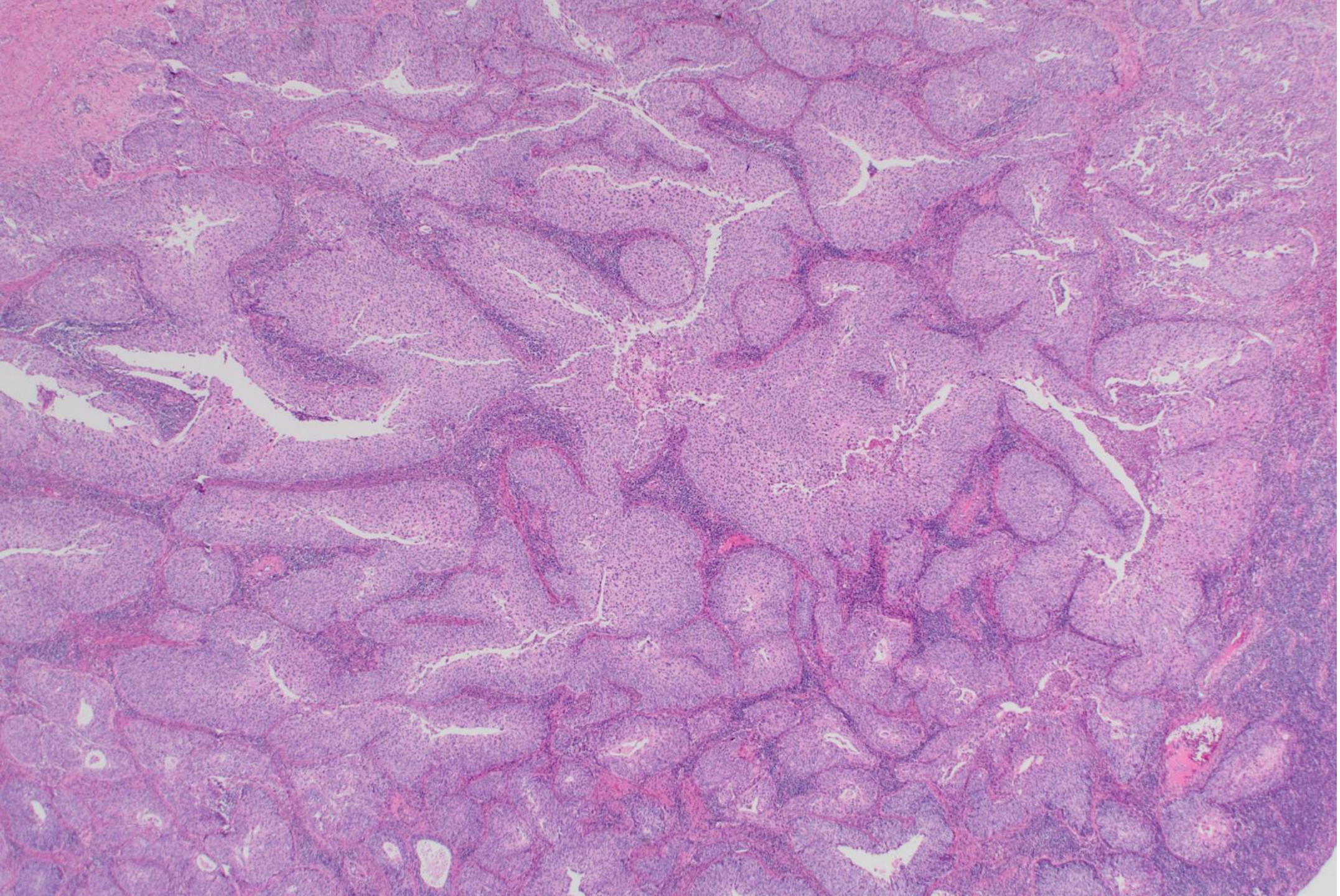

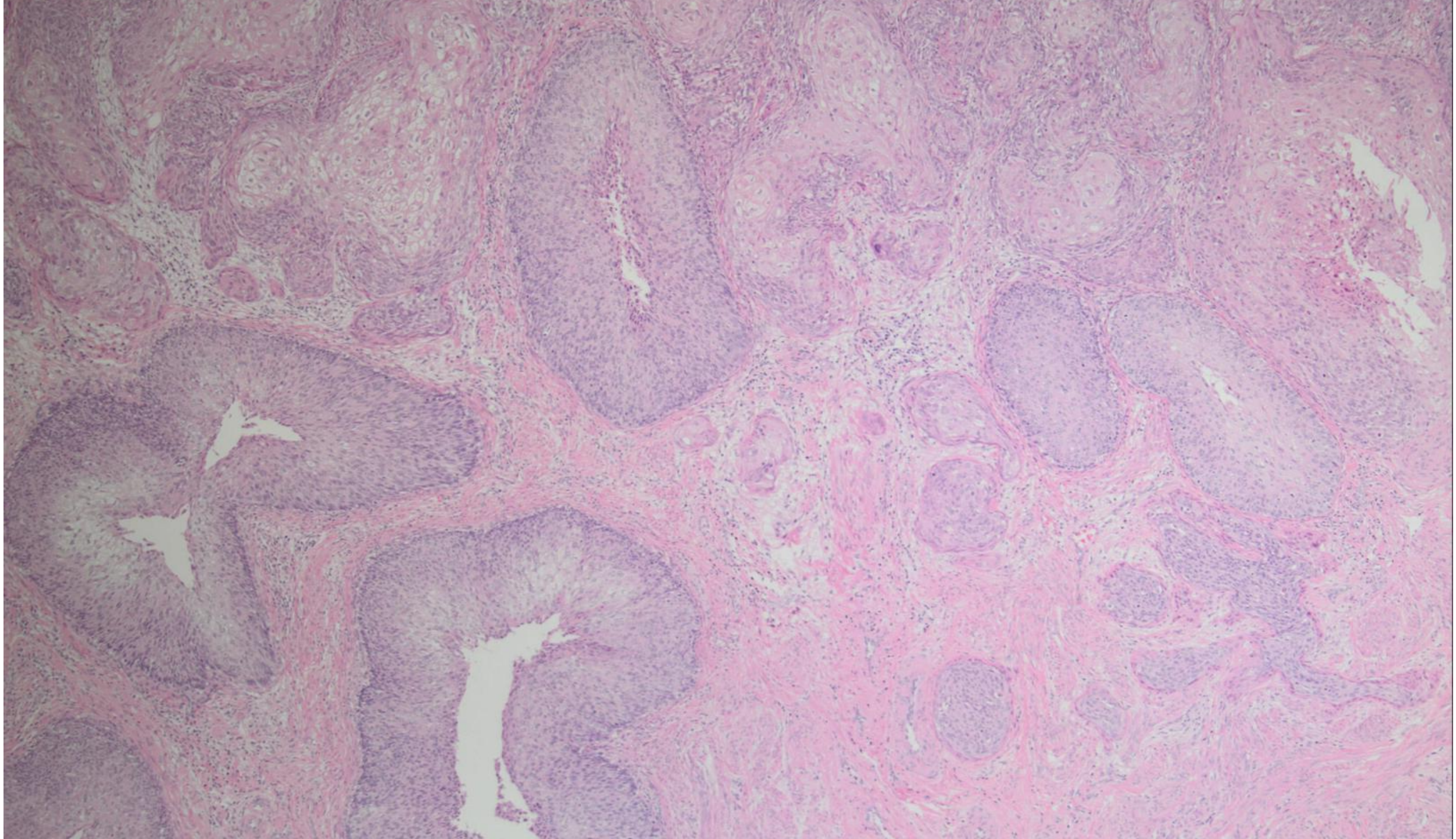

Histopathology 2017, **70**, 367–374. DOI: 10.1111/his.13094

Cervical intraepithelial neoplasia (CIN) 3-like squamous cell carcinoma of the cervix: a review of 14 cases with comparison of E-cadherin and cyclin D1 expression in the CIN 3-like and infiltrative tumour elements

Colin J R Stewart[1,2] & Maxine L Crook[1]

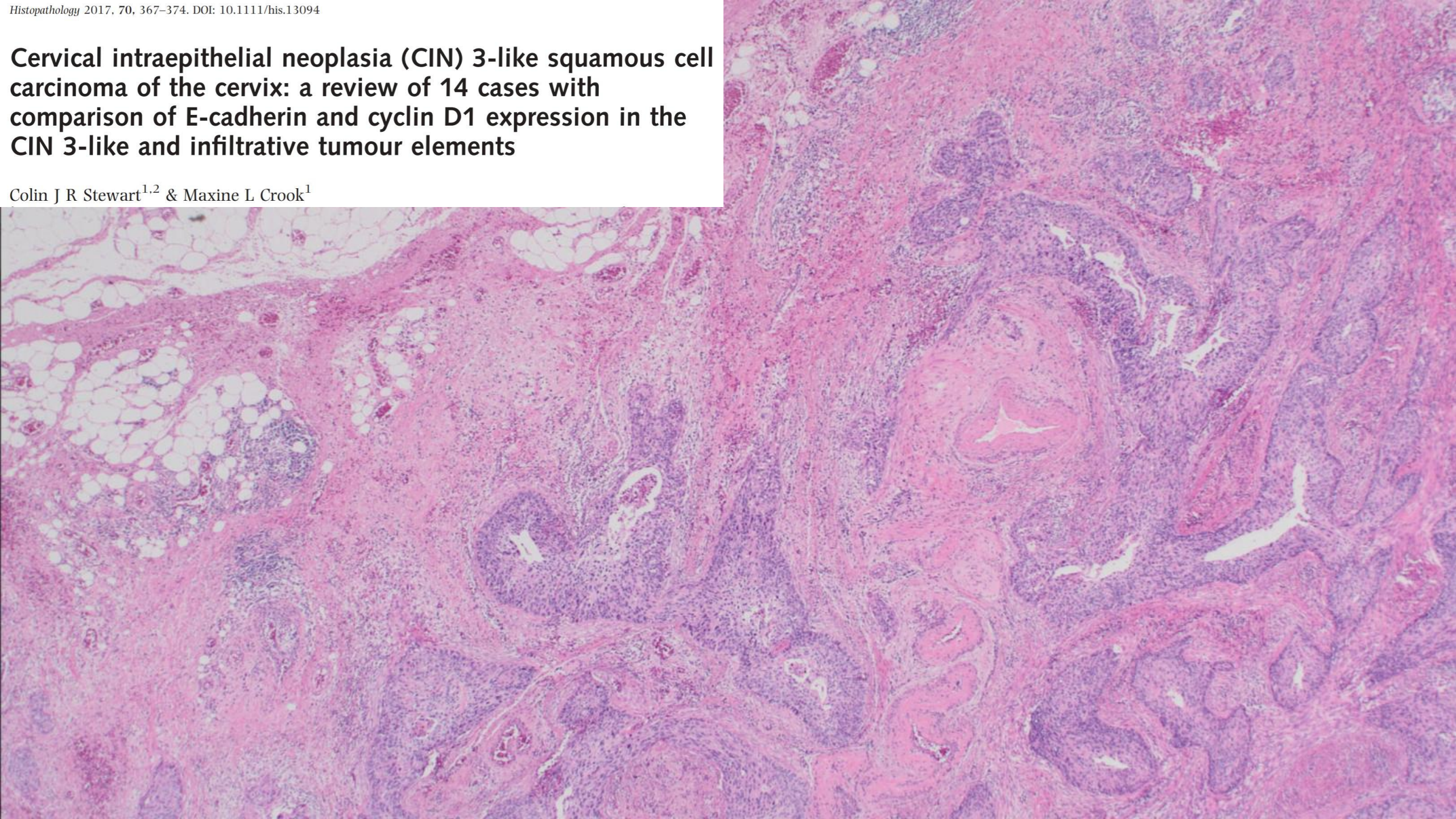

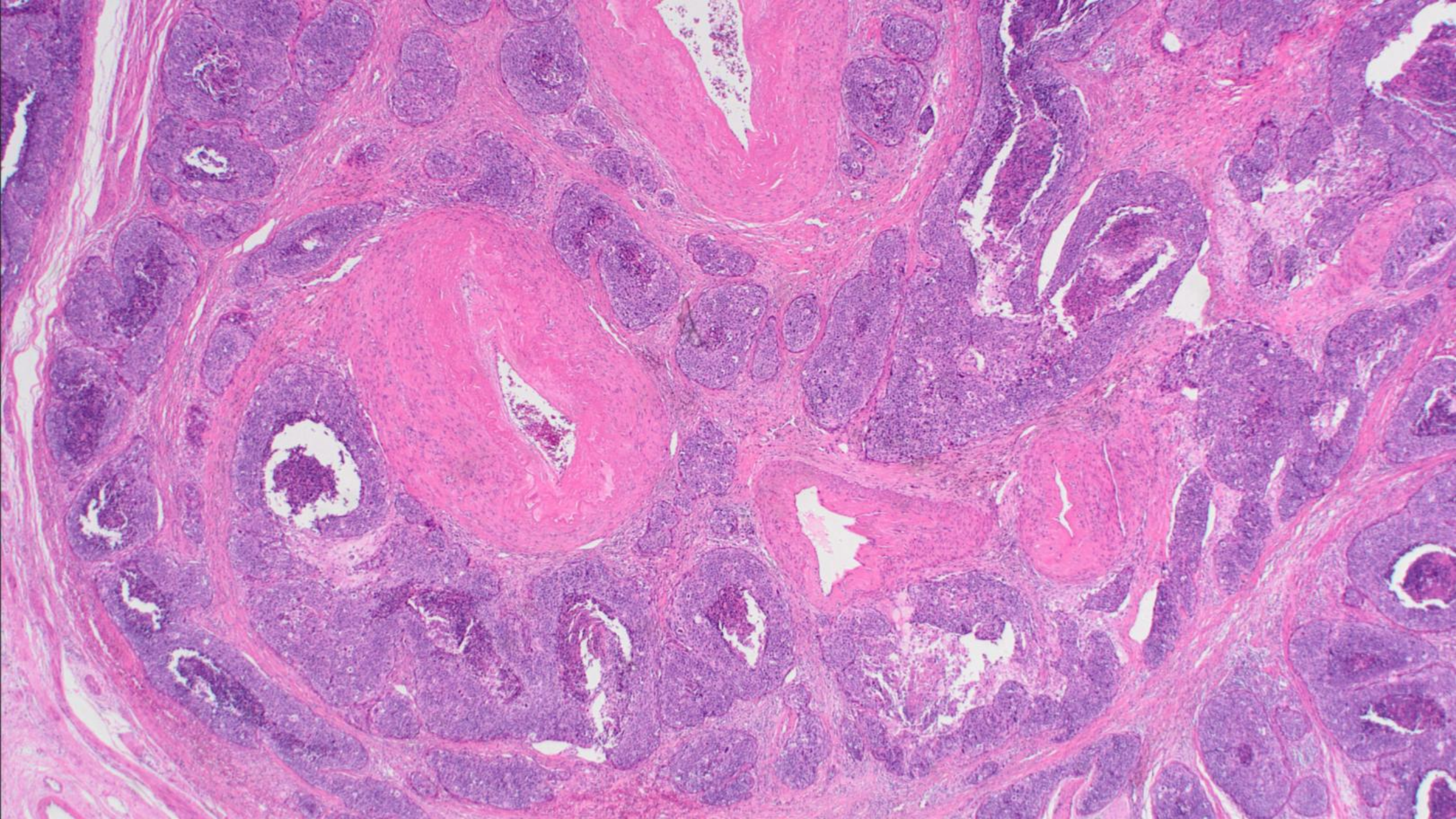

Unusual morphologies in HPVA SCC

- Warty
- Papillary
- Keratinising
- Lymphoepithelioma like
- Associated with numerous calcifications
- Micropapillary architecture
- Pseudoglandular pattern
- Adenoid cystic like morphology
- Cytoplasmic clearing
- Rarely, cytoplasmic mucin
- Sarcomatoid / spindle cells

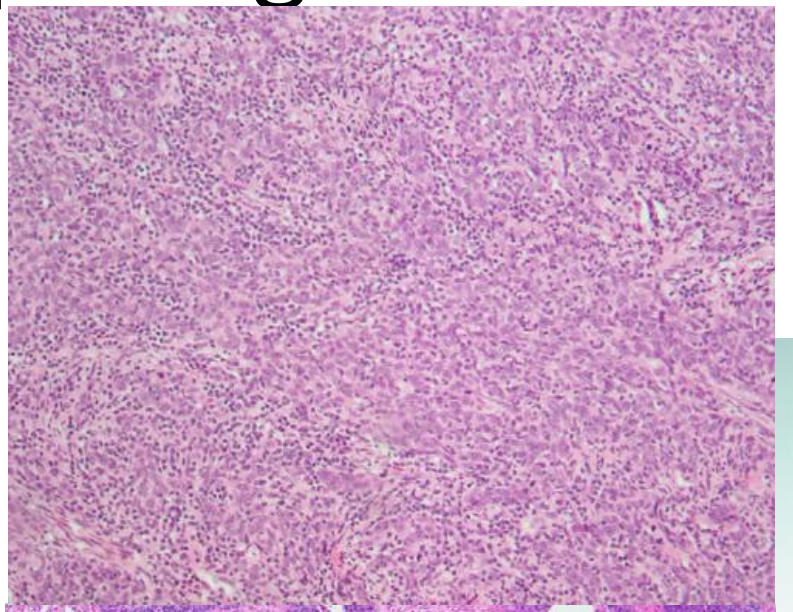

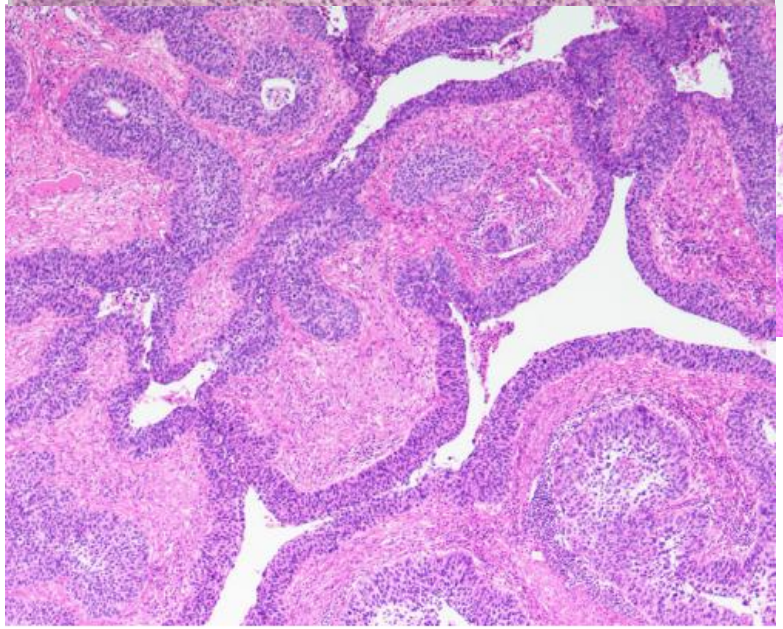

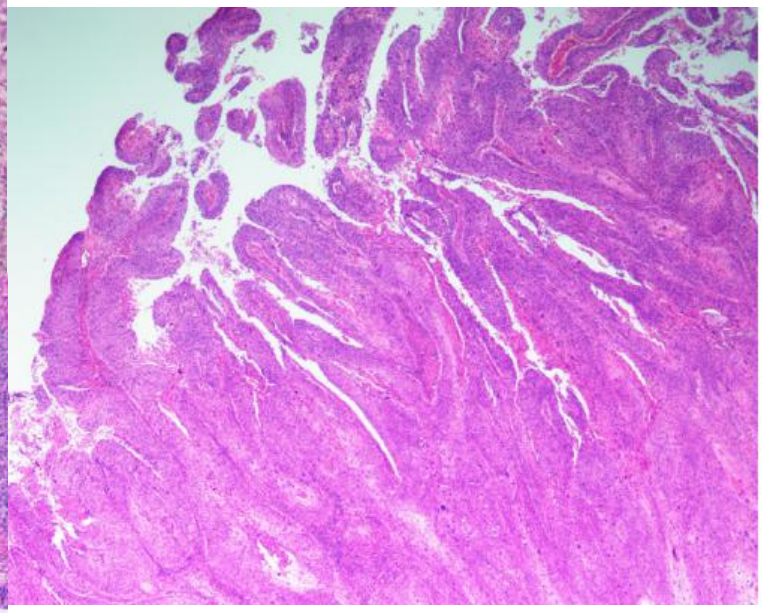

Low grade squamous lesions: SKLL

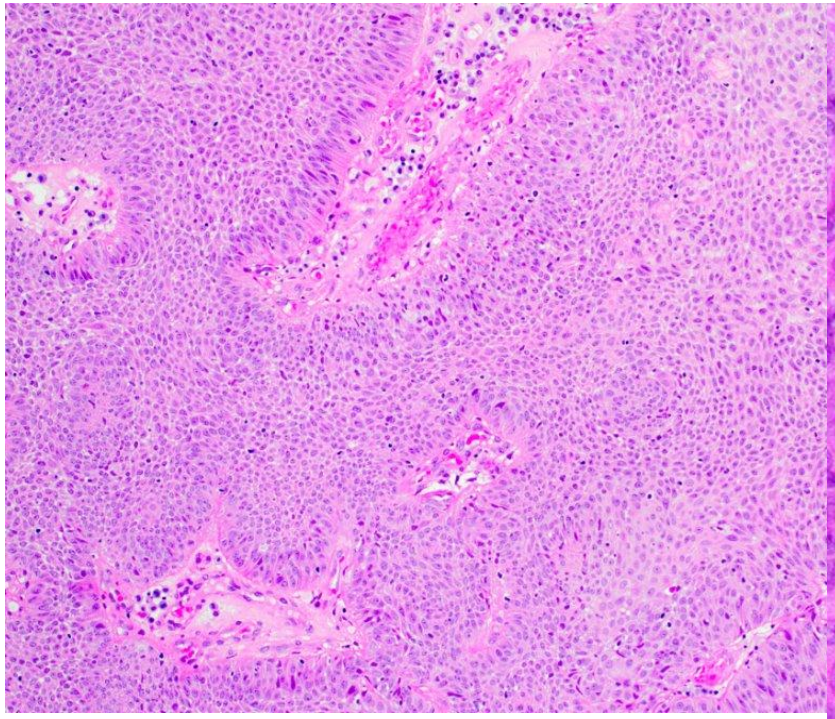

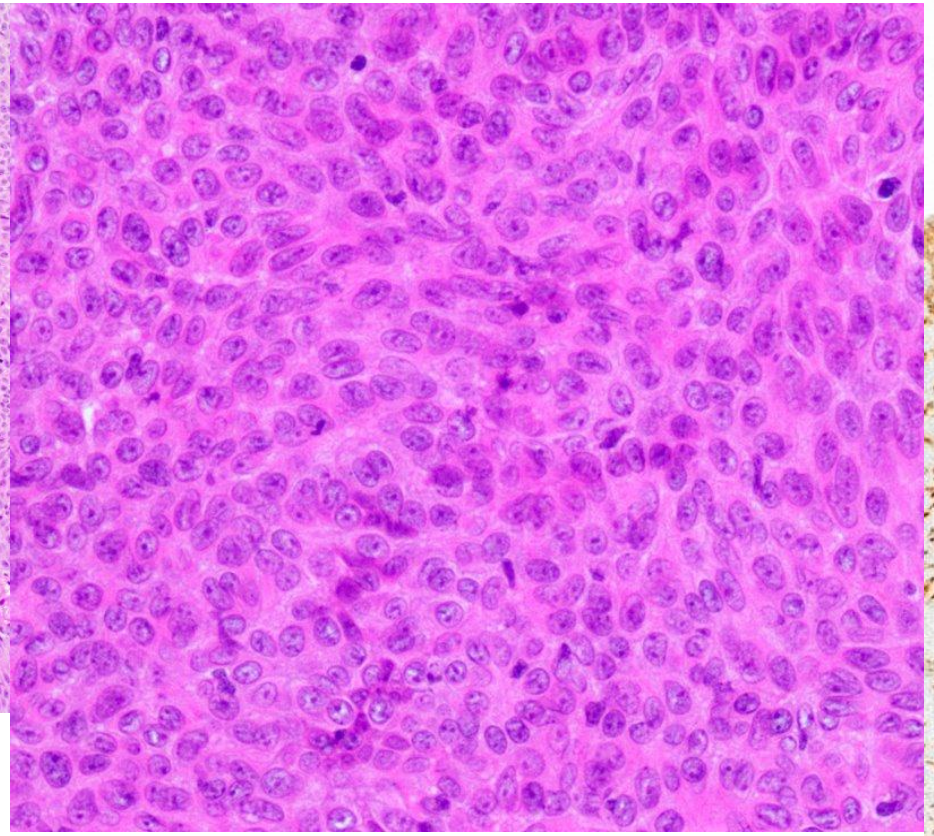

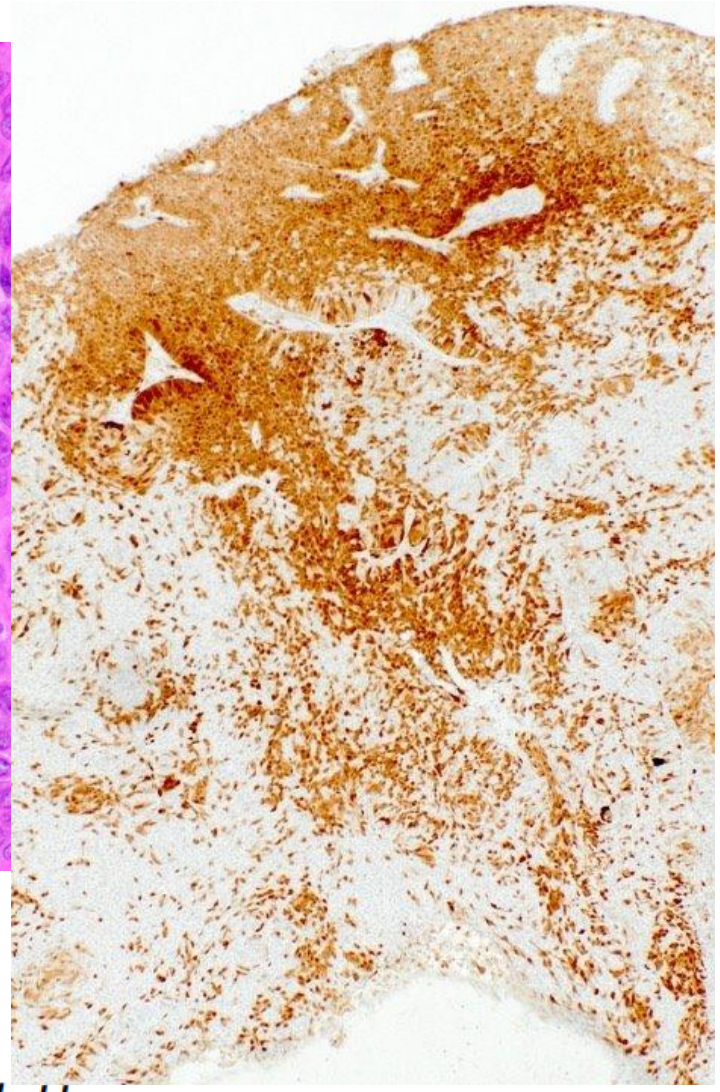

Seborrheic Keratosis-like Lesions of the Cervix

Report of a New Entity Possibly Related to Low-risk Human Papillomavirus Infection

Karen L. Talia, FRCPA, MBBS and W. Glenn McCluggage, FRCPath†*

Low grade squamous lesions: SKLL

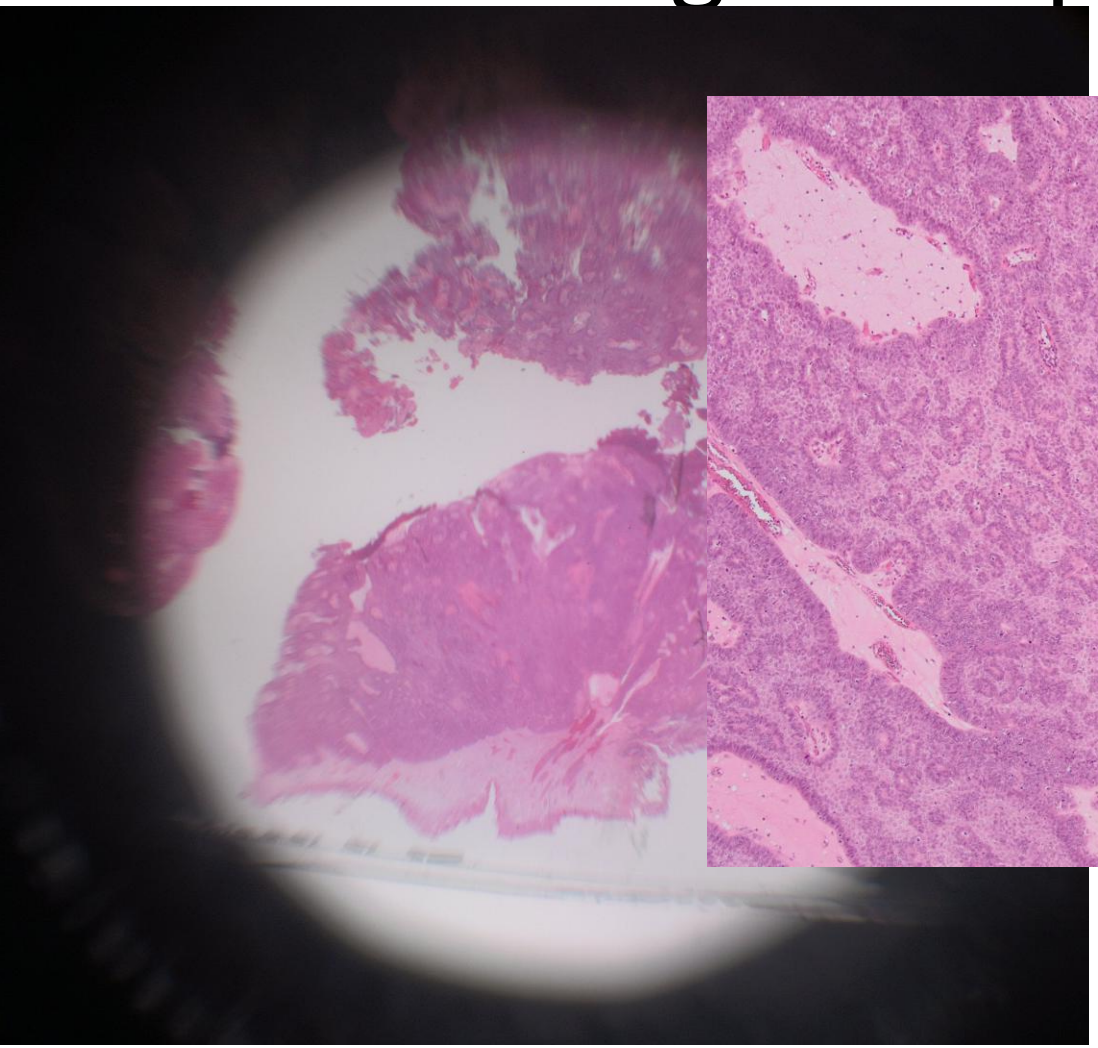

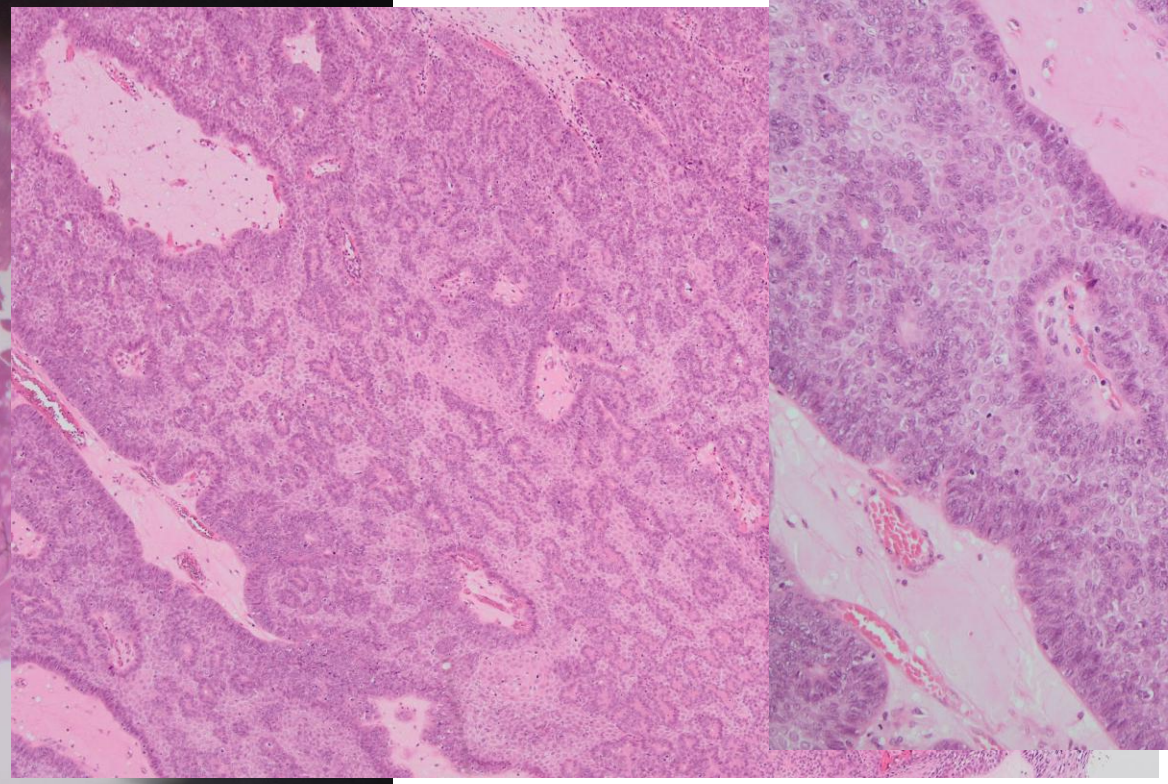

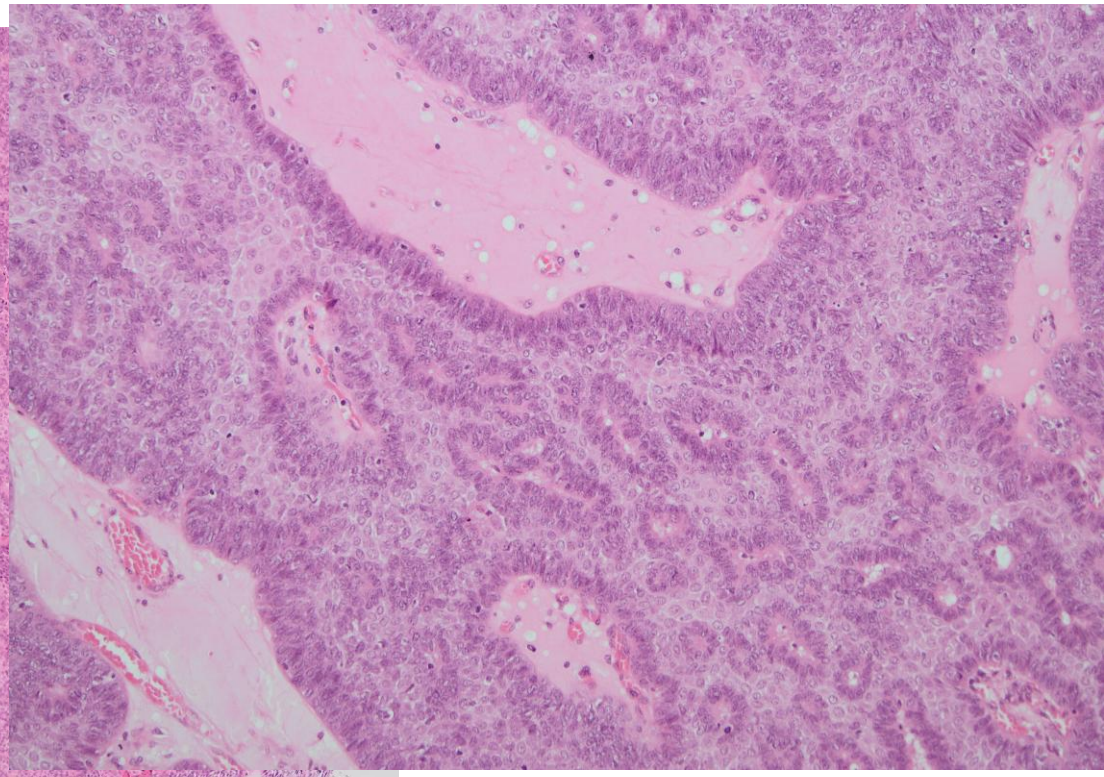

HPV 11

SKLL with high grade morphology

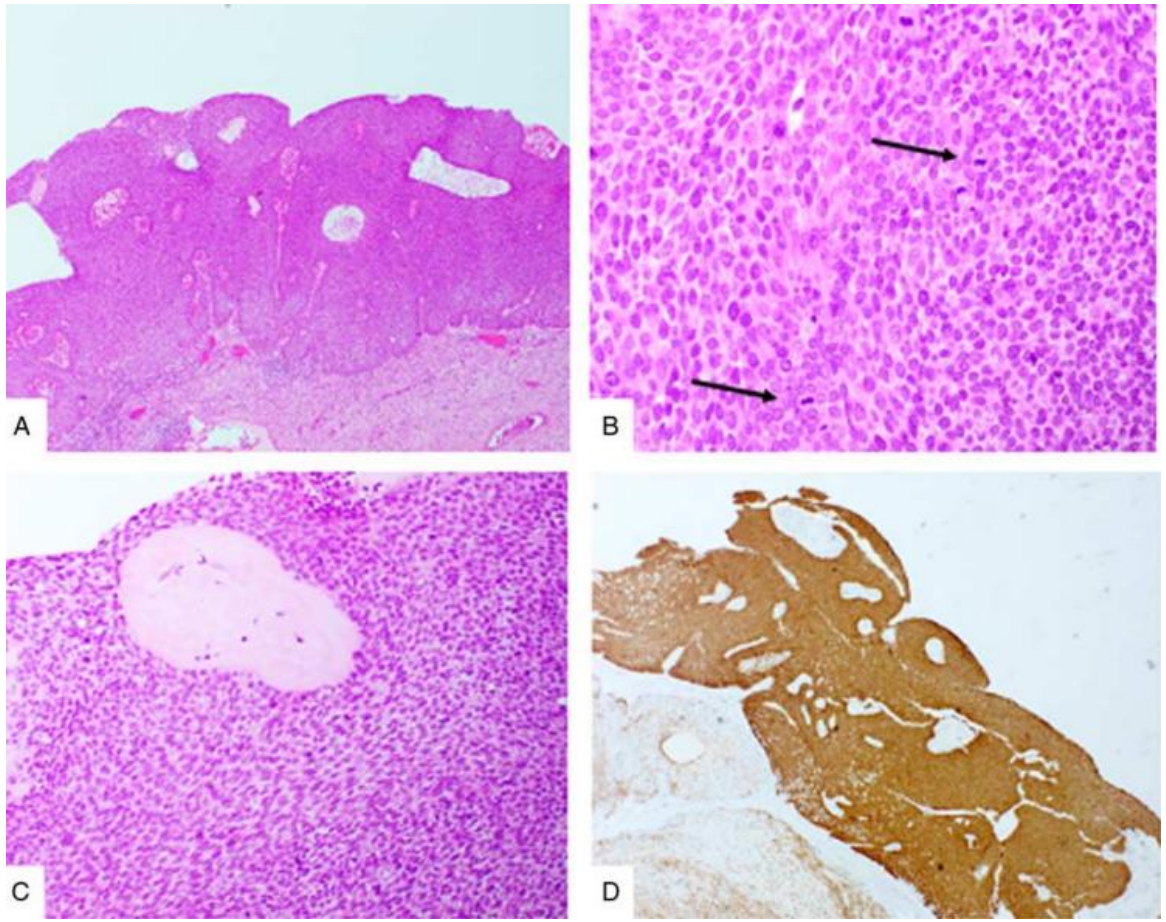

HPV42-associated Seborrhoeic Keratosis-like Lesion of the Cervix: First Reported Case With High-grade Morphology

Karen L. Talia, F.R.C.P.A., Siavash Rahimi, F.R.C.Path., David Hawkes, Ph.D., and W. Glenn McCluggage, F.R.C.Path.

Low grade squamous lesions:
Papillary immature metaplasia of the uterine cervix

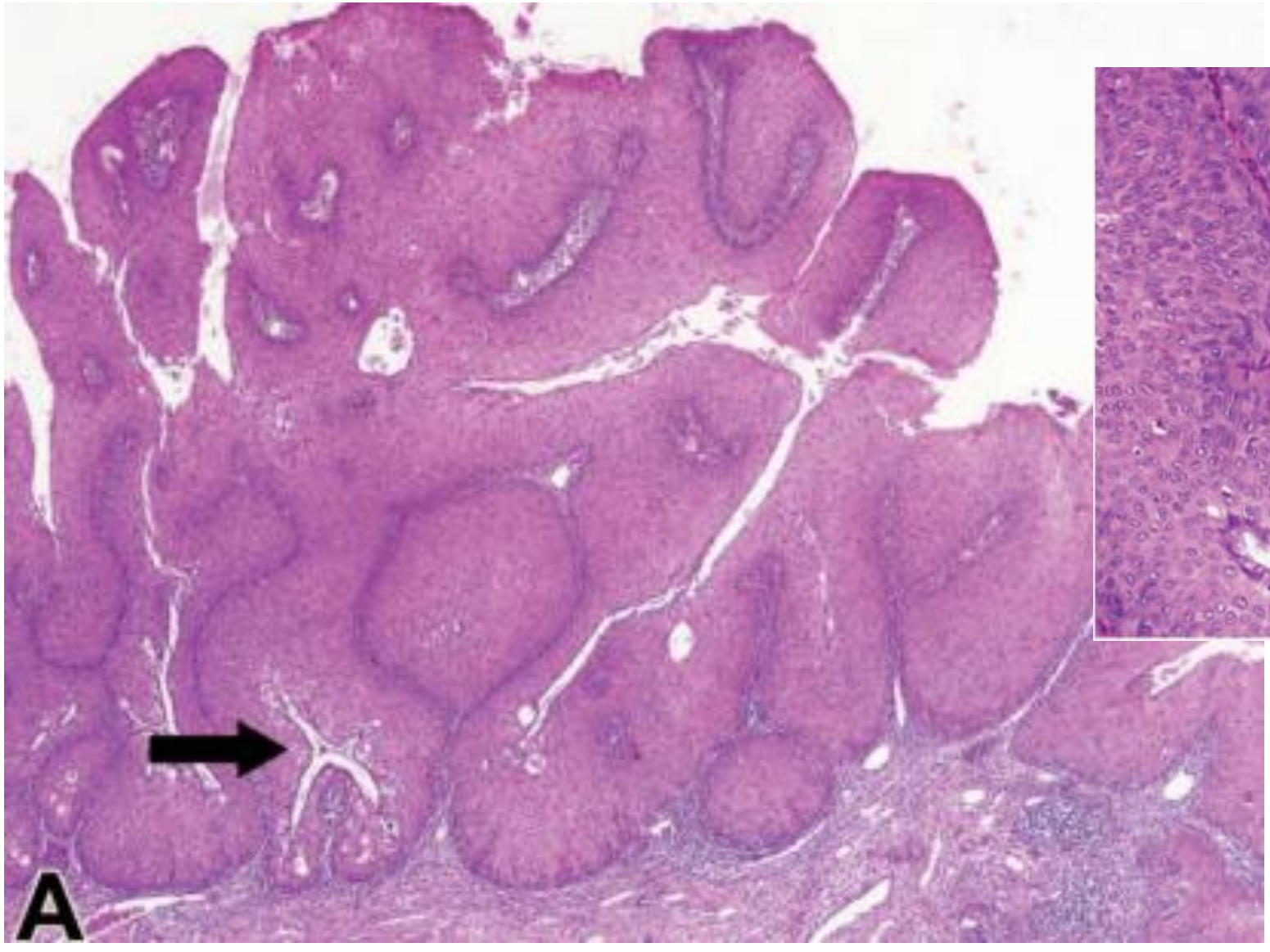

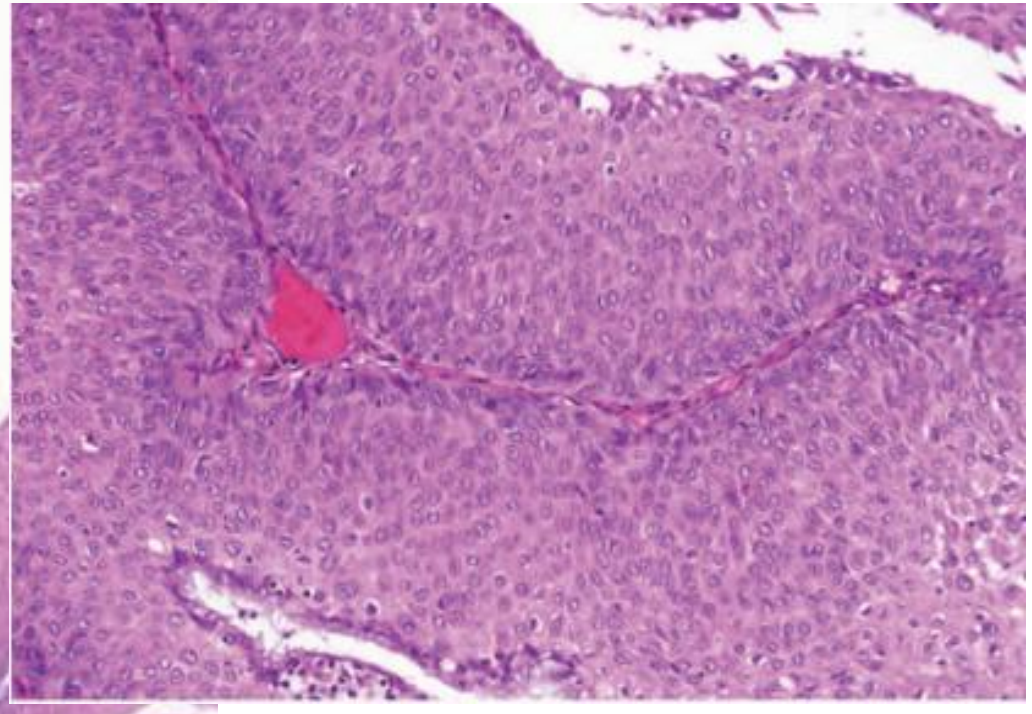

A Review and Update on Papillary Immature Metaplasia of the Uterine Cervix

A Distinct Subset of Low-Grade Squamous Intraepithelial Lesion, Proposing a Possible Cell of Origin

Low risk HPVA SCC of cervix

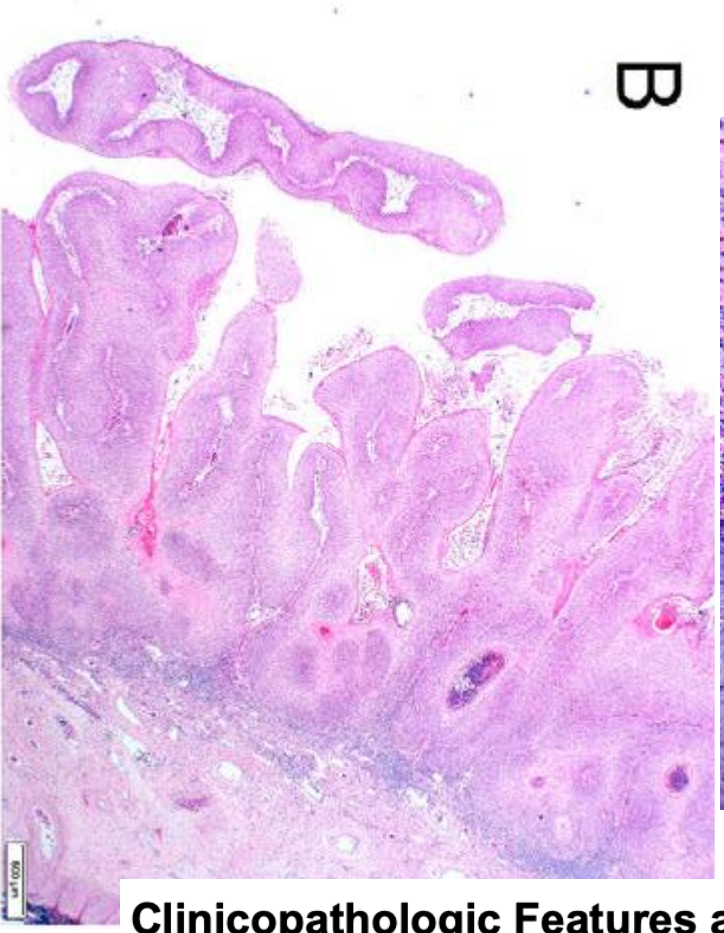

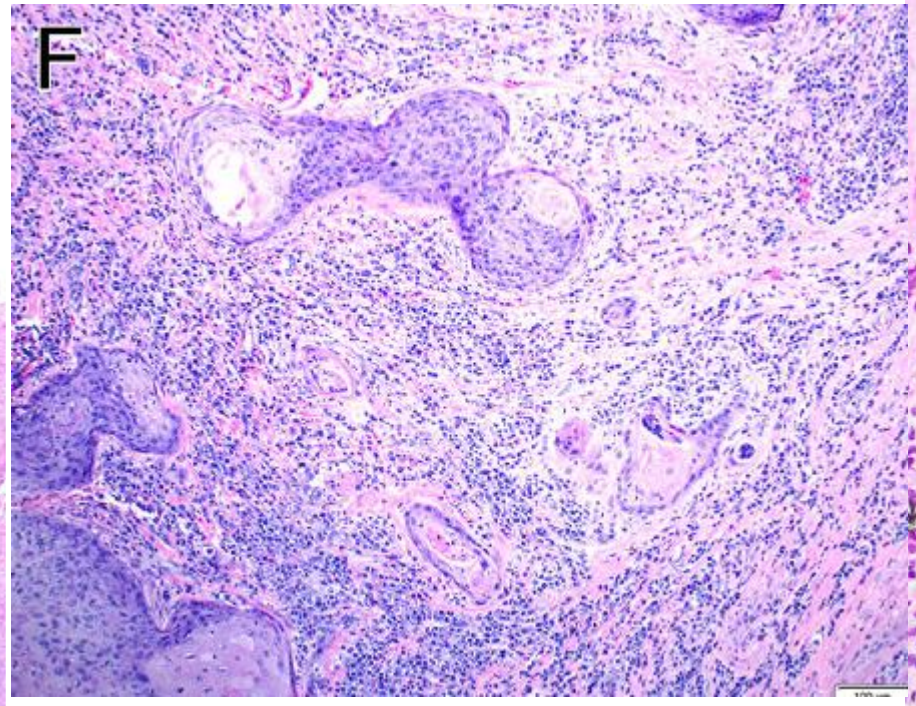

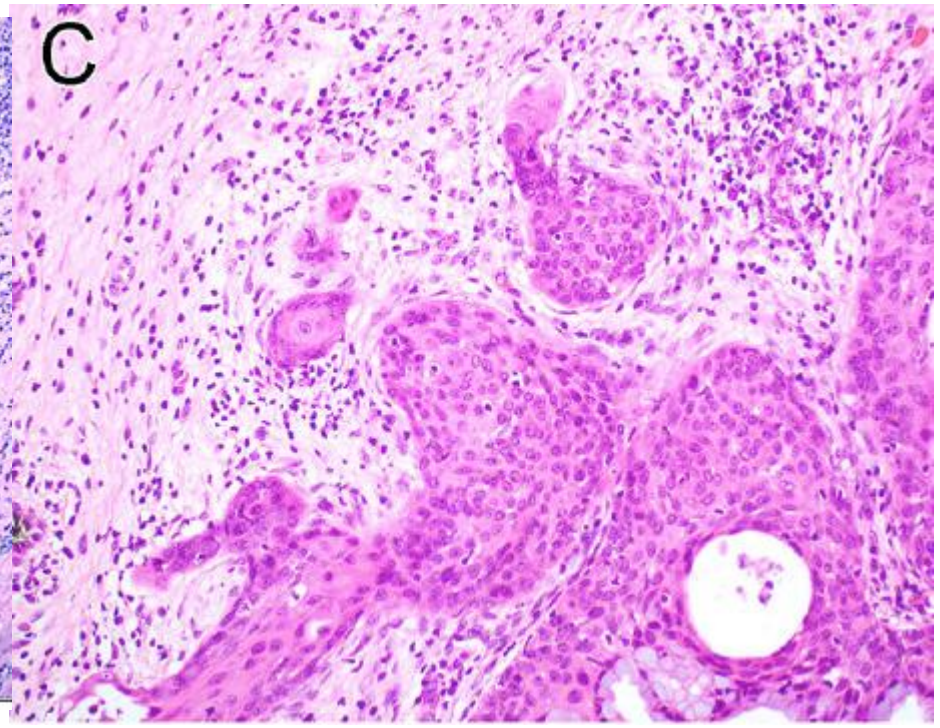

Clinicopathologic Features and Viral Status of Low-risk HPV6 and HPV11-Associated Squamous Cell Carcinoma of the Uterine Cervix and Vulva

Guy A. Williams II, MD[*], Annie A. Wu, MD, PhD[*], Henrietta C. Eugene, MS[*], Ya-Chea Tsai, MS[*], Margaret Wong, MS[*], Hiro Nonogaki, MS[*], Richard B.S. Roden, PhD[*,†,‡], Chien-Fu Hung, PhD[*,†], Tzyy-Choou Wu, MD, PhD[*,†,‡], Russell Vang, MD[*,‡], Deyin Xing, MD PhD[*,†,‡]

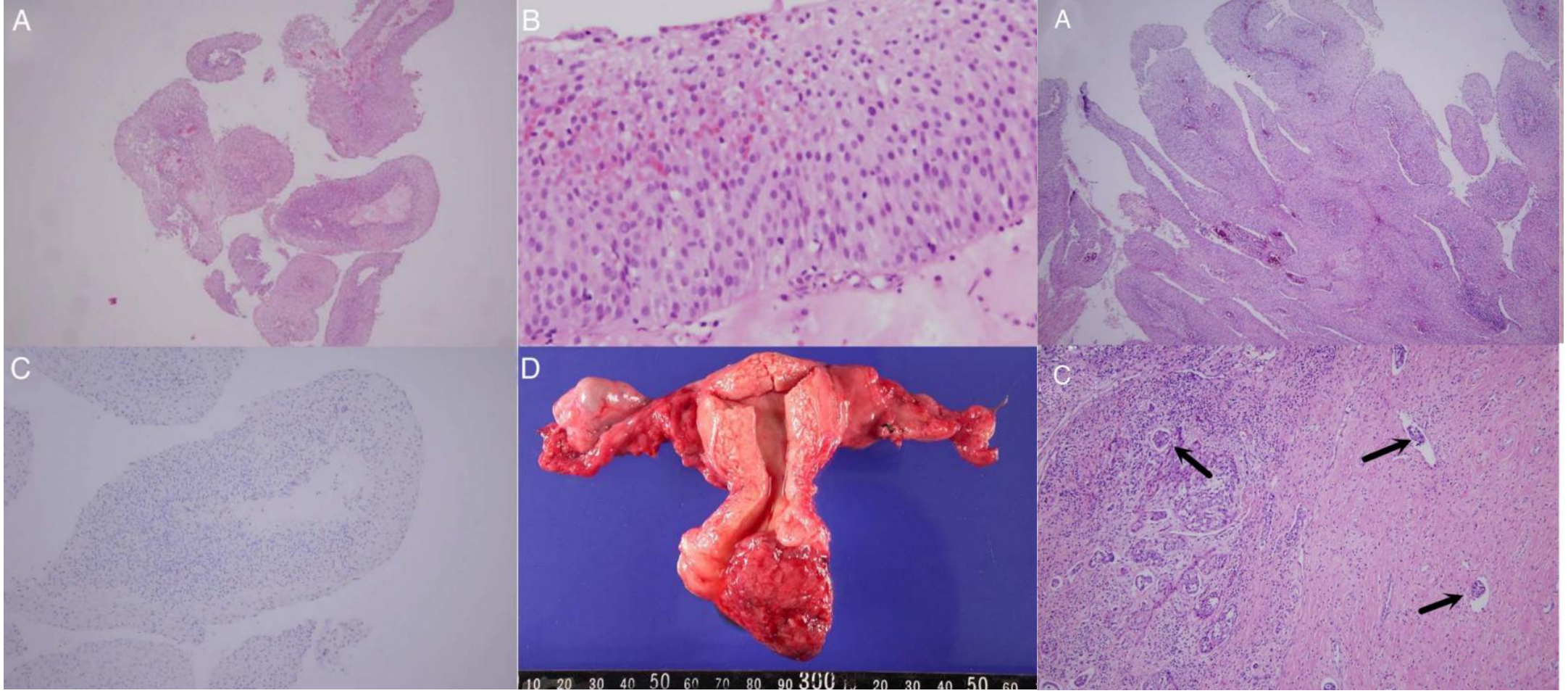

Non HPV-related cervical squamous cell carcinoma with unusual histologic characteristics mimicking a giant immature condyloma: a case report

HPVI squamous cell carcinoma

Squamous and Glandular Epithelial Tumors of the Cervix

A Pragmatical Review Emphasizing Emerging Issues in Classification, Diagnosis, and Staging

Simona Stolnicu, MD, PhD[a,*], Robert A. Soslow, MD[b]

Table 1
Comparison of 2014 and 2020 World Health Organization classification of epithelial malignant tumors of the cervix

2014 WHO Classification	2020 WHO Classification
SCC usual type	SCC, HPVA
Keratinizing	SCC, HPVI
Nonkeratinizing	SCC, NOS
Papillary	
Basaloid	
Warty	
Verrucous	
Squamotransitional	
Lymphoepithelioma-like	

HPVI SCC associated with prolapse

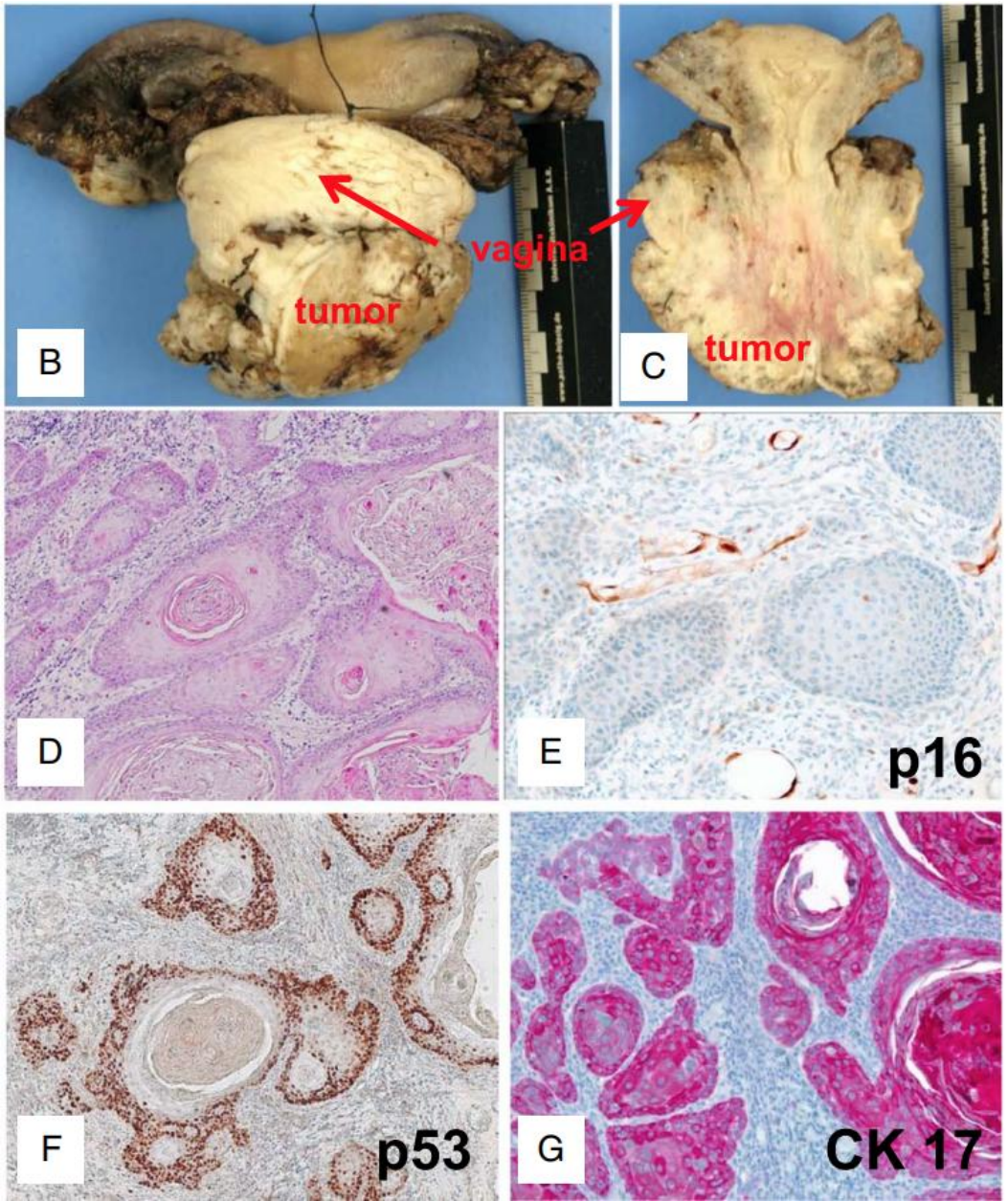

Human Papilloma Virus–Independent/p53abnormal Keratinizing Squamous Cell Carcinoma of the Uterine Cervix Associated With Uterine Prolapse

Lars-Christian Horn, MD, PhD, Christine E. Brambs, PhD,† Bahriye Aktas, PhD,‡ Astrid Dannenmann, MD,§ Jens Einenkel, PhD,§ Michael Höckel, PhD,‡ Irene Krücken, MD,*‖ Sabine Taubenheim, MD,¶ Gero Teichmann, MD,# Ulrike Obeck, MD,‖ Mathias Stiller, MD,‖ and Anne Kathrin Höhn, MD**

HPVI SCC associated with prolapse

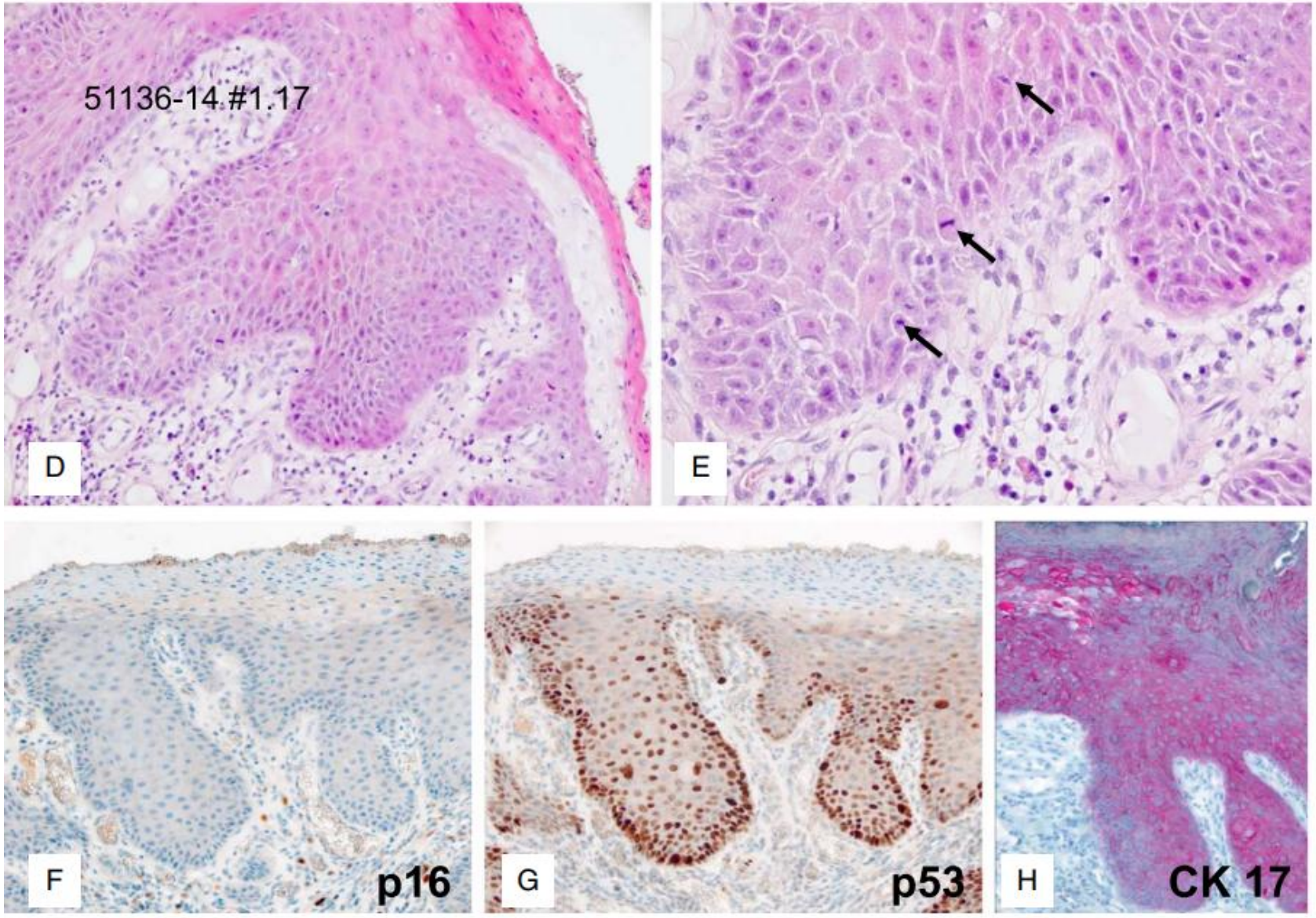

Immunohistochemical markers

P16 – negative or non-block staining

P53 – aberrant or wild-type

CK17 – strong diffuse expression

	HPV-associated invasive squamous cell carcinoma	**HPV-independent invasive squamous cell carcinoma**
Etiology/pathogenesis	HR-HPV and LR-HPV	No HR-HPV and LR-HPV
Clinical features	Small or large tumors	Large tumors
Mean age	51 years	>60 years
Location	Transformation/junctional zone	Transformation/junctional zone
Microscopic features	Any growth pattern	Any growth pattern
p16 expression/HPV testing	Block-type positive for p16/ HR-HPV and LR-HPV ISH positive	Negative for p16/ HR-HPV and LR-HPV ISH negative
Treatment	Surgery and oncologic treatment	Surgery and oncologic treatment
Prognosis	Usually good	Worse

HPVI adenosquamous carcinoma

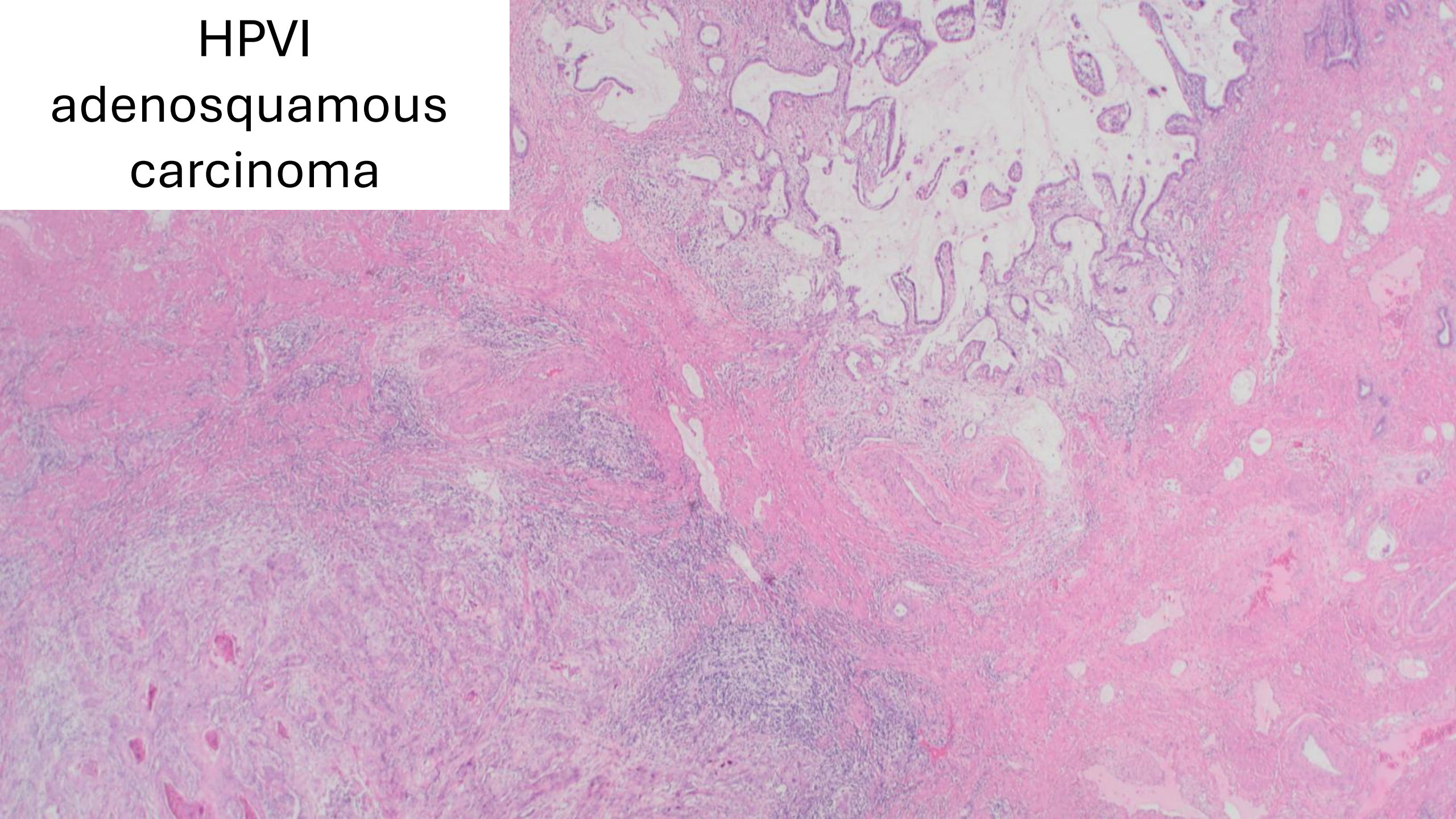

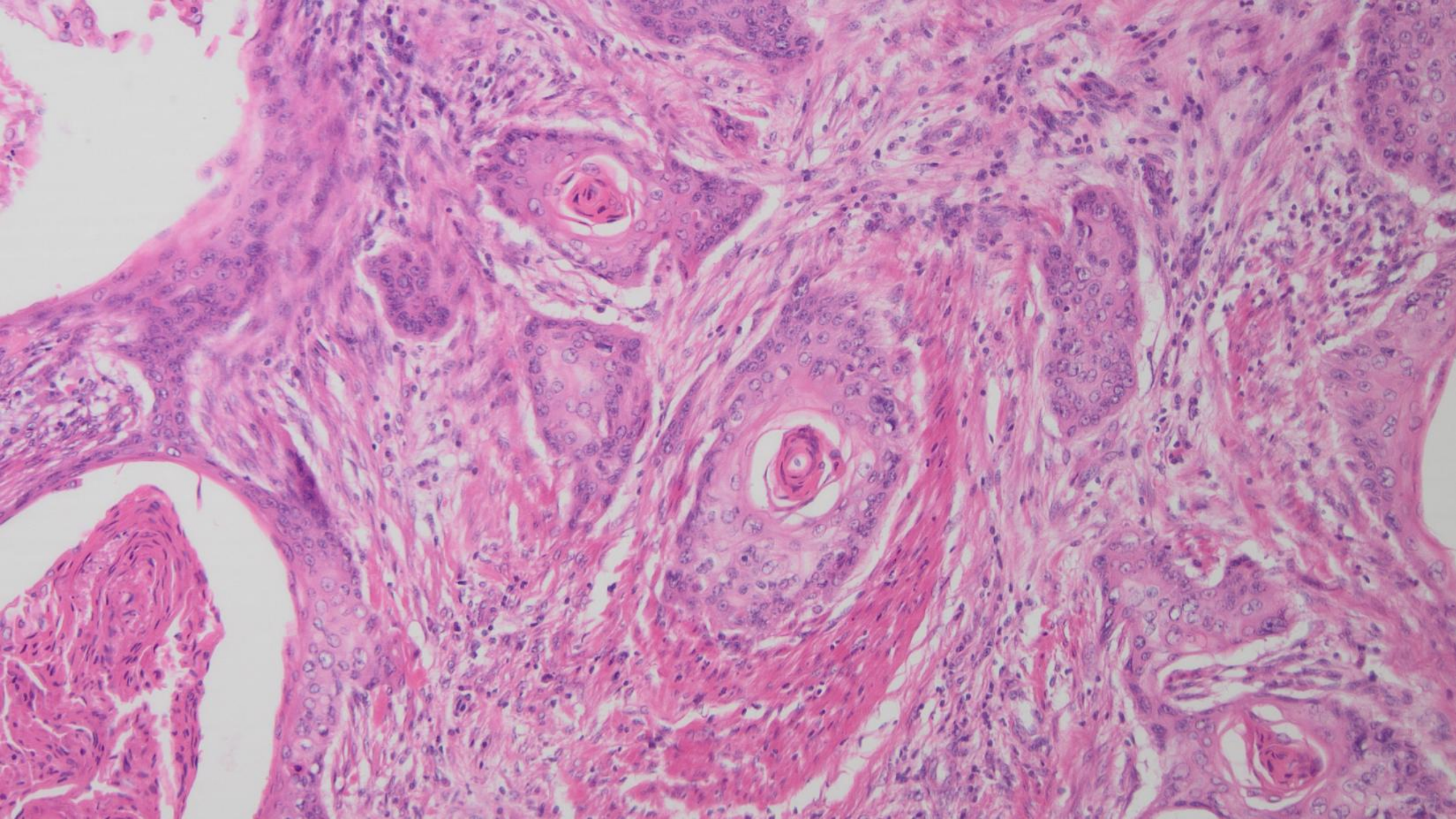

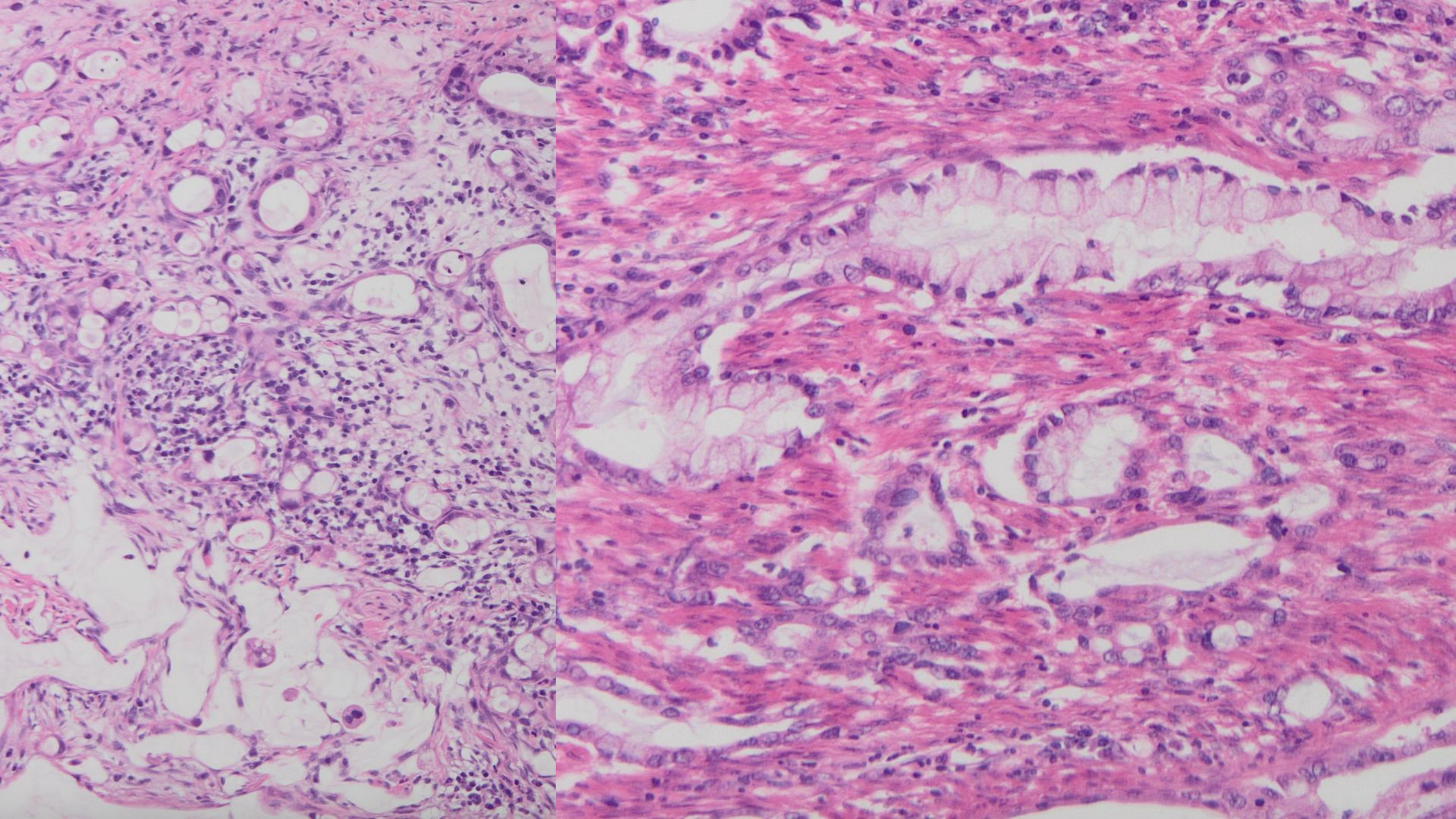

A case report of an HPV-independent gastric type adeno-squamous carcinoma of the uterine cervix.

Dr Rohaila Ahmed & Dr Iteeka Arora Barts Health NHS Trust

The British Association of Gynaecological Pathologists

2025 Poster Presentation

Challenges in measurement

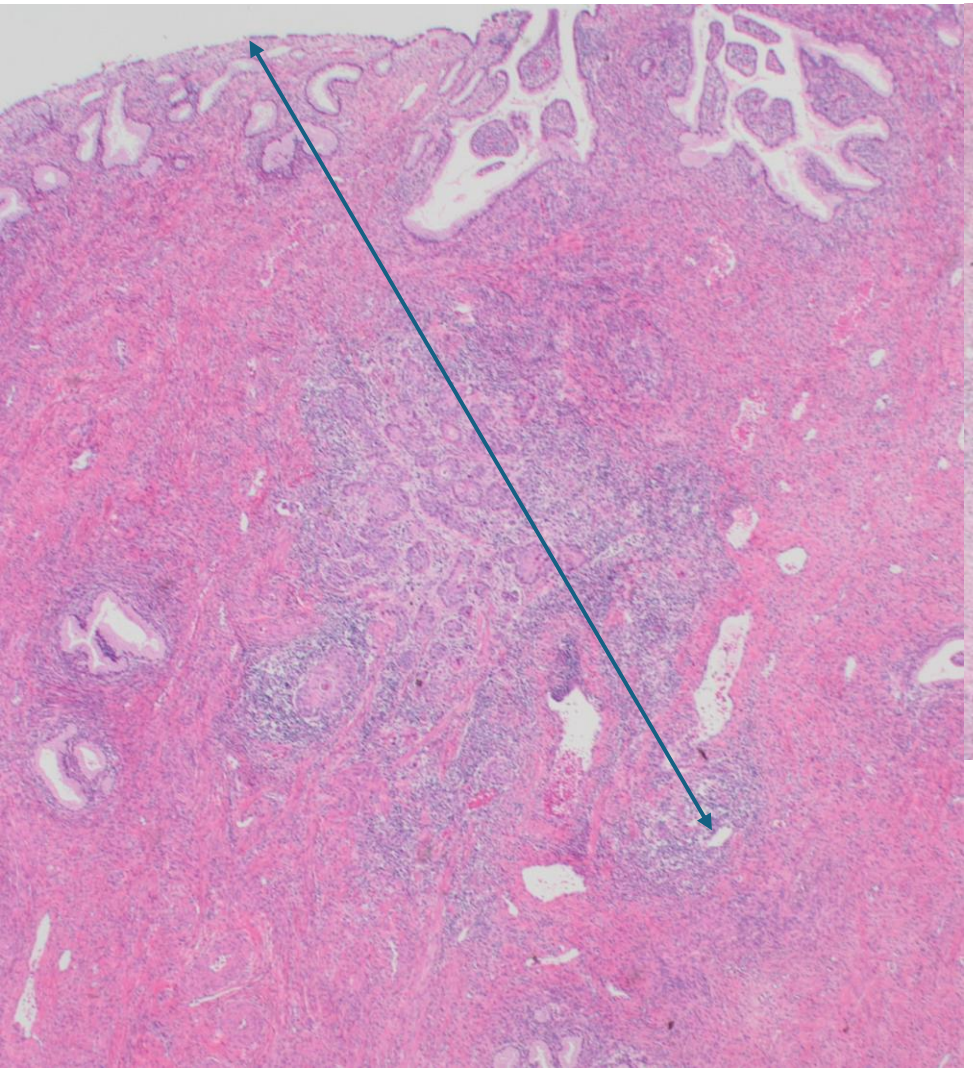

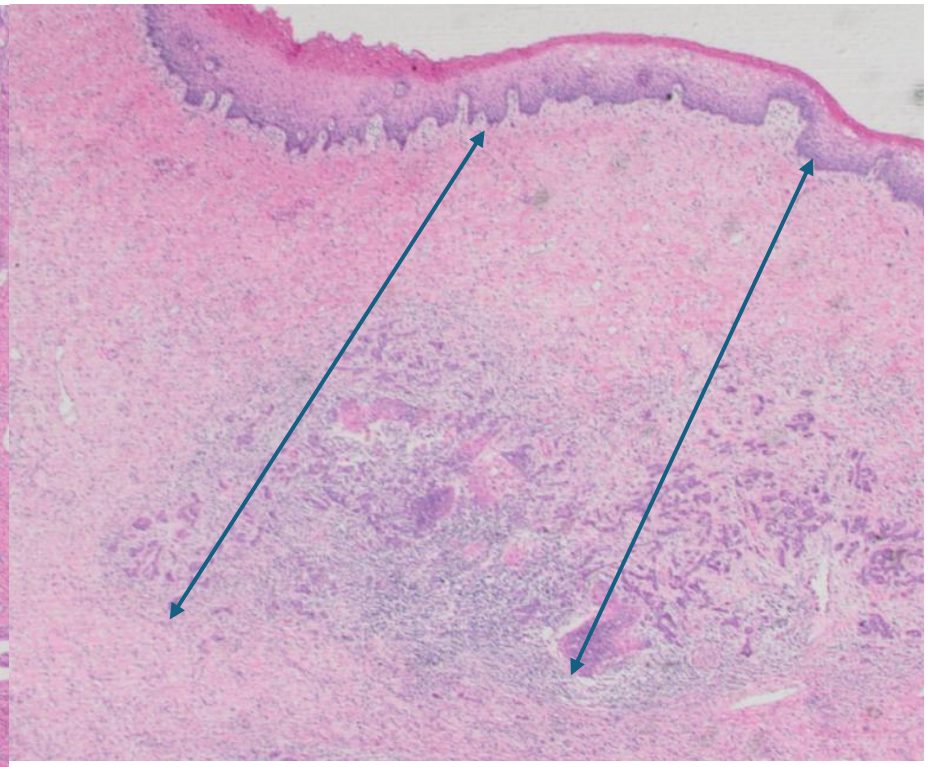

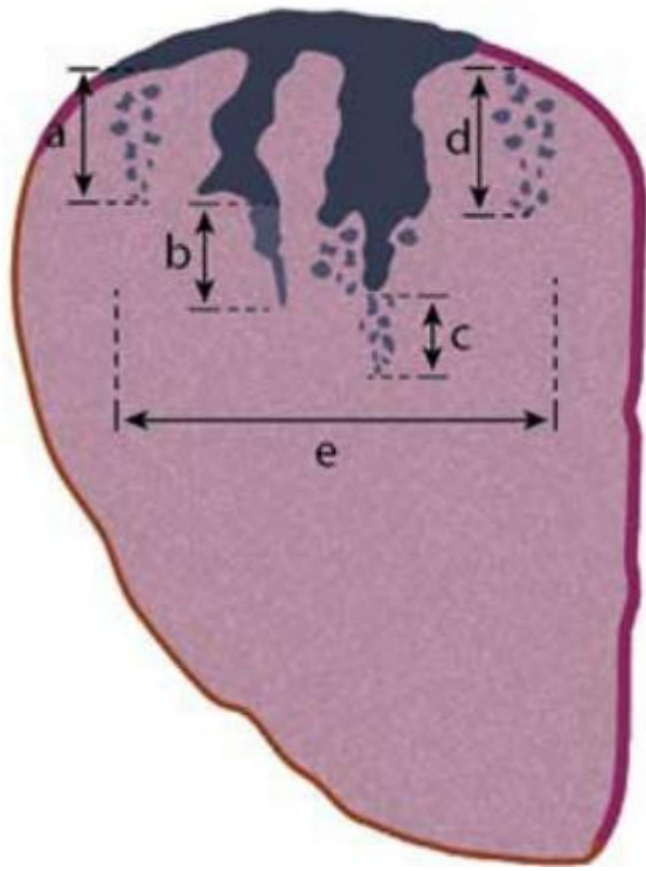

Invasion underlying normal epithelium

Challenges in measurement

Polypoid/papillary

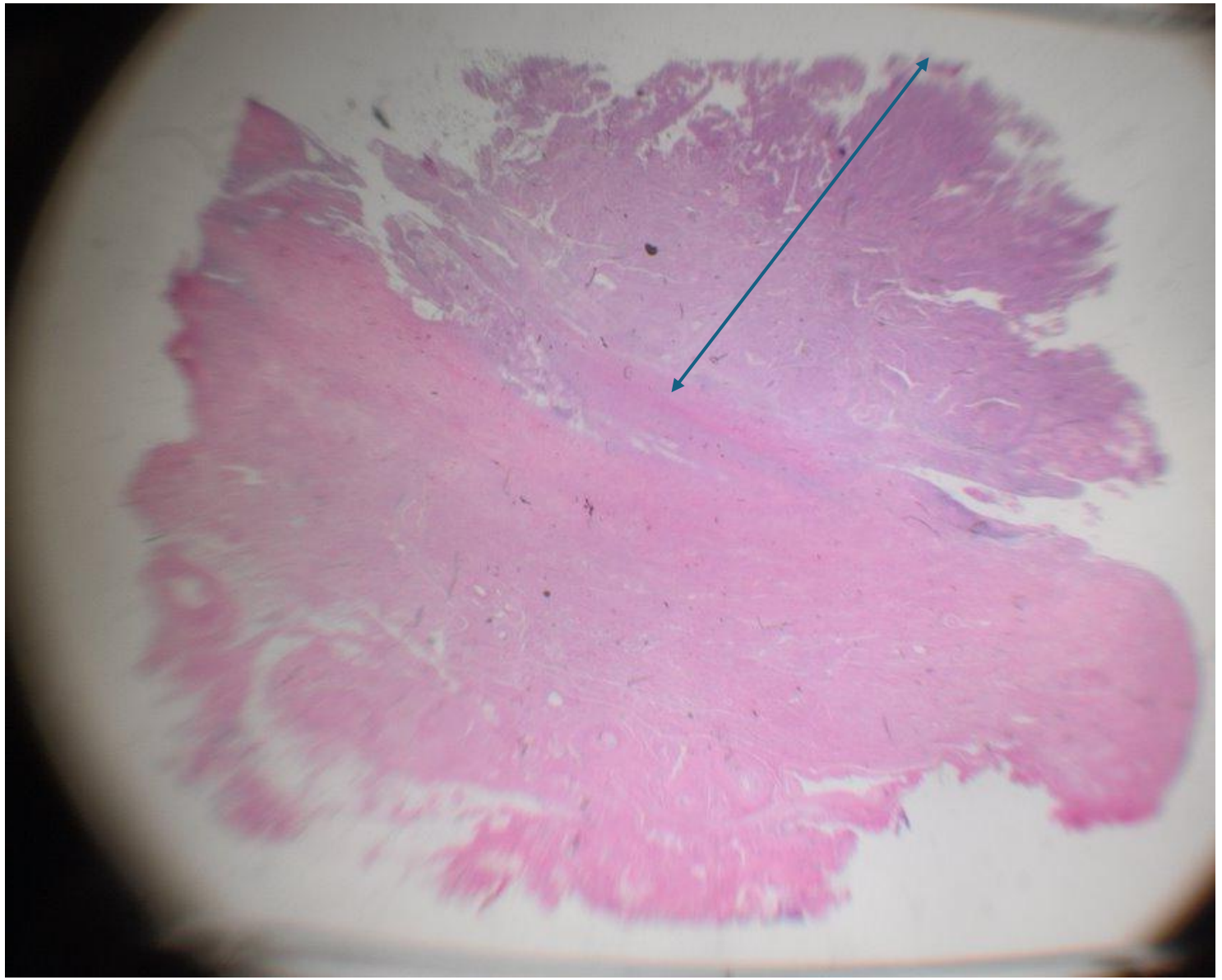

Challenges in measurement: After previous biopsy or treatment

- In providing the final tumour dimensions, the measurements in any prior specimens, for example loop/cone excisions, will need to be taken into account.
- Many cervical carcinomas of large size or advanced stage are treated by chemoradiation, without surgical resection.
- Occasionally resections are undertaken following chemoradiation for cervical carcinoma.
- Endocervical carcinomas

Vascular invasion

Intravascular tumour nests covered with endothelium

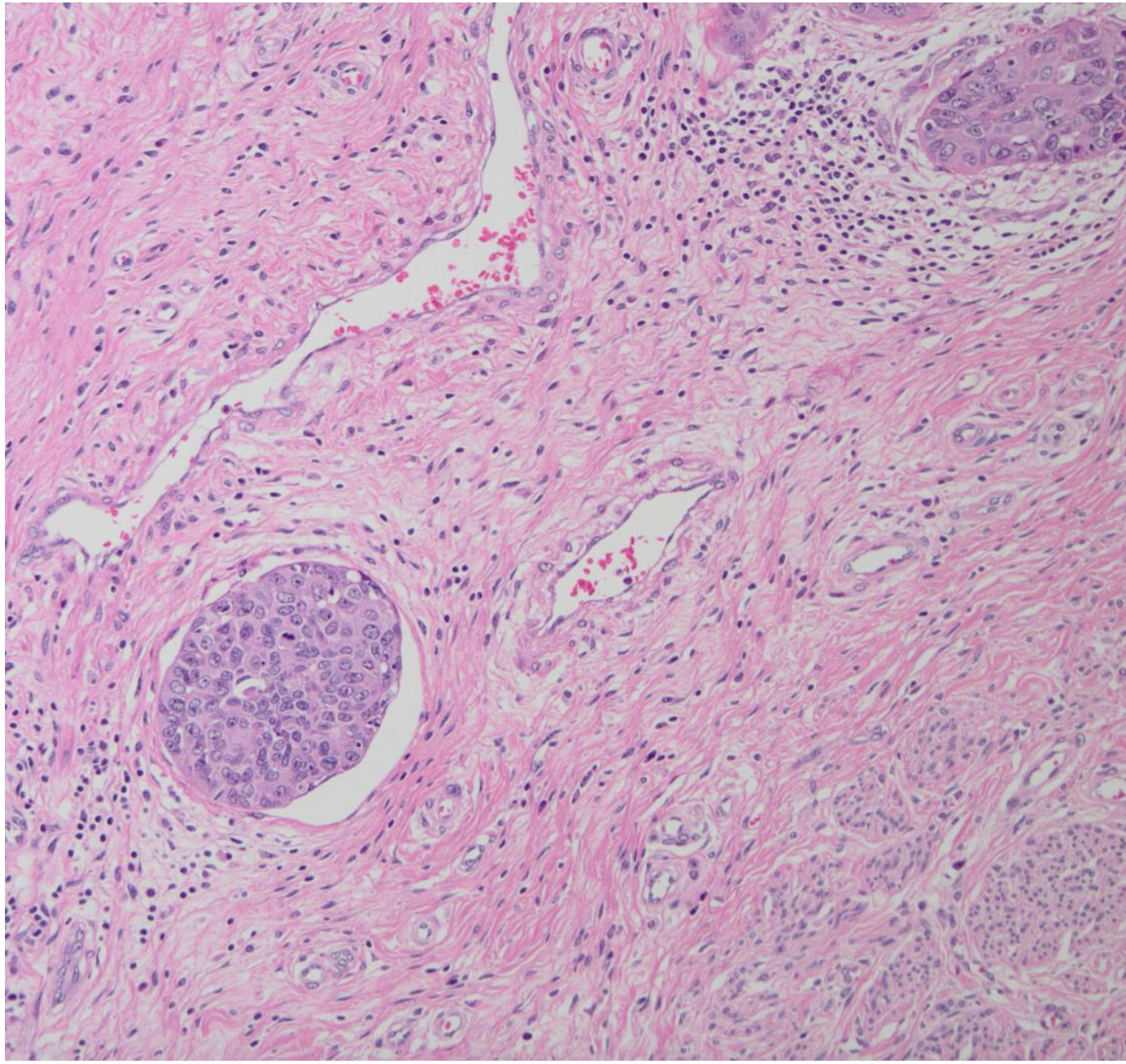

Vascular invasion

Tumour emboli in the blood vessel lumen

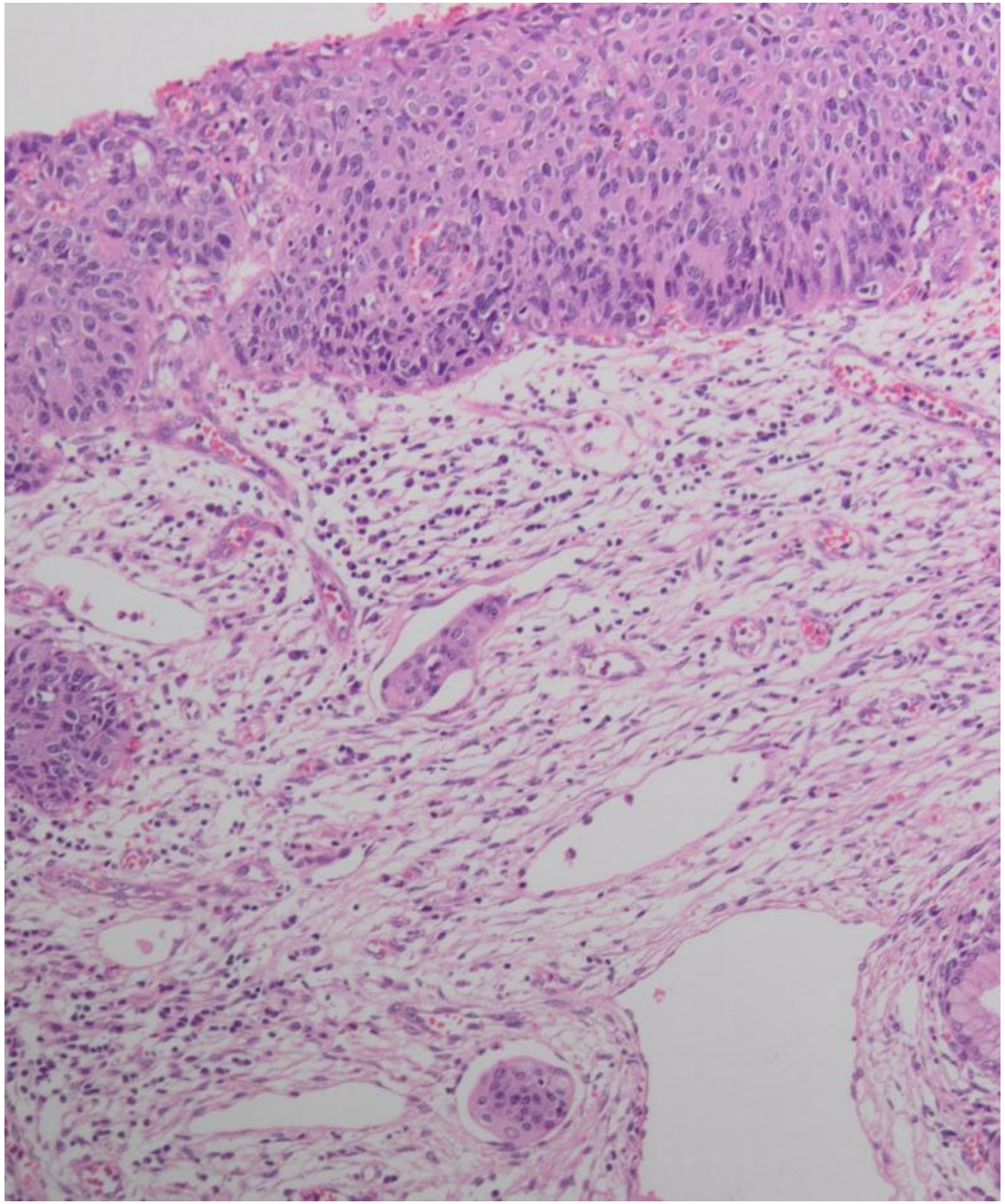

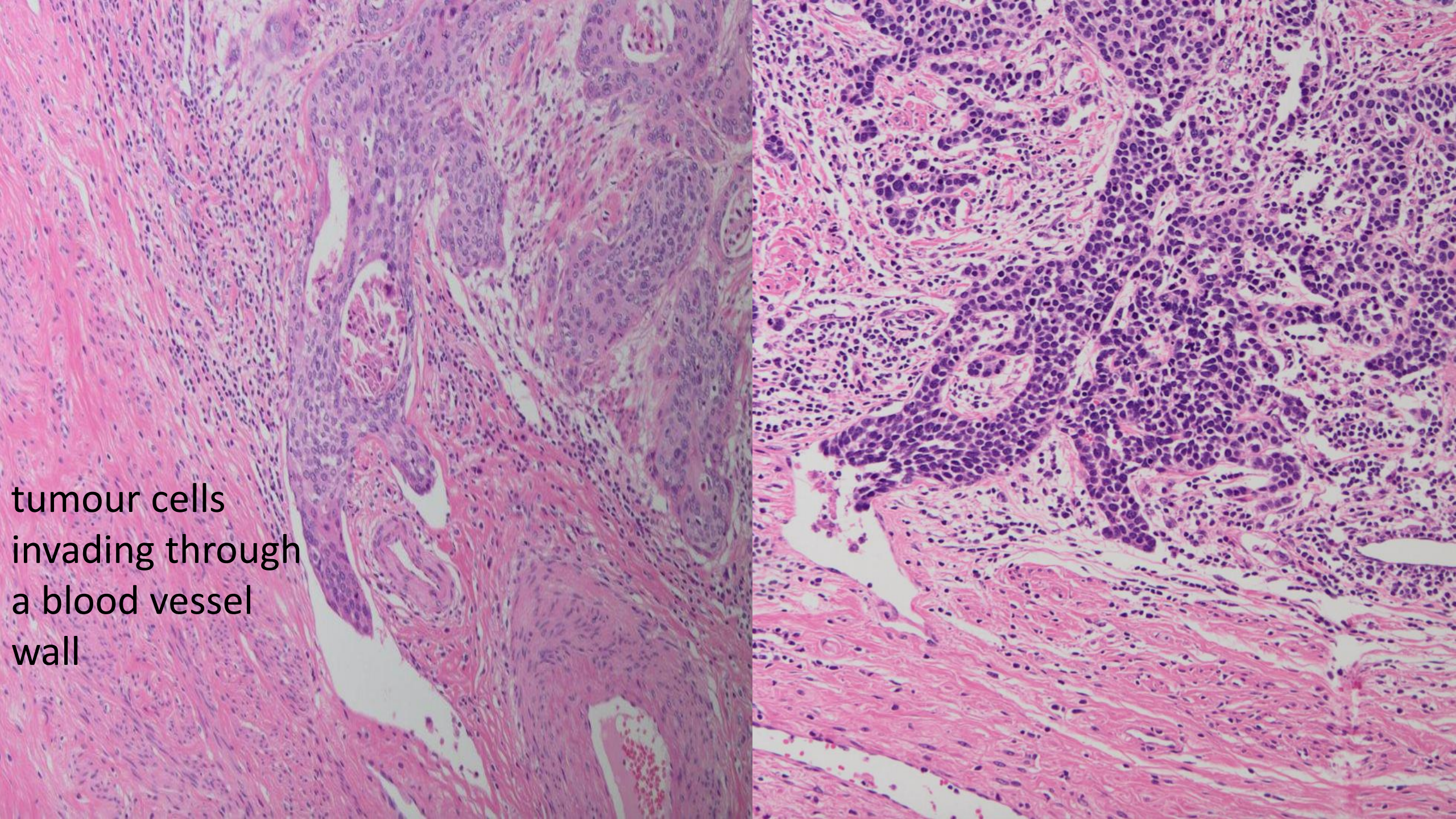
tumour cells
invading through
a blood vessel
wall

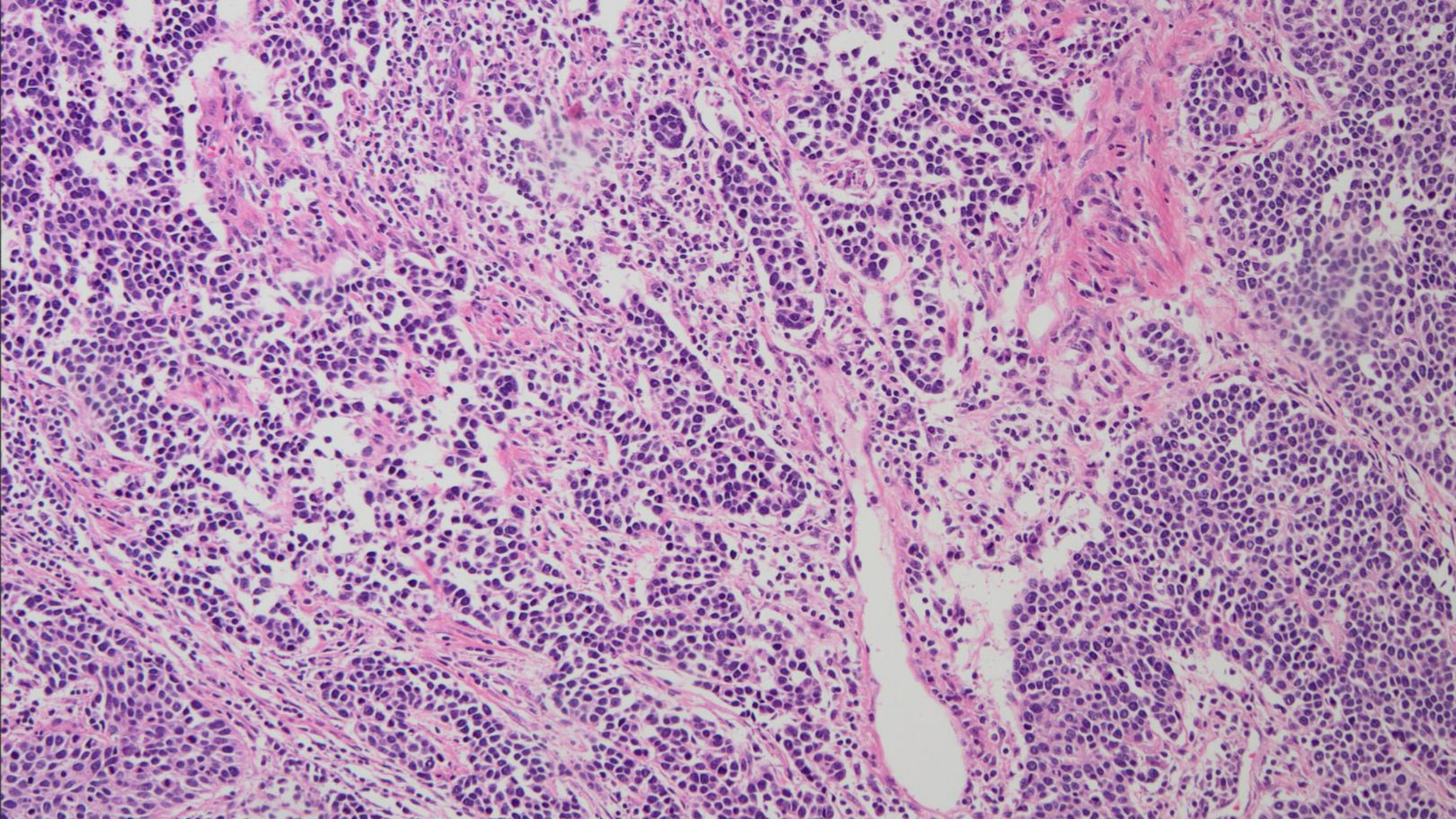

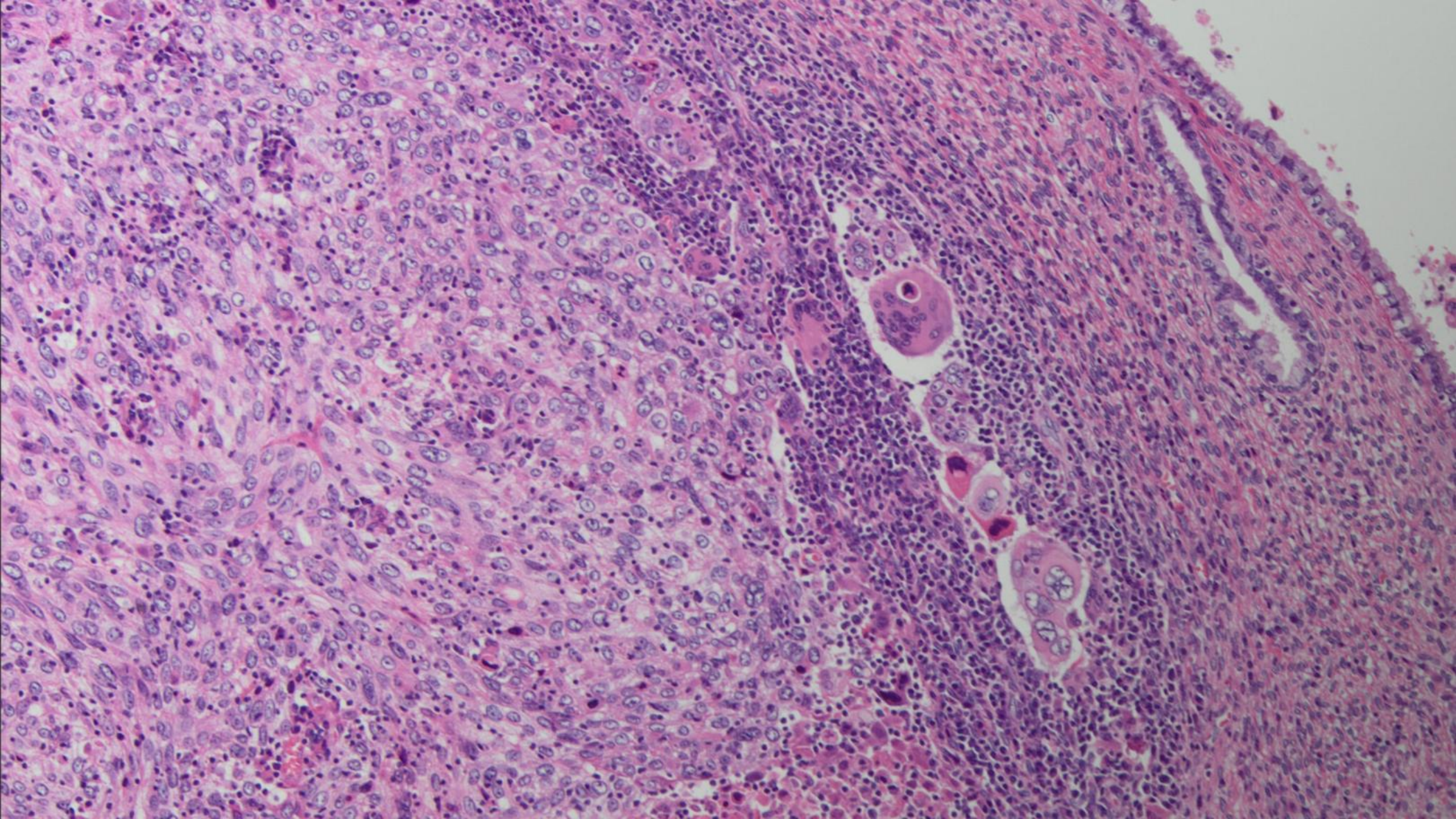

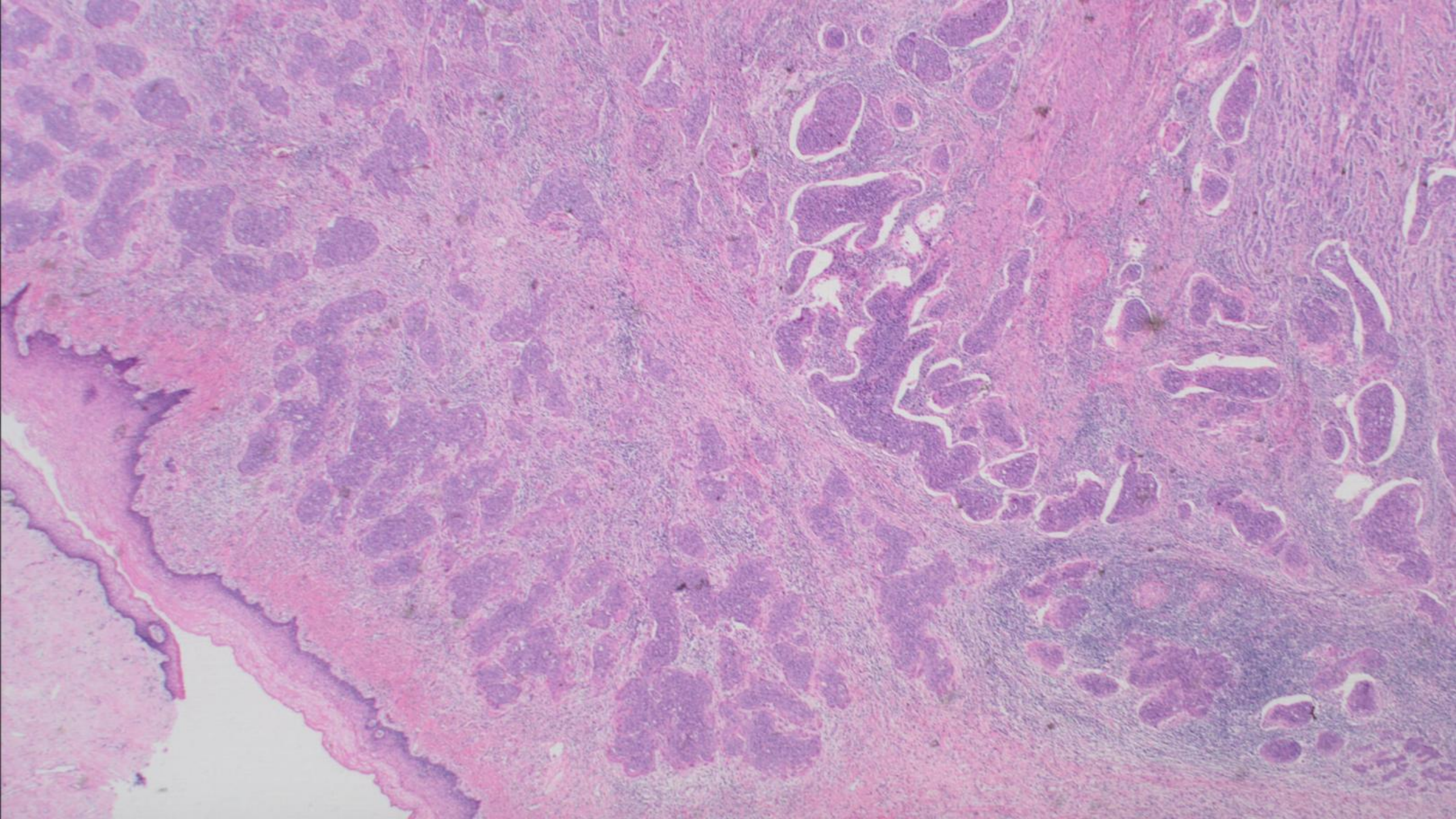

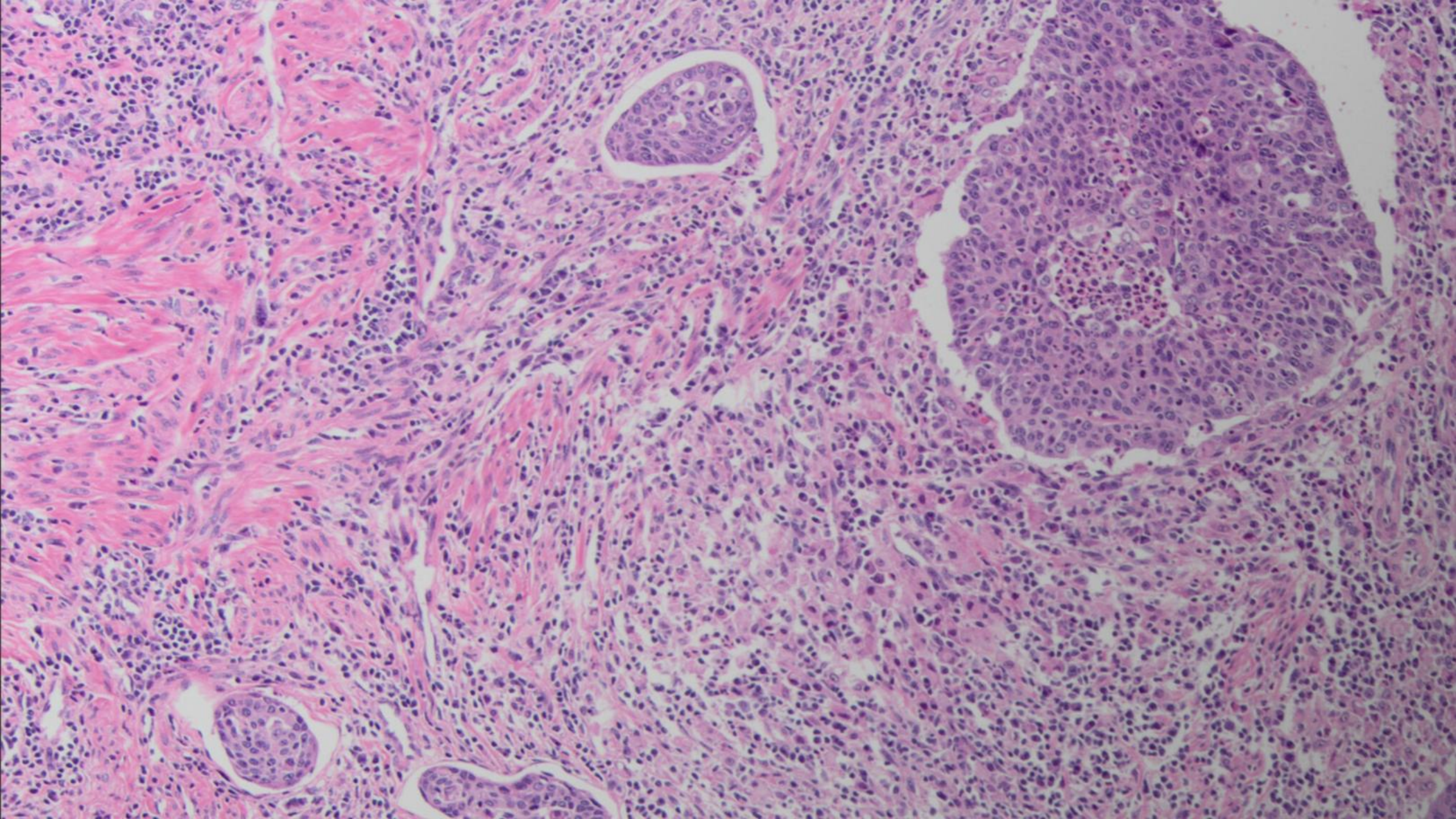

Summary

- Invasion – features of invasive squamous carcinoma
- Mimics - pseudoinvasion, pleomorphic CIN3
- CIN3-like carcinoma
- Unusual low-grade lesions – prompting HPV genotyping and reevaluation of malignant potential of 'low-risk' HPV
- HPV independent squamous lesions
- Measurements – depth of invasion vs tumour thickness
- Diagnosis of vascular invasion