FIGO 2023 Staging of Endometrial Cancer

New Dilemmas for Daily Practice

Joseph Rabban MD MPH
Professor
Director of Gynecologic Pathology
UCSF Pathology Department

Joseph.Rabban@ucsf.edu

UCSF
University of California
San Francisco

UCSF PATHOLOGY

Outline of Talk

- Overview of FIGO 2023 staging system for endometrial cancer
- Practical approach to potentially challenging “new” staging variables

Stage I/II	▪ Aggressive mimics of non-aggressive histotypes
	▪ Quantifying lymphovascular space invasion
Stage III/IV	▪ Defining sub-serosal tumor
	▪ Synchronous endometrial and ovarian tumor
	▪ Molecular staging pitfalls

Timeline of Updates to Endometrial Cancer Staging

FIGO 2009 → **Re-affirmed without change in subsequent years** → *Current* **FIGO 2023**

FIGO
International Federation of Gynecology and Obstetrics

DOI: 10.1002/ijgo.14923

SPECIAL ARTICLE

GYNECOLOGY OBSTETRICS FIGO WILEY

FIGO staging of endometrial cancer: 2023

Jonathan S. Berek[1] | Xavier Matias-Guiu[2] | Carien Creutzberg[3] | Christina Fotopoulou[4] | David Gaffney[5] | Sean Kehoe[6] | Kristina Lindemann[7] | David Mutch[8] | Nicole Concin[9,10] | Endometrial Cancer Staging Subcommittee, FIGO Women's Cancer Committee

Variables
Tumor
Nodes
Metastasis

Comprehensive risk stratification

Variables	
Tumor	
Nodes	
Metastasis	
Histotype	***New***
Grade	
LVSI	
Molecular subtype	

2021 European Risk Group System

Risk group	
Low	▶ Stage I–II ***POLEmut*** endometrial carcinoma, no residual disease ▶ Stage IA **MMRd/NSMP** endometrioid carcinoma + low-grade‡ + LVSI negative or focal
Intermediate	▶ Stage IB **MMRd/NSMP** endometrioid carcinoma + low-grade‡ + LVSI negative or focal ▶ Stage IA **MMRd/NSMP** endometrioid carcinoma + high-grade‡ + LVSI negative or focal ▶ Stage IA **p53abn** and/or non-endometrioid (serous, clear cell, undifferentiated carcinoma, carcinosarcoma, mixed) without myometrial invasion
High–intermediate	▶ Stage I **MMRd/NSMP** endometrioid carcinoma + substantial LVSI regardless of grade and depth of invasion ▶ Stage IB **MMRd/NSMP** endometrioid carcinoma high-grade‡ regardless of LVSI status ▶ Stage II **MMRd/NSMP** endometrioid carcinoma
High	▶ Stage III–IVA **MMRd/NSMP** endometrioid carcinoma with no residual disease ▶ Stage I–IVA **p53abn** endometrial carcinoma with myometrial invasion, with no residual disease ▶ Stage I–IVA **NSMP/MMRd** serous, undifferentiated carcinoma, carcinosarcoma with myometrial invasion, with no residual disease
Advanced metastatic	▶ Stage III–IVA with residual disease of any molecular type ▶ Stage IVB of any molecular type

ESGO/ESTRO/ESP guidelines for the management of patients with endometrial carcinoma

Nicole Concin [1,2] Xavier Matias-Guiu,[3,4] Ignace Vergote,[5] David Cibula,[6] Mansoor Raza Mirza,[7] Simone Marnitz,[8] Jonathan Ledermann [9] Tjalling Bosse,[10] Cyrus Chargari,[11] Anna Fagotti,[12] Christina Fotopoulou [13] Antonio Gonzalez Martin,[14] Sigurd Lax,[15,16] Domenica Lorusso,[12] Christian Marth,[17] Philippe Morice,[18] Remi A Nout,[19] Dearbhaile O'Donnell,[20] Denis Querleu [12,21] Maria Rosaria Raspollini,[22] Jalid Sehouli,[23] Alina Sturdza,[24] Alexandra Taylor,[25] Anneke Westermann,[26] Pauline Wimberger,[27] Nicoletta Colombo,[28] François Planchamp,[29] Carien L Creutzberg[30]

PMID: 33397713

Variables
Tumor
Nodes
Metastasis
Histotype
Grade
LVSI
Molecular subtype

FIGO 2023 Staging of Endometrial Cancer

Prognostic Value is More Refined than FIGO 2009

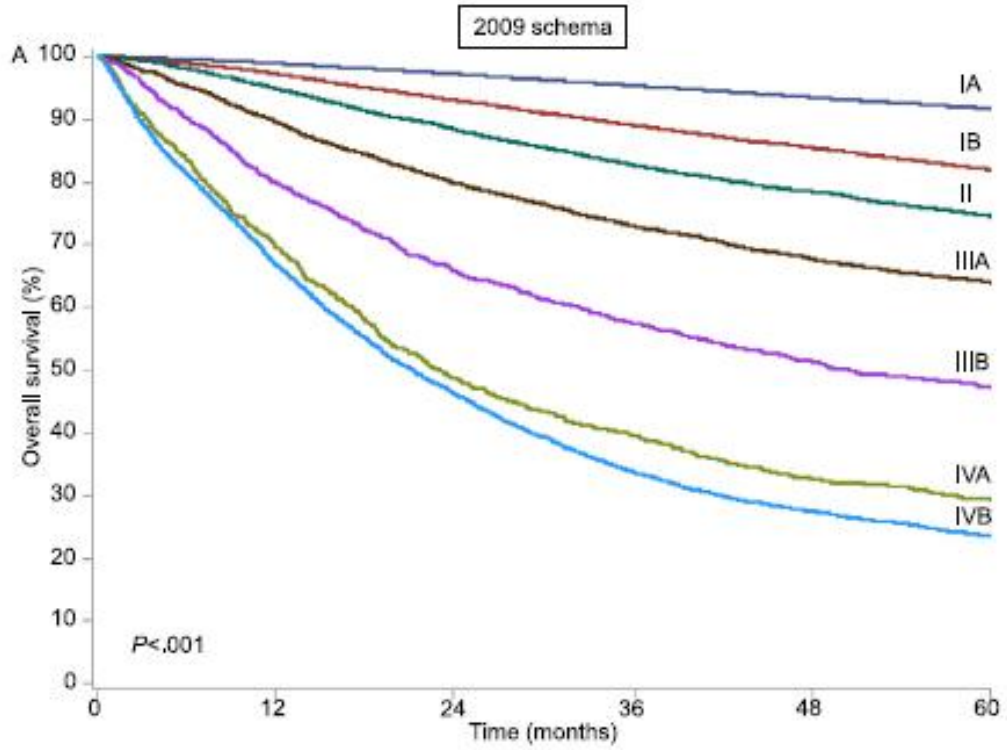

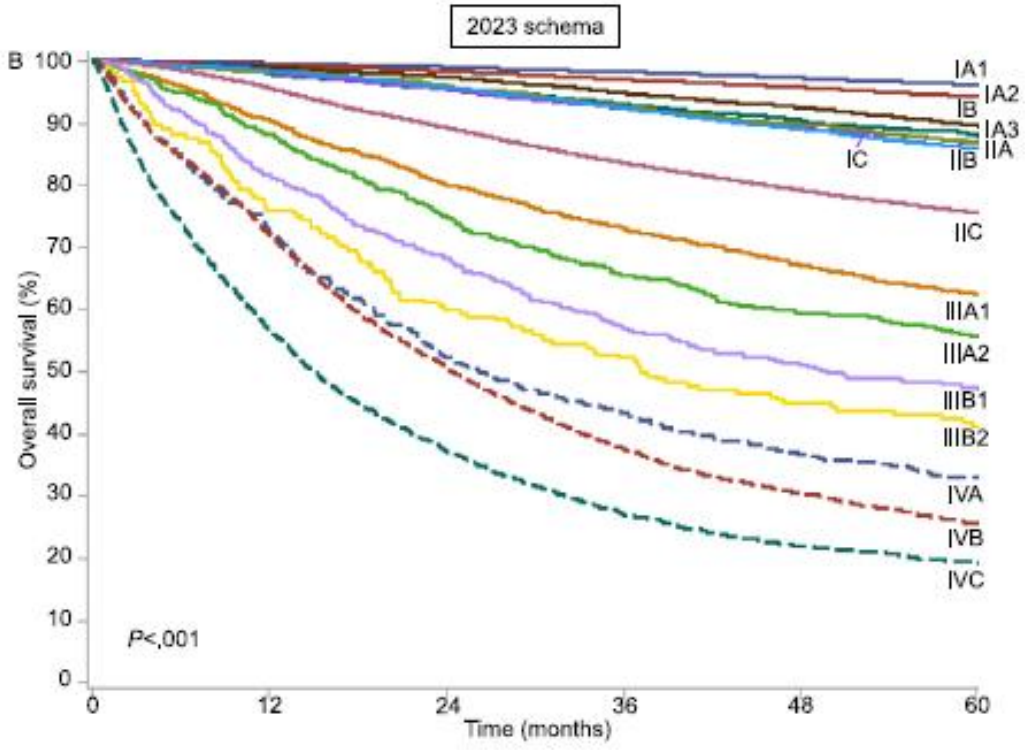

National Cancer Database
N=129,146

Images from PMID 38713997

Prognostic performance of the 2023 FIGO staging schema for endometrial cancer

Koji Matsuo [a,b,*,1], Ling Chen [c,1], Maximilian Klar [d], Matthew W. Lee [a], Hiroko Machida [e], Mikio Mikami [e], Laila I. Muderspach [a], Joseph W. Carlson [f], Lynda D. Roman [a,b], Jason D. Wright [c,**]

[a] Division of Gynecologic Oncology, Department of Obstetrics and Gynecology, University of Southern California, Los Angeles, CA, USA
[b] Norris Comprehensive Cancer Center, University of Southern California, Los Angeles, CA, USA
[c] Division of Gynecologic Oncology, Department of Obstetrics and Gynecology, Columbia University College of Physicians and Surgeons, New York, NY, USA
[d] Department of Obstetrics and Gynecology, University of Freiburg Faculty of Medicine, Freiburg, Germany
[e] Department of Obstetrics and Gynecology, Tokai University School of Medicine, Kanagawa, Japan
[f] Department of Pathology, University of Southern California, Los Angeles, CA, USA

FIGO 2023 Staging: No Longer Pure Anatomic Mapping

Now a Risk Stratification System, Parallel to 2021 European Risk Grouping

DOI: 10.1002/ijgo.14923

SPECIAL ARTICLE

FIGO staging of endometrial cancer: 2023

Jonathan S. Berek[1] | Xavier Matias-Guiu[2] | Carien Creutzberg[3] | Christina Fotopoulou[4] | David Gaffney[5] | Sean Kehoe[6] | Kristina Lindemann[7] | David Mutch[8] | Nicole Concin[9,10] | Endometrial Cancer Staging Subcommittee, FIGO Women's Cancer Committee

PMID: 37337978

ESGO/ESTRO/ESP guidelines for the management of patients with endometrial carcinoma

Nicole Concin [1,2] Xavier Matias-Guiu,[3,4] Ignace Vergote,[5] David Cibula,[6] Mansoor Raza Mirza,[7] Simone Marnitz,[8] Jonathan Ledermann [9] Tjalling Bosse,[10] Cyrus Chargari,[11] Anna Fagotti,[12] Christina Fotopoulou [13] Antonio Gonzalez Martin,[14] Sigurd Lax,[15,16] Domenica Lorusso,[12] Christian Marth,[17] Philippe Morice,[18] Remi A Nout,[19] Dearbhaile O'Donnell,[20] Denis Querleu [12,21] Maria Rosaria Raspollini,[22] Jalid Sehouli,[23] Alina Sturdza,[24] Alexandra Taylor,[25] Anneke Westermann,[26] Pauline Wimberger,[27] Nicoletta Colombo,[28] François Planchamp,[29] Carien L Creutzberg[30]

PMID: 33397713

<u>Practical consequence</u>: FIGO stage is no longer comparable between pre-2023 and post-2023

Concerns have been raised

PMID: 37935523
PMID: 38733417

FIGO 2023 Staging of Endometrial Cancer

Stage I, II Uterus-confined	▪ **Histotype**	Non-aggressive vs aggressive
	▪ **Grade**	Low vs high
	▪ **LVSI**	None/focal vs substantial
	▪ **Anatomic spread**	Myometrium, cervix, ovary*
Stage IAm, IIAm Molecular	▪ ***POLE*** mutation	
	▪ ***TP53*** mutation / **p53** aberrant	
Stage III, IV Extra-uterine	▪ **Anatomic spread beyond uterus** *except synchronous ovarian involvement*	
	▪ **Lymph nodes**	

Outline of Talk

- Overview of FIGO 2023 staging system for endometrial cancer
- **Practical approach to potentially challenging "new" staging variables**



Stage I/II	▪ **Aggressive mimics of non-aggressive histotypes**

Non-Aggressive versus Aggressive Histotypes

FIGO 2023 Definition

Non-Aggressive	Aggressive
Grade 1 and 2 endometrioid carcinoma	▪ Grade 3 endometrioid carcinoma ▪ Serous carcinoma ▪ Carcinosarcoma ▪ Clear cell carcinoma ▪ Undifferentiated carcinoma ▪ Mesonephric like carcinoma ▪ Gastro-intestinal type carcinoma

Counterpoint raised:

Grade 3 endometrioid carcinoma is heterogeneous; spans all TCGA subtypes including POLE

Non-Aggressive versus Aggressive Histotypes

Low Grade
Endometrioid Carcinoma
(conventional and variant forms)



High Risk
Carcinomas with Deceptive Morphology
(many different histotypes)



Non-Aggressive versus Aggressive Histotypes

Diagnostic Pitfalls





Low Grade Endometrioid Carcinoma *Morphologic Variant*	High Risk Mimic
***Glandular** pattern*	▪ Glandular pattern serous carcinoma
	▪ Mesonephric-like carcinoma
	▪ Gastric type carcinoma

Glandular Pattern Serous Carcinoma

Mimics grade 1 endometrioid carcinoma

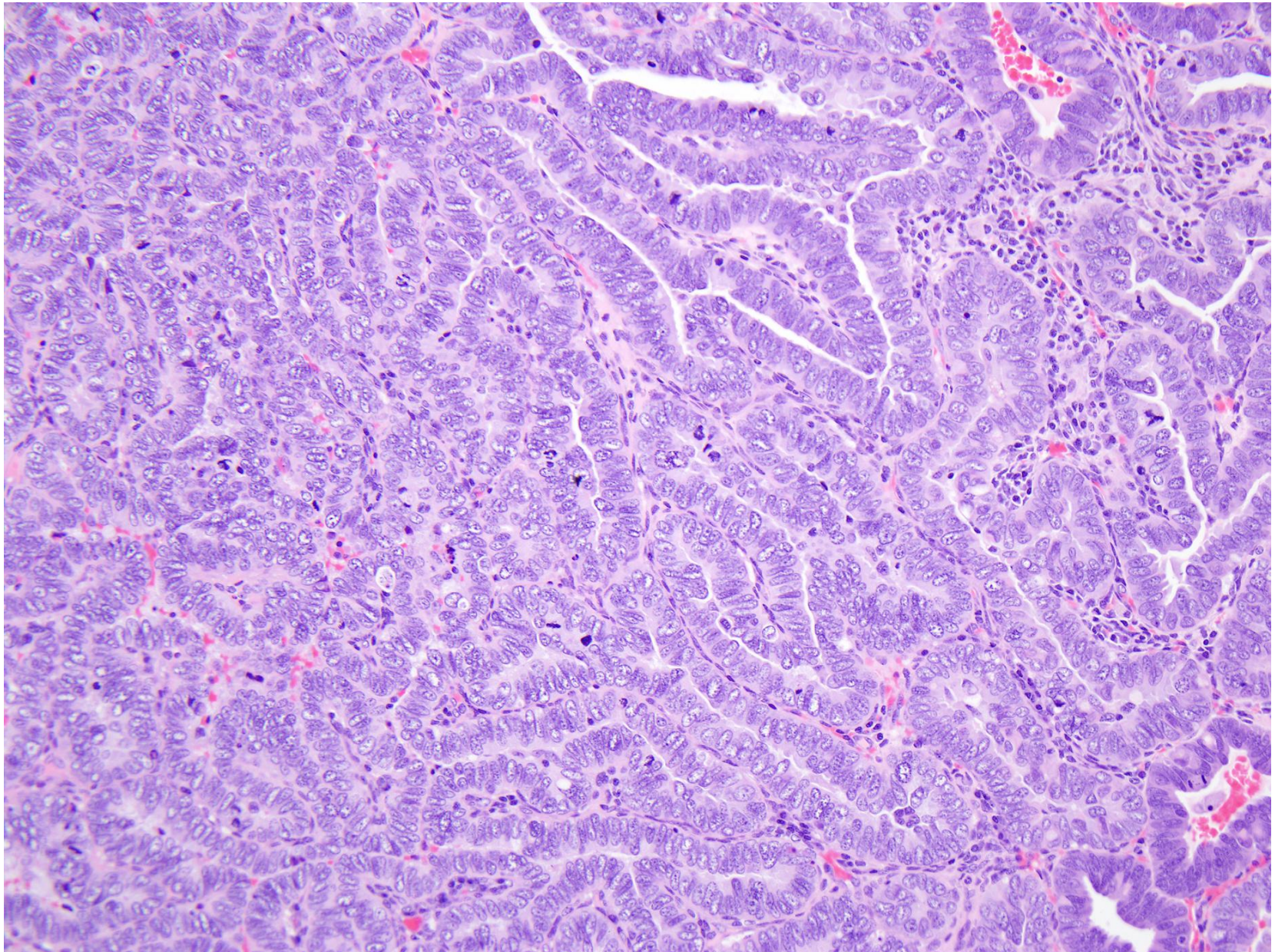

Glandular Pattern Serous Carcinoma

Mimics grade 1 endometrioid carcinoma

Polyp

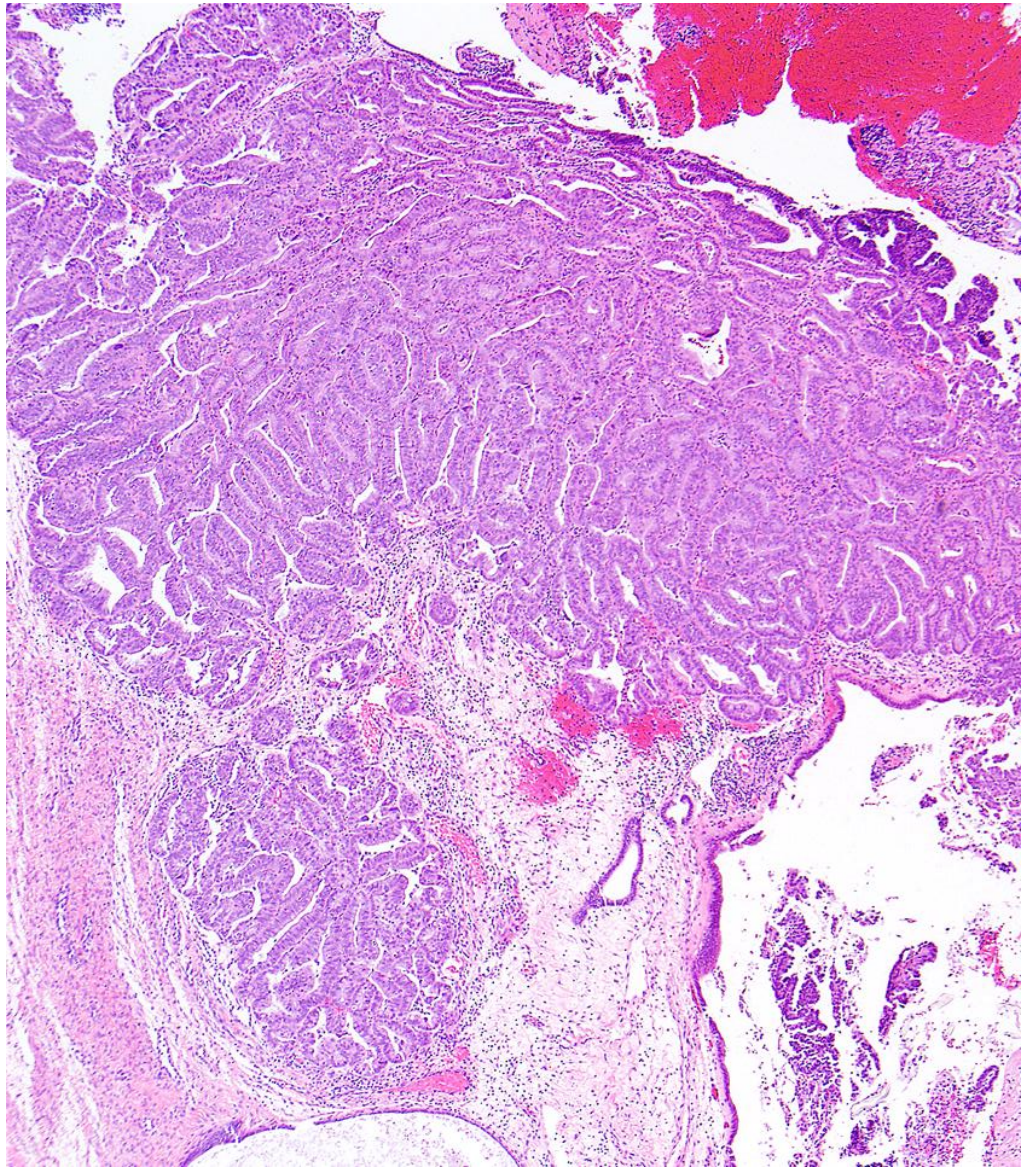

Biopsy

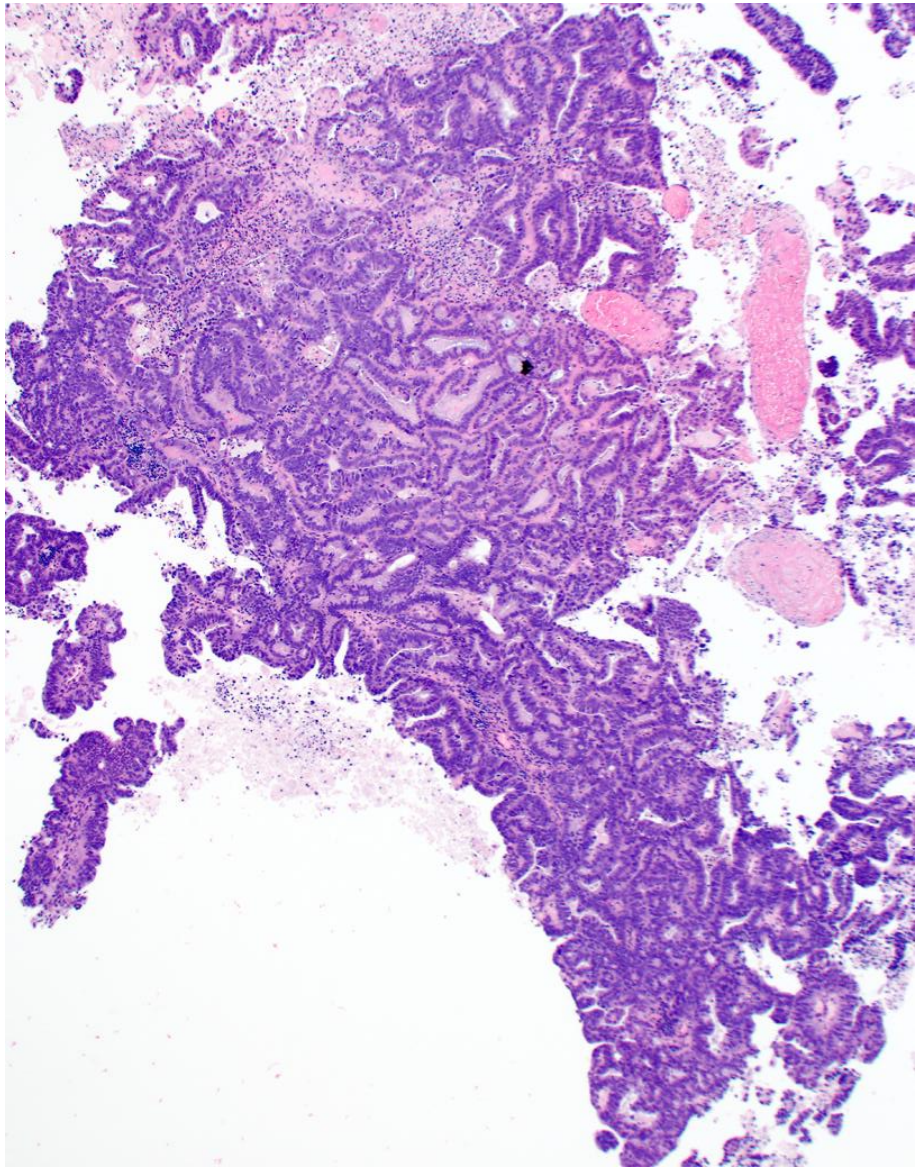

Distinguishing Low Grade Endometrioid versus Glandular Pattern Serous Carcinoma

Concordance of Architecture and Nuclear Grade

	Endometrioid Carcinoma Low Grade	Serous Carcinoma Glandular-Pattern
Architectural grade	Low	Low
Nuclear grade	Low	High

Concordant ***Discordant***

<u>High nuclear grade:</u>

- High N/C ratio
- Pleomorphic
- Hyperchromatic
- Macronucleoli
- Brisk, atypical mitoses

Serous carcinoma –*glandular variant*

High nucleus to cytoplasm ratio

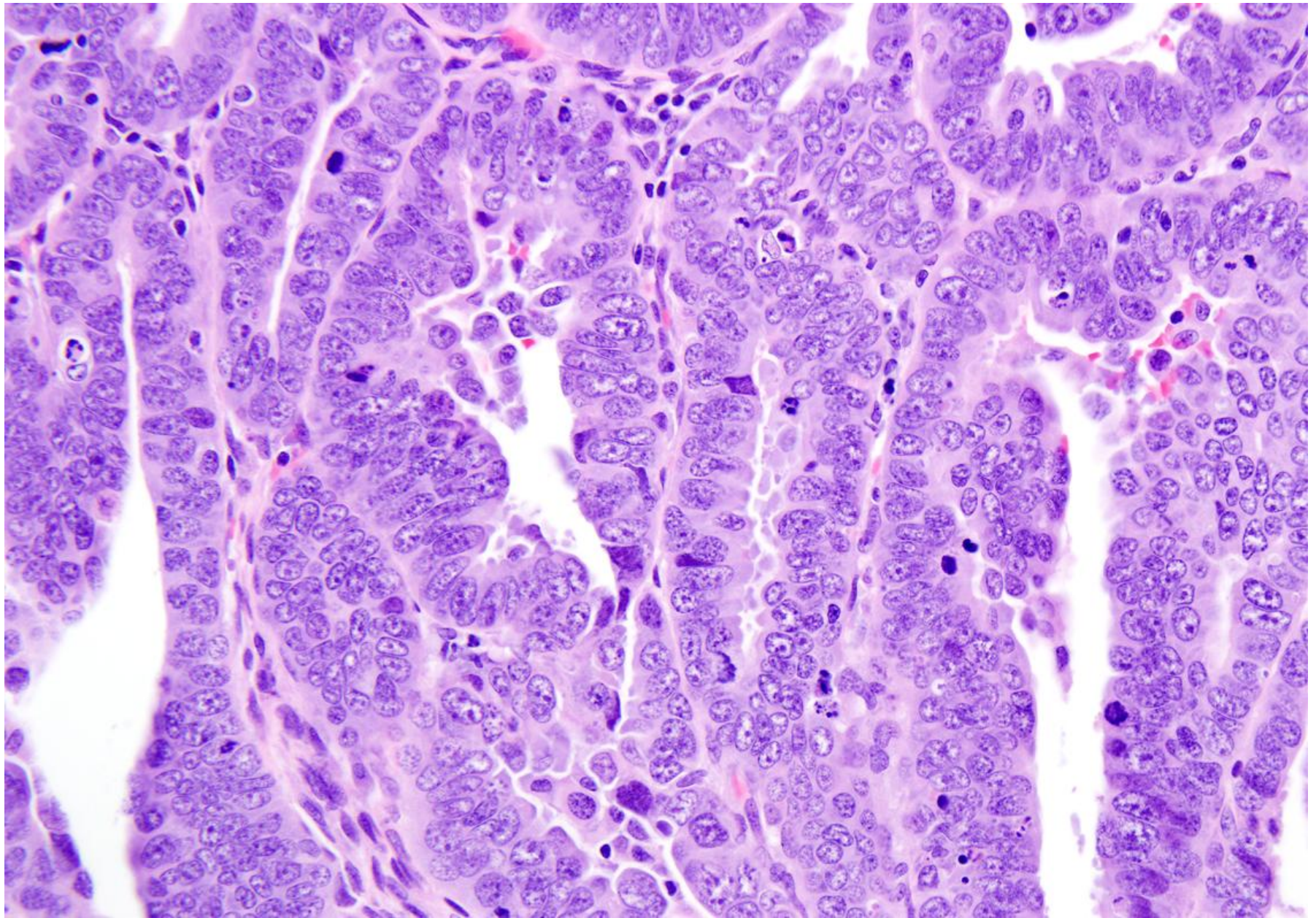

Serous carcinoma –*glandular variant*

Irregular macronucleoli

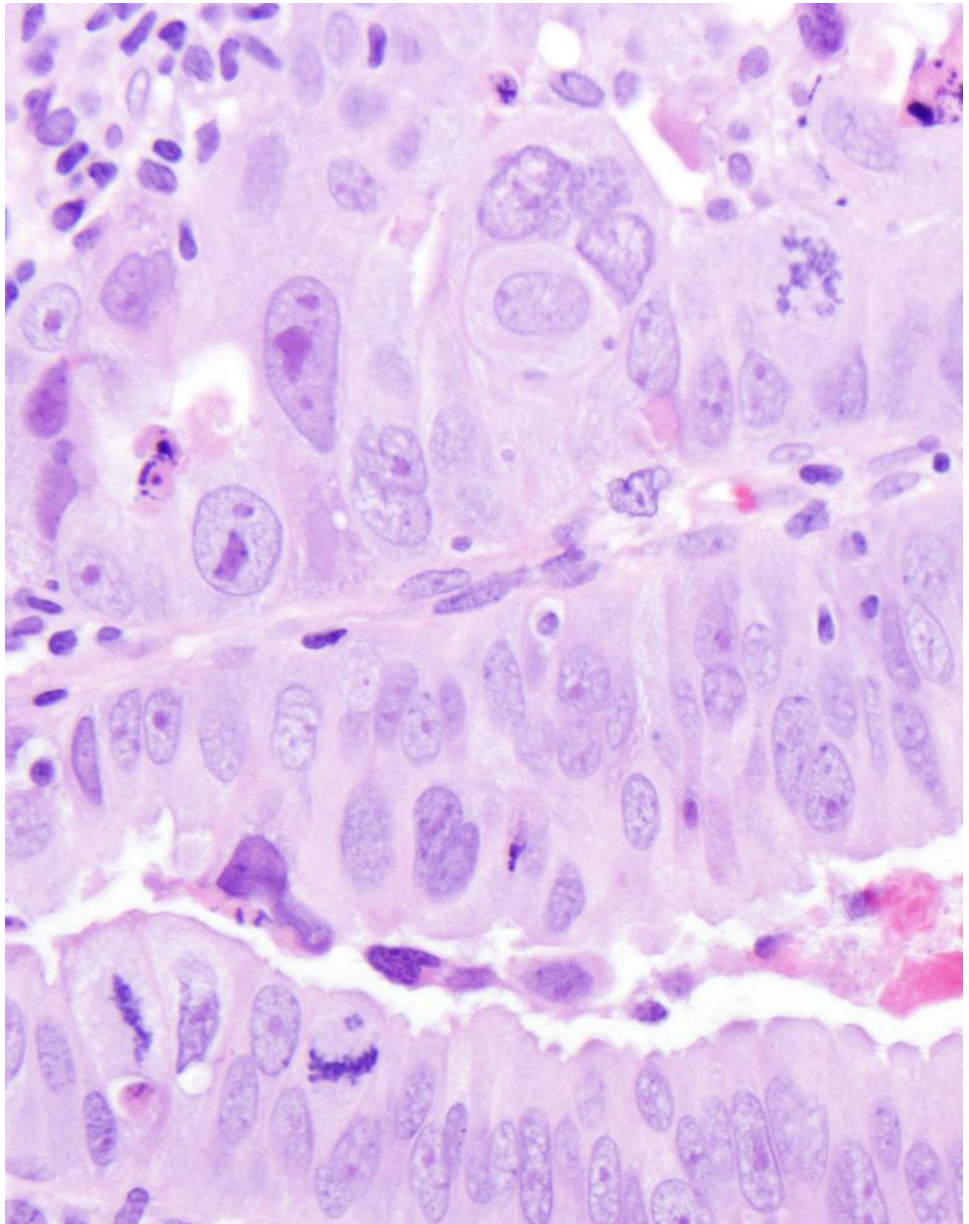

Purple bizarre nuclei, smudged chromatin

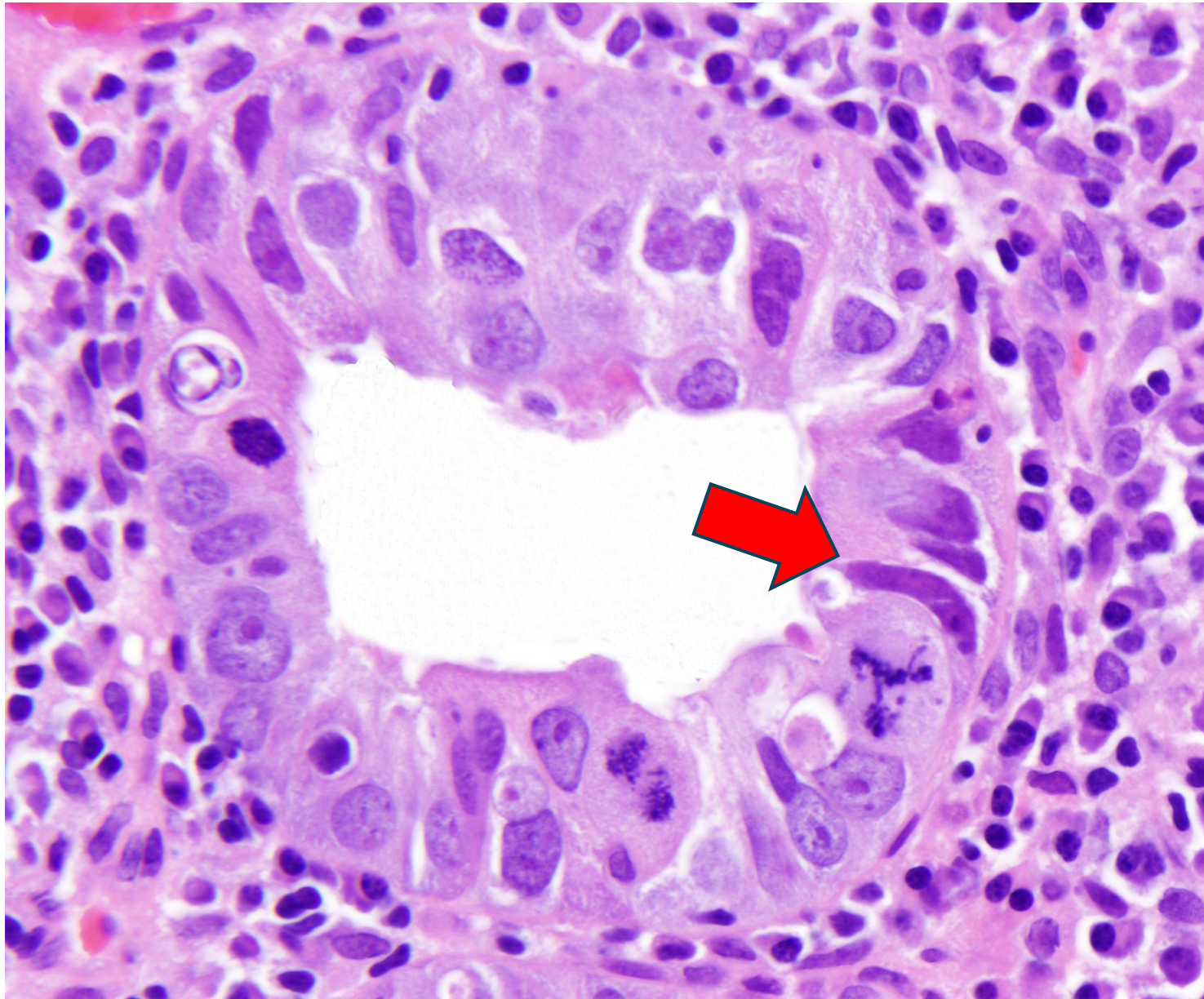

Serous carcinoma –*glandular variant*

High mitotic rate

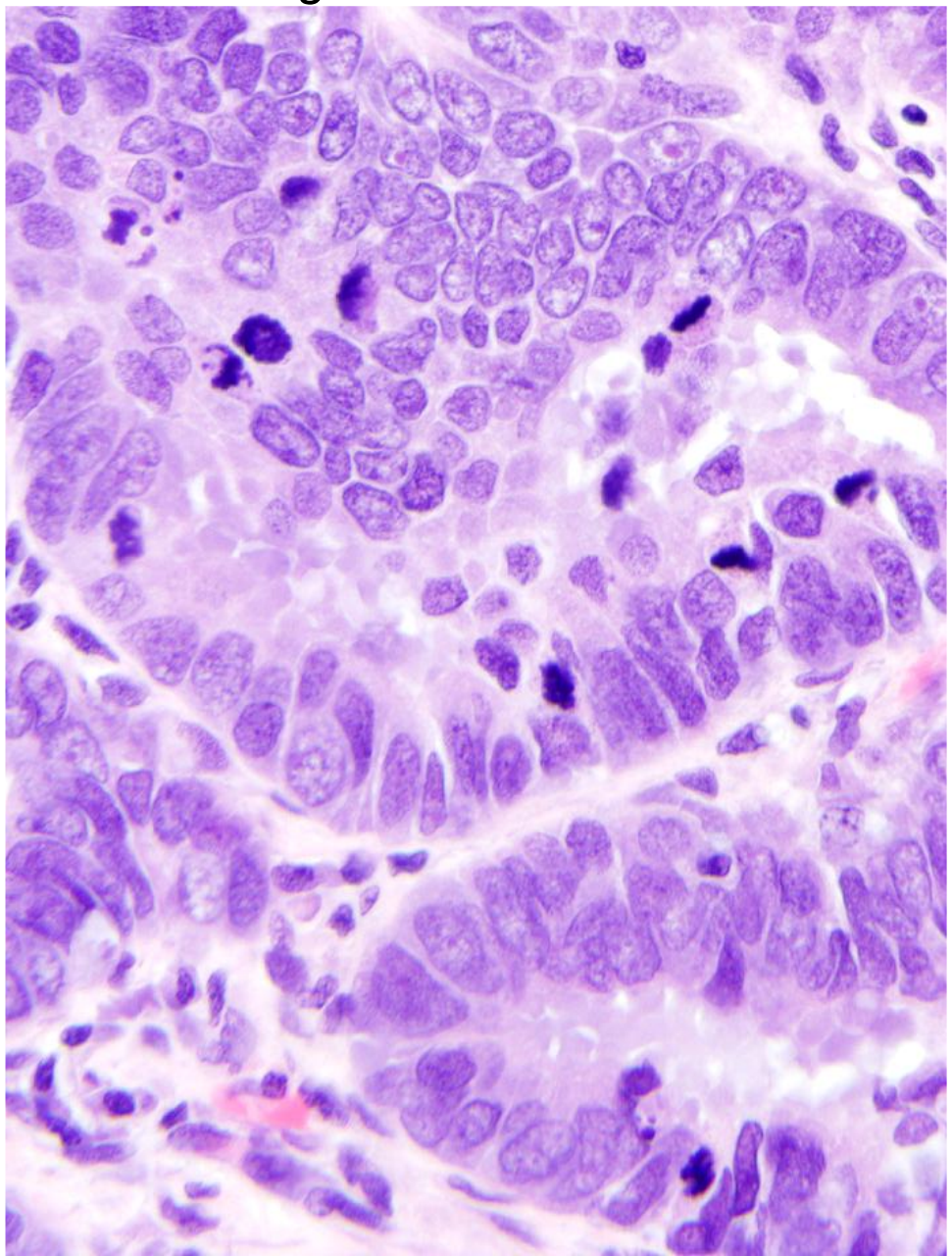

Atypical mitoses

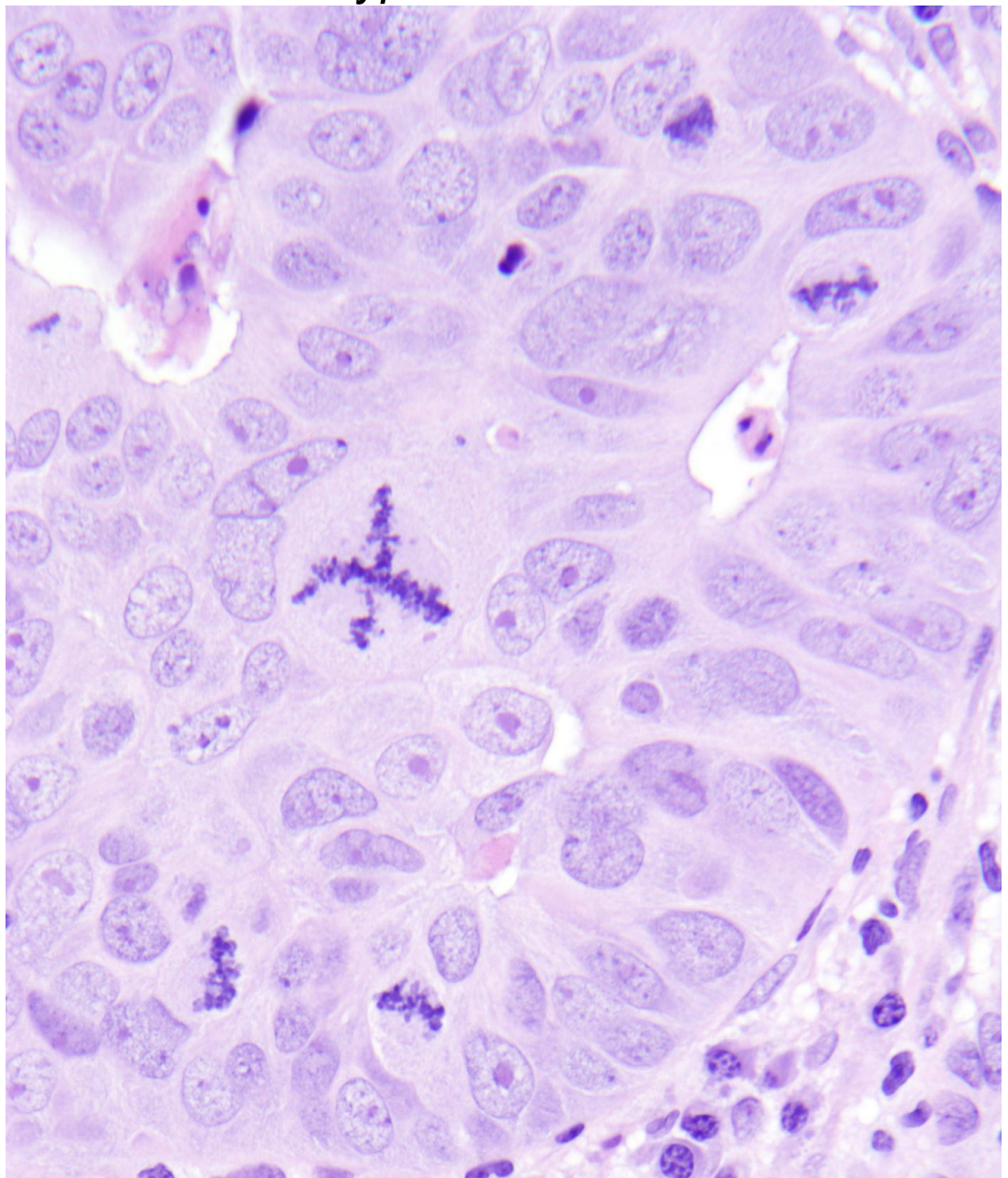

Distinguishing Low Grade Endometrioid versus Glandular Pattern Serous Carcinoma

	Endometrioid Carcinoma Low Grade	Serous Carcinoma Glandular-Pattern
Architectural grade	Low	Low
Nuclear grade	Low	High
p53 IHC	**Wild type pattern**	**Aberrant pattern**

Mesonephric-like Carcinoma of Endometrium

Clinical Significance

Behavior:

- **Aggressive**
- **Median progressive free survival ~ 18 months**
- **Predilection for lung metastasis** (over half of all patients) **and liver metastasis**

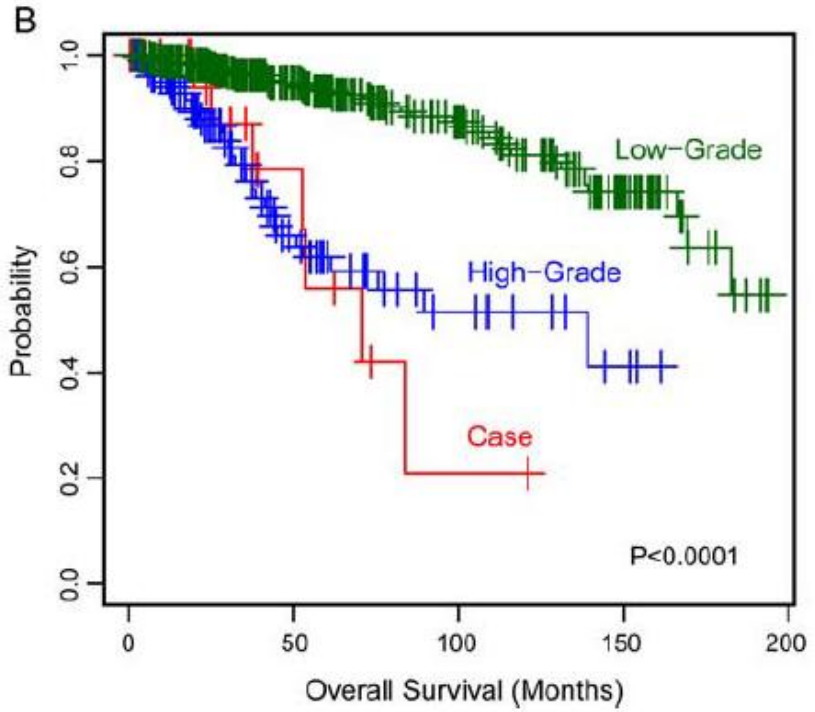

Endometrioid

Serous

Mesonephric-like

From AJSP 2020; 44: 429-443. PMID: 31725471

Mesonephric-like Carcinoma of Endometrium

Architecture

Dominant pattern:
Small glands and tubules with eosinophilic luminal material

Special patterns:
Retiform, papillary, glomeruloid, solid, spindled, sarcomatoid

Mesonephric remnants not observed

Cytology

Moderate nuclear atypia

Vesicular chromatin

Nuclear angles, grooves, overlapping distribution

Cuboidal cells with scant cytoplasm (but can be columnar)
"Blue" appearance at low magnification

Reminiscent of papillary thyroid carcinoma

Mesonephric-like Carcinoma of Endometrium

Mimics grade 1 endometrioid carcinoma

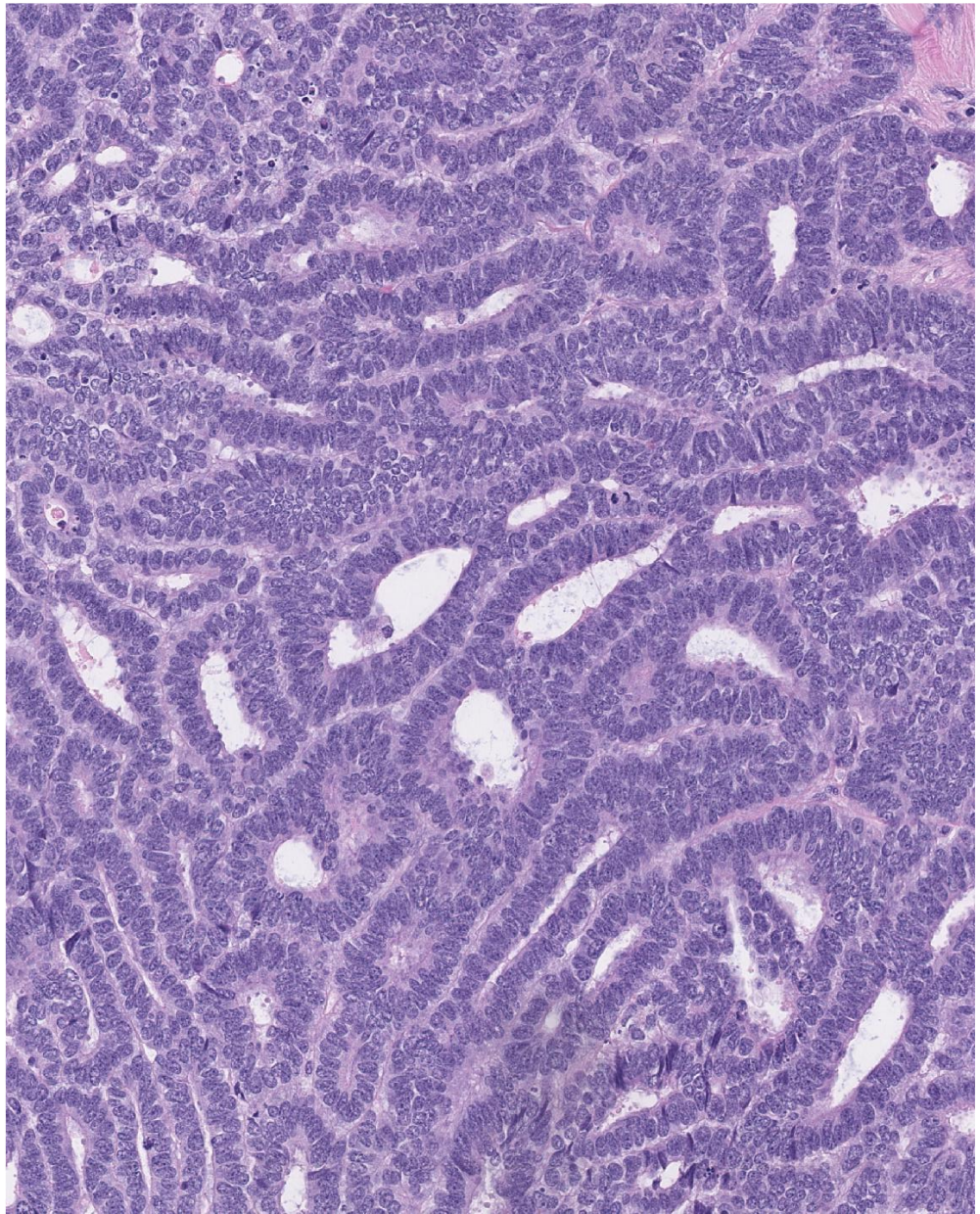

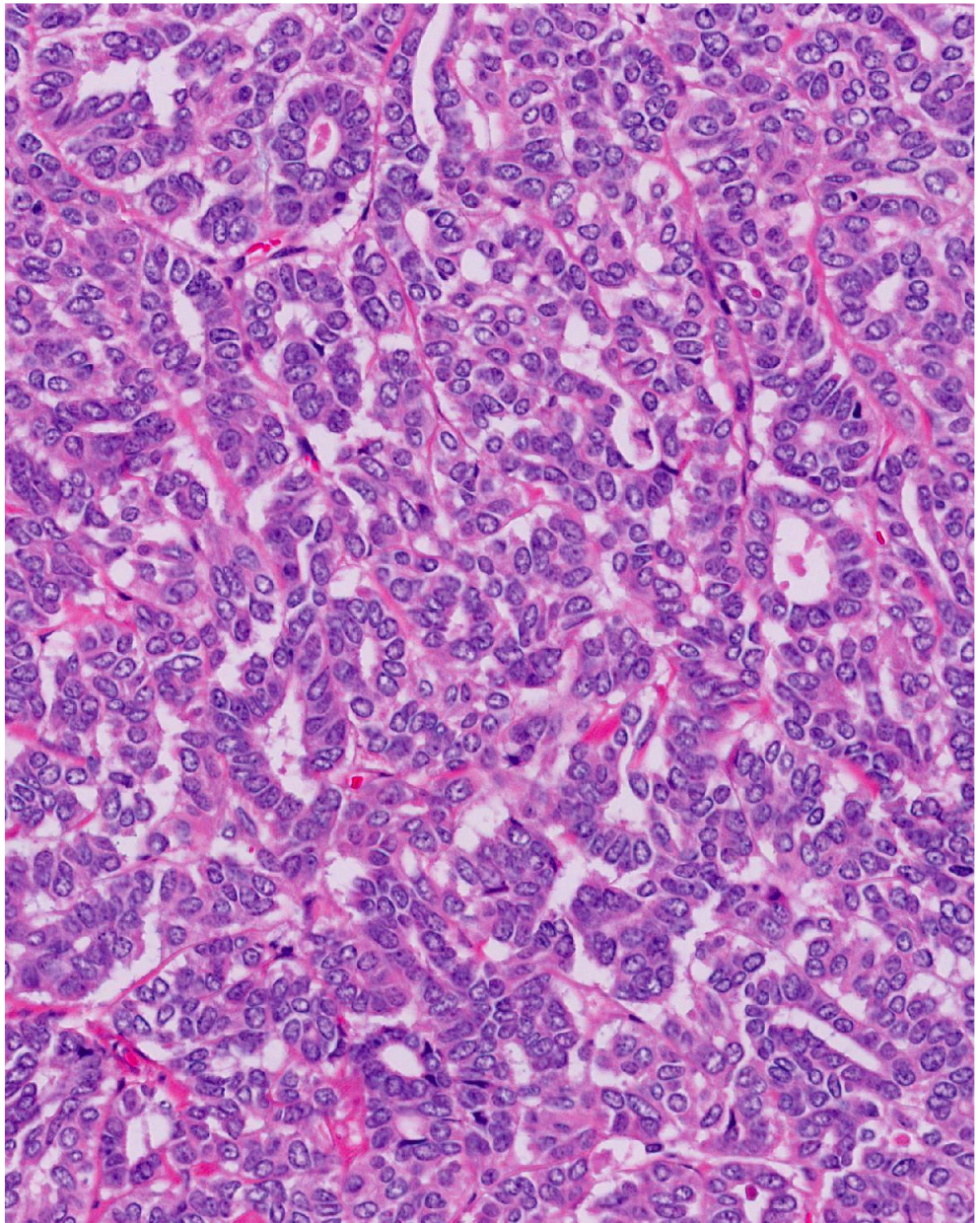

Mesonephric-like Carcinoma of Endometrium

Intraluminal eosinophilic secretions

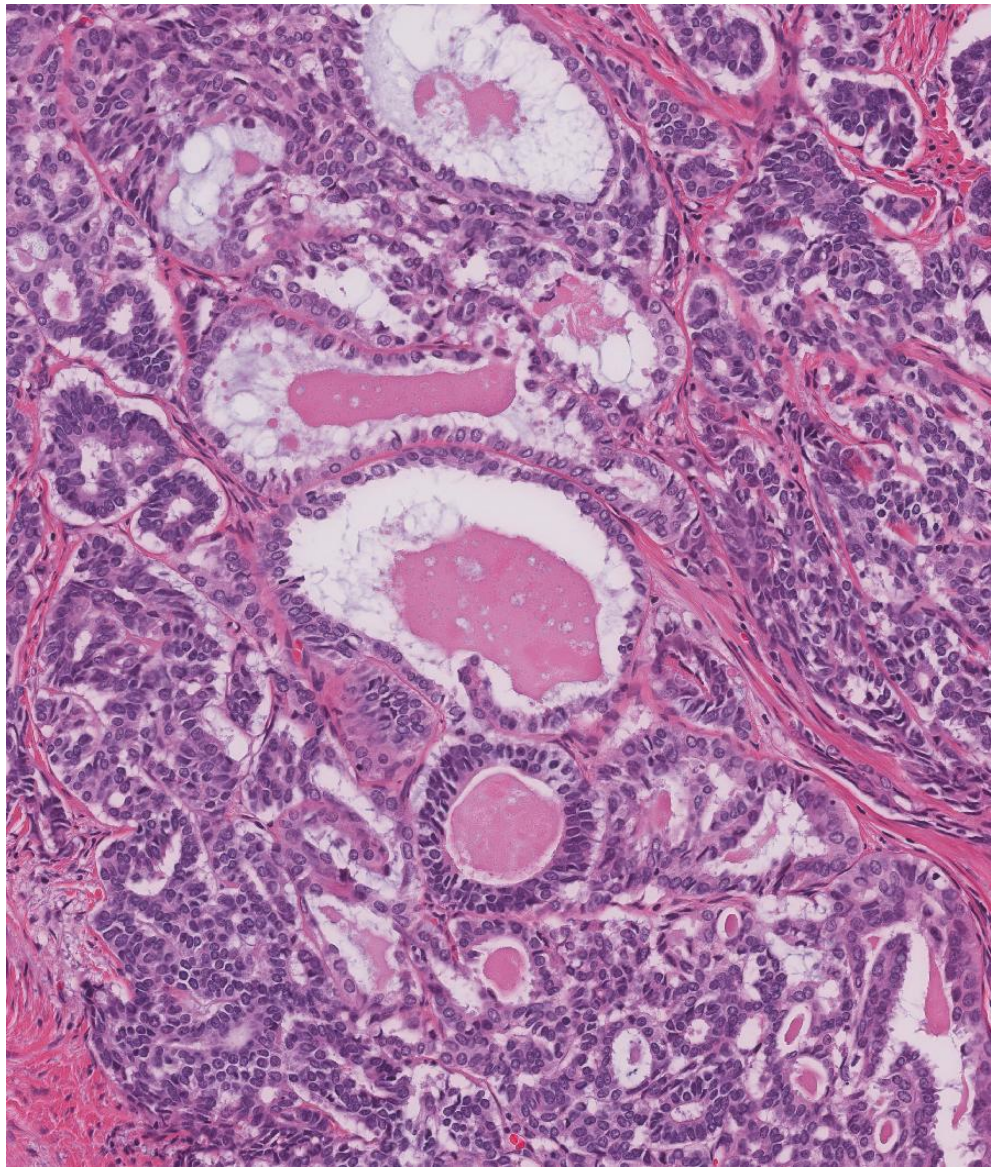

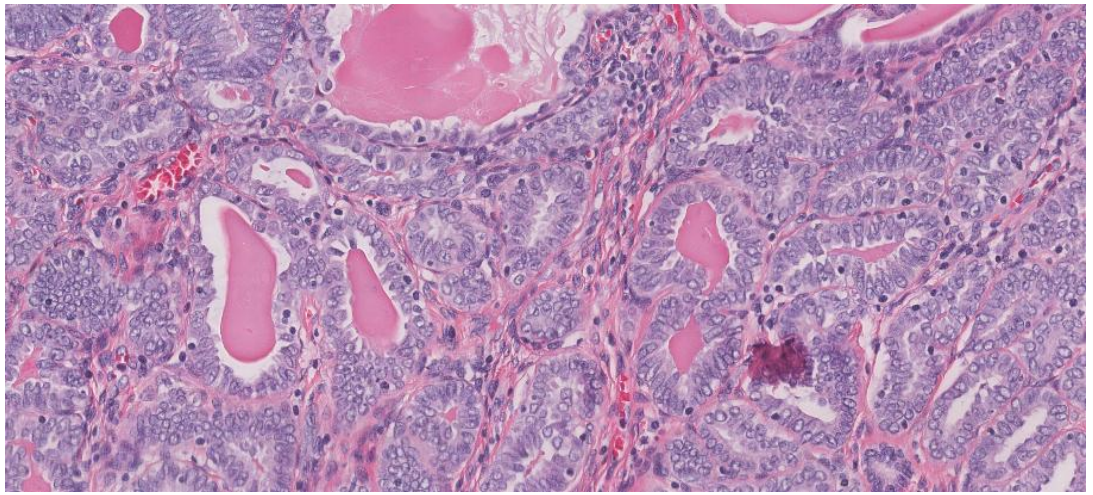

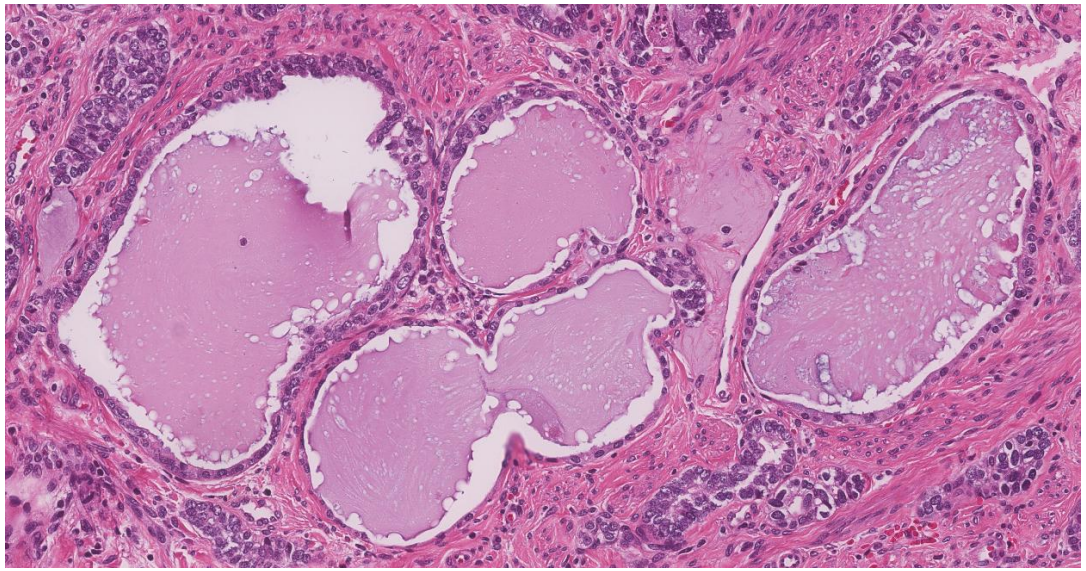

Intraluminal Eosinophilic Secretions

<u>Not</u> pathognomonic for mesonephric differentiation

Endometrial polyp

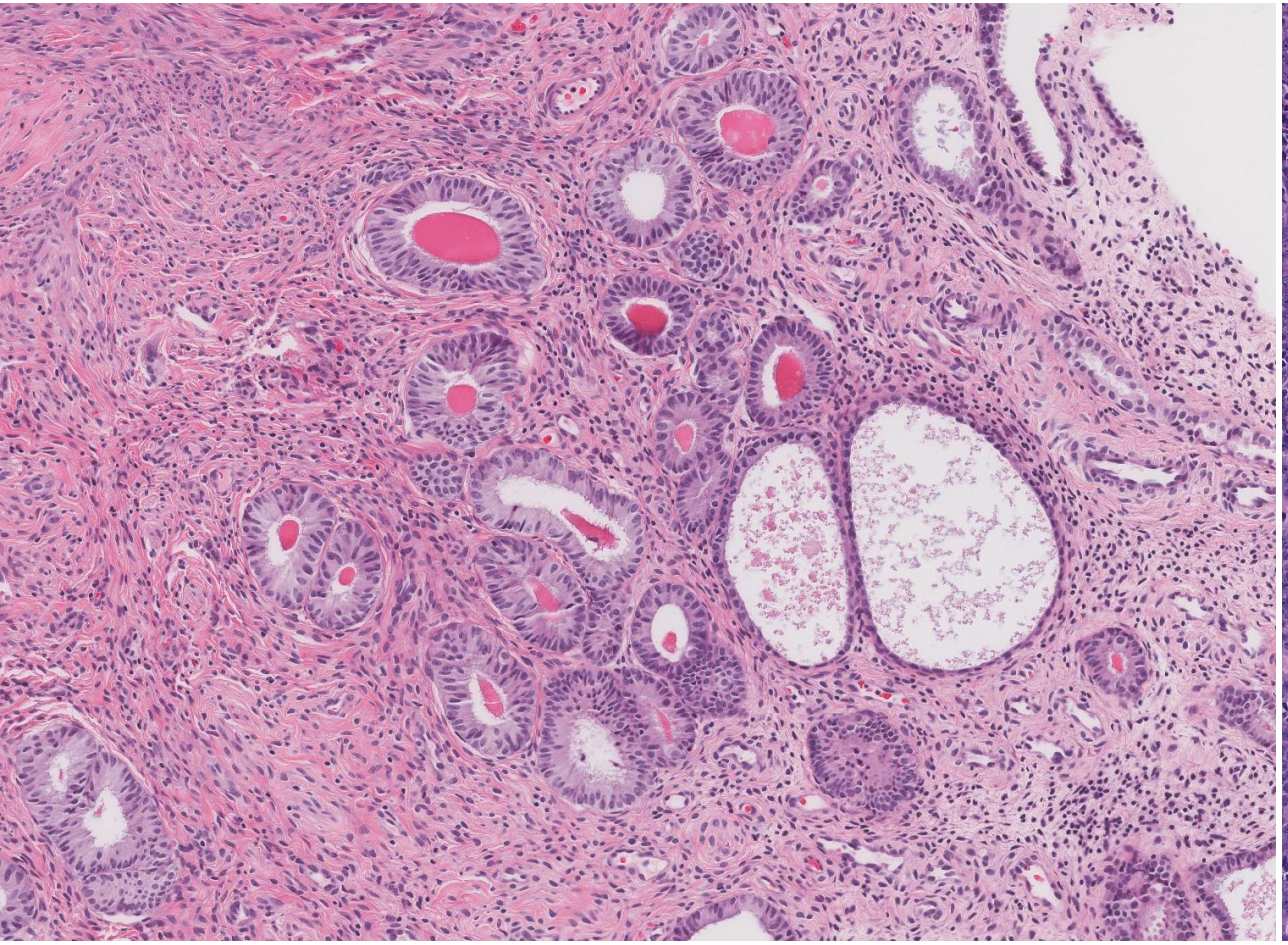

Endometrioid carcinoma

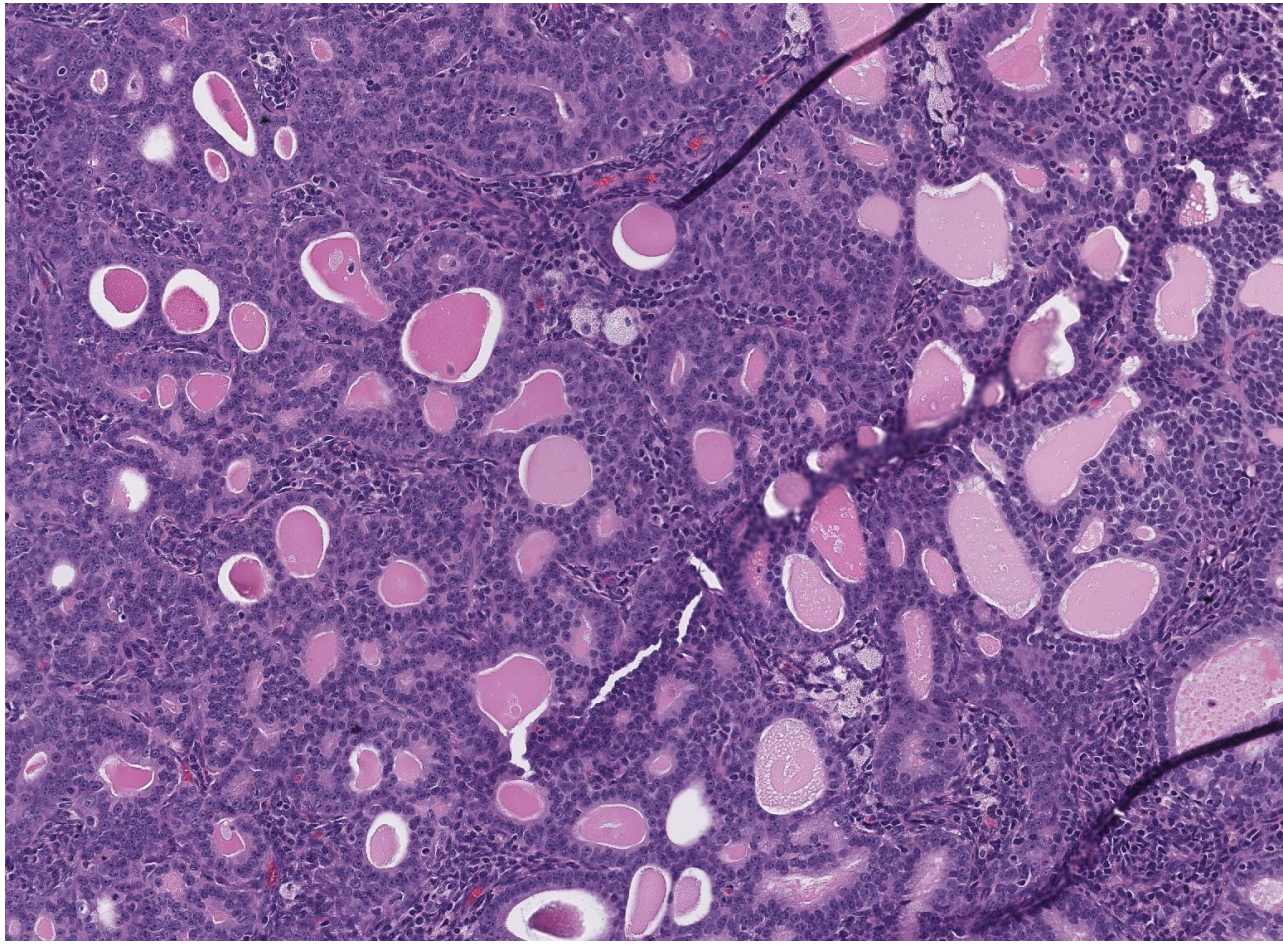

Mesonephric-like Carcinoma of Endometrium

Retiform

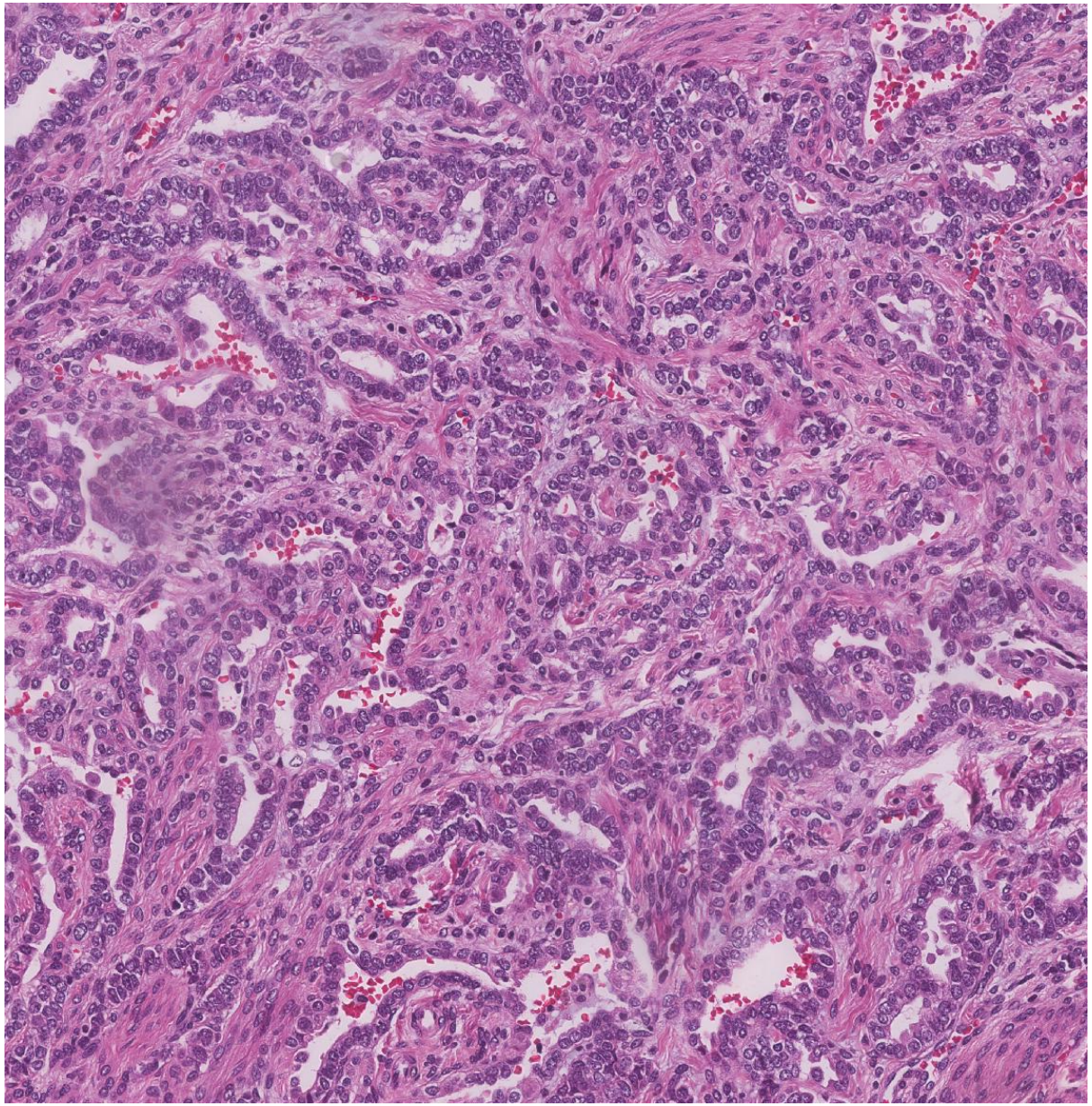

Ductal



Mesonephric-like Carcinoma of Endometrium

Sieve-like

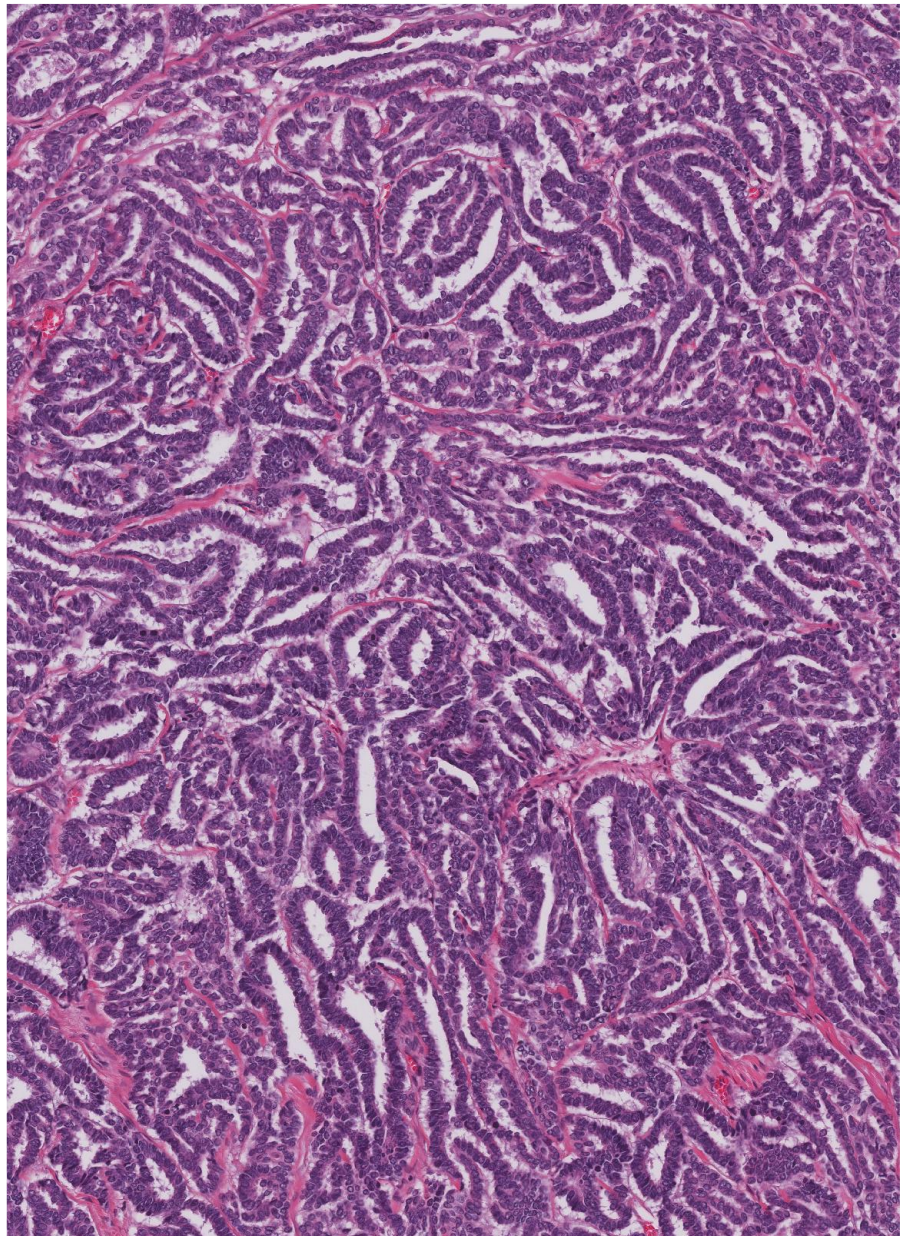

Papillary

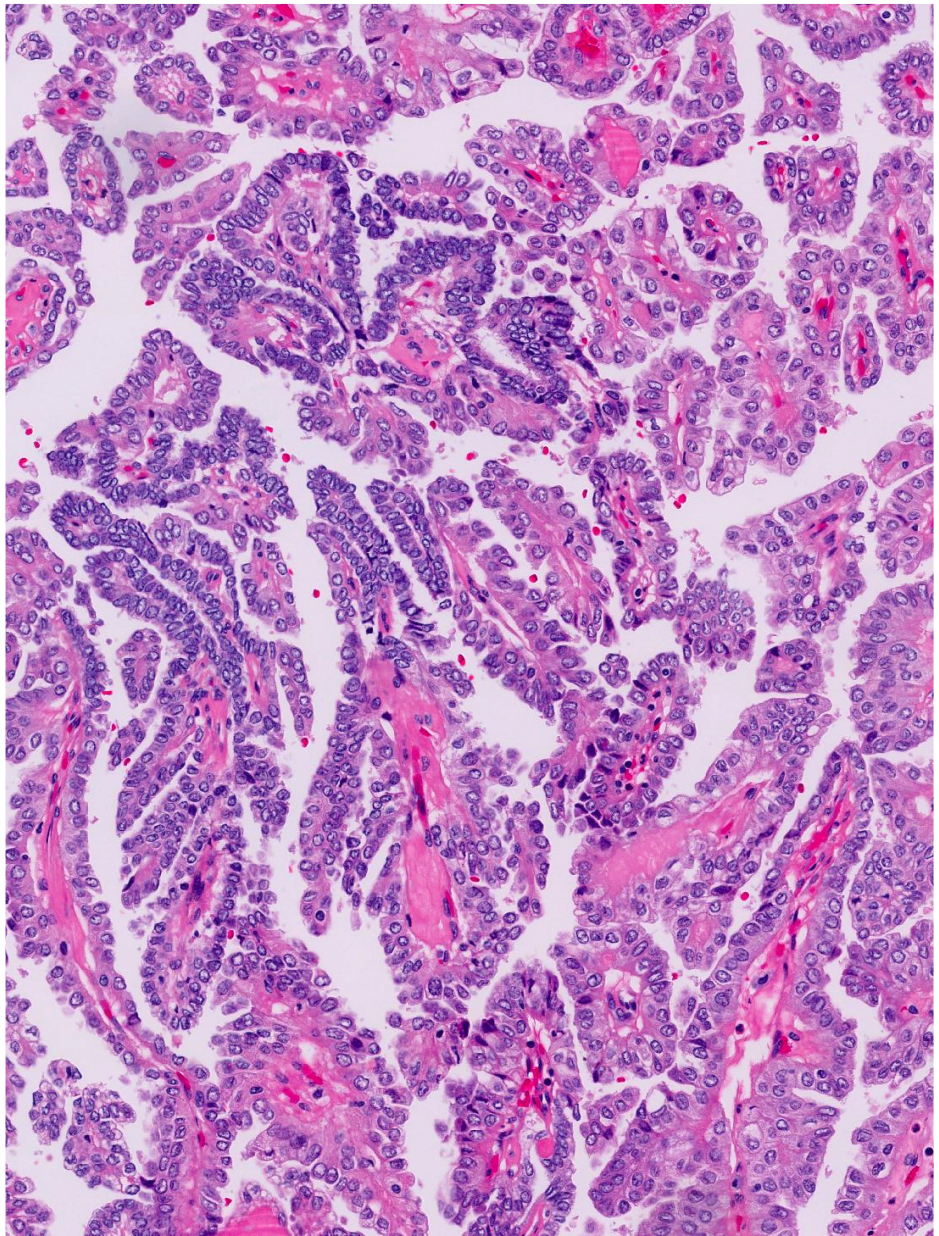

Mesonephric-like Carcinoma of Endometrium

Vesicular chromatin, nuclear grooves

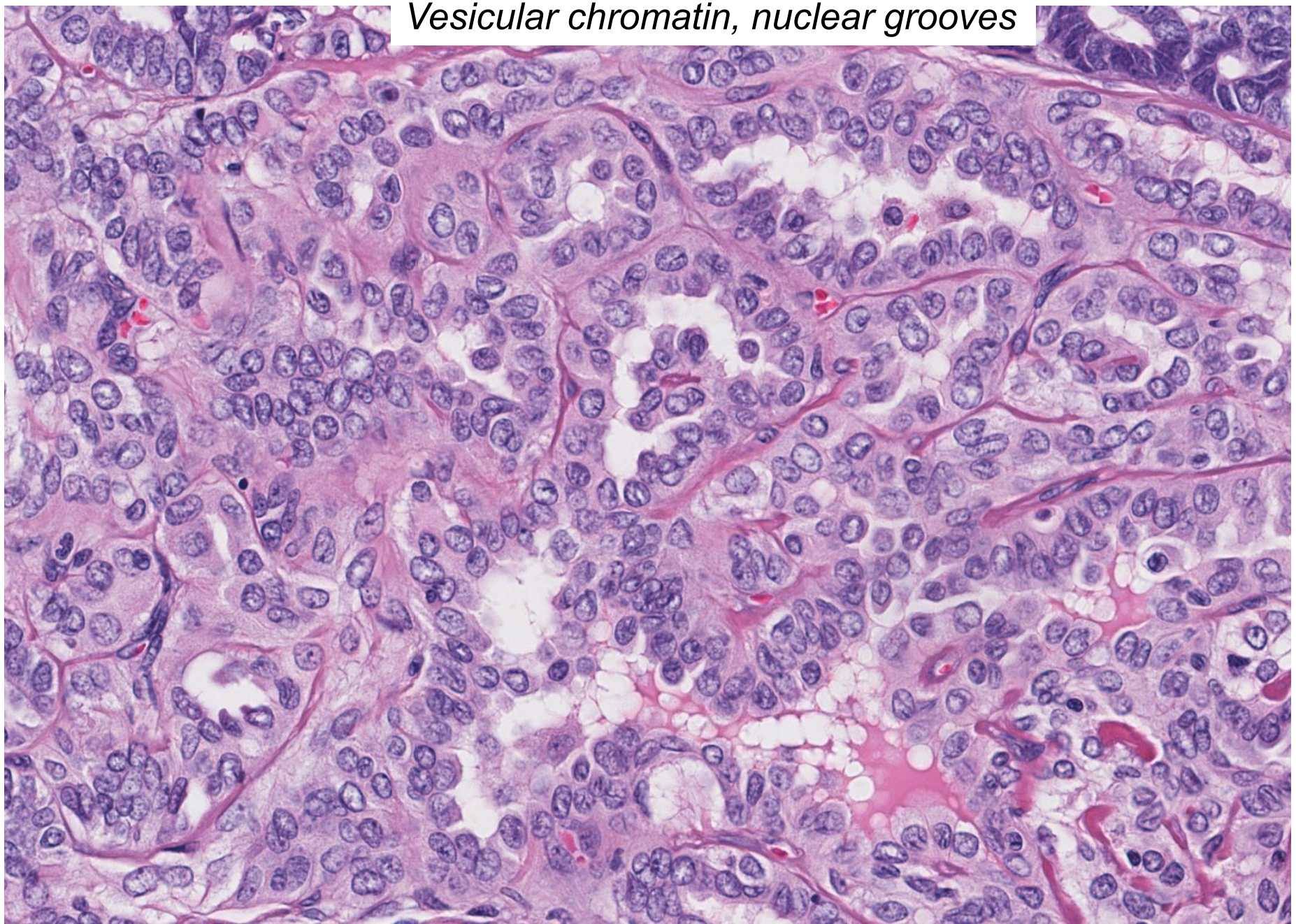

Unique Morphology of Mesonephric-Like Adenocarcinoma of Ovary

Distinct from Endometrioid Carcinoma?

No	Yes	Most Distinctive
Architecture: ▪ Solid ▪ Spindled ▪ Nested ▪ Papillary ▪ Villoglandular	*Architecture*: ▪ "Blue" appearance ▪ Colloid luminal material ▪ Sieve-like ▪ Cribriform/microcystic ▪ Glomeruloid ▪ 3+ patterns	*Architecture*: ▪ "Blue" appearance
Cytology: ▪ Chromatin ▪ Mitotic index ▪ Clear cytoplasm ▪ Cilia ▪ Psammoma bodies	*Cytology*: ▪ Cuboidal shape cells ▪ Scant cytoplasm	*Cytology*: ▪ Cuboidal shape cells ▪ Scant cytoplasm
		Must not show: ▪ Squamous differentiation ▪ Mucinous differentiation

➢ *Practical implication:* **These features should trigger IHC in ovarian "endometrioid" cancers**

PMID: 38970797

Mesonephric-like Carcinoma of Endometrium

Immunohistochemical profile:

Positive	Negative
GATA3	**ER / PR**
TTF1 (inverse of GATA3)	Wild type p53
CD10	MMR intact
Calretinin	
PAX8, CK7	

Molecular profile:

Mutations	
***KRAS* hotspot mutation** (in up to ~90%)	
PTEN	in up to 30%
CTNNB1	
ARID1A	
PIK3CA	
Chromosomal alterations	
1q gain	

Non-specific to histotype

PMIDs:
33772212
37668797
31725471
30489318
33024807
26484981
28984674
29189288
30148742
34829389
31927619
35195579
35732320
35865471

Mesonephric-like Carcinoma of Endometrium

GATA3

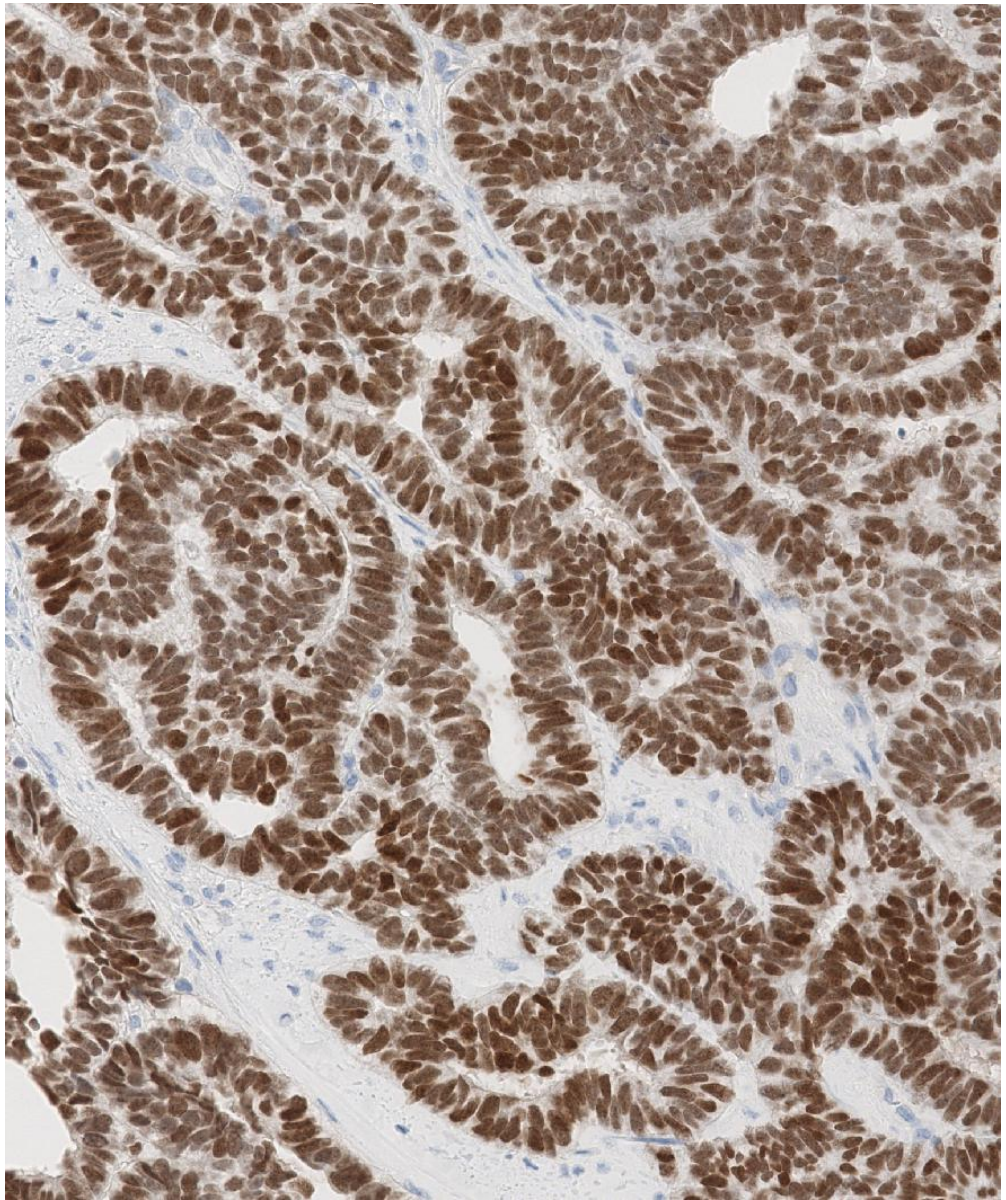

Estrogen Receptor

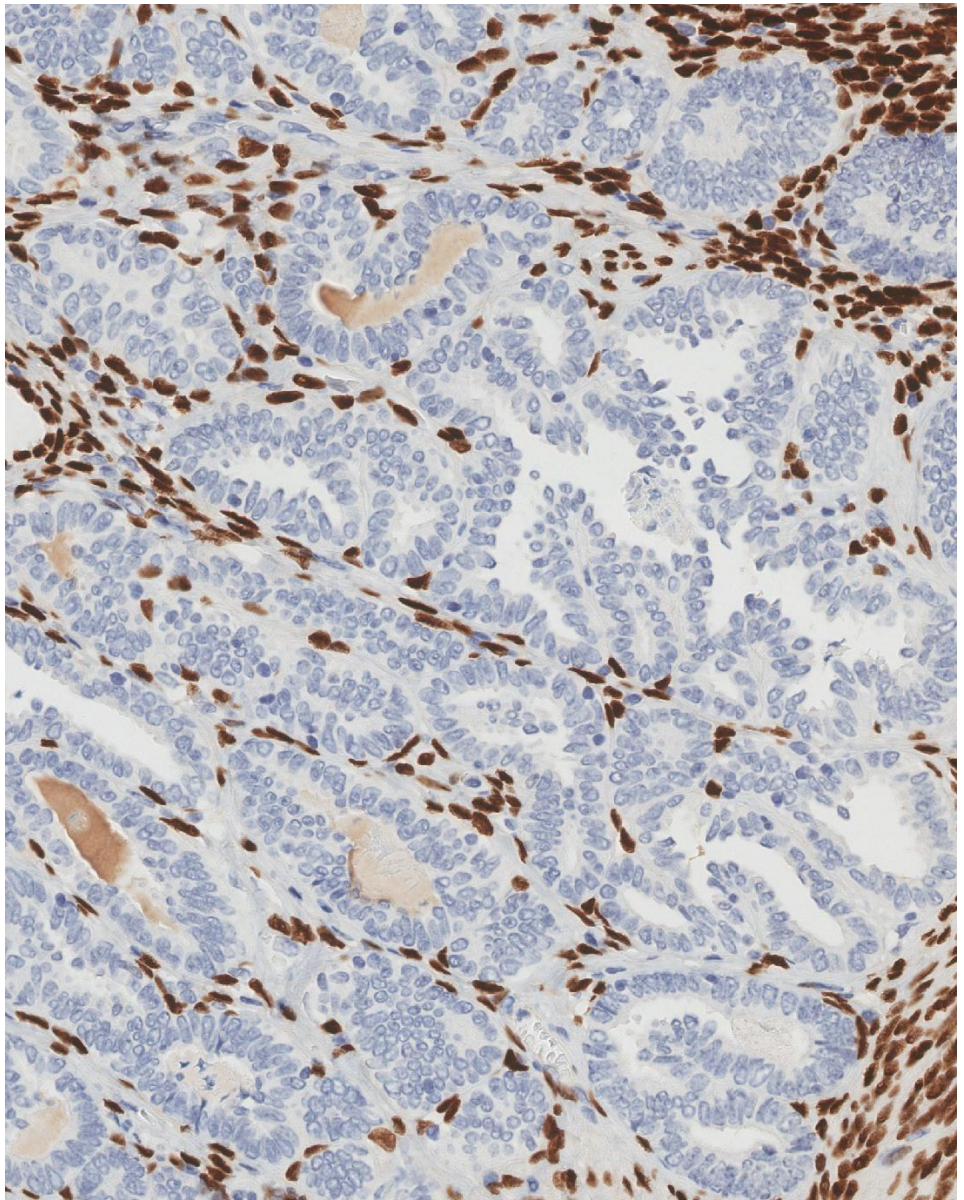

Mesonephric-like Adenocarcinoma versus Low Grade Endometrioid Carcinoma

Overlapping immunophenotype

	GATA3	TTF1	CD10
Mesonephric like adenocarcinoma of endometrium	**Diffuse, strong**	**Patchy**	**Patchy**
Endometrioid carcinoma	Minority: **focal, variable intensity**		

Compare distribution and intensity

Original Article

Comprehensive Immunohistochemical Analysis of Mesonephric Marker Expression in Low-grade Endometrial Endometrioid Carcinoma

Yurimi Lee, M.D., Sangjoon Choi, M.D., and Hyun-Soo Kim, M.D., Ph.D.

PMID: 37566876

Gastric-type Endometrial Cancer

Voluminous pale cytoplasm

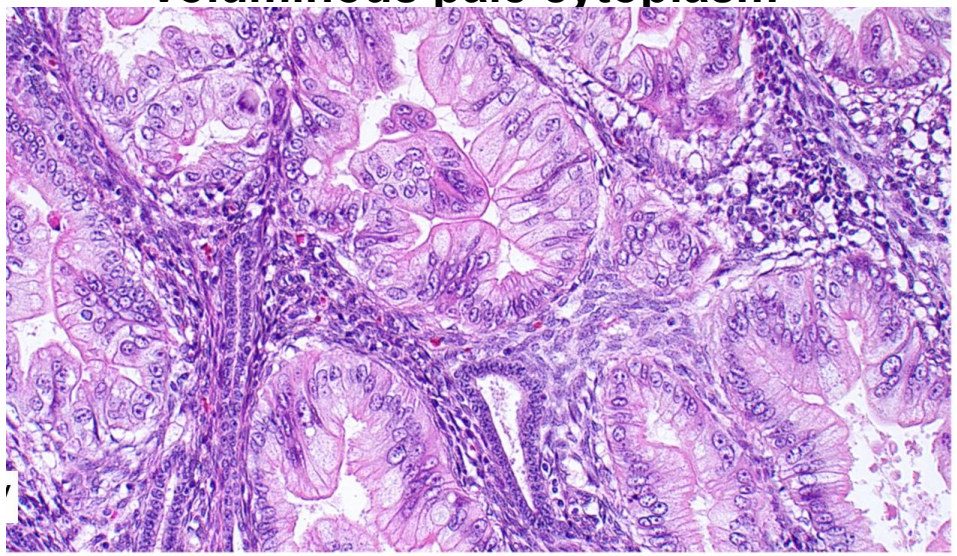

Goblet cells

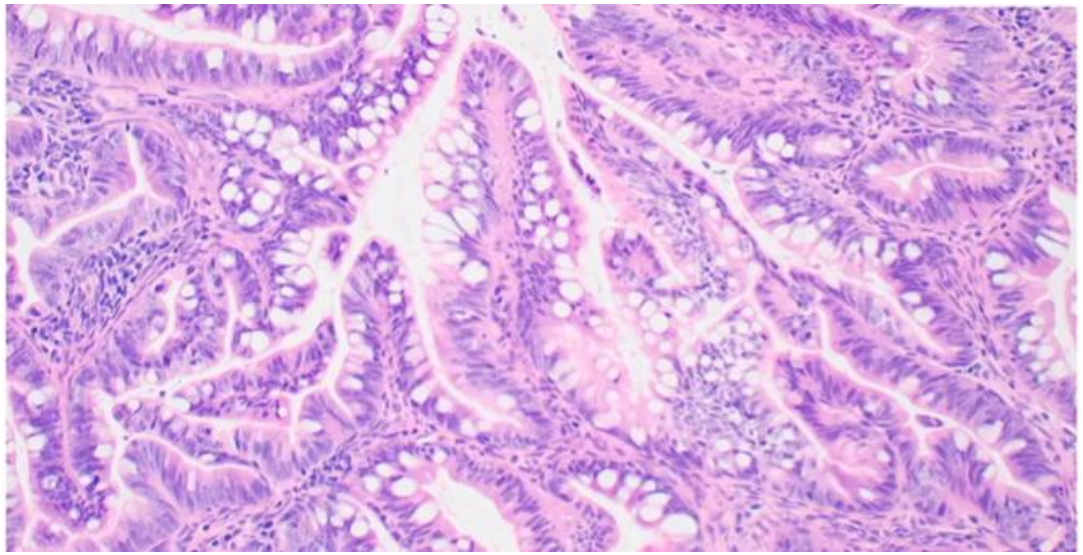

Paneth cells

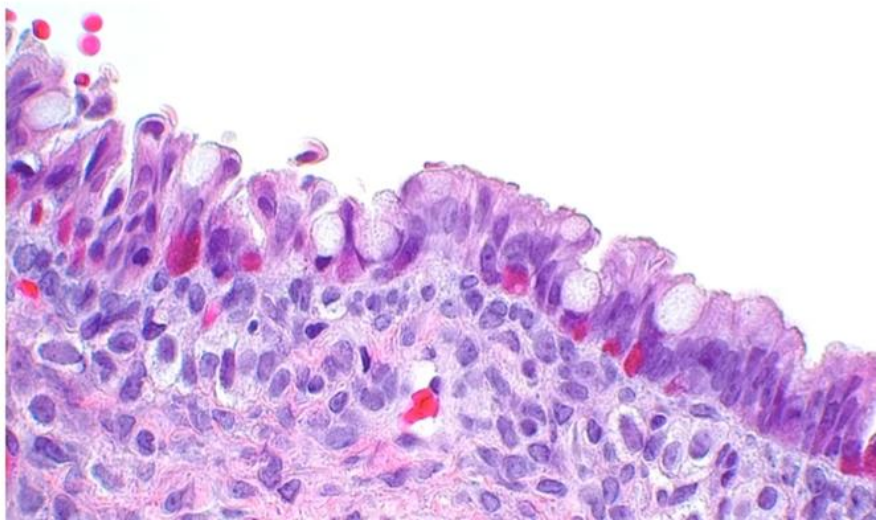

Signet ring cells

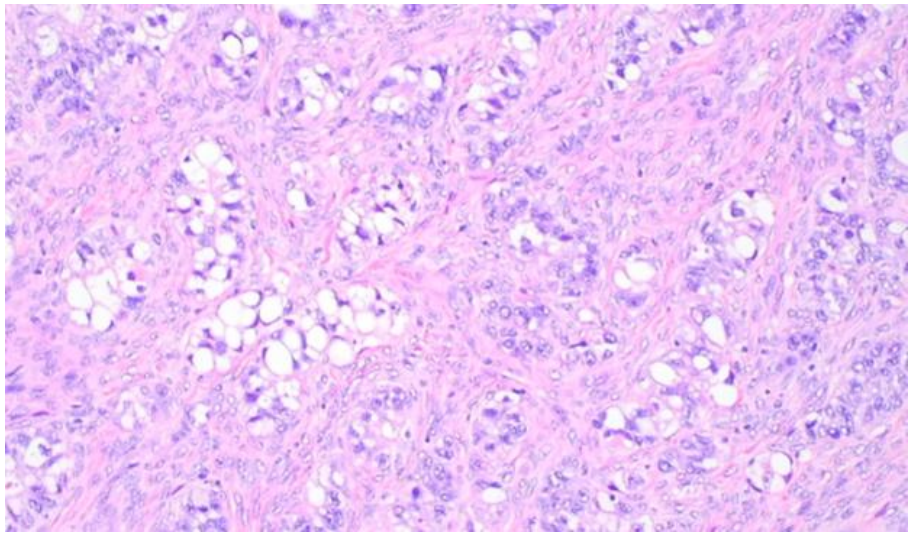

Courtesy of Marisa Nucci MD

Gastric-type Endometrial Cancer

An emerging topic

Immunohistochemistry:

Intestinal Markers	Pattern
Claudin 18	▪ Mostly positive
CK20, CDX2, SATB2	▪ +/-

Mullerian Markers	Pattern
PAX8	▪ +/-
CK7	▪ Mostly positive
ER	▪ Mostly negative

Other Markers	Pattern
p53	Conflicting data: ▪ 1 study: most are aberrant ▪ 1 study: half are aberrant

Molecular alterations:

***TP53* mutation in most cases**

PMID 31567280, 38477341; 40066786

Non-Aggressive versus Aggressive Histotypes

Diagnostic Pitfalls





Low Grade Endometrioid Carcinoma *Morphologic Variant*	High Risk Mimic
Glandular pattern	▪ Glandular pattern serous carcinoma ▪ Mesonephric-like carcinoma ▪ Gastric type carcinoma
***Papillary** pattern*	▪ **Serous carcinoma** ▪ **Clear cell carcinoma** ▪ **Mesonephric-like carcinoma**

Papillary Variants of Grade 1 Endometrioid Carcinoma

Mimic serous carcinoma

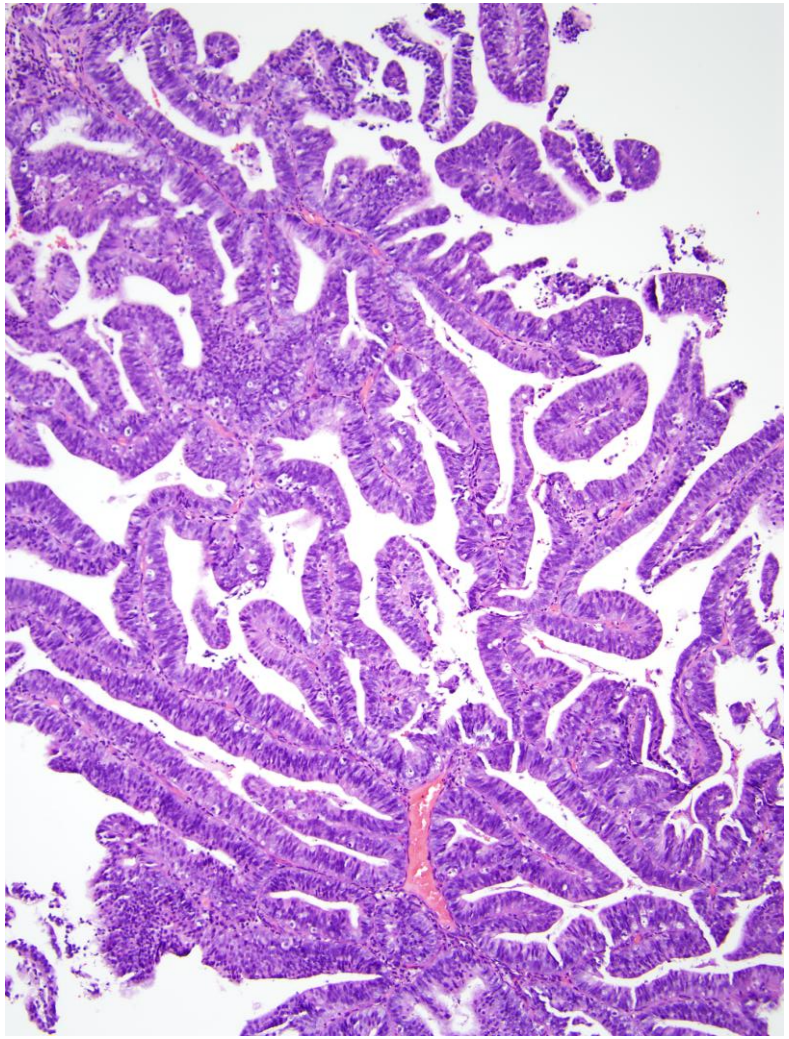

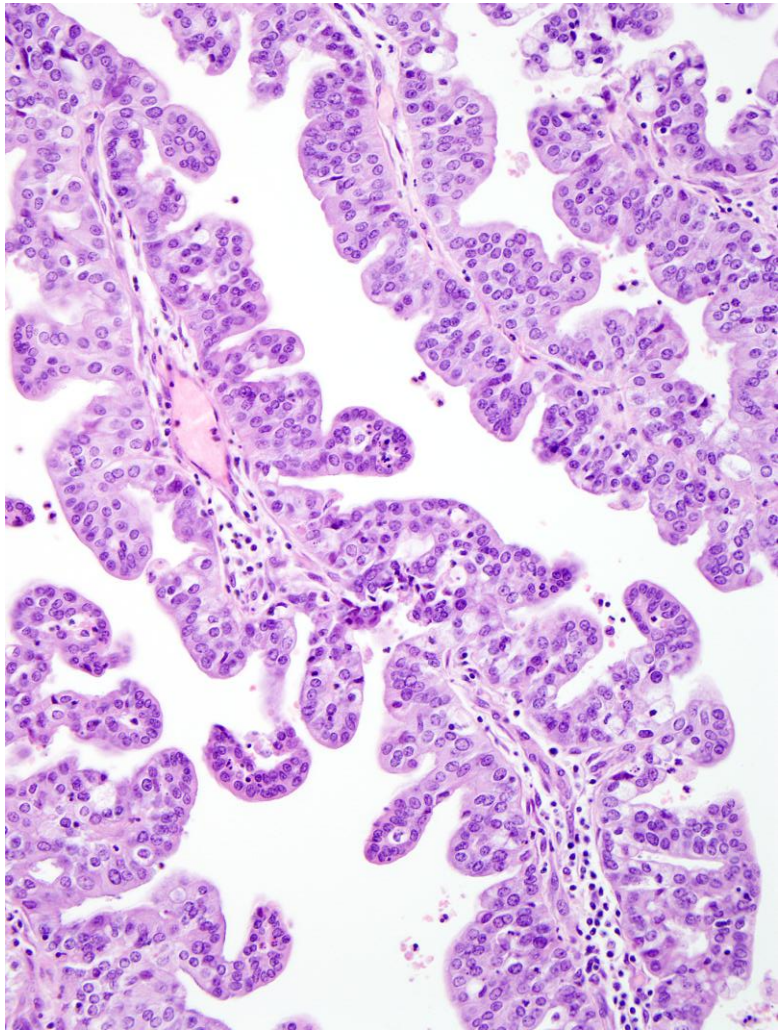

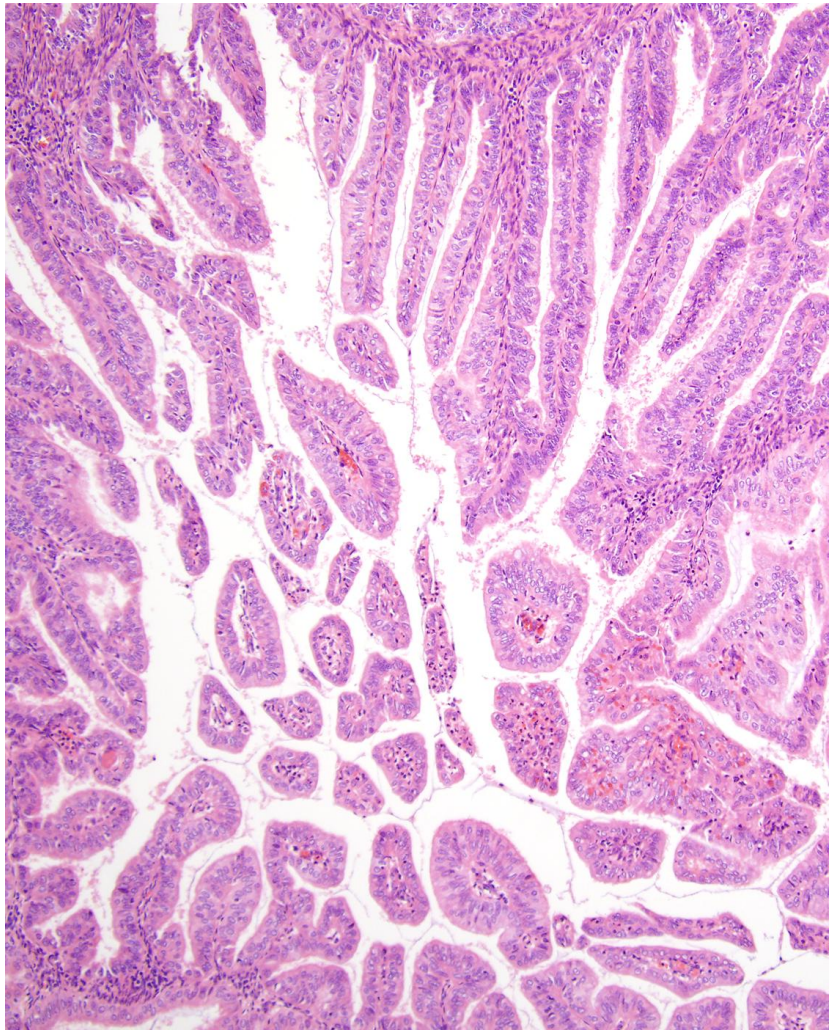

Non-Aggressive versus Aggressive Histotypes

Diagnostic Pitfalls





Low Grade Endometrioid Carcinoma *Morphologic Variant*	High Risk Mimic
Glandular pattern	▪ Glandular pattern serous carcinoma ▪ Mesonephric-like carcinoma ▪ Gastric type carcinoma
Papillary pattern	▪ Serous carcinoma ▪ Clear cell carcinoma ▪ Mesonephric-like carcinoma
Minor solid component *(grade 2)*	▪ **Dedifferentiated carcinoma**

Dedifferentiated Endometrial Carcinoma

Mimics grade 1 or 2 endometrioid carcinoma

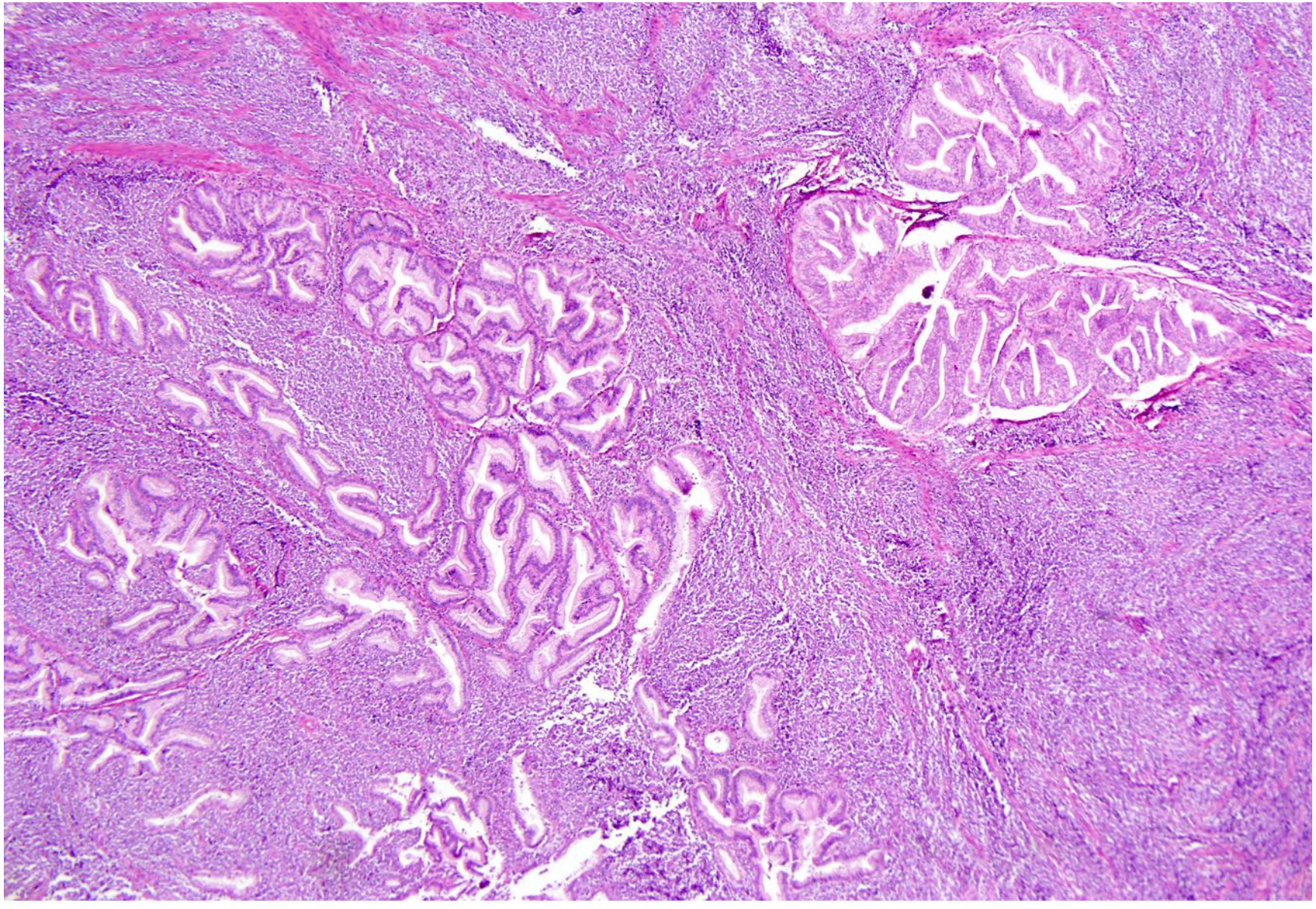

Dedifferentiated Endometrial Carcinoma

Undifferentiated component

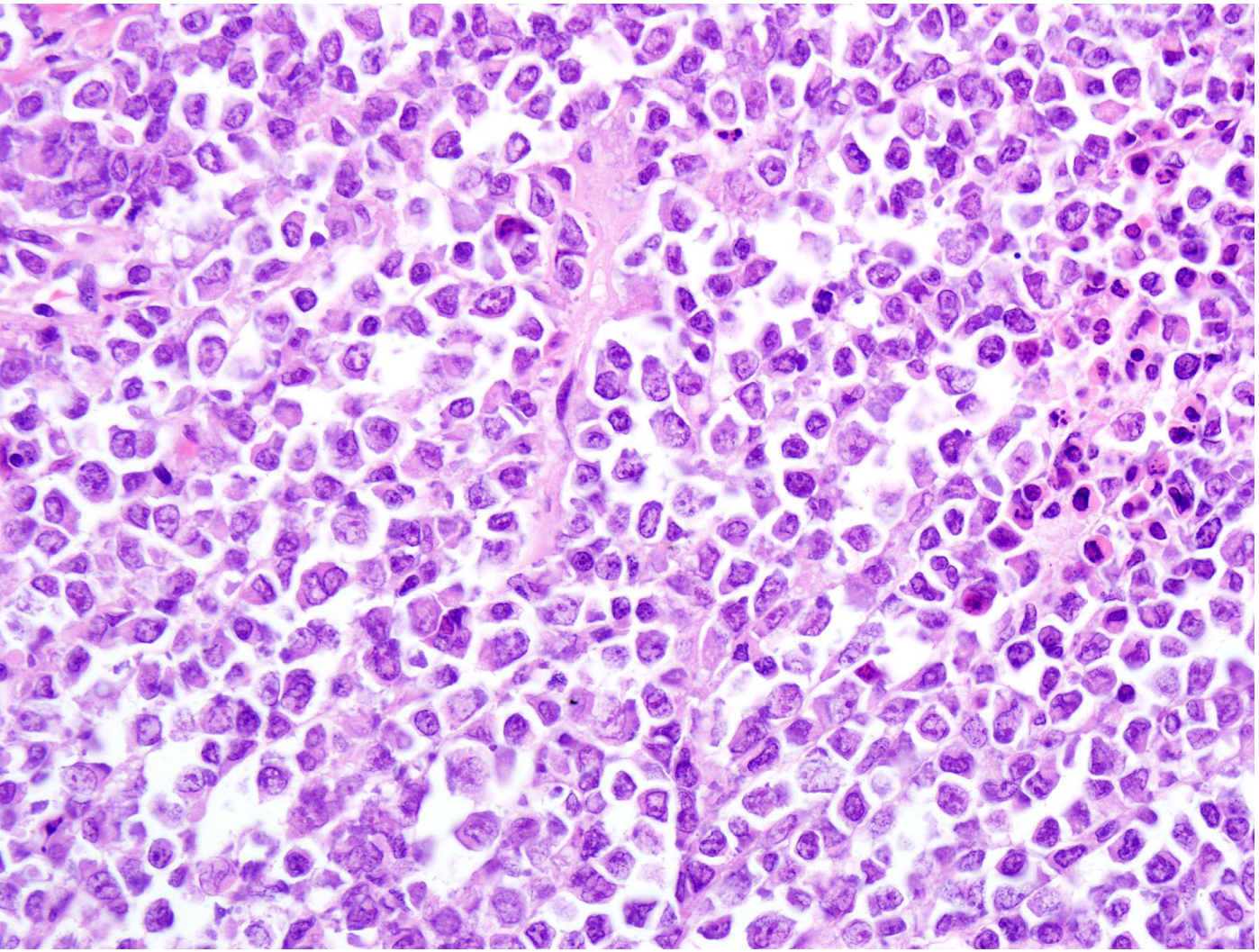

Architecture
Discohesive, sheet-like growth
Corded growth within myxoid stroma
Geographic necrosis

Cytology
Monomorphic tumor cells
Limited nuclear atypia / mitoses
+/- Rhabdoid cytology

Non-Aggressive versus Aggressive Histotypes

Diagnostic Pitfalls





Low Grade Endometrioid Carcinoma *Morphologic Variant*	High Risk Mimic
Glandular pattern	▪ Glandular pattern serous carcinoma ▪ Mesonephric-like carcinoma ▪ Gastric type carcinoma
Papillary pattern	▪ Serous carcinoma ▪ Clear cell carcinoma ▪ Mesonephric-like carcinoma
Minor solid component (grade 2)	▪ Dedifferentiated carcinoma
***Clear cell rich** pattern*	▪ **Clear cell carcinoma**

Non-Aggressive versus Aggressive Histotypes

Diagnostic Pitfalls





Low Grade Endometrioid Carcinoma *Morphologic Variant*	High Risk Mimic
Glandular pattern	▪ Glandular pattern serous carcinoma ▪ Mesonephric-like carcinoma ▪ Gastric type carcinoma
Papillary pattern	▪ Serous carcinoma ▪ Clear cell carcinoma ▪ Mesonephric-like carcinoma
Minor solid component (grade 2)	▪ Dedifferentiated carcinoma
Clear cell rich pattern	▪ Clear cell carcinoma
***Spindled / Corded and hyalinized** pattern*	▪ **Carcinosarcoma**

Universal ER and p53 to Identify Aggressive Mimics of Low Grade Endometrioid Carcinoma

Results must be integrated with morphology for tumor typing

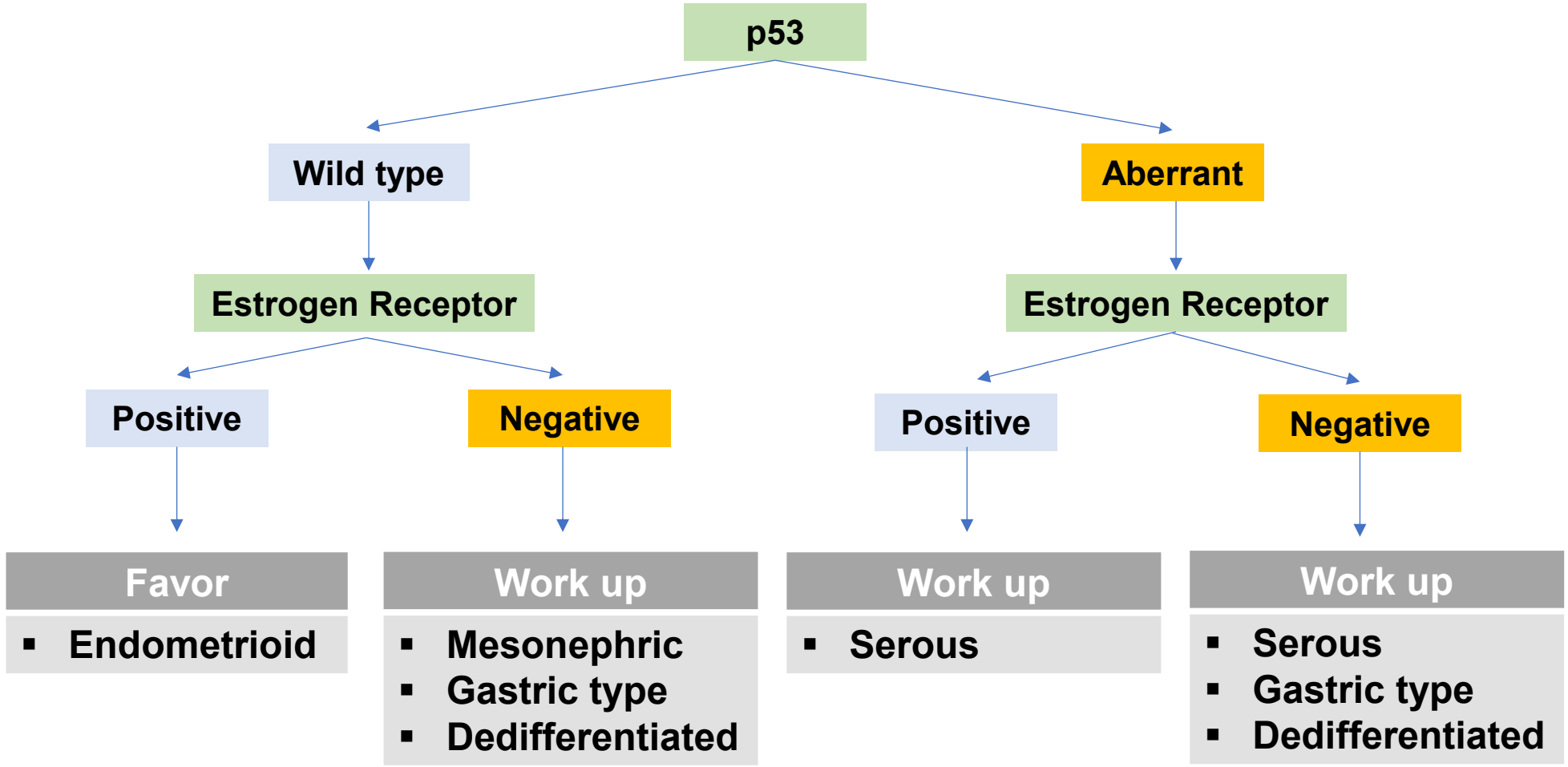

Outline of Talk

- Overview of FIGO 2023 staging system for endometrial cancer
- **Practical approach to potentially challenging "new" staging variables**

Stage I/II

- Aggressive mimics of non-aggressive histotypes
- **Quantifying lymphovascular space invasion**

Relevance of Lymphovascular Space Invasion

- **~10-15% in all endometrial cancers**
- **Predicts recurrence in early stage endometrioid carcinoma**
  - *Criteria to consider radiation therapy*

National Comprehensive Cancer Network®

NCCN Guidelines Version 3.2025
Endometrial Carcinoma

NCCN Guidelines Index
Table of Contents
Discussion

All staging in guideline is based on 2009 FIGO staging. (ST-1)

CLINICAL FINDINGS (Endometrioid Histology)[a]

HISTOLOGIC GRADE/ADJUVANT TREATMENT[g,h,m]

Surgically staged: Stage I[e] →

FIGO Stage	Histologic Grade	Adjuvant Treatment
IA	G1, G2	Observation preferred or Consider vaginal brachytherapy if lymphovascular space invasion (LVSI) and/or age ≥60 y[n]
	G3	Vaginal brachytherapy preferred or Consider observation if no myoinvasion or Consider EBRT if either age ≥70 y or LVSI (category 2B)
IB	G1	Vaginal brachytherapy preferred or Consider observation if age <60 y and no LVSI
	G2	Vaginal brachytherapy preferred or Consider EBRT if ≥60 y and/or LVSI or Consider observation if age <60 y and no LVSI
	G3	RT (EBRT and/or vaginal brachytherapy) ± systemic therapy (category 2B for systemic therapy)

LVSI in FIGO 2023 Endometrial Cancer Staging

- **Quantifying LVSI is a new staging criteria**

Three-tier system
None
Focal
Substantial

- **Quantifying LVSI affects staging of grade 1/2 endometrioid carcinoma** (not POLE or p53 abn)

Scenario	+ Substantial LVSI
Potential stage IA, IB, IIA (uterus confined)	**Increase to stage IIB**
Potential stage IA3 (confined to endometrium and ovary)	**Increase to stage IIIA**

LVSI in FIGO 2023 Endometrial Cancer Staging

- **LVSI has <u>no</u> effect on staging if:**

  - **Aggressive tumor histology**
  - **Stage IIC or higher stage**
  - **Molecular class *POLE* or p53abn**

Though evidence shows there is some prognostic value of LVSI.
PMID: 34392268, 35264314

PMID 37666529

LVSI in FIGO 2023 Endometrial Cancer Staging

- LVSI has no effect on staging if:
  - Aggressive tumor histology
  - Stage IIC or higher stage
  - Molecular class *POLE* or p53abn

Though evidence shows there is some prognostic value of LVSI.
PMID: 34392268, 35264314

PMID 37666529

Quantifying LVSI is a core variable for all endometrial cancers (all histotypes, grades, stages) **in CAP 2025 and ICCR reporting templates**

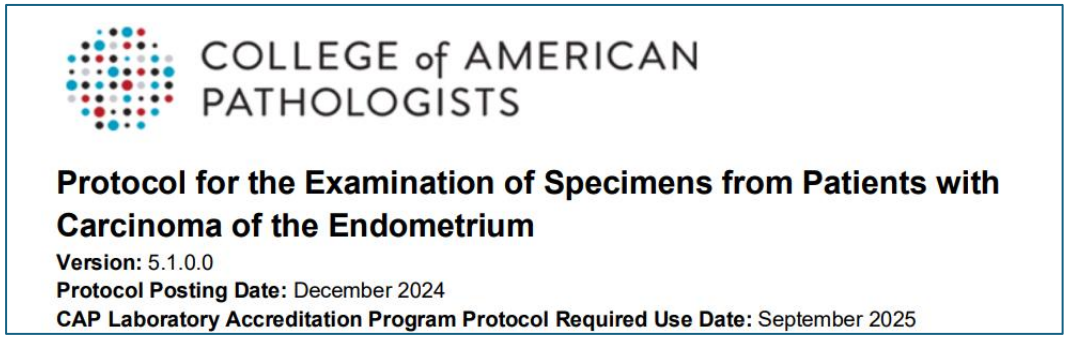
COLLEGE of AMERICAN PATHOLOGISTS

Protocol for the Examination of Specimens from Patients with Carcinoma of the Endometrium

Version: 5.1.0.0
Protocol Posting Date: December 2024
CAP Laboratory Accreditation Program Protocol Required Use Date: September 2025



LVSI in FIGO 2023 Endometrial Cancer Staging

- **Definition of LVSI**

Presence of viable tumor in endothelium-lined spaces

Absence of artifactual displacement as the cause

→ **Focal**

→ **Substantial**

- **No difference between tumor in lymphatic versus blood vessel space for FIGO 2023 staging**

Some evidence of prognostic value but not relevant for staging PMID: 19207942

Tumor molds to contour of vessel

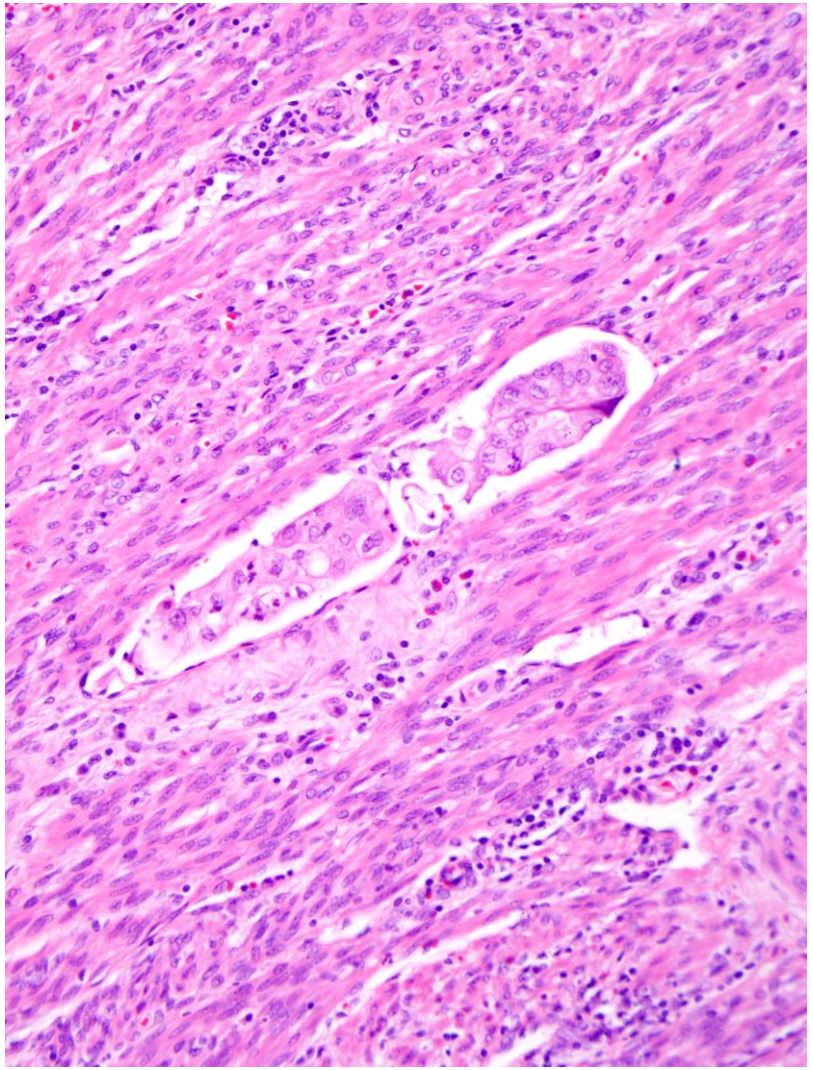

Lymphoid aggregate next to vessels

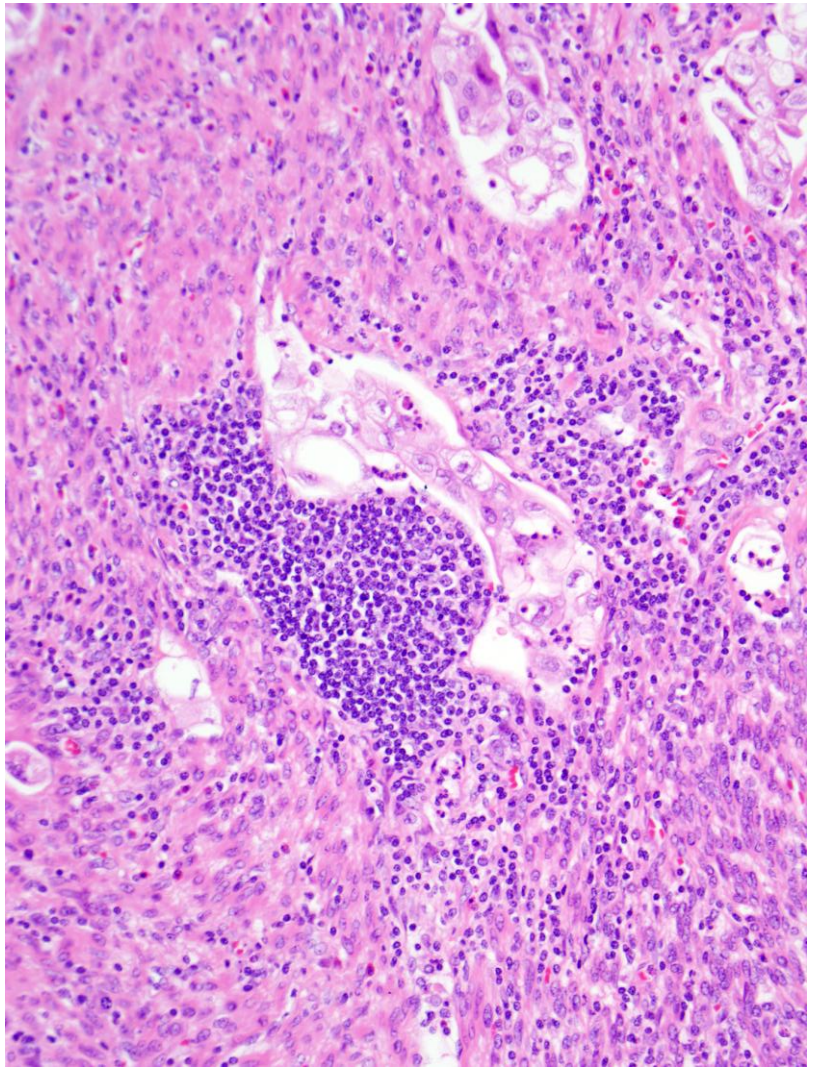

Lymphatics near arteries

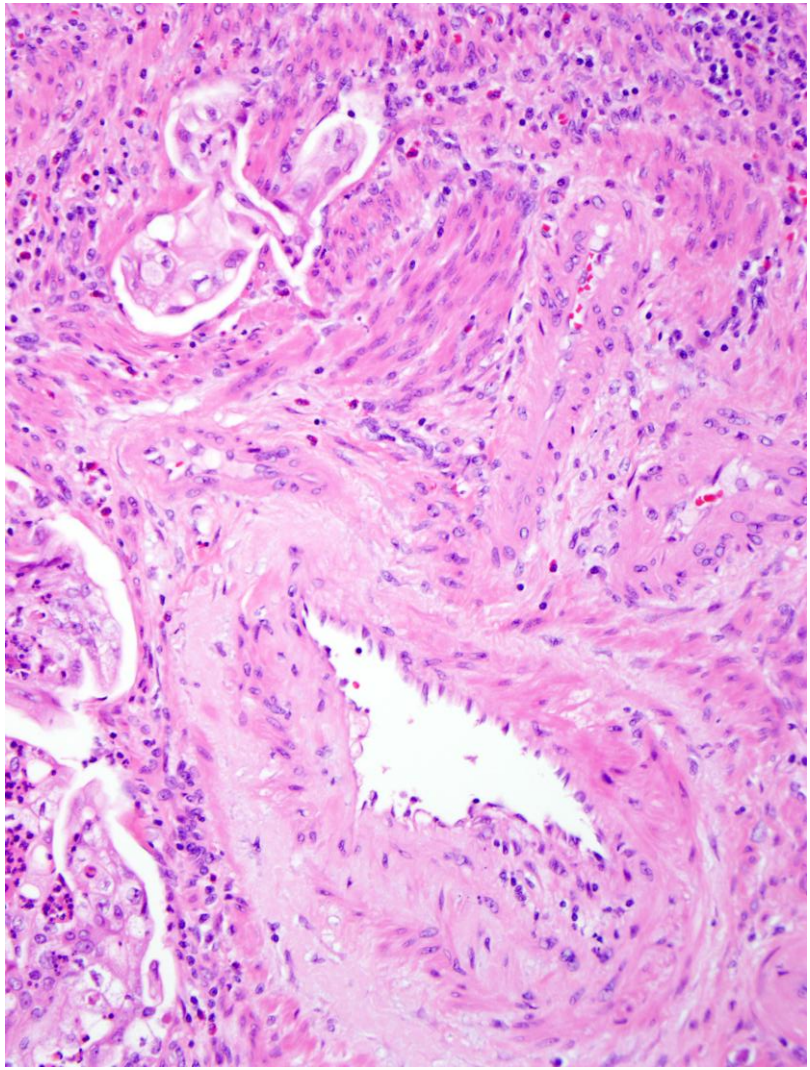

Quantifying LVSI

Clinical significance of quantification (“focal” versus “substantive” rather than “absent” versus “present”)

Substantial LVSI
▪ **Higher risk of** **-lymph node involvement** **-pelvic recurrence** **-distant metastasis**
▪ **Worse prognosis**

PMID 26049688, 19062082, 33470061, 33217679, 10570436, 28709703, 40055122

Quantifying LVSI

FIGO 2023 uses the 5th edition WHO Definition

# of Vessels with Tumor	LVSI Classification
0	None
1 to 4	Focal
5 or more	Substantial

Limitations:

- Consensus-based definition
- Criteria for counting vessels vague
- Reproducibility is imperfect

Quantifying LVSI

- **Study of PORTEC-1, -2 clinical trials of radiation therapy in endometrioid cancer** (intermediate and high intermediate risk)

- **Detailed morphologic classification on H&E slides**
  - # of vessels with LVSI per slide
  - # of slides with LVSI
  - # of tumor cells in largest embolus
  - Distance of deepest LVSI to serosa

- **Outcome = pelvic lymph node recurrence**
  distinguish between <10% risk and at least 10% risk
  threshold for justifying radiation treatment

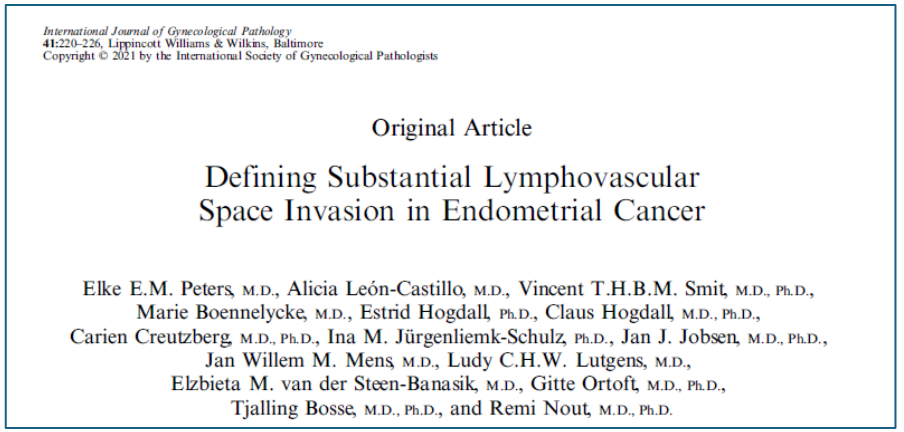

International Journal of Gynecological Pathology
41:220–226, Lippincott Williams & Wilkins, Baltimore
Copyright © 2021 by the International Society of Gynecological Pathologists

Original Article

Defining Substantial Lymphovascular Space Invasion in Endometrial Cancer

Elke E.M. Peters, M.D., Alicia León-Castillo, M.D., Vincent T.H.B.M. Smit, M.D., Ph.D., Marie Boennelycke, M.D., Estrid Hogdall, Ph.D., Claus Hogdall, M.D., Ph.D., Carien Creutzberg, M.D., Ph.D., Ina M. Jürgenliemk-Schulz, Ph.D., Jan J. Jobsen, M.D., Ph.D., Jan Willem M. Mens, M.D., Ludy C.H.W. Lutgens, M.D., Elzbieta M. van der Steen-Banasik, M.D., Gitte Ortoft, M.D., Ph.D., Tjalling Bosse, M.D., Ph.D., and Remi Nout, M.D., Ph.D.

PMID: 34261899

Quantifying LVSI

PORTEC Study Recommendations

# of Vessels with Tumor in a Single Slide	LVSI Classification	5-yr Risk Pelvic Lymph Node Recurrence
0	None	3.3%
1 to 3	Focal	6.7%
4 or more	Substantial	23.3%

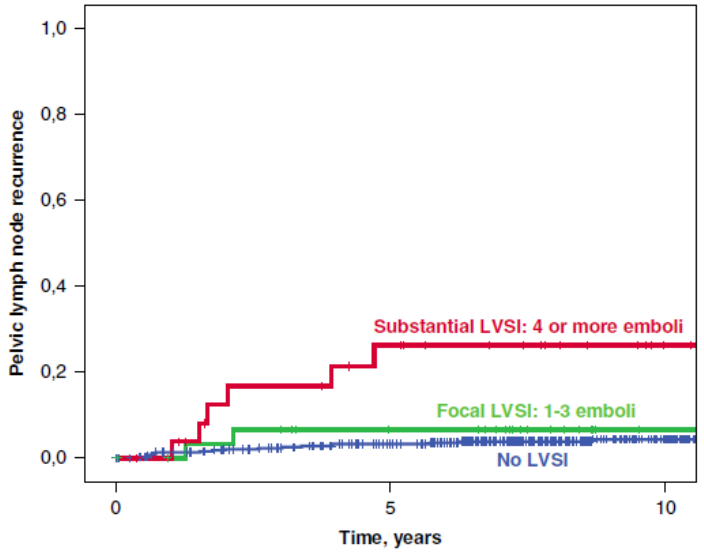

FIG. 1. Kaplan-Meier curves for the 5-yr risk of pelvic lymph node recurrence in the combined PORTEC-1 and PORTEC-2 cohorts, for no lymphovascular space invasion (LVSI), 1 to 3 LVSI-positive vessels, or 4 or more LVSI-positive vessels.

PMID: 34261899

Quantifying LVSI

LVSI in 6 vessels in 1 of 5 slides
Classify as
Substantial LVSI

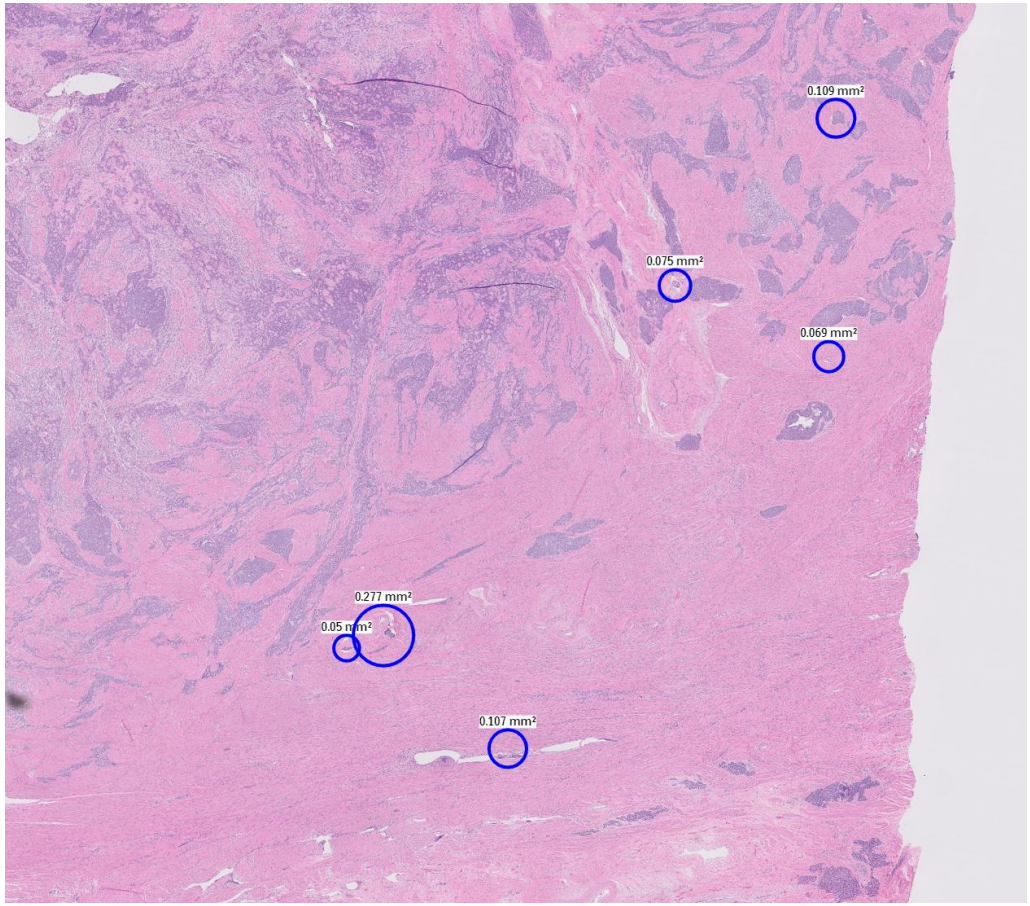

LVSI in 2 vessels per slide, in each of 5 slides
Classify as
Focal LVSI

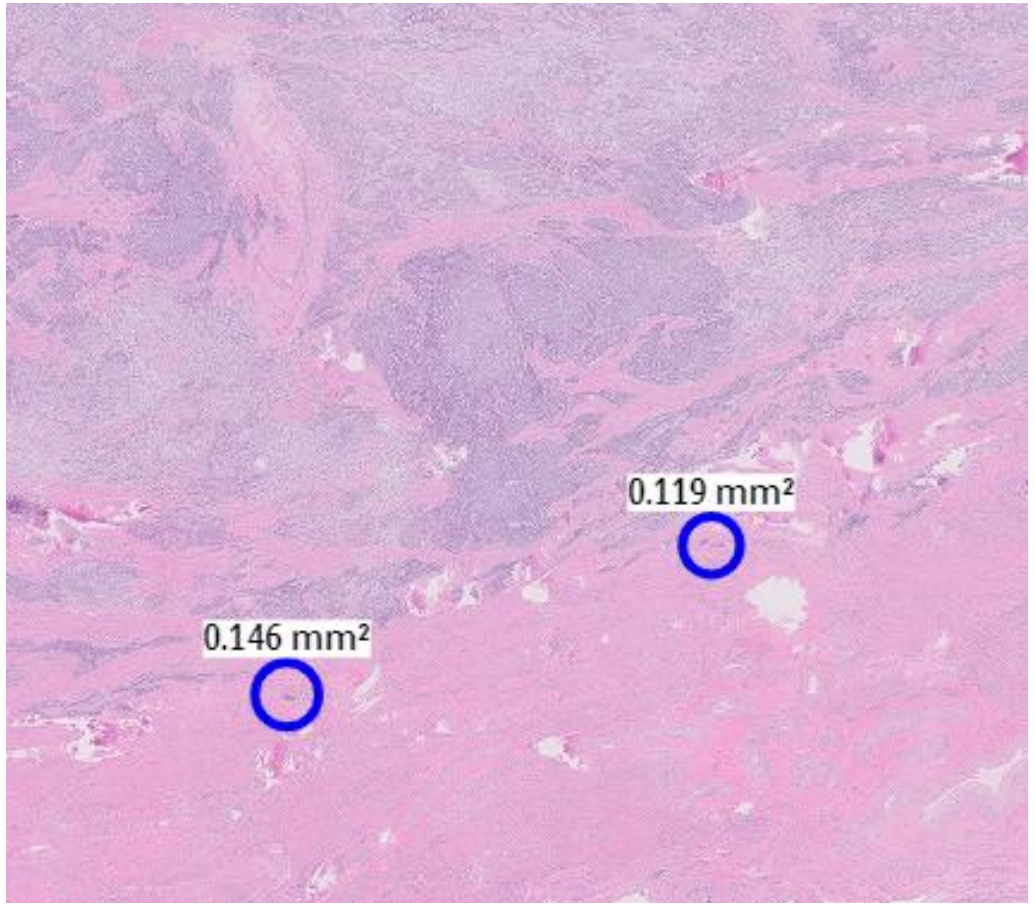

Quantifying LVSI

Emboli belong to 1 vessel

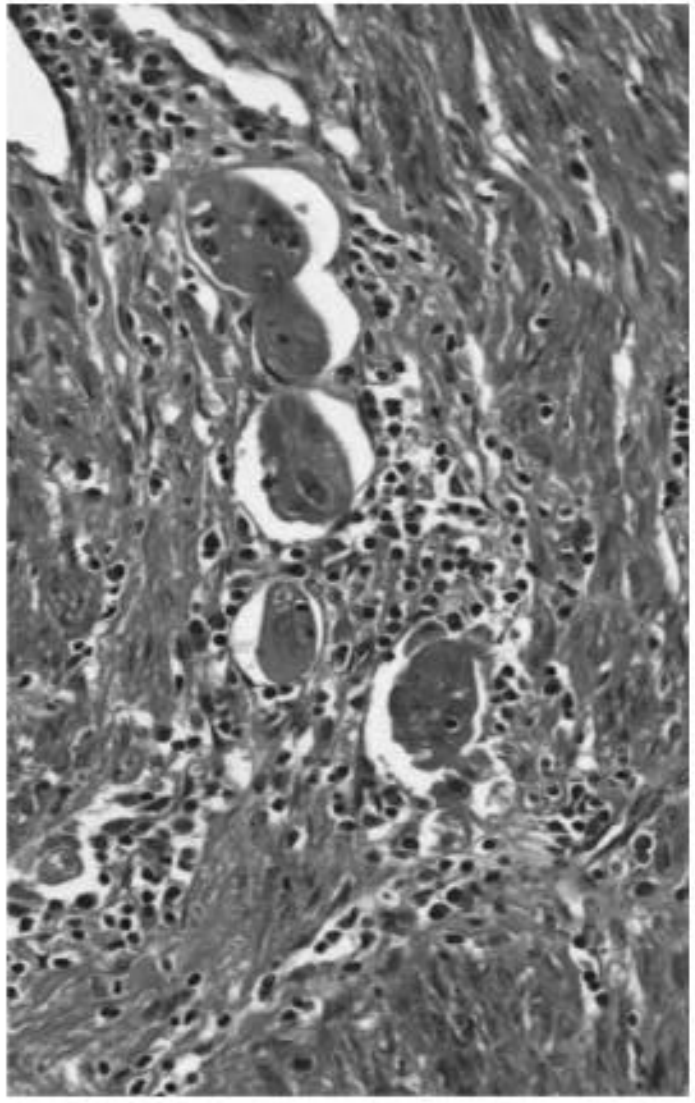

Emboli belong to 1 vessel

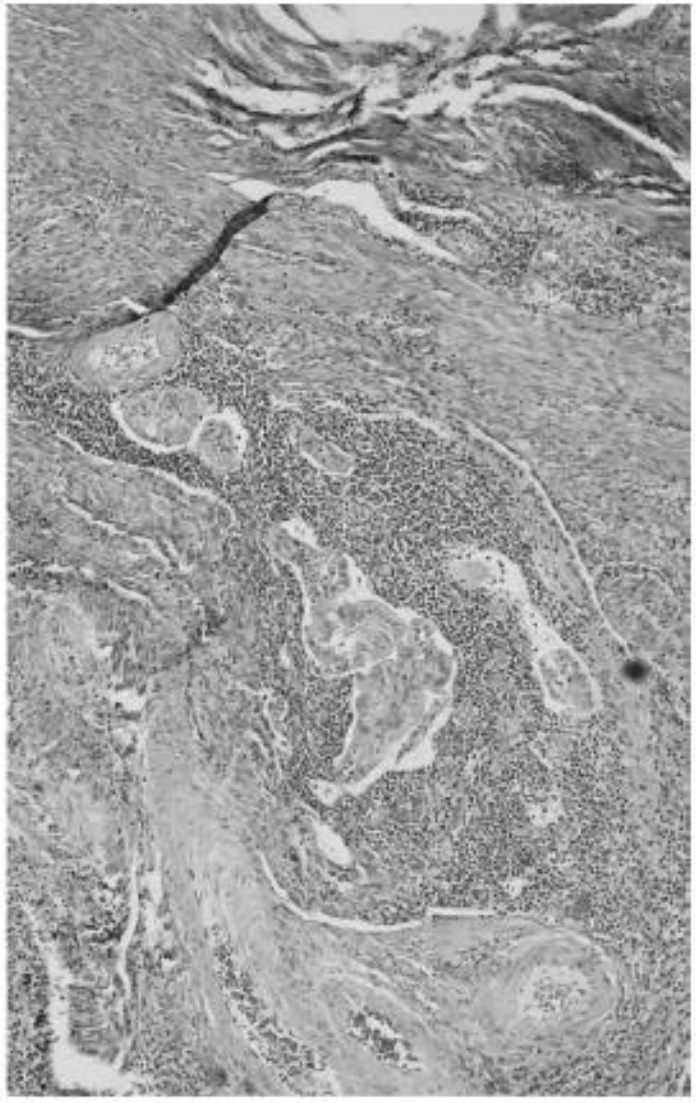

REVIEW

Practical guidance for assessing and reporting lymphovascular space invasion (LVSI) in endometrial carcinoma

Elke E M Peters,[1,2] Marisa R Nucci,[3] C Blake Gilks,[4] W Glenn McCluggage[5] & Tjalling Bosse[2]

[1]Department of Pathology, Haaglanden Medical Centre, The Hague, [2]Department of Pathology, Leiden University Medical Center, Leiden, the Netherlands, [3]Division of Women's and Perinatal Pathology, Department of Pathology, Brigham and Women's Hospital/Harvard Medical School, Boston, MA, USA, [4]Department of Pathology and Laboratory Medicine, University of British Columbia, Vancouver, BC, Canada and [5]Department of Pathology, Belfast Health and Social Care Trust, Belfast, UK

PMID: 38937066

Quantifying LVSI

Conflicting Literature

- **Retrospective single institution study**
- **Stage 1 endometrioid cancer** (n=335)

# of Vessels with Tumor in a Single Slide	LVSI Classification	2-yr Recurrence Free Survival
0	None	92.5%
1 to 3	Focal	98%
4 or more	Substantial	91.4%

- Limitation: adjuvant treatment not standardized

Is Substantial Lymphovascular Space Invasion Prognostic in Patients With Pathologically Lymph Node-Negative Endometrial Cancer?

Phillip M. Pifer, MD, PhD,* Sruthi Jaishankar, BS,* Rohit Bhargava, MD,† Michael D. Schad, BS,* Andrew Keller, MD,* Hima Bindu Musunuru, MD,* Michael Cohen, MD,‡ Paniti Sukumvanich, MD,‡ Madeleine Courtney-Brooks, MD, MPH,‡ Michelle Boisen, MD,† Jessica L. Berger, MD,‡ Alexander Olawaiye, MD,‡ Jamie Lesnock, MD,† Robert Edwards, MD,† Sarah Taylor, MD, PhD,† John Austin Vargo, MD,* and Sushil Beriwal, MD, MBA‖,†

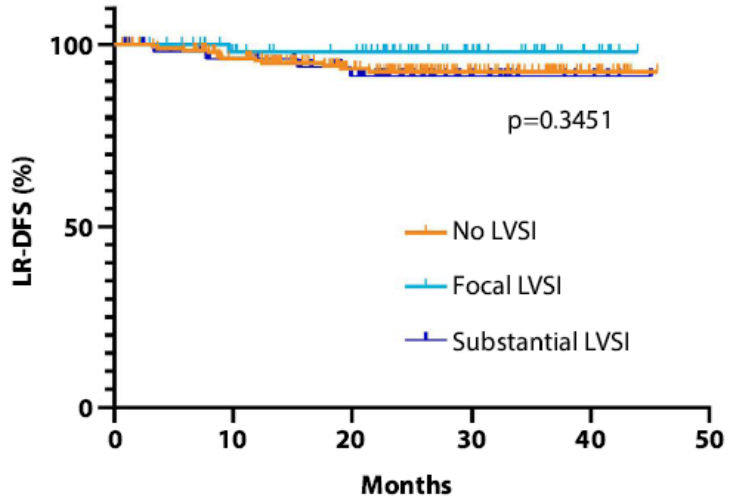

PMID: 36893818

Quantifying LVSI

Conflicting Literature

- **Retrospective multi-institutional study**
  Adjuvant therapy by local institutional practice

- **Stage 1 endometrioid carcinoma** (n=1554)

LVSI (WHO Criteria)	5-yr Progression Free Survival
None	**90.7%**
Focal	**70.5%**
Substantial	**68.7%**

- **Conclusion: Focal LVSI is similar to Substantial LVSI**

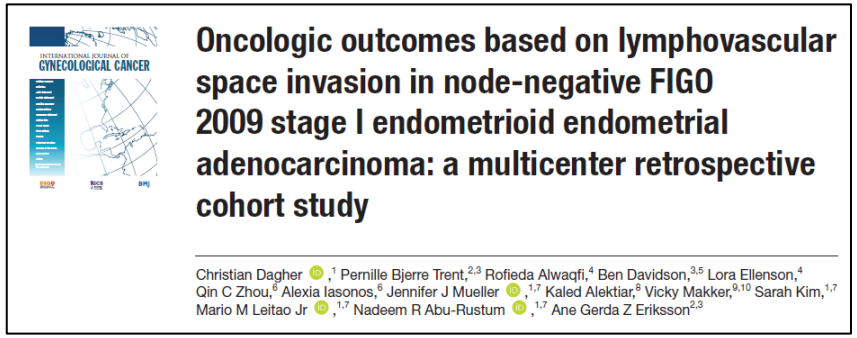

PMID: 40055122

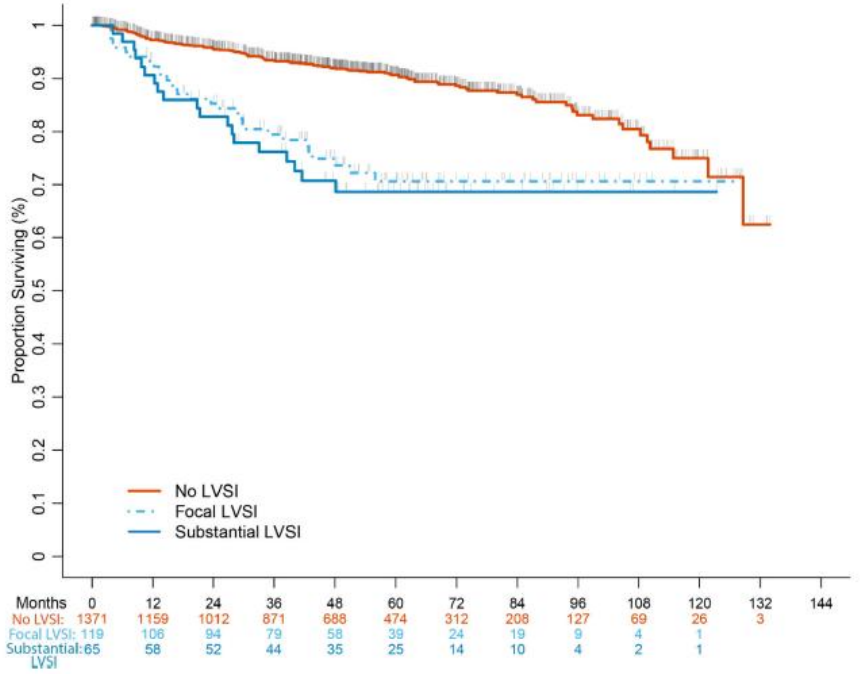

Quantifying LVSI

Reproducibility?

- **Reproducibility is a concern**
- **Root cause is multi-factorial**
  - **Differences in tissue sampling**
  - **Distinction from pseudo-LVSI and from mimics of LVSI**
  - **Distinction of multiple emboli in a single-vessel versus multi-vessel involvement**

Quantifying LVSI

Reproducibility?

Quantifying LVSI (0.62)

Presence or absence of LVSI (0.64)

0-0.19	0.2-0.39	0.4-0.59	0.6-0.79	0.8+
Slight	**Fair**	**Moderate**	**Substantial**	**Almost perfect**
Intraclass correlation coefficient / level of agreement				

Agreement between 6 pathologists	LVSI Present vs Absent	Quantifying LVSI
Full or partial	**69%**	**71%**
None	**31%**	**29%**

Reproducibility of lymphovascular space invasion (LVSI) assessment in endometrial cancer

Elke E M Peters,[1,2] Carla Bartosch,[3] W Glenn McCluggage,[4] Catherine Genestie,[5] Sigurd F Lax,[6] Remi Nout,[7] Jan Oosting,[1] Naveena Singh,[8] Huub C S H Smit,[9] Vincent T H B M Smit,[1] Koen K Van de Vijver[9] & Tjalling Bosse[1]

[1]*Department of Pathology, Leiden University Medical Center, Leiden, the Netherlands,* [2]*Department of Pathology, Haaglanden Medical Center, The Hague, the Netherlands,* [3]*Department of Pathology, Portuguese Oncology Institute-Porto, Porto, Portugal,* [4]*Department of Pathology, Belfast Health and Social Care Trust, Belfast, Northern Ireland, UK,* [5]*Department of BioPathology, University Paris-Saclay, Gustave-Roussy Cancer Center, Villejuif, France,* [6]*Department of Pathology, Hospital Graz II and Medical University of Graz, Graz, Austria,* [7]*Department of Radiation Oncology, Leiden University Medical Center, Leiden, the Netherlands,* [8]*Department of Cellular Pathology, Barts Health NHS Trust, London, UK, and* [9]*Department of Pathological Anatomy, Ghent University Hospital, Ghent, Belgium*

PMID: 31155736

Quantifying LVSI

Reproducibility?

- **The number of patients affected by potential reproducibility issues may be small**

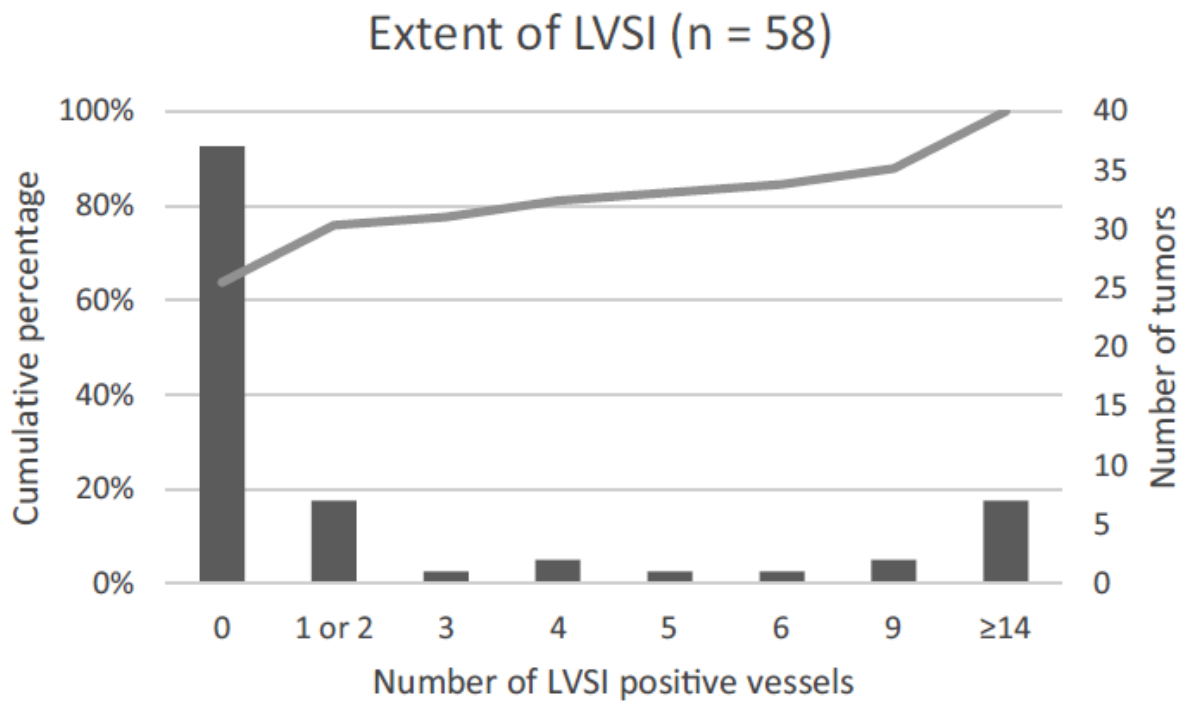

REVIEW

Practical guidance for assessing and reporting lymphovascular space invasion (LVSI) in endometrial carcinoma

Elke E M Peters,[1,2] Marisa R Nucci,[3] C Blake Gilks,[4] W Glenn McCluggage[5] & Tjalling Bosse[2]

[1]Department of Pathology, Haaglanden Medical Centre, The Hague, [2]Department of Pathology, Leiden University Medical Center, Leiden, the Netherlands, [3]Division of Women's and Perinatal Pathology, Department of Pathology, Brigham and Women's Hospital/Harvard Medical School, Boston, MA, USA, [4]Department of Pathology and Laboratory Medicine, University of British Columbia, Vancouver, BC, Canada and [5]Department of Pathology, Belfast Health and Social Care Trust, Belfast, UK

PMID: 38937066

Quantifying LVSI

Still An Evolving Topic

For today, FIGO 2023 Staging Criteria:

# of Vessels with Tumor in a Single Slide	LVSI Classification
0	None
1 to 4	Focal
5 or more	Substantial

Practical Approach to Diagnosing LVSI

- Appropriate tissue sampling
- Distinction from
  - Pseudo-LVSI
  - Mimics of LVSI

Tissue Sampling Guidelines and LVSI

- **No evidence-based or consensus guidelines specific for finding LVSI**
- **Consensus-based guidelines from ISGyP for endometrial cancer sampling** *in general*:

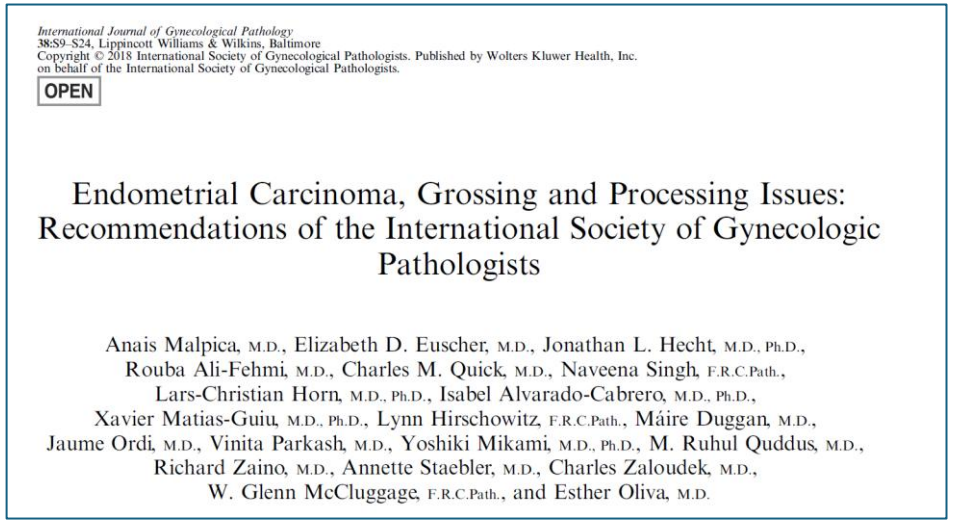

International Journal of Gynecological Pathology
38:S9–S24, Lippincott Williams & Wilkins, Baltimore
Copyright © 2018 International Society of Gynecological Pathologists. Published by Wolters Kluwer Health, Inc. on behalf of the International Society of Gynecological Pathologists.
OPEN

Endometrial Carcinoma, Grossing and Processing Issues: Recommendations of the International Society of Gynecologic Pathologists

Anais Malpica, M.D., Elizabeth D. Euscher, M.D., Jonathan L. Hecht, M.D., Ph.D., Rouba Ali-Fehmi, M.D., Charles M. Quick, M.D., Naveena Singh, F.R.C.Path., Lars-Christian Horn, M.D., Ph.D., Isabel Alvarado-Cabrero, M.D., Ph.D., Xavier Matias-Guiu, M.D., Ph.D., Lynn Hirschowitz, F.R.C.Path., Máire Duggan, M.D., Jaume Ordi, M.D., Vinita Parkash, M.D., Yoshiki Mikami, M.D., Ph.D., M. Ruhul Quddus, M.D., Richard Zaino, M.D., Annette Staebler, M.D., Charles Zaloudek, M.D., W. Glenn McCluggage, F.R.C.Path., and Esther Oliva, M.D.

PMID: 30550481

- **1 tissue section per centimeter of tumor**
  if <3 cm, fully submit
- **1 tissue section of deepest myoinvasion**
  full thickness from surface to serosa
- **Demonstrate tumor / myometrium interface**
  no recommendation on number of sections

- **Practical approach: tailor sampling to the individual case based on gross findings**

Low Magnification Clues to Identifying LVSI

- Leading edge of invasive tumor
- Lymphatics often near small arteries, veins
- Perivascular lymphoid aggregates
- Microcystic elongated fragmented (MELF) pattern myoinvasion

LVSI in FIGO 2023 Endometrial Cancer Staging

- LVSI does <u>not</u> count when measuring depth of myoinvasion by tumor for staging

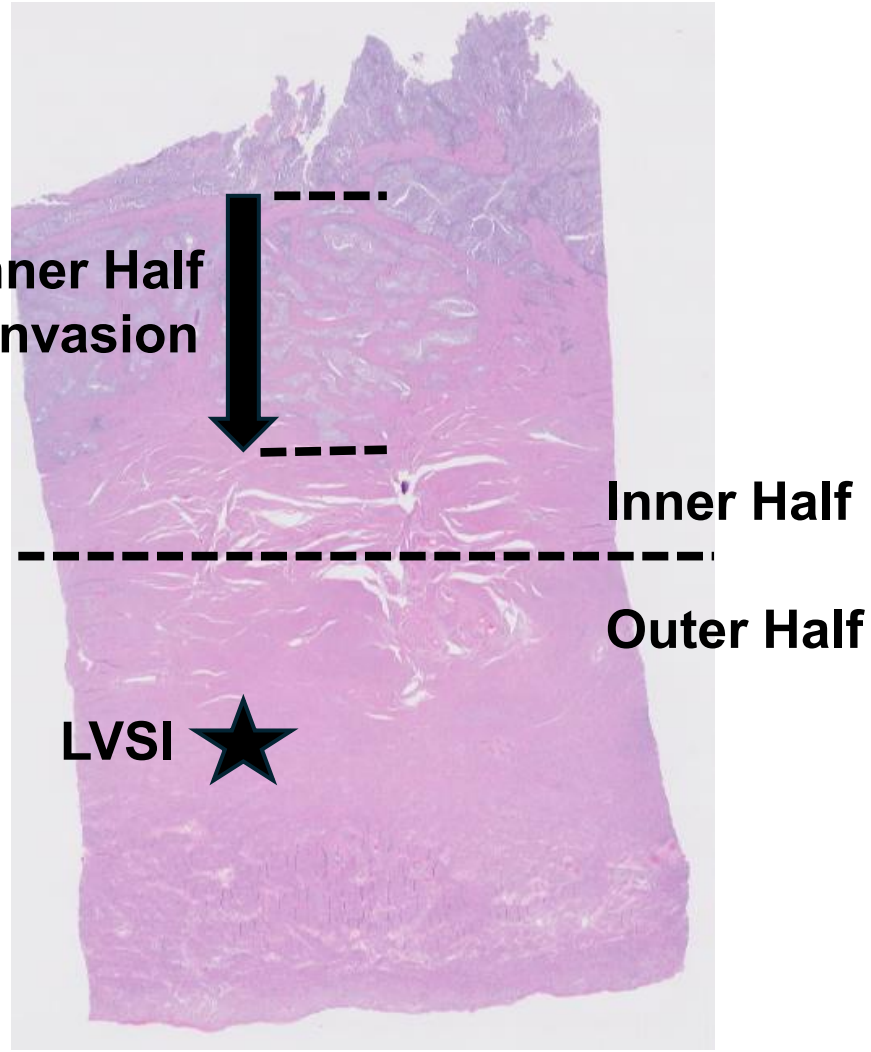

Pseudo-LVSI

- **Definition: Artifactual displacement of tumor into lymphovascular spaces**
- **Causes:**

Mechanical transfer	▪ "Knife" transfer while slicing uterus ▪ Cutting board "floaters" ▪ Under-fixed specimen
Increased intrauterine pressure	▪ Pre-op / intra-op manipulation of uterus ▪ Uterine manipulator device

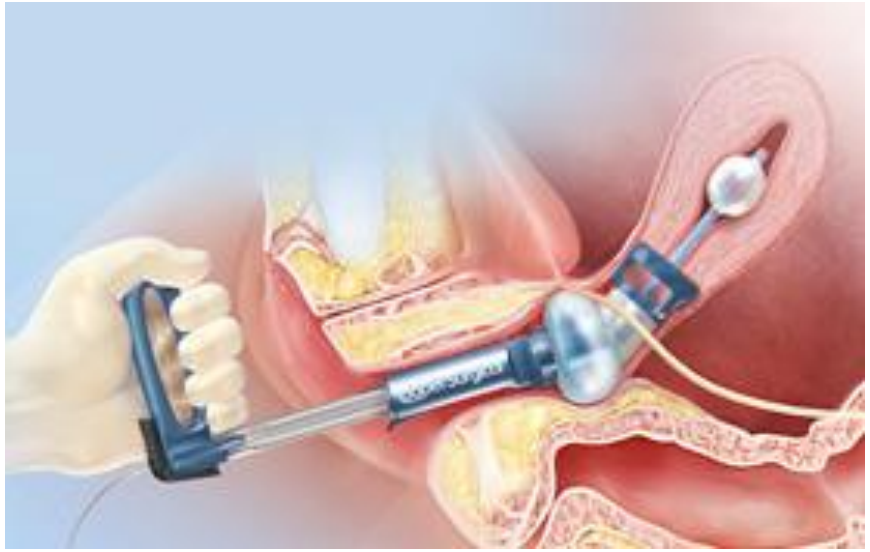

Pseudo-LVSI

Fragmented tumor

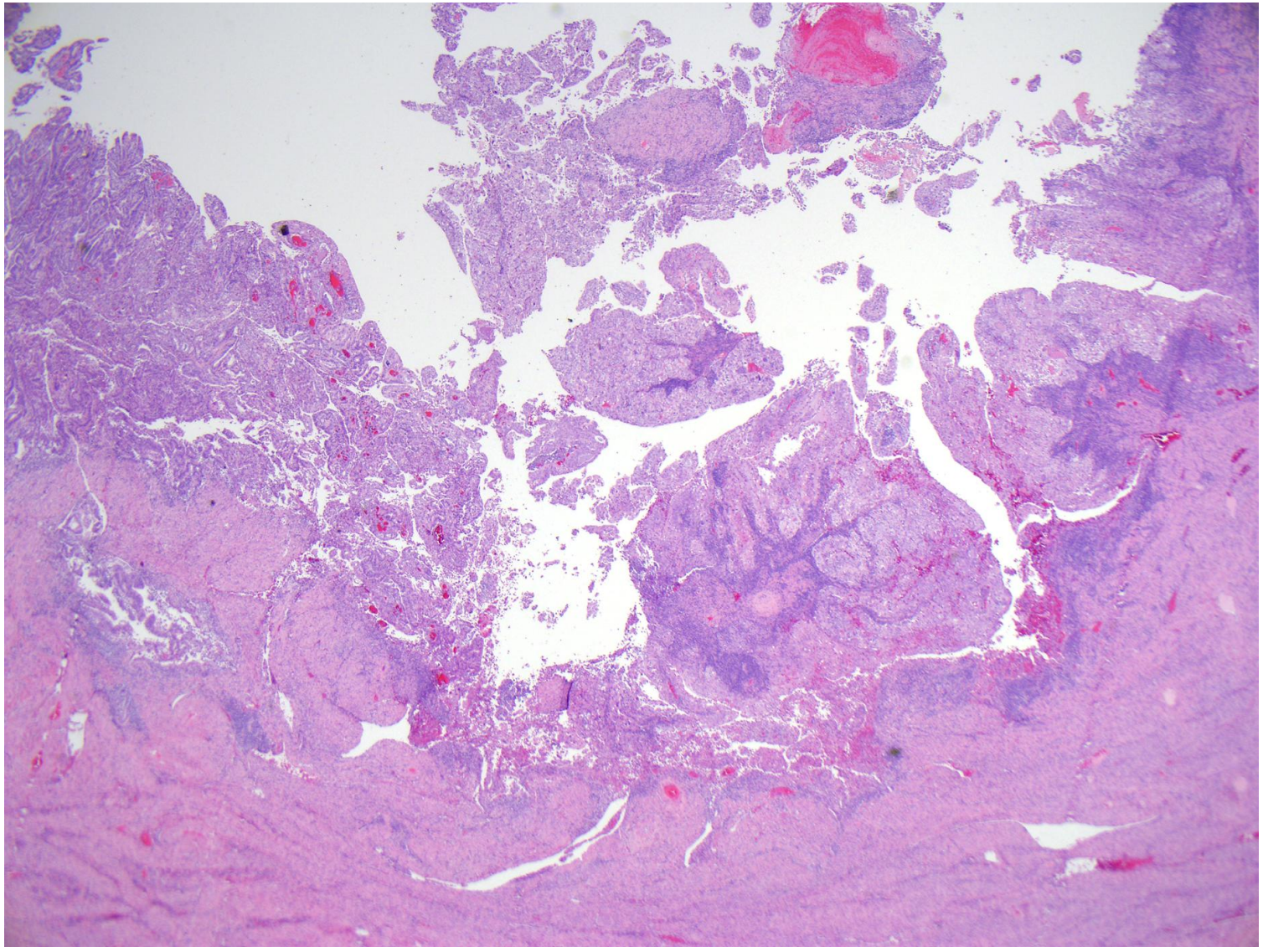

Fragmented, lack of molding

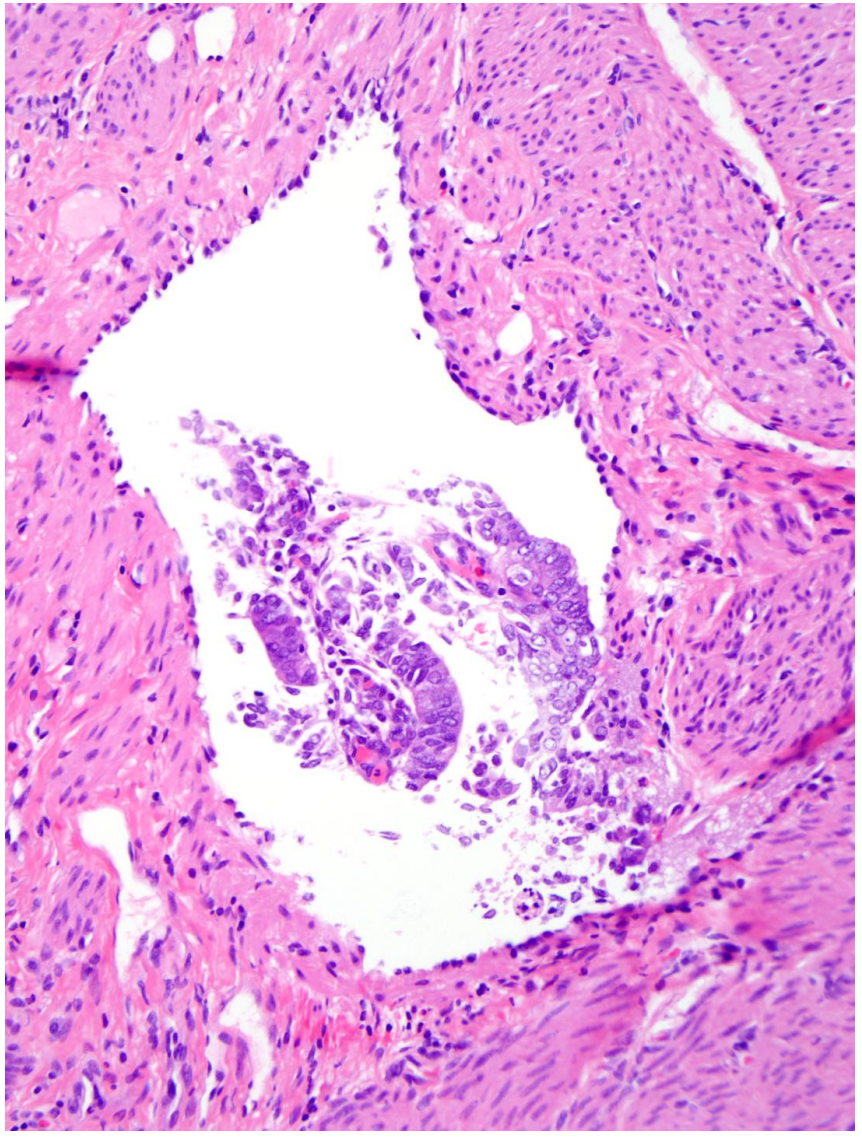

Recommendations to Distinguish True versus Pseudo LVSI

Criteria	True LVSI	Pseudo LVSI
Tumor emboli	Cohesive	Disaggregated
Altered cytology	Yes	No
Admixed inflammatory cells	No	Yes
Location of emboli	Leading edge of invasion	Superficial only
Near large vessels	Yes	No
Retraction artifacts	No	Yes

Evaluation of vascular space involvement in endometrial adenocarcinomas: laparoscopic *vs* abdominal hysterectomies

Ann K Folkins[1,*,†], Nicole S Nevadunsky[2,*], A Saleemuddin[1], Elke A Jarboe[1], Michael G Muto[2], Colleen M Feltmate[2], Chris P Crum[1] and Michelle S Hirsch[1]

PMID: 20473276

Diagnostic Mimics of LVSI

MELF pattern myoinvasion

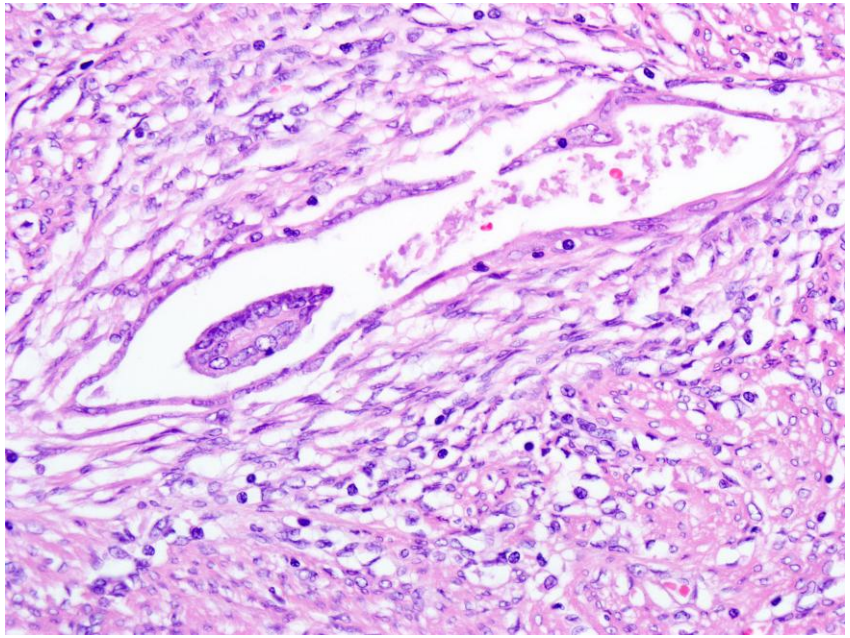

Intravascular inflammation

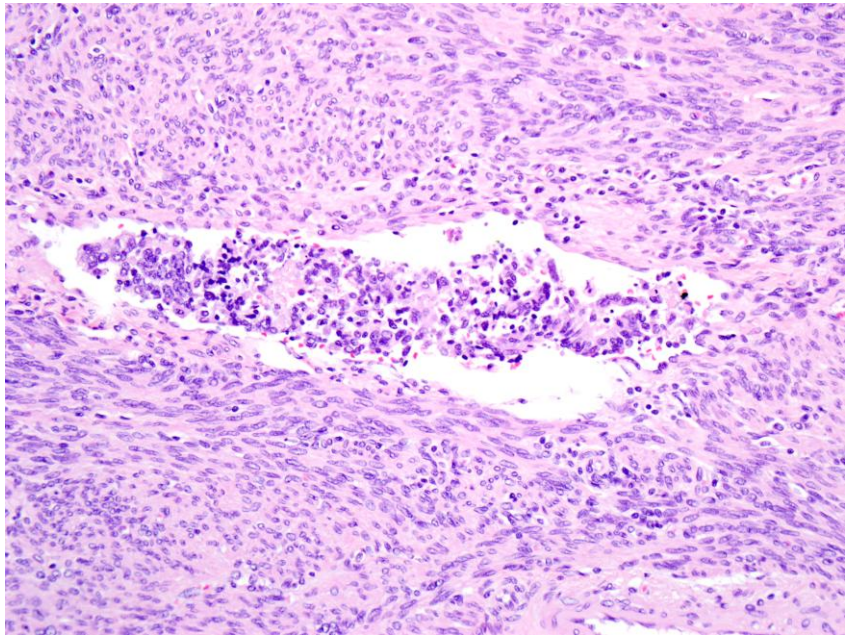

Intravascular adenomyosis

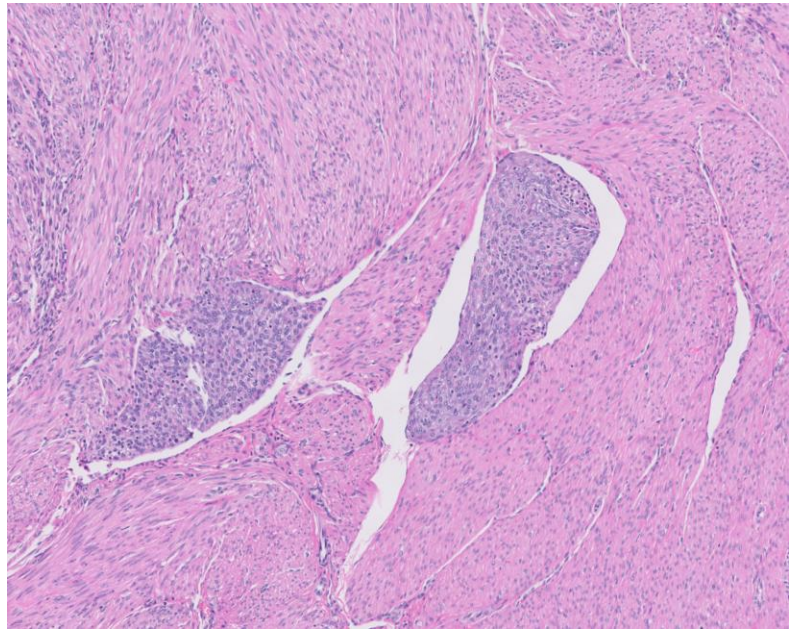

Outline of Talk

- Overview of FIGO 2023 staging system for endometrial cancer
- **Practical approach to potentially challenging "new" staging variables**

Stage I/II	▪ Aggressive mimics of non-aggressive histotypes ▪ Quantifying lymphovascular space invasion
Stage III/IV	**Defining sub-serosal tumor**

FIGO 2023 Staging of Endometrial Cancer

IIIA2 Involvement of uterine subserosa or spread through the uterine serosa

What is the uterine subserosa ???

Stage IIIA2: Involvement of Uterine Subserosa

Likely a rare event

- Tumor infiltrating the full myometrial thickness and reaching submesothelial fibroconnective tissue or the mesothelial layer should be reported as serosal involvement; tumor may or may not be present on the surface of the uterus; a desmoplastic response may or may not be present.

There is essentially no information in the literature pertaining to the recognition of this parameter. For

Pathologic Prognostic Factors in Endometrial Carcinoma (Other Than Tumor Type and Grade)

Naveena Singh, F.R.C.Path., Lynn Hirschowitz, F.R.C.Path., Richard Zaino, M.D., Isabel Alvarado-Cabrero, M.D., Maire A. Duggan, M.D., Rouba Ali-Fehmi, M.D., Elizabeth Euscher, M.D., Jonathan L. Hecht, M.D., Ph.D., Lars-Christian Horn, M.D., Olga Ioffe, M.D., Xavier Matias-Guiu, M.D., W. Glenn McCluggage, F.R.C.Path., Yoshiki Mikami, M.D., Jaume Ordi, M.D., Vinita Parkash, M.D., M. Ruhul Quddus, M.D., M.Phil(Path)., Charles M. Quick, M.D., Annette Staebler, M.D., Charles Zaloudek, M.D., Marisa Nucci, M.D., Anais Malpica, M.D., and Esther Oliva, M.D.

ISGyP Consensus Recommendations PMID: 30550486

What is the Uterine Subserosa ?

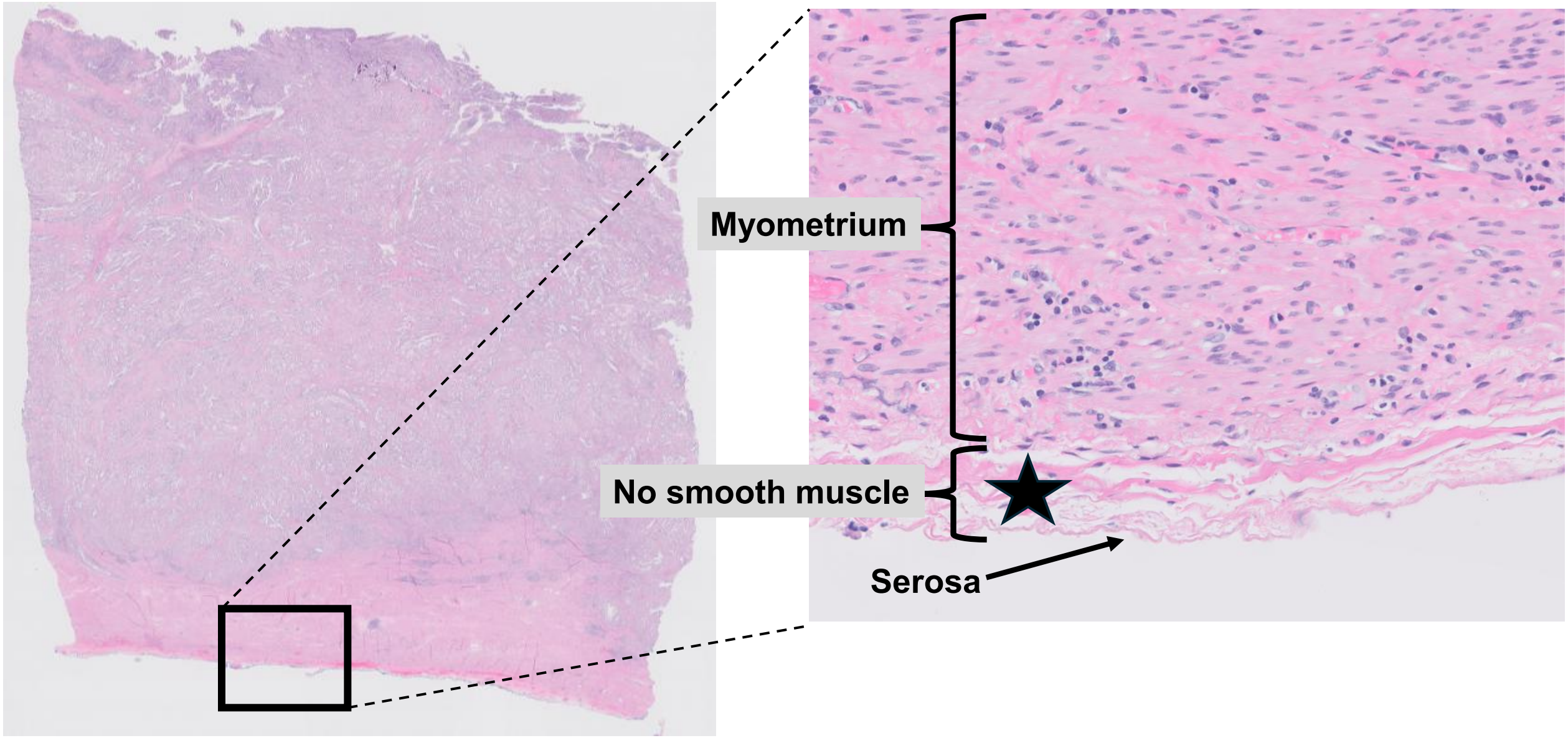

Stage IIIA2: Involvement of Uterine Subserosa

More than just "outer myoinvasion"

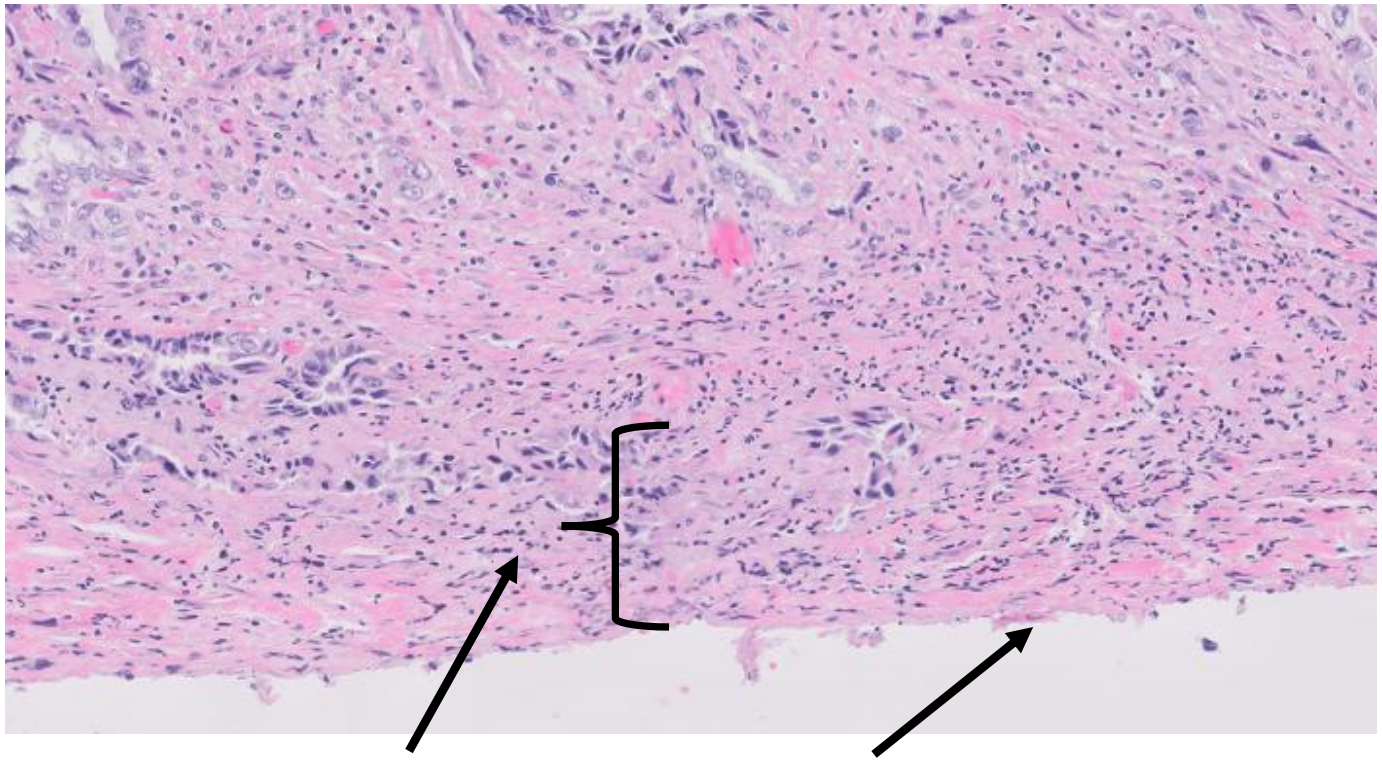

Keratin

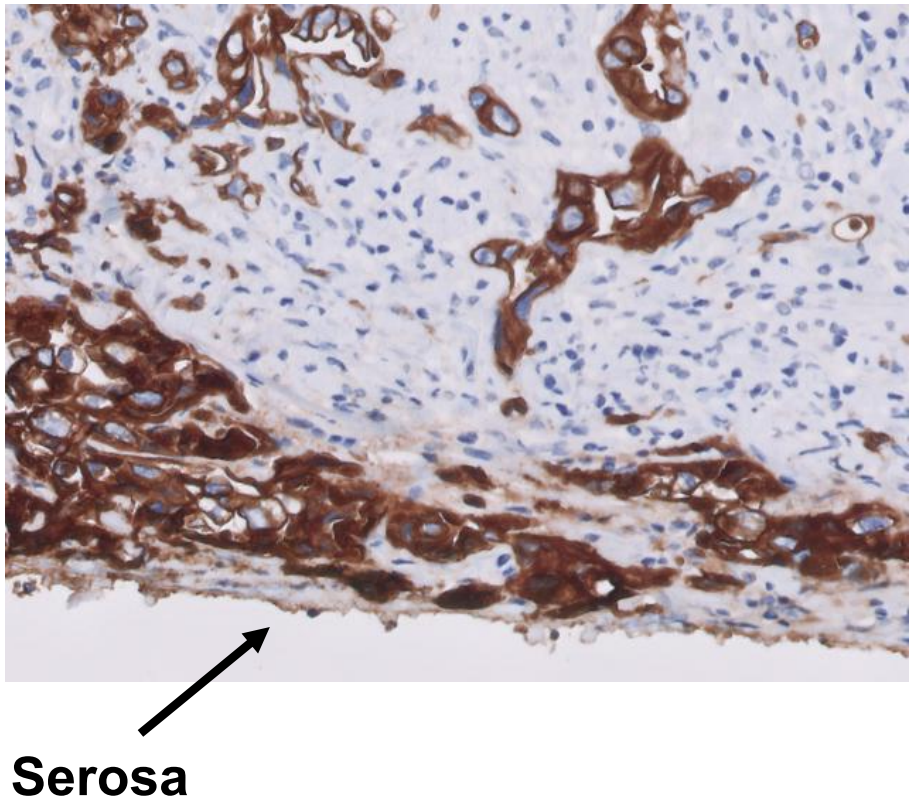

- **No clear smooth muscle**
- **Only fibroblastic tissue**

Outline of Talk

- **Overview of FIGO 2023 staging system for endometrial cancer**
- **Practical approach to potentially challenging "new" staging variables**

Stage I/II	▪ Aggressive mimics of non-aggressive histotypes ▪ Quantifying lymphovascular space invasion
Stage III/IV	▪ Defining sub-serosal tumor **Synchronous endometrial and ovarian tumor**

The New Category of Stage IA3 in FIGO 2023

- **Definition**: Low grade endometrioid carcinoma limited to uterus and one ovary

FIGO 2009	Stage IIIA
FIGO 2023	Stage IA3

- **Rationale**: Behavior is favorable, similar to Stage I endometrial cancer PMID: 28986093

- **Relevance**: Treat as Stage I low grade endometrioid endometrial cancer

The New Category of Stage IA3 in FIGO 2023

- **Criteria: all criteria must be met**

Criteria	Endometrial Tumor	Ovarian Tumor	Tumor in Any Other Site
Histotype	Endometrioid	Endometrioid	None
FIGO Grade	1 or 2	1 or 2	
LVSI	None or focal	None	
Myoinvasion	None or <50%	--	
Laterality	--	Unilateral	
Capsule	--	Intact	

- Nuances:
  - Criteria are consensus-based
  - No comment on role of ovarian precursors (endometriosis, adenofibroma)
  - No comment on concept of synchronous primary endometrial tumor and primary ovarian tumor

The New Category of Stage IA3 in FIGO 2023

Favorable Outcome is Confirmed in Subsequent Studies

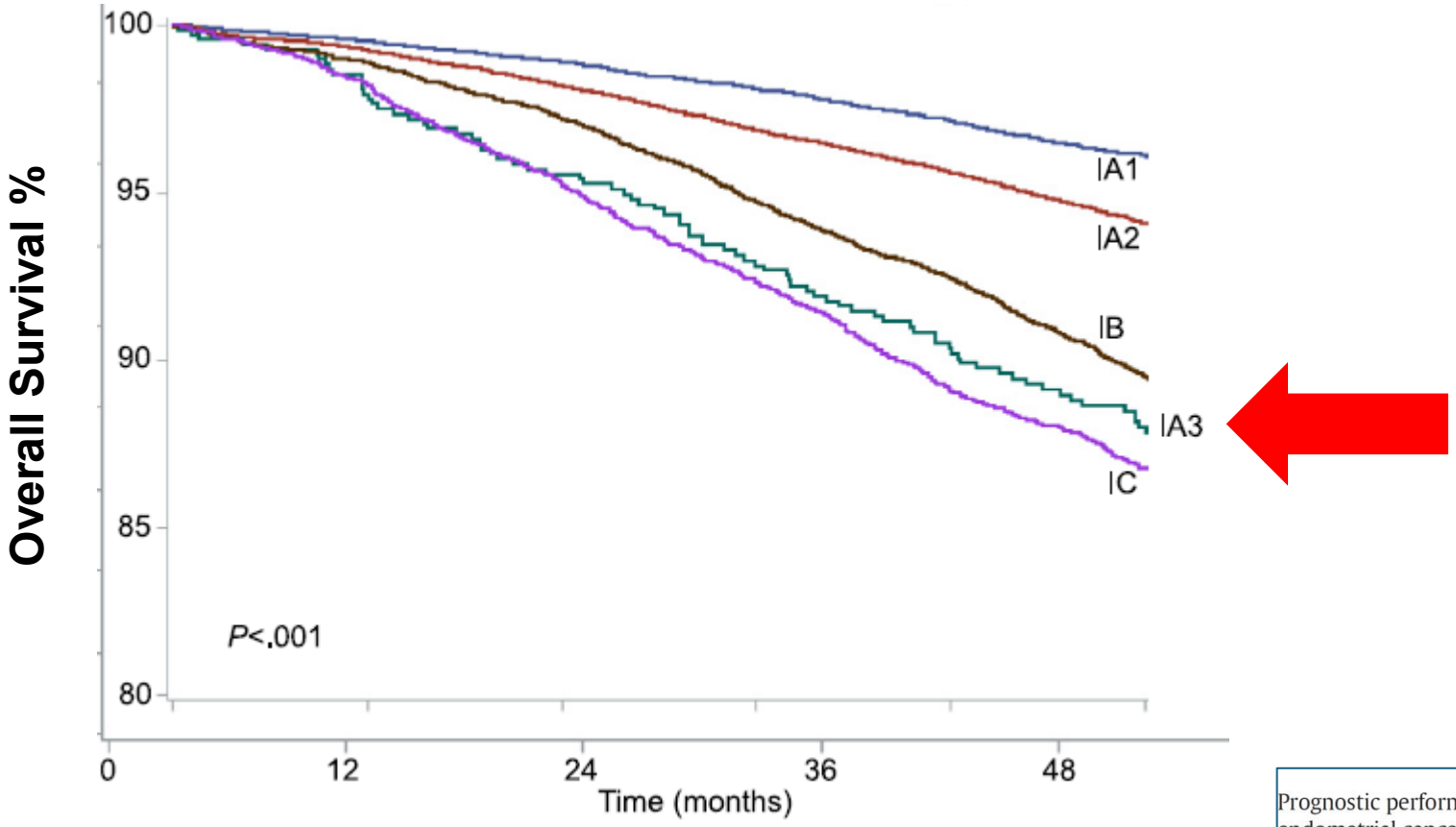

Image from PMID 38713997

Prognostic performance of the 2023 FIGO staging schema for endometrial cancer

Koji Matsuo [a,b,*,1], Ling Chen [c,1], Maximilian Klar [d], Matthew W. Lee [a], Hiroko Machida [e], Mikio Mikami [e], Laila I. Muderspach [a], Joseph W. Carlson [f], Lynda D. Roman [a,b], Jason D. Wright [c,**]

[a] Division of Gynecologic Oncology, Department of Obstetrics and Gynecology, University of Southern California, Los Angeles, CA, USA
[b] Norris Comprehensive Cancer Center, University of Southern California, Los Angeles, CA, USA
[c] Division of Gynecologic Oncology, Department of Obstetrics and Gynecology, Columbia University College of Physicians and Surgeons, New York, NY, USA
[d] Department of Obstetrics and Gynecology, University of Freiburg Faculty of Medicine, Freiburg, Germany
[e] Department of Obstetrics and Gynecology, Tokai University School of Medicine, Kanagawa, Japan
[f] Department of Pathology, University of Southern California, Los Angeles, CA, USA

PMID 38713997

The New Category of Stage IA3 in FIGO 2023

- **Evolving issues:**

  - **No relationship to concept of multiple independent stage I tumors**
  - **Conflicting implications of clonality studies in stage IA3 tumors**
  - **Uncertain role for TCGA molecular classification**

Traditional Concept of 3 Options of Tumor Origin of Synchronous Tumors

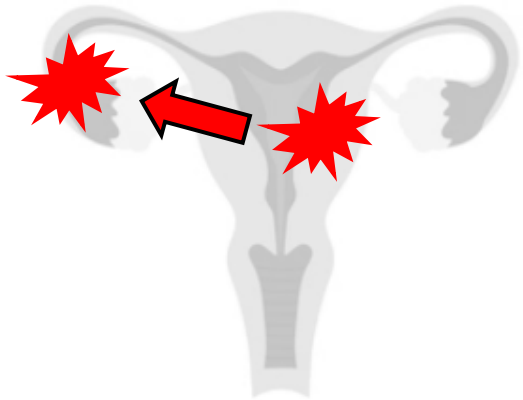



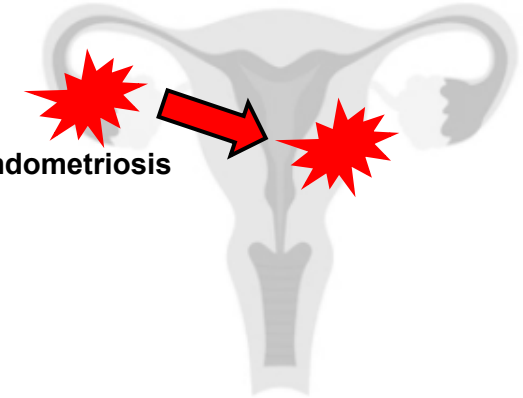

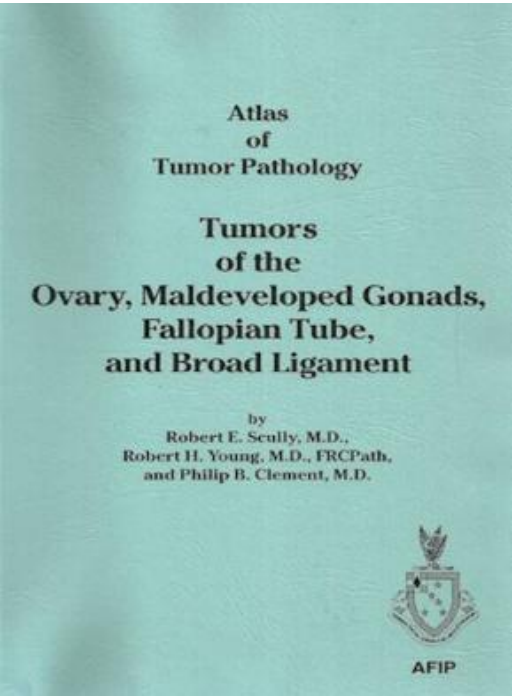

Endometrial Primary
Ovarian Secondary

1. Histologic similarity of the tumors
2. Large endometrial tumor - small ovarian tumor(s)
3. Atypical endometrial hyperplasia additionally present
4. Deep myometrial invasion
   a. Direct extension into adnexa
   b. Vascular space invasion in myometrium
5. Spread elsewhere in typical pattern of endometrial carcinoma
6. Ovarian tumors bilateral and/or multinodular
7. Hilar location, vascular space invasion, surface implants, or combination in ovary
8. Ovarian endometriosis absent
9. Aneuploidy with similar DNA indices or diploidy of both tumors*
10. Similar molecular genetic or karyotypic abnormalities in both tumors

Independent Primary Tumors

1. Histologic dissimilarity of the tumors
2. No or only superficial myometrial invasion of endometrial tumor
3. No vascular space invasion of endometrial tumor
4. Atypical endometrial hyperplasia additionally present
5. Absence of other evidence of spread of endometrial tumor
6. Ovarian tumor unilateral (80 to 90 percent of cases)
7. Ovarian tumor located in parenchyma
8. No vascular space invasion, surface implants, or predominant hilar location in ovary
9. Absence of other evidence of spread of ovarian tumor
10. Ovarian endometriosis present
11. Different ploidy or DNA indices, if aneuploid, of the tumors*
12. Dissimilar molecular genetic or karyotypic abnormalities in the tumors

Ovarian Primary
Endometrial Secondary

1. Histologic similarity of the tumors
2. Large ovarian tumor - small endometrial tumor
3. Ovarian endometriosis present
4. Location in ovarian parenchyma
5. Direct extension from ovary predominantly into outer wall of uterus
6. Spread elsewhere in typical pattern of ovarian carcinoma
7. Ovarian tumor unilateral (80 to 90 percent of cases) and forming single mass
8. No atypical hyperplasia in endometrium
9. Aneuploidy with similar DNA indices or diploidy of both tumors*
10. Similar molecular genetic or karyotypic abnormalities in both tumors

Traditional Concept of 3 Options of Tumor Origin of Synchronous Tumors

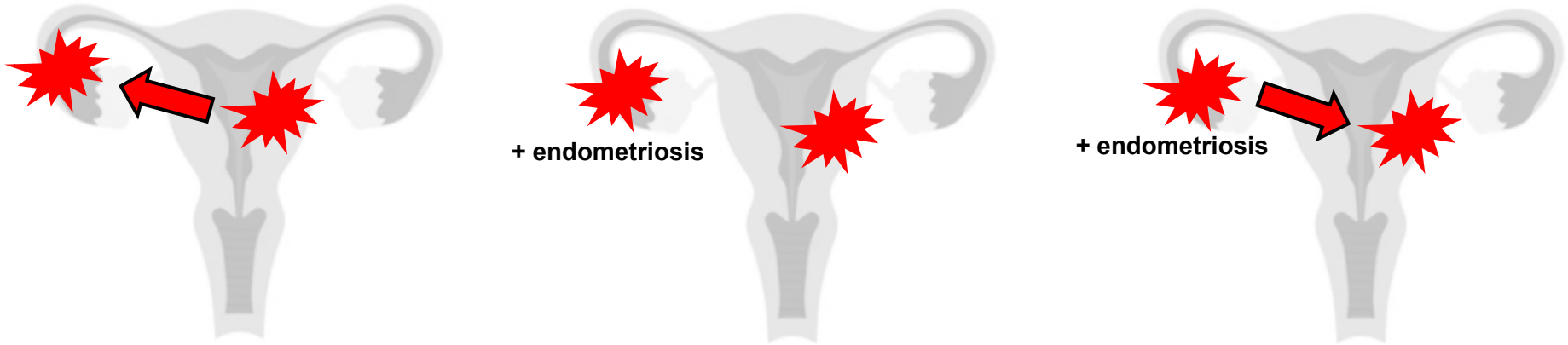

Multiple Studies Demonstrate Most Tumors are Clonal

Massively Parallel Sequencing-Based Clonality Analysis of Synchronous Endometrioid Endometrial and Ovarian Carcinomas

Anne M. Schultheis*, Charlotte K. Y. Ng*, Maria R. De Filippo, Salvatore Piscuoglio, Gabriel S. Macedo, Sonia Gatius, Belen Perez Mies, Robert A. Soslow, Raymond S. Lim, Agnes Viale, Kety H. Huberman, Jose C. Palacios, Jorge S. Reis-Filho, Xavier Matias-Guiu, Britta Weigelt

PMID: 26832770

Synchronous Endometrial and Ovarian Carcinomas: Evidence of Clonality

Michael S. Anglesio, Yi Kan Wang, Madlen Maassen, Hugo M. Horlings, Ali Bashashati, Janine Senz, Robertson Mackenzie, Diljot S. Grewal, Hector Li-Chang, Anthony N. Karnezis, Brandon S. Sheffield, Melissa K. McConechy, Friedrich Kommoss, Florin A. Taran, Annette Staebler, Sohrab P. Shah, Diethelm Wallwiener, Sara Brucker, C. Blake Gilks, Stefan Kommoss, David G. Huntsman

PMID: 26832771

Synchronous Endometrial and Ovarian Carcinomas: Pathologic and Molecular Analysis Highlights the Monoclonal Origin of the Lesions

Angela Guerriero, M.D., Margherita Moro, M.D., Valentina Angerilli, M.D., Giada Munari, B.M., Luisa Santoro, M.D., Lara Alessandrini, M.D., Lara Favero, B.M., Giulia Tasca, M.D., Matteo Fassan, M.D., Ph.D., and Angelo Paolo Dei Tos, M.D.

PMID: 37922918

Molecular profiling identifies synchronous endometrial and ovarian cancers as metastatic endometrial cancer with favorable clinical outcome

Casper Reijnen[1,2], Heidi V.N. Küsters-Vandevelde[3], Marjolijn J.L. Ligtenberg[4,5], Johan Bulten[4], Marloes Oosterwegel[1], Marc P.L.M. Snijders[2], Sanne Sweegers[4], Joanne A. de Hullu[1], Maria C. Vos[6], Anneke A.M. van der Wurff[7], Anne M. van Altena[1], Astrid Eijkelenboom[4] and Johanna M.A. Pijnenborg[1]

PMID: 32022266

Elucidation of genomic origin of synchronous endometrial and ovarian cancer (SEO) by genomic and microsatellite analysis

Ikuko Sakamoto[1,2] Yosuke Hirotsu[2] Kenji Amemiya[2,3] Takahiro Nozaki[1] Hitoshi Mochizuki[2] Masao Omata[2,4]

PMID: 36245225

DNA Methylation Signature of Synchronous Endometrioid Endometrial and Ovarian Carcinomas

Lawrence Hsu Lin[a], Douglas H.R. Allison[b], Gulisa Turashvili[c], Varshini Vasudevaraja[a], Ivy Tran[a], Jonathan Serrano[a], Britta Weigelt[b], Marc Ladanyi[b], Nadeem R. Abu-Rustum[d,e], Matija Snuderl[a,*], Sarah Chiang[b,*]

[a] Department of Pathology, New York University Langone Health and School of Medicine, New York, New York; [b] Department of Pathology and Laboratory Medicine, Memorial Sloan Kettering Cancer Center, New York, New York; [c] Department of Pathology and Laboratory Medicine, Emory University Hospital, Atlanta, Georgia; [d] Gynecology Service, Department of Surgery, Memorial Sloan Kettering Cancer Center, New York, New York; [e] Department of Obstetrics and Gynecology, Weill Cornell Medical College, New York, New York

PMID: 37652400

The New Category of Stage IA3 in FIGO 2023

Unresolved Dilemmas

Is the concept of independent primary endometrial and primary ovarian tumors still viable?

Presenting symptom: **Ovary**	*Incidental finding:* **Endometrium**
grade 1 endometrioid carcinoma + endometriosis	**Microfocus of grade 1 endometrioid carcinoma**

Which is the correct classification ? *Answer depends on what model you use:*

Model	*Answer*
FIGO 2023	▪ **Stage IA3 endometrial cancer**
AFIP / Scully	*<u>Two independent cancers:</u>* ▪ **stage IA endometrial cancer +** ▪ **stage IA ovarian cancer**

Multi-site endometrioid carcinoma, grade 1

Endometrium
No myoinvasion
No LVSI

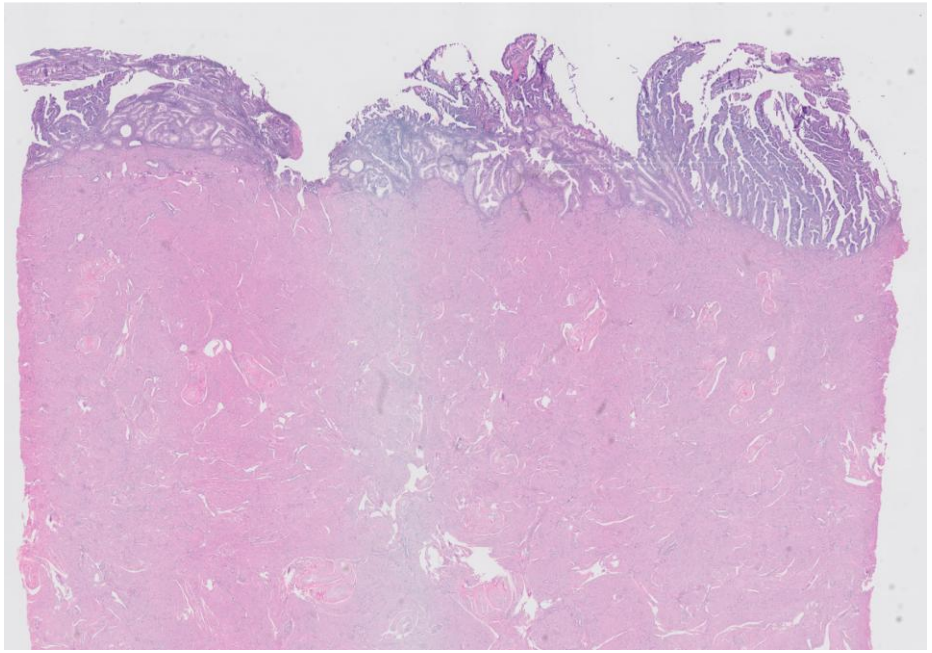

Fallopian tube
No stromal invasion
No LVSI

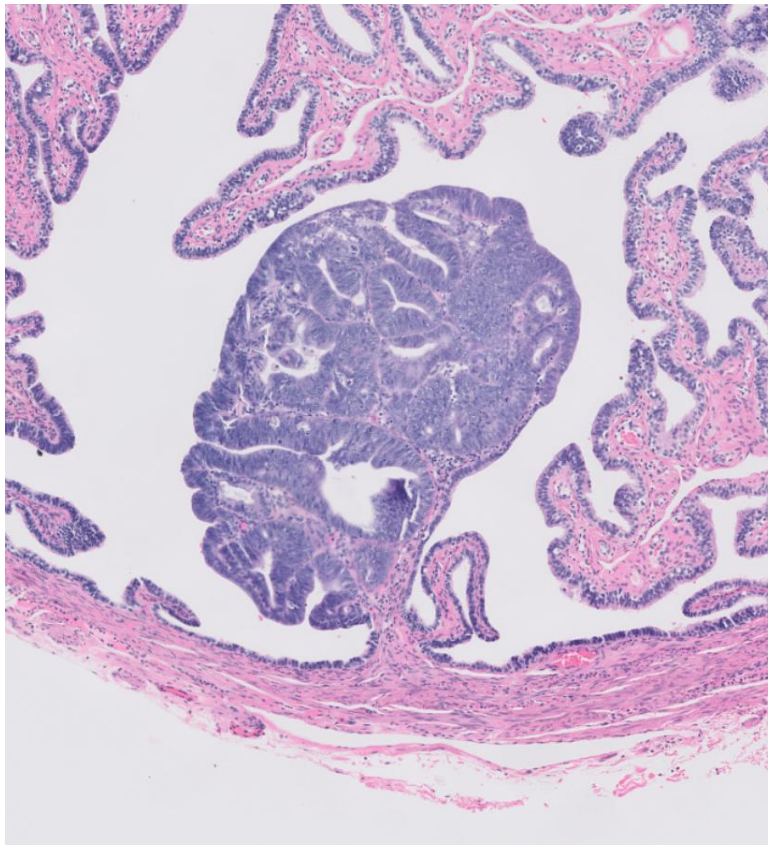

Ovary
Unilateral
Intact capsule

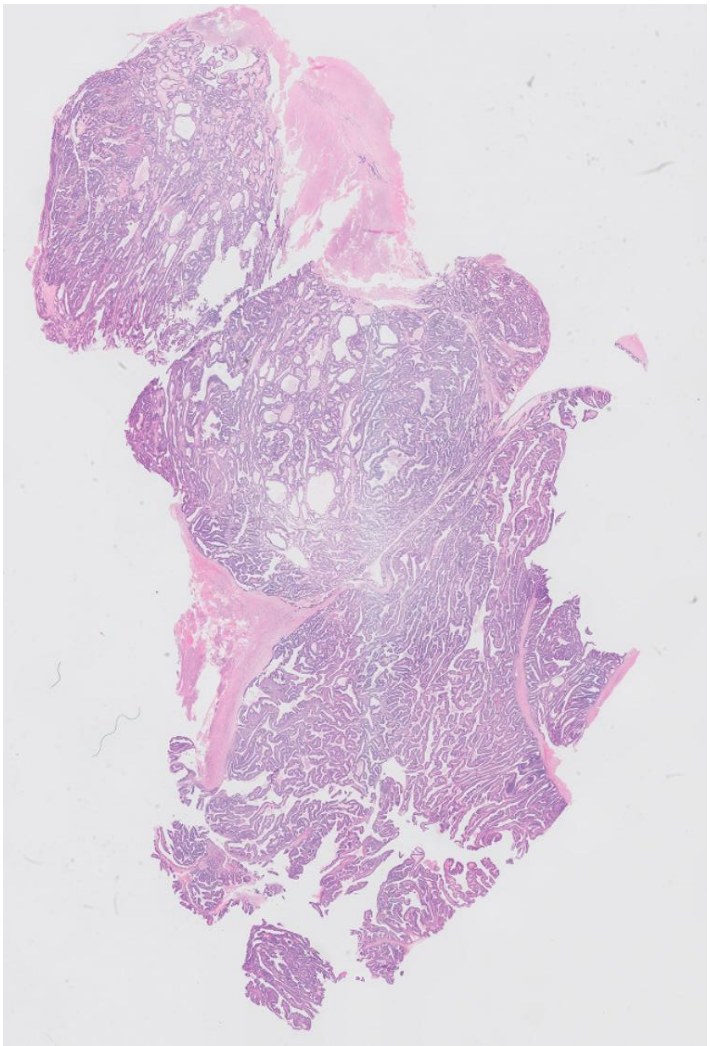

- No other sites of tumor
- No endometriosis in tube or ovary

Outline of Talk

- Overview of FIGO 2023 staging system for endometrial cancer
- **Practical approach to potentially challenging "new" staging variables**

Stage I/II	▪ Aggressive mimics of non-aggressive histotypes
	▪ Quantifying lymphovascular space invasion
Stage III/IV	▪ Defining sub-serosal tumor
	▪ Synchronous endometrial and ovarian tumor



Molecular staging pitfalls

FIGO 2023 Endometrial Cancer: Molecular Staging

- **Aim:** **To refine morphology-based stage I or II if p53abn or *POLE* mutated**
  - More than just documenting molecular subtype

- **Requirements:**
  - **Surgical staging to confirm cancer is confined to the uterus**
    - Cannot assign on biopsy specimen
  - **3 tests to define TCGA molecular subtype**

	Test Options
Mismatch repair status	**MMR IHC, MSI test**
p53 / *TP53* status	**p53 IHC, sequencing**
***POLE* status**	***POLE* mutation test**

FIGO 2023 Endometrial Cancer: Molecular Staging

Down-staging of POLE mutated / Ultramutated cancer

Stage	Morphologic Stage	Molecular Stage
I	IA1	IAm-POLE
	IA2	
	IB	
	IC	
II	IIA	
	IIB	
	IIC	

- **Stage IA3, III/IV are not affected by molecular staging**

FIGO 2023 Endometrial Cancer: Molecular Staging

Up-staging of p53 abnormal / TP53 mutated cancer

p53abn endometrial carcinoma confined to the uterine corpus with any myometrial invasion, with or without cervical invasion, and regardless of the degree of LVSI or histological type

FIGO 2023 Endometrial Cancer: Molecular Staging

Up-staging of p53 abnormal / TP53 mutated cancer

p53abn endometrial carcinoma confined to the uterine corpus with any myometrial invasion, with or without cervical invasion, and regardless of the degree of LVSI or histological type

?

Myoinvasion	Myoinvasion
✗ None	✓ None
✓ Inner	✓ Inner
✓ Outer	✓ Outer

FIGO 2023 Endometrial Cancer: Molecular Staging

Up-staging of p53 abnormal / TP53 mutated cancer

Stage	Morphologic Stage	Molecular Stage
I	IA1	n/a
	IA2	IICm p53
	IB	
	IC	n/a
II	IIA	IICm p53
	IIB	
	IIC	

- **Stage IA3, III/IV are not affected by molecular staging**

FIGO 2023 Endometrial Cancer: Molecular Staging

Clear Documentation of Staging System in Pathology Report is Essential to Avoid Confusion

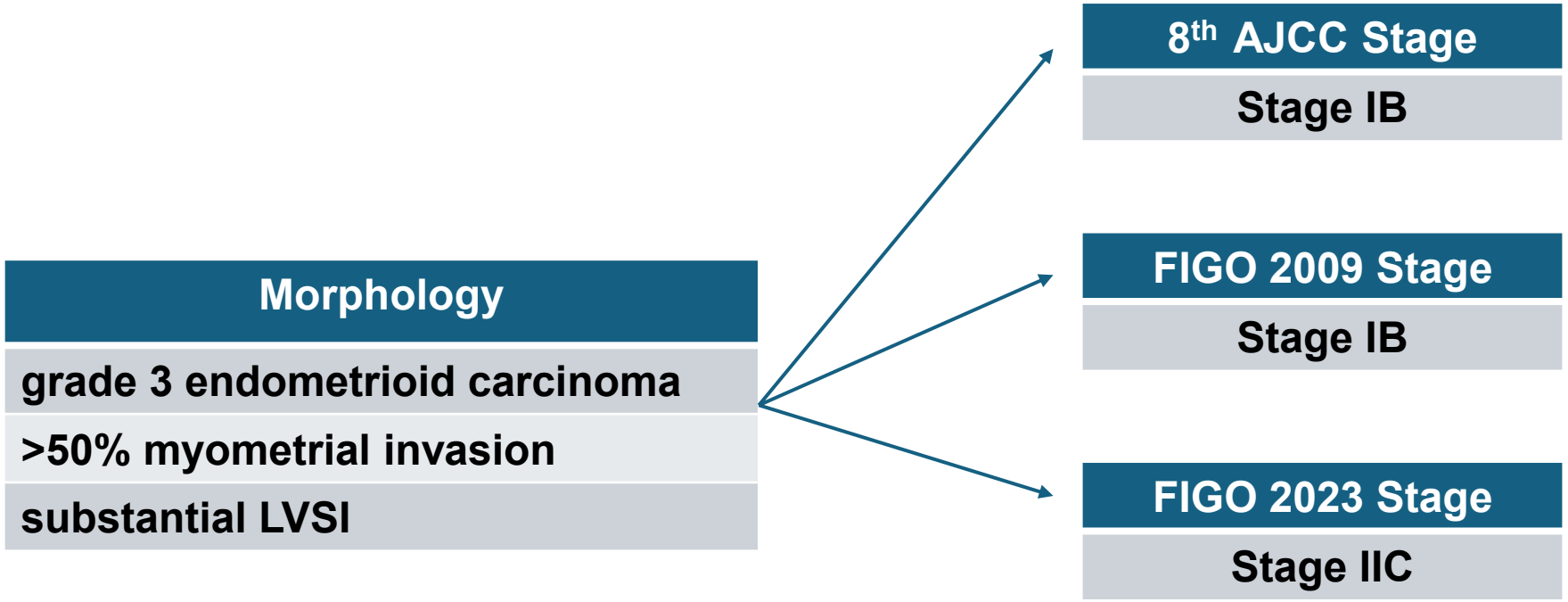

FIGO 2023 Endometrial Cancer: Molecular Staging

Clear Documentation of Staging System in Pathology Report is Essential to Avoid Confusion

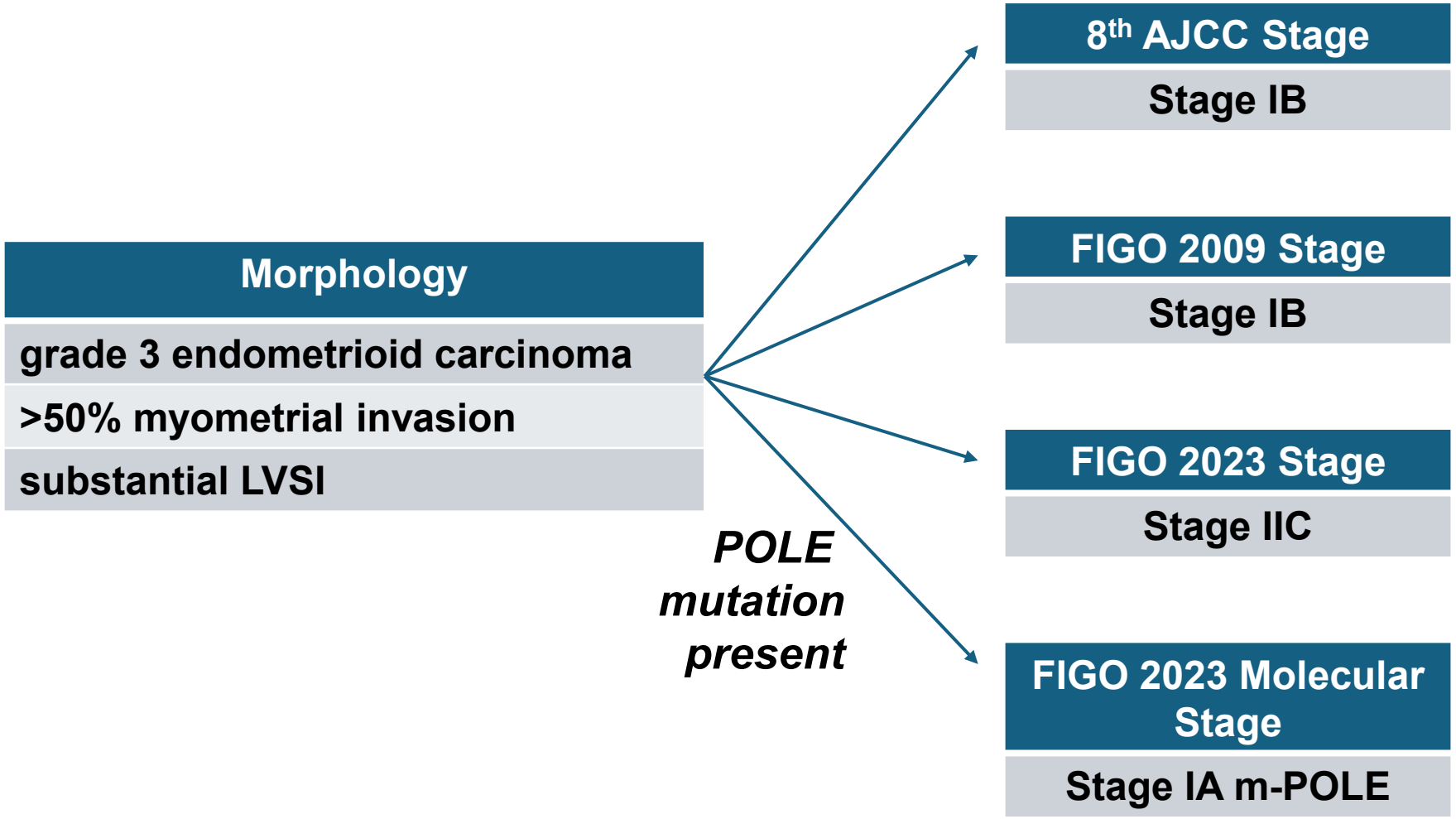

FIGO 2023 Staging of Endometrial Cancer

Take-away Points

- **For standardization, use the FIGO 2023 versions of the definitions of criteria**
  - Use ISGyP consensus recommendations on staging to guide uncertain scenarios

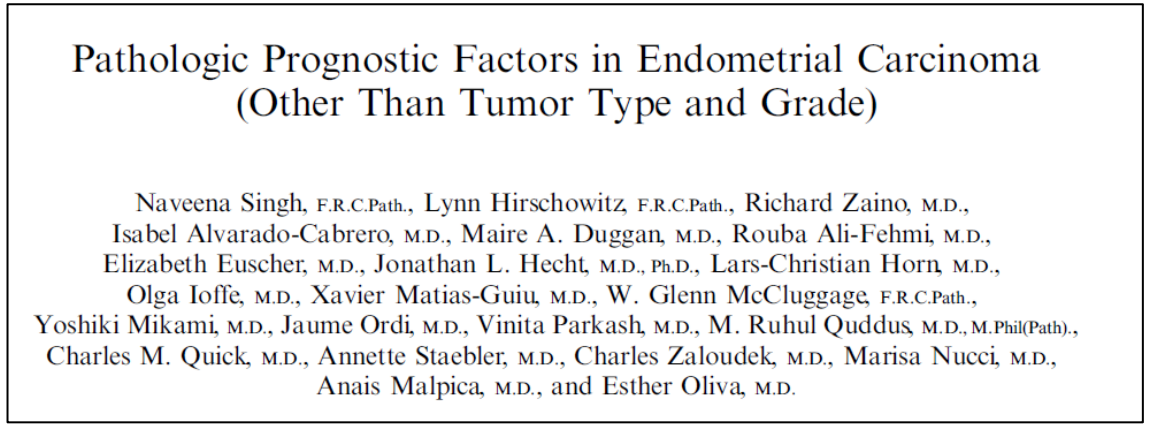

Pathologic Prognostic Factors in Endometrial Carcinoma
(Other Than Tumor Type and Grade)

Naveena Singh, F.R.C.Path., Lynn Hirschowitz, F.R.C.Path., Richard Zaino, M.D., Isabel Alvarado-Cabrero, M.D., Maire A. Duggan, M.D., Rouba Ali-Fehmi, M.D., Elizabeth Euscher, M.D., Jonathan L. Hecht, M.D., Ph.D., Lars-Christian Horn, M.D., Olga Ioffe, M.D., Xavier Matias-Guiu, M.D., W. Glenn McCluggage, F.R.C.Path., Yoshiki Mikami, M.D., Jaume Ordi, M.D., Vinita Parkash, M.D., M. Ruhul Quddus, M.D., M.Phil(Path)., Charles M. Quick, M.D., Annette Staebler, M.D., Charles Zaloudek, M.D., Marisa Nucci, M.D., Anais Malpica, M.D., and Esther Oliva, M.D.

PMID: 30550486

- **Use clear documentation in reports of the specific staging system used**

Outline of Talk

- Overview of FIGO 2023 staging system for endometrial cancer
- Practical approach to potentially challenging “new” staging variables

Stage I/II

- Aggressive mimics of non-aggressive histotypes
- Quantifying lymphovascular space invasion

Stage III/IV

- Defining sub-serosal tumor
- Synchronous endometrial and ovarian tumor

- Molecular staging pitfalls

