Luteinized Ovarian Tumors

Joseph Rabban MD MPH
Professor
Director of Gynecologic Pathology
UCSF Pathology Department

UCSF
University of California
San Francisco

UCSF PATHOLOGY

Outline of Talk

- **Luteinized sex cord stromal tumor (AGCT, thecoma)**
- **Steroid cell tumor: risk stratification**

Case 1

Clinical History

- **Unilateral ovarian mass in a 52 year old.**
- **8 cm solid, lobulated and yellow/orange *("luteinized")***

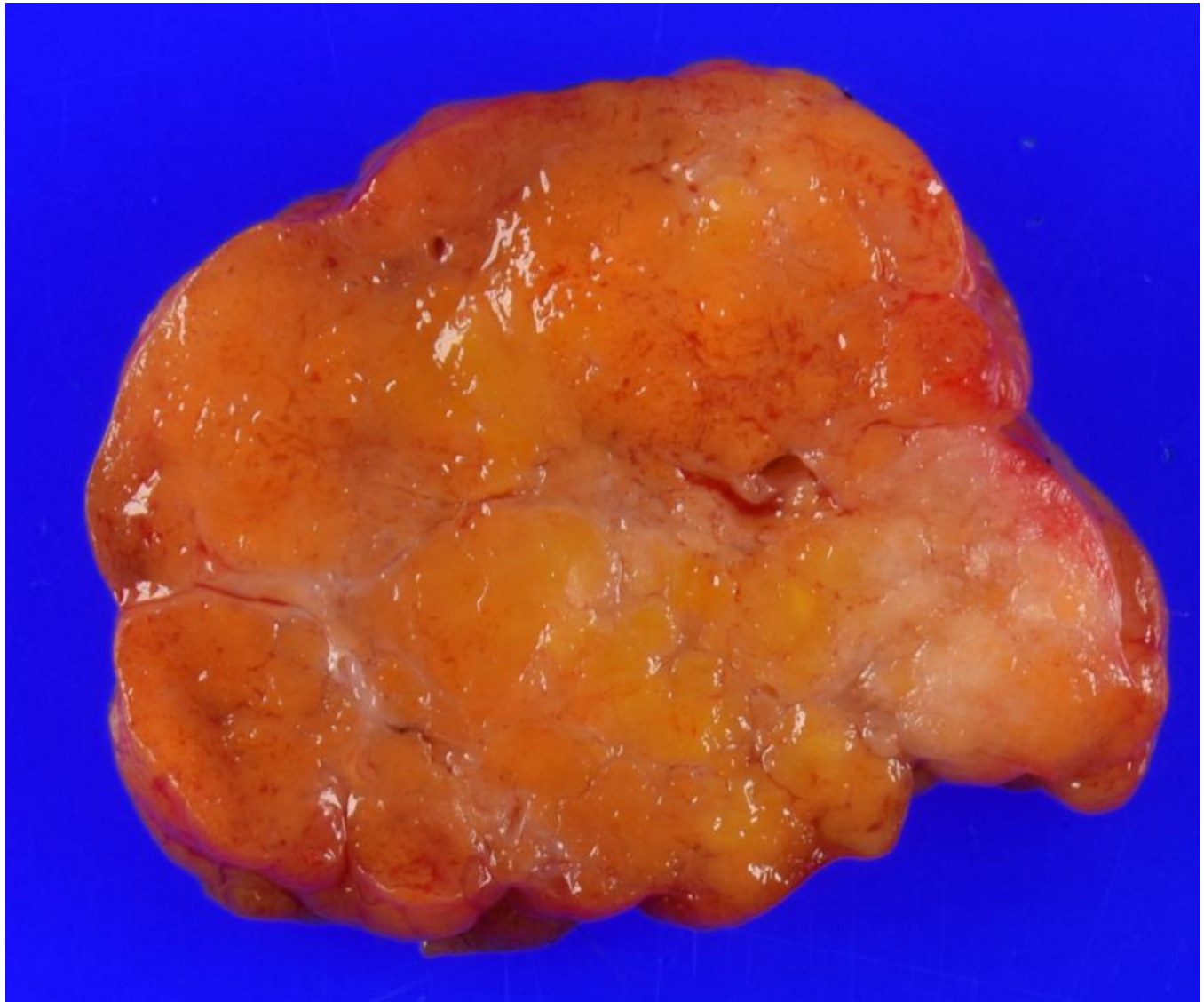

“Luteinized”

What does this mean ?

Latin term “luteum / luteus” = yellow

Reseda luteola *(“dyer’s weed”)*

native to Europe/Western Asia



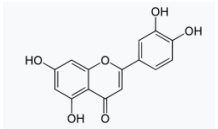

Natural plant dye to make yellow color



“Luteinized”

What does this mean ?

Lutein

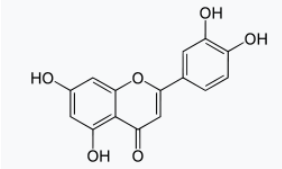

- **Yellow pigment synthesized by plants** (yellow carrots, spinach, kale)
- **Member of xanthophyll (carotenoids) family** (Greek “xanthos” = yellow)

In animals, a byproduct of ingested plants







“Luteinized”

What does this mean ?





“Luteinized”

What does this mean ?








Grain-fed
Grass-fed

“Luteinized”

Corpus luteum of ovary = “yellow body”

- **Luteal phase of menstrual cycle**
- **Ovarian granulosa cells produce steroids** (progesterone, estrogen, inhibinA)
  - Abundant eosinophilic cytoplasm

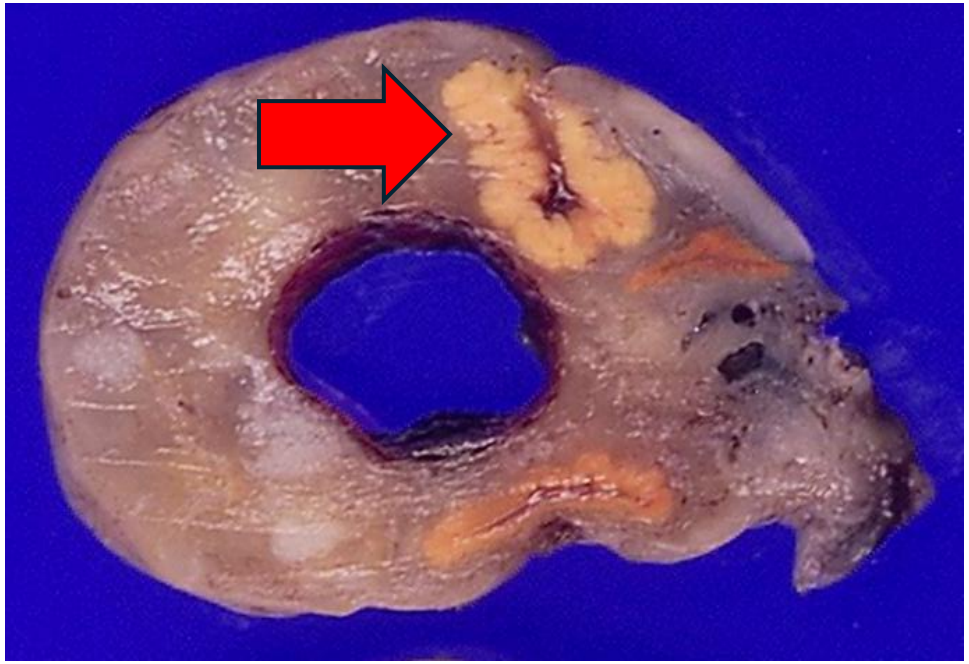

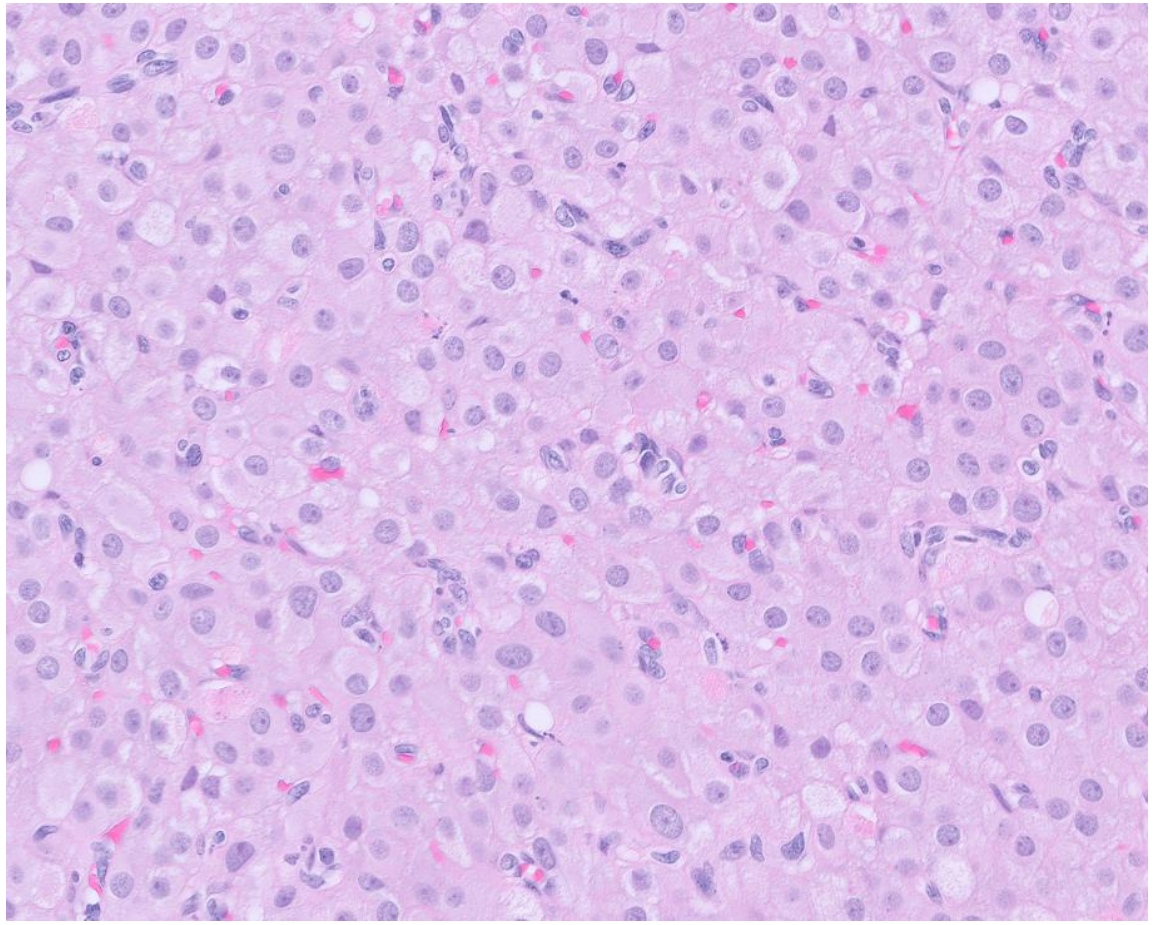

“Luteinized”

Macroscopic pathology = yellow – orange – red/brown

Differential diagnosis: steroid-rich entities

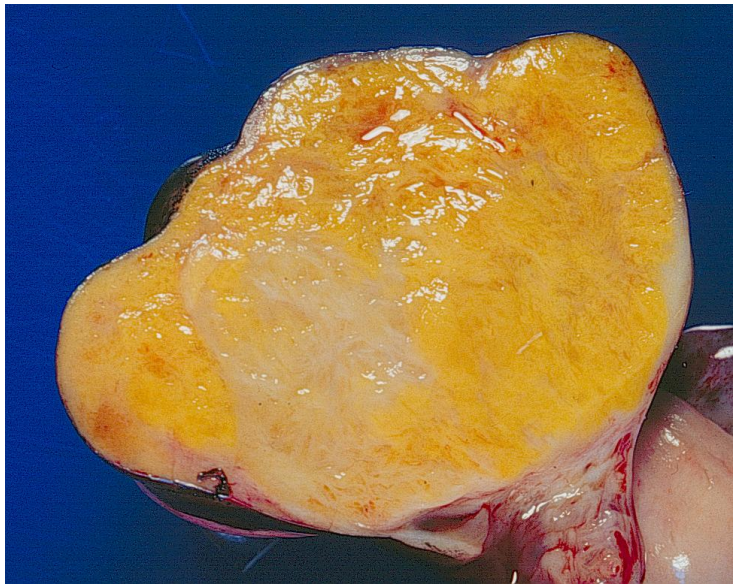

Thecoma



Steroid cell tumor

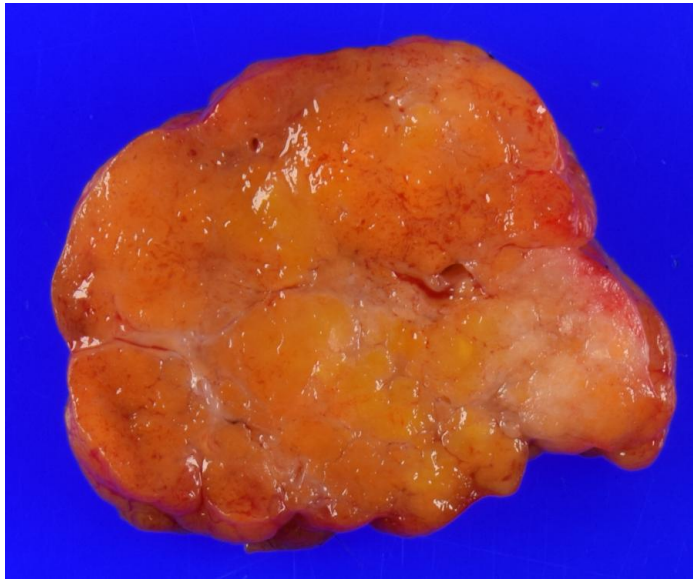

Luteinized AGCT

“Luteinized”

Macroscopic pathology = “Mahogany brown” (dark red-brown)

Differential diagnosis: steroid-rich entities

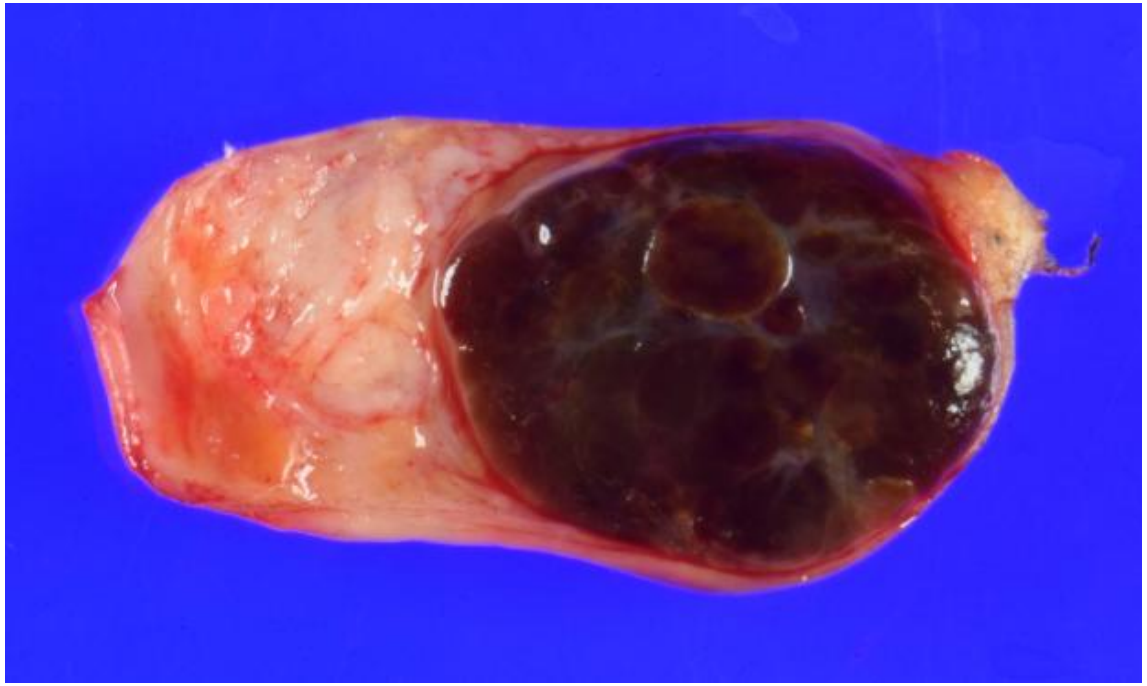

Leydig cell tumor

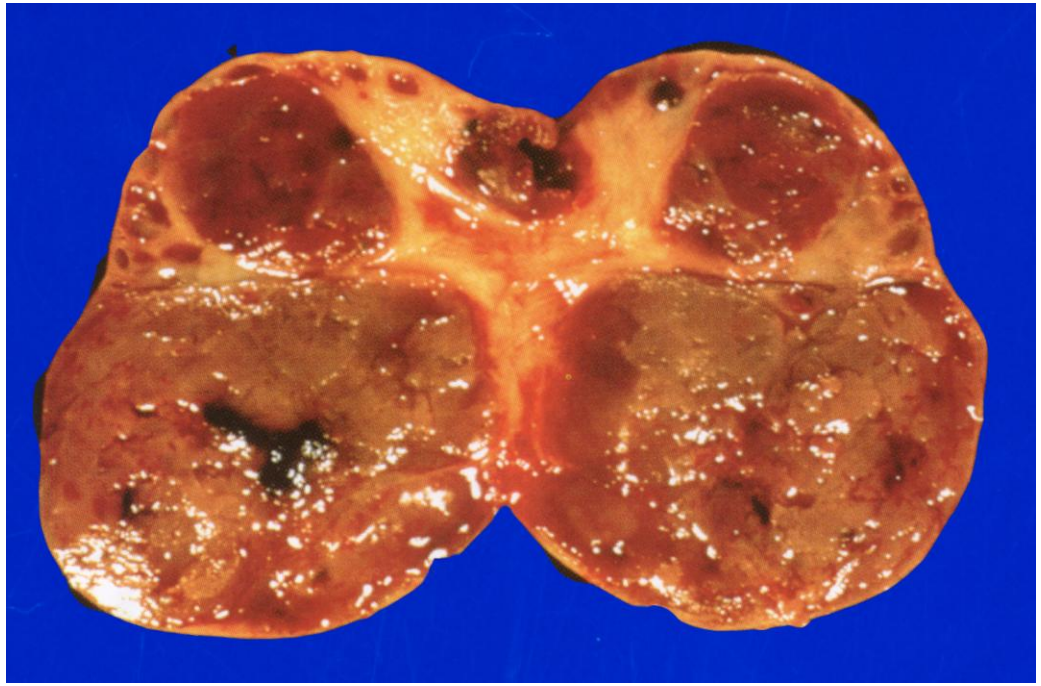

Pregnancy luteoma

Luteinized cells: abundant eosinophilic, granular cytoplasm

Independent of neoplastic/non-neoplastic classification

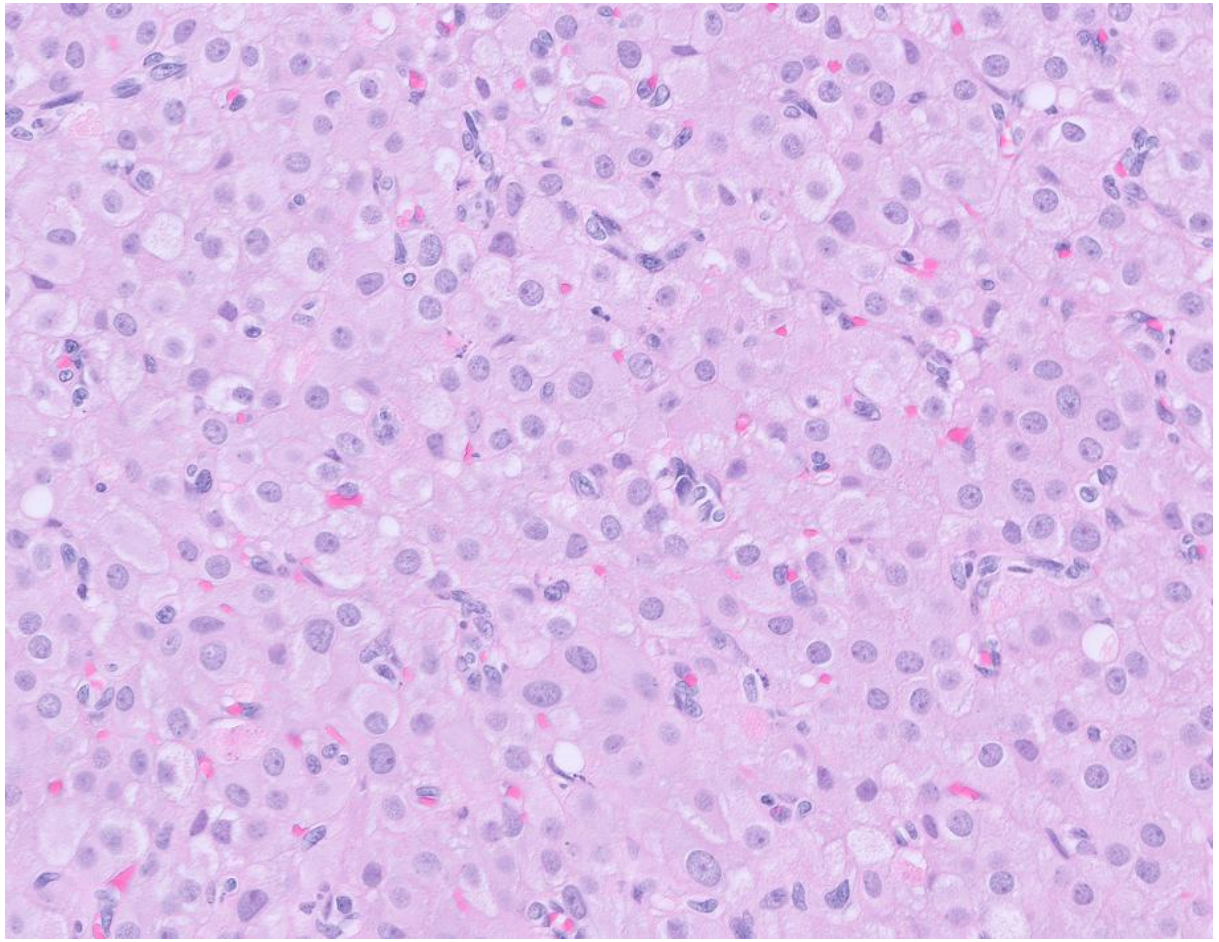

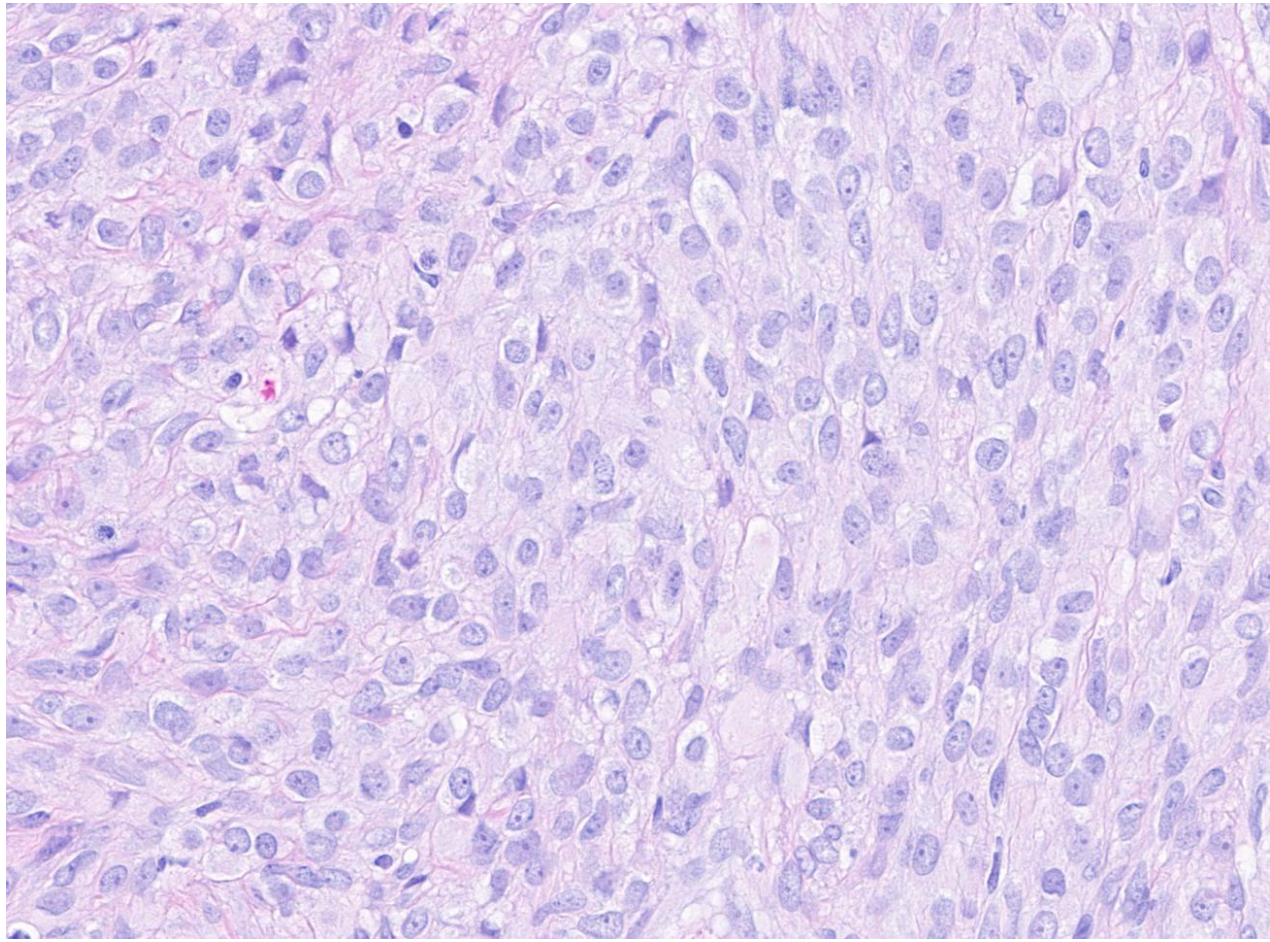

Luteinized cells: abundant eosinophilic, granular cytoplasm

Synonyms in other cell types and other anatomic sites

▪ **Luteinized**	▪ Steroid-rich ovarian sex cord-stromal pathology
▪ **Decidualized**	▪ Progestin / gestational hormone-induced endometrial stromal or mesothelial pathology
▪ **Epithelioid**	▪ Mesenchymal (smooth muscle, endometrial stroma), trophoblastic pathology
▪ **Oxyphilic**	▪ Abundant “acidophilic” eosinophilic cytoplasm in endometrioid or clear cell carcinoma
▪ **Hepatoid**	▪ Yolk sac tumor, hepatoid pattern

▪ **Oncocytic**	▪ Mitochondia-rich cytoplasm (oncocytoma)
▪ **Granular**	▪ Lysosome rich cytoplasm of granular cell tumor
▪ **Rhabdoid**	▪ Skeletal muscle tumors

Case 1

Multiple rounded lobules

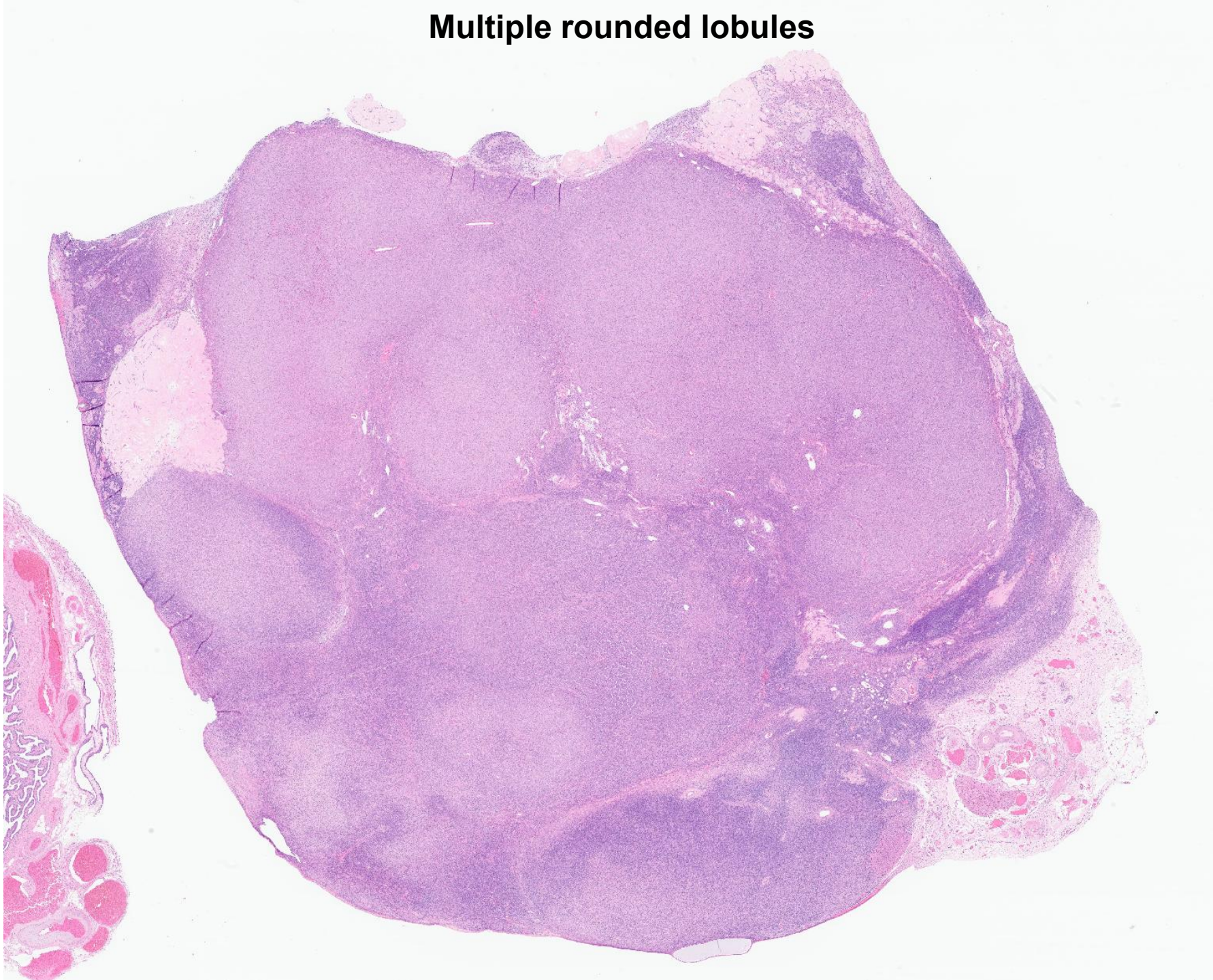

Case 1

Vague nested pattern

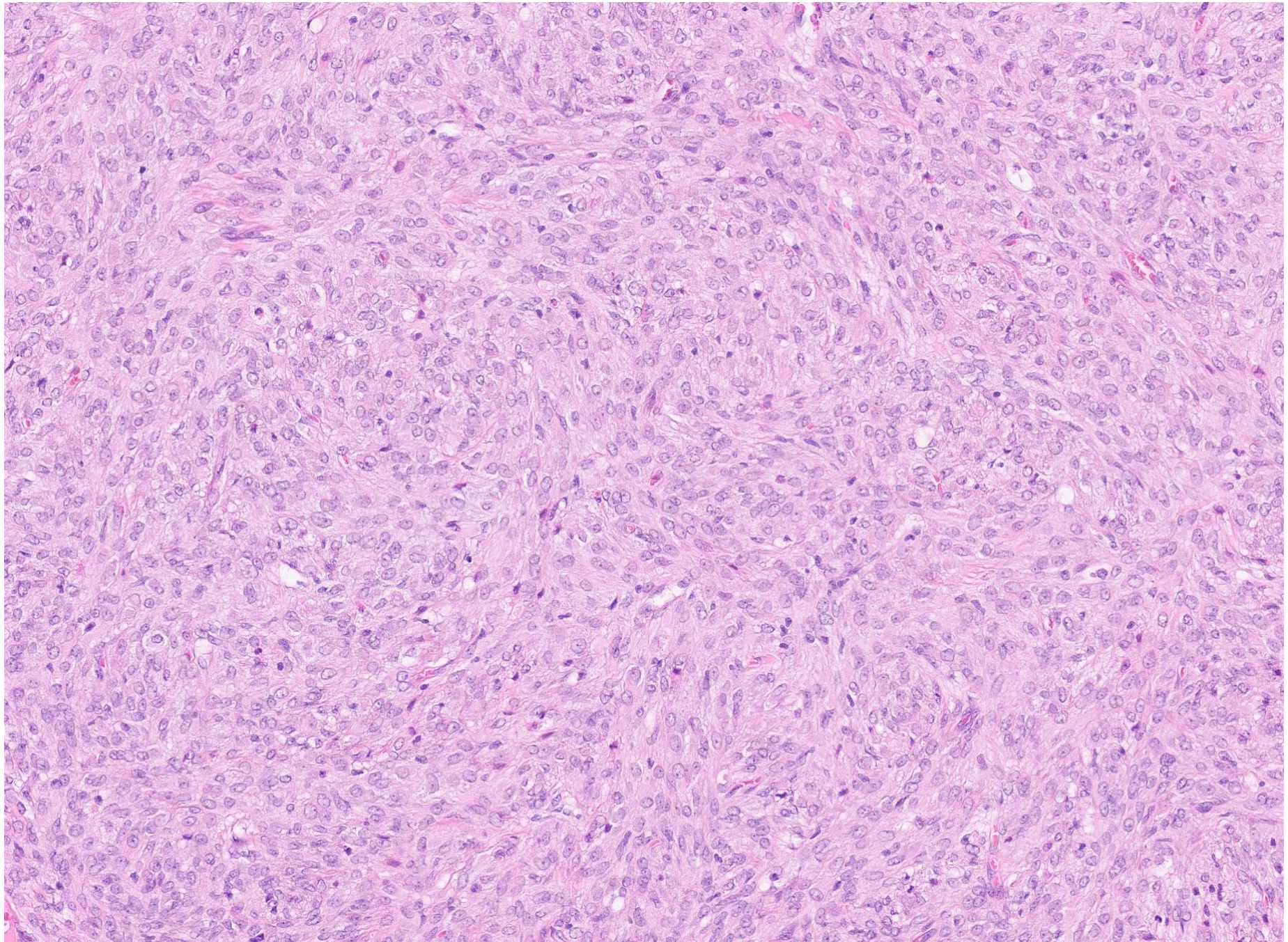

Case 1

Vague fascicular pattern

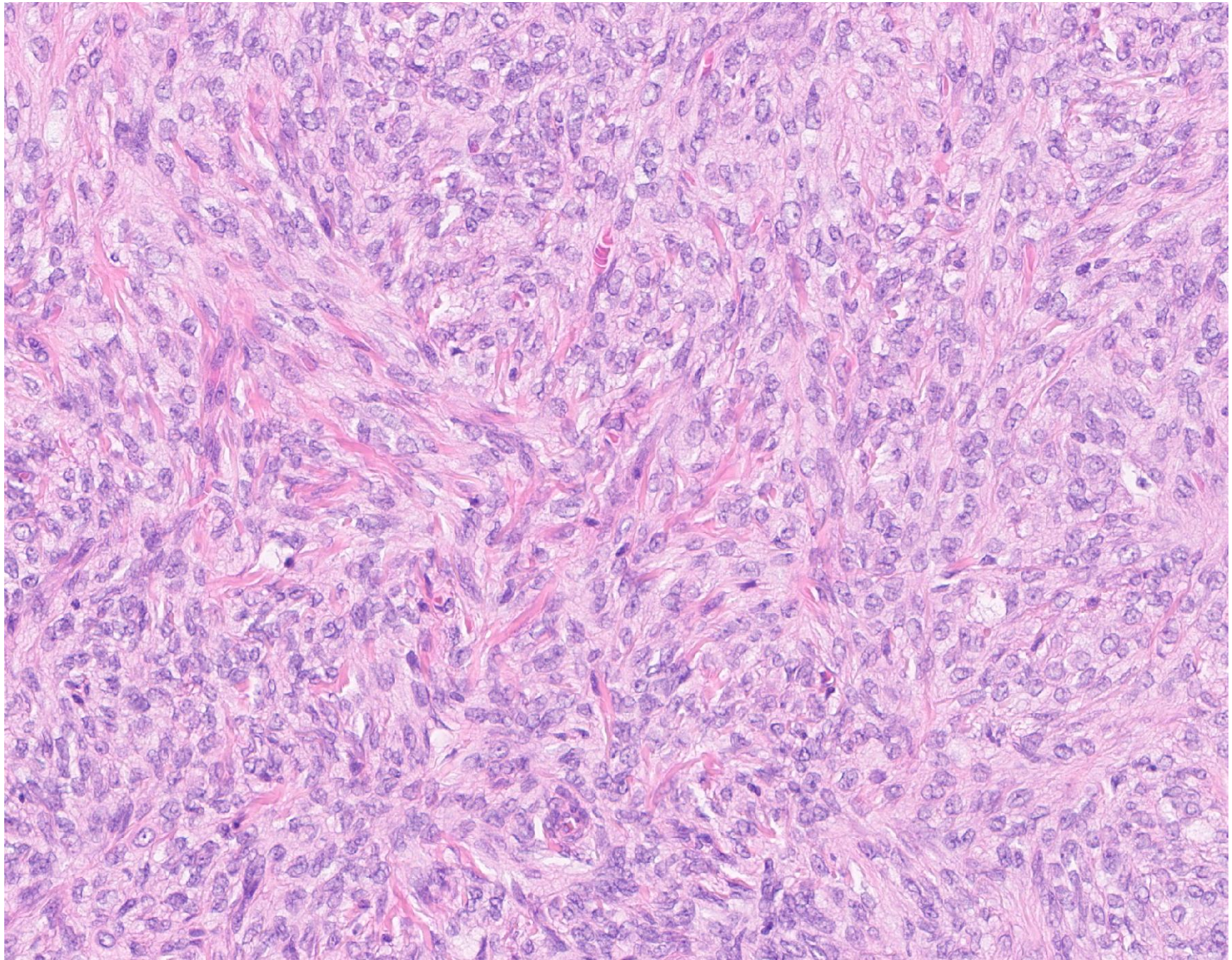

Case 1

Plump epithelioid cells, bland nuclei

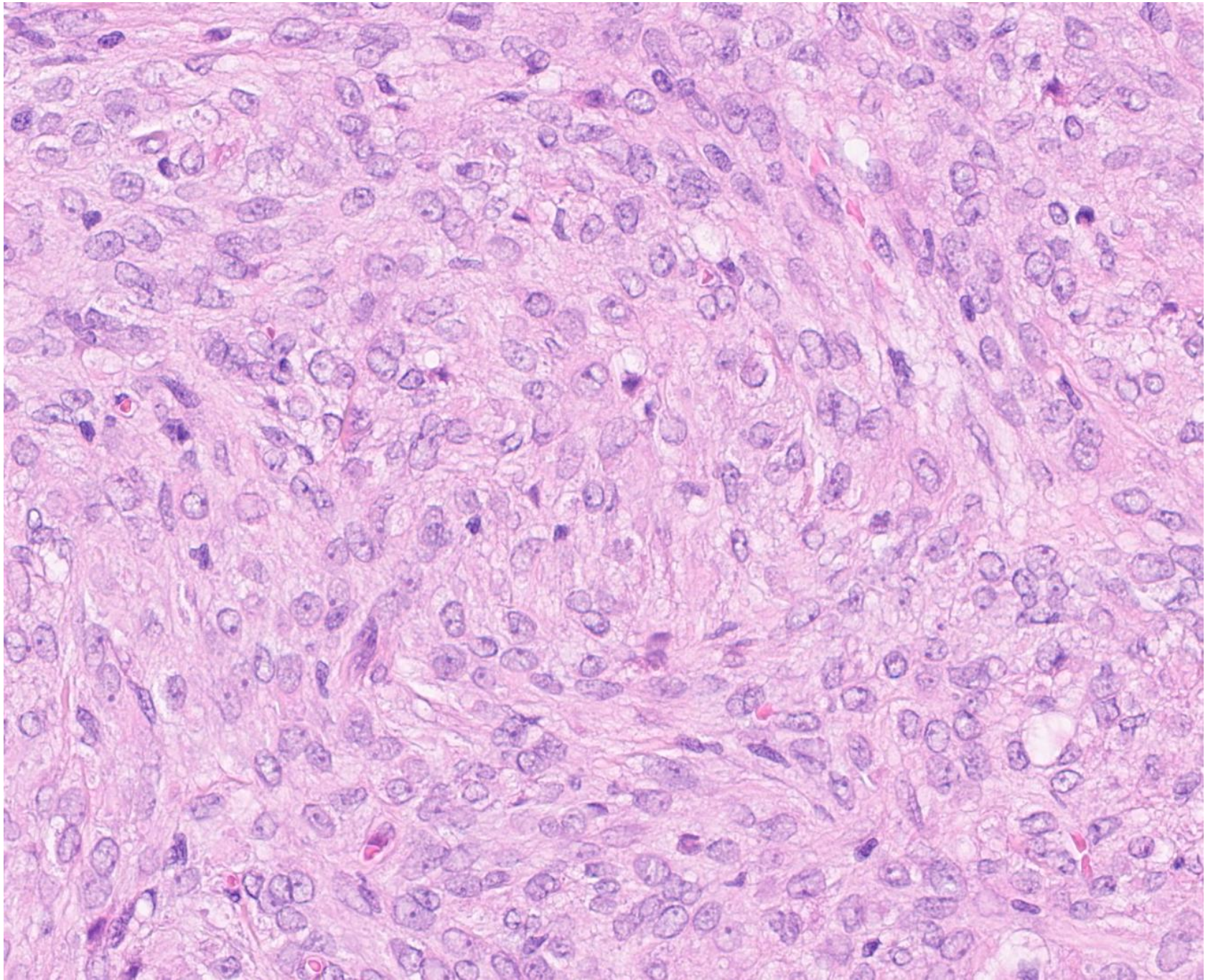

Epithelioid pattern ovarian tumors: *Differential Diagnosis*

Epithelial Tumors

- Brenner tumor
- Endometrioid carcinoma
- Oxyphilic clear cell carcinoma
- Squamous cell carcinoma
- Metastatic carcinoma

Germ Cell Tumors

- Insular carcinoid
- Hepatoid yolks sac tumor

Sex Cord Stromal Tumors

- Thecoma
- AGCT, luteinized type
- Steroid cell tumor
- Leydig cell tumor
- Pregnancy luteoma

Mesenchymal Tumors

- PEComa
- Epithelioid endometrial stromal sarcoma
- Epithelioid smooth muscle tumor
- Epithelioid GIST

Other Cell Type Tumors

- Deciduoid mesothelioma
- Melanoma
- Large cell small cell carcinoma, hypercalcemic type
- Trophoblastic tumor

Major Ovarian Tumor Families

Immunohistochemistry

Epithelial Tumors

↓

EMA

Malignant Germ Cell Tumors

↓

SALL4

Sex Cord-Stromal Tumors

↓

FOXL2*
Calretinin
Inhibin
SF1

***except steroid cell tumors**

PMID: 23240671

Major Ovarian Tumor Families

Immunohistochemistry

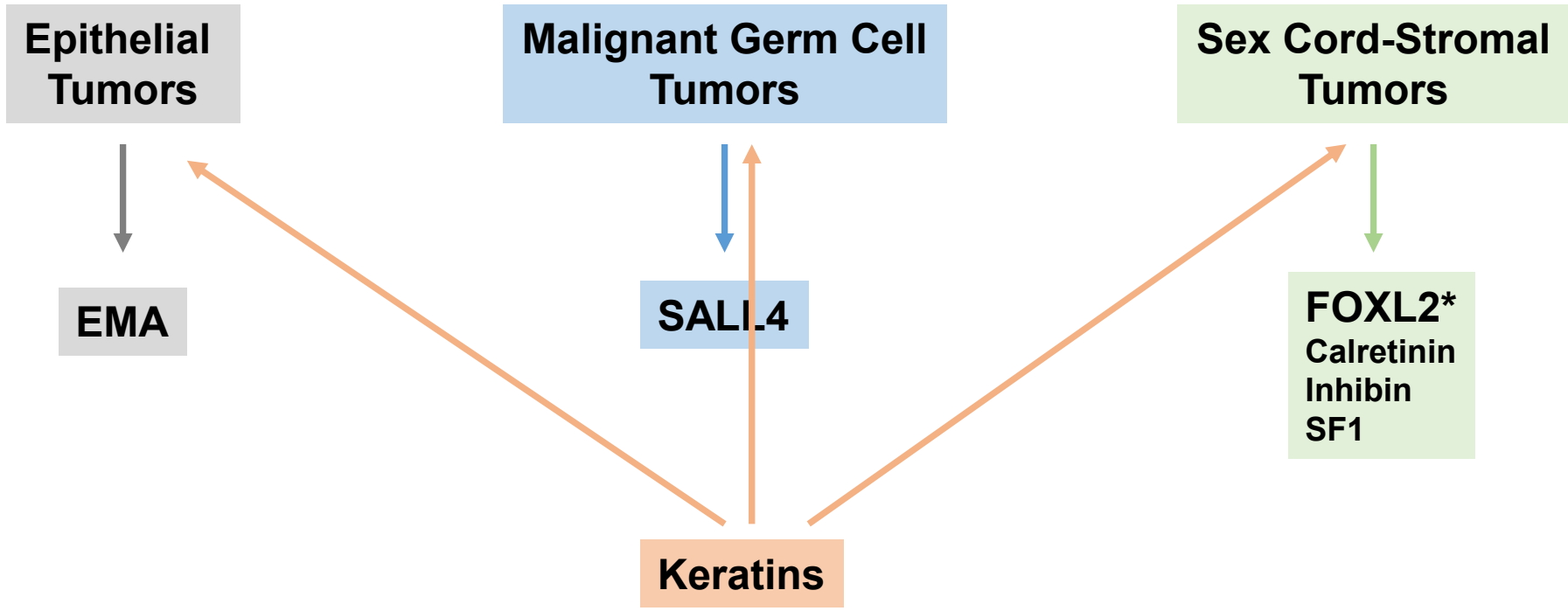

Caution advised using keratins to confirm "epithelial differentiation"
EMA is much more specific for this purpose

***except steroid cell tumors**

PMID: 23240671

Sex Cord-Stromal Family Immunohistochemistry

- ***Keratin can be positive in AGCT***
- ***Use EMA instead to exclude carcinoma***

Keratin positive AGCT

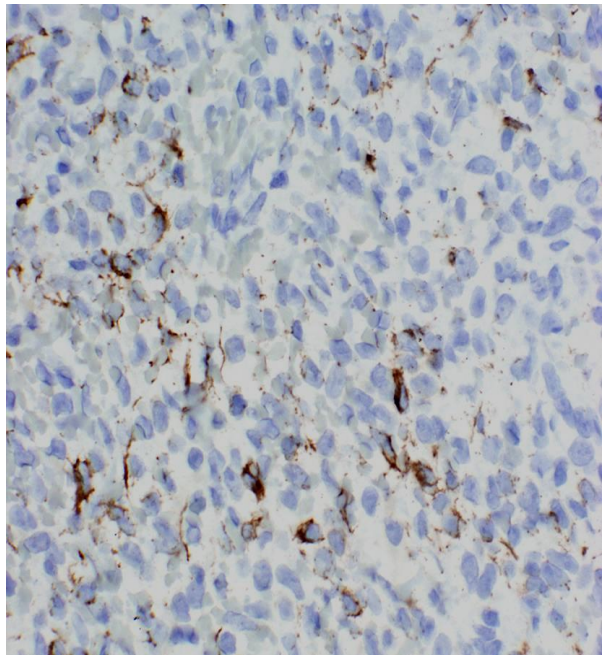

Keratin positive AGCT

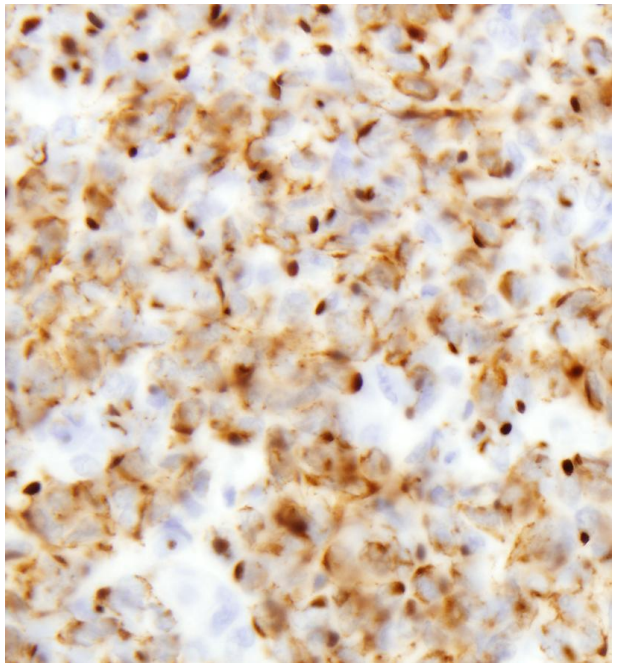

Keratin positive AGCT

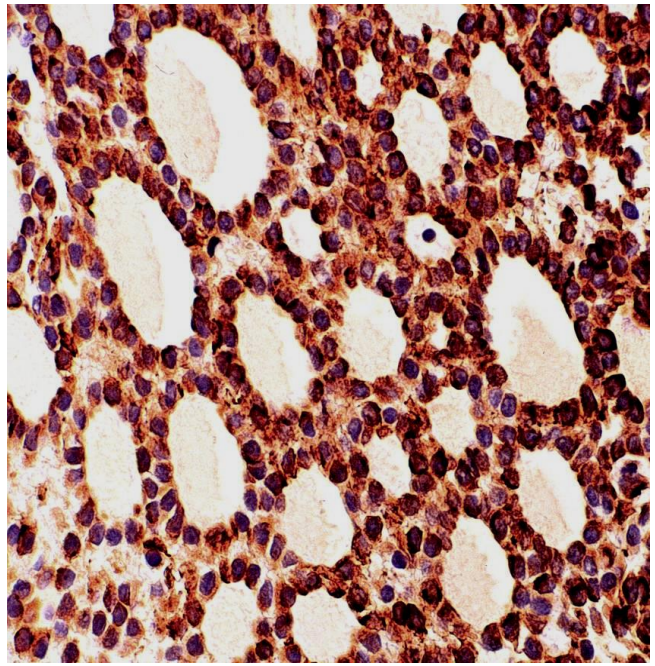

Sex Cord-Stromal Family Immunohistochemistry

Inhibin, calretinin

- **Variable sensitivity;** can be negative
- **Variable distribution / intensity**

- *Negative* **in microcystic stromal tumor**
- *Positive* **in mesothelial lesions**

Adult Granulosa Cell Tumor

Inhibin

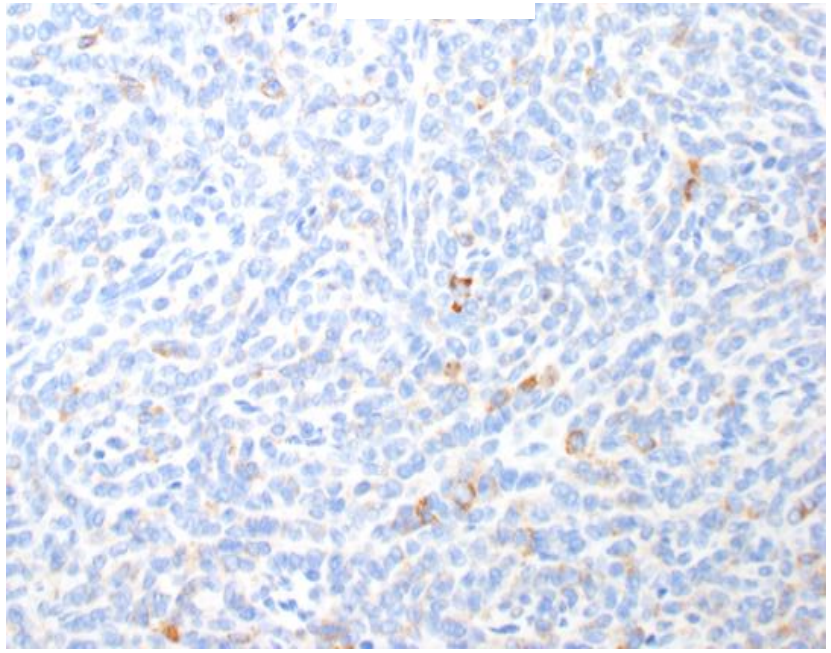

Calretinin

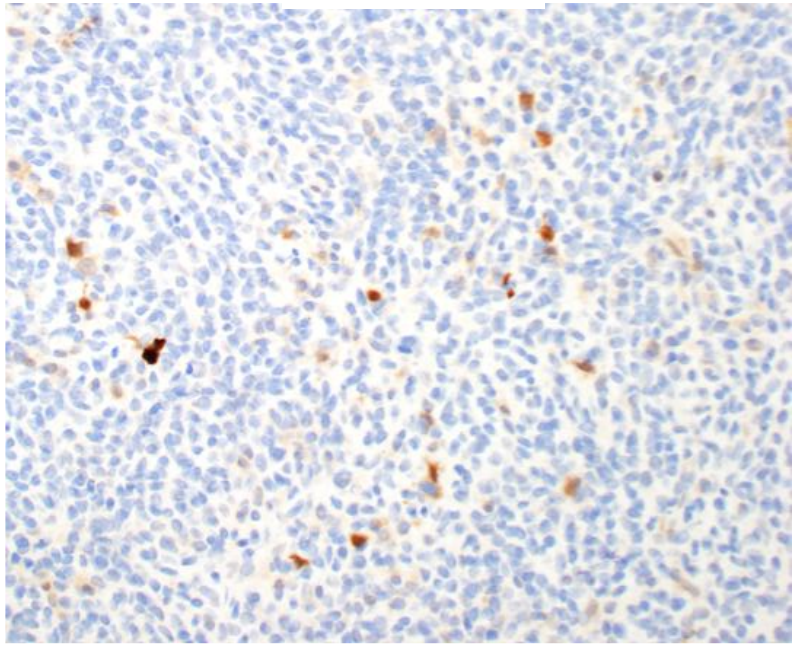

Sex Cord-Stromal Family Immunohistochemistry

SF-1

- **Nuclear pattern**
- **Highly sensitive for all sex cord stromal differentiation**
  (normal, benign, malignant entities)

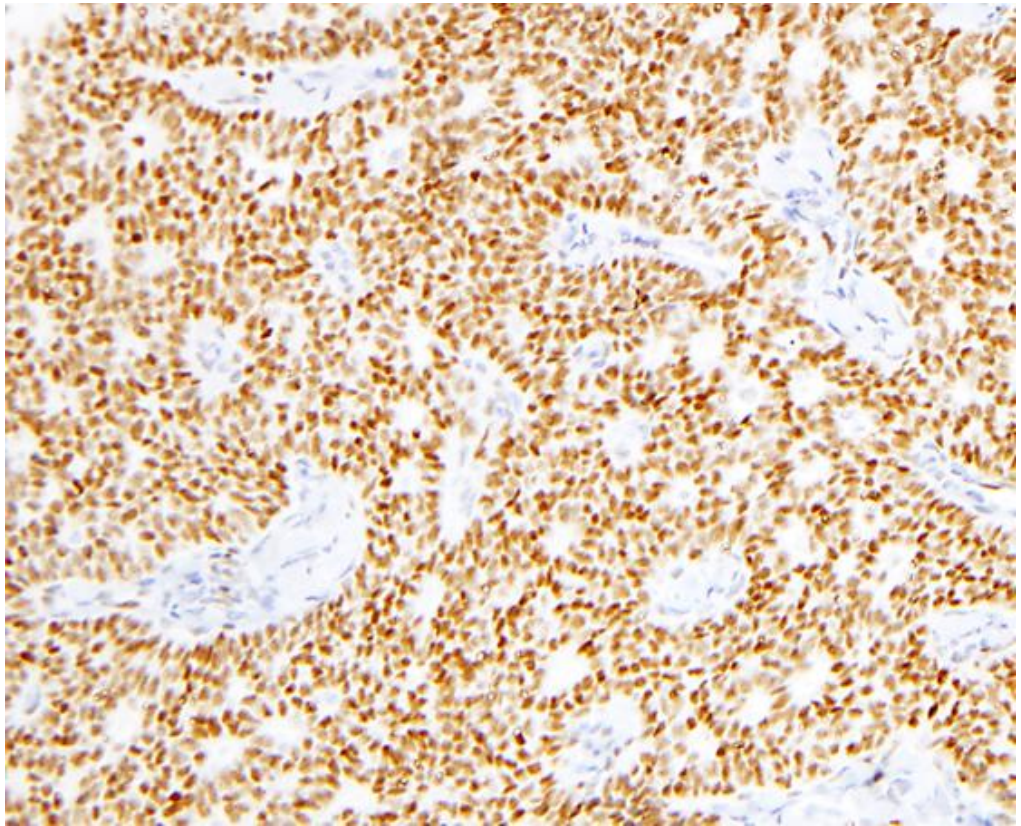

FOXL2

- **Nuclear pattern**
- **Same as SF1 <u>except:</u>**
  <u>negative</u> in all steroid cell differentiation
  (normal, benign, malignant entities)

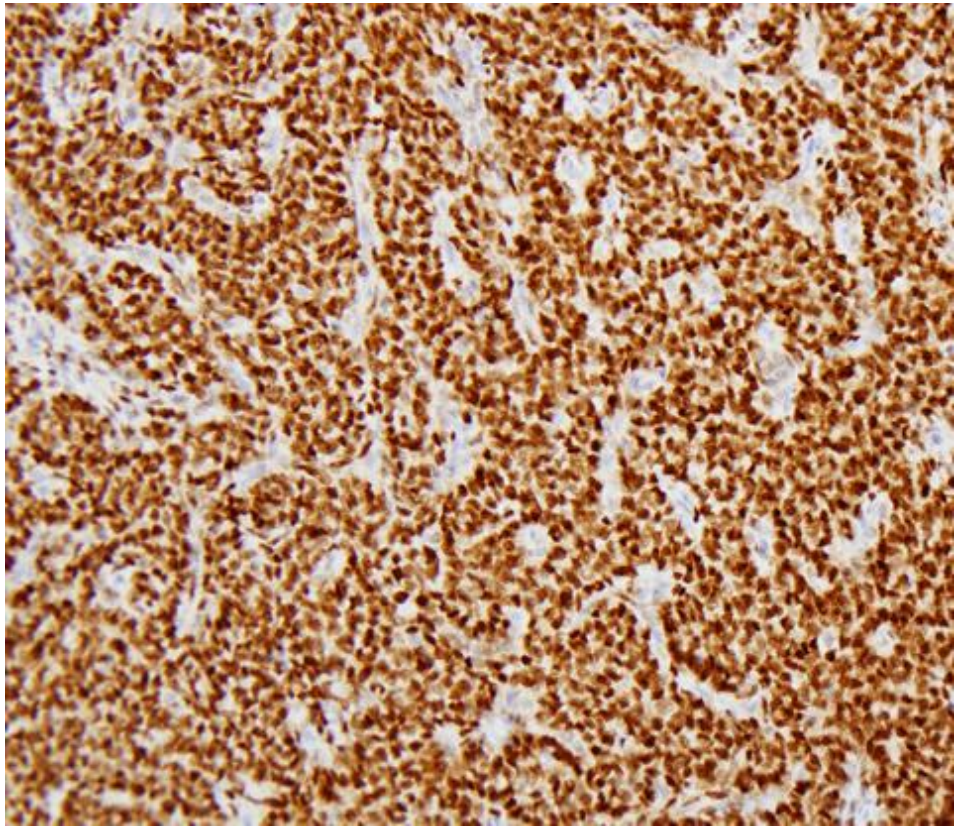

Sex Cord-Stromal Family Immunohistochemistry

<u>Exceptions</u> to the Rule of Positive Inhibin-Calretinin-SF1-FOXL2

Inhibin-Calretinin negative

FOXL2 negative

Sex cord-stromal tumours

Pure stromal tumours

- Ovarian fibroma
- Thecoma
- Luteinized thecoma associated with sclerosing peritonitis
- Sclerosing stromal tumour
- Microcystic stromal tumour
- Signet-ring stromal tumour
- Leydig cell tumour
- Steroid cell tumour
- Ovarian fibrosarcoma

Pure sex cord tumours

- Adult granulosa cell tumour
- Juvenile granulosa cell tumour
- Sertoli cell tumour
- Sex cord tumour with annular tubules

Mixed sex cord-stromal tumours

- Sertoli-Leydig cell tumour
- Sex cord-stromal tumour NOS
- Gynandroblastoma

Case 1

Immunohistochemistry

Inhibin

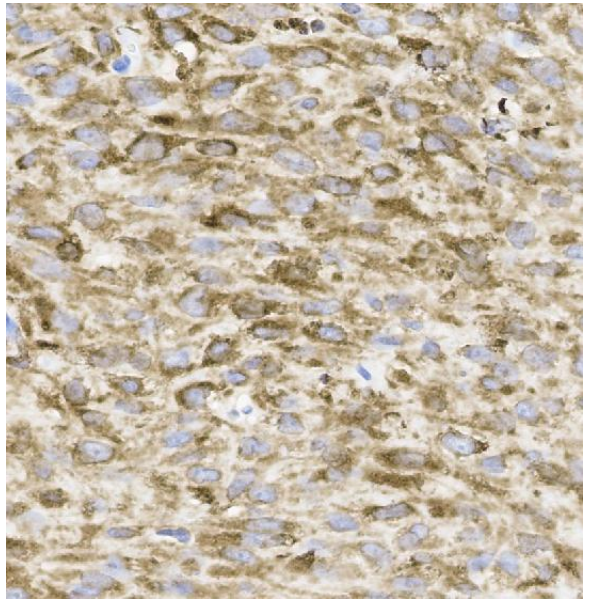

Calretinin

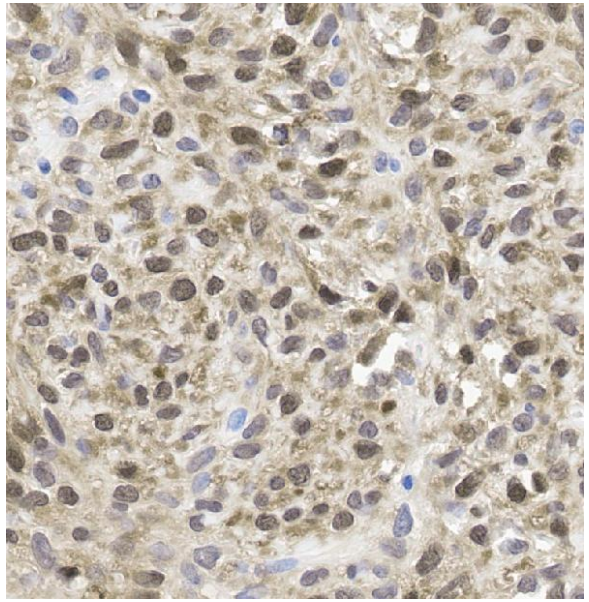

SF1

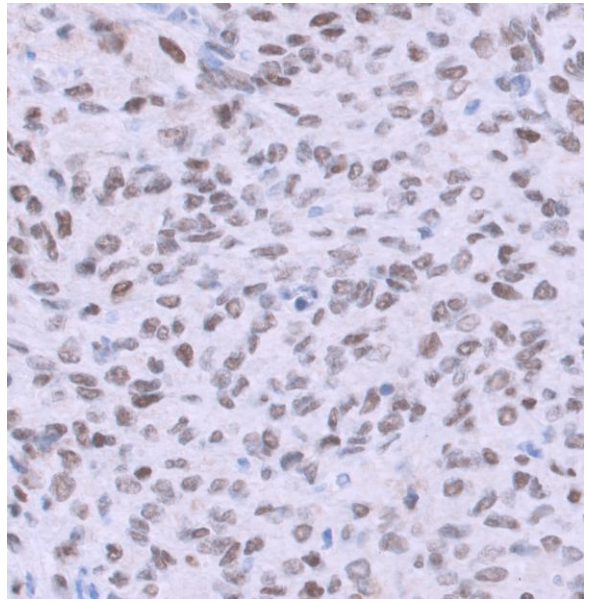

FOXL2

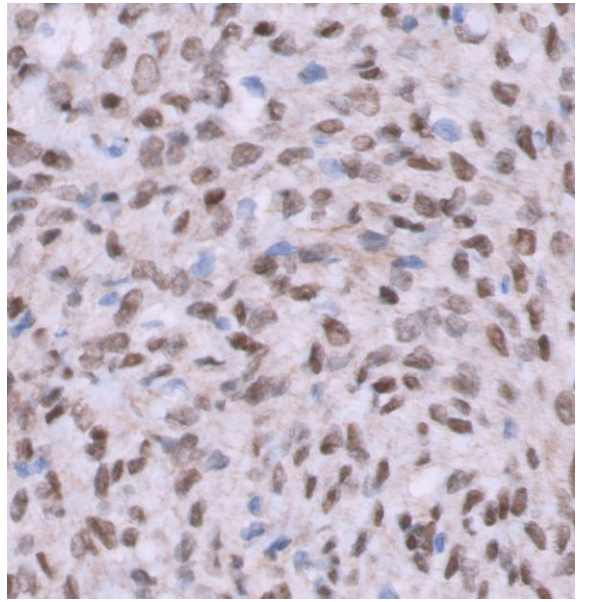

Case 1

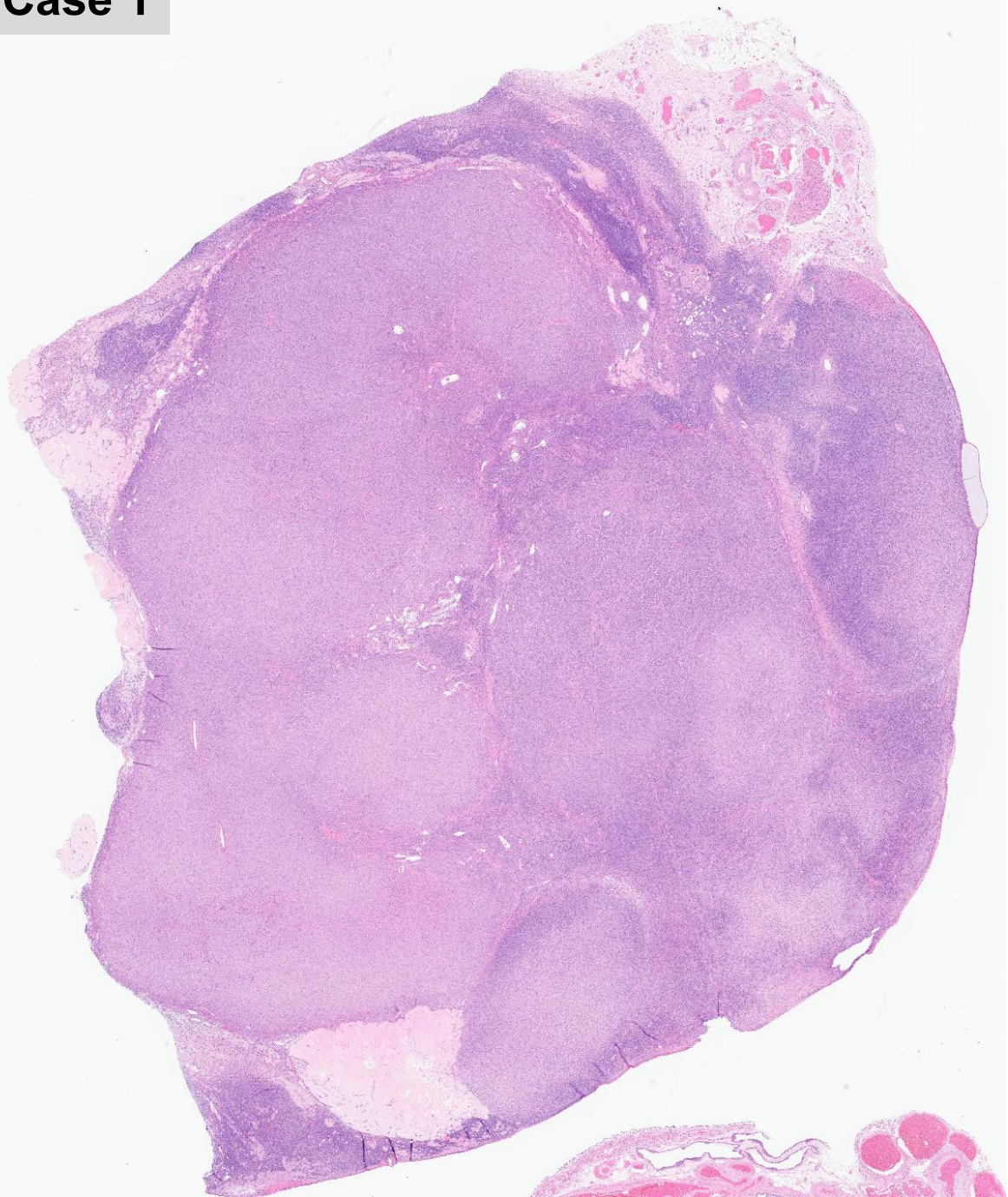

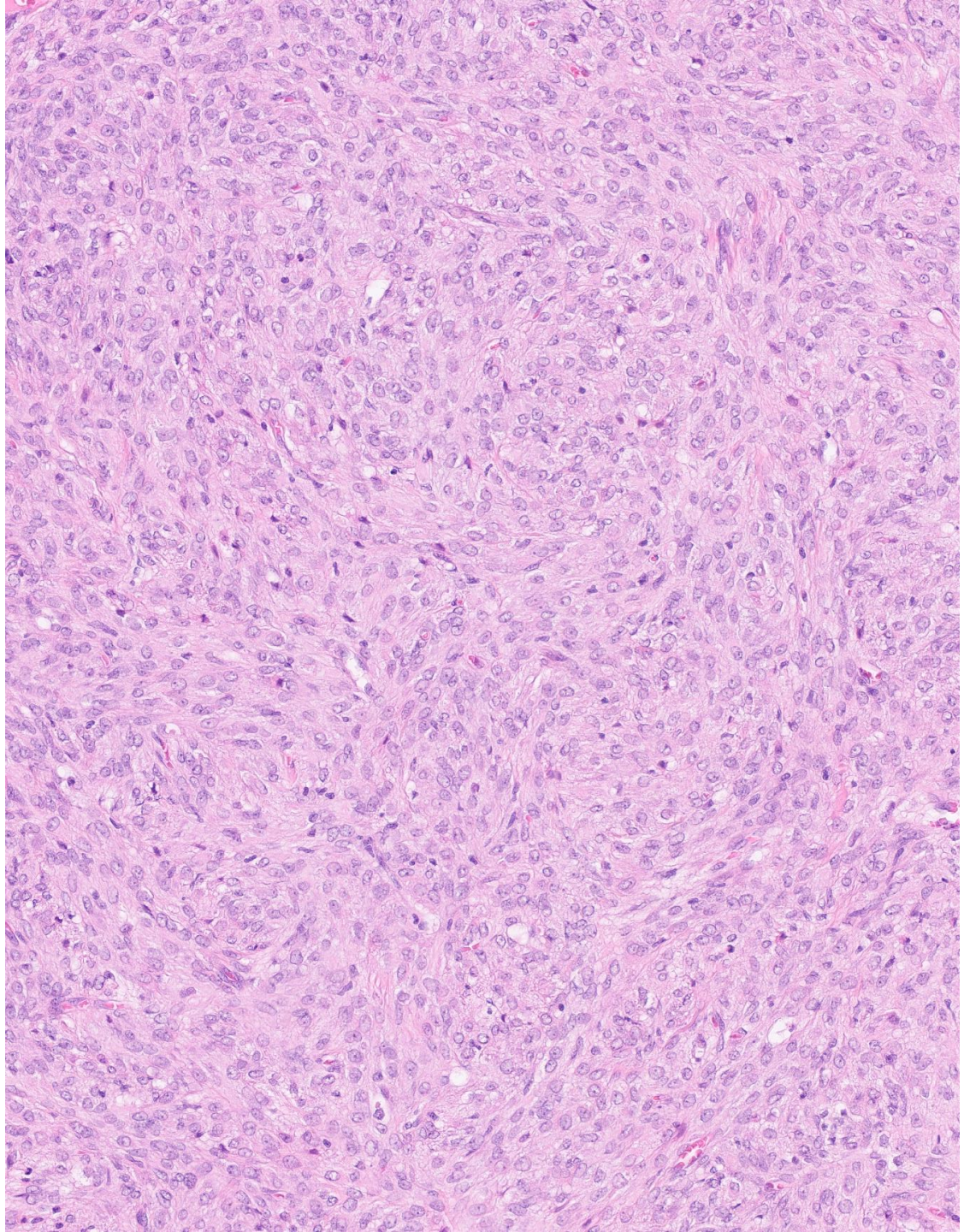

Case 1

Differential Diagnosis:

- Thecoma
- Luteinized variant of Adult Granulosa Cell Tumor

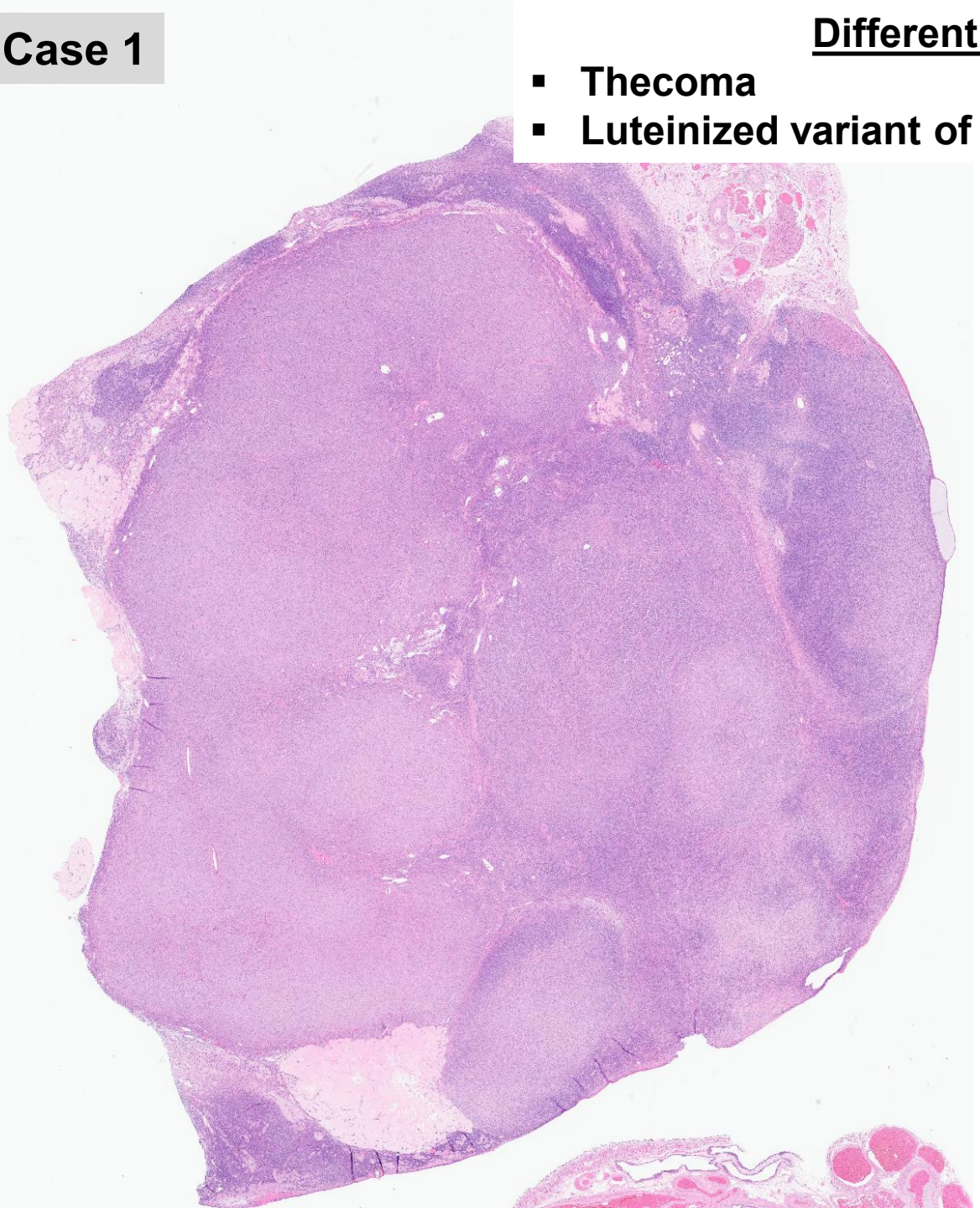

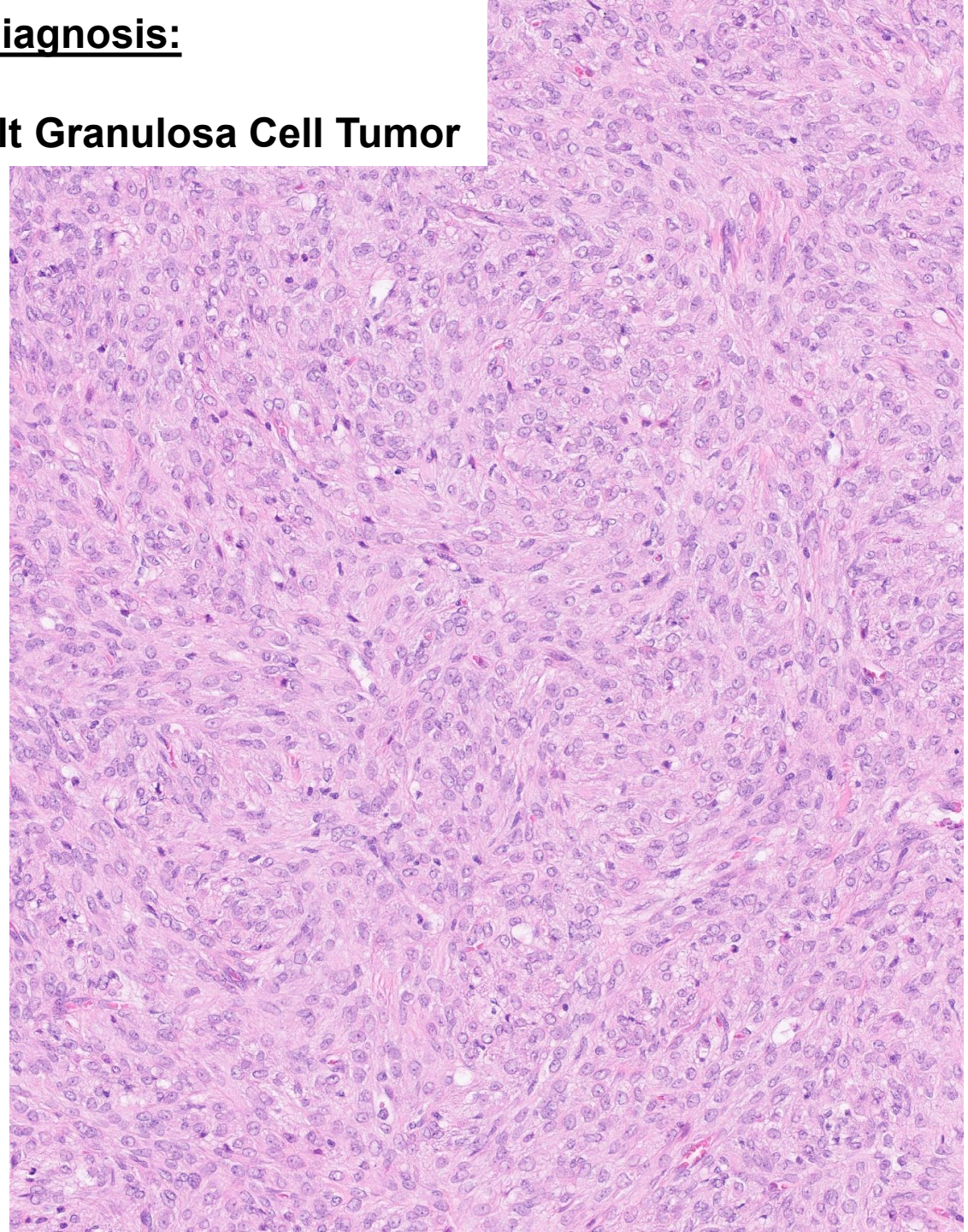

Reticulin Stain

	Pericellular Reticulin Fibers
Fibroma and Thecoma	▪ Present
Adult Granulosa Cell Tumor	▪ Completely absent ▪ Patchy areas of absence ▪ ”Broken” fibers

History of Staining for Reticulin

- "Net-like" reticular fibers in connective tissues described by Mall in 1891
- Material called "reticulin" isolated from those fibers by Siegfried in 1892

Latin words "rete", "reticulum" = net



ÜBER DIE

CHEMISCHEN EIGENSCHAFTEN

DES

RETICULIRTEN GEWEBES.

HABILITATIONSSCHRIFT,

DURCH WELCHE

MIT ZUSTIMMUNG DER PHILOSOPHISCHEN FACULTÄT

DER

UNIVERSITÄT LEIPZIG

ZU SEINER

AM 6. DECEMBER NACHMITTAGS 3 UHR IM CZERMAKEION

ZU HALTENDEN

PROBEVORLESUNG:

„ÜBER DIE ZERSETZUNGEN DER EIWEISSKÖRPER"

EINLADET

DR. PHIL. MAX SIEGFRIED.

TIERSPITAL in BERN
No 1424
BIBLIOTHEK

LEIPZIG

DRUCK VON F. A. BROCKHAUS

1892.

History of Staining for Reticulin

- "Net-like" reticular fibers in connective tissues described by Mall in 1891
- Material called "reticulin" isolated from those fibers by Siegfried in 1892
- **Bielschowsky's silver stain for reticulin fibers introduced in 1905** PMID: 711512
- **Composed of type III collagen** (in contrast to type IV in basement membrane)
- **Contemporary reticulin stains are silver-based stains**

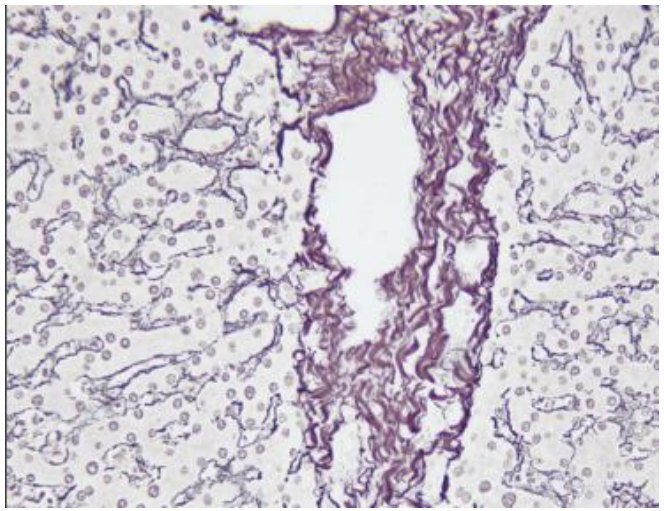

without counterstain

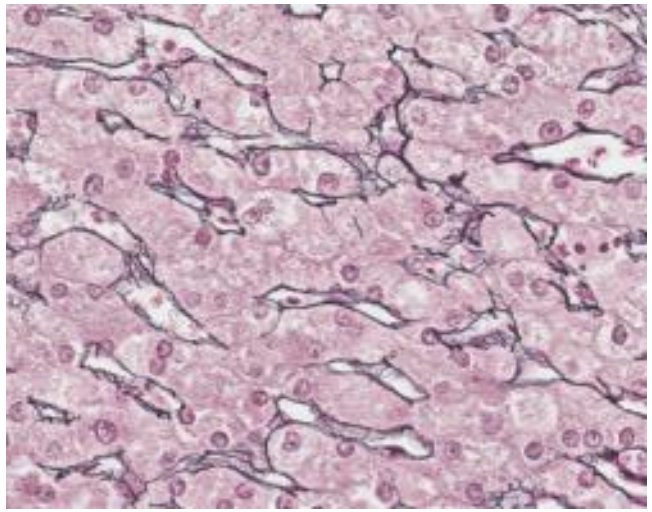

with counterstain

A STUDY OF THE RETICULUM AND OF LUTEINIZATION IN GRANULOSA AND THECA CELL TUMORS OF THE OVARY*

HERBERT F. TRAUT, M.D., ALBERTA KUDER, M.A., AND J. F. CADDEN, M.A., NEW YORK, N. Y.

(From the Department of Obstetrics and Gynecology, Cornell University Medical College and New York Hospital)

Am J Ob Gynecol. 1939; 38: 798-814

Foot's silver stain

Graafian follicle

Granulosa cell tumor

<u>Granulosa cells:</u>
Absence of pericellular reticulin fibers

<u>Theca cells:</u>
Presence of pericellular Reticulin fibers



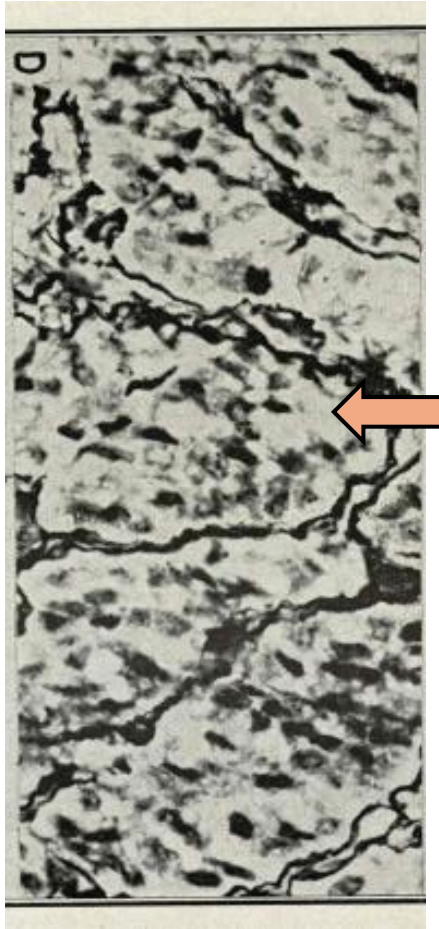

No pericellular reticulin fibers

Cellular Fibroma

Complete presence of pericellular reticulin fibers

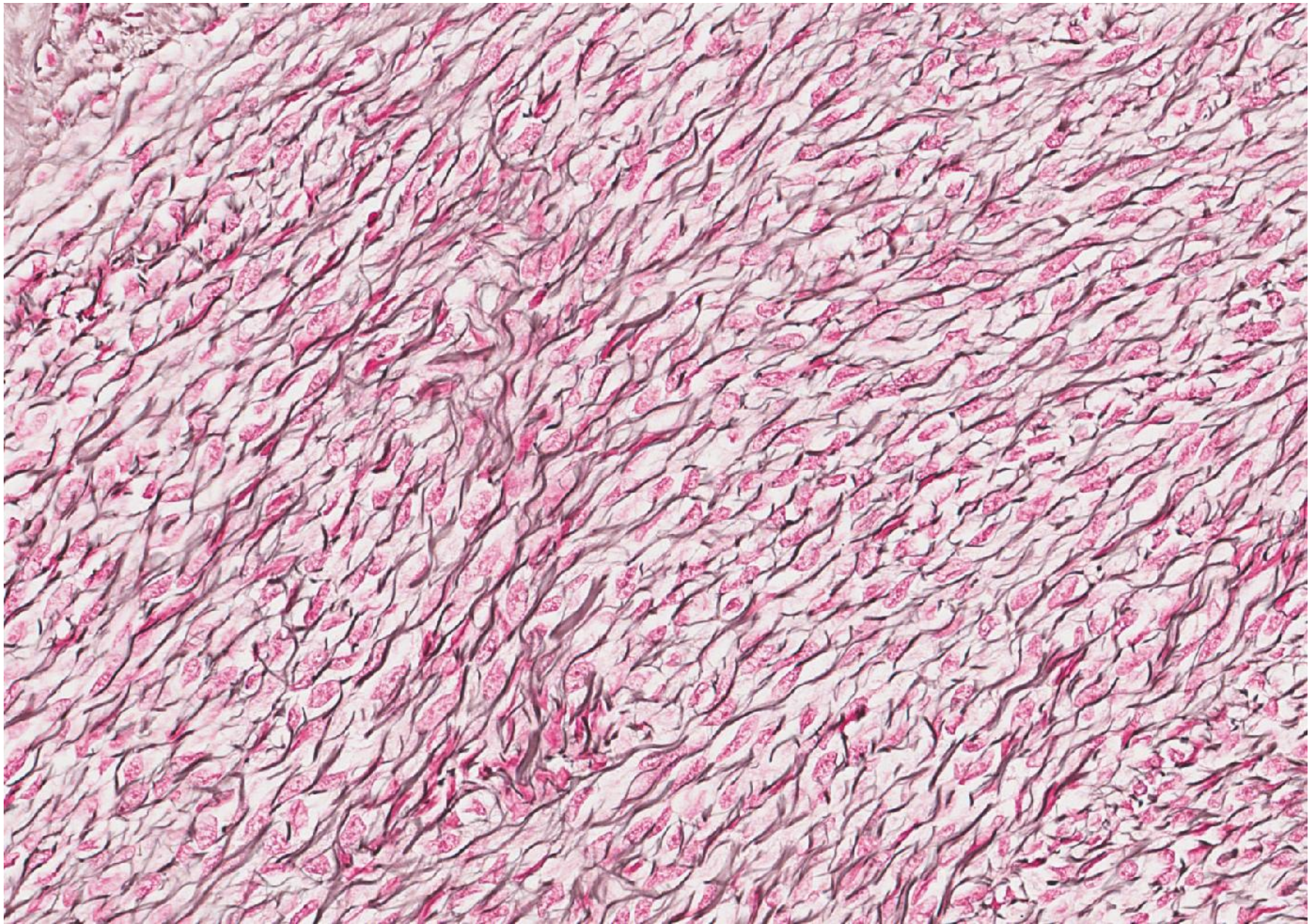

Adult Granulosa Cell Tumor

Absence of pericellular reticulin fibers

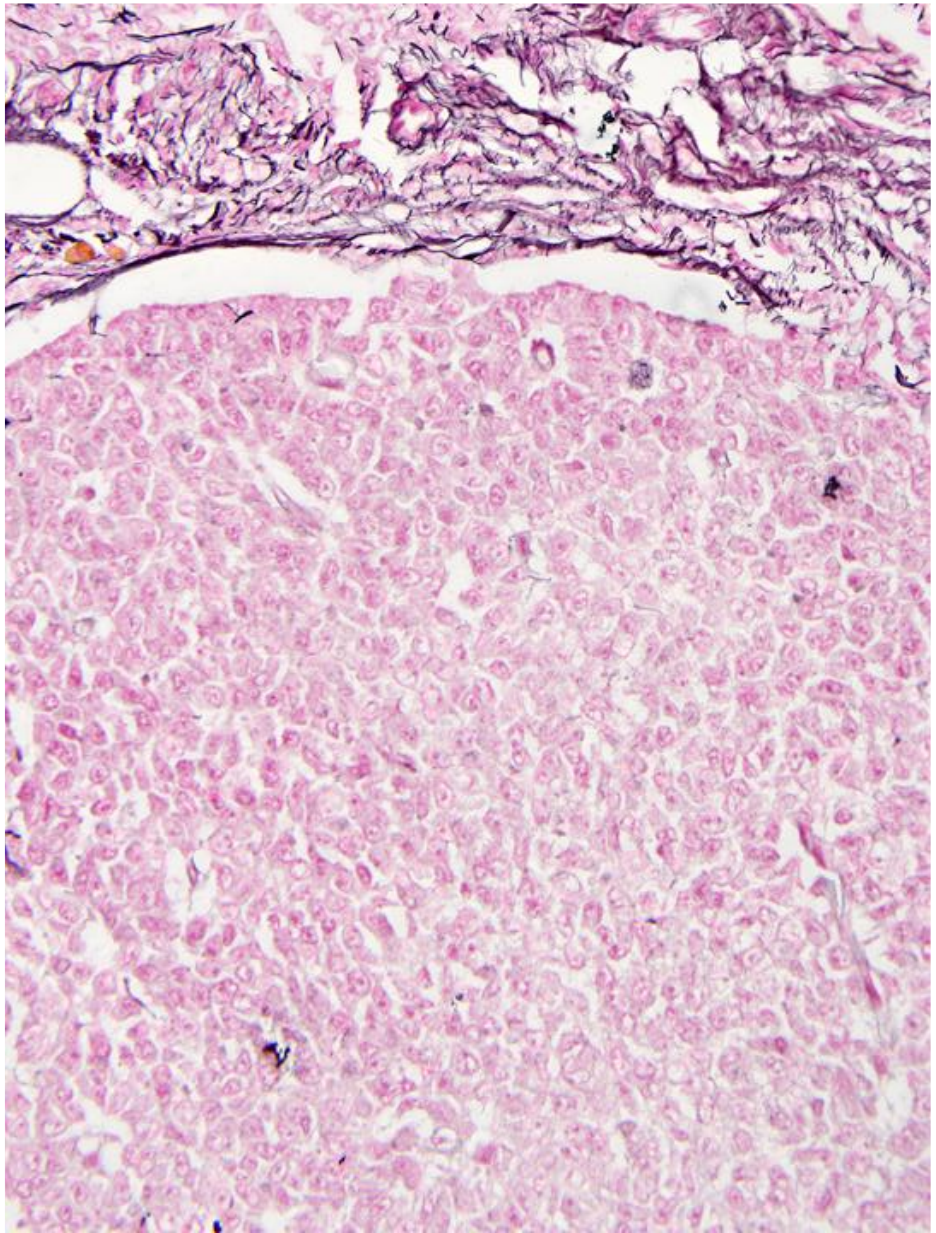

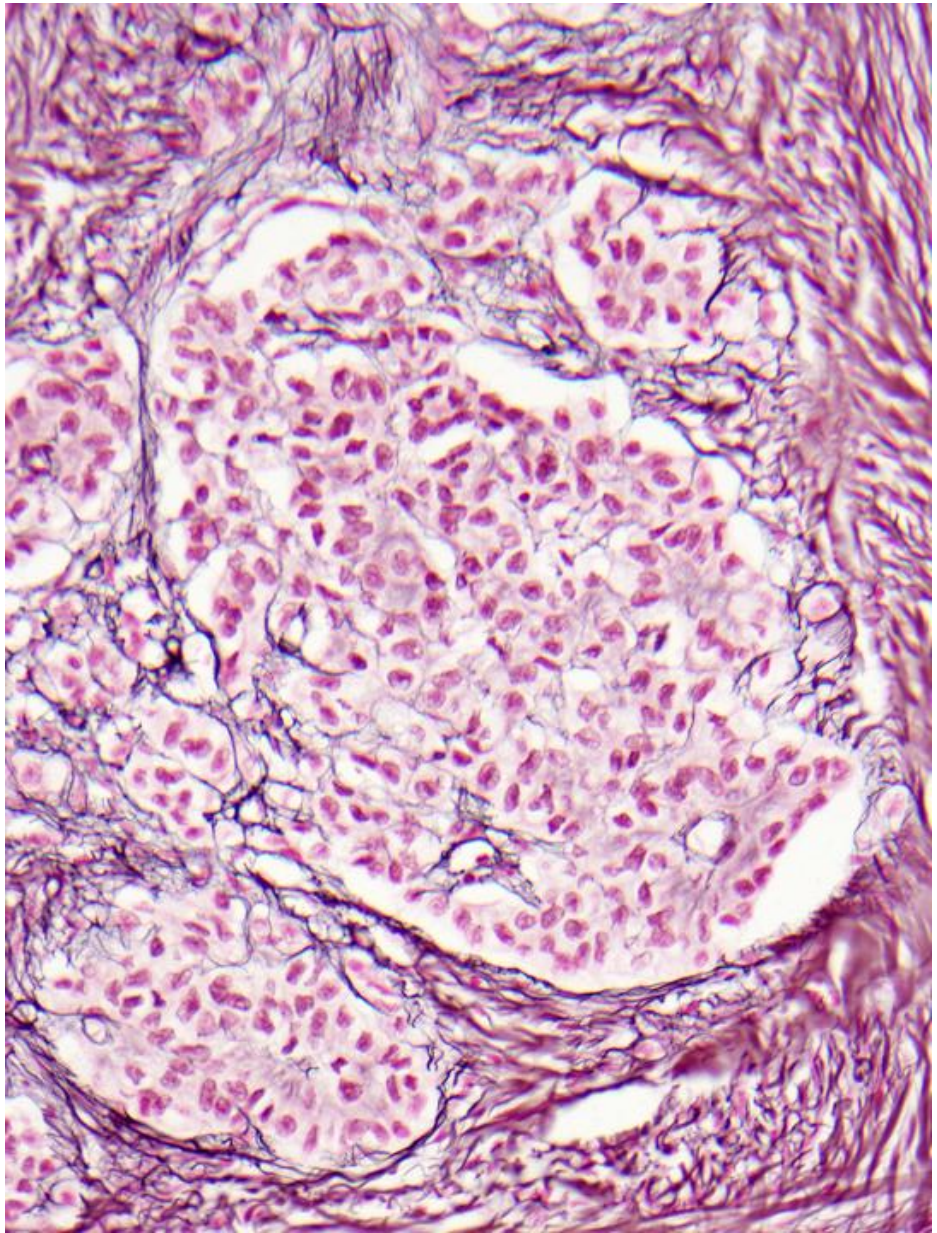

Reticulin Stain: Challenging Pattern to Interpret

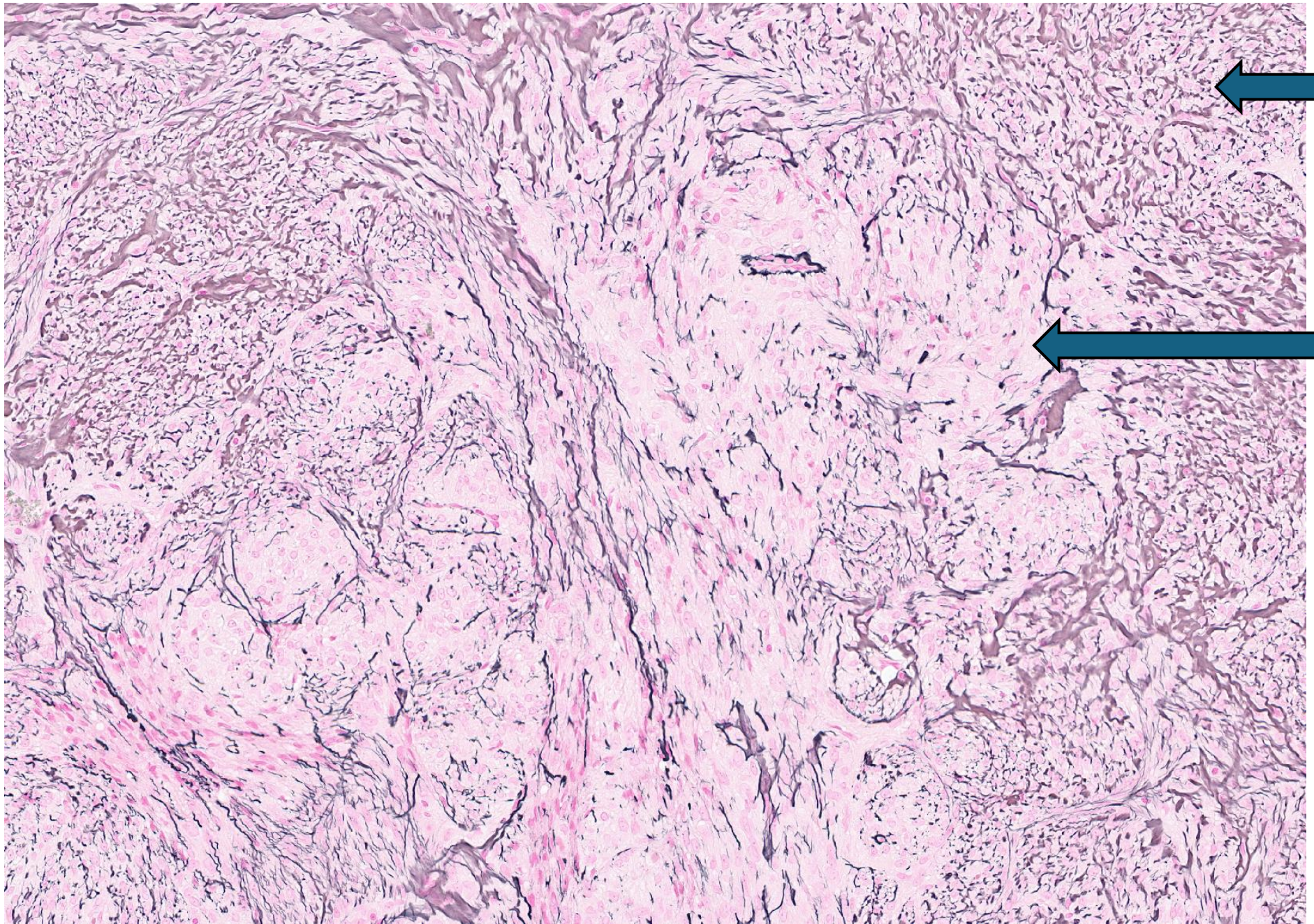

Interpreting Reticulin Stain is Not Always Simple

Original Article

FOXL2 Mutation Analysis of Ovarian Sex Cord-Stromal Tumors: Genotype-Phenotype Correlation With Diagnostic Considerations

Natalia Buza, M.D., Serena Wong, M.D., and Pei Hui, M.D., Ph.D.

PMID: 28700438

- **In ~1/4 cases, experts could not interpret reticulin stain with confidence**

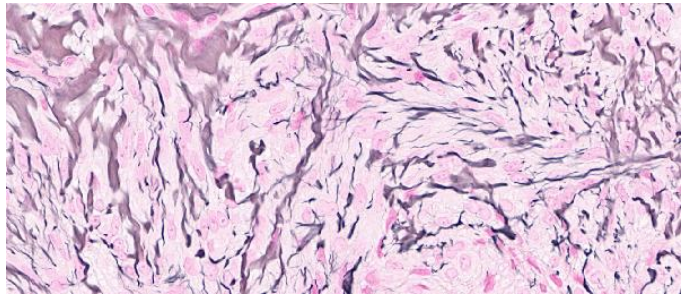

Correlation of Morphology, Reticulin Pattern and *FOXL2* mutation

- **Morphology can be strikingly similar between AGCT, fibroma and thecoma**

	Predicts presence of *FOXL2* mutation
Nuclear grooves	No
Nuclear atypia	No
Tumor size	No
Abundant pale cytoplasm	Yes

⇦ >95% had a mutation

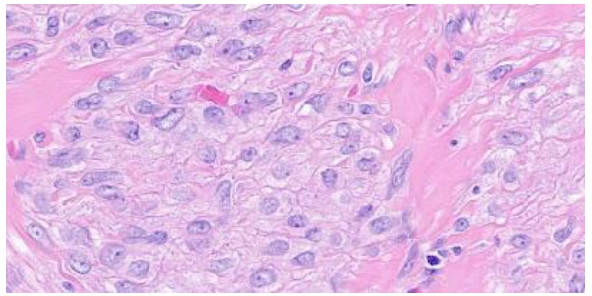

PMID: 28700438

Diffuse pattern Adult Granulosa Cell Tumor

Diagnostic clue: **nodular, nested pattern of plump / epithelioid cells**

- *Highly associated with FOXL2 mutation*

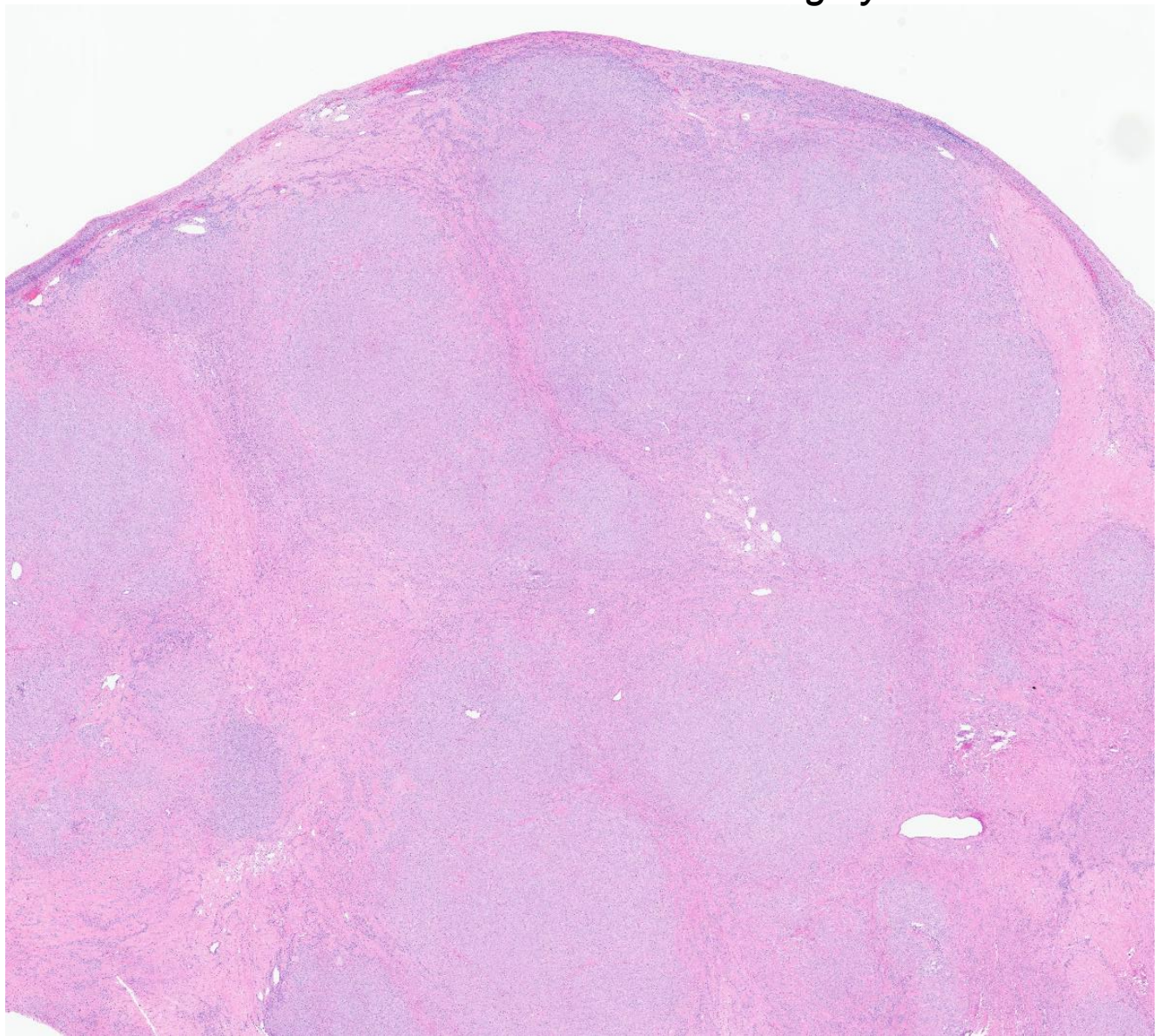

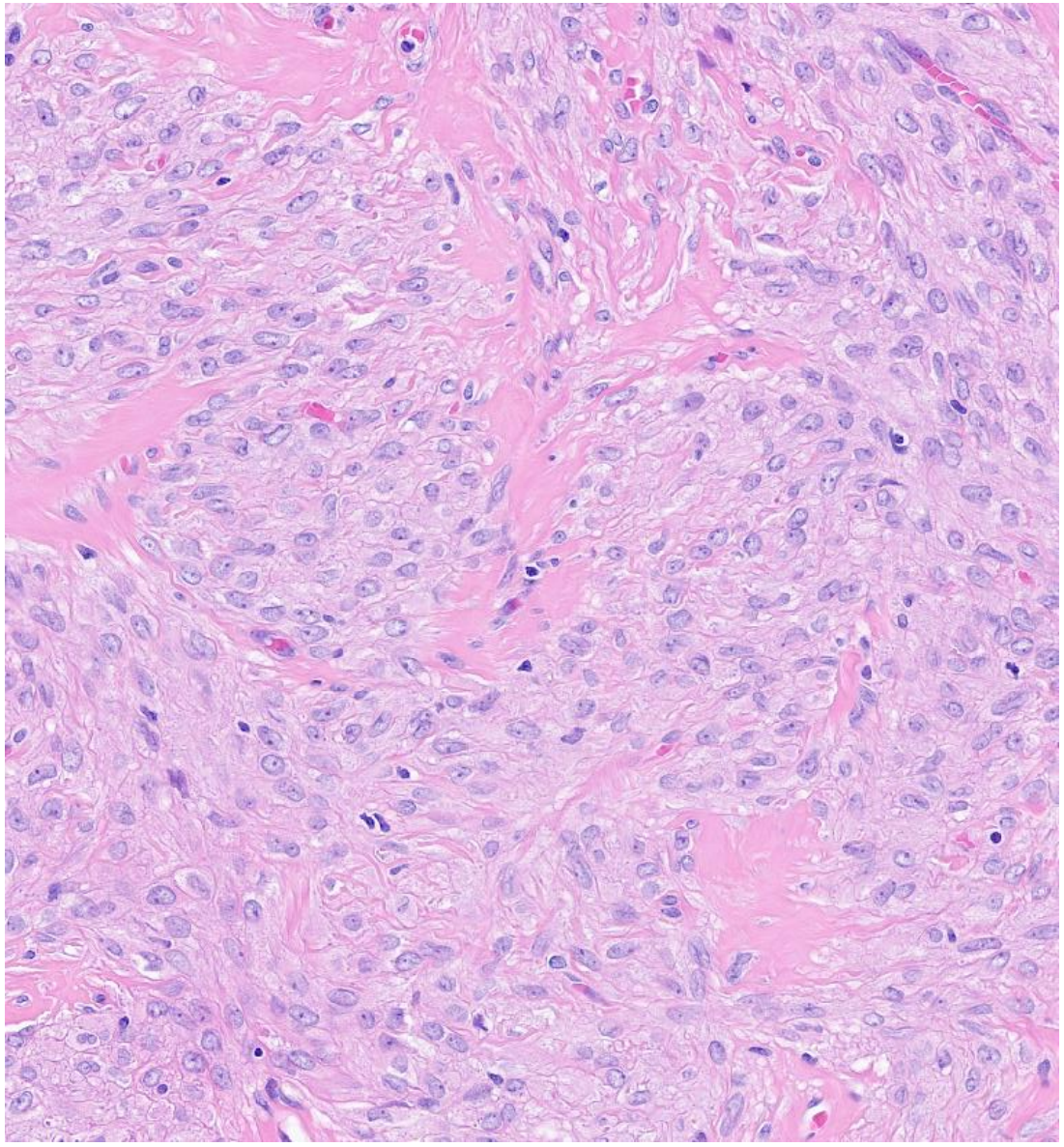

Correlation of Morphology, Reticulin Pattern and *FOXL2* mutation

- **Reticulin pattern can be used to triage to *FOXL2* mutation testing**

Reticulin Pattern	*FOXL2* mutation
Uniform pericellular staining	None
Nests with loss of uniform pericellular staining	87.5%
Indeterminate interpretation	50%

PMID: 28700438

Practical recommendation:

Reticulin Pattern	Order *FOXL2* test ?
Uniform pericellular staining	No
Nests with loss of uniform pericellular staining	Only if secondary confirmation is preferred
Indeterminate interpretation	Yes

Case 1

Reticulin stain

Areas of intact pericellular reticulin

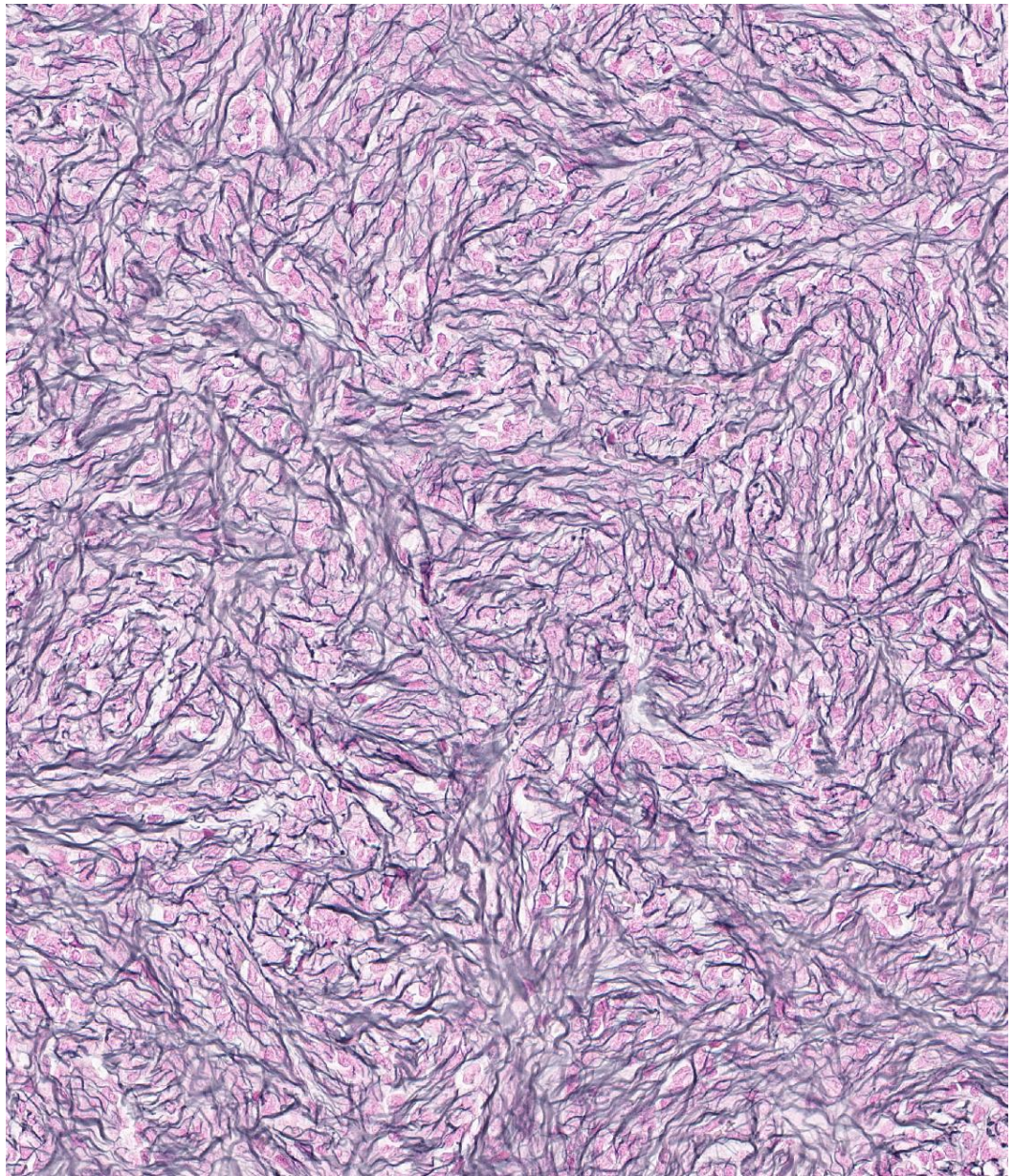

Case 1

Reticulin stain

Areas of intact pericellular reticulin

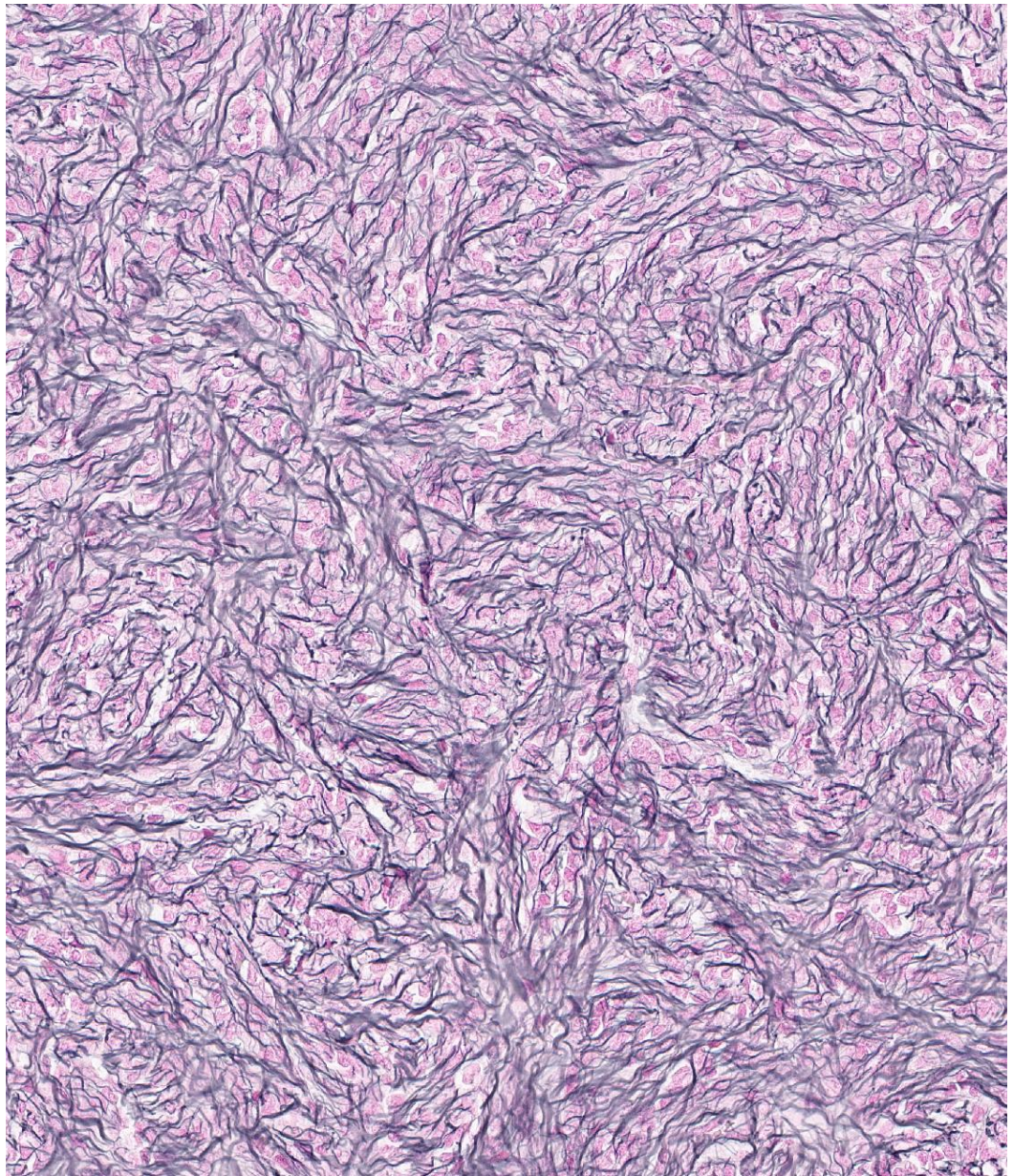

Practical Recommendation:

Consider testing multiple blocks either:

a.) upfront

or

b.) in follow up to confirm first stain showing intact result

Case 1

Reticulin stain

Areas of intact pericellular reticulin

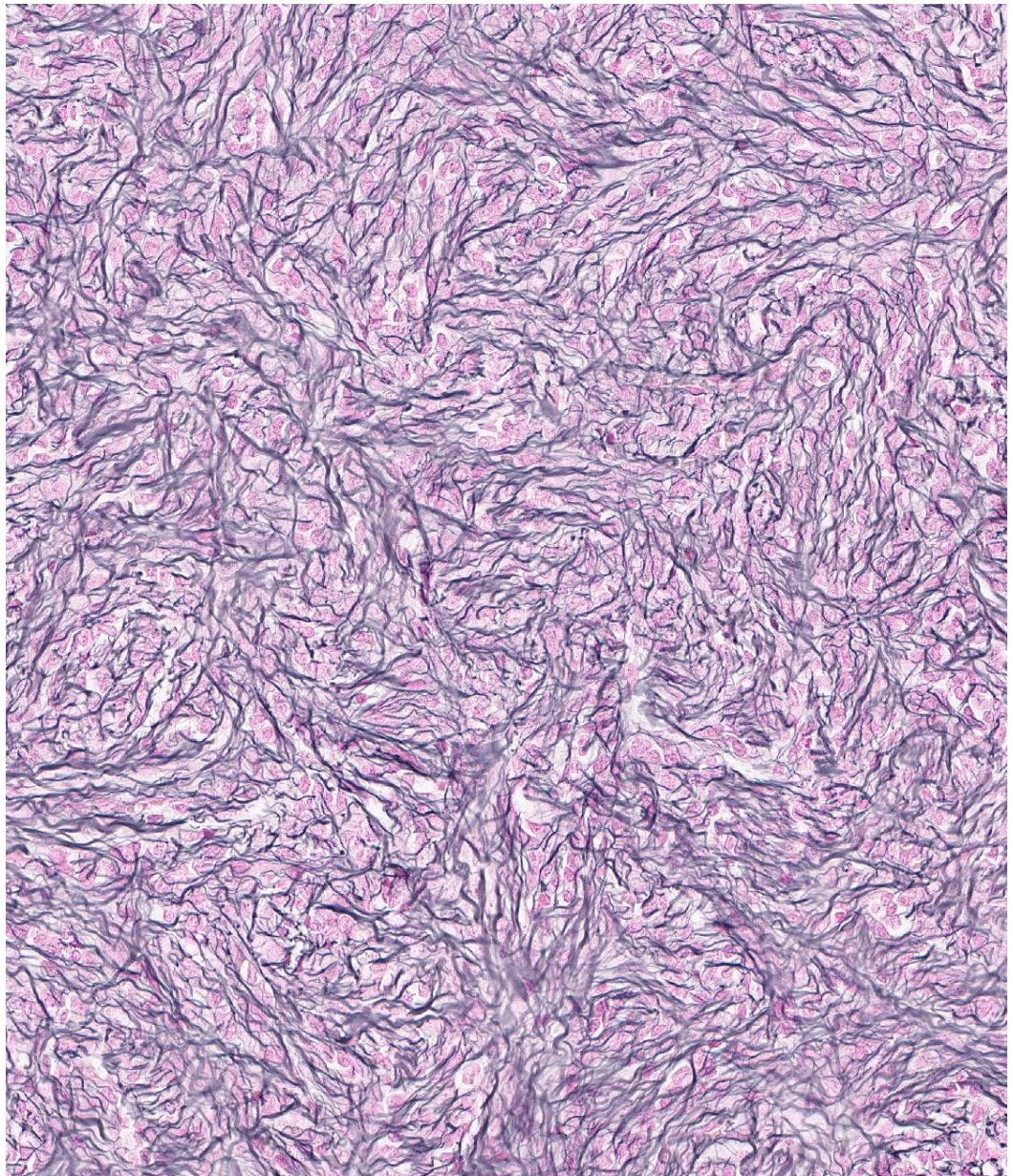

Areas of absence of pericellular reticulin

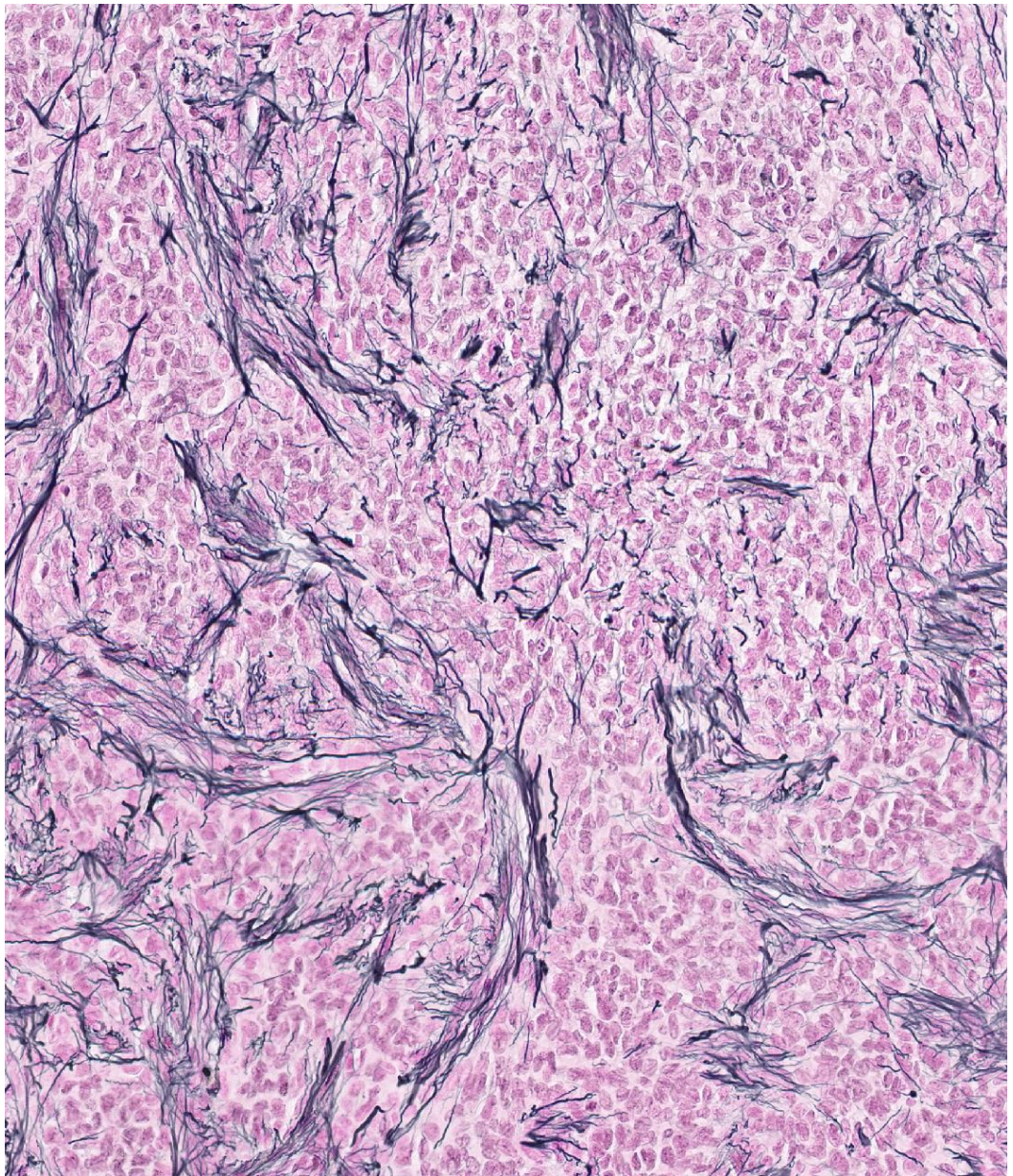

Case 1

Reticulin stain

Areas of intact pericellular reticulin

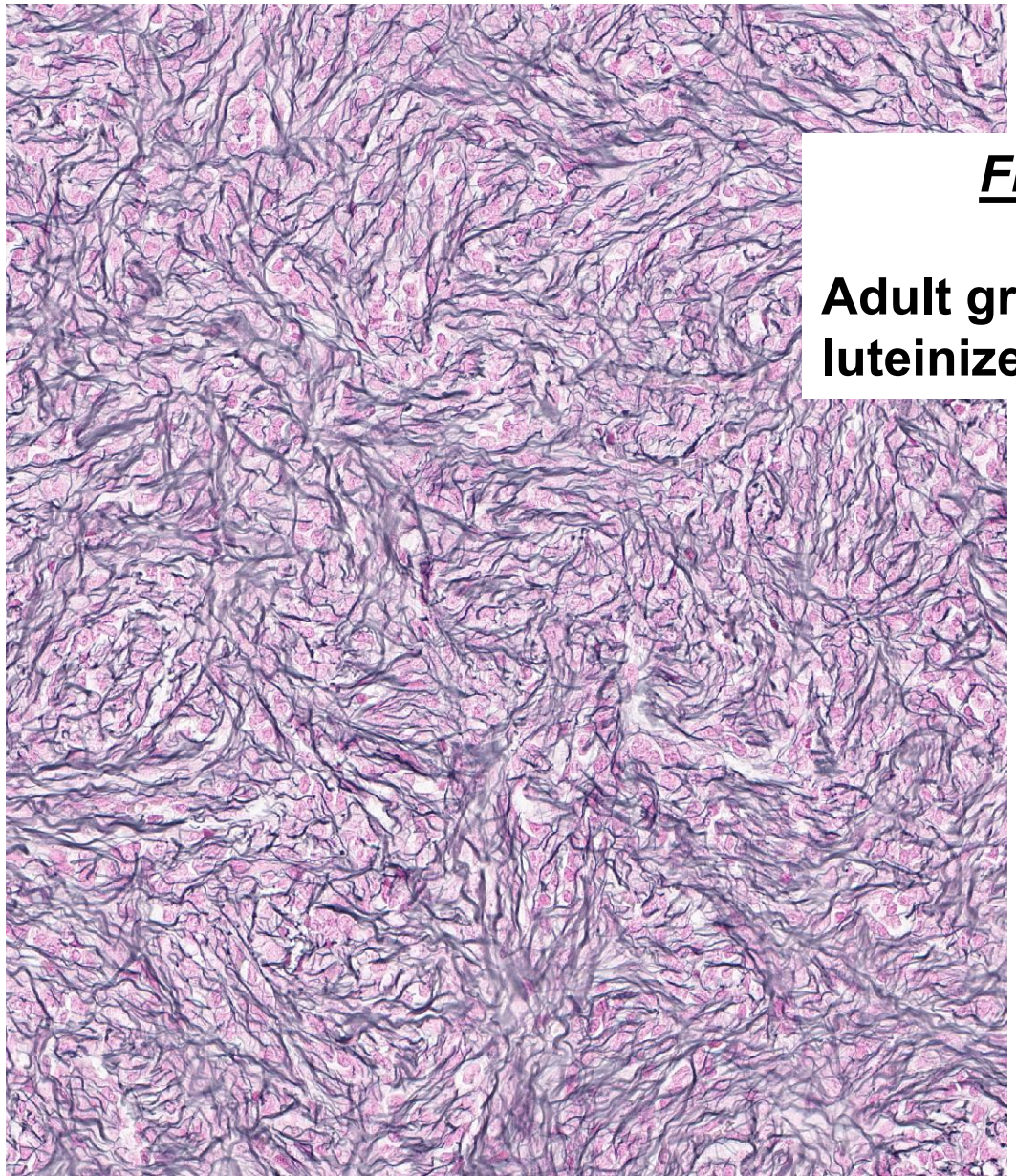

Final Diagnosis

Adult granulosa cell tumor, luteinized variant

Areas of absence of pericellular reticulin

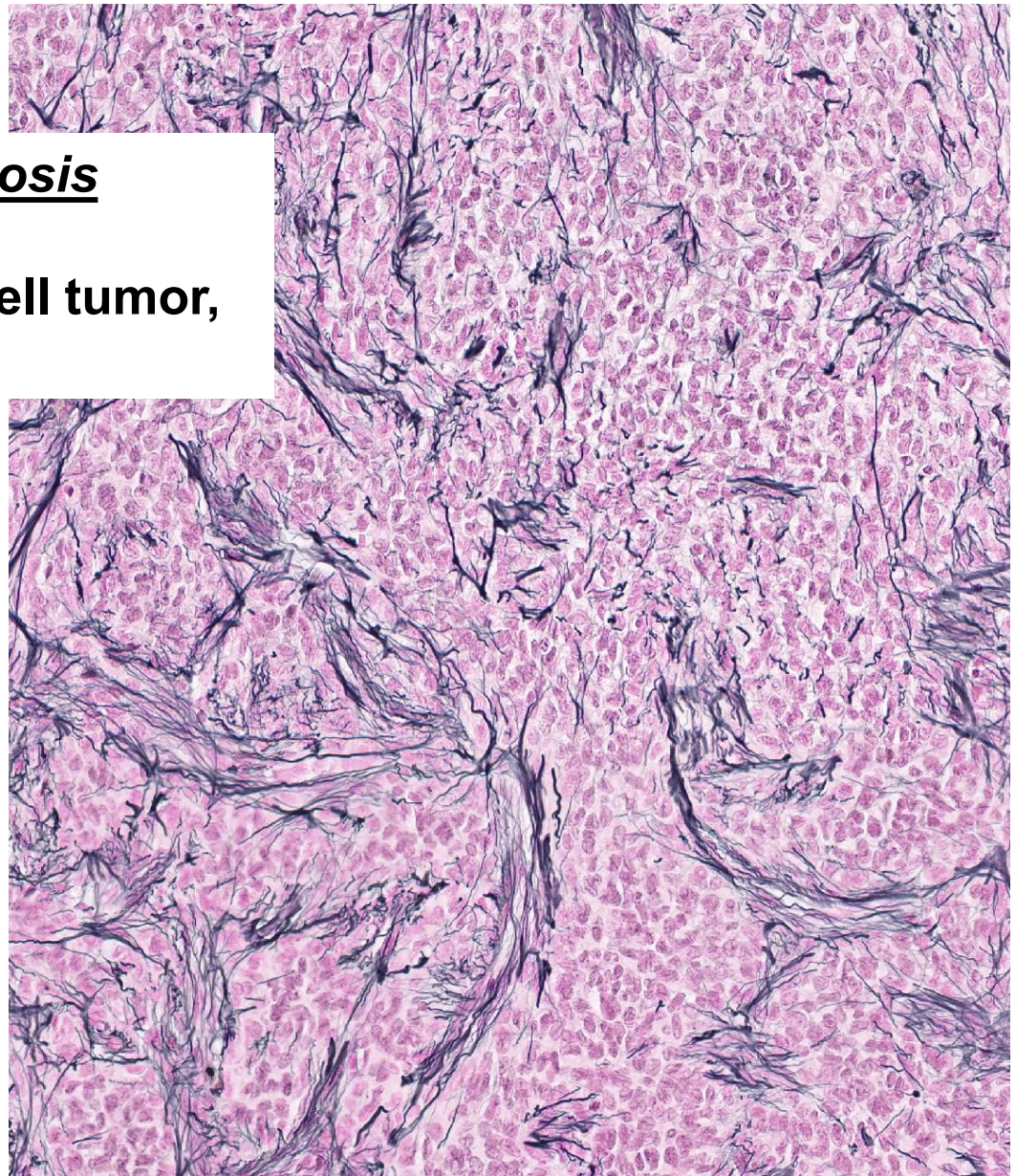

Case 1

FOXL2 mutation test

- Positive
- *FOXL2* c.402C>G mutation

Final Diagnosis

- Adult granulosa cell tumor, luteinized variant

Luteinized Adult Granulosa Cell Tumor

A Rare Variant

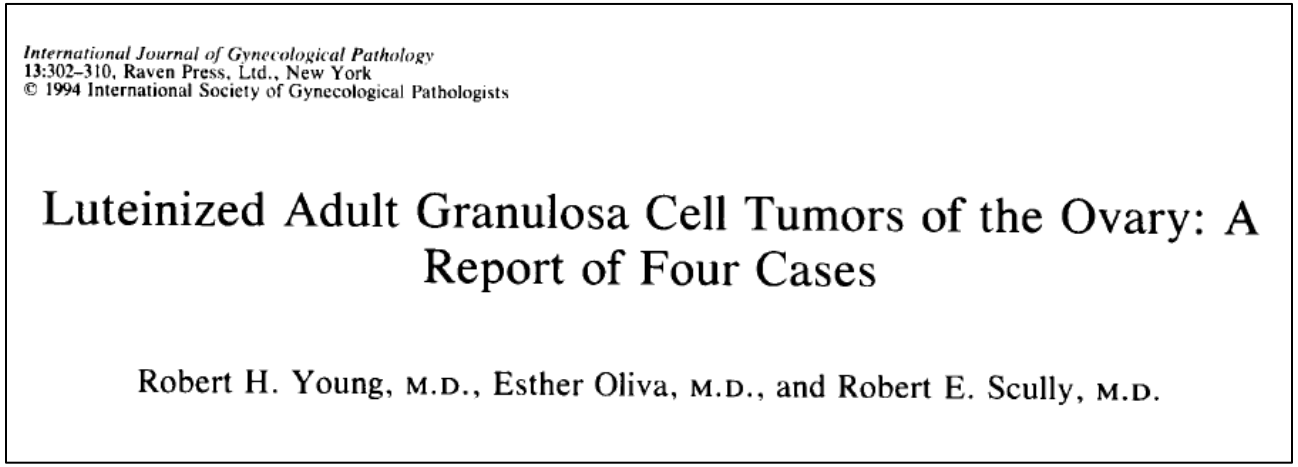

International Journal of Gynecological Pathology
13:302–310, Raven Press, Ltd., New York
© 1994 International Society of Gynecological Pathologists

Luteinized Adult Granulosa Cell Tumors of the Ovary: A Report of Four Cases

Robert H. Young, M.D., Esther Oliva, M.D., and Robert E. Scully, M.D.

PMID: 7814191

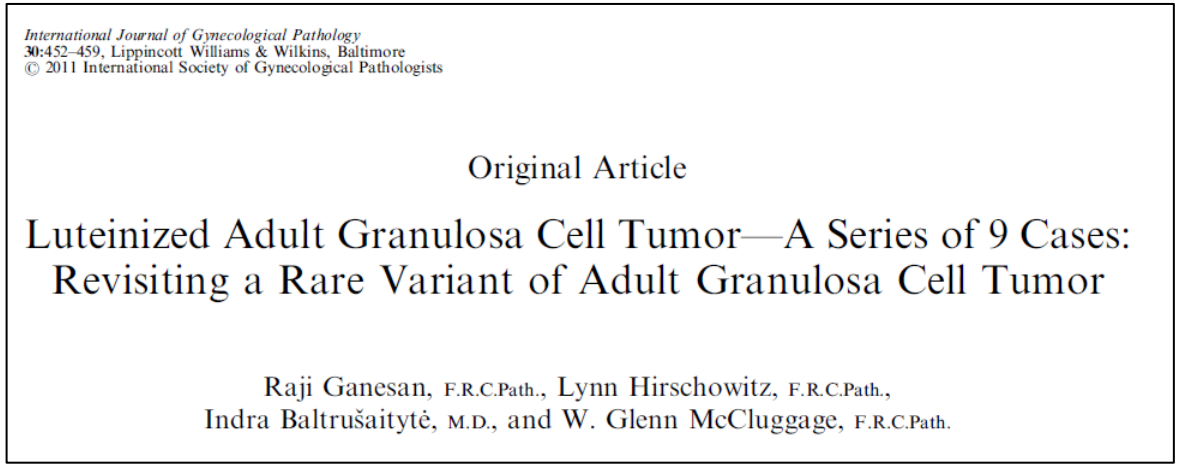

International Journal of Gynecological Pathology
30:452–459, Lippincott Williams & Wilkins, Baltimore
© 2011 International Society of Gynecological Pathologists

Original Article

Luteinized Adult Granulosa Cell Tumor—A Series of 9 Cases: Revisiting a Rare Variant of Adult Granulosa Cell Tumor

Raji Ganesan, F.R.C.Path., Lynn Hirschowitz, F.R.C.Path.,
Indra Baltrušaitytė, M.D., and W. Glenn McCluggage, F.R.C.Path.

PMID: 21804396

- **Additional reports of varying degrees of luteinization in AGCT:** PMID: 4290164, 21005311, 7250754, 28700438

Luteinized Adult Granulosa Cell Tumor

Definition: **AGCT with abundant eosinophilic cytoplasm in ≥50% tumor cells**

Clinical Context:

- **Rare** (<2 dozen reported)
- **Mostly in post-menopause**
- **Uterine bleeding common**
- **Pelvic mass symptoms less common**
- **Stage I**

Clinical Relevance:

- **Mostly indolent behavior**
  only 1 report of local recurrence in case series of 9 patients

- **Main reason for recognizing it as a variant is to avoid mis-diagnosis**
  Under-diagnosis as thecoma
  Mis-classification as steroid cell tumor, carcinoma, PEComa, melanoma, etc. etc.

PMID: 21804396, 7814191

Luteinized Adult Granulosa Cell Tumor

Macroscopic Pathology:

- **4 to 14 cm**
- **Most are unilateral**
- **Solid, lobulated**
- **Yellow / yellow-brown**

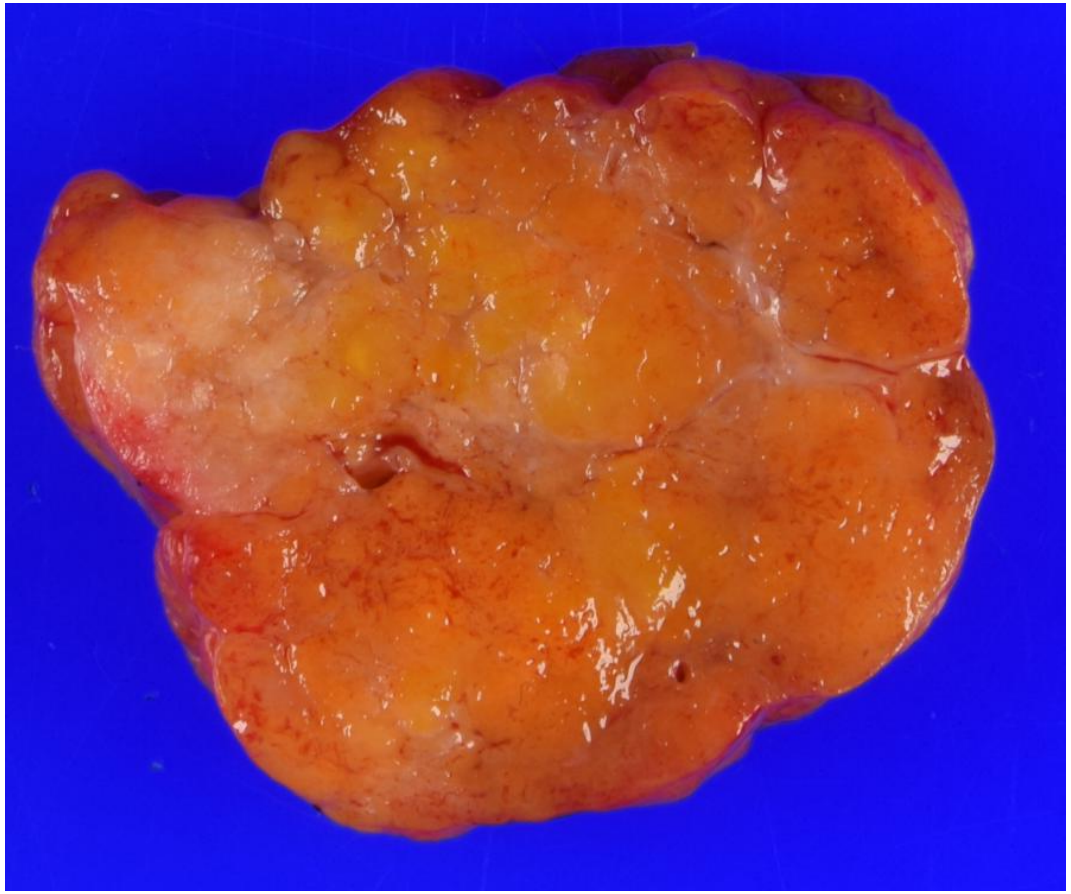

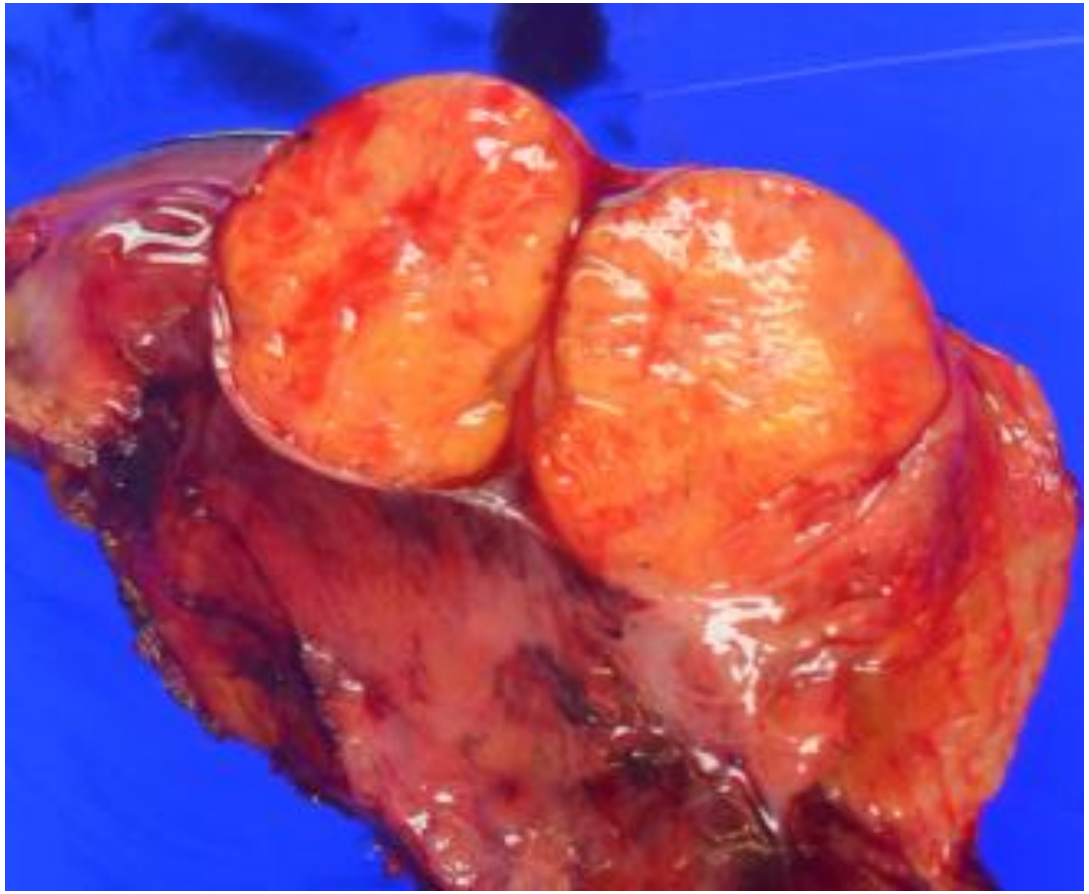

Luteinized Adult Granulosa Cell Tumor

Microscopic Pathology:

- **50% to 90% of tumor cells are luteinized**
- **Non-luteinized tumor cells tend to be at periphery of tumor**

Architecture	▪ **Multinodular solid sheets, nests separated by fibrous tissue** ▪ **+/- cords, trabeculae, follicles** ▪ **+/- myxoid stroma**
Cytology	▪ **Polygonal shape** <u>Cytoplasm</u> **Abundant eosinophilic cytoplasm** *resembling that of corpus luteum cells* **+/- vacuolated cytoplasm** <u>Nuclei:</u> **round/oval** **nuclear grooves not prominent** **prominent nucleoli** **limited mitoses (<4/10 hpf)**

PMID: 21804396, 7814191

Luteinized Adult Granulosa Cell Tumor

Multinodular growth

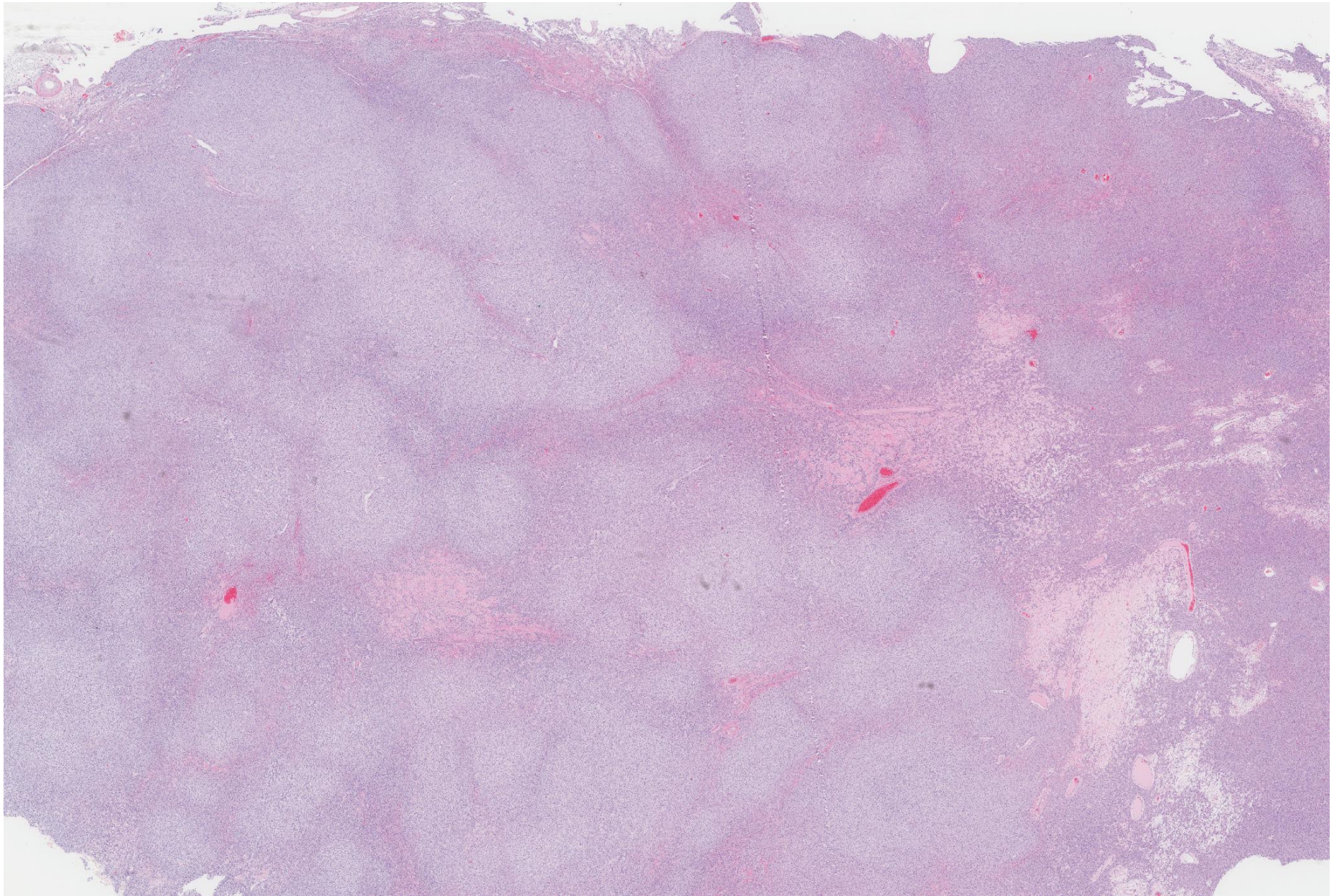

Luteinized Adult Granulosa Cell Tumor

Multinodular growth

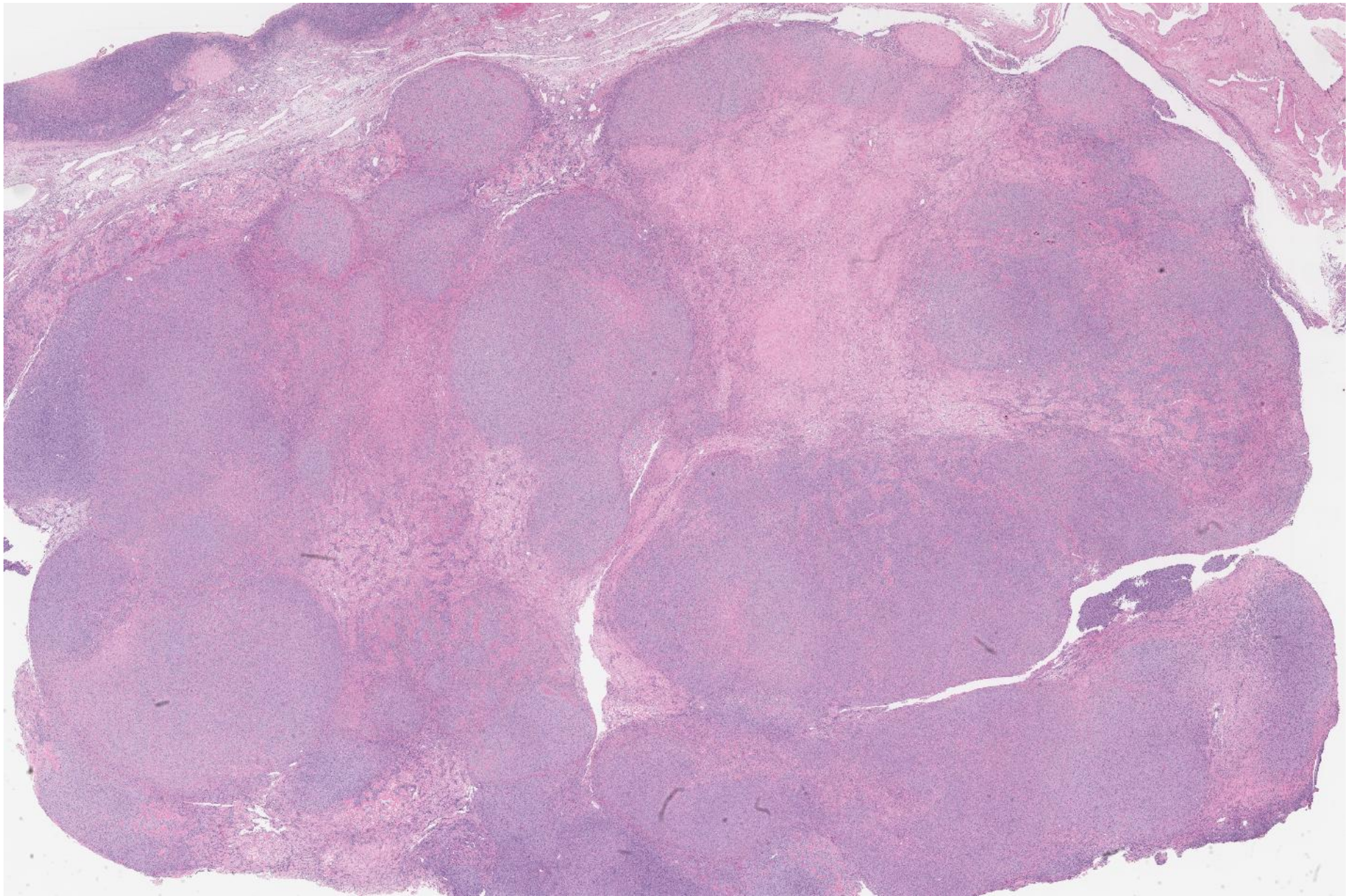

Luteinized Adult Granulosa Cell Tumor

Fibroma-like background

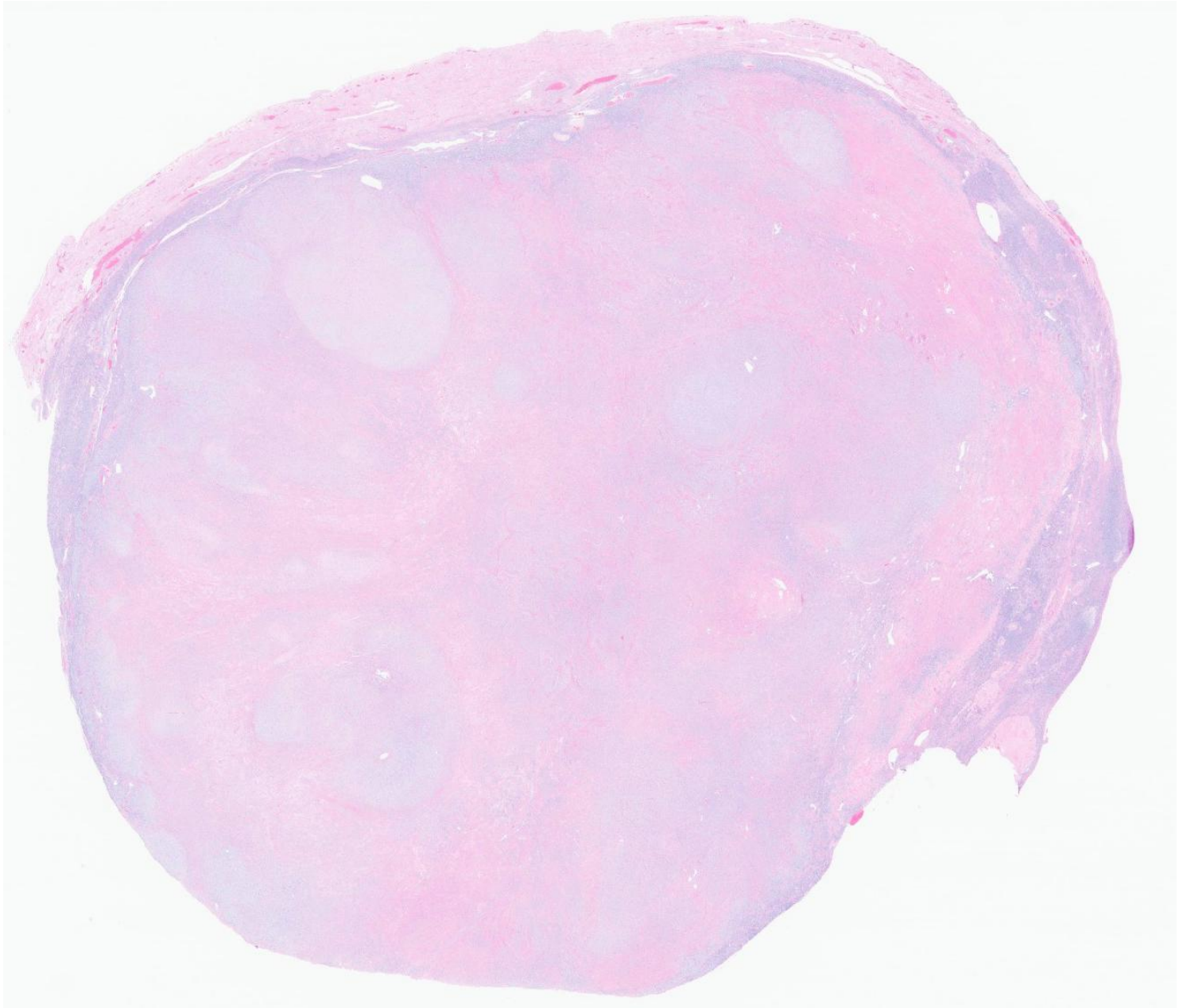

Luteinized Adult Granulosa Cell Tumor

May be as small as a few centimeters

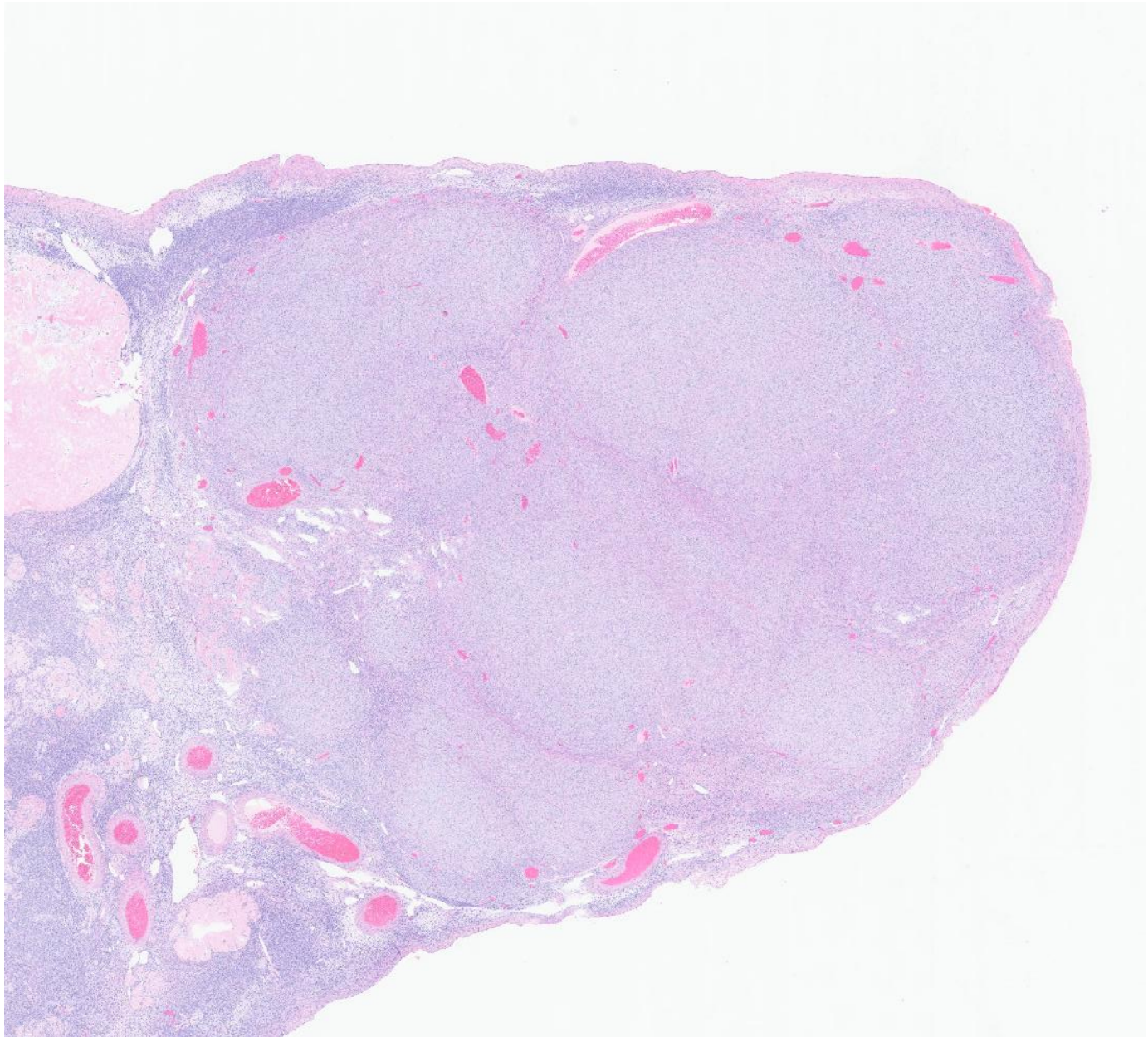

Luteinized Adult Granulosa Cell Tumor

Abundant eosinophilic cytoplasm

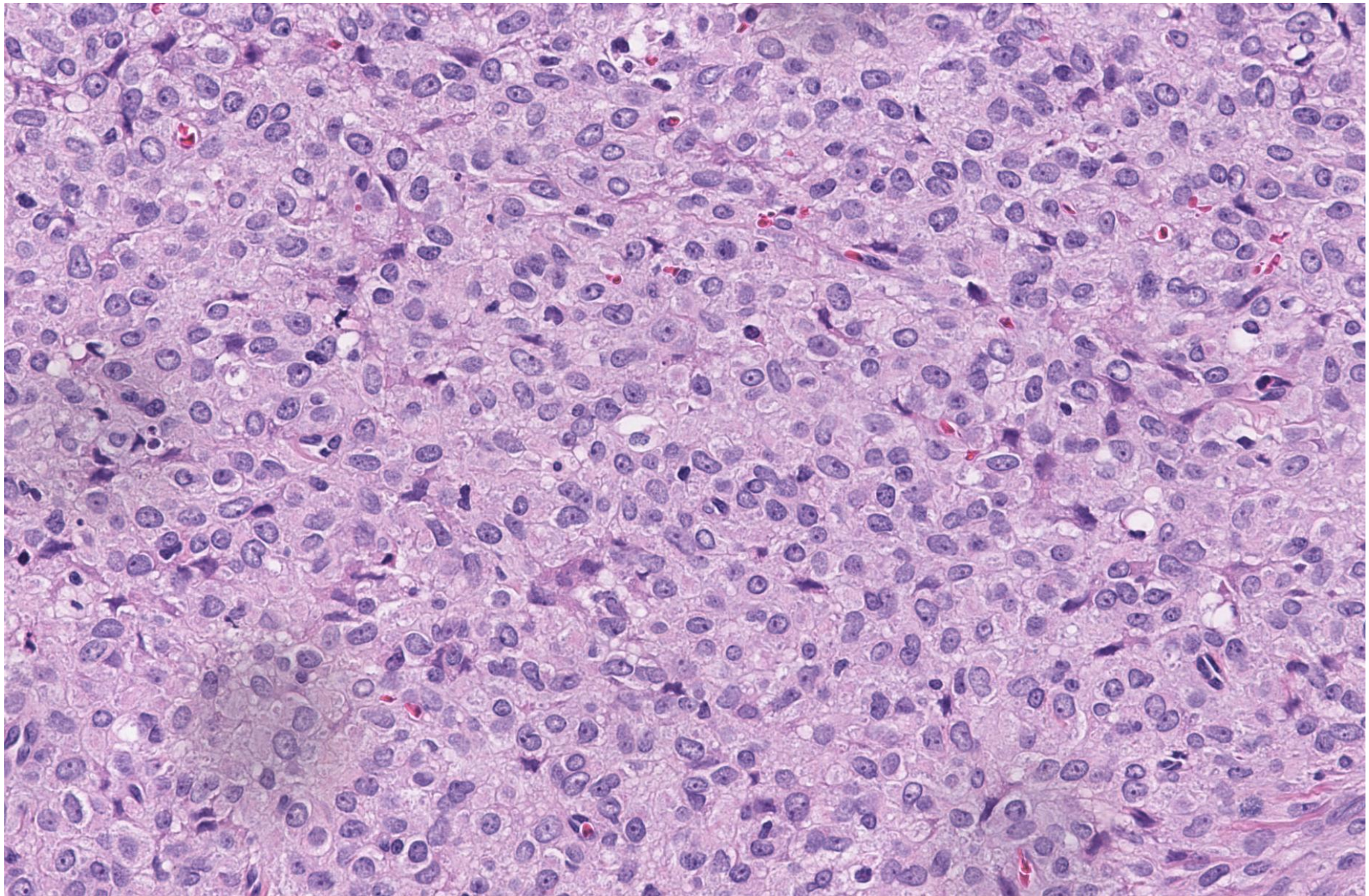

Luteinized Adult Granulosa Cell Tumor

Hyaline plaque

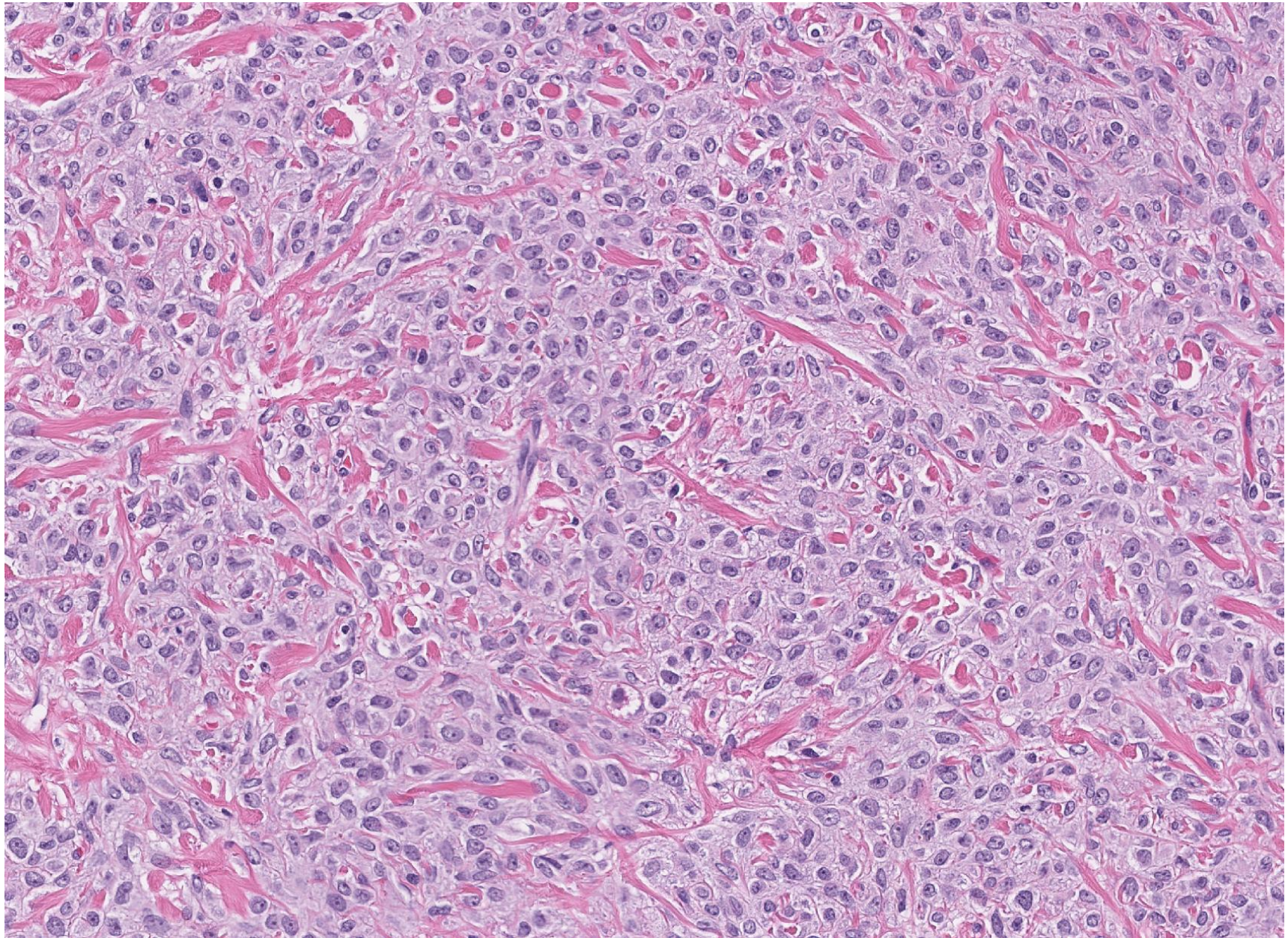

Luteinized Adult Granulosa Cell Tumor

Background sclerosis

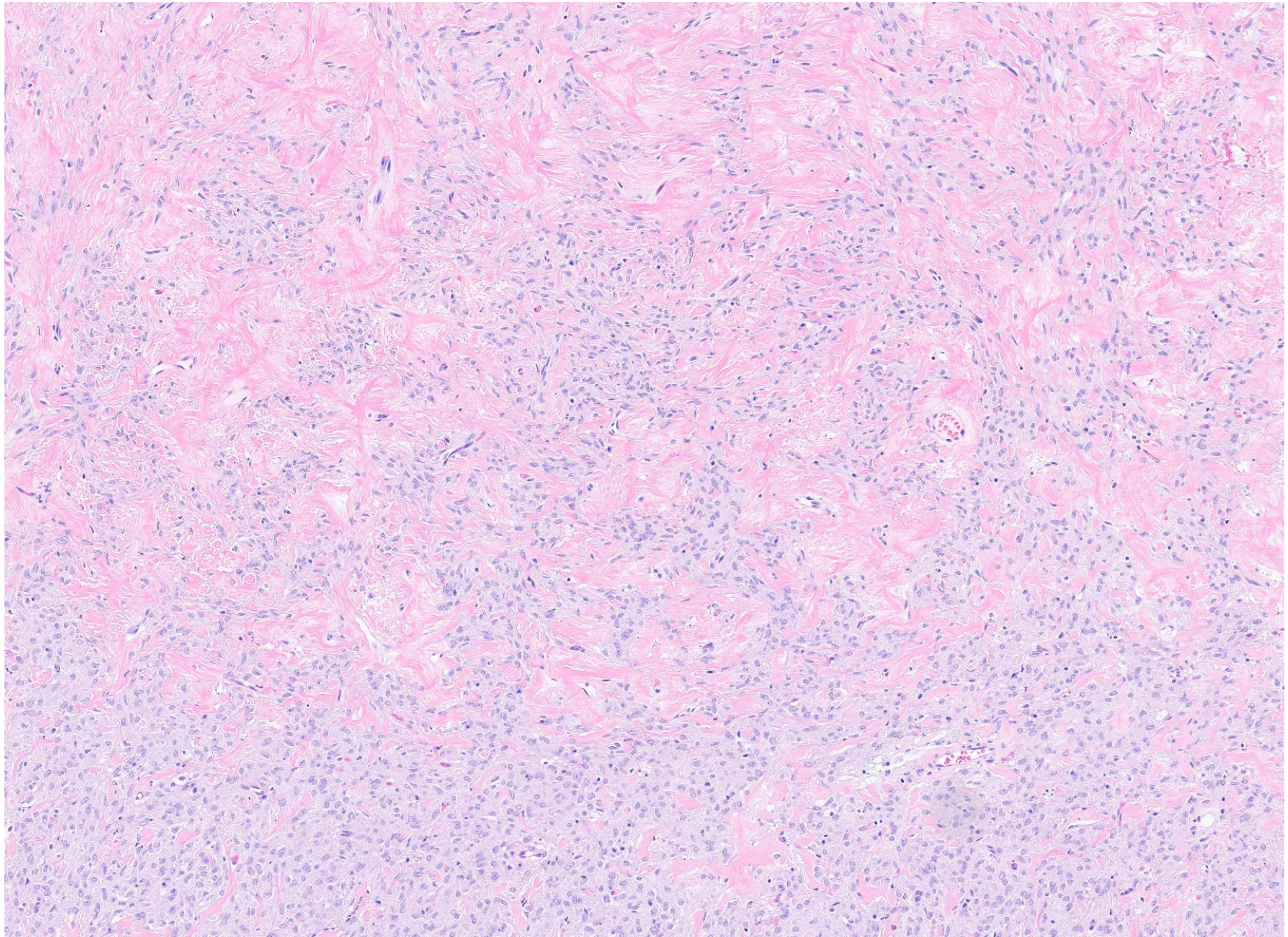

Luteinized Adult Granulosa Cell Tumor

Immunophenotype:
- **Positive calretinin, inhibin**
- **Negative EMA**

Reticulin stain:
- **Absent or patchy pericellular staining**

FOXL2 mutation:
- **Not formally studied in AGCT classified as luteinized variant**
  Case series of FOXL2 mutated AGCT: 45% had variable luteinization

PMID: 28700438

Luteinized Adult Granulosa Cell Tumor

Inhibin

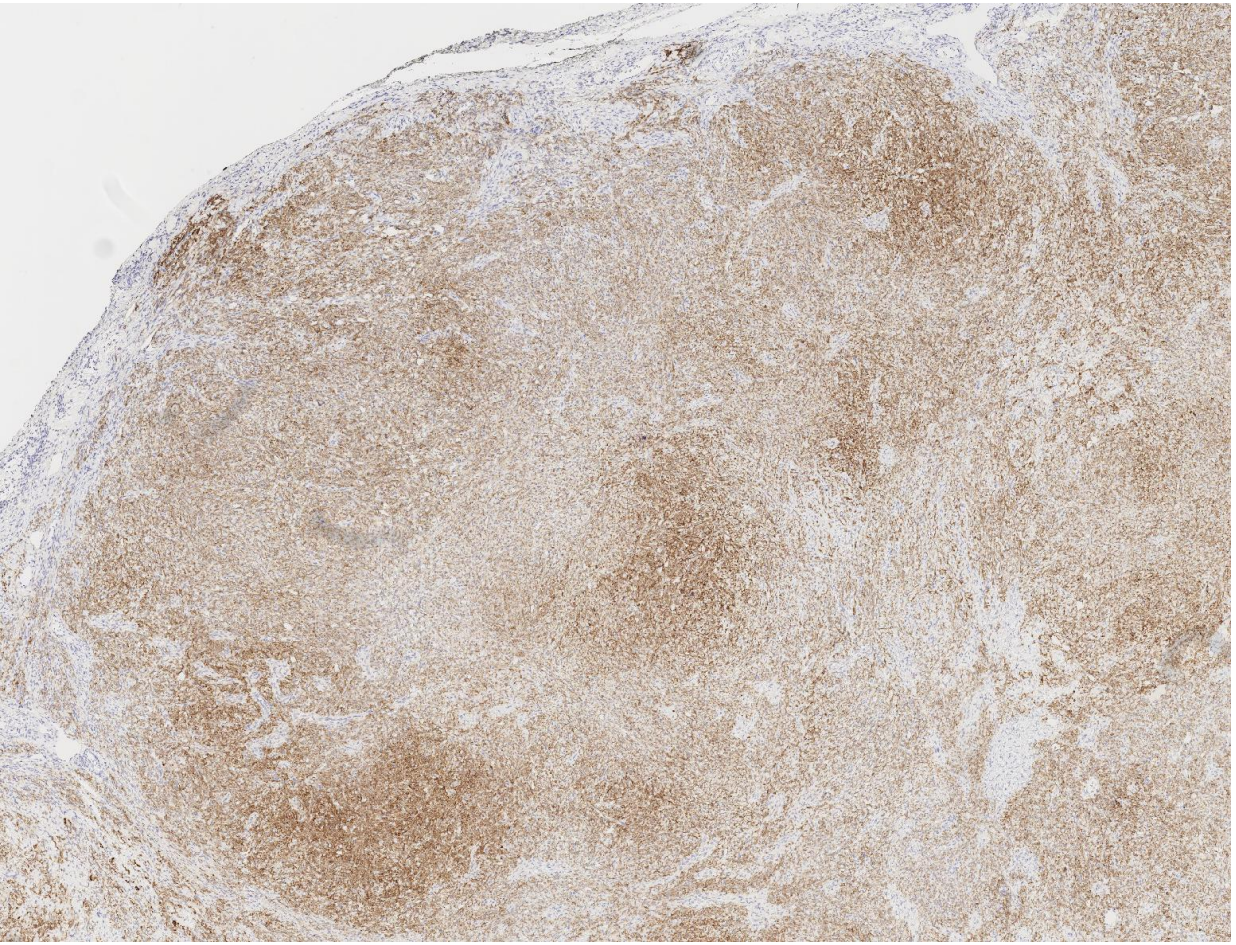

Calretinin

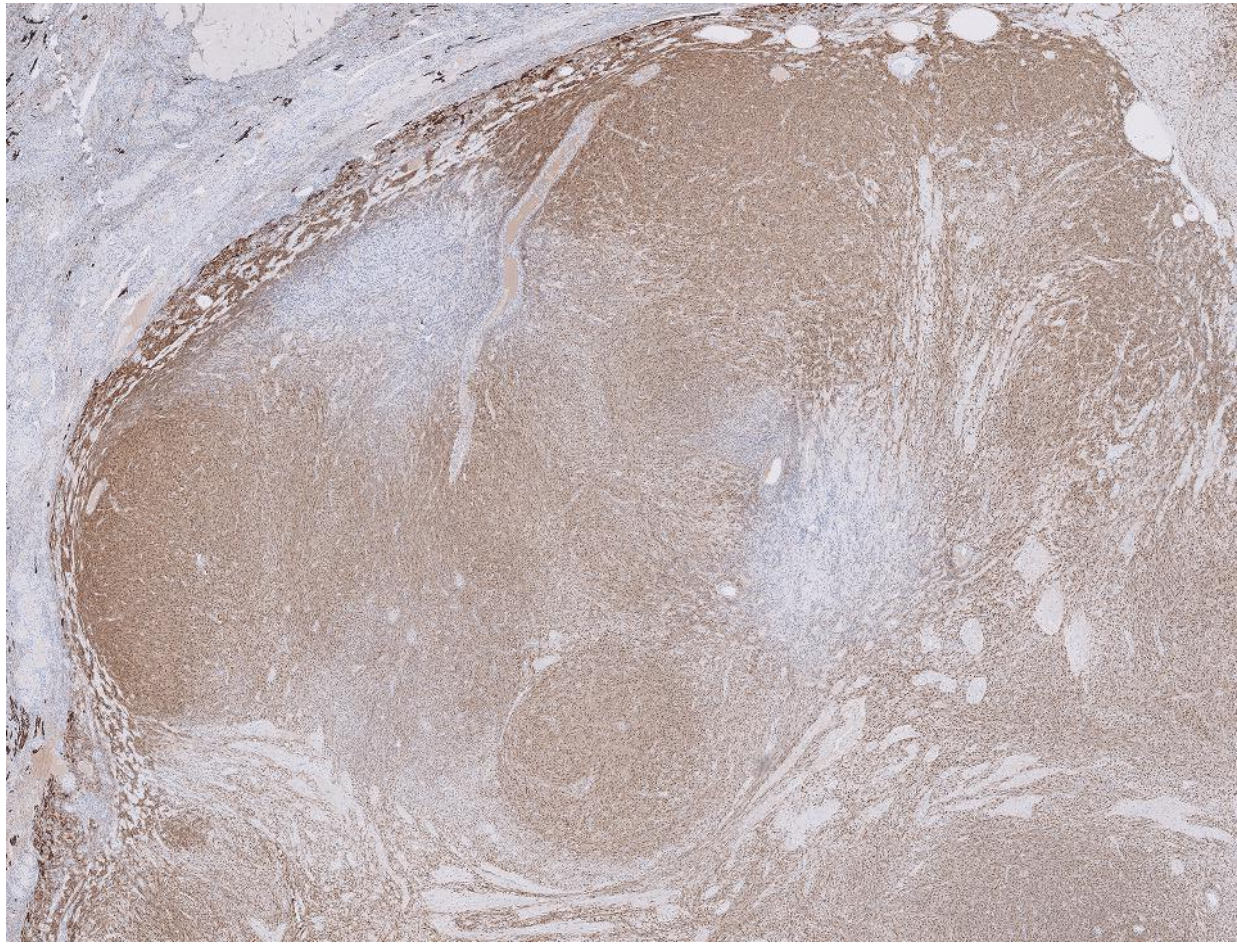

Luteinized Adult Granulosa Cell Tumor

SF1

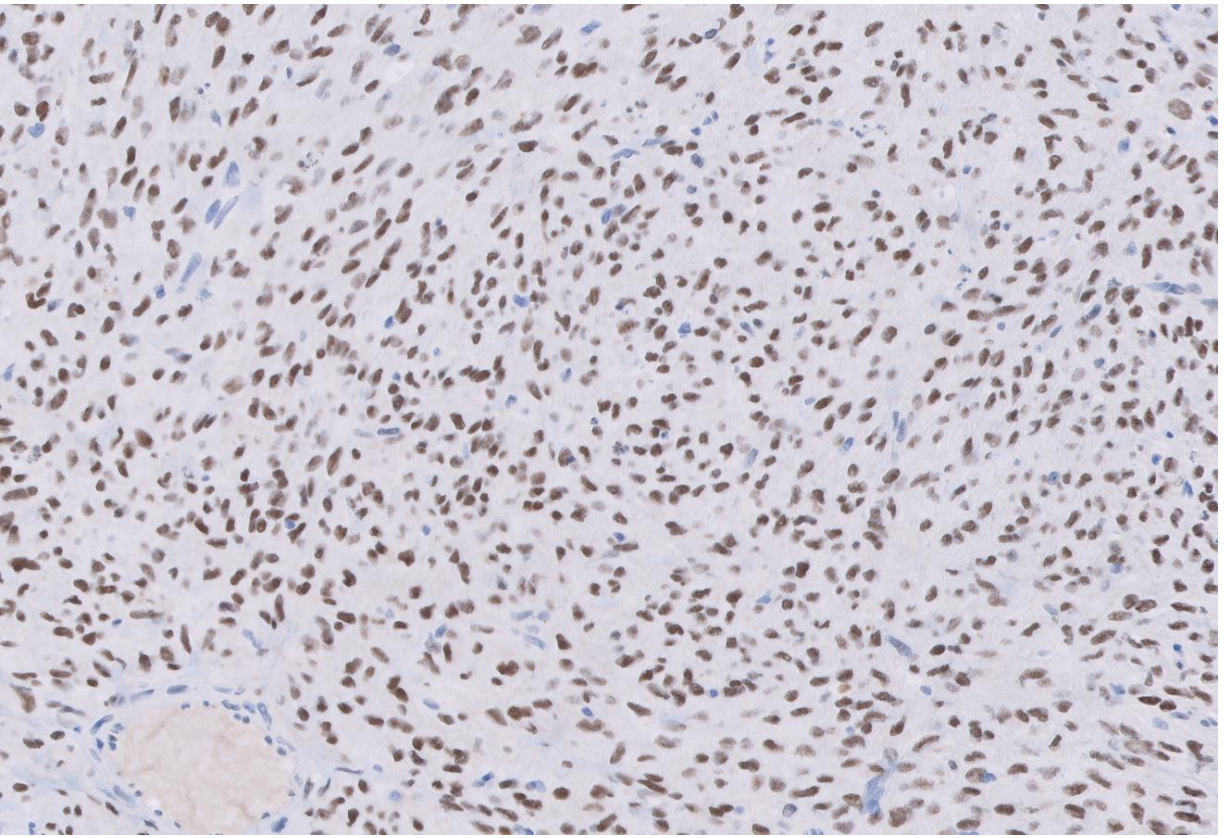

FOXL2

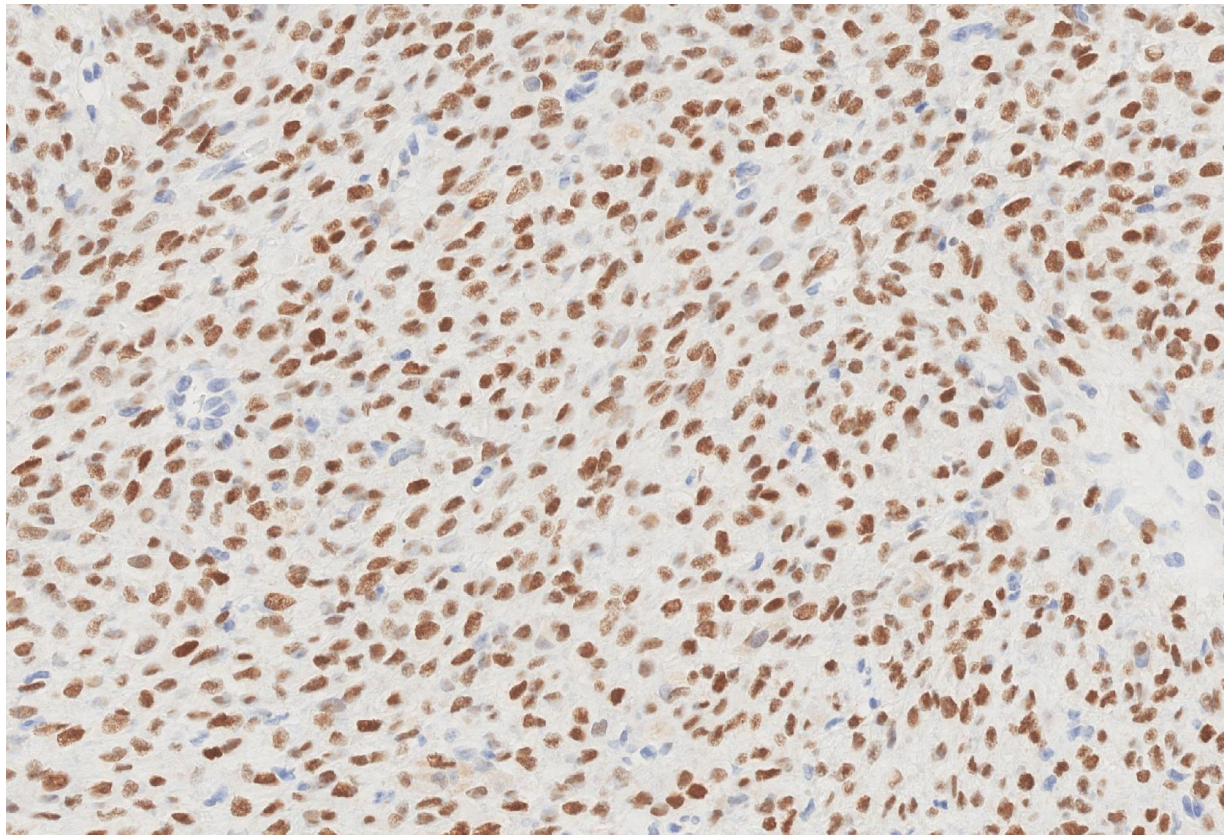

Luteinized Adult Granulosa Cell Tumor

Reticulin stain: loss of uniform pericellular staining

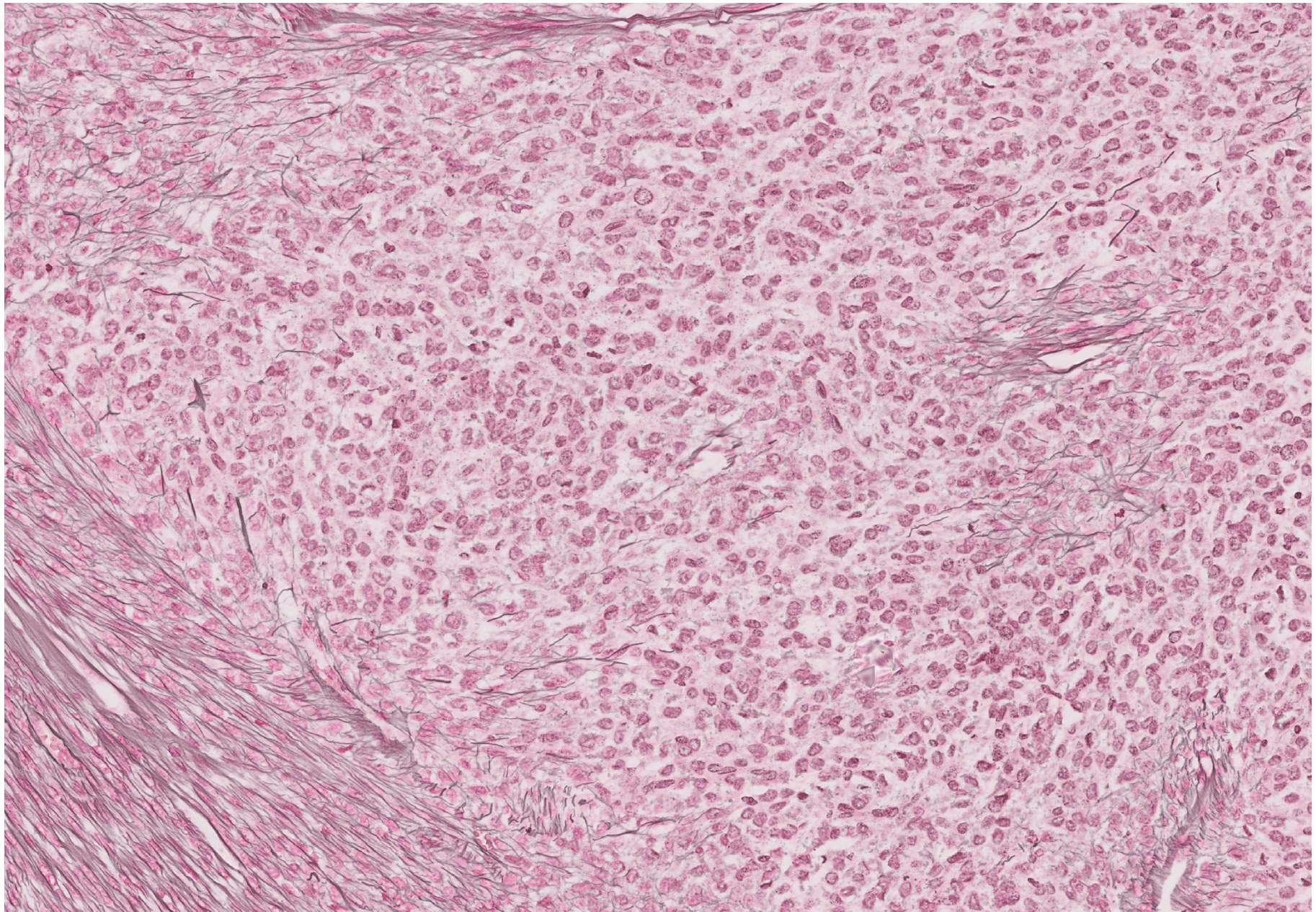

Luteinized Adult Granulosa Cell Tumor

Reticulin stain: loss of uniform pericellular staining

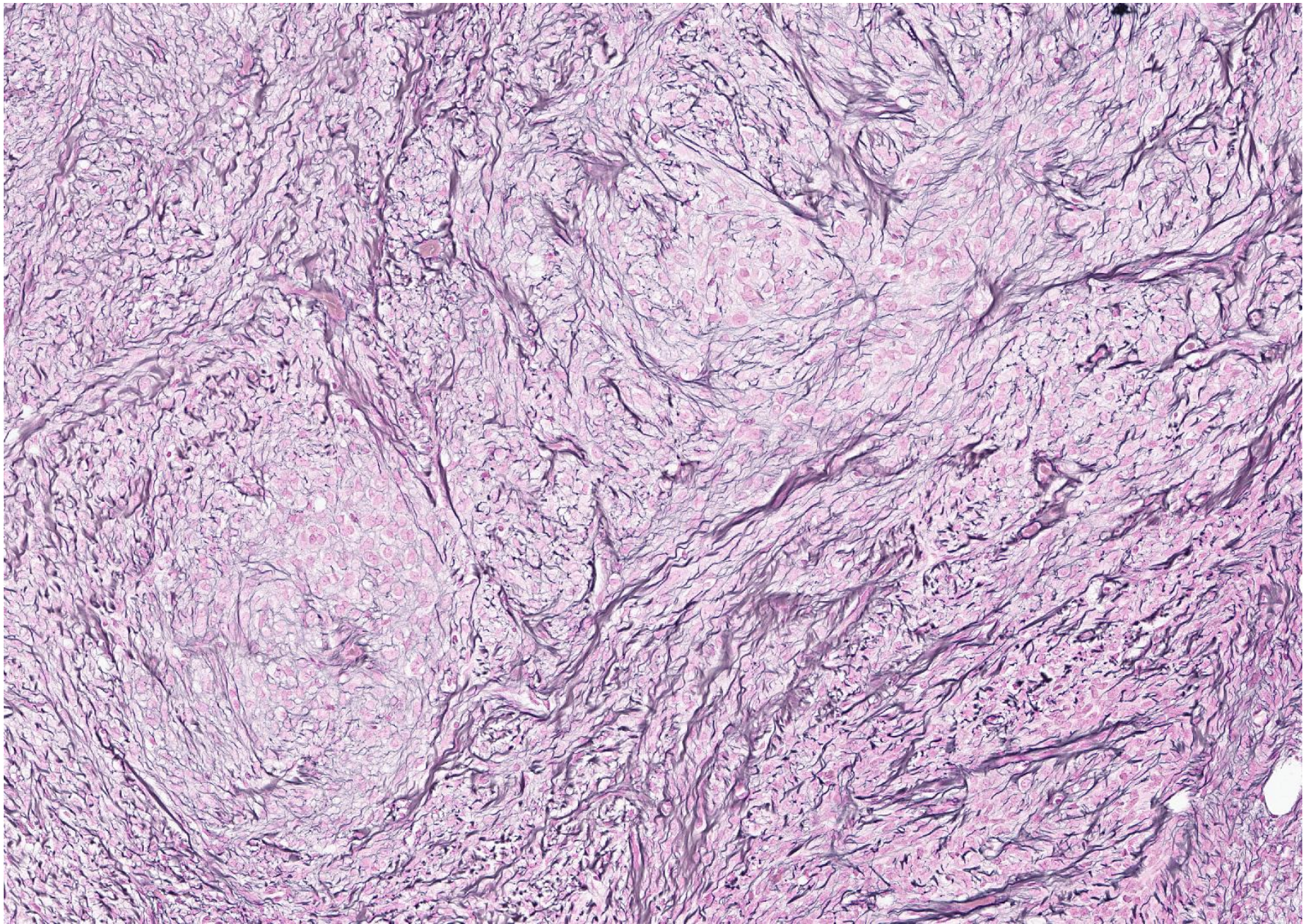

Original Article

FOXL2 Mutation Analysis of Ovarian Sex Cord-Stromal Tumors: Genotype-Phenotype Correlation With Diagnostic Considerations

Natalia Buza, M.D., Serena Wong, M.D., and Pei Hui, M.D., Ph.D.

Half of *FOXL2* mutated tumors had focal luteinized morphology

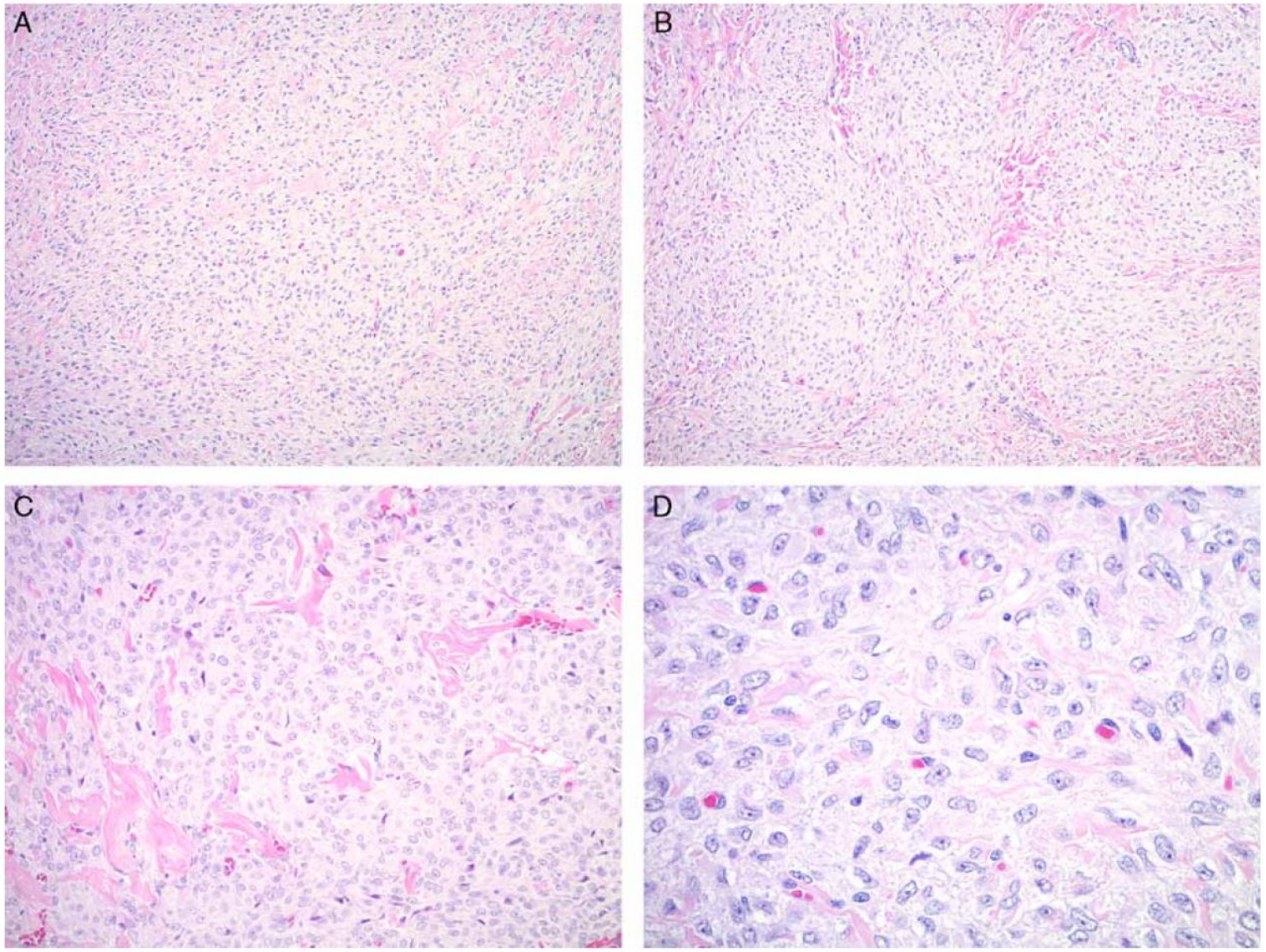

Figures from PMID: 28700438

AGCT with Thecoma-like Features

- **Rare variant**
- **Majority ≤ 5 cm** (most conventional AGCT > 5 cm)

Architecture	**Confluent nodules and sheets**
Cytology	▪ **Abundant pale cytoplasm** ▪ **Rare nuclear grooves** ▪ **No nucleoli**

- **Pericellular reticulin pattern is absent, diminished**
- **Differential diagnosis:**
  - Thecoma
  - Steroid cell tumor
- **No outcome data reported**
- ***FOXL2* mutation testing not performed in this series**

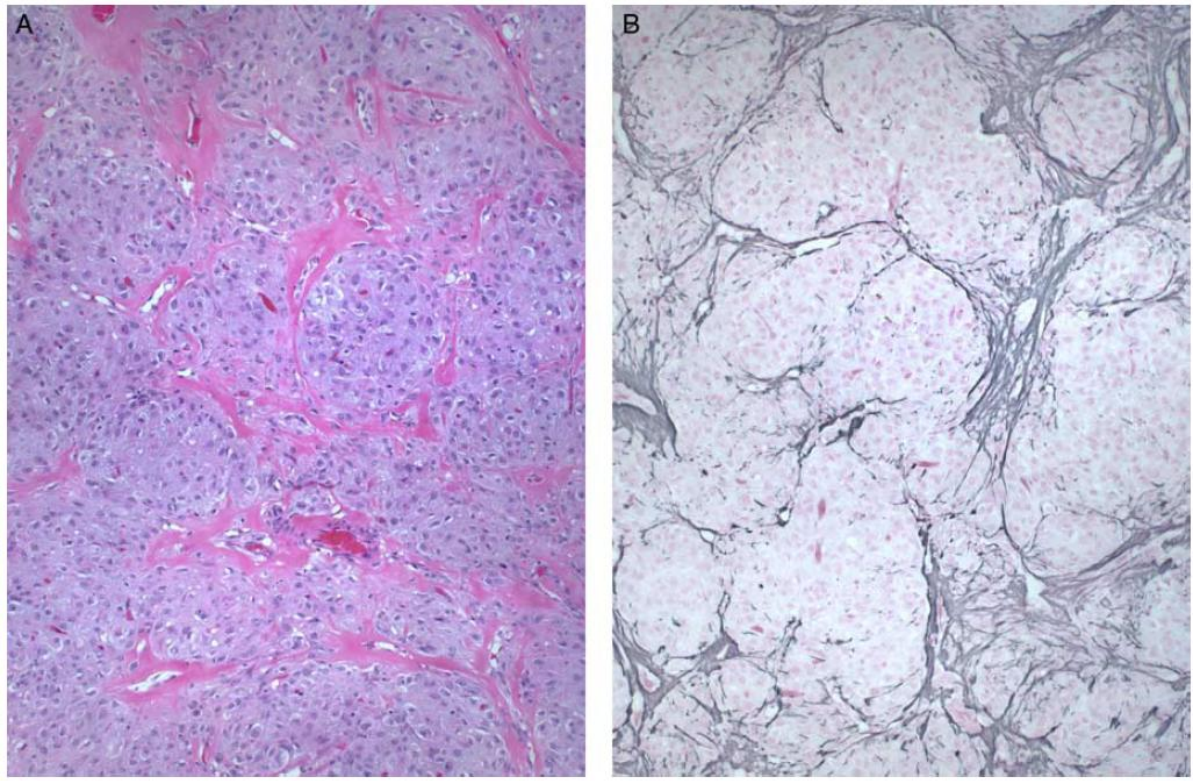

Figures from PMID: 29708950

Granulosa Cell Tumors of the Ovary With Prominent Thecoma-like Foci: A Report of 16 Cases Emphasizing the Ongoing Utility of the Reticulin Stain in the Modern Era

Jennifer N. Stall, M.D. and Robert H. Young, M.D.

Int J Gynecol Pathol Vol. 38, No. 2, March 2019

	AGCT, luteinized variant	AGCT, thecoma-like variant
★ **Abundant eosinophilic cytoplasm** *"…akin to a corpus luteum…"*	+	-
Prominent nucleoli	+	-
Myxoid stroma	+	-

Distinction is subject to observer variation but <u>not</u> clinically relevant

PMID: 29708950

AGCT with Thecoma-like Features

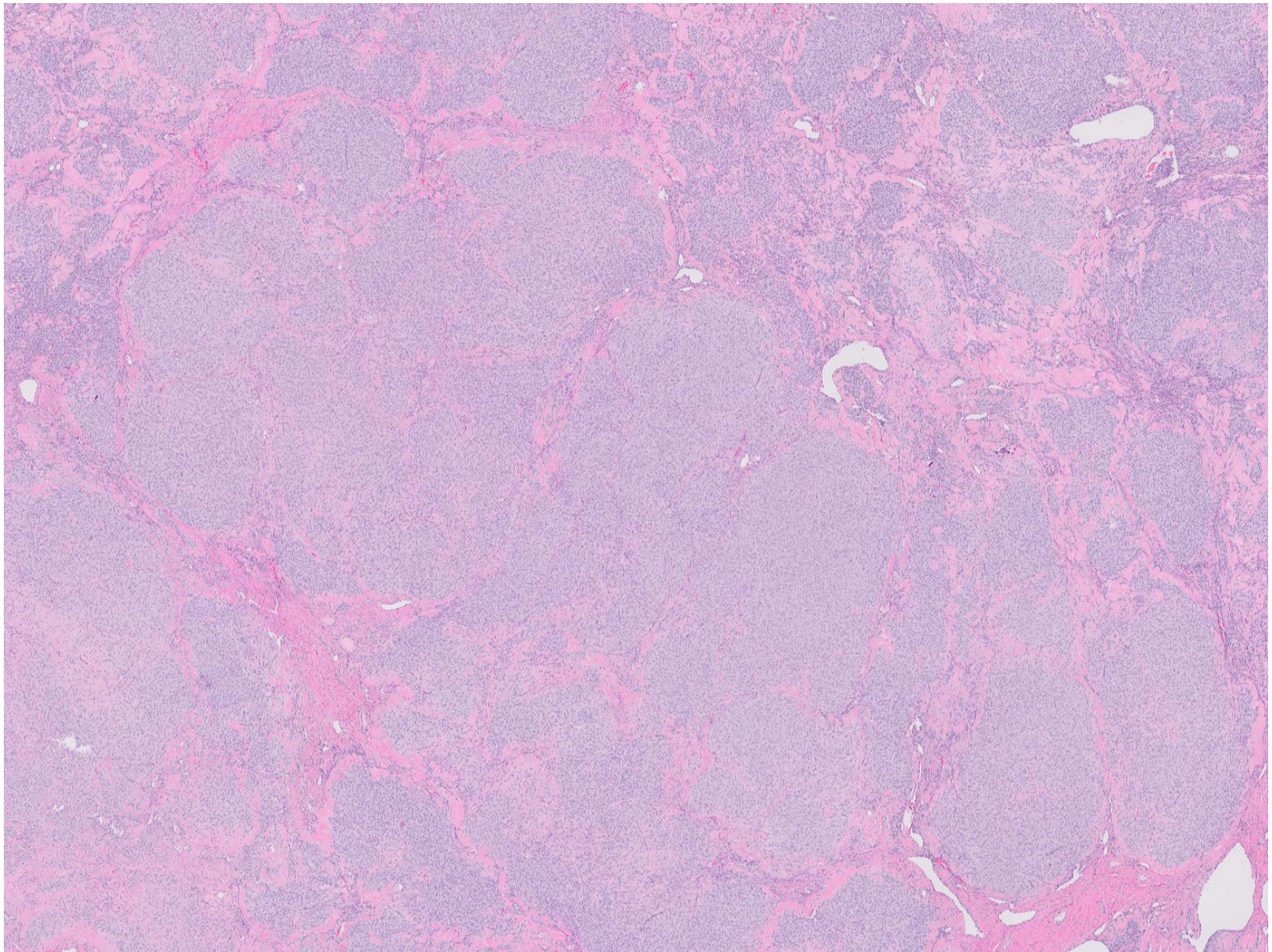

AGCT with Thecoma-like Features

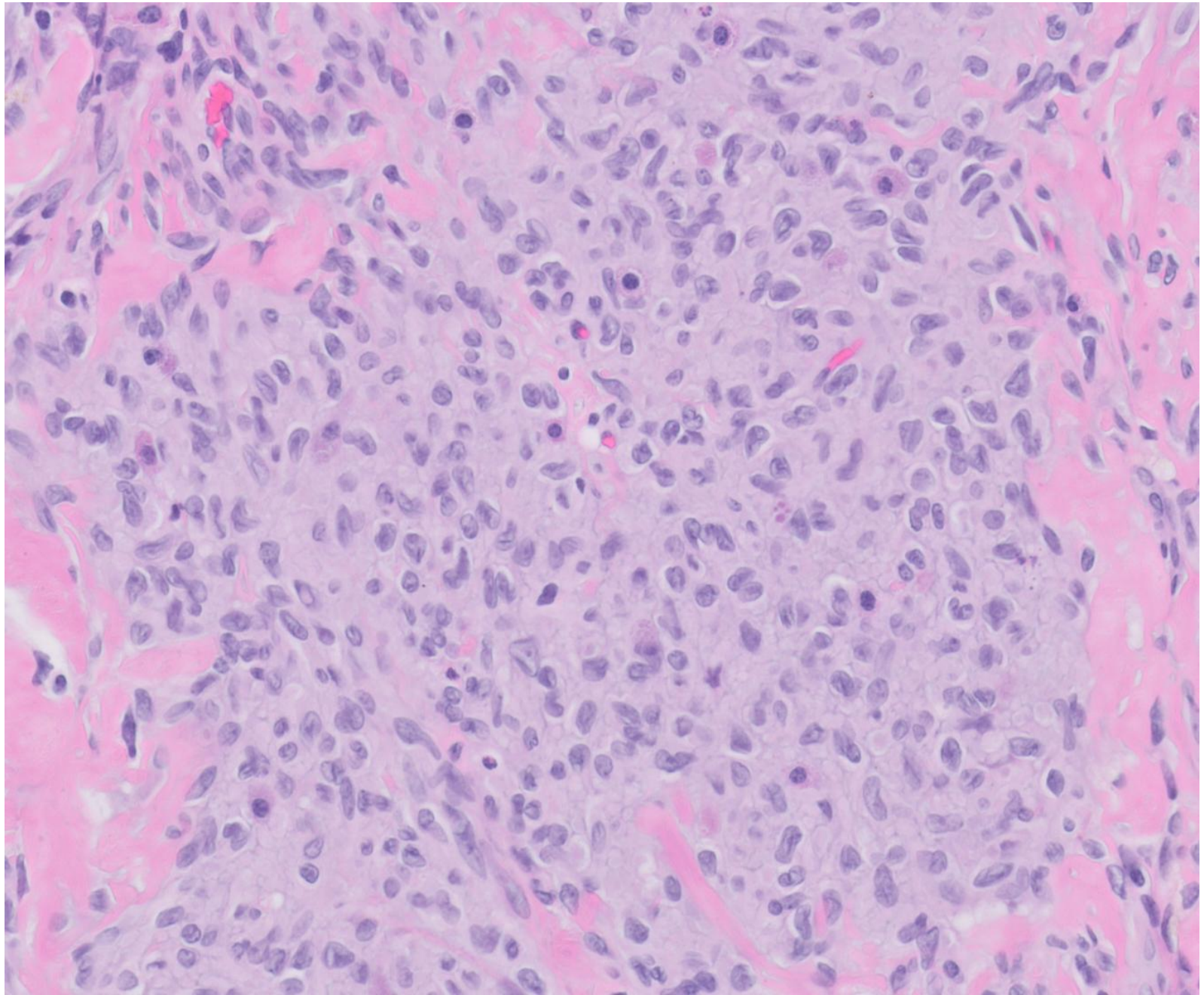

Reticulin stain:
Absence of pericellular staining

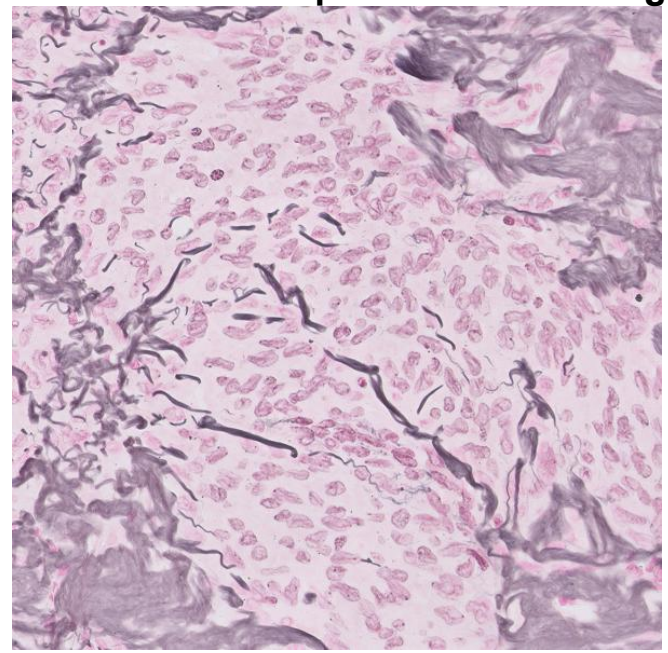

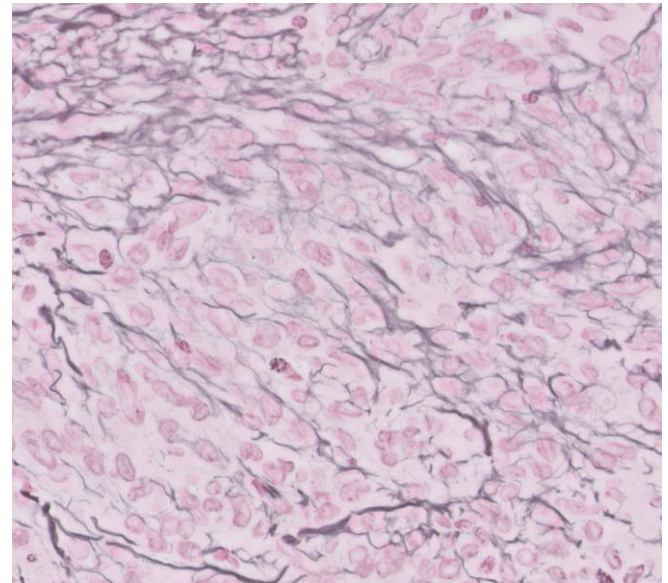

Luteinized / Thecoma-like Adult Granulosa Cell Tumor

Differential Diagnosis

Tumor Family	Mimics
Sex Cord Stromal	Thecoma ▪ Steroid cell tumor ▪ Leydig cell tumor ▪ Pregnancy luteoma ▪ Nodular hyperthecosis ▪ Microcystic stromal tumor, solid variant
Epithelial	▪ Oxyphilic endometrioid / clear cell carcinoma ▪ Metastatic carcinoma to ovary ▪ Brenner tumor
Mesenchymal	▪ PEComa ▪ Epithelioid smooth muscle tumor ▪ Epithelioid GIST
Germ Cell	▪ Oxyphilic struma ovarii ▪ Hepatoid yolk sac tumor
Other	▪ Melanoma ▪ Deciduoid mesothelioma ▪ Large cell variant small cell carcinoma, hypercalcemic ▪ Solid pseudopapillary tumor

Thecoma

New refined criteria

- **Rare**
- **Wide age range** (average 49 y)
- **Abnormal uterine bleeding**
- **Wide size range** (average 4.9 cm)



Architecture	**Diffuse / nodular** **+/- hyaline plaque, sclerosis** **+/- calcification** **+/- minor component of fibroma**
Cytology	**Ill-defined cell membranes** (syncytial-like) **Pale gray cytoplasm** ▪ **+/- nuclear grooves**

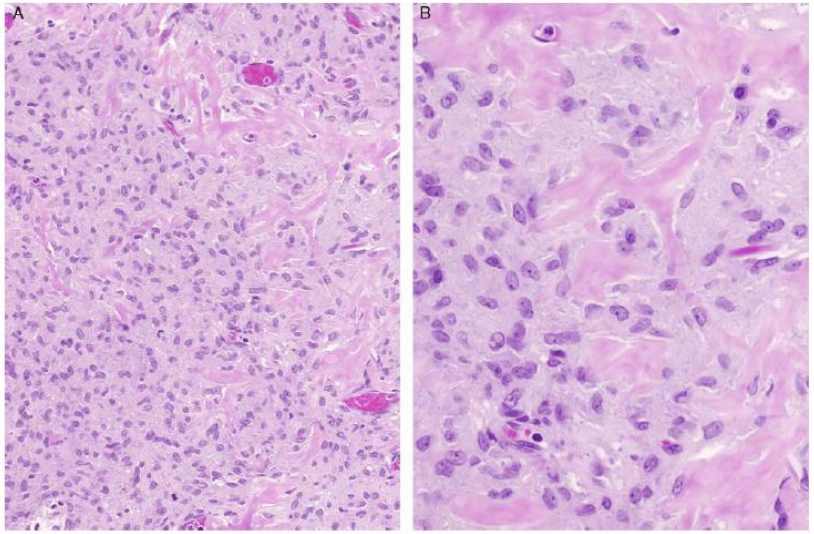

Figures from PMID: 25025365

- **Pericellular reticulin pattern present** (only rare cases tested)
- **No outcome data in this new series but historically these are benign**
- **No *FOXL2* mutation testing in this new series**

Thecoma of the Ovary

A Report of 70 Cases Emphasizing Aspects of Its Histopathology Different From Those Often Portrayed and Its Differential Diagnosis

Eike Burandt, MD† and Robert H. Young, MD*†*

Am J Surg Pathol 2014;38:1023–1032

Thecoma

nodular

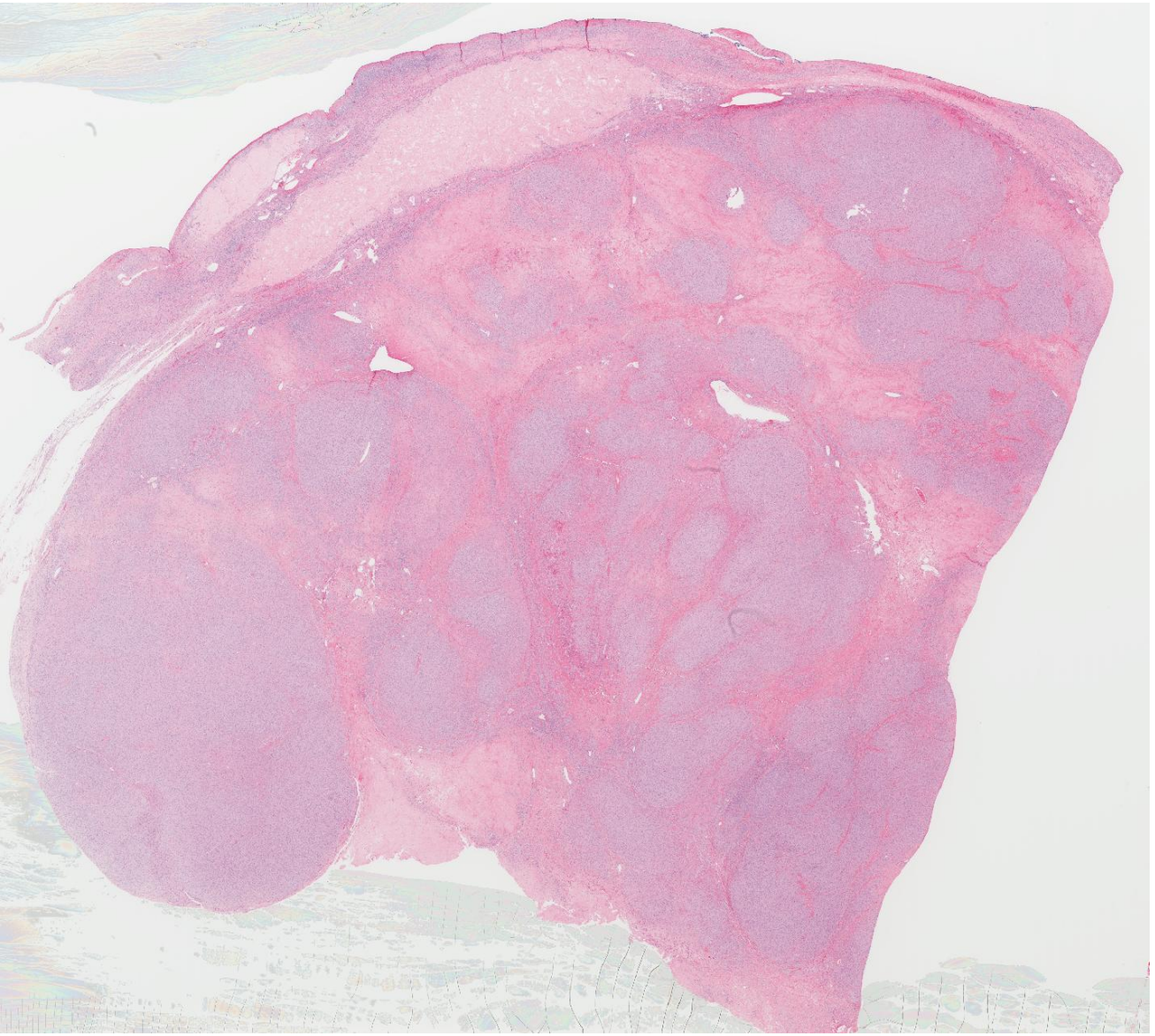

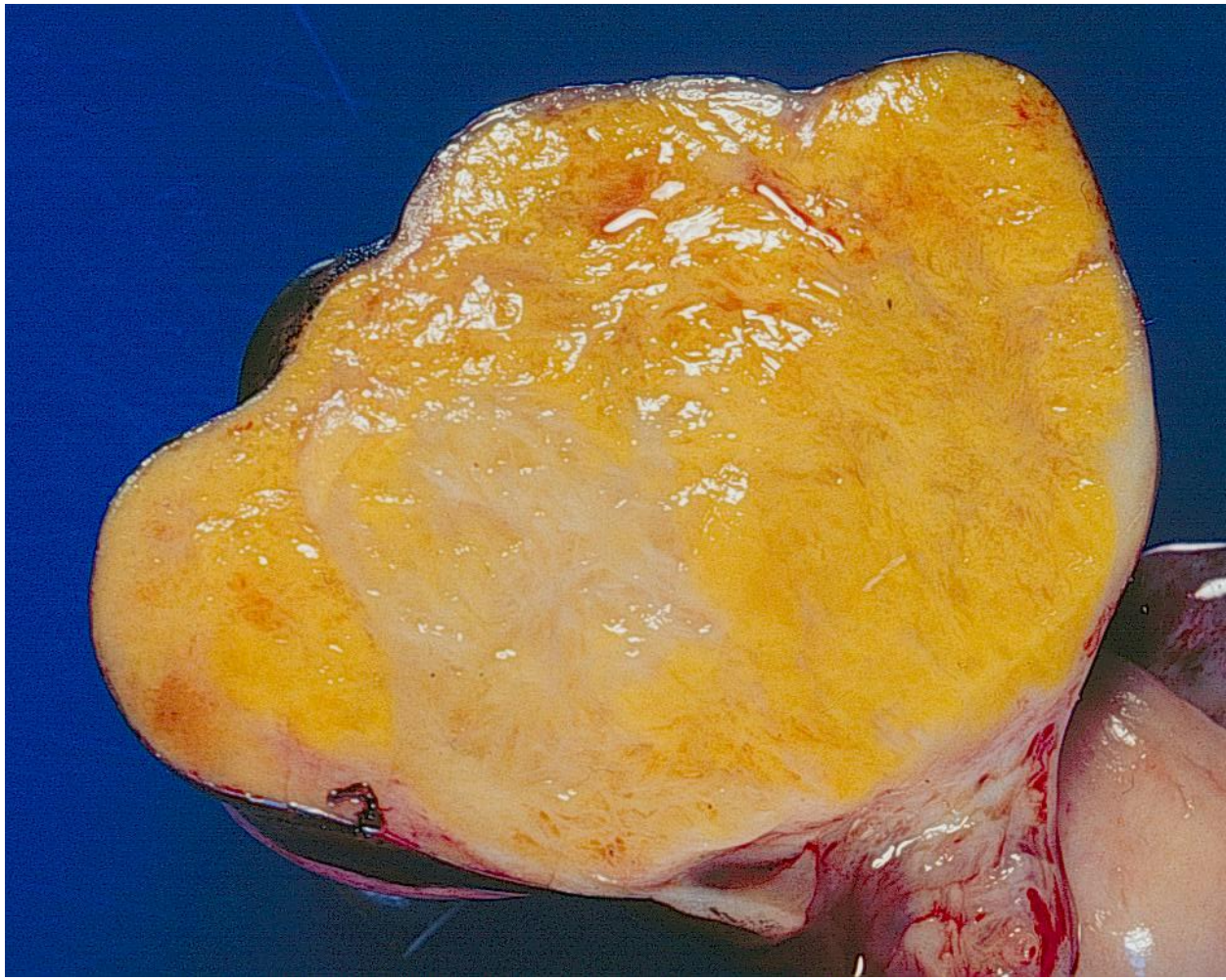

Thecoma

pale grey cytoplasm

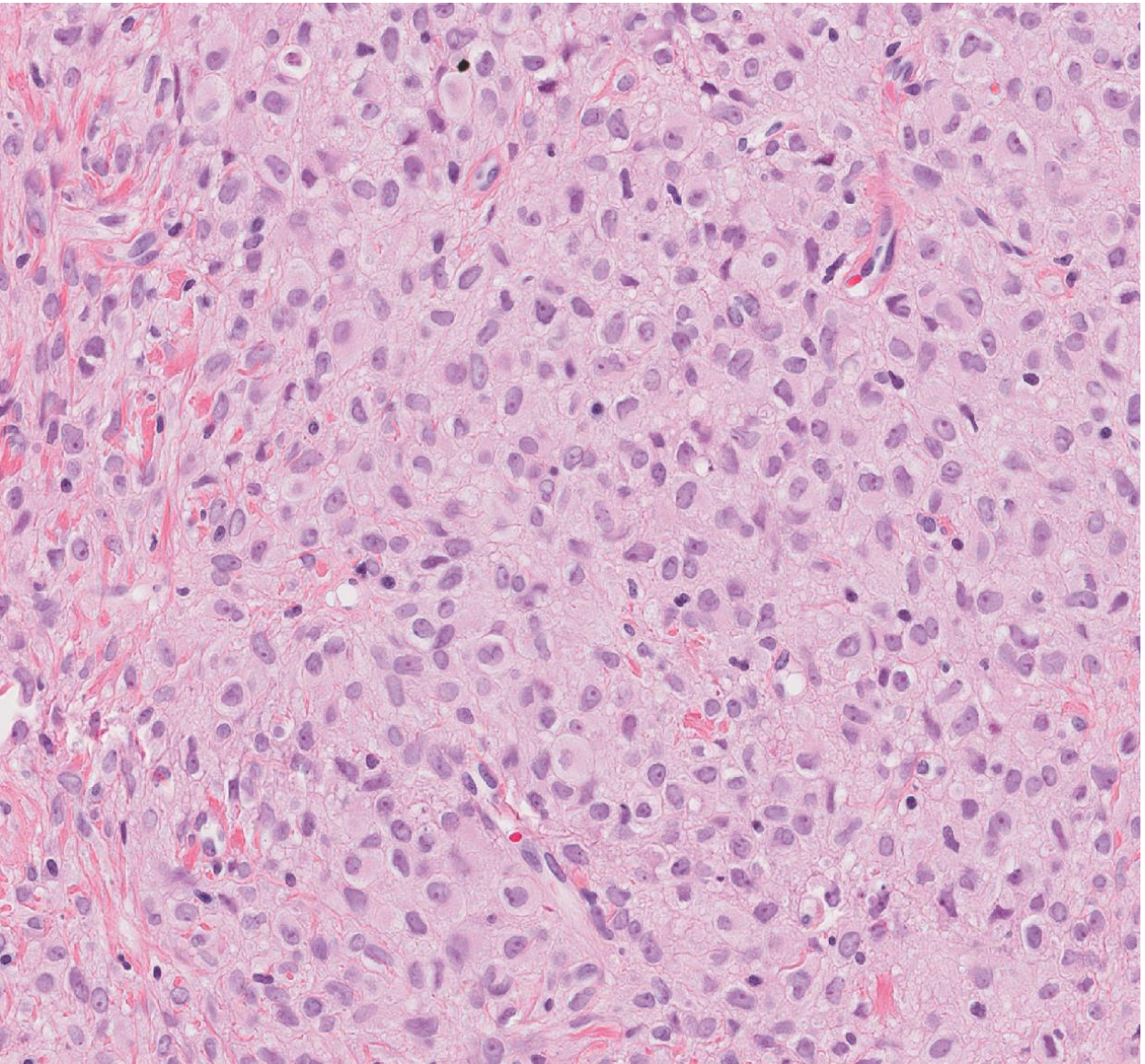

Intact pericellular reticulin

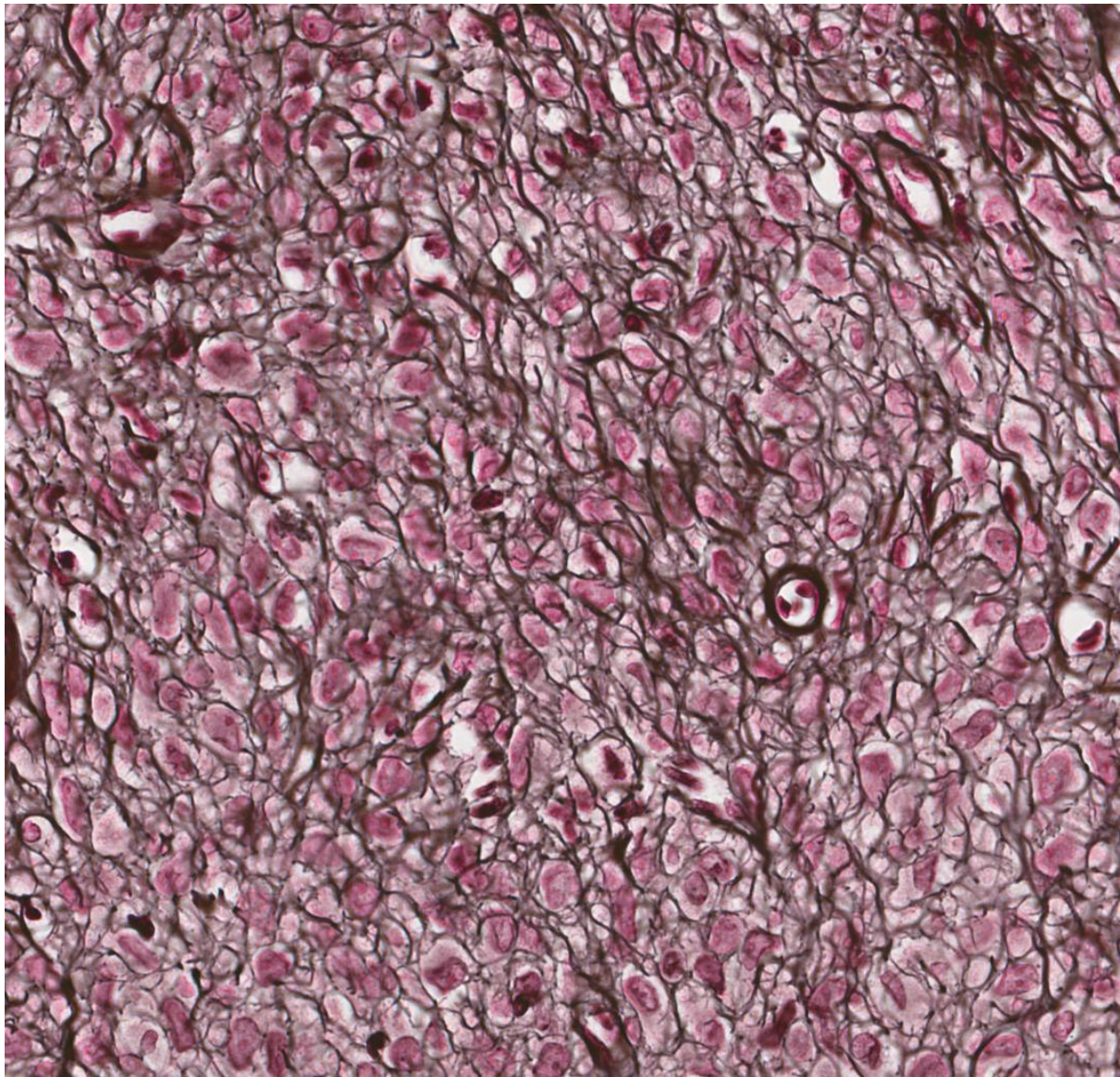

	AGCT Luteinized variant, Thecoma-like variant	Thecoma
Age	**Same**	
Macroscopic appearance	**Same**	
Sheets, nodules, nests	**Same**	
Hyaline plaque/fibromatous	**Same**	
Monomorphic cells	**Same**	
Minimal nuclear grooves	**Same**	
Low mitotic index	**Same**	
Cytoplasm	**Eosinophilic**	**Pale grey**
Pericellular reticulin	**Incomplete / absent*** (*limited studies)	**Complete*** (*limited studies)

	AGCT Luteinized variant, Thecoma-like variant	Thecoma
Age	Same	
Macroscopic appearance	Same	
Sheets, nodules, nests	Same	
Hyaline plaque/fibromatous	Same	
Monomorphic cells	Same	
Minimal nuclear grooves	Same	
Low mitotic index	Same	
Cytoplasm	Eosinophilic	Pale grey
Pericellular reticulin	Incomplete / absent* (*limited studies)	Complete* (*limited studies)
***FOXL2* status** (in concept)	**Mutated**	**Wild type**

Literature on FOXL2 status in these variants:

- *sparse*
- *complex due to classification dilemma* *(morphology versus molecular)*

**some cases in literature reported with mutation*

	Pericellular reticulin	*FOXL2* mutation
Luteinized AGCT	Absent	Present

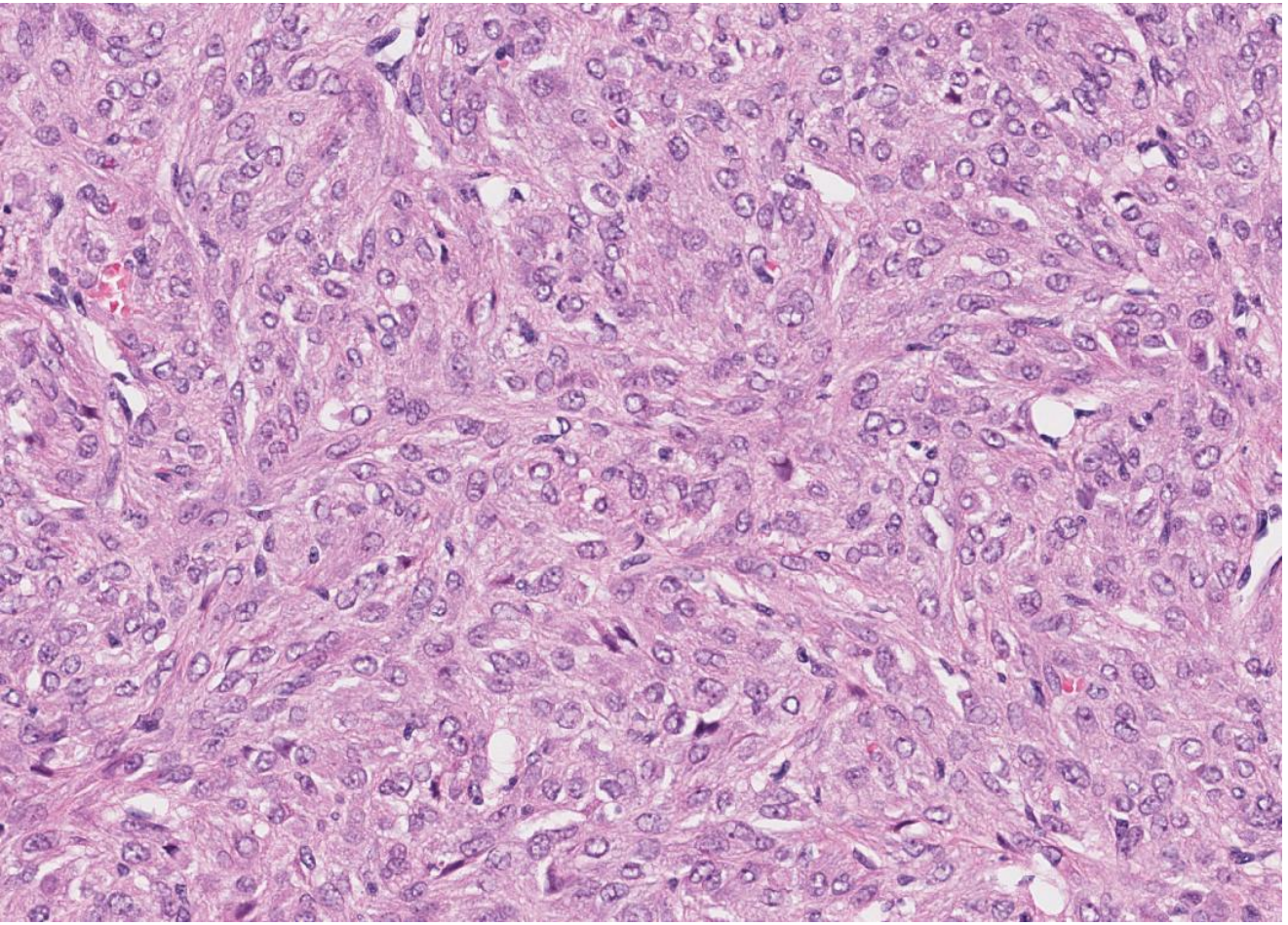

	Pericellular reticulin	*FOXL2* mutation
Thecoma	Present	Absent

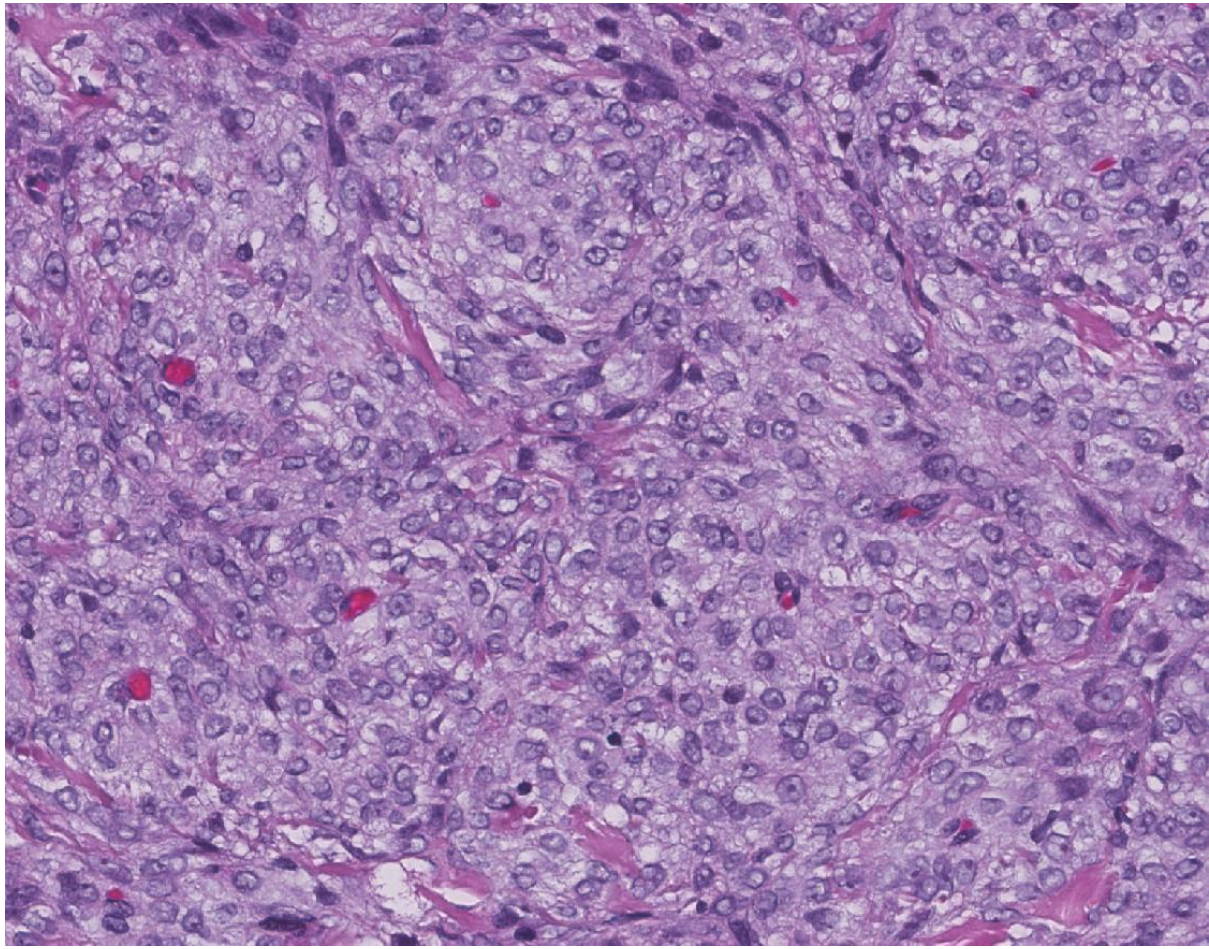

"Thecomas" with *FOXL2* mutation

First author	PMID	Total # Thecomas	# *FOXL2* Mutated	Pericellular Reticulin stain	Granulosa cell component	Recurred
Kim	20198651	16	**2 (12%)**	Not studied	0	Not studied
Shah	19516027	14	**3 (21%)**	Absent 1/1	1/3	Not studied
Al-Agha	21378549	5	**2 (40%)**	Not studied	0	1
Buza	28700438	3	**2 (66%)** **Reclassified as AGCT**	Detail not reported	Not studied	0
Maillet	24157616	4	**4 (100%)** **Reclassified as AGCT**	Present 3/3	Not studied	Not studied
Kommoss	23348906	3	**2 (66%)** **Reclassified as AGCT**	Not studied	Not studied	Not studied

Luteinized features

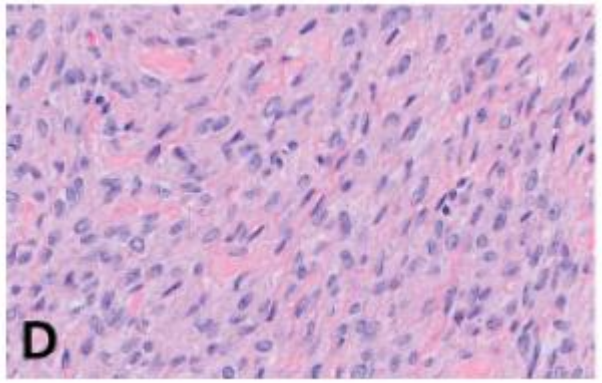

Figure from PMID: 20198651

Loss of pericellular reticulin

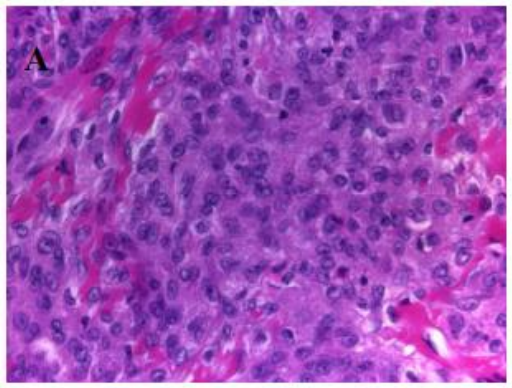

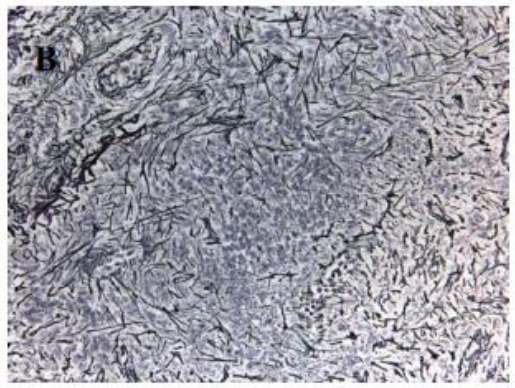

Figures from PMID: 19516027

Unresolved Dilemma for WHO Classification

How to Classify Discordant Morphology versus Molecular ?

Scenario	Morphology	FOXL2 status	WHO Final Classification	My Personal View
1	**Classic for AGCT**	**Wild type**	**?**	SCST, NOS
2	**Classic for thecoma**	**FOXL2**	**?**	AGCT

- *Outcome-based classification remains elusive as only rare examples of adverse outcome exist*
- *Descriptive classification as sex cord stromal tumor NOS is reasonable option*
- *Long term surveillance for recurrence is advised*

AGCT, thecoma-like, *FOXL2* mutated

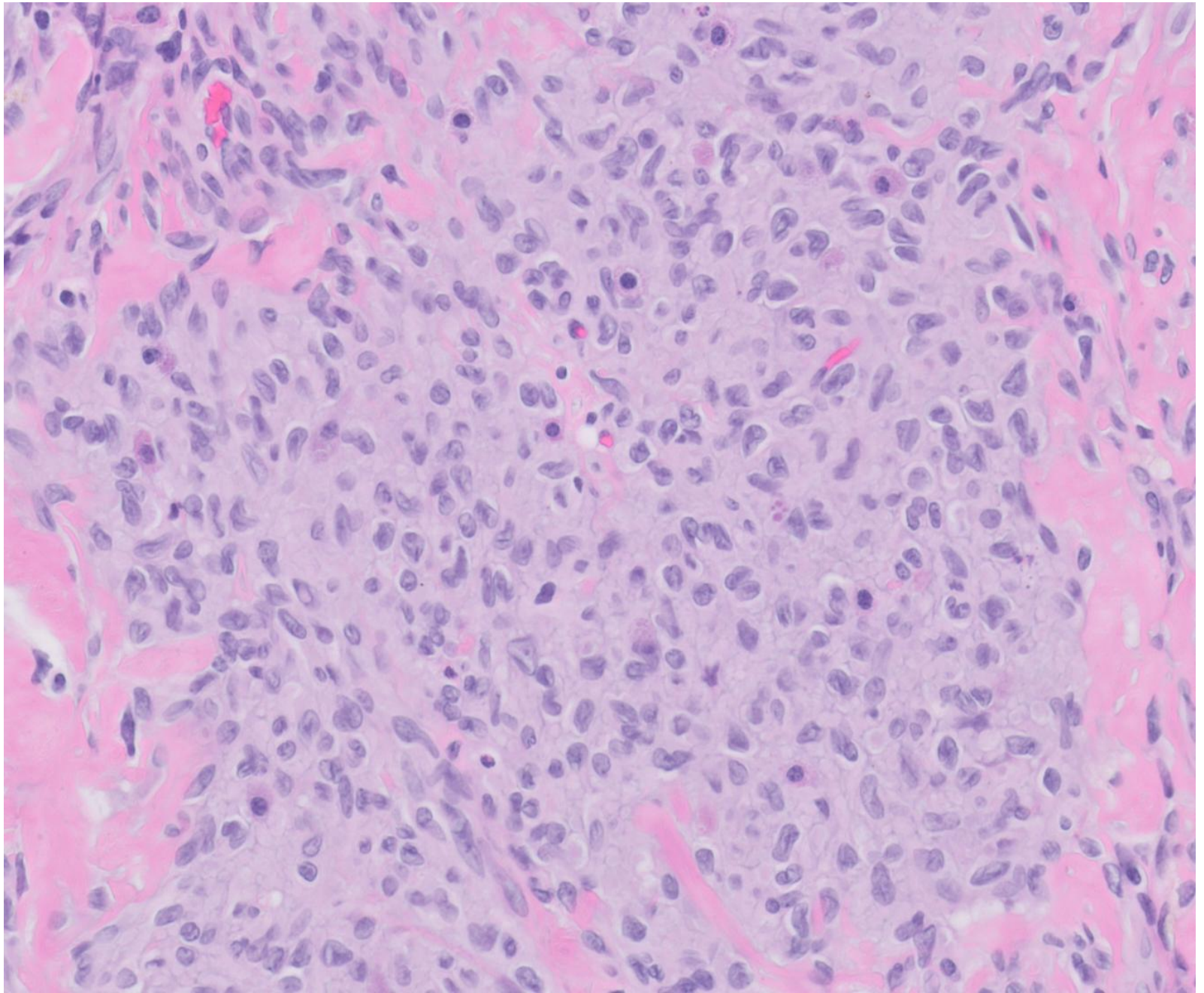

Practical Issues with Diagnosis of Ovarian “Thecoma”

- **Best viewed as a diagnosis of exclusion**
  - **Confirm entirely intact reticulin staining**
  - **Confirm wild type FOXL2**
- **Distinguish the entities of fibroma versus thecoma**
  - **WHO discourages the term “fibro-thecoma”**

Cellular Fibroma

WHO Definition

- **Ovarian fibroma with increased cellularity**
- **Mitotic activity may be present**
- **No nuclear atypia**

Cellular Fibromas of the Ovary: A Study of 75 Cases Including 40 Mitotically Active Tumors Emphasizing Their Distinction From Fibrosarcoma

Julie A. Irving, MD, Abdulmohsen Alkushi, MD,† Robert H. Young, MD,‡ and Philip B. Clement, MD**

Am J Surg Pathol 2006;30:929–938

PMID: 16861962

Clinical Significance

- **Mostly benign**
- **Rare risk of local recurrence** (rupture, adherent to other organs)
- **No progression to malignancy**

- **Diagnostic mimicry of diffuse pattern adult granulosa cell tumor**

Ovarian Cellular Fibromas Lack *FOXL2* Mutations

A Useful Diagnostic Adjunct in the Distinction From Diffuse Adult Granulosa Cell Tumor

W. Glenn McCluggage, FRCPath, Naveena Singh, FRCPath,† Stefan Kommoss, MD,‡ David G. Huntsman, MD,‡ and C. Blake Gilks, MD§‖*

Am J Surg Pathol 2013;37:1450–1455

PMID: 23774170

Cellular Fibroma

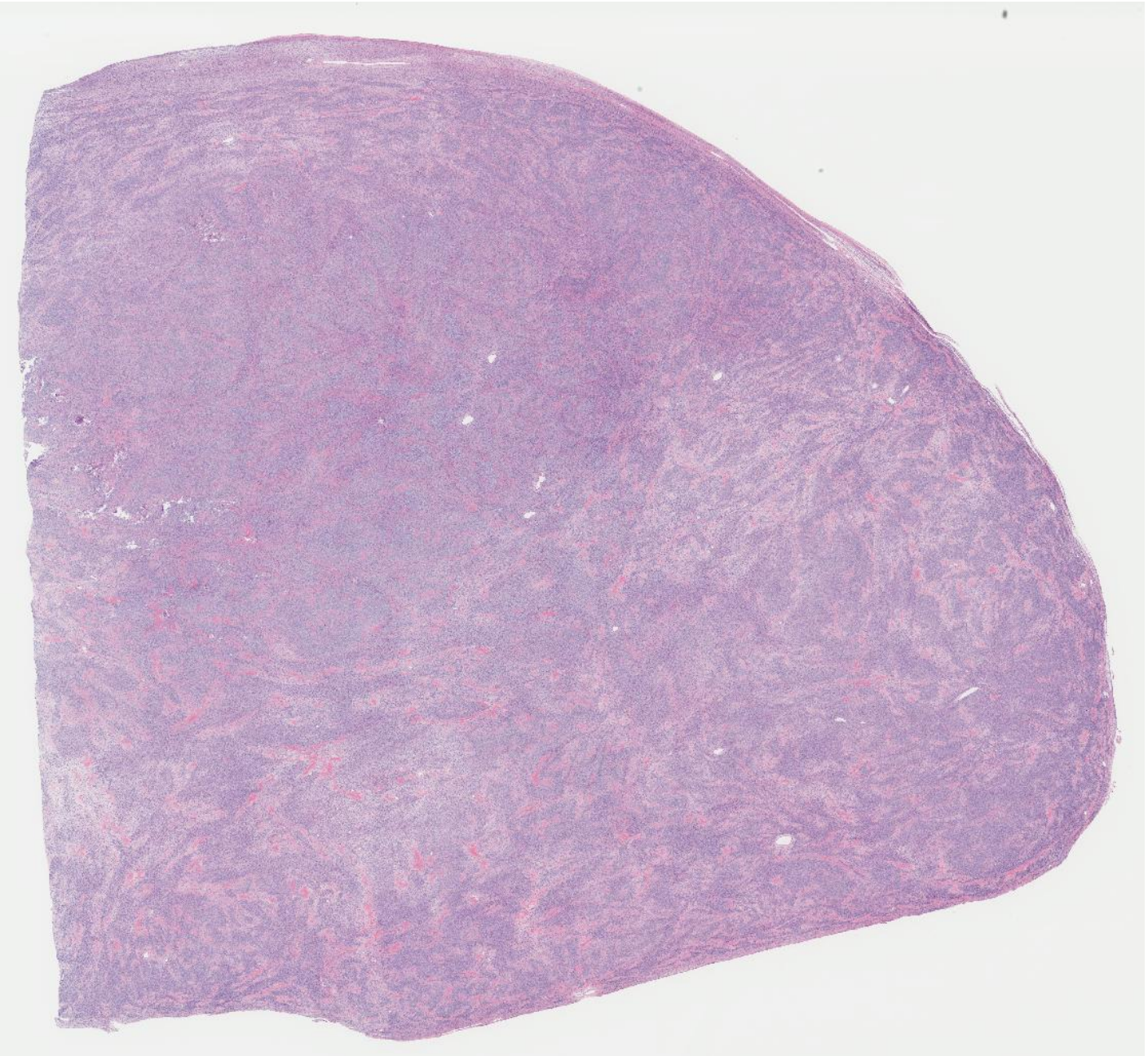

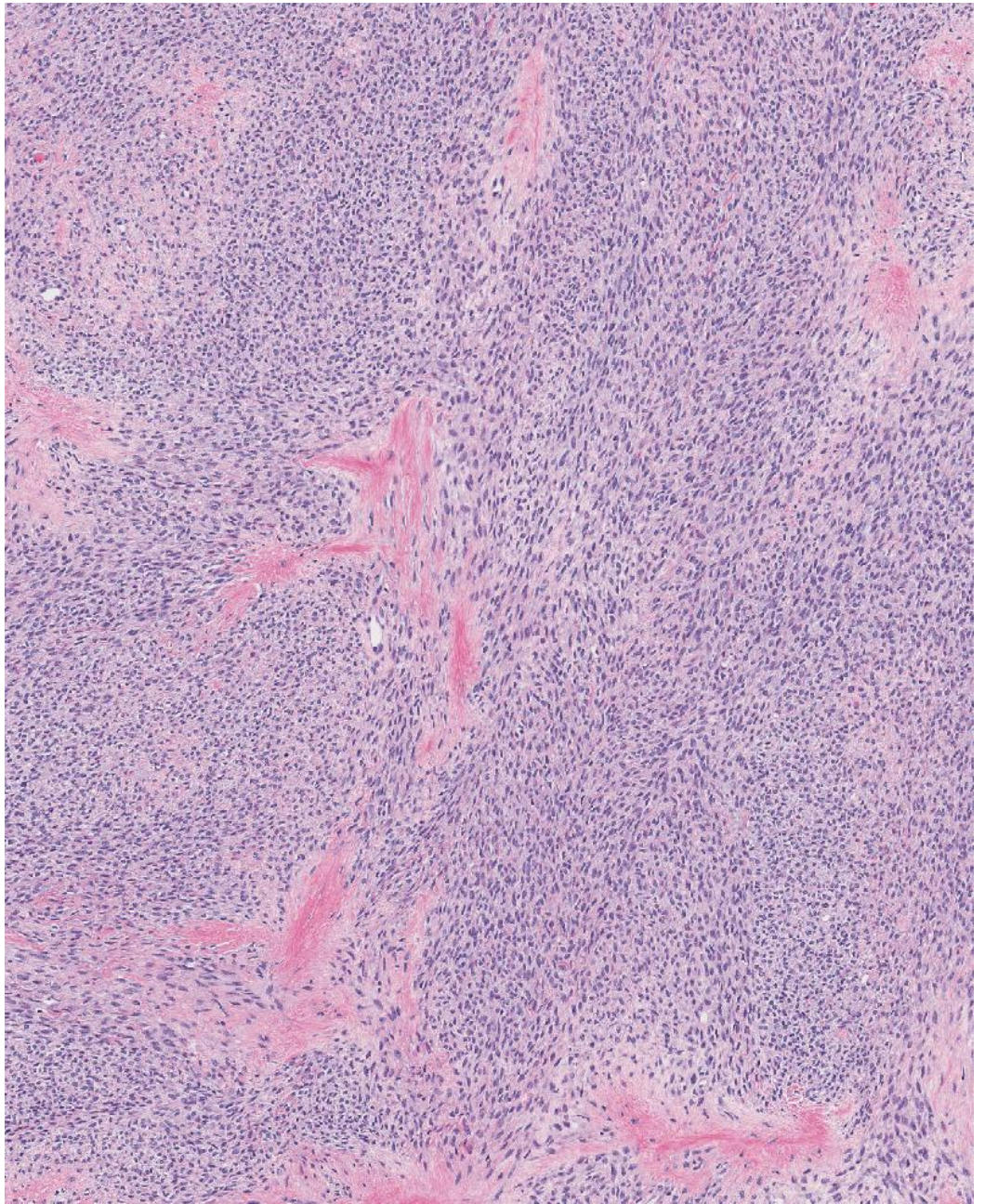

Cellular Fibroma

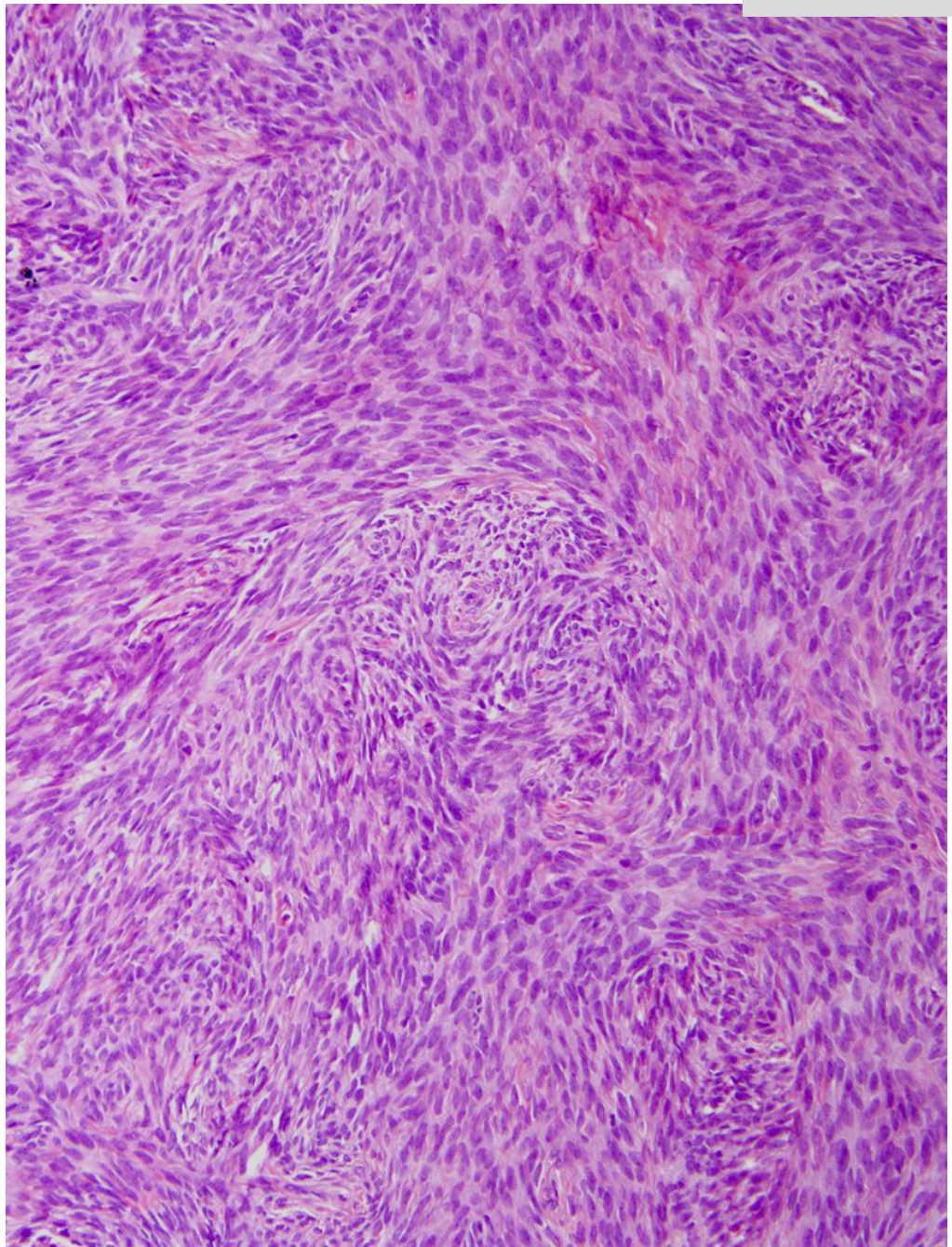

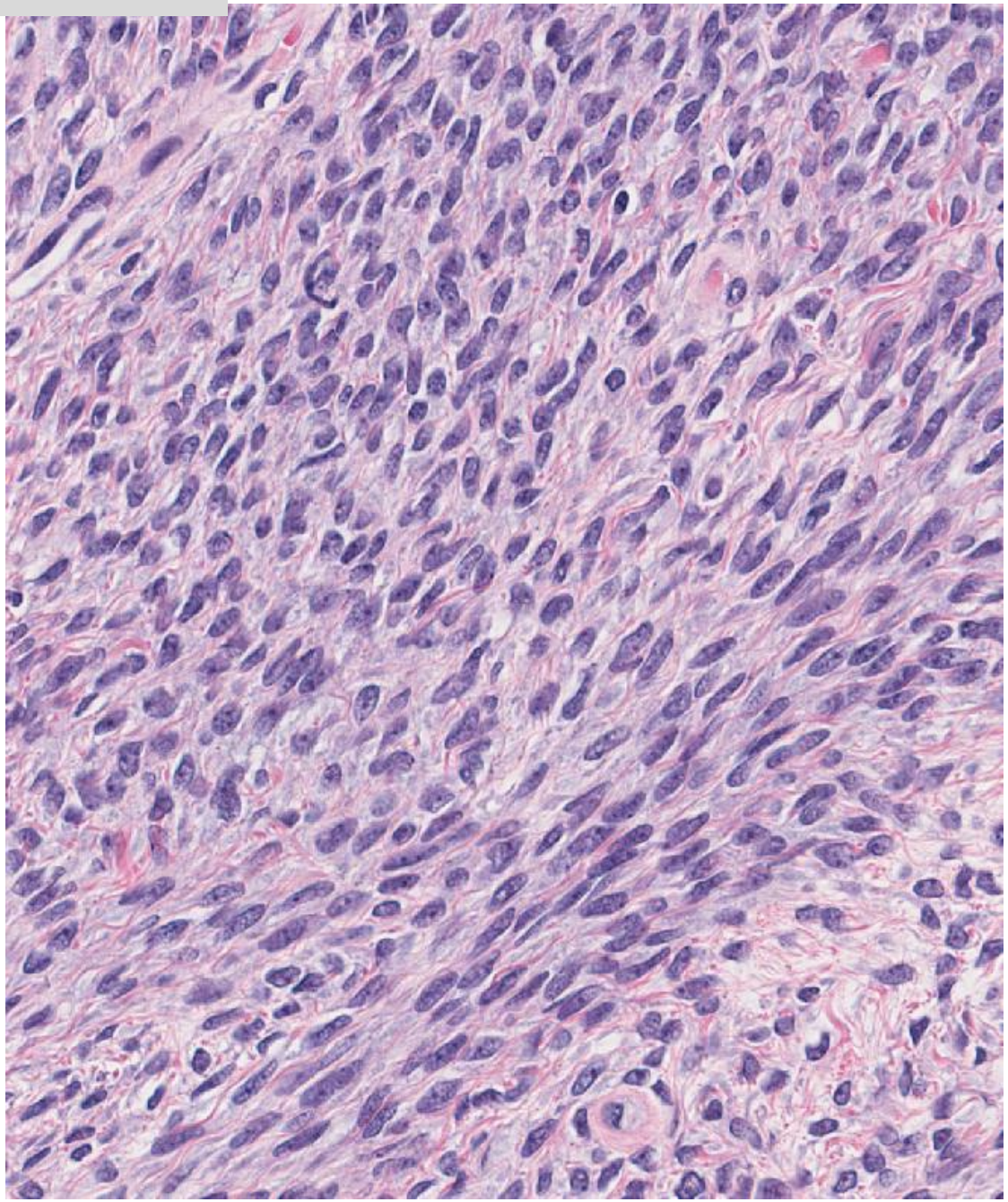

Diffuse Pattern AGCT

Mimics cellular fibroma

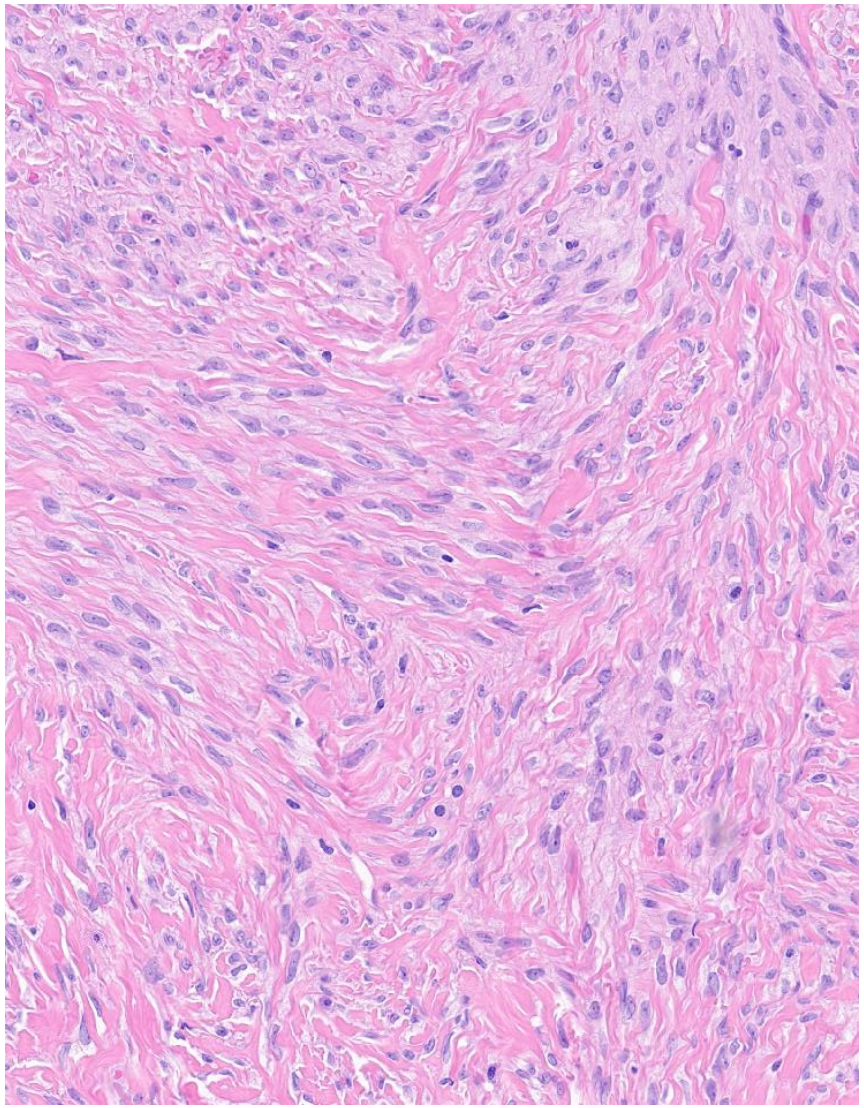

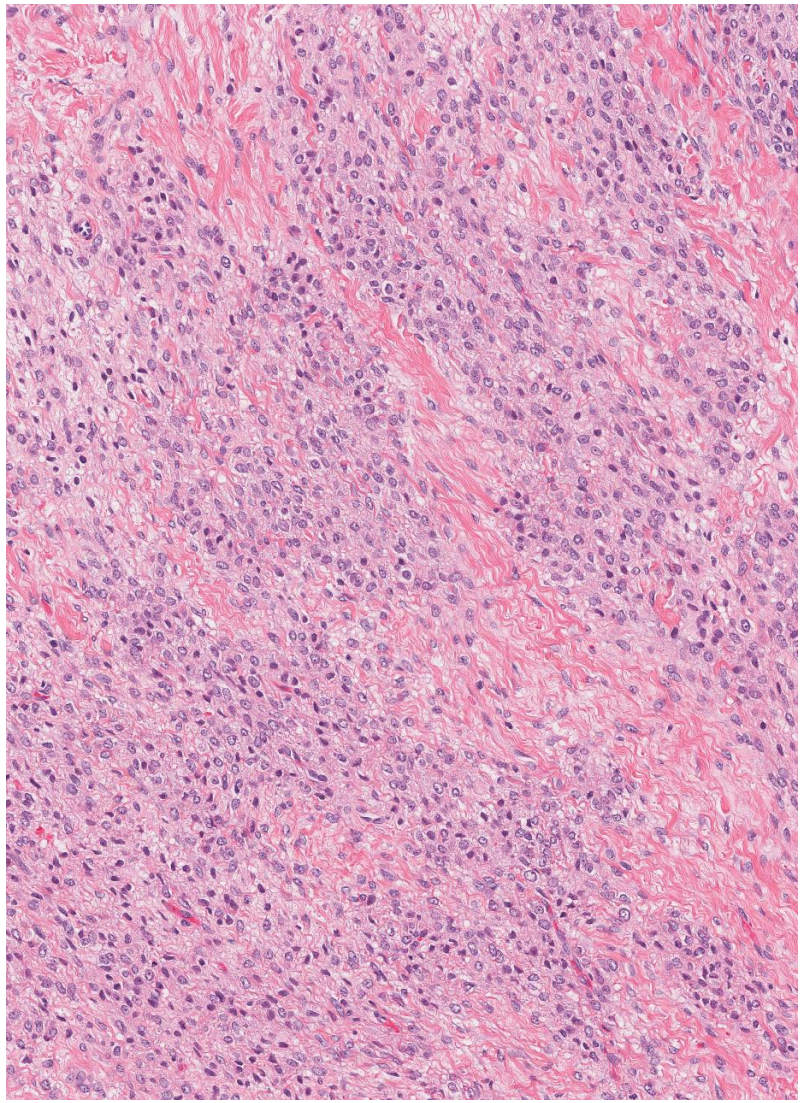

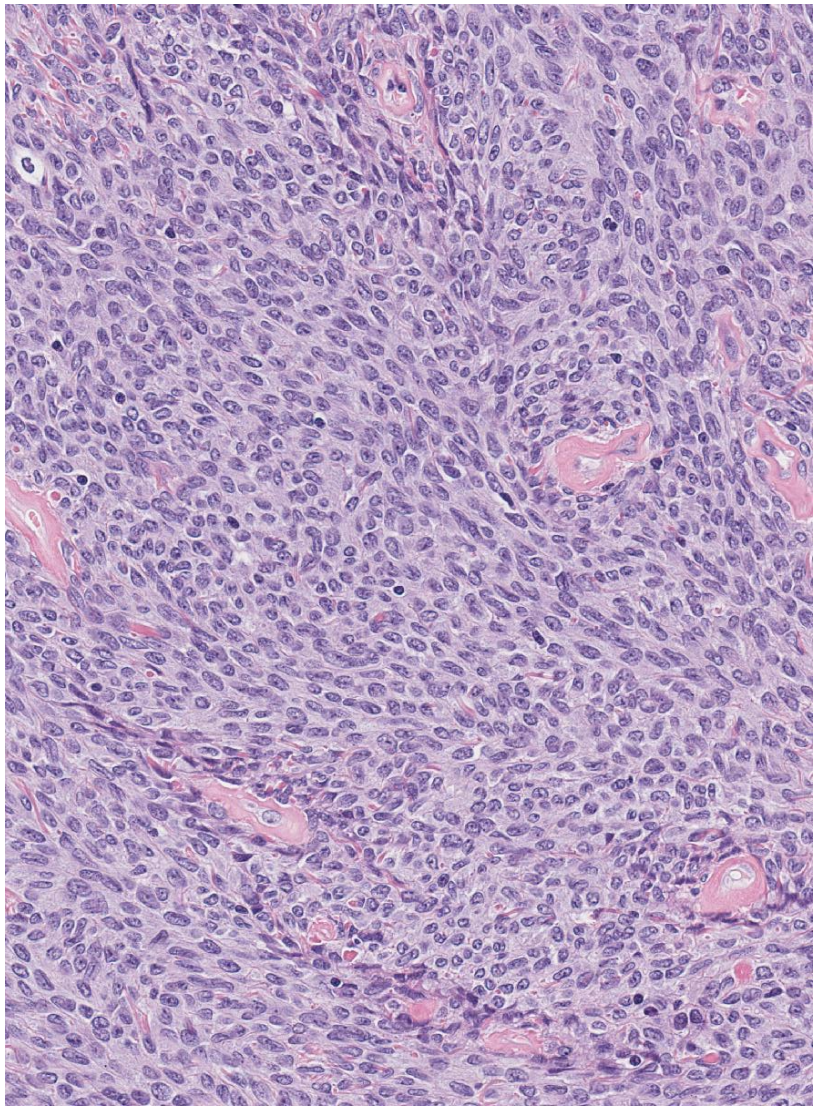

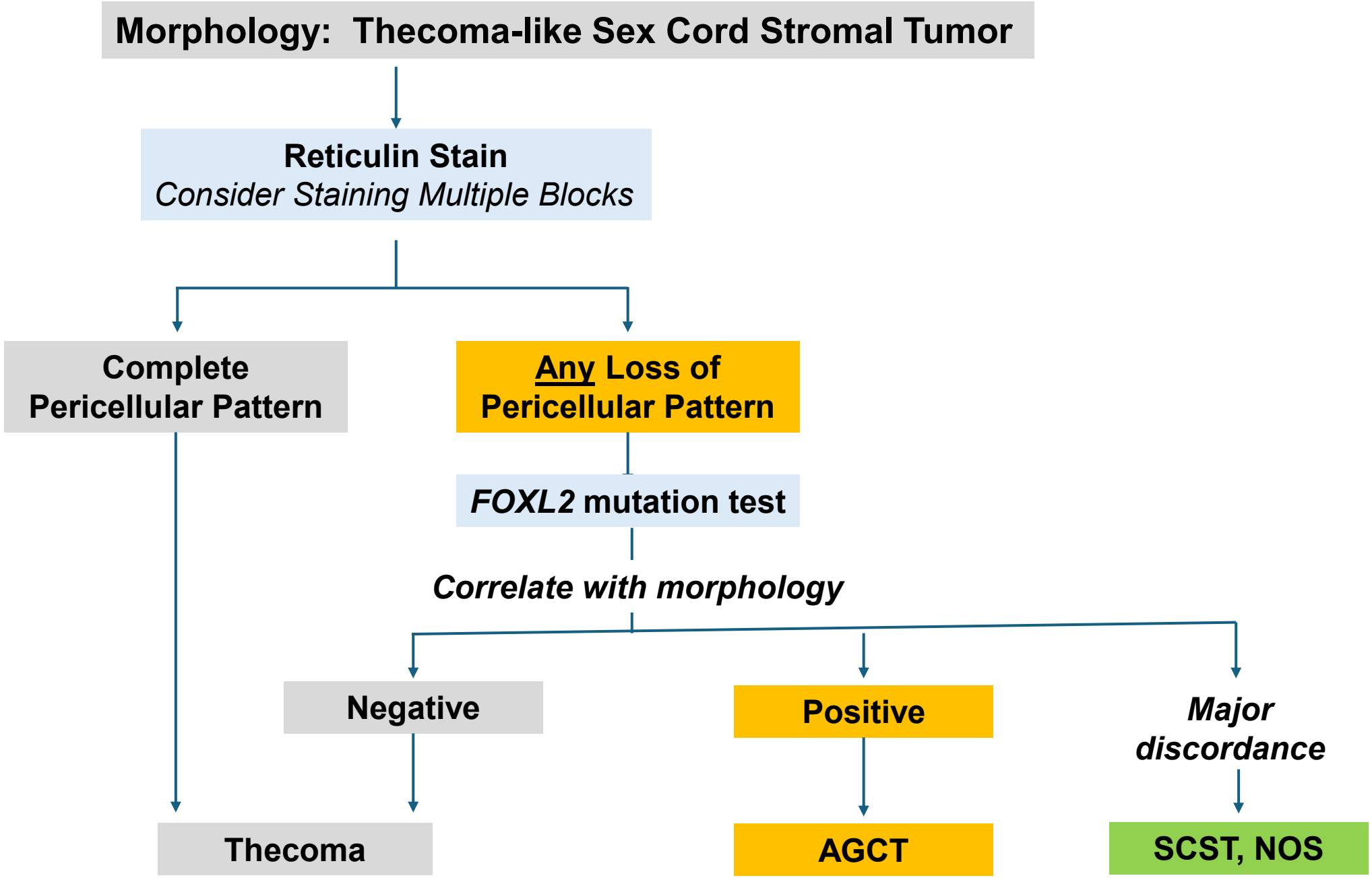
Morphology: Thecoma-like Sex Cord Stromal Tumor
Reticulin Stain
Consider Staining Multiple Blocks
Complete Pericellular Pattern
Any Loss of Pericellular Pattern
FOXL2 mutation test
Correlate with morphology
Negative
Positive
Major discordance
Thecoma
AGCT
SCST, NOS

Outline of Talk

- Luteinized sex cord stromal tumor (AGCT, thecoma)

Steroid cell tumor: risk stratification

Steroid Cell Tumor of Ovary

WHO Definition:

- **Tumor composed of steroid cells in parenchyma of ovary**

Location in ovary	Classification	Malignant Potential
Parenchyma	Steroid cell tumor	Yes
Hilum	Leydig cell tumor	No

Steroid Cell Tumor of Ovary

WHO Definition:

- **Tumor composed of steroid cells in <u>parenchyma</u> of ovary**

Clinical presentation:

- **Endocrine symptoms are common:** *Androgenic, estrogenic, or Cushing syndrome*

- **Unilateral**
- **~8 cm**
- **Solid fleshy yellow / orange / dark red**

Steroid Cell Tumor of Ovary

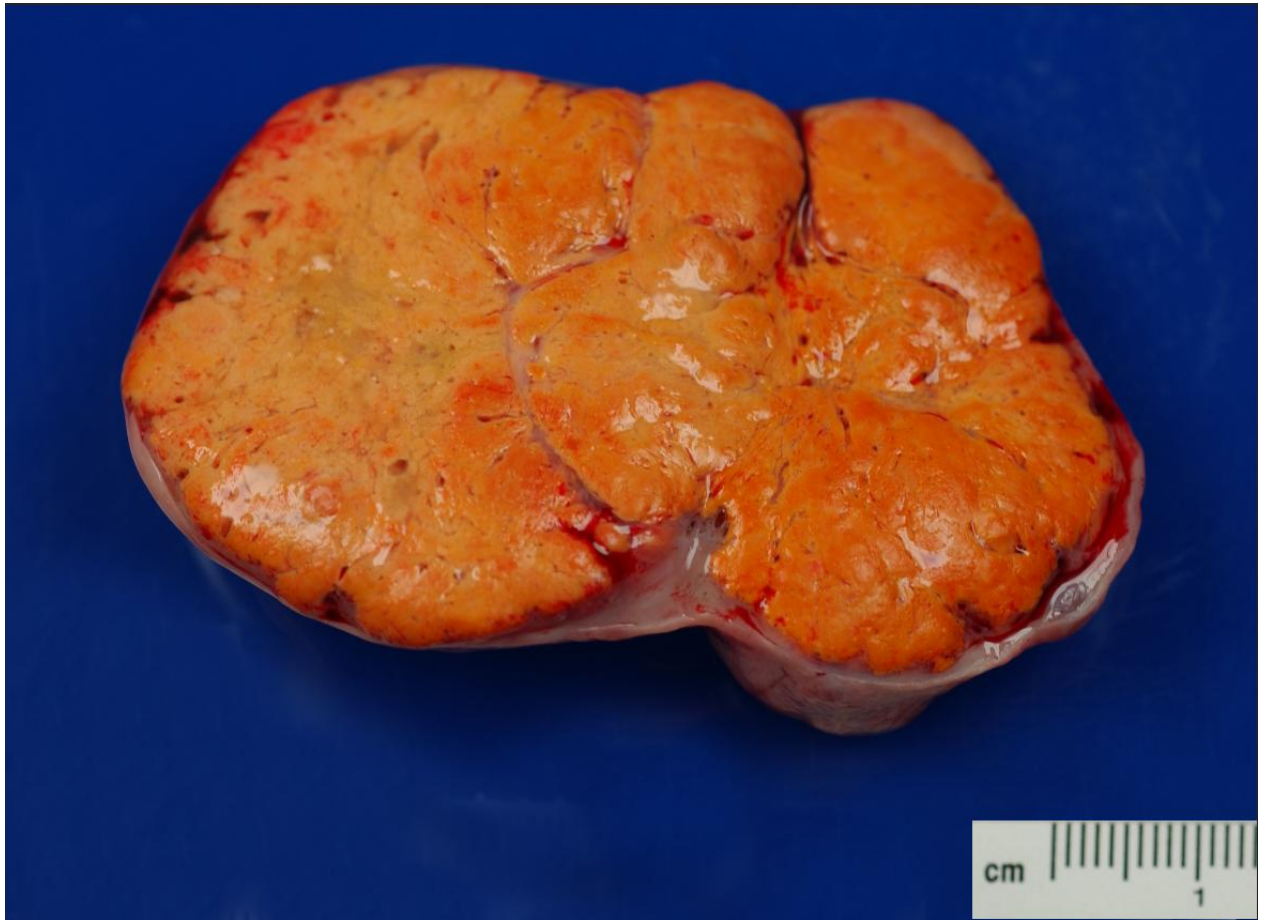

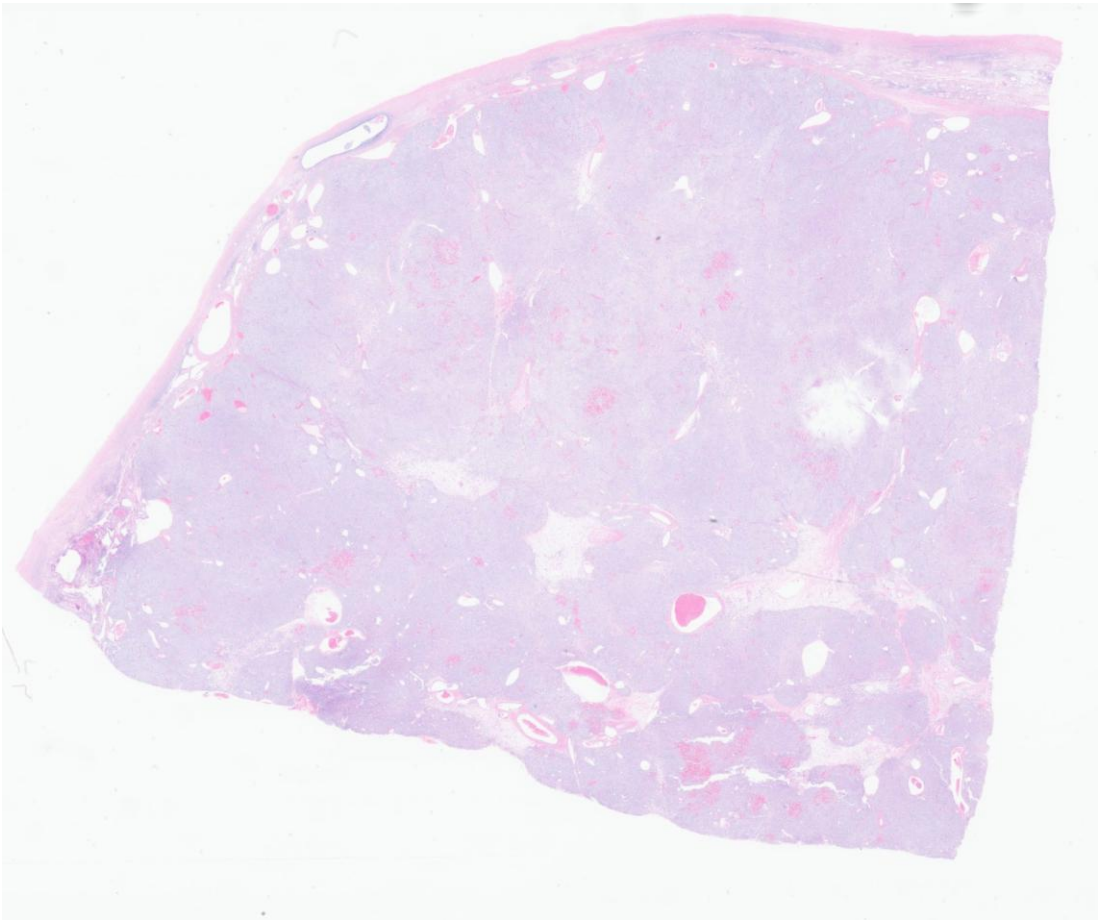

Steroid Cell Tumor of Ovary

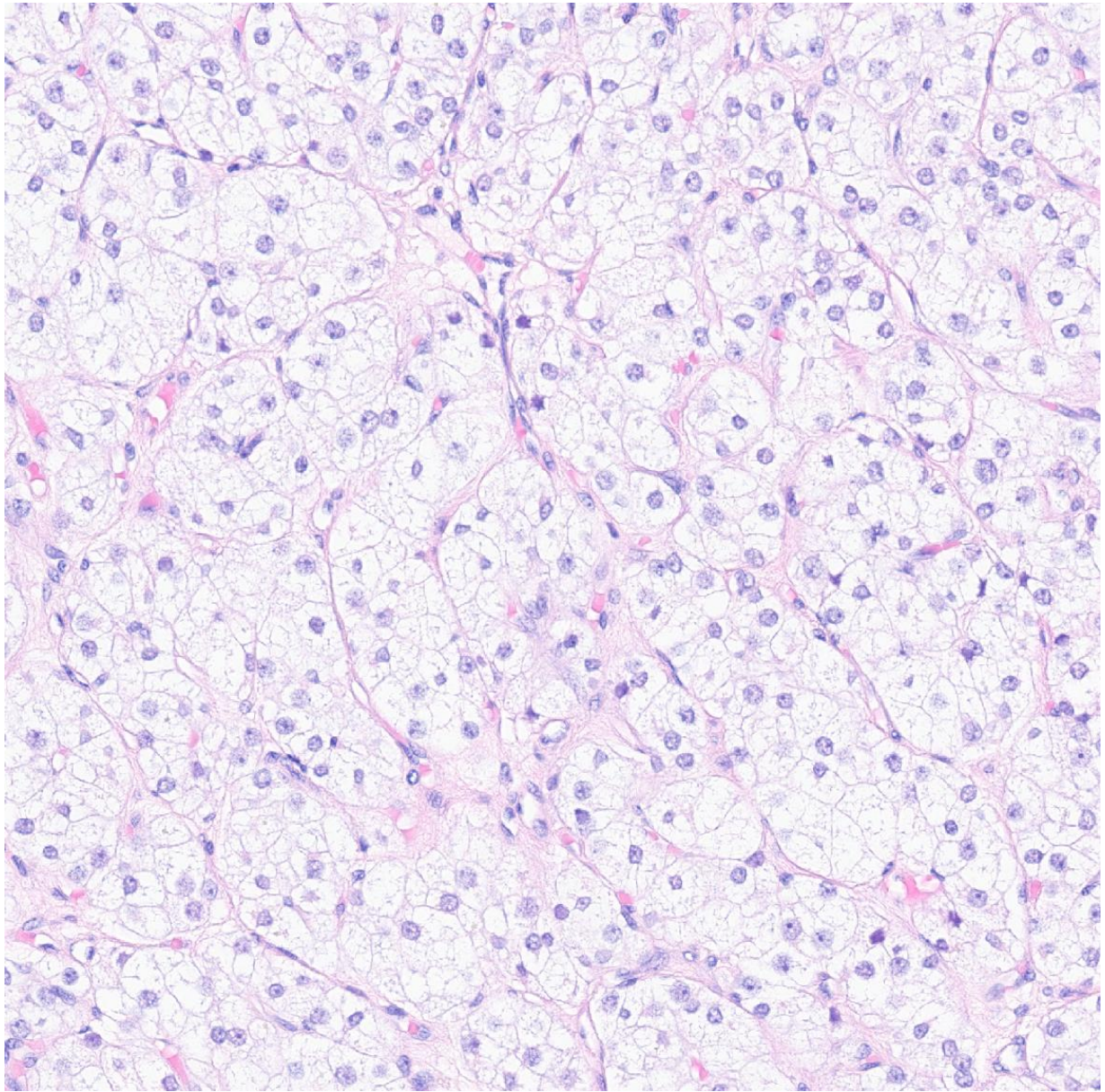

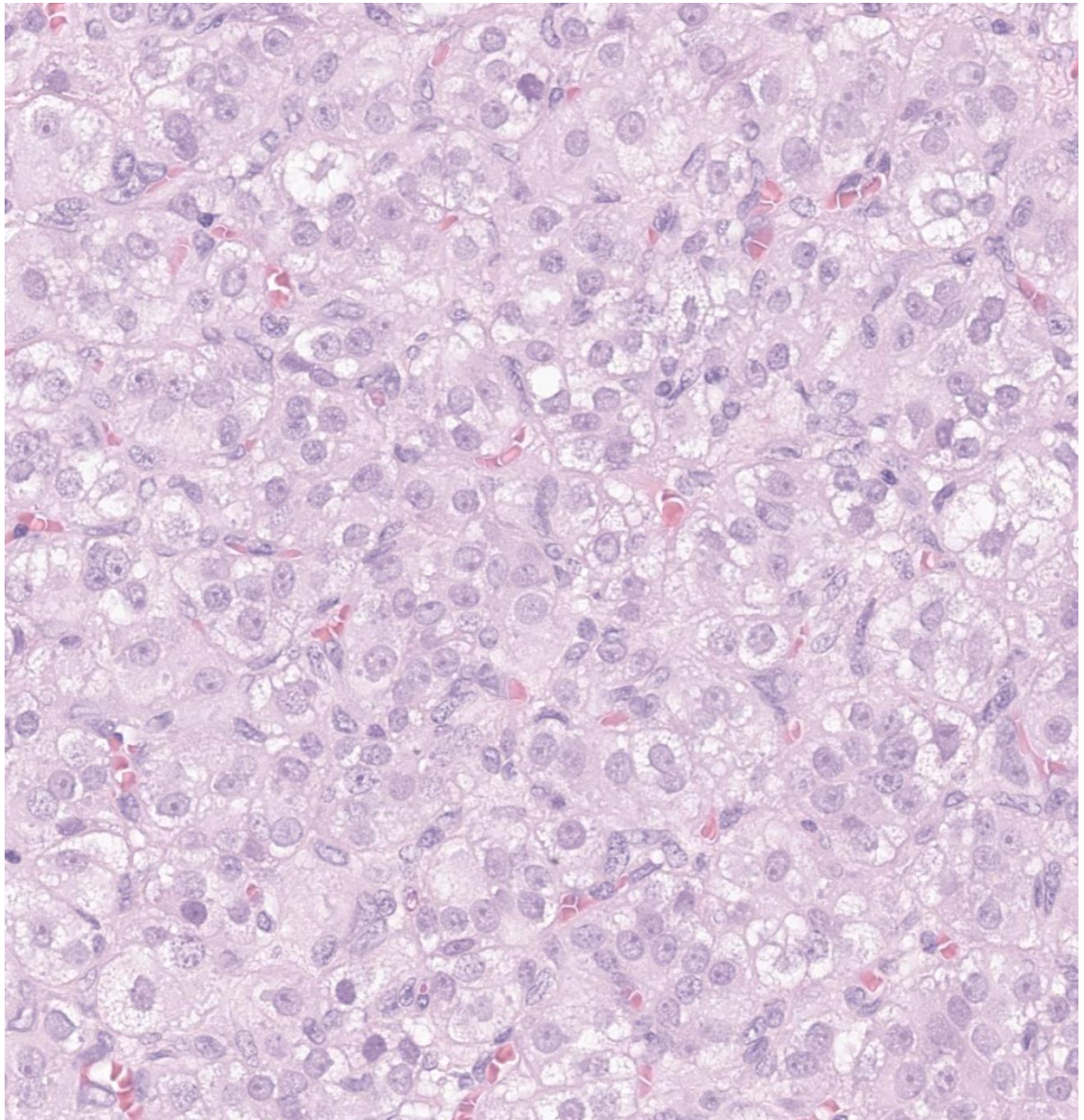

Steroid Cell Tumor of Ovary

Prognostic Variables

Limited literature:

- **50 patients**
- **5.2 year average follow up**
- **36% had malignant behavior** (recurrence or death)

Ovarian Steroid Cell Tumors
(Not Otherwise Specified)
A Clinicopathological Analysis of 63 Cases

Mary C. Hayes, M.D., and Robert E. Scully, M.D.

Am J Surg Pathol 1987. PMID: 2823622

Variable	Prevalence in Malignant Cases
≥2 mitoses/ 10 hpf	92%
Necrosis	86%
≥7 cm	78%
Hemorrhage	77%
Moderate/severe atypia	64%
Advanced stage	66%

Note: multivariate analysis not performed

Steroid Cell Tumor of Ovary

Refined Prognostic Variables

New literature:

- **115 patients**
- **3 year median follow up**
- **Lower prevalence of adverse behavior**
  - **6% recurred**
  - **3.4% died of tumor**

The Malignant Potential of Ovarian Steroid Cell Tumors Revisited

A Multi-institutional Clinicopathologic Analysis of 115 Cases

Oluwole Fadare, MD, Elmira Vaziri Fard, MD, MPH,* Rohit Bhargava, MBBS,† Mohamed Mokhtar Desouki, MD, PhD,‡ Krisztina Z. Hanley, MD,§ Philip P.C. Ip, MBChB,‖ Joshua J.X. Li, MBChB,¶ Bingjian Lu, MD, PhD,# Fabiola Medeiros, MD,** Joshua Hoi Yan Ng, MBBS, FHKCPath,†† Vinita Parkash, MBBS, MPH,‡‡ Andre Pinto, MD,§§ Charles M. Quick, MD,‖‖ Stephanie L. Skala, MD,¶¶ Minami Tokuyama, MD,## Gulisa Turashvili, MD, PhD,§ Christina H. Wei, MD,*** Deyin Xing, MD, PhD,††† Wenxin Zheng, MD,‡‡‡ T. Rinda Soong, MD, PhD, MPH,† and Brooke E. Howitt, MD##*

Am J Surg Pathol. 2024 PMID: 38512100

- *Mulitvariate analysis: recurrence free survival*

Independent Prognostic Variables
> Stage IA
> 65 years old

"adverse" morphology was associated with stage

Steroid Cell Tumor of Ovary

Refined Prognostic Variables

New literature:

- **21 patients**
- **12% recurred, died**

- **Next generation sequencing**

Clinicopathologic Analysis and Molecular Profiling of Ovarian Steroid Cell Tumors

Rachelle P. Mendoza, MD, Peng Wang, MD, PhD,* Heather L. Smith, MD, PhD,* Carrie A. Fitzpatrick, PhD,* Rishikesh Haridas, MS,* Pankhuri Wanjari, MS,* Renee Briese, BS,* Anum Shahid, BS,* W. Glenn McCluggage,† and Jennifer A. Bennett, MD**

Am J Surg Pathol. 2023. PMID: 37796179

Malignant tumors
Genomically unstable
No recurrent gene alterations

Steroid Cell Tumor of Ovary

Practical Reporting Advice

- **Document the traditional morphologic prognostic variables:**

Variables
≥2 mitoses/ 10 hpf
Necrosis
≥7 cm
Hemorrhage
Moderate/severe atypia

Am J Surg Pathol 1987. PMID: 2823622

- **Reference new study prognostic variables:**

Independent Variables
> Stage IA
> Age 65

Am J Surg Pathol. 2024 PMID: 38512100

- **No role for tumor sequencing**

