The British Association of Gynaecological Pathologists

Lecturer – Dr Pinias Mukonoweshuro



I am a Consultant Histopathologist with a specialist interest in Gynaecological pathology based at the Royal United Hospital Bath NHS Foundation Trust. I am the current BAGP secretary and have previously held roles as host for ISGYP LiVE webinar series, BAGP council and National Gynaecological EQA.

The British Association of Gynaecological Pathologists

Everyday Dilemmas in Gynaecological Pathology

- P16 IHC interpretation and CIN grading
- Dr Pinias Mukonoweshuro
- Royal United Hospital Bath NHS Foundation Trust
- 7 March 2025

The British Association of Gynaecological Pathologists

Speaker disclosures

- ❑ I have no financial conflicts of interest to disclose

Outline

- CIN
- Biomarkers (p16)
- Diagnostic dilemmas

Cervical intraepithelial neoplasia (SIL)

- Abnormal proliferations of squamous cells driven by HPV infection
- Do not extend beyond the basement membrane
- Show maturation abnormalities and/or viral cytopathic changes
- Arise in the cervical transformation zone
- Peak incidence in young women

Role of HPV in cervical neoplasia

- HPV DNA carries oncogenes that specify proteins which inactivate tumour suppressors which allows the infected cells to keep proliferating

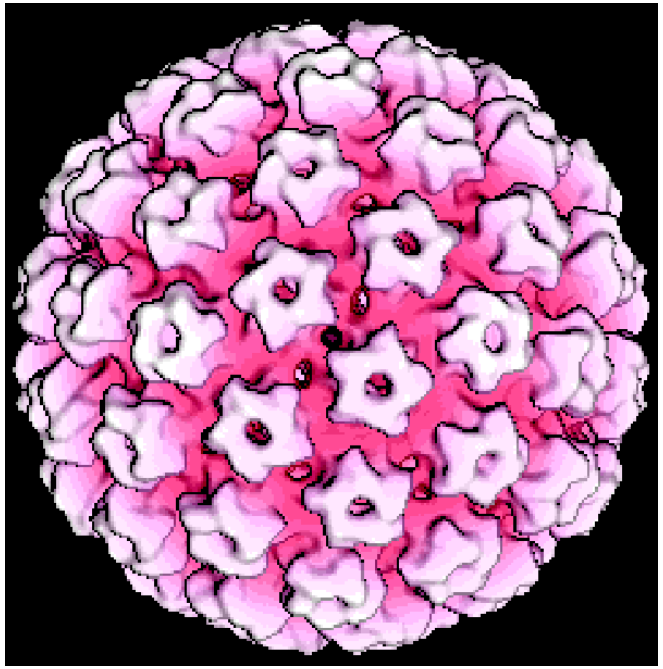

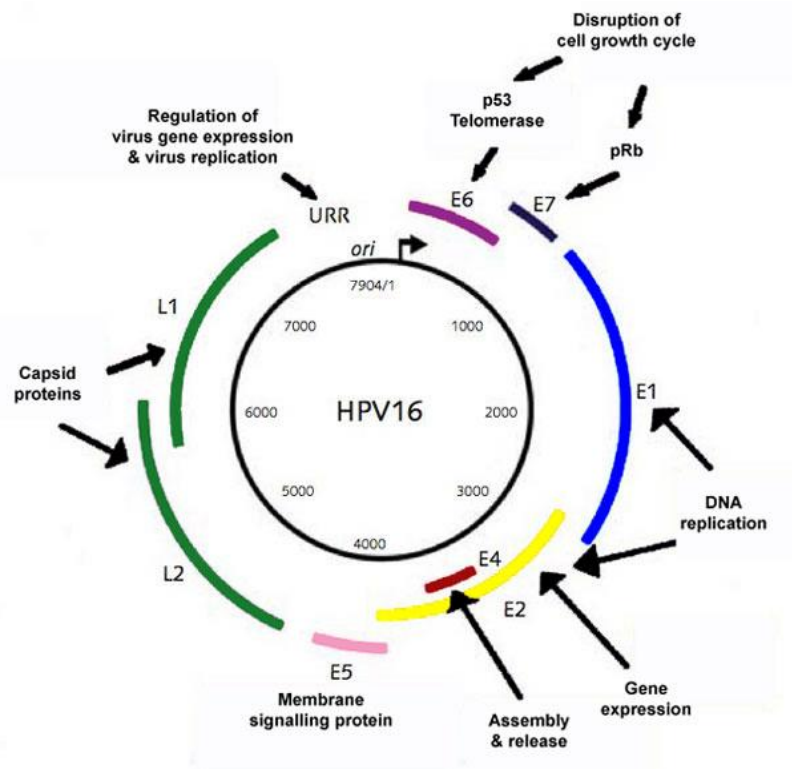

Role of HPV in cervical neoplasia

- HPV infection established in basal layers of squamous epithelium
- HPV genes classified as “early (E)” or “late (L)” depending on the timing of their expression in the epithelium
- E6 and E7 play a significant role in cervical neoplasia
- E6 binds to p53 – blocks cell apoptosis
- E7 binds to retinoblastoma (RB) tumour suppressor protein - abolishes cell cycle arrest and leads to unscheduled cellular proliferation.

Koilocyte

- Mature squamous cell with recognisable nuclear and cytoplasmic alterations due to HPV infection
- Sharply defined perinuclear clearing/halo
- Nuclear enlargement (2 - 3 x normal)
- Nuclear membrane irregularity – wrinkled/raisinoid appearance
- Nuclear hyperchromasia
- Binucleation

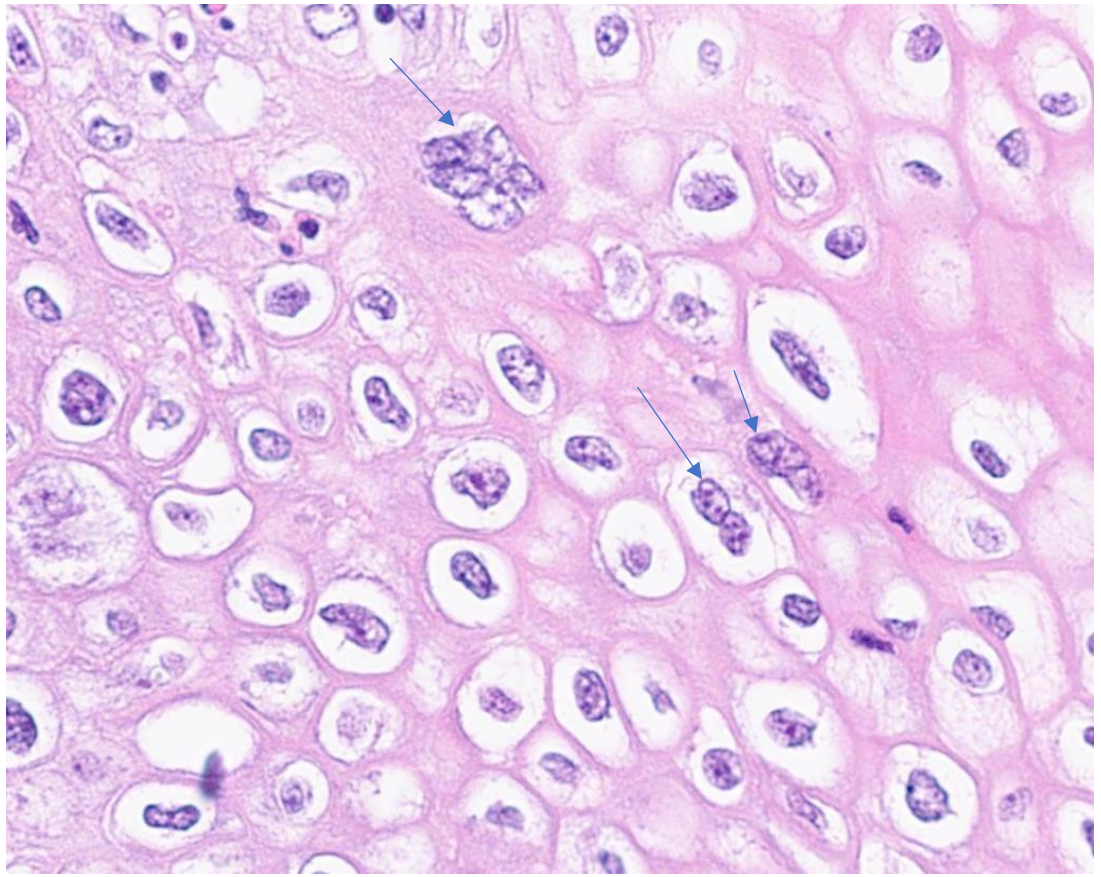

Squamous intraepithelial lesions/CIN

- Divided into:

Low grade squamous intraepithelial lesion (LSIL) - condyloma/CIN1
acceptable terminology: mild squamous dysplasia

High grade squamous intraepithelial lesion (HSIL) - CIN2
acceptable terminology: moderate squamous dysplasia

High grade squamous intraepithelial lesion (HSIL) – CIN3
acceptable terminology: severe squamous dysplasia; ~~squamous cell carcinoma in situ~~

Histological features of cervical intraepithelial neoplasia

- Hypercellularity
- Loss of polarity
- Variation in nuclear size
- Vertical orientation of nuclei
- Excess mitosis + atypical forms
- Lack of distinct basal layer

Diagnostic criteria (WHO) – LSIL (condyloma/CIN1)

- Full thickness epithelial atypia with moderate to abundant cytoplasm in cells within the upper two thirds of the epithelium
- Proliferation of basal/parabasal-like cells +/- mitoses within the lower third of epithelium (usually without abnormal mitoses)
- Basaloid morphology and significant mitotic activity restricted to **lower third of epithelium**
- Koilocytic atypia present within the middle and surface cells

CIN1 (LSIL). 80-90% of flat LSIL due to HR-HPV

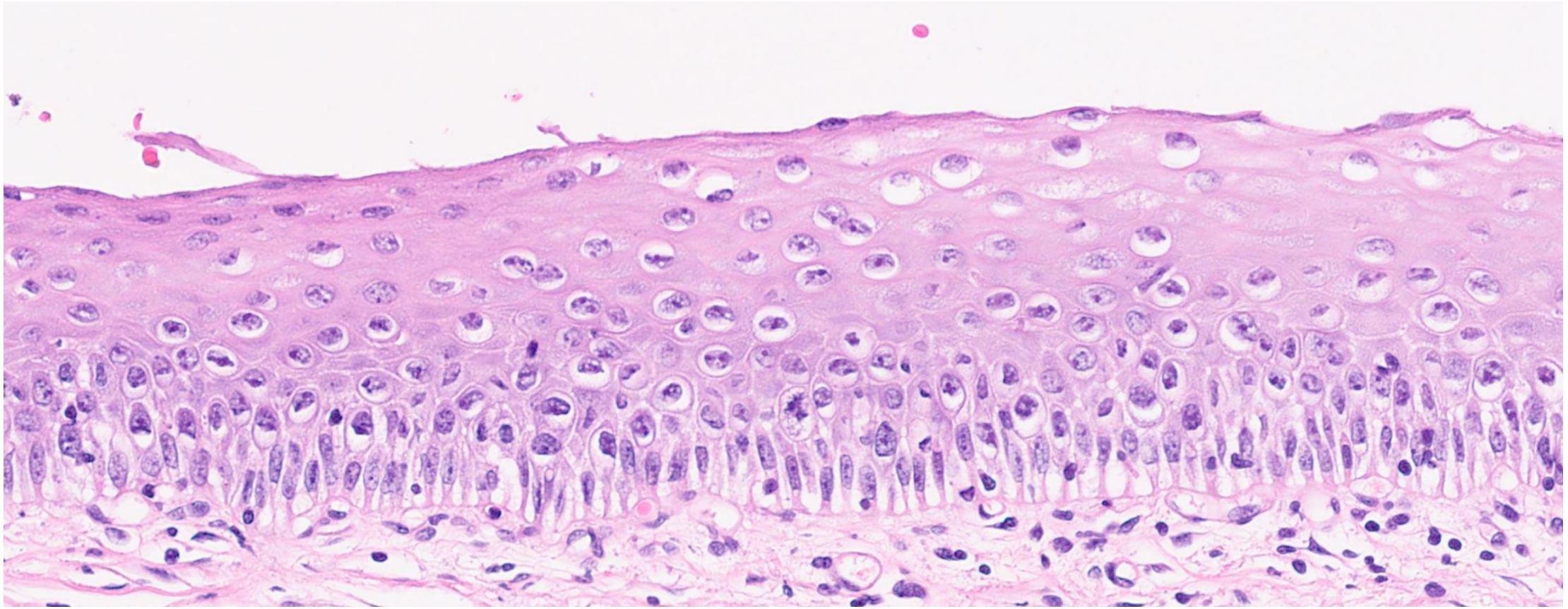

HSIL (CIN2/CIN3) – nuclear features

- Nuclear hyperchromasia
- Coarse chromatin
- Irregular nuclear membranes
- Increased N:C ratio
- Mitoses including atypical forms
- Superficial koilocytic change

Diagnostic criteria (WHO) - CIN2 (HSIL)

- Full thickness epithelial atypia
- Basaloid cells and mitotic activity extending into the **upper half to upper two thirds** of the epithelium
- Retained koilocytic change on the surface
- CIN2 diagnosis best reviewed at MDT if conservative treatment is considered

CIN2

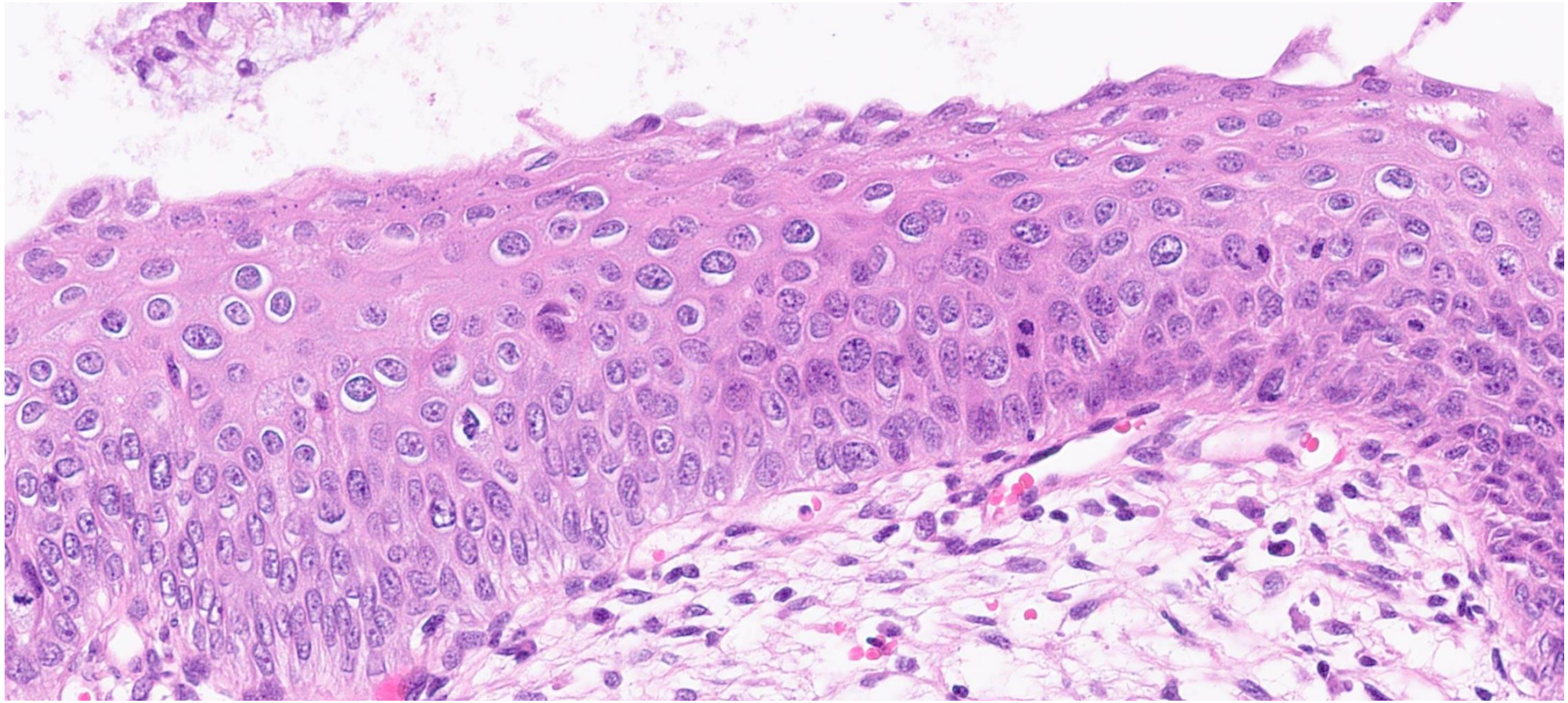

CIN 2 in thin metaplastic epithelium

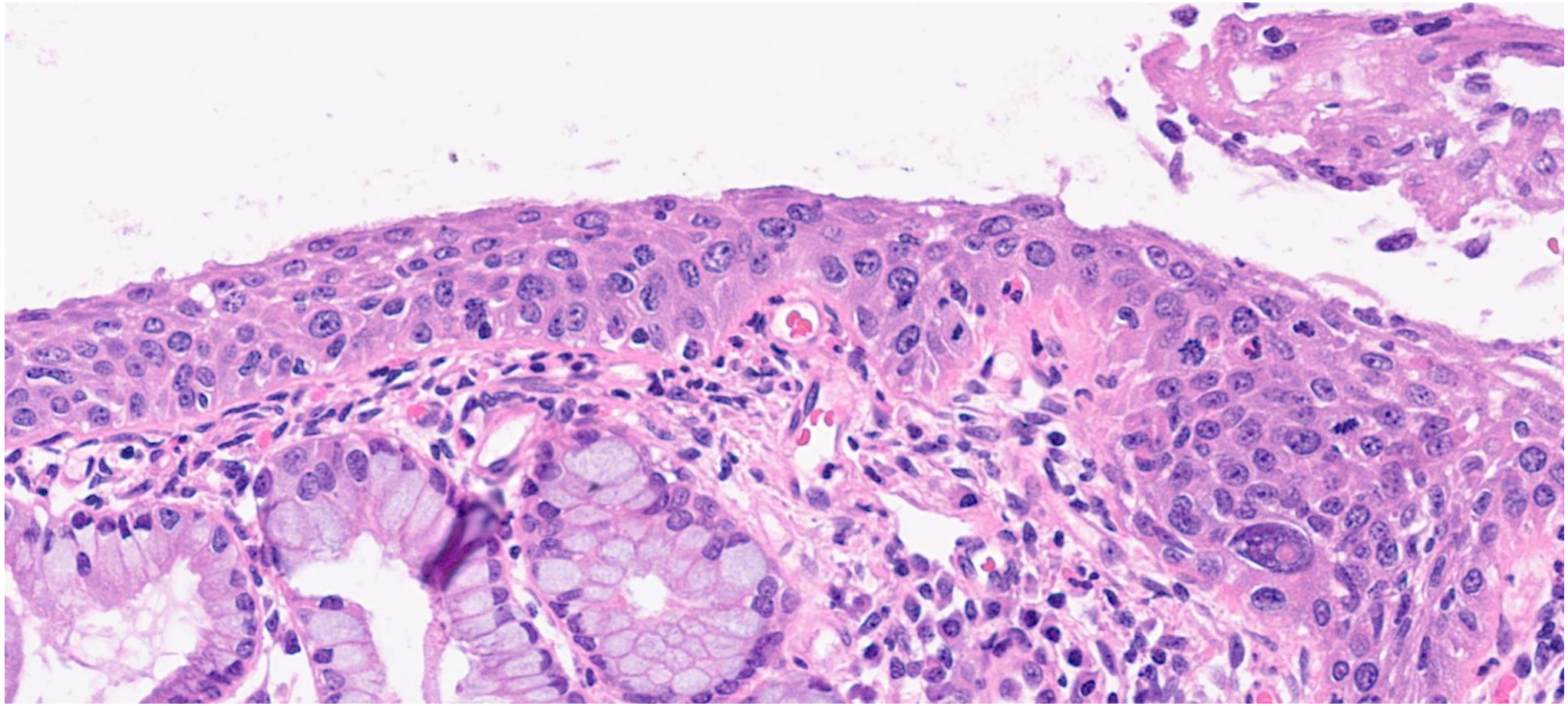

CIN2

- Classified as HSIL together with CIN3
- Significant rates of regression in young women <30yrs (*BMJ* 2018;360:k499)
- Conservative management appropriate in correct clinical context
- Accurate histological diagnosis important
- Histological diagnosis prone to underdiagnosis or overdiagnosis
- MDT review with careful use of p16 useful in diagnosis

CIN2 diagnosis on H&E

- Significant interobserver variability
- Likely to include a mixture of misclassified CIN1 and CIN3
- Poor diagnostic reproducibility between pathologists
- Consider using p16 immunohistochemistry to refine this diagnosis

HSIL (CIN3)

- Full thickness basal/parabasal-type epithelial atypia with no appreciable difference in maturation of cells from base to surface
- Mitotic activity identified throughout the epithelium including atypical mitoses
- Upper portions of epithelium show a significantly higher N:C ratio than in LSIL and HSIL (CIN2)

CIN3

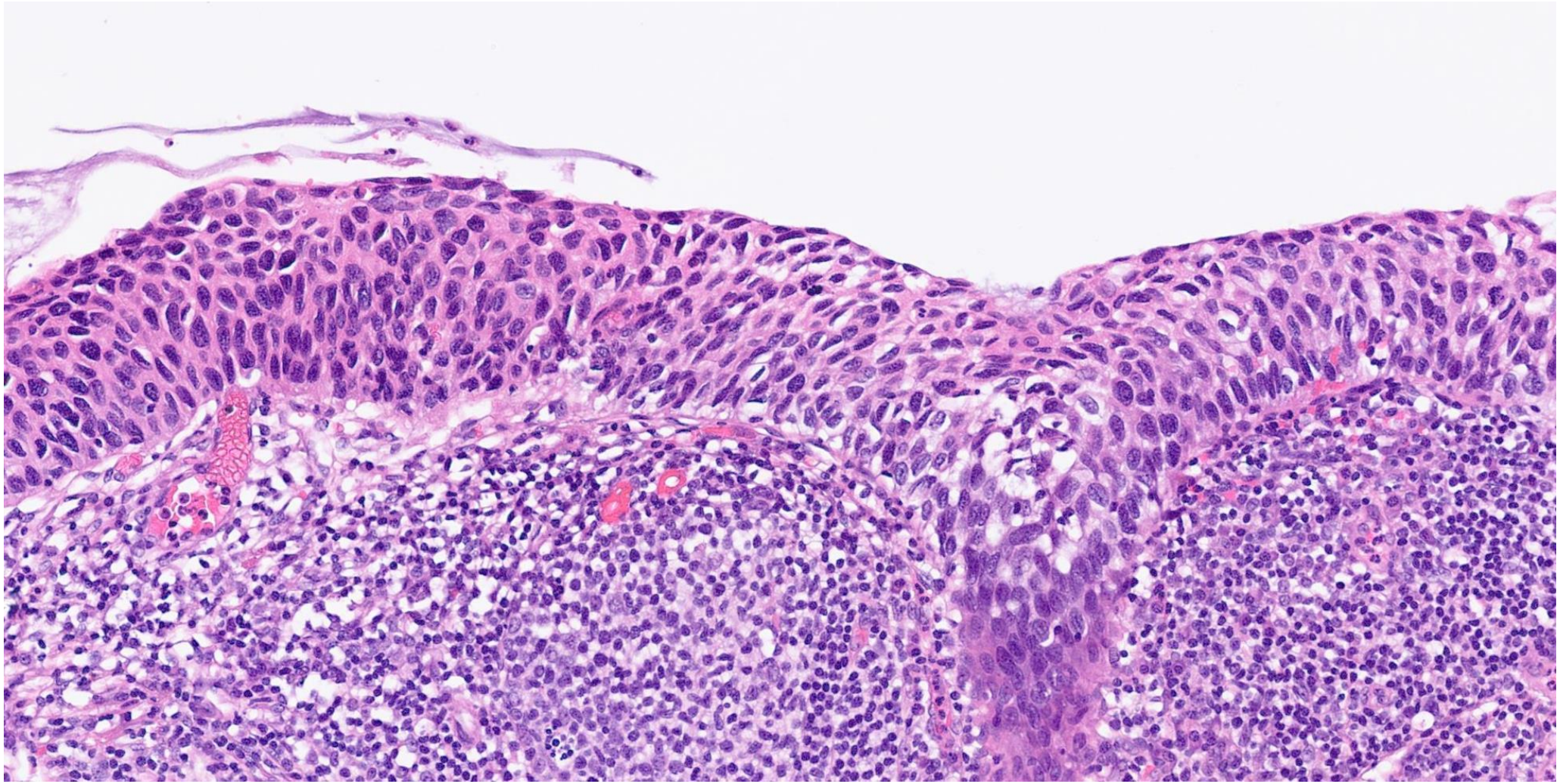

CIN3 (keratinising)

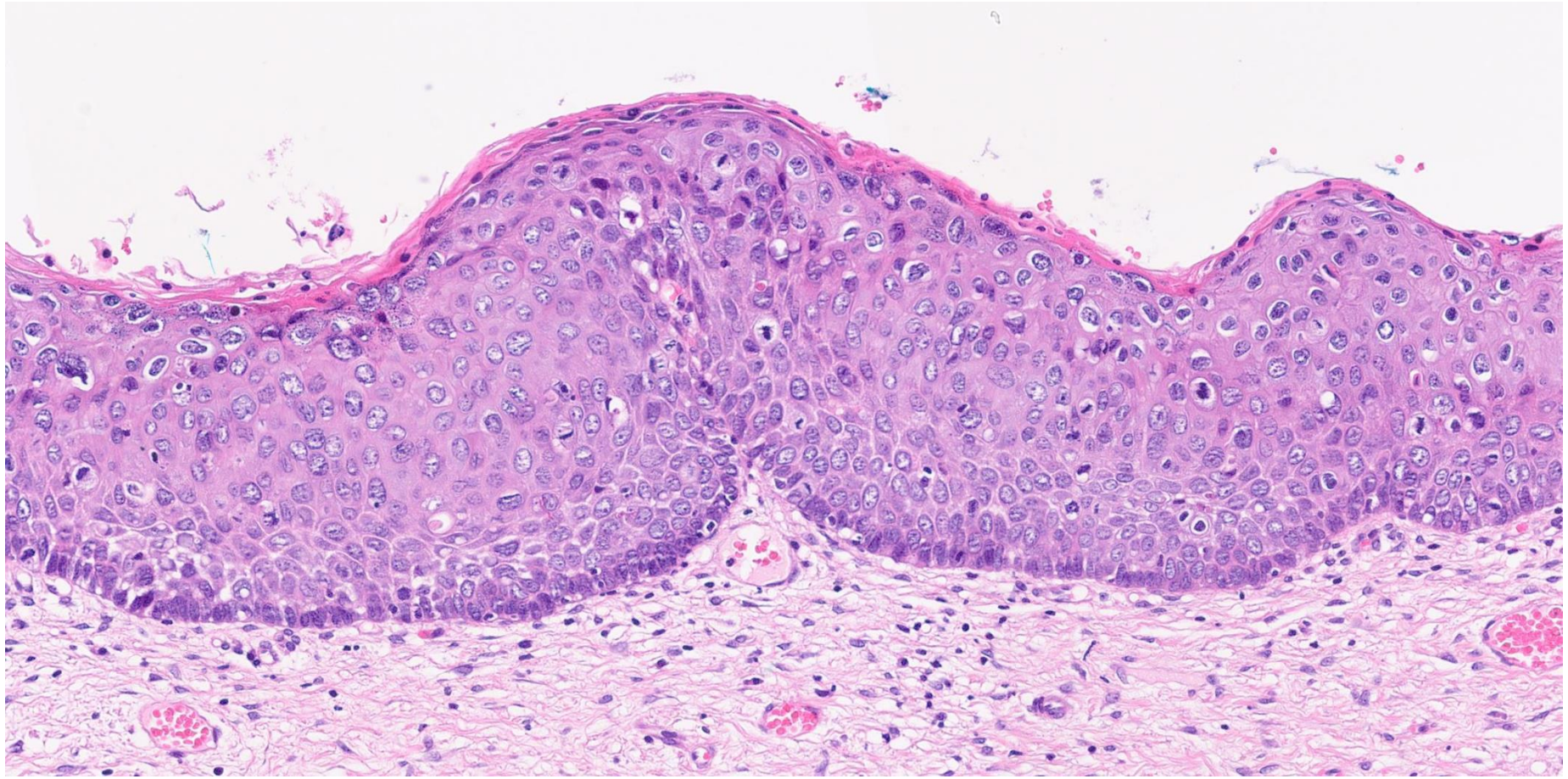

Poll Q1. What is your diagnosis?

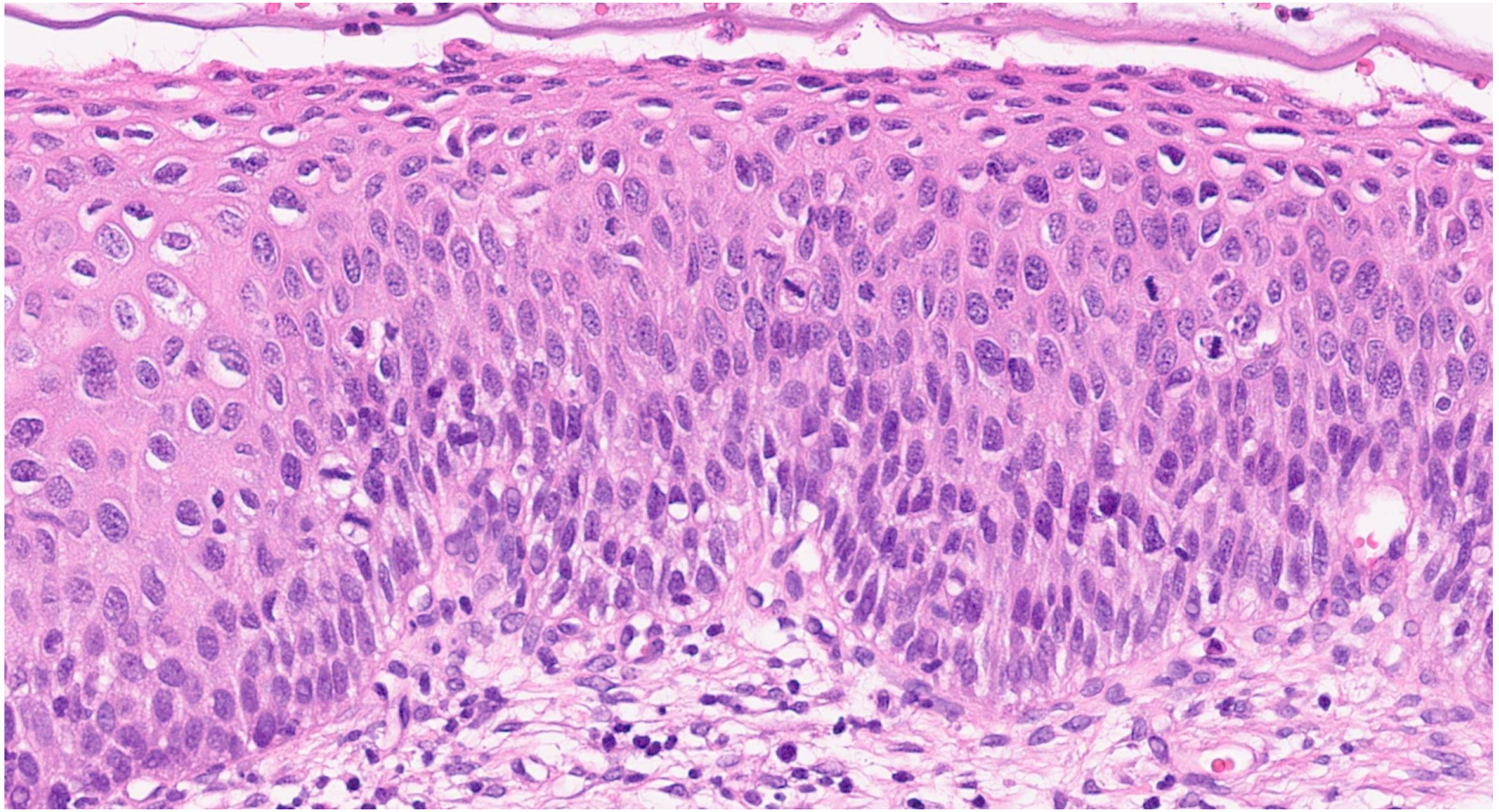

Poll Q1 – CIN2

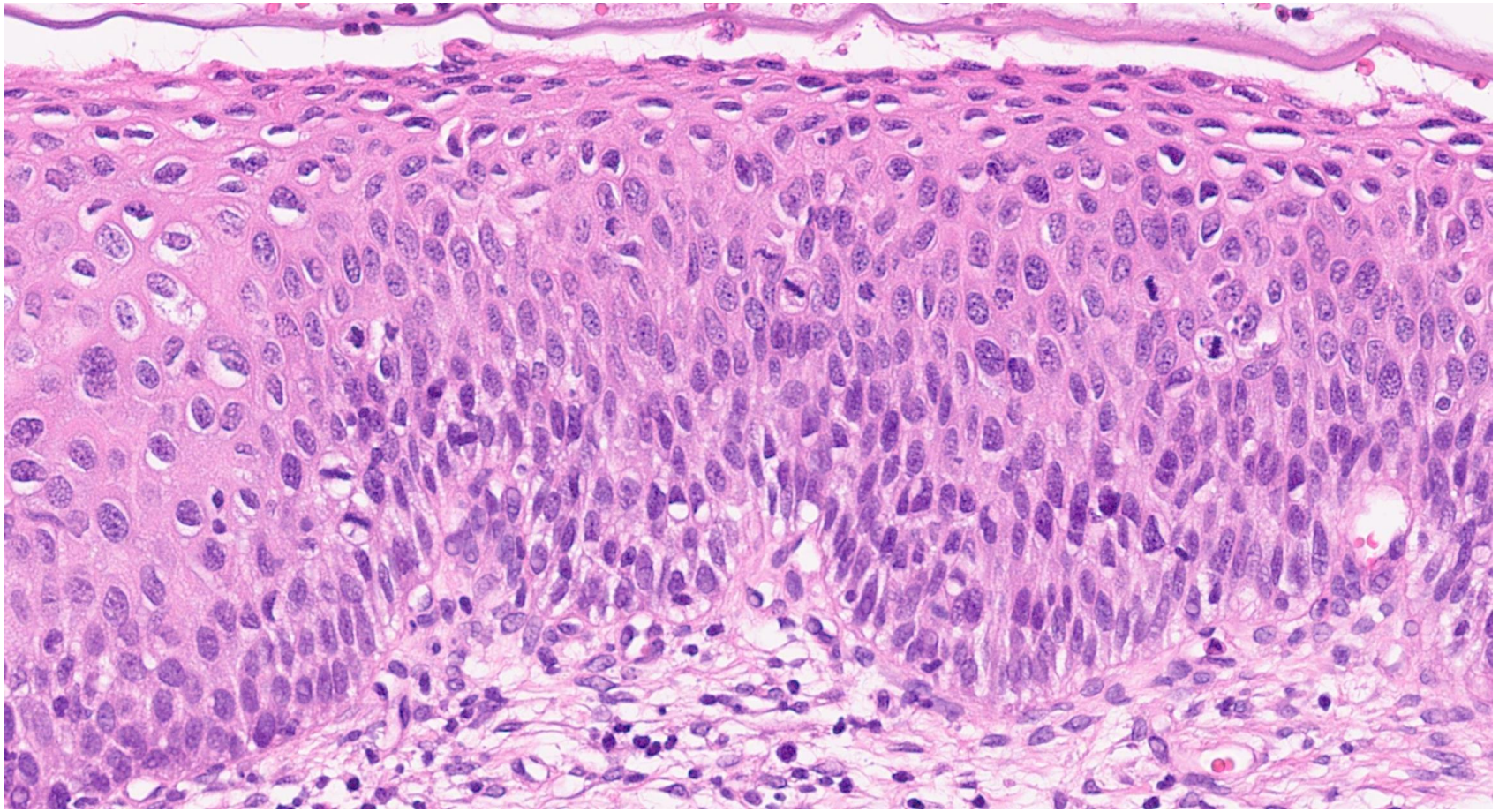

p16

THE BRITISH ASSOCIATION OF GYNAECOLOGICAL PATHOLOGISTS

Interpretation of p16 Immunohistochemistry In Lower Anogenital Tract Neoplasia

Authors: Naveena Singh[1], C Blake Gilks[2], Richard Wing-Cheuk Wong[3], W Glenn McCluggage[4], C Simon Herrington[5]

[1]Barts Health NHS Trust, London, UK; [2]Vancouver General Hospital [3]Pamela Youde Nethersole Eastern Hospital, Hong Kong, [4]Belfast Health and Social Care Trust, Belfast, UK; [5]University of Edinburgh

The Lower Anogenital Squamous Terminology Standardization Project for HPV-Associated Lesions: background and consensus recommendations from the College of American Pathologists and the American Society for Colposcopy and Cervical Pathology

Teresa M Darragh[1], Terence J Colgan, J Thomas Cox, Debra S Heller, Michael R Henry, Ronald D Luff, Timothy McCalmont, Ritu Nayar, Joel M Palefsky, Mark H Stoler, Edward J Wilkinson, Richard J Zaino, David C Wilbur; Members of LAST Project Work Groups. PMID: 22742517

p16 staining in high risk HPV infection

- Abnormal p16 IHC is a marker of E7 mediated inactivation of Rb protein and is therefore a diagnostic marker of transforming hrHPV infection (necessary but not sufficient for progression to cancer)

- p16 expression is not abnormal in all hrHPV infections as these form a spectrum from silent, through productive to transforming/abortive infections; abnormal p16 expression is not seen in silent/latent infections and in half of the CIN1 lesions caused by hrHPV

BAGP guidance document. Interpretation of p16 Immunohistochemistry In Lower Anogenital Tract Neoplasia.

p16 INK4A

- Block positive staining for p16 indicates a squamous intraepithelial lesion is driven by high risk HPV
- Immunostaining for p16 has emerged as a surrogate for detection of potentially transforming hrHPV infection.
- Good biomarker for high grade CIN/HSIL(overexpressed in >95%) but is also expressed in some cases of low grade CIN (up to 50% of LSIL/HPV block positive)
- p16 immunohistochemistry does not grade an intraepithelial lesion
- Any p16 block positive intraepithelial lesion must meet H&E criteria of the suggested diagnosis

Indication for p16 in cervical squamous intraepithelial lesions

- Differential diagnosis is between high grade intraepithelial neoplasia 2/3 (IN2/IN3) and a mimic (e.g. atrophy, squamous metaplasia etc)

- If H&E diagnosis is IN2+, abnormal p16 helps with clarifying diagnosis. Negative p16 staining favours a low grade intraepithelial lesion

- Can be used an adjunct where there is concern for missed high grade intraepithelial neoplasia

Criteria for p16 block positive staining

- Strong and continuous nuclear or nuclear and cytoplasmic staining
- Involves basal and parabasal epithelial cells with upward extension
- Extends beyond the lower third of epithelium
- Abnormal expression must involve at least 6 contiguous cells in horizontal extent (this criteria not well validated)

p16 overexpression.
WHO Classification of Tumours 5th edition

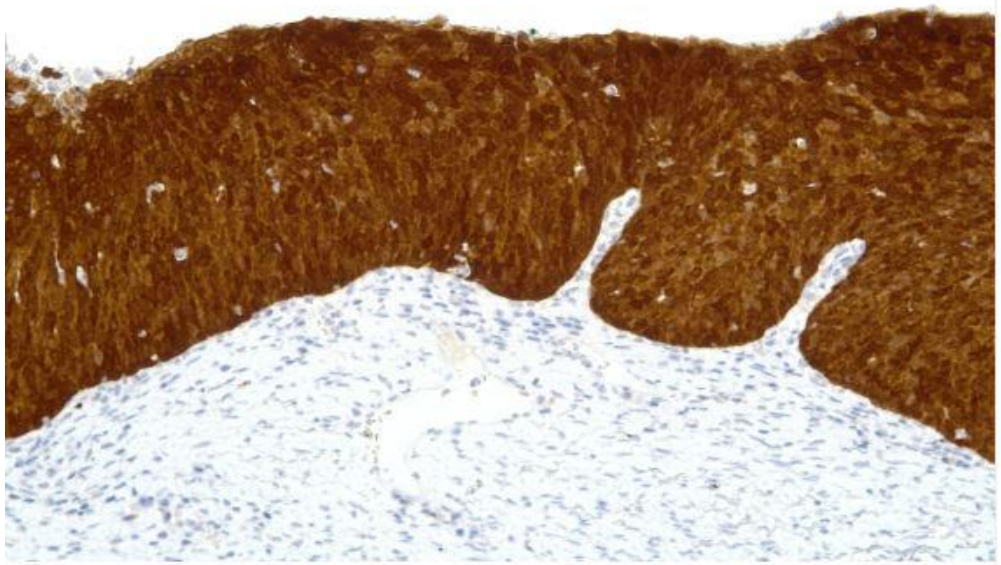

#13822

View Original

Diagnosis:
High-grade squamous intraepithelial lesion (CIN 3)
Legend:
Abnormal cells with a high N:C ratio involve more than two thirds of the mucosal thickness (see <<#16771>>Fig. #16771) and exhibit block-positive p16 reactivity (shown here).

P16 negative staining in immature squamous metaplasia – patchy with sparing of the base

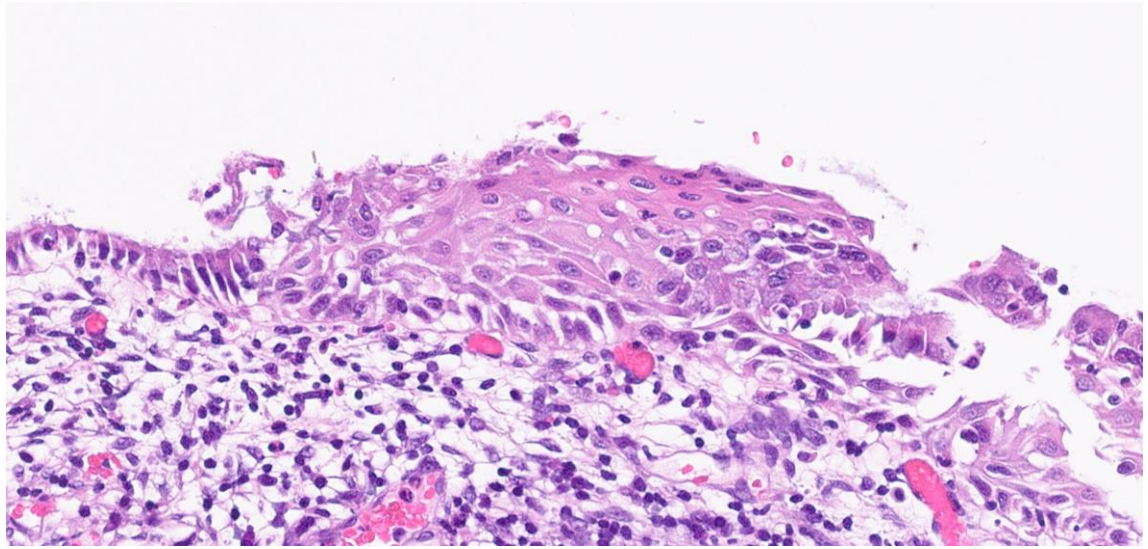

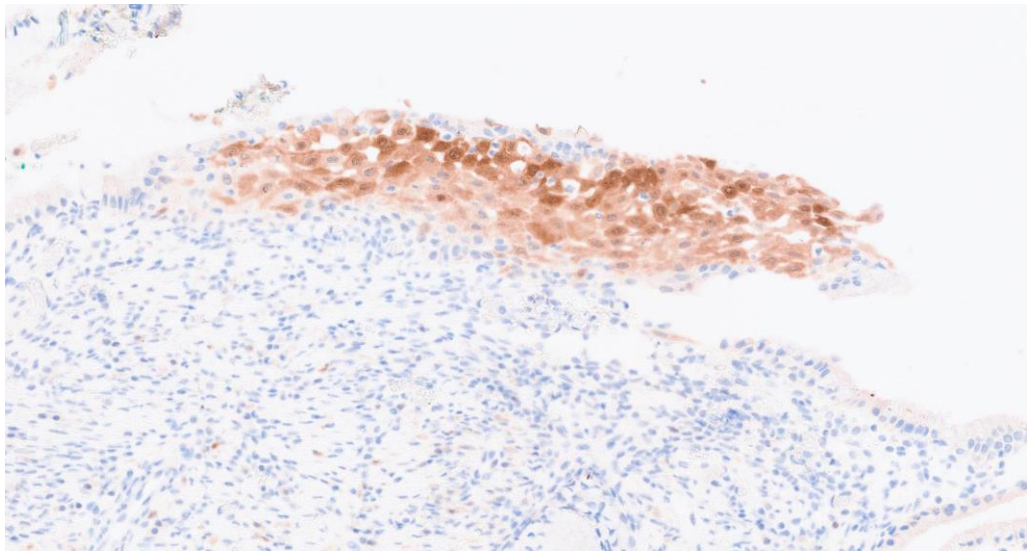

p16 should not be used

- For grading intraepithelial neoplasia. Up to 50% of low grade squamous intraepithelial neoplasia in cervix can show abnormal staining

- Grading of all intraepithelial neoplasia should be based on H&E morphology

- Predict biological behaviour/progression of intraepithelial lesion – Colposcopy treatment should be guided by grade of lesion not p16 result (>90% of CIN1 and up to 2/3rds of CIN2 in young women will regress regardless of p16 result)

P16 – cannot reliably predict biology of CIN

- Currently no reliable way to predict CIN2 that will progress or regress

Relationships of p16 Immunohistochemistry and Other Biomarkers With Diagnoses of Cervical Abnormalities: Implications for LAST Terminology

Philip E. Castle, PhD, MPH; Rachael Adcock, BS; Jack Cuzick, PhD; Nicolas Wentzensen, MD, PhD; Norah E. Torrez-Martinez, BS; Salina M. Torres, PhD, MPH; Mark H. Stoler, MD; Brigitte M. Ronnett, MD; Nancy E. Joste, MD; Teresa M. Darragh, MD; Patti E. Gravitt, PhD; Mark Schiffman, MD; William C. Hunt, MS; Walter K. Kinney, MD; Cosette M. Wheeler, PhD ; New Mexico HPV Pap Registry Steering Committee; p16 IHC Study Panel

Arch Pathol Lab Med (2020) 144 (6): 725–734.

MODERN PATHOLOGY (2016) 29, 51–59
© 2016 USCAP, Inc All rights reserved 0893-3952/16 $32.00

p16 staining has limited value in predicting the outcome of histological low-grade squamous intraepithelial lesions of the cervix

Amaia Sagasta[1], Paola Castillo[1], Adela Saco[1], Aureli Torné[2], Roser Esteve[1], Lorena Marimon[1], Jaume Ordi[1,3] and Marta Del Pino[2,3]

Diagnostic dilemmas

Ungradable/unclassifiable CIN (SIL)

- Some biopsies will fall into this category
- Avoid reporting this category as not useful to clinician
- Attempt to make a diagnosis with help of levels/deeper sections and ancillary tests (p16 immunohistochemistry)
- Consult a colleague
- p16 negative staining favours a low grade lesion
- p16 block positive staining - could be low grade/high grade intraepithelial lesion
- Discuss in MDT if appropriate

Thin CIN (<10 cells).
CIN3 with crypt involvement, p16 block positive

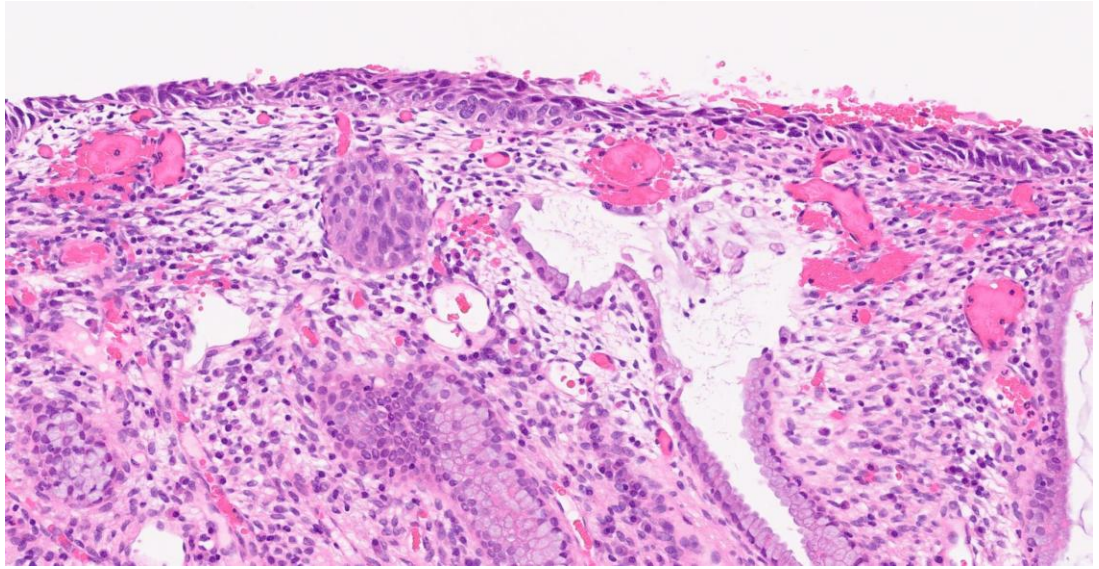

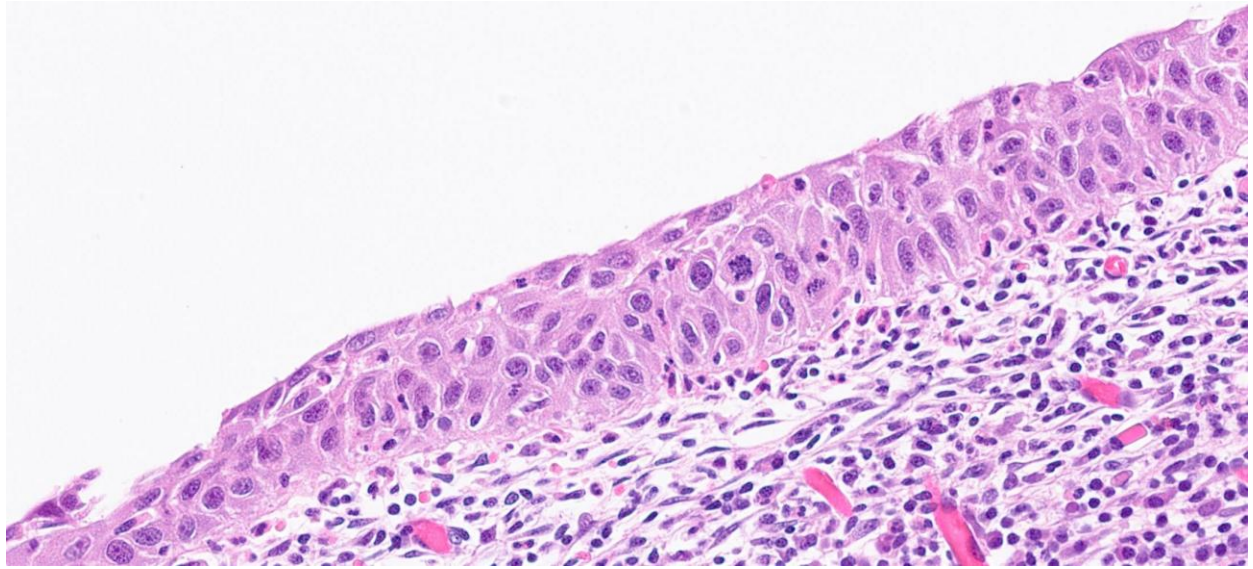

CIN involving crypts

- Request deeper levels
- grade lesion in endocervical gland similar to surface assessment if you can identify the full thickness of the abnormal epithelium
- If the whole gland is filled with epithelium showing minimal or no maturation then consider classifying as high grade CIN (CIN2+)
- P16 may be useful - negative IHC excludes high grade CIN
- Consider discussing in MDT

- Consider tangential sectioning in all cases

Fragmented biopsies, p16 positive in fragments

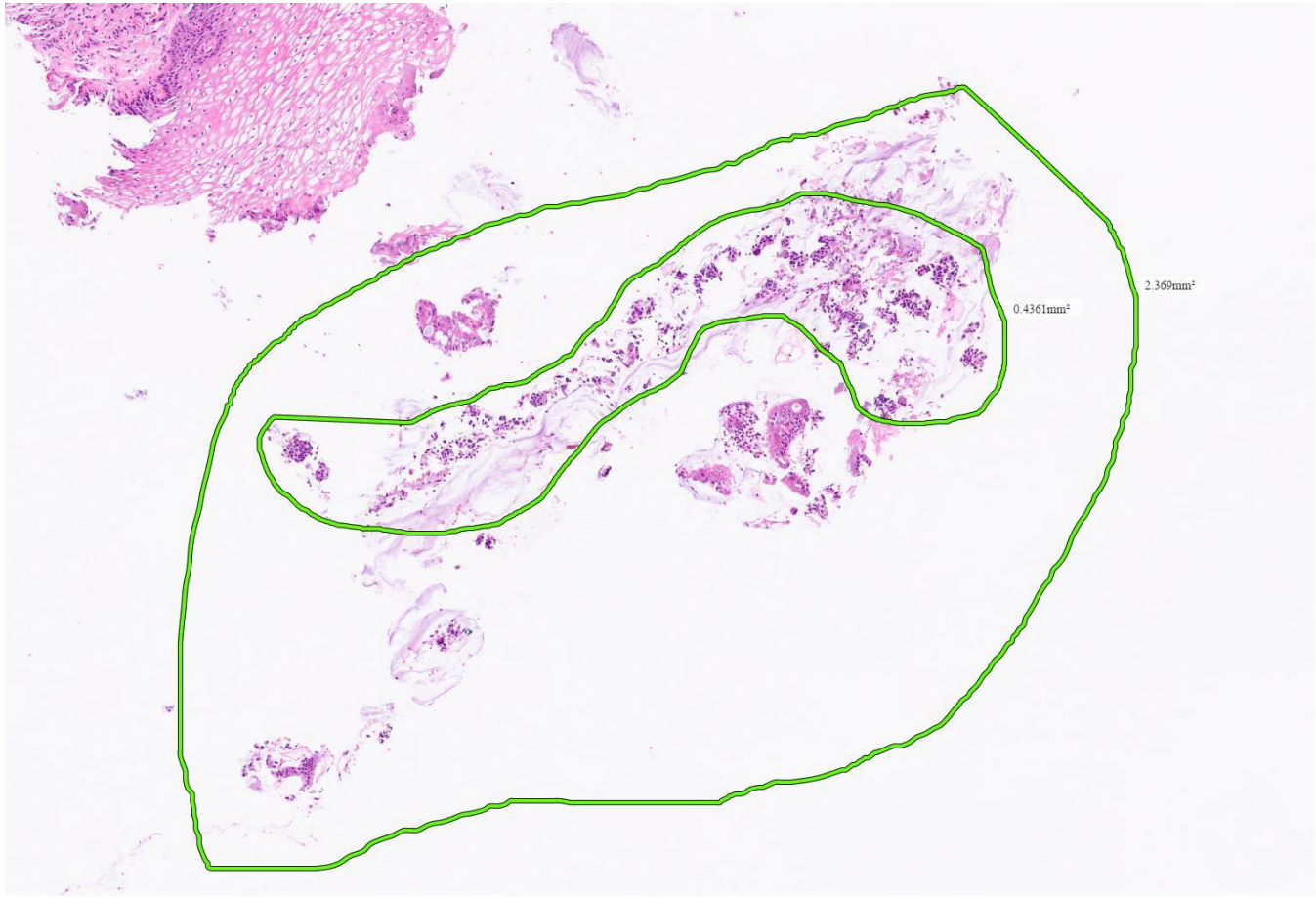

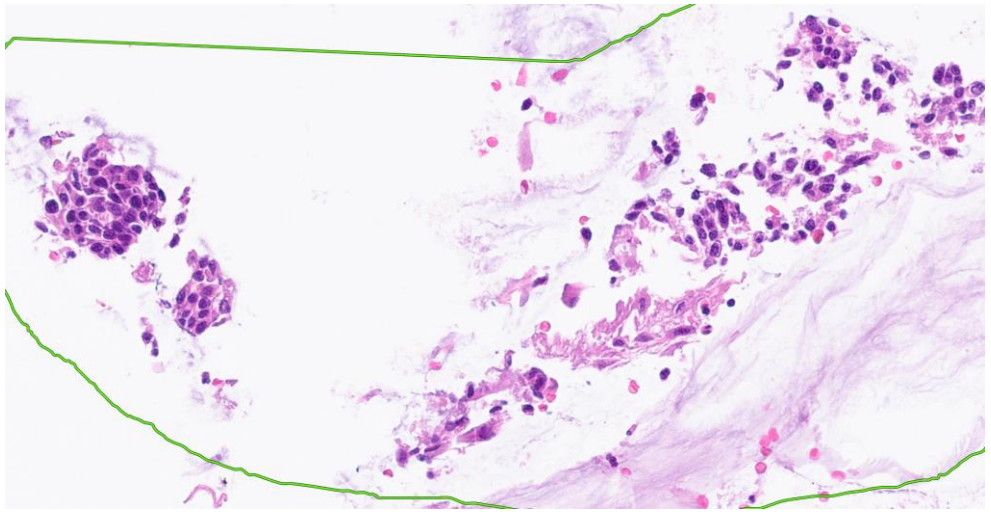

Abnormal mitosis and marked nuclear atypia with p16 block positive IHC = CIN2 (HSIL)

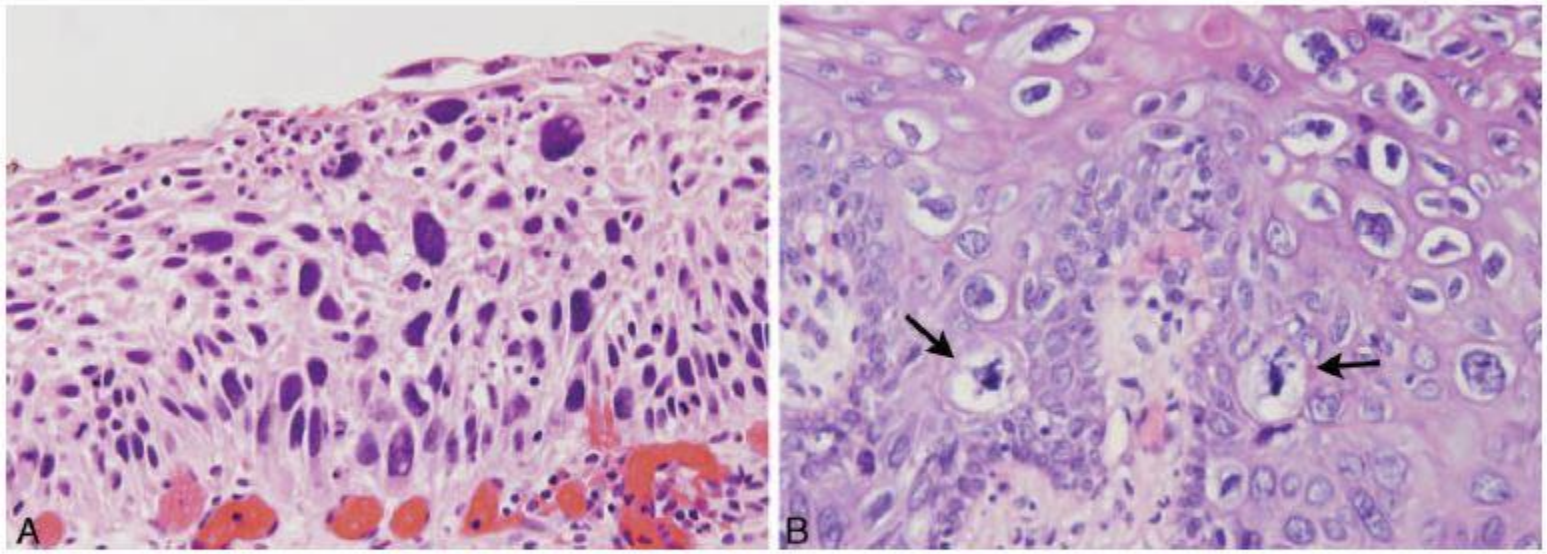

Figure 5. A and B, Cervical HSIL (CIN 2). A, Marked nuclear atypia is seen extending throughout the full thickness of the epithelium. Unlike classic –IN 3, these cells have more abundant cytoplasm. However, this degree of nuclear change is considered to be high grade. B, In this biopsy, there are abnormal mitoses (arrows) that are in the lower one third of the epithelium. The overlying cells show maturation and koilocytic change. The presence of these abnormal mitoses suggests HSIL and, in the presence of block-positive p16 staining, the diagnosis is HSIL (CIN 2). A and B, High power, H&E.

Poll Q2a. What is your diagnosis?

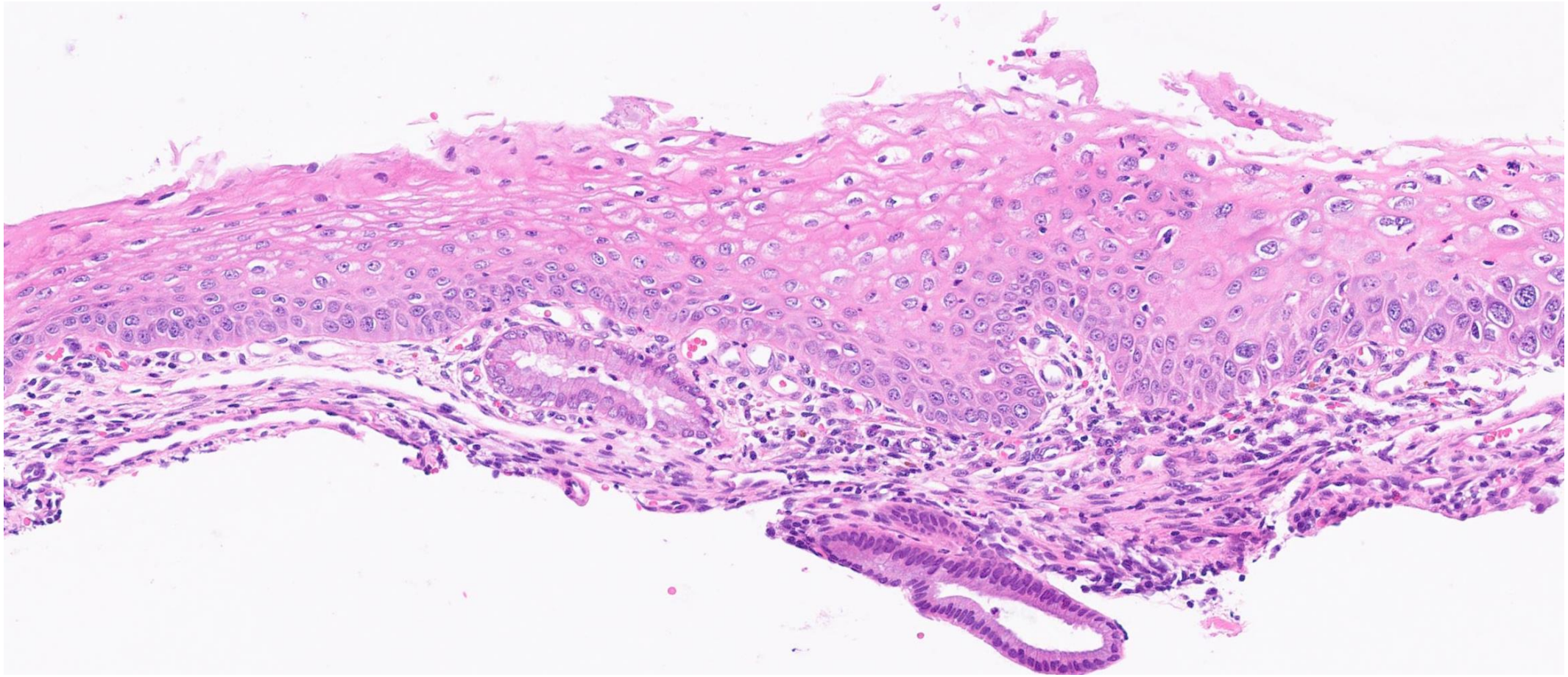

Poll Q2b. Does this p16 stain change your diagnosis?

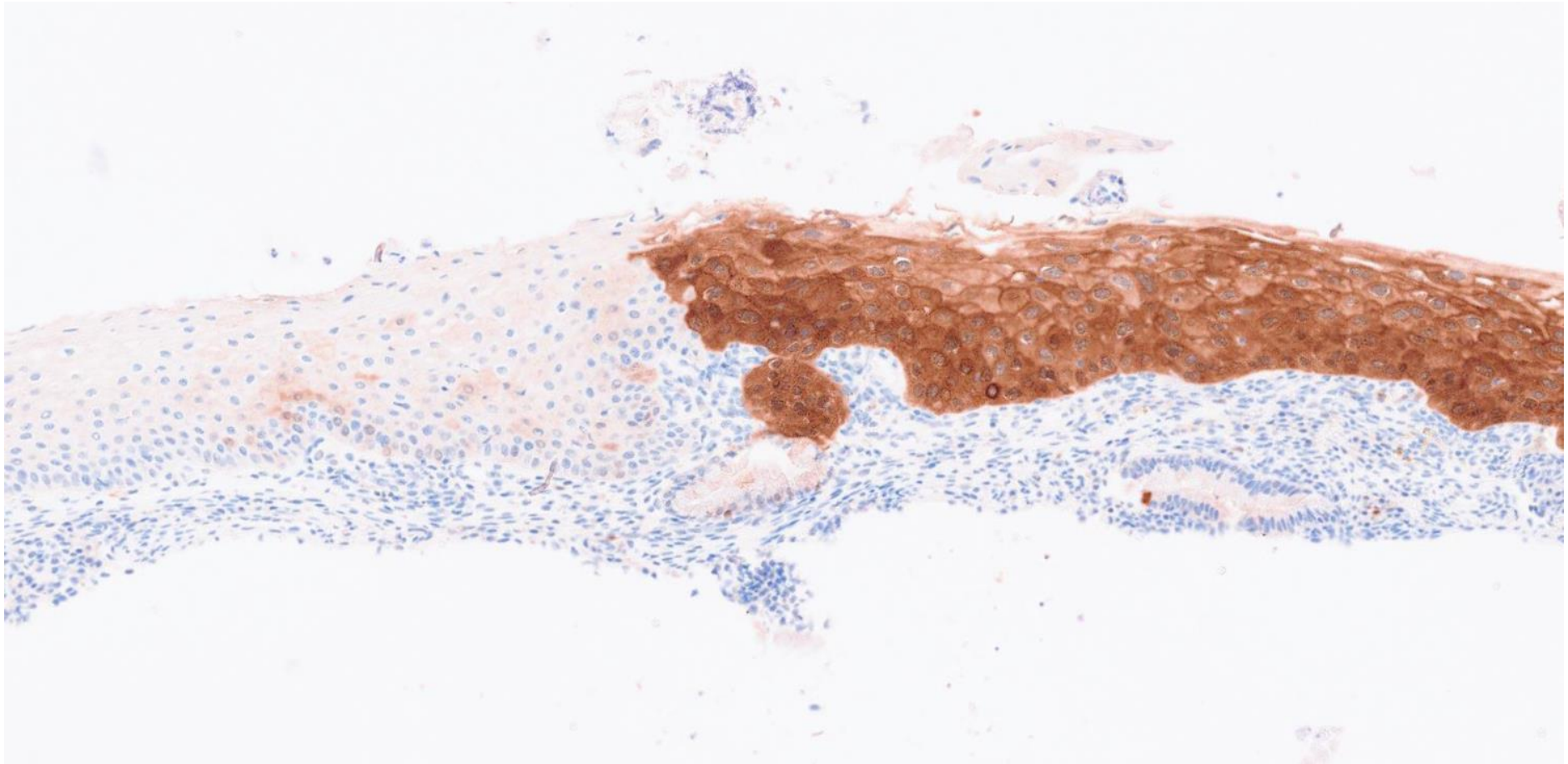

Poll Q2 – CIN1 (LSIL), p16 block positive

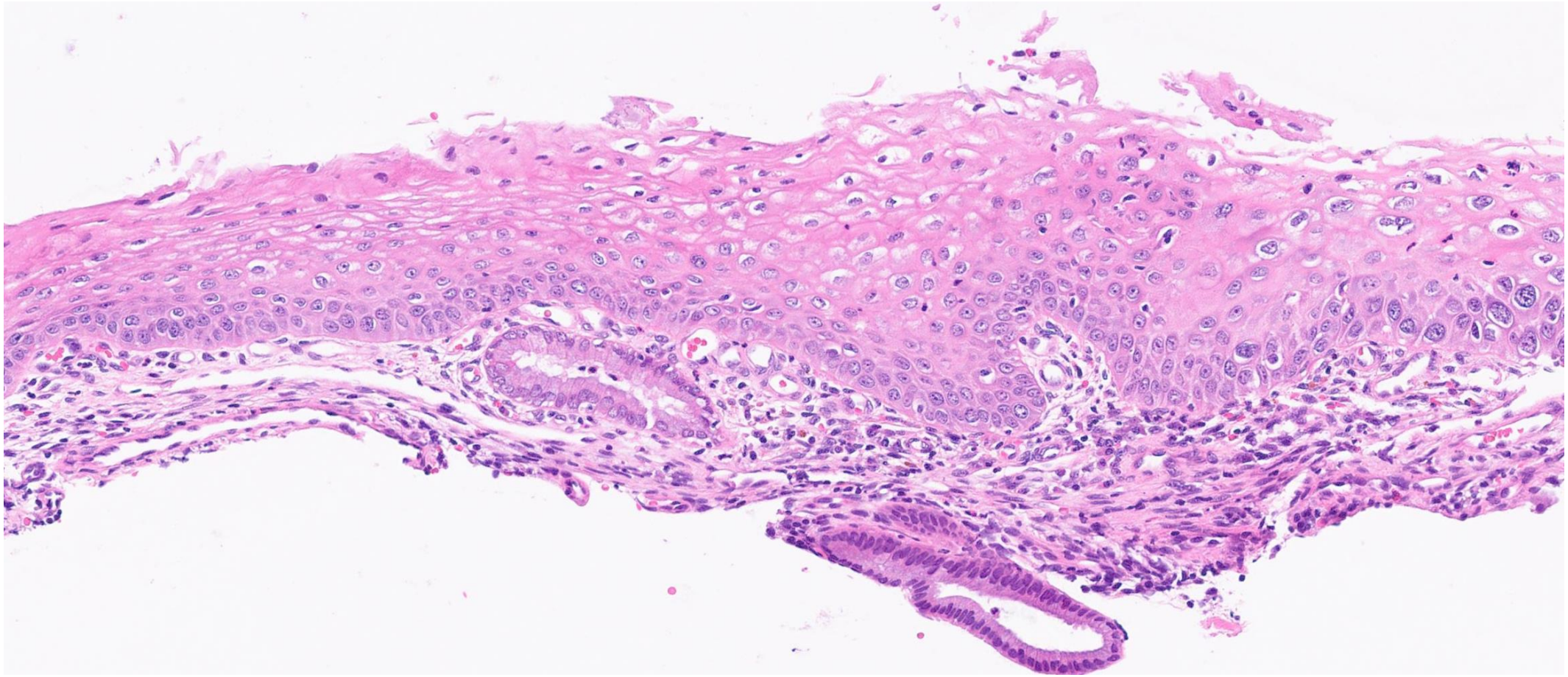

P16 use - take home message

- Any identified p16 block positive tissue must meet H&E morphological criteria for a high grade lesion to be reported as high grade squamous intraepithelial lesion.

Utility of p16 in equivocal CIN1/?CIN2 lesions

- If pathologists is considering a diagnosis of CIN2 in an equivocal lesion

  p16 immunohistochemistry is useful and recommended to refine diagnosis in combination with H&E morphology.
- Negative p16 immunohistochemistry favours CIN1/LSIL
- Negative p16 immunohistochemistry is useful to exclude a high grade intraepithelial lesion provided morphology is consistent with a low grade lesion (negative p16 can occur due technical reasons, inactivation of p16 gene or HPV independent lesion)

Poll Q3. 25 year old P0, cytology low grade squamous dyskarysosis. What is your diagnosis on H&E?

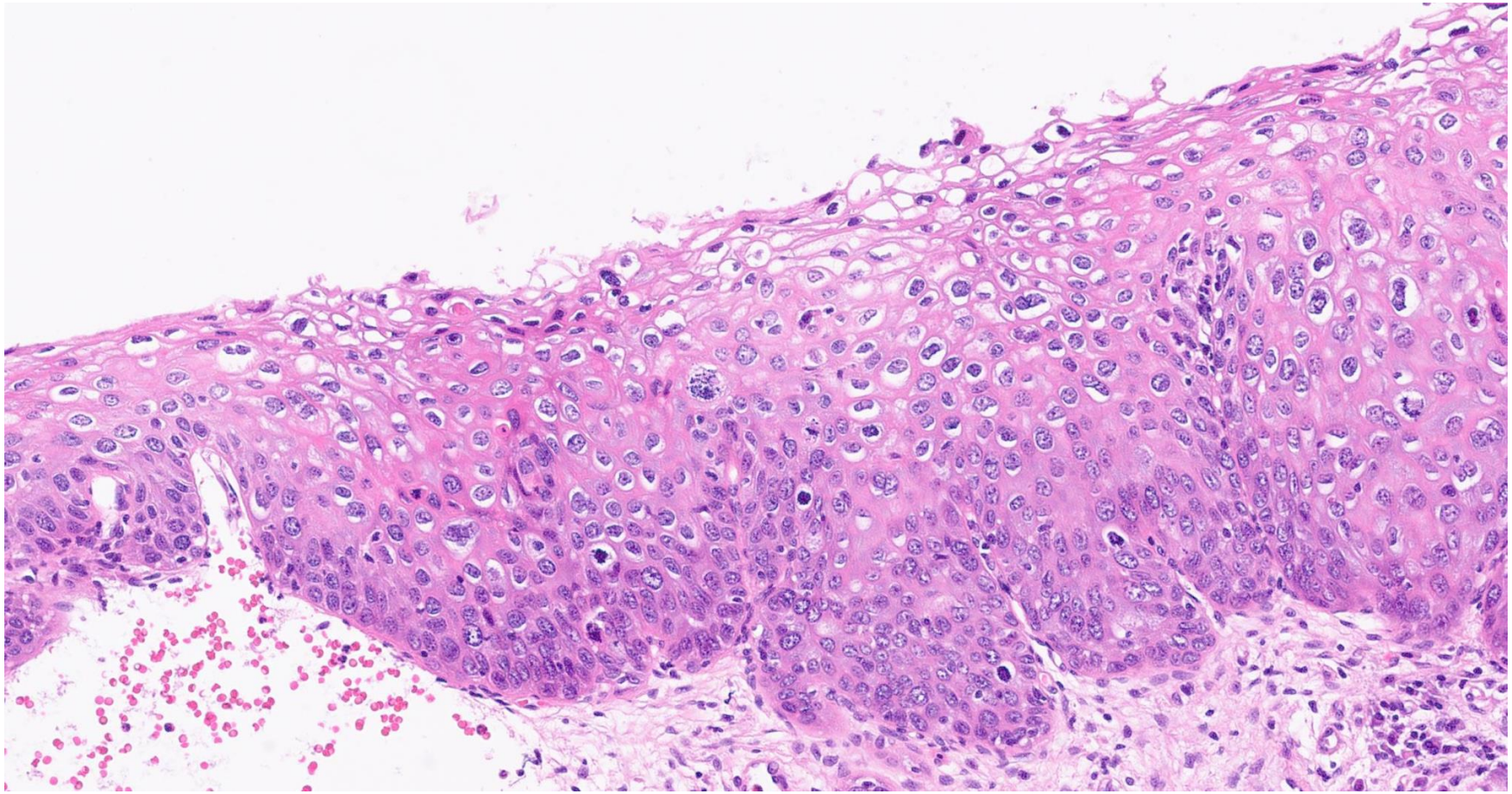

Poll Q3. p16 IHC normal/negative

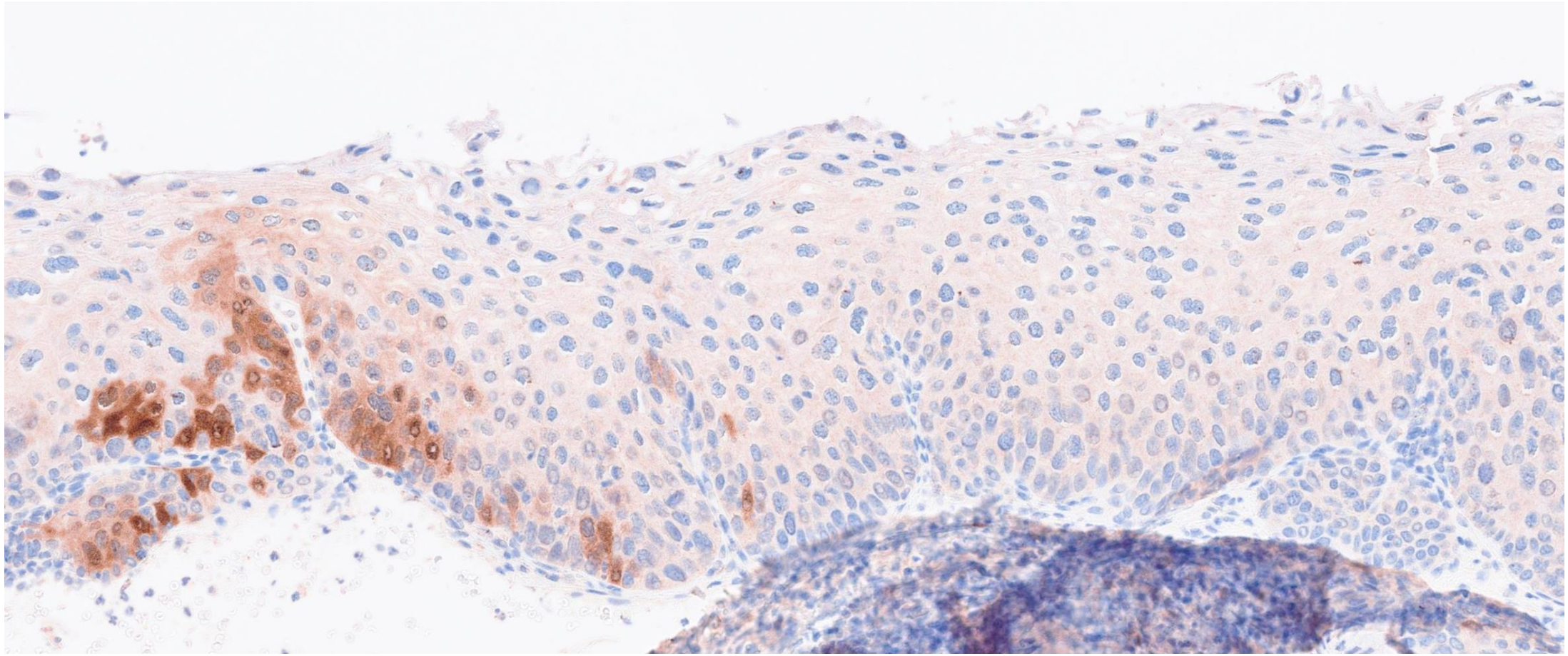

Poll Q3: CIN1 + florid koilocytosis, p16 normal/negative

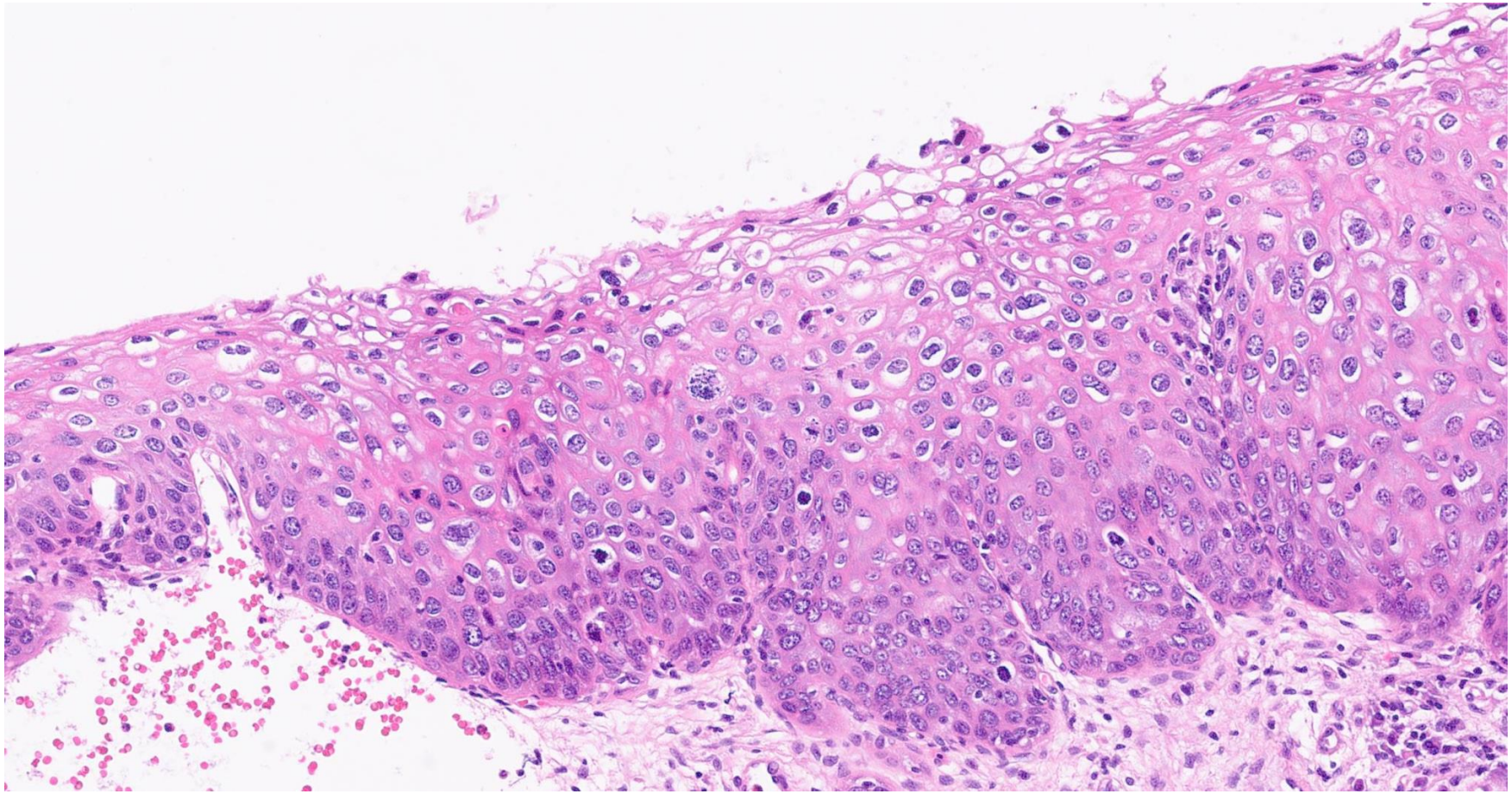

Frequency of p16 IHC use

- WHO recommends using p16 IHC in 20-40% of cervical biopsies to avoid CIN2 (HSIL) overcall

- BAGP guidance recommends use of p16 IHC in no more than 20% of cervical biopsies to avoid CIN2 (HSIL) overcall.

Summary

- CIN is graded on H&E morphology
- P16 IHC is useful in refining diagnosis
- AI may improve diagnosis in future

Thank you for listening

- Comments/questions