The British Association of Gynaecological Pathologists



Lecturer– Dr Sana Khalid

ST6 Histopathology Trainee at the Royal Marsden Hospital, London

The British Association of Gynaecological Pathologists

Everyday Dilemmas in Gynaecological Pathology

- Ovary case based discussion
- Sana Khalid
- The Royal Marsden NHS Foundation Trust
- 7th March 2025

The British Association of Gynaecological Pathologists

Speaker disclosures

I have no financial conflicts of interest to disclose

Case

- Core biopsy of Left level 4 SCF Lymph node from a 68 year old female

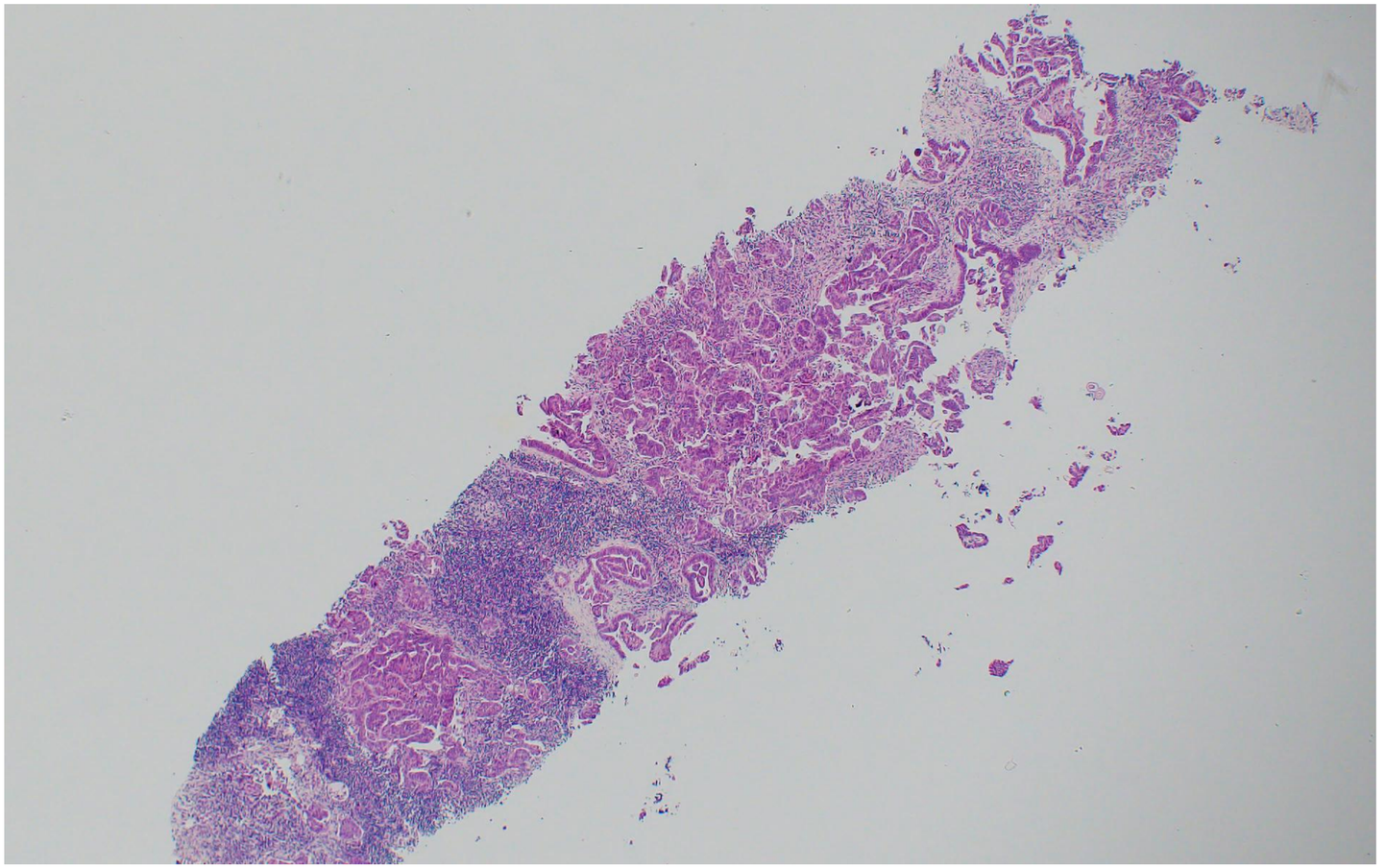

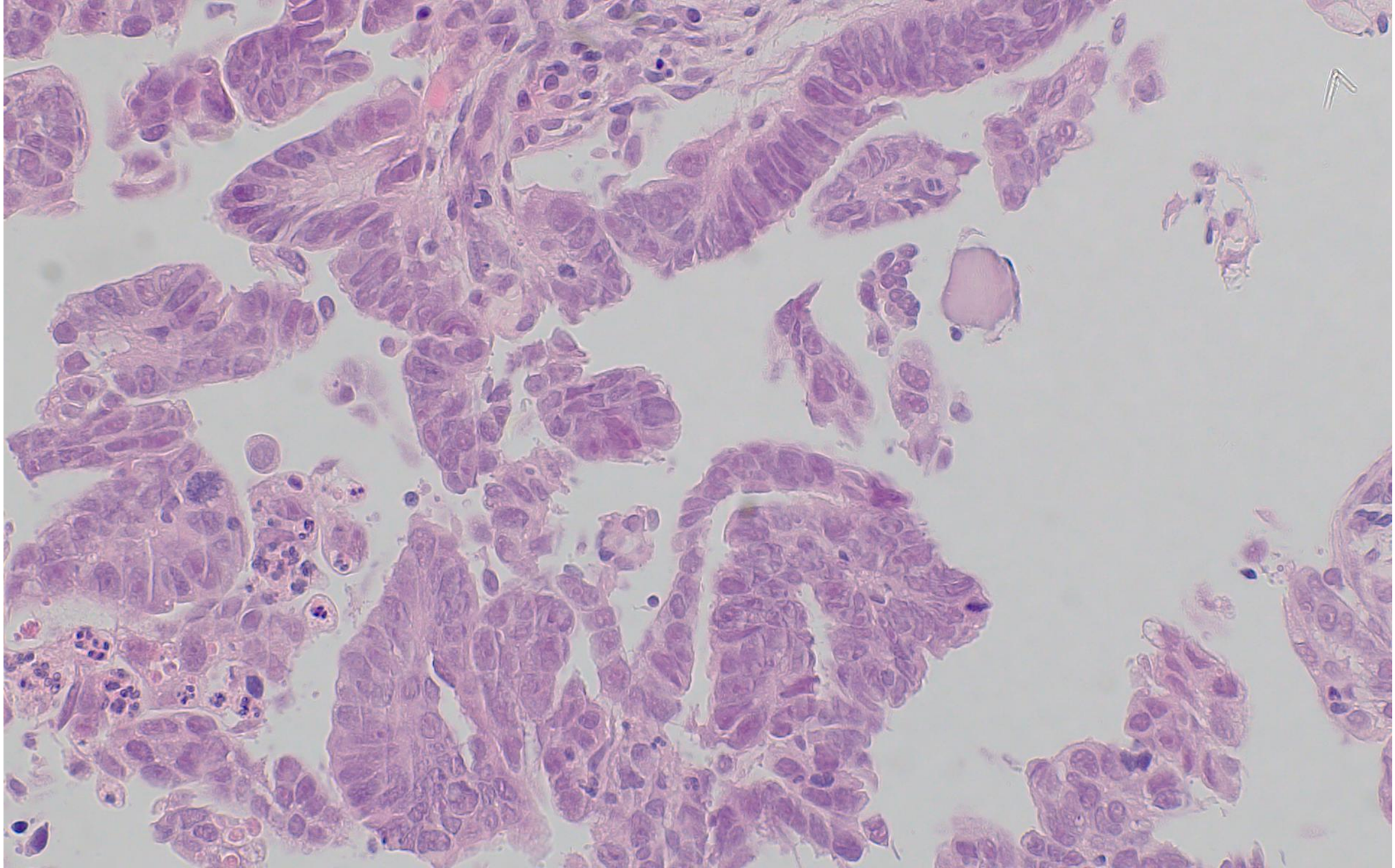

Immunohistochemistry

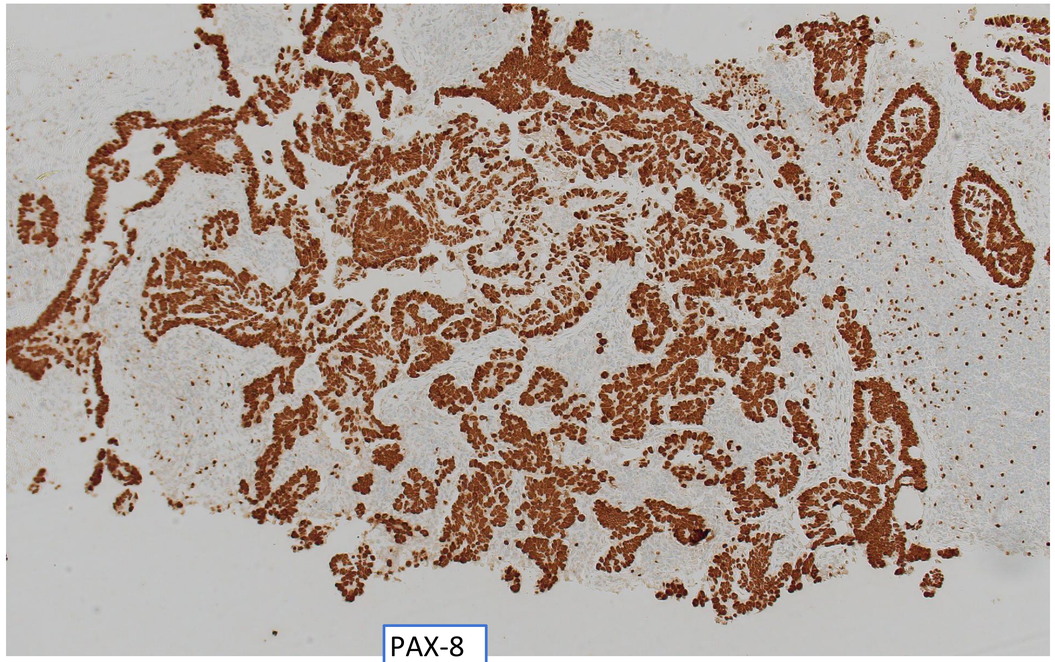

PAX-8

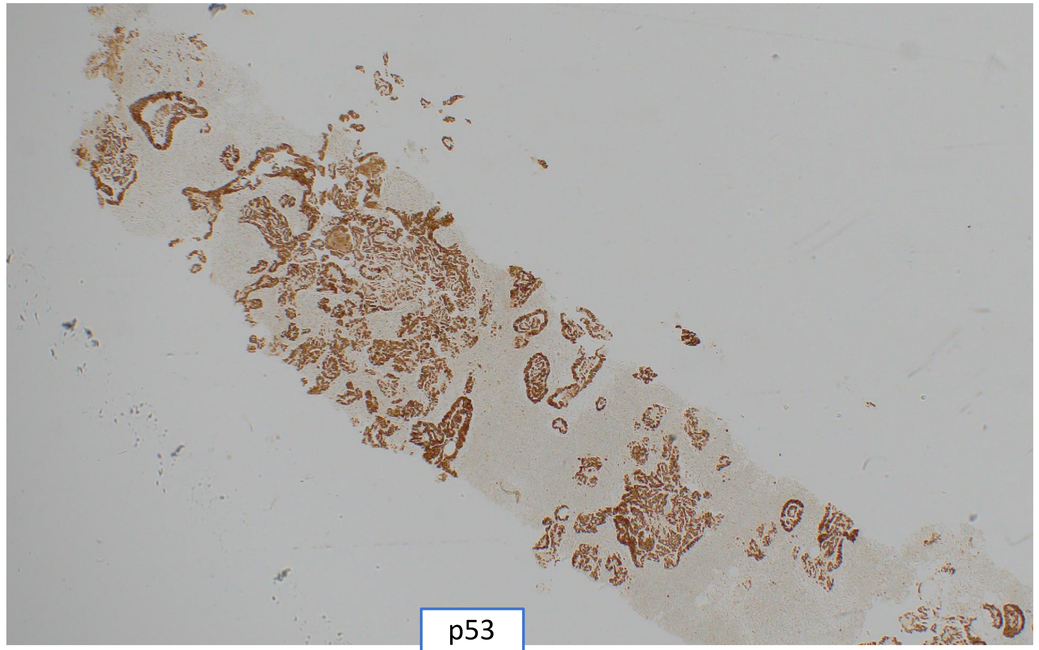

p53

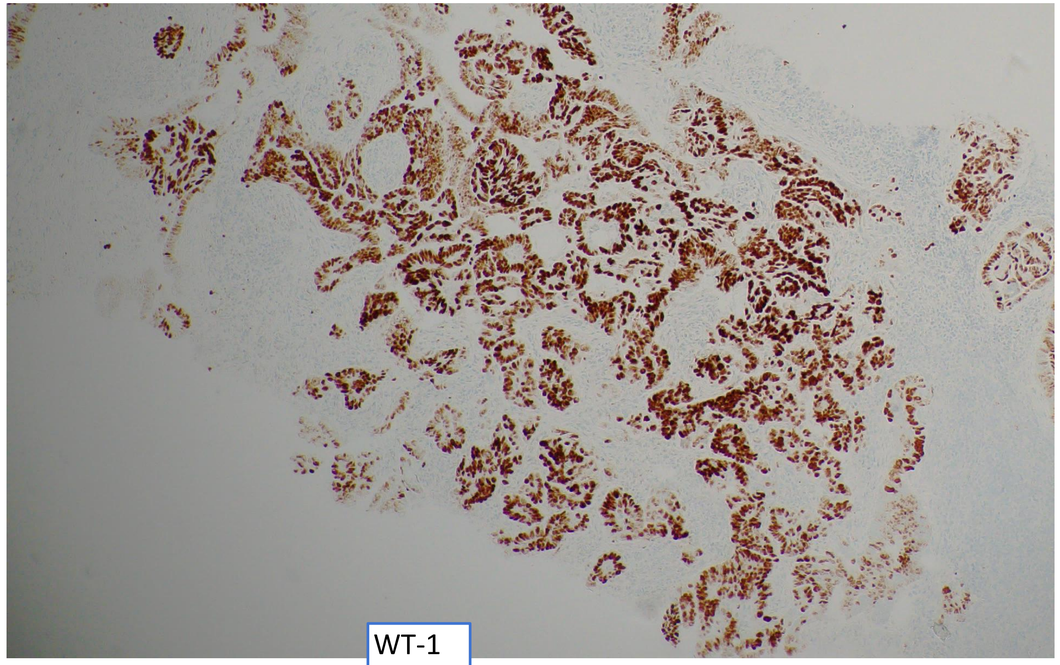

WT-1

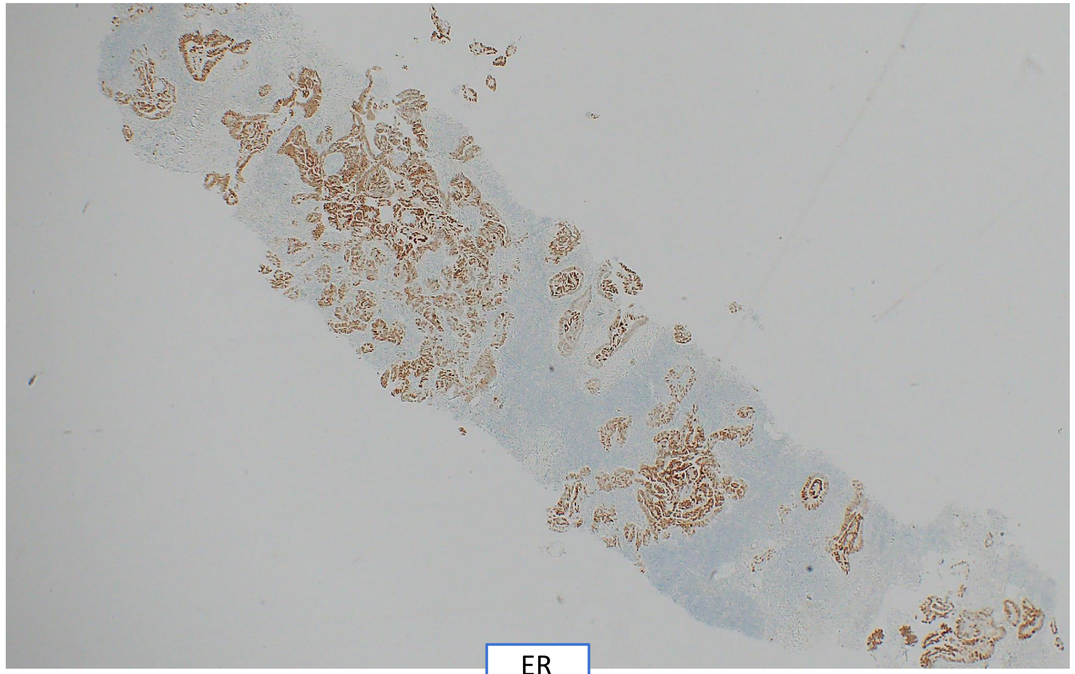

ER

Let’s dig a little deeper….

PET avid supra and infradiaphragmatic lymph nodes


2021
2022
2023
2024

Bilateral Ovarian tumours

Ovarian tumours in 2021

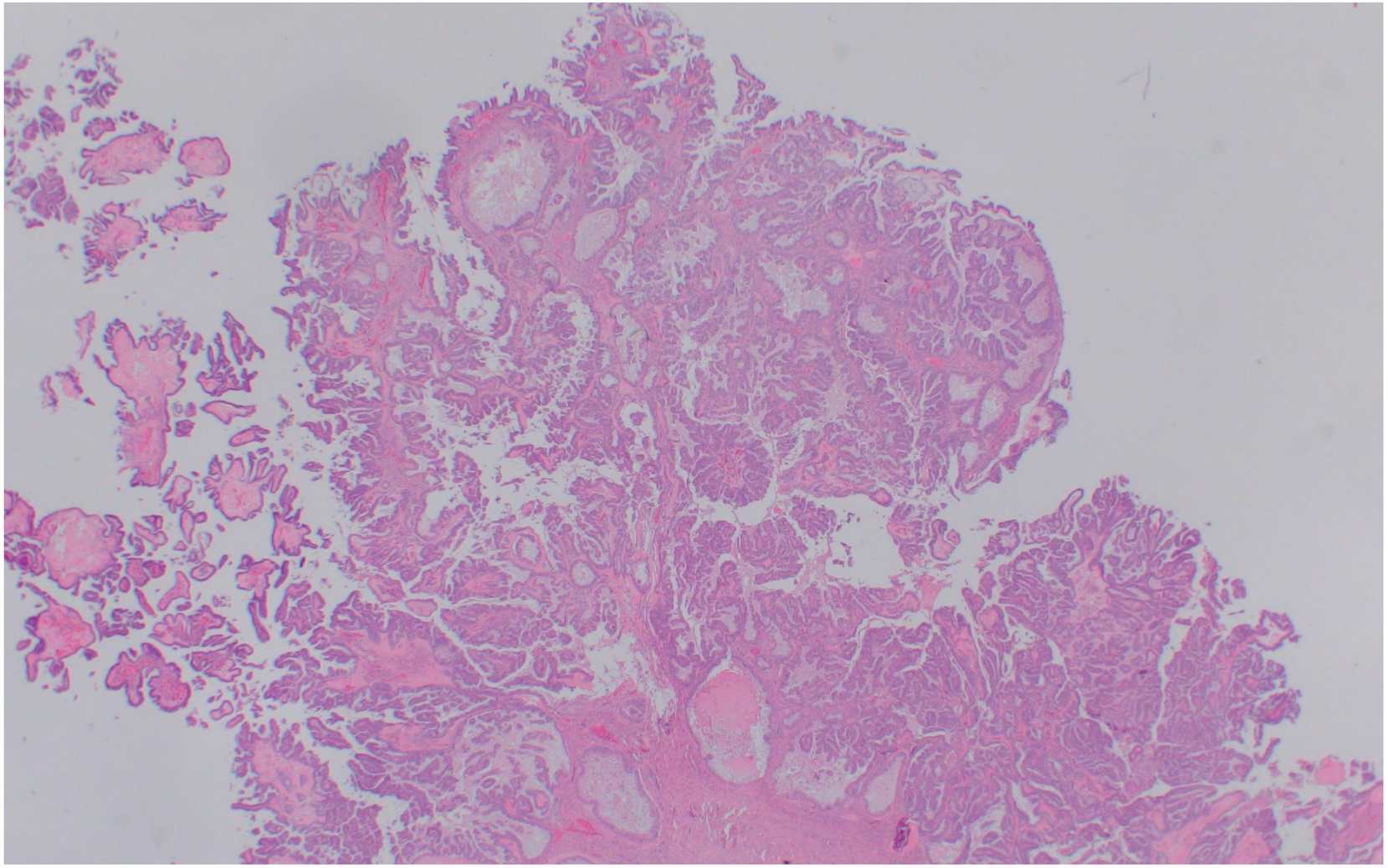

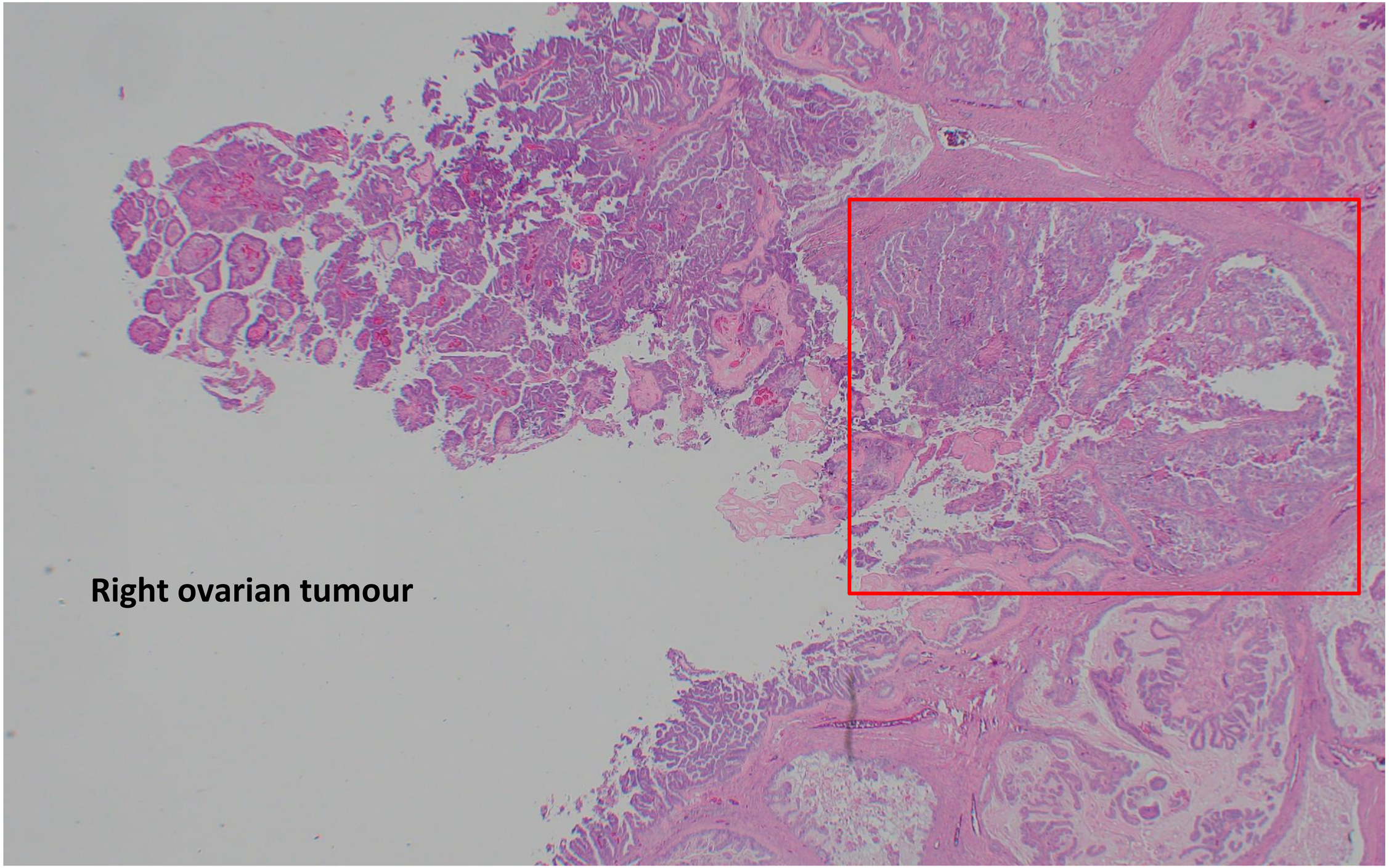
Right ovarian tumour

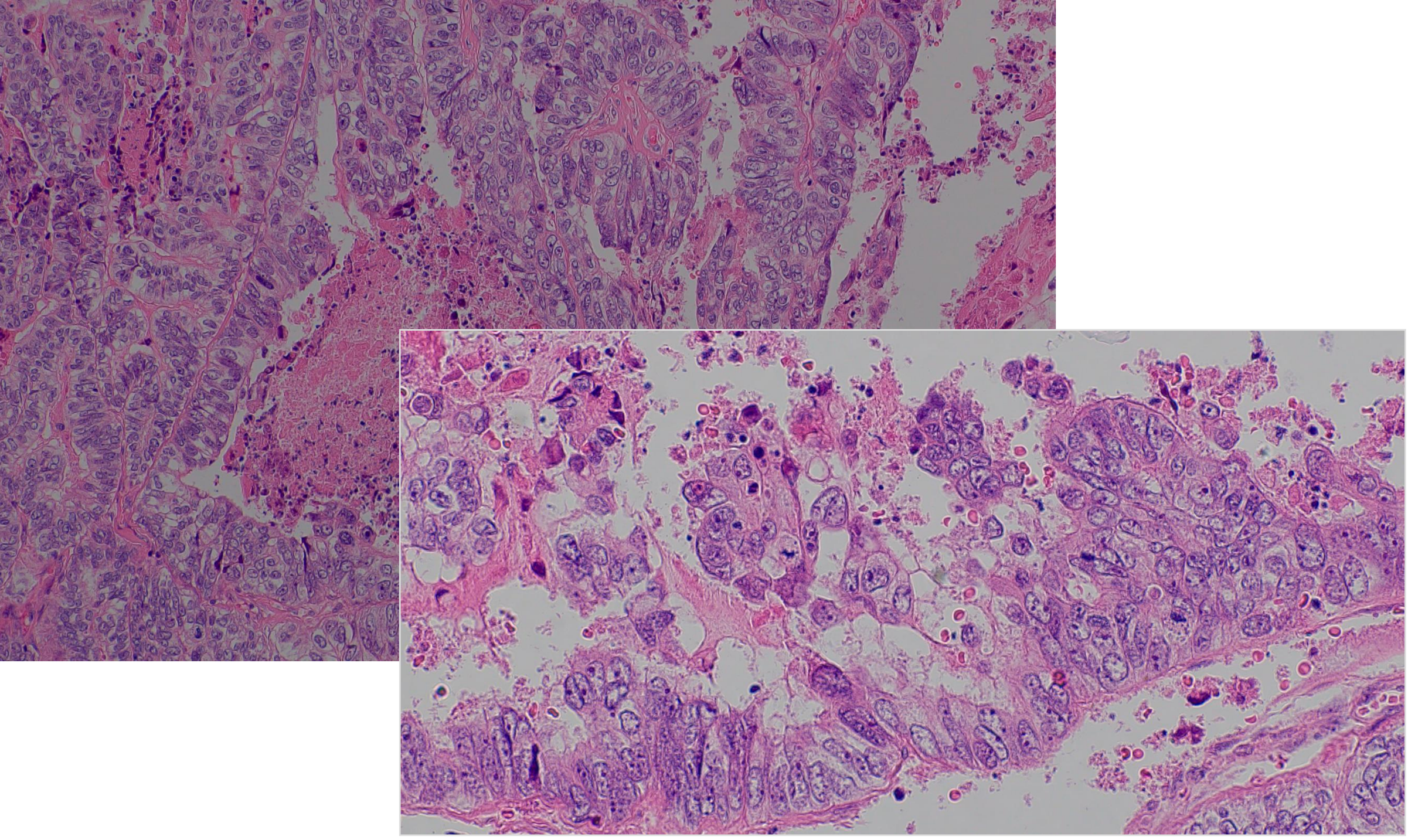

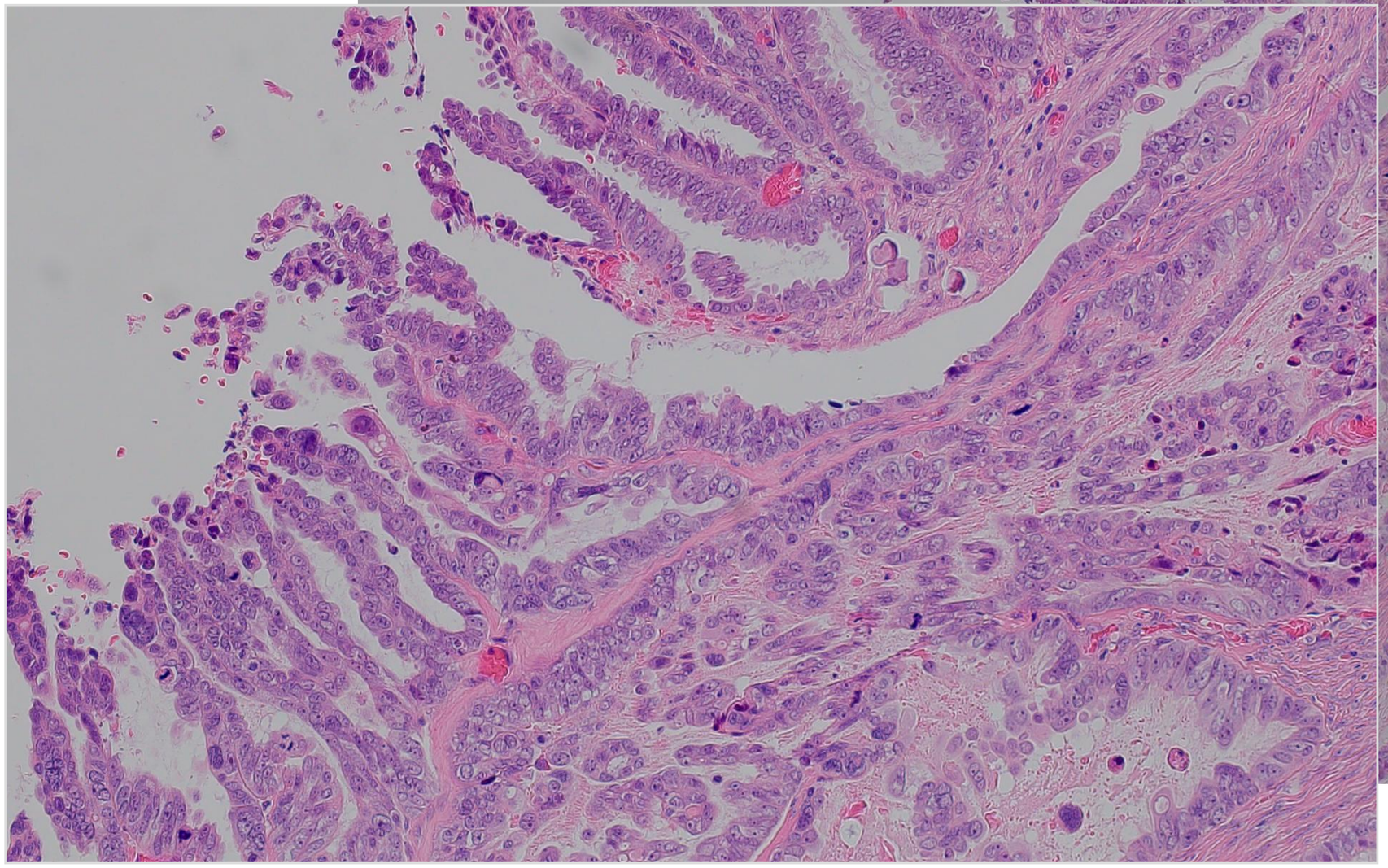

Immunohistochemistry

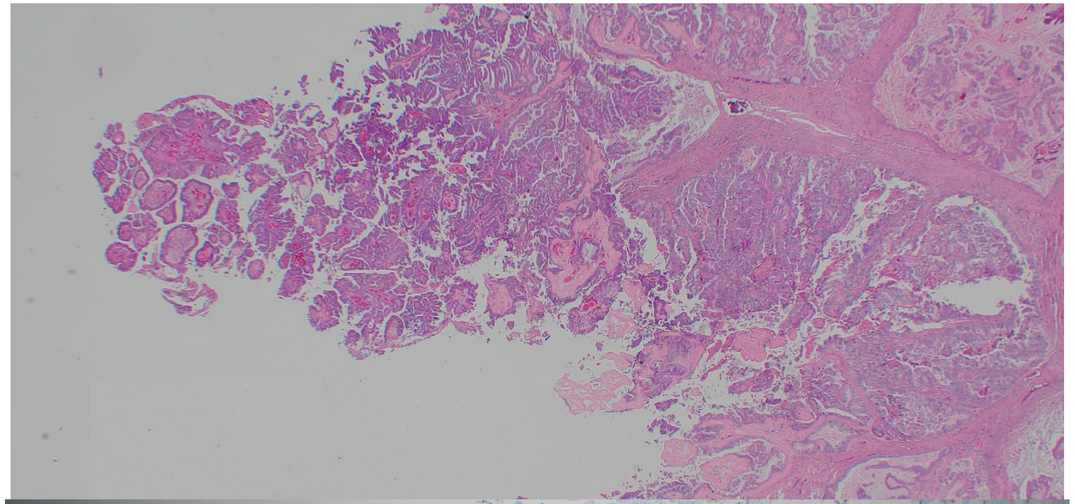

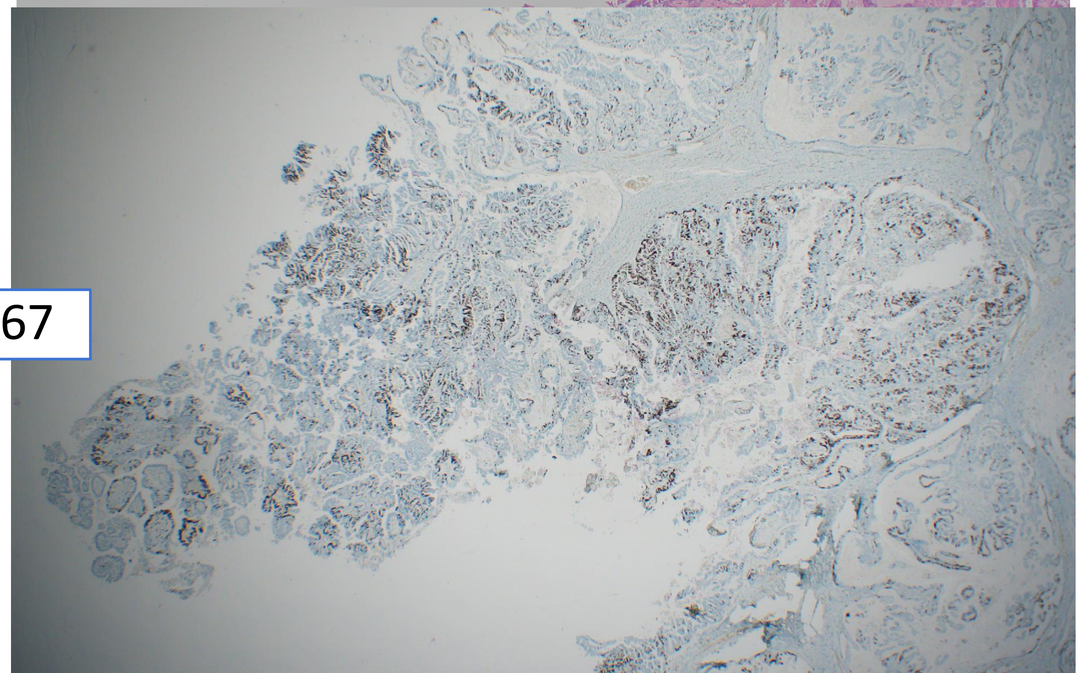

Ki67

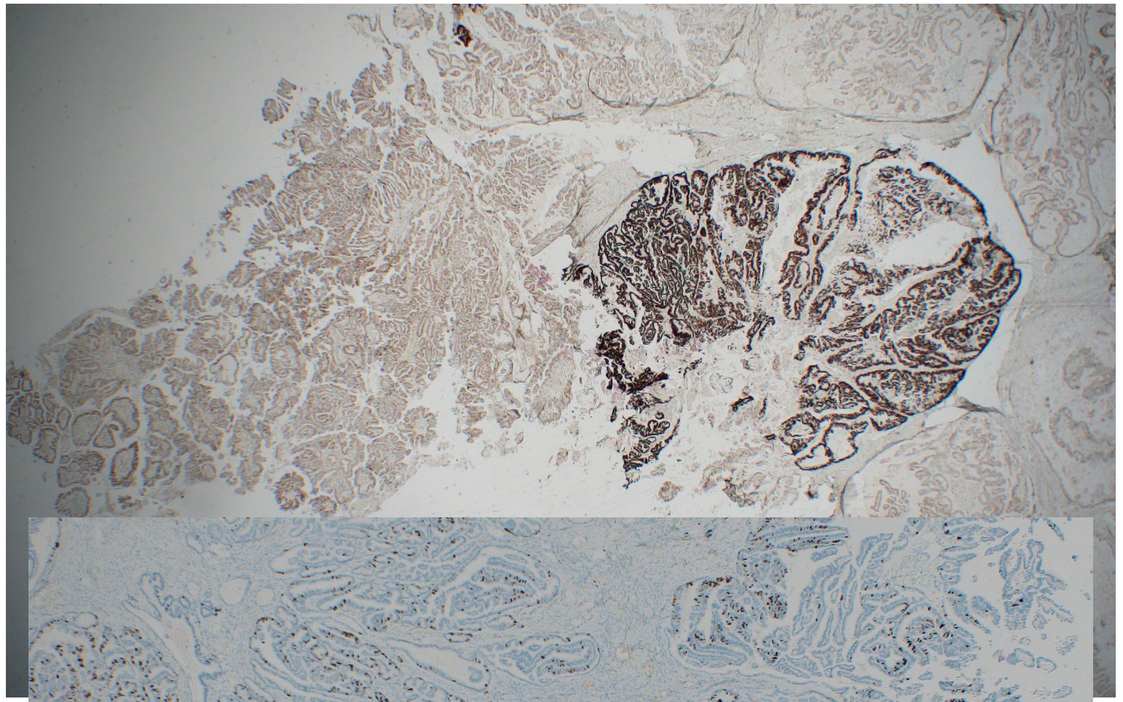

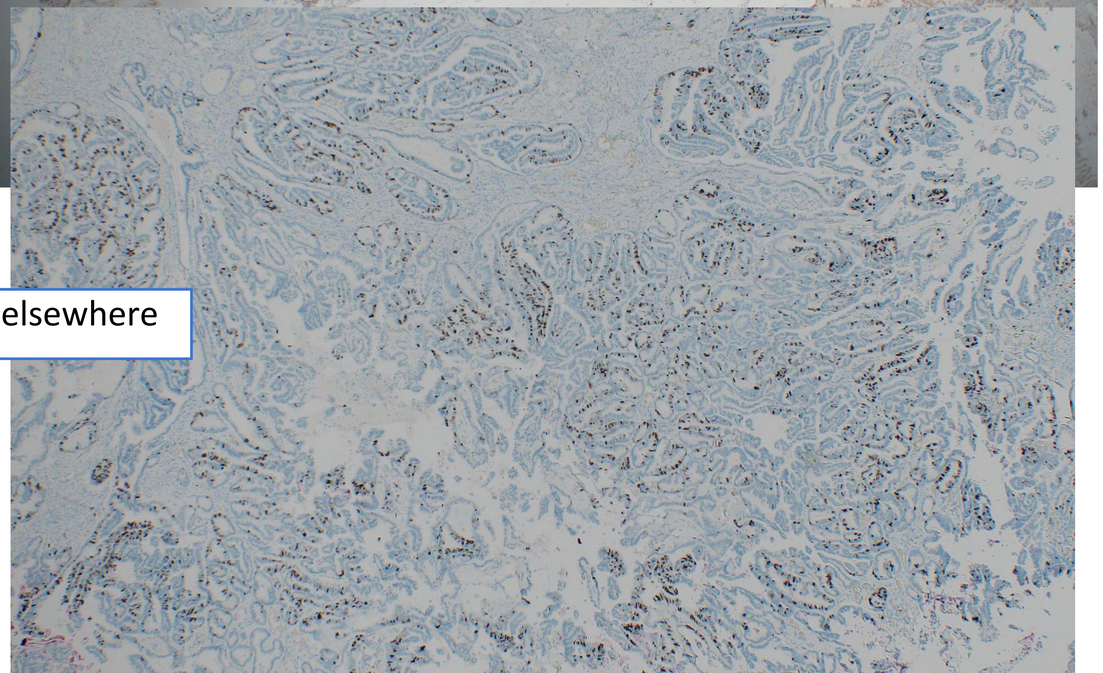

Ki67 elsewhere

Immunohistochemistry

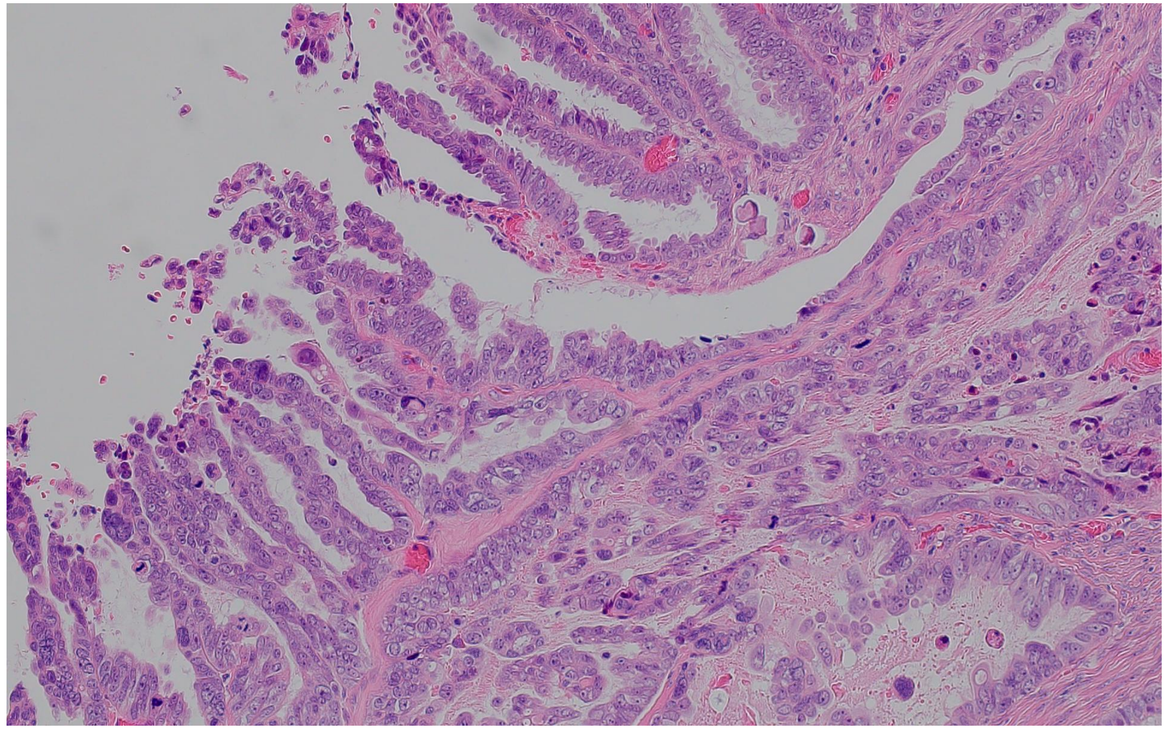

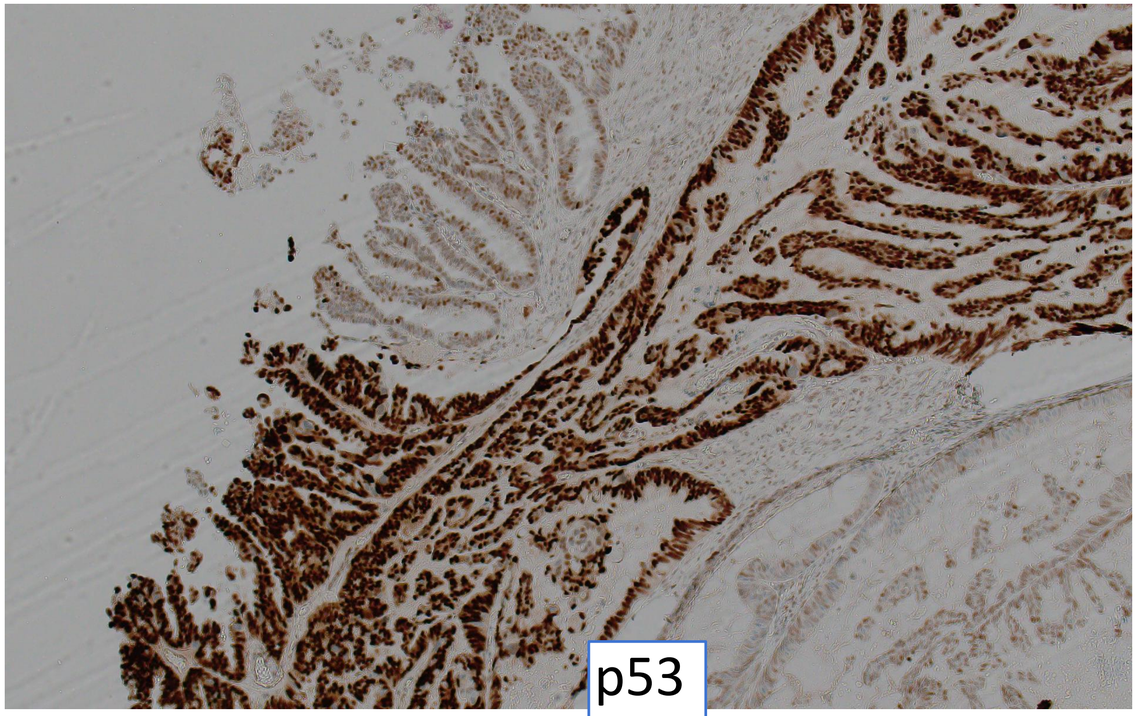

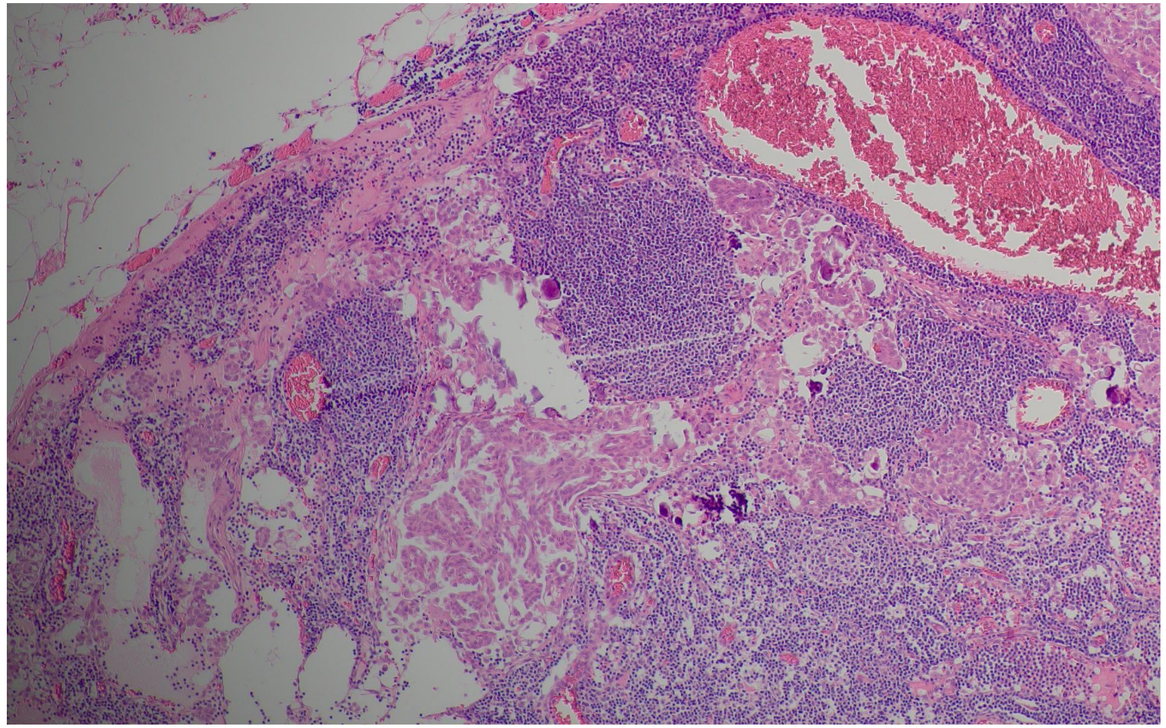

Lymph node in omentum

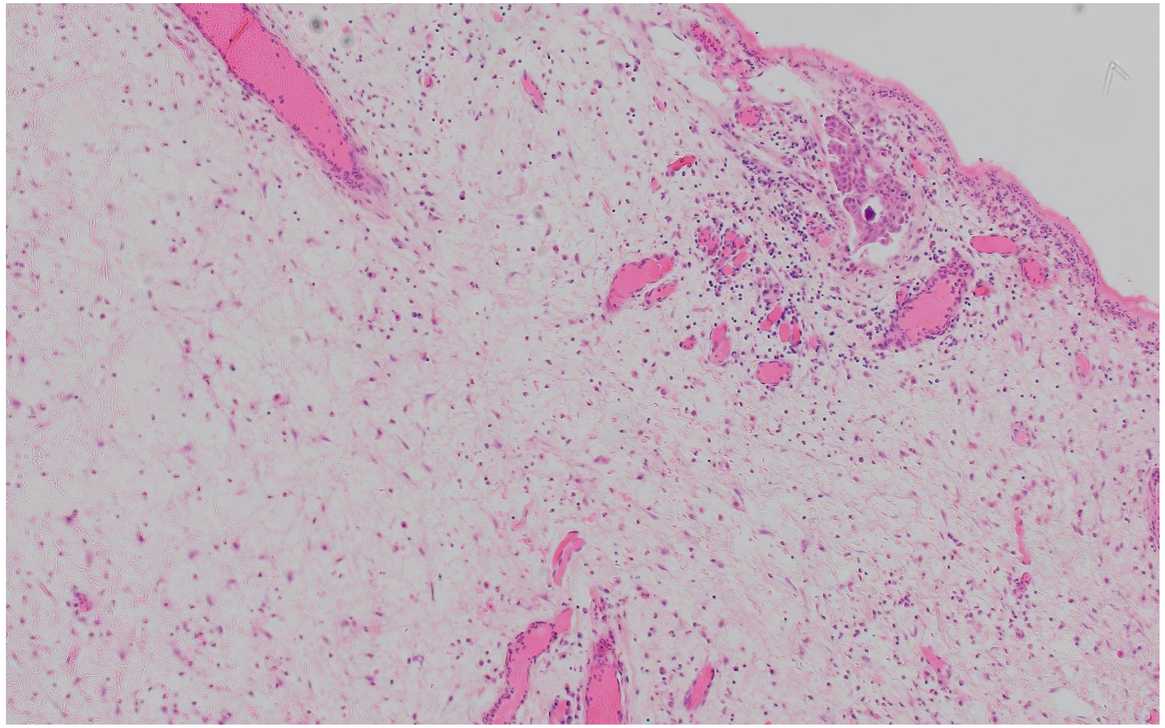

Non-invasive implant in mesoappendix

Molecular report

2021

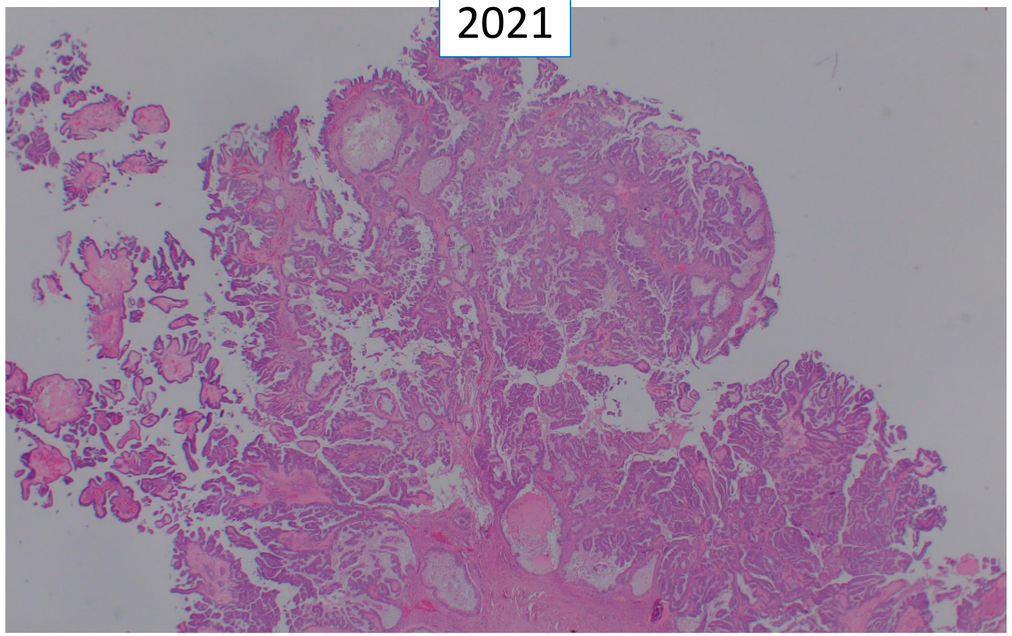

A pathogenic hotspot variant was detected in the *KRAS* gene – G12D

2024

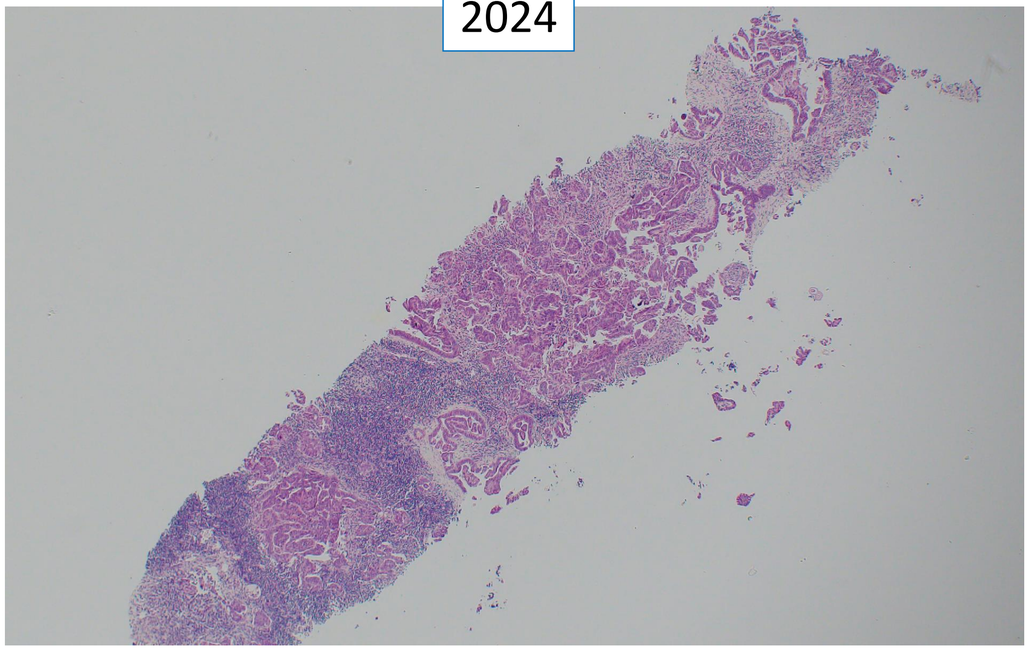

A pathogenic hotspot variant was detected in the *KRAS* gene – G12D

A nonsense variant was also detected in the *TP53* gene

What is going on?

2021

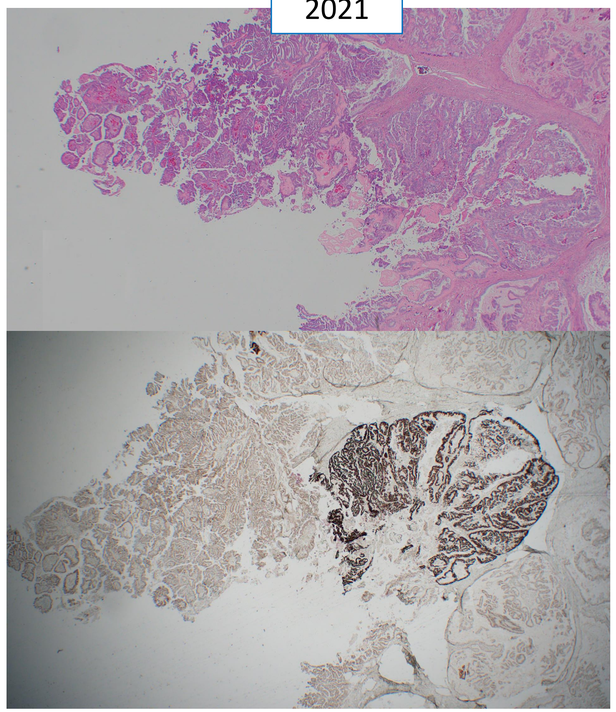



2024

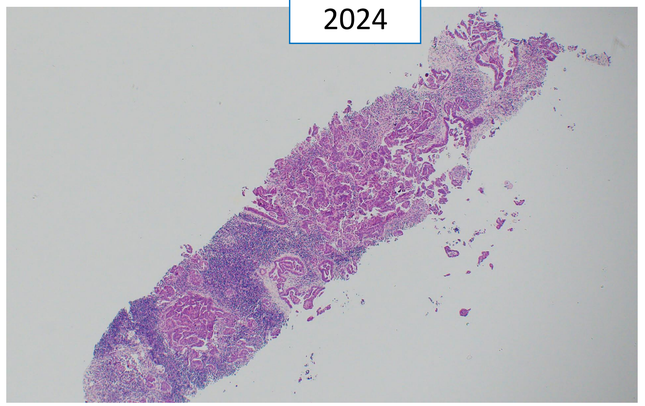

? De novo metastatic high grade serous carcinoma

Or something else ?

- Identical KRAS mutations consistent with clonal relationship
- 3 year gap between initial resection and ‘relapse’
- Subclonal p53 mutant focus with cytopathic changes in a micropapillary SBT
- De novo high grade serous carcinoma – stromal infiltration is not required for diagnosis
- Low grade serous neoplasms – stromal infiltration distinguishes borderline from carcinoma
- There are no established criteria for this scenario, but given the marked atypia is this carcinoma?

High grade transformation of a low grade serous neoplasm of ovary

Recap….What do we know

- Ovarian serous neoplasms are classified into low grade (cystadenomas, SBT and LGSC) and high- grade subtypes
- Distinct diseases with different histomorphology, molecular pathogenesis and as a consequence different clinical behaviours
- Low grade serous neoplasms lie on a spectrum and represent sequential steps in the progression of disease.
- Most (60%) of LGSCs harbor mutations in *BRAF*, *KRAS*, or *NRAS*, resulting in constitutive activation of downstream MAPK signalling pathway
- High grade serous carcinoma harbours an essential driver mutation in *TP53* – an early event in pathogenesis.

Dualistic pathway

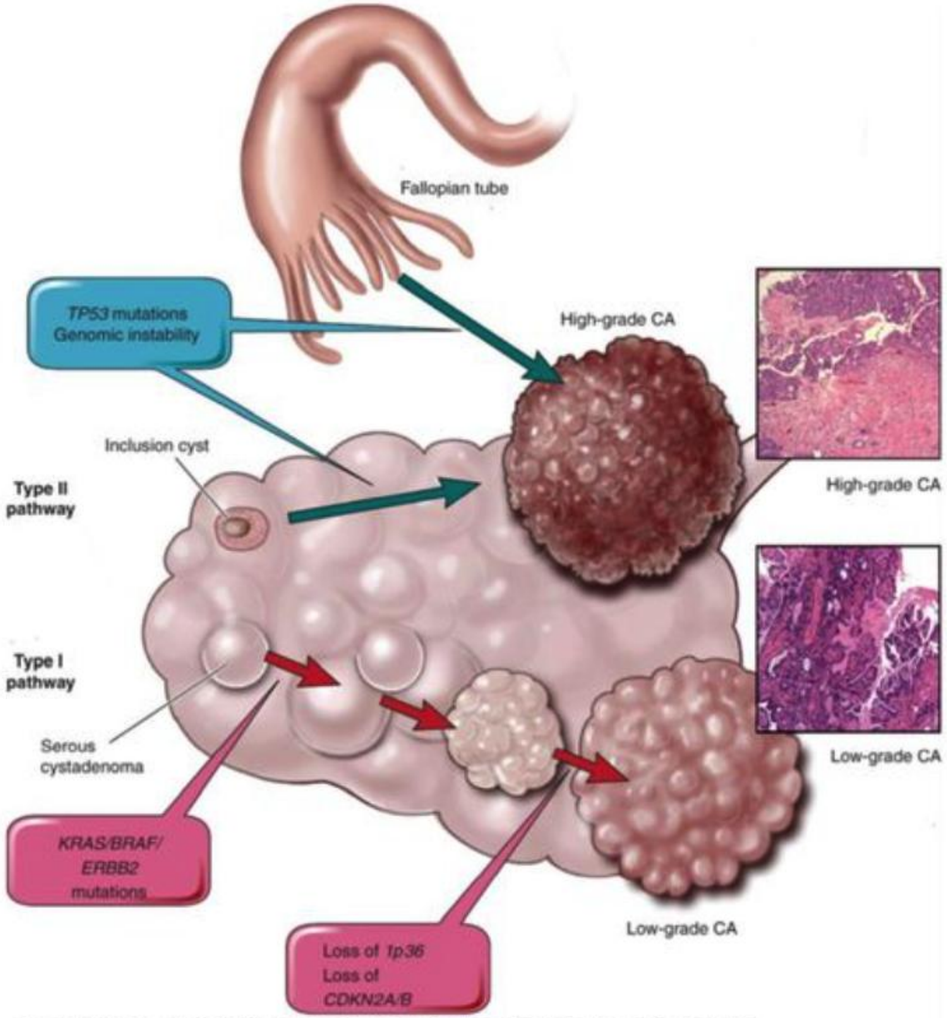

Source: B. Y. Karlan, R. E. Bristow, A. J. Li: Gynecologic Oncology: Clinical Practice and Surgical Atlas
www.obgyn.mhmedical.com
Copyright © McGraw-Hill Education. All rights reserved.

What we also know

PATHOLOGY OF THE UPPER GENITAL TRACT: ORIGINAL ARTICLES

Low-grade Serous Neoplasms of the Ovary With Transformation to High-grade Carcinomas

A Report of 3 Cases

Garg, Karuna M.D.; Park, Kay J. M.D.; Soslow, Robert A. M.D

Author Information

International Journal of Gynecological Pathology 31(5):p 423-428, September 2012. | ***DOI:*** 10.1097/PGP.0b013e31824ae6f2

ORIGINAL ARTICLES

Clinicopathologic and Molecular Features of Paired Cases of Metachronous Ovarian Serous Borderline Tumor and Subsequent Serous Carcinoma

Chui, Michael Herman MD[*]; Xing, Deyin MD, PhD[*]; Zeppernick, Felix MD[*,†]; Wang, Zoe Q. BS[*]; Hannibal, Charlotte G. PhD[‡]; Frederiksen, Kirsten PhD[‡]; Kjaer, Susanne K. MD[‡,§]; Cope, Leslie PhD[‖]; Kurman, Robert J. MD[*,¶]; Shih, Ie-Ming MD, PhD[*,¶]; Wang, Tian-Li PhD[*]; Vang, Russell MD[*,¶]

Author Information

The American Journal of Surgical Pathology 43(11):p 1462-1472, November 2019. | ***DOI:*** 10.1097/PAS.0000000000001325

Histopathology

Full Access

High-grade serous carcinoma arising in a low-grade serous carcinoma and micropapillary serous borderline tumour of the ovary in a 23-year-old woman

M Ruhul Quddus, Lanita B Rashid, Katrine Hansen, C James Sung, W Dwayne Lawrence

First published: 24 April 2009 | https://doi.org/10.1111/j.1365-2559.2009.03283.x | Citations: 25

Low-Grade Ovarian Serous Neoplasms (Low-Grade Serous Carcinoma and Serous Borderline Tumor) Associated With High-Grade Serous Carcinoma or Undifferentiated Carcinoma

Report of a Series of Cases of an Unusual Phenomenon

Boyd, Clinton MB; McCluggage, W. Glenn FRCPath

MODERN PATHOLOGY

USCAP UNITED STATES AND CANADIAN ACADEMY OF PATHOLOGY Creating a Better Pathologist

Journal homepage: https://modernpathology.org/

Research Article

Early Genetic Divergence of High-Grade Carcinomas Originating from Low-Grade Serous Ovarian Neoplasms

M. Herman Chui[a,*], Qianqian Song[b], Jiarun Zhu[b], Yuchen Jiao[b], Brant Wang[c], Yeh Wang[d], Tian-Li Wang[d], Russell Vang[d,e], Ie-Ming Shih[d,e]

[a] *Department of Pathology and Laboratory Medicine, Memorial Sloan Kettering Cancer Center, New York, New York;* [b] *State Key Lab of Molecular Oncology, Laboratory of Cell and Molecular Biology, National Cancer Center/National Clinical Research Center for Cancer/Cancer Hospital, Chinese Academy of Medical Sciences and Peking Union Medical College, Beijing, PR China;* [c] *Department of Pathology, Inova Fairfax Hospital, Falls Church, Virginia;* [d] *Department of Pathology, Johns Hopkins Medical Institutions, Baltimore, Maryland;* [e] *Department of Gynecology/Obstetrics, Johns Hopkins Medical Institutions, Baltimore, Maryland*

ORIGINAL CONTRIBUTIONS

Early Recurrence of Ovarian Serous Borderline Tumor as High-grade Carcinoma: A Report of Two Cases

Parker, Robin L. M.D.; Clement, Philip B. M.D.; Chercover, David J. M.D.; Sornarajah, Thangaraja M.D.; Gilks, C. Blake M.D.

Author Information

International Journal of Gynecological Pathology 23(3):p 265-272, July 2004. | ***DOI:*** 10.1097/01.pgp.0000130049.19643.f6

The Development of High-grade Serous Carcinoma From Atypical Proliferative (Borderline) Serous Tumors and Low-grade Micropapillary Serous Carcinoma

A Morphologic and Molecular Genetic Analysis

Dehari, Reiko MD, PhD[* †]; Kurman, Robert J. MD[* †]; Logani, Sanjay MD[* †]; Shih, Ie-Ming MD, PhD[* †]

Author Information

The American Journal of Surgical Pathology 31(7):p 1007-1012, July 2007. | ***DOI:*** 10.1097/PAS.0b013e31802cbbe9

Histopathology

Original Article

Somatic genetic alterations in synchronous and metachronous low-grade serous tumours and high-grade carcinomas of the adnexa

Rajmohan Murali, Pier Selenica, David N Brown, R Keira Cheetham, Raghu Chandramohan, Nidia L Claros, Nancy Bouvier, Donavan T Cheng, Robert A Soslow, Britta Weigelt, W Glenn McCluggage

First published: 22 November 2018 | https://doi.org/10.1111/his.13796 | Citations: 17

Is there a pattern?

HGSC : >12/ 10HPF, Grade 3 nuclear atypia

LGSC: <12/10HPF, Grade 1 nuclear atypia

IGSC: ≥ 12/ 10HPF, Grade 2 nuclear atypia

P53 wild type by IHC

- Reported to be as high as 6% by Emr
- Age range - 22- 82
- Tumour subtype (low grade) - Serous g micropapillary subtype and LGSC
- Tumour subtype (transformation)- HGSC, *IGSC, poorly differentiated carcinomas, carcinosarcomas
- Stage - I - IV
- Time to transformation - At presentation, 18 months - 25 years
- Site of recurrence- local abdominal and pelvic to distant lymph nodes in axilla/ mediastinum
- Immunohistochemistry
- Molecular
- Clinical outcome - lost to follow up, died- aggressive clinical outcome and poor response to treatment

*IGSC: Indeterminate- grade serous carcinomas

Imunohistochemistry (p53)

Table 2
Histologic, immunophenotypic, and molecular features

Case no.	Tumor component	Nuclear grade	Mitotic rate (per 10 HPF)	Immunophenotype						Mutated cancer driver genes	Fraction of genome altered (%)	Proportion of somatic variants shared/truncal (%)
				Pax8	WT1	ER	PR	p16	p53			
1	SBT (ovary)	1	2	+	+	+	+/−	Het	WT	*KRAS*	0.62	26
	HGSC (ovary)	3	13	+	+	+	+/−	Het	Abn (cyto)	*KRAS, TP53*	100[c]	25
2	SBT (ovary)	1	2	+	+	+/−	+/−	Het	WT	*KRAS*	14	33
	IGSC (rec)	2	14	+	+	+/−	-	Diff	WT	*KRAS*	30	26
3	LGSC (ovary)	2	3	+	+	+	+/−	Het	WT	*KRAS*	100[c]	18
	LGSC (lymph node)	2	0	+	+	+	+/−	Het	WT	*KRAS*	37	32
	HG. Ca. (rec)[a]	3	17	+	−	−	−	Het	WT	*KRAS*	100[c]	28
4	SBT (ovary)	1	3	+	+	+/−	+	Het	WT[b]	*BRAF, TP53*	5.9	38
	HGSC (ovary)	3	12	+	+	+/−	+/−	Diff	Abn (Diff.)	*BRAF, TP53*	28	21
	HGSC (lymph node)	3	14	+	+	+/−	+/−	Diff	Abn (Diff.)	*BRAF, TP53*	22	29
5	miSBT (ovary)	1	2	+	+	+	+/−	Null	WT	*NF1, NF2, ATRX*	8.9	33
	IGSC (diaphragm)	2	13	+	+	+	+/−	Null	WT	*NF2, ATRX*	14	18
	HGSC (rec)	3	22	+	+	−	−	Null	WT	*NF2, ATRX, TP53*	21	9.4
6	miSBT (ovary)	1	0	+	+	+	+	Het	WT	None	0.10	43
	LGSC (ovary)	1	0	+	+	+	+	Het	WT	None	25	58
	IGSC (rec)	2	23	+	+	+	−	Het	WT	None	32	39
	LGSC (rec)	1	3	+	+	+	−	Null	WT	*CDKN2A (del)*	27	29
7	LGSC (ovary)	1	0	+	+/−	+	+/−	Het	WT	*KRAS, USP9X*	82	50
	Undiff. Ca. (rec)	3	3	−	−	−	−	Het	WT	*KRAS, USP9X*	97[c]	41

Modern Pathology 2025 Chui et al.

TABLE 2. Mutational Status of KRAS, BRAF, and p53 Genes

Cases	KRAS	BRAF	p53
A			
APST	GGT to GAT	Wild type	Wild type
HG	GGT to GAT	Wild type	Wild type
B			
APST	GGT to GCT	Wild type	Wild type
HG	GGT to GCT	Wild type	Wild type
C			
LG	Wild type	Wild type	Wild type
HG	Wild type	Wild type	Wild type
D			
LG	Wild type	Wild type	Wild type
HG	Wild type	Wild type	Wild type
E			
LG	Wild type	Wild type	Wild type
HG	Wild type	Wild type	Wild type
F			
APST	Wild type	Wild type	Wild type
HG	Wild type	Wild type	Wild type

Am J Surg Pathology 2007 Dehari et al.

Unifying Molecular Pathogenesis ?

- Is high grade transformation driven by *TP53* mutation?
- Techniques- targeted gene panel and WES
- Clonal relatedness and transformation initially proposed by Chui et al
- Early genetic divergence
- Biallelic inactivation of *TP53* gene associated with transformation to HGSC
- Increased median *FGA in Low grade serous neoplasms with subsequent transformation compared to conventional LGSCs
- Foci of endosalpingiosis and extra-ovarian implants harbour concordant *KRAS/ BRAF* mutations as ovarian neoplasms

*FGA: Fraction of genome altered, % age of genome altered/ affected by copy number gains/ losses

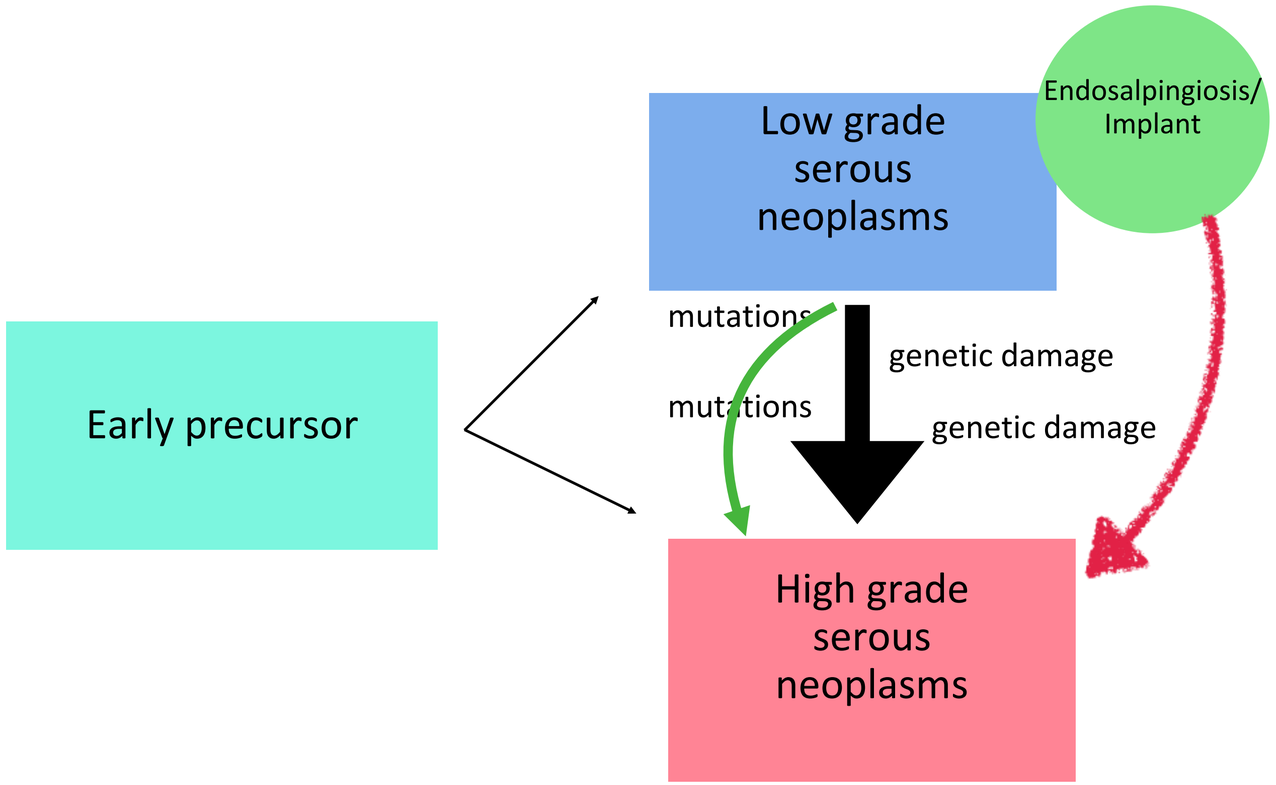
Endosalpingiosis/
Implant
Low grade
serous
neoplasms
mutations
genetic damage
mutations
genetic damage
Early precursor
High grade
serous
neoplasms

What can we learn from this case

- Although a rare event, high grade transformation is a known phenomenon
- Clinical history (if available) and/or shared mutations between low grade and high grade components
- If foci of marked cytological atypia are observed in a low grade serous neoplasm - further sampling, p53 immunostaining – findings should be mentioned in the report and potential clinical implications discussed at MDT
- Immunostaining should be viewed in conjunction with histomorphology
- Occasional HGSC can have an architecture resembling SBT and do not exhibit overt destructive invasion but should be diagnosed as HGSC based on nuclear features
- 'Borderline' is a better term than 'atypical proliferative lesion'
- Does it matter? High grade transformation v/s de novo **– YES**

Questions for further research

- Which SBT/ LGSC are likely to transform?
- What causes some to escape the dormancy given the large period of latency observed in some cases?

References

- Boyd C, McCluggage WG. Low-grade ovarian serous neoplasms (low-grade serous carcinoma and serous borderline tumor) associated with high-grade serous carcinoma or undifferentiated carcinoma: report of a series of cases of an unusual phenomenon. *Am J Surg Pathol*. 2012;36(3):368-375. doi:10.1097/PAS.0b013e31823732a9
- Garg K, Park KJ, Soslow RA. Low-grade serous neoplasms of the ovary with transformation to high-grade carcinomas: a report of 3 cases. *Int J Gynecol Pathol*. 2012;31(5):423-428. doi:10.1097/PGP.0b013e31824ae6f2
- Parker RL, Clement PB, Chercover DJ, Sornarajah T, Gilks CB. Early recurrence of ovarian serous borderline tumor as high-grade carcinoma: a report of two cases. *Int J Gynecol Pathol*. 2004;23(3):265-272. doi:10.1097/01.pgp.0000130049.19643.f6
- Quddus MR, Rashid LB, Hansen K, Sung CJ, Lawrence WD. High-grade serous carcinoma arising in a low-grade serous carcinoma and micropapillary serous borderline tumour of the ovary in a 23-year-old woman. *Histopathology*. 2009;54(6):771-773. doi:10.1111/j.1365-2559.2009.03283.x
- Dehari R, Kurman RJ, Logani S, Shih IeM. The development of high-grade serous carcinoma from atypical proliferative (borderline) serous tumors and low-grade micropapillary serous carcinoma: a morphologic and molecular genetic analysis. Am J Surg Pathol. 2007;31(7):1007-1012. doi:10.1097/PAS.0b013e31802cbbe9
- Murali R, Selenica P, Brown DN, et al. Somatic genetic alterations in synchronous and metachronous low-grade serous tumours and high-grade carcinomas of the adnexa. Histopathology. 2019;74(4):638-650. doi:10.1111/his.13796
- Chui MH, Xing D, Zeppernick F, et al. Clinicopathologic and Molecular Features of Paired Cases of Metachronous Ovarian Serous Borderline Tumor and Subsequent Serous Carcinoma. Am J Surg Pathol. 2019;43(11):1462-1472. doi:10.1097/PAS.0000000000001325
- Zarei S, Wang Y, Jenkins SM, Voss JS, Kerr SE, Bell DA. Clinicopathologic, Immunohistochemical, and Molecular Characteristics of Ovarian Serous Carcinoma With Mixed Morphologic Features of High-grade and Low-grade Serous Carcinoma. Am J Surg Pathol. 2020;44(3):316-328. doi:10.1097/PAS.0000000000001419
- Chui MH, Song Q, Zhu J, et al. Early Genetic Divergence of High-Grade Carcinomas Originating from Low-Grade Serous Ovarian Neoplasms. Mod Pathol. 2025;38(1):100629. doi:10.1016/j.modpat.2024.100629
- Chui MH, Shih IM. Oncogenic BRAF and KRAS mutations in endosalpingiosis. J Pathol. 2020;250(2):148-158. doi:10.1002/path.5353

Acknowledgments



Dr Ayoma Attygalle

Thank you for listening!

