WHO Classification, 5th Edition (2020), Female Genital Tumours: Endometrial Carcinomas – changes in classification

Naveena Singh
Barts Health NHS Trust

BAGP Update January 27, 2021

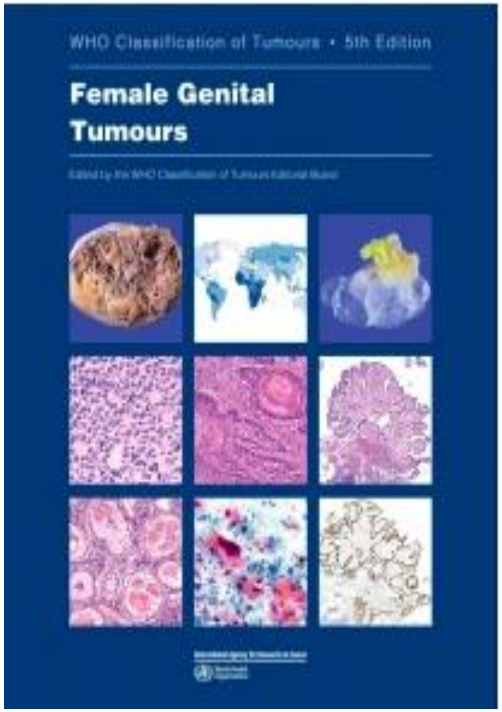

Joint statement



ESGO/ESTRO/ESP guidelines for the management of patients with endometrial carcinoma

Nicole Concin [1,2] Xavier Matias-Guiu,[3,4] Ignace Vergote,[5] David Cibula,[6] Mansoor Raza Mirza,[7] Simone Marnitz,[8] Jonathan Ledermann [9] Tjalling Bosse,[10] Cyrus Chargari,[11] Anna Fagotti,[12] Christina Fotopoulou [13] Antonio Gonzalez Martin,[14] Sigurd Lax,[15,16] Domenica Lorusso,[12] Christian Marth,[17] Philippe Morice,[18] Remi A Nout,[19] Dearbhaile O'Donnell,[20] Denis Querleu [12,21] Maria Rosaria Raspollini,[22] Jalid Sehouli,[23] Alina Sturdza,[24] Alexandra Taylor,[25] Anneke Westermann,[26] Pauline Wimberger,[27] Nicoletta Colombo,[28] François Planchamp,[29] Carien L Creutzberg[30]

Revised Guidelines for Management of EC, 2020



ISGyP Endometrial Carcinoma Project:

January 2019, Supplementary issue Open Access

Prof W Glenn McCluggage

NICE National Institute for Health and Care Excellence

NICE guidance

Testing strategies for Lynch syndrome in people with endometrial cancer, 2020

Outline

- Changes to non-endometrioid carcinoma
- Changes to endometrioid carcinoma:
  - Grade
  - Synchronous endometrial and ovarian carcinoma
  - LVSI
  - Subtypes
- Molecular classification
- Summary

WHO 2020: Classification of EC

WHO 2014

- Endometrioid
  - Squamous differentiation
  - Villoglandular
  - Secretory
- Mucinous
- Serous endometrial intraepithelial
- Serous
- Clear cell
- Neuroendocrine
  - Low grade
  - High grade
- Mixed cell
- Undifferentiated
- Dedifferentiated

WHO 2020

- Endometrioid
  - *POLE*-ultramutated
  - Mismatch repair-deficient
  - p53-mutant
  - No specific molecular profile
- Serous
- Clear cell
- Carcinoma, undifferentiated
- Mixed cell
- Mesonephric
- Squamous cell
- Mucinous, intestinal type
- Mesonephric-like
- Carcinosarcoma

WHO 2020: Classification of EC

WHO 2014

- Endometrioid
  - Squamous differentiation
  - Villoglandular
  - Secretory
- **Mucinous**
- Serous endometrial intraepithelial
- Serous
- Clear cell
- Neuroendocrine
  - Low grade
  - High grade
- Mixed cell
- Undifferentiated
- Dedifferentiated

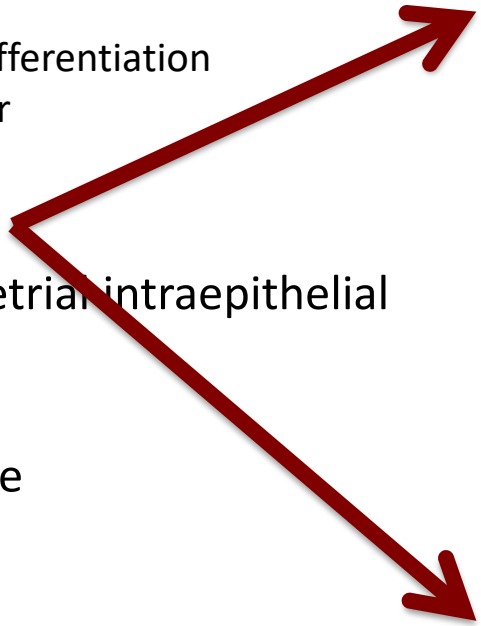

WHO 2020

- Endometrioid
  - *POLE*-ultramutated
  - Mismatch repair-deficient
  - p53-mutant
  - No specific molecular profile
- Serous
- Clear cell
- Carcinoma, undifferentiated
- Mixed cell
- Mesonephric
- Squamous cell
- Mucinous, intestinal type
- Mesonephric-like
- Carcinosarcoma

WHO 2020: Classification of EC

WHO 2014

- Endometrioid
  - Squamous differentiation
  - Villoglandular
  - Secretory
- **Mucinous**
- Serous endometrial intraepithel
- Serous
- Clear cell
- Neuroendocrine
  - Low grade
  - High grade
- Mixed cell
- Undifferentiated
- Dedifferentiated

WHO 2020

- Endometrioid

- Mucinous pattern may be seen to varying degrees in endometrioid carcinoma; not classified as mucinous; amount does not matter
- Mucinous intestinal type: NEW, included in OTHER EC
- Exclude cervical or extra-uterine origin

- Mucinous, intestinal type
- Mesonephric-like
- Carcinosarcoma

WHO 2020: Classification of EC

WHO 2014

- Endometrioid
  - Squamous differentiation
  - Villoglandular
  - Secretory
- Mucinous
- **Serous endometrial intraepithelial**
- **Serous**
- Clear cell
- Neuroendocrine
  - Low grade
  - High grade
- Mixed cell
- Undifferentiated
- Dedifferentiated



WHO 2020

- Endometrioid
  - *POLE*-ultramutated
  - Mismatch repair-deficient
  - p53-mutant
  - No specific molecular profile
- Serous
- Clear cell
- Carcinoma, undifferentiated
- Mixed cell
- Mesonephric
- Squamous cell
- Mucinous, intestinal type
- Mesonephric-like
- Carcinosarcoma

WHO 2020: Classification of EC

WHO 2014

- Endometrioid
  - Squamous differentiation
  - Villoglandular
  - Secretory
- Mucinous
- **Serous endometrial intraepithelial**
- **Serous**
- Clear cell
- Neuroendocrine
  - Low grade
  - High grade
- Mixed cell
- Undifferentiated
- Dedifferentiated

WHO 2020

- Endometrium-confined serous ca has metastatic potential
- In the absence of peritoneal spread endometrium-confined serous ca has good prognosis
- Serous ca benefit from chemotherapy
- >30% show HER2 amplification

- Mucinous, intestinal type
- Mesonephric-like
- Carcinosarcoma

WHO 2020: Classification of EC

WHO 2014

- Endometrioid
  - Squamous differentiation
  - Villoglandular
  - Secretory
- Mucinous
- Serous endometrial intraepithelial
- Serous
- **Clear cell**
- Neuroendocrine
  - Low grade
  - High grade
- Mixed cell
- Undifferentiated
- Dedifferentiated



WHO 2020

- Endometrioid
  - *POLE*-ultramutated
  - Mismatch repair-deficient
  - p53-mutant
  - No specific molecular profile
- Serous
- Clear cell
- Carcinoma, undifferentiated
- Mixed cell
- Mesonephric
- Squamous cell
- Mucinous, intestinal type
- Mesonephric-like
- Carcinosarcoma

WHO 2020: Classification of EC

WHO 2014

- Endometrioid
  - Squamous differentiatio
  - Villoglandular
  - Secretory
- Mucinous
- Serous endometrial intr
- Serous
- **Clear cell**
- Neuroendocrine
  - Low grade
  - High grade
- Mixed cell
- Undifferentiated
- Dedifferentiated

- Morphological diagnosis
- Molecular heterogeneity
- [ESGO: prognostic risk group unclear for stage IB-IVA with myometrial invasion and NSMP/MMRd]

WHO 2020

- Endometrioid
- ficient
- ar profile
- ntiated
- Mesonephric
- Squamous cell
- Mucinous, intestinal type
- Mesonephric-like
- Carcinosarcoma

WHO 2020: Classification of EC

WHO 2014

- Endometrioid
  - Squamous differentiation
  - Villoglandular
  - Secretory
- Mucinous
- Serous endometrial intraepithe
- Serous
- Clear cell
- **Neuroendocrine**
  - **Low grade**
  - **High grade**
- Mixed cell
- Undifferentiated
- Dedifferentiated

WHO 2020

- Throughout 5th edition NEN have been separated from other neoplasms
- For consistent management and to facilitate comparisons
- Neuroendocrine tumour: low- or intermediate grade – extremely rare (apart from ovary where the term 'carcinoid' is retained)
- SCNEC, LCNEC, Carcinoma admixed with NEC: High grade; most common in cervix (HPV-related); diagnosis is morphological and in case of LCNEC or Ca admixed with NEC expression of at least on NE marker is essential

WHO 2020: Classification of EC

WHO 2014

- Endometrioid
  - Squamous differentiation
  - Villoglandular
  - Secretory
- Mucinous
- Serous endometrial intraepithelial
- Serous
- Clear cell
- Neuroendocrine
  - Low grade
  - High grade
- **Mixed cell**
- Undifferentiated
- Dedifferentiated



WHO 2020

- Endometrioid
  - *POLE*-ultramutated
  - Mismatch repair-deficient
  - p53-mutant
  - No specific molecular profile
- Serous
- Clear cell
- Carcinoma, undifferentiated
- Mixed cell
- Mesonephric
- Squamous cell
- Mucinous, intestinal type
- Mesonephric-like
- Carcinosarcoma

WHO 2020: Classification of EC

WHO 2014

- Endometrioid
  - Squamous differentiation
  - Villoglandular
  - Secretory
- Mucinous
- Serous endometrial intrae
- Serous
- Clear cell
- Neuroendocrine
  - Low grade
  - High grade
- **Mixed cell**
- Undifferentiated
- Dedifferentiated

WHO 2020

- EC with 2 distinct histological types, at least one of which is either clear cell or serous
- (does not include dedifferentiated ca or carcinosarcoma)
- Immunohistochemical support for 2 distinct types is desirable
- Avoid using this for morphological variations in a single histotype or tumours with ambiguous morphology
- Any amount that can be confidently identified is sufficient

WHO 2020: Classification of EC

WHO 2014

- Endometrioid
  - Squamous differentiation
  - Villoglandular
  - Secretory
- Mucinous
- Serous endometrial intraepithelial
- Serous
- Clear cell
- Neuroendocrine
  - Low grade
  - High grade
- Mixed cell
- **Undifferentiated**
- **Dedifferentiated**



WHO 2020

- Endometrioid
  - *POLE*-ultramutated
  - Mismatch repair-deficient
  - p53-mutant
  - No specific molecular profile
- Serous
- Clear cell
- Carcinoma, undifferentiated
- Mixed cell
- Mesonephric
- Squamous cell
- Mucinous, intestinal type
- Mesonephric-like
- Carcinosarcoma

WHO 2020: Classification of EC

WHO 2014

- Endometrioid
  - Squamous differentiation
  - Villoglandular
  - Secretory
- Mucinous
- Serous endometrial intraep
- Serous
- Clear cell
- Neuroendocrine
  - Low grade
  - High grade
- Mixed cell
- **Undifferentiated**
- **Dedifferentiated**

WHO 2020

- Combined under: Carcinoma, undifferentiated
- Association with mismatch repair deficiency/Lynch Syndrome
- Can show other EC molecular profiles
- High incidence of mutations in SWI-SNF complex (SMARCA4, SMARCB1, ARID1A, ARID1B)
- Important to distinguish from G3 EEC, NEC and solid serous EC:
  - Morphology
  - Lack of PAX8
  - Reduced/absent cytokeratin/EMA
  - <10% neuroendocrine marker expression

WHO 2020: Classification of EC

WHO 2014

- Endometrioid
  - Squamous differentiation
  - Villoglandular
  - Secretory
- Mucinous
- Serous endometrial intraepithelial
- Serous
- Clear cell
- Neuroendocrine
  - Low grade
  - High grade
- Mixed cell
- Undifferentiated
- Dedifferentiated

WHO 2020

- Endometrioid
  - *POLE*-ultramutated
  - Mismatch repair-deficient
  - p53-mutant
  - No specific molecular profile
- Serous
- Clear cell
- Carcinoma, undifferentiated
- Mixed cell
- **Mesonephric**
- **Squamous cell**
- **Mucinous, intestinal type**
- **Mesonephric-like**
- **Carcinosarcoma**

Mesonephric Carcinoma

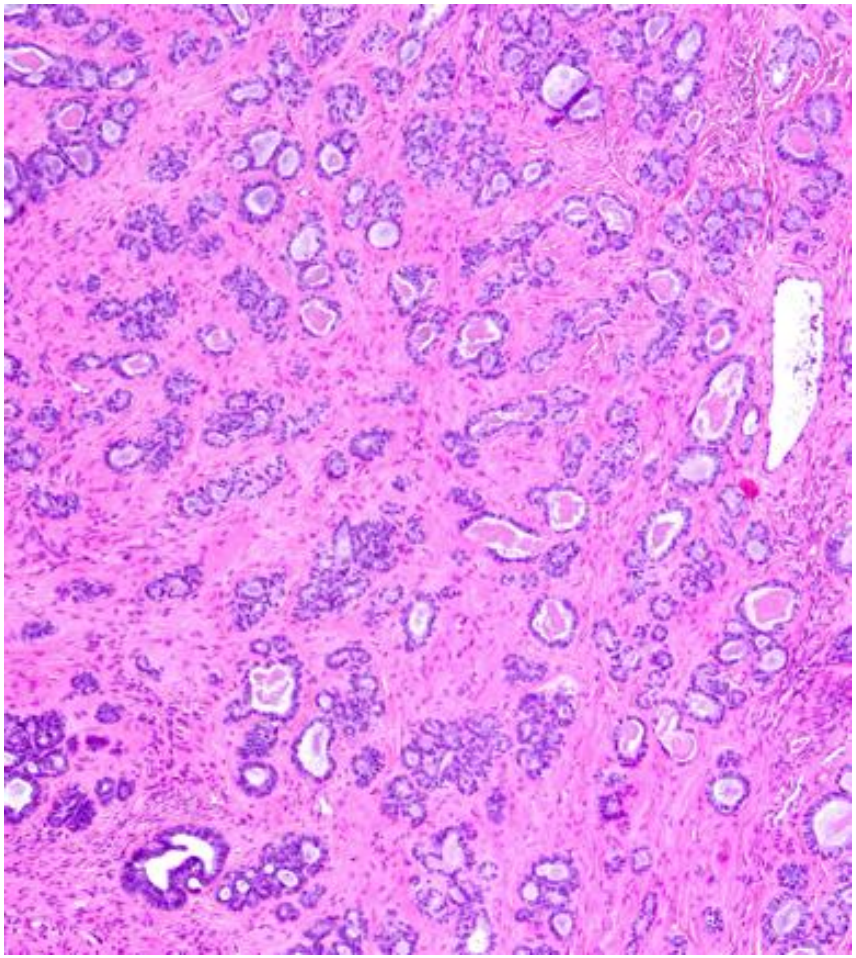

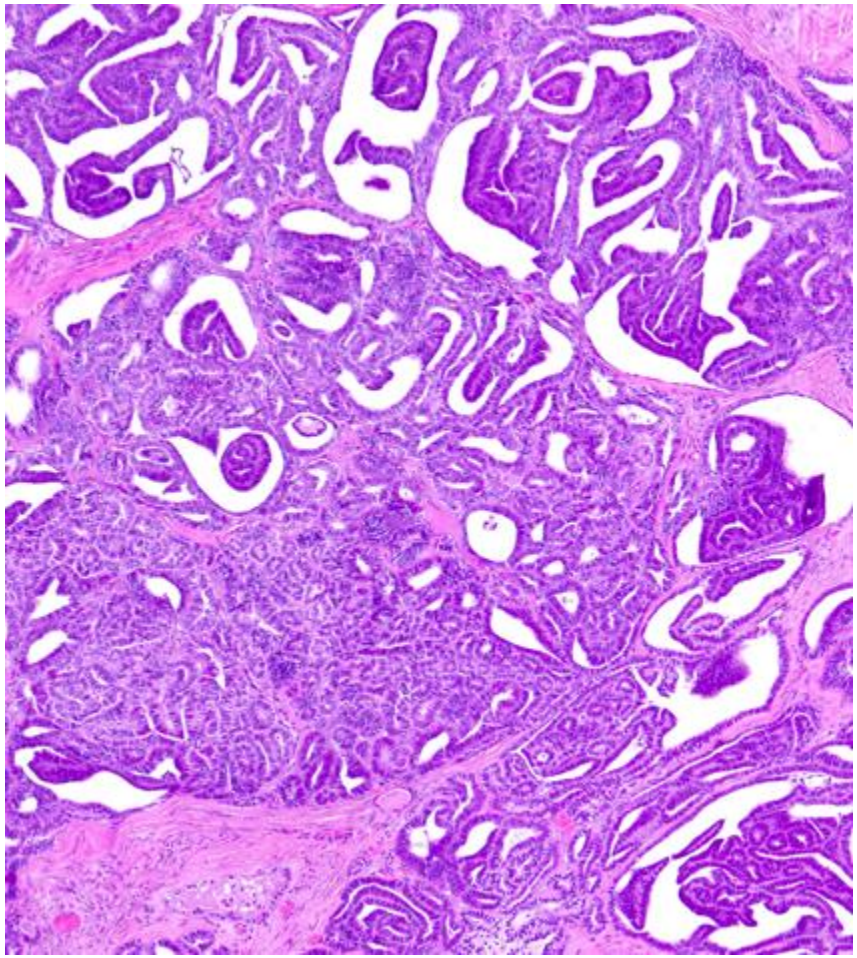

Mesonephric Carcinoma

- Arises from mesonephric remnants
- Centred on lateral wall of the uterus where these remnants occur
- Identical to cervical tumour which is commoner by far
- ER/PR negative; p53 wt, diffuse GATA3 +, luminal CD10 +, calretinin +, TTF1 + (inverse with GATA3)
- High proportion show KRAS mutations, gain of 1q; lower proportion have ARID1A mutations (all lack specificity)

Mesonephric-like Carcinoma

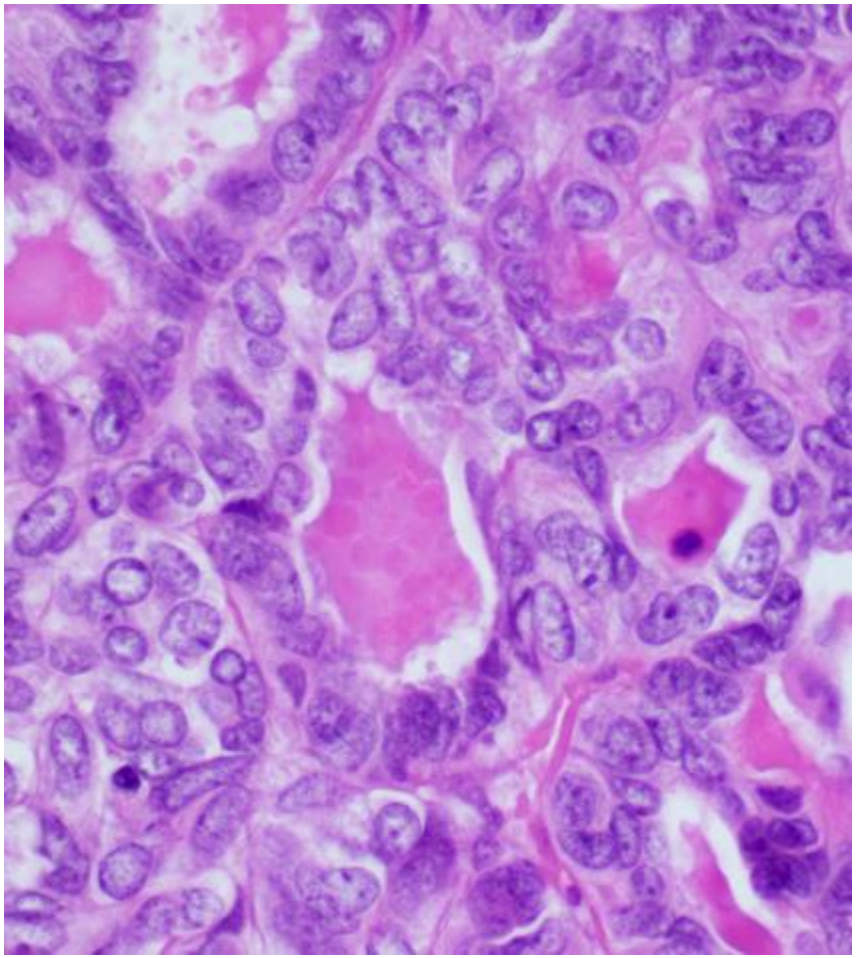

- Recently described (ovary and endometrium)
- Morphologically and immunohistochemically identical to mesonephric ca
- Differences:
  - Mucosa-based
  - Lack of mesonephric remnants
- Uncertain if mullerian or wolffian in origin; likely mesonephric diffn rather than origin
- Some molecular differences emerging: in addition to KRAS, NRAS, 1q, ARID1A, **about 50% show PIK3CA mutations not described in mesonephric ca**
- Rare (<1% EC); aggressive

Mucinous (gastro-)intestinal type carcinoma

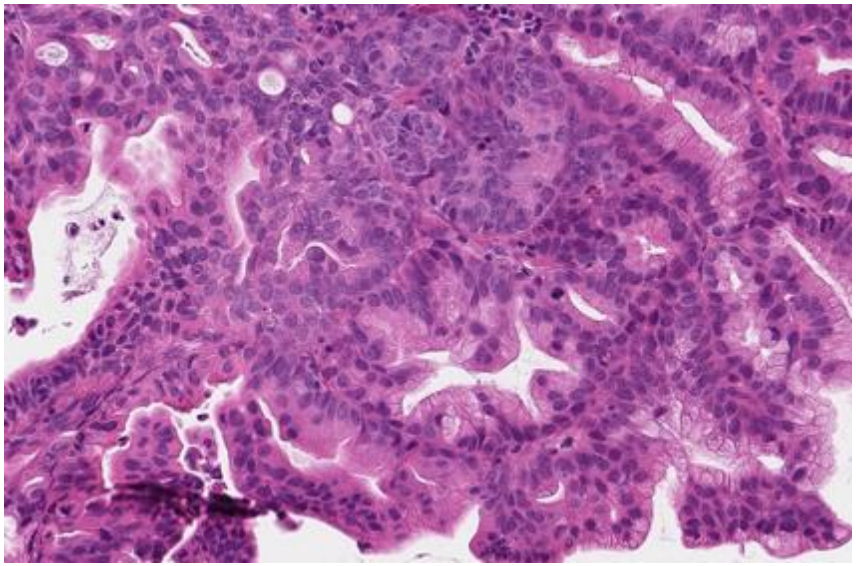

- New entity, rare
- Similar to gastric-type endocervical adenocarcinomas
- ER/PR negative; positive for gastro-intestinal type markers
- Exclude metastasis and cervical origin
- Aggressive behaviour

Squamous carcinoma

- Chronic inflammation, icthyosis uteri, pyometra, HPV, previous irradiation
- Similar to SCC at other sites
- Exclude cervical origin

Carcinosarcoma

- 5% of all uterine malignancies
- Biphasic but acknowledged to be epithelial in origin
- About 2/3rds are p53abn; <5% POLEmut or MMRd; remainder NSMP

Endometrioid carcinoma

- Grade
- Synchronous endometrial and ovarian carcinoma
- LVSI
- Subtypes

WHO 2020: Endometrioid carcinoma

- **Grade**:
  - FIGO grading as previously
  - BINARY grading recommended:
    - G1 and G2 = Low grade
    - G3 = High grade

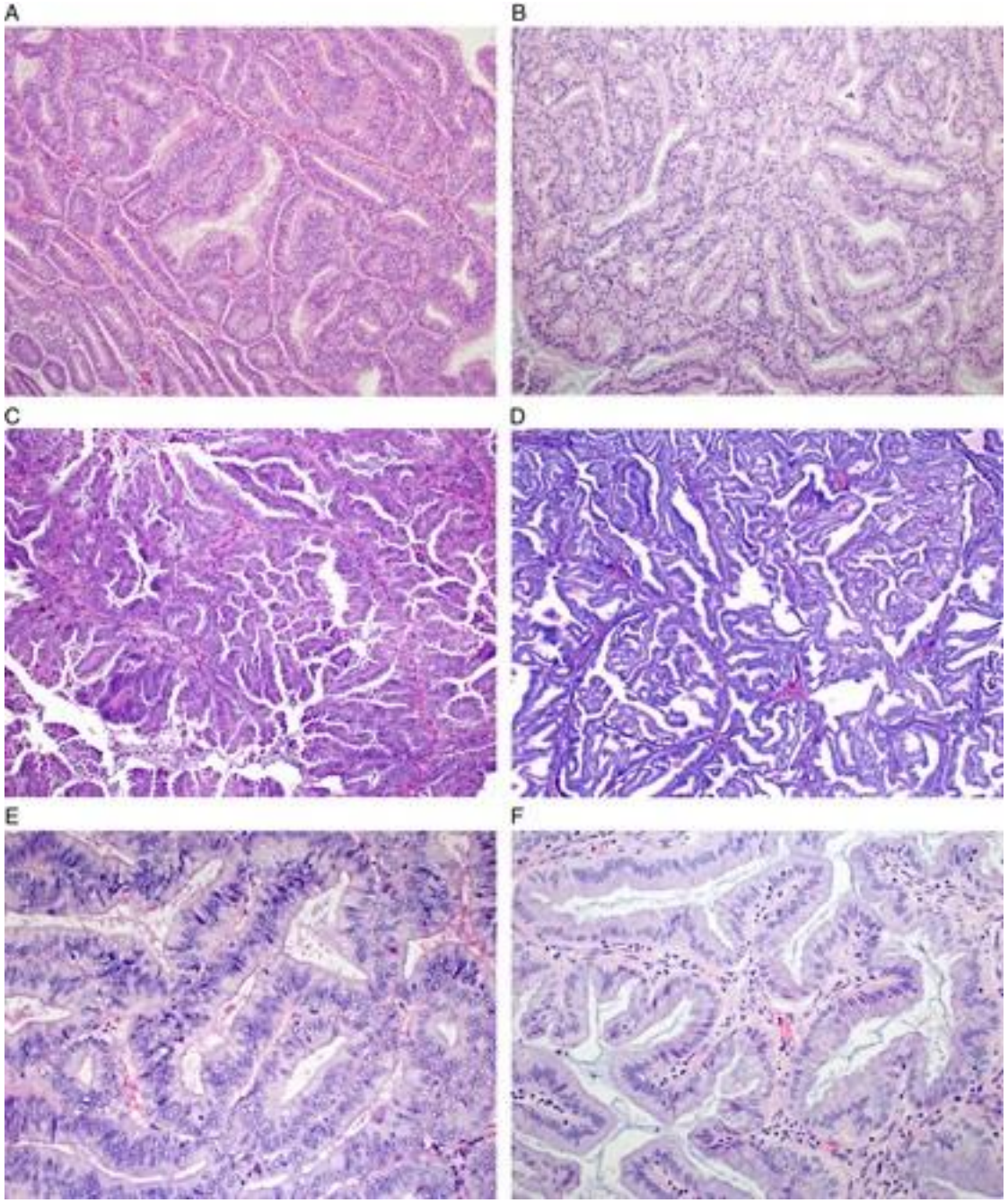

Grade 1 endometrioid carcinoma:

Confluent glandular
or
villoglandular/papillary growth pattern
AND
low nuclear grade

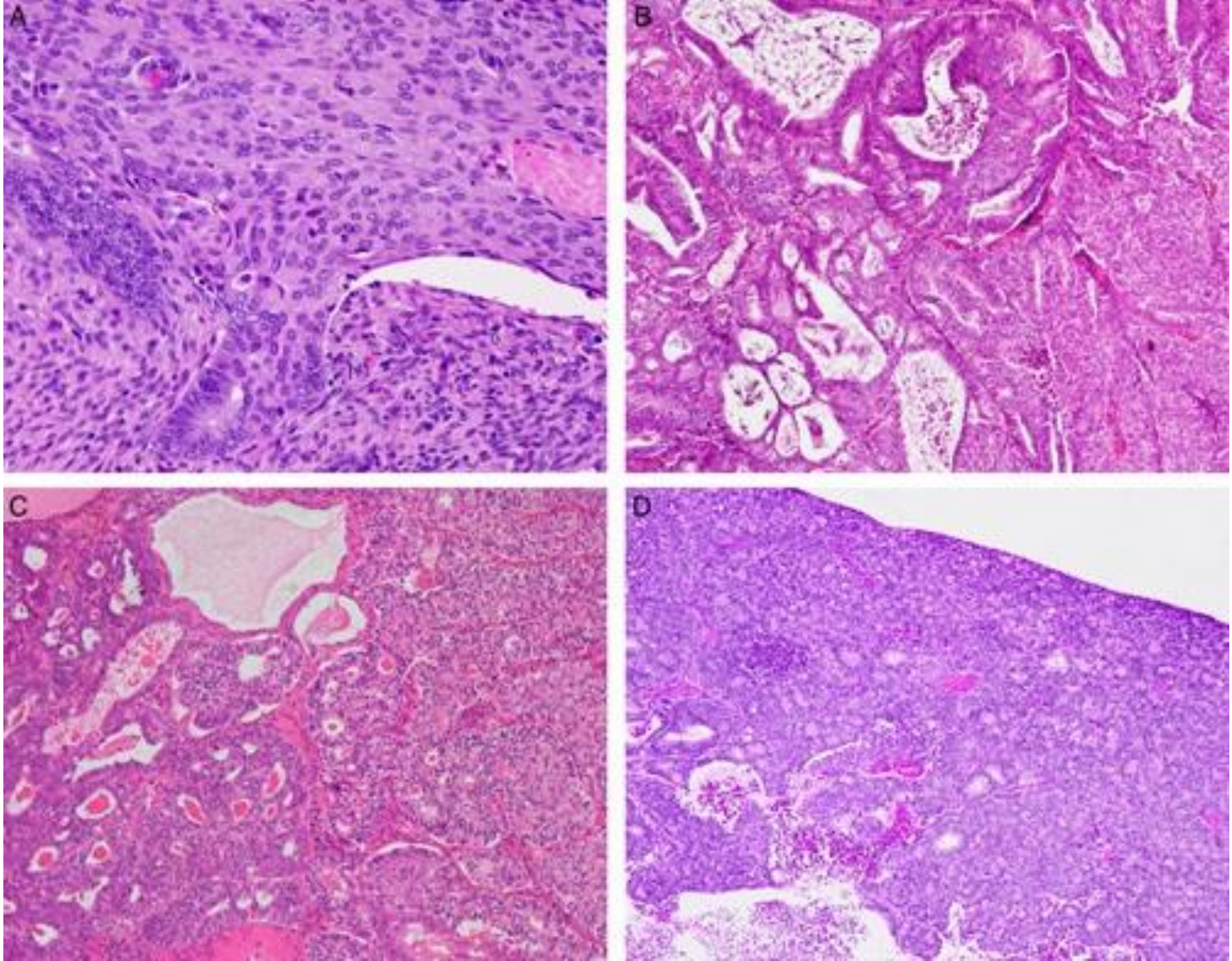
A
B
C
D

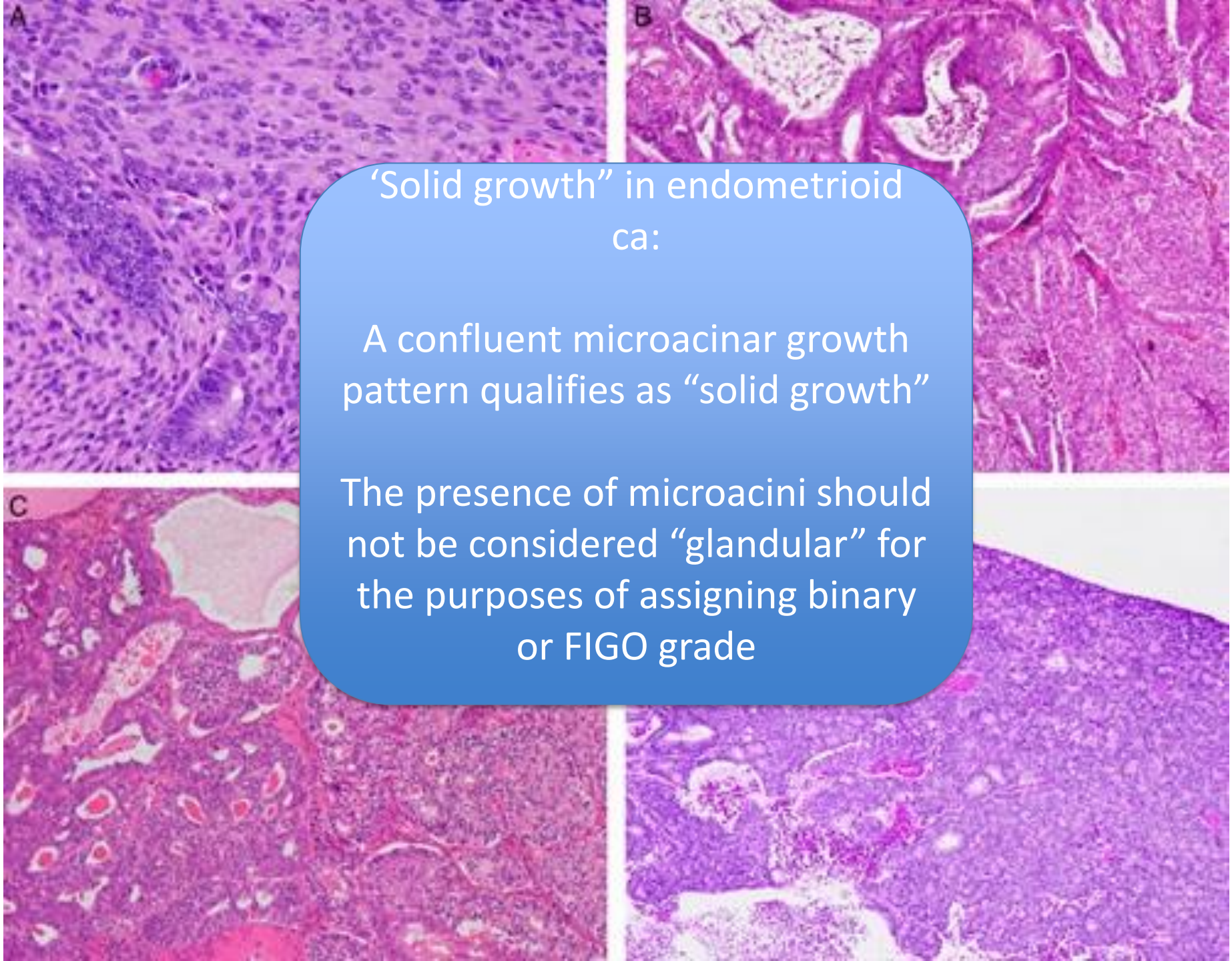

‘Solid growth” in endometrioid ca:

A confluent microacinar growth pattern qualifies as “solid growth”

The presence of microacini should not be considered “glandular” for the purposes of assigning binary or FIGO grade

WHO 2020: Endometrioid carcinoma

- **Synchronous endometrial and ovarian carcinoma**
  - Recent data demonstrate these are clonally related and therefore metastases (endometrium to ovary)
  - Although late recurrences are documented, behaviour is indolent and akin to two low-stage primaries rather than usual stage III
  - Conservative management should be considered when:
    - Both low-grade
    - No or inner myometrial invasion
    - Absence of extensive LVSI
    - No involvement of any other site
    - (Ovarian tumour stage IA - ESGO guidelines)

WHO 2020: Endometrioid carcinoma

- **Lymphovascular space invasion**
  - **Extensive/substantial LVSI defined as presence of tumour cells in ≥5 vessels**
  - **Exclude artefacts**
  - **Rare in endometrioid EC; 5-15%, associated with MELF and MMRd**

- ESGO: Focal=1; Substantial = ≥5

- Recommended approach:
  - Absent
  - Present, focal (1 vessel)
  - Present (enumerate number of foci)
  - Present, substantial (≥5 foci)

WHO 2020: Endometrioid carcinoma

- **Subtypes**
  - Morphological variants replaced by molecular types
  - Exclude mimics: Serous, clear cell, undiff/dediff, mesonephric, mesonephric-like, mucinous of gastrointestinal type
  - Morphology: relatively low nuclear grade; squamous diffn
  - ER/PR positive
  - wild type p53 (2-5% lg and 20% hg EEC are p53abn)
  - patchy (‘mosaic’) p16
  - MMRd
  - PTEN loss
  - ARID1A loss

WHO 2020: Classification of EC

WHO 2014

- Endometrioid
  - Squamous differentiation
  - Villoglandular
  - Secretory
- Mucinous
- Serous endometrial intraepithelial
- Serous
- Clear cell
- Neuroendocrine
  - Low grade
  - High grade
- Mixed cell
- Undifferentiated
- Dedifferentiated

WHO 2020

- **Endometrioid**
  - ***POLE*-ultramutated**
  - **Mismatch repair-deficient**
  - **p53-mutant**
  - **No specific molecular profile**
- Serous
- Clear cell
- Carcinoma, undifferentiated
- Mixed cell
- Mesonephric
- Squamous cell
- Mucinous, intestinal type
- Mesonephric-like
- Carcinosarcoma

Molecular clusters of EC

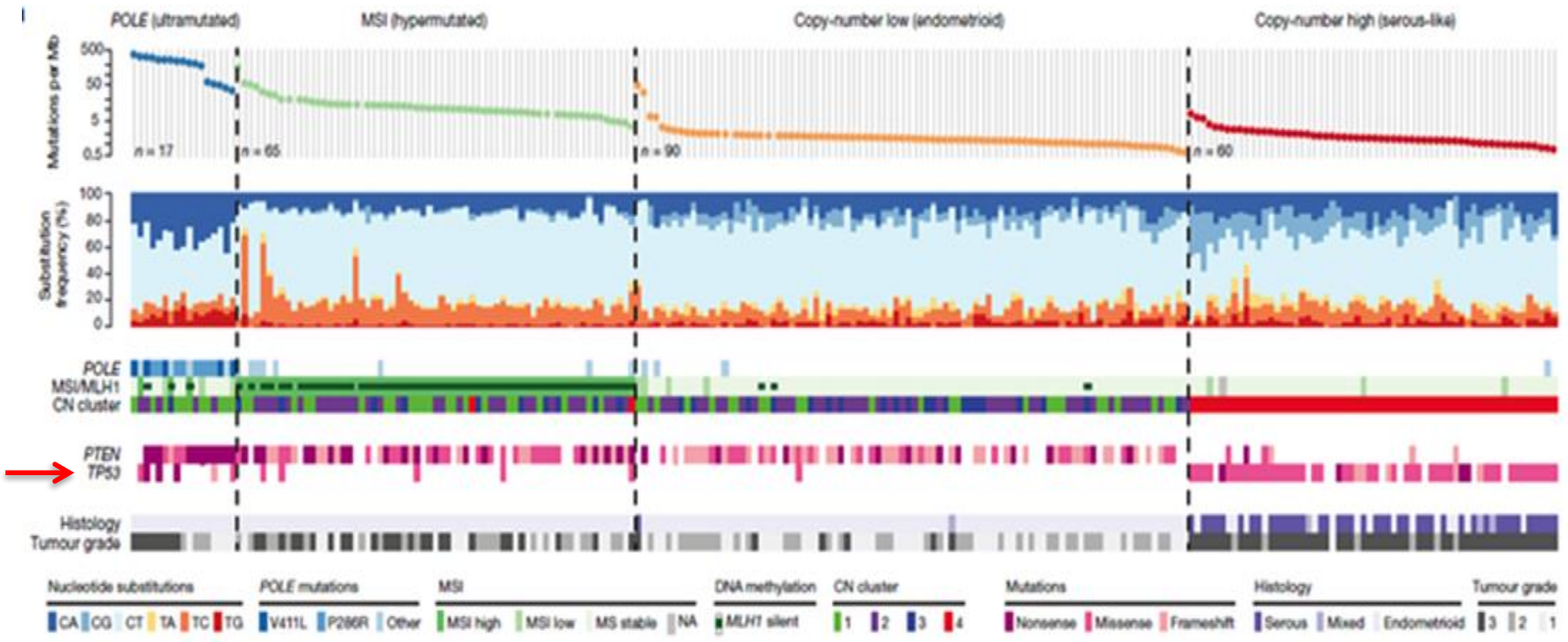

TCGA, Nature 2013

Endometrial cancer: Molecular groups

- 4 distinct groups:
  - **POLE (ultramutated)**
  - **MSI (hypermutated)**
  - **Copy-number low (endometrioid)**
  - **Copy-number high (serous-like)**

TCGA, Nature 2013

Endometrial carcinoma: Molecular classification strategies, ProMisE

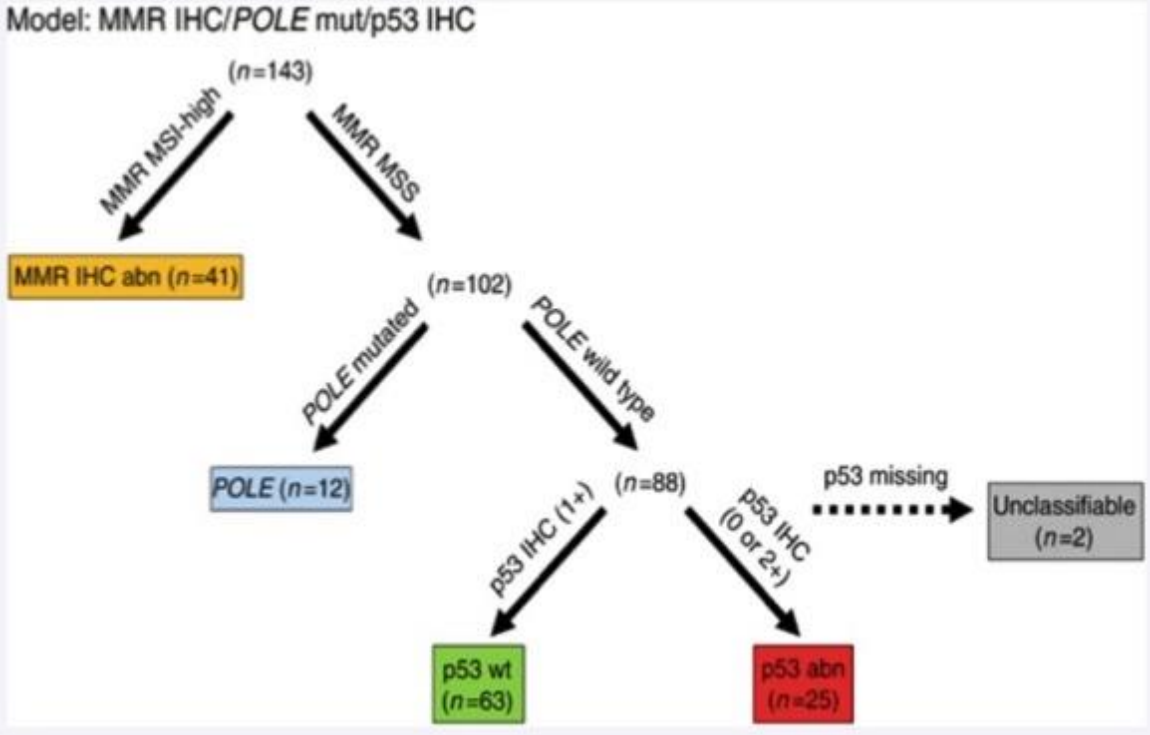

- 3 tests are sufficient for translating TCGA clusters into routine diagnostic practice: MMR IHC, p53 IHC, POLE sequencing
- Further refinement of algorithm:
  - Pathogenic POLE mutants defined
  - Behaviour of 'multiple classifiers' (3% EC) studied

British Journal of Cancer **113**, 299-310.

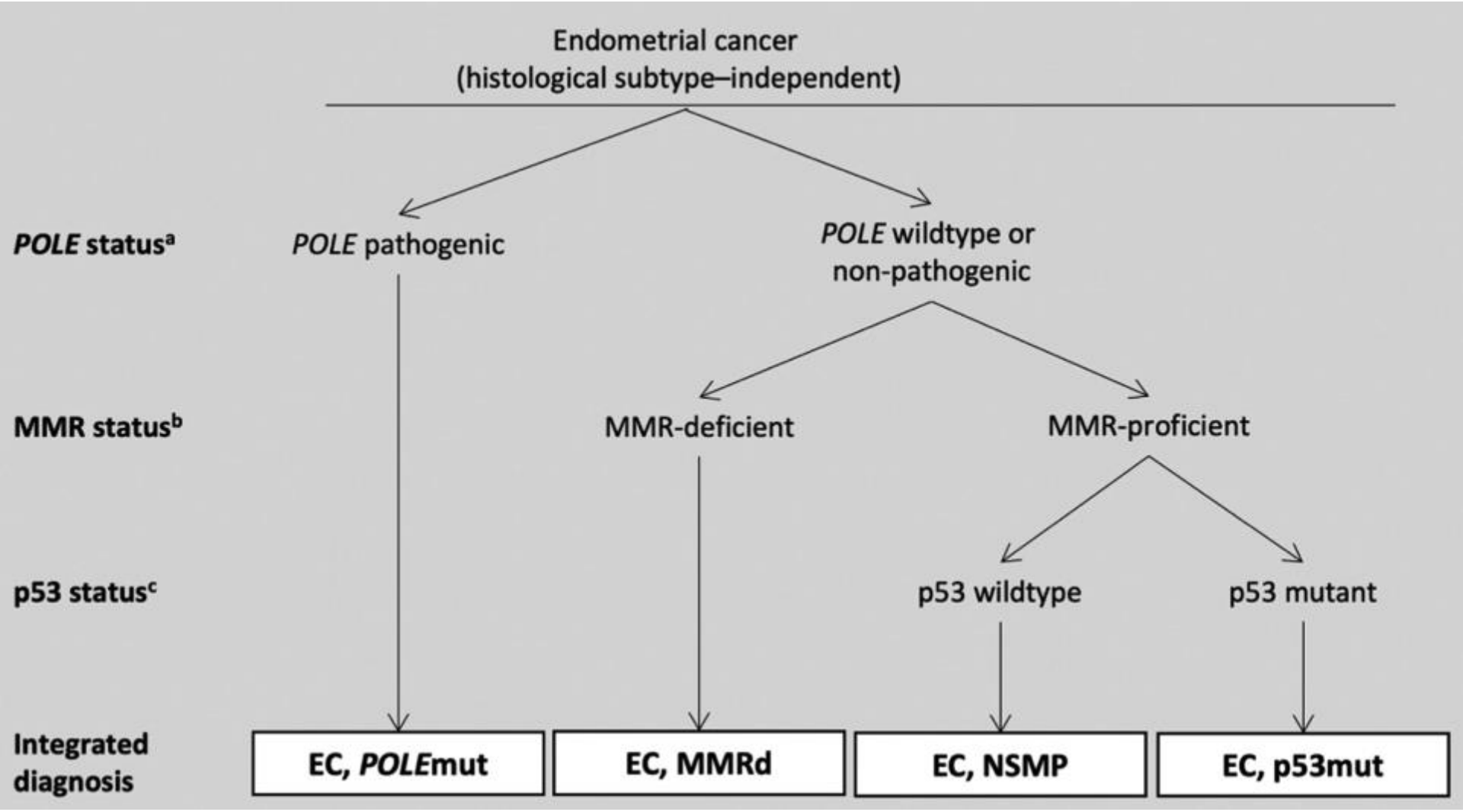
Endometrial cancer
(histological subtype–independent)
POLE status[a]
POLE pathogenic
POLE wildtype or
non-pathogenic
MMR status[b]
MMR-deficient
MMR-proficient
p53 status[c]
p53 wildtype
p53 mutant
Integrated
diagnosis
EC, POLEmut
EC, MMRd
EC, NSMP
EC, p53mut

Molecular testing in EC: Rationale

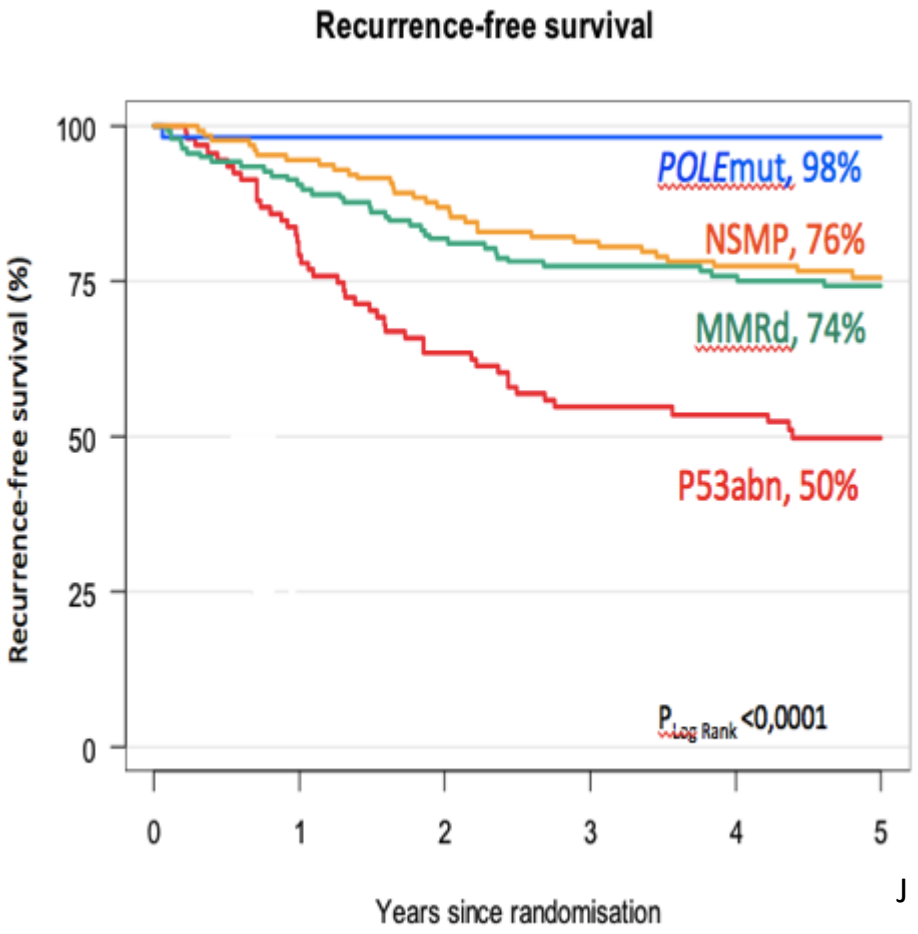

Molecular classification is PROGNOSTIC

J Clin Oncol 2020 38:29, 3388.

PORTEC-3, HREC cohort

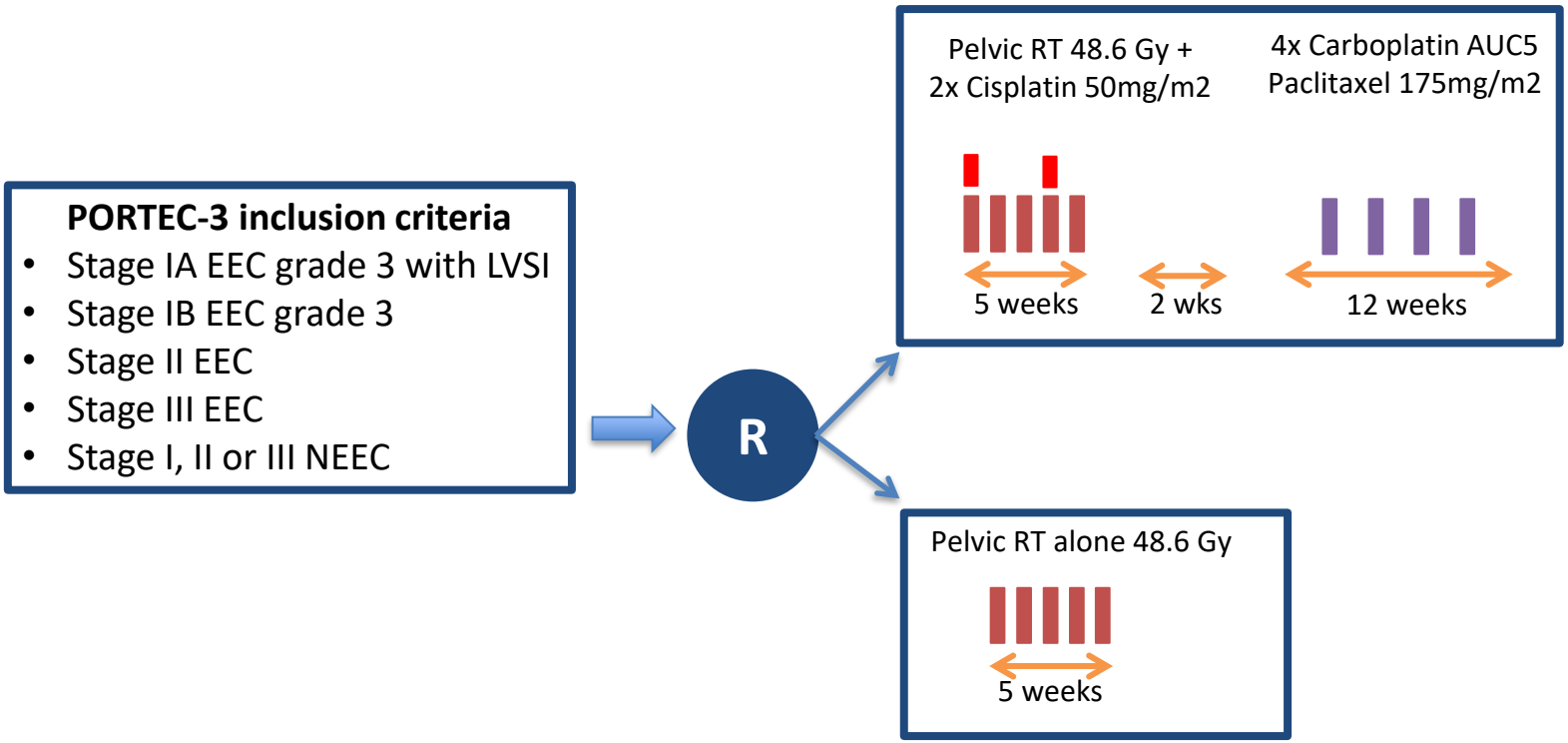

*De Boer et al; Lancet Oncology 2019.

Molecular subgroups of high-risk EC (PORTEC-3, n=410)

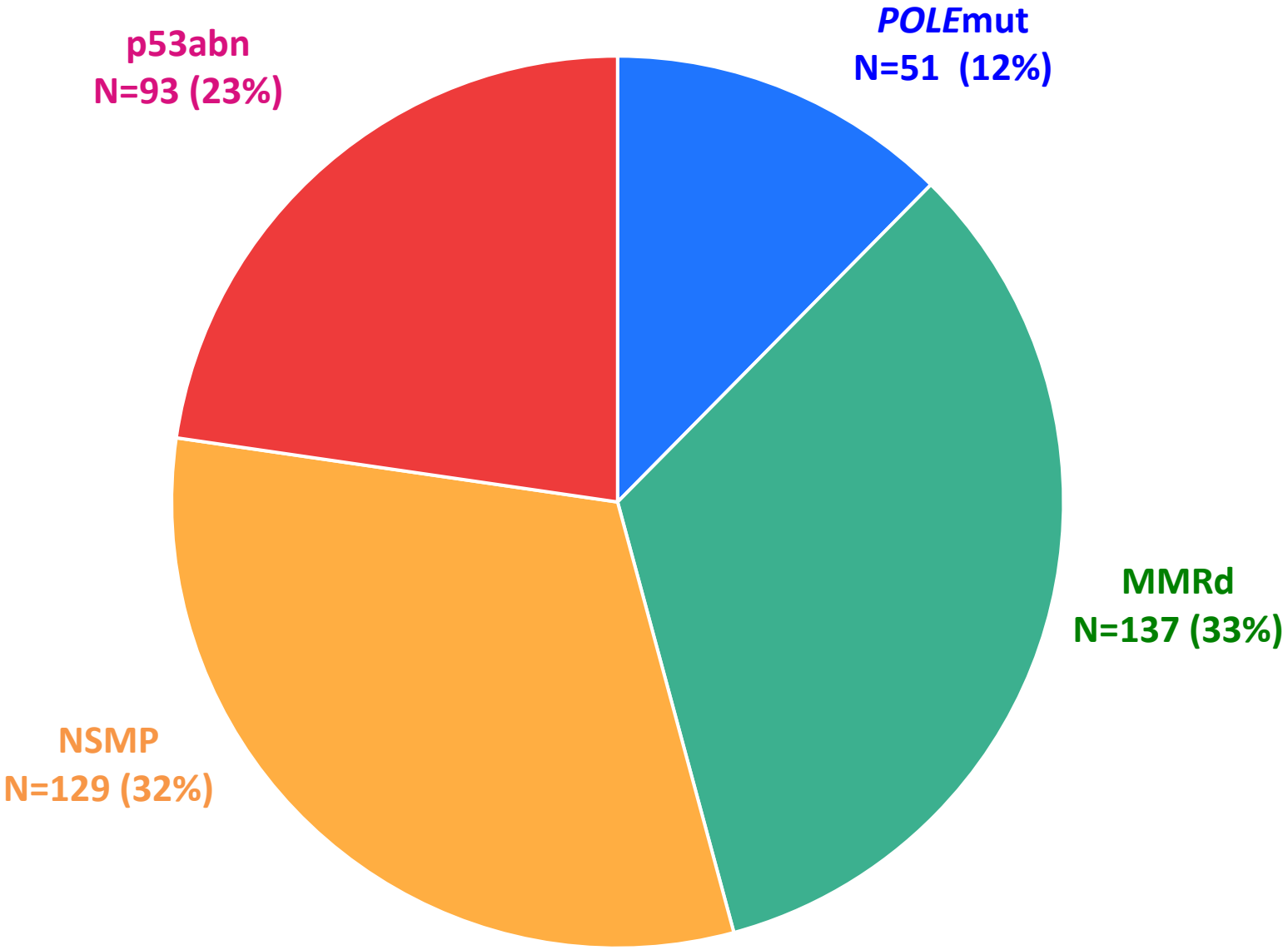

HREC outcomes

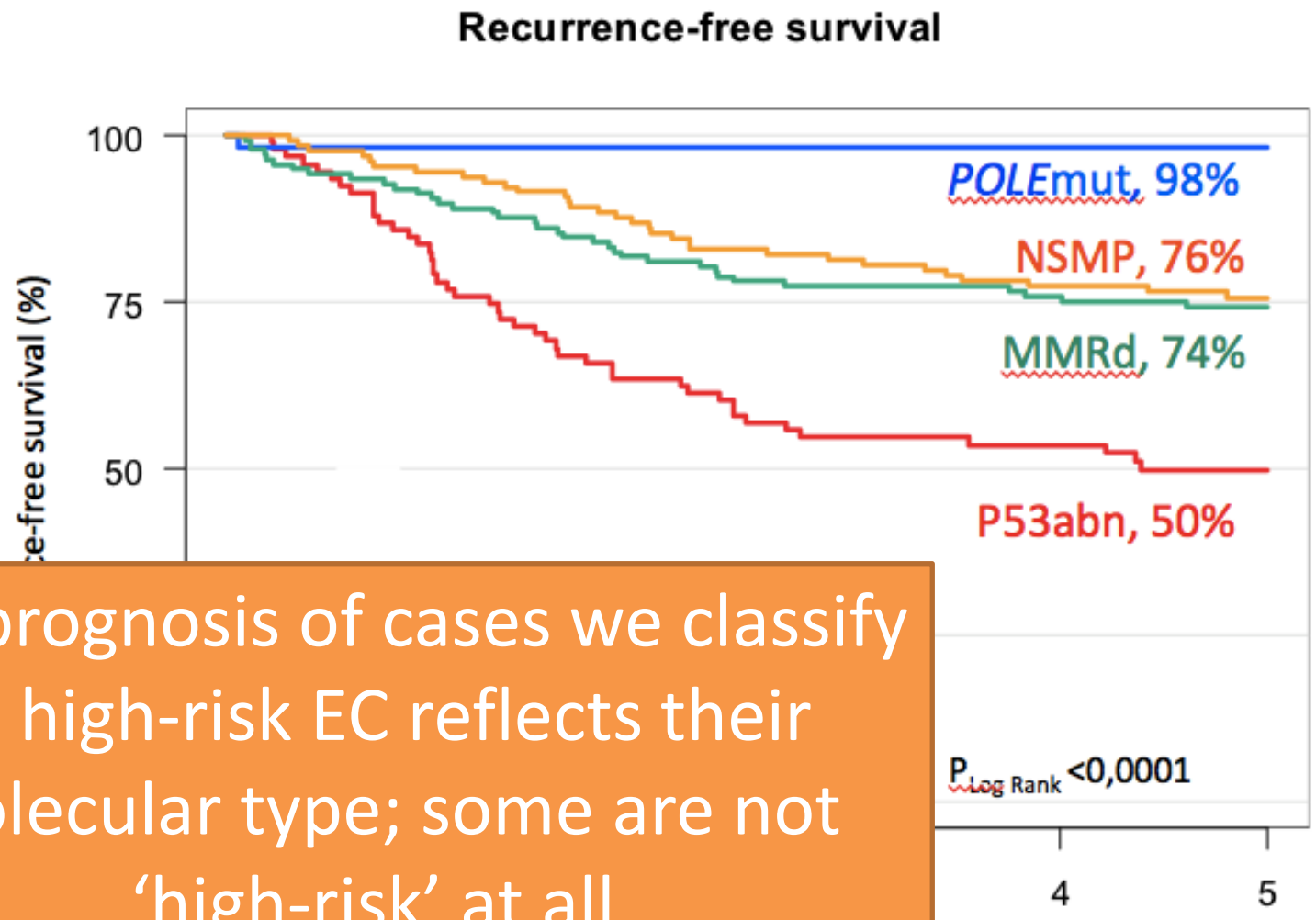

The prognosis of cases we classify as high-risk EC reflects their molecular type; some are not 'high-risk' at all

Histotype distribution in p53abn EC

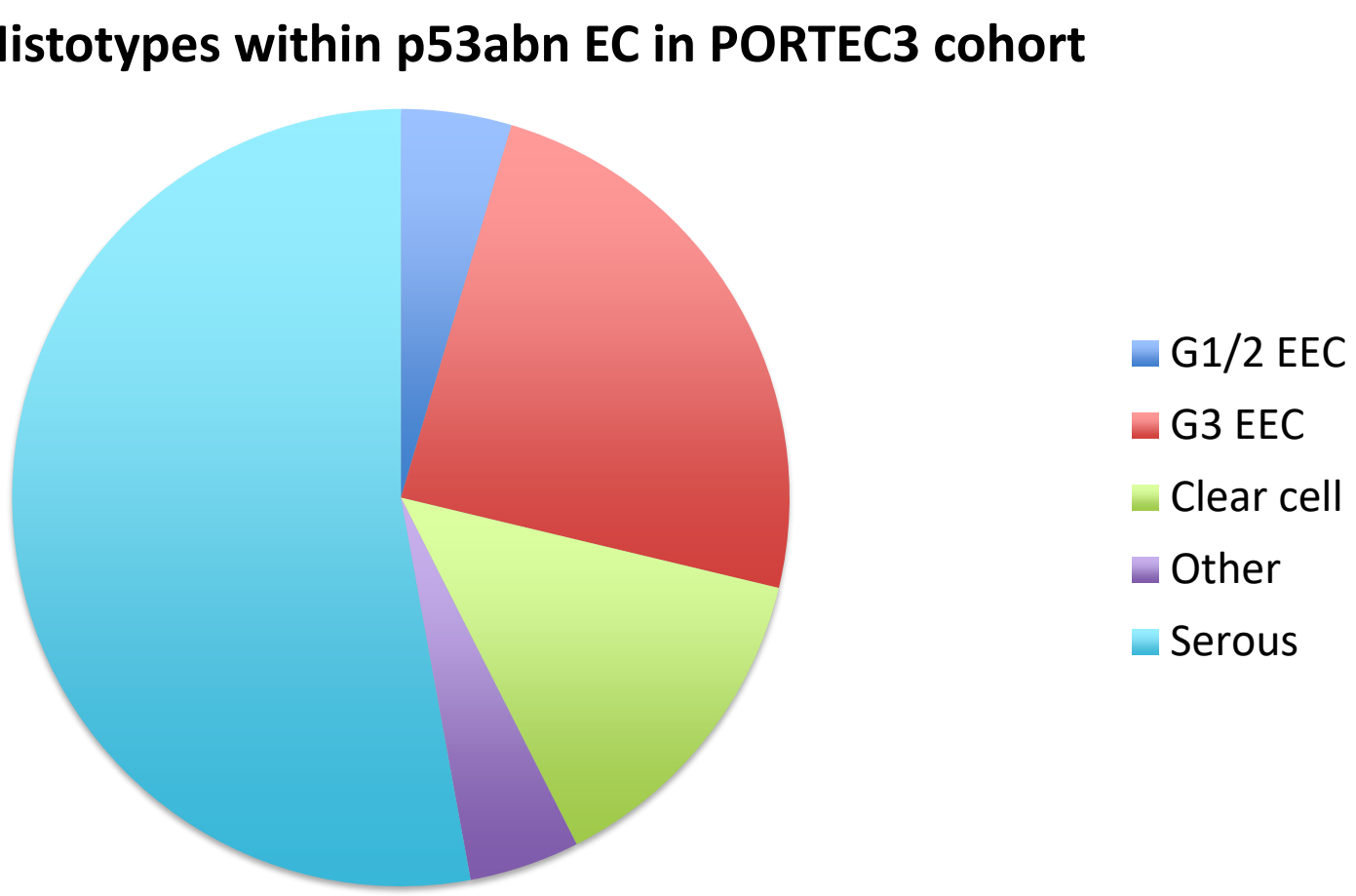

Molecular classes of EC are different diseases

	POLEmut EC	MMRd EC	NSMP EC	P53abn EC
Proportion of all EC	9%	28%	50%	12%
Clinical features	Relatively young; no association with metabolic syndromes	Wide age range; no association with metabolic syndromes	Wide age range; strong association with BMI and hyperoestrogenic states	Elderly; no association with metabolic syndromes
Hereditary susceptibility	Rare	10% hereditary	Rare	Association with BRCA1/BRCA2 hereditary syndromes (weak)
Stage at presentation	Generally low-stage, LVSI frequently observed	Greater likelihood of high-stage and presence of substantial LVSI	Generally low-stage	Potential for high-stage, LVSI and also peritoneal spread in absence of invasion into myometrium

ESGO-ESP-ESTRO Guidelines for EC management

- Acknowledge importance of molecular classification
- Provide guidance for clinical management with and without molecular classification

Concin N, et al. Int J Gynecol Cancer 2020;0:12–39. doi:10.1136/ijgc-2020-002230

Table 2 Definition of prognostic risk groups

Risk group	Molecular classification unknown
Low	▶ Stage IA endometrioid + low-grade‡ + LVSI negative or focal
Intermediate	▶ Stage IB endometrioid + low-grade‡ + LVSI negative or focal ▶ Stage IA endometrioid + high-grade‡ + LVSI negative or focal ▶ Stage IA non-endometrioid (serous, clear cell, undifferentiared carcinoma, carcinosarcoma, mixed) without myometrial invasion
High–intermediate	▶ Stage I endometrioid + substantial LVSI regardless of grade and depth of invasion ▶ Stage IB endometrioid high-grade‡ regardless of LVSI status ▶ Stage II
High	▶ Stage III–IVA with no residual disease ▶ Stage I–IVA non-endometrioid (serous, clear cell, undifferentiated carcinoma, carcinosarcoma, mixed) with myometrial invasion, and with no residual disease
Advanced metastatic	▶ Stage III–IVA with residual disease ▶ Stage IVB

Summary of Adjuvant Rx recommendations (ESGO 2020)

Risk Category	Adjuvant Rx
Low	• No adjuvant Rx
Intermediate	• Brachytherapy can be recommended to decrease vaginal recurrence • Omission of brachytherapy can be considered especially <60 years age
High-intermediate, N0	• Brachytherapy can be recommended to decrease vaginal recurrence • EBRT can be considered for substantial LVSI and/or stage II • Omission of any adjuvant Rx is an option
High-intermediate, nodal status unknown	• Adjuvant EBRT is recommended, especially if substantial LVSI and/or stage II • Additional adjuvant chemo can be considered especially for hg and/or substantial LVSI • Adjuvant brachytherapy alone can be considered for hg, LVSI negative and stage II G1 endometrioid
High	• EBRT with concurrent/sequential chemo OR chemo alone

Table 2 Definition of prognostic risk groups

Risk group	Molecular classification unknown	Molecular classification known*†
Low	► Stage IA endometrioid + low-grade‡ + LVSI negative or focal	► Stage I–II ***POLEmut*** endometrial carcinoma, no residual disease ► Stage IA **MMRd/NSMP** endometrioid carcinoma + low-grade‡ + LVSI negative or focal
Intermediate	► Stage IB endometrioid + low-grade‡ + LVSI negative or focal ► Stage IA endometrioid + high-grade‡ + LVSI negative or focal ► Stage IA non-endometrioid (serous, clear cell, undifferentiared carcinoma, carcinosarcoma, mixed) without myometrial invasion	► Stage IB **MMRd/NSMP** endometrioid carcinoma + low-grade‡ + LVSI negative or focal ► Stage IA **MMRd/NSMP** endometrioid carcinoma + high-grade‡ + LVSI negative or focal ► Stage IA **p53abn** and/or non-endometrioid (serous, clear cell, undifferentiated carcinoma, carcinosarcoma, mixed) without myometrial invasion
High–intermediate	► Stage I endometrioid + substantial LVSI regardless of grade and depth of invasion ► Stage IB endometrioid high-grade‡ regardless of LVSI status ► Stage II	► Stage I **MMRd/NSMP** endometrioid carcinoma + substantial LVSI regardless of grade and depth of invasion ► Stage IB **MMRd/NSMP** endometrioid carcinoma high-grade‡ regardless of LVSI status ► Stage II **MMRd/NSMP** endometrioid carcinoma
High	► Stage III–IVA with no residual disease ► Stage I–IVA non-endometrioid (serous, clear cell, undifferentiated carcinoma, carcinosarcoma, mixed) with myometrial invasion, and with no residual disease	► Stage III–IVA **MMRd/NSMP** endometrioid carcinoma with no residual disease ► Stage I–IVA **p53abn** endometrial carcinoma with myometrial invasion, with no residual disease ► Stage I–IVA **NSMP/MMRd** serous, undifferentiated carcinoma, carcinosarcoma with myometrial invasion, with no residual disease
Advanced metastatic	► Stage III–IVA with residual disease ► Stage IVB	► Stage III–IVA with residual disease of any molecular type ► Stage IVB of any molecular type

Table 2 Definition of prognostic risk groups

Risk group	Molecular classification unknown	Molecular classification known*†
Low	► Stage IA endometrioid + low-grade‡ + LVSI negative or focal	► Stage I–II ***POLEmut*** endometrial carcinoma, no residual disease ► Stage IA **MMRd/NSMP** endometrioid carcinoma + low-grade‡ + LVSI negative or focal
Intermediate	► Stage IB endometrioid + low-grade‡ + LVSI negative or focal ► Stage IA endometrioid + high-grade‡ + LVSI negative or focal ► Stage IA non-endometrioid (serous, clear cell, undifferentiared carcinoma, carcinosarcoma, mixed) without invasion	► Stage IB **MMRd/NSMP** endometrioid carcinoma + low-grade‡ + LVSI negative or focal ► Stage IA **MMRd/NSMP** endometrioid carcinoma + high-grade‡ + LVSI negative or focal ► Stage IA **p53abn** and/or non-endometrioid
High–intermediate	► Stage I endometrioid + subst regardless of grade and depth ► Stage IB endometrioid high-g regardless of LVSI status ► Stage II	
High	► Stage III–IVA with no residual ► Stage I–IVA non-endometrioi clear cell, undifferentiated carci carcinosarcoma, mixed) with m invasion, and with no residual d	► Stage I–IVA **NSMP/MMRd** serous, undifferentiated carcinoma, carcinosarcoma with myometrial invasion, with no residual disease
Advanced metastatic	► Stage III–IVA with residual disease ► Stage IVB	► Stage III–IVA with residual disease of any molecular type ► Stage IVB of any molecular type

IMPACT OF KNOWING POLE STATUS:

- POLEmut EC accounts for about 12% of HREC
- Omission of any adjuvant treatment should be considered in stages I-II
- For the rare cases of POLEmut stage III-IVA there are no outcome data to support omission of adjuvant treatment; prospective registration is recommended

Table 2 Definition of prognostic risk groups

Risk group	Molecular classification unknown	Molecular classification known*†
Low	► Stage IA endometrioid + low-grade‡ + LVSI negative or focal	► Stage I–II ***POLEmut*** endometrial carcinoma,
Intermediate	► Stage IB endometrioid + low-g LVSI negative or focal ► Stage IA endometrioid + high-grade‡ + LVSI negative or focal ► Stage IA non-endometrioid (serous, clear cell, undifferentiared carcinoma, carcinosarcoma, mixed) without myometrial invasion	► Stage IA **MMRd/NSMP** endometrioid carcinoma + high-grade‡ + LVSI negative or focal ► Stage IA **p53abn** and/or non-endometrioid (serous, clear cell, undifferentiated carcinoma, carcinosarcoma, mixed) without myometrial invasion
High–intermediate	► Stage I endometrioid + substantial LVSI regardless of grade and depth of invasion ► Stage IB endometrioid high-grade‡ regardless of LVSI status ► Stage II	► Stage I **MMRd/NSMP** endometrioid carcinoma + substantial LVSI regardless of grade and depth of invasion ► Stage IB **MMRd/NSMP** endometrioid carcinoma high-grade‡ regardless of LVSI status ► Stage II **MMRd/NSMP** endometrioid carcinoma
High	► Stage III–IVA with no residual disease ► Stage I–IVA non-endometrioid (serous, clear cell, undifferentiated carcinoma, carcinosarcoma, mixed) with myometrial invasion, and with no residual disease	► Stage III–IVA **MMRd/NSMP** endometrioid carcinoma with no residual disease ► Stage I–IVA **p53abn** endometrial carcinoma with myometrial invasion, with no residual disease ► Stage I–IVA **NSMP/MMRd** serous, undifferentiated carcinoma, carcinosarcoma with myometrial invasion, with no residual disease
Advanced metastatic	► Stage III–IVA with residual disease ► Stage IVB	► Stage III–IVA with residual disease of any molecular type ► Stage IVB of any molecular type

IMPACT OF KNOWING p53 STATUS:
2-5% of low-grade and 20% high grade endometrioid EC are p53abn

Molecular type does not equate to morphological types!

- Endometrioid
- Serous
- Clear cell
- Carcinoma, undifferentiated
- Mixed cell
- Carcinosarcoma

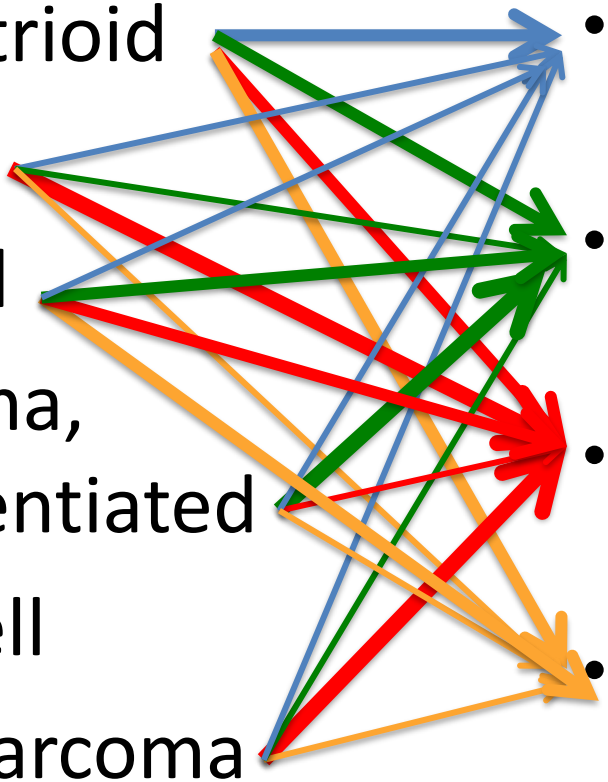

- *POLE*-ultramutated
- Mismatch repair-deficient
- p53-mutant
- No specific molecular profile

EC: Molecular testing

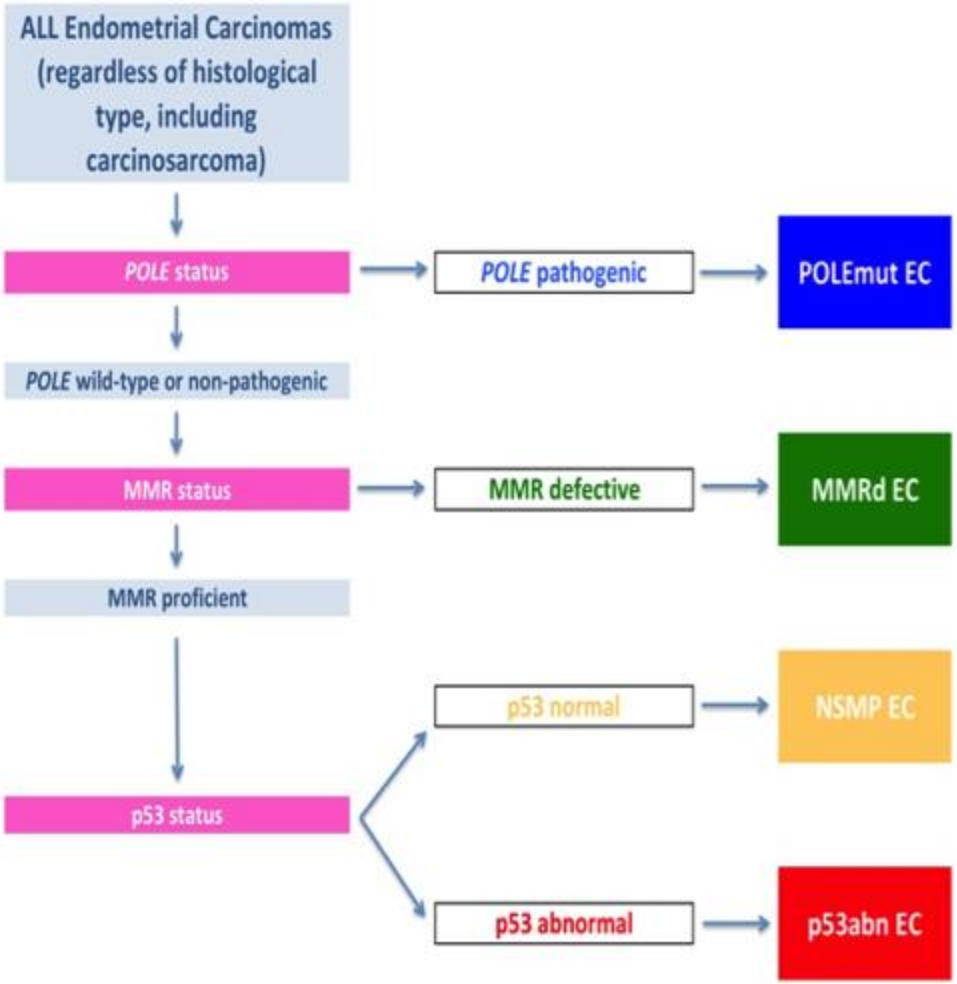

"Integration of microscopic features with molecular characteristics is the best approach to stratify patients to predict prognosis in regions with resources available to incorporate such techniques."



EC: Molecular testing

- Most laboratories in UK do not have *POLE* testing facility
- *POLE* testing not included in current national genomics directory
- BAGP application for inclusion of *POLE* testing in EC is being prepared

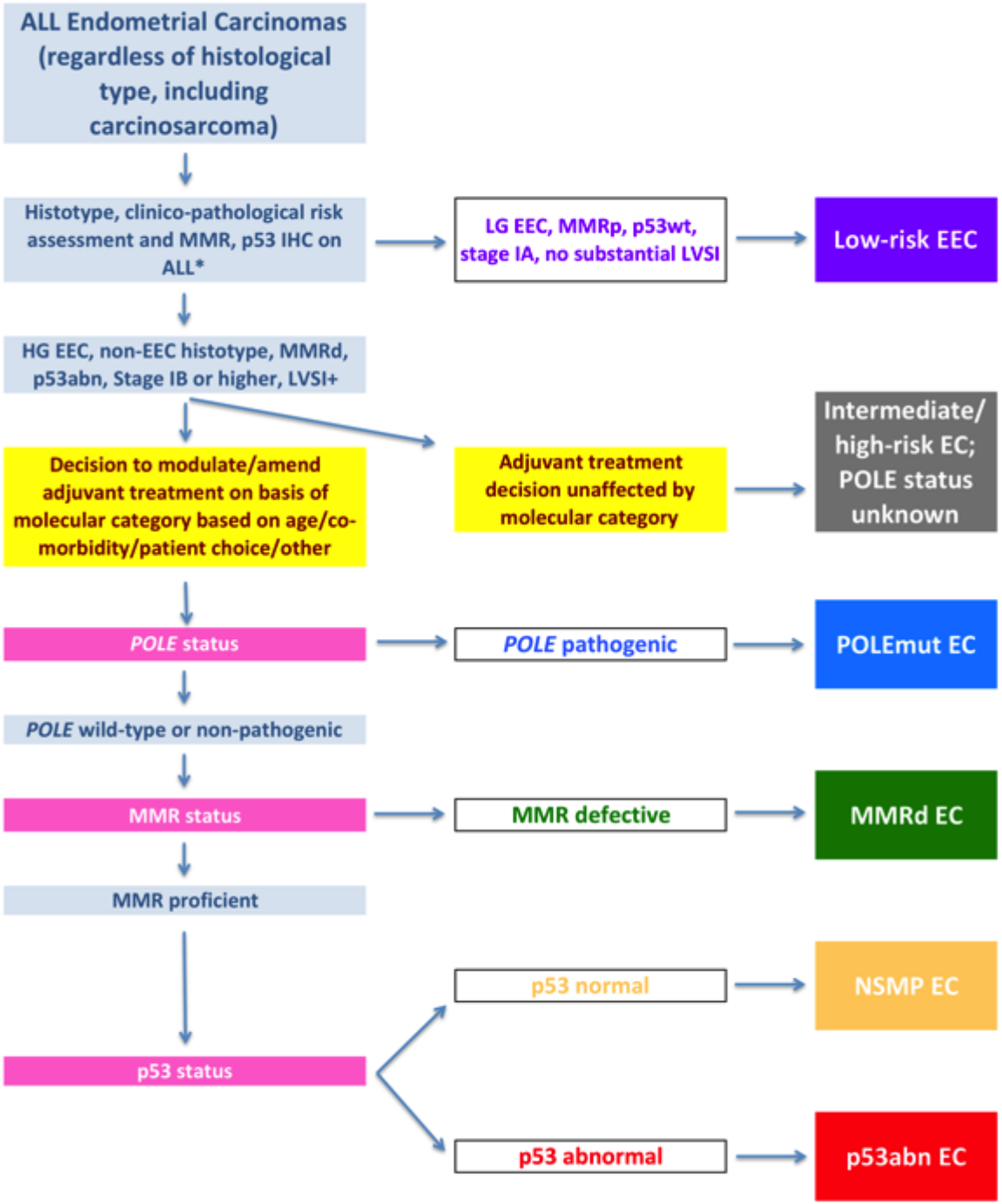
ALL Endometrial Carcinomas (regardless of histological type, including carcinosarcoma)
Histotype, clinico-pathological risk assessment and MMR, p53 IHC on ALL*
LG EEC, MMRp, p53wt, stage IA, no substantial LVSI
Low-risk EEC
HG EEC, non-EEC histotype, MMRd, p53abn, Stage IB or higher, LVSI+
Decision to modulate/amend adjuvant treatment on basis of molecular category based on age/co-morbidity/patient choice/other
Adjuvant treatment decision unaffected by molecular category
Intermediate/ high-risk EC; POLE status unknown
POLE status
POLE pathogenic
POLEmut EC
POLE wild-type or non-pathogenic
MMR status
MMR defective
MMRd EC
MMR proficient
p53 status
p53 normal
NSMP EC
p53 abnormal
p53abn EC

EC: Molecular testing

- While we are in transition phase:
  - UNIVERSAL MMR IHC (NICE, other indications)
  - UNIVERSAL (if not then very low threshold at least) p53 IHC
    - Low proportion of G1-2 EEC are p53 abn
    - p53abn includes all histotypes
    - *Note: low number of cases with TP53 mutations (c2%) show wild type p53 IHC*
  - ER IHC if unusual morphology
    - New entities: Intestinal, mesonephric, mesonephric-like
    - Hormonal therapies/HRT

EC: Molecular testing

- If p53 or MMR IHC is abnormal, include molecular category in diagnosis
- If EC with ‘serous’-like morphology is MMRd (or POLEmut), classify as ENDOMETRIOID
- Use ‘mixed’ cell category when there are two discrete components, one of which is serous or clear cell
- ESGO guidance is new; there are only exceptional cases where POLE status will change current management

NICE recommendations (2020)

1. Offer testing for Lynch syndrome to people who are diagnosed with endometrial cancer. Use immunohistochemistry (IHC) to identify tumours with mismatch repair (MMR) deficiency:
    - If IHC is abnormal with loss of MLH1, or loss of both MLH1 and PMS2 protein expression, do MLH1 promoter hypermethylation testing of tumour DNA. If MLH1 promoter hypermethylation is not detected, offer germline genetic testing to confirm Lynch syndrome.
    - If IHC is abnormal with loss of MSH2, MSH6 or isolated PMS2 protein expression, offer germline genetic testing to confirm Lynch syndrome.

1. Healthcare professionals should inform people about the possible implications of test results for both themselves and their relatives, and give support and information. Discussion of genetic testing and obtaining consent should be done by a healthcare professional with appropriate training.

1. Laboratories doing IHC for MMR proteins, MLH1 promoter hypermethylation testing or germline genetic testing should take part in a recognised external quality assurance programme.

Implementation

- Reflex MMR IHC testing on all EC (consent not required) – *no additional funding*
- MLH1 promoter methylation (for those with MLH1 loss): To be carried out at NHSE Genomic Laboratory Hubs (GLH)
- Screen-positive cases undergo referral to Clinical Genetics Services for genetic counseling and informed consent
- Germline genetic testing at GLH of patient wishes to proceed

Benefits of MMR testing

- Lynch Syndrome screening
- Prognostic (molecular classification)
- Predictive (immune checkpoint inhibition)
- Diagnostic: supports categorisation as endometrioid in cases with ambiguous/serous-like moprhology
- Fertility-sparing treatment is not recommended in women with genetic risk factors (ESGO 2020)

BRITISH GYNAECOLOGICAL CANCER SOCIETY

The British Association of Gynaecological Pathologist

The Royal College of Pathologists
Pathology: the science behind the cure

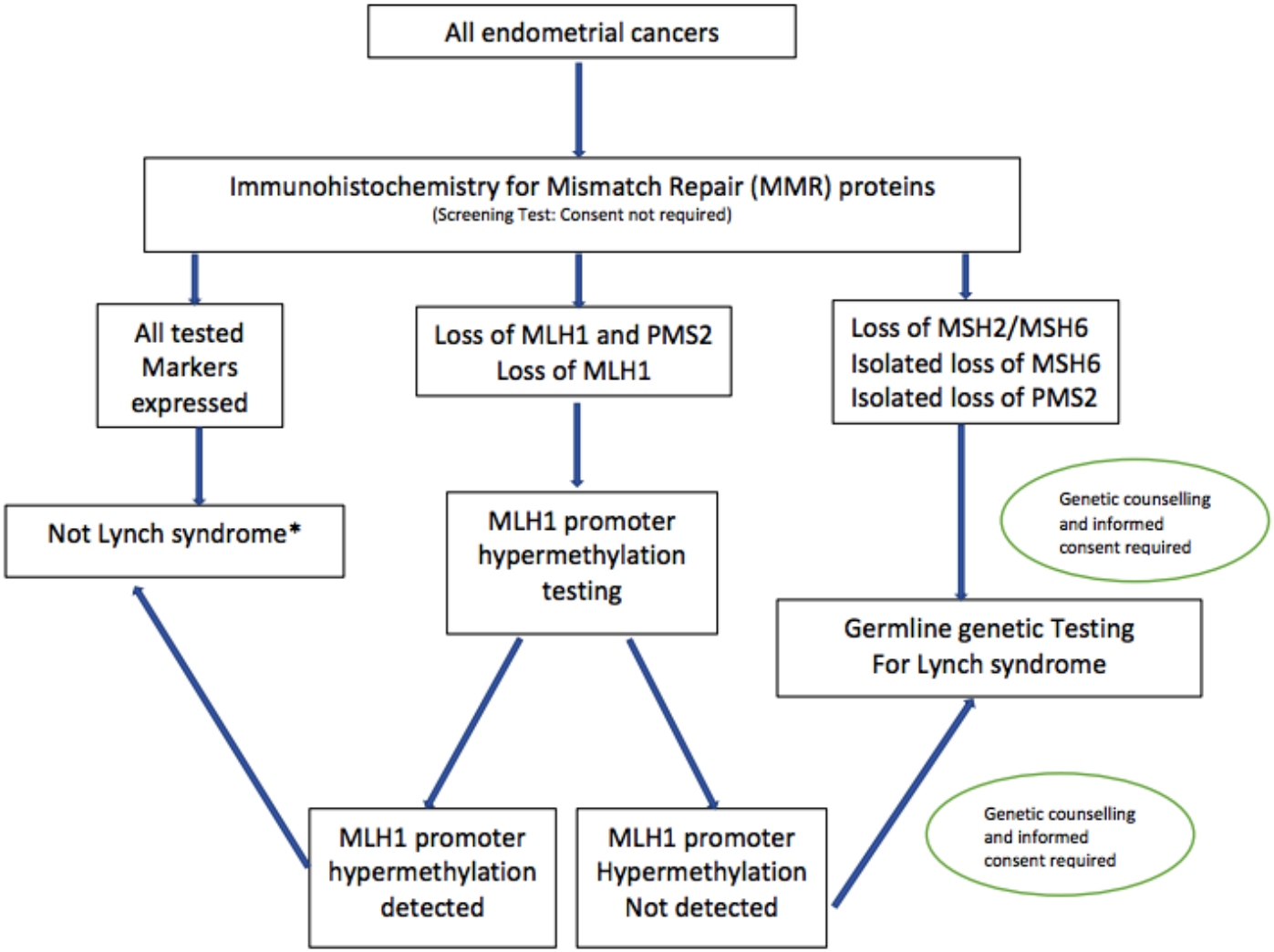

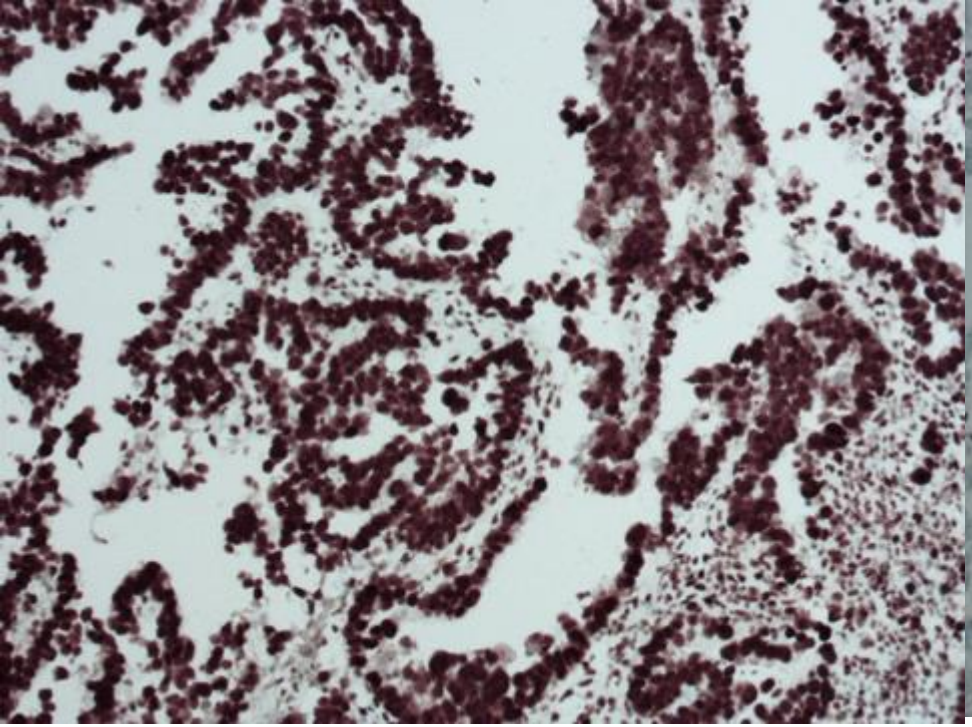

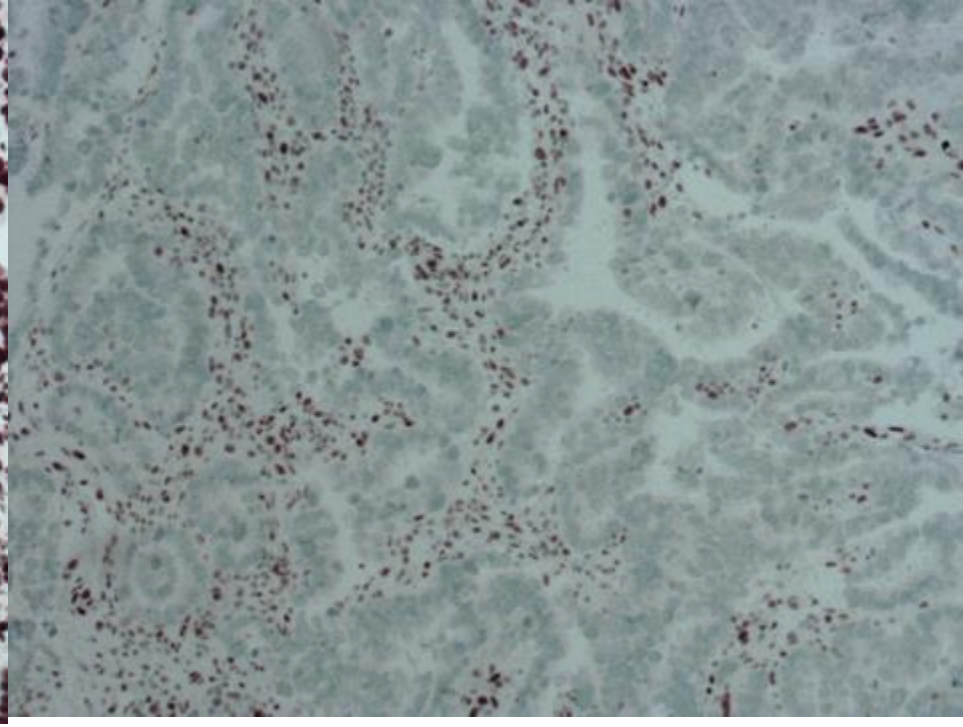

- MMR IHC interpretation is straightforward (strong expression vs complete loss in the majority of cases BUT NOT ALL
- ONLY ONE ABSOLUTE RULE: Strong nuclear expression relative to internal control, typically uniform throughout the tumour in well-fixed specimens = NORMAL
- Poor fixation can affect intensity and distribution of expression; compare with internal control in that area
- BE CAUTIOUS OF ANYTHING ELSE: weak, focal, heterogeneous/subclonal, dot-like, cytoplasmic

BAGP guidance

The British Association of Gynaecological Pathologists

Interpretation and Reporting Terminology for Mismatch Repair Protein Immunohistochemistry in Endometrial Cancer

www.thebagp.org/resources

Summary and conclusions

- WHO/NICE/ESGO guidance mandates universal MMR IHC on all cases of EC
- WHO 2020 endorses the use of molecular classification alongside clinicopathological risk assessment parameters for accurate prognostic assessment and clinical management
- Universal MMR, universal (or very low threshold for) p53; *POLE* if clinically requested (when this will *definitely* impact on treatment)

Summary and conclusions 2

- EIC is now included in serous carcinoma
- Mixed carcinoma: admixture of histotypes of which one is serous or clear cell; any amount
- Carcinosarcoma included in epithelial neoplasms
- Be aware of new entities in WHO 2020

Summary and conclusions 3

- Binary grading of endometrioid carcinoma is recommended
- Substantial LVSI is defined as tumour in ≥ 5 blood vessels (rare in endometrioid EC; take care to exclude artefacts)
- Criteria for reporting synchronous low grade endometrioid endometrial and ovarian ca

Polling Q1

Do you currently carry out MMR IHC or MSI testing on cases of endometrial carcinoma (in your own Department or within cancer network)?

- Yes, on **all** cases
- Yes, on **selected** cases
- Yes, but **only** when requested by clinician
- No, never

Polling Q2 (if not doing on all cases or not at all)

Which of the following are reasons for not carrying out MMR IHC/MSI testing within your Department/Cancer network (please select all that apply)?

- Not convinced of clinical importance/need
- Lack of expertise/experience with testing
- Lack of access to testing
- Lack of funding
- Lack of agreed pathway for testing within network
- Lack of pressure to comply with NICE guidance
- Lack of awareness of NICE guidance
- Other

Thank you

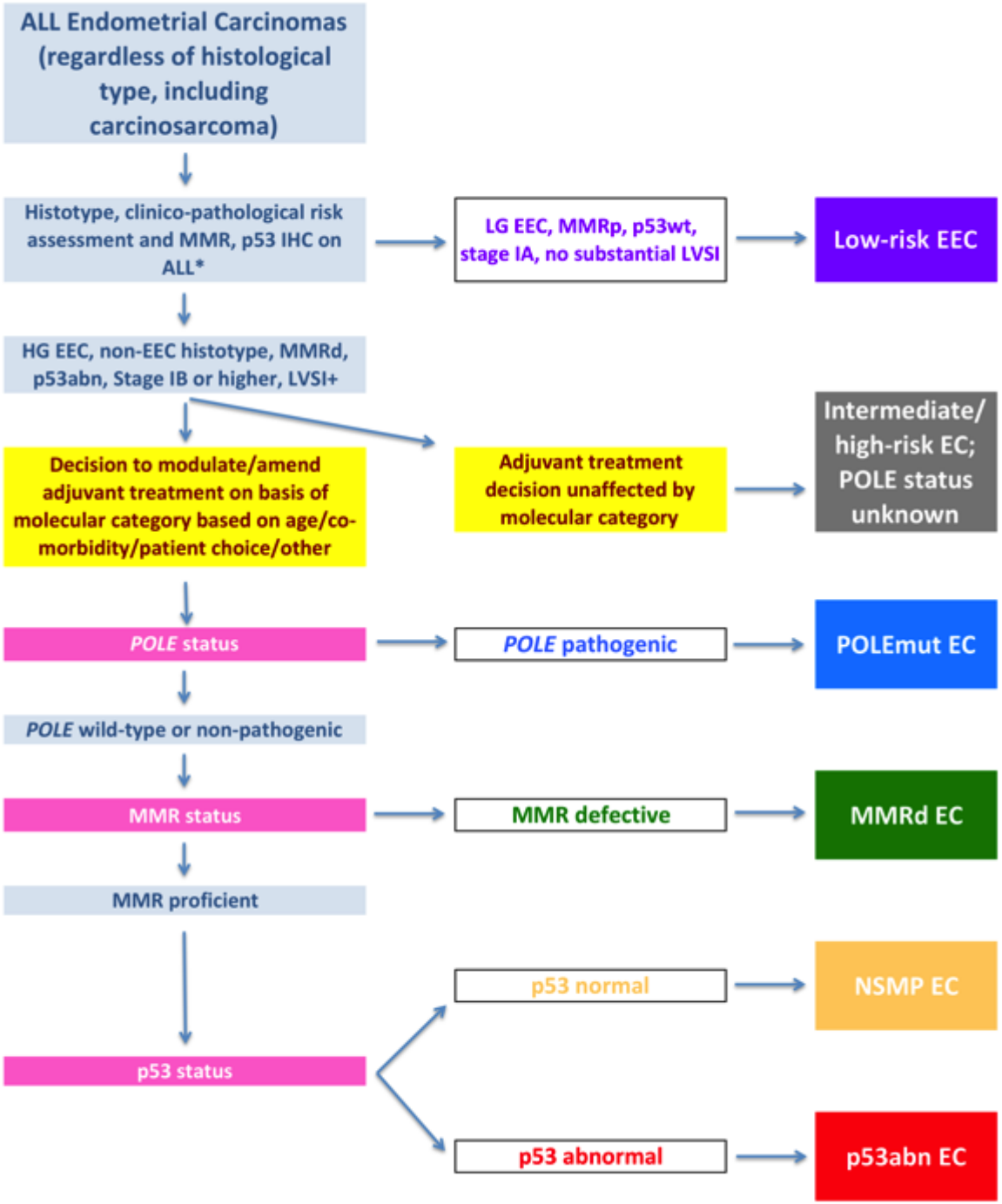
ALL Endometrial Carcinomas (regardless of histological type, including carcinosarcoma)
Histotype, clinico-pathological risk assessment and MMR, p53 IHC on ALL*
LG EEC, MMRp, p53wt, stage IA, no substantial LVSI
Low-risk EEC
HG EEC, non-EEC histotype, MMRd, p53abn, Stage IB or higher, LVSI+
Decision to modulate/amend adjuvant treatment on basis of molecular category based on age/co-morbidity/patient choice/other
Adjuvant treatment decision unaffected by molecular category
Intermediate/ high-risk EC; POLE status unknown
POLE status
POLE pathogenic
POLEmut EC
POLE wild-type or non-pathogenic
MMR status
MMR defective
MMRd EC
MMR proficient
p53 status
p53 normal
NSMP EC
p53 abnormal
p53abn EC