The British Association of Gynaecological Pathologists

Lecturer – Dr William Boyle

Consultant pathologist based at Birmingham Women's Hospital.
Gynaecological and autopsy pathologist.



The British Association of Gynaecological Pathologists

Mock Exam

- Dr Will Boyle
- Birmingham Women's Hospital
- 25th September 2024

Format

Each case dealt with in turn:

1. Recap of histology with discussion
2. Answer
3. Principle histological features
4. Differential diagnosis and how to resolve
5. Extra information

Case 11

- Specimen: Ovary from a resection
- Age: 74
- Clinical: Cystic right ovary

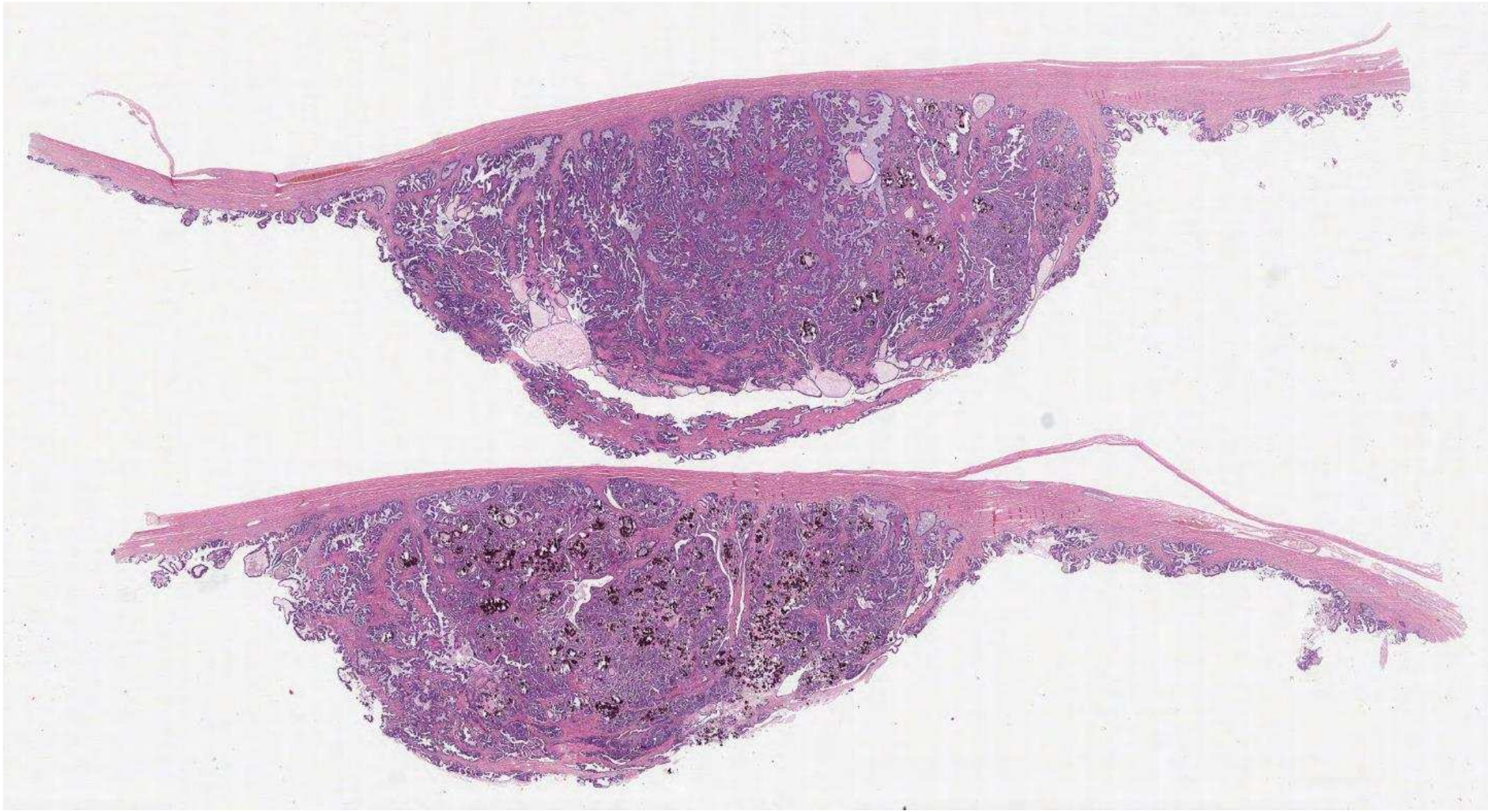



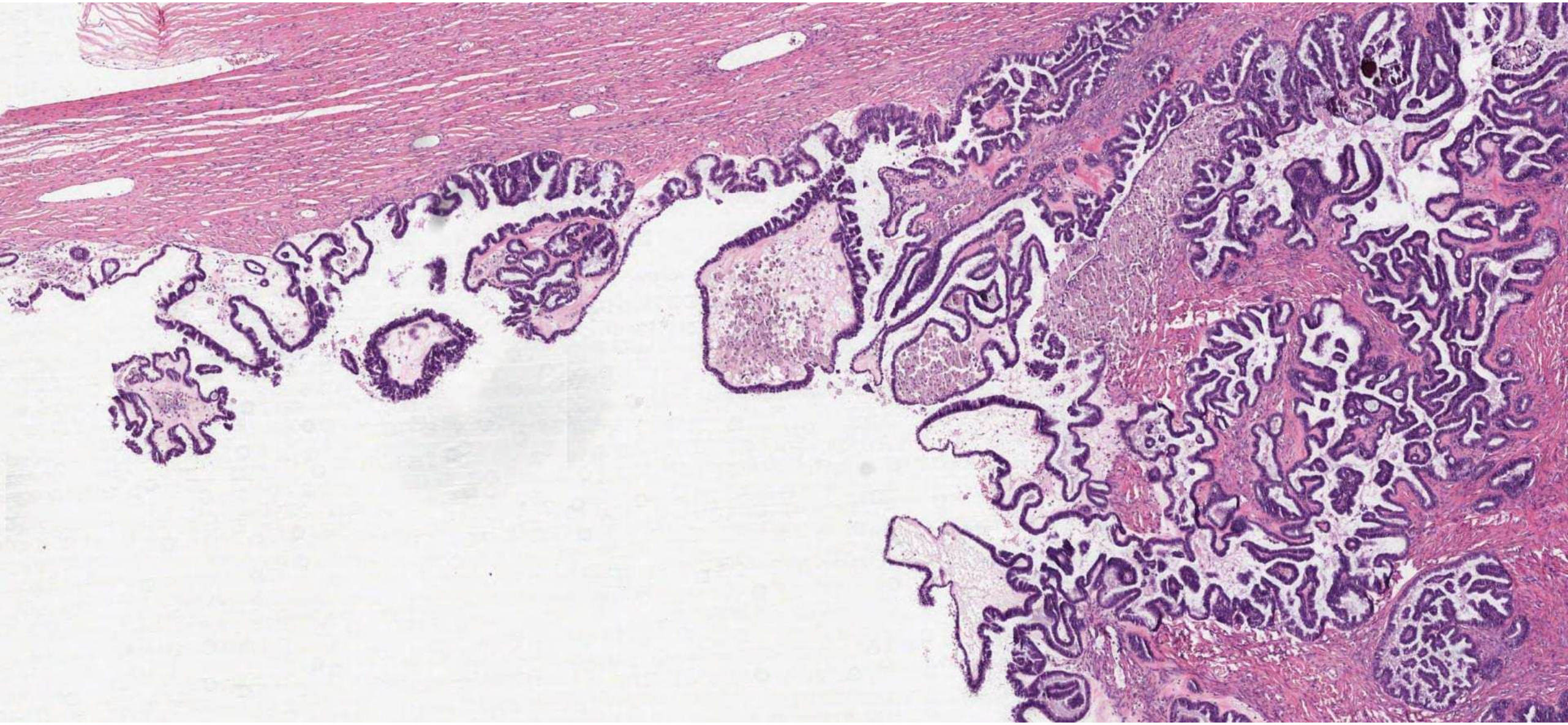

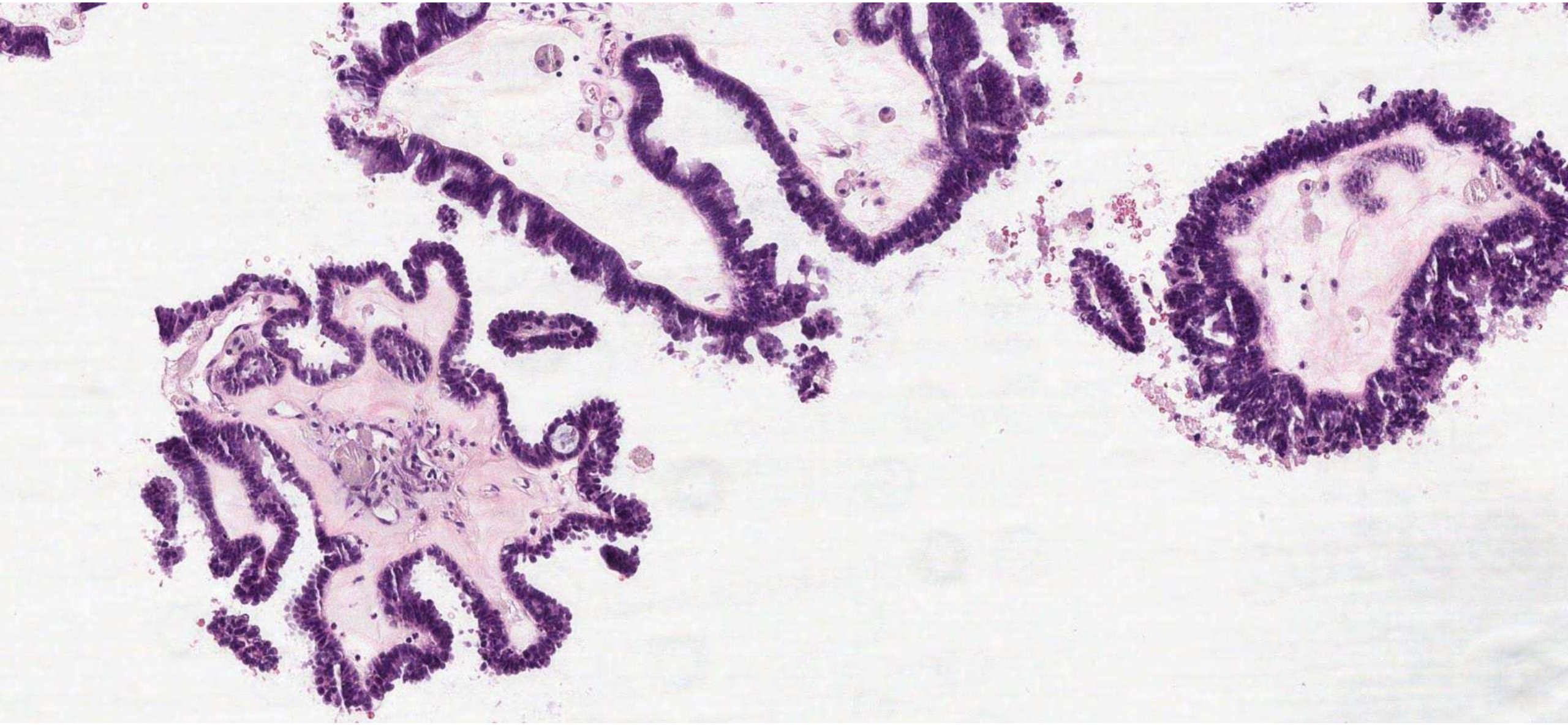



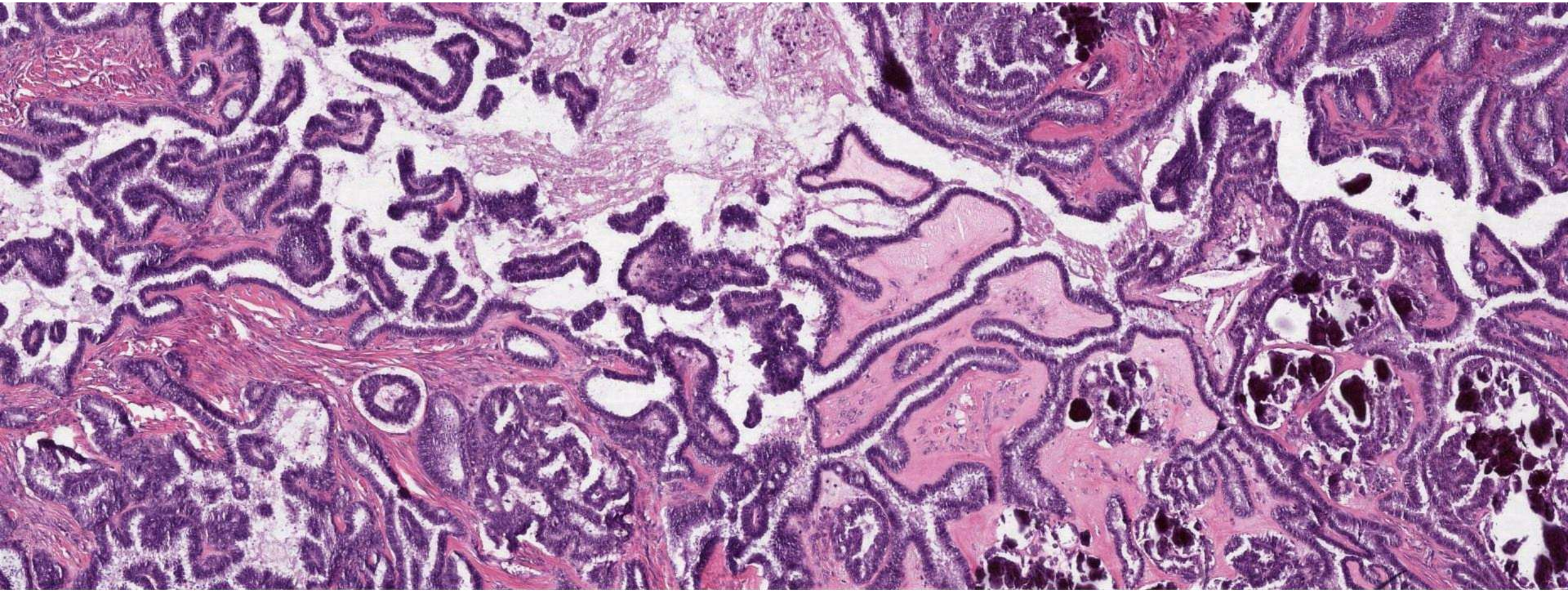

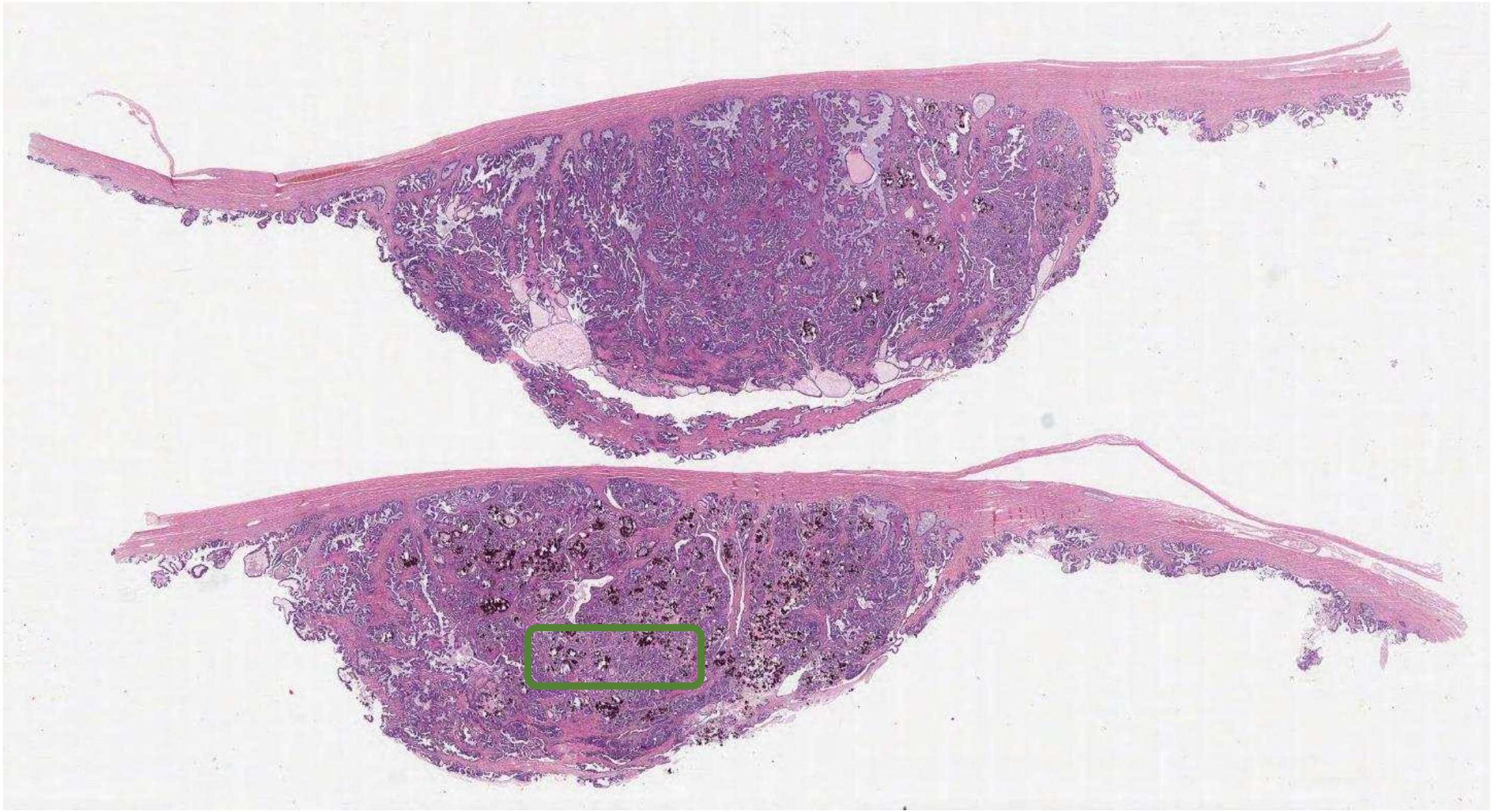

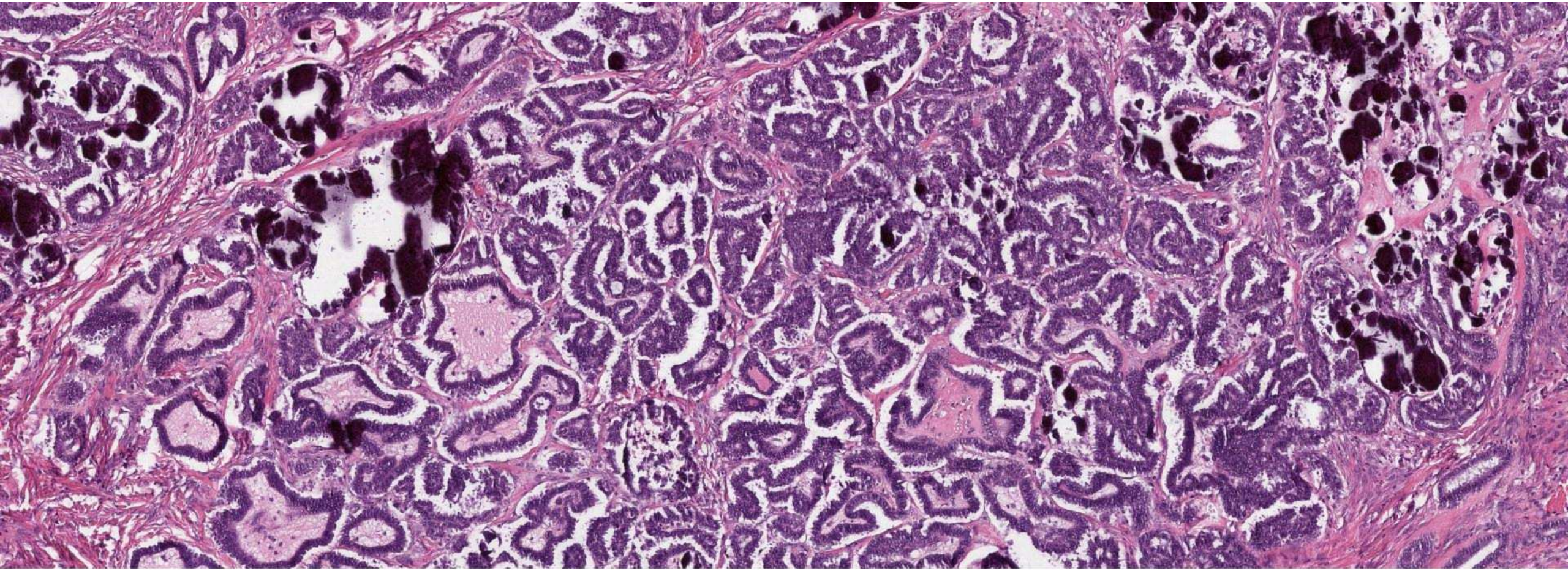

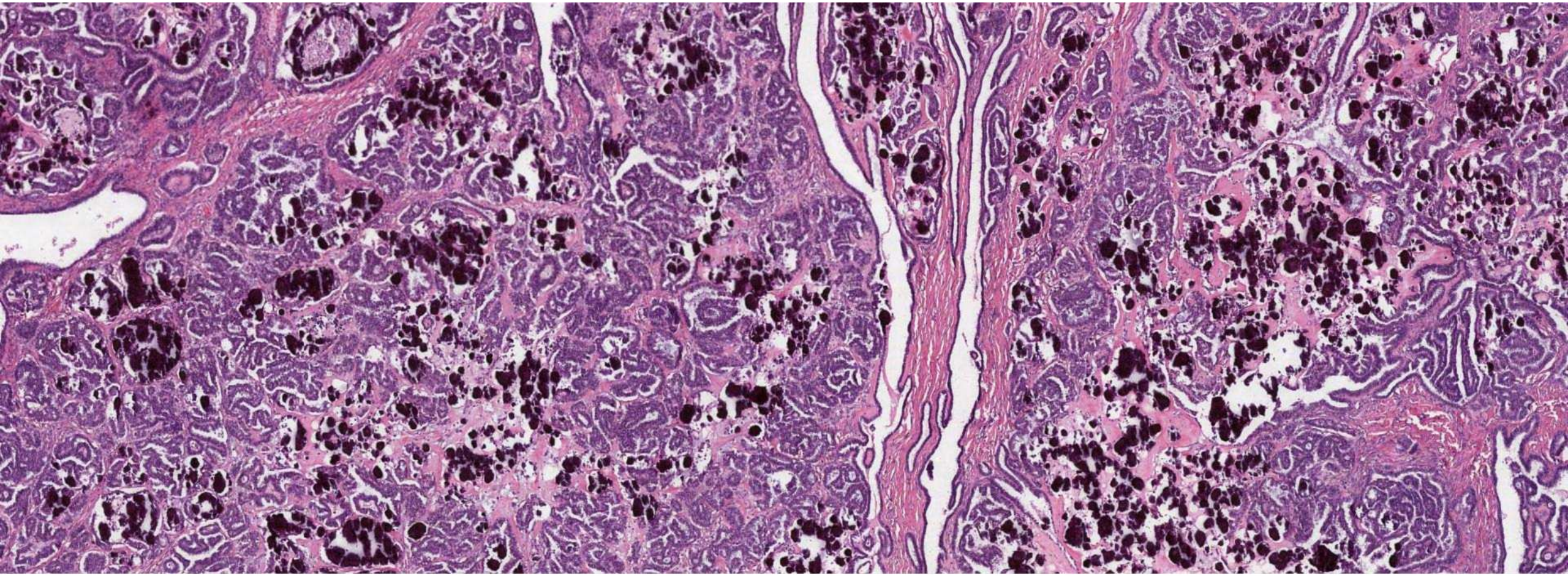

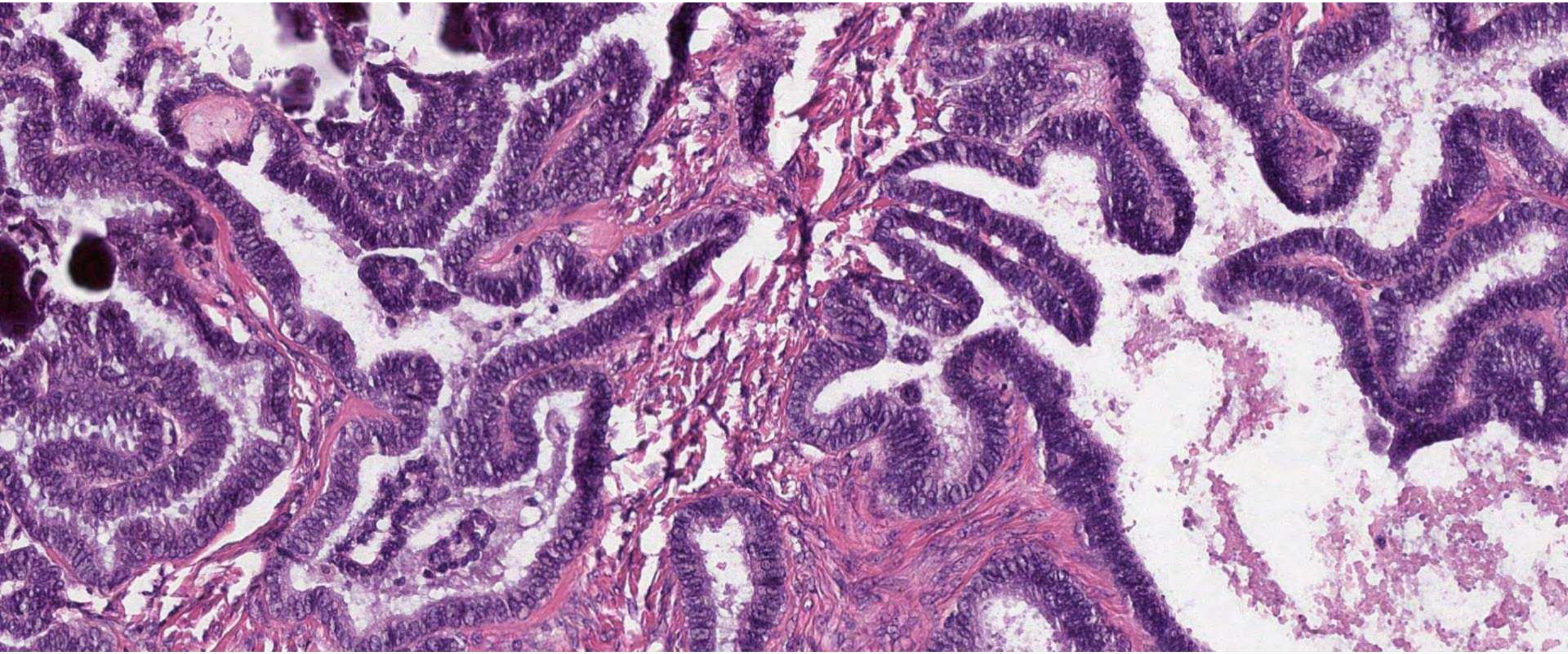

Low grade serous carcinoma

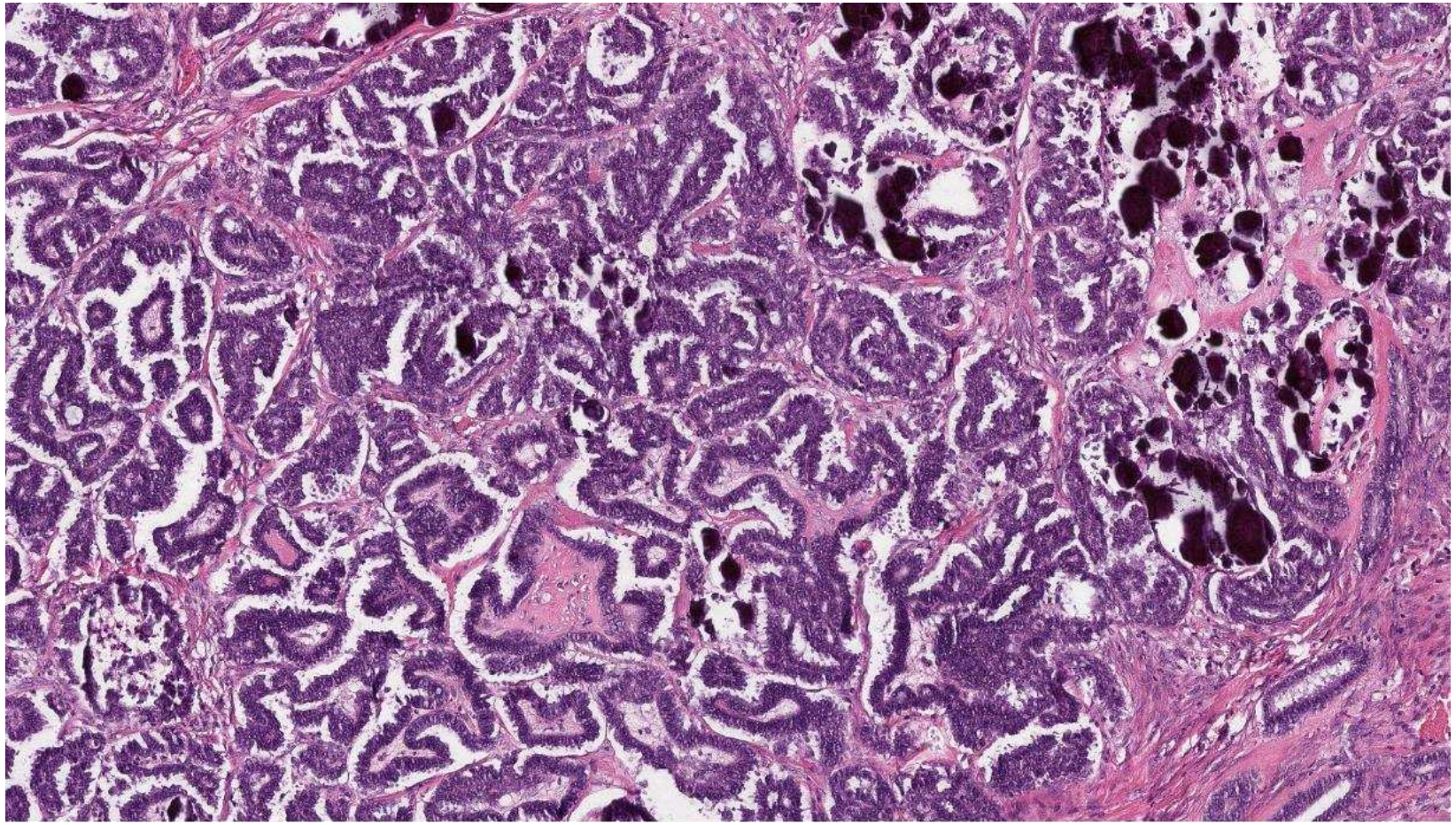

Case 11 – Low grade serous carcinoma

Principle histological features

- Uniform population of small cuboidal cells with scant cytoplasm.
- Mild to moderate nuclear atypia.
- Less than 3-fold variation in size.
- Low mitotic index: < 12 mitotic figures per 10 high power fields.
- Psammoma bodies.
- Invasion characterised by papillae or micropapillae (or inverted macropapillae with broad fibrovascular cores), often surrounded by clefts.
- Background of serous borderline tumour.

Case 11 – Low grade serous carcinoma

DDx and how to resolve

▪ Serous borderline tumour (+/-) microinvasion	Cuboidal to columnar cells with mild to moderate atypia (less than threefold variation in nuclear size) and few mitotic figures	Invasion / invasive foci <5mm confluent Invaginations with smooth contours rather than irregular islands eliciting desmoplastic response /surrounded by clefts
▪ High grade serous carcinoma	Cells with high N:C ratio Papillary architecture WT1+	High grade atypia, mitoses ++ p53 aberrant
▪ Seromucinous borderline tumour/ endometrioid carcinoma showing seromucinous morphology	Cystic tumour with cells showing no/mild atypia Heirarchical branching architecture	Ciliated, mucinous and indifferent cells Papillary cores oedematous and contain polymorphs WT1 -

Case 11 – Low grade serous carcinoma

Extra marks?

- Difficult
- Expected to be p53 wild type, ER+, WT1+
- Discuss criteria for invasion vs microinvasion.
- Various molecular alterations have been described, especially KRAS, NRAS and BRAF mutations.

Case 12

- Specimen: Vulval biopsy
- Age: 36
- Clinical: Vulval rash

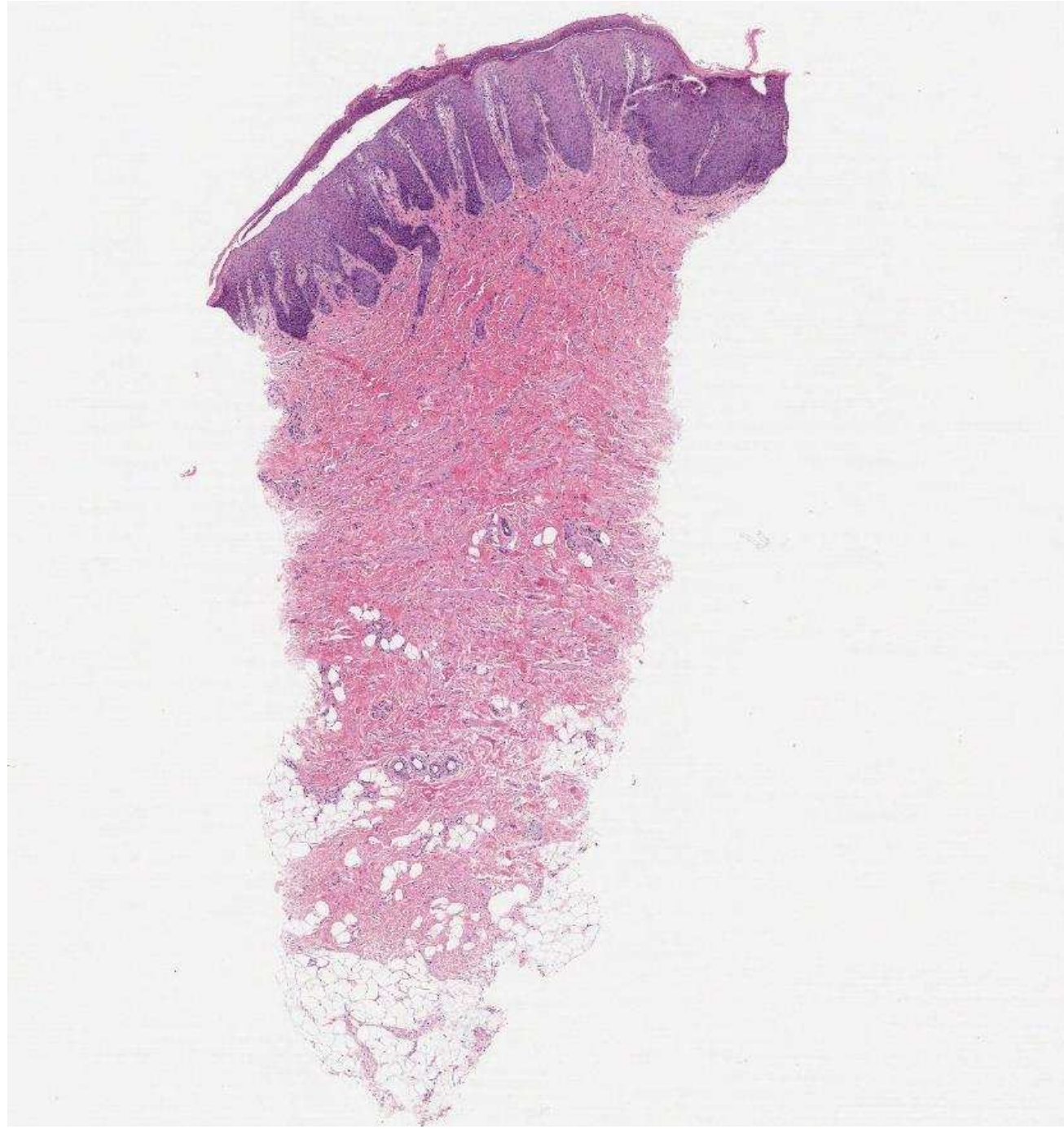

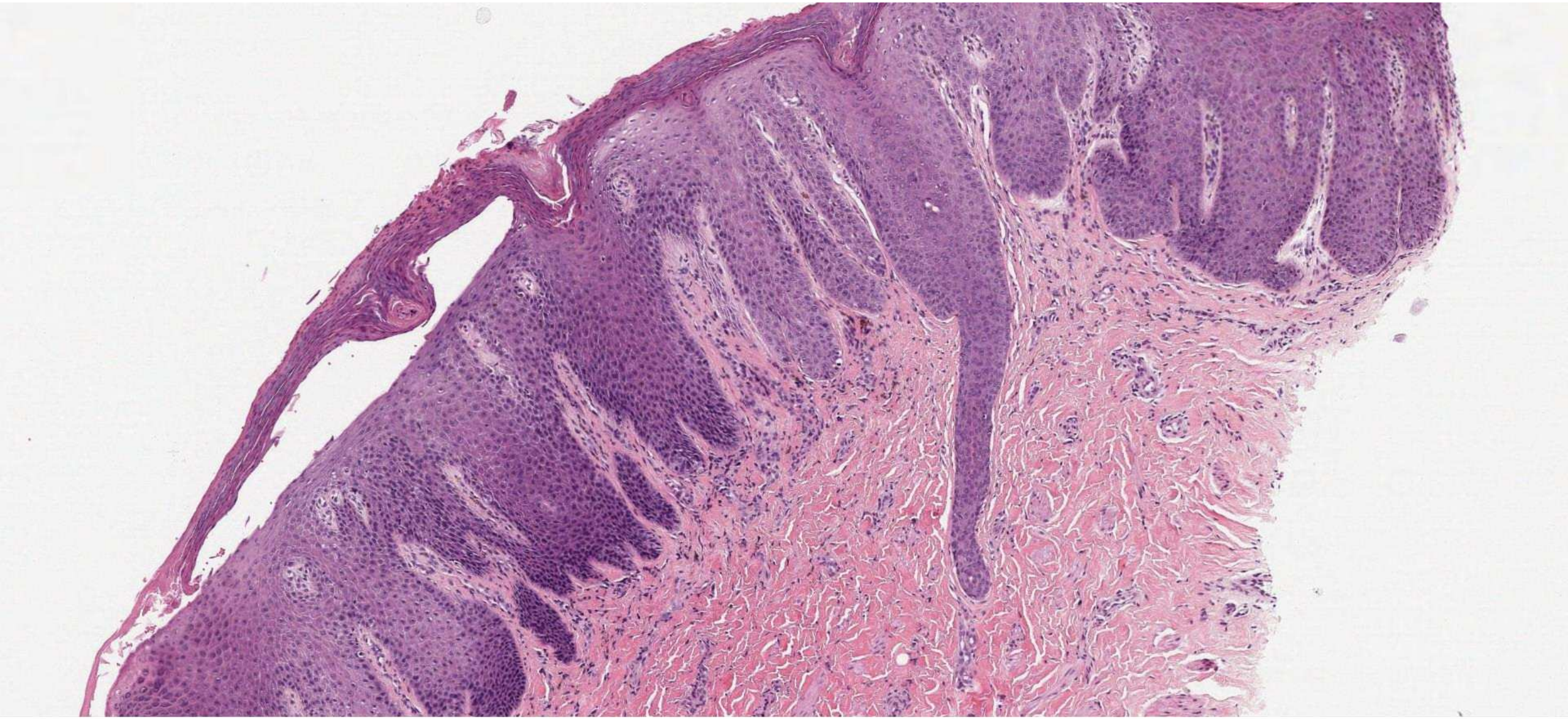

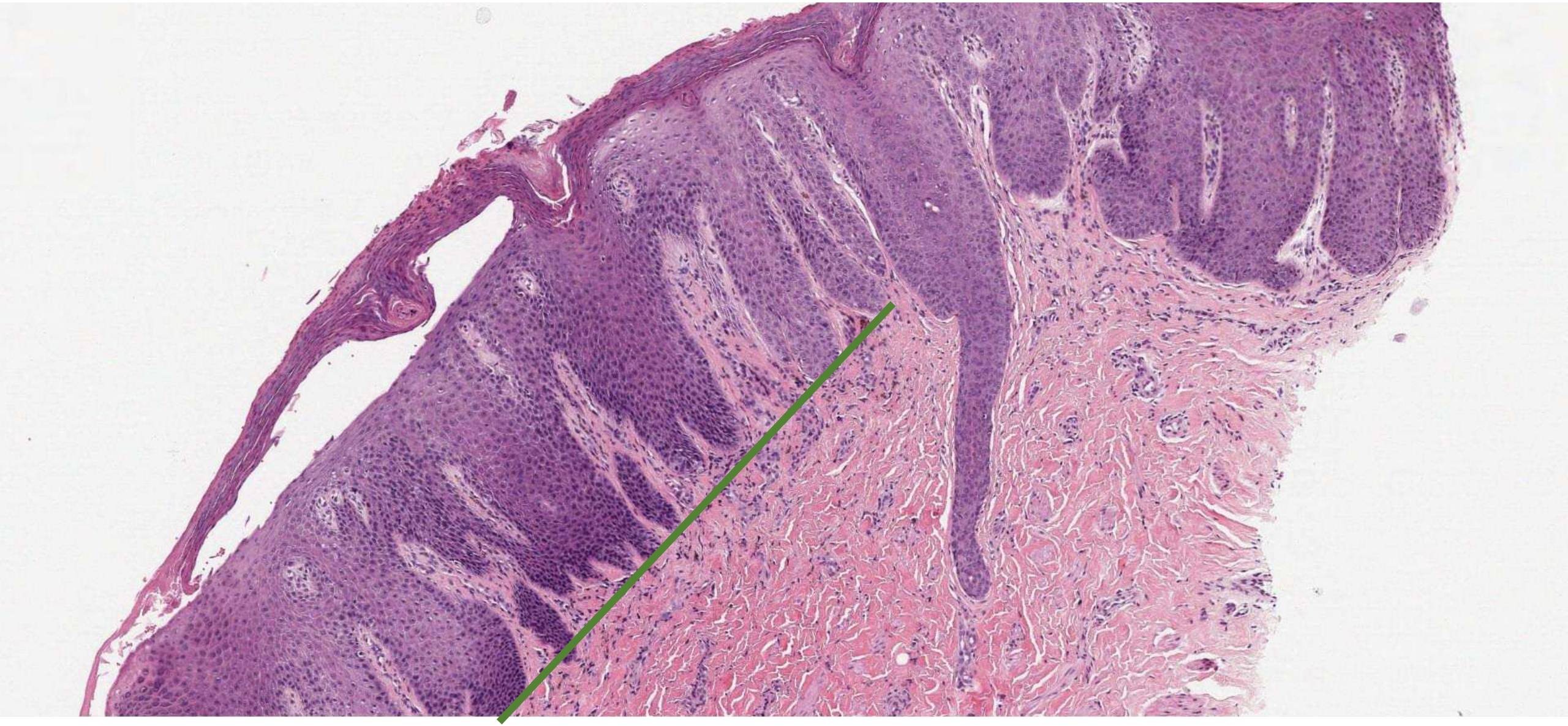

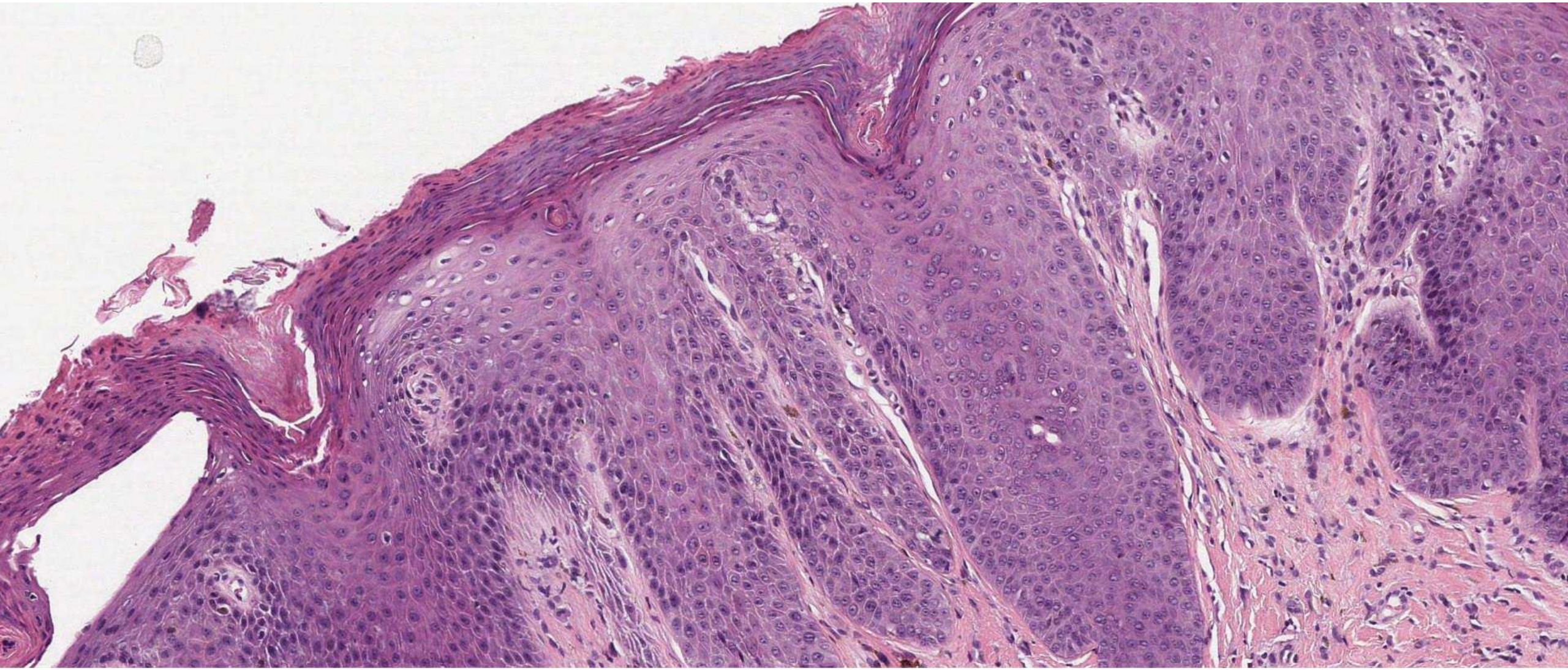





Psoriasis

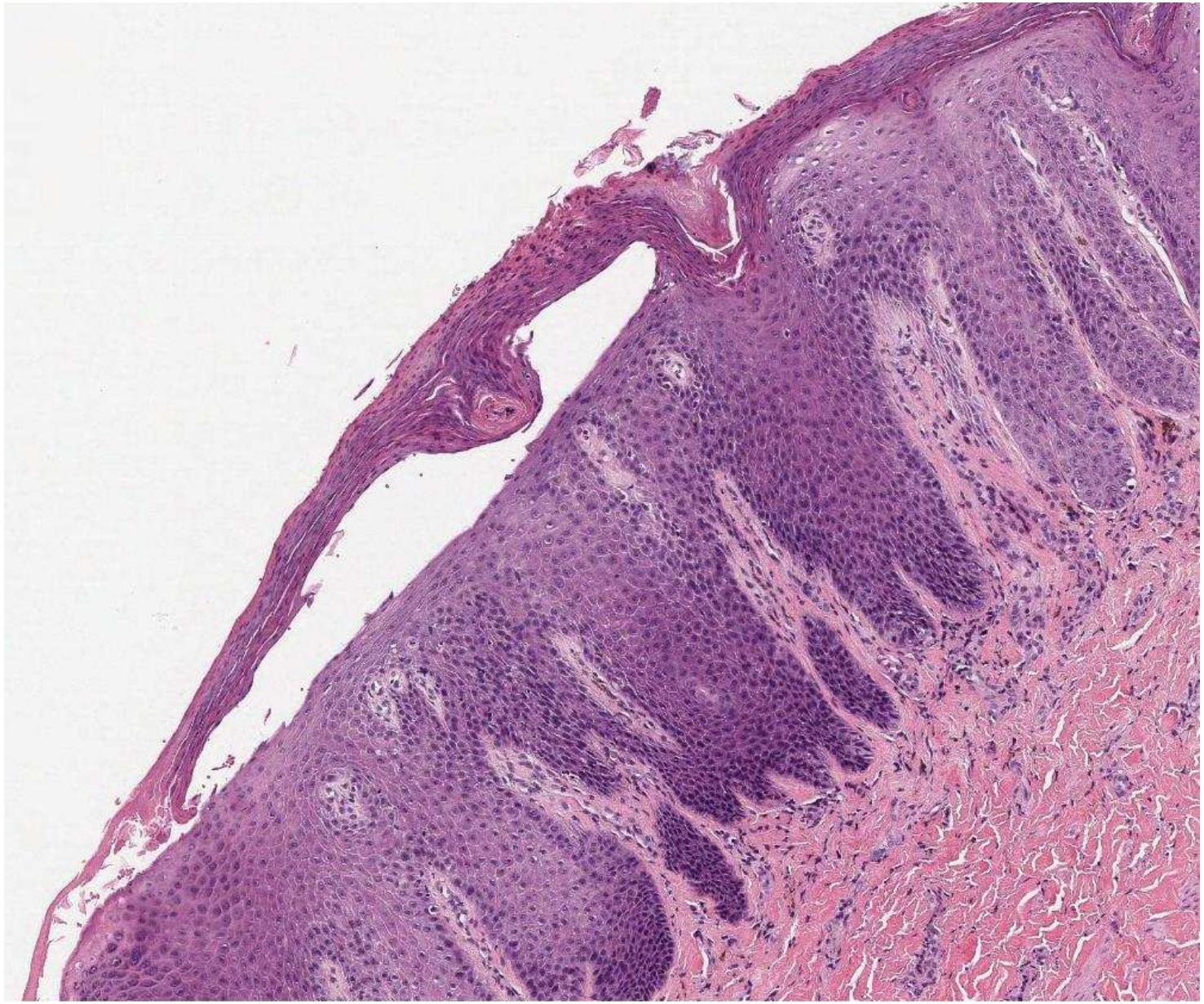

Case 12 – Psoriasis

Principle histological features

- Regular acanthosis with elongated rete.
- Alternating zones of hypo and hypergranulosis.
- Thinning of the suprapapillary plates
- Areas of parakeratosis in the stratum corneum with mounds of neutrophils (Munro microabscesses).
- Perivascular, predominantly lymphocytic infiltrate in the upper dermis.

Case 12 – Psoriasis

DDx and how to resolve
Neoplastic

- dVIN

Often acanthotic with rete enlargement
Parakeratosis

Clinical features
Basal nuclear atypia
Abnormal maturation (deep keratin)
Aberrant p53

- HPV independent, p53 wild type precursor (VaVIN)

Acanthotic, no atypia
Aberrant maturation overlapping with psoriasis features

Discreet lesion, not a diffuse process
Warty low power appearance
Lacks some specific features (suprapapillary plate thinning, regular acanthosis)

Case 12 – Psoriasis

DDx and how to resolve
Non-neoplastic

▪ Fungal infection	Acanthotic lesion with dermal inflammation	Positive fungal stains (PASD)
▪ Lichen simplex chronicus	Acanthotic, elongated rete	Vertical papillary dermal fibrosis, no neutrophils in stratum corneum, usually not parakeratotic
▪ Spongiotic dermatosis (e.g. atopic or contact dermatitis	Acanthotic Both can show spongiosis	Spongiosis more pronounced Eosiniophils ofen more prominent
▪ Psoriasiform drug eruption	Morphologically similar to psoriasis	Clinical history

Case 12 – Psoriasis

Extra marks?

- Discuss the differentials
- Fungal stains
- ?Known psoriasis – isolated to vulva = uncommon

Case 13

- Specimen: Vaginal wall
- Age: 49
- Clinical: Indurated vaginal wall



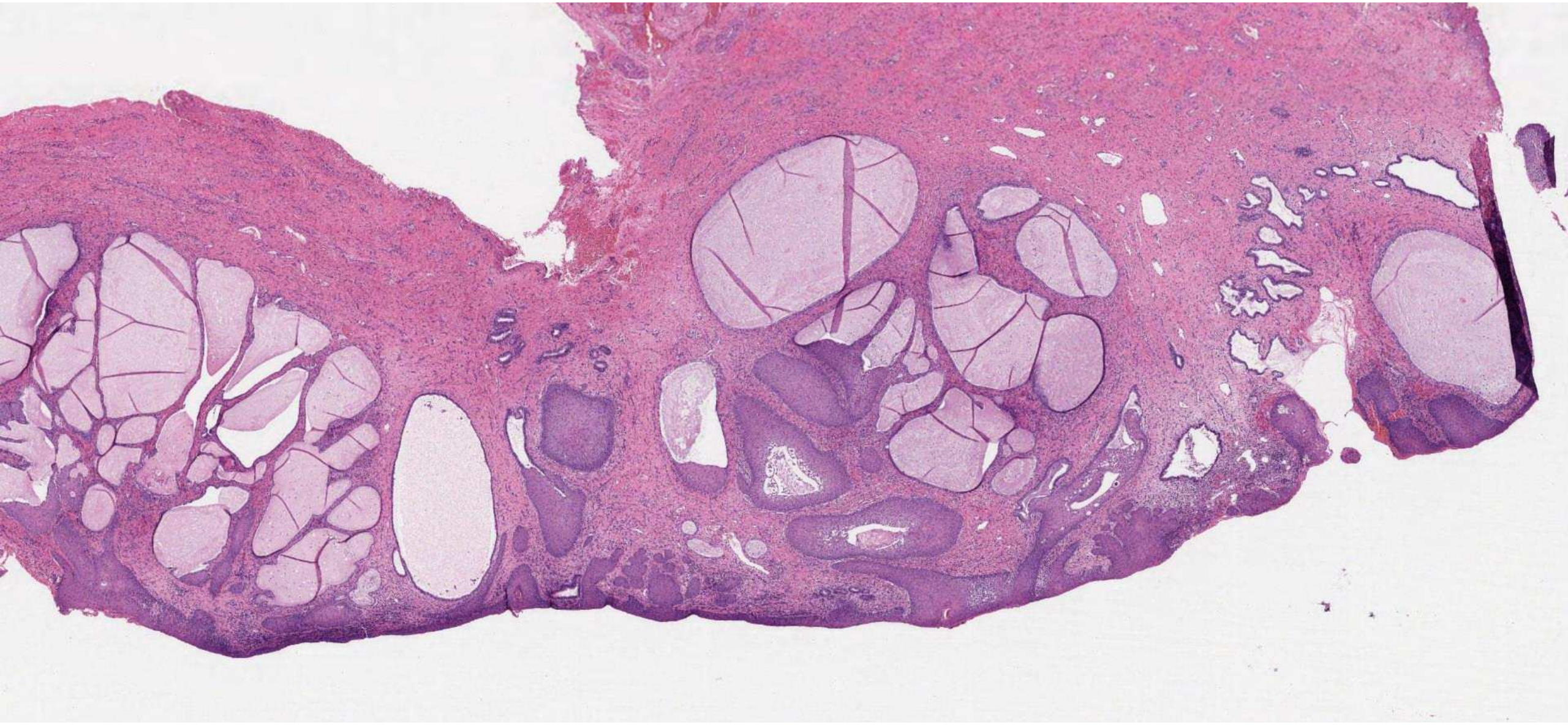

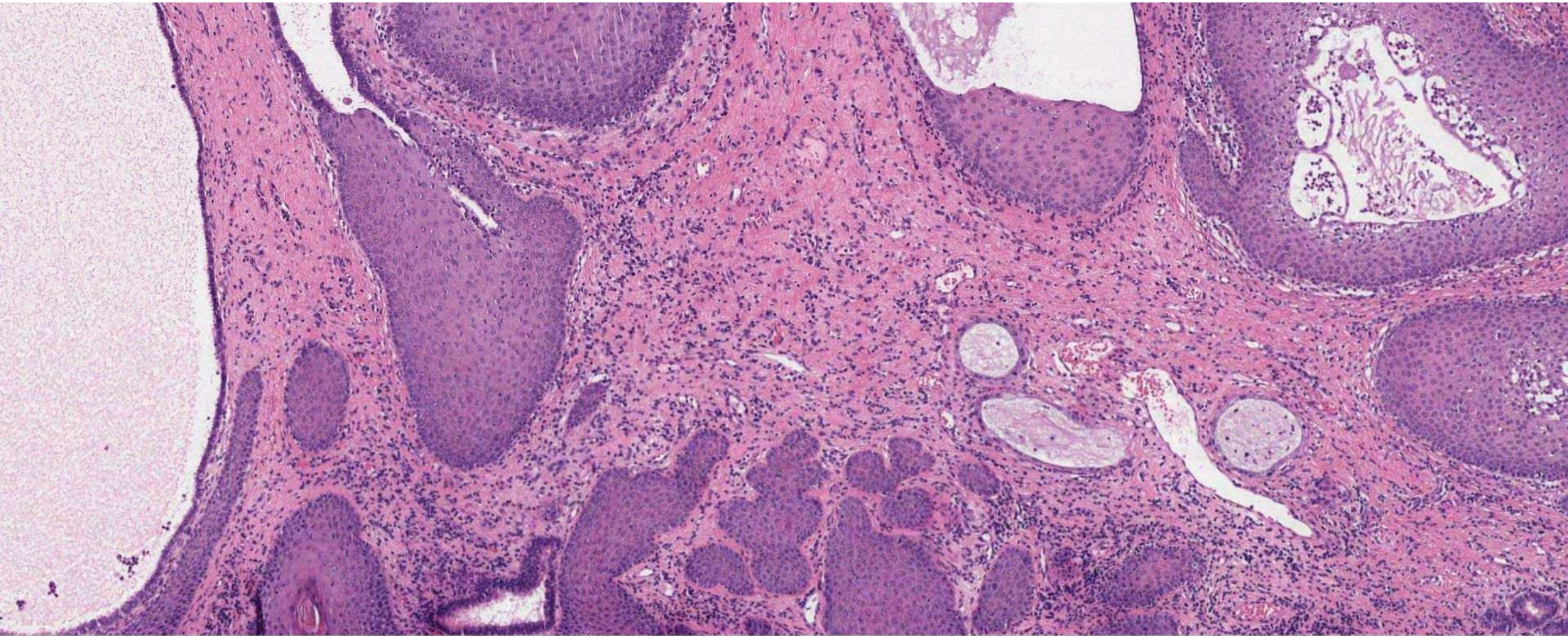

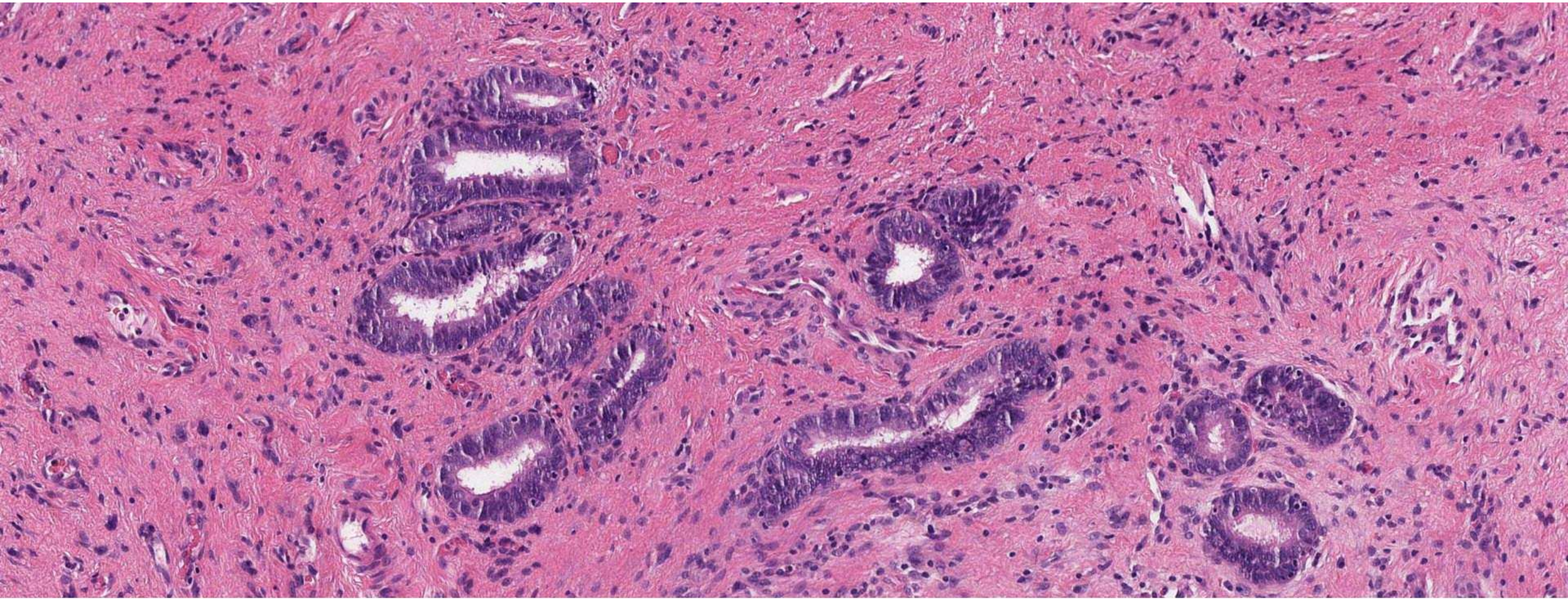

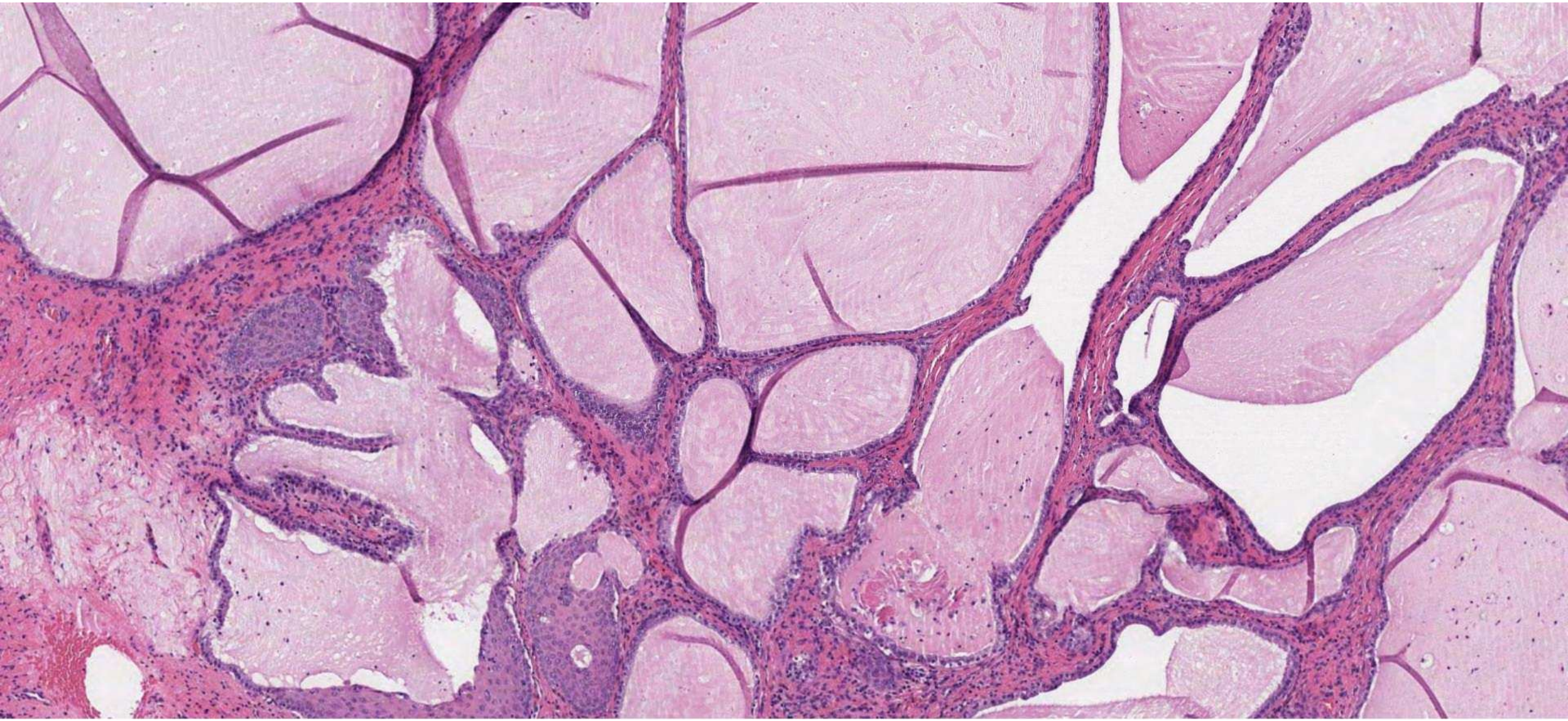

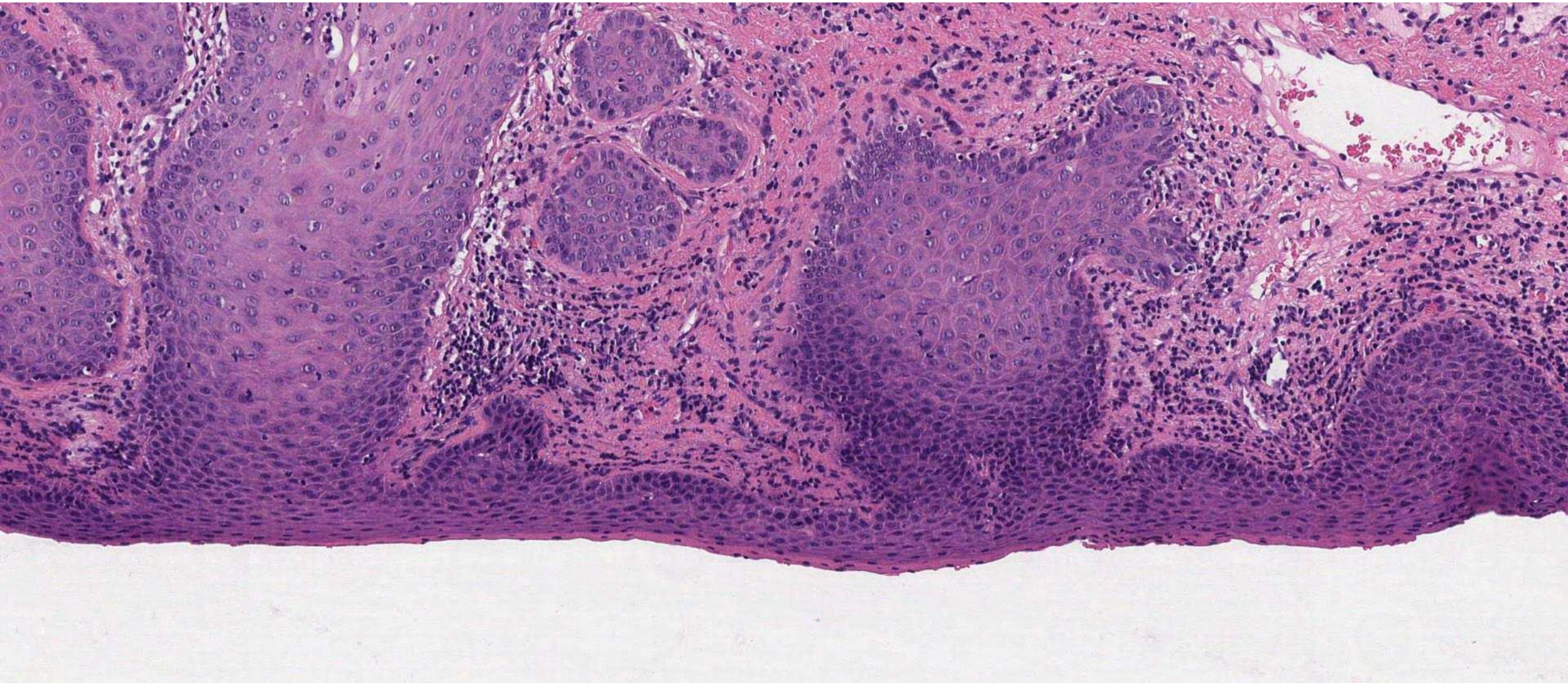

Vaginal adenosis



Case 13 – Vaginal adenosis

Principle histological features

- Vaginal call contains glands lined by either mucinous columnar cells resembling endocervical mucosa or tuboendometrial glands i.e. columnar cells with higher N:C ratios +/- cilia
- Glands may be simple, complex, cystic (resembling Nabothian cysts) or papillary
- Squamous metaplasia

Case 13 – Vaginal adenosis

DDx and how to resolve

▪ Vaginal adenocarcinoma, metastatic carcinoma, vault recurrence of uterine carcinoma	Glands in the vulval wall Shared potential for complex architecture and crowding	Nuclear atypia Infiltrative growth and destructive growth
▪ Endometriosis	Glands resembling endometrial glands	Mucinous glands and squamous metaplasia less likely Glands surrounded by endometrial stroma +/- evidence of haemorrhage
▪ Mesonephric remnants	Glands in vaginal wall	Mesonephric morphological features: cuboidal cells surrounding tubules with eosinophilic secretions

Case 13 – Vaginal adenosis

Extra marks?

- Association with in utero exposure to diethylstilbestrol, used in the past to prevent miscarriage and premature labour.
- Most commonly used in 1940s and 1950s and discontinued in 1970s, i.e. adenosis unlikely to be attributable to DES in women aged under ~ 50.

- Also associated with vaginal trauma; can be iatrogenic (e.g. 5-fluoruracil)

- A risk factor for clear cell carcinoma.

- Treated with excision or cautery if symptomatic.

Case 14

- Specimen: Hysterectomy
- Age: 62
- Clinical: Fibroid uterus

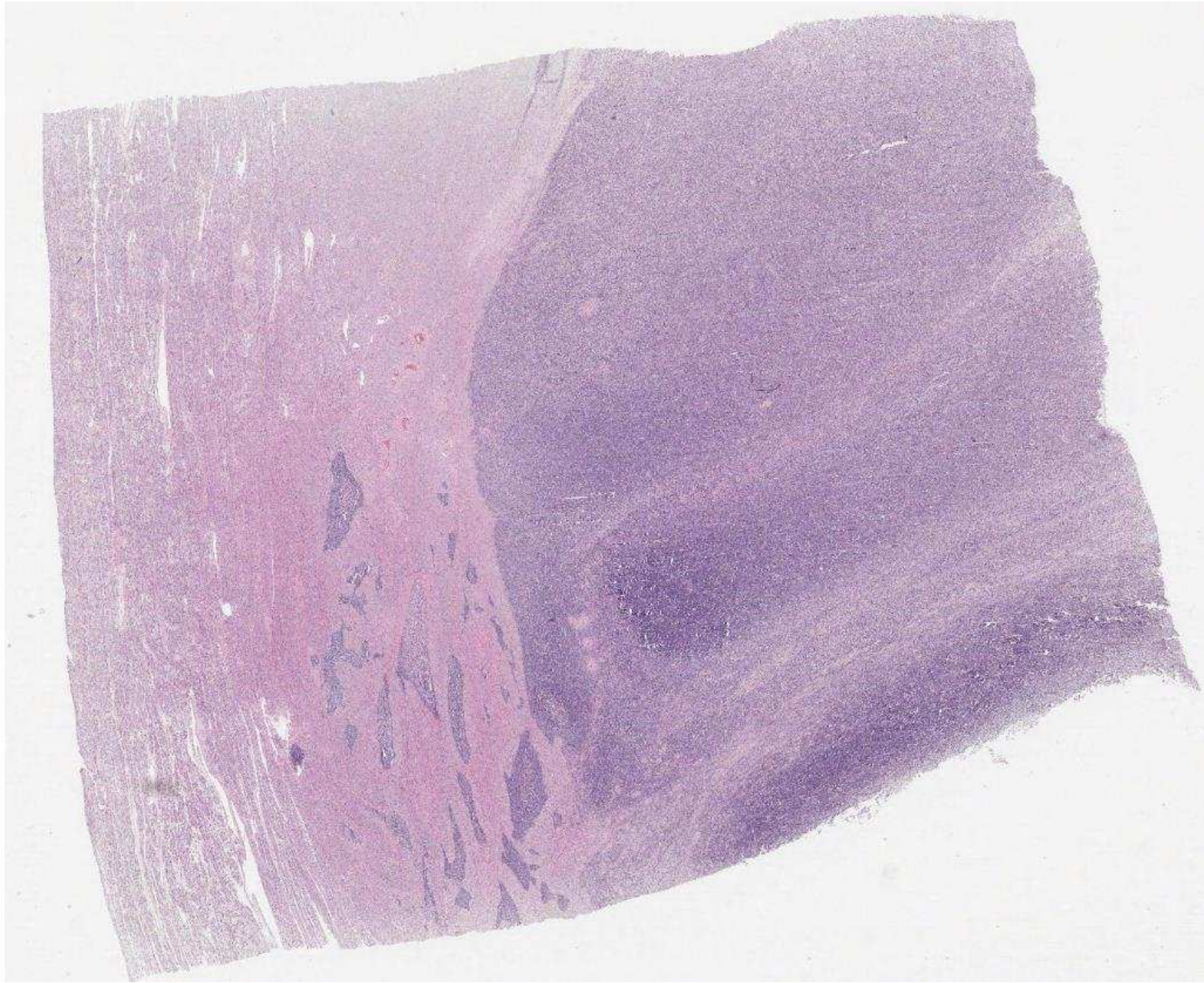

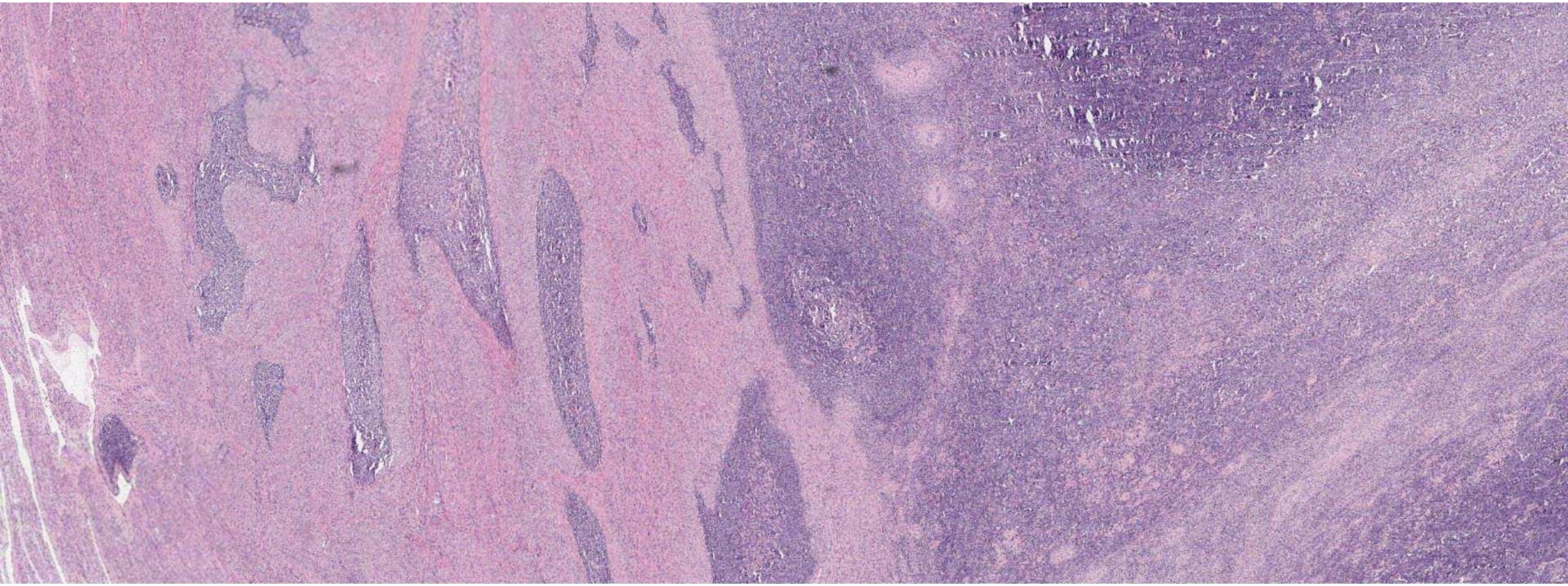

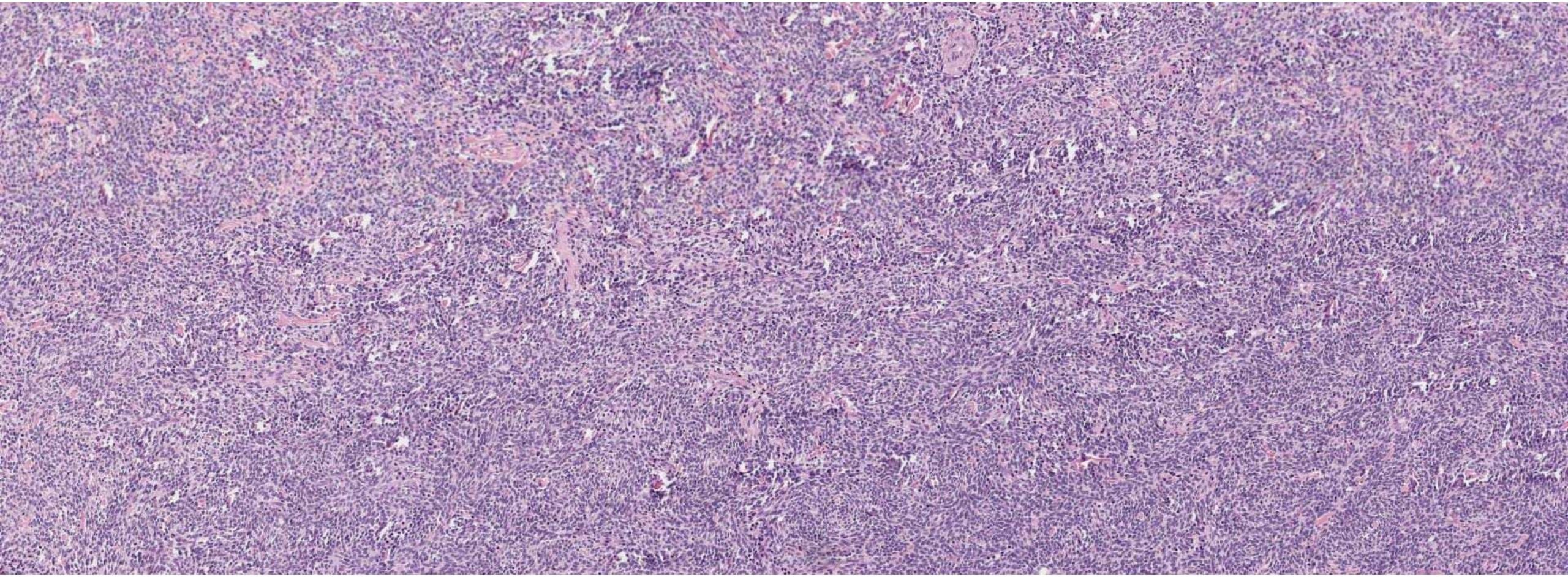

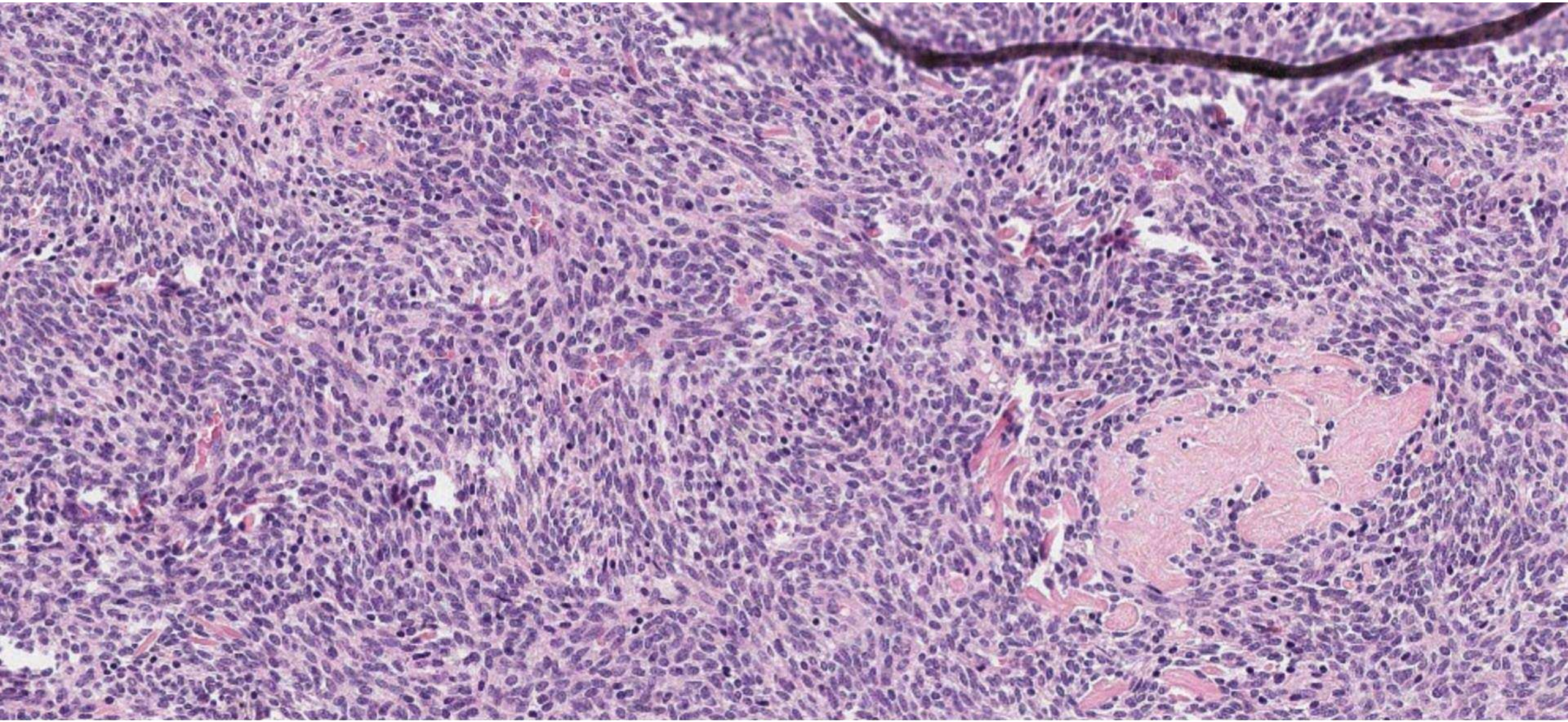

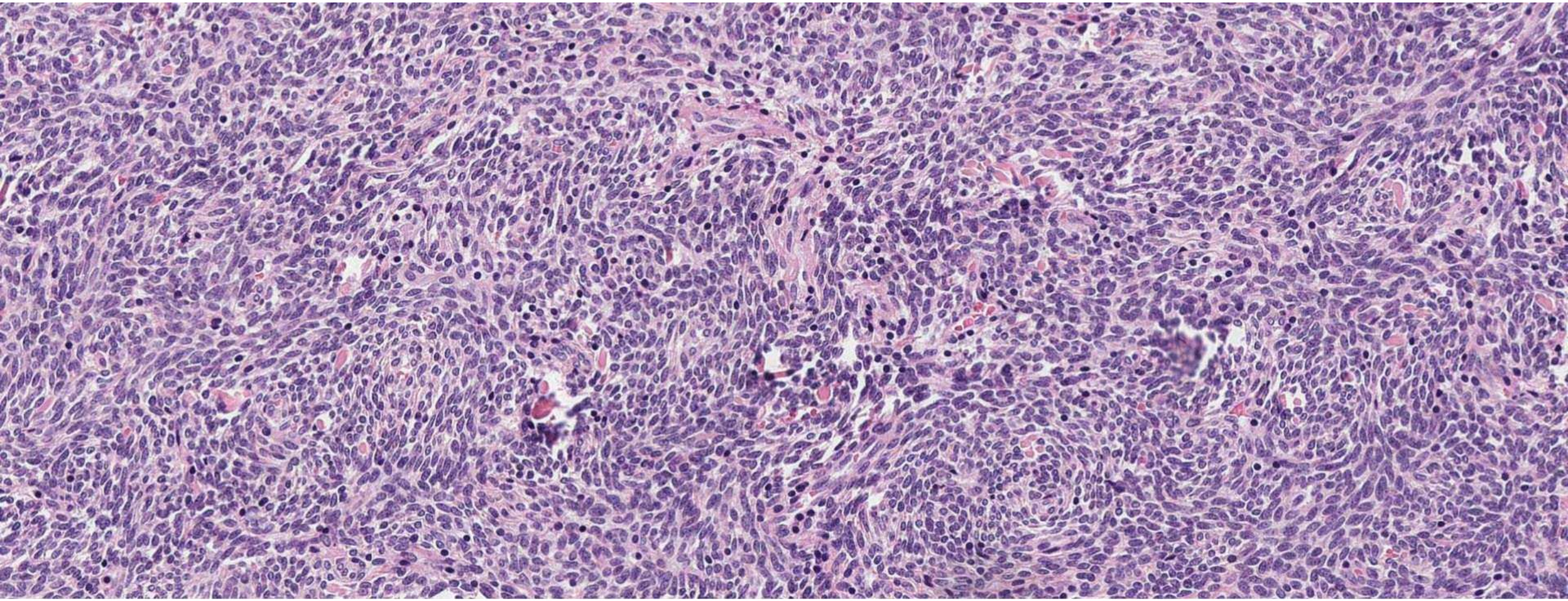

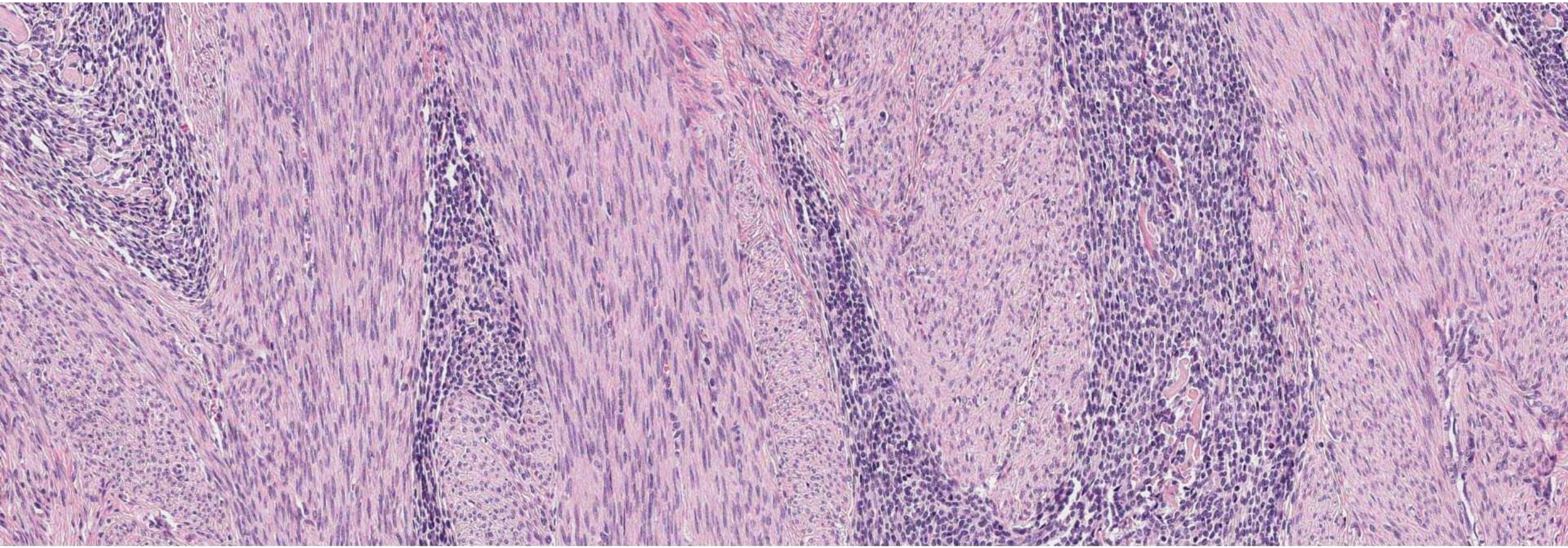

Low grade endometrial stromal sarcoma

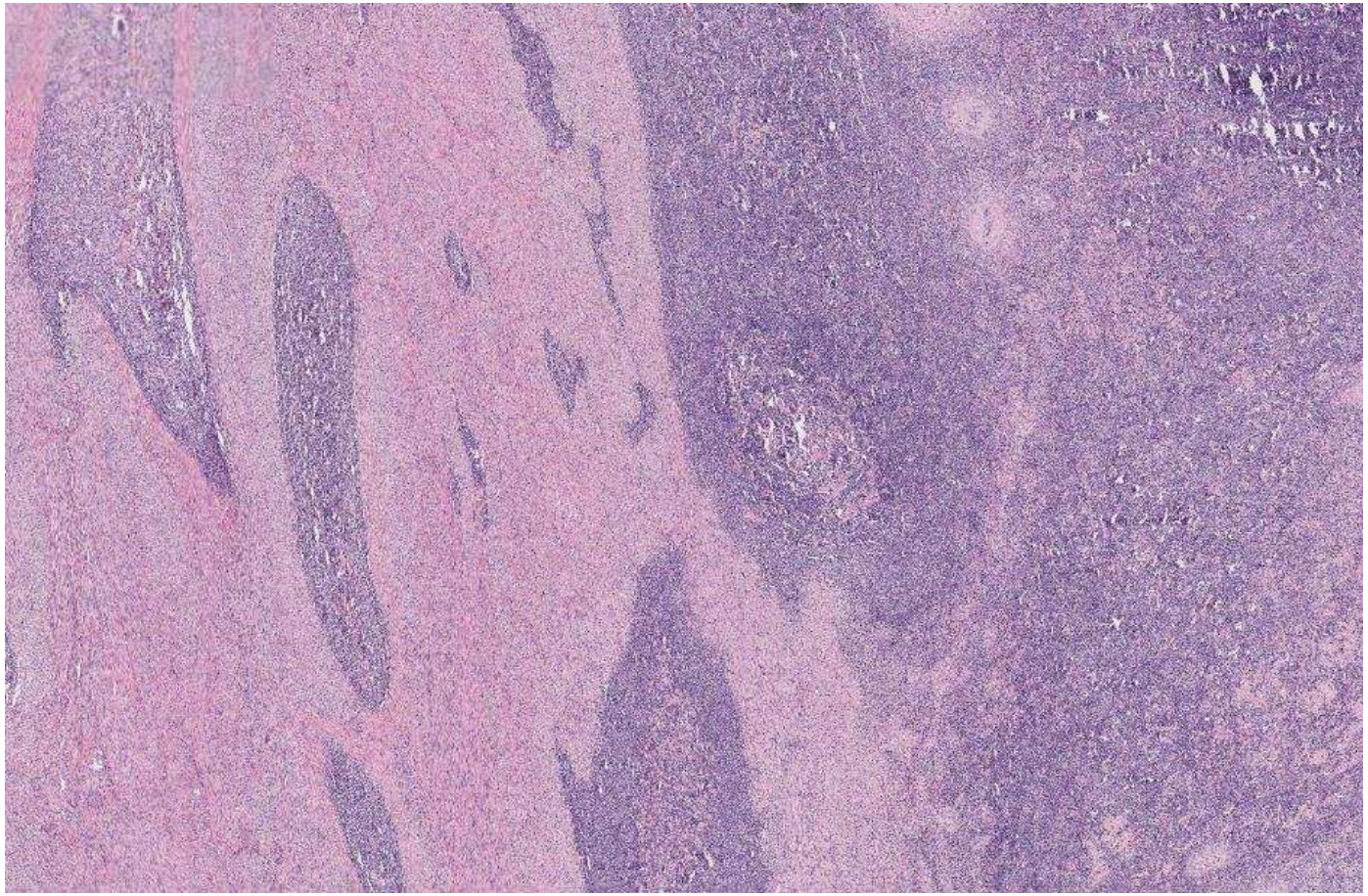

Case 14 – Low grade endometrial stromal sarcoma / LGESS

Principle histological features

- Irregular cellular islands, forming permeative tongue-like pattern of myometrial invasion; frequent vascular invasion.
- Monotonous oval to spindle cells with minimal cytologic atypia and vesicular chromatin.
- Mitotic count is usually low (< 5/10 high power fields), necrosis is usually absent.
- Whorling around delicate arteriolar type vessels, reminiscent of proliferative endometrial stroma.
- Admixed collagen bands / plaques.
- ‘Starburst’ smooth muscle differentiation, glandular, sex cord-like differentiation possible.

Case 14 – LGESS

DDx and how to resolve

▪ Endometrial stromal nodule	Same cytomorphology	Absent myometrial invasion OR minimal invasion (≤ 3 protrusions, each <3mm); no lymphovascular invasion
▪ High grade endometrial stromal sarcoma	Sarcoma invading myometrium	High grade (uniform) nuclear morphology High mitotic count Different IHC & molecular
▪ Smooth muscle tumour (cellular leiomyoma, lyomyosarcoma)	Spindly uterine mesenchymal lesion	Fascicular with thick-walled vessels Elongated tapered nuclei (LM); nuclear atypia (LMS)
▪ Other translocation sarcomas	Spindly uterine mesenchymal lesion with uniform nuclei	Usually fibrosarcoma-like Lacking whorling architecture and vascular pattern of LGESS

Case 14 – LGESS

Extra marks?

IHC	**CD10**	**CyclinD1**	**Caldesmon**	**SMA**	**Desmin**	**ER**	**BCOR**
LG-ESS	Diffuse +	Non diffuse	-/+	-/+	-/+	+	-
HG-ESS (YWHAE-NUTM2A/B fusion)	-	Diffuse +	-	-	-	-	+
HG-ESS (BCOR translocation)	+	Diffuse +	-	-	-	-	+
Smooth muscle tumour	-/+	Non-diffuse	+	+	+	+/-	-

Case 14 – LGESS

Extra marks?

- Several specific translocations implicated, most commonly JAZF1-SUZ12

Case 15

- Specimen: Endometrial biopsy
- Age: 29
- Clinical: Unscheduled PV bleeding

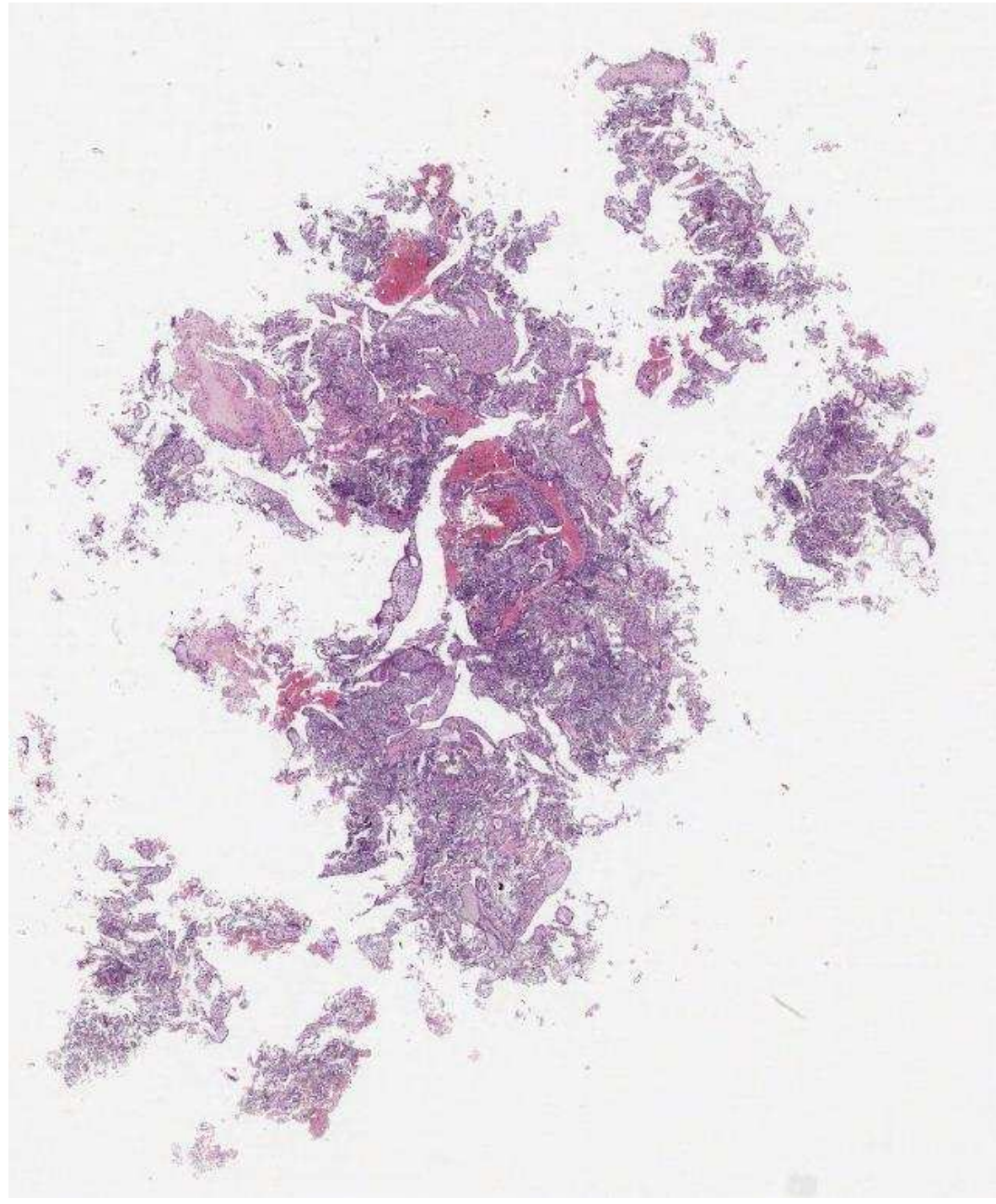

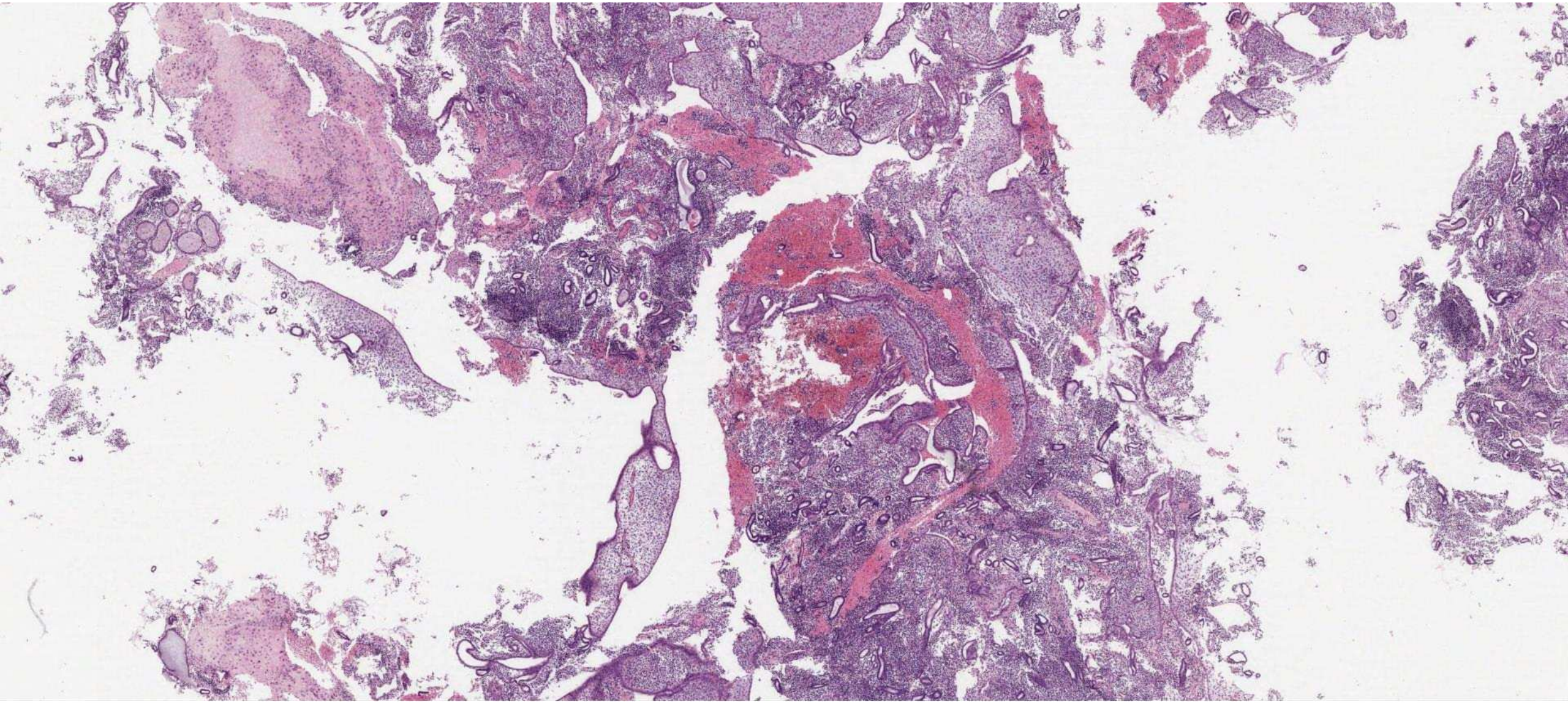

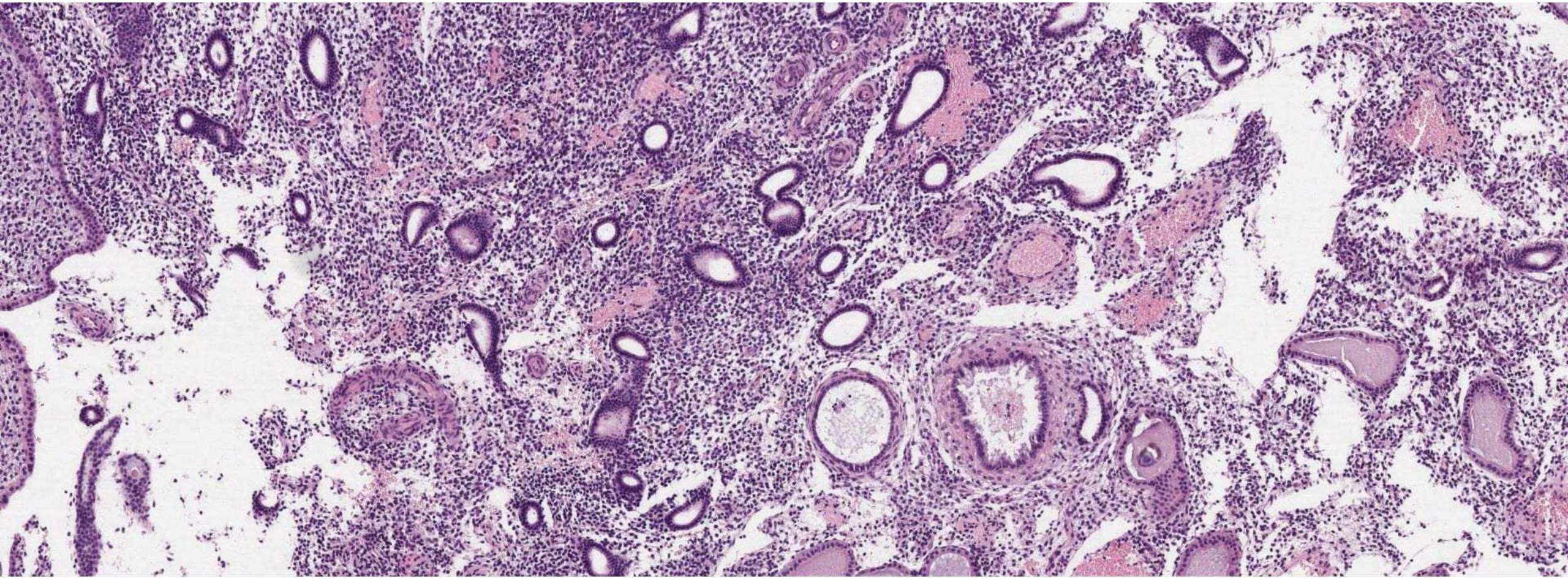

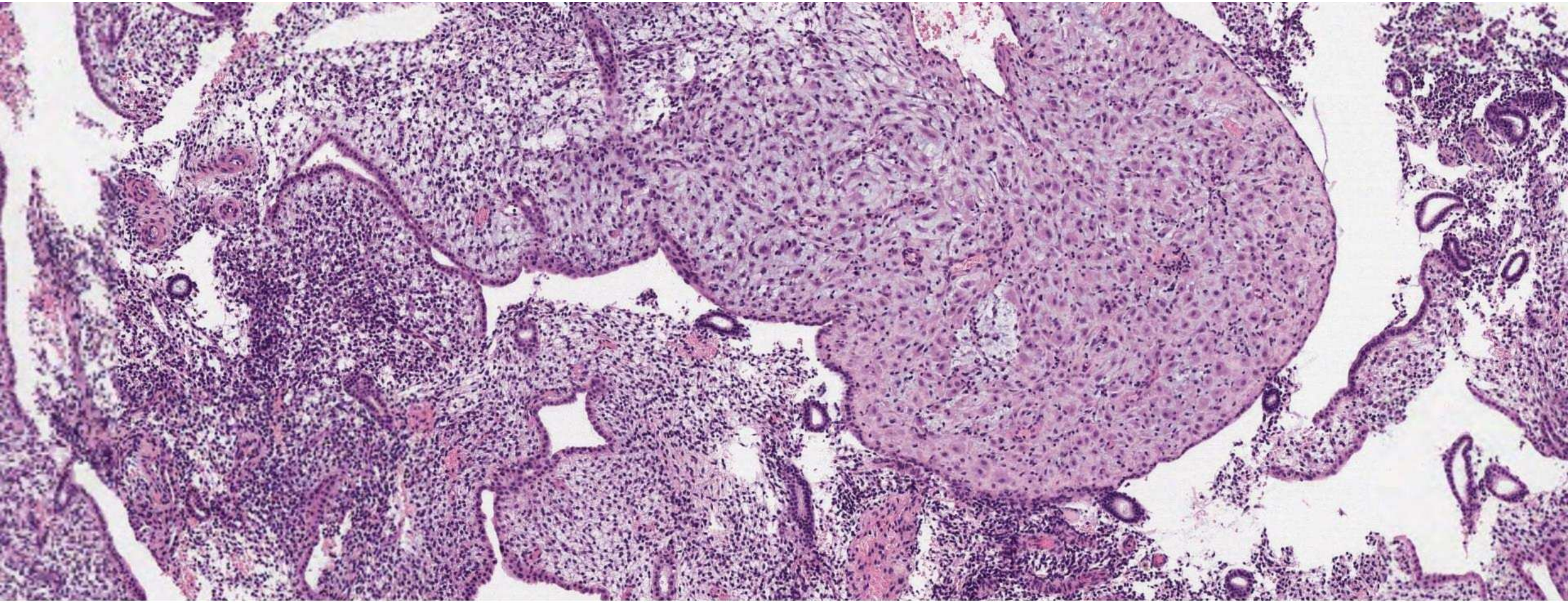

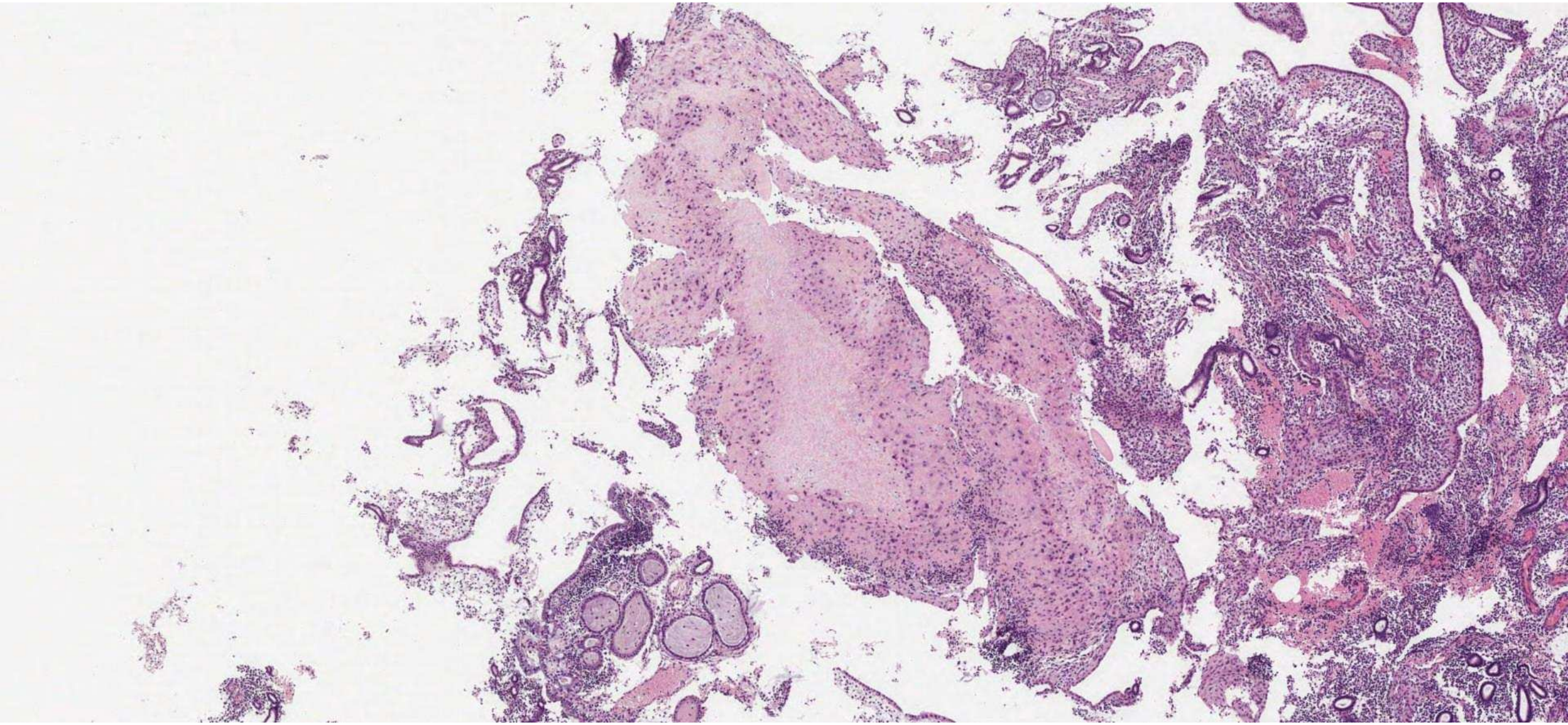

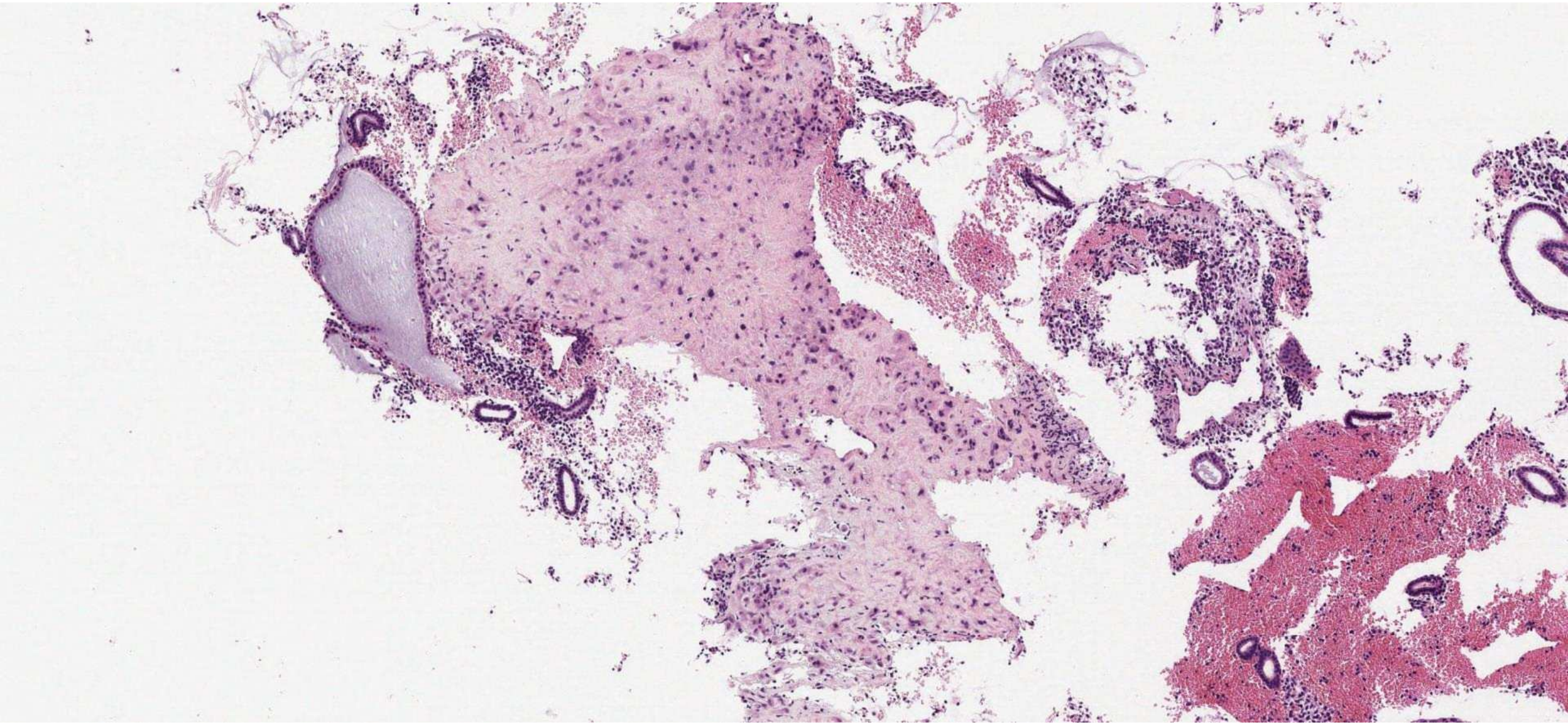

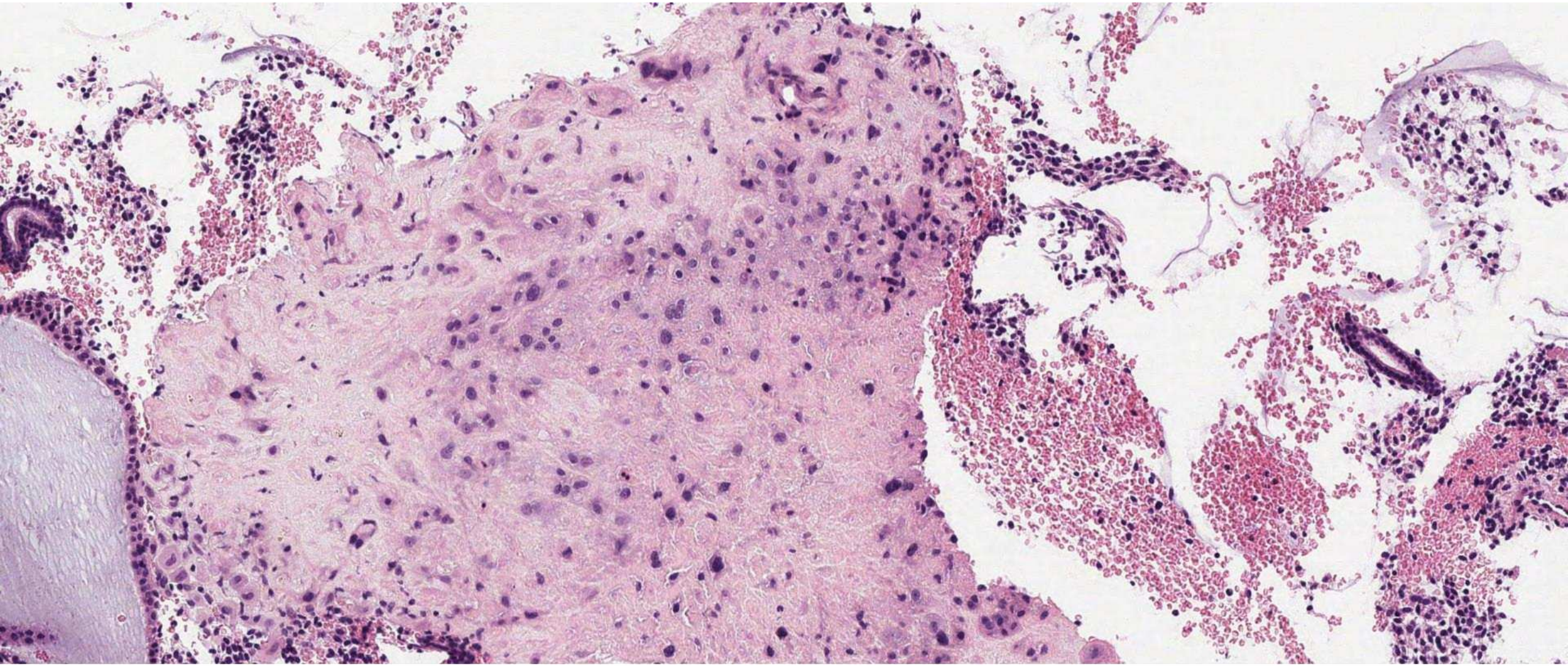

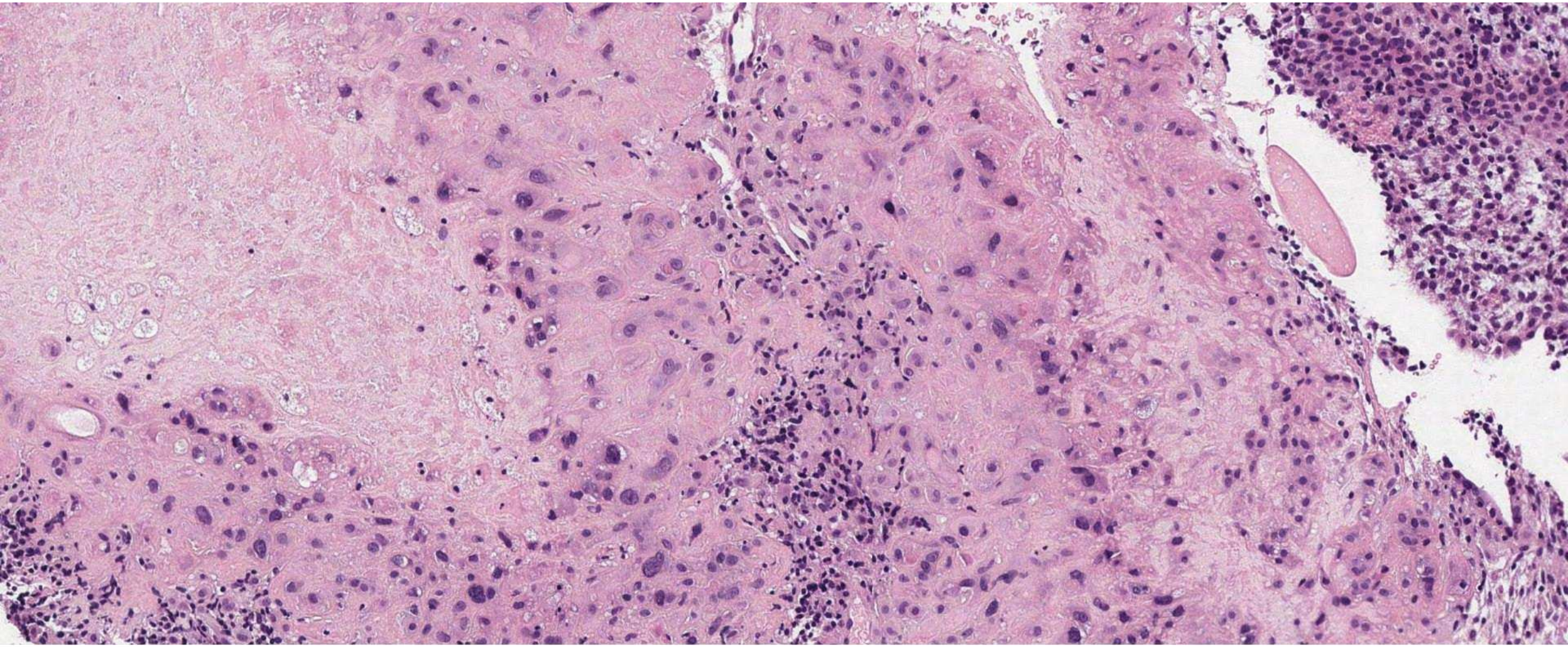

Placental site nodule

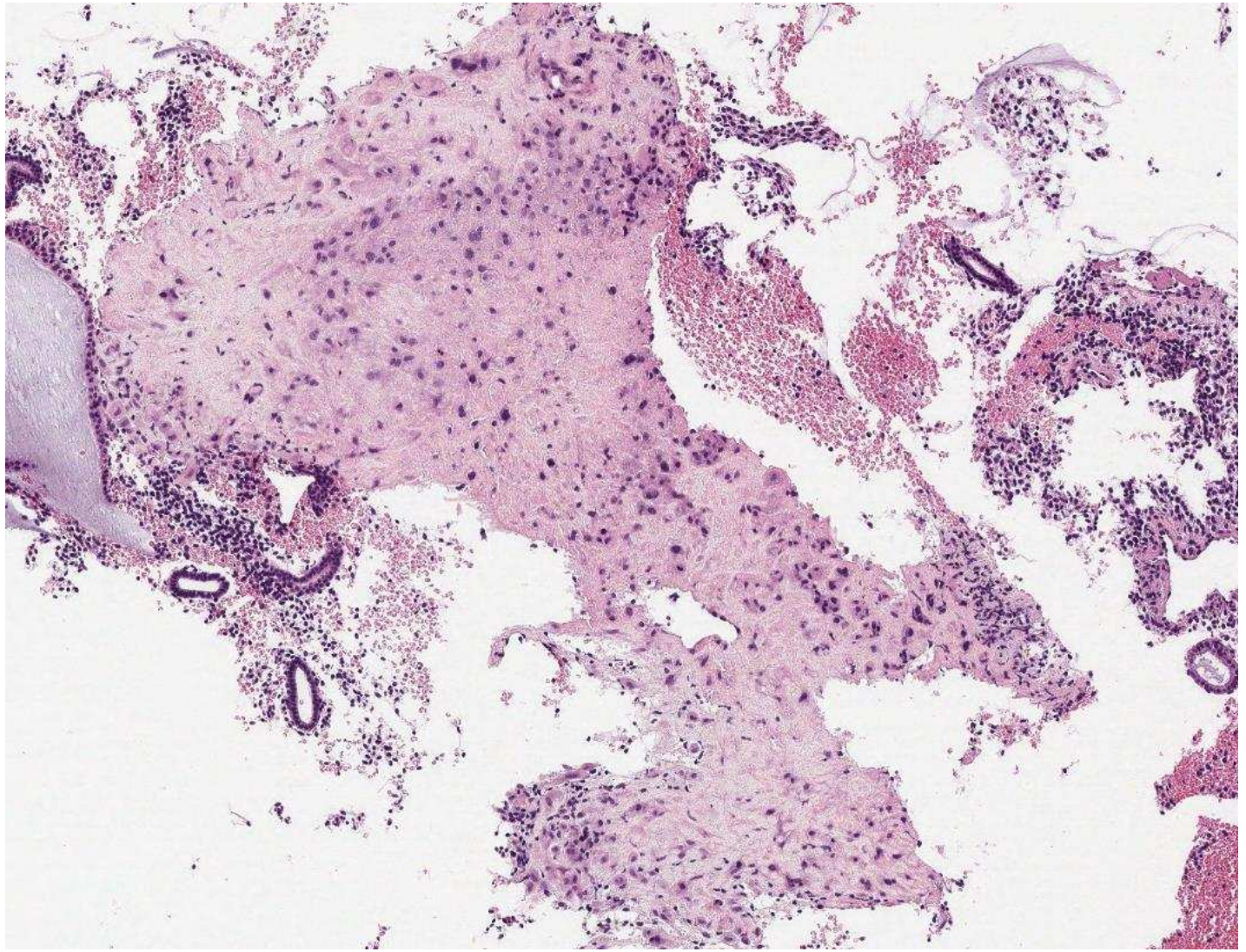

Case 15 – Placental site nodule

Principle histological features

- Singly dispersed chorionic type intermediate trophoblast cells arranged in a haphazardly within a circumscribed eosinophilic nodule.
- Cells typically located peripherally; the centre of the nodule is hyalinized.
- The trophoblast cells often appear pleomorphic and can have large, hyperchromatic, smudgy nuclei. Multinucleation is possible.

Case 15 – Placental site nodule

DDx and how to resolve

▪ Atypical placental site nodule	A nodule containing trophoblastic cells that appear atypical	Increased cellularity Marked nuclear atypia Iincreased mitotic activity Ki-67 index >5%.
▪ Epithelioid trophoblastic tumour	Similar cytomorphology	Larger, more cellular, more atypia Necrosis Invasion into stroma

Case 15 – Placental site nodule

Answer example:

The endometrial biopsy shows inactive glands set within pseudodecidualised stroma in keeping with exogenous progesterone therapy effect. There is no hyperplasia, atypia or malignancy.
There are hypocellular solid nodules containing dispersed, pleomorphic intermediate trophoblast cells set within hyaline matrix. No mitotic figures are identified.

Diagnosis: Placental site nodule (PSN)

- PSN is a benign lesion typically diagnosed incidentally.
- They can present up to 8 years post partum.
- Atypical placental site nodules, which represents a precursor to epithelioid trophoblastic tumour, are expected to be larger, associated with increased cellularity, marked nuclear atypia, increased mitotic activity and ki-67 index >5%.
- The trophoblastic cells would be expected to react to CKs, inhibin, PLAP, GATA3 and p63 (hyalinised decidua would be negative for all of the above)

Case 16

- Specimen: Omental biopsy
- Age: 69
- Clinical: Ovarian mass



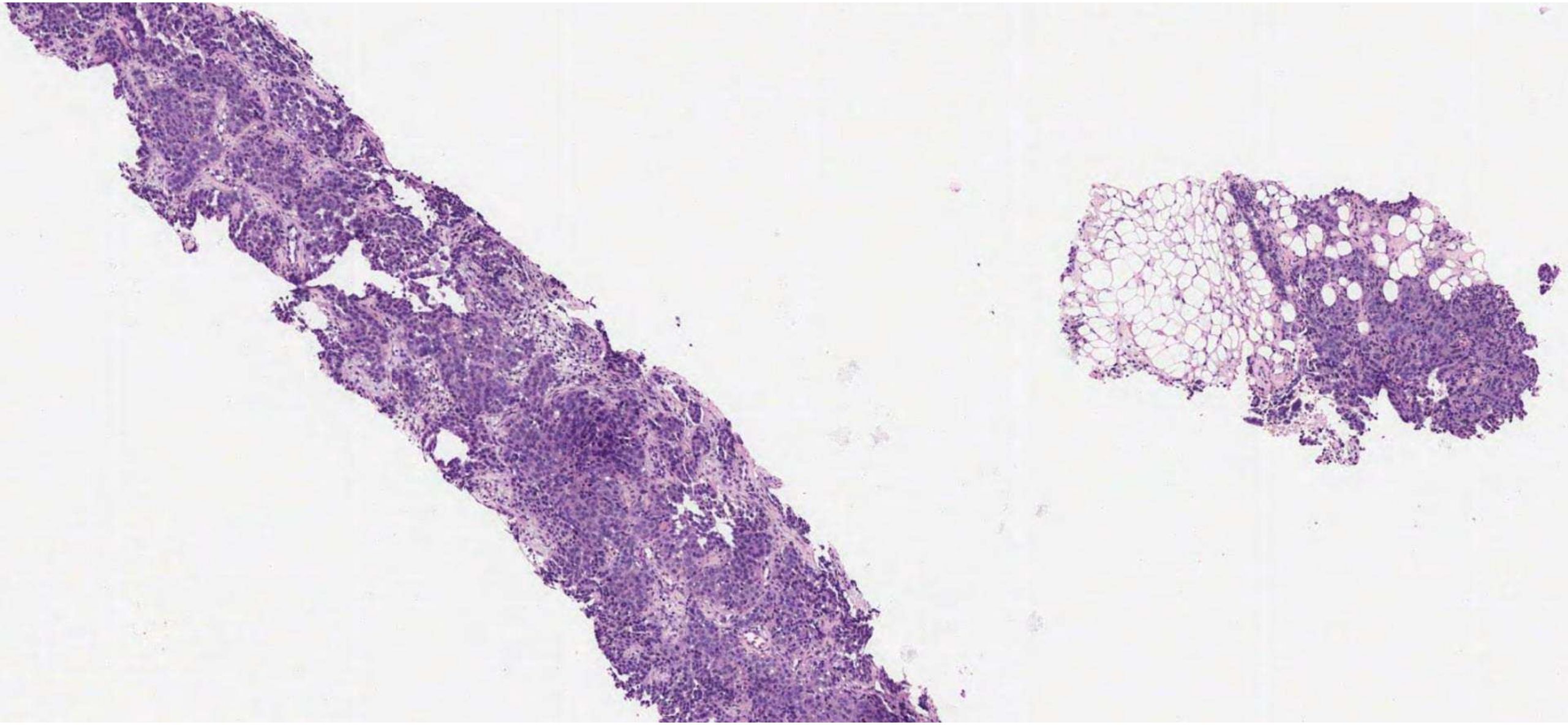

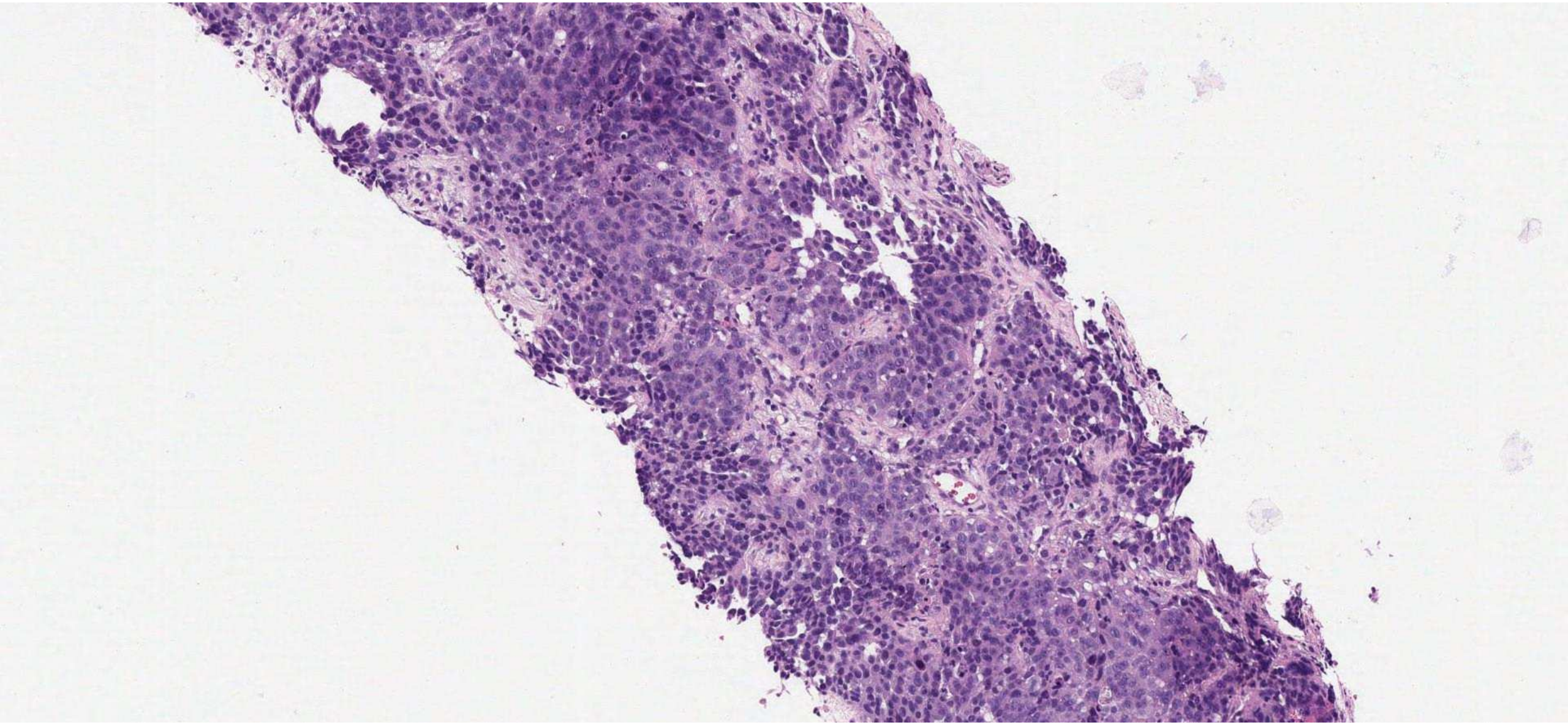

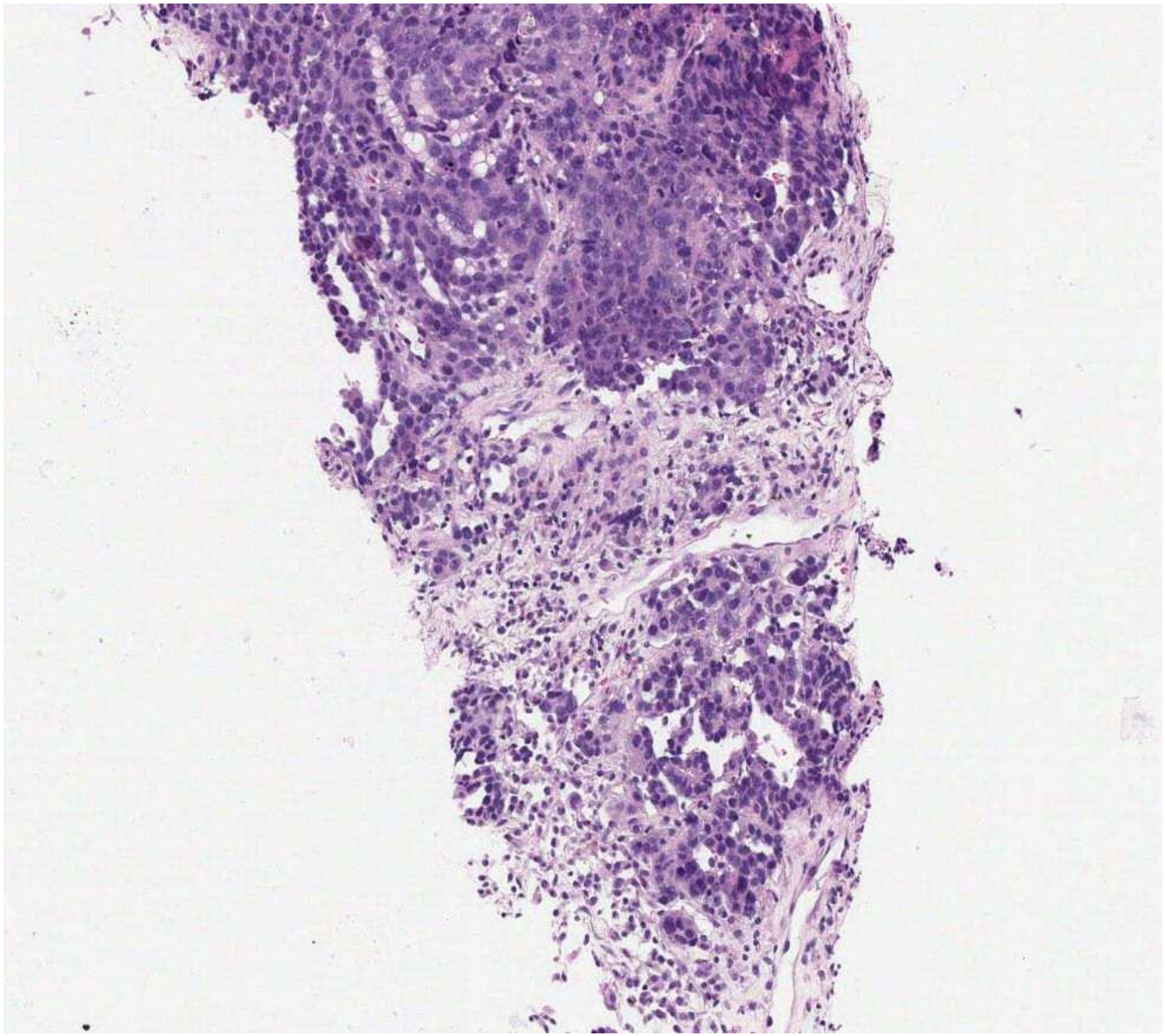

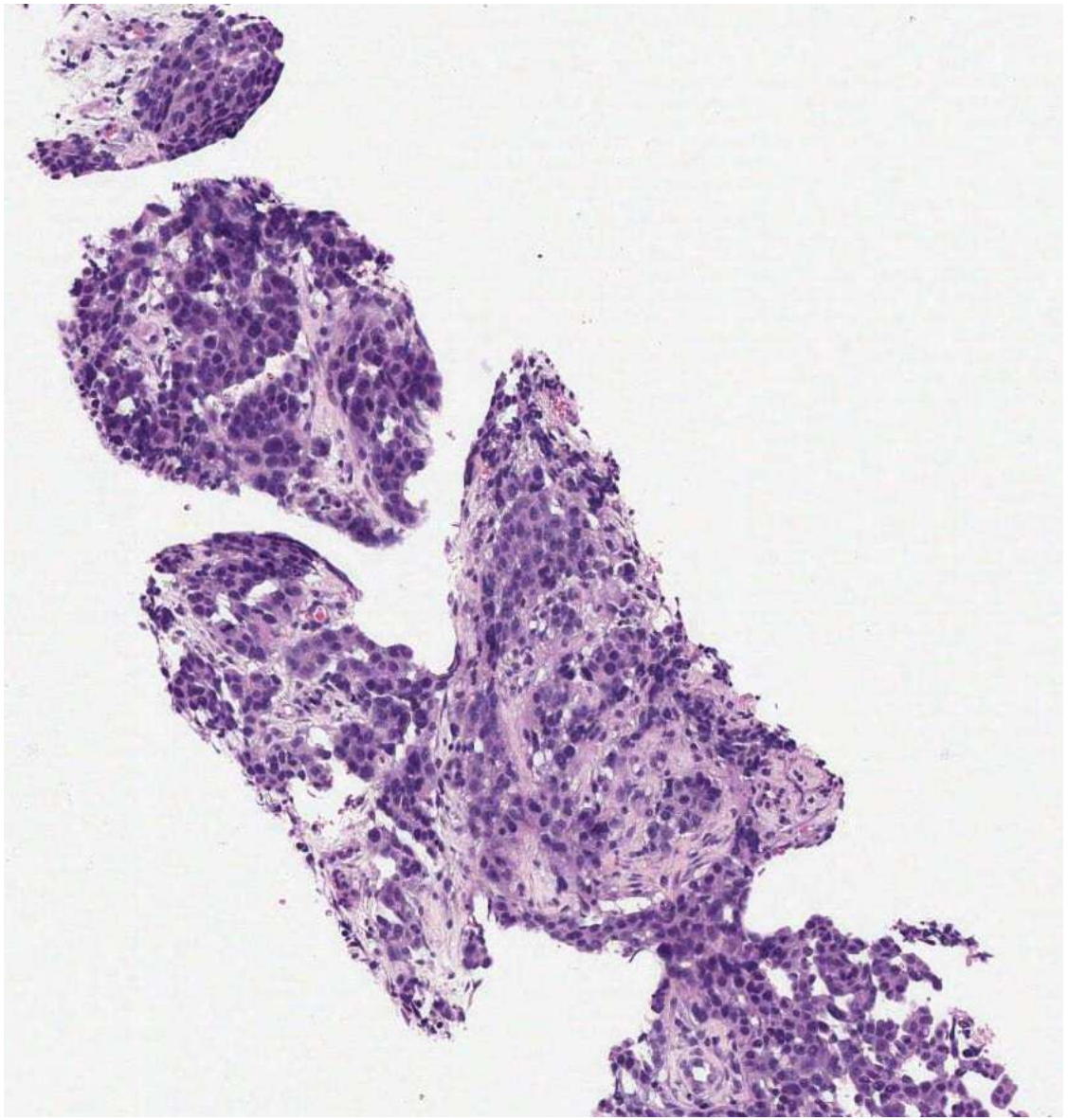

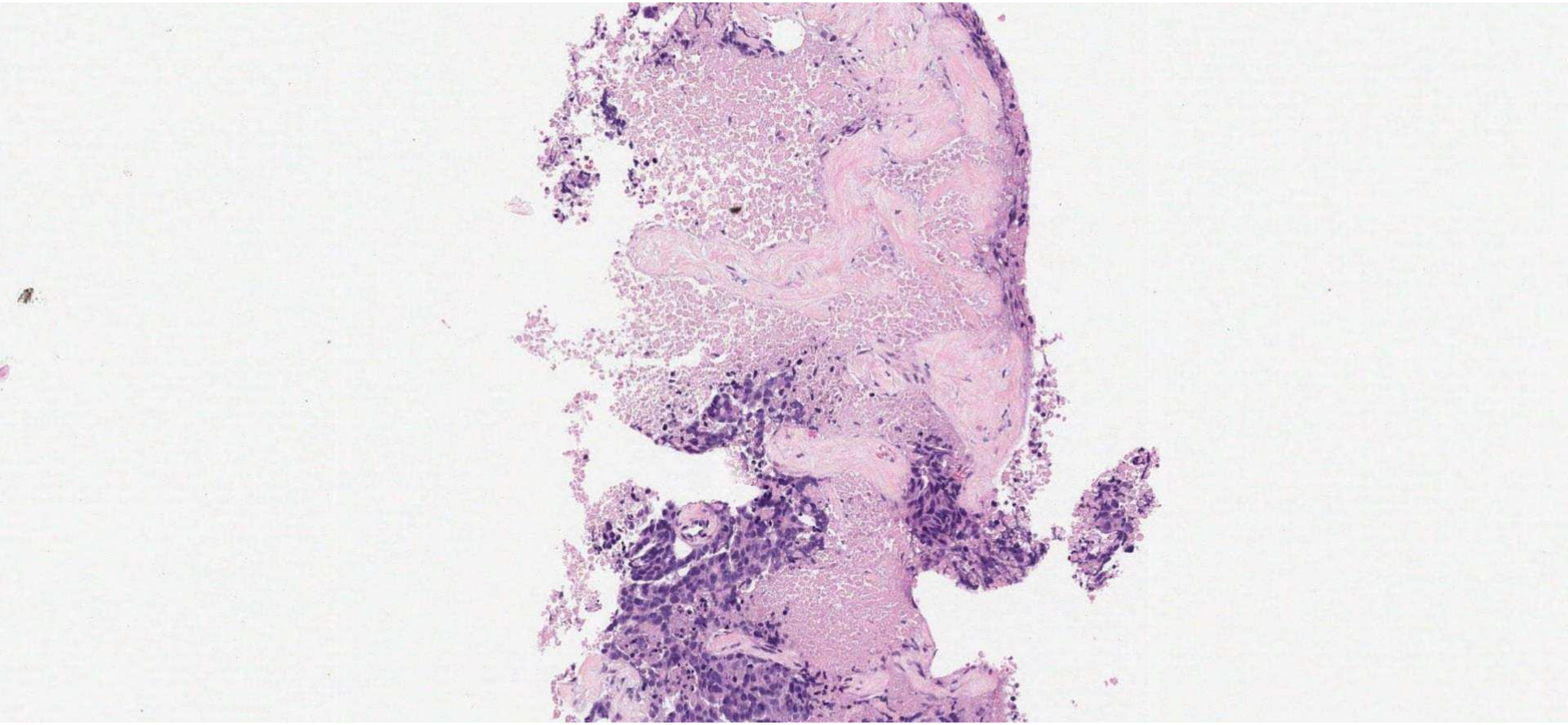

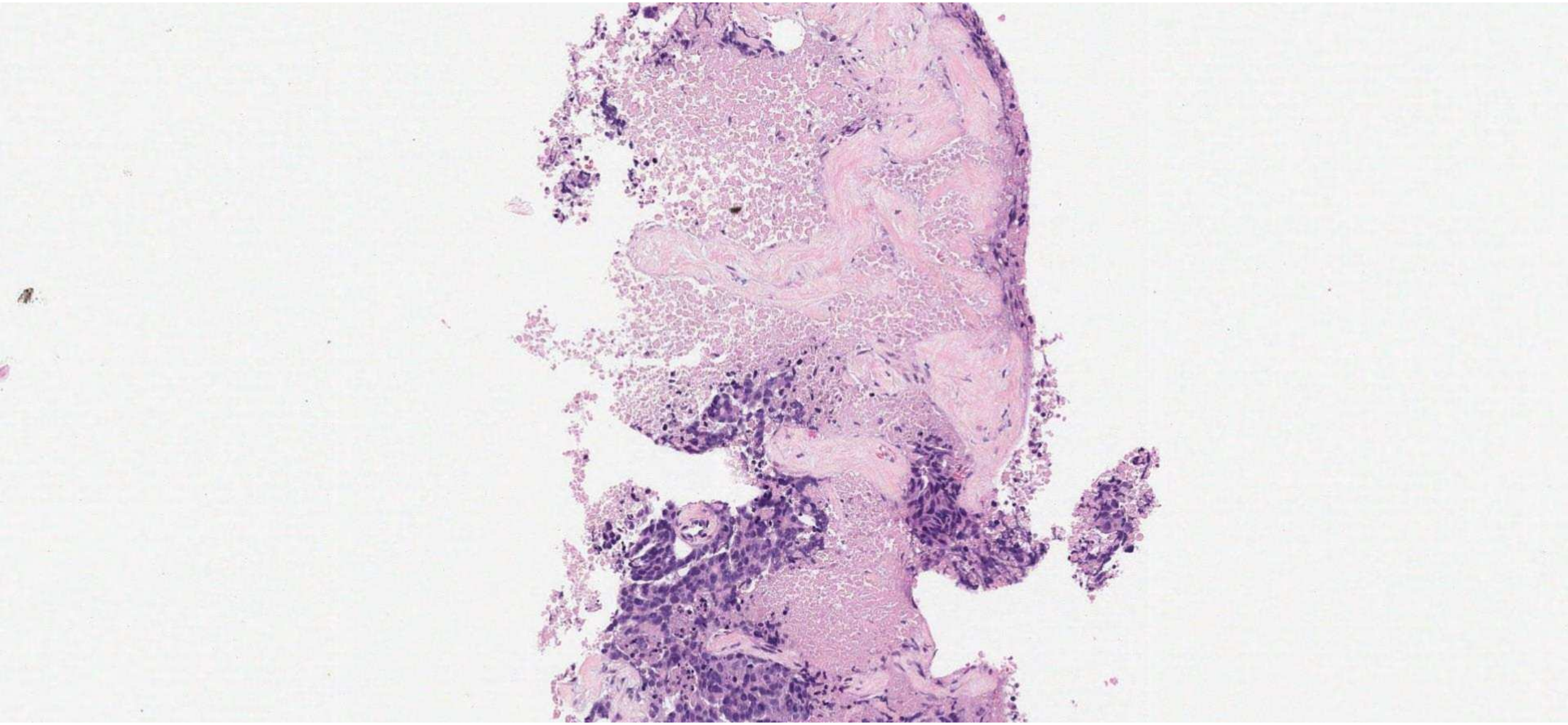

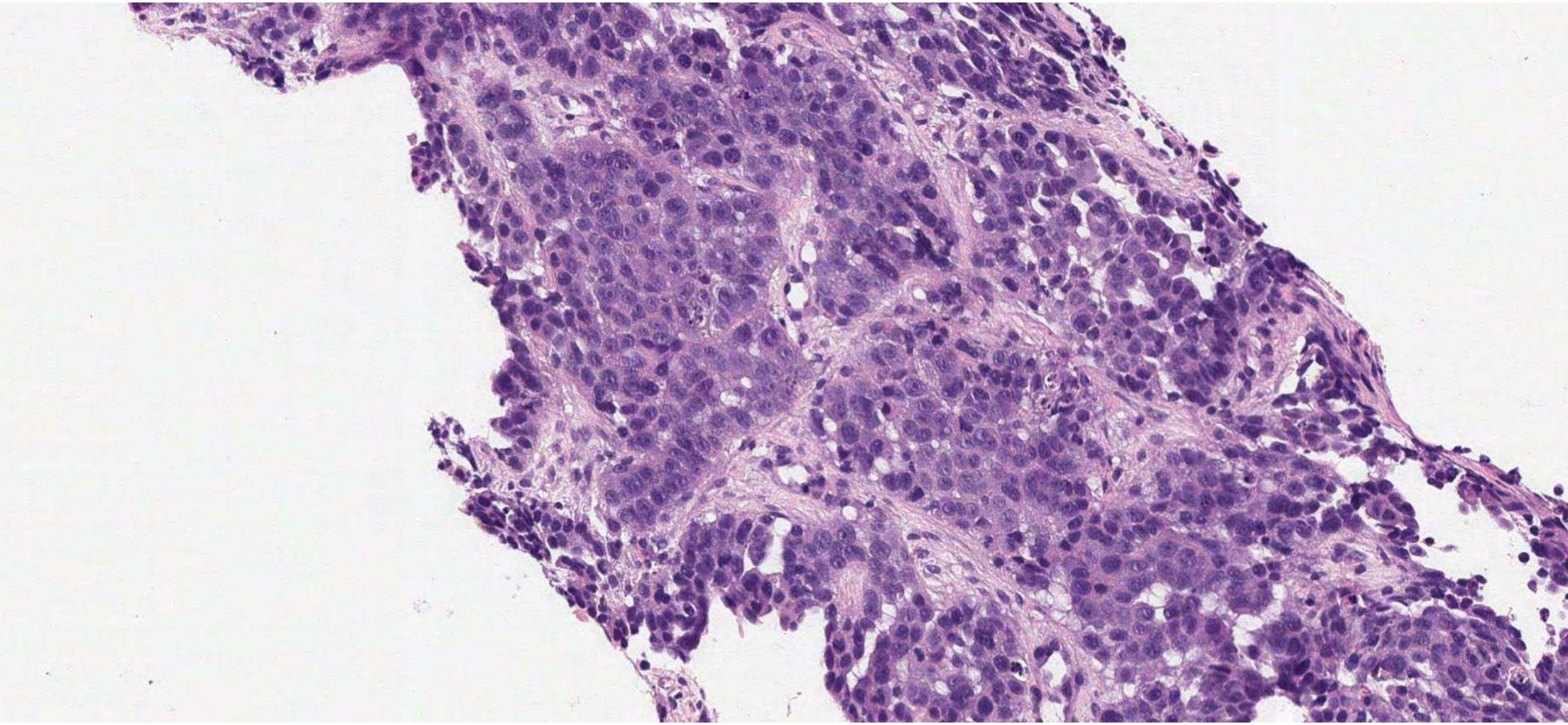

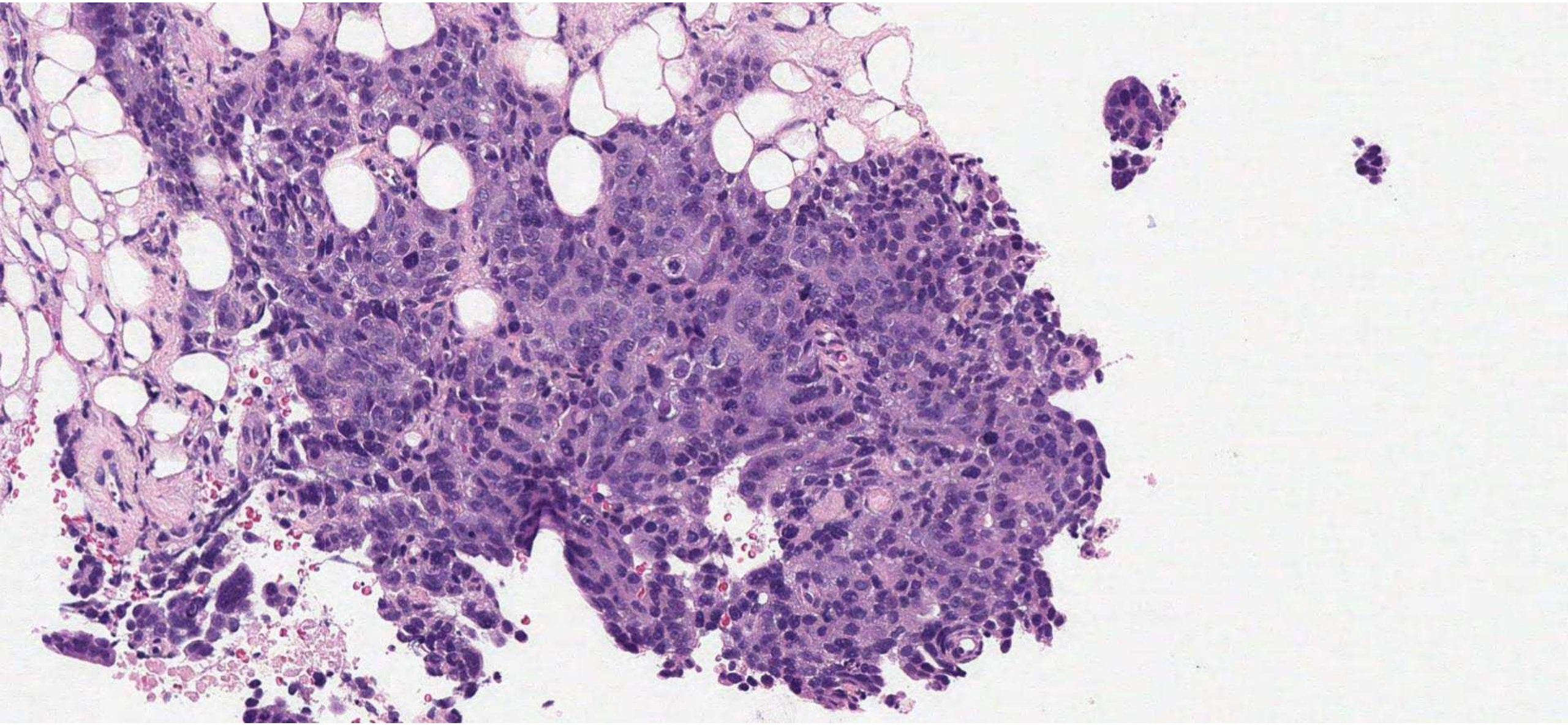

Metastatic high-grade carcinoma

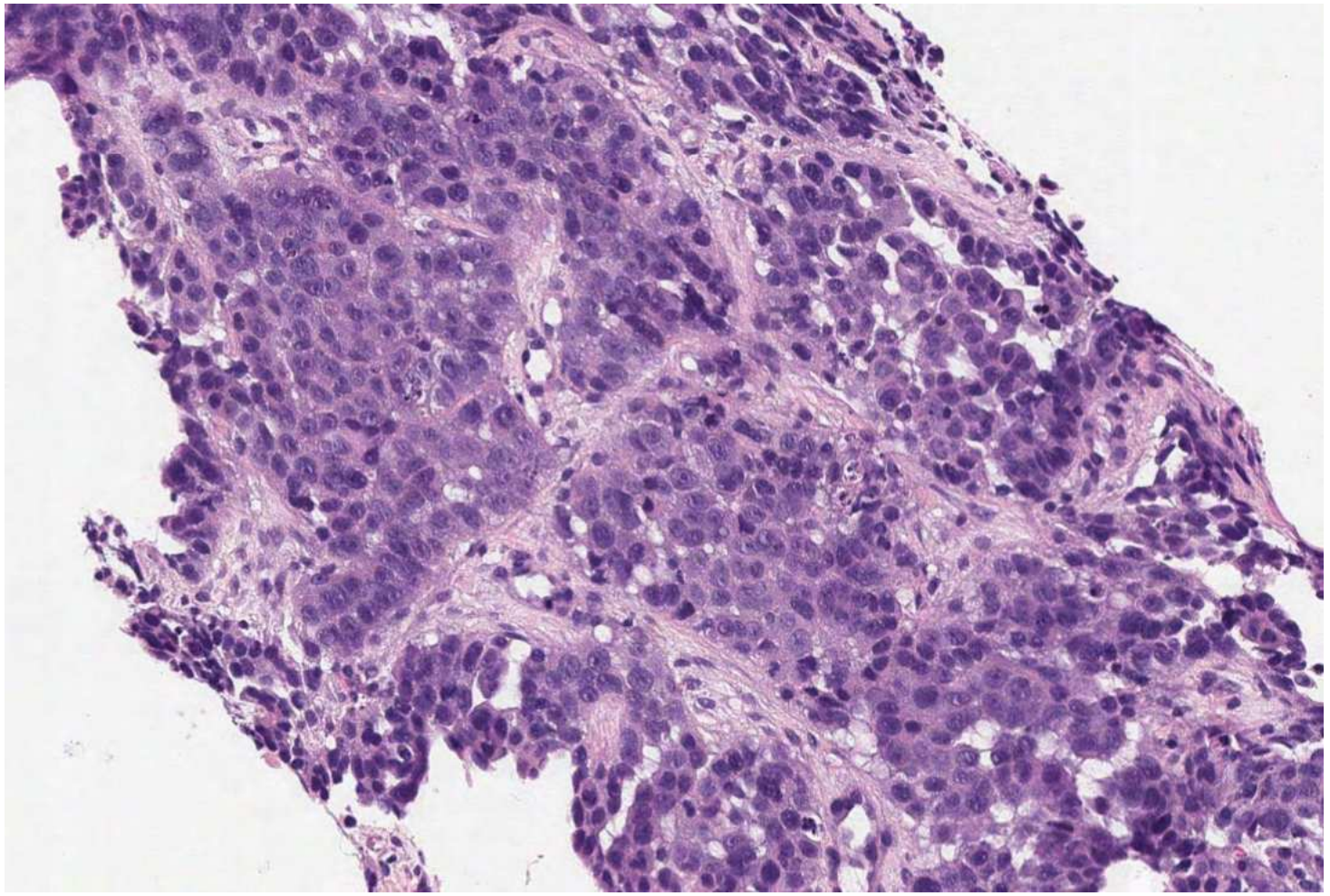

Case 16 – Metastatic carcinoma

Answer example:

This biopsy shows a high grade carcinoma infiltrating fibrofatty stroma. Malignant epithelial cells shows high grade nuclear atypia with pleomorphic, hyperchromatic nuclei and prominent nucleoli. There are areas of coagulative necrosis. Abortive gland formation is seen.

Diagnosis: Metastatic high grade carcinoma

Comment: Immunohistochemistry is required. Based on morphology and the presence of an ovarian mass, tubo-ovarian high grade serous carcinoma is the preferred differential.

Case 16 – Metastatic carcinoma

Extra marks?

IHC	CK7	CK20	PAX8	WT1	P53	CDX2	SATB2
Tubo-ovarian high grade serous	+	-	+	+	Aberrant	-	-
High grade endometrioid	+	-	+	-	Wild type / maybe aberrant	-	-
Colorectal carcinoma	-	+	-	-	Wild type	+	+

- If IHC supports a diagnosis of high grade serous carcinoma, I would send for homologous recombination deficiency testing (HRD) + BRCA testing which can identify BRCA syndromes and can predict response to PARP inhibitor therapy

Case 17

- Specimen: Ovary (TAH BSO)
- Age: 45
- Clinical: Hysterectomy for grade 1 endometrioid endometrial carcinoma







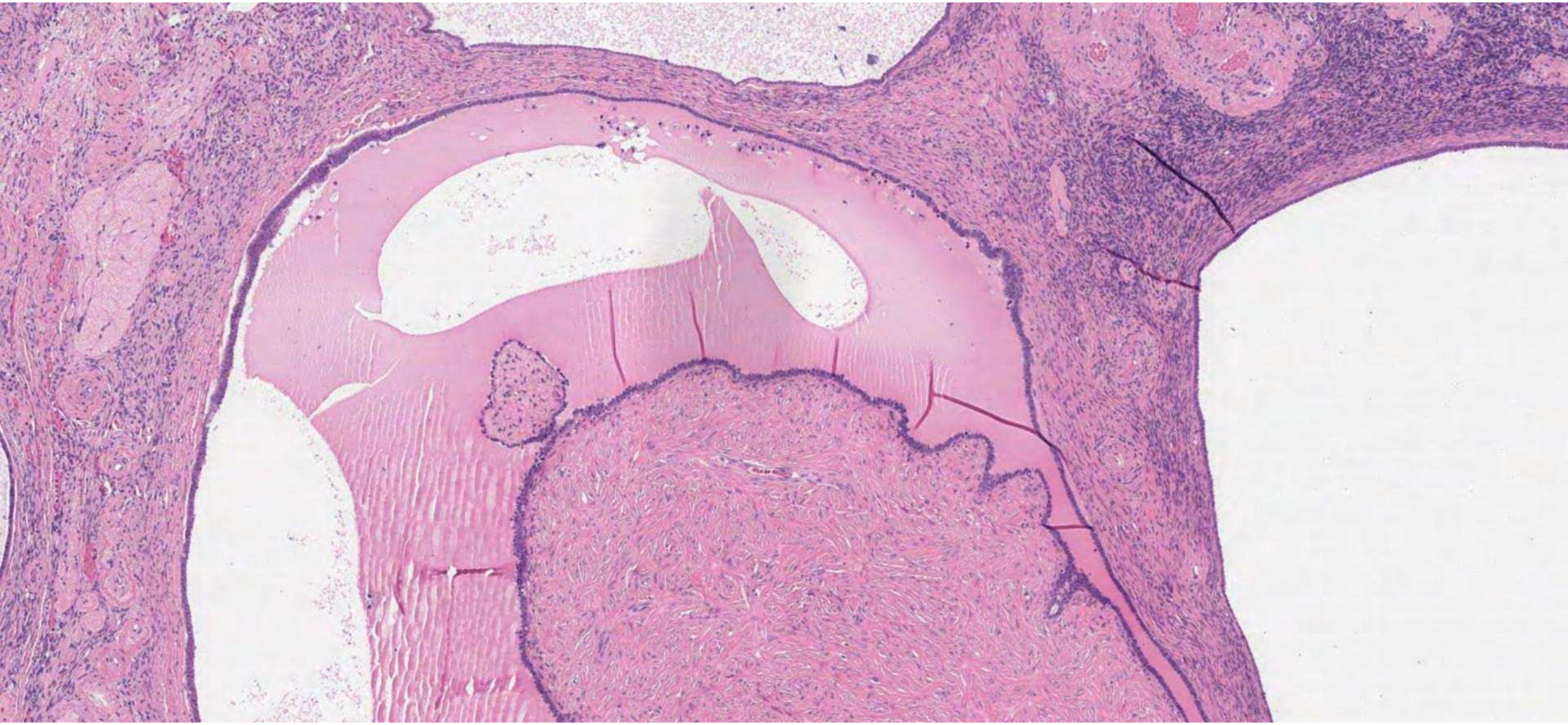

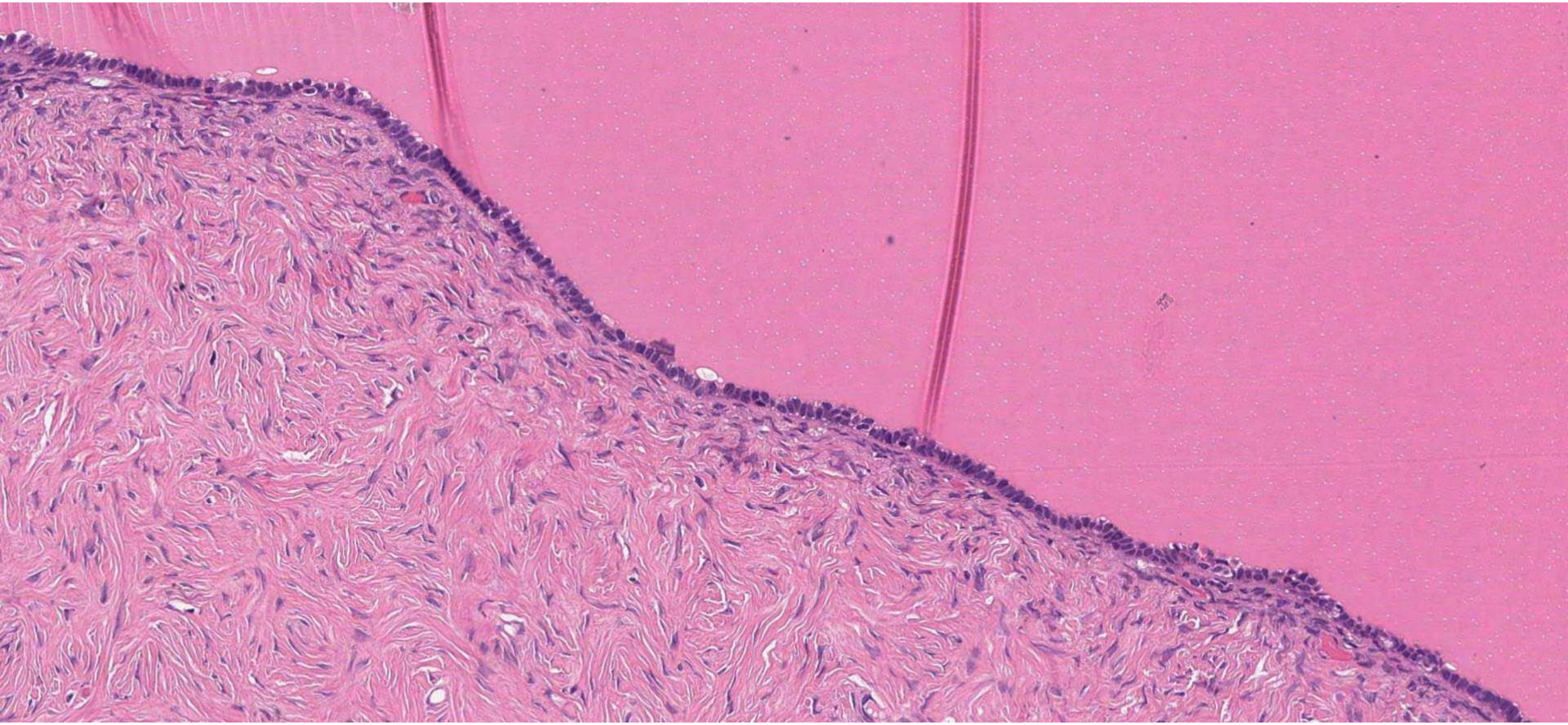

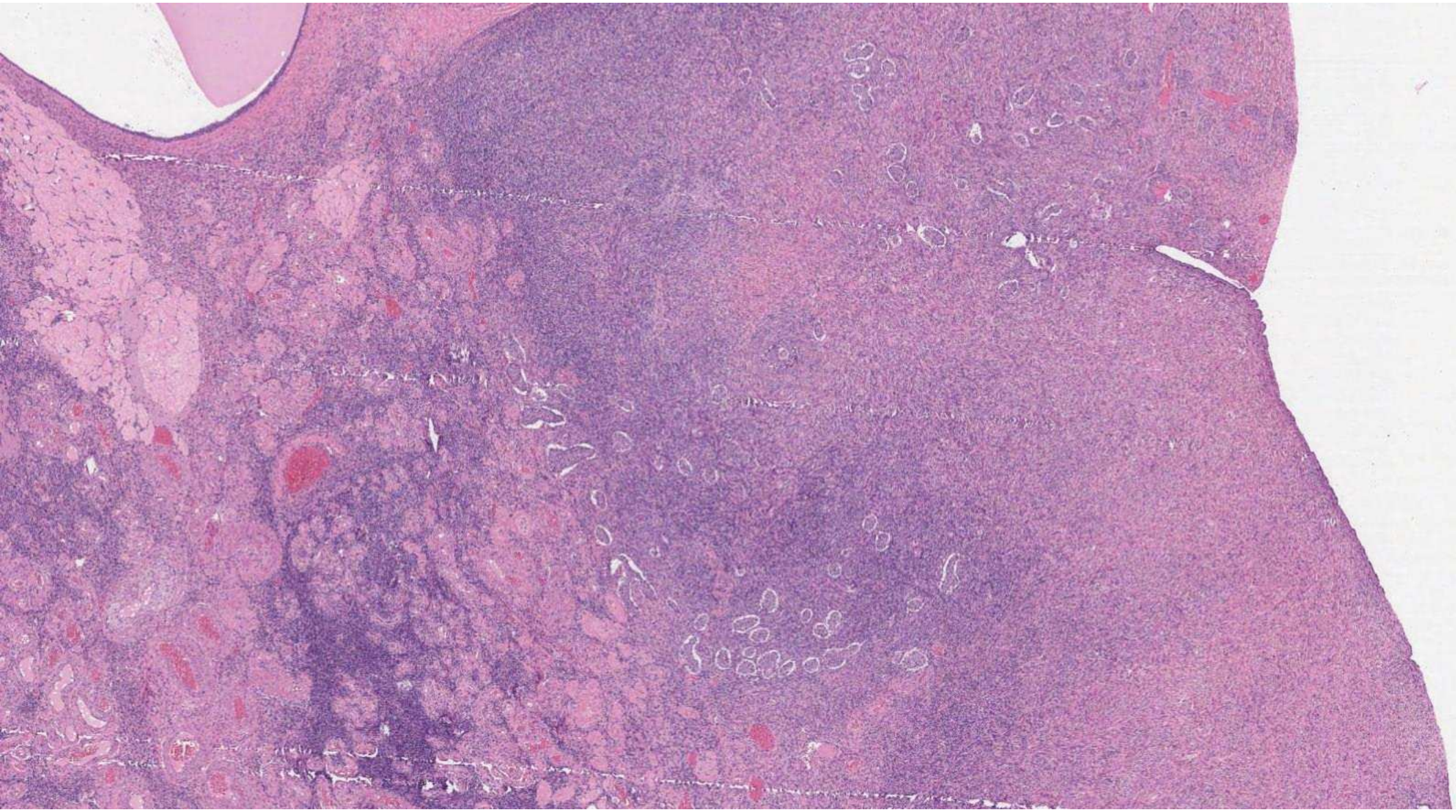

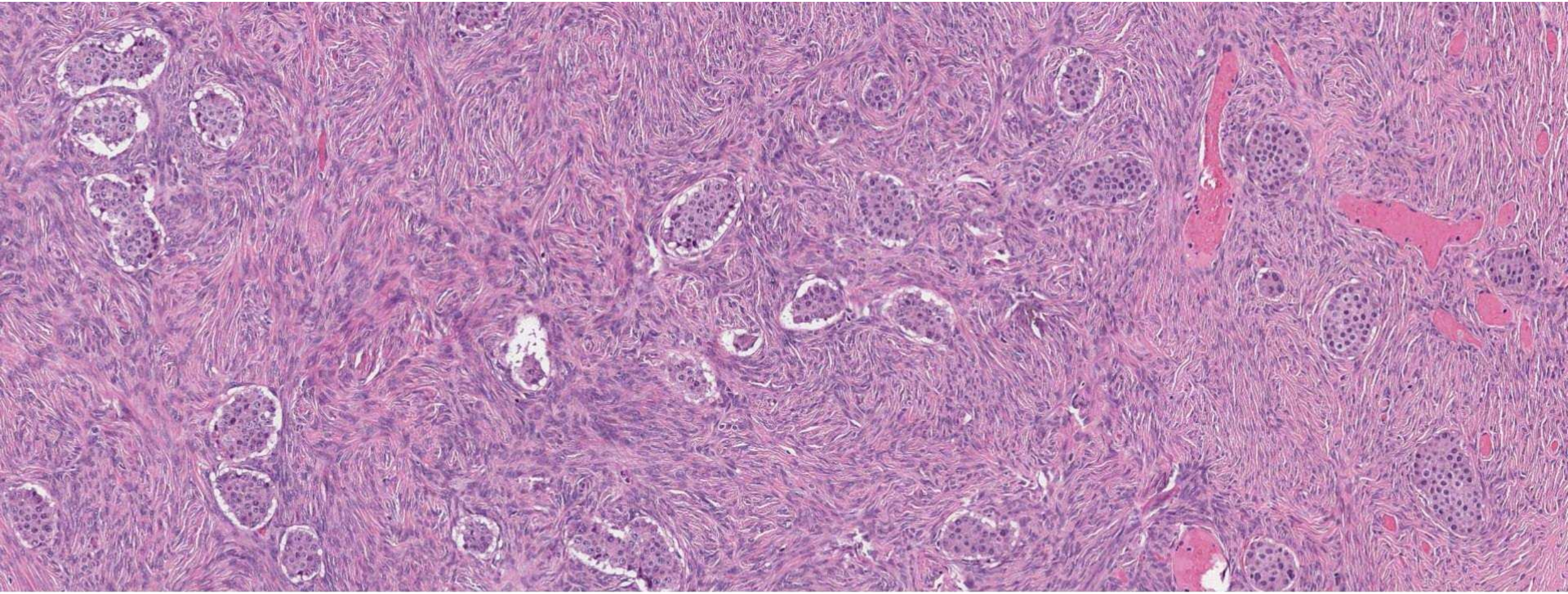

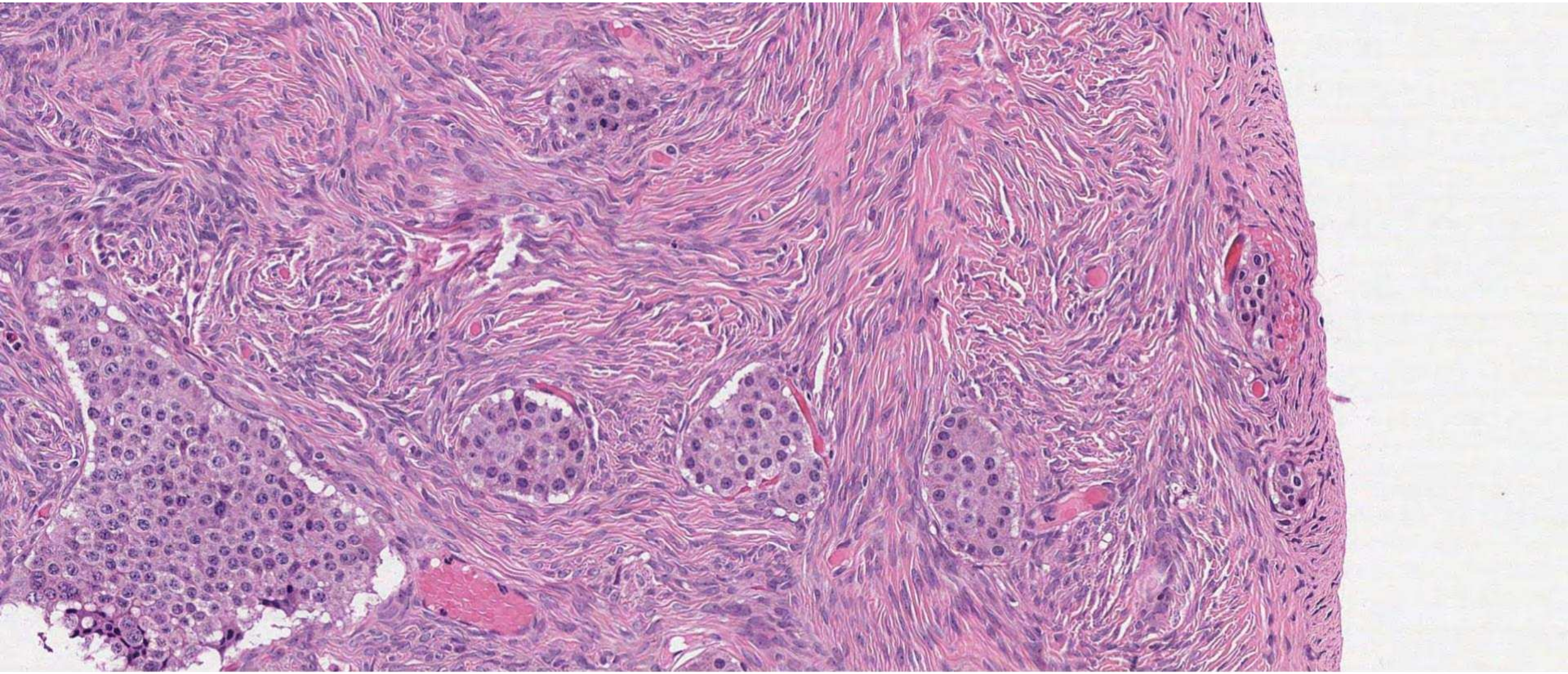

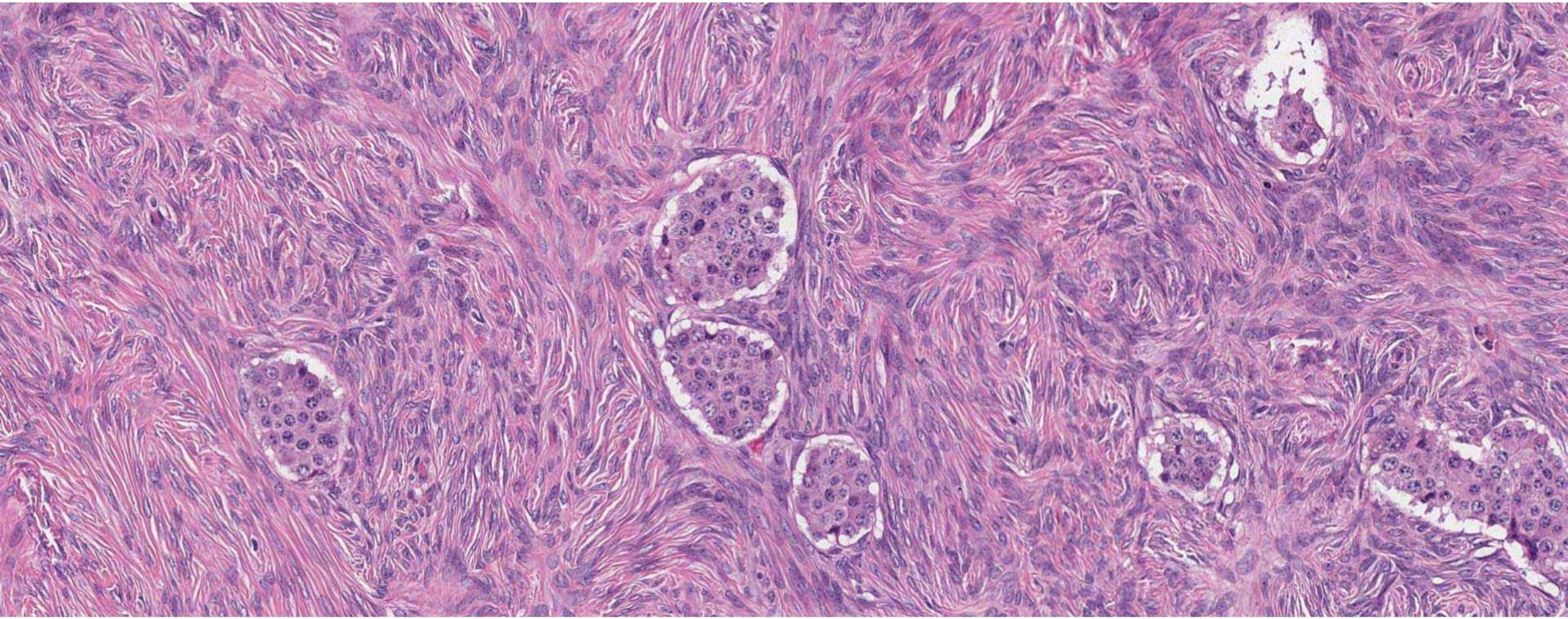

Well-differentiated neuroendocrine tumour
&
(Serous cystadenofibroma)

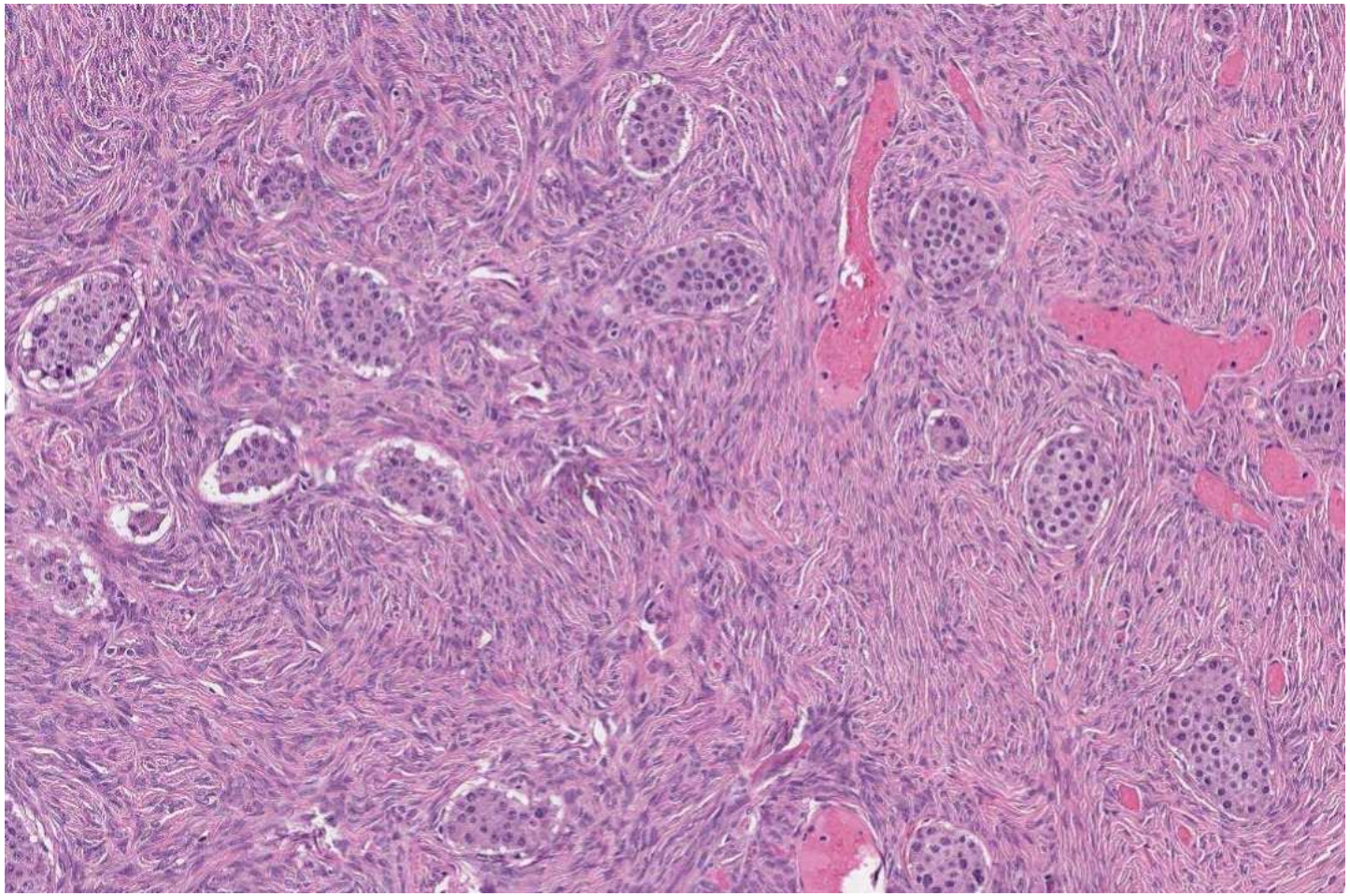

Case 17 – Well differentiated NE tumours

OVARIAN CARCINOID - Principle histological features

- Usually a small, solid (or occasionally cystic) nodular tumour.

- Insular carcinoid: Solid nests, often with peripheral acini
- Trabecular carcinoid: Ribbons, cords, trabeculae
- Mucinous carcinoid (rare): Acini (with goblet cells) floating in extra-cellular mucin

- Uniform cells with central, round to oval nuclei, salt and pepper chromatin, granular cytoplasm.

- Can occur as pure monodermal teratoma or be seen in association with mature teratoma or struma ovarii.

Case 17 – Well differentiated NE tumours

METASTATIC WELL-DIFFERENTIATED NEUROENDOCRINE TUMOURS - Principle histological features

- Most commonly insular; trabecular also reported.
- Mucinous carcinoid resembles goblet cell carcinoma of appendix, so this should be considered.
- No cytomorphologic differences

- More likely to be bilateral and have a multinodular low power appearance with peripheral / cortical distribution.
- The presence of an underlying teratoma or struma makes metastasis unlikely.

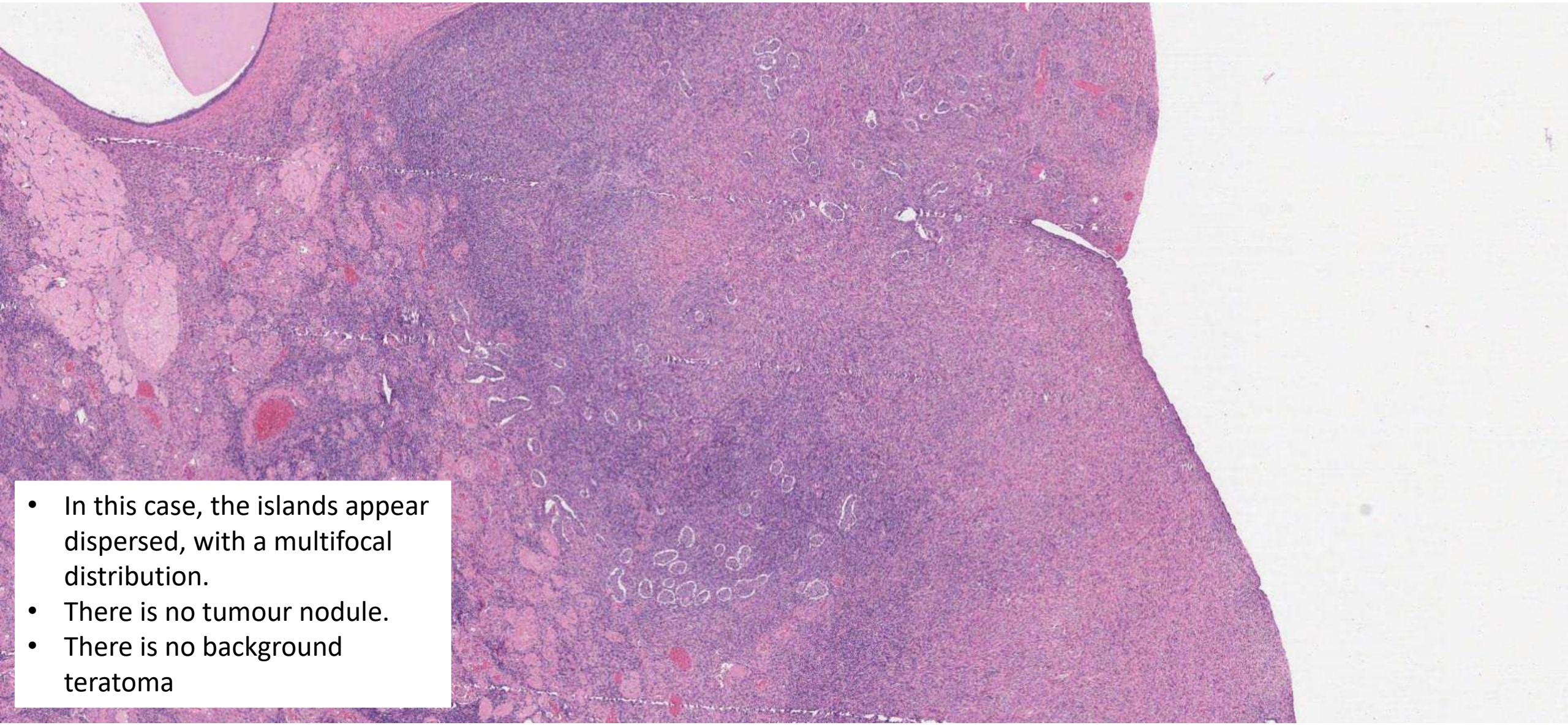

- In this case, the islands appear dispersed, with a multifocal distribution.
- There is no tumour nodule.
- There is no background teratoma

Case 17

- Recognising the carcinoid will probably get you passing mark
- Discussing the possibility of this being metastatic will enhance your score

Answer example:

…Morphological description…

Diagnosis: Well differentiated neuroendocrine tumour: differential diagnosis of metastatic tumour vs primary ovarian carcinoid

Due to the cortical, multifocal distribution of tumour islands, metastasis is favoured. Clinical and imaging correlation is required for this distinction.

Case 17

Additional extra marks?

- Ovarian carcinoids express neuroendocrine markers (synaptophysin, chromogranin, CD56), CDX2 and are typically CK7+ and CK20-.
- As such, IHC is unhelpful in the distinction from metastatic well-differentiated neuroendocrine tumours arising in the GI tract.
- Larger ovarian carcinoids and WD-NETs can uncommonly be associated with carcinoid syndrome: serotonin secretion leads to flushing, tachycardia, GI symptoms and wheeze.

Case 18

- Specimen: Ovary (TAH BSO)
- Age: 49
- Clinical: Hysterectomy for endometrial cancer

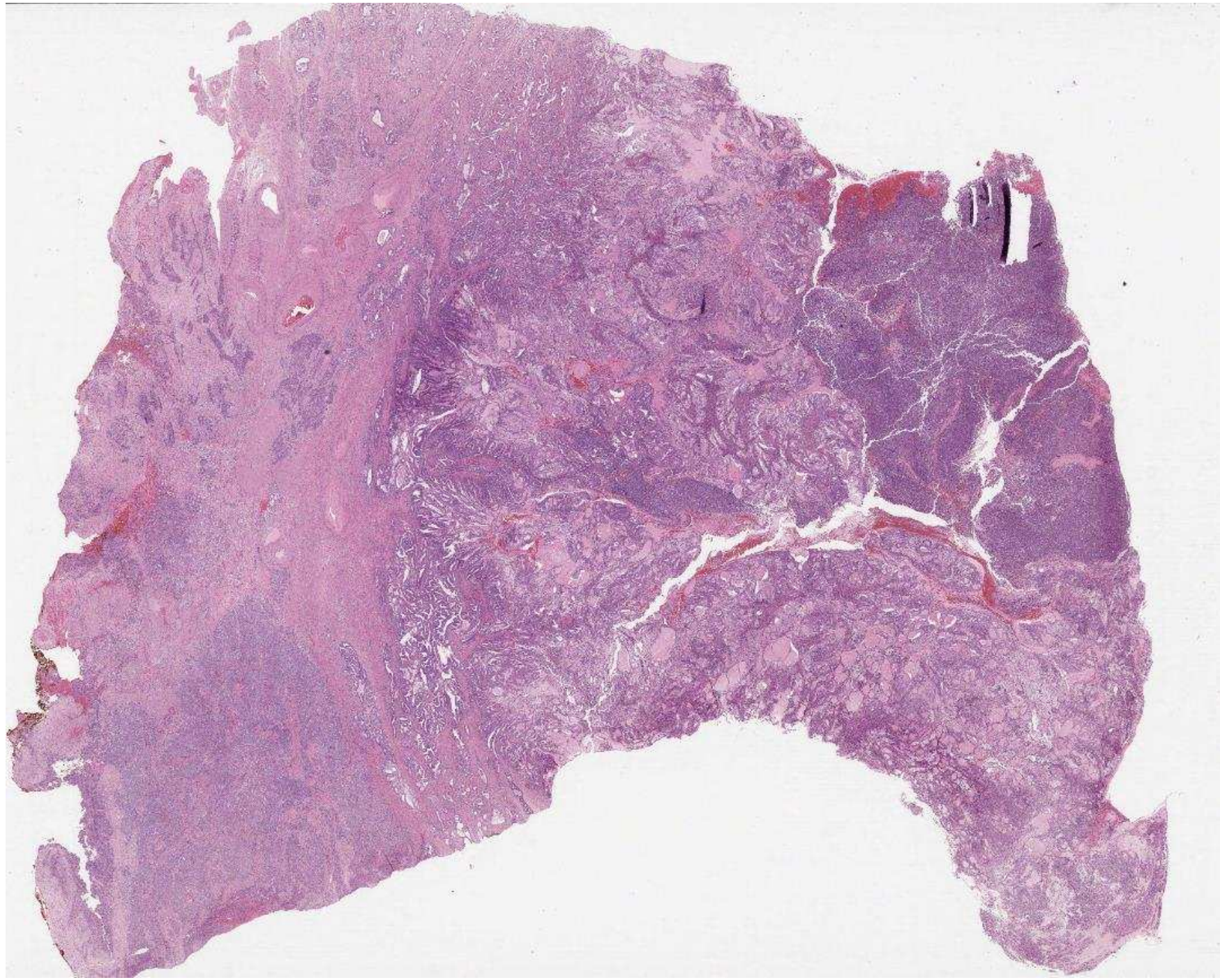

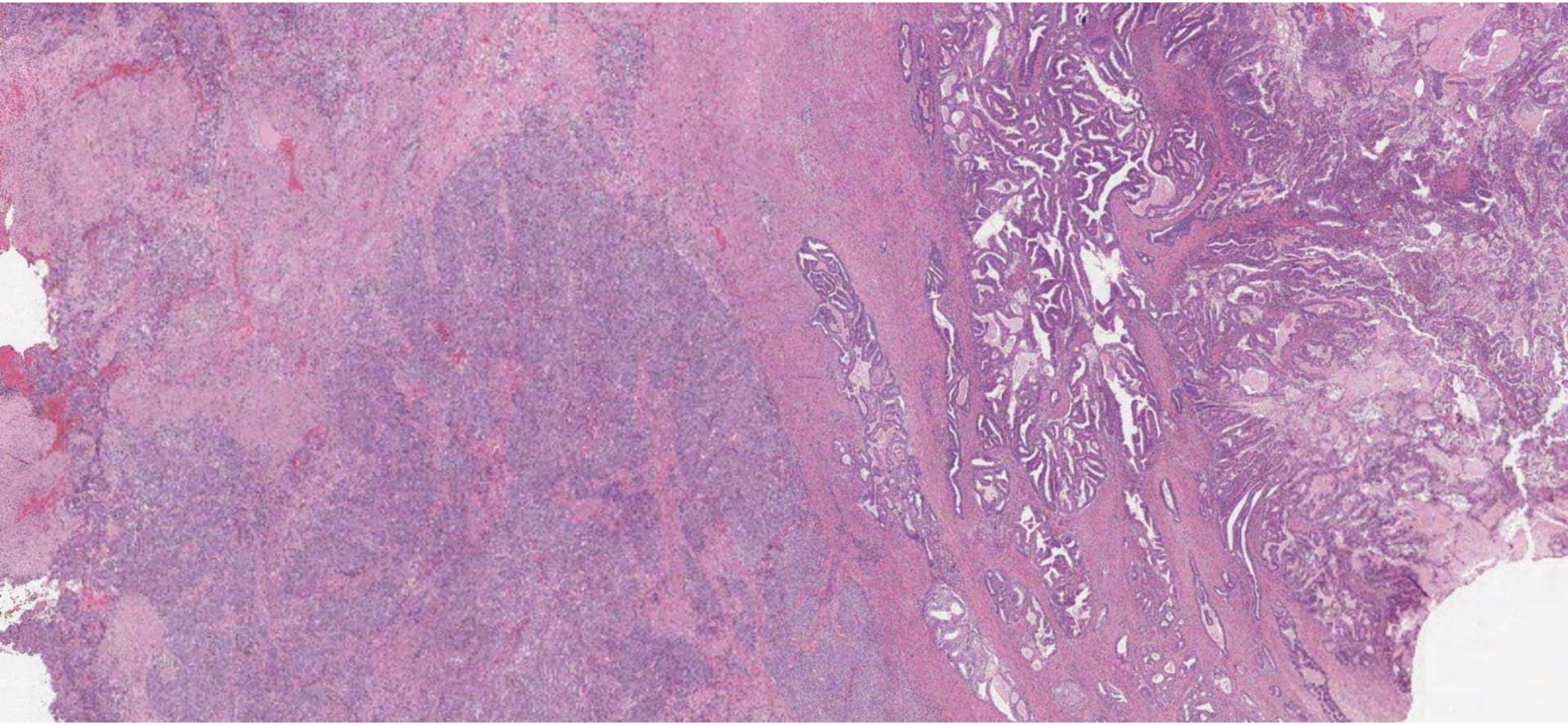

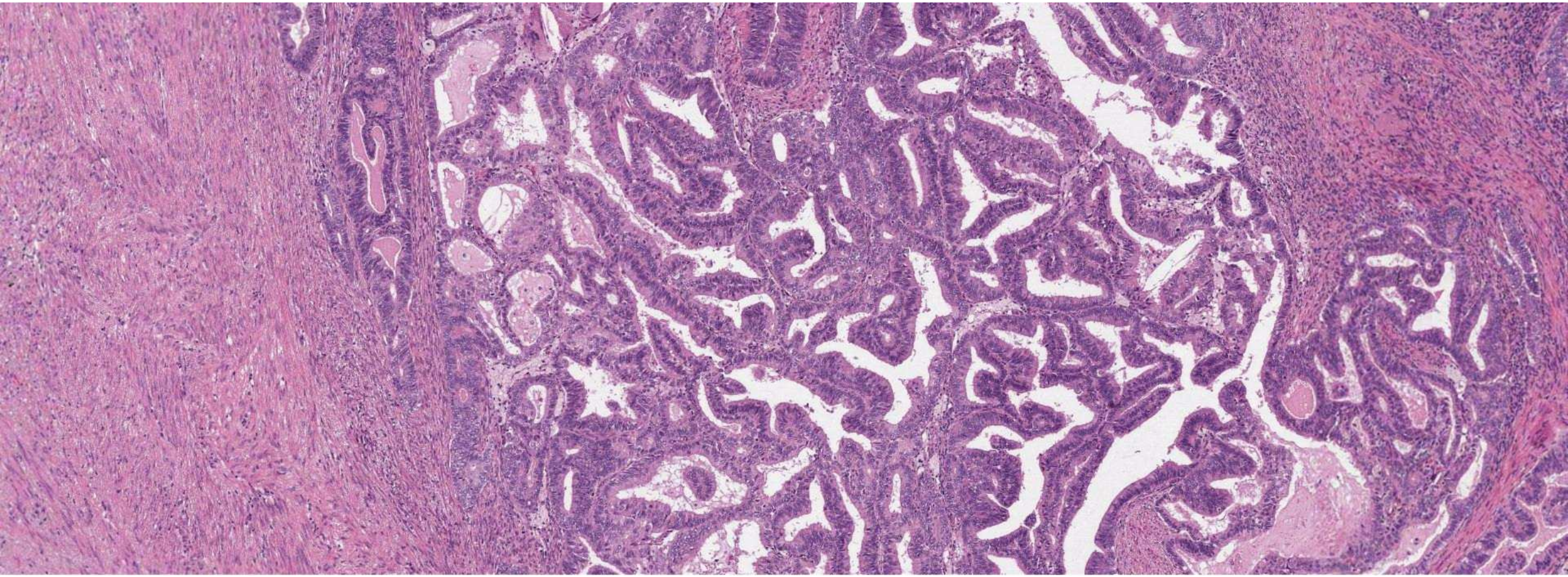

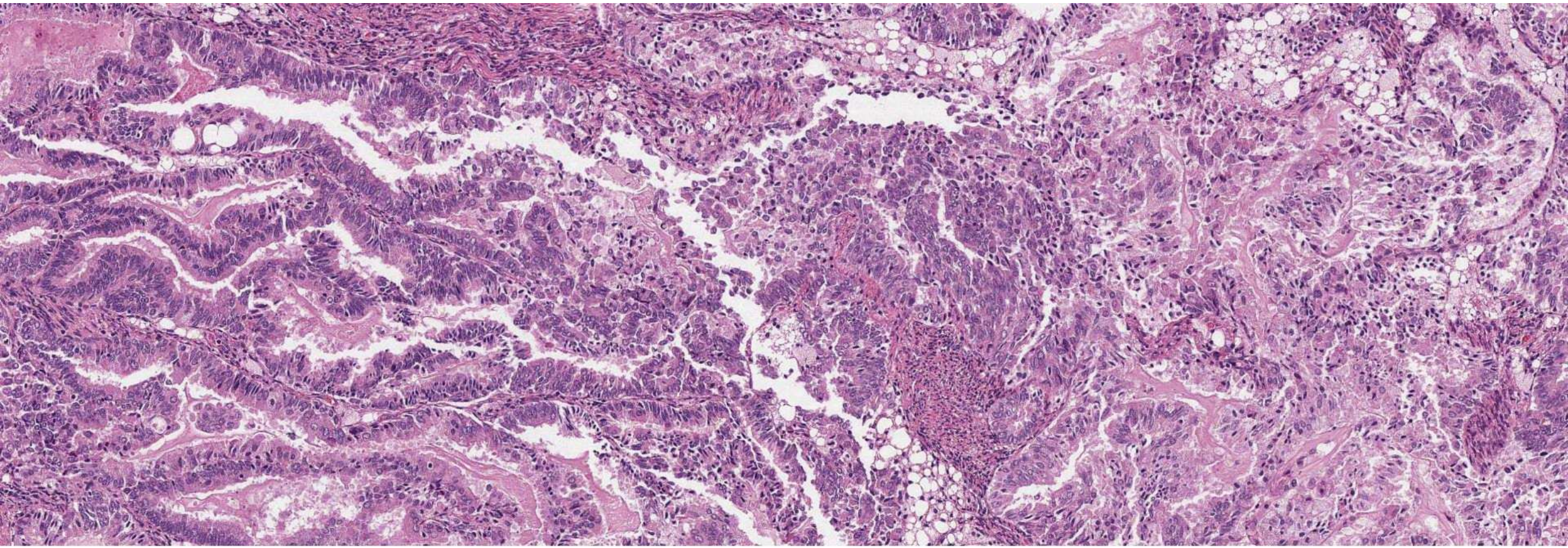

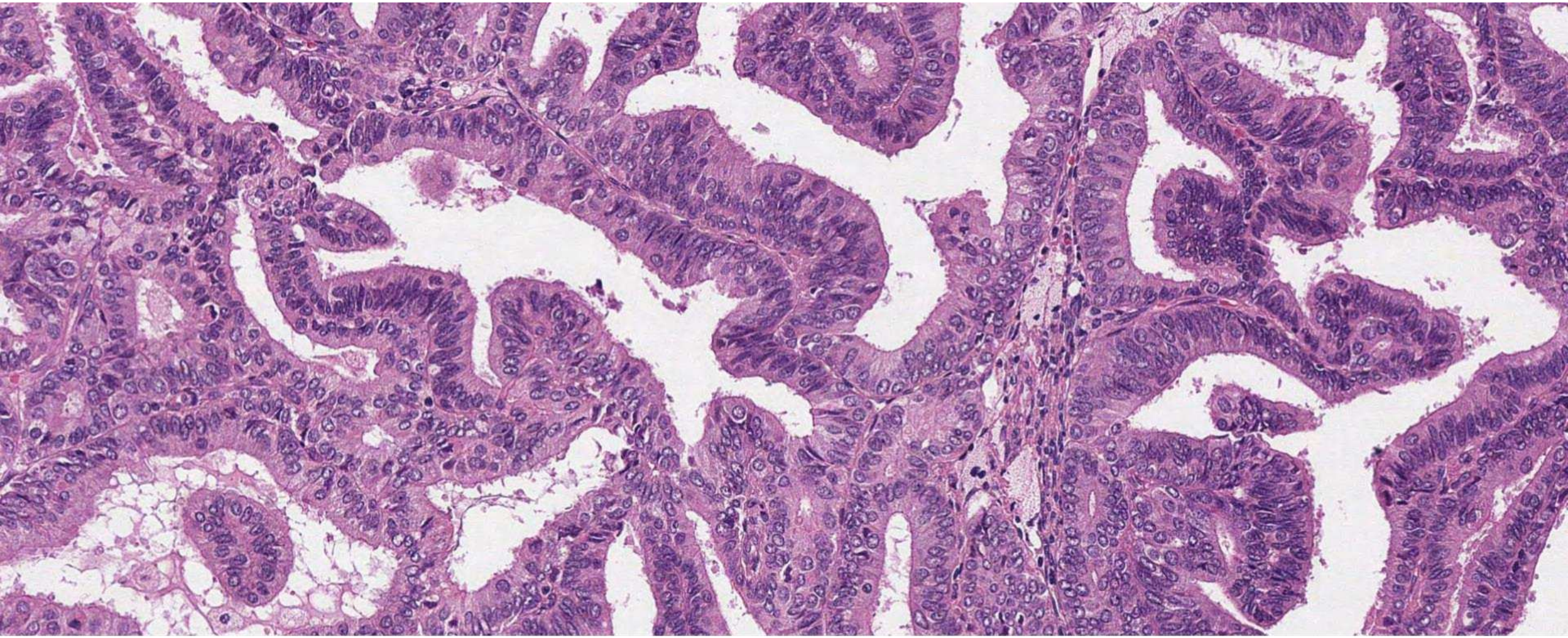

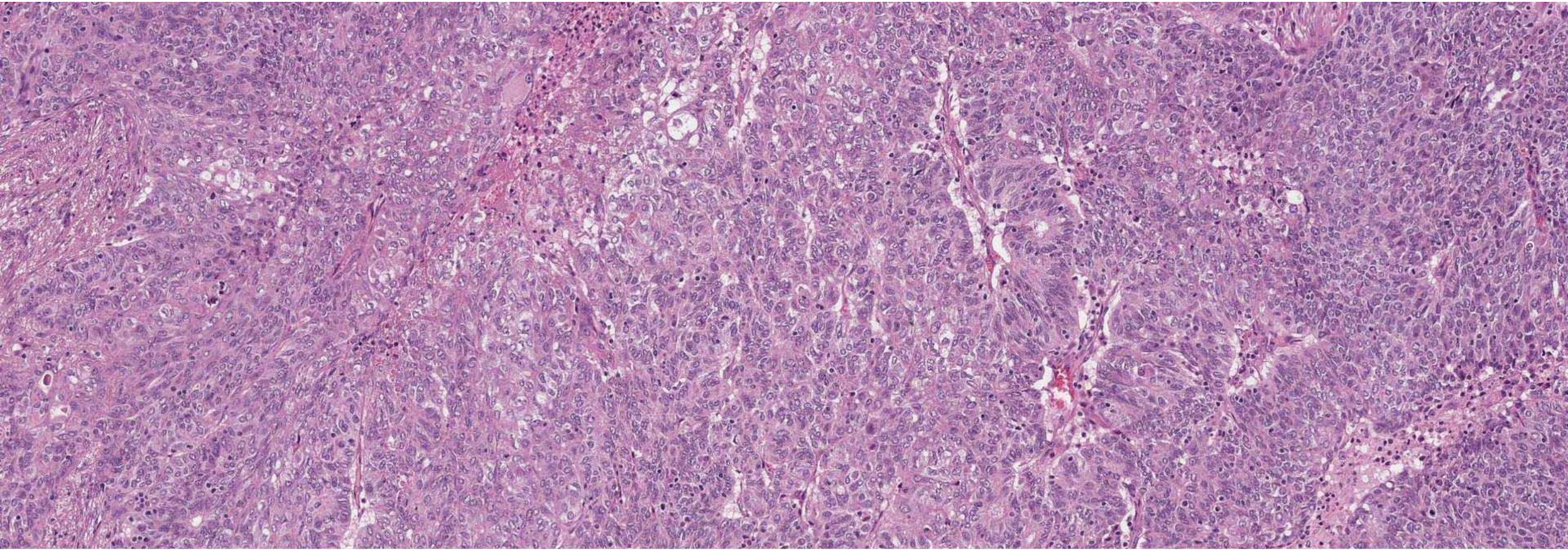

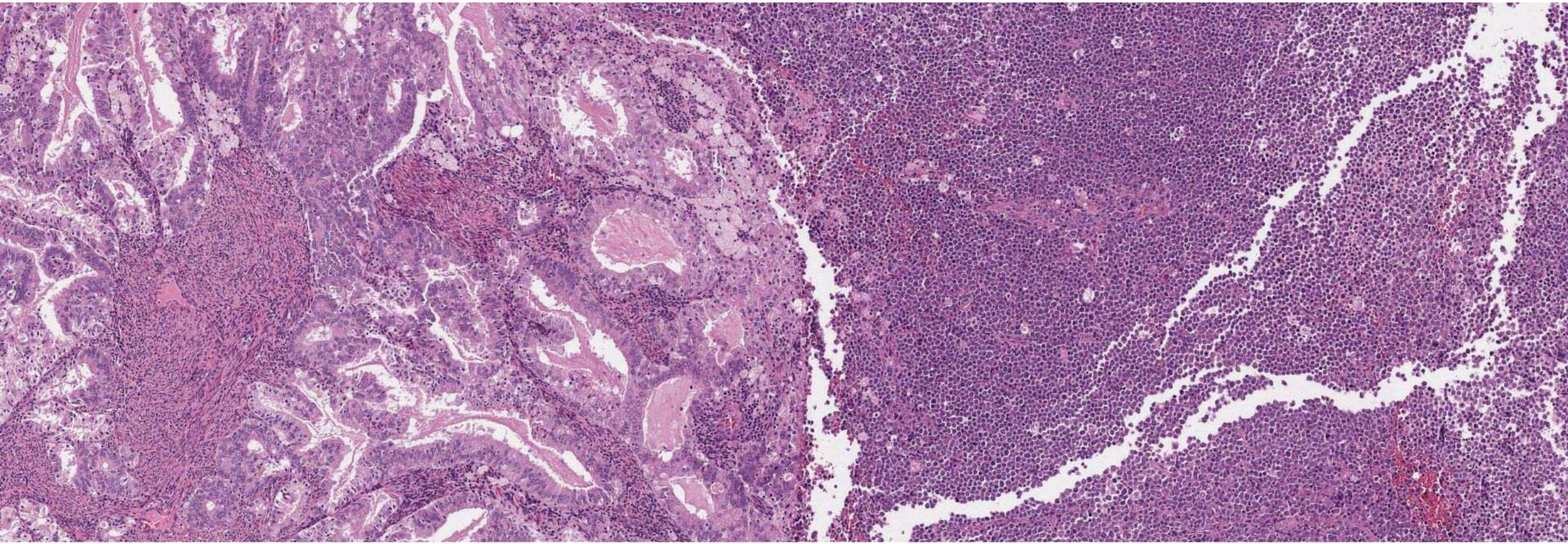

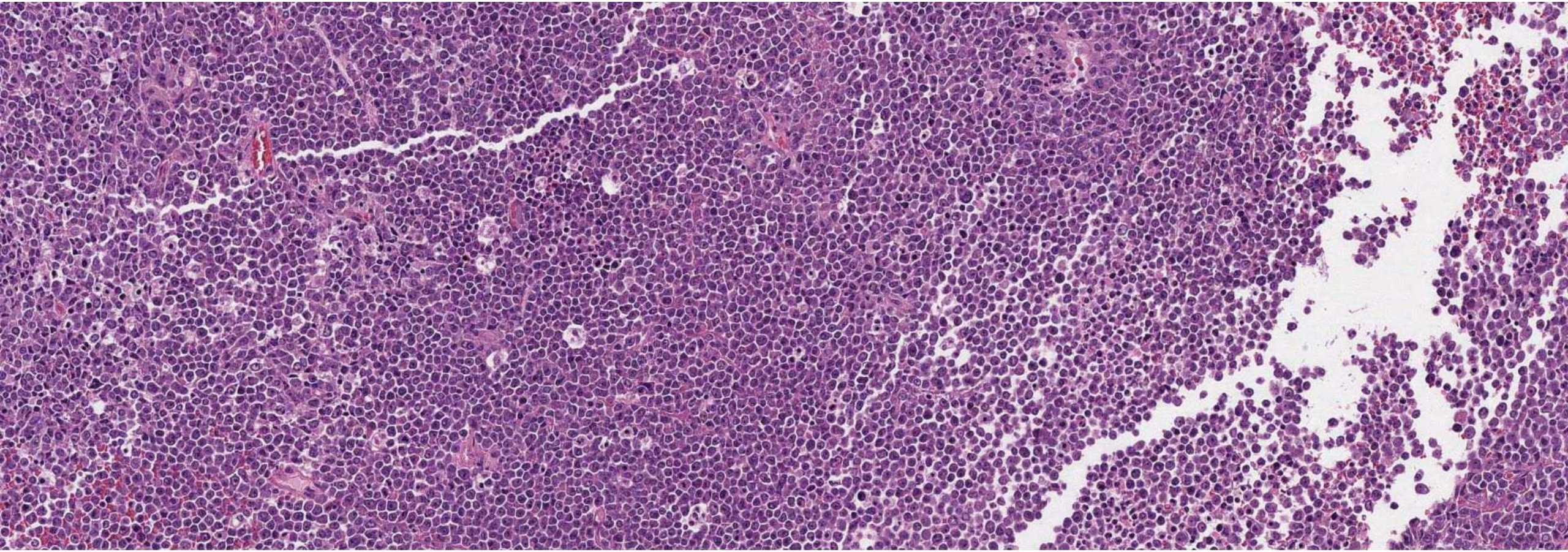

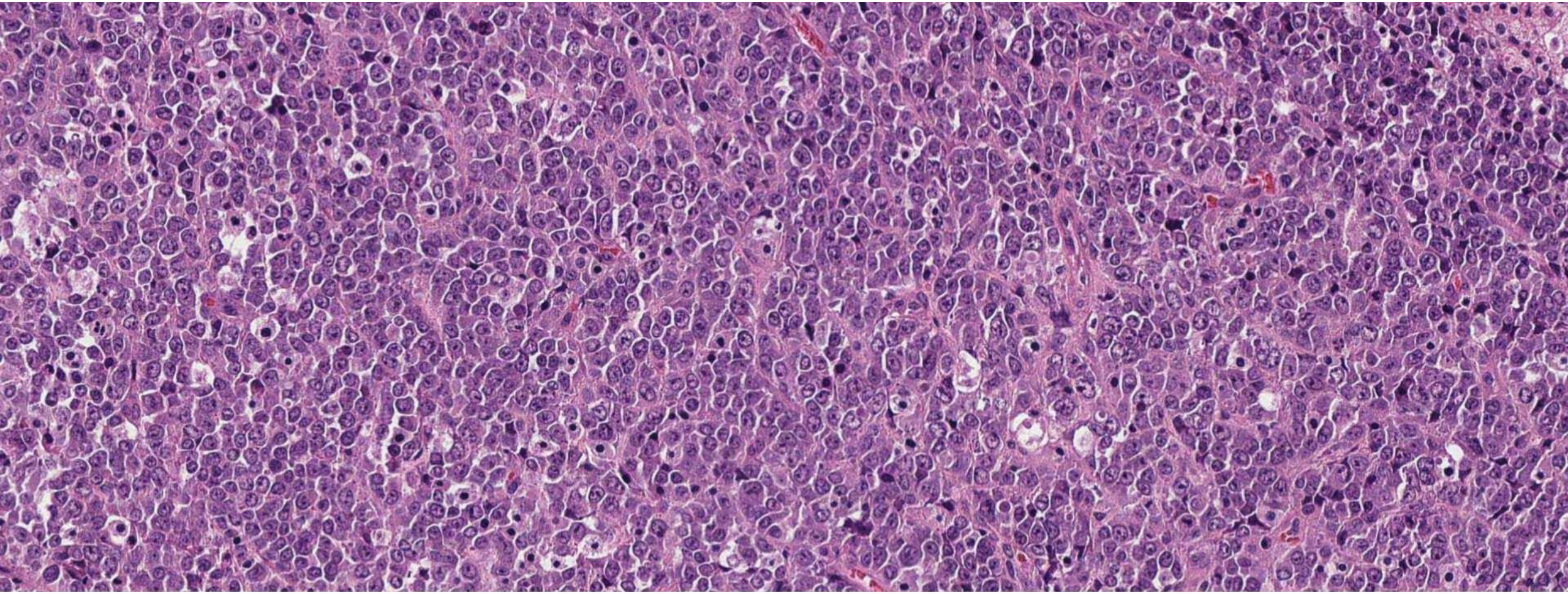

Dedifferentiated carcinoma

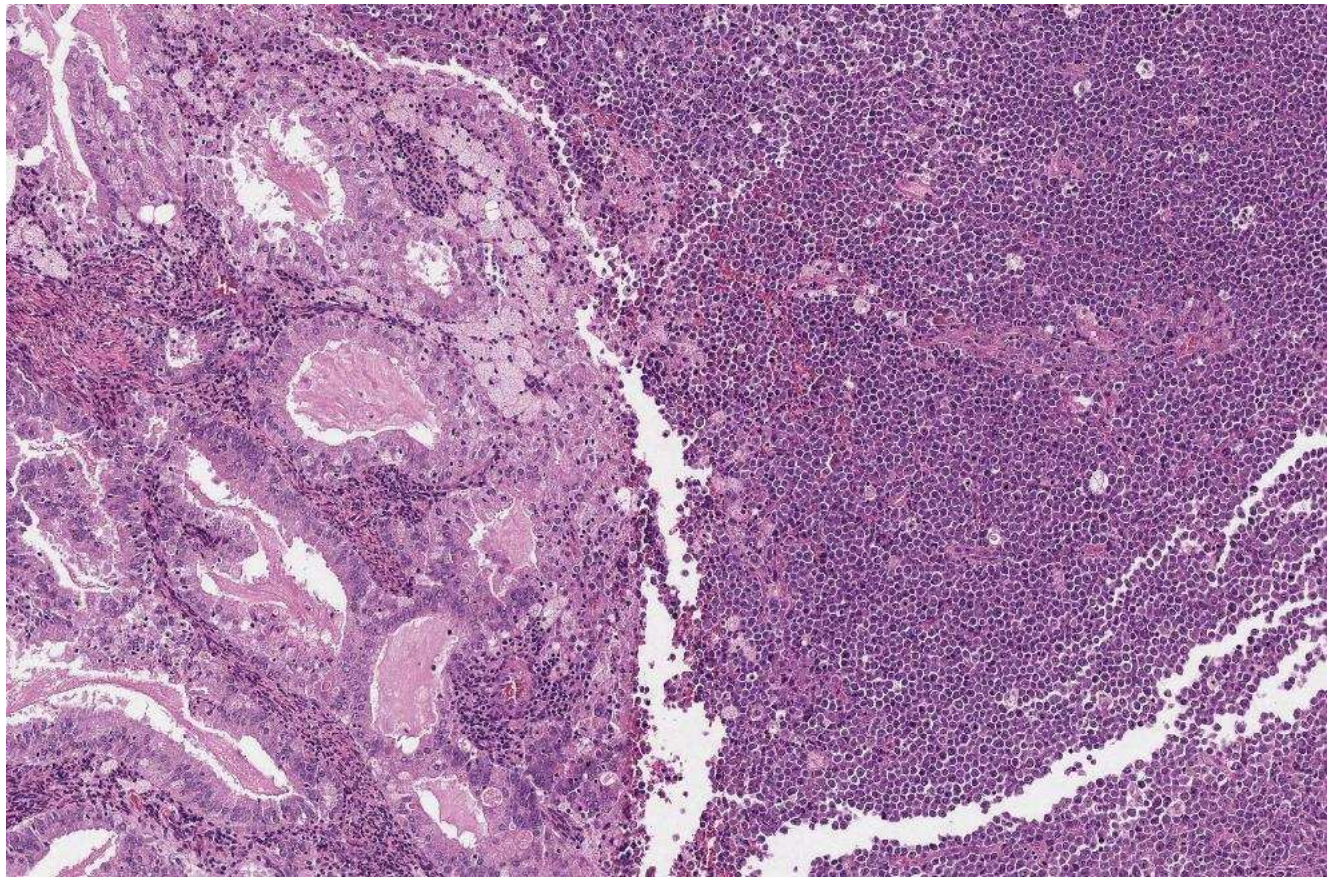

Case 18 – Dedifferentiated carcinoma

Principle histological features

- Usually a low grade endometrioid carcinoma (occasionally grade 3 endometrioid or serous carcinoma) with an abrupt transition to undifferentiated carcinoma, resulting in a biphasic appearance.

- The dedifferentiated component:
  - Discohesive sheets of small, uniform, mitotically active cells.
  - Cells are often plasmacytoid or rhabdoid and it resembles lymphoma.
  - No evidence of epithelial differentiation i.e. no nested or trabecular architecture.
  - No sarcomatous differentiation (i.e. pleomorphic spindled cells, matrix).

Case 18 – Dedifferentiated carcinoma

DDx and how to resolve

▪ Grade 3 endometrioid carcinoma	Uterine carcinoma with solid morphology	Solid areas are cohesive, pleomorphic and show epithelial differentiation e.g. nesting, trabeculation, PAX8+, AE1/3+ Abrupt transition from low grade to high grade not seen
▪ High grade neuroendocrine carcinoma	Discohesive uniform high-grade cells	Diffuse neuroendocrine positivity (focal in dediff) Moulding and smudgy chromatin Low grade endometrioid carcinoma not present
▪ Serous carcinoma with solid morphology	Uterine carcinoma with solid morphology	Same as for G3 EEC

Case 18 – Dedifferentiated carcinoma

Extra marks?

- Primary dedifferentiated carcinoma of the ovary has been described; however, this patient presented with endometrial carcinoma. Assessment of the rest of the specimen is required to determine relationship between this tumour and any endometrial cavity disease.

- A relatively high proportion of dedifferentiated carcinomas are associated with mismatch repair deficiency (50-66%) compared to endometrioid carcinomas (25-33%). I will request MMR immunohistochemistry as part of the work-up.

- SMARCA4 and SMARCB1 inactivation is seen in 2/3 of dedifferentiated carcinomas.

Case 19

- Specimen: Cervix (TAH BSO)
- Age: 57
- Clinical: Hysterectomy for irregular bleeding

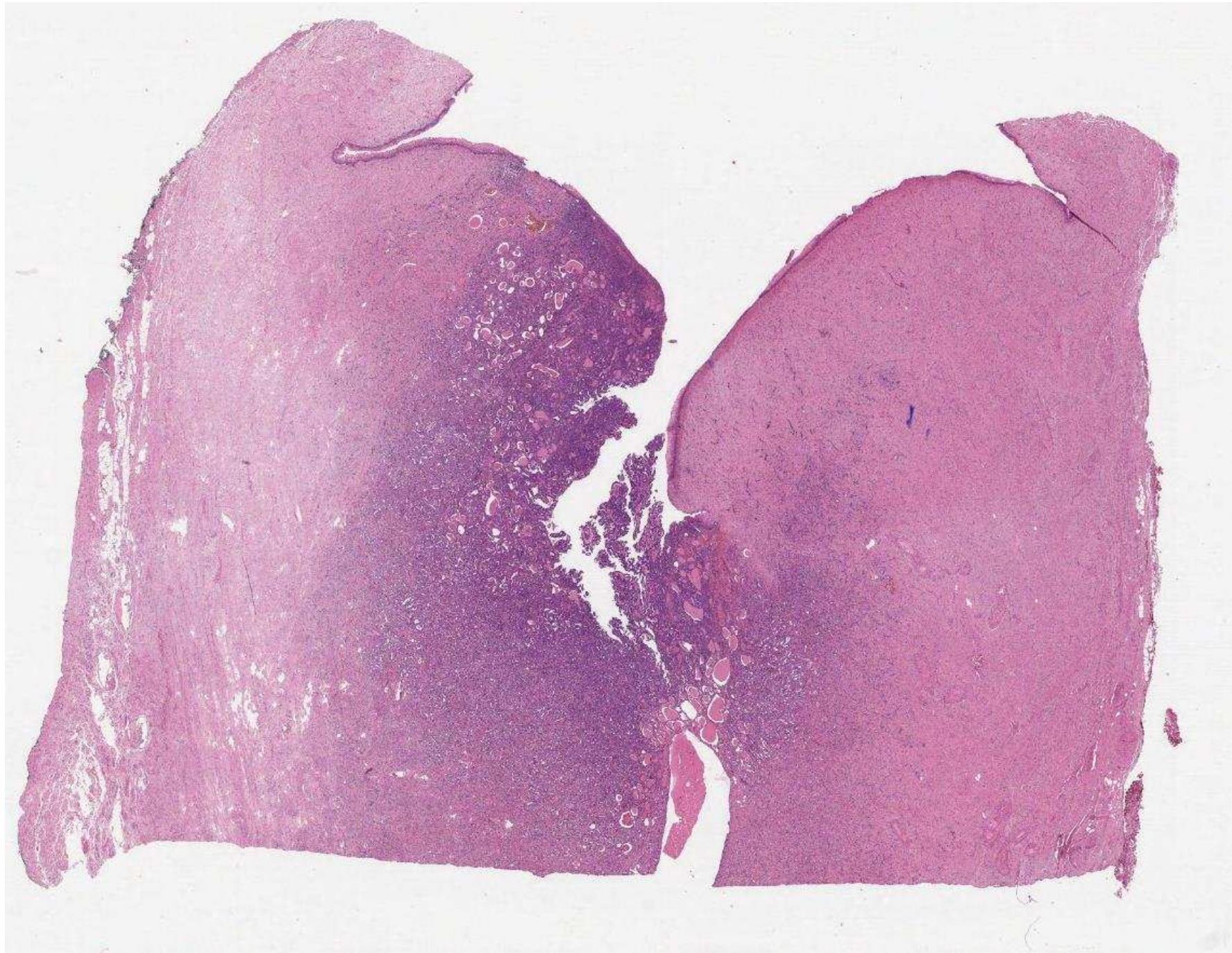

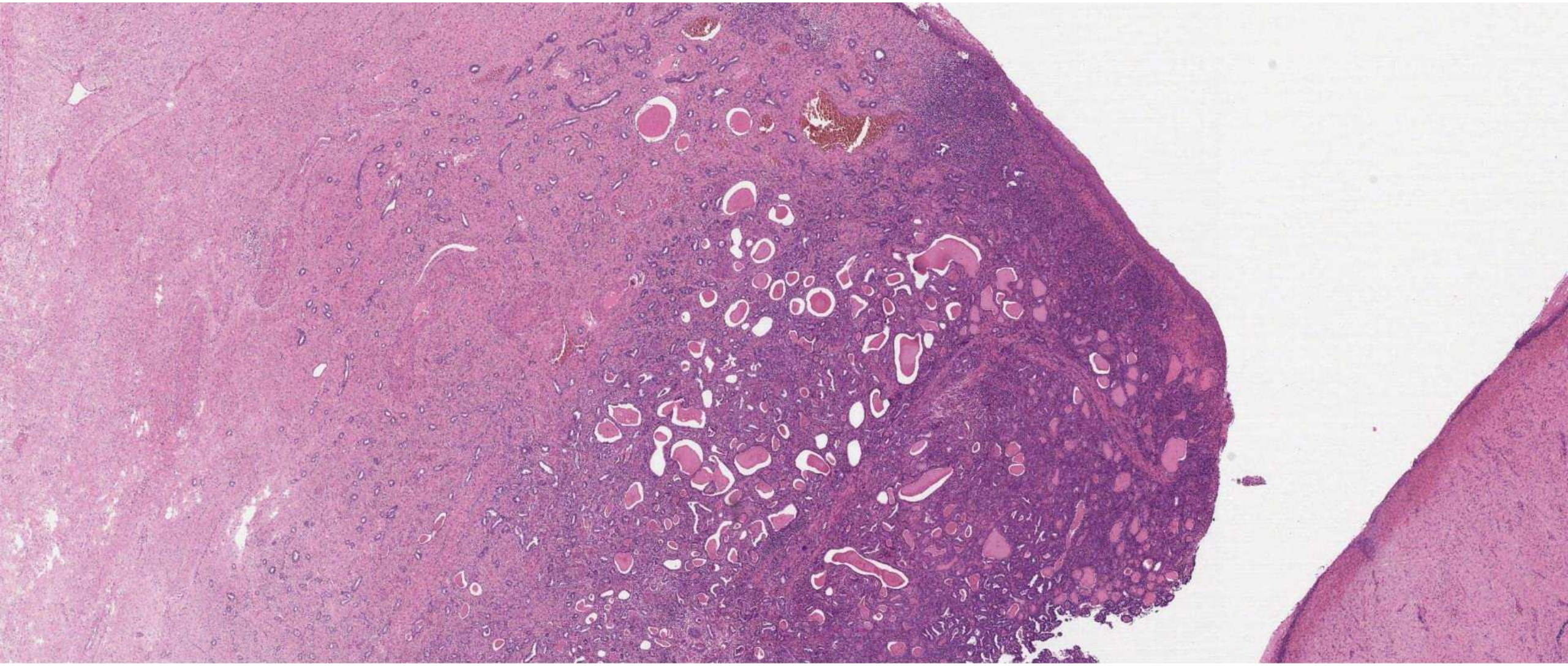

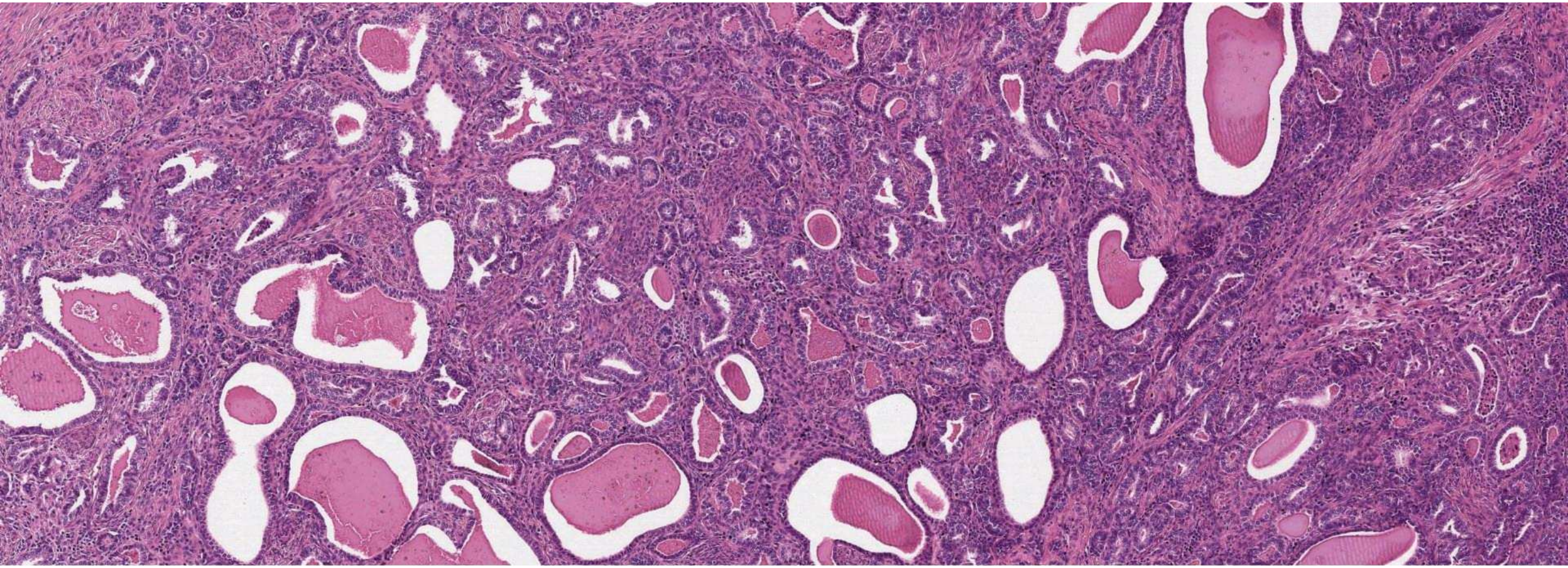

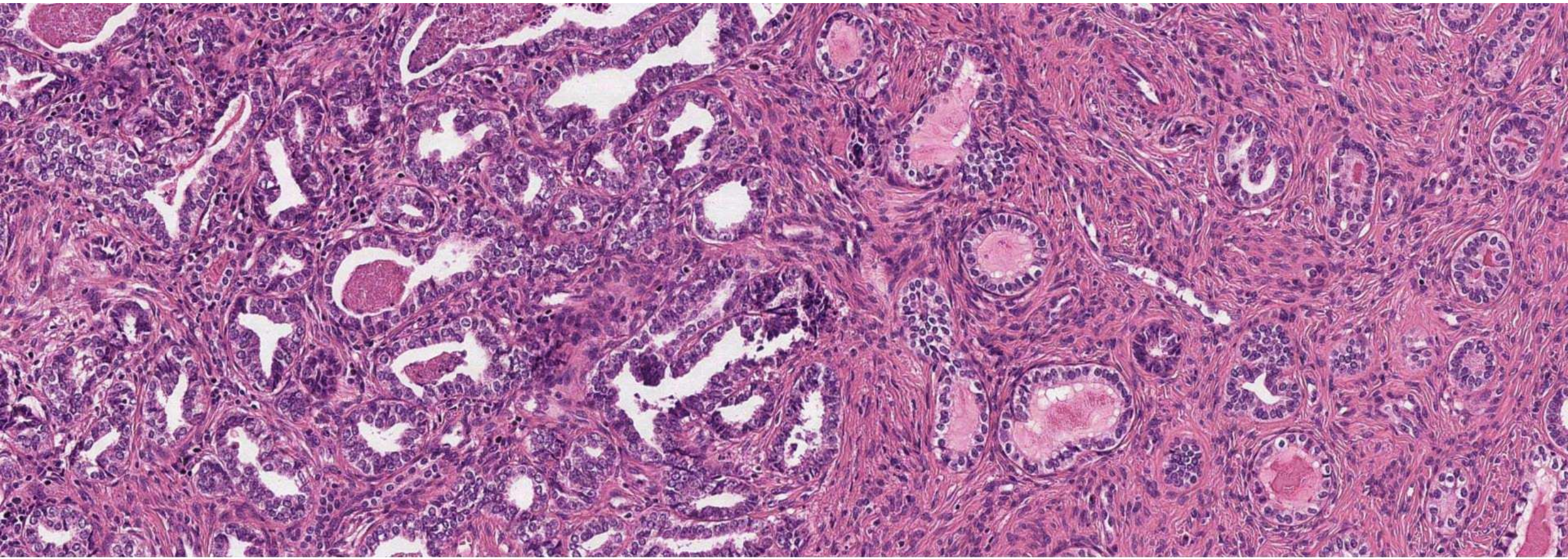

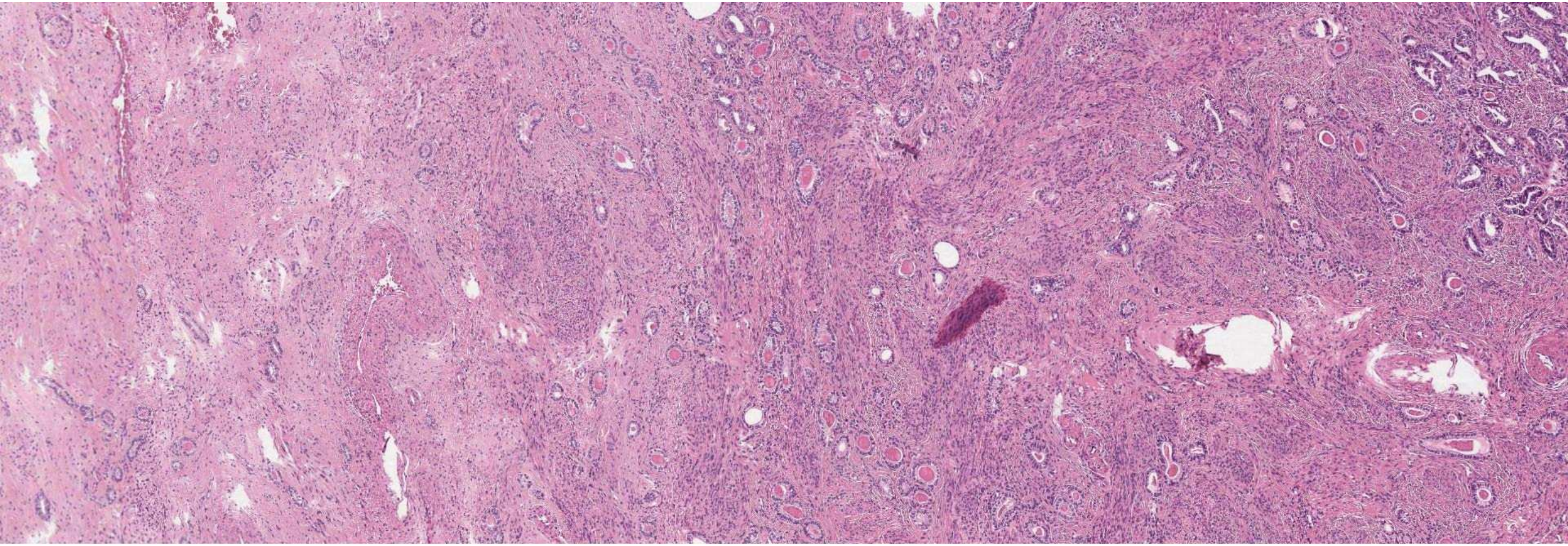

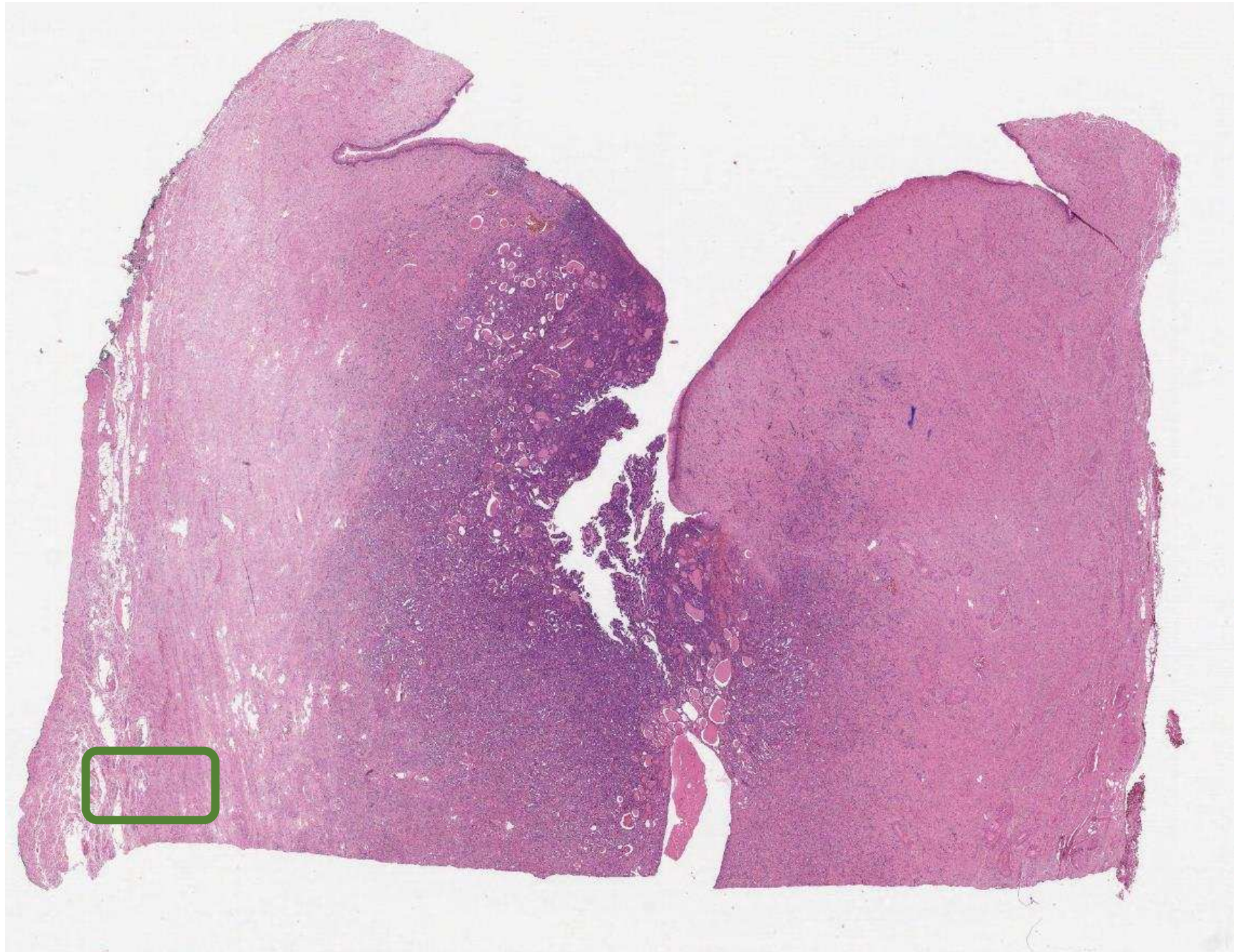

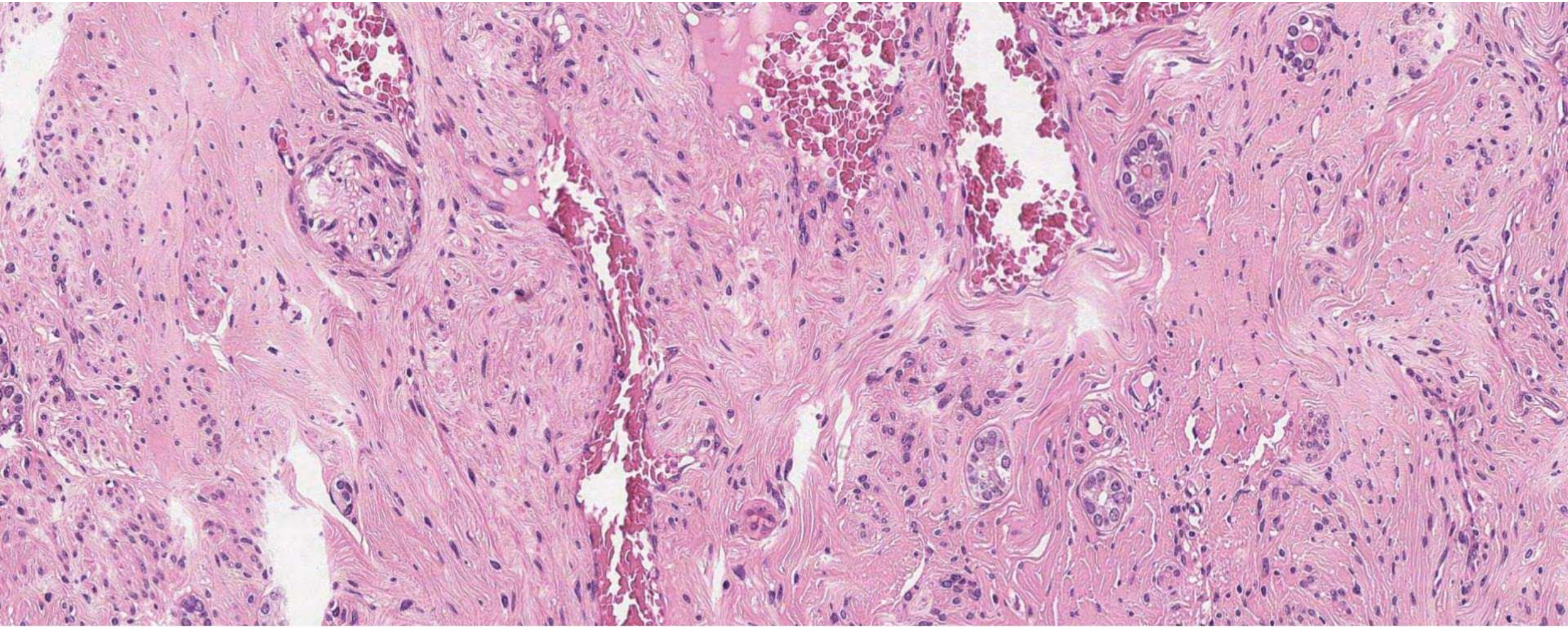

Mesonephric adenocarcinoma

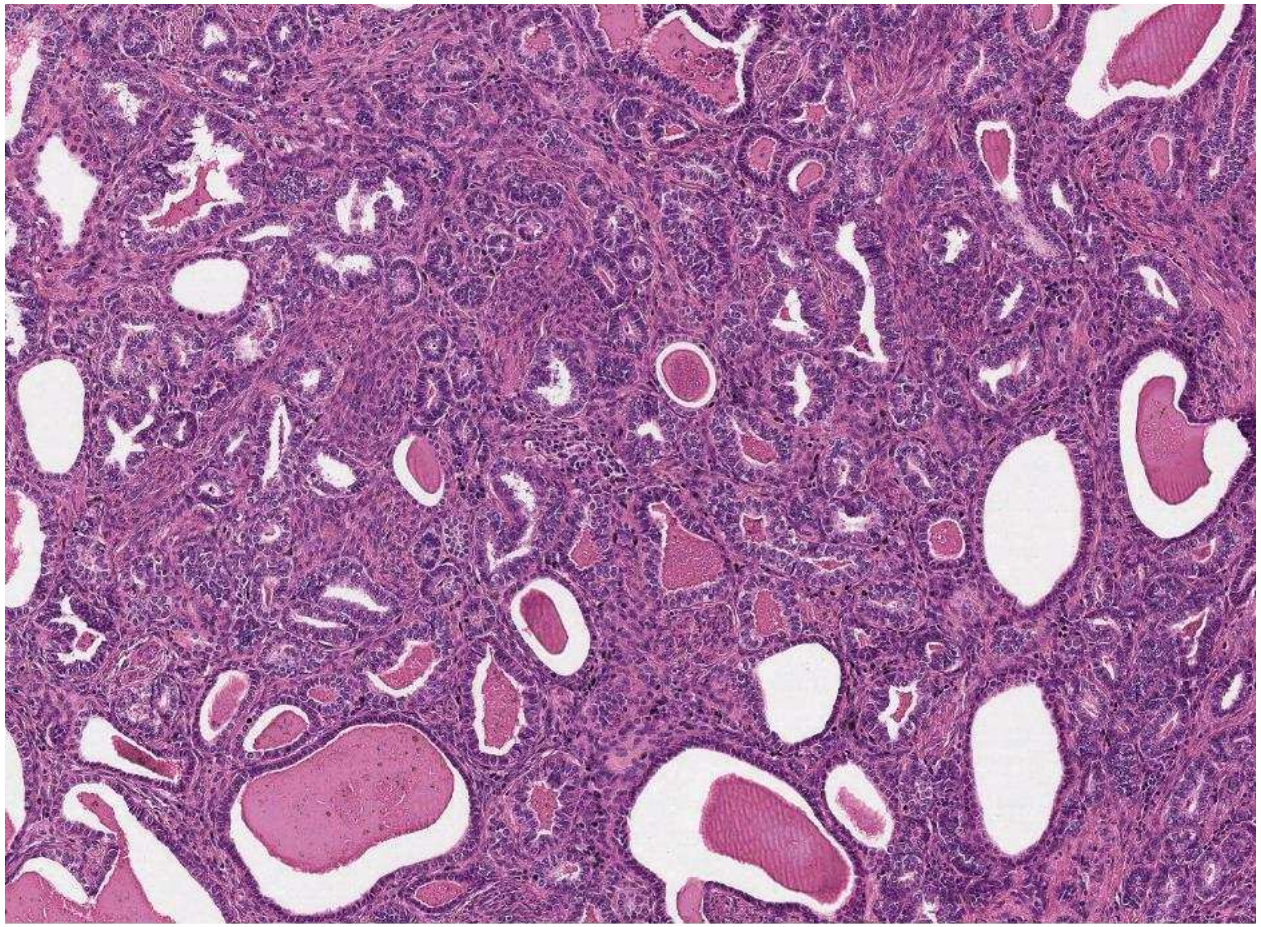

Case 19 – Mesonephric carcinoma

Principle histological features

- Architecture:
  - Most common appearance: back-to-back tubules.
  - Other possibilities (usually admixed): angulated glands, retiform, hobnail, sieve-like, solid, spindled.

- Cytology:
  - Uniform, bland, cuboidal cells.

- Luminal spaces filled with dense, eosinophilic, PAS+ secretions.

Case 19 – Dedifferentiated carcinoma

DDx and how to resolve

▪ Mesonephric remnants or hyperplasia	Tubules containing eosinophilic secretions lined by bland cuboidal cells	Shouldn't see crowding, haphazard or widely infiltrative growth Features like atypia, necrosis and mitotic activity not seen, but cannot be relied upon
▪ Mesonephric-like carcinoma	Tubules containing eosinophilic secretions lined by bland cuboidal cells	Usually an endometrial carcinoma showing mesonephric differentiation, i.e. not arising from mesonephric remnants. LOCATION
▪ HPV-associated cervical adenocarcinoma	Adenocarcinoma in cervix	Large, atypical nuclei; apical mitoses, basal apoptotic figures, diffuse p16 expression

Case 19 – Dedifferentiated carcinoma

Extra marks?

- Cervical mesonephric carcinomas come under the umbrella of HPV-independent cervical adenocarcinoma and are expected to show non-diffuse expression of p16.
- Despite their low-grade nuclear features, prognosis is typically poor.
- Usually positive for one or more mesonephric markers (GATA3, TTF1, CD10 (luminal)).
- Usually positive for PAX8 and negative for ER.

Case 20

- Specimen: Cervix (TAH BSO)
- Age: 52
- Clinical: Hysterectomy for fibroids and PV discharge



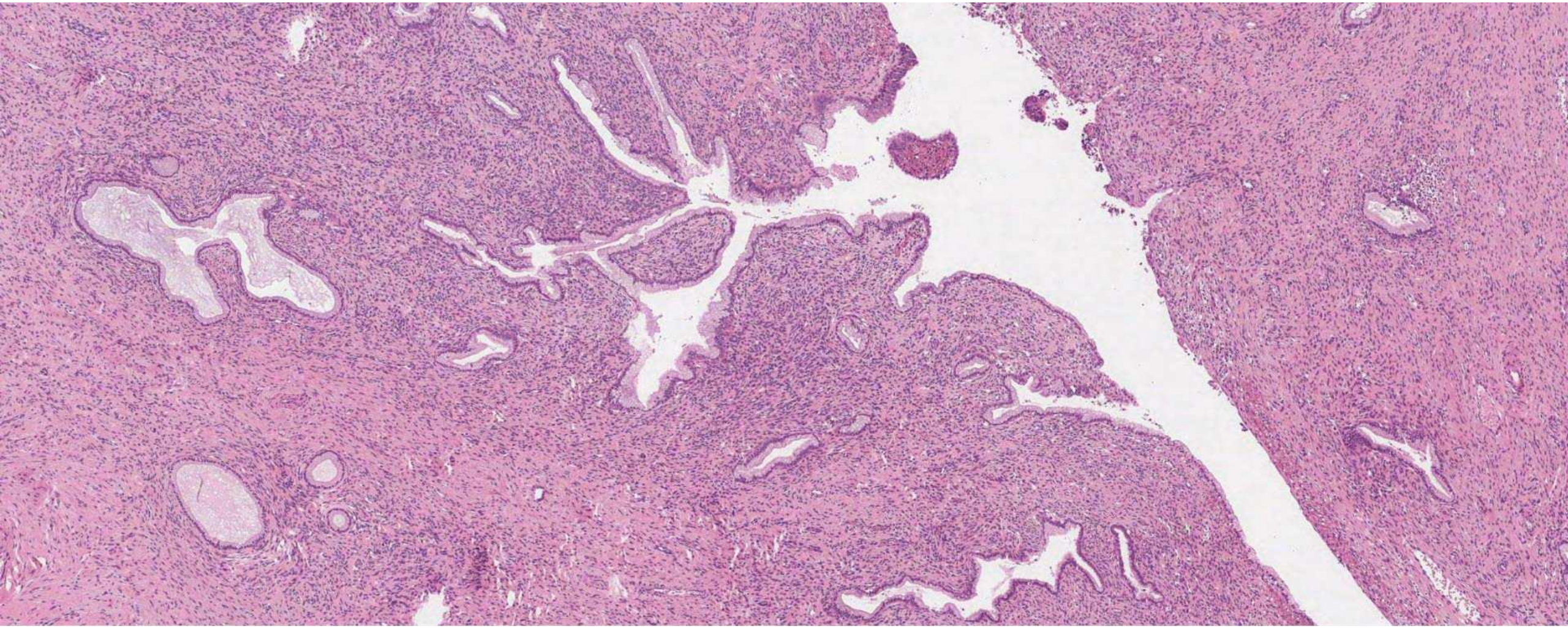

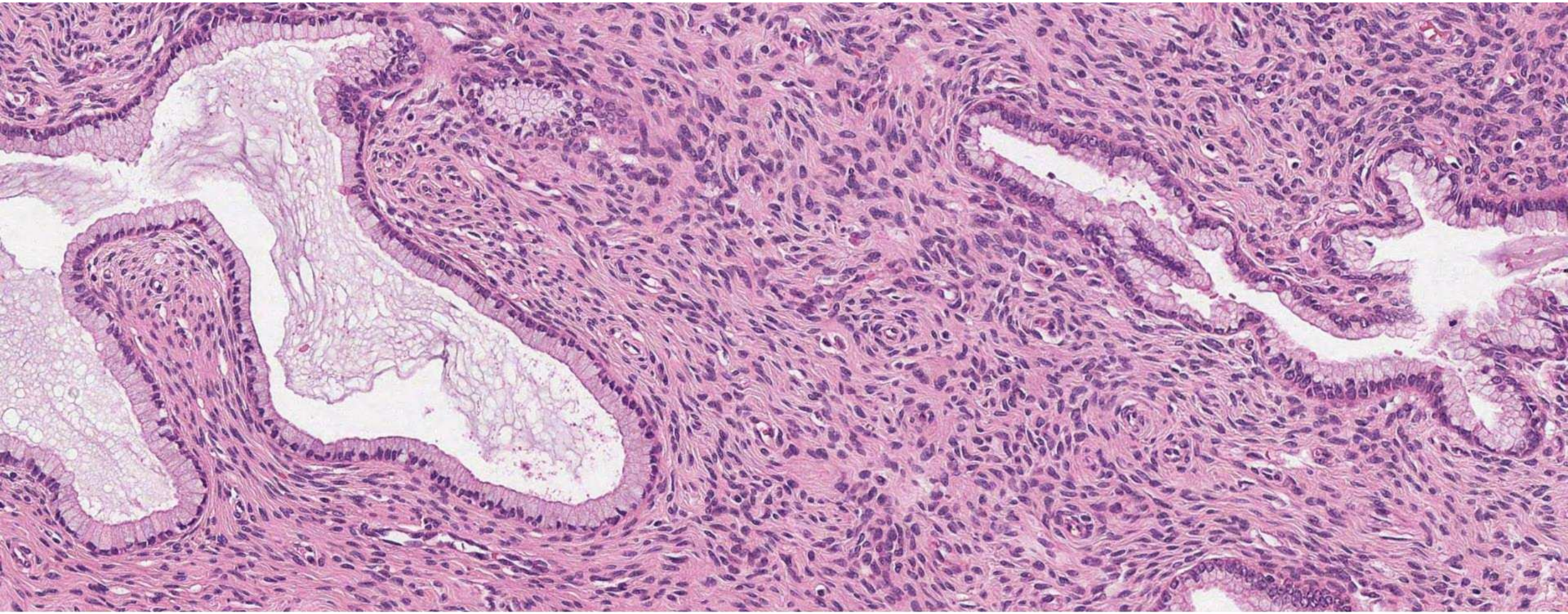

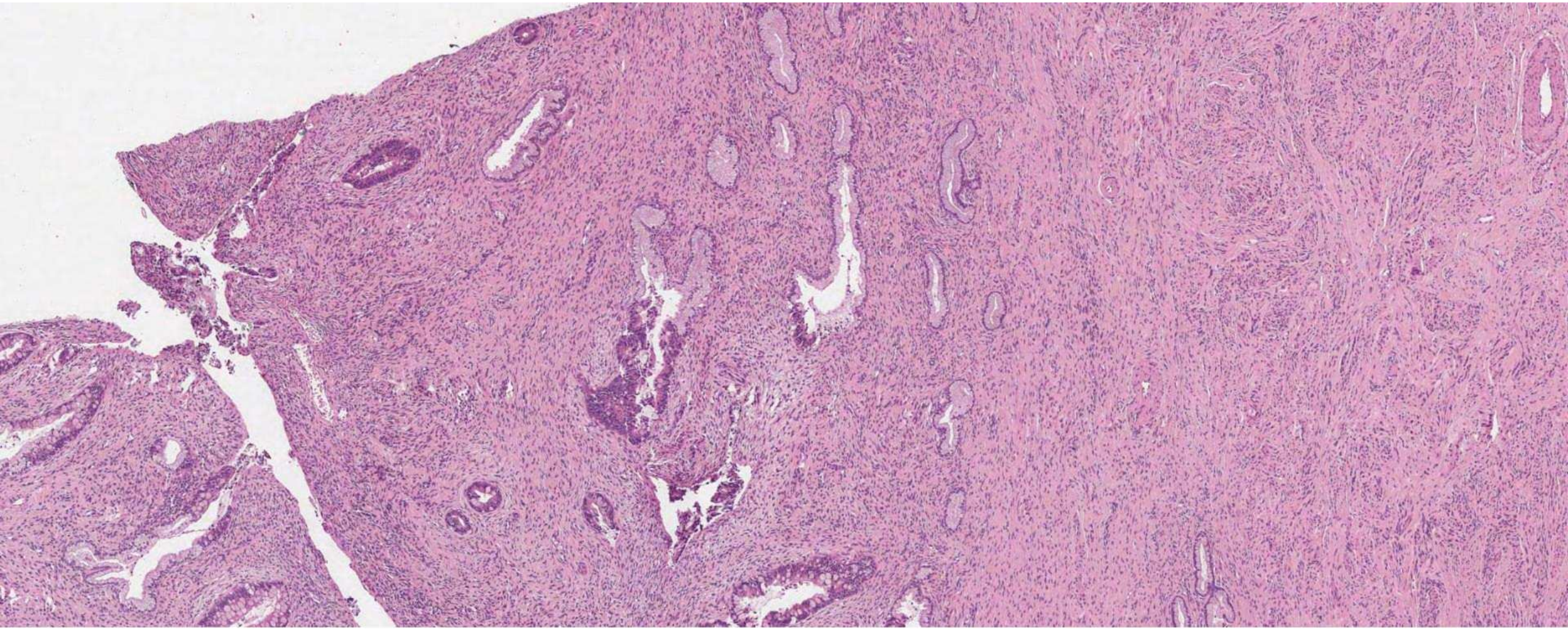

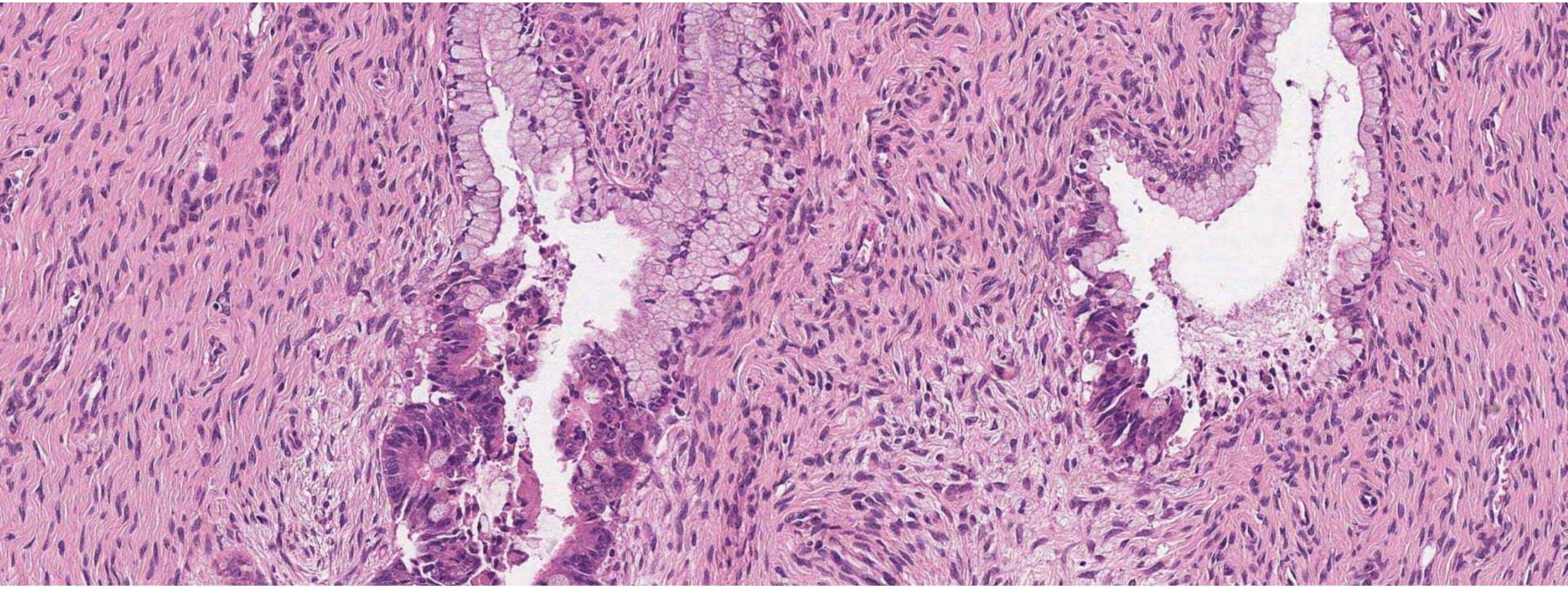

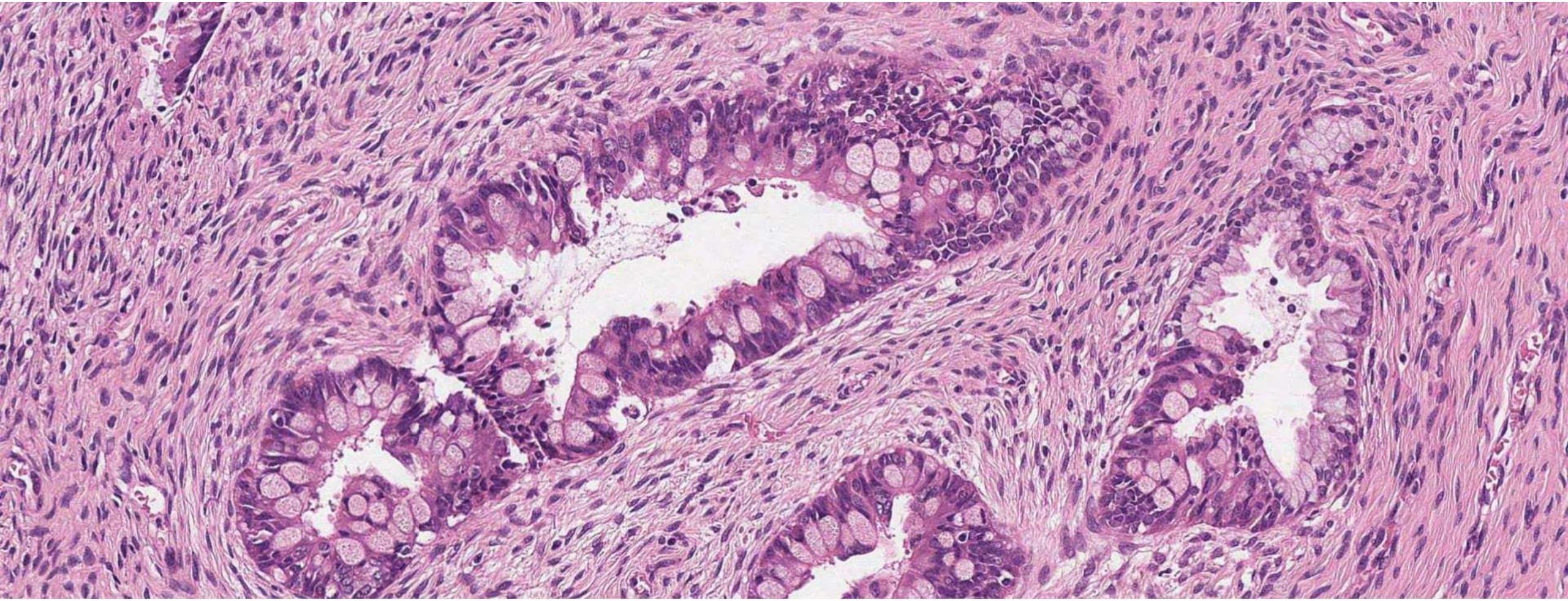

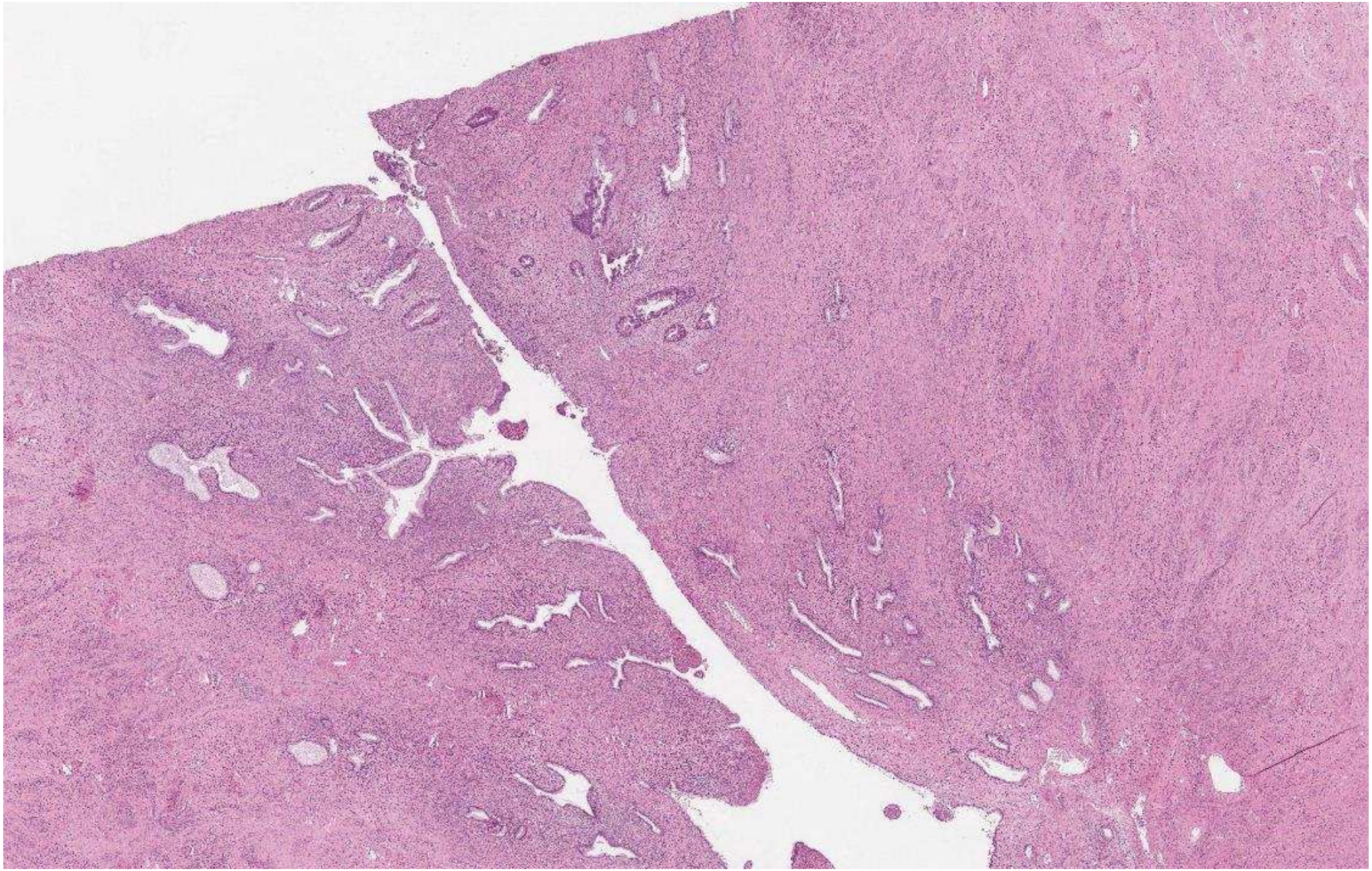

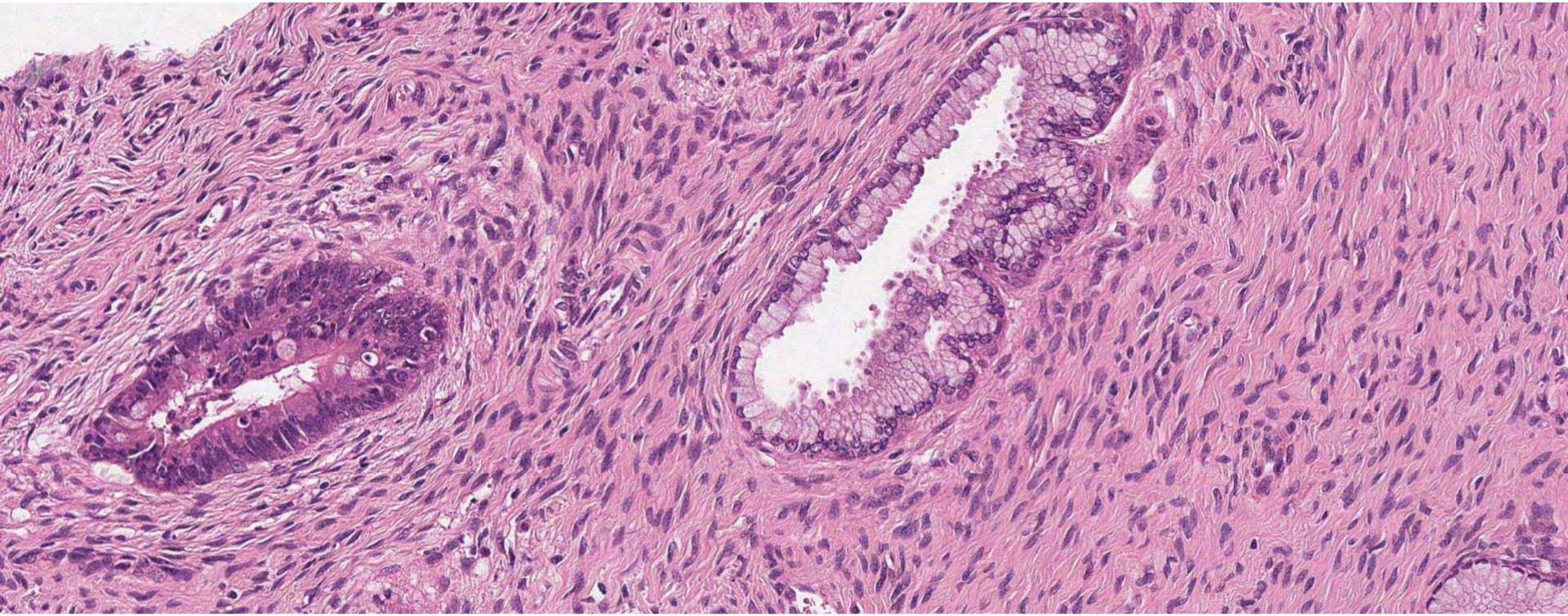

Gastric-type adenocarcinoma in situ

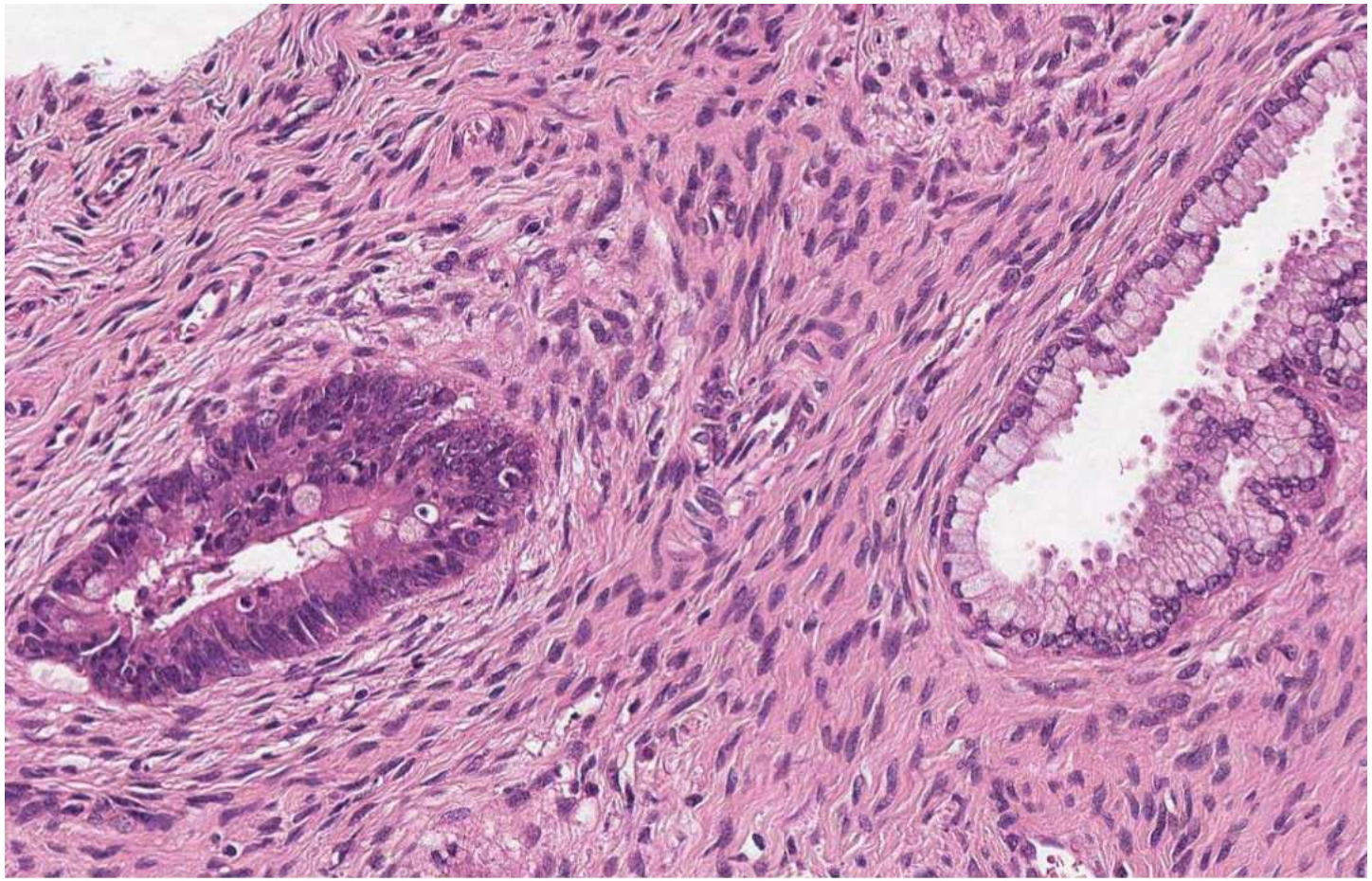

Case 20 – Gastric-type carcinoma in situ

Principle histological features

- Cuboidal to columnar cells showing atypia that can range from mild to severe.
- Eosinophilic or pale and foamy cytoplasm.
- Intestinal / goblet cell differentiation often seen.
- Involves / colonises pre-existing glands.
- When occurring as a lobulated proliferation of glands, called *lobular endocervical glandular hyperplasia.*

Case 20 – Gastric-type carcinoma in situ

DDx and how to resolve

▪ High grade CGIN	Atypical in situ cervical glandular lesion Can see intestinal differentiation	Higher N:C ratio, lacks eosinophilic, pale or pyloric-like cytoplasm p16 diffusely positive Apical mitoses and basal apoptoses
▪ Gastric type adenocarcinoma	Same cytomorphology A degree of intraluminal complexity is possible	Often associated with dispersed infiltration (previously termed adenoma malignum) Haphazard growth, crowding or gland confluence

Case 20 – Gastric-type carcinoma in situ

Extra marks?

- Gastric adenocarcinoma in situ is HPV-independent and therefore p16 is expected to be non-diffuse.
- Expected to be positive for CK7, PAX8 and CDX2. Expected to be negative for ER and PR. Often associated with loss of PAX2 expression.
- Cytoplasm contains neutral mucins, i.e. red on PAS-AB, versus the cytoplasm of normal endocervical glands which contain acid mucins, i.e. dark purple on PAS-AB.

Short surgical cases 11 - 12

11. Ovary: Low grade serous carcinoma
12. Vulva: Psoriasis
13. Vagina: Vaginal adenosis
14. Uterus: Low-grade endometrial stromal sarcoma
15. Endometrium: Placental site nodule
16. Omentum: Metastatic high-grade carcinoma
17. Ovary: Metastatic well-differentiated NET
18. Ovary: Dedifferentiated carcinoma
19. Cervix: Mesonephric adenocarcinoma
20. Cervix: Gastric-type adenocarcinoma in situ

Tips for answering SS questions

- Information provided within the question may or may not be useful, but should not mislead.
  - e.g. elderly patient, germ cell tumour unlikely.

Tips for answering SS questions

- **Succinct** histological description.

- If you spot the diagnosis, aim to use specific descriptors associated with certain entities (if those features are there!).
  - Adult granulosa cell tumour – Call-Exner bodies.
  - Adenosarcoma – Phyloides-like architecture.
  - Serous borderline tumour – Heirarchical branching.

- If unsure of the diagnosis, say what you see.

Tips for answering SS questions

- Reach a 'bottom line' diagnosis. Clearly identify it as such.

- A firm diagnosis is not always expected.
- Better to provide a suitable differential diagnoses and a way to resolve using ancillary tests than to confidently provide a wrong answer.

- Single slide, limited time
  - Be careful about spending time providing a tumour stage, searching for LSVI, tumour dimensions, margin status

Tips for answering SS questions

- After your diagnosis line or conclusion, aim to gain additional marks by providing extra information
  - Immunohistochemistry table
  - Molecular information
  - Awareness of staging and other prognostic factors
  - Awareness of clinical presentation and clinical implications



Thank you

Questions