The British Association of Gynaecological Pathologists

Lecturer - Dr Nataliya Piletska

Consultant Pathologist based at Maidstone Hospital with a particular interest in gynae pathology, in addition to skin pathology, cytology and post mortems.



The British Association of Gynaecological Pathologists

Mock Exam

- Dr Nataliya Piletska
- Maidstone and Tunbridge Wells NHS Trust

- 25 September 2024

The British Association of
Gynaecological Pathologists

Mock Exam

Short Cases 1 - 10

Short case 1

Female 65 years

Right ovarian tumour.

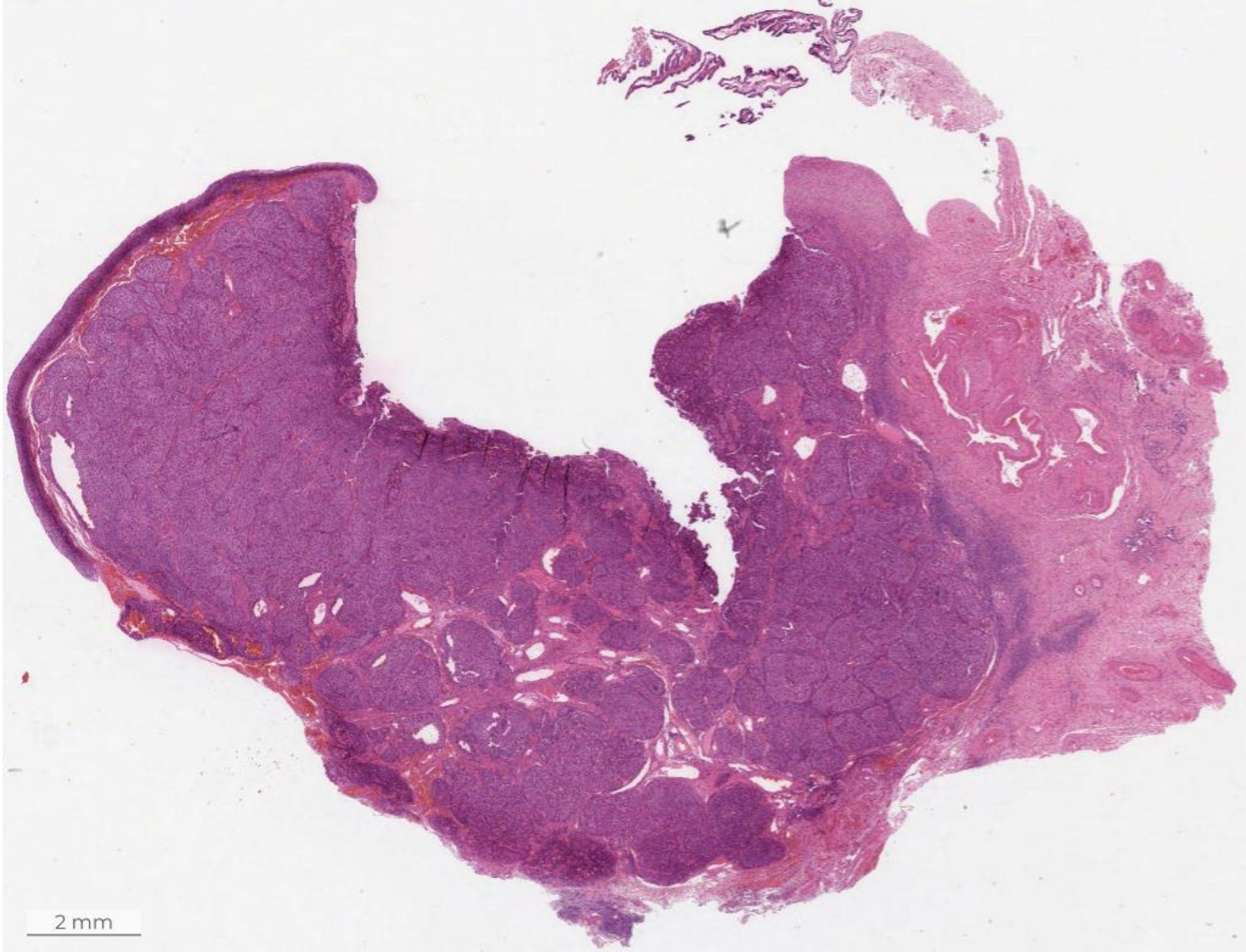
2 mm

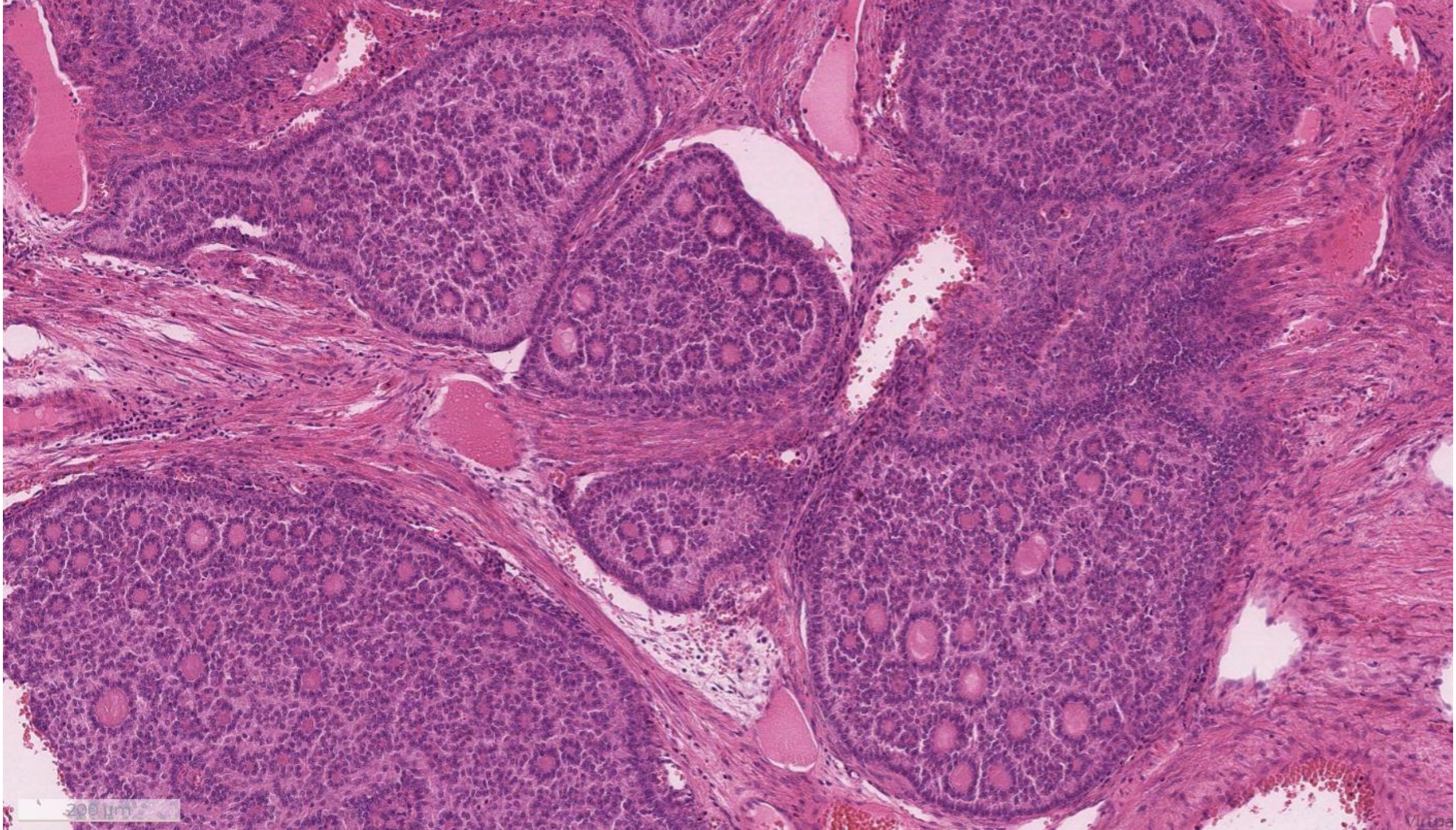
200 µm

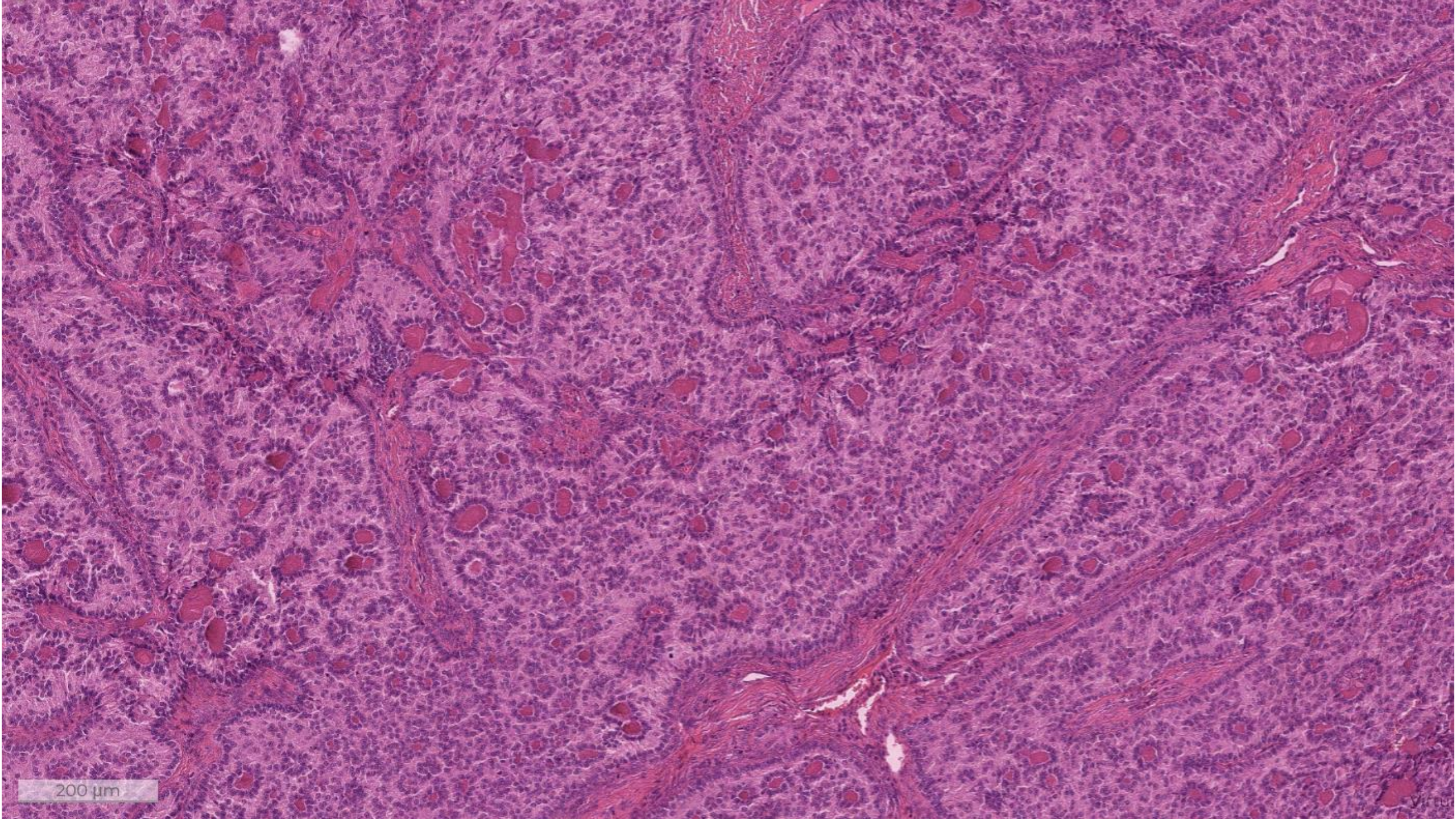
200 µm

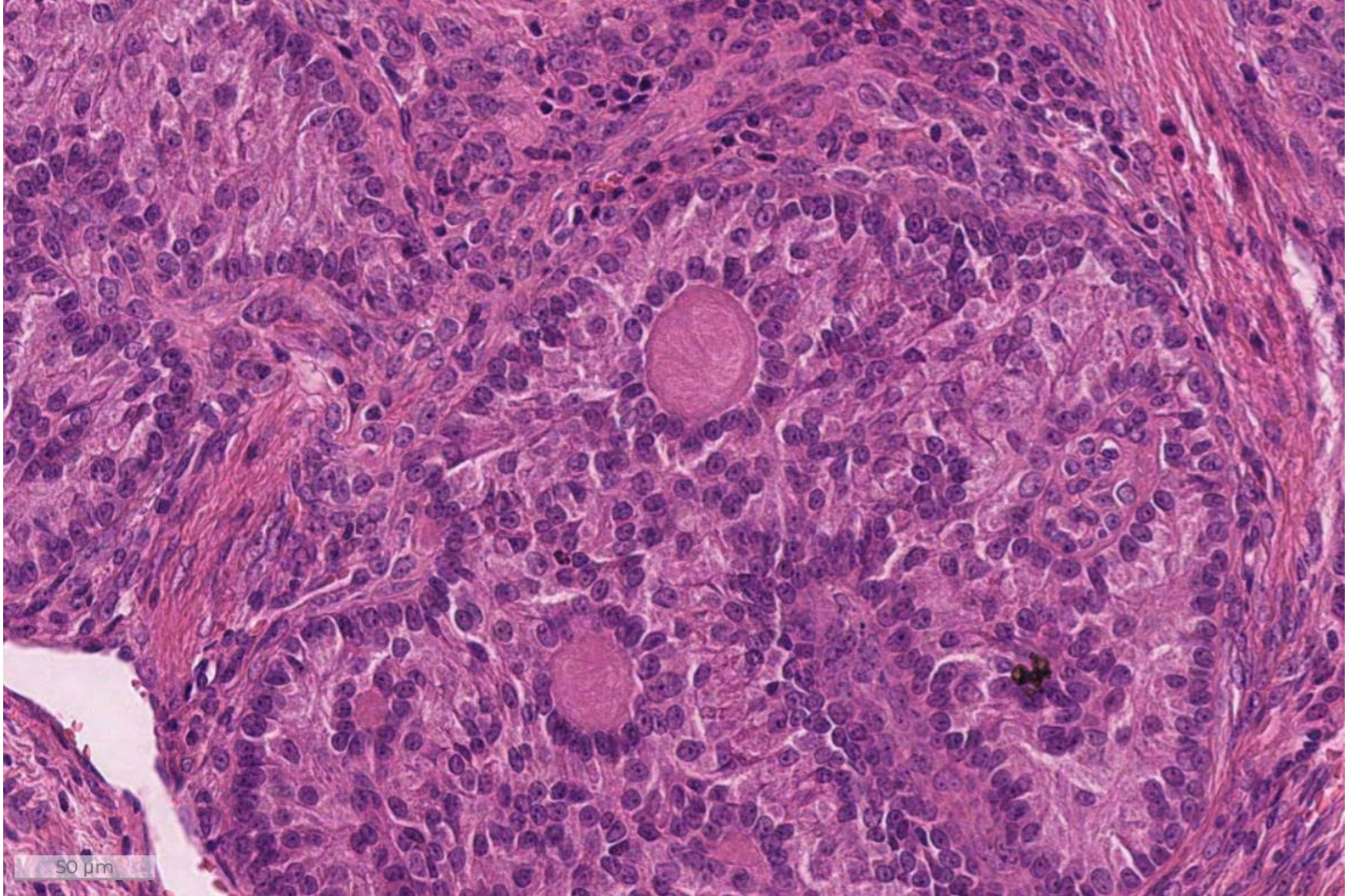
50 µm

Short case 1 : Sex cord tumour with annular tubules (SCTAT)

- Rare tumour (<1% of all sex cord tumours)
- Occur at any age, peak in 30-40s
- Oestrogenic manifestations may be present
- 1/3 of cases associated with Peutz-Jeghers syndrome
- Syndromic cases: germline STK11 gene mutation on 19p13.3
- Syndrome-associated tumours are typically benign. Non-syndromic cases exhibit extraovarian spread in ~20%
- DDx: gonadoblastoma (Stromal & germ cell components must be present; no PJS association; almost always involves underlying gonadal disorders)

Short case 1 : Sex cord tumour with annular tubules (SCTAT)

- Macro:
  - Syndromic - small (microscopic to 3cm), bilateral, multifocal, gritty texture
  - Non-syndromic – sizeable, unilateral, solid, yellow
- H&E:
  - Sharply circumscribed, variably sized nests of tubules encircling basement membrane-like material
  - Extensive calcification within tubules may be seen in PJS
  - Cells – tall, pale cytoplasm, basally located round nuclei, antipodal distribution
  - May focally transition to granulosa or Sertoli cell morphology
  - Cytological atypia and mitotic activity rarely seen in non-syndromic cases
- IHC: Inhibin, calretinin, WT1, SF1, FOXL2, CD56

Short case 1 : Sex cord tumour with annular tubules (SCTAT)

Mark	Features
1.5 or 1	Fails to diagnose
2	Does not commit to a diagnosis, inadequate morphological description
2.5	Adequate description with confident diagnosis but no additional information
3	Some additional information, as mentioned below:
3.5	Good description, mention expected findings and IHC, association with Peutz-Jeghers syndrome, STK11 germline mutation, good prognosis, DDx (gonadoblastoma)

Short case 2

- Female 65 years
- Right ovarian tumour, raised testosterone.

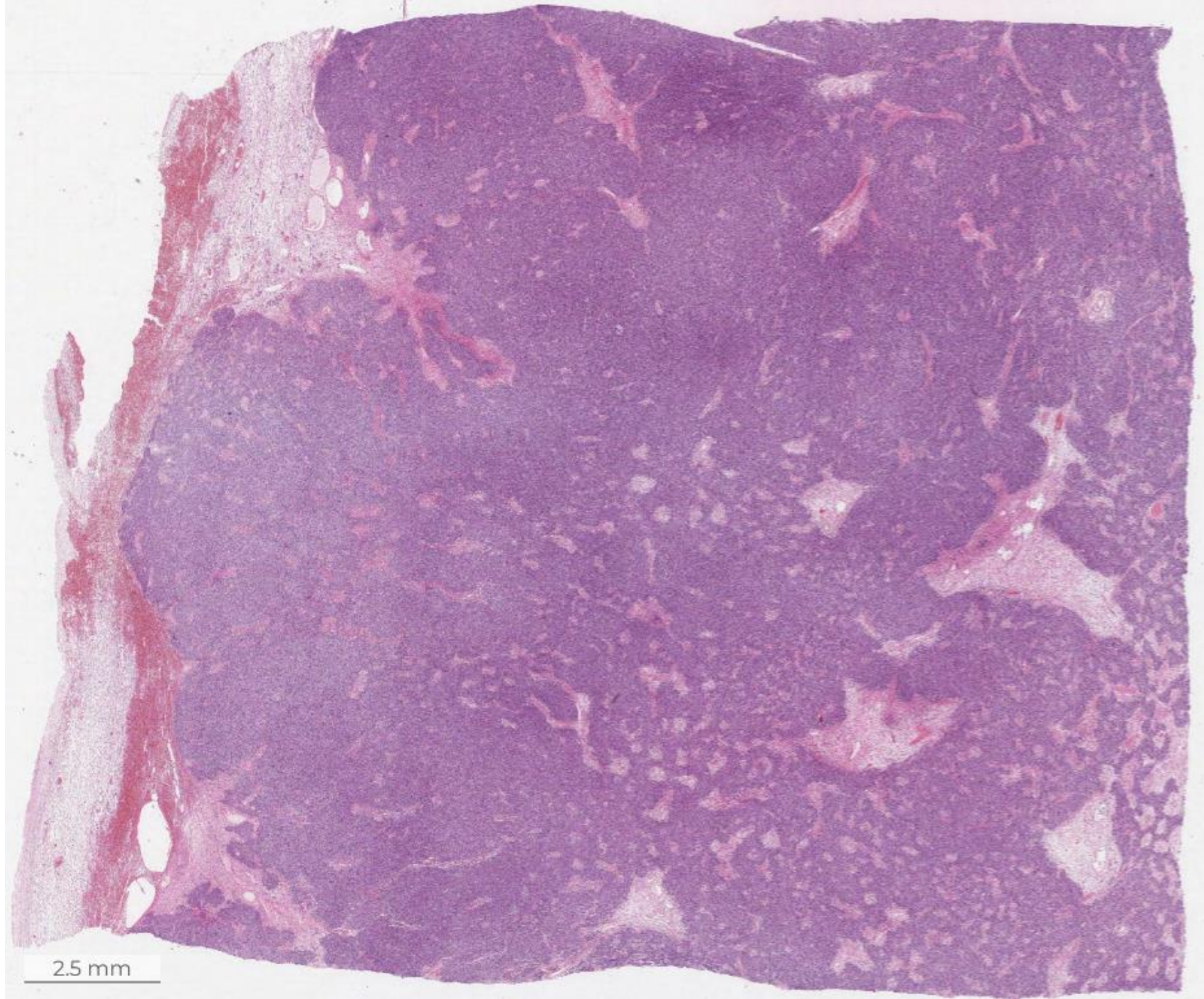
2.5 mm

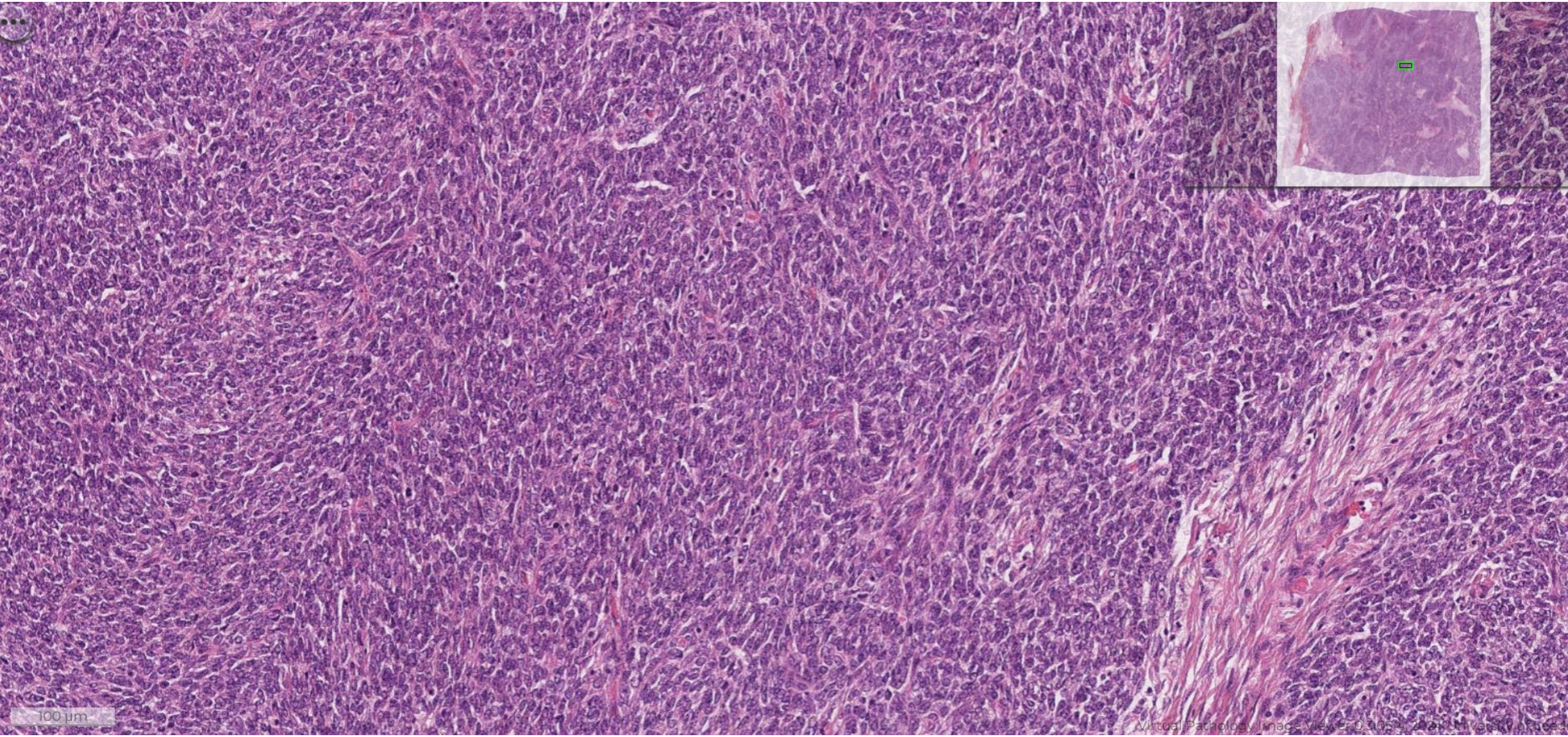
100 µm

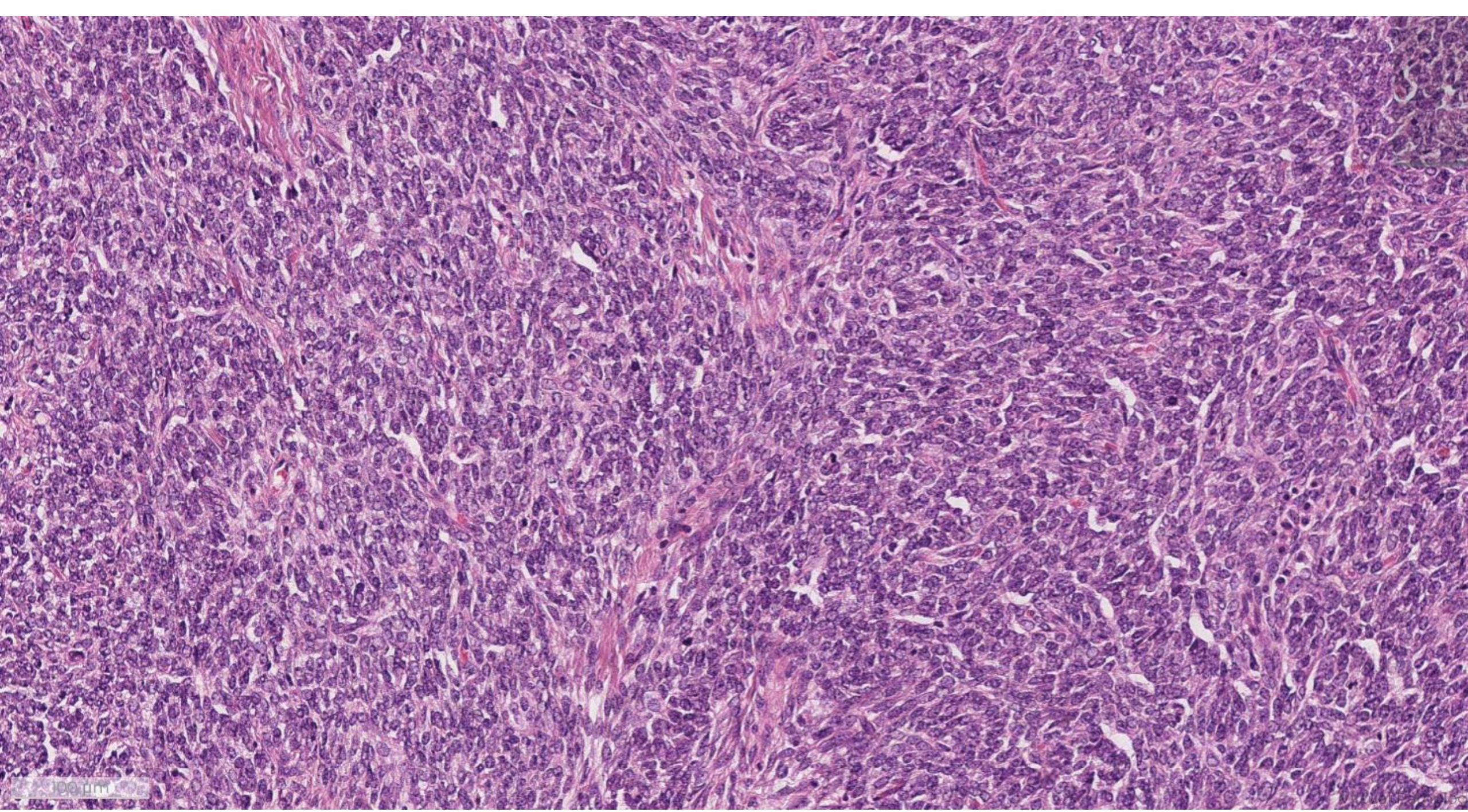

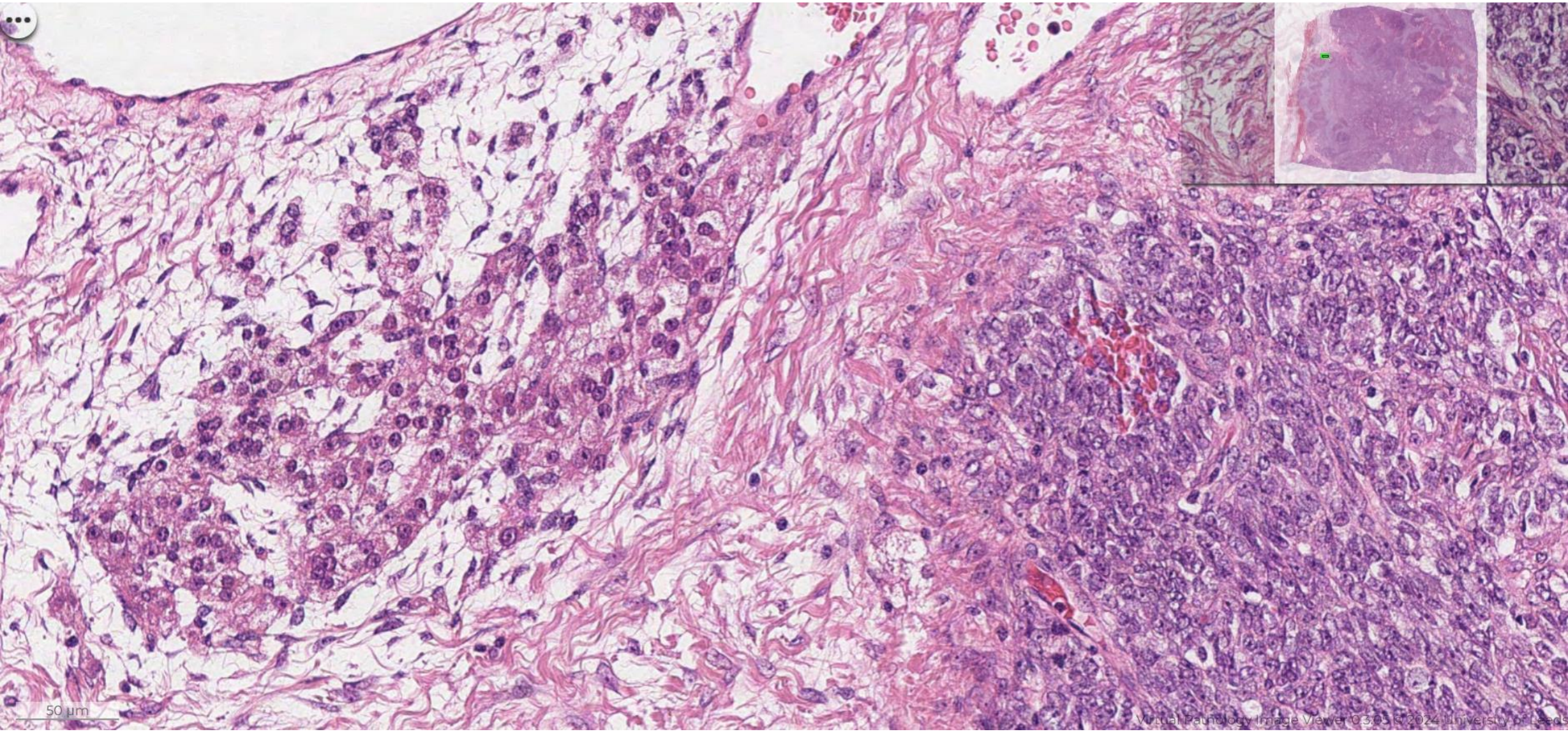
50 µm
Virtual Pathology Image Viewer 0.3.95 © 2024 University of Leeds

Short case 2 : Poorly differentiated Sertoli-Leydig cell tumour

- <0.5% ovarian neoplasms
- Ages 1-84 years (mean: 25y)
- Presentation may include hormonal manifestations (40-60% have androgenic manifestations. Occasionally oestrogenic symptoms).
- Moderately and poorly differentiated forms are most common
- Mostly sporadic. Can occur in DICER1 syndrome
- Molecular subtypes:
  - **DICER1-mutant (younger, moderately/poorly differentiated)**
  - **FOXL2-mutant (postmenopausal, moderately/poorly differentiated)**
  - DICER1/FOXL2-wildtype (intermediate patient age, well-differentiated tumours)
- Poorly differentiated tumours are clinically malignant in about 60% of cases, typically recur in peritoneal cavity within 2 years

Short case 2 : Poorly differentiated Sertoli-Leydig cell tumour

- Macro: 97% unilateral, 2 – 35 cm, solid, solid and cystic, rarely cystic. Fleshy and yellow/pink/grey. Haemorrhage and necrosis possible
- H&E: Diffuse pattern of densely packed pleomorphic spindle-shaped (sarcoma-like) cells, frequent mitotic figures. Typically with a minor component of moderately differentiated SLCT. Leydig cells typically sparse. Heterologous elements may be seen in about 20% of mod/poorly diff tumours
- IHC:
  - Sertoli – vimentin, pancytokeratin, sex cord markers (inhibin, calretinin, SF1, WT1, FOXL2)
  - Leydig – Inhibin, melan A

Short case 2 : Poorly differentiated Sertoli-Leydig cell tumour

Mark	Features
1.5 or 1	Fails to diagnose
2	Does not commit to a diagnosis, inadequate morphological description
2.5	Adequate description with confident diagnosis but no additional information
3	Some additional information, as mentioned below:
3.5	Good description, mention hormonal manifestations, expected findings and IHC, DICER1 or FOXL2 mutations, poor prognosis

Short case 3

- Female 57 years
- Vulval lesion.

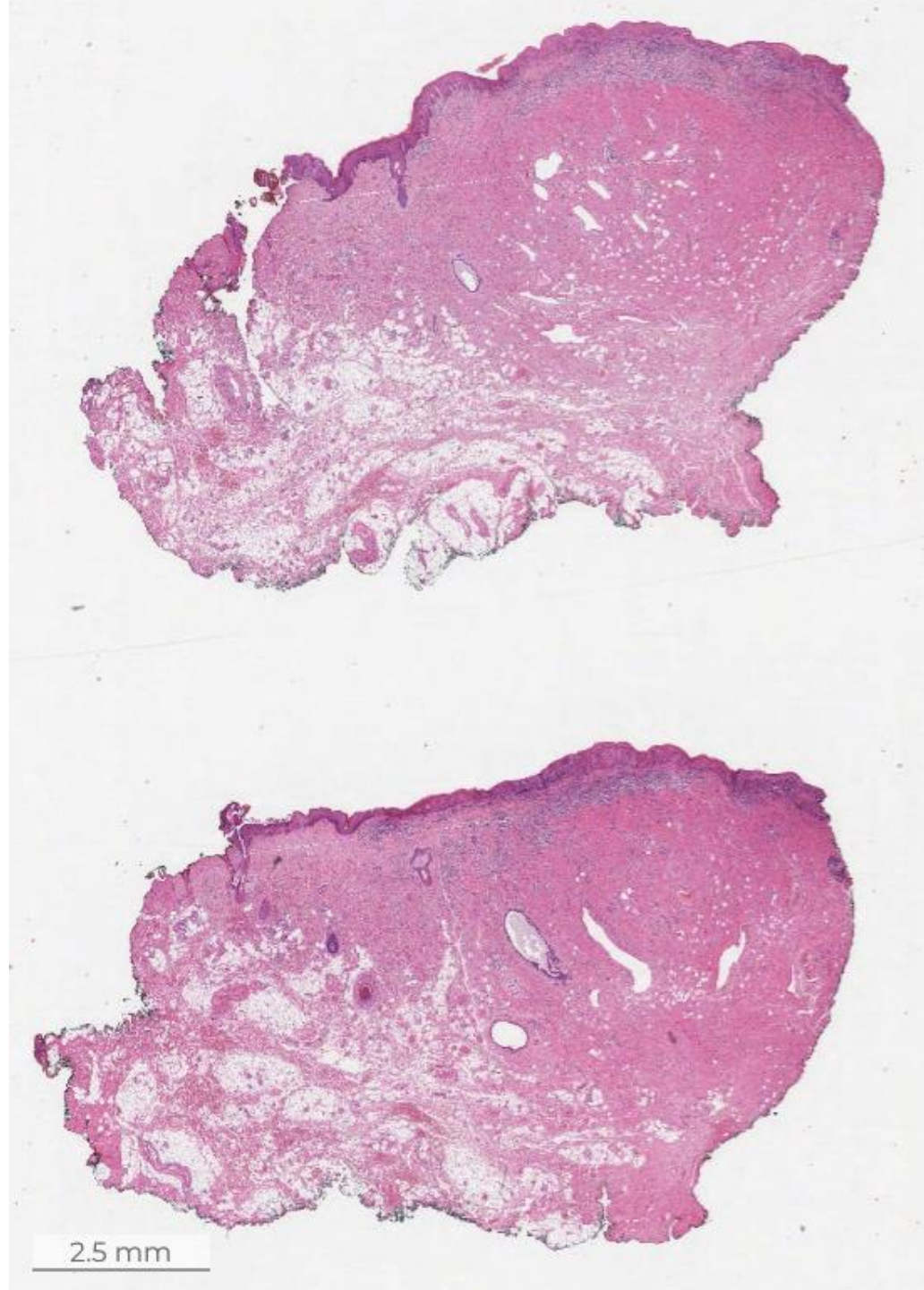
2.5 mm

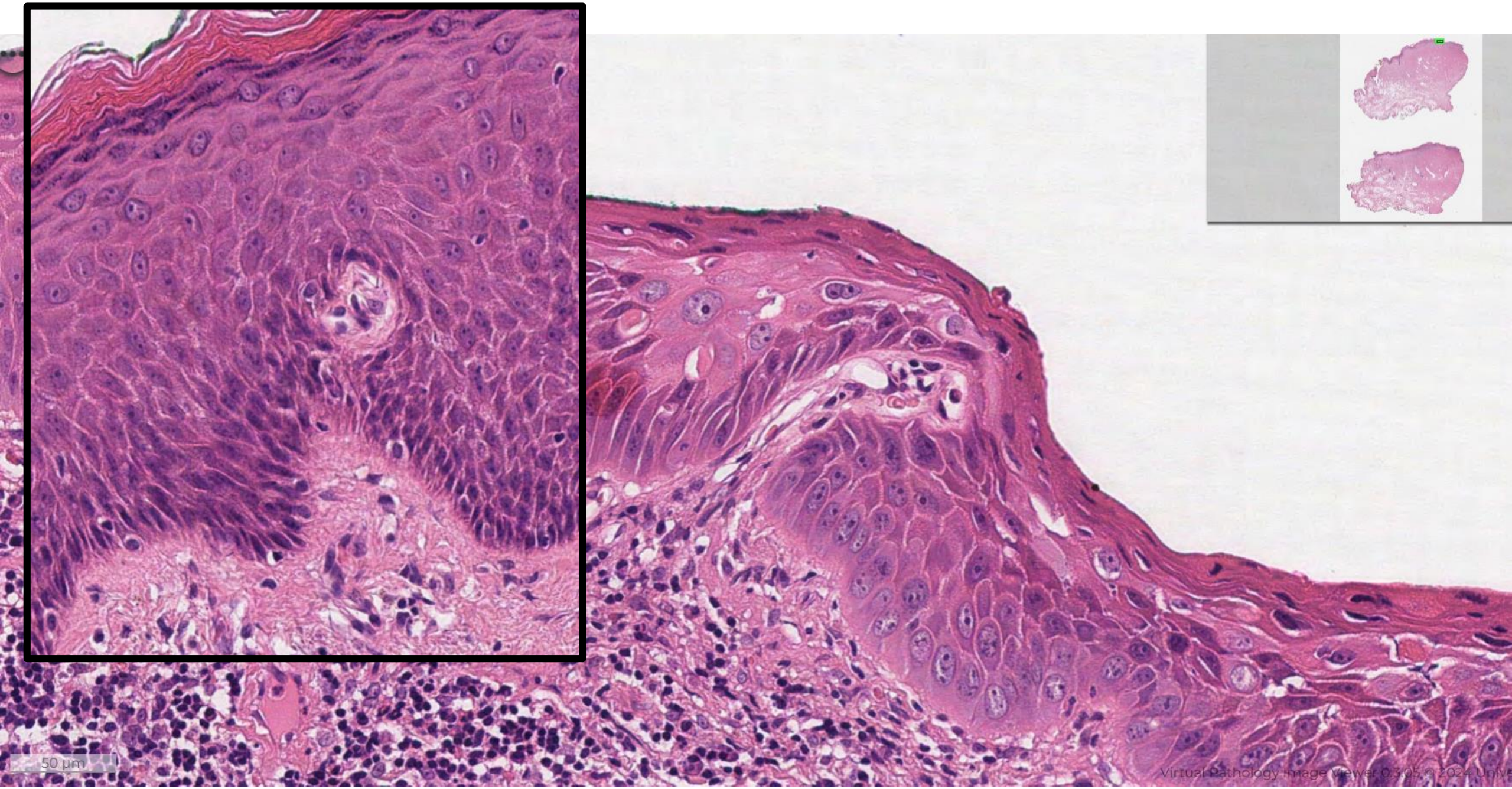
50 µm
Virtual Pathology Image Viewer 0.3.05 © 2024 Unive

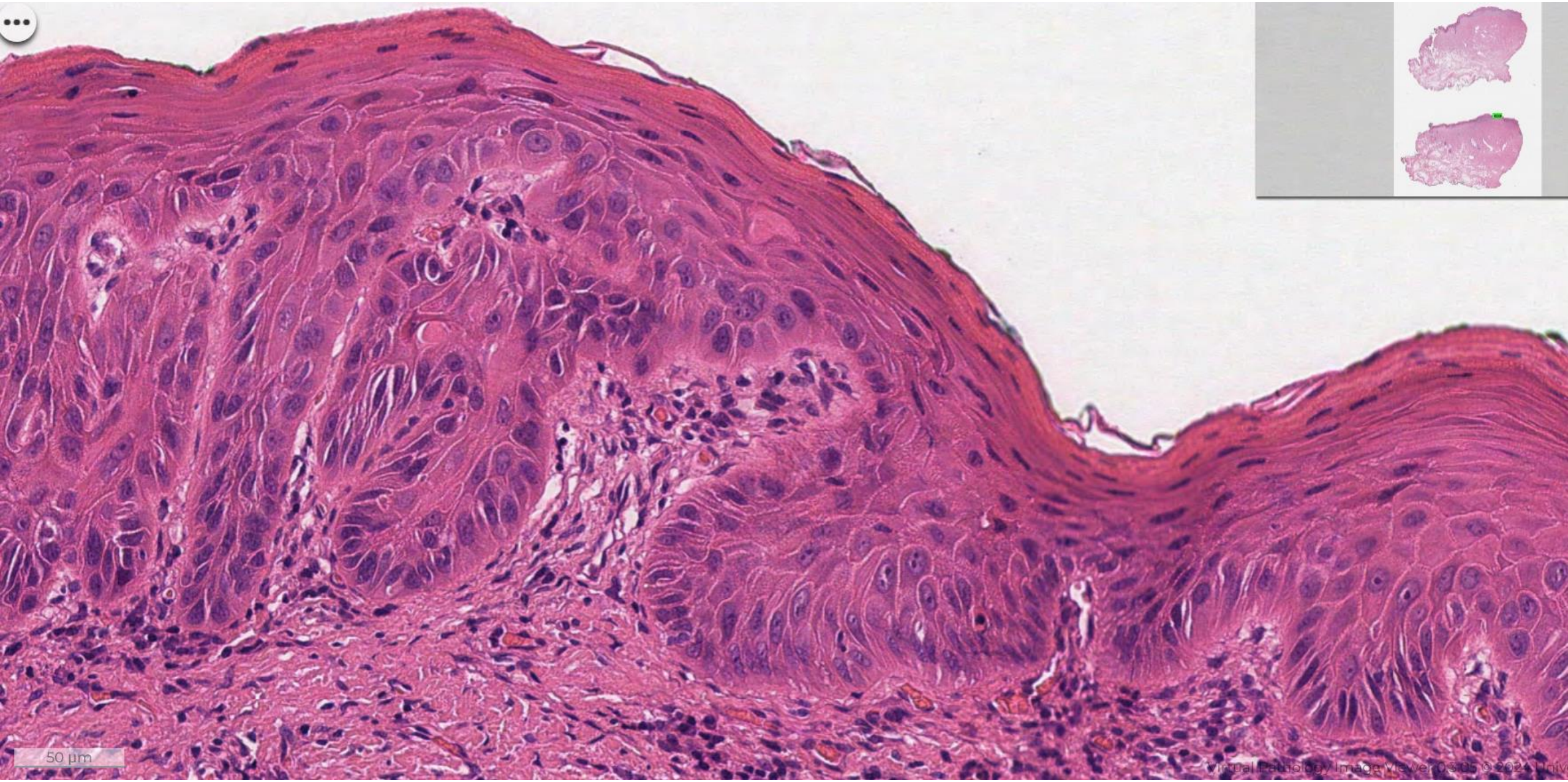
50 µm

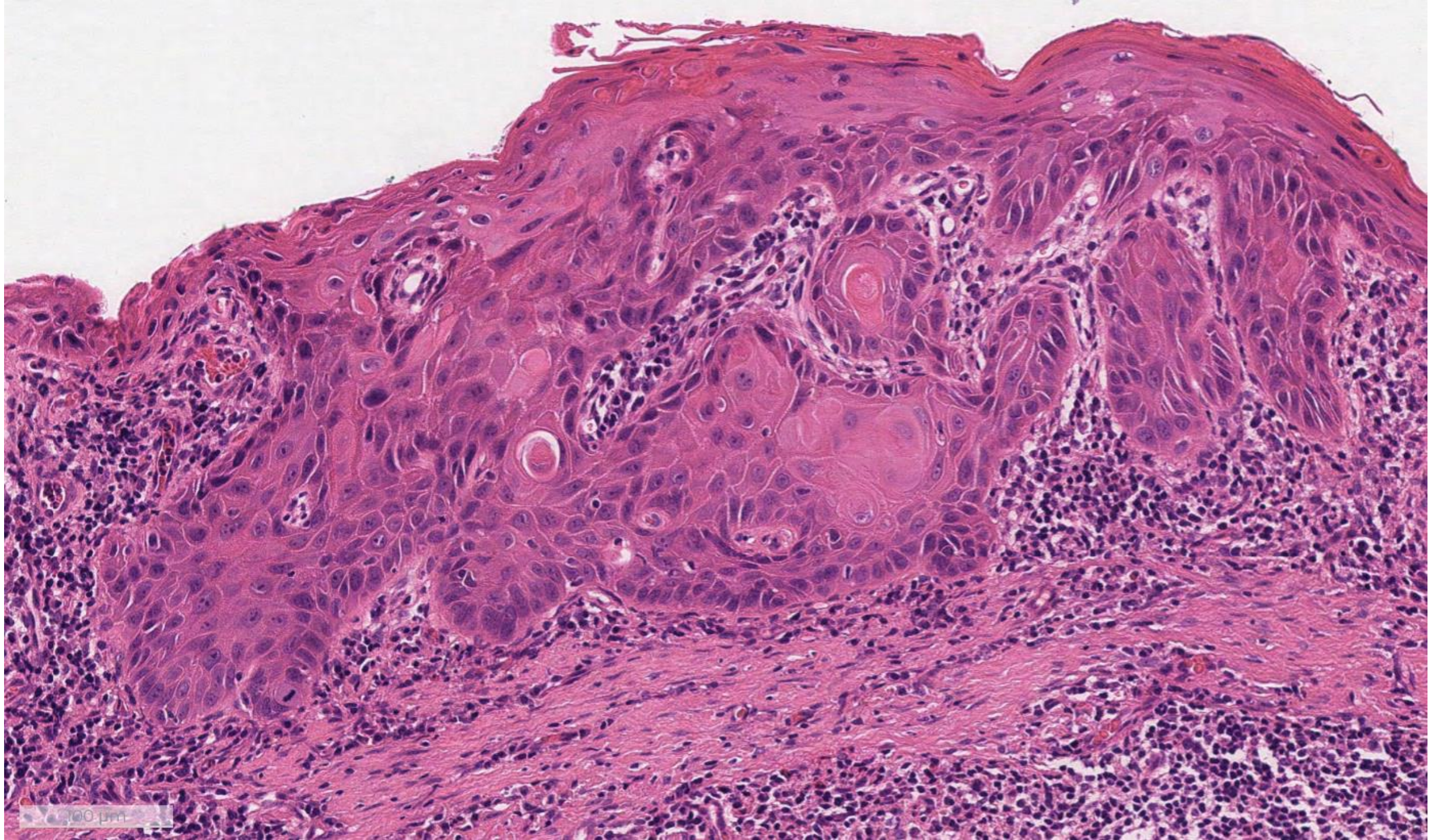
200 µm

Short case 3 : HPV-independent VIN

- Associated with lichen sclerosus or lichen planus
- Symptoms: itching, burning. 50% of cases are asymptomatic
- Typically postmenopausal, but can occur in younger patients
- TP53 mutations frequently identified
- Prognosis: High risk of malignant transformation
- DDx: HPV-associated VIN, benign reactive epithelium (lichen simplex chronicus, hypertrophic lichen sclerosus, lichen planus)

Short case 3 : HPV-independent VIN

- Macro: usually unifocal. Thick keratinised plaques or erosive erythematous plaques
- H&E: Atypia of basal and parabasal keratinocytes in an otherwise well-differentiated epithelium. Parakeratosis. Can be atrophic or acanthotic with elongated and anastomosing rete ridges. Keratin pearls or dyskeratosis
- Atypical cells: enlarged, eosinophilic, large vesicular/hyperchromatic nuclei, macronucleoli, prominent intercellular bridges, mitoses
- Extension into skin appendages is rare
- IHC: abnormal p53 expression (e.g. overexpression or null pattern), p16 negative

Short case 3 : HPV-independent VIN

Mark	Features
1.5 or 1	Fails to diagnose
2	Does not commit to a diagnosis, inadequate morphological description
2.5	Adequate description with confident diagnosis but no additional information
3	Some additional information, as mentioned below:
3.5	Good description, association with LS or LP, TP53 mutation, IHC (p16 negative, p53 abnormal)

Short case 4

- Female 25 years
- Products of conception.

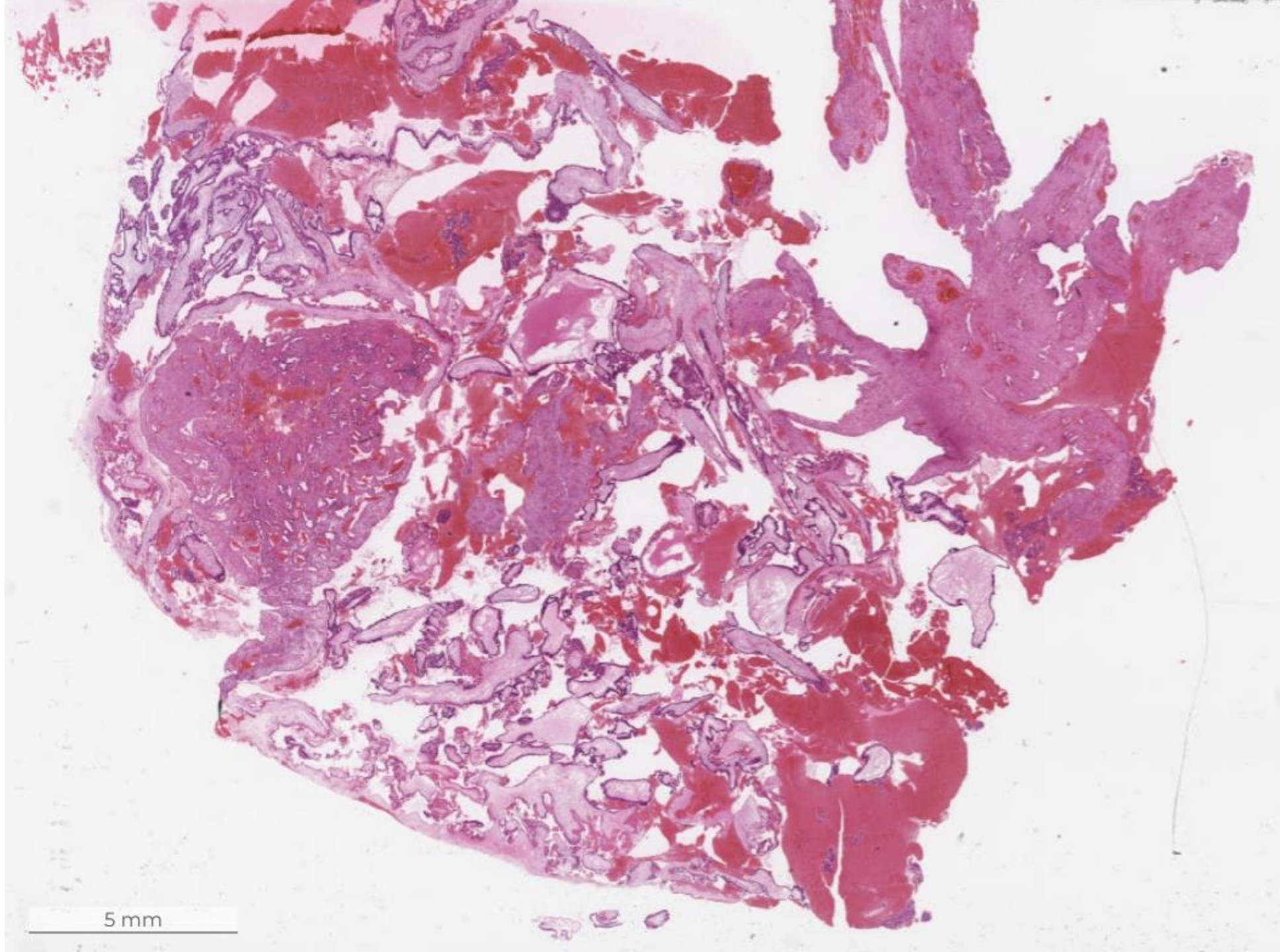
5 mm


200 µm

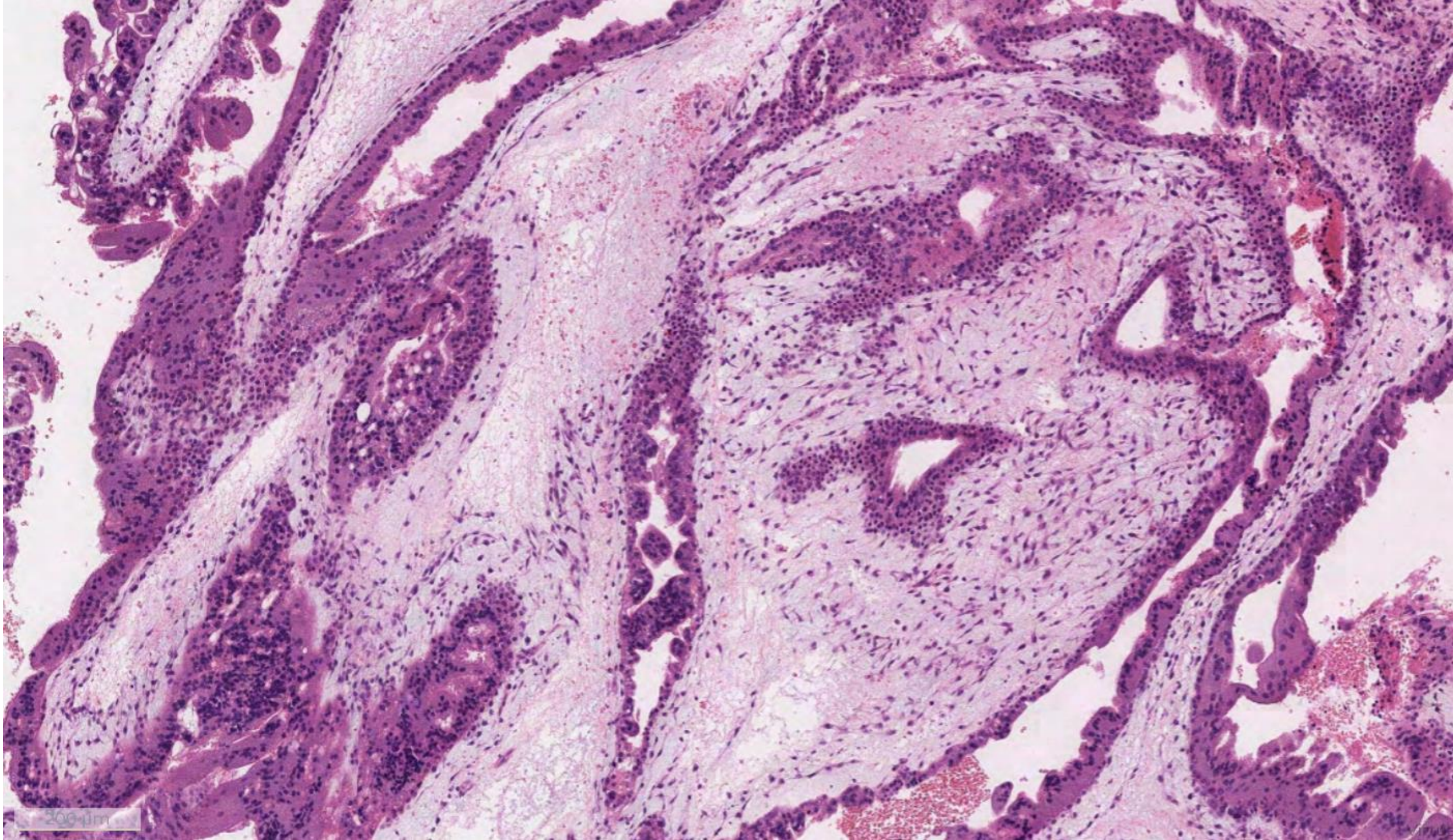
200 µm

Short case 4 : Complete hydatidiform mole

- Abnormal gestation with diffuse trophoblastic proliferation and villous hydrops without embryonic development
- Aetiology: paternal-only (androgenetic diploid) genome
- Second trimester vaginal bleeding, excessive uterine size, hyperemesis, hyperthyroidism, pre-eclampsia
- Markedly elevated serum β-hCG
- USS: Snow-storm appearance (numerous cystic hypoechoic spaces), absence of fetal development
- PMH of mole = increased risk for future molar pregnancy

Short case 4 : Complete hydatidiform mole

- Macro: Grape-like clusters of vesicles. Fetal parts absent
- H&E: Enlarged, oedematous villi, cistern formation, circumferential trophoblast hyperplasia, trophoblastic pseudoinclusions (irregularly shaped/oval). Prominent karyorrhexis. No fetal vessels or RBCs. Significant atypia and mitotic figures at the implantation site.
- IHC: p57 - absence of nuclear staining in villous stroma & cytotrophoblast
- DDx: Partial hydatidiform mole, hydropic abortion, chromosomal trisomies
- Requires referral to trophoblastic disease centre, follow-up of hCG
- 15-20% risk of persistent gestational trophoblastic disease
- 2-3% risk of choriocarcinoma

Short case 4 : Complete hydatidiform mole

Mark	Features
1.5 or 1	Fails to diagnose
2	Does not commit to a diagnosis, inadequate morphological description
2.5	Adequate description with confident diagnosis but no additional information
3	Some additional information, as mentioned below:
3.5	Good description, mention aetiology (paternal-only genome), p57 negative villous cells and cytotrophoblast, risk of persistent gestational trophoblastic disease/choriocarcinoma, requires referral to GTD centre

Short case 5

- Female 67 years
- Endometrial tumour. Hysterectomy, BSO, BSLND.

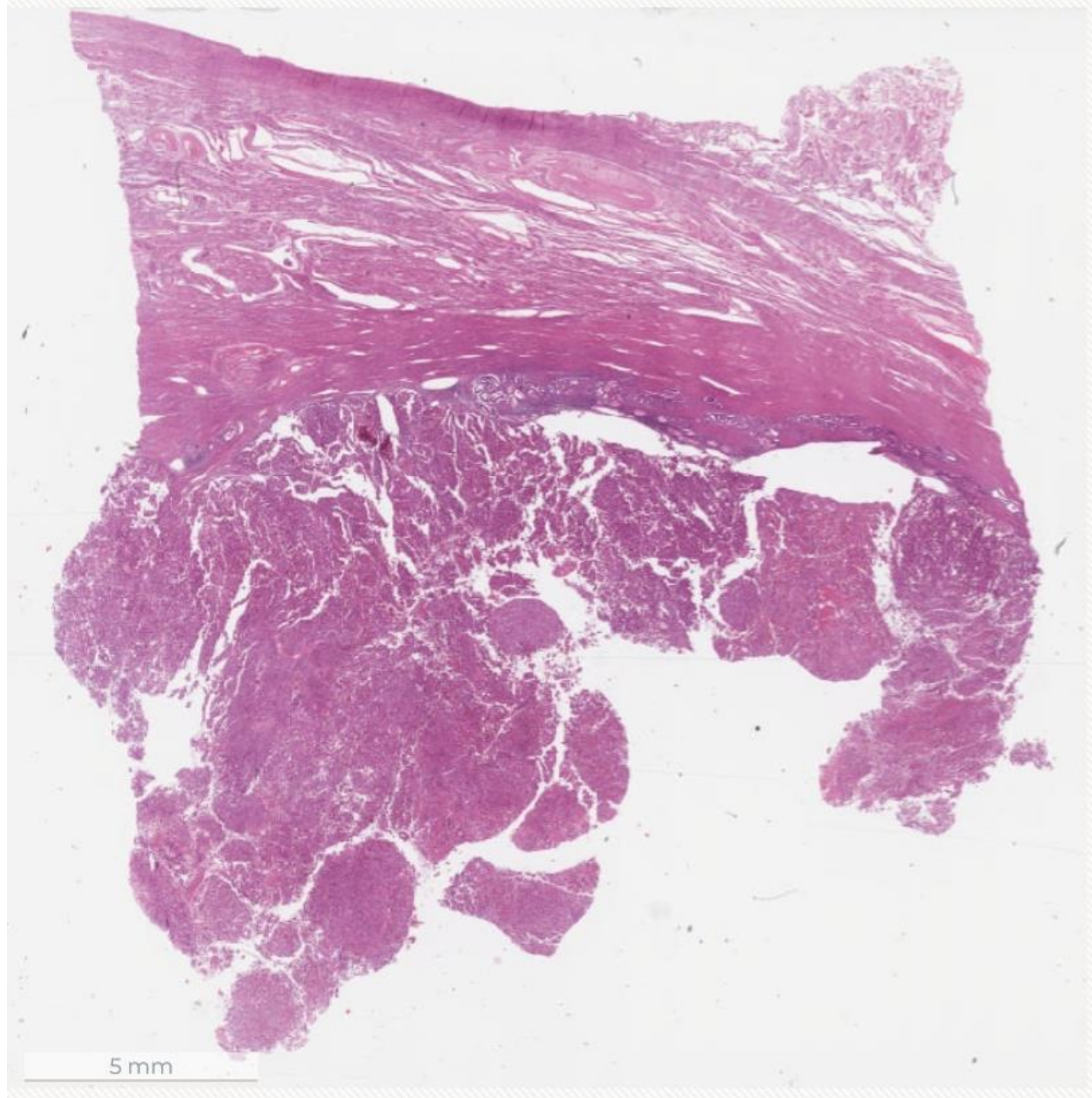
5 mm

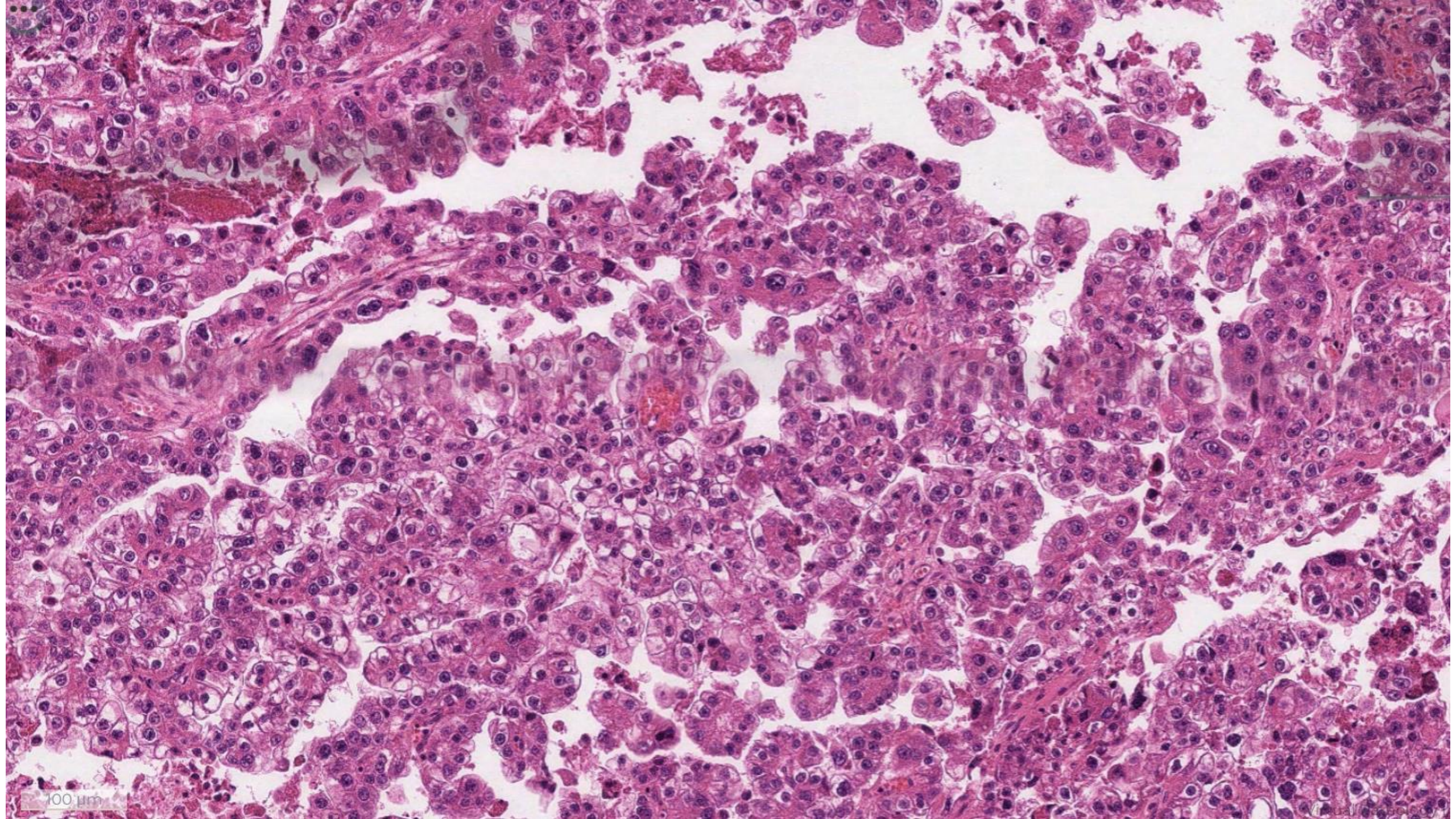
100 µm

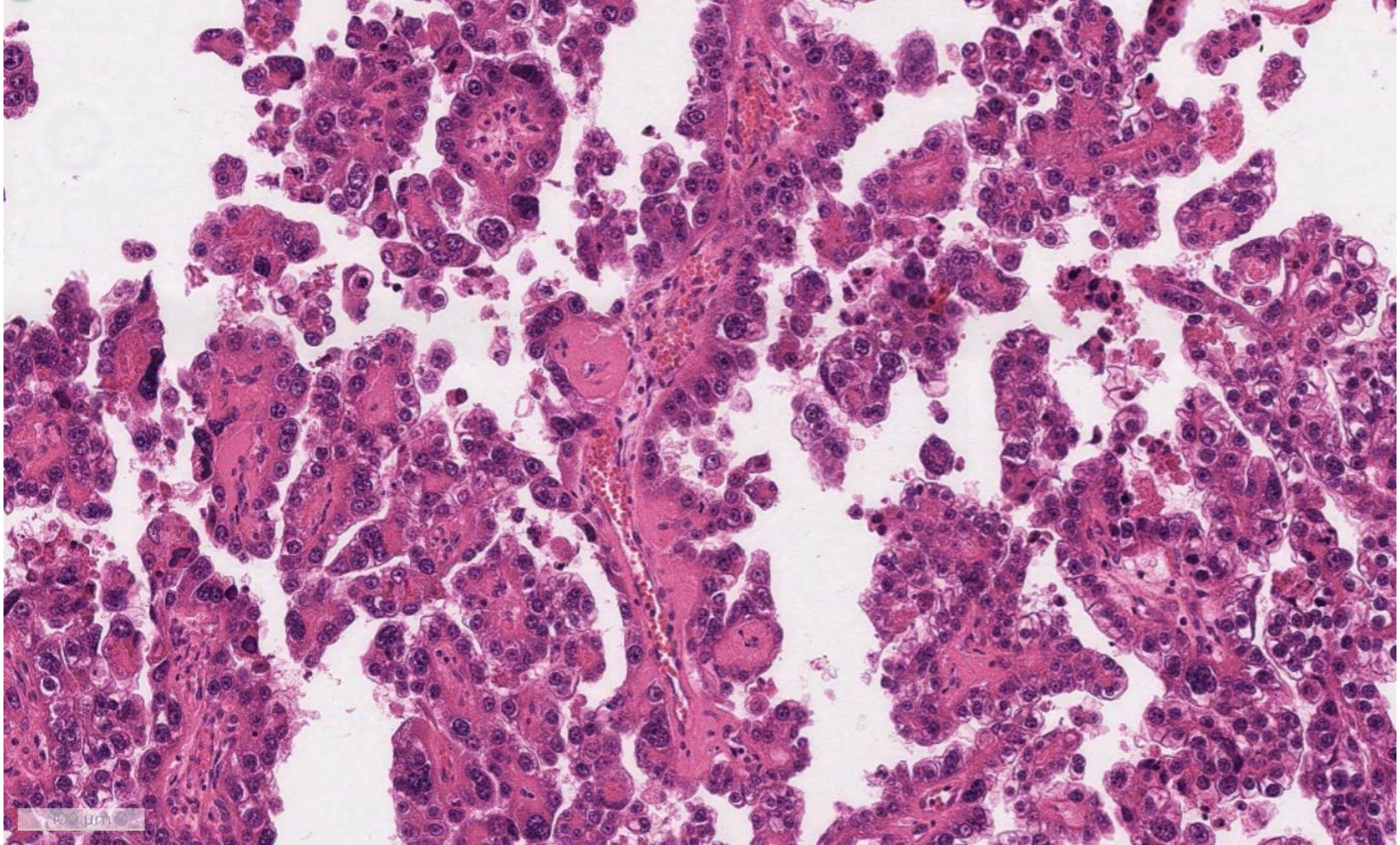
100 µm

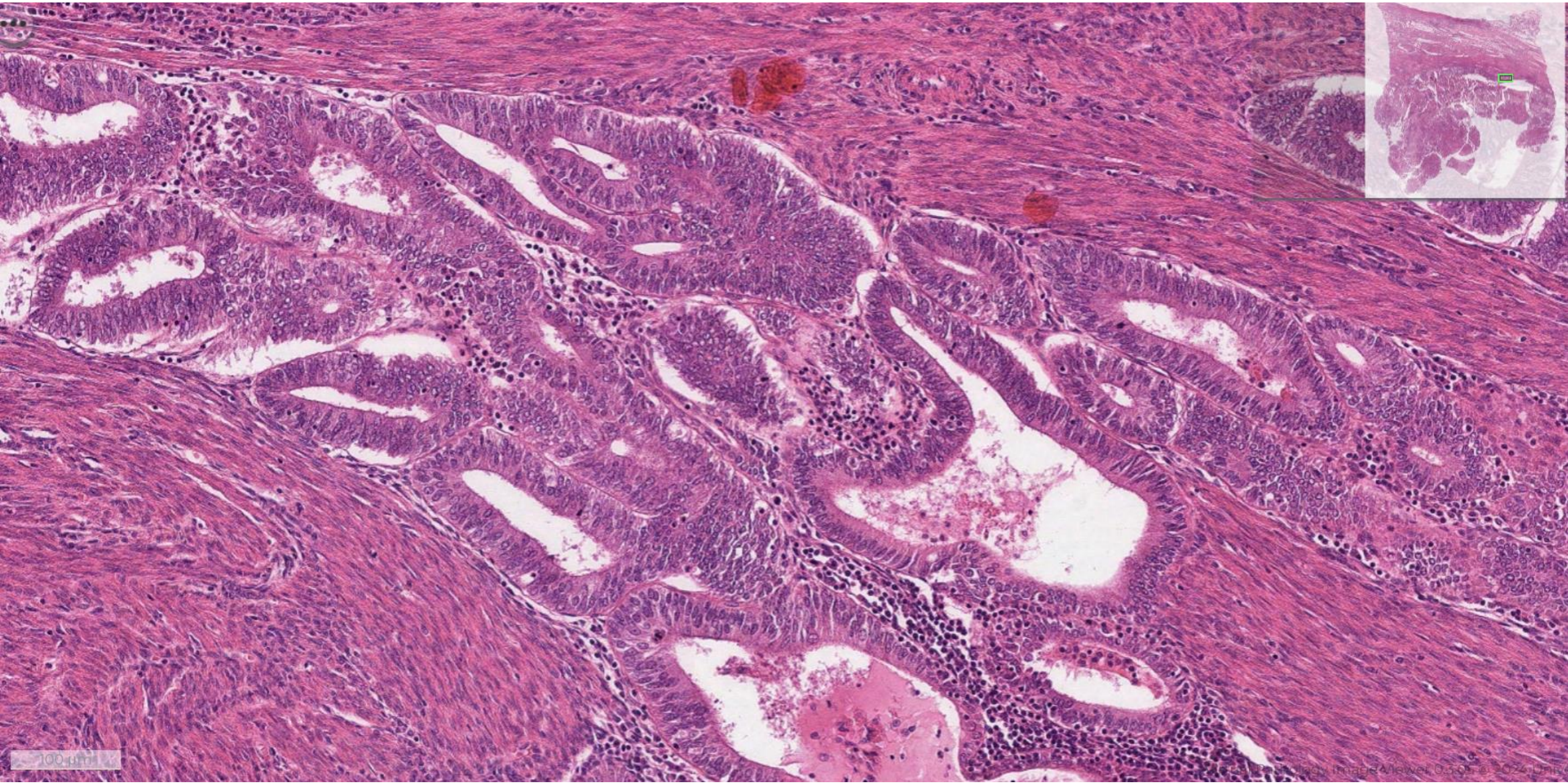
100 µm

Short case 5 : Clear cell carcinoma of the endometrium

- Rare, <10% of all endometrial carcinomas
- Mean age: mid to late 70s
- PMB most common presenting symptom. Cervical cytology screening may be abnormal
- About 50-60% are early stage at presentation
- No known histotype-specific molecular profile
- 5-year survival 55-78%. Most relapses occur outside the pelvis.

  Poor prognostic factors: advanced age and stage

Short case 5 : Clear cell carcinoma of the endometrium

- Macro: friable intrauterine mass
- H&E:
  - Tubulo-cystic, papillary, solid patterns – frequently admixed. Papillae are short and rounded and often have hyalinised stroma.
  - Cuboidal, polygonal, hobnail, or flat appearances of cells, with clear/eosinophilic cytoplasm
  - Can have tall columnar cells, abundant stratification, intraglandular tufting, detached budding
  - Nuclear pleomorphism variable – usually at least focal moderate to severe atypia
- IHC: napsin A positive. ER, PR usually negative/focal. 22-72% show mutated p53

Short case 5 : Clear cell carcinoma of the endometrium

Mark	Features
1.5 or 1	Fails to diagnose
2	Does not commit to a diagnosis, inadequate morphological description
2.5	Adequate description with confident diagnosis but no additional information
3	Some additional information, as mentioned below:
3.5	Good description, mention expected findings and IHC, all four molecular subtypes can be seen, mention background endometrial hyperplasia

Short case 6

- Female 33 years
- Prophylactic BSO, BRCA 1 carrier, section from ovary.

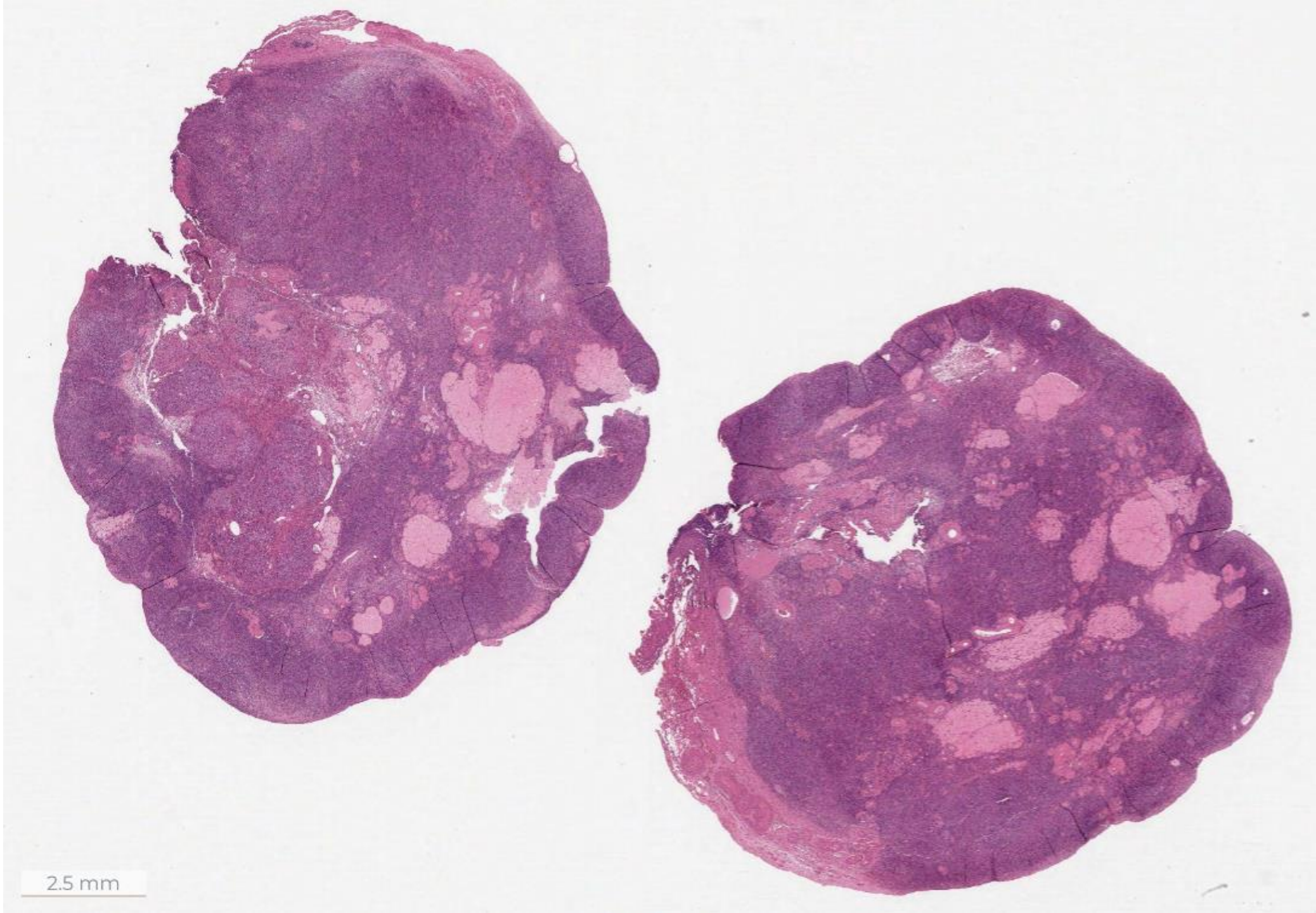
2.5 mm

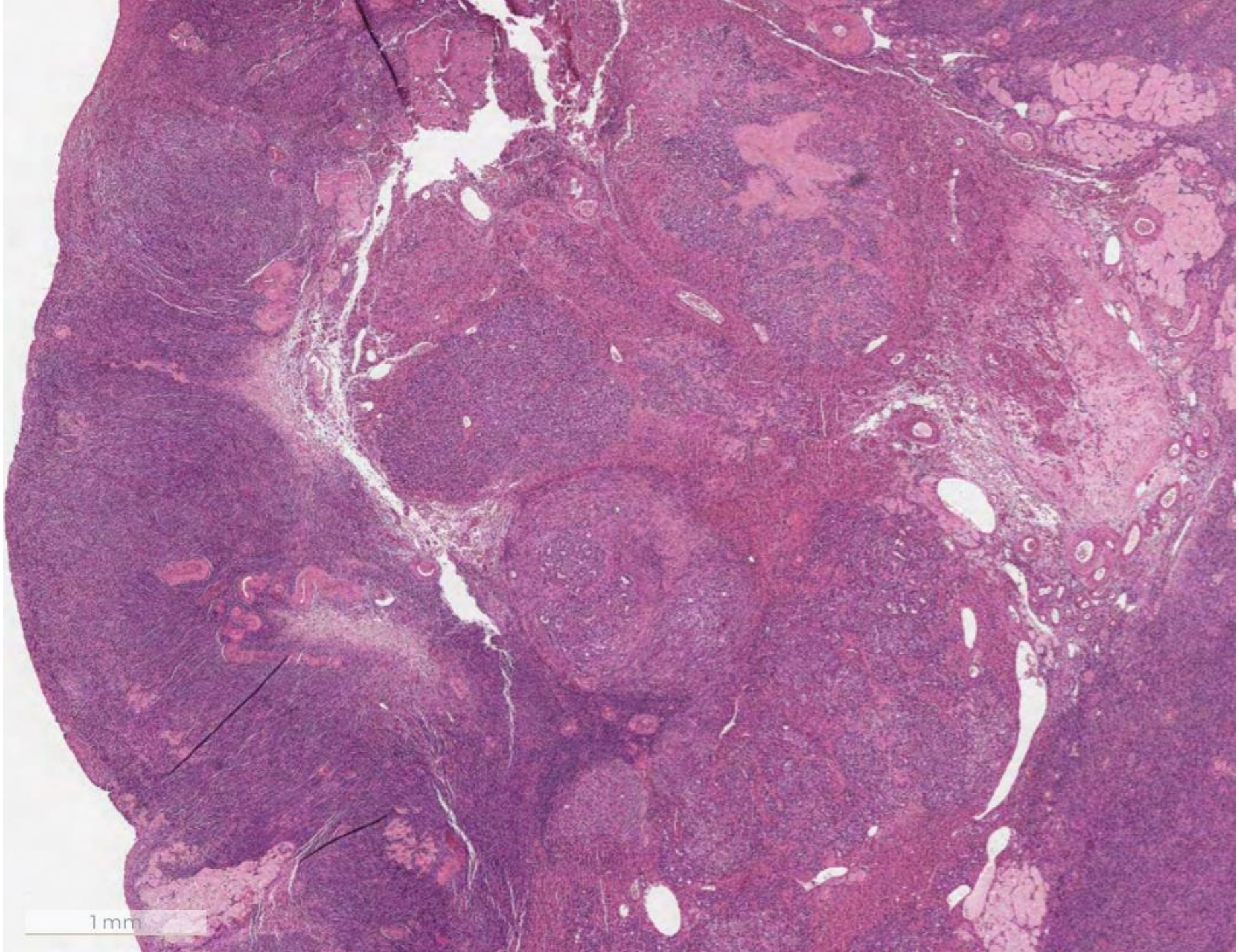
1 mm

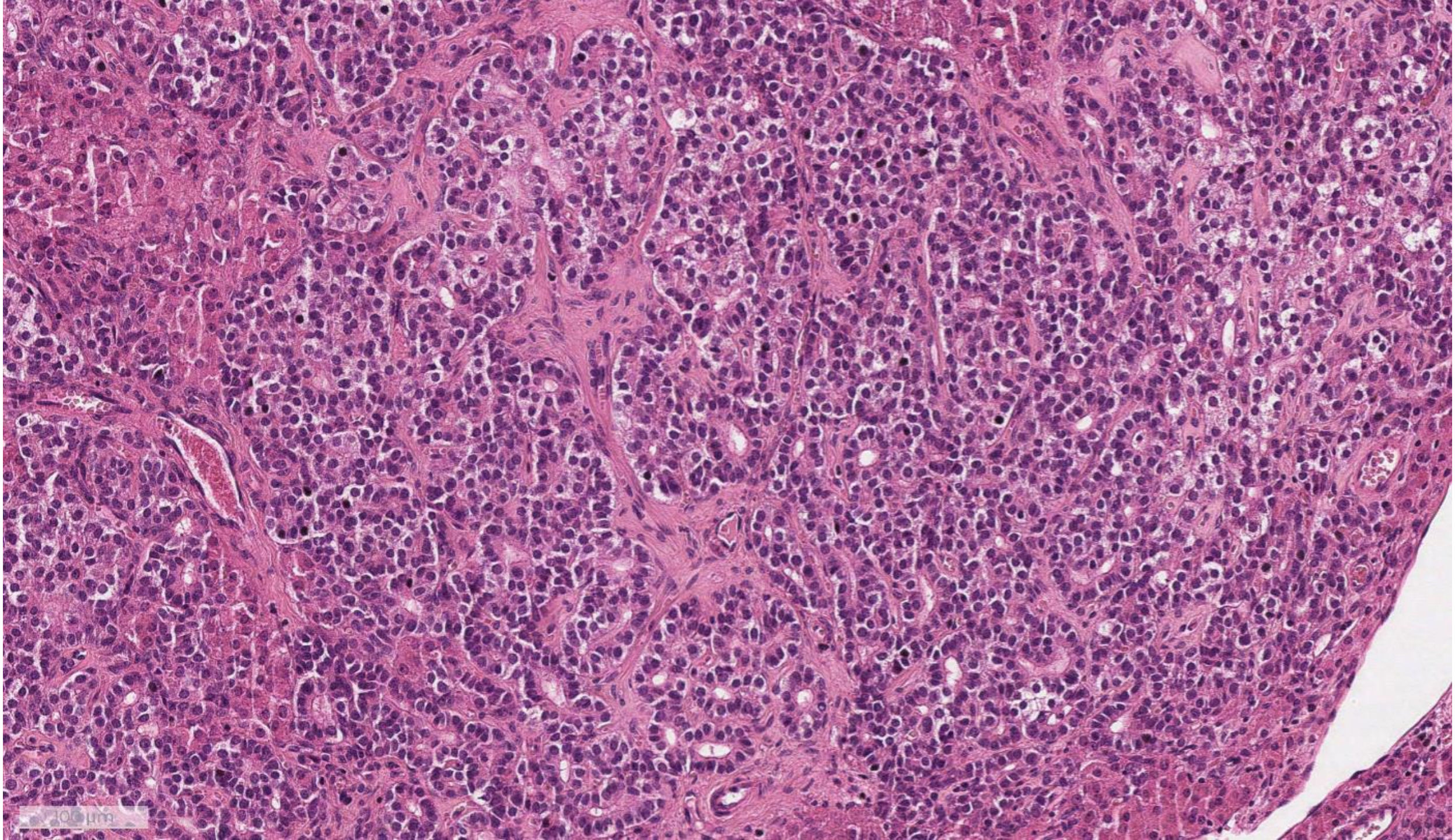
100 µm

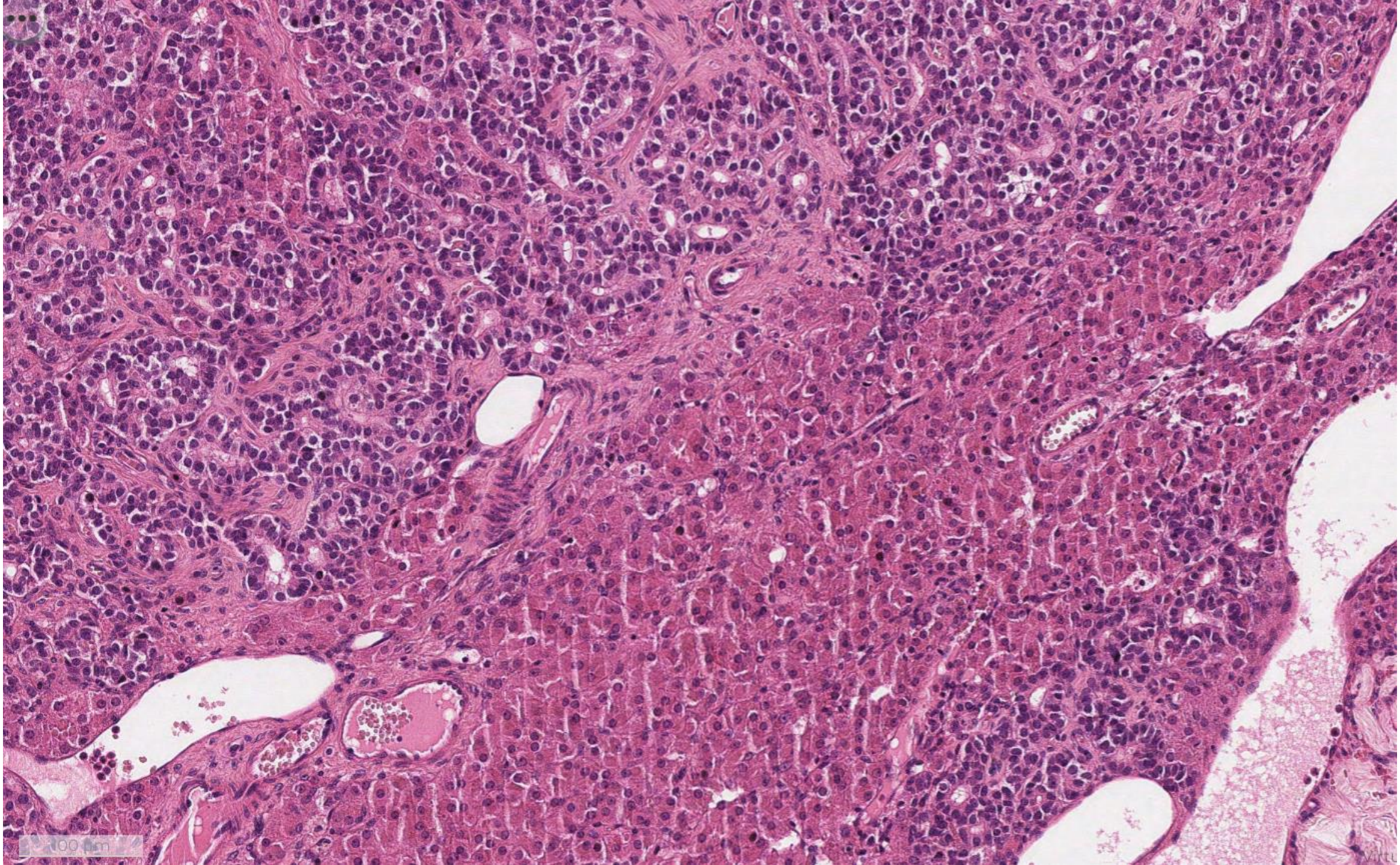

Short case 6 : Well differentiated Sertoli-Leydig cell tumour

- <0.5% ovarian neoplasms
- Ages 1-84 years (mean: 25y)
- Presentation may include hormonal manifestations (40-60% have androgenic manifestations. Occasionally oestrogenic symptoms). Other symptoms: abdominal pain, ascites, tumour rupture
- **Well differentiated tumours almost always occur in pure form**
- Mostly sporadic
- Molecular subtypes:
  - DICER1-mutant (younger, moderately/poorly differentiated)
  - FOXL2-mutant (postmenopausal, moderately/poorly differentiated)
  - **DICER1/FOXL2-wildtype (intermediate patient age, well-differentiated tumours)**
- **Well differentiated tumours – survival rate of almost 100%**

Short case 6 : Well differentiated Sertoli-Leydig cell tumour

- Macro: 97% unilateral, 2 – 35 cm, solid, solid and cystic, rarely cystic. Fleshy and pale yellow/pink/grey. Haemorrhage and necrosis possible
- **H&E: Sertoli cells in open/closed tubules without significant nuclear atypia or mitotic activity. Delicate fibrous stroma contains Leydig cells in clusters/cords/singly. These cells may be vacuolated, contain lipofuscin, and have Reinke crystals**
- IHC:
  - Sertoli – vimentin, pancytokeratin, sex cord markers (inhibin, calretinin, SF1, WT1, FOXL2)
  - Leydig – Inhibin, melan A

Short case 6 : Well differentiated Sertoli-Leydig cell tumour

Mark	Features
1.5 or 1	Fails to diagnose
2	Does not commit to a diagnosis, inadequate morphological description
2.5	Adequate description with confident diagnosis but no additional information
3	Some additional information, as mentioned below:
3.5	Good description, mention hormonal manifestations, expected findings and IHC, DICER1/FOXL2 wildtype, excellent prognosis

Short case 7

- Female 42 years
- Ovarian mass, benign appearance on imaging, section from ovary.

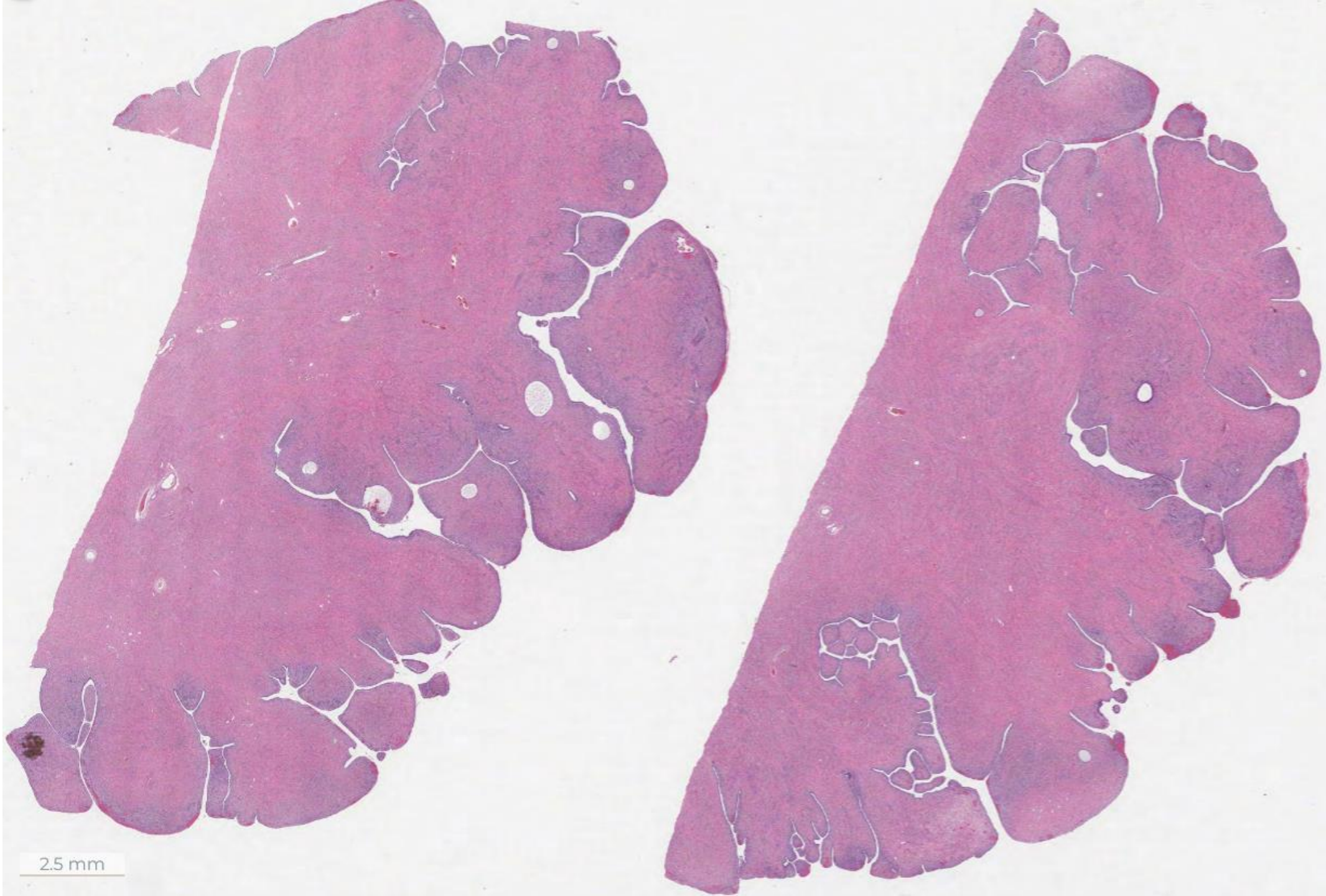
2.5 mm

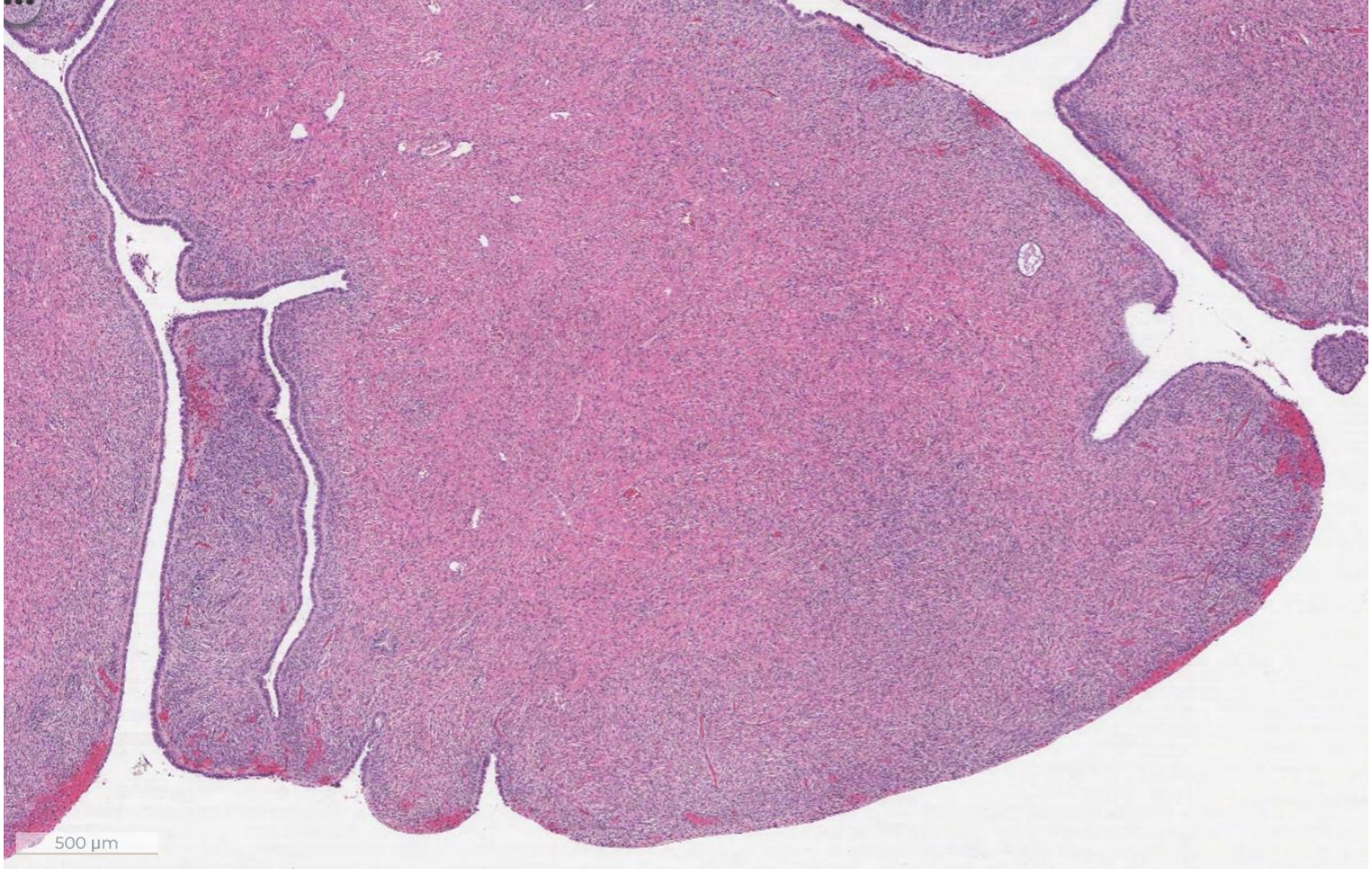
500 µm

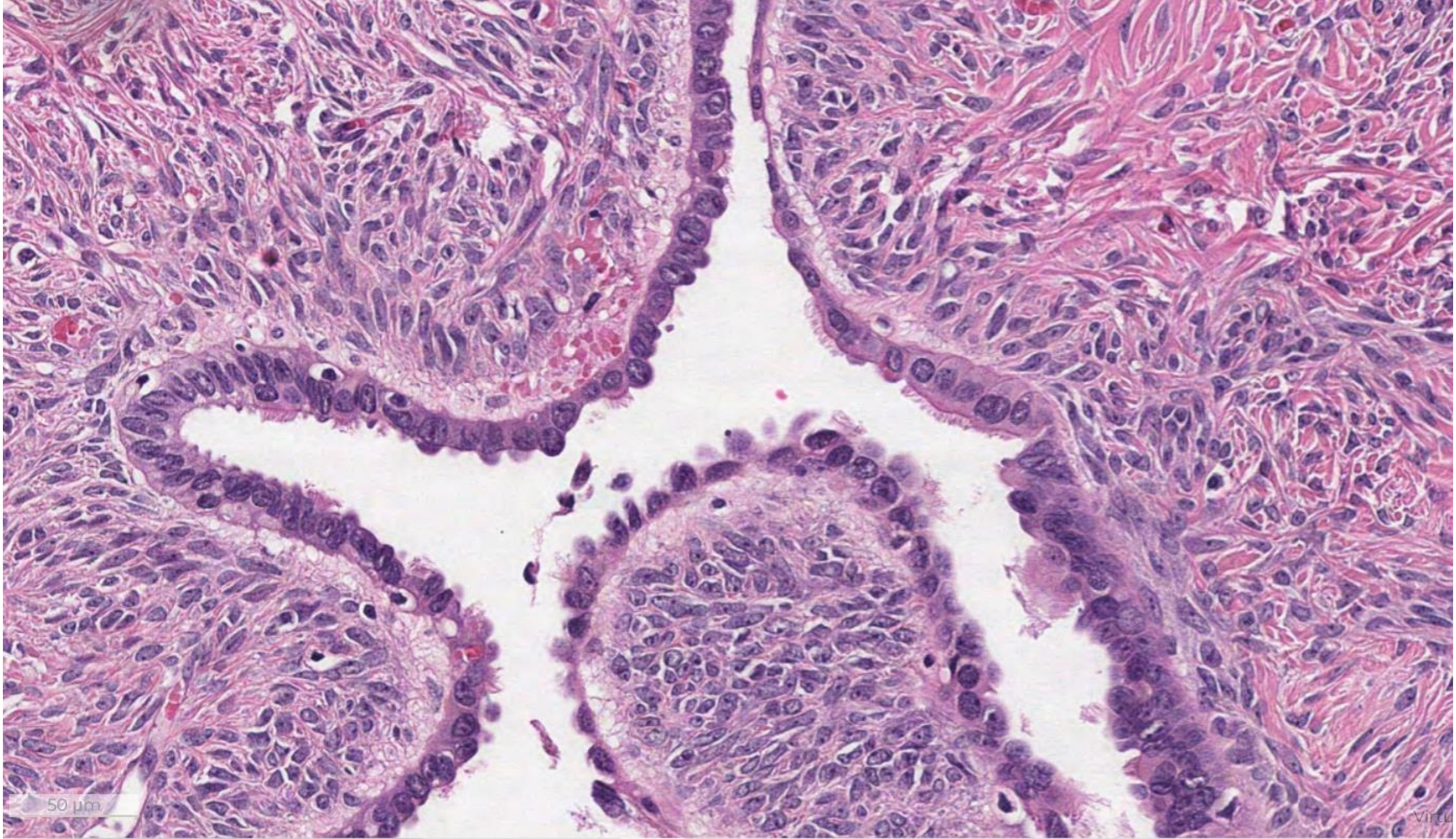
50 µm

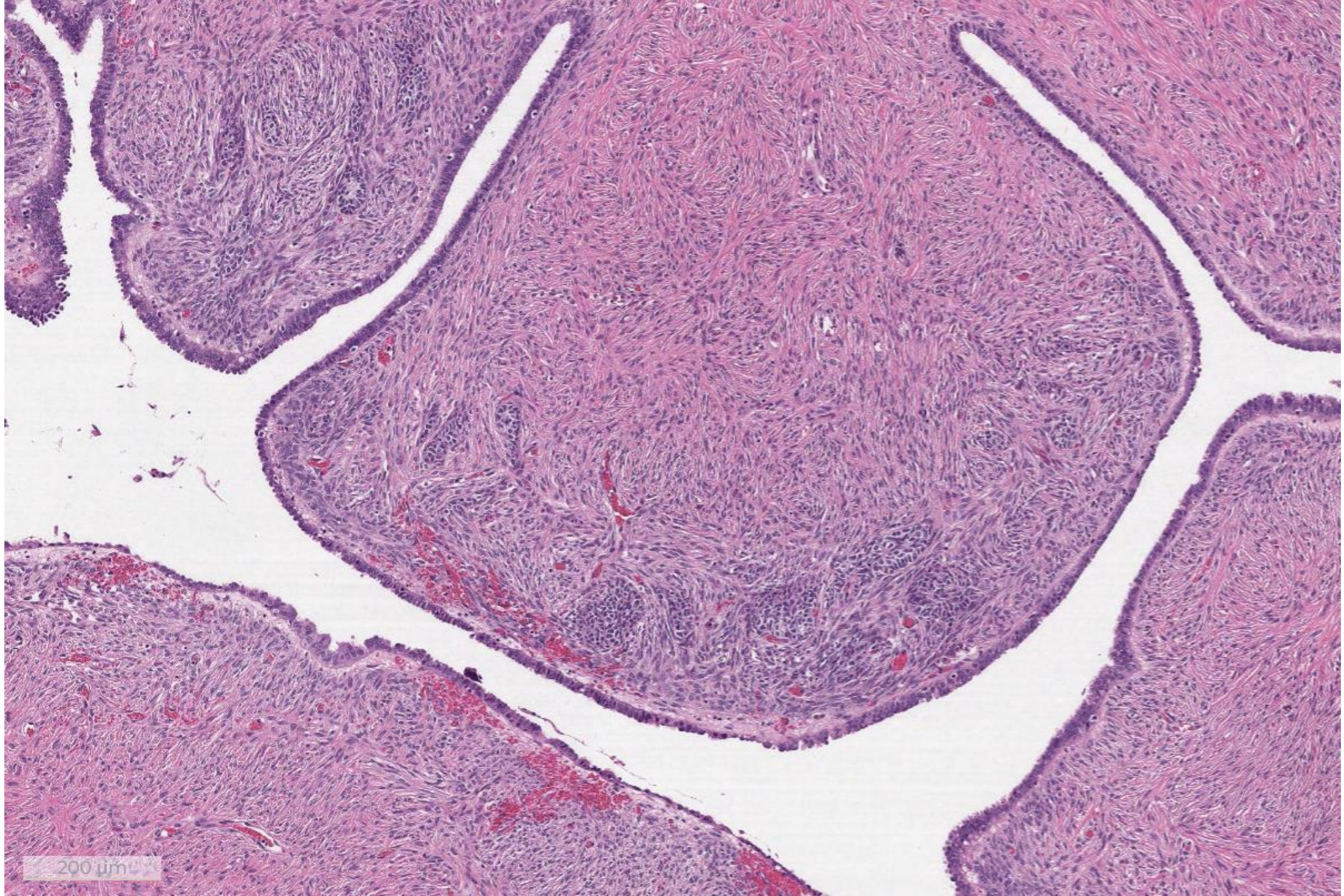
200 µm

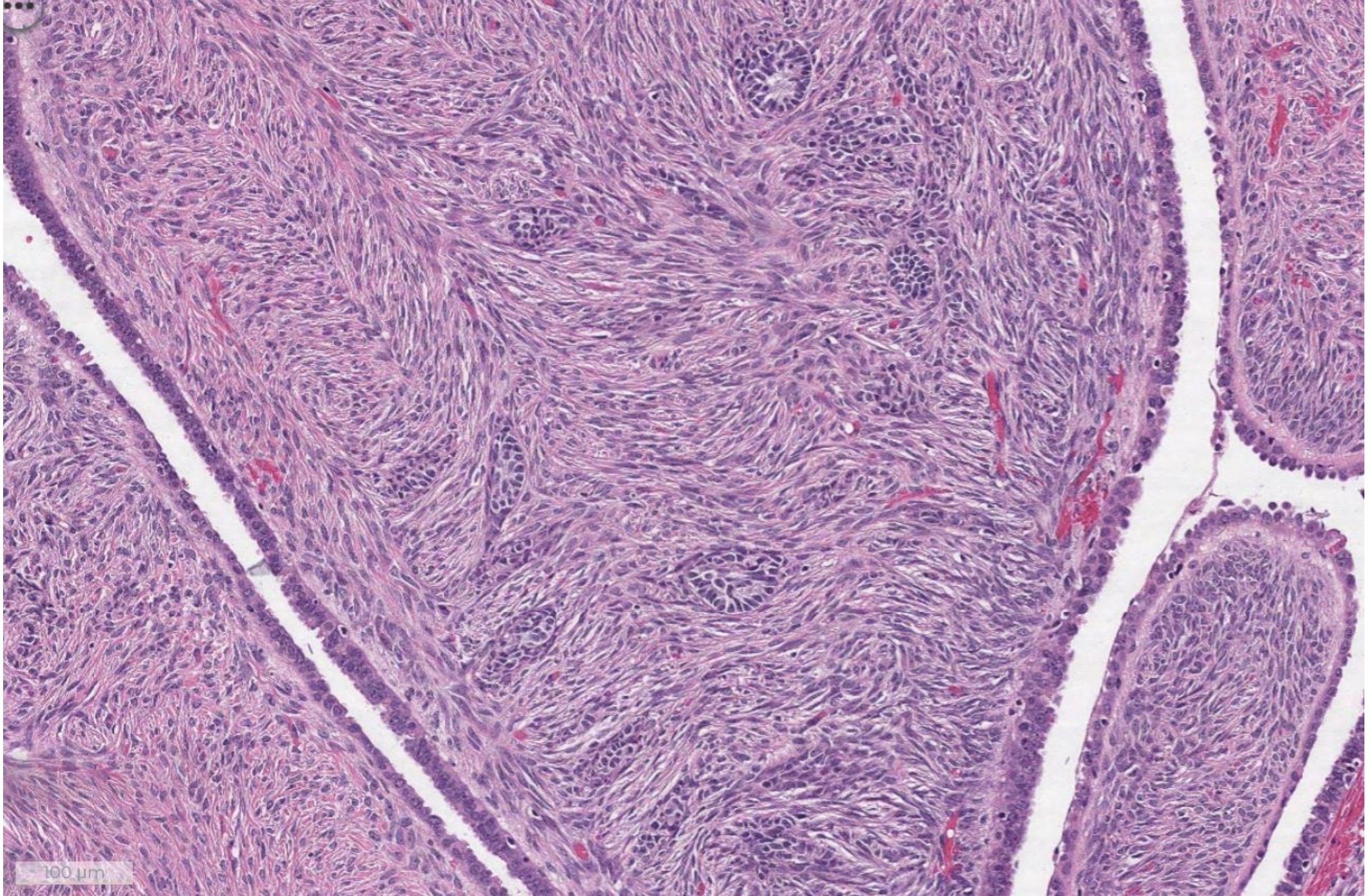
100 µm

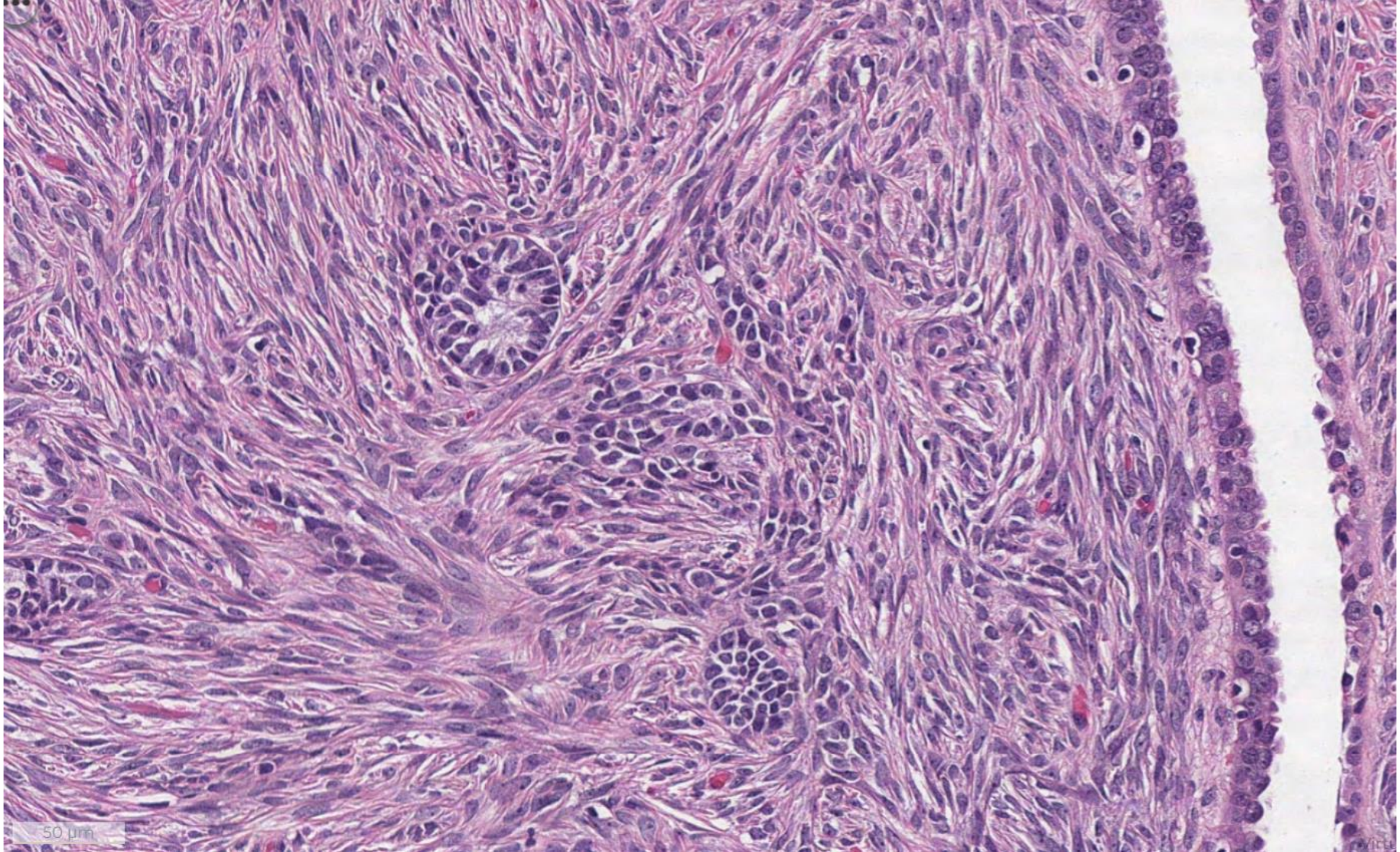
50 µm

Short case 7 : Serous cystadenofibroma with minor sex cord elements

- Serous cystadenofibromas - ovarian serous tumours often present with symptoms related to ovarian mass, or are found incidentally
- Common neoplasms, with wide age range
- Rarely contain sex cord-stromal elements
- Benign behaviour, good prognosis
- May recur after incomplete excision

Short case 7 : Serous cystadenofibroma with minor sex cord elements

- Macro: tumours vary widely in size. Smooth outer surfaces, may be septated and filled with watery fluid. Cysts surrounded by variable amount of solid areas. Broad, firm papillae along cyst lining.
- H&E: Broad and simple papillae with prominent fibromatous stroma, epithelial lining consists of non-stratified cuboidal/columnar cells.
- IHC: sex cord elements – inhibin, calretinin positive
- No borderline features

Short case 7 : Serous cystadenofibroma with minor sex cord elements

Mark	Features
1.5 or 1	Fails to diagnose
2	Does not commit to a diagnosis, inadequate morphological description
2.5	Adequate description with confident diagnosis but no additional information
3	Some additional information, as mentioned below:
3.5	Good description, identification of sex cord component and expected IHC, mention absence of borderline features

Short case 8

- Female 50 years
- Ovarian mass, increasing in size, section from ovary.

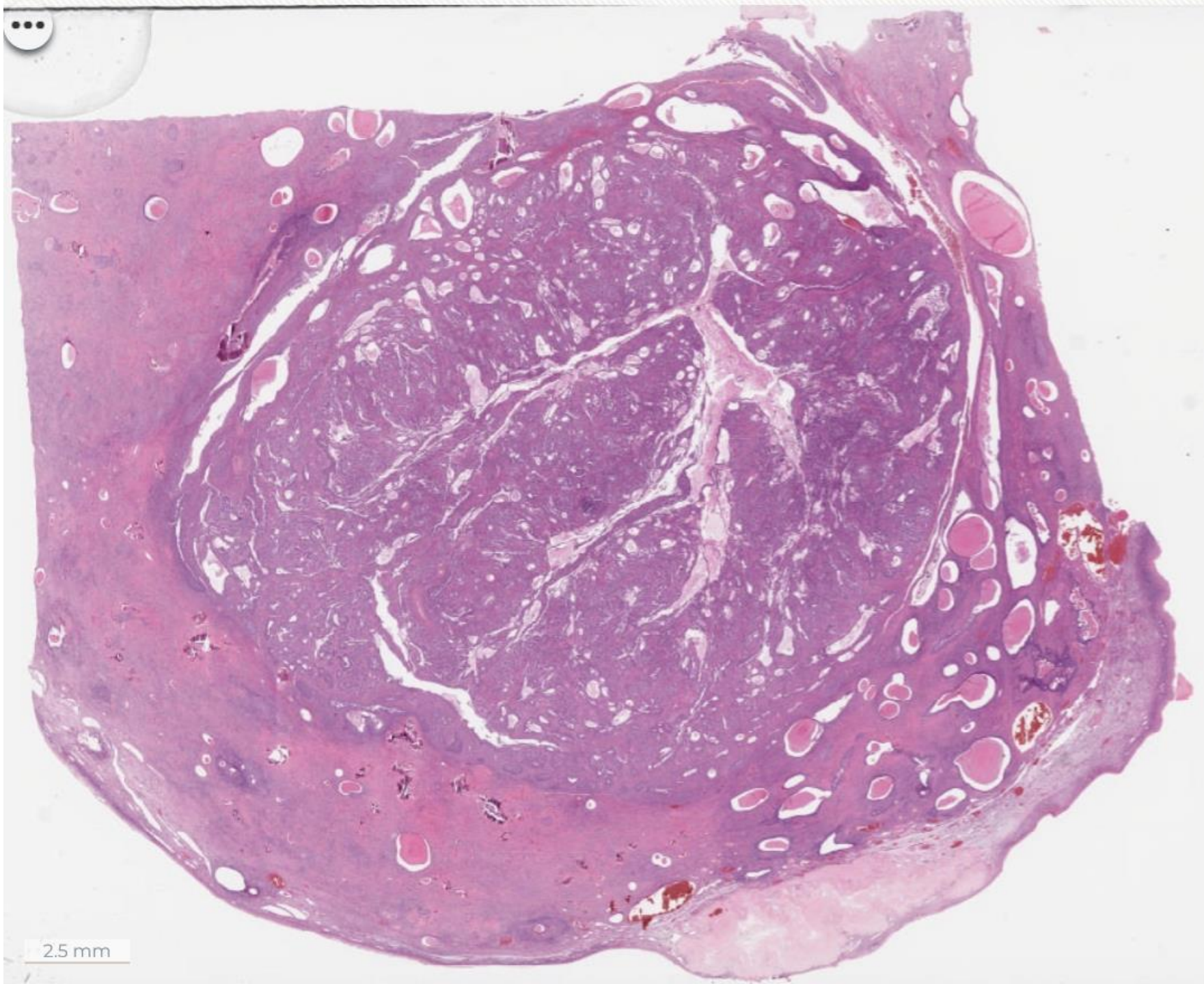
2.5 mm

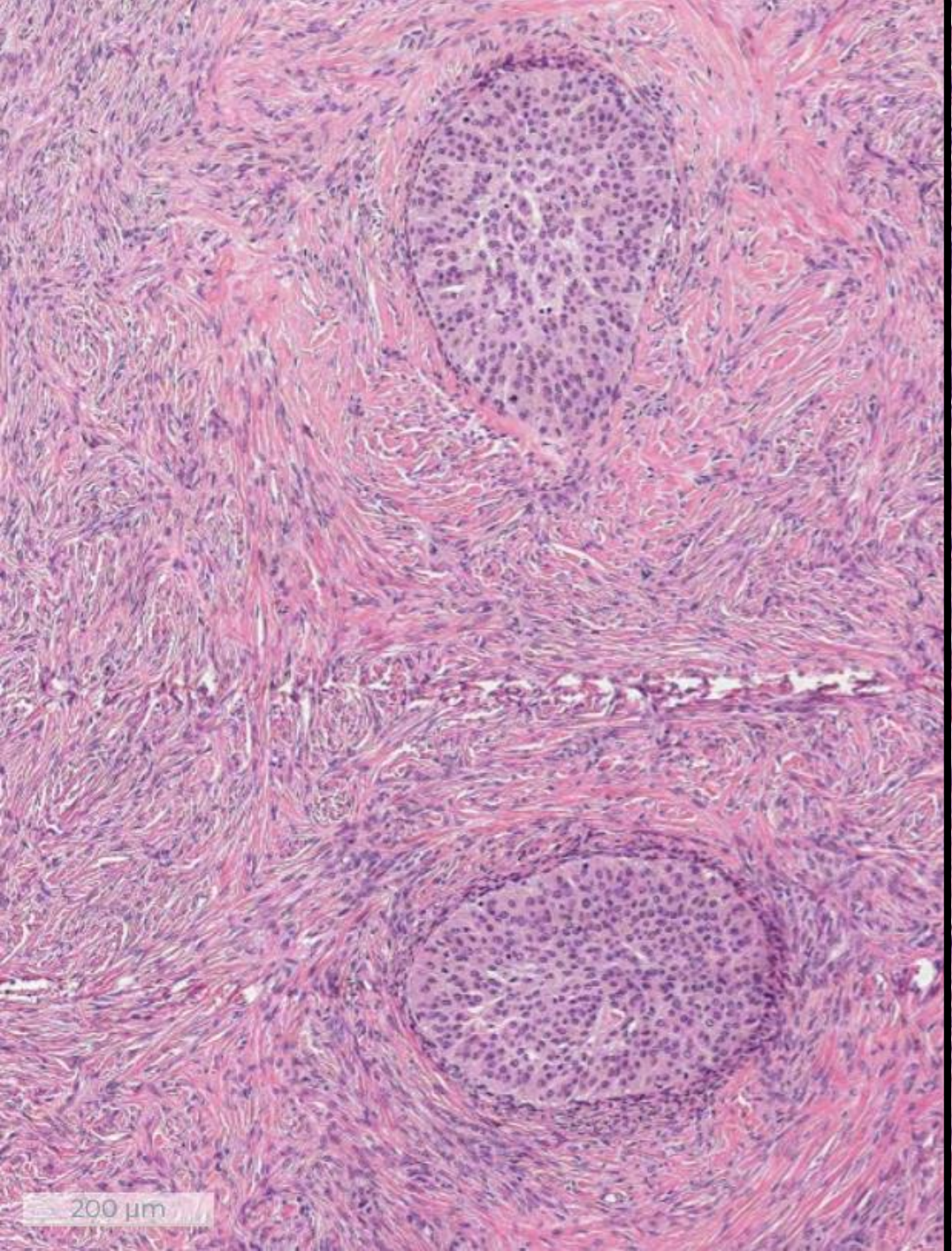
200 µm

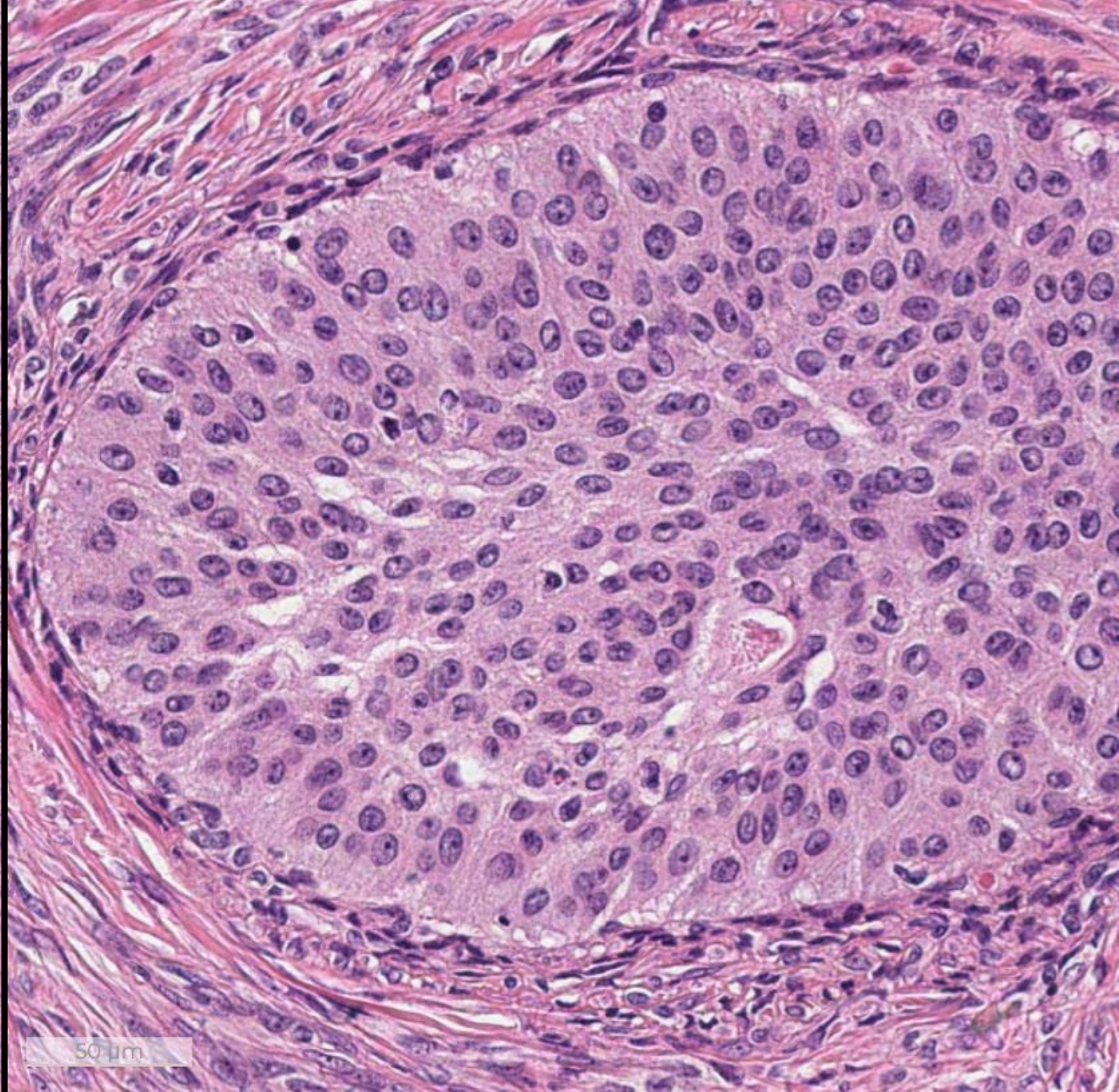
50 µm

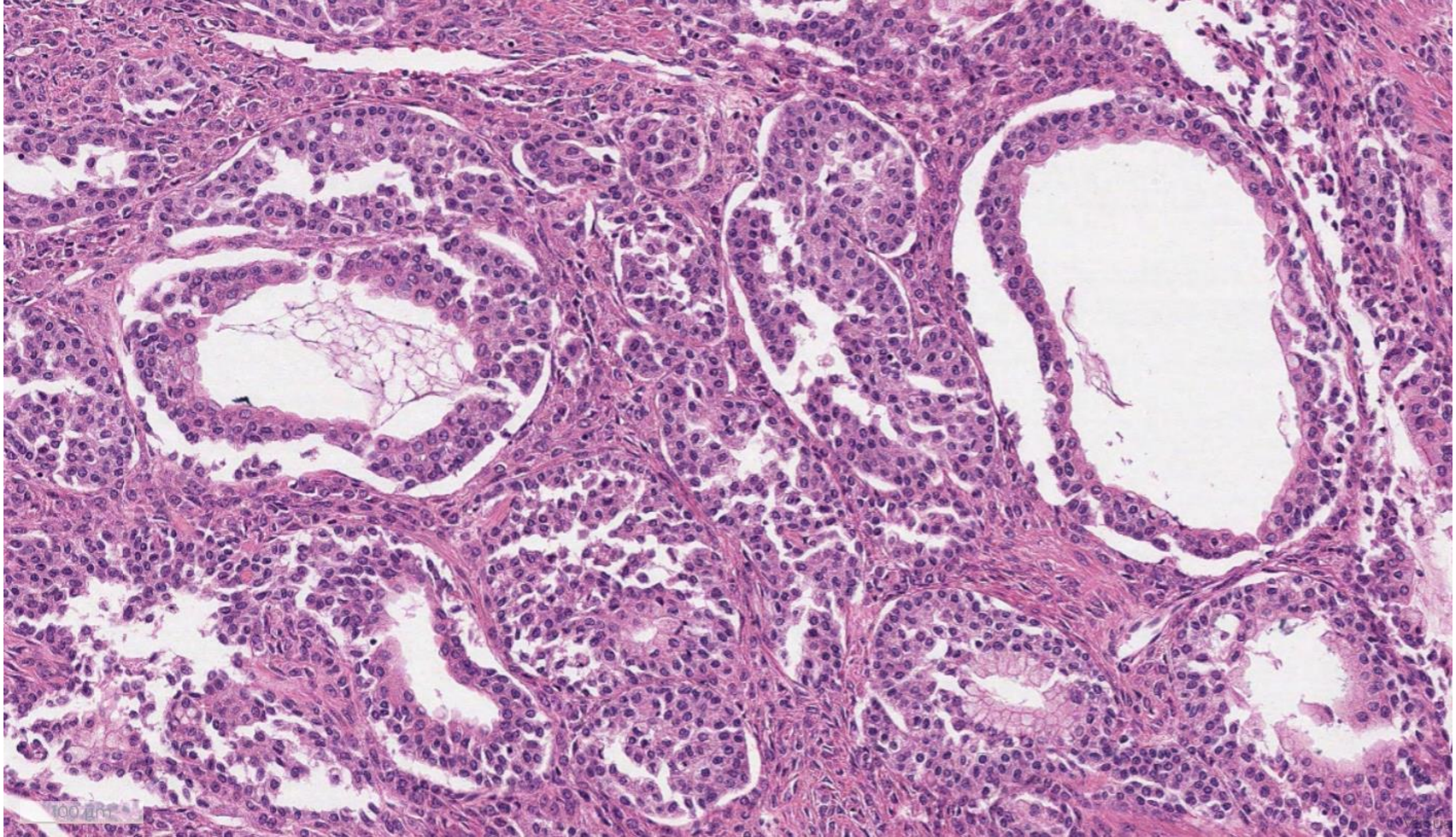
100 µm

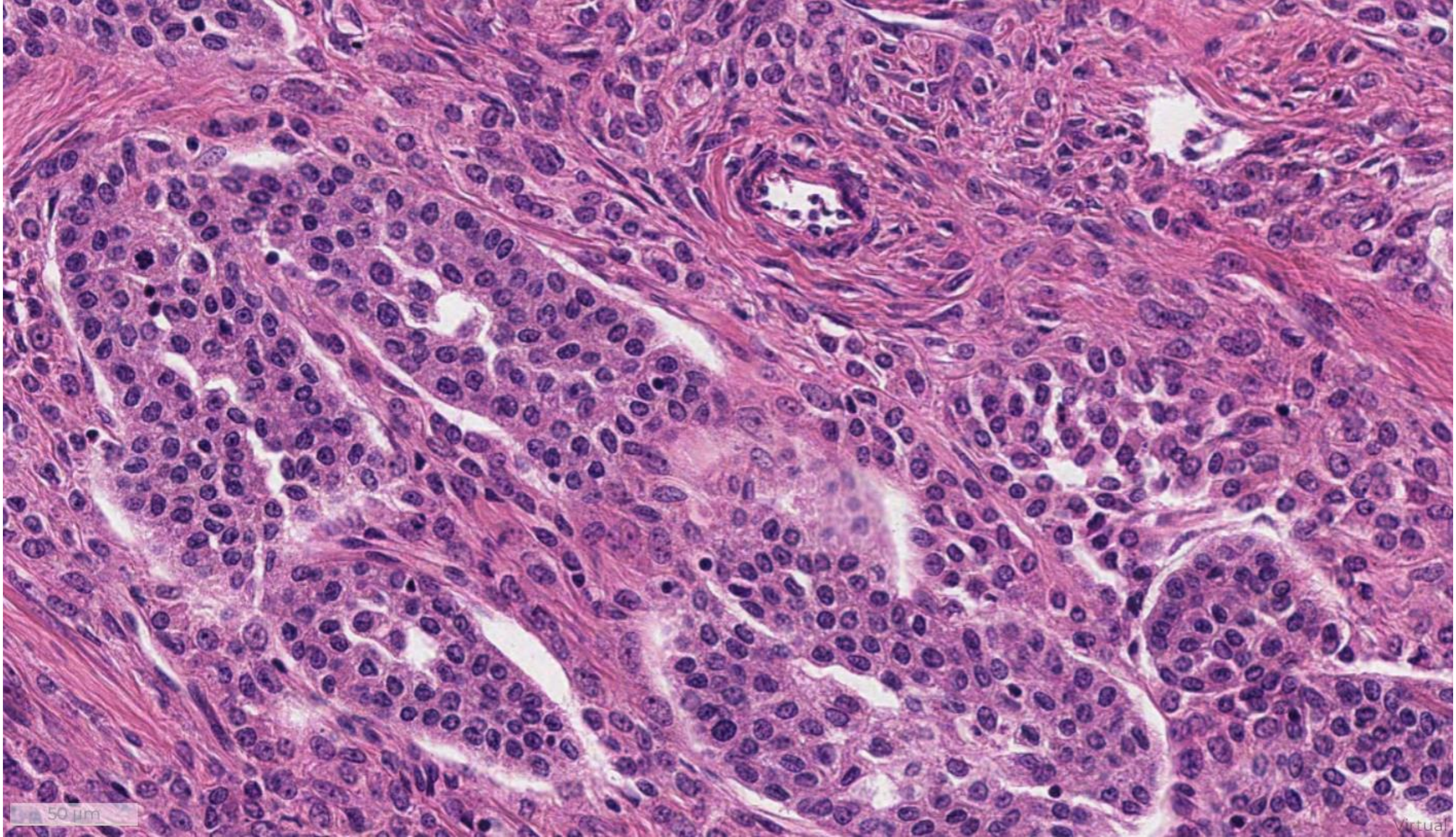
50 µm

Short case 8 : Brenner tumour with malignant transformation

- Rare ovarian carcinoma resembling invasive urothelial carcinoma, associated with benign/borderline Brenner tumour
- Malignant Brenner tumours: <5% of all Brenner tumours
- Brenner tumour peak incidence: 5th decade. Malignant: 7th decade
- May have oestrogenic, or less often, androgenic manifestations
- Disease-specific mutations not known. PIK3CA mutations, MDM2 amplifications reported
- Poor prognosis, unless confined to one ovary. Overall 5y survival: 35%

Short case 8 : Brenner tumour with malignant transformation

- Macro: median 10 cm. Solid or cystic with mural nodules.
- H&E: irregularly shaped masses of cytologically atypical transitional-type cells, sometimes with focal squamous/mucinous differentiation
- Hyperchromatic, pleomorphic nuclei, variably prominent nucleoli, dense eosinophilic cytoplasm, prominent mitotic activity.
- Invasion may be difficult to detect due to dense fibromatous background. Desmoplastic reaction helpful
- IHC: p63, GATA3 positive. Focal p16. Weak ER, PR. WT1 negative. P53 wildtype.

Short case 8 : Brenner tumour with malignant transformation

Mark	Features
1.5 or 1	Fails to diagnose
2	Does not commit to a diagnosis, inadequate morphological description
2.5	Adequate description with confident diagnosis but no additional information
3	Some additional information, as mentioned below:
3.5	Good description, hormonal manifestations, expected findings (e.g. often see benign Brenner component), IHC, poor prognosis

Short case 9

- Female 14 years
- Nodular lesions over vulva, biopsy from vulva.

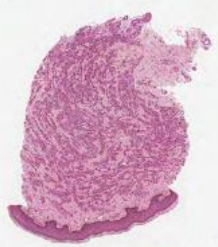

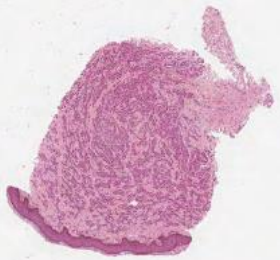

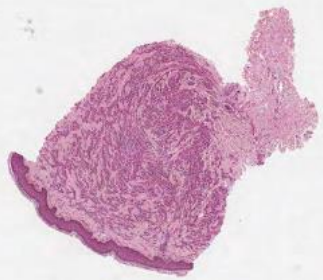

2 mm

Virtual Pathology Image Viewer 0.3.05 © 2024 University of Leeds

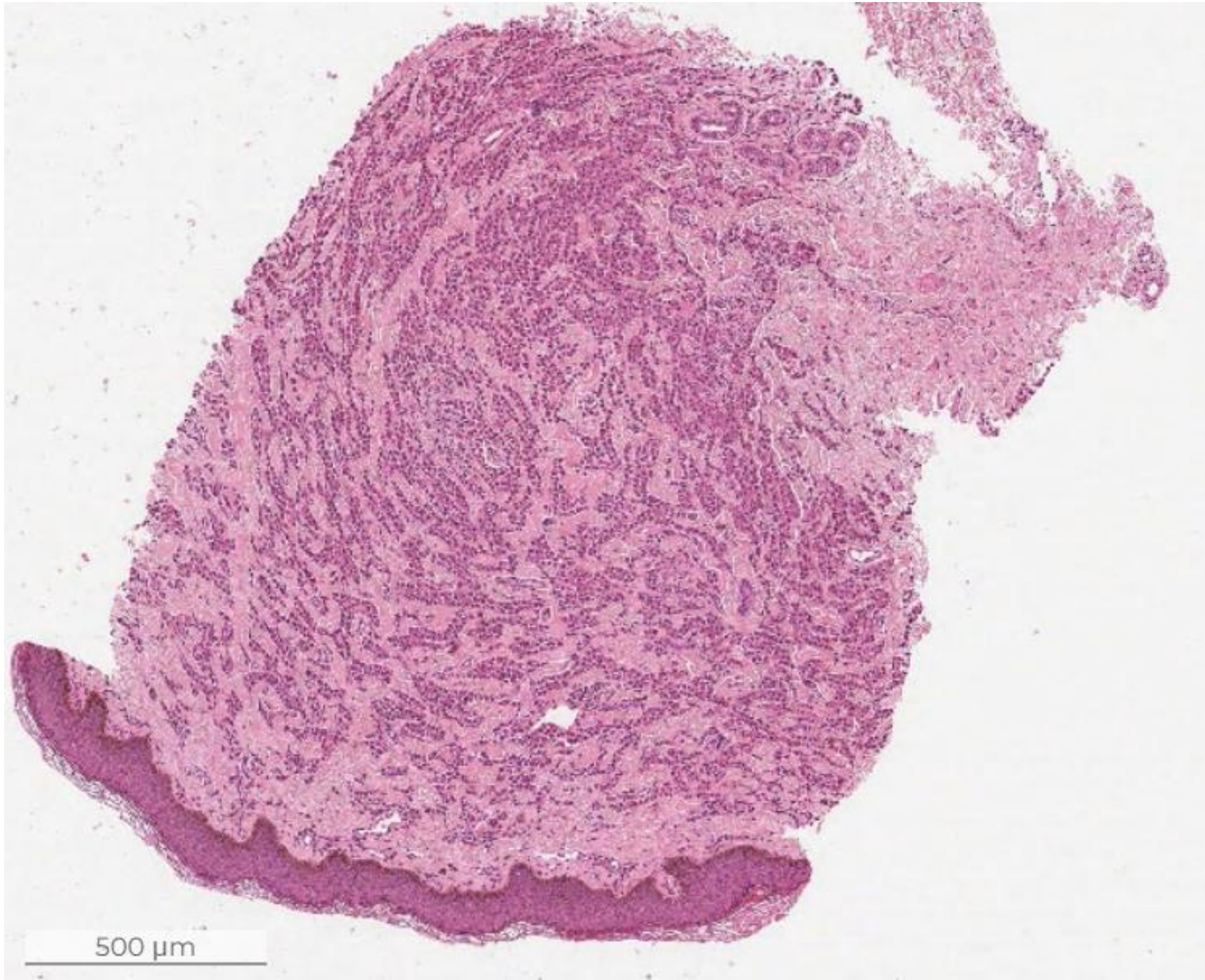
500 µm

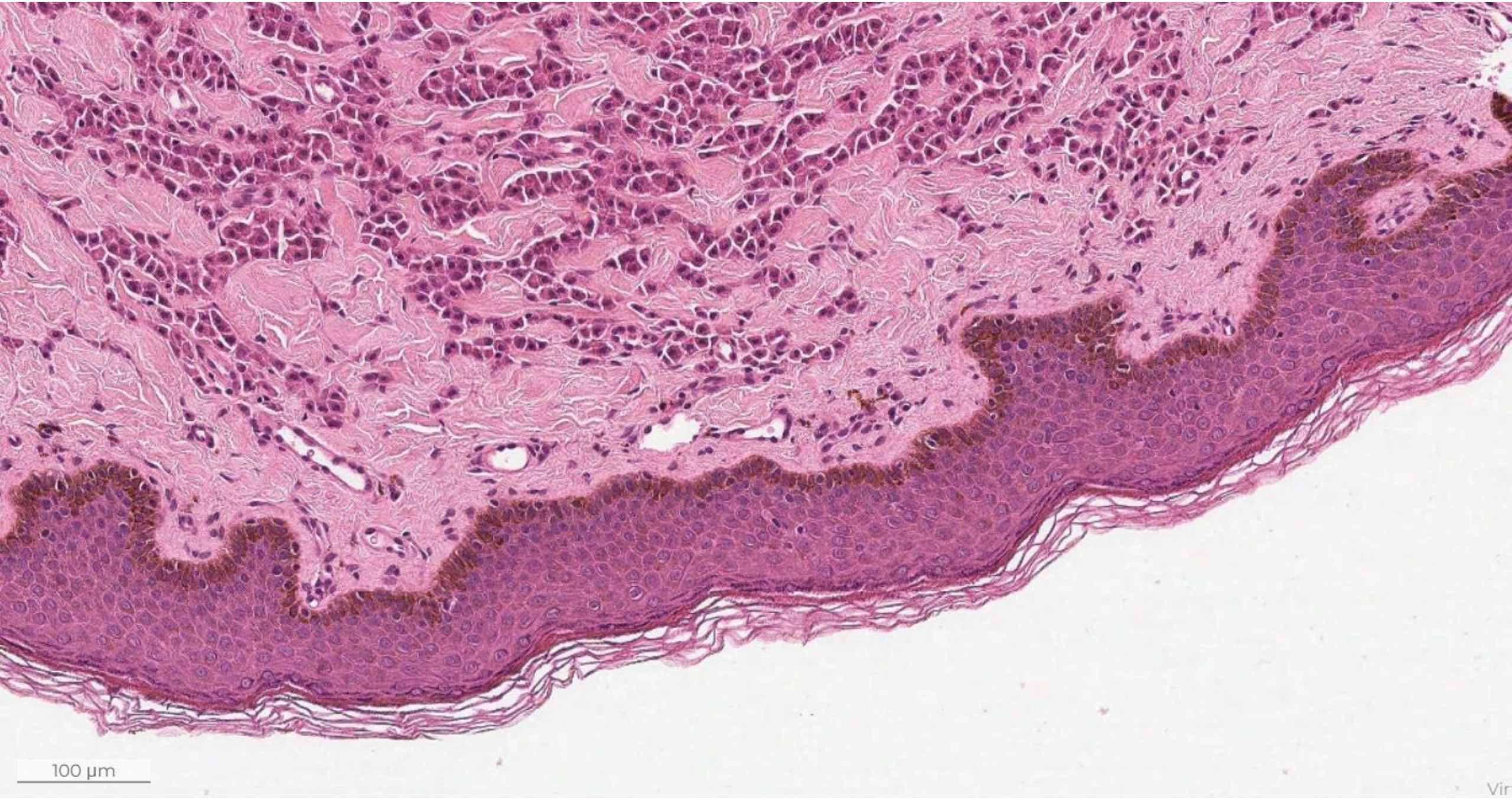
100 µm

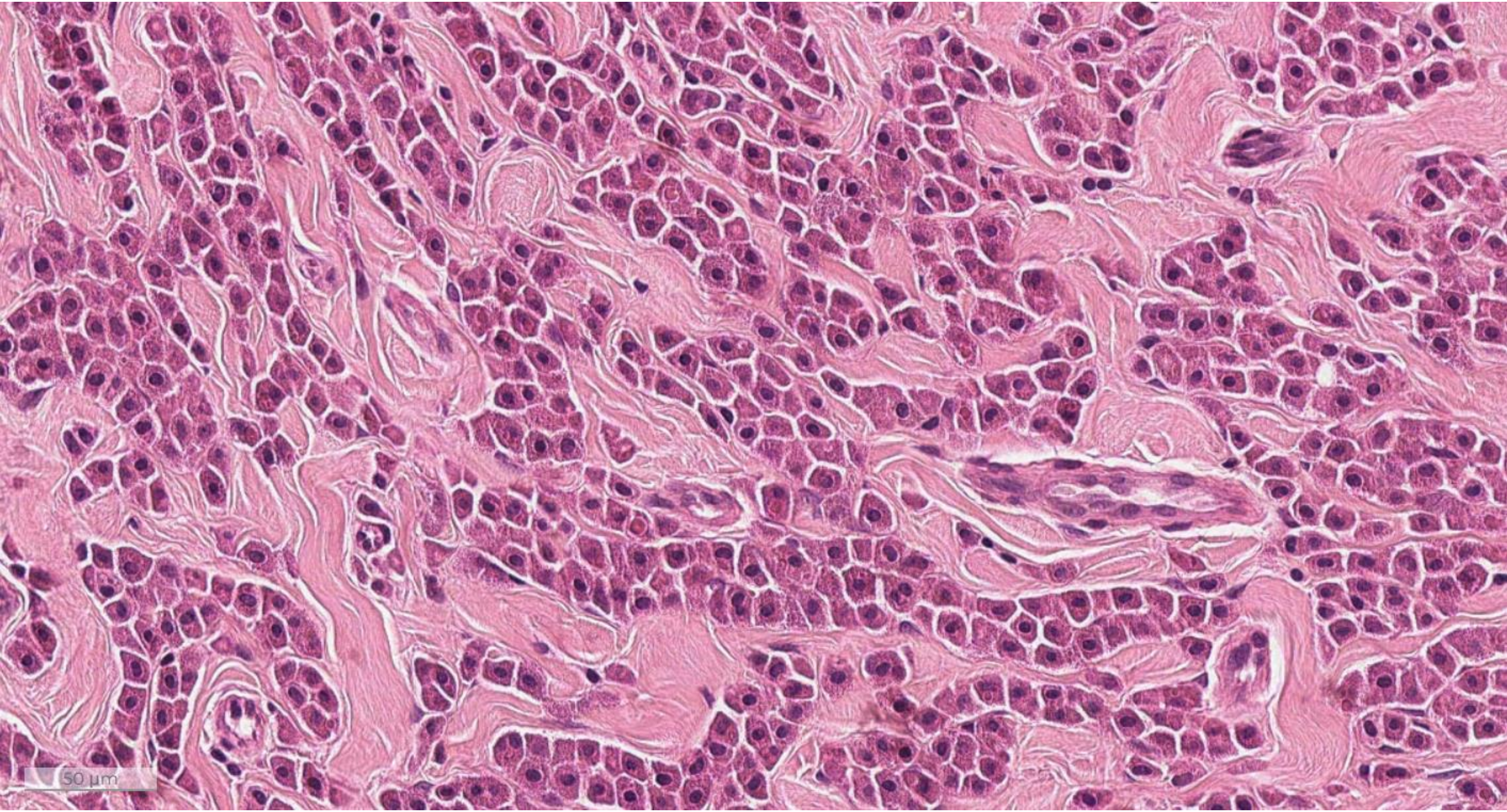
50 µm

Short case 9 : Vulvar mastocytosis

- Cutaneous mastocytosis: mast cell proliferation, common in paediatric age group
- May present with systemic complaints: e.g. flushing, dizziness, palpitations, diarrhoea, fever, weight loss
- Lesions can be localised or systemic. In most children, systemic involvement is absent
- Good prognosis with spontaneous involution common
- DDx: Langerhans cell histiocytosis (eosinophils. CD1a, S100 positive)

Short case 9 : Vulval mastocytosis

- Macro: small red/brown/pink/yellow nodules or plaques
- H&E: Submucosal infiltrate of mast cells with round/oval/spindled cells and variable cytoplasmic granularity. Distinct cytoplasmic boundaries. Eosinophils may be seen
- IHC: CD117, mast cell tryptase positive. Toluidine blue and Giemsa demonstrate metachromasia (granules are purple red)

Short case 9 : Vulval mastocytosis

Mark	Features
1.5 or 1	Fails to diagnose
2	Does not commit to a diagnosis, inadequate morphological description
2.5	Adequate description with confident diagnosis but no additional information
3	Some additional information, as mentioned below:
3.5	Good description, expected findings, IHC, special stains, suggest assess for systemic involvement, good prognosis in children

Short case 10

- Female 52 years
- Bleeding PV, endometrial curetting.

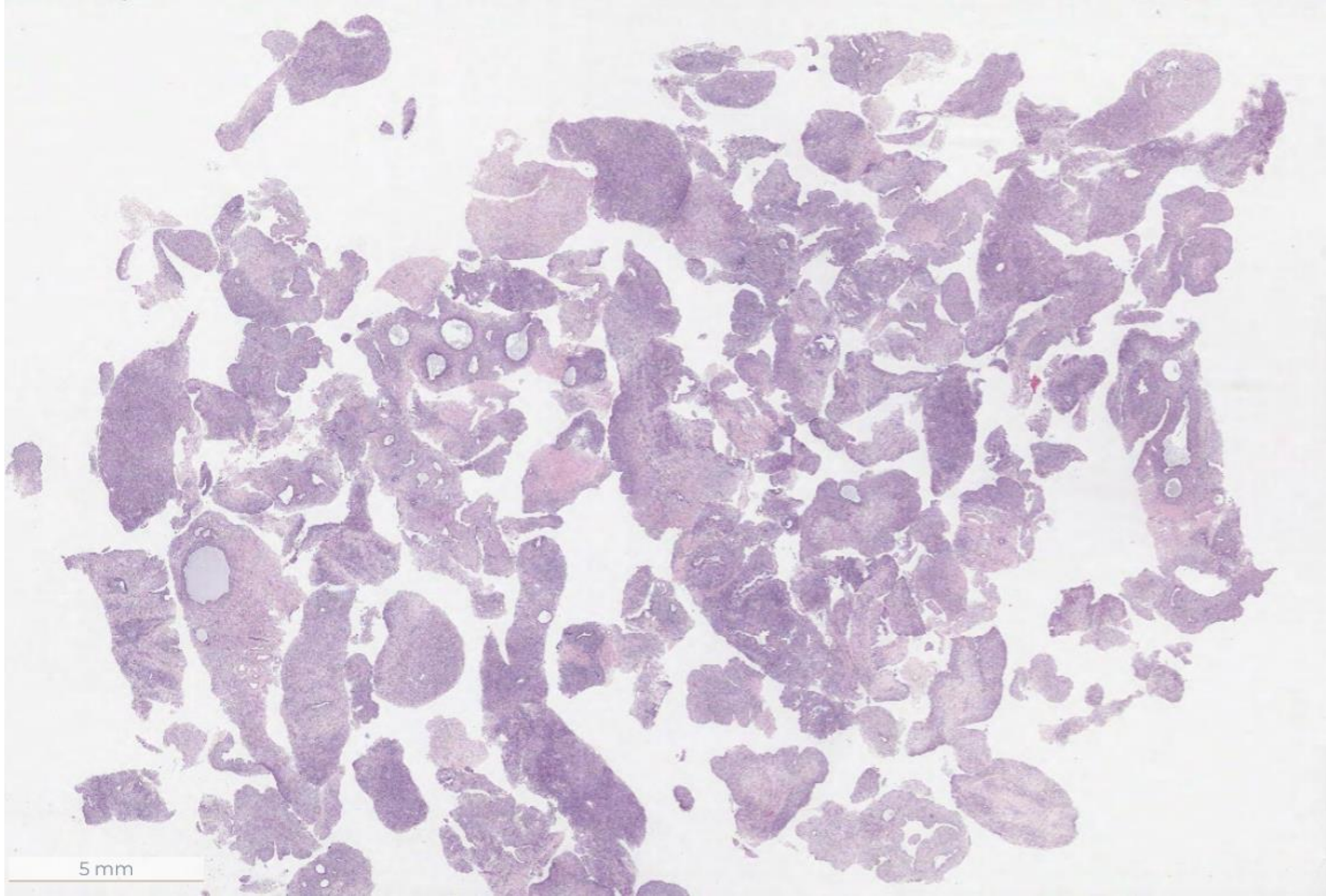
5 mm

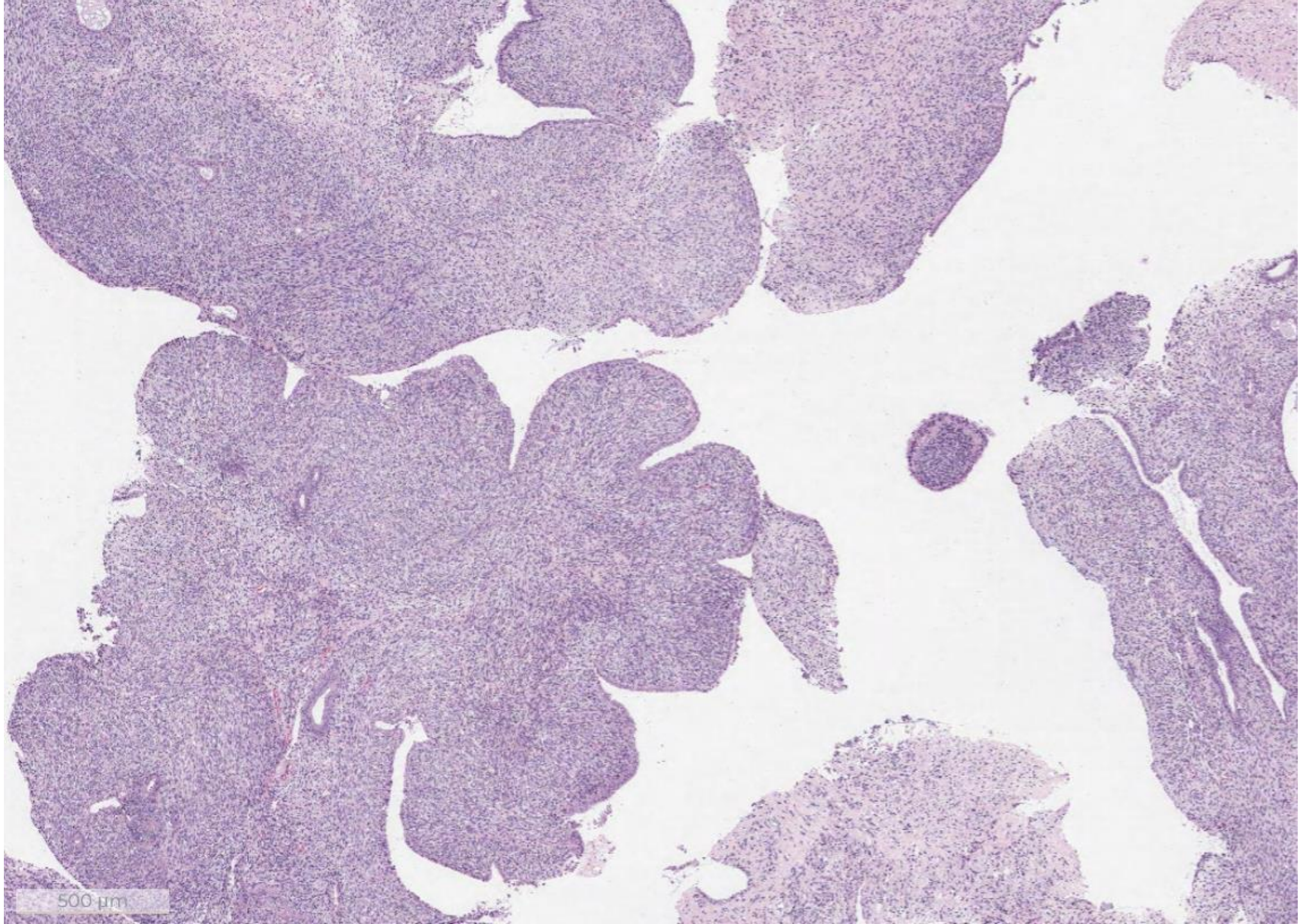
500 µm

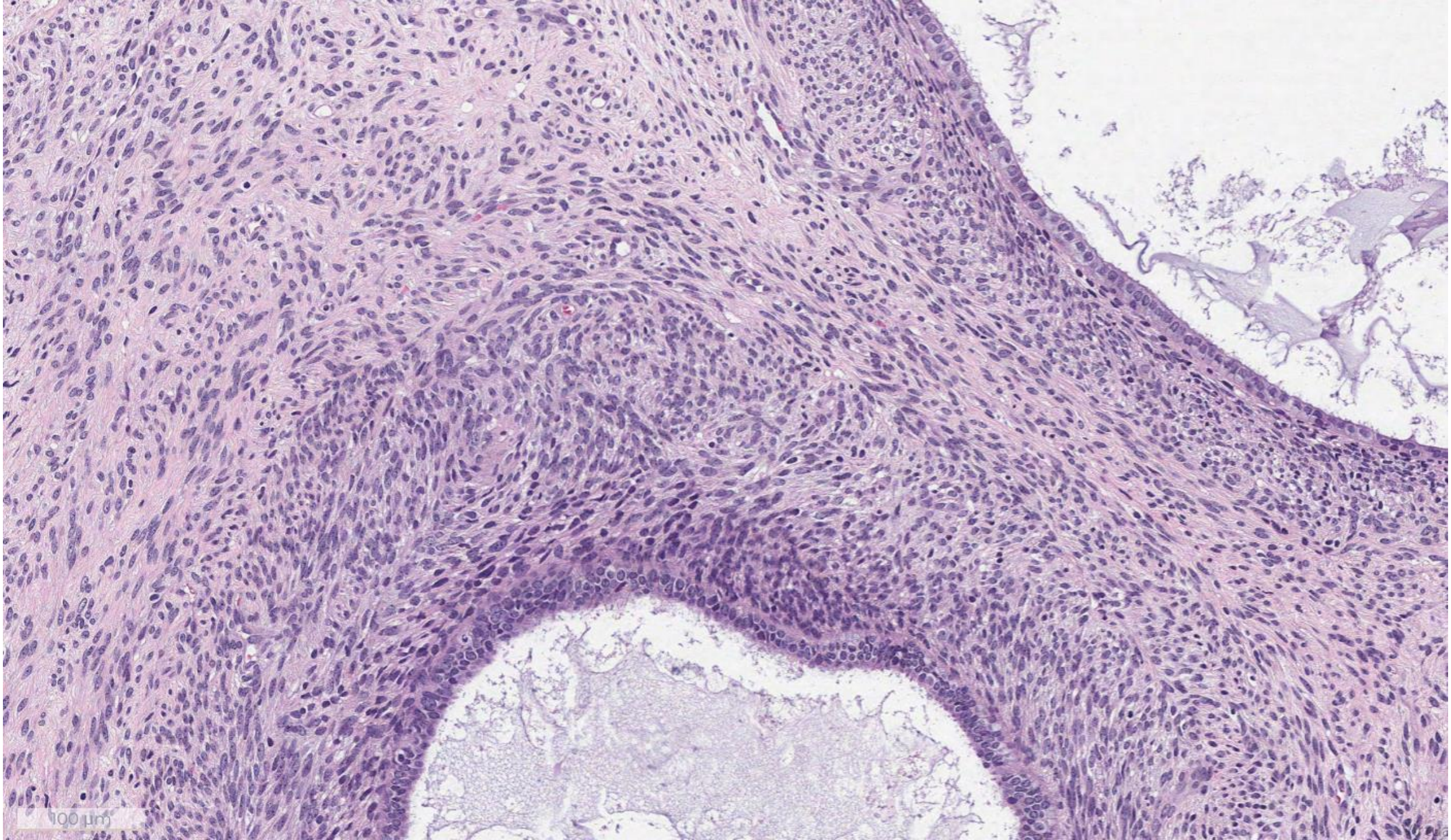
100 µm

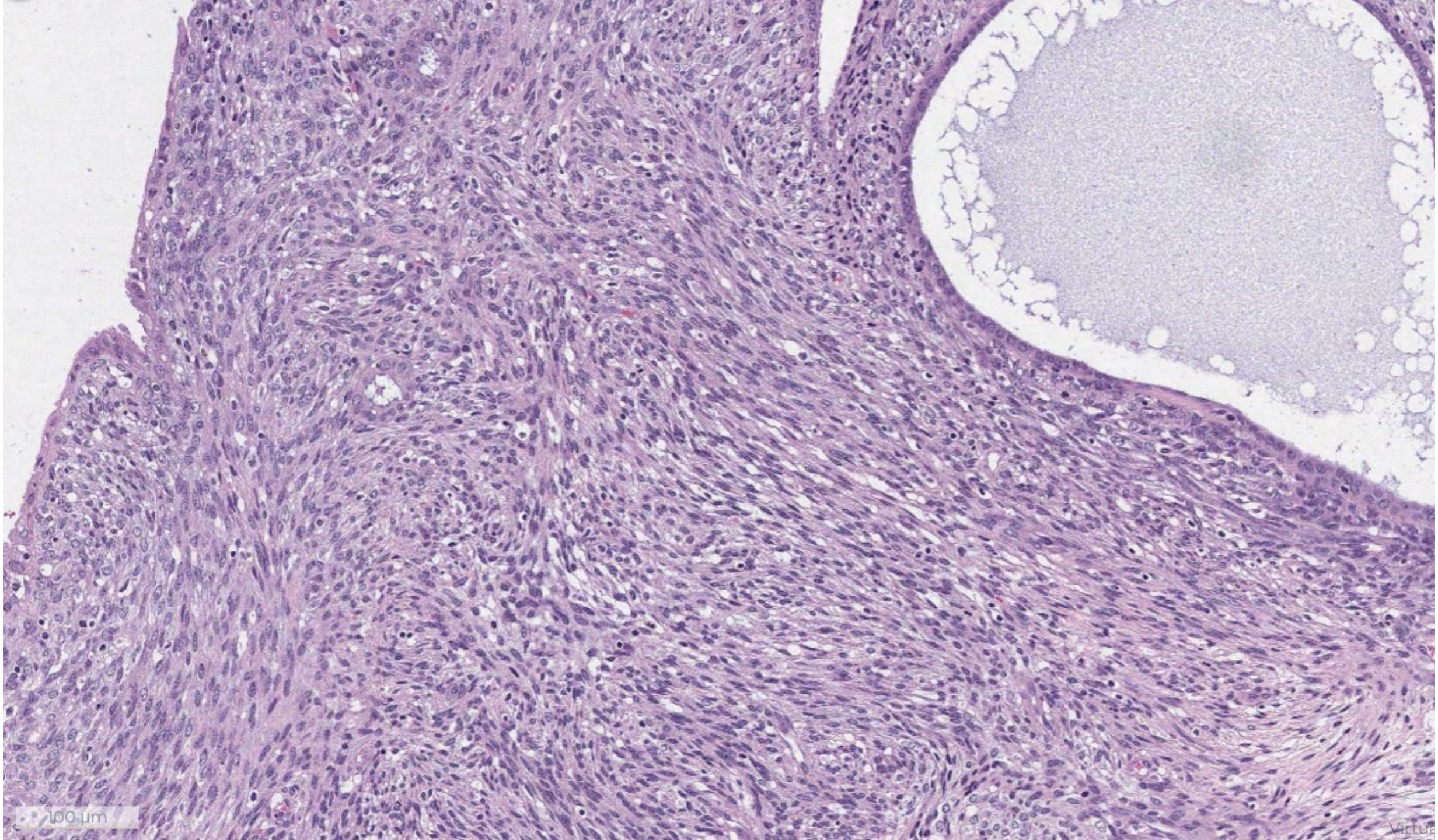
100 µm

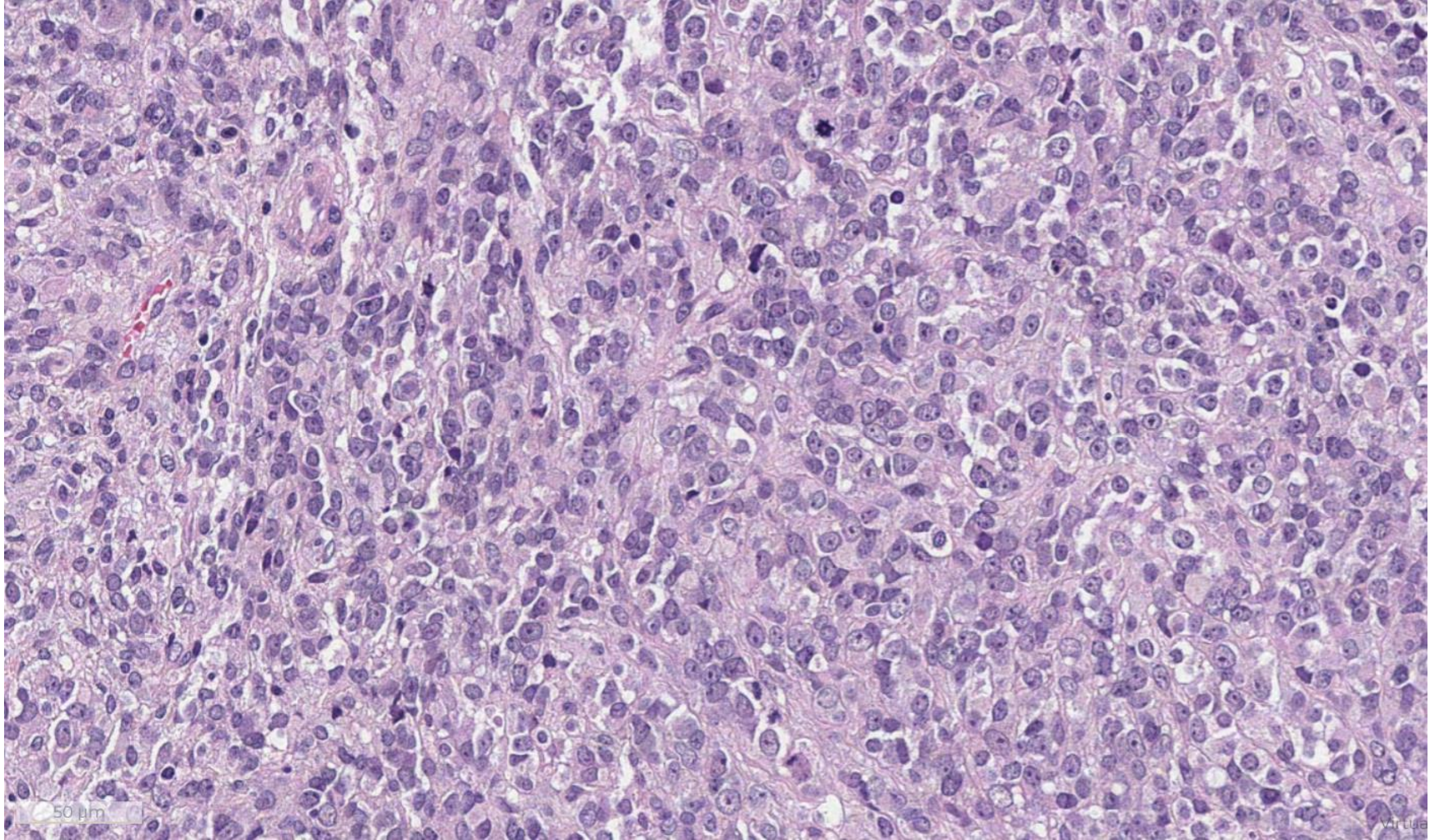
50 µm

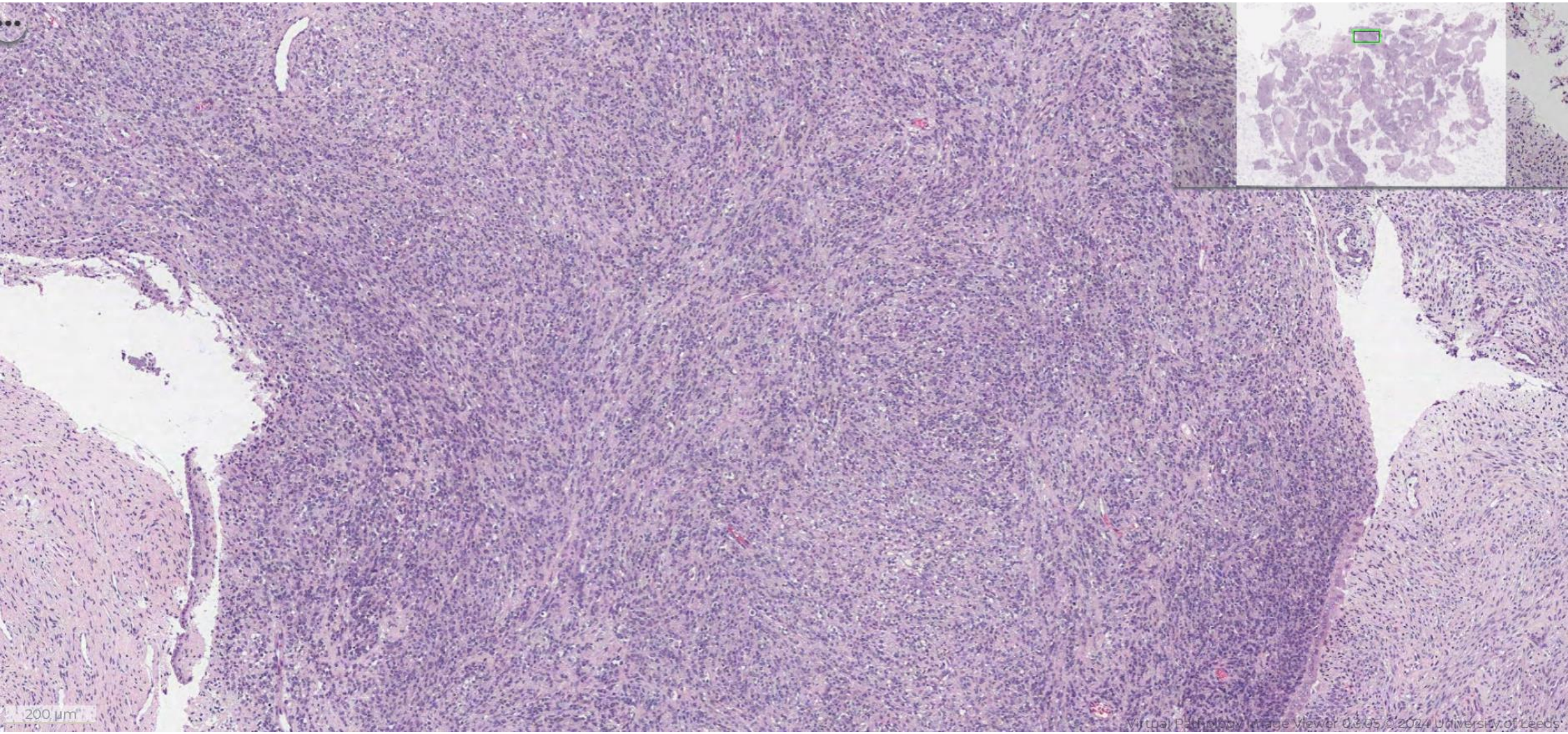
200 µm
Virtual Pathology Image Viewer 0.3.05 © 2024 University of Leeds

Short case 10 : Adenosarcoma with sarcomatous (high grade) overgrowth

- Biphasic neoplasm: benign epithelial component, malignant stromal component
- Wide age range, most often post-menopausal
- Usually within uterus, can occur in cervix, vagina, or be extrauterine
- No specific genomic aberrations
- Staging differs from that of other uterine sarcomas (pT1 depends on myometrial invasion, not tumour size)
- Prognosis generally favourable compared with other gynae sarcomas. Adverse prognostic variables: sarcomatous overgrowth, high grade atypia, deep myometrial invasion, and extrauterine recurrence

Short case 10 : Adenosarcoma with sarcomatous (high grade) overgrowth

- Macro: solitary, exophytic, polypoid mass filling endometrial cavity
- H&E:
  - Phyllodiform architecture, bland endometrial glands, periglandular condensation of neoplastic stroma, cytological atypia, mitoses
  - Haemorrhage and necrosis common
  - Sarcomatous overgrowth and transformation to HG sarcoma may be seen
  - Sarcomatous component: often homologous. Rhabdomyosarcomatous/sex cord differentiation possible
- IHC: CD10, ER, PR positive (often negative in sarcomatous overgrowth)

Short case 10 : Adenosarcoma with sarcomatous (high grade) overgrowth

Mark	Features
1.5 or 1	Fails to diagnose
2	Does not commit to a diagnosis, inadequate morphological description
2.5	Adequate description with confident diagnosis but no additional information
3	Some additional information, as mentioned below:
3.5	Good description, identifies sarcomatous overgrowth, high grade of tumour, looks for heterologous differentiation, highlight awareness that staging differs for these tumours, prognostic variables

The British Association of Gynaecological Pathologists

Mock Exam

Thank you for your attention

Any questions?