The British Association of Gynaecological Pathologists

Lecturer – Dr Mahfooz Basha Mohamed

I am a Consultant Gynaecological Pathologist at University College London Hospitals NHS Foundation Trust, London and a BAGP Councillor



The British Association of Gynaecological Pathologists

Mock Exam

- Dr Mahfooz Basha Mohamed
- University College London Hospitals NHS Foundation Trust, London

- 25 September 2024

Mock exam 2024
Long cases

Case 1

Female 45 years

110mm size ovarian mass, underwent USO

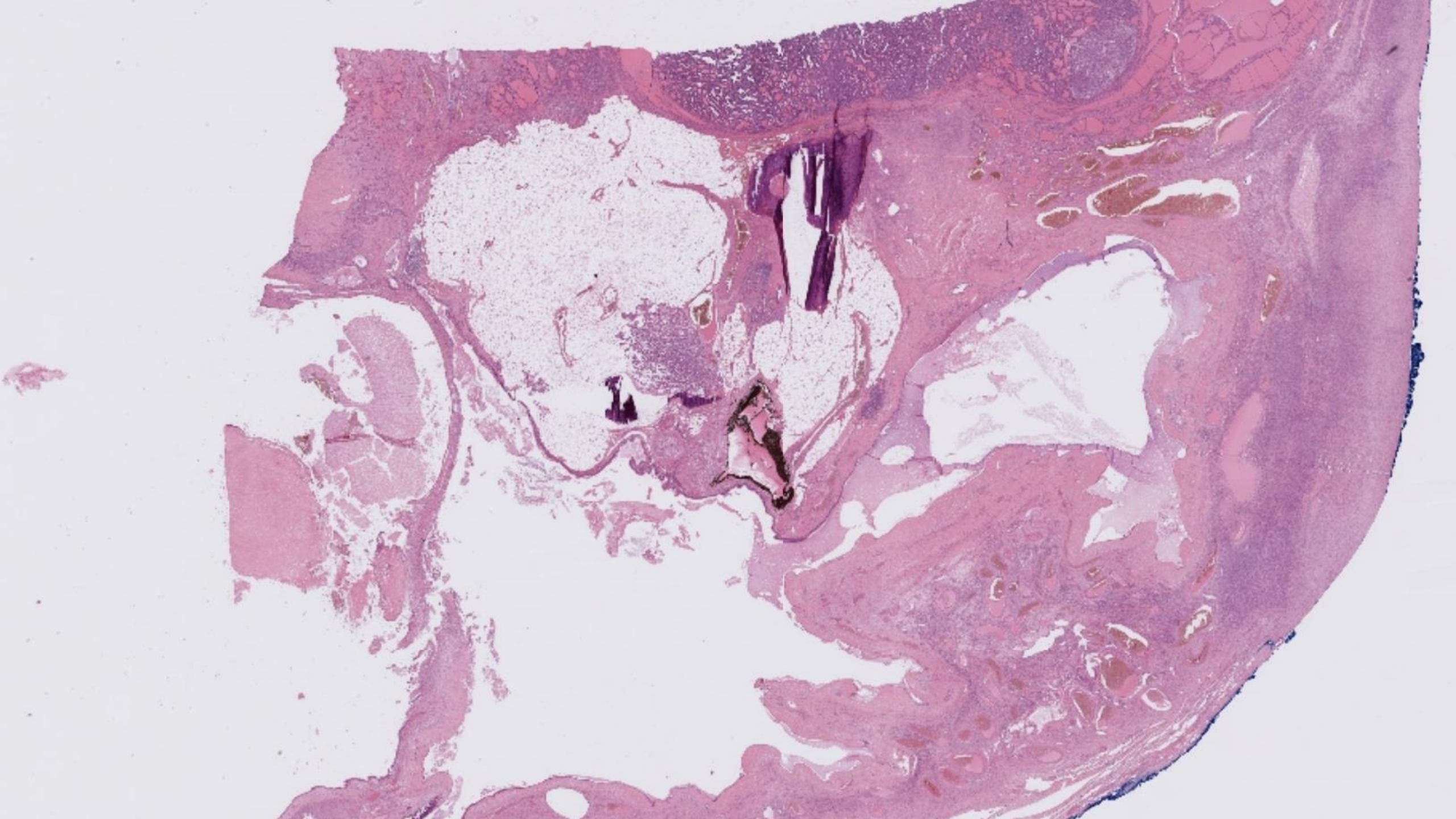

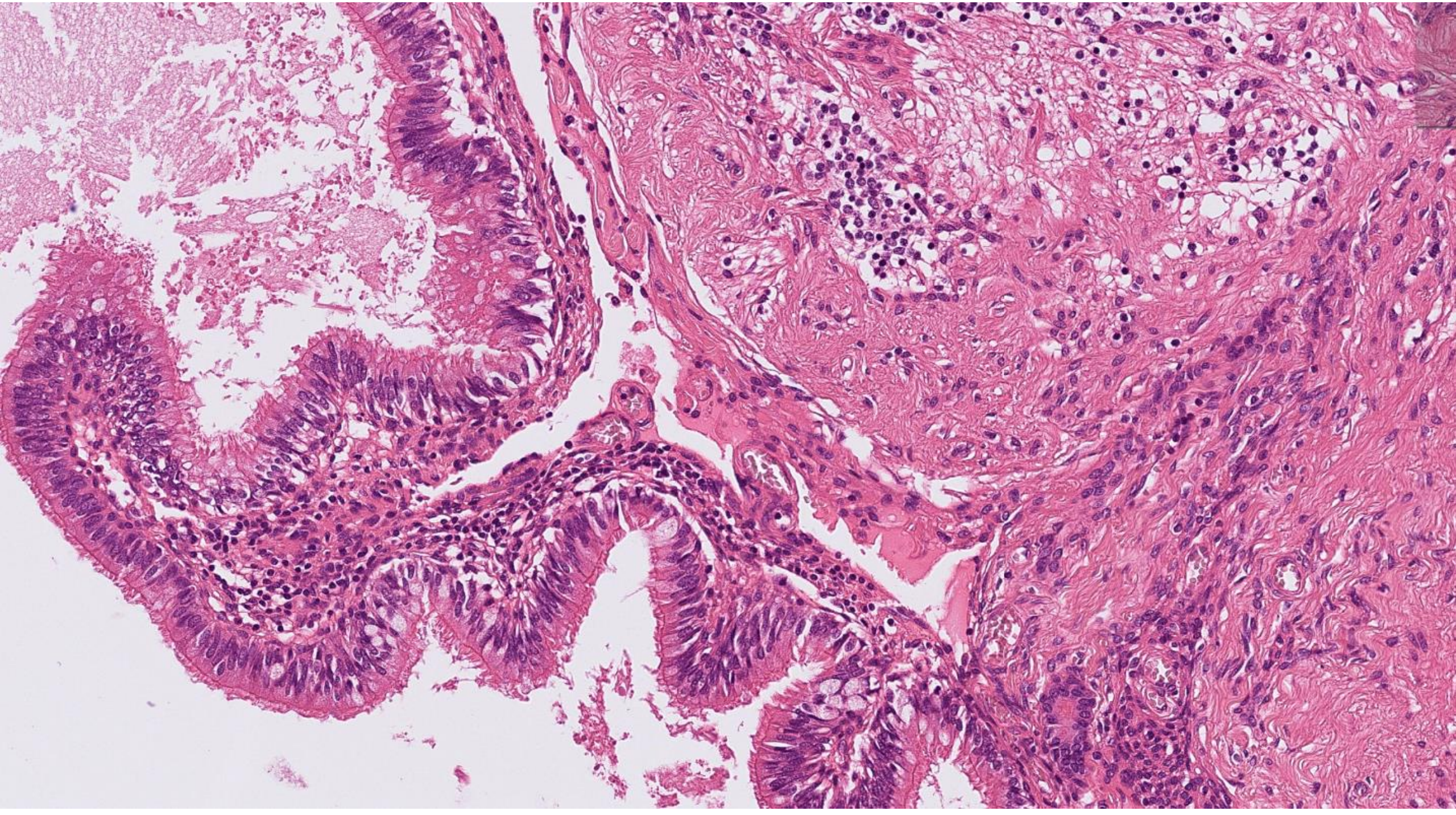

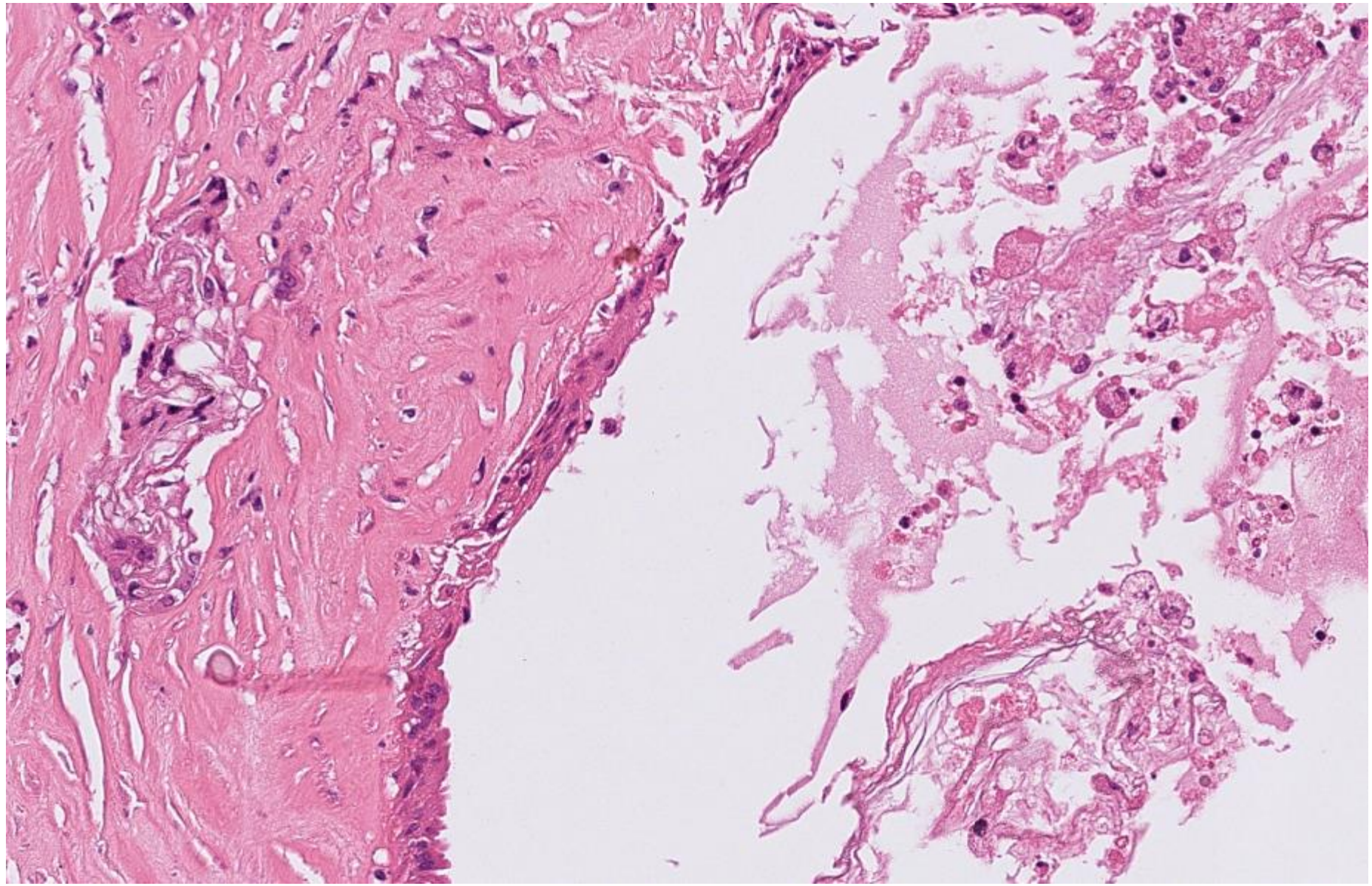

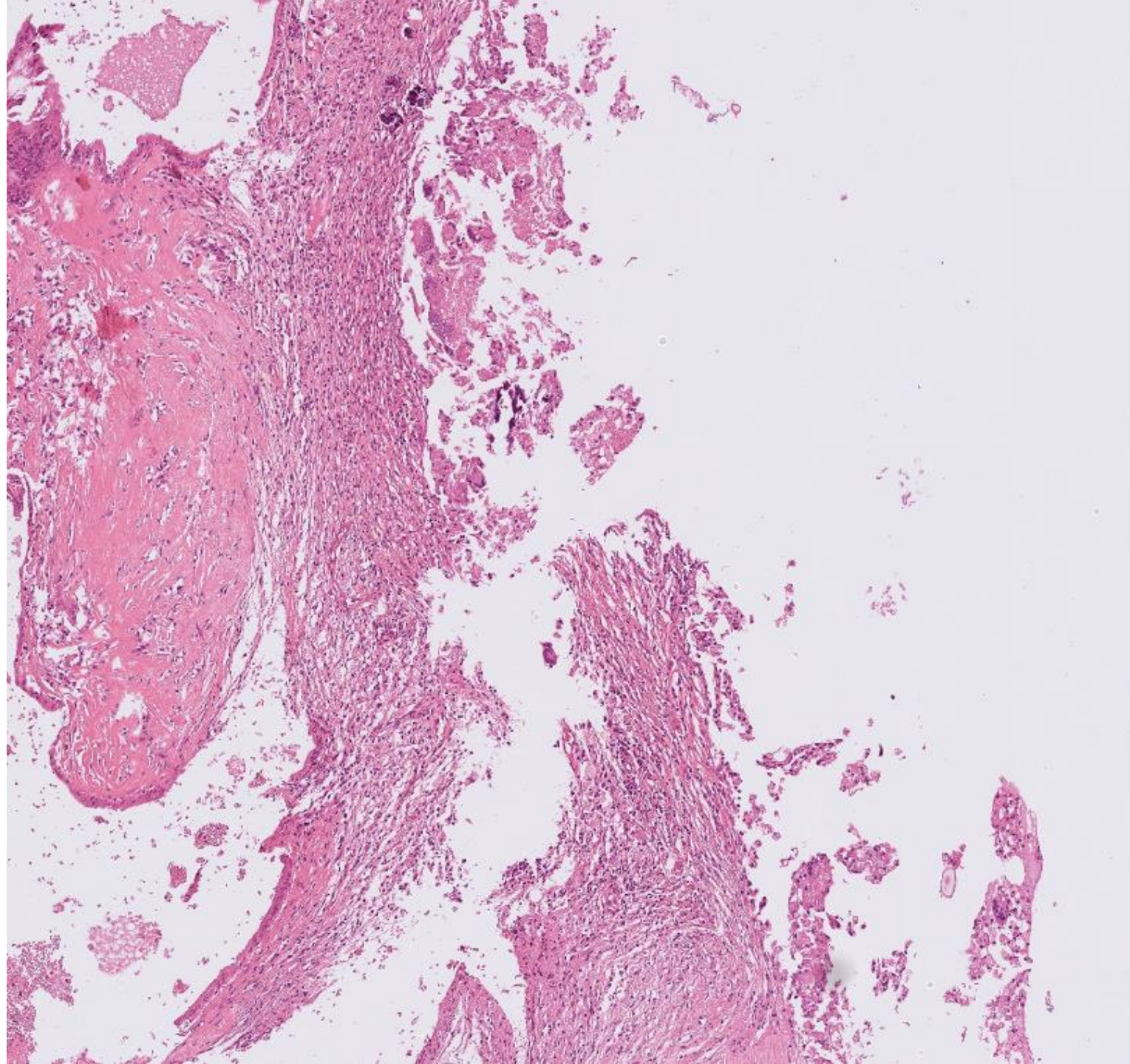

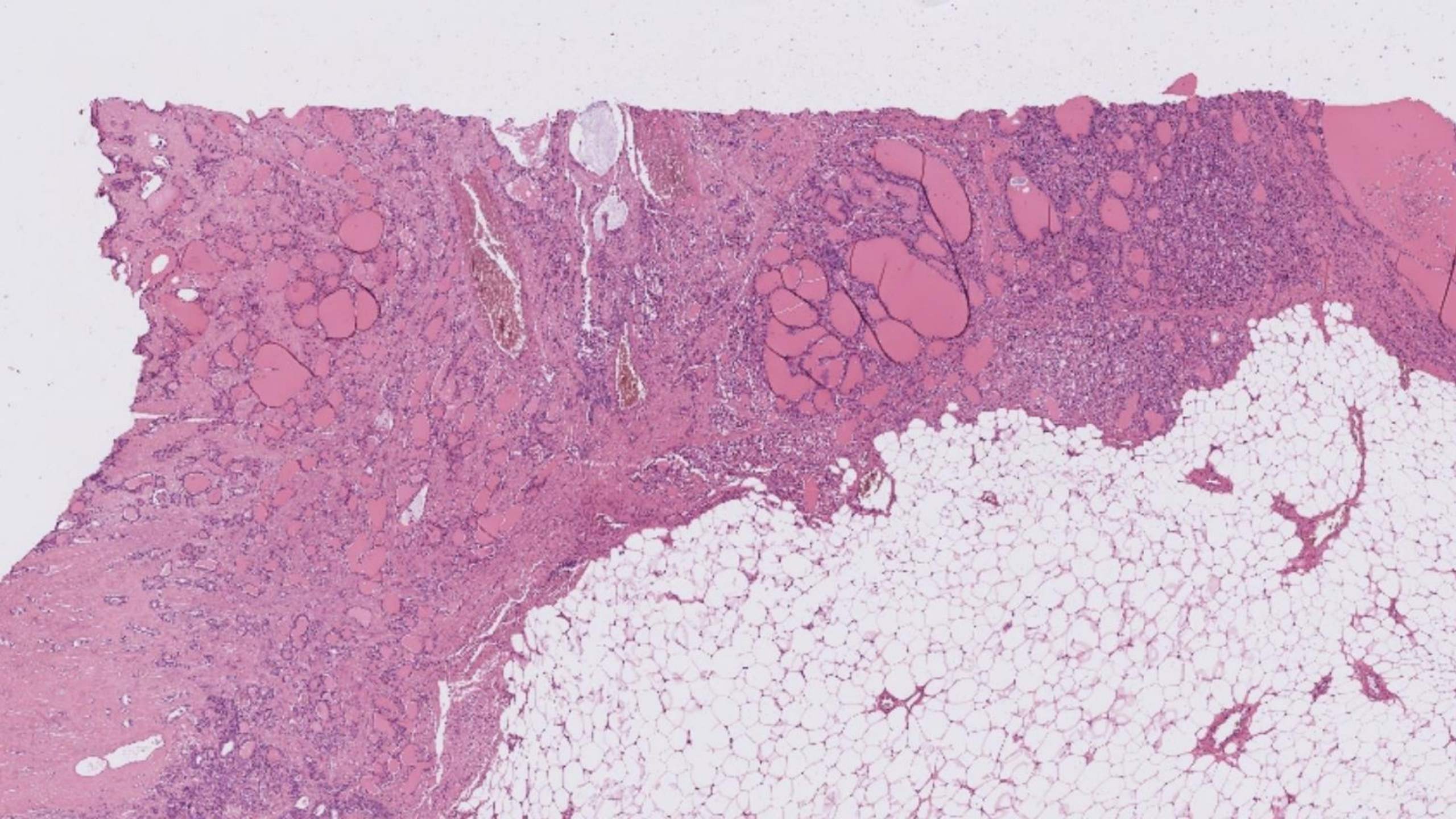

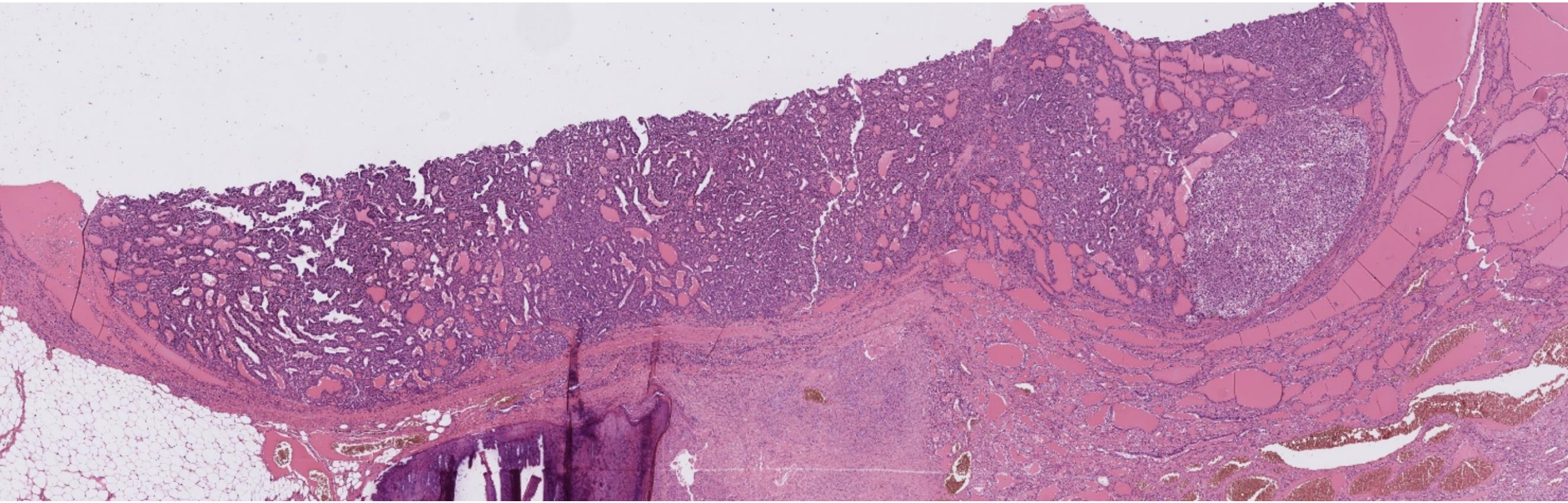

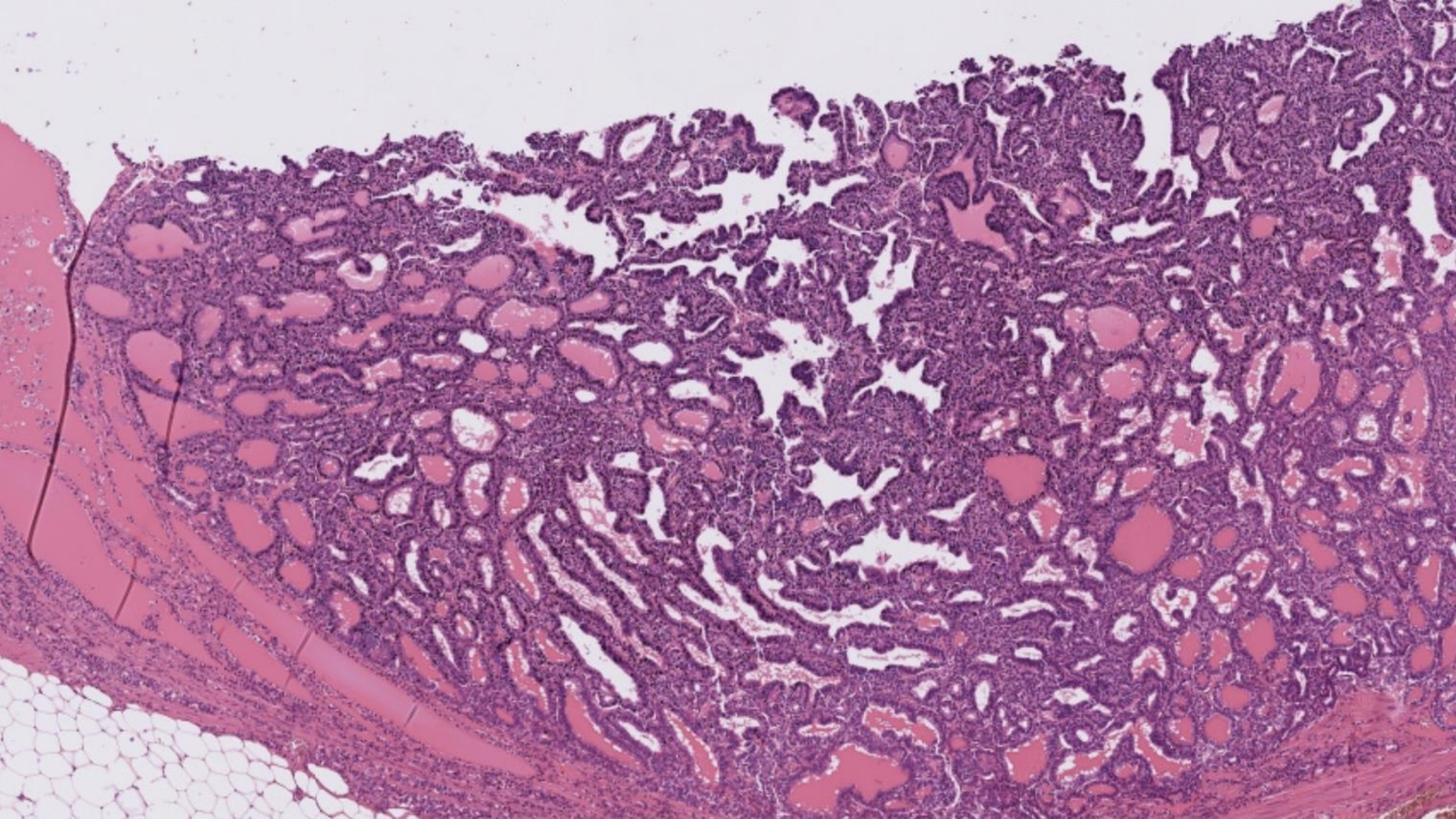

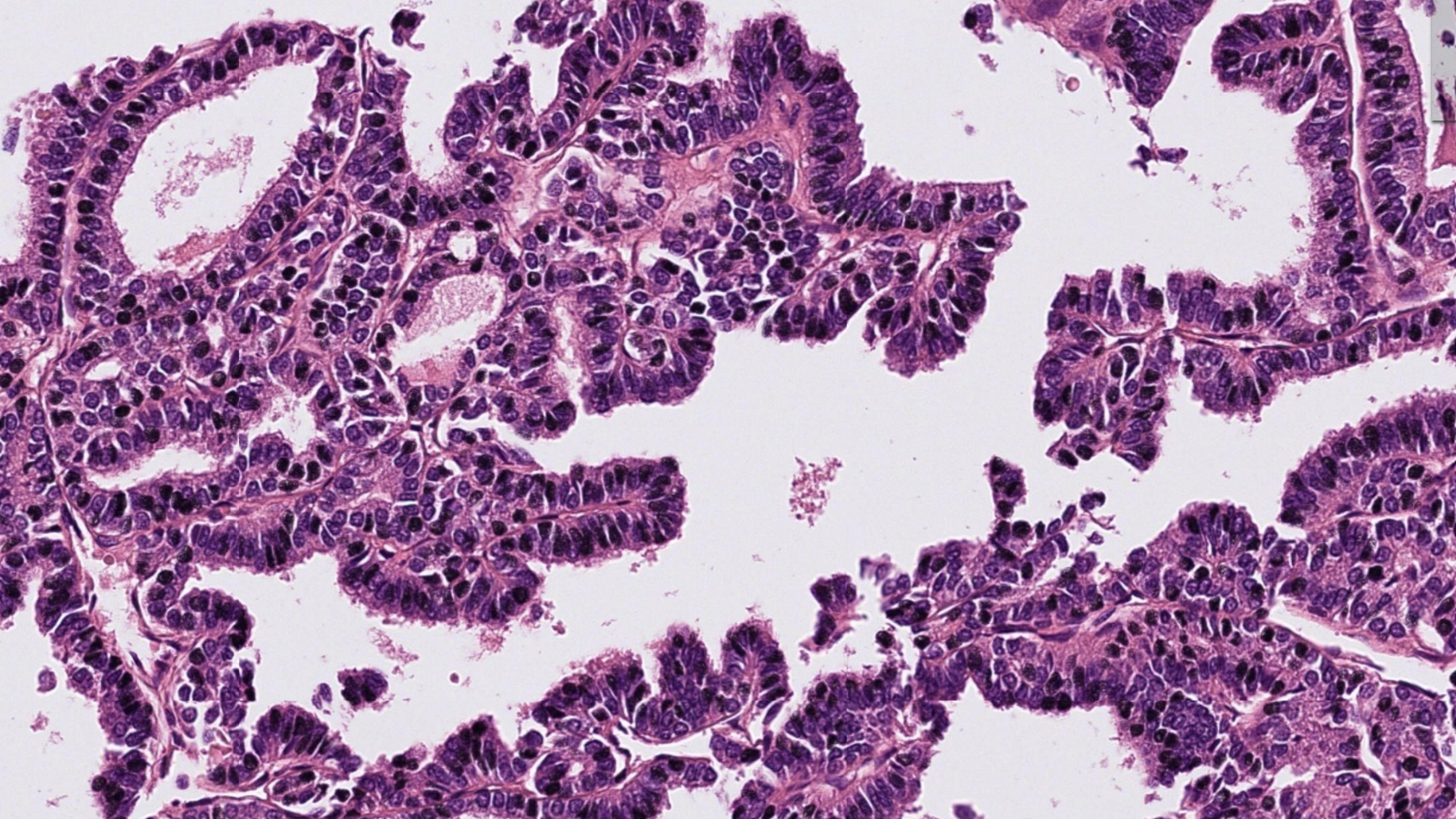

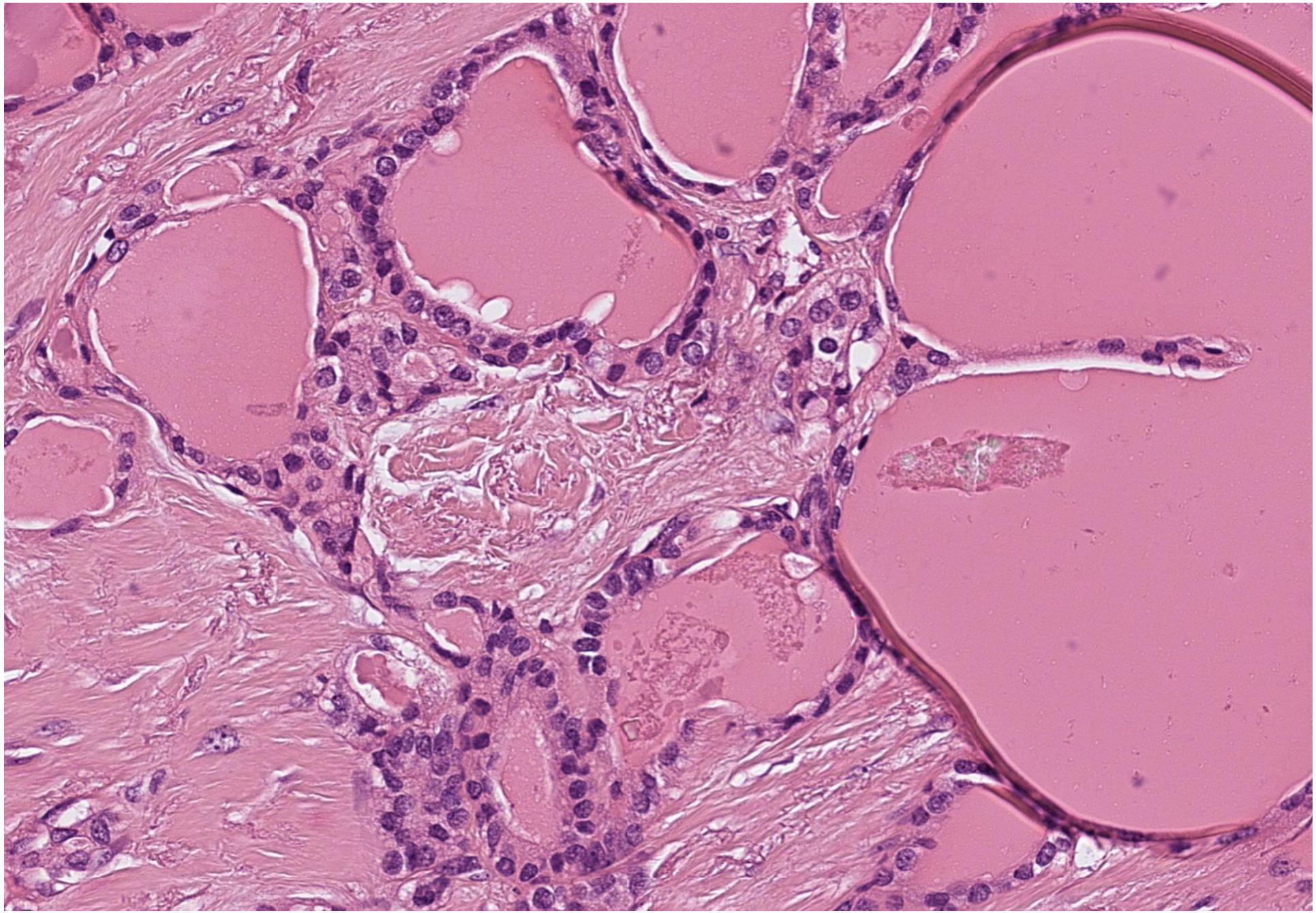

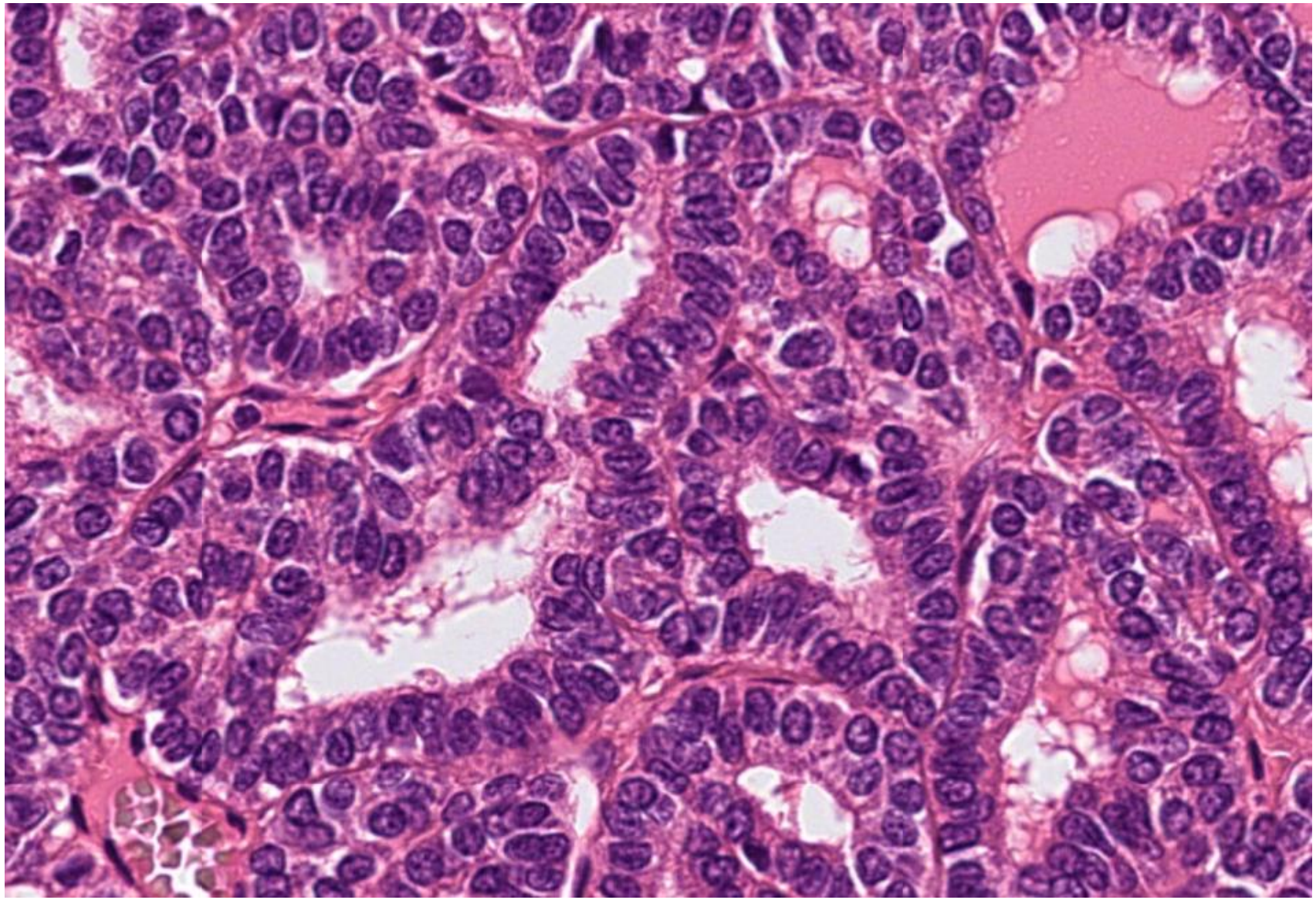

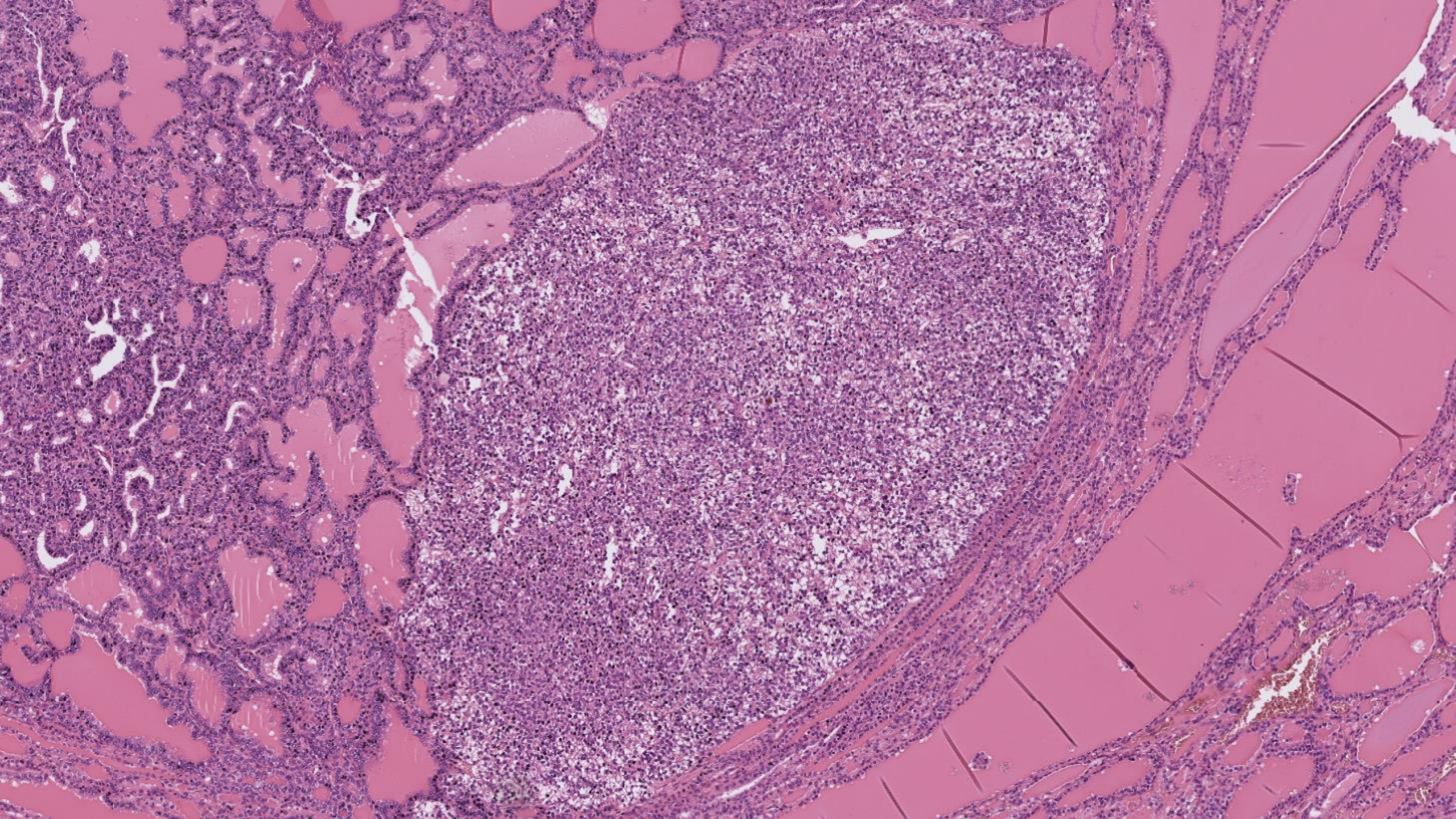

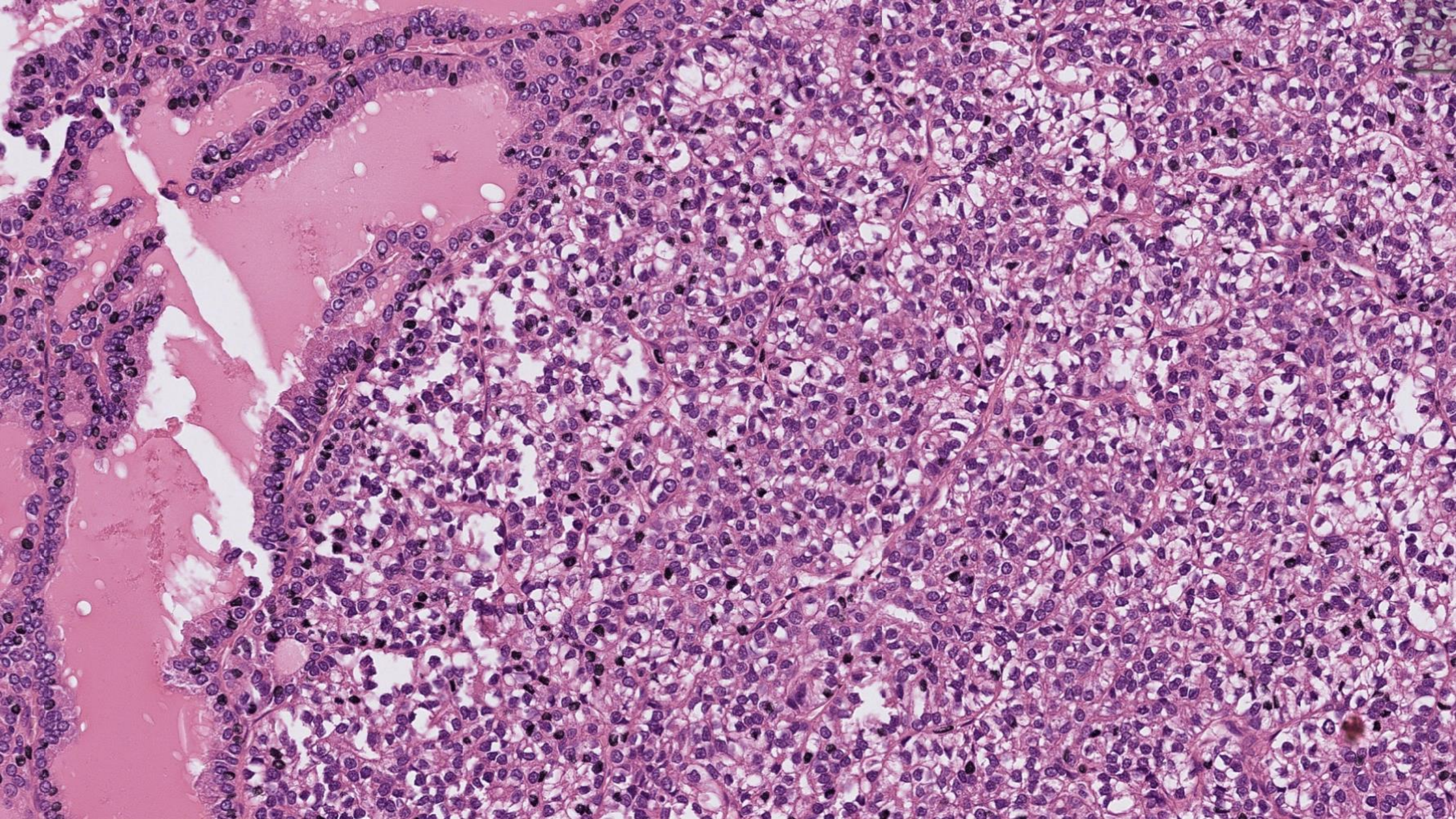

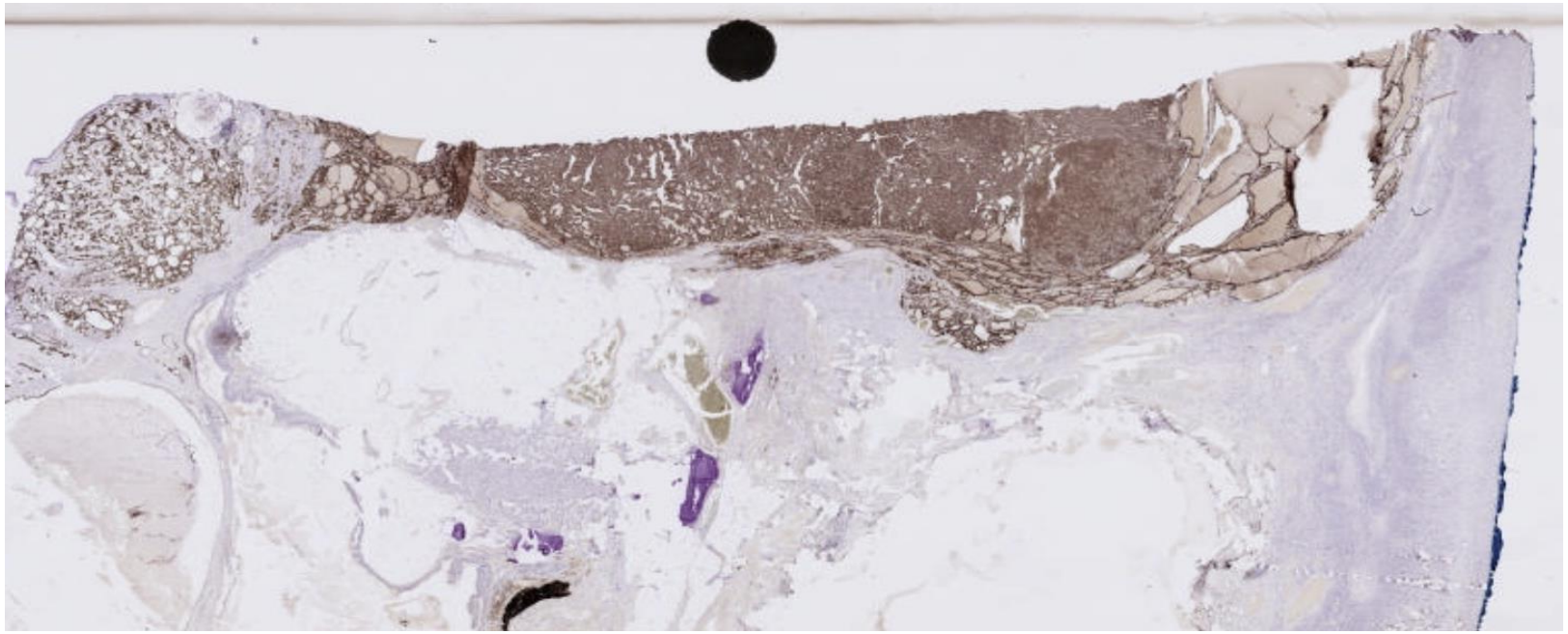

TTF1

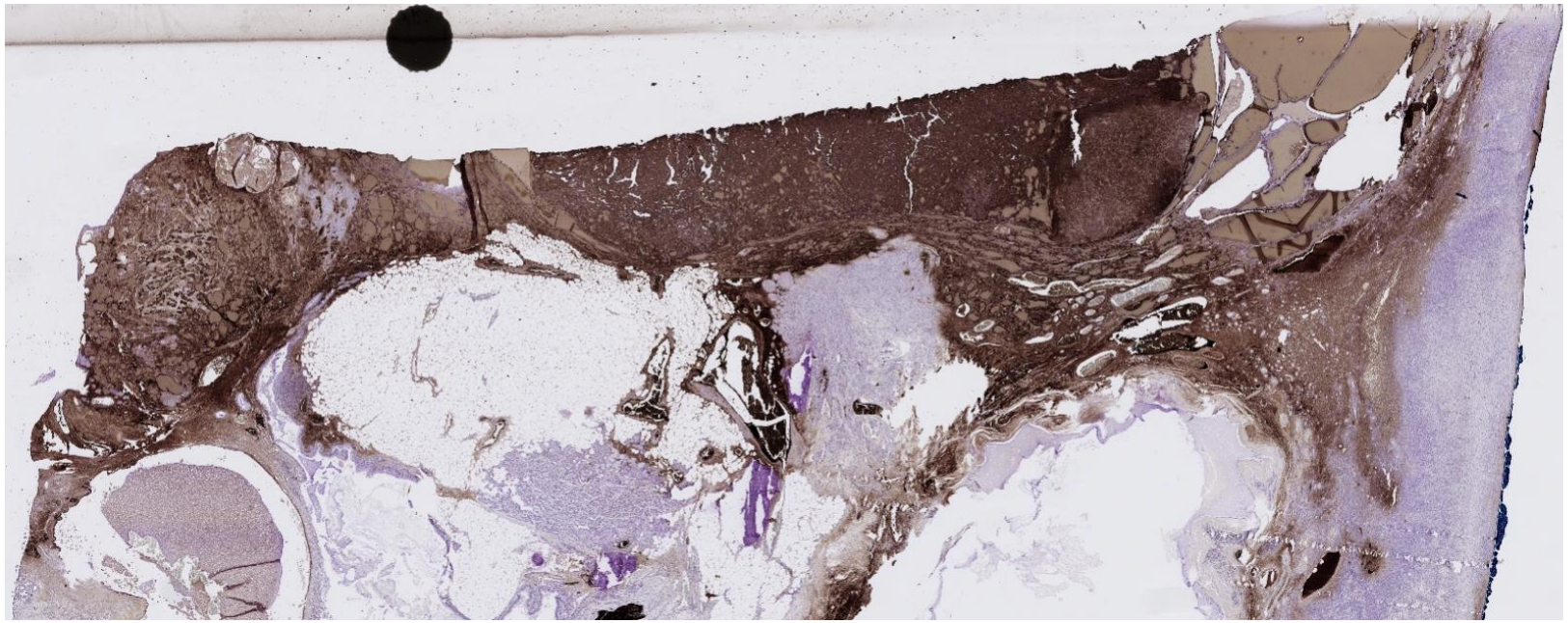

Thyroglobulin

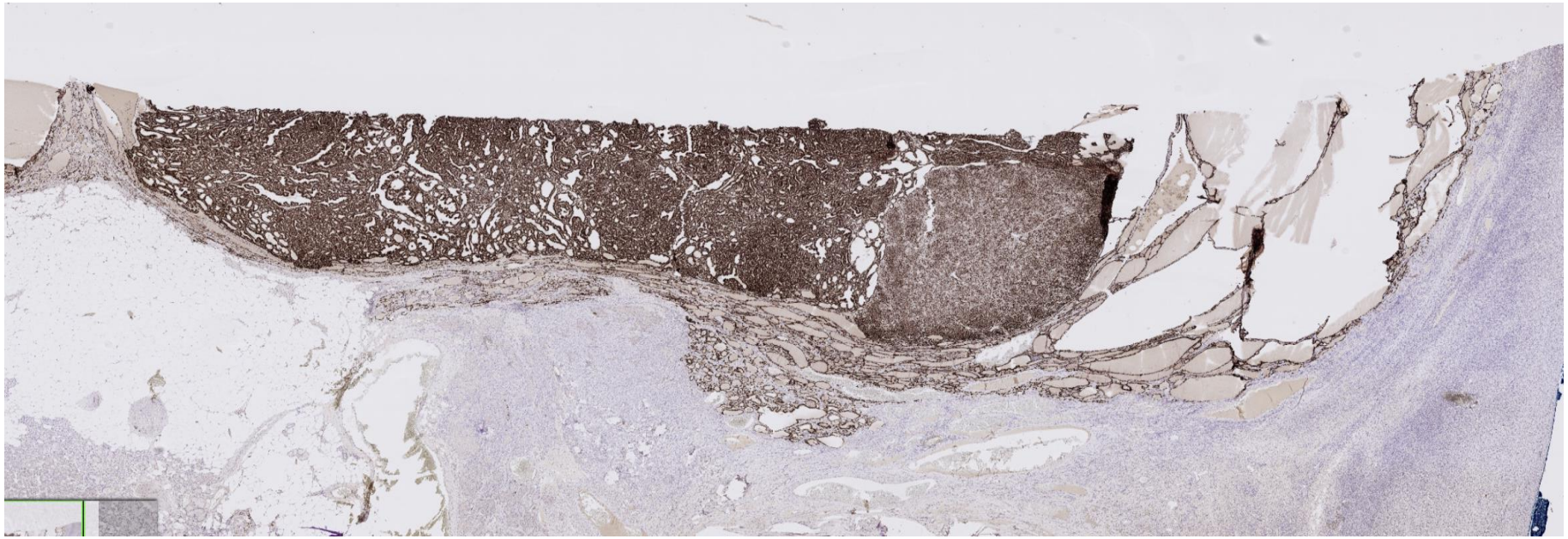

PAX 8

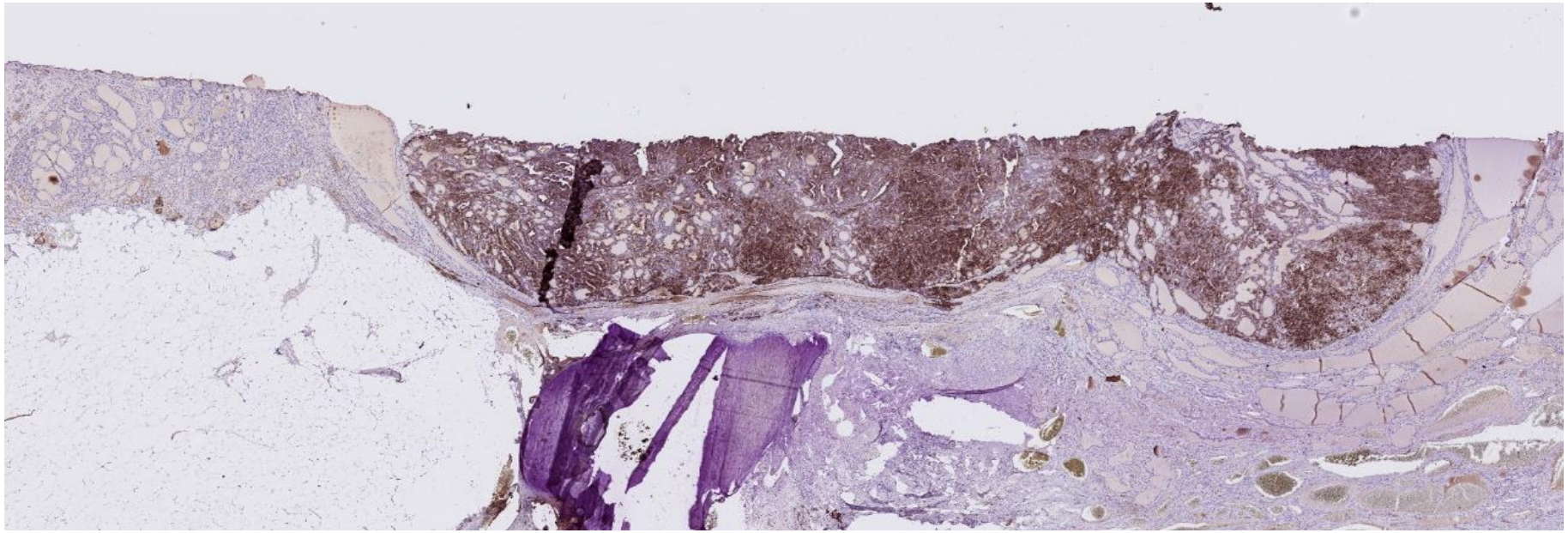

HBME 1

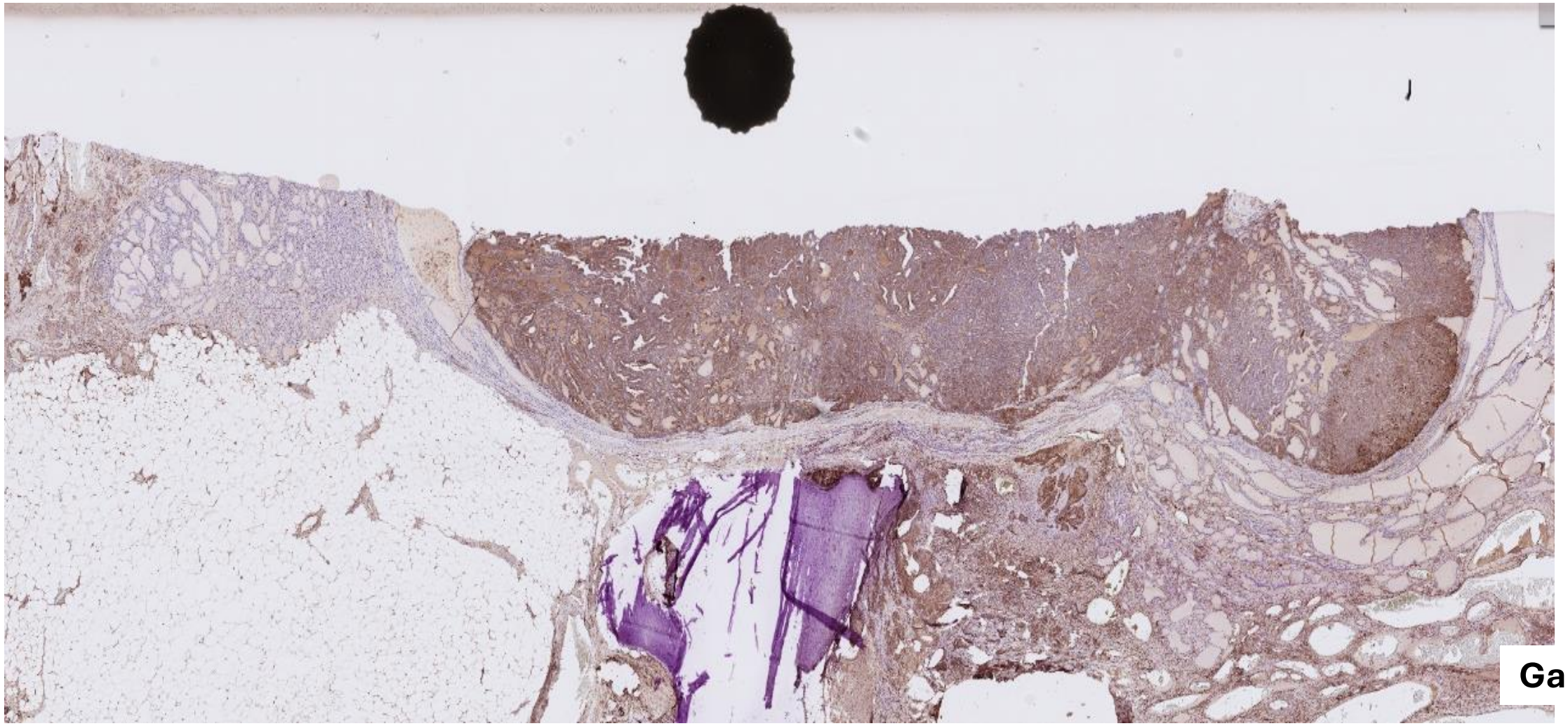

Galectin

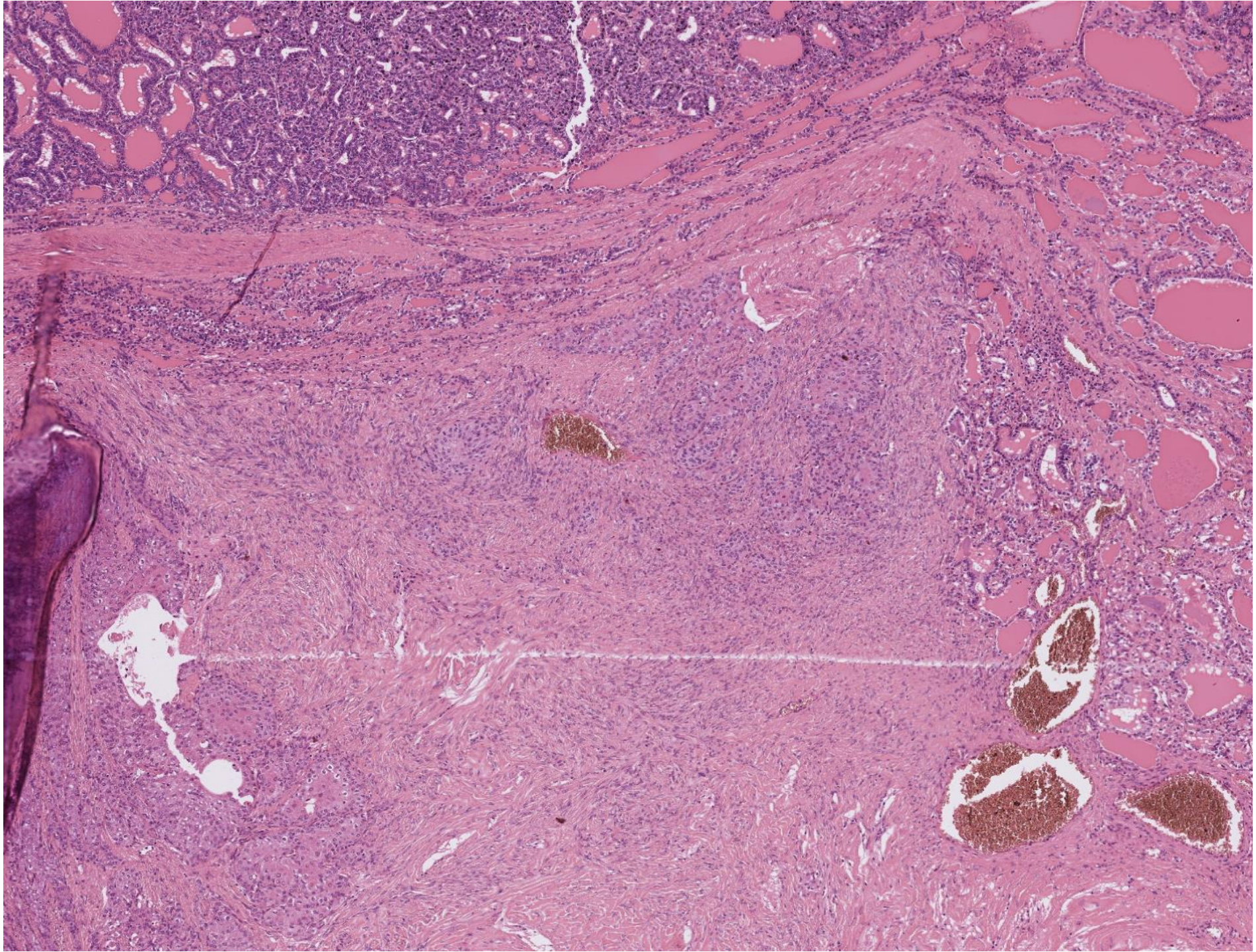

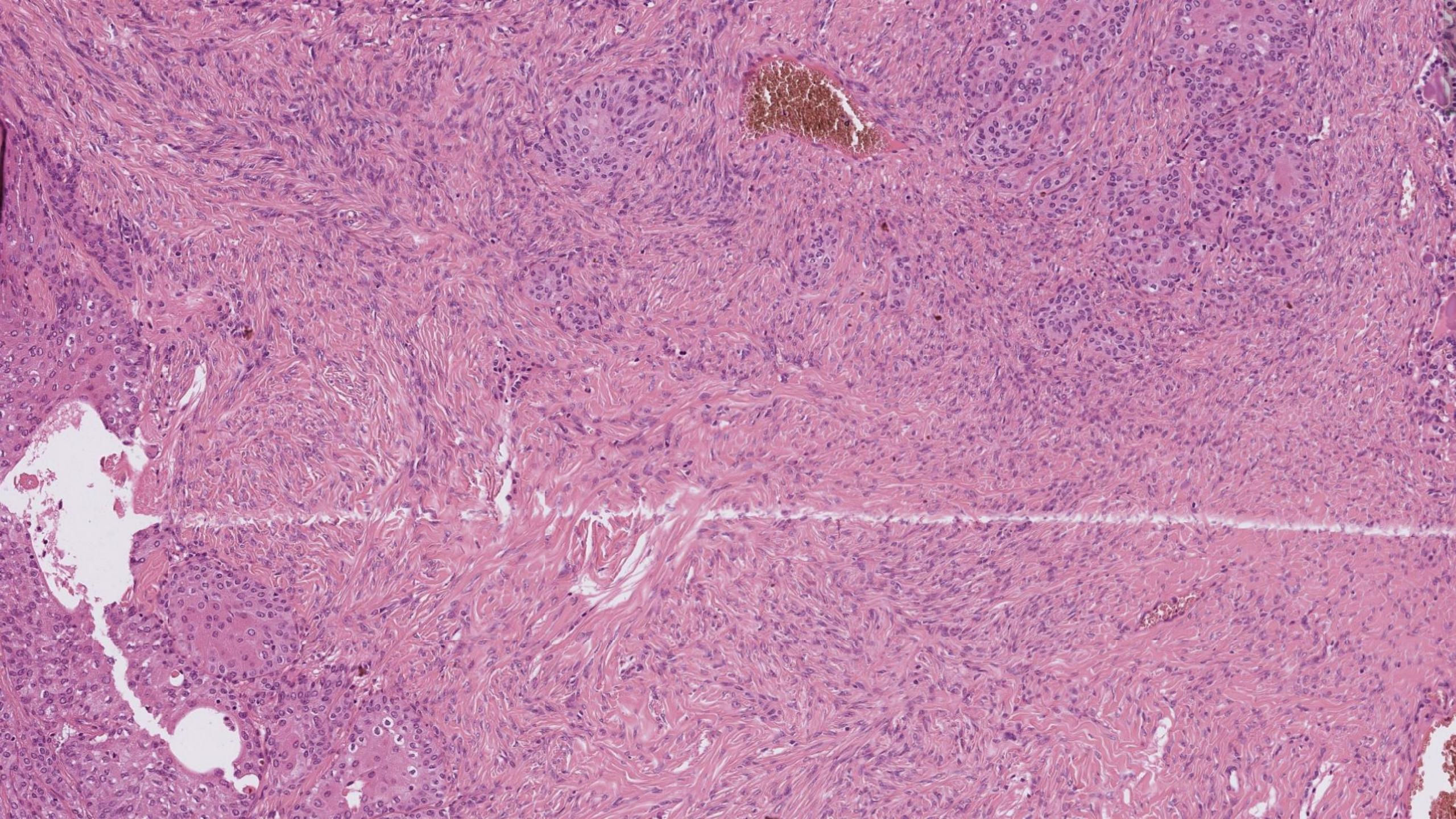

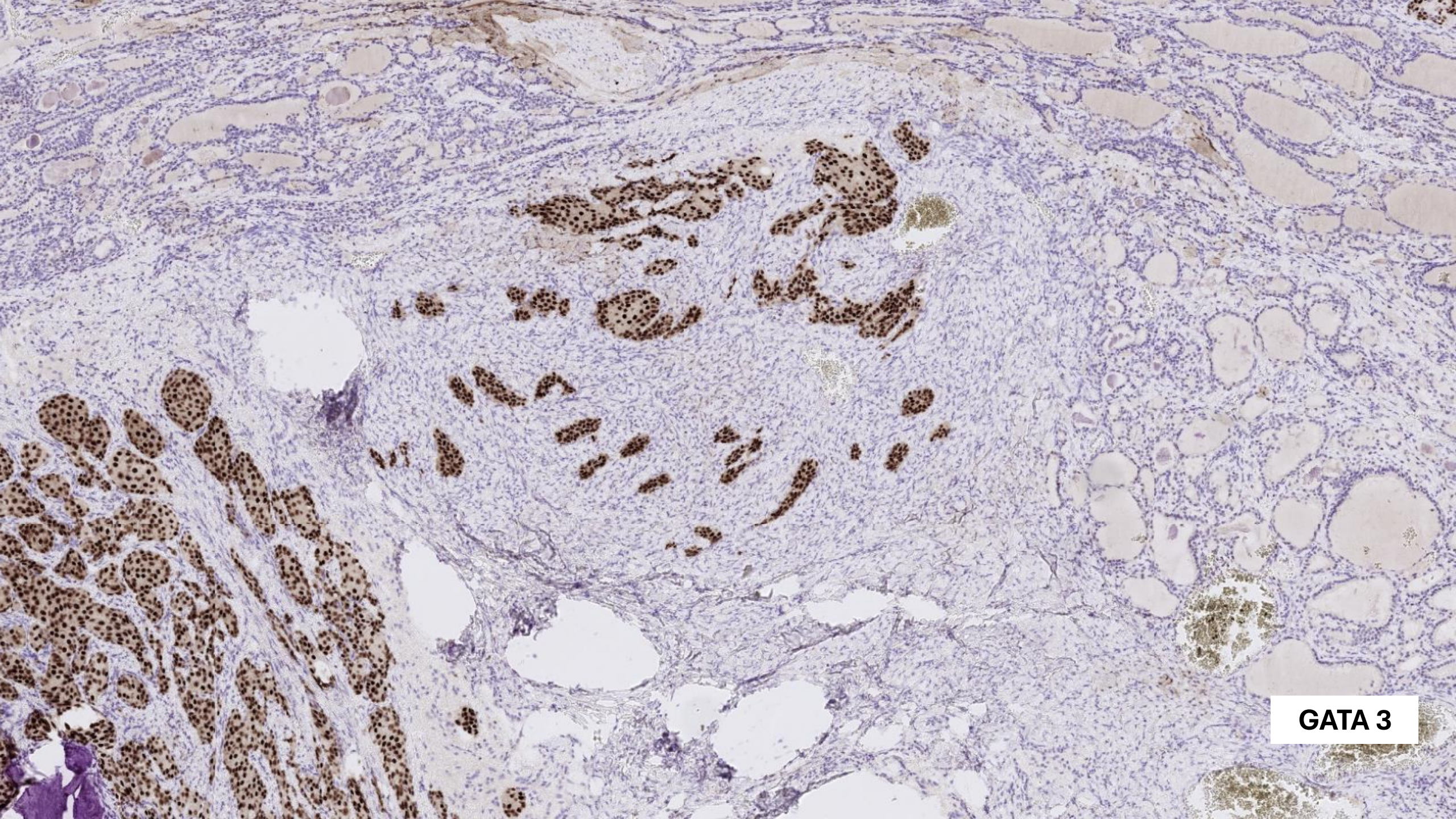
GATA 3

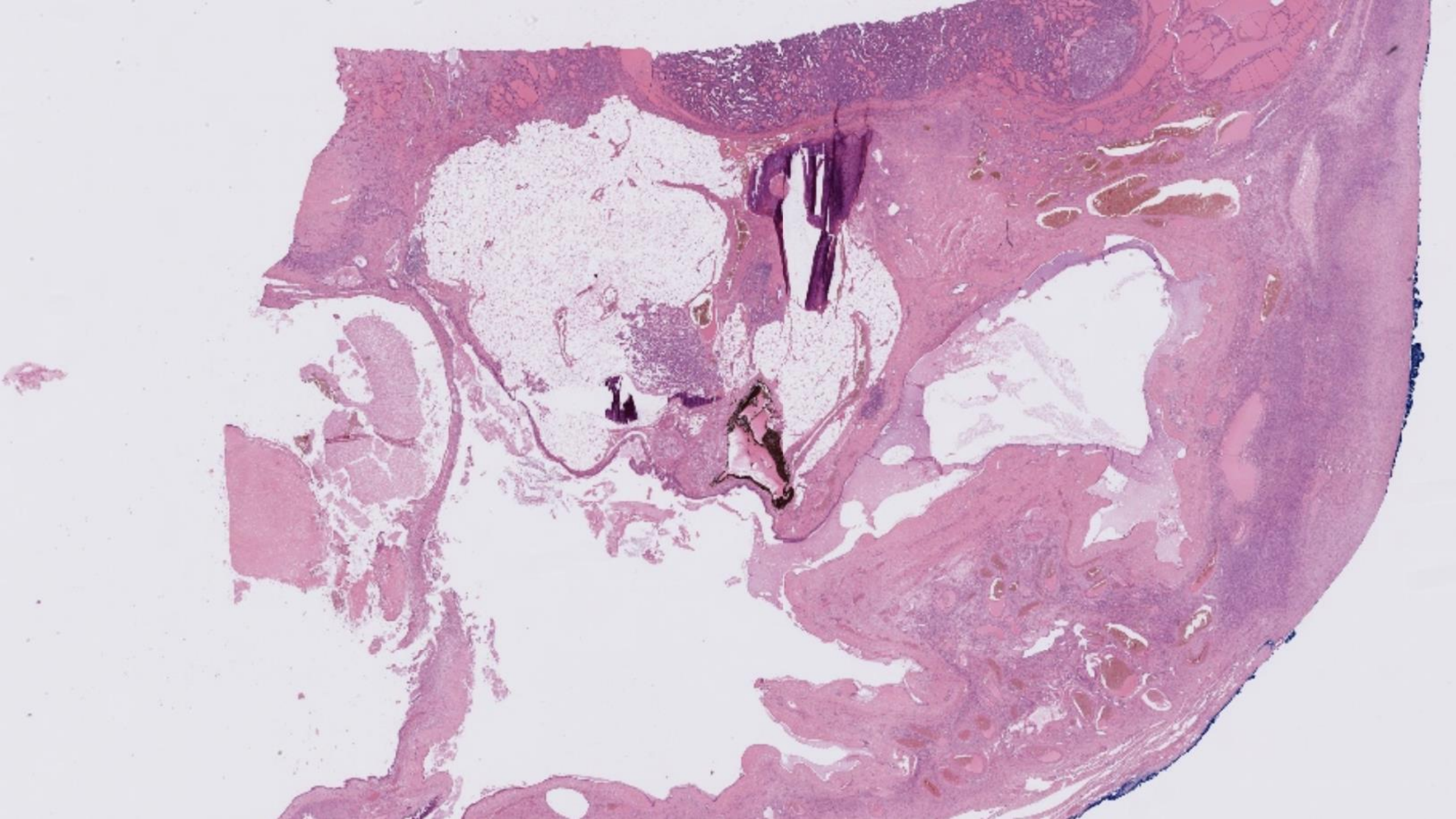

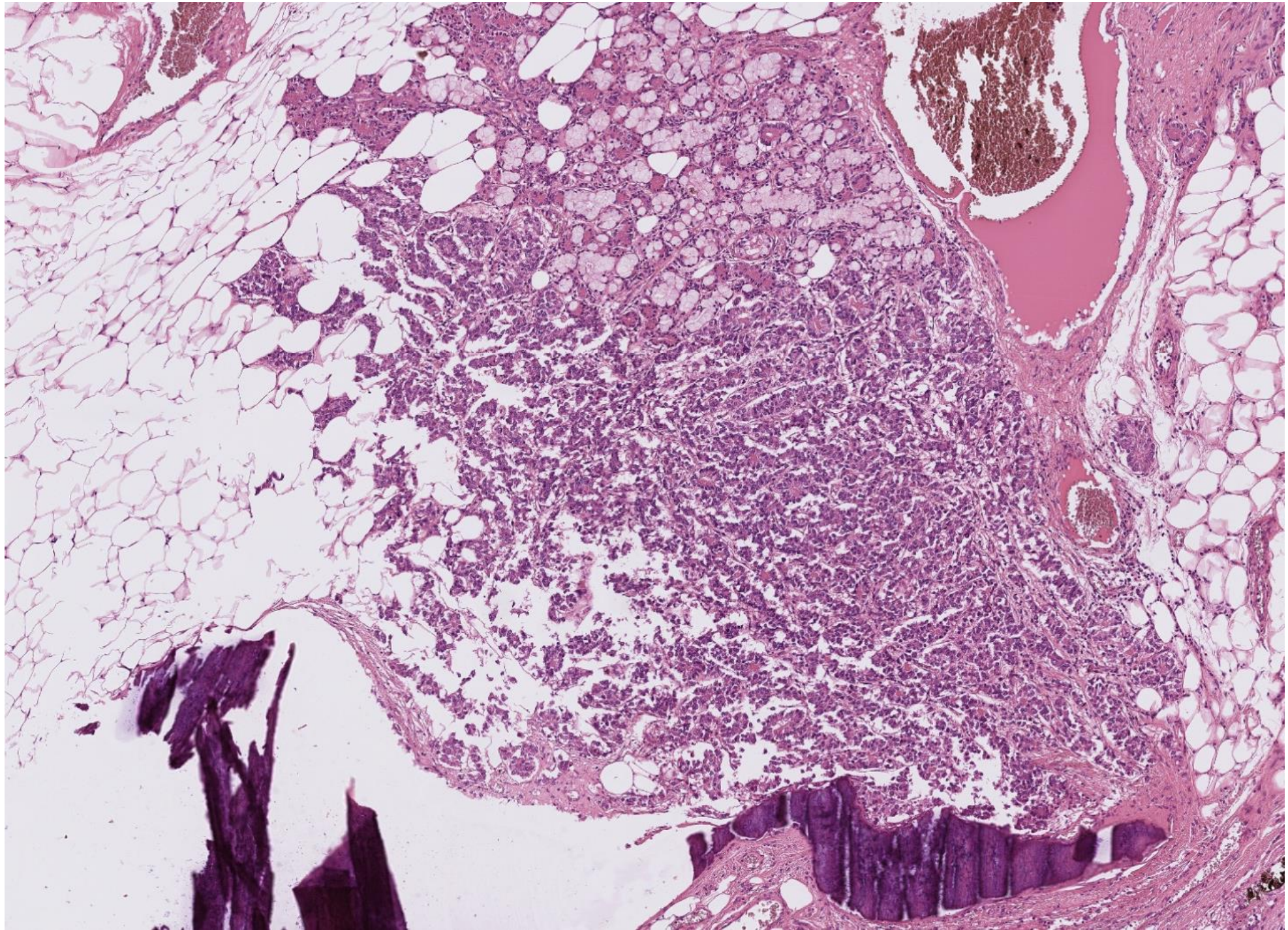

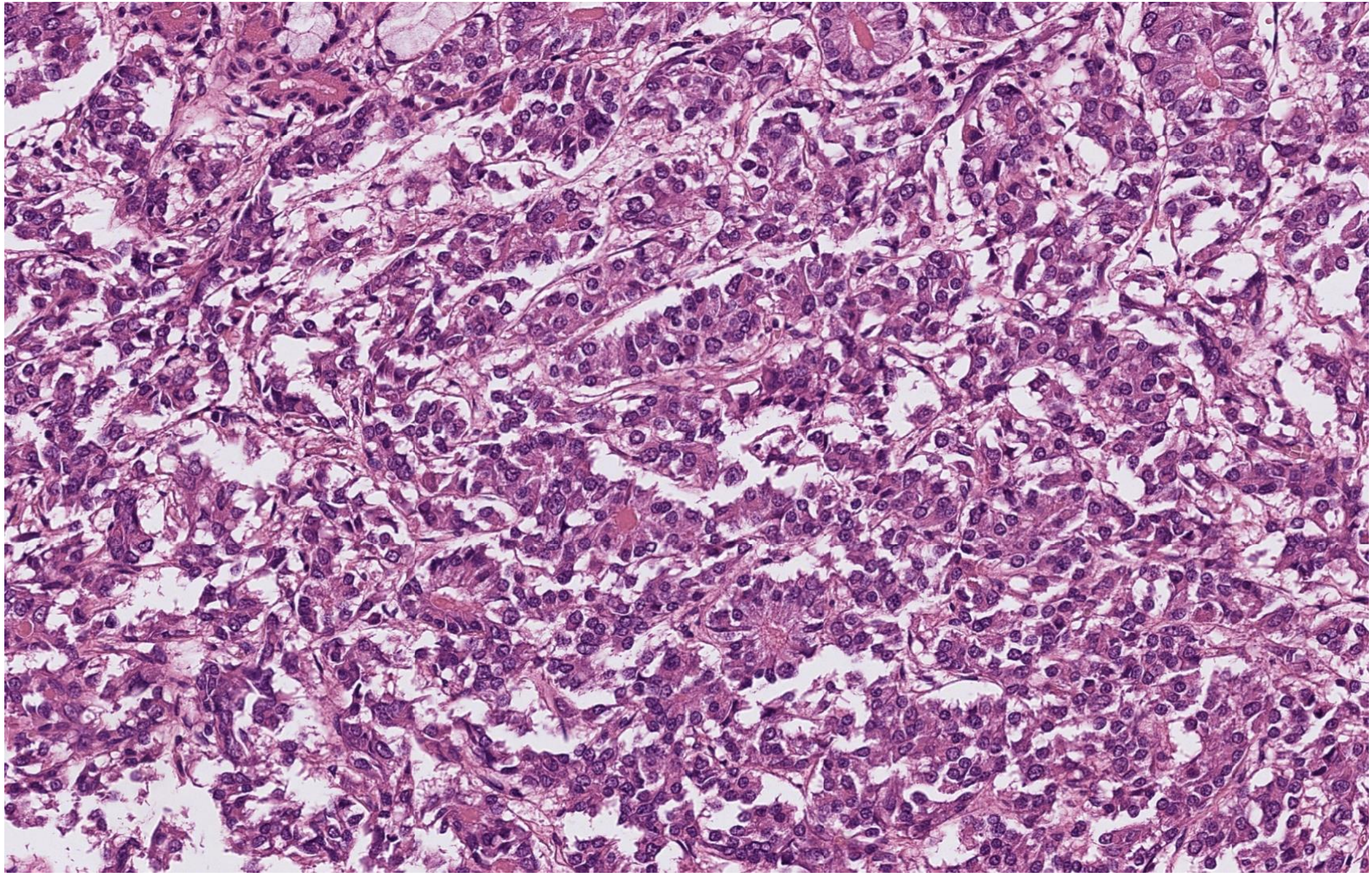

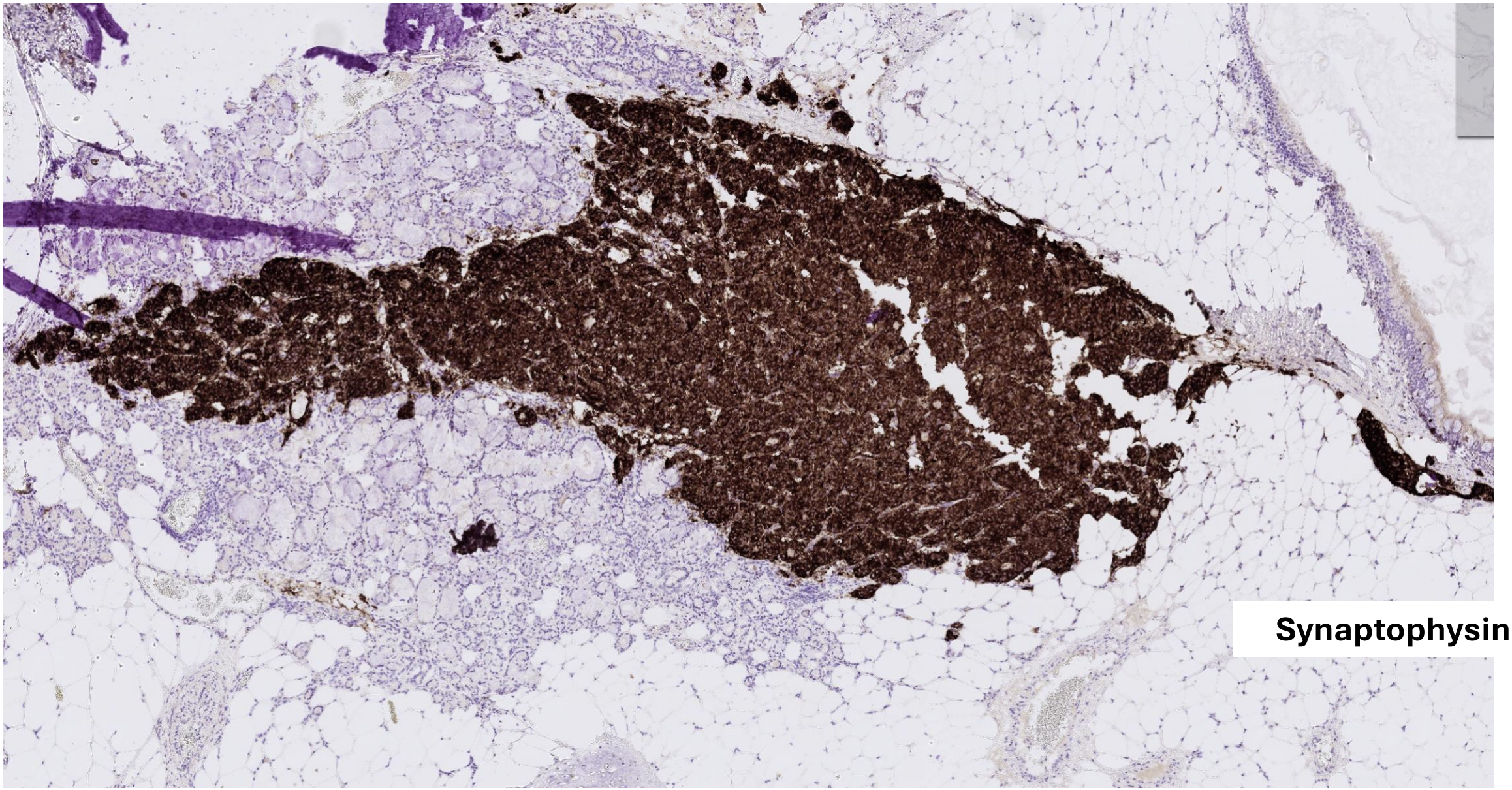
Synaptophysin

Microscopic features

- Teratoma: Epithelial types, calcified area, fat, glial tissue etc
- No immature neuroepithelium

- Thyroid neoplasm: Cellular, fairly well demarcated area, crowded follicles, papillary architecture, nuclear crowding/overlapping, grooves. IHC : TTF1, PAX8 +; HBME and Galectin +

- Carcinoid tumour: Acinar pattern, fairly uniform nuclei, no mitosis, necrosis, atypia etc. IHC : Synaptophysin +

- Brenner tumour: Nests of transitional type epithelium, fibrous stroma, no atypia. IHC: GATA 3 +

Other points

- Capsule status of ovary: appears ok in section provided
- Adequacy of sampling: 110cm mass - to evaluate
- Cross speciality opinion: PTC is subjective
- Appropriate MDT referral, may need thyroid evaluation, status of other ovary
- Comment on prognosis:

PTC small, confined: good outcome.

Brenner – benign

Carcinoid: assoc. with teratoma- excellent prognosis – no grading

LC1:Teratoma with neoplastic thyroid tissue (c/w or s/o PTC), Brenner tumour and carcinoid tumour

Mark	Features
1-7	Fails to diagnose
8-9	Fails to diagnose a lesion in thyroid tissue, suboptimal /inaccurate description
10	Just adequate description with confident diagnosis but no additional information
11-14	Good description, comments on cross specialty opinion for thyroid lesion, capsule status, extra sampling, raises concern for potential upgrading of the Brenner or carcinoid tumour
15-16	In addition, shows knowledge of immunostains and their limitations. Awareness of clinicopathological correlation.

Case 2

- Female 78 years

  Vulvectomy - vulval lesion

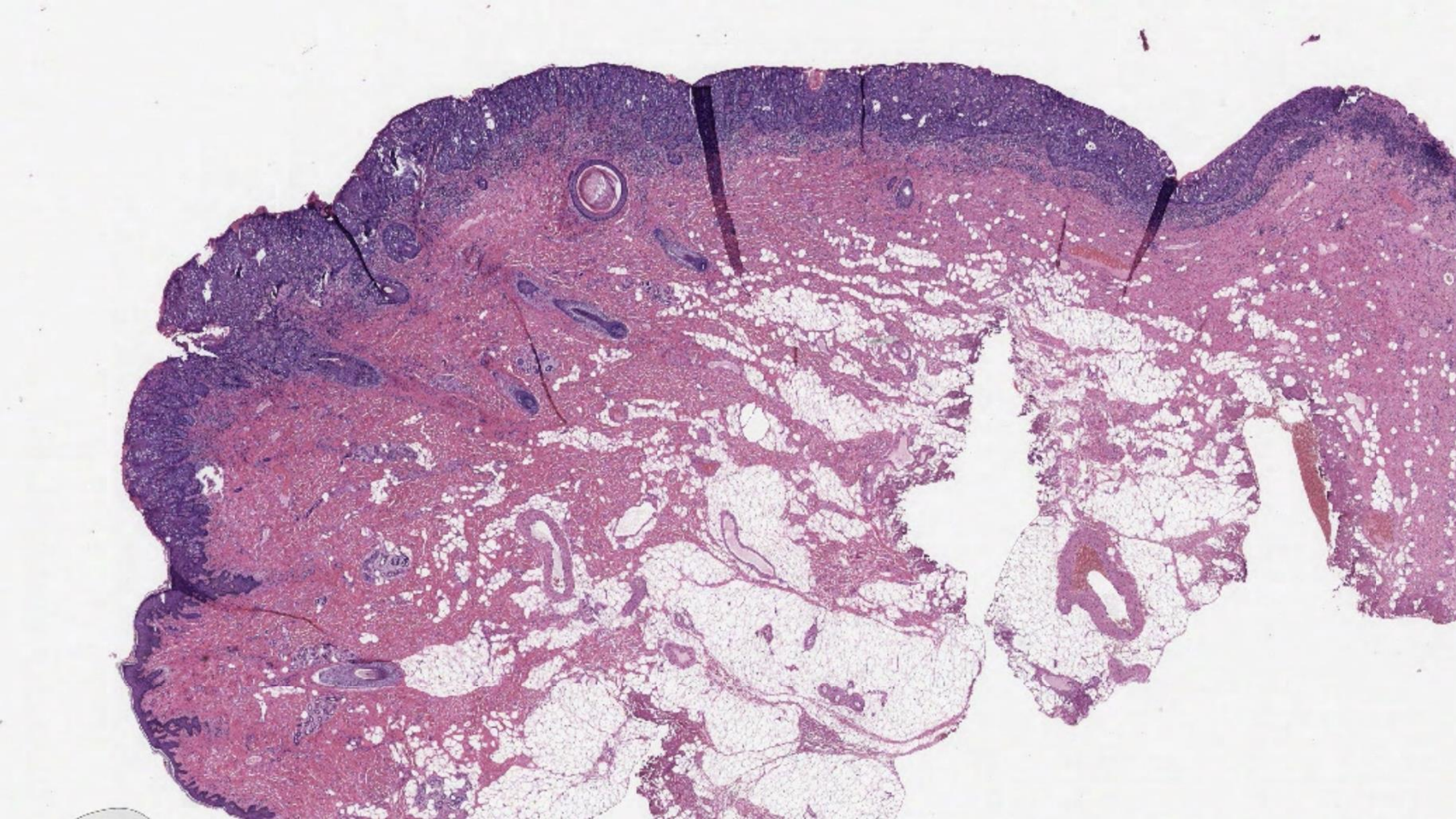

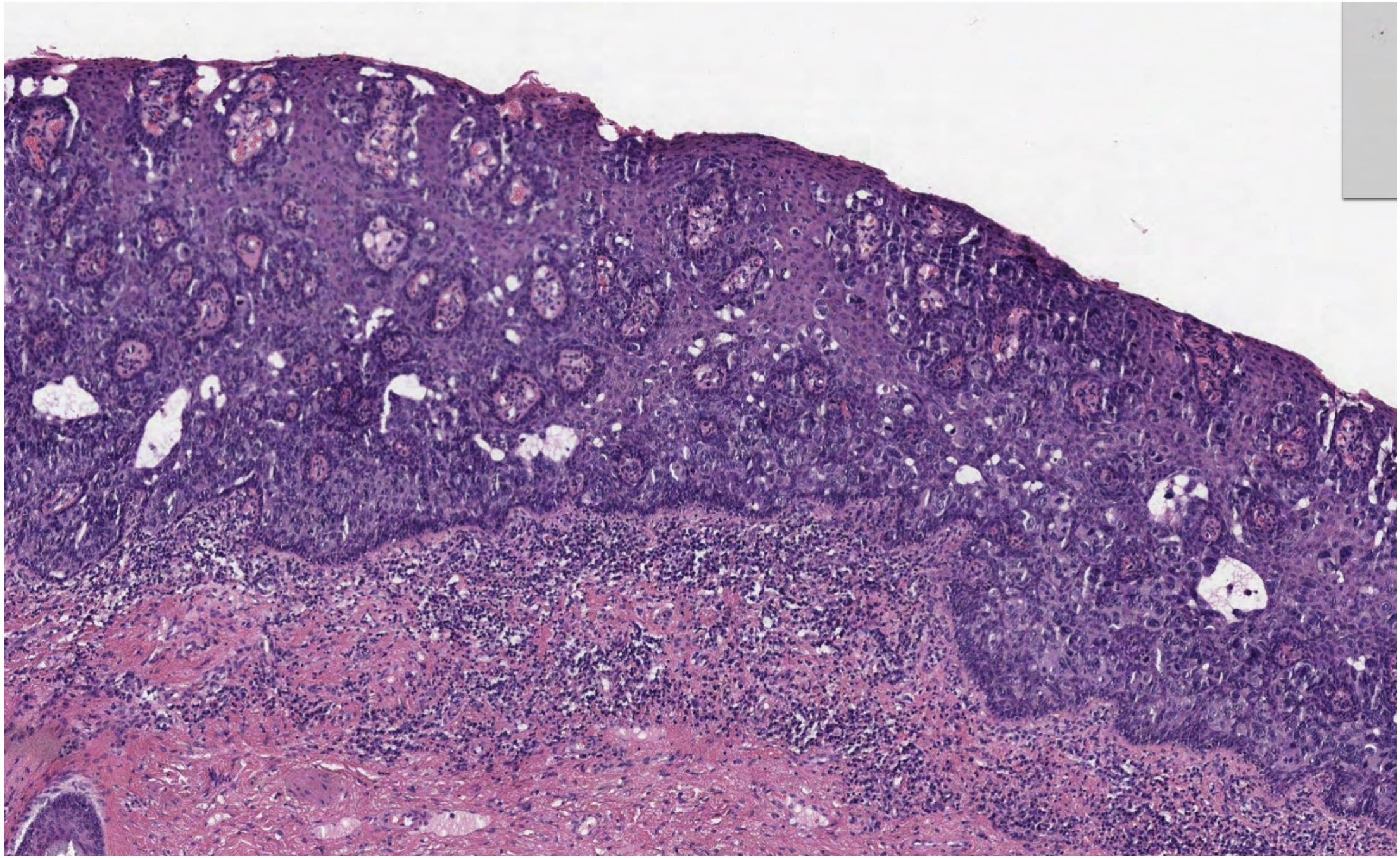

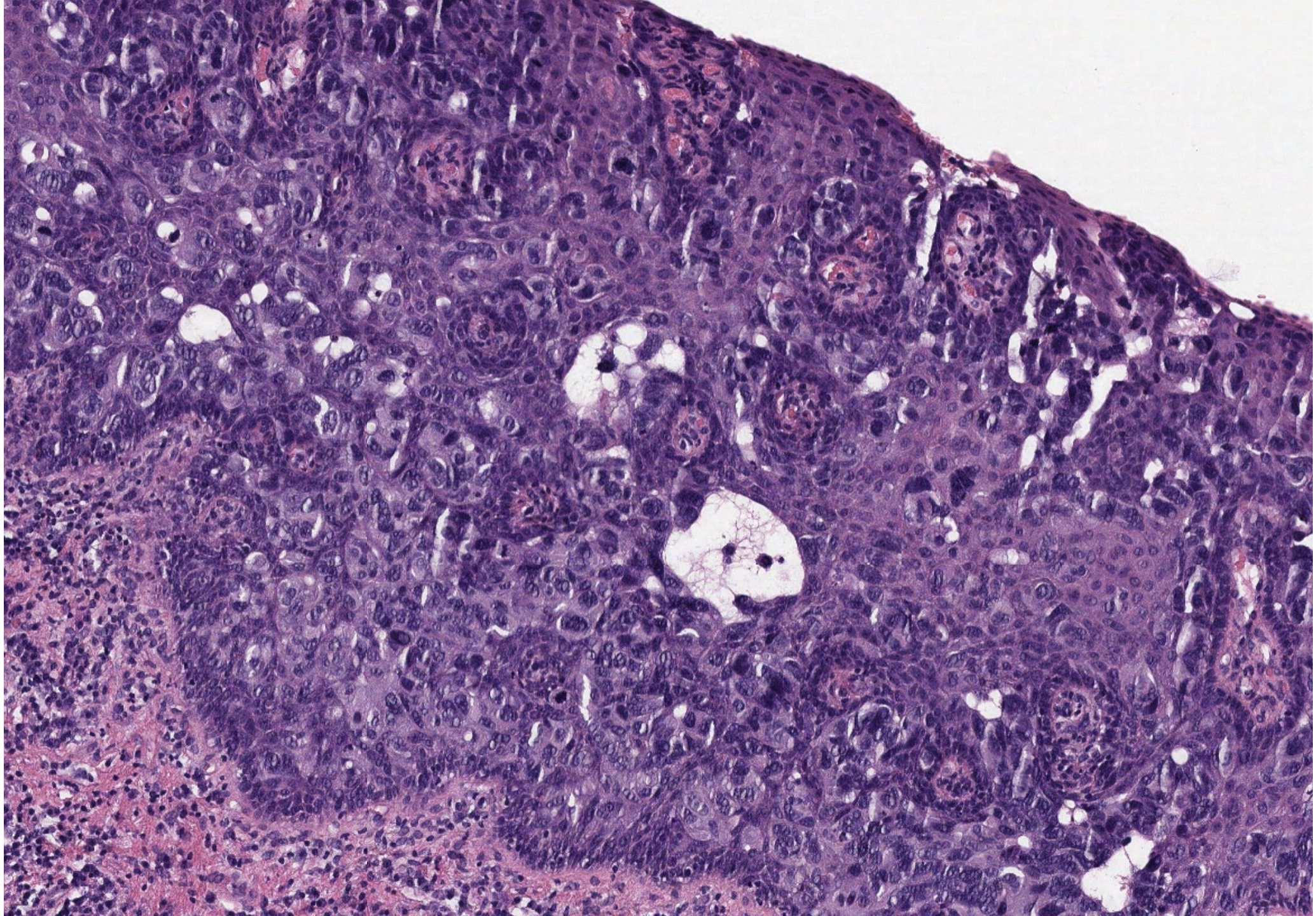

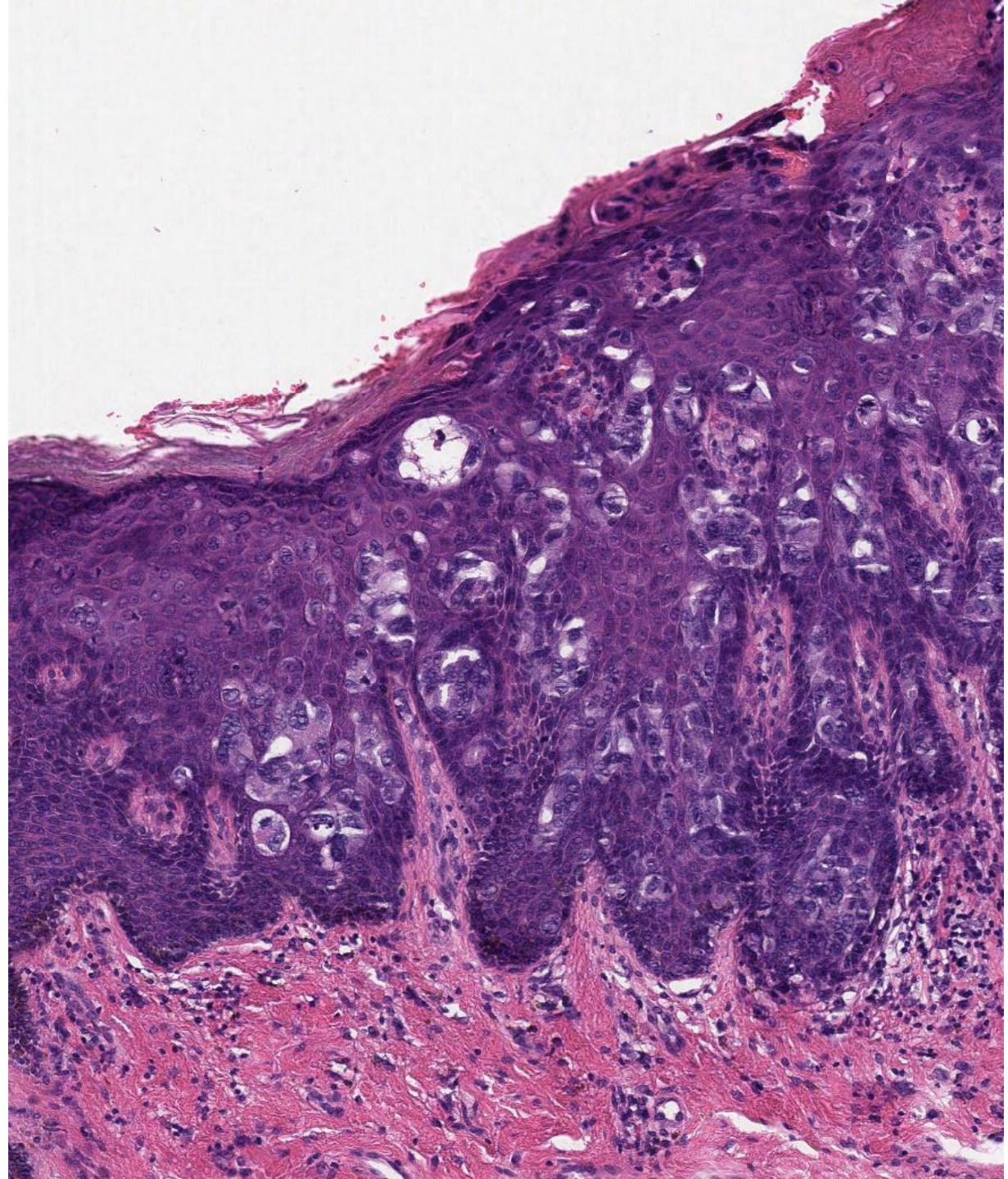

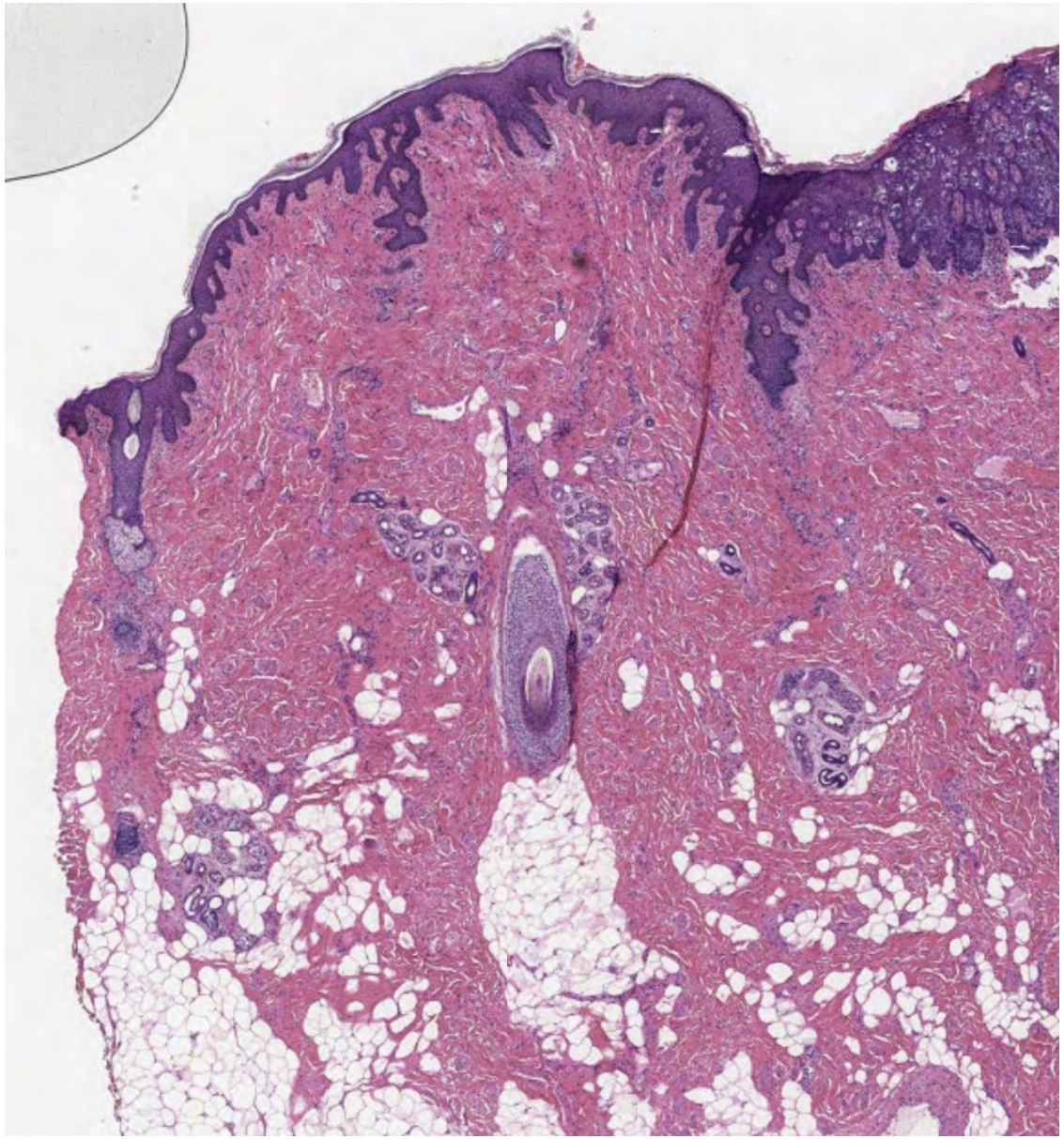

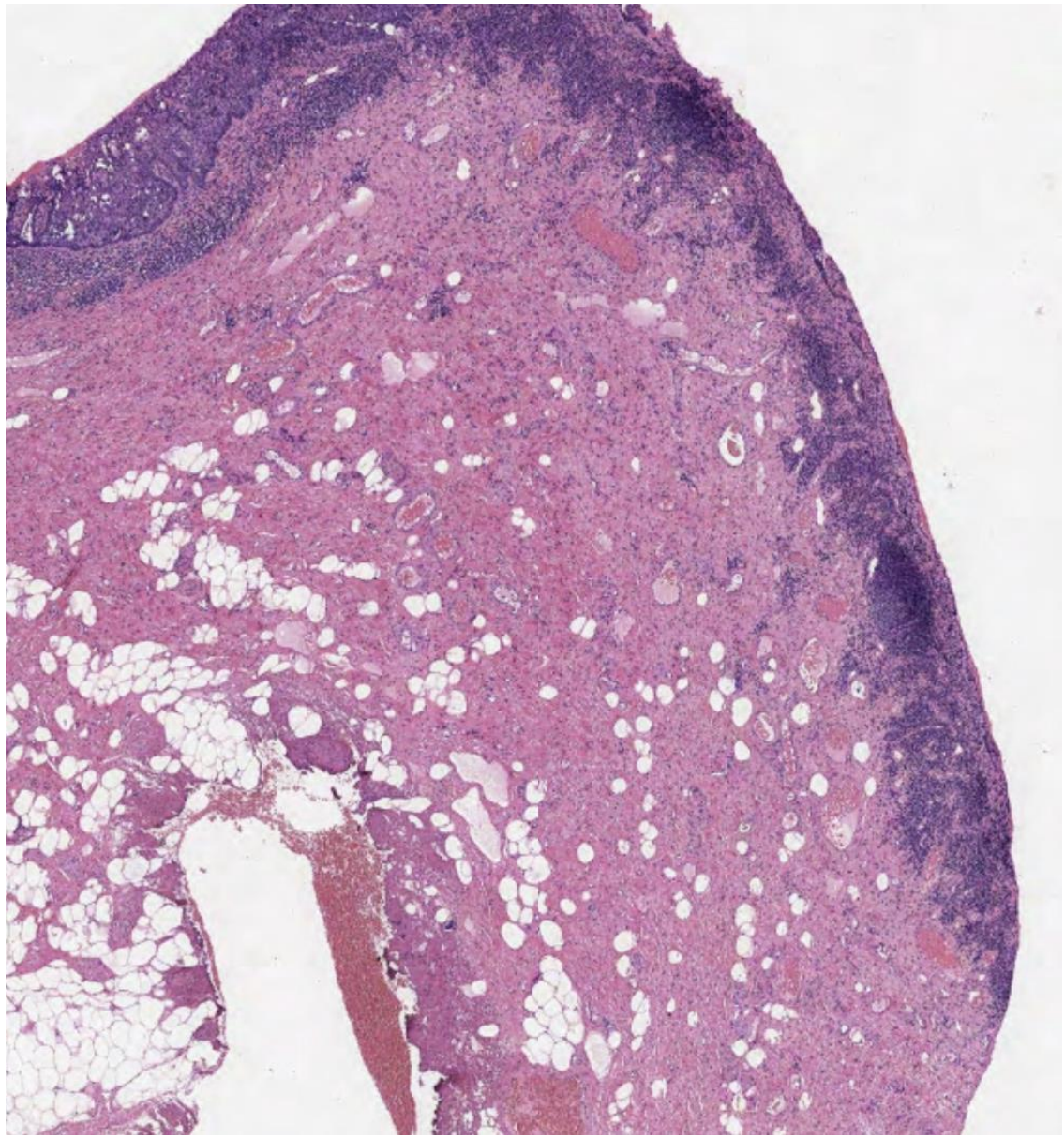

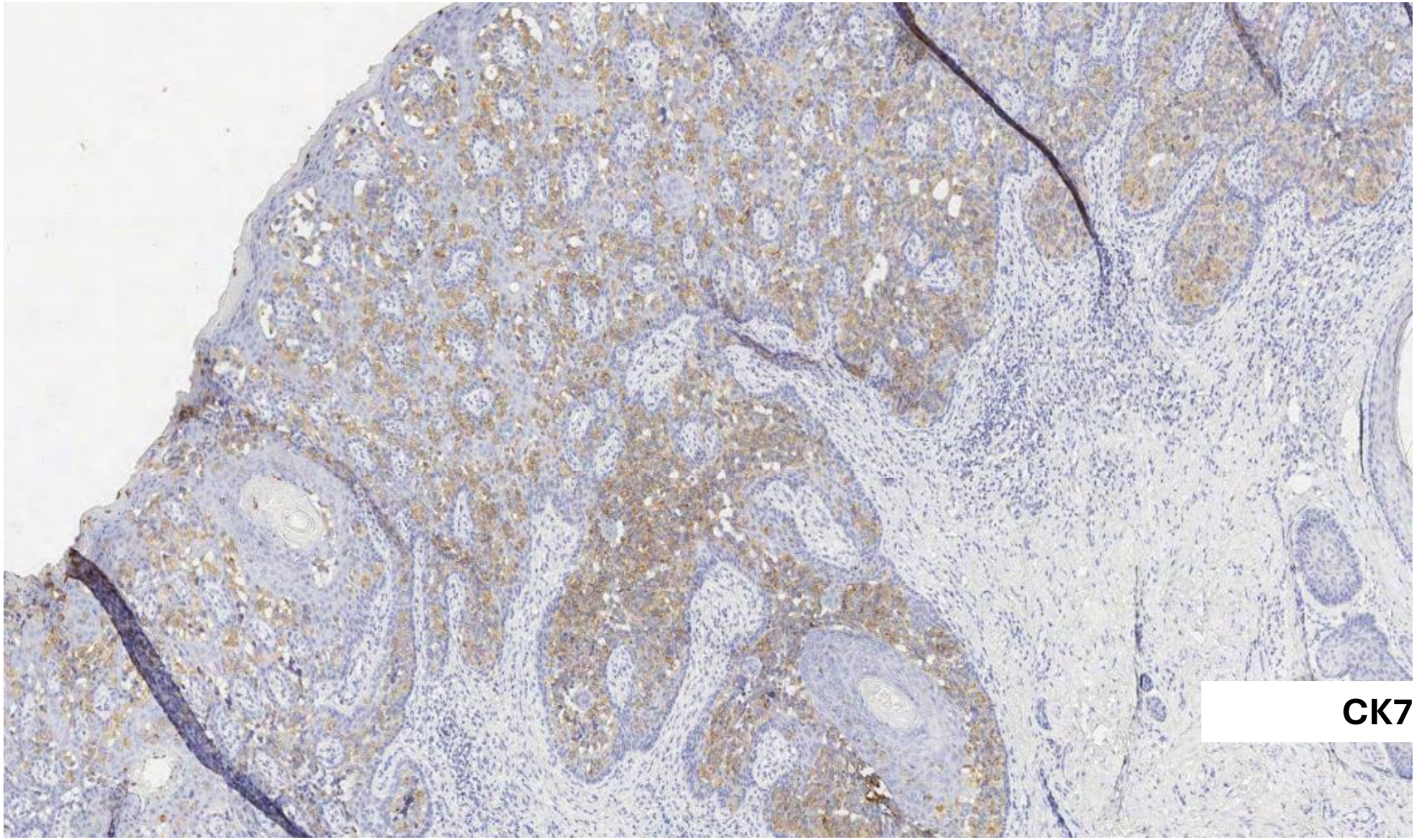
CK7

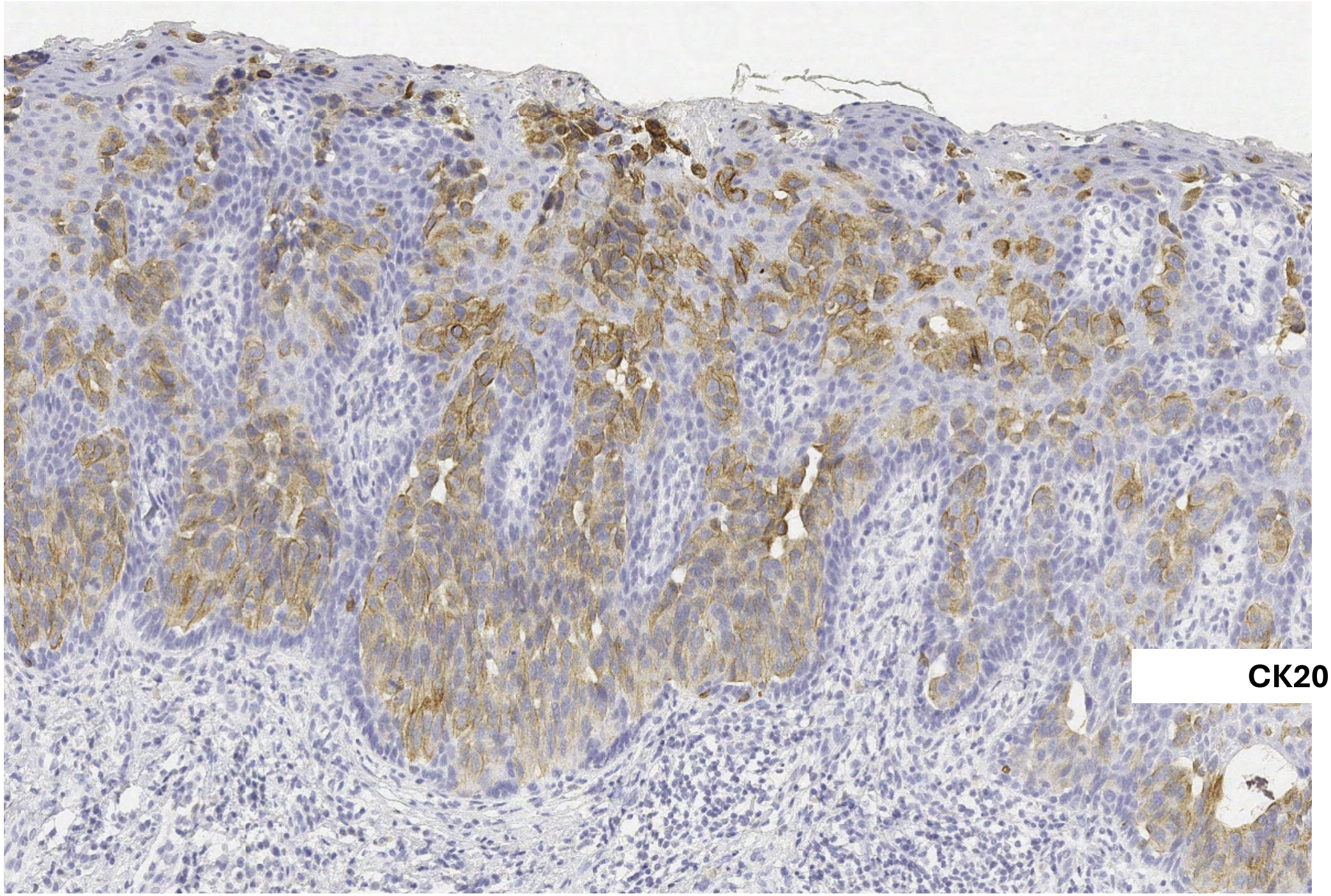
CK20

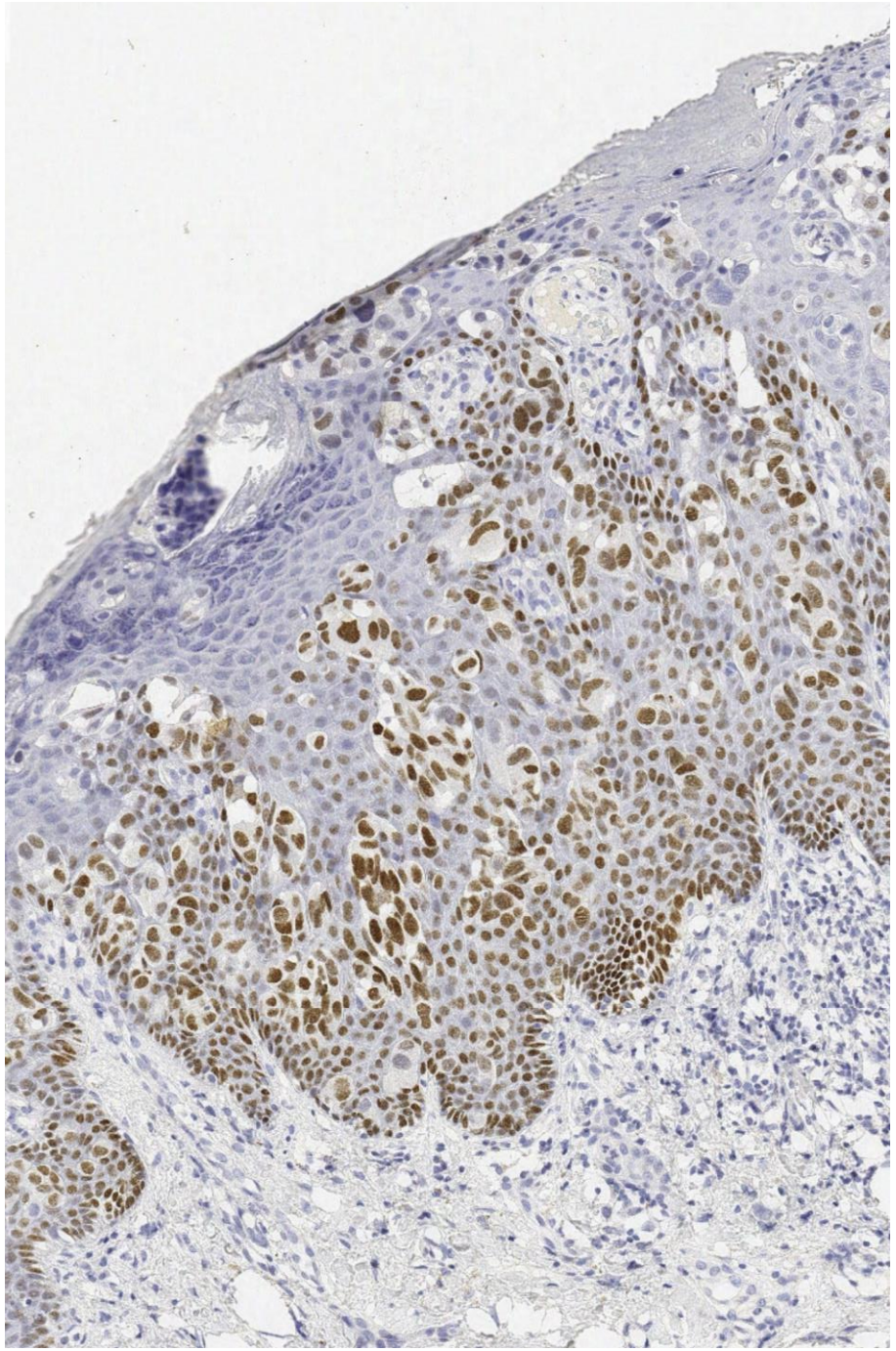

p63

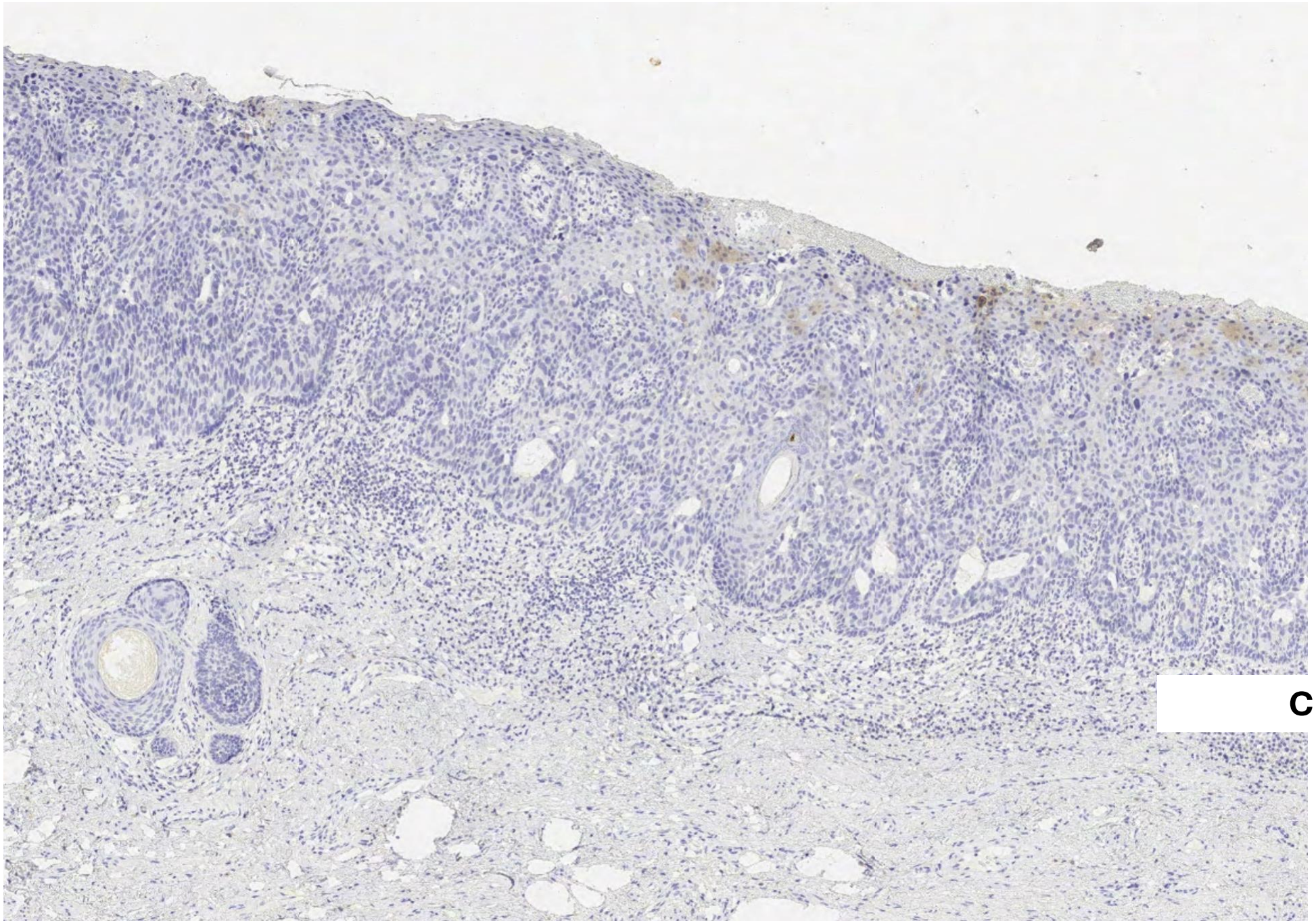

CEA

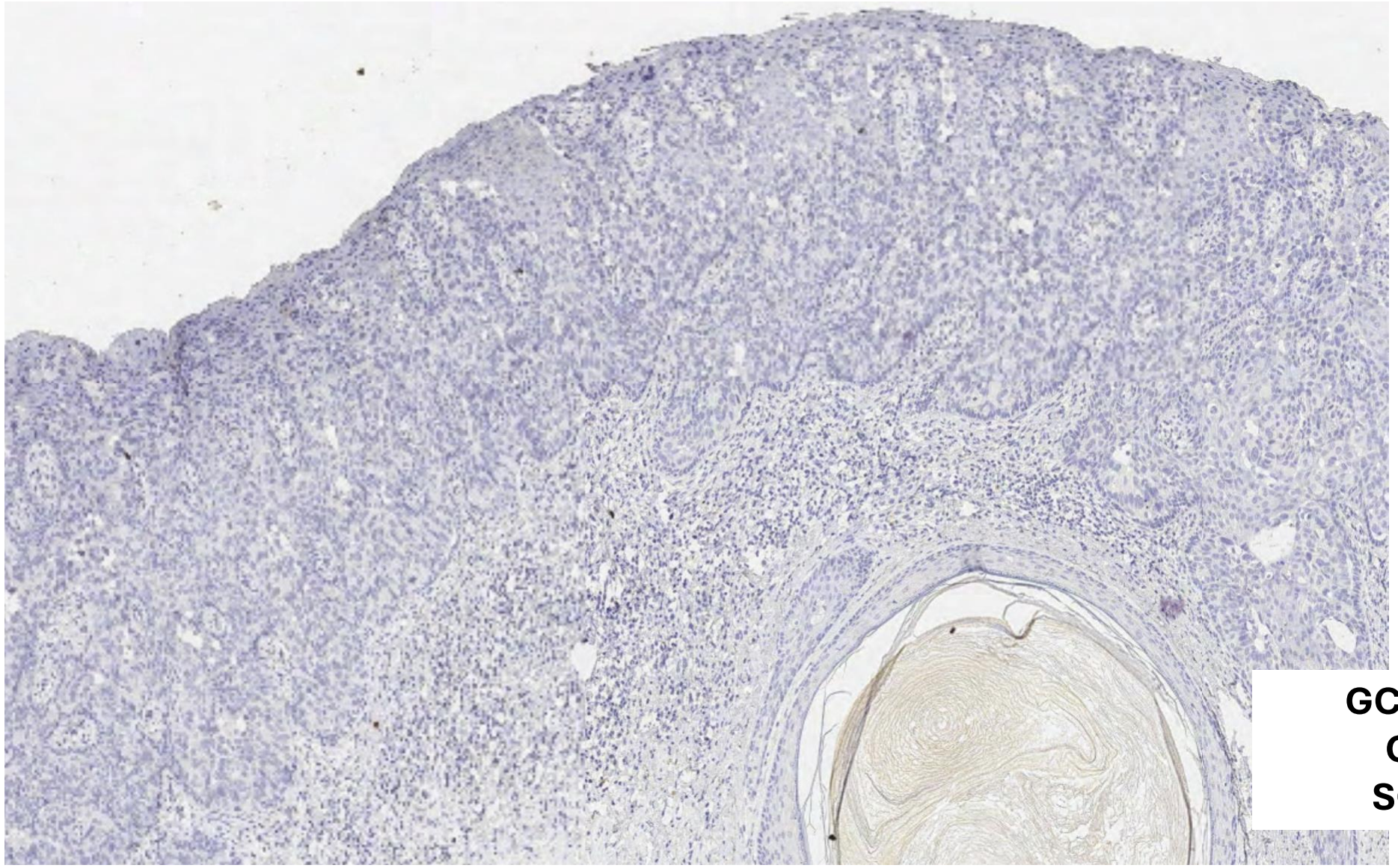

GCDFP 15
CDX2
SOX 10

Microscopic features

- Intraepidermal scattering of single/clusters of large cells characterized by abundant amphophilic cytoplasm, round / ovoid atypical nuclei.
- No stromal invasion. Margin cannot be assessed due to ulceration.
- Epidermis acanthotic, accompanied by focal hyperkeratosis and ulceration

IHC findings:

- CK7 and CK20 weak +, p63+. CEA neg, GCDFP 15 neg, SOX10 neg

LC 2: Paget disease

An in-situ adenocarcinoma of the vulval skin with or without invasive adenocarcinoma.

- Primary Paget disease : Primary vulval in-situ adenocarcinoma

  AKA extramammary Paget disease

- Secondary Paget disease : secondary involvement of vulval skin by carcinoma of rectal, bladder or cervical origin

LC 2: Paget disease

- Common in elderly, postmenopausal, Caucasian women
- Unknown aetiology
- Origin from pluripotent stem cell of epidermis or skin adnexa
- Present as slowly expanding, erythematous or eczematous, focally eroded or crusted plaques
- Frequently multifocal
- Clearance of disease with wide margins remains a challenge as Paget cells often extend further than is clinically appreciable.
- Local recurrences are common

IHC profile

- Primary Paget disease : CK7, GATA 3, GCDFP-15, CEA, p16 non-block

- Secondary Paget disease, anorectal primary: CK20, CDX2, SATB2
- Secondary Paget disease, urothelial primary: CK7, CK20, GATA 3, Uroplakin, p63
- Secondary Paget disease, cervical primary: CK7, PAX8, p16 block type +, HR HPV

Differentials:

- Melanoma in situ- SOX10, Melan A, HMB 45
- VIN- p16/p53, HR HPV

LC 2: Paget disease of Vulva

Mark	Features
1-7	Fails to diagnose
8-9	Fails to offer confident diagnosis, suboptimal /inaccurate description
10	Just adequate description with confident diagnosis but no additional information
11-14	Good micro and IHC description, comments on likely primary site of origin and further action plan, awareness of clinicopathological features
15-16	In addition, elucidates the differential diagnosis well using tables/chart

Case 3

- Female 47 years

  Ovarian mass

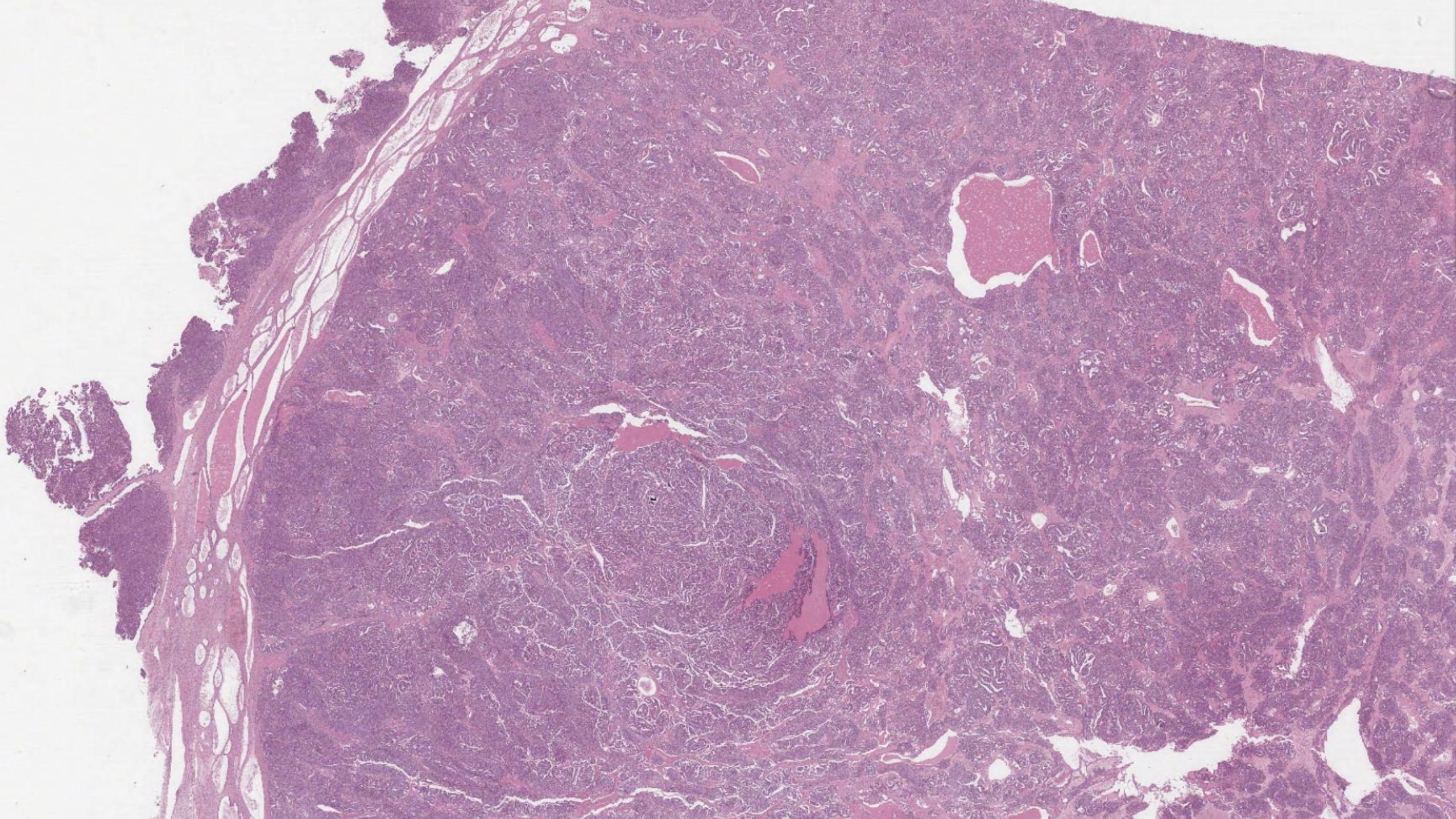

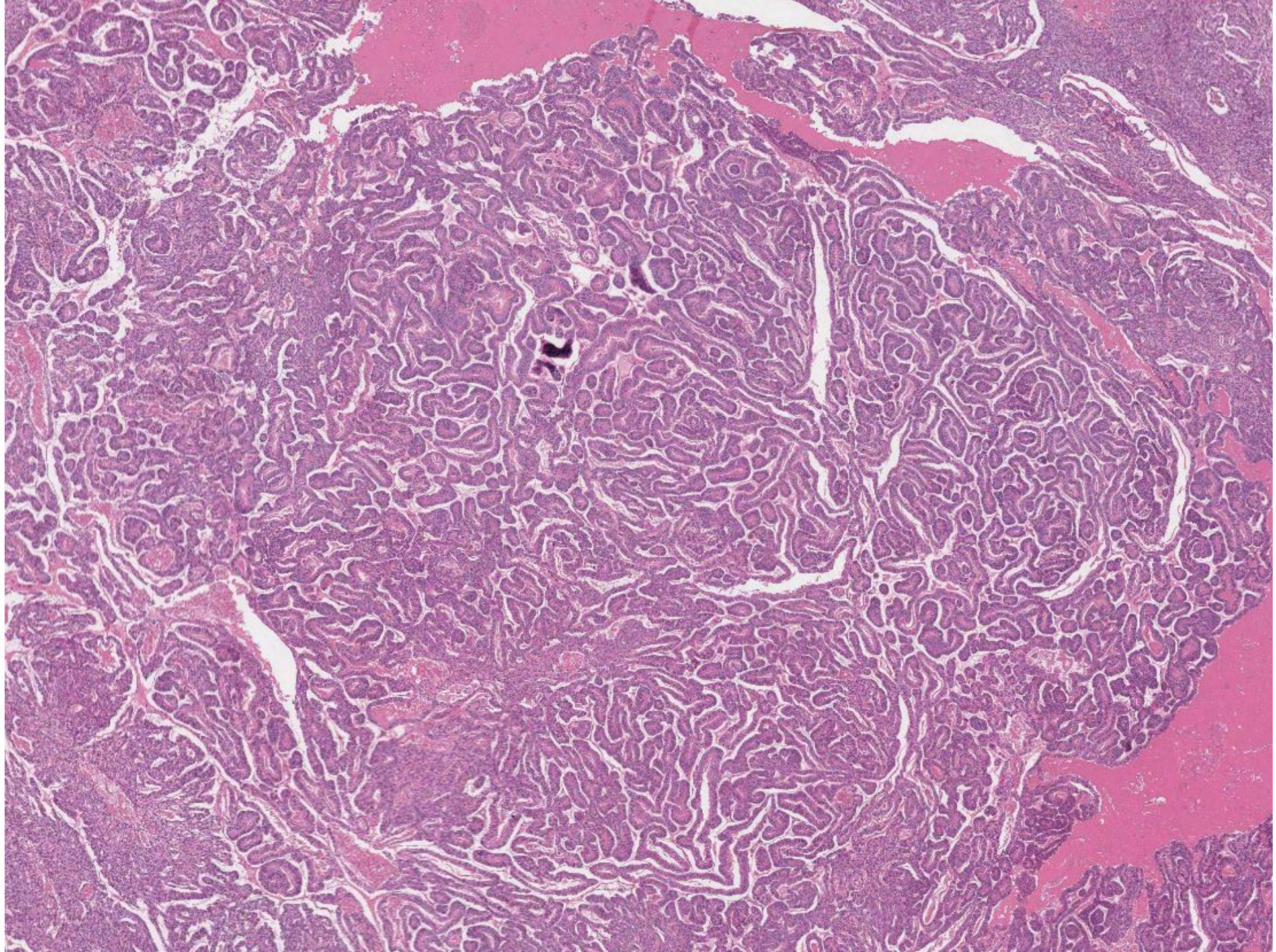

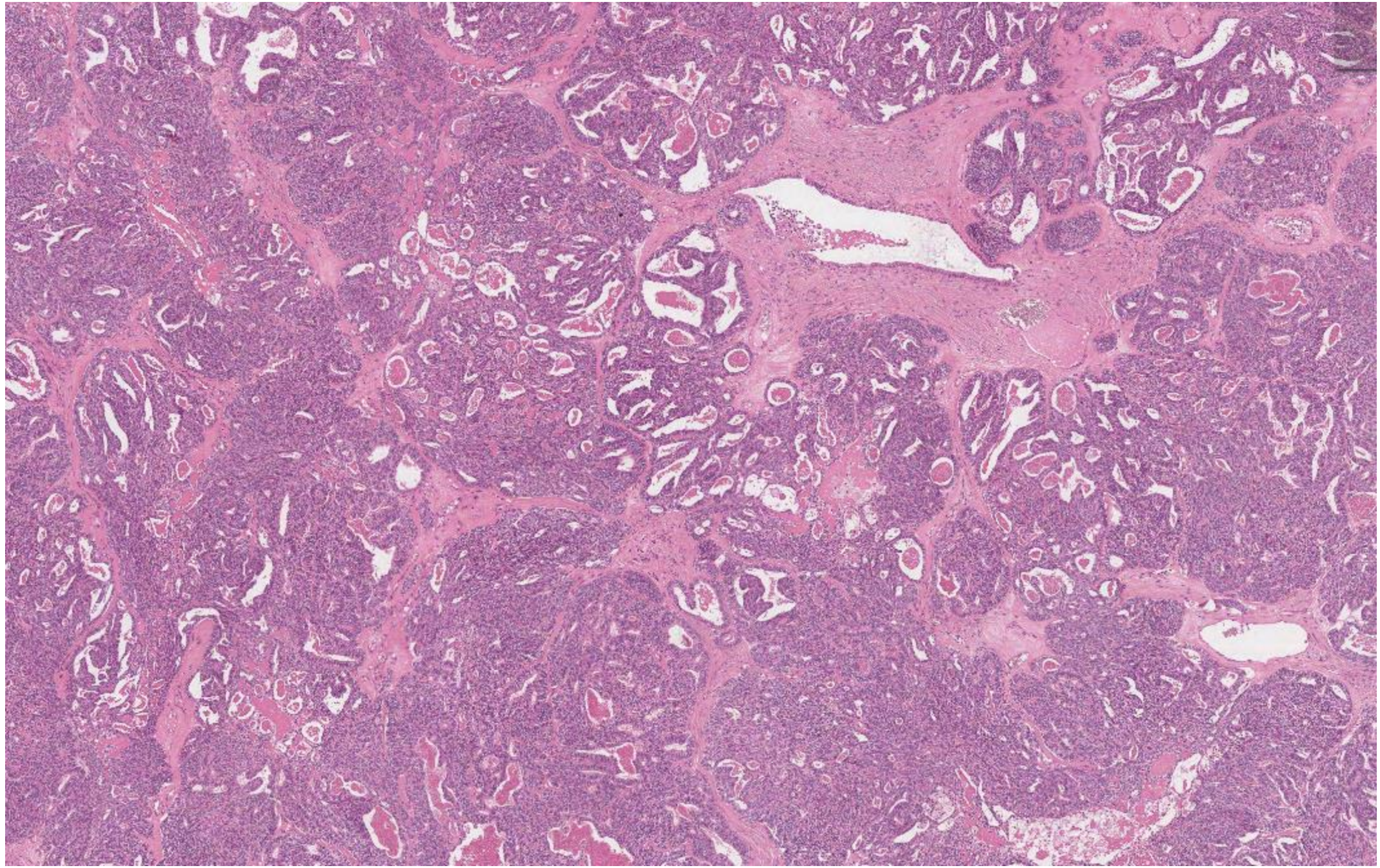

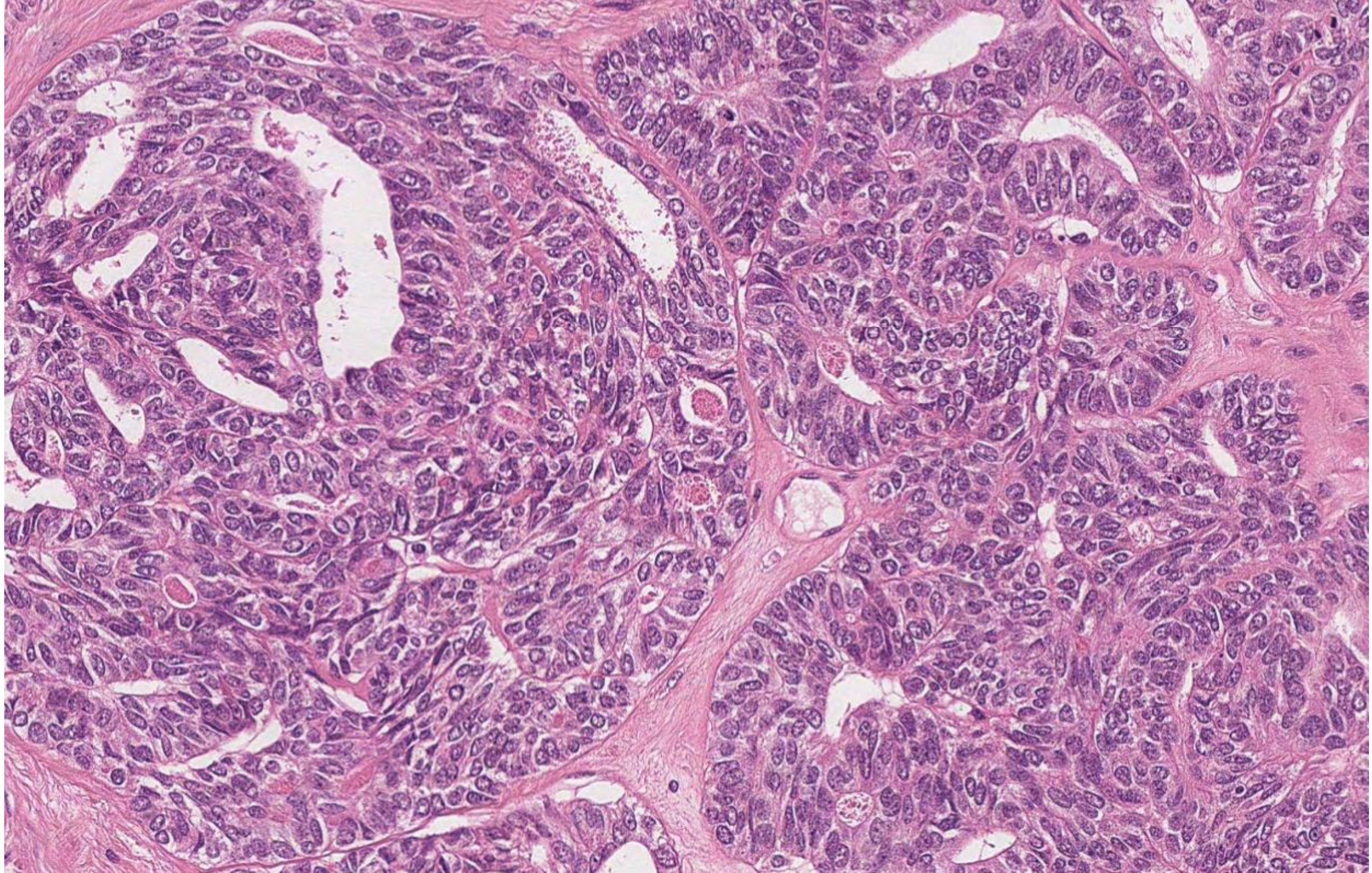

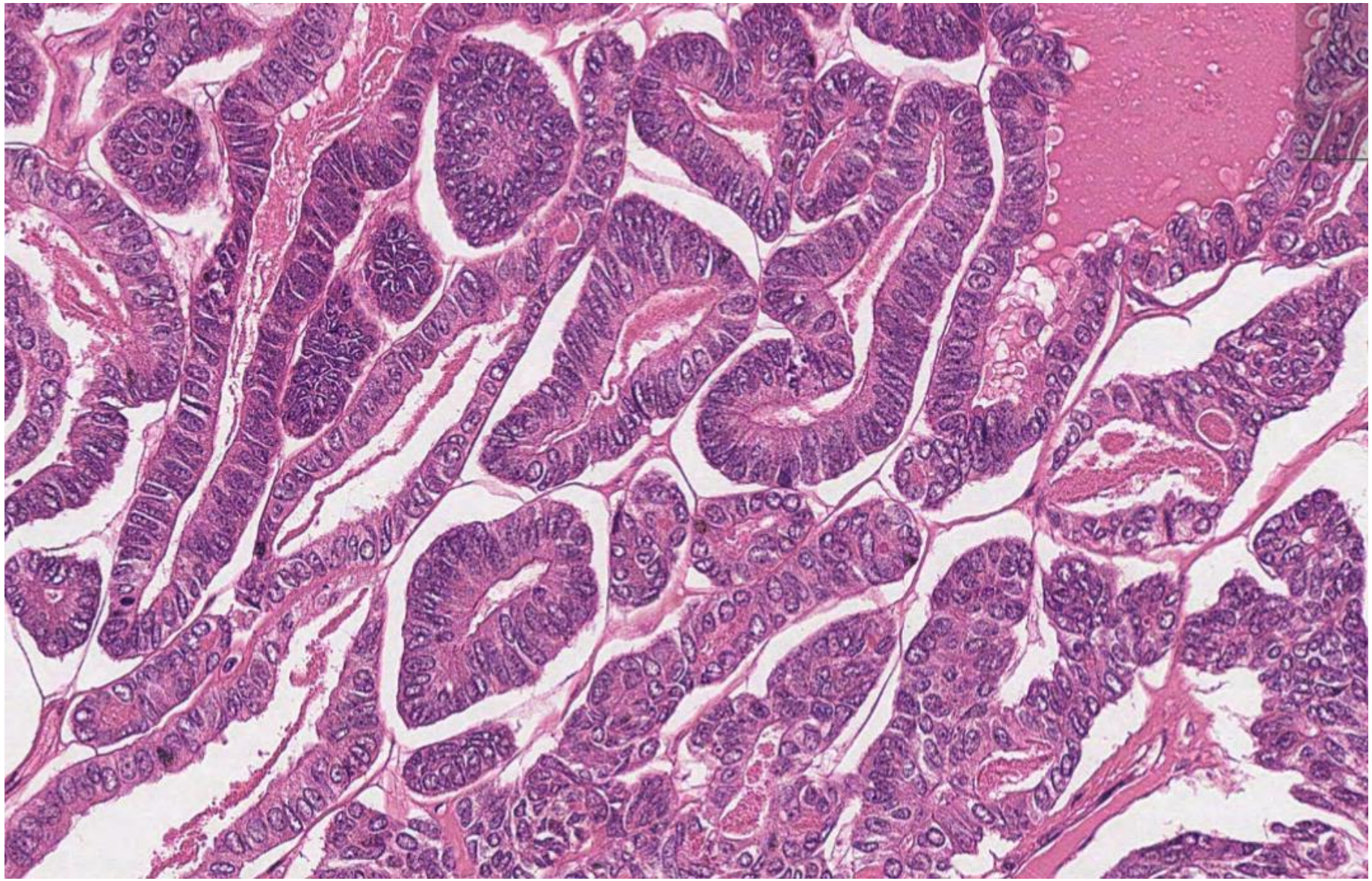

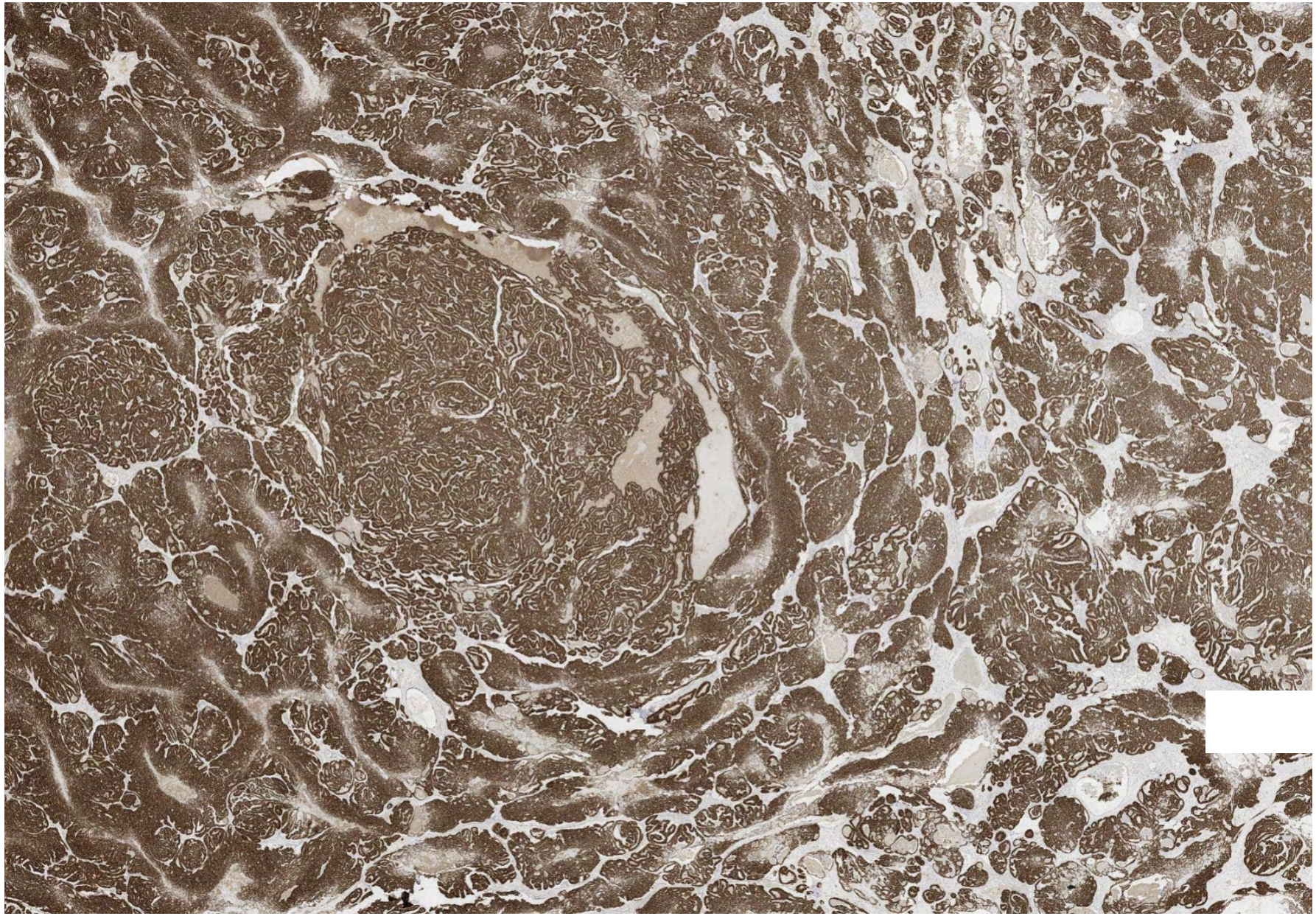

PAX 8

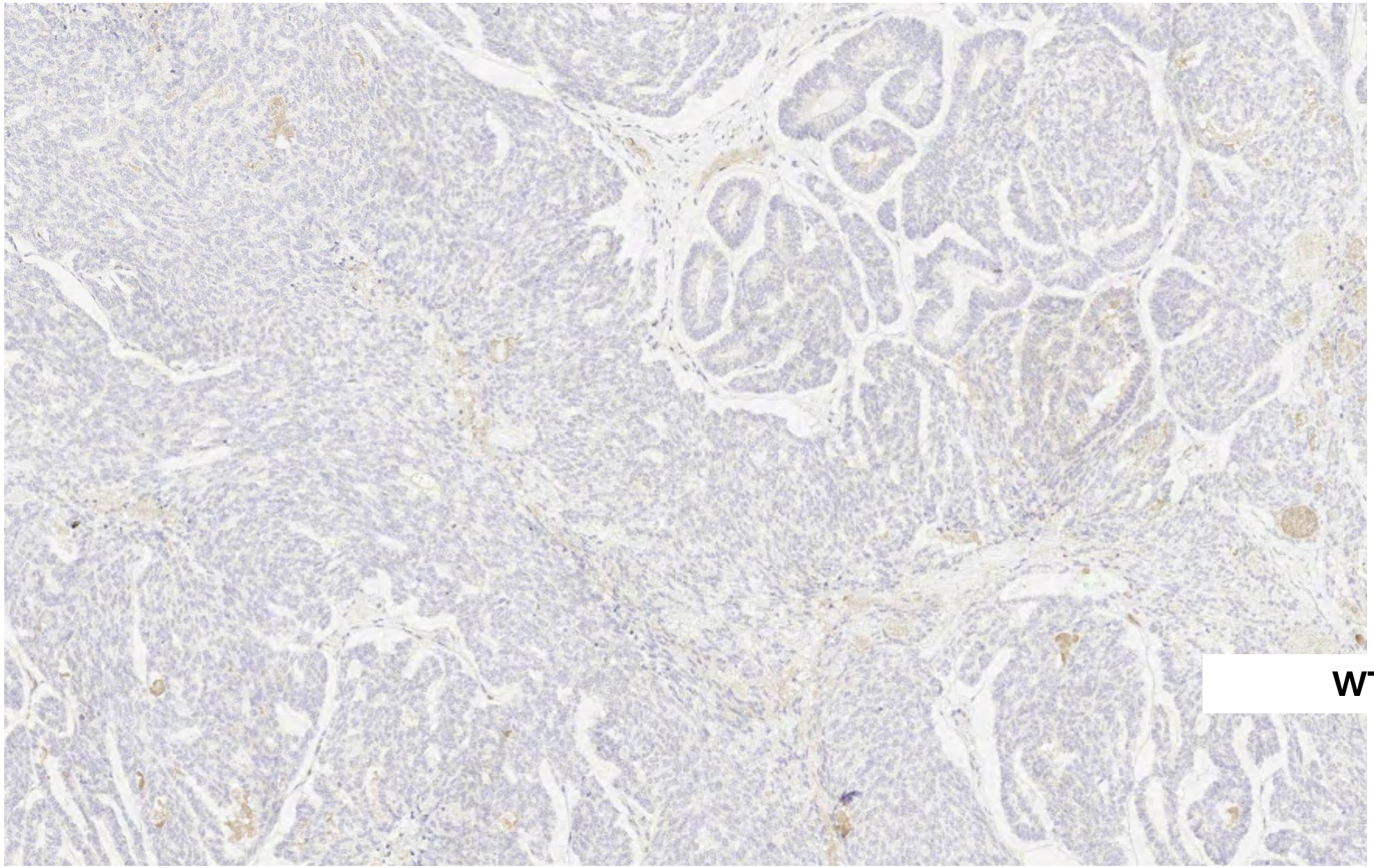

WT-1

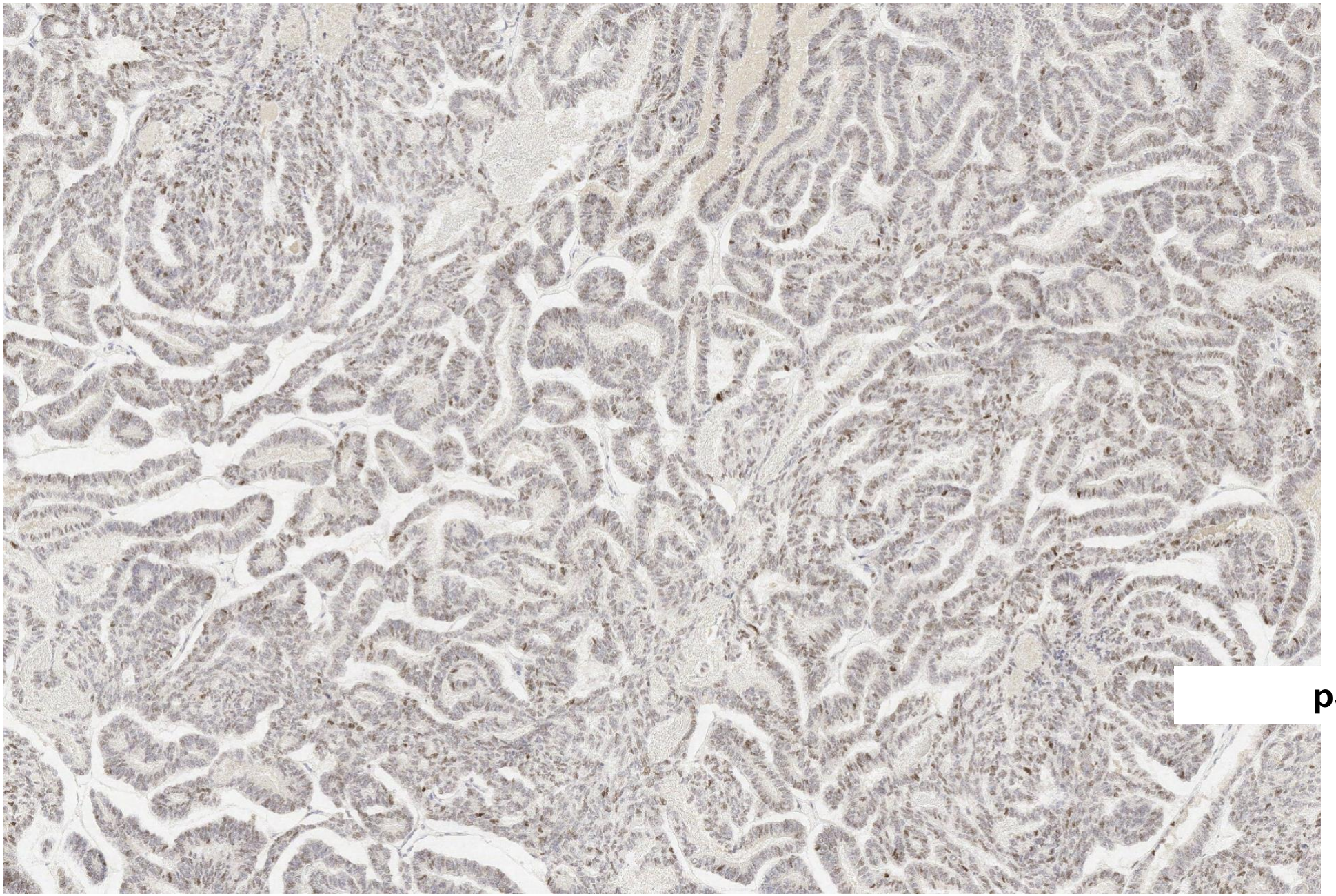

p53

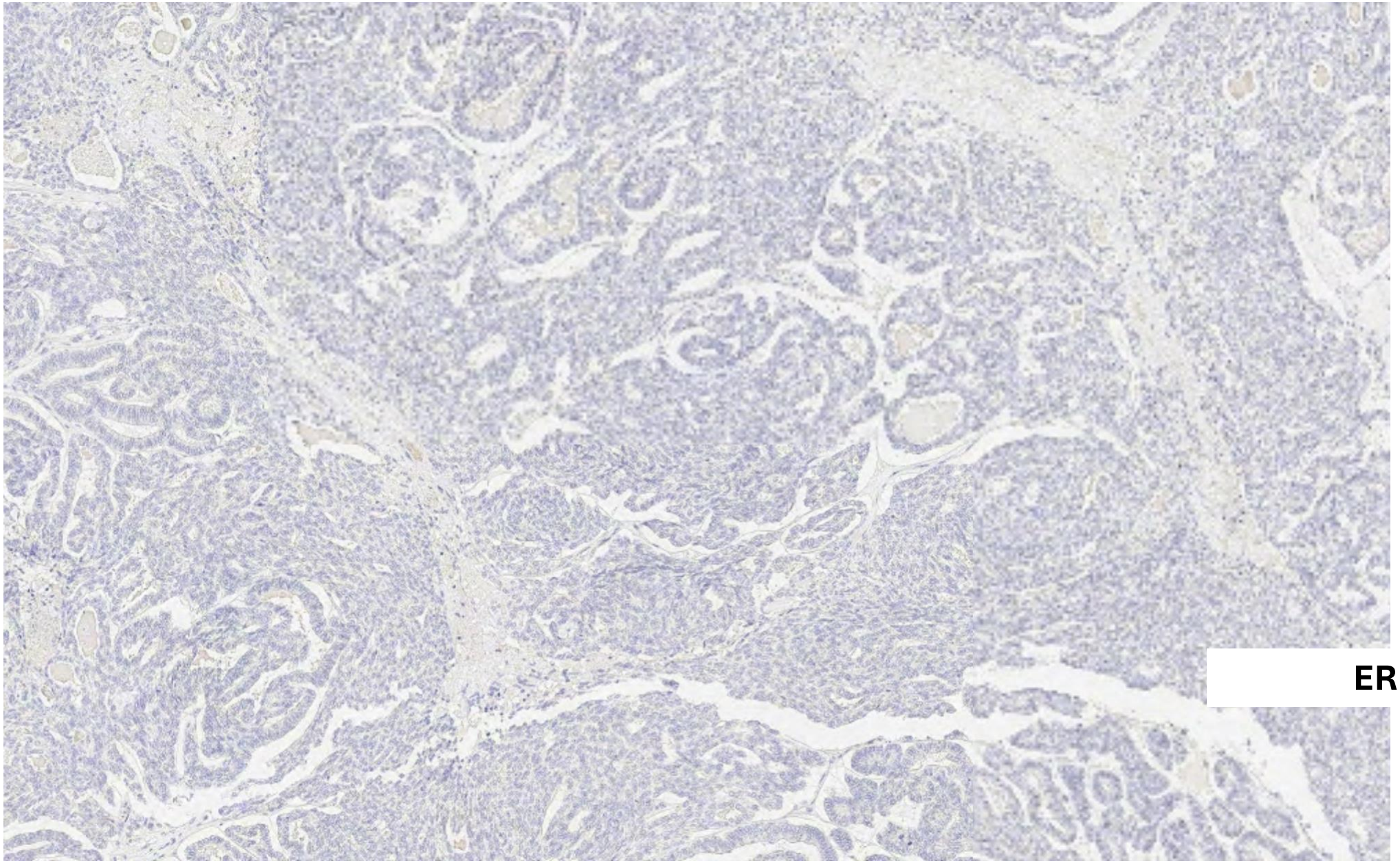
ER

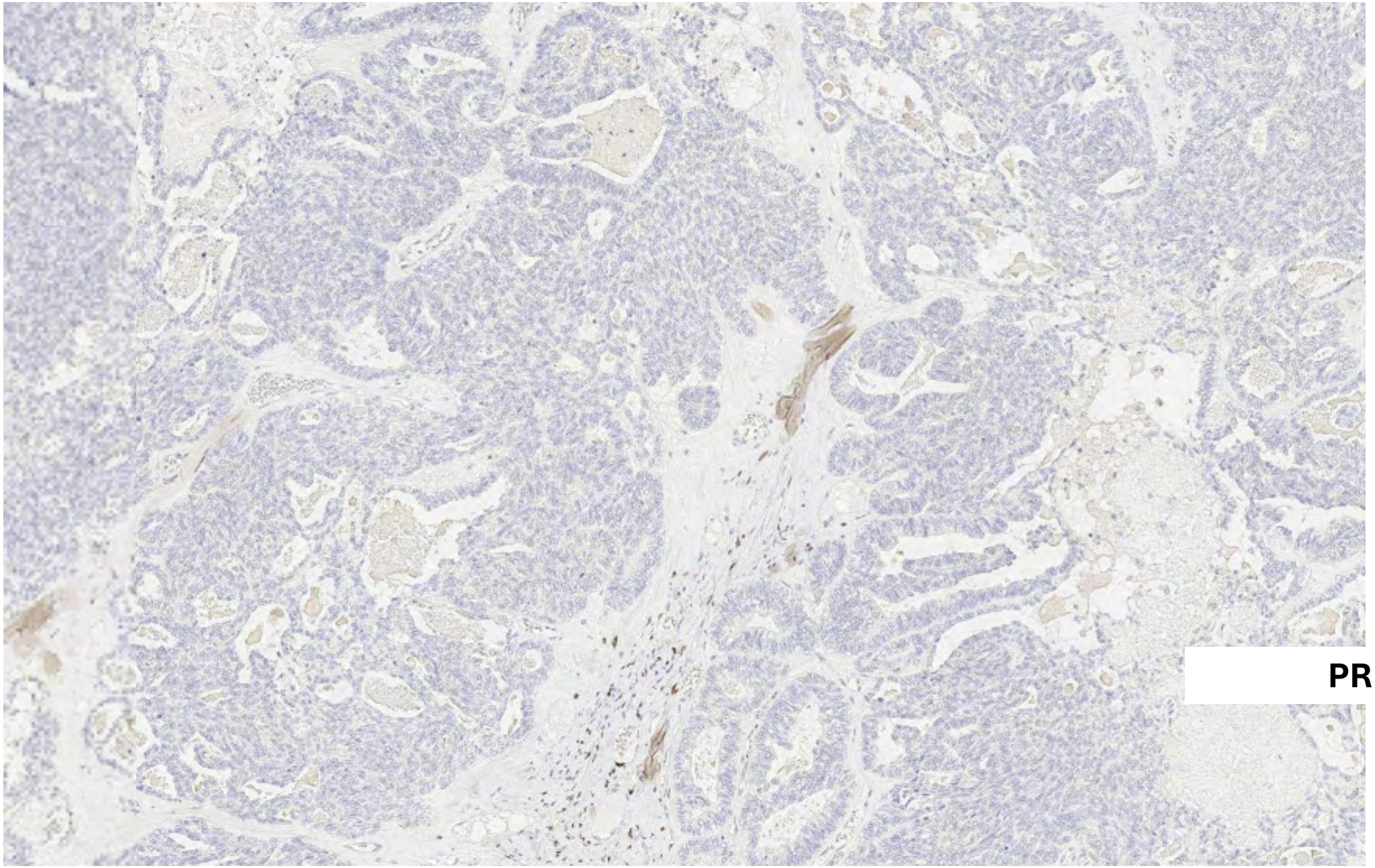
PR

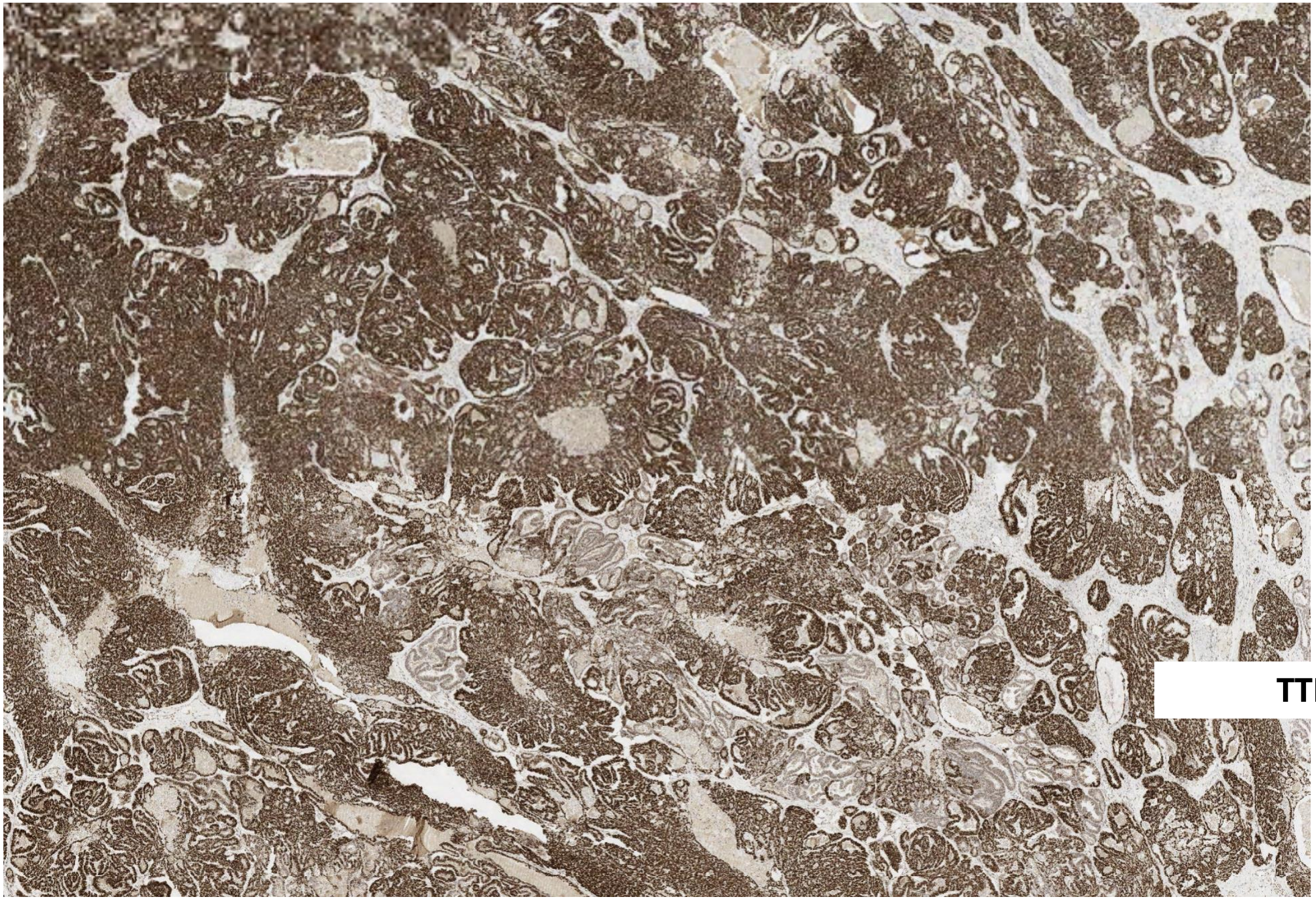

TTF-1

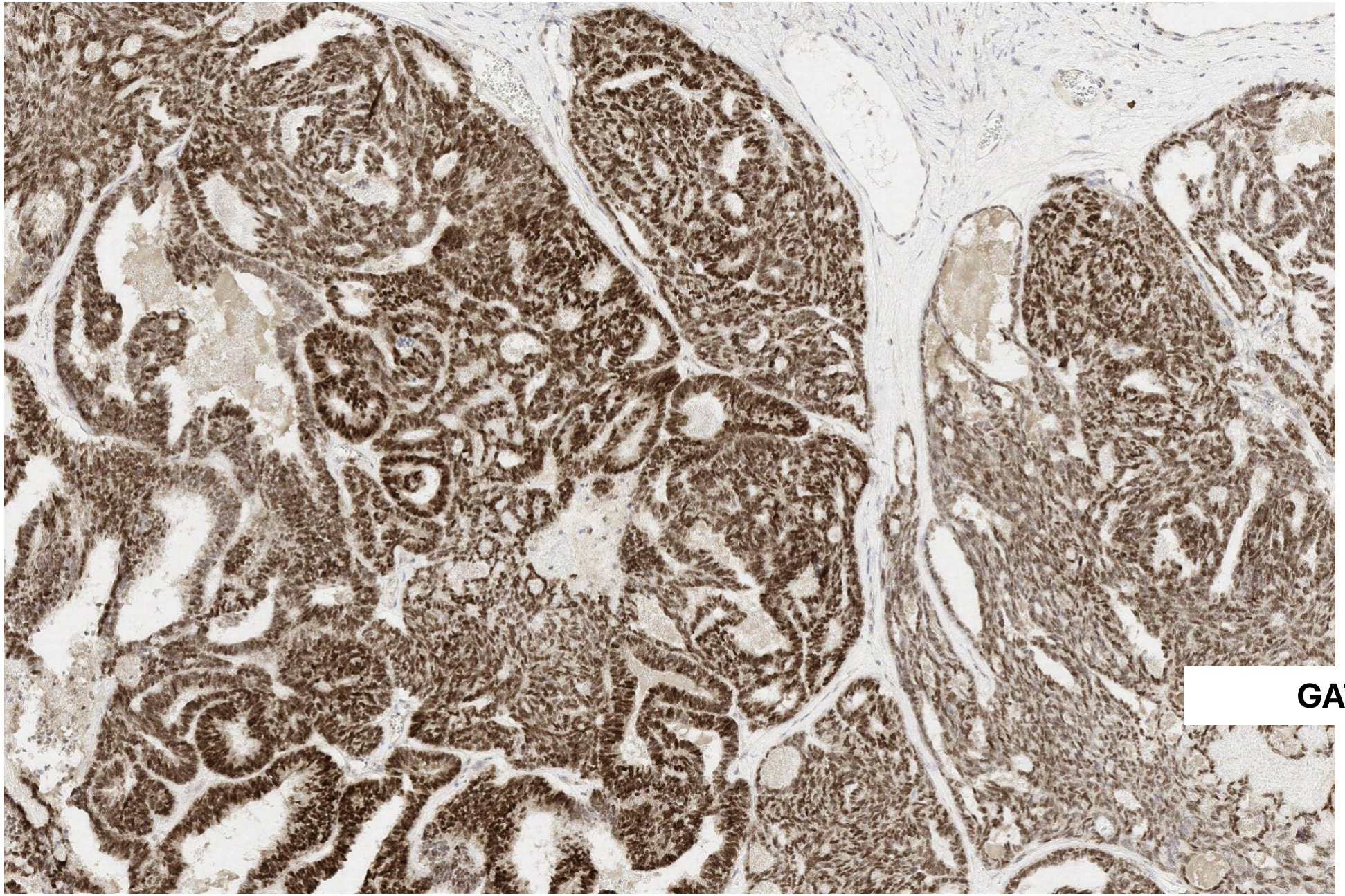

GATA 3

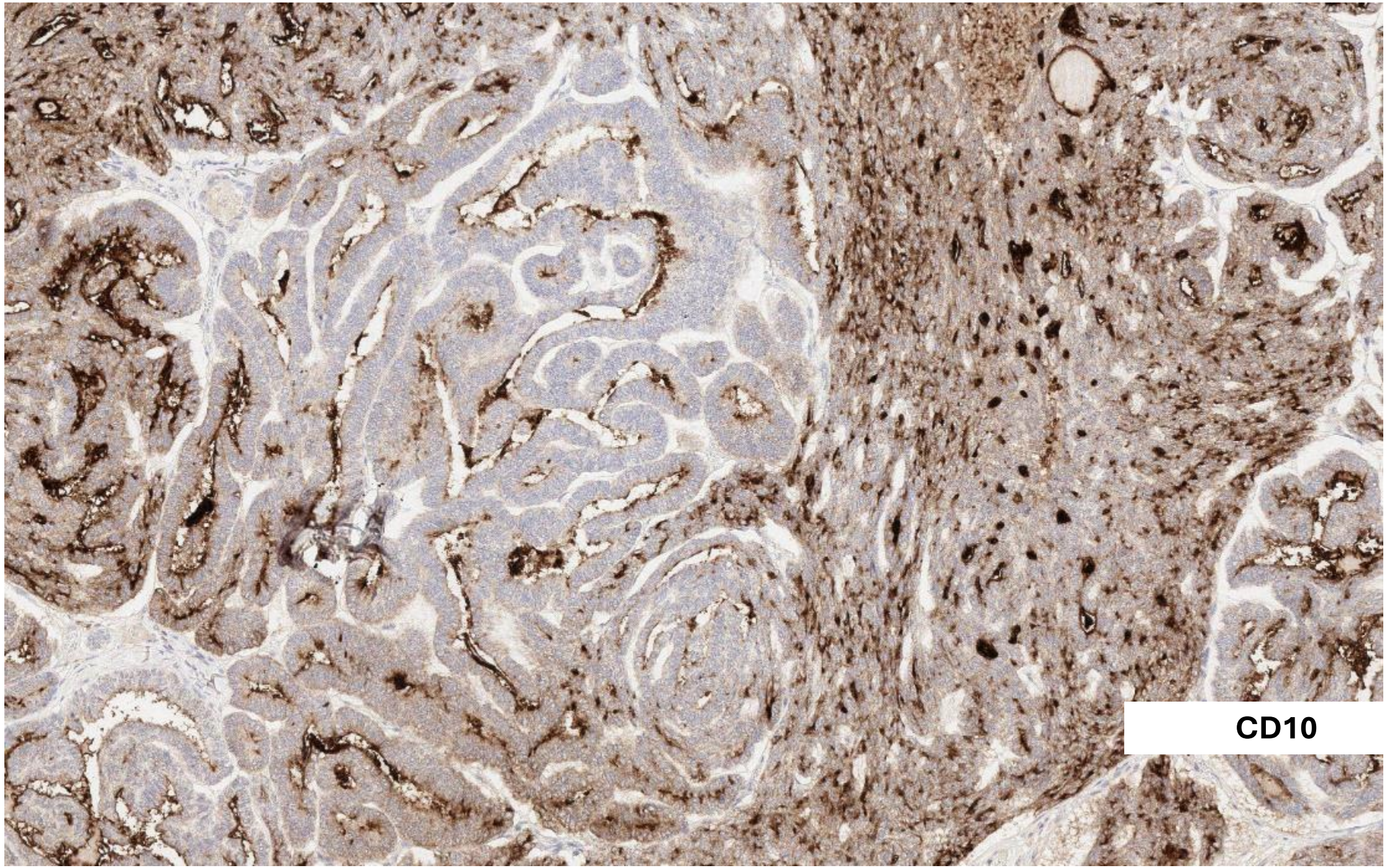
CD10

Microscopic features

- Architecture– angulated glands, tubules, papillary, solid
- Contain eosinophilic colloid-like material in the lumen
- Cuboidal to columnar epithelial cells, no significant nuclear pleomorphism

IHC profile

- p53wt, PAX 8 +, WT-1 neg, ER neg, PR neg
- GATA3, TTF-1, CD10 +

Mesonephric like adenocarcinoma of ovary

- Rare tumour, usually post-menopausal women, unilateral
- Can mimic low grade endometrioid
- Can be associated with endometriosis, cystadenoma, adenofibroma, low grade serous carcinoma
- Considered to have aggressive potential

Differentials:

- Low grade endometrioid: ER , PR +
- Low grade serous ca: WT 1 +
- High grade serous ca: WT 1 +, p53 mut
- Clear cell ca: Napsin A +
- Exclude mets from cervix, endometrium

LC 3: Mesonephric like adenocarcinoma of ovary

Mark	Features
1-7	Fails to diagnose
8-9	Fails to offer confident diagnosis, suboptimal /inaccurate description
10	Just adequate description with confident diagnosis but no additional information
11-14	Good micro and IHC description, comments on capsule status, association with endometriosis etc, aggressive nature, MMR testing/BRCA HRD
15-16	In addition, elucidates the work up of an ovarian carcinoma with tables/chart

Case 4

- Female 57 years

  Underwent TAH BSO for intramural nodule within myometrium

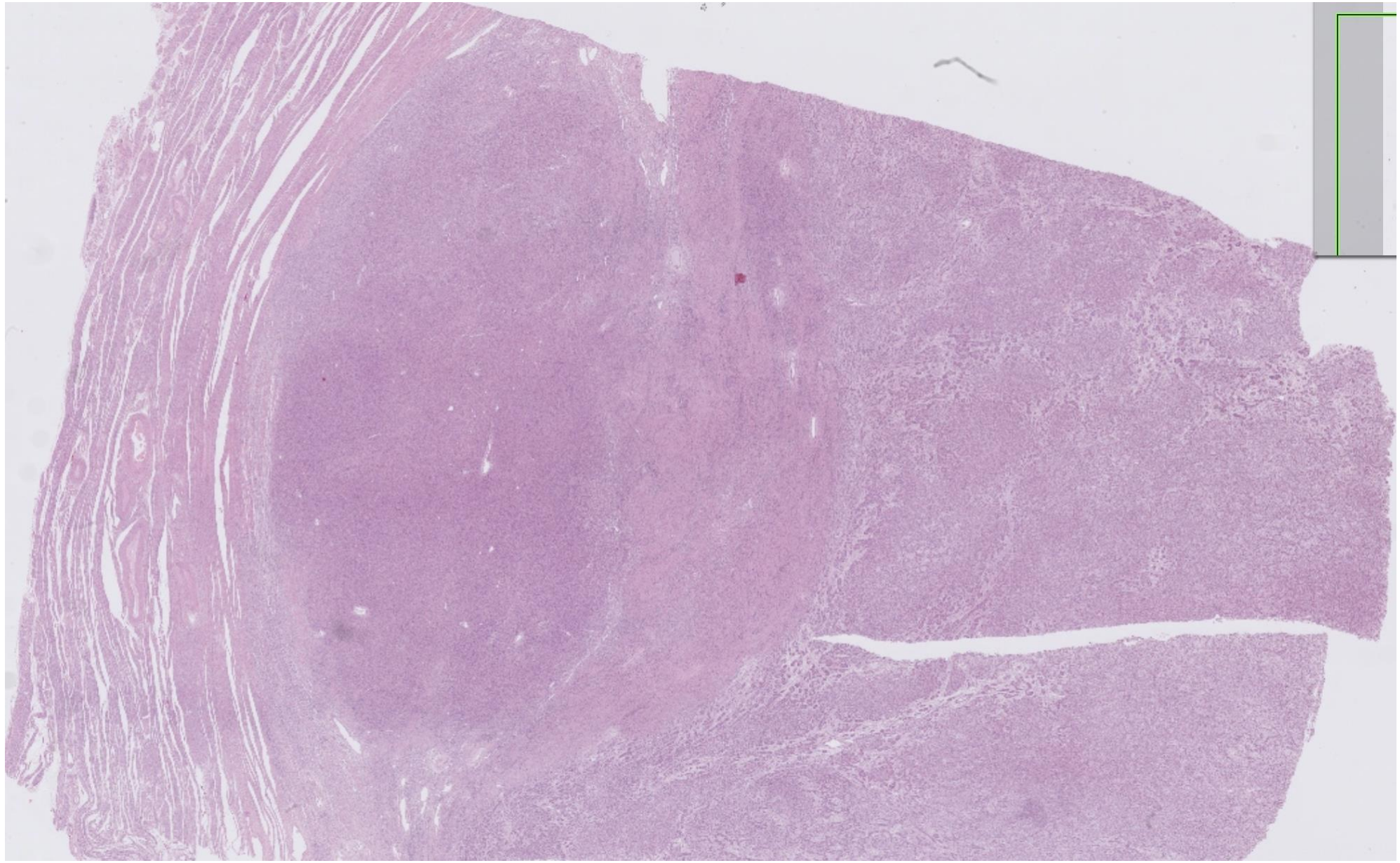

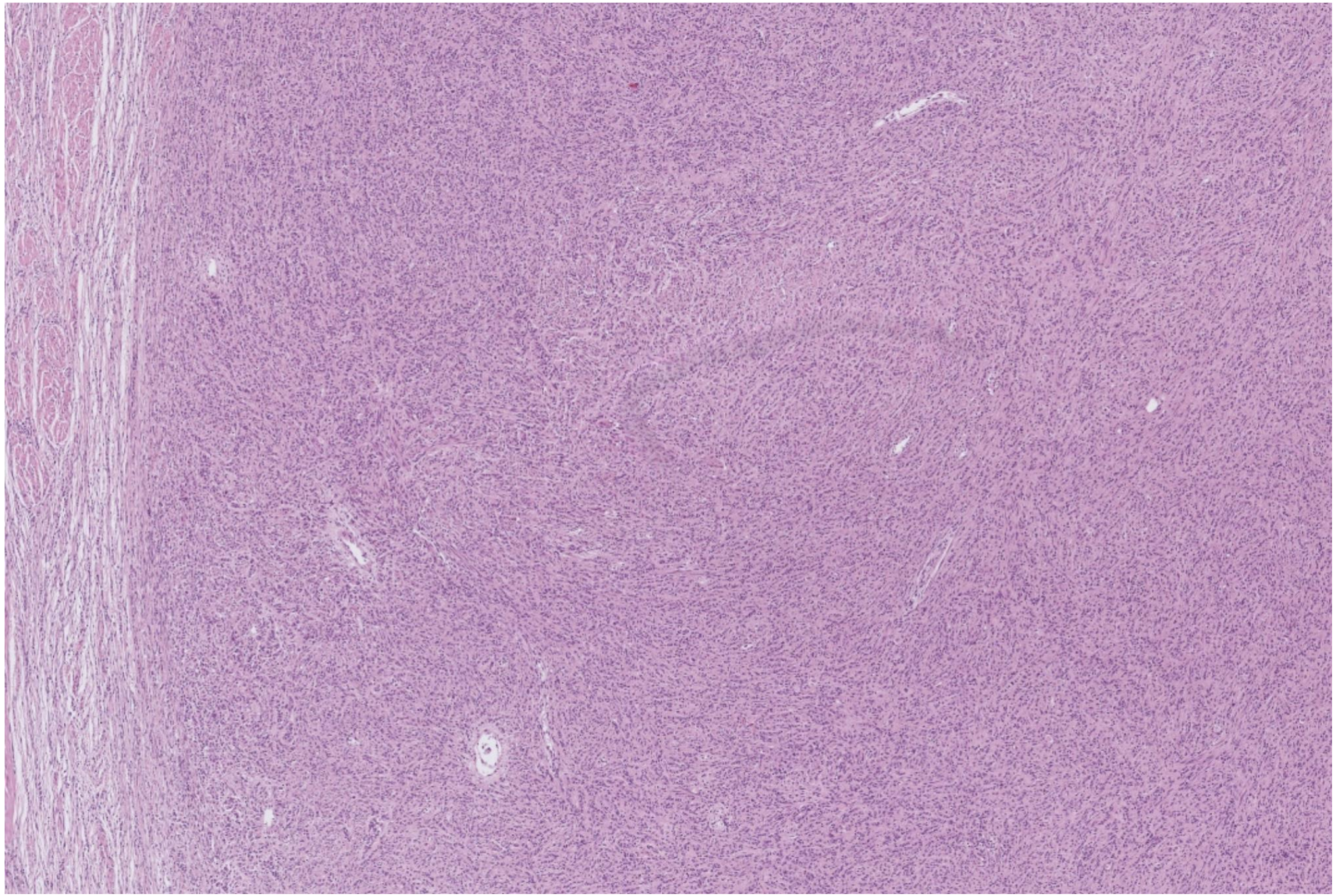

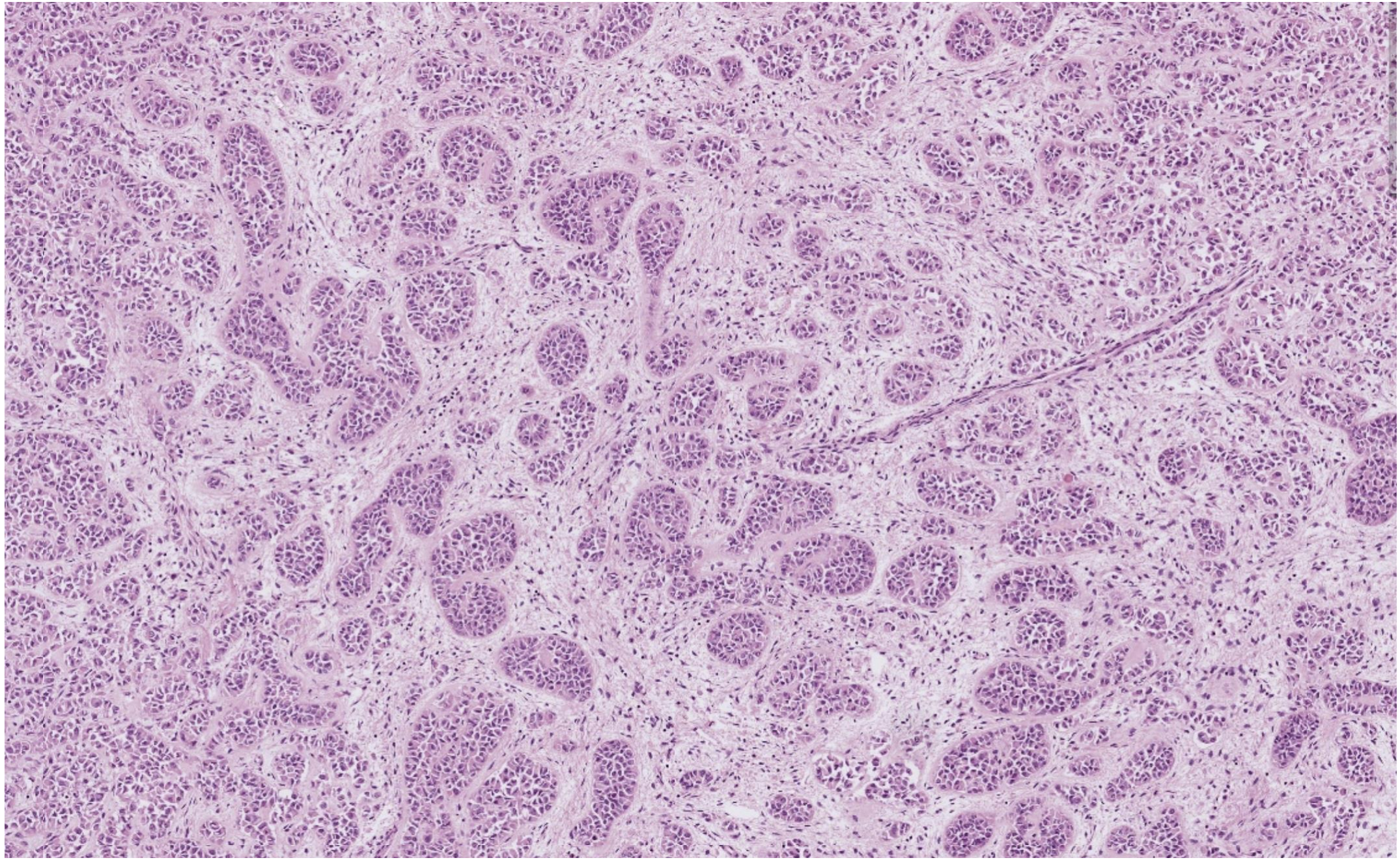

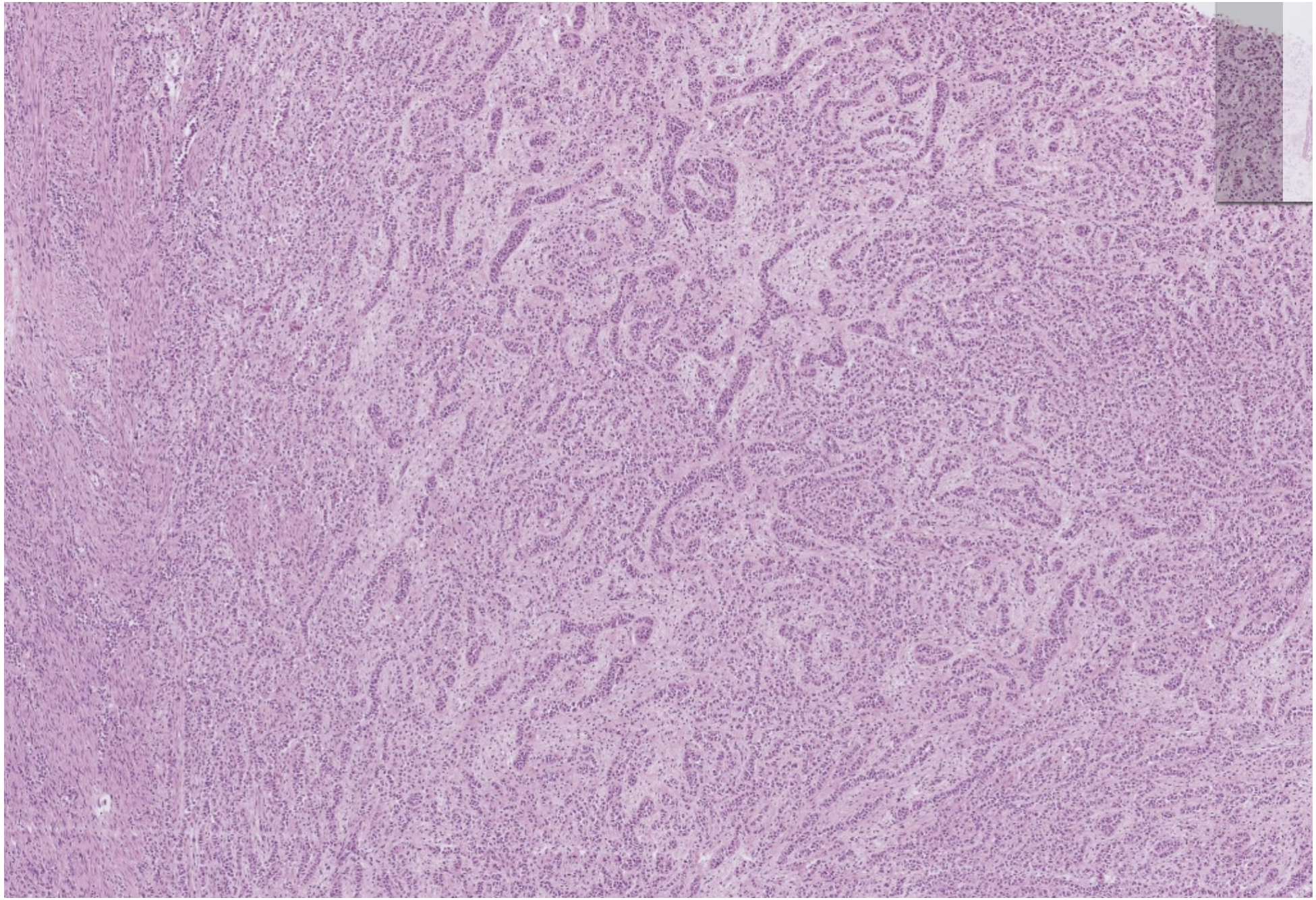

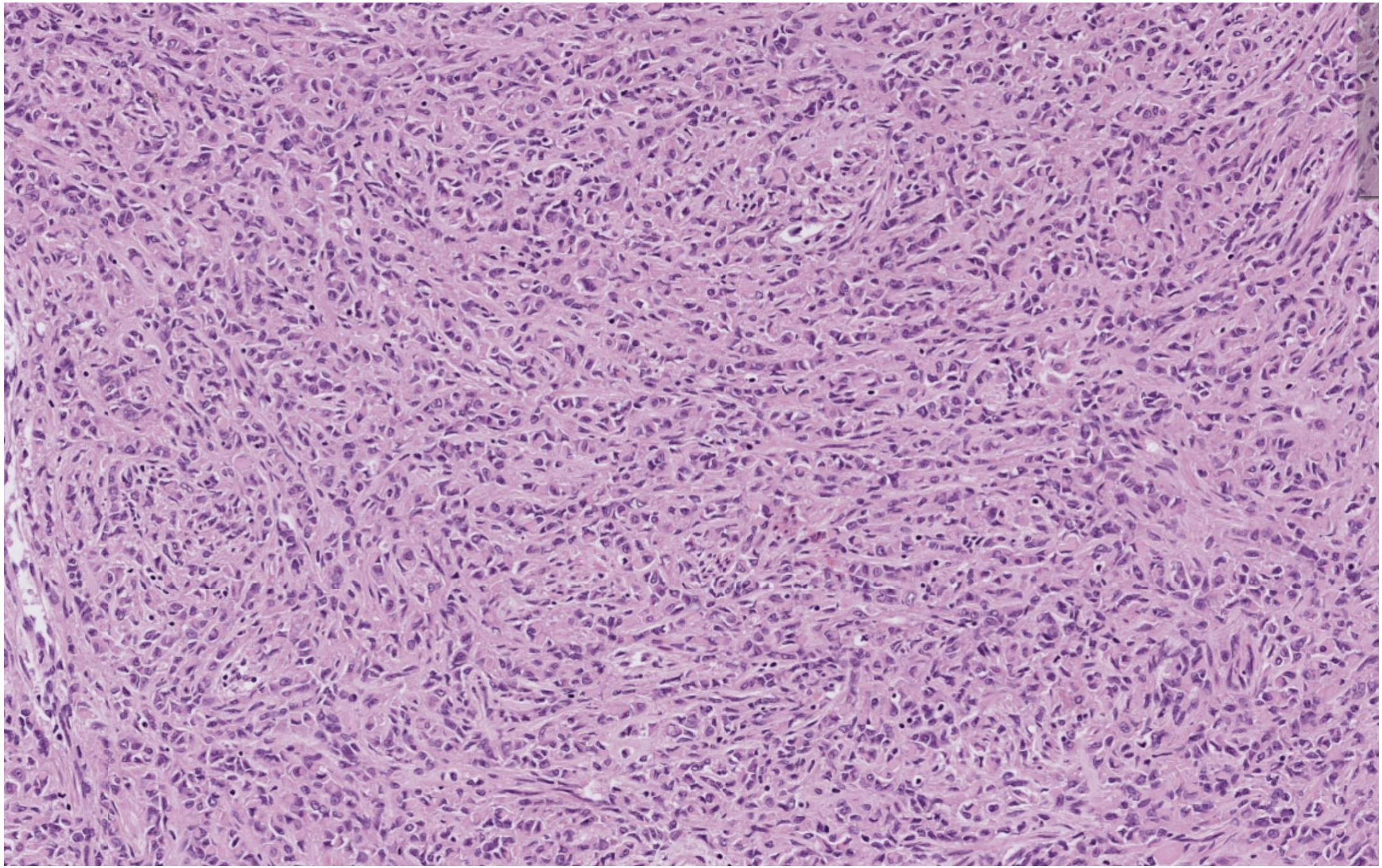

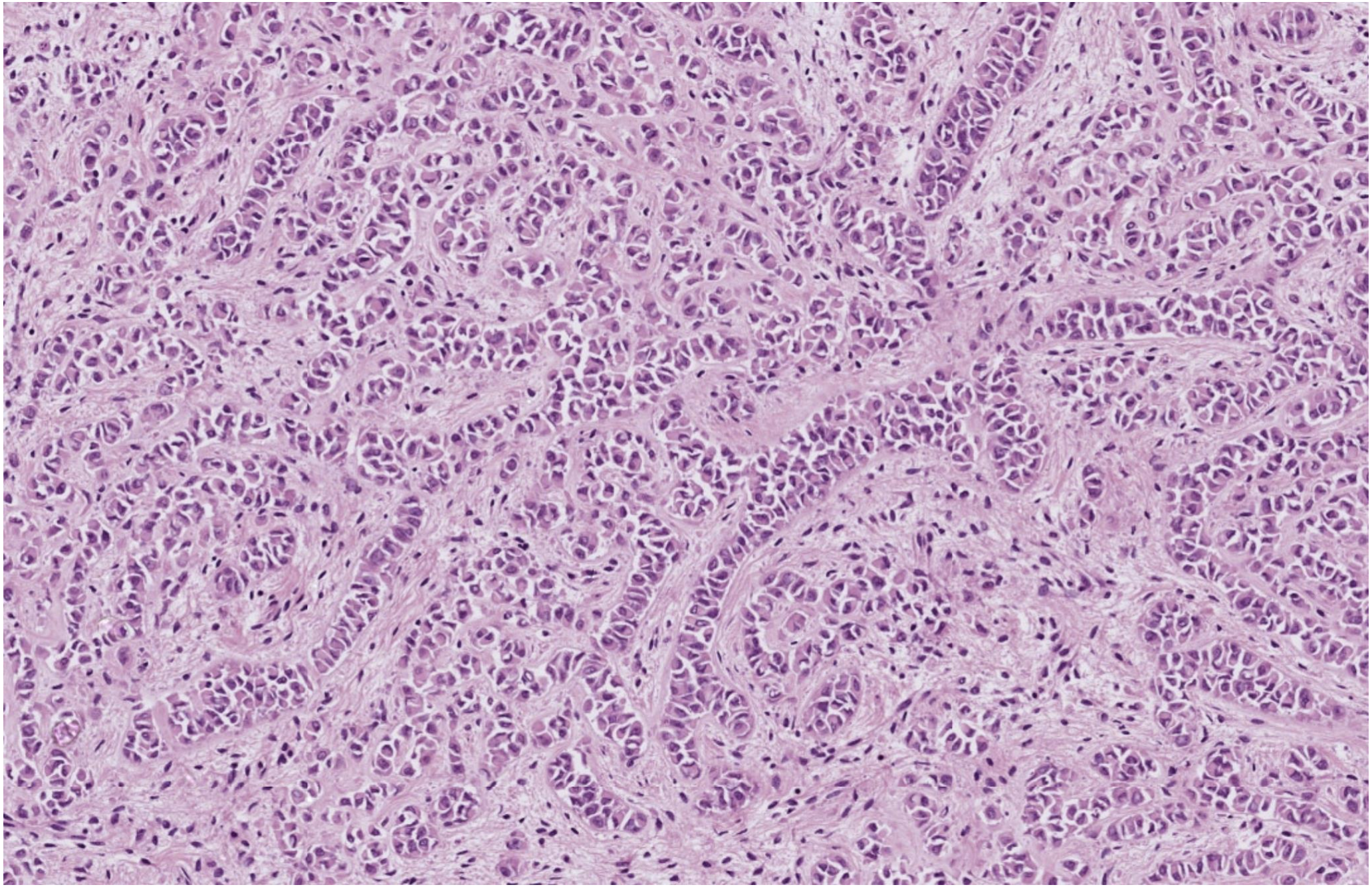

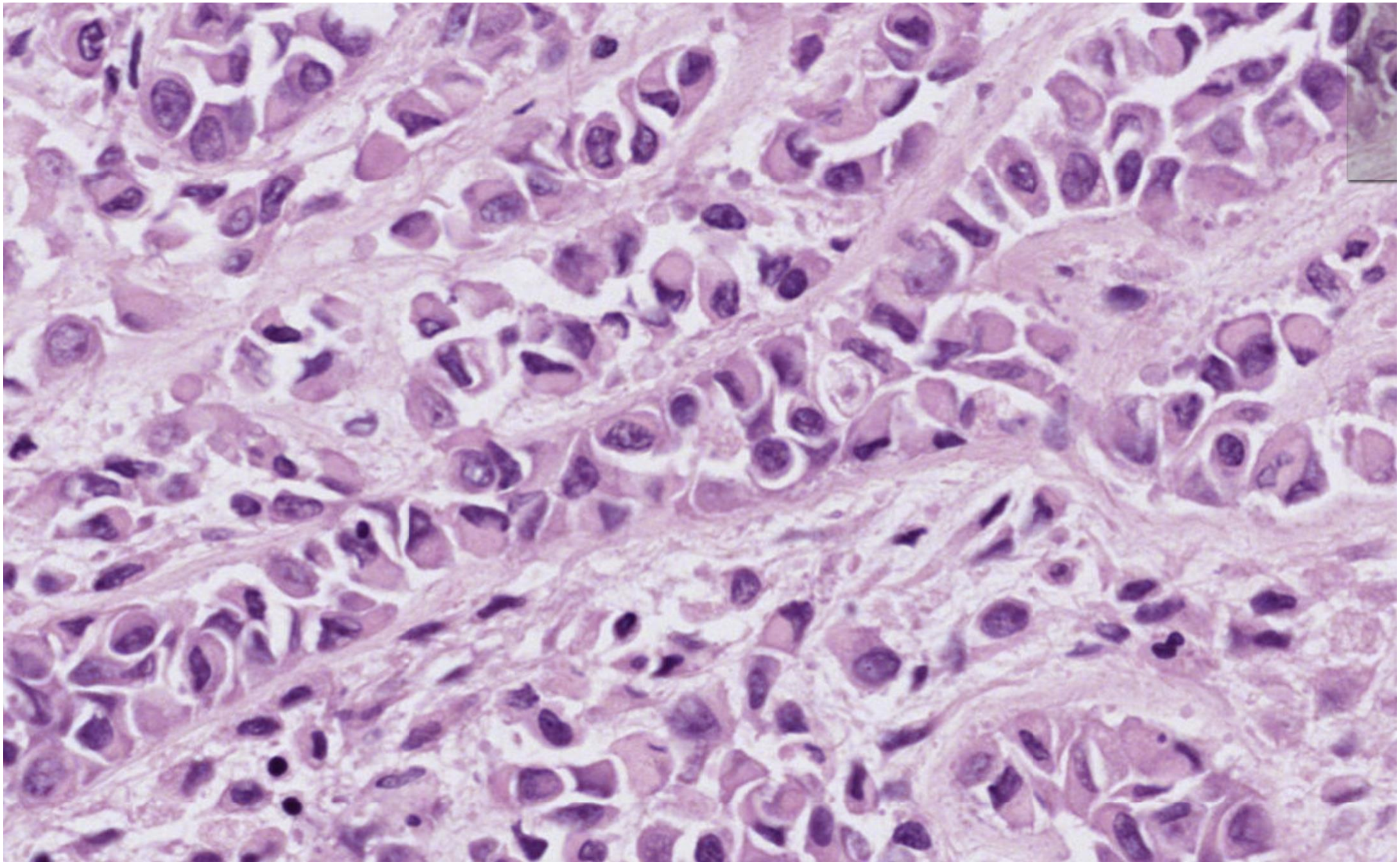

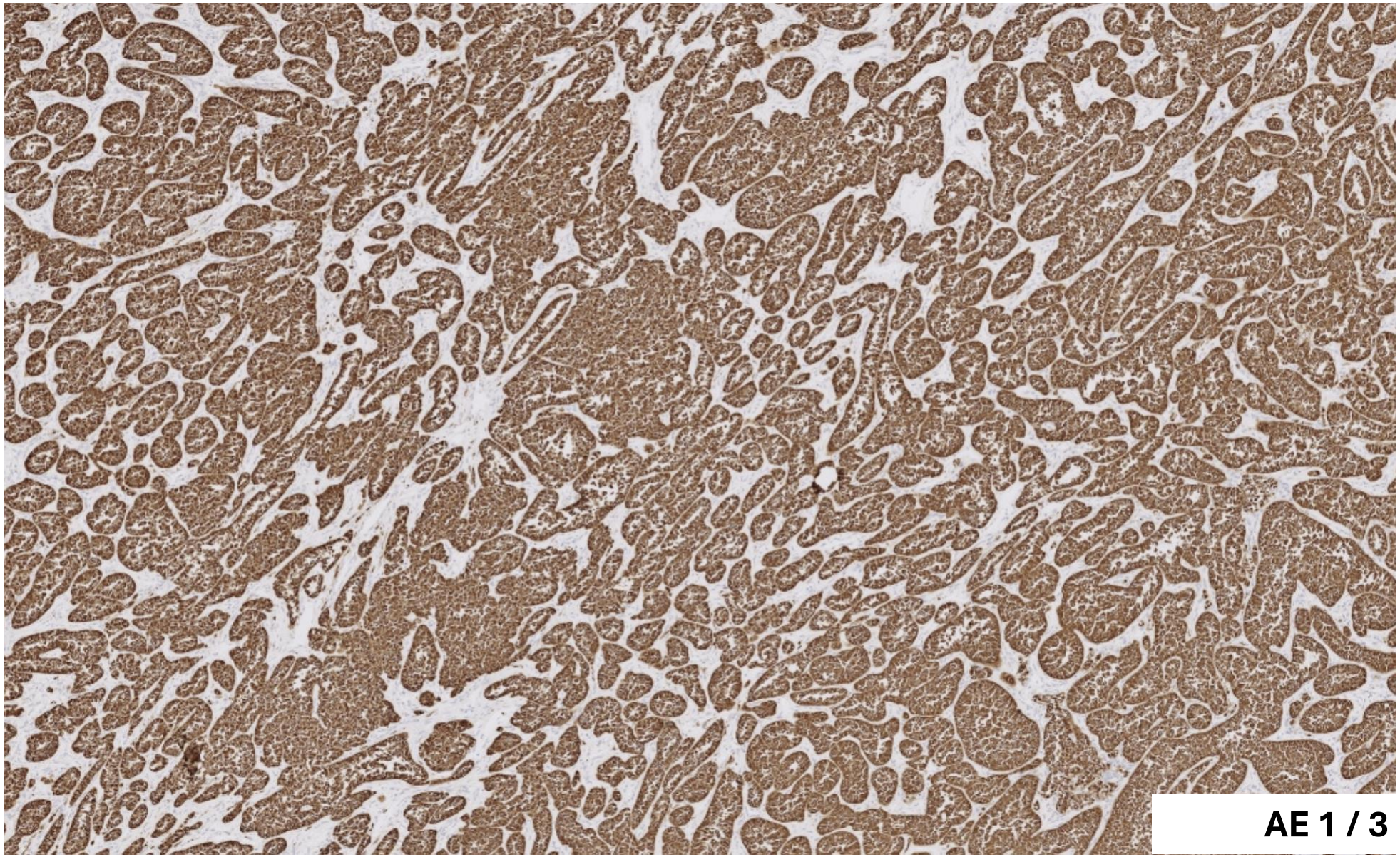
AE 1 / 3

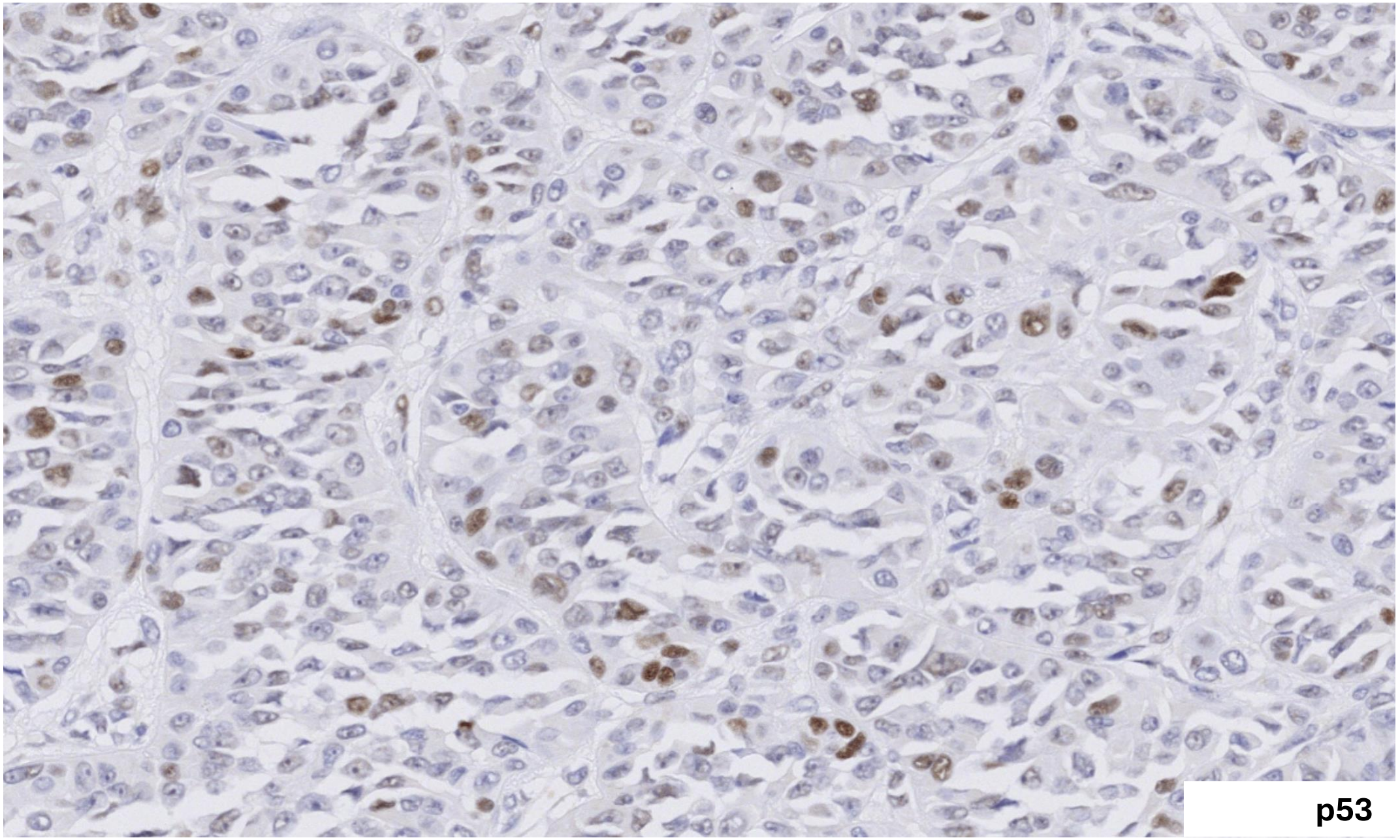
p53

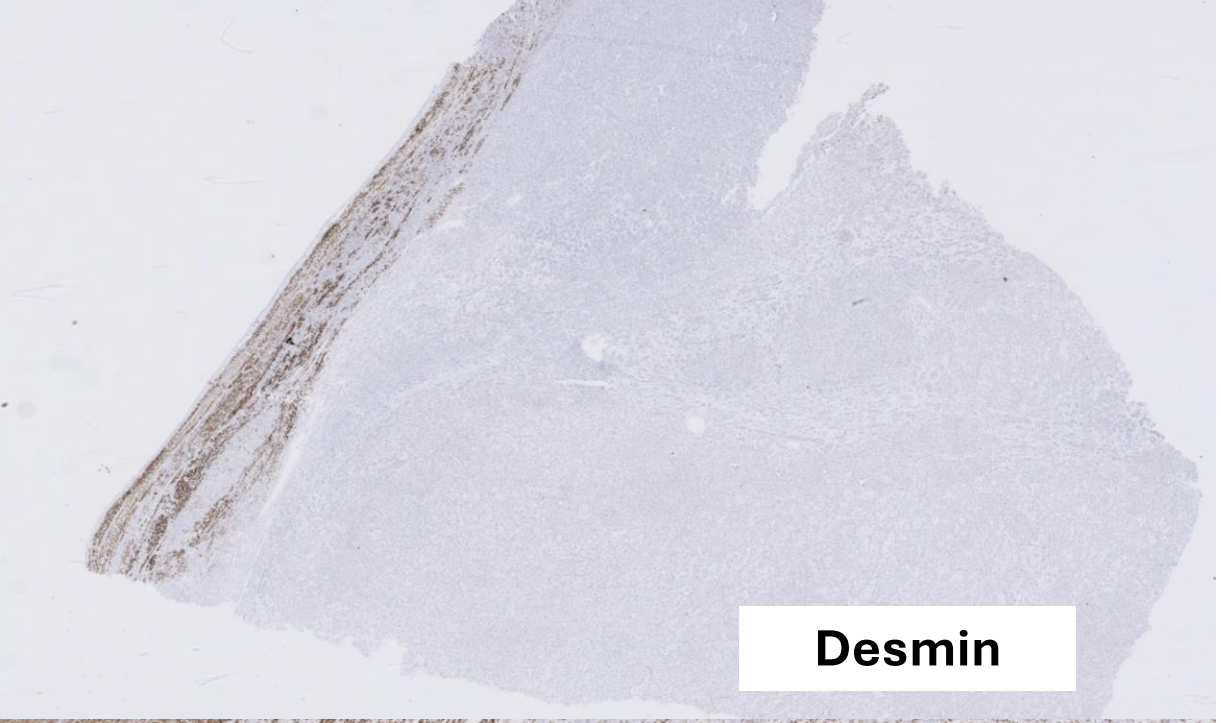
Desmin

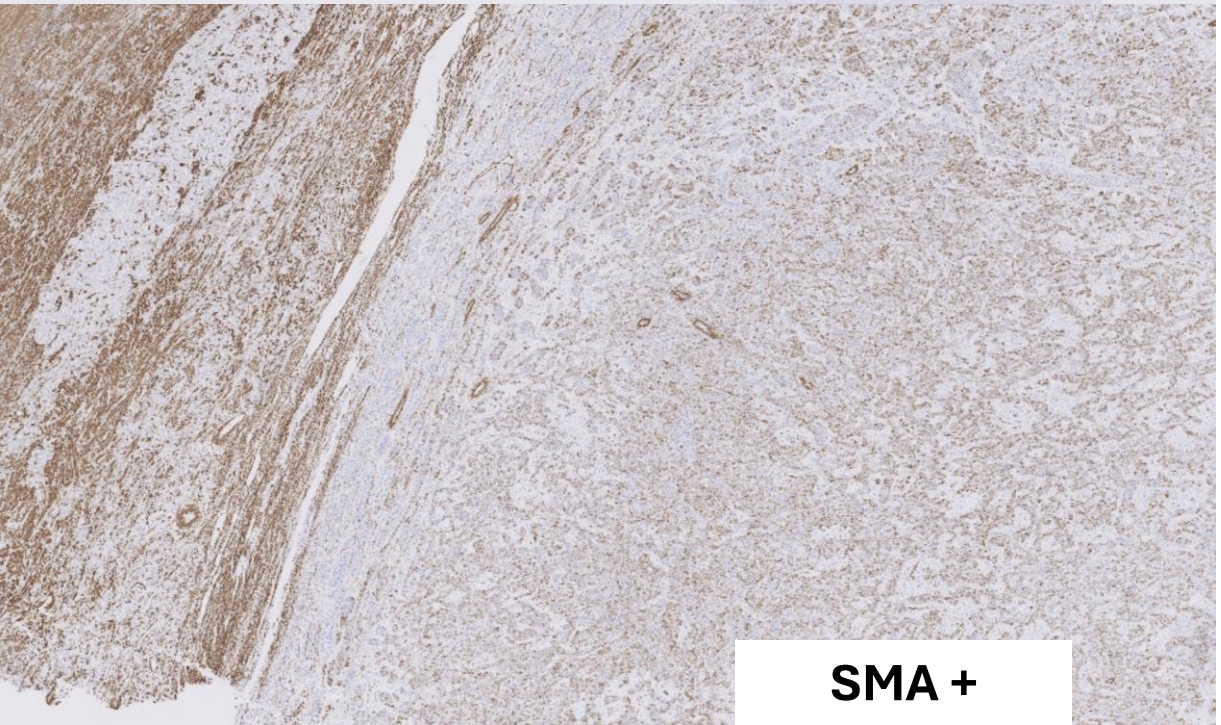
SMA +


Melan A

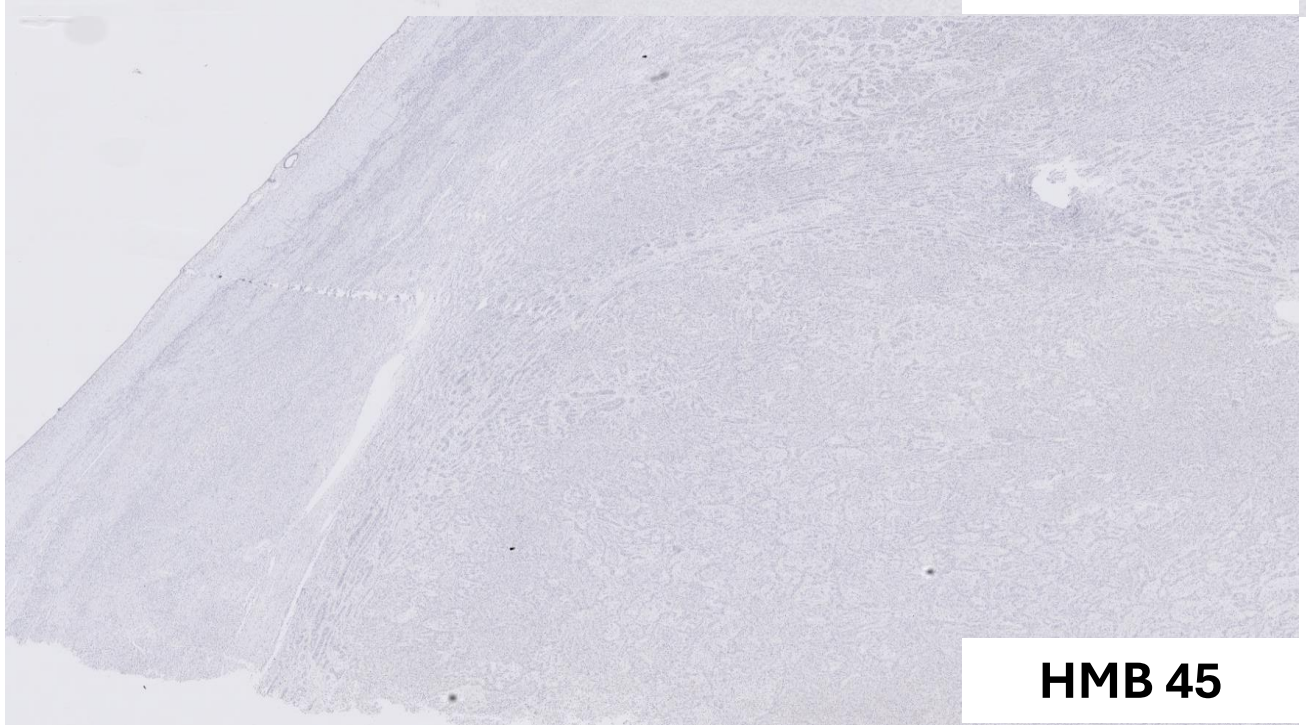
HMB 45

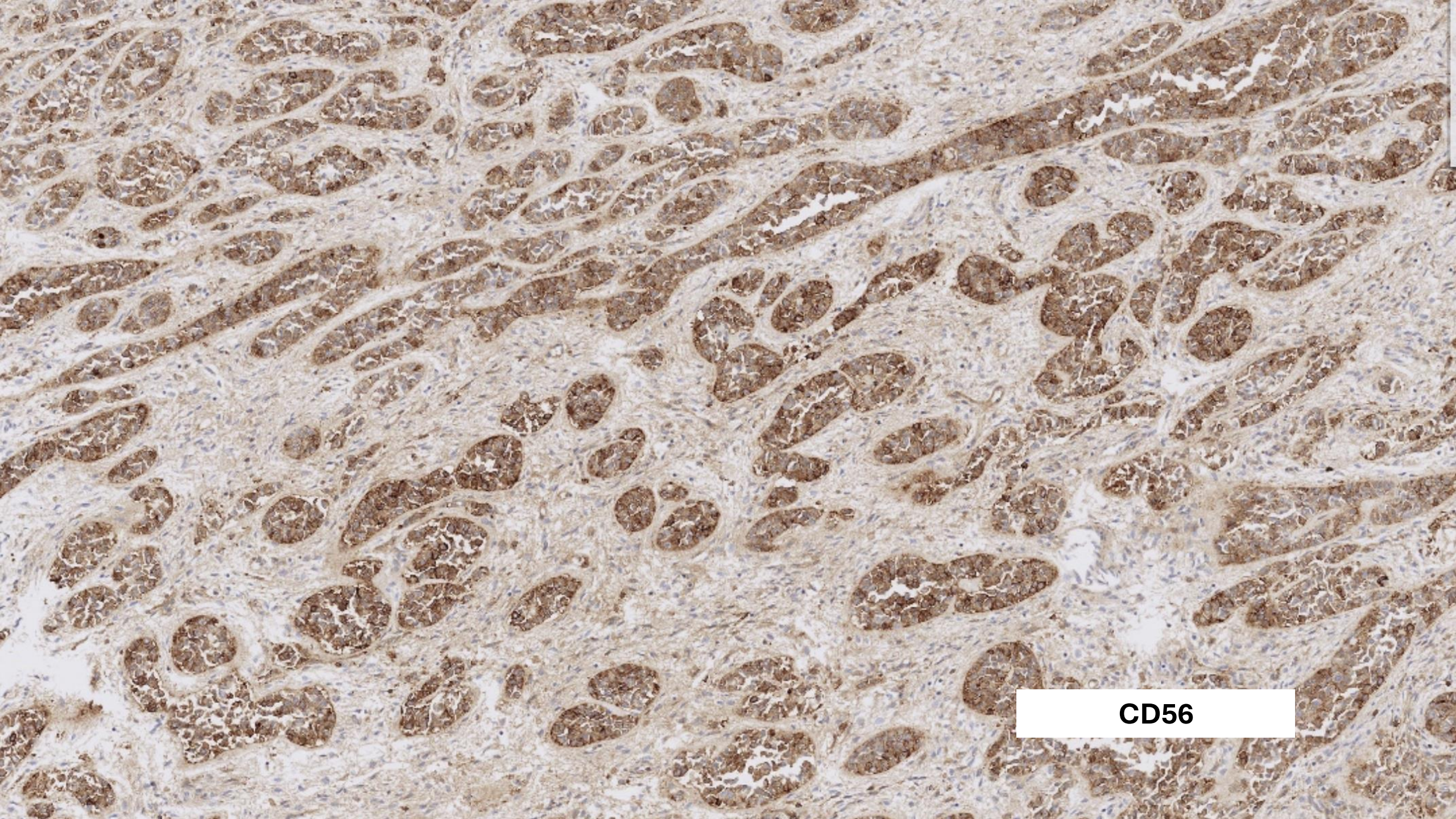
CD56

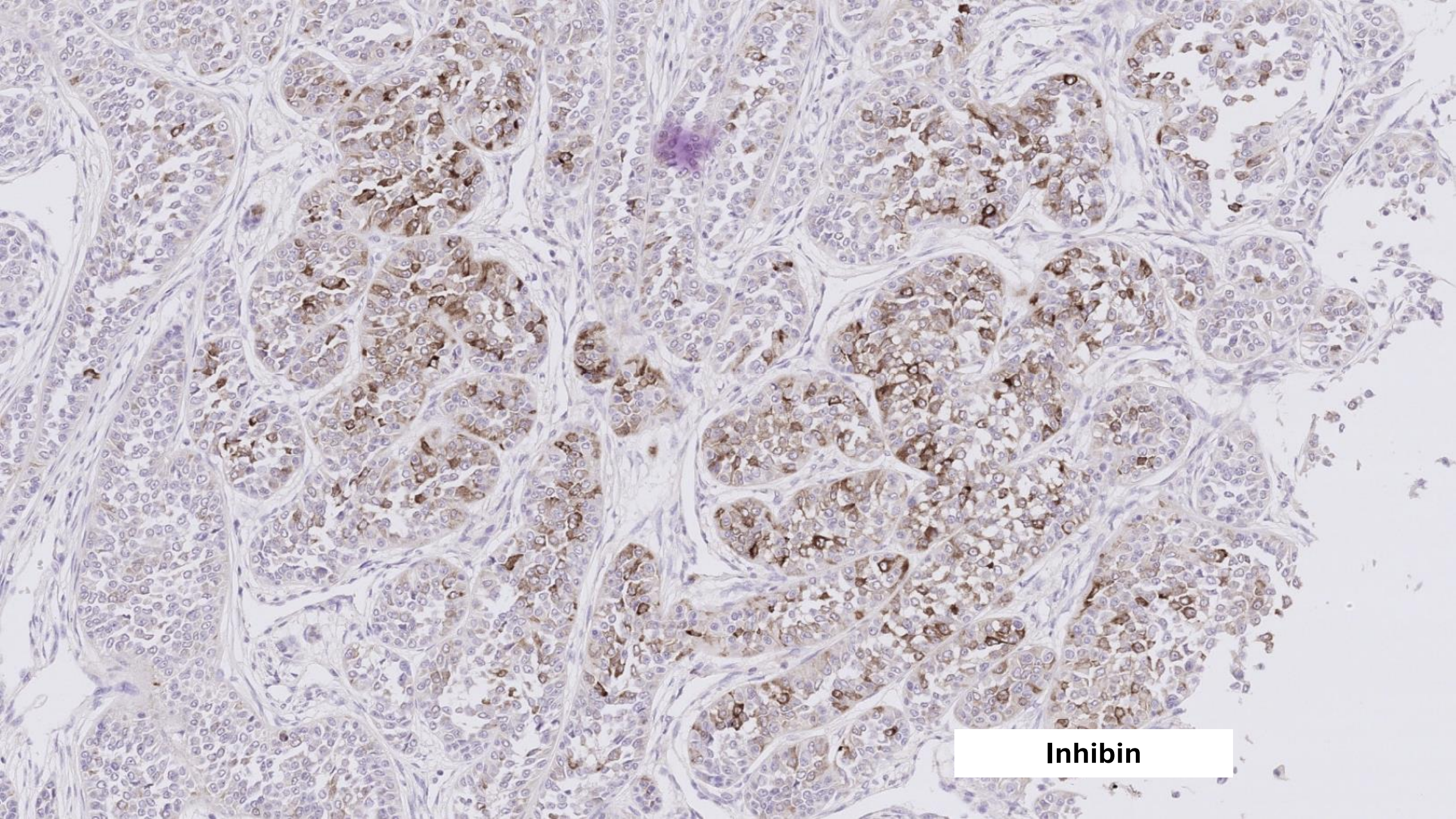
Inhibin

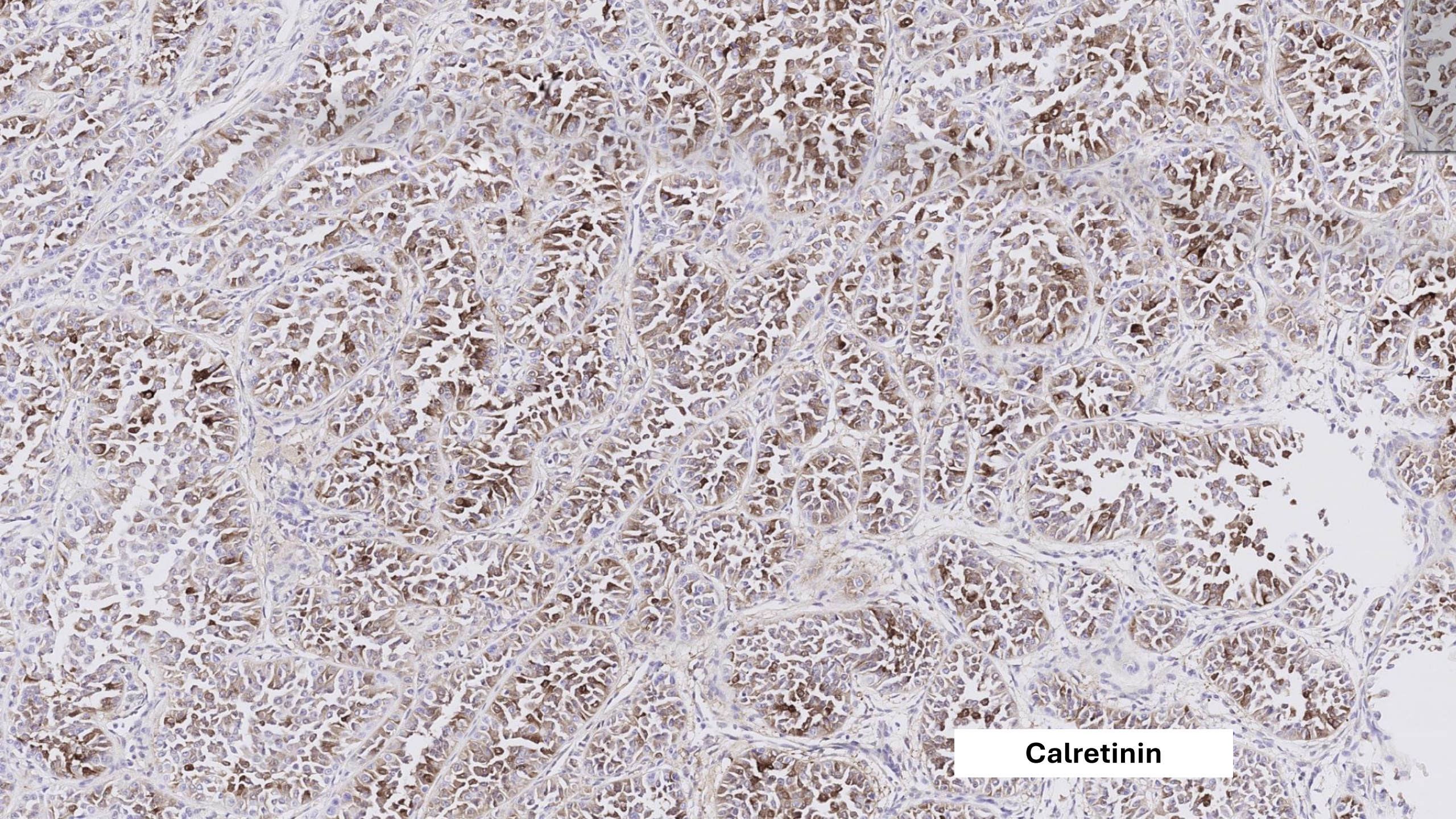
Calretinin

Microscopic features

- Lesion in myometrium
- Well circumscribed edge
- Sheets, nests, trabeculae, cords
- Epithelioid/rhabdoid appearance, moderate nuclear atypia, low mitotic activity
- No LVSI

IHC findings:

AE1/3 +, Calretinin + inhibin + CD56 + SMA+

Melan A, HMB45, desmin - negative

UTROSCT Uterine tumour resembling ovarian sex cord tumour

- Typically middle aged women, mean 50yrs
- Present with bleeding pain, can be incidental
- Uncertain histogenesis, varied architectural and morphological appearances
- Usually benign behaviour but can exhibit malignant behaviour and are considered neoplasms of uncertain malignant potential.
- In one study (PMID: 36306239) malignant tumors showed >3 of the following 5 features compared with benign tumors: size >5 cm, at least moderate cytologic atypia, ≥3 mitoses/10 HPF, infiltrative borders, and necrosis.
- Re arrangements involving GREB 1 or ESR 1

Differential:

- ESS with sex cord like areas: sample well, lack expression of sex cord markers, JAZF1-SUZ12 alteration
- Adenosarcoma with sex cord like areas: sample well, morphological features of adenosarcoma

LC 4: Uterine tumour resembling ovarian sex cord tumour

Mark	Features
1-7	Fails to diagnose
8-9	Fails to offer confident diagnosis, suboptimal /inaccurate description
10	Just adequate description with confident diagnosis but no additional information
11-14	Good micro and IHC description, comments on histological features to predict aggressive behaviour, importance of sampling
15-16	In addition, shows awareness of molecular events


Thank you