The British Association of Gynaecological Pathologists

bsccp | The British Society for Colposcopy and Cervical Pathology



Tanya Alan MRCPath
Consultant Gynaecological Histopathologist at University College London Hospital.
Lead histopathologist for the cervical screening service and CSPL (Cervical Screening Programme Lead) for UCLH.
Reporting gynae cytology at the Cervical Screening London laboratory (CSL).



Deirdre Lyons MRCOG MSc
President BSCCP
CSPL Imperial College Healthcare NHS Trust
Consultant Gynaecologist



Theresa Freeman-Wang FRCOG
President-Elect IFCPC
Joint CSPL Whittington NHS Trust
Consultant Gynaecologist

The British Association of Gynaecological Pathologists

bsccp | The British Society for Colposcopy and Cervical Pathology

Basic Cervical Histopathology Course

- Colposcopy MDT
- Drs Tanya Alan, Deirdre Lyons, Theresa Freeman-Wang
- 26/02/25

The British Association of Gynaecological Pathologists

bsccp | The British Society for Colposcopy and Cervical Pathology

Speaker disclosures

- ❑ Tanya Alan has no financial conflicts of interest to disclose
- ❑ Deirdre Lyons has been an invited speaker for Procare and MSD
- ❑ Theresa Freeman-Wang is a medical advisor for Procare

Purpose and MDT attendance

- The primary purpose of the meeting is to plan the management of patients with discordant histology, cytology and colposcopic findings.
- Part of quality assurance measures for the cervical screening programme
- All meetings must be attended by at least 1 colposcopist, and representatives to present and discuss the histology, HPV and cytology from the relevant laboratories.
- All colposcopists must attend at least half the meetings
- Lead cytopathologists and lead histopathologists should attend some of the meetings (>/=3)
- Admin support and trainees and students should attend
- Attendance at meetings must be recorded and attendance is in person or via video link
- Monthly meetings as a minimum are required (at least 12 per year)
- Lead colposcopist should act as the meeting chair
- Governance lies with the Cervical Screening Programme Lead (CSPL)
- If a case is to be discussed at MDT the patient should be informed as there may be a delay in the treatment

Histology and cytology

- All histopathology and cytology must be reviewed prior to the meeting and presented at the meeting by a consultant histopathologist or appropriately qualified consultant biomedical scientist who undertakes the reporting of histology and cytology specimens arising from the colposcopy service routinely.

- Histopathology and cytology reviews must be performed by a second individual different to the original reporter. If discordant results arise or potential bias is identified, a third opinion must be obtained.

Which cases to discuss

- Cases to be discussed must be documented in a clear local protocol. These may include (but are not limited to):
- All cases where high grade cytology including ?invasion has not been confirmed on colposcopy and or histology (2 grades difference)
- Borderline change in endocervical cells, with minor abnormalities or less on colposcopy and or histology
- Any case where colposcopists wish to ask for an ‘off protocol’ HPV subtype test
- All cases of invasive cervical cancer identified from the screening programme
- All cases of ?glandular neoplasia of endocervical type, CGIN/SMILE
- All conservatively managed CIN2 cases
- Further management of individuals who have had 2 previous treatments or that will be complex to treat or follow up or requires clarification
- Plus any other cases causing concern or for education (from colp, histo or cyto)

Outcome

- The outcome of MDT discussion (often treatment or further screening from colposcopy or GP at differing intervals) must be recorded in the patient notes and reported to the managing clinician in writing. Outcomes should be recorded on the cytology and colposcopy computer system or other systems allowing access to cytology/histology in the future.

- Note that the laboratory does not reissue cytology reports as a result of an MDT review.

- Regular audit of MDT case selection and outcomes is recommended. All cases of cervical cancer must be reviewed by a gynaecological cancer centre MDT.

- The outcome must also be communicated to the patient and their GP via a letter.

Scenario 1

- 40 year old P0+0, asymptomatic with cervical screen history as follows:
- 2021 – HPV positive and Low grade dyskaryosis
  - Colposcopy and biopsy
  - Biopsy CIN1
- Community screen at end of 2022 – HPV positive and cytology negative
- 2024 – HPV positive and Low grade dyskaryosis

Scenario 1 cytology

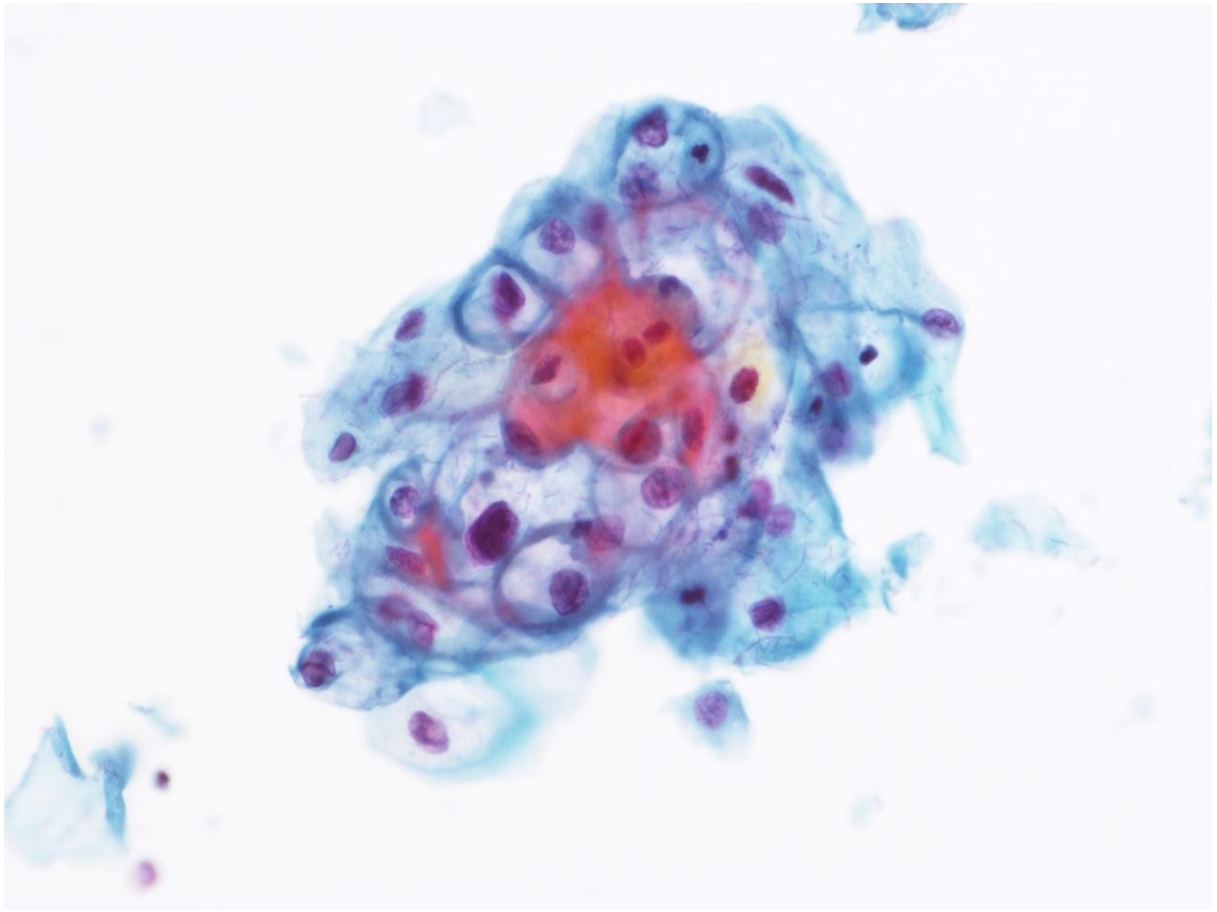

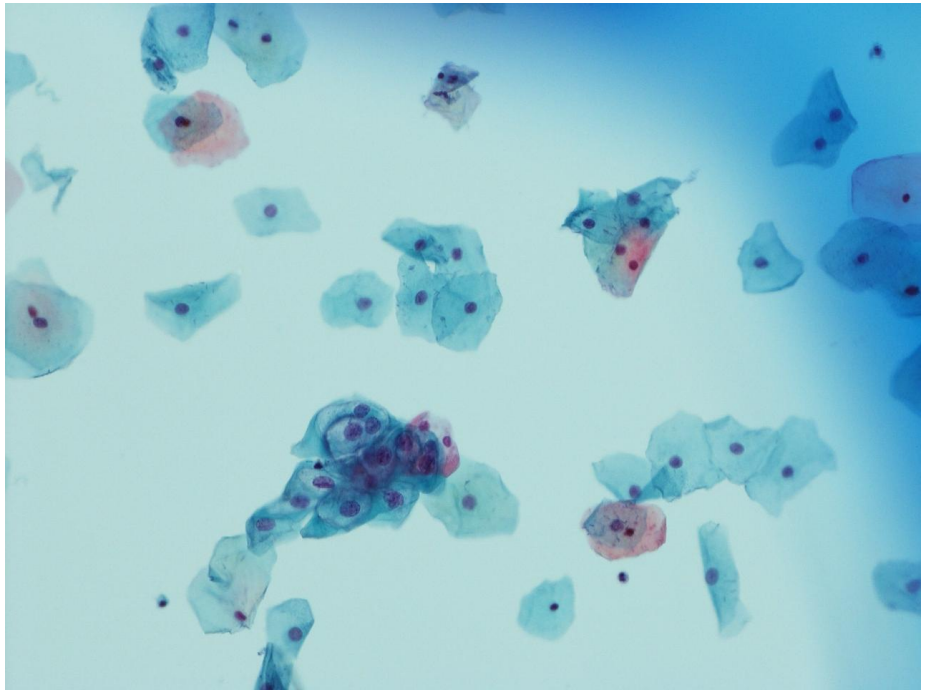

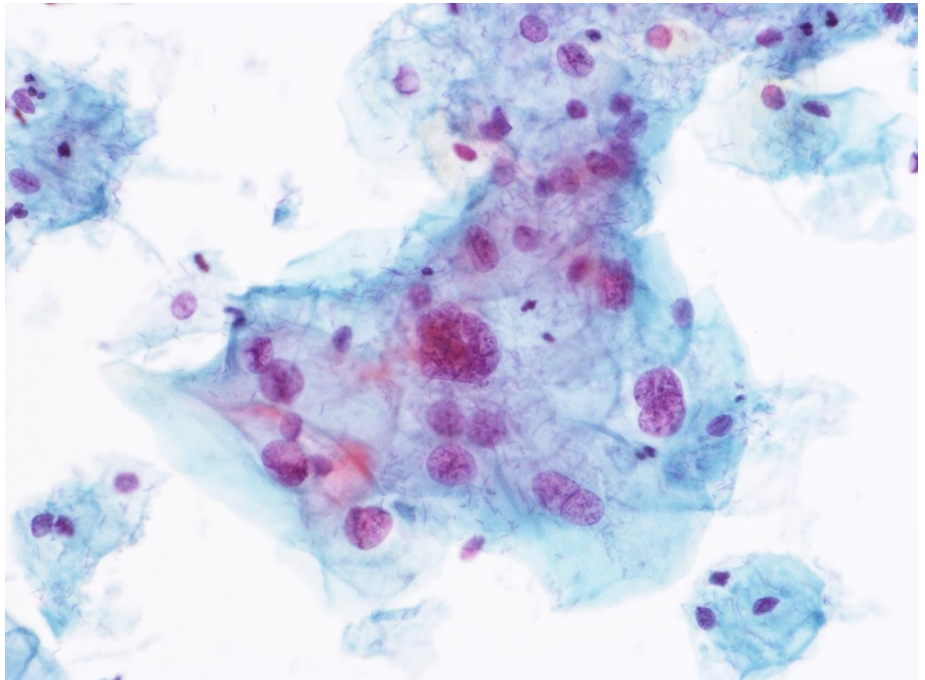

Scenario 1 colposcopy



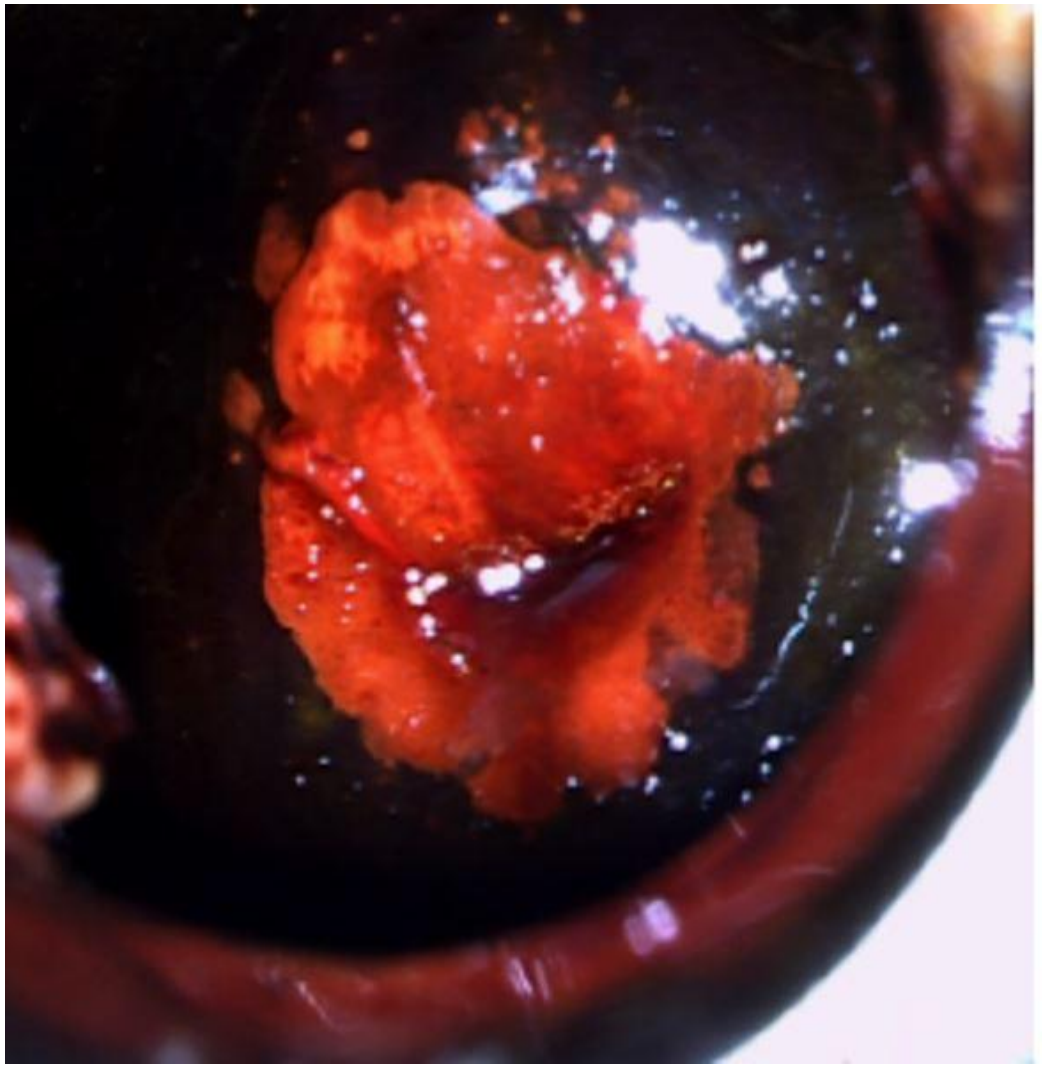

Scenario 1 histology

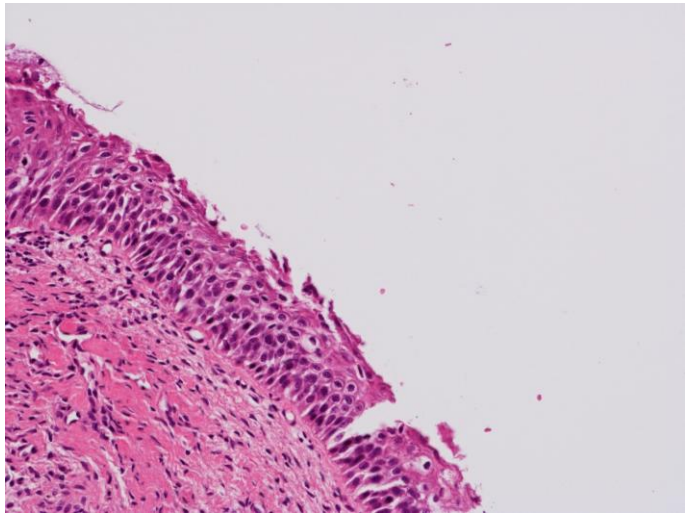

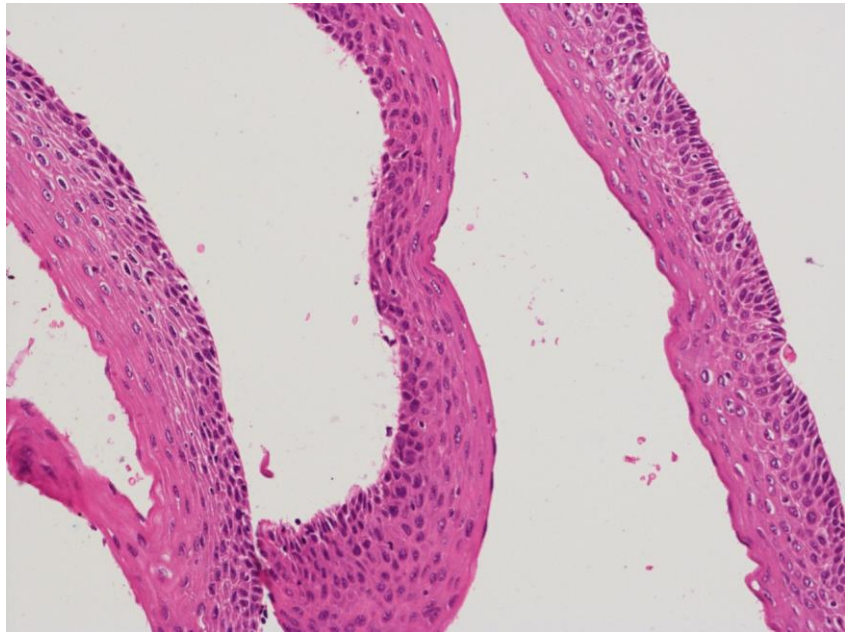

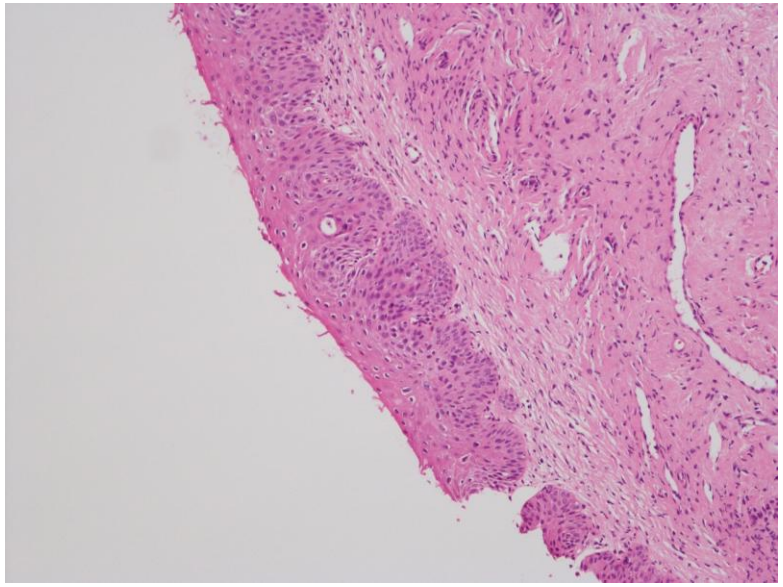

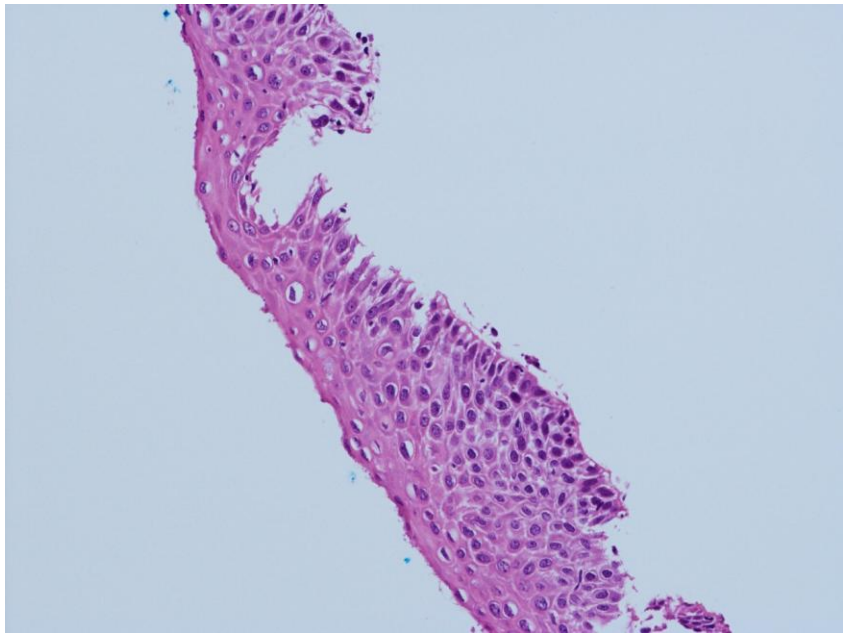

Poll 1 – How would you manage this patient?

- Follow up with cervical sample 6-12 months
- Follow up in 4/6 months with colposcopy and cervical sample
- Follow up in 12 months with colposcopy and cervical sample
- Thermal ablation/cold coagulation
- Cryocautery
- LLETZ
- Knife/Needle/laser cone
- Hysterectomy

Recommendation

- Persistent CIN1 for at least 2-3 years
- TZ fully visible
- No discrepancy
- No concern re cancer or glandular
- Suitable for ablation or excision
- If patient does not wish to have treatment or fertility an issue, then see in 12 months

Scenario 2 – clinical history

- 26 year-old having 1st cervical screen test, P0
- No HPV vaccination
- Non-smoker
- No symptoms
- Referred to colposcopy with HPV positive and high grade dyskaryosis (moderate)

Scenario 2 cytology

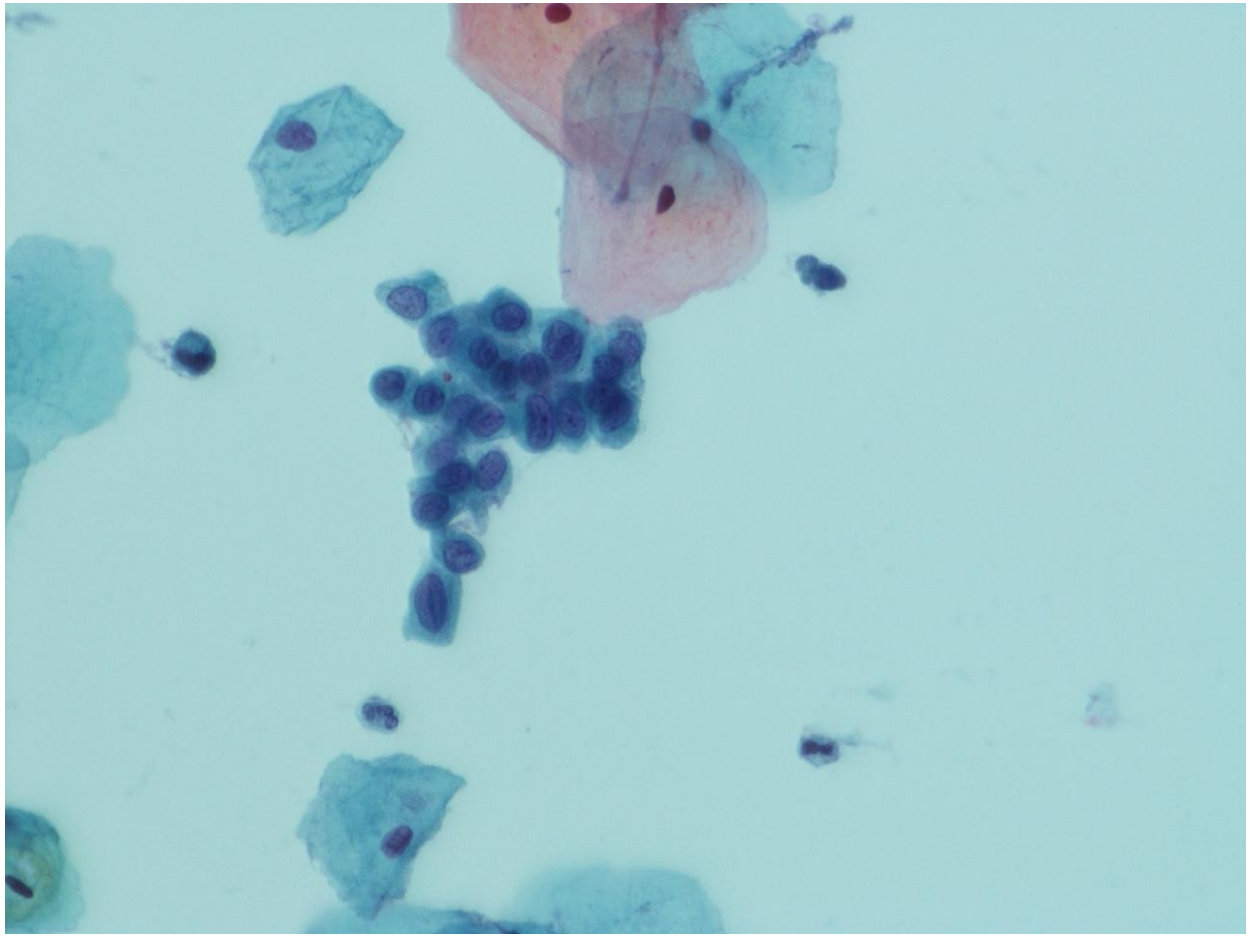

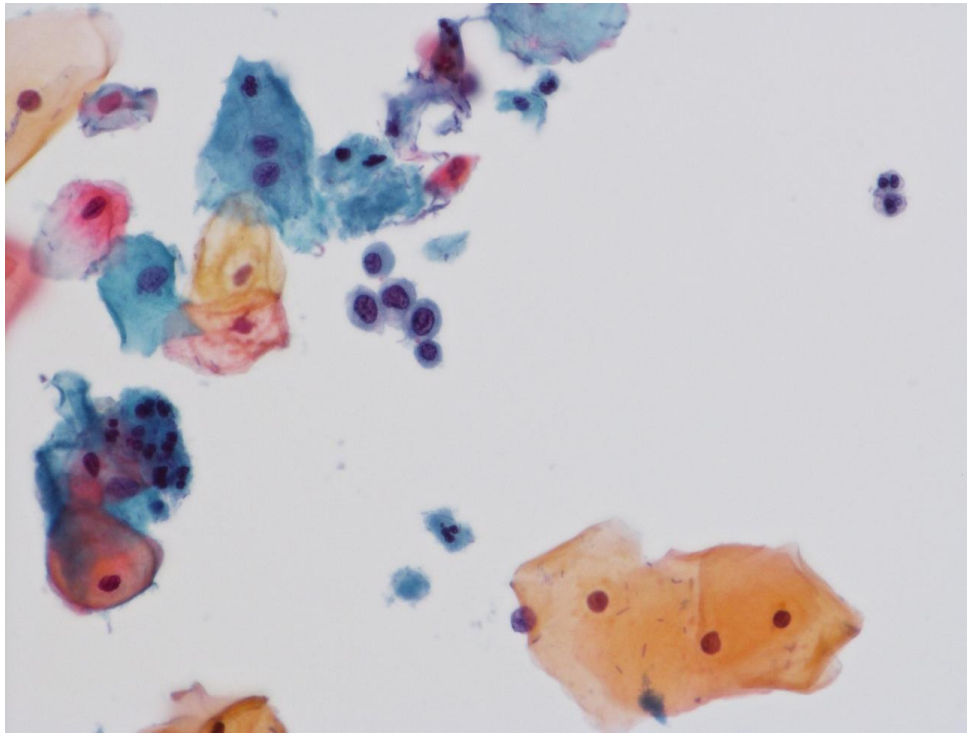

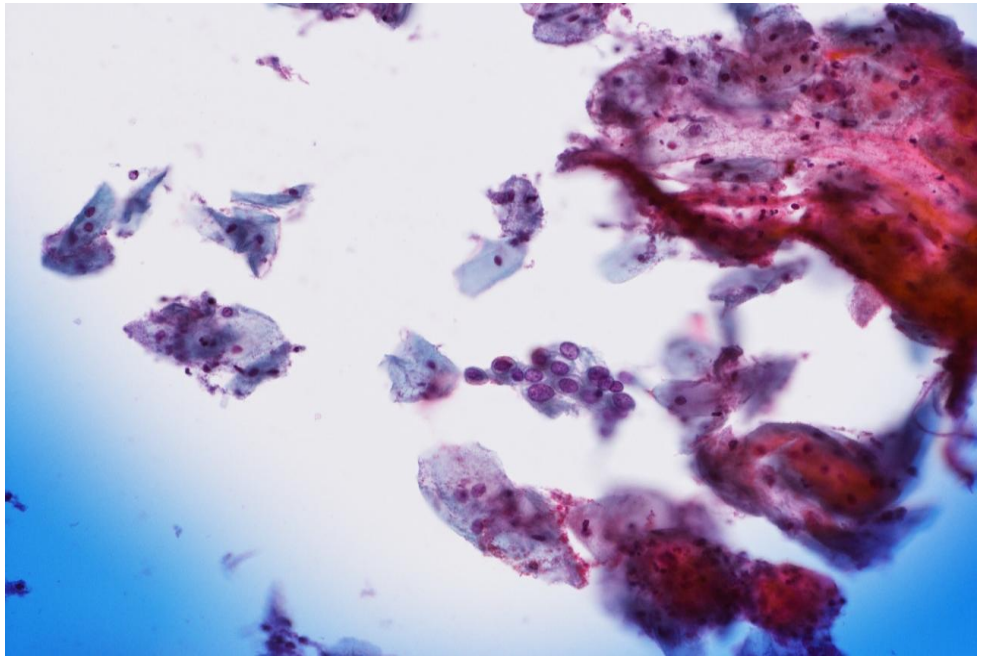

Scenario 2 colposcopy

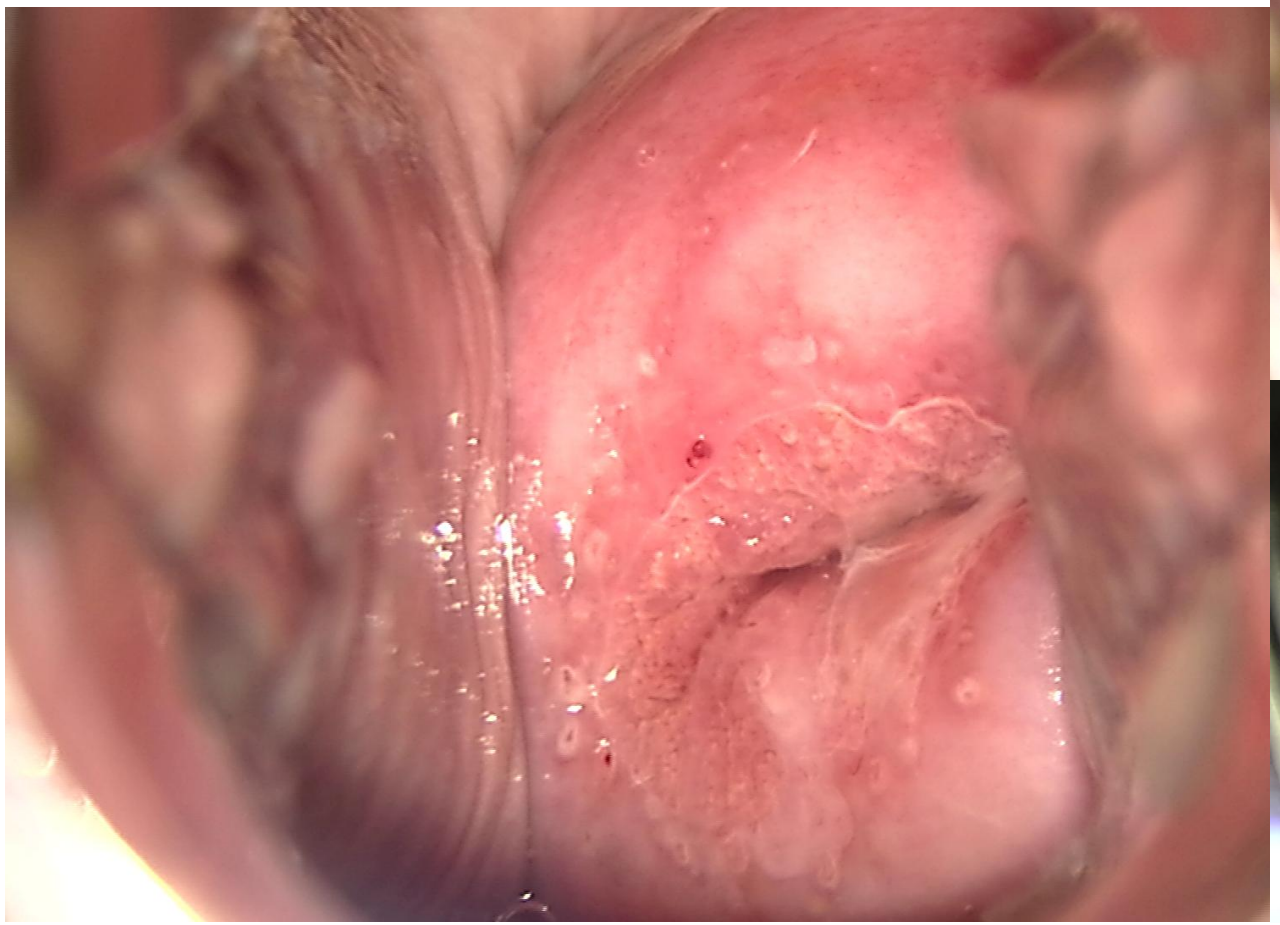

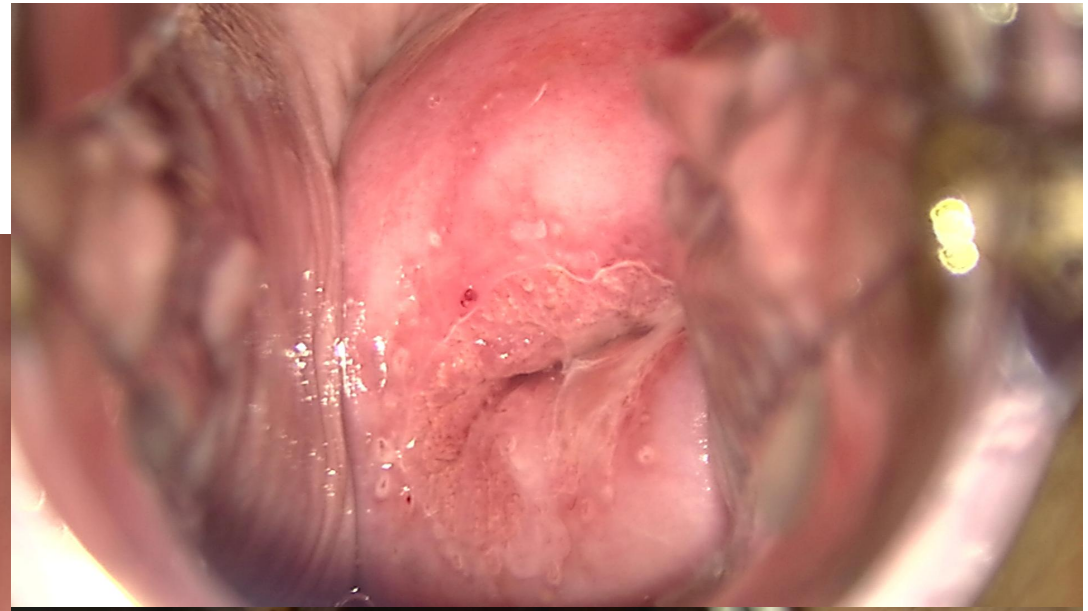



Scenario 2 histology

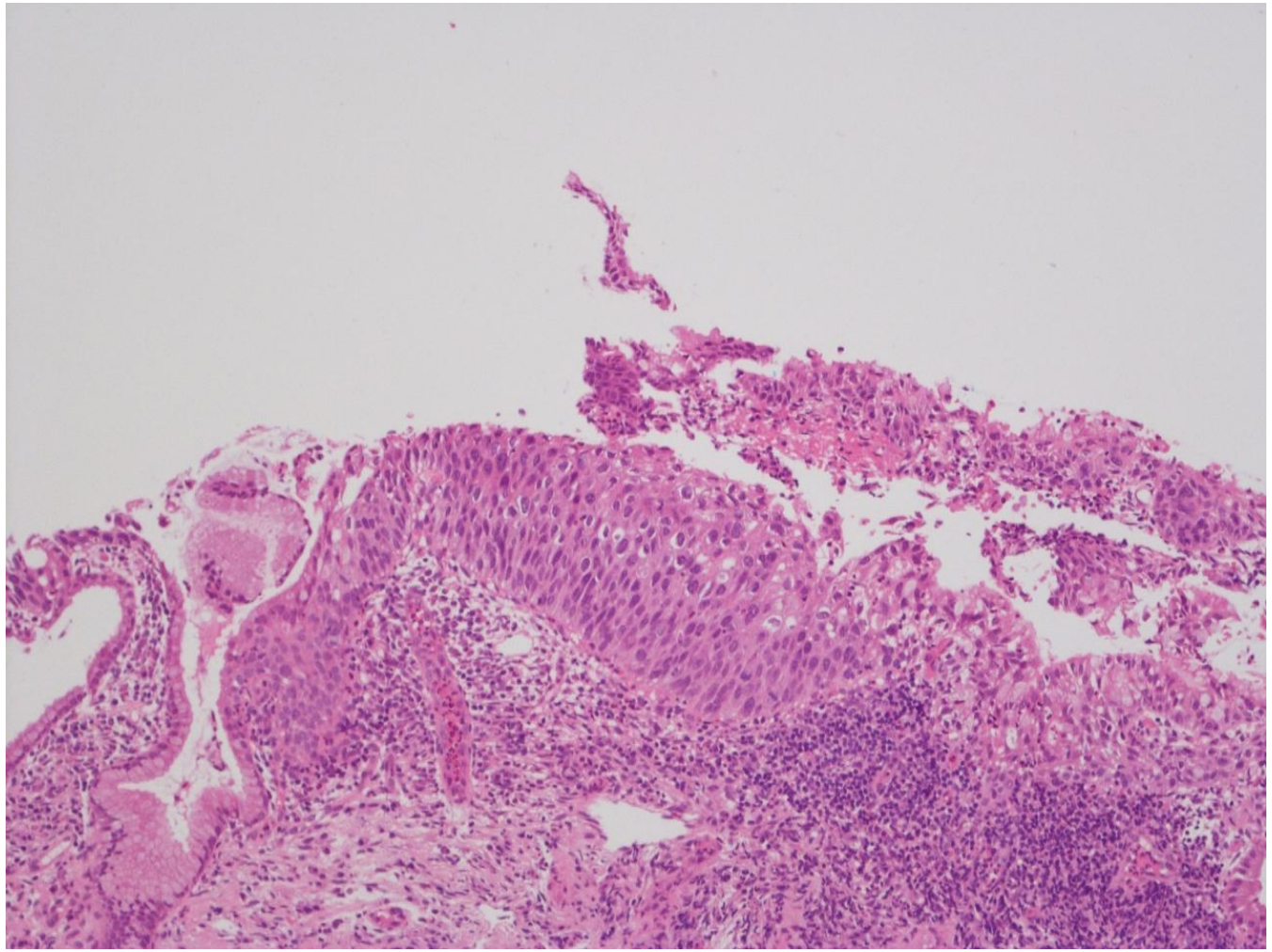

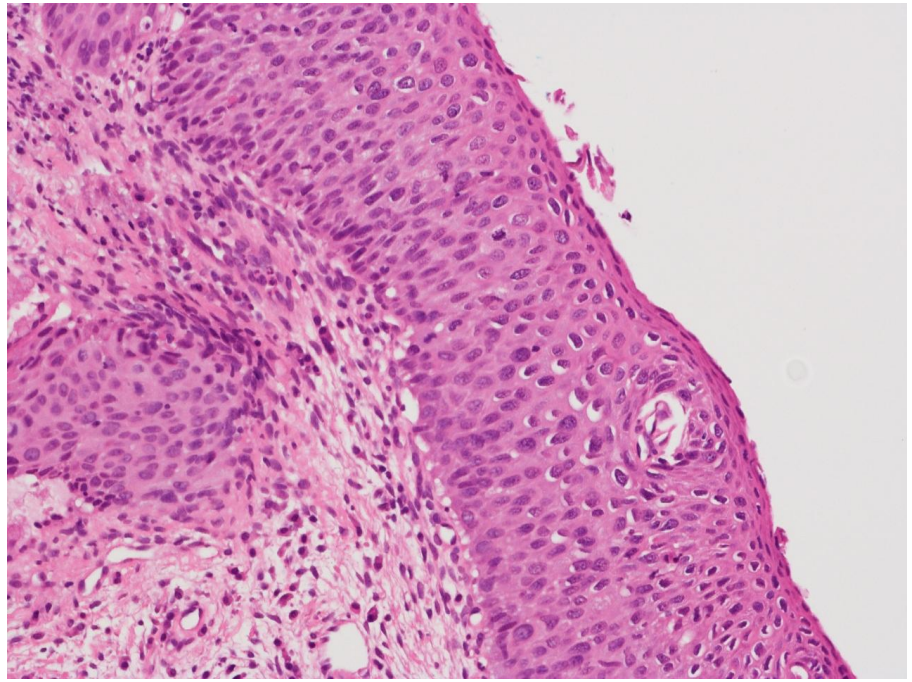

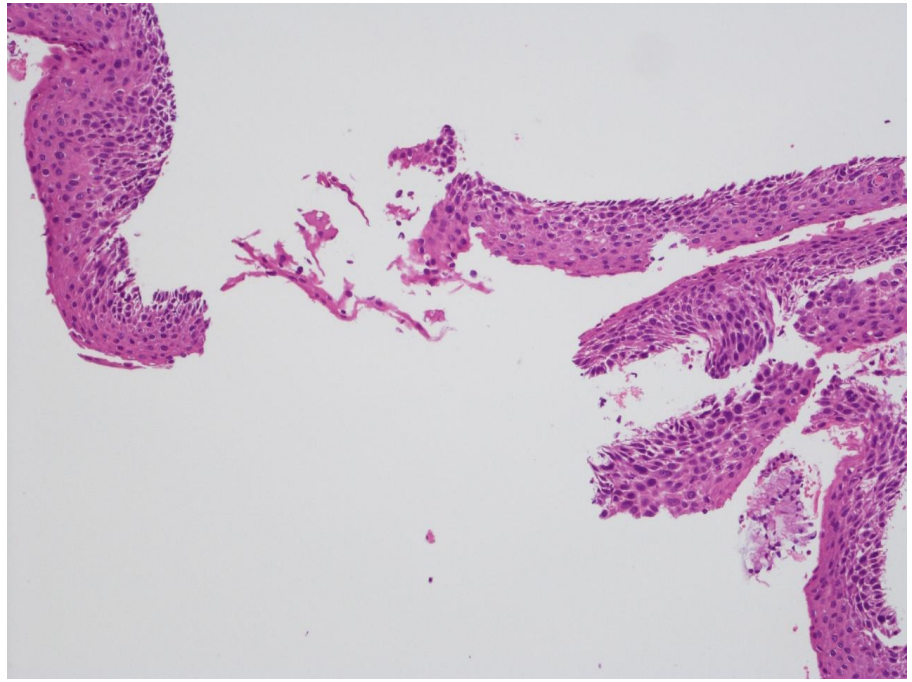

Poll 2 – How would you manage this patient?

- Follow up with cervical sample 6-12 months
- Follow up in 4/6 months with colposcopy and cervical sample
- Follow up in 12 months with colposcopy and cervical sample
- Thermal ablation/cold coagulation
- Cryocautery
- LLETZ
- Knife/Needle/laser cone
- Hysterectomy

Scenario 2 outcome

- Follow up with colposcopy and 4/6 months cervical sample
  - indications-
  - young and nulliparous,
  - adequate colposcopy,
  - fully visible TZ
  - CIN2 in only 1-2 quadrants

- For treatment if CIN2 not resolved within 2 years – ablative versus excision

- If any PCB/IMB or expansile CIN2 not for ablation/cold coagulation

Scenario 3

- 33 year old P0 with IMB
- Had HPV vaccination – 3 doses

- Cervical screen history as follows:
  - 2023 HPV positive and LG
  - Colposcopy and biopsy – CIN 1

  - 2024 HPV positive and high grade dyskaryosis (moderate)

Scenario 3 cytology

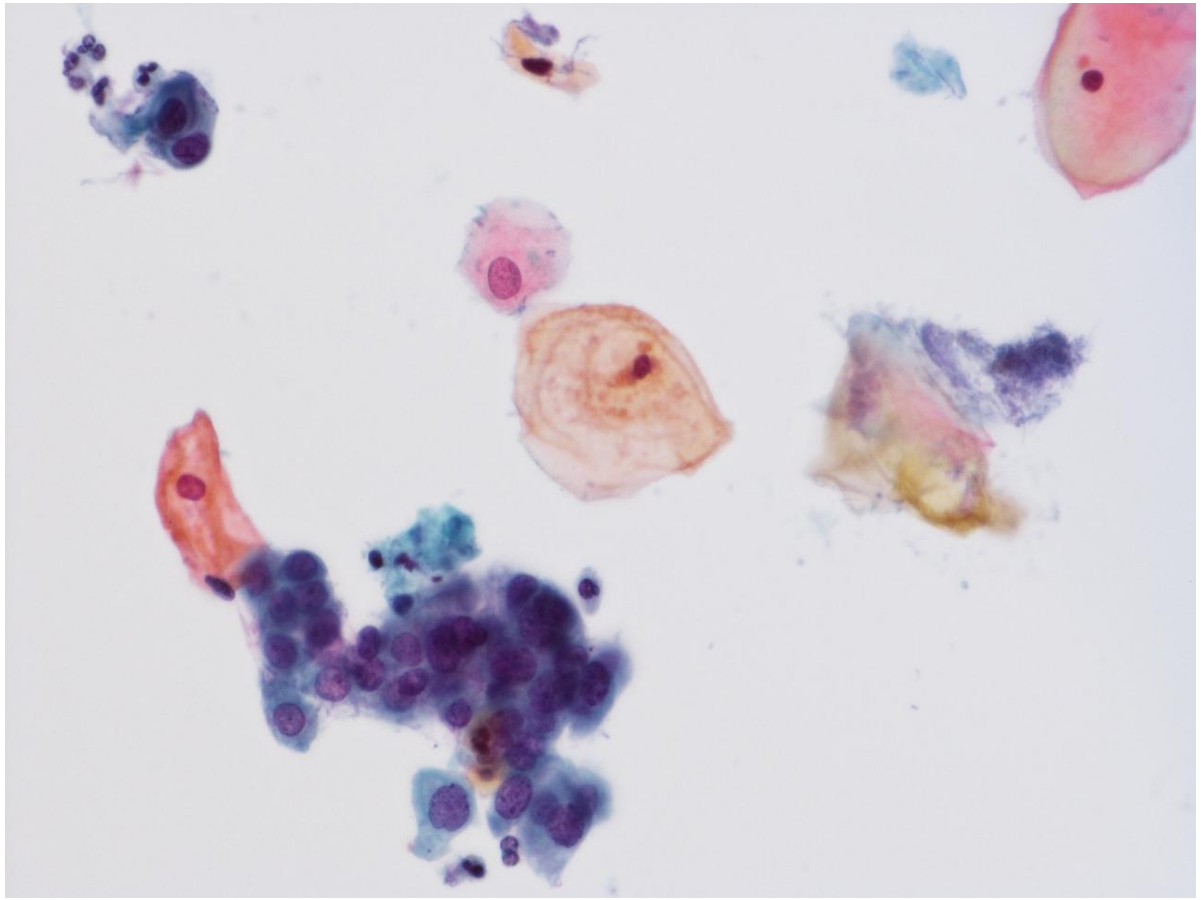

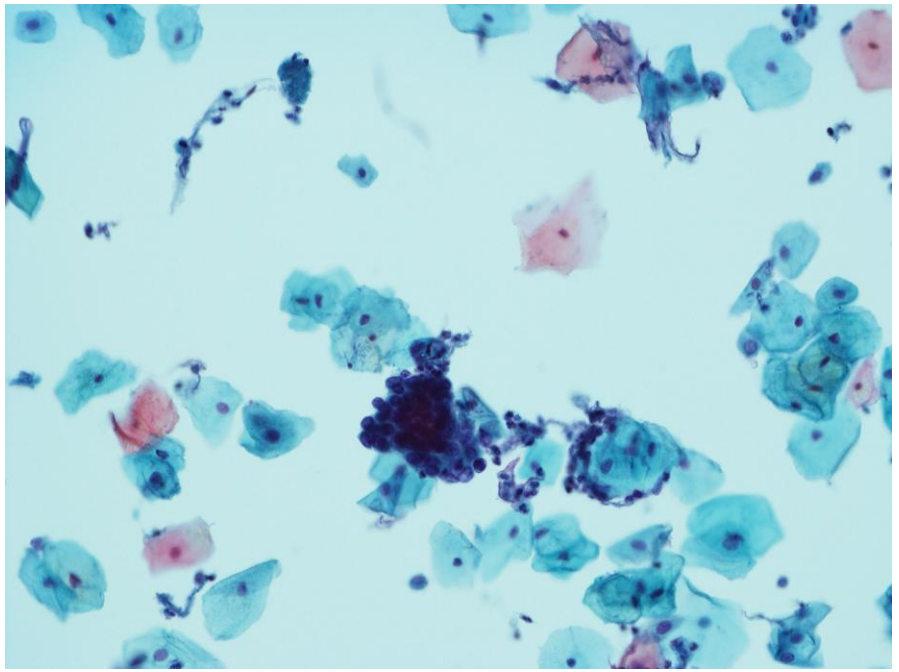

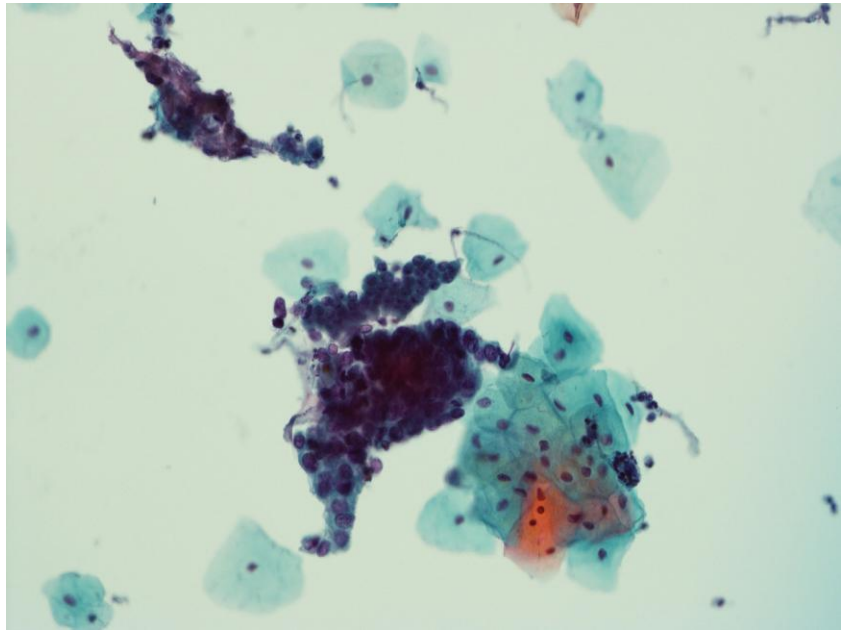

Scenario 3 colposcopy

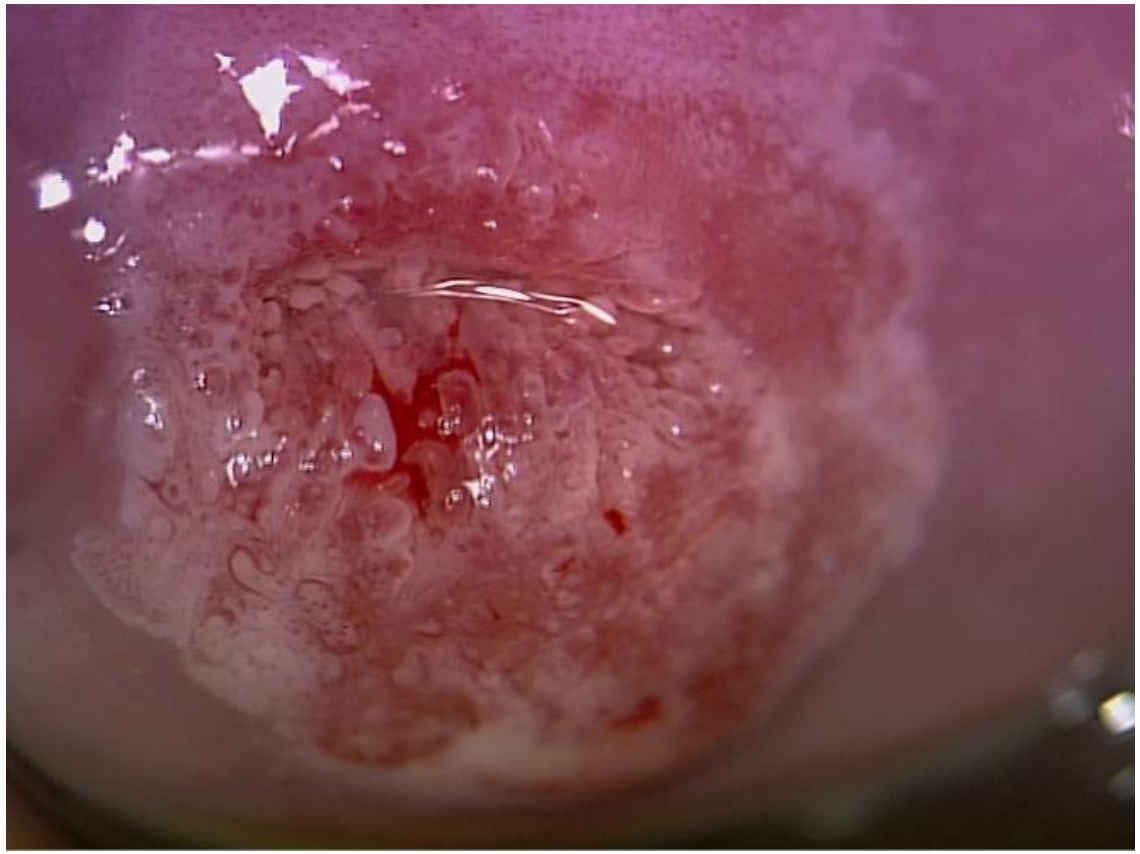

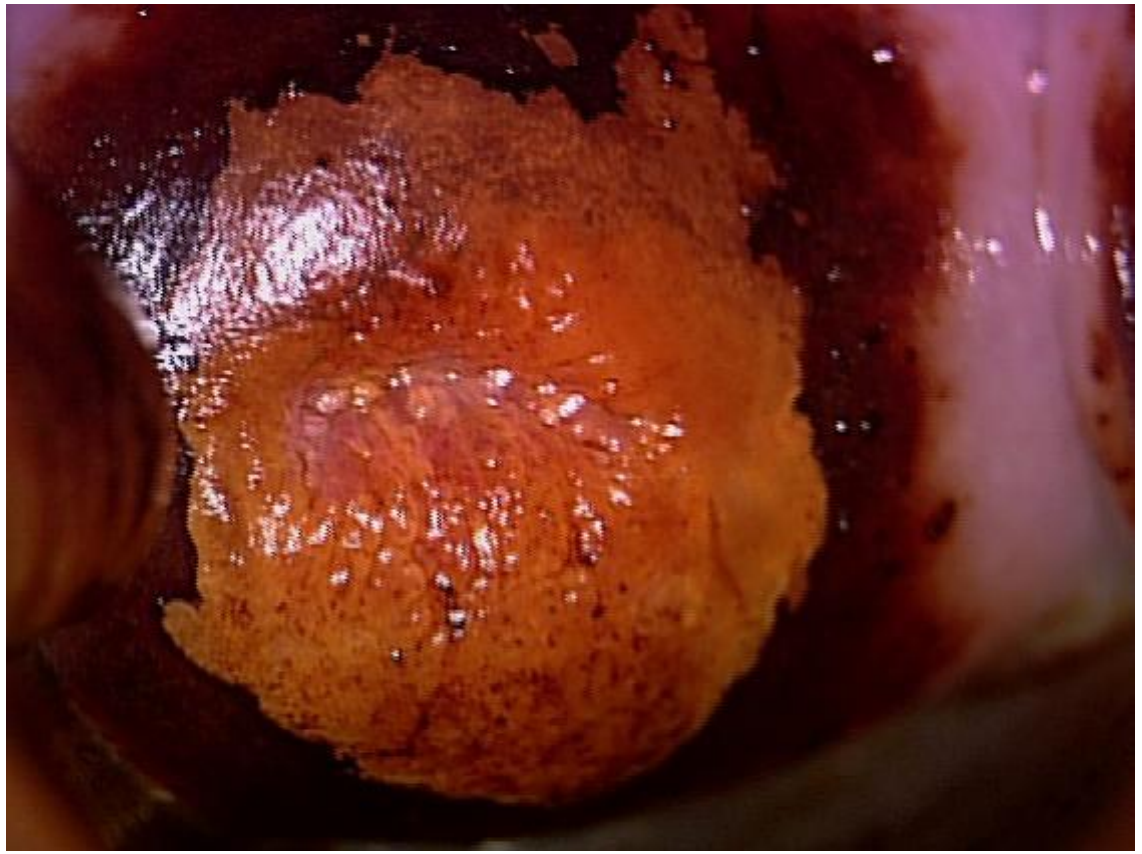

Scenario 3 histology

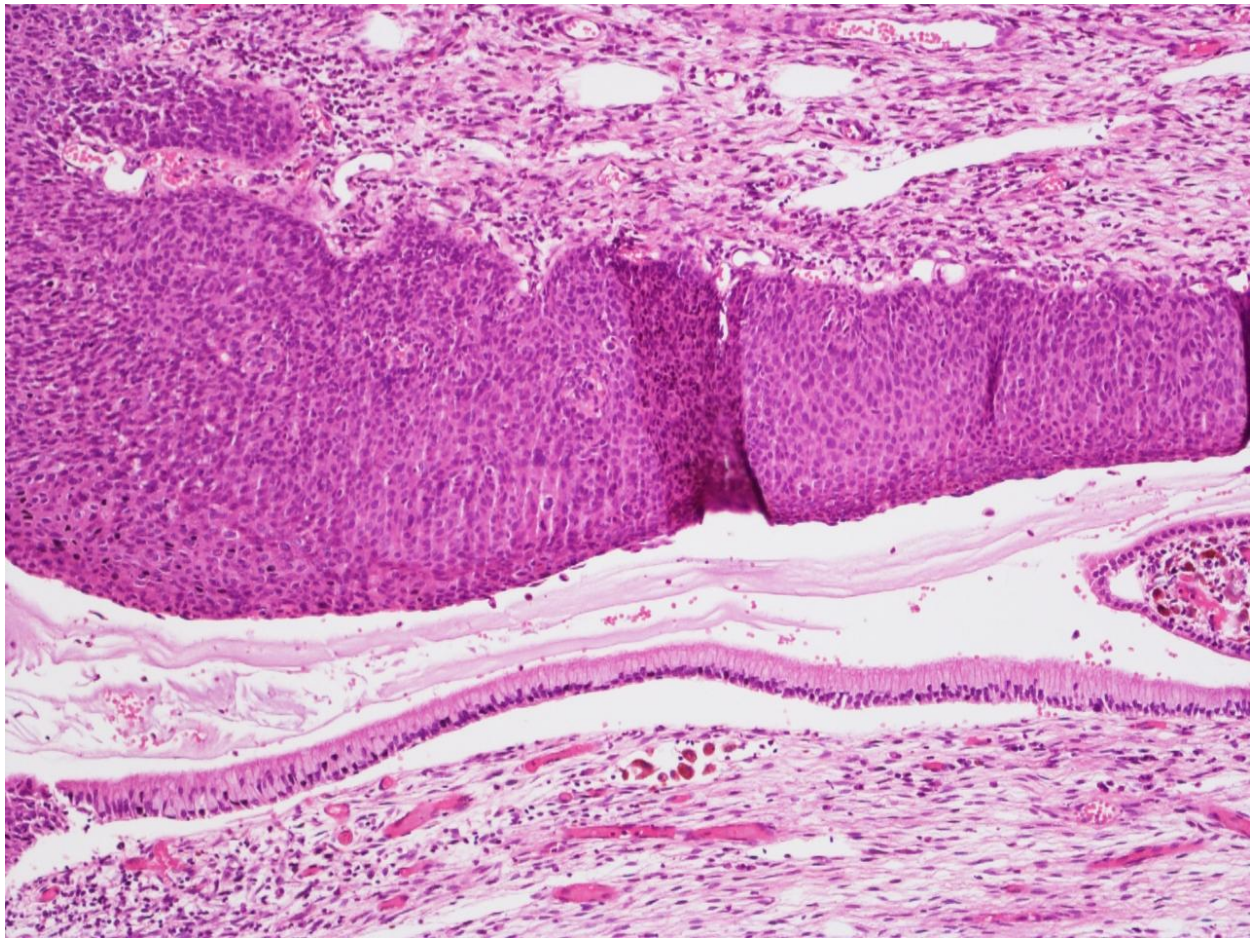

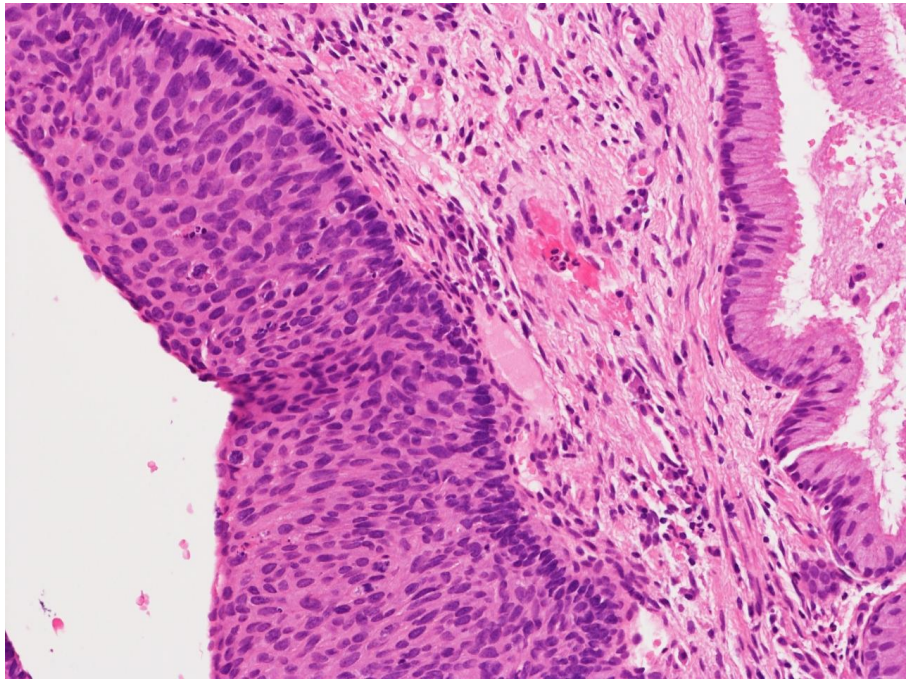

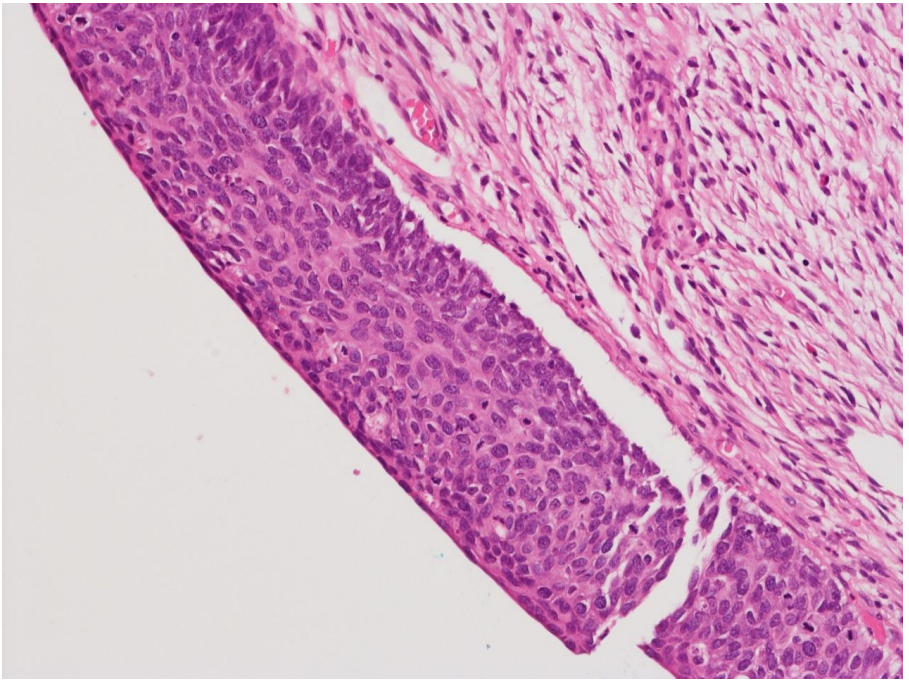

Scenario 3 histology (crypt involvement)

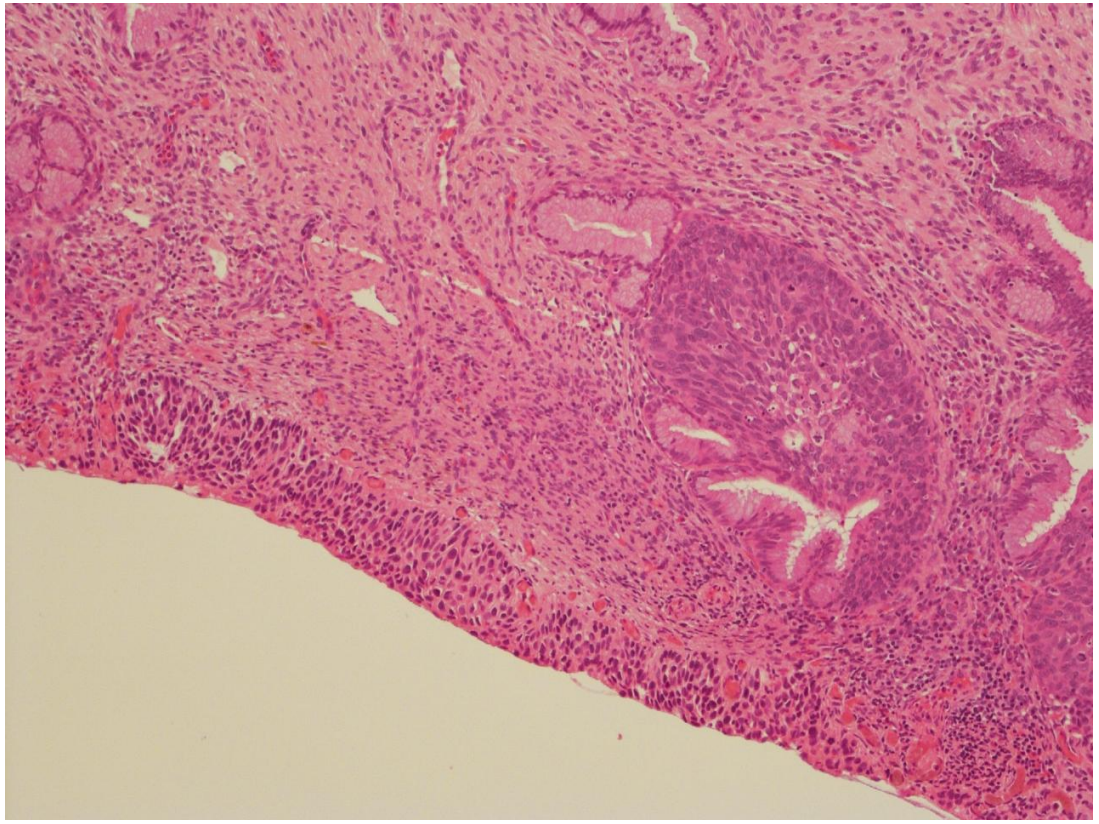

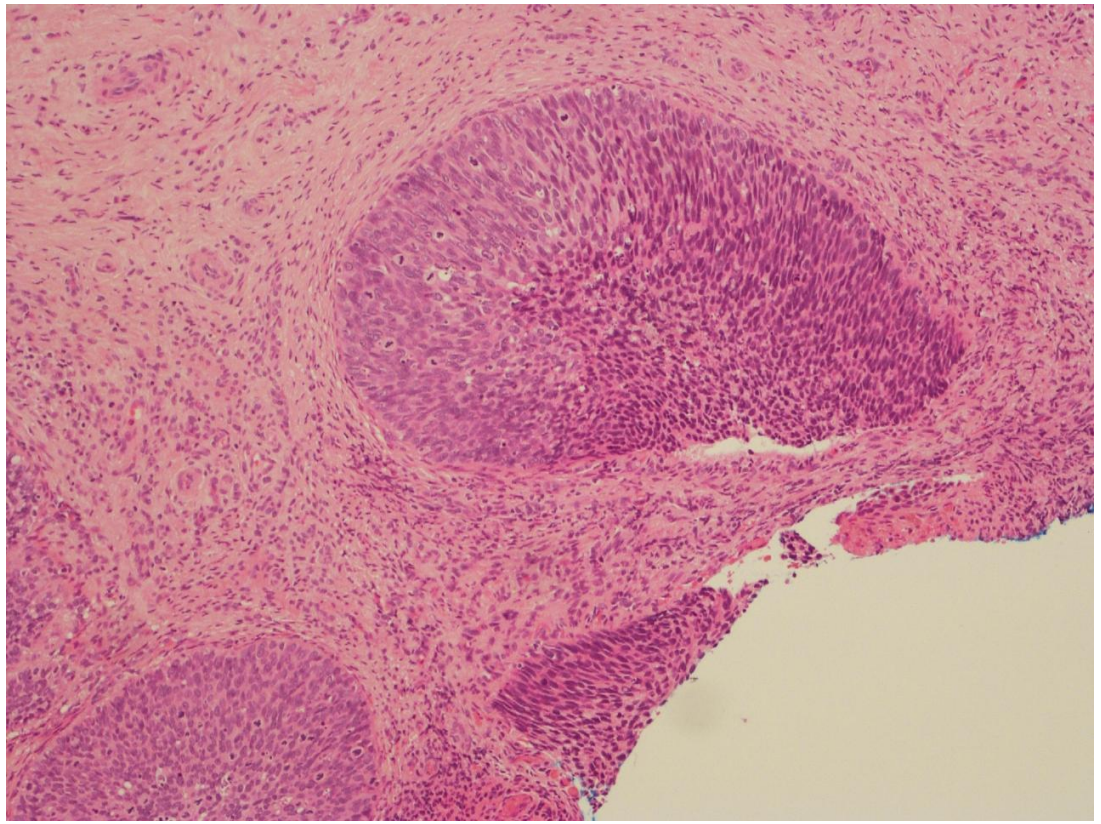

Poll 3 – How would you manage this patient?

- Follow up with cervical sample 6-12 months
- Follow up in 4/6 months with colp and cervical sample
- Follow up in 12 months with colp and cervical sample
- Thermal ablation/cold coagulation
- Cryocautery
- LLETZ
- Knife/Needle/laser cone
- Hysterectomy

Scenario 3 outcome

- For excisional treatment followed by Test Of Cure (TOC) at 6 months
- As CIN 3 crypt involvement is expansile there is a risk of subsequent invasion being detected and high-grade cytology recurrence in TOC

Scenario 4

- 34 year old with PCB, nulliparous
- Previous negative cervical screen history abroad
- 1st cervical sample in this country:

- 2024 current screen test reported as HPV positive ?glandular neoplasia

Scenario 4 cytology

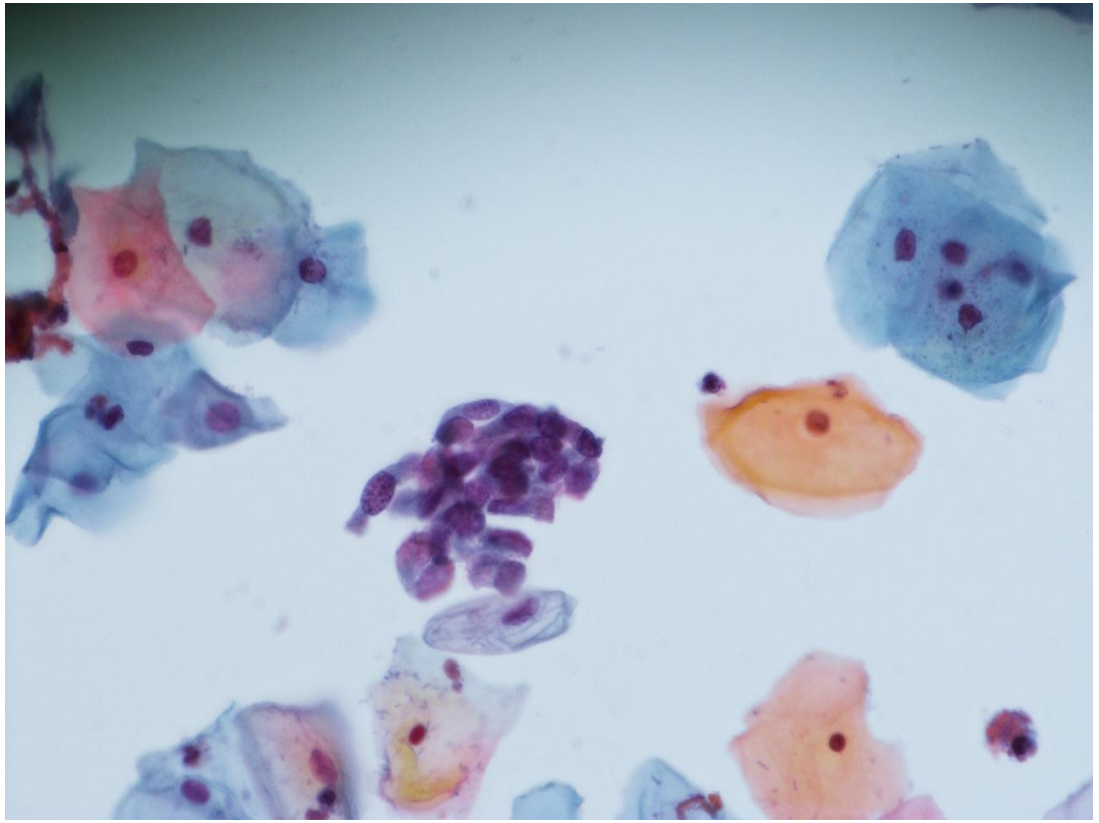

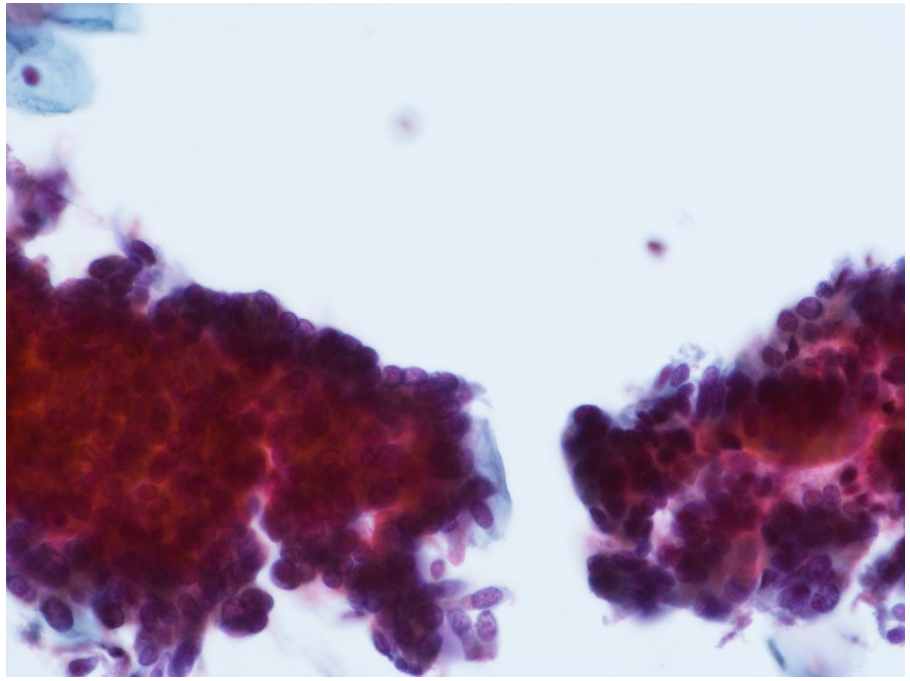

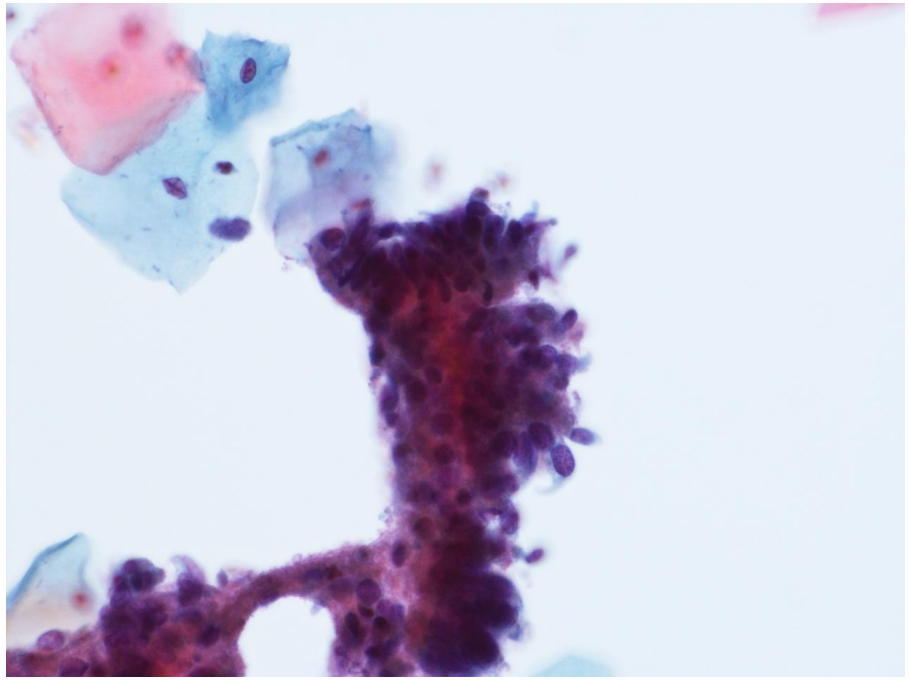

Scenario 4 colposcopy

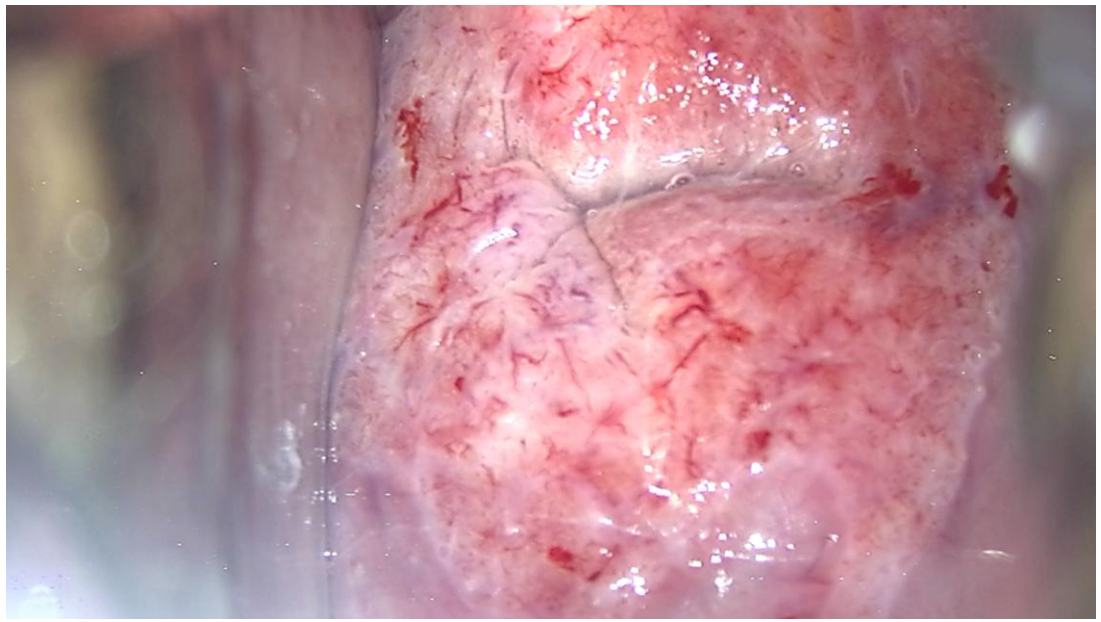

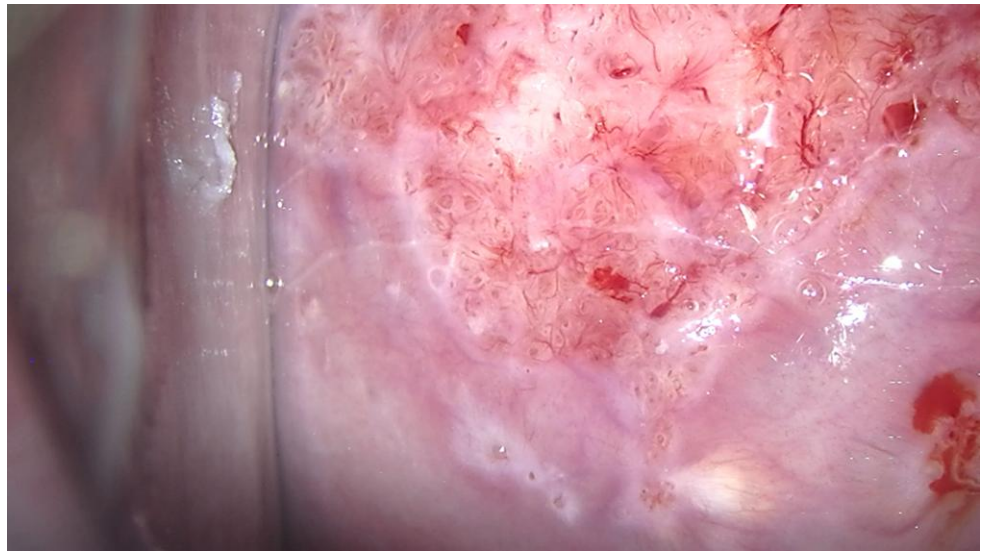

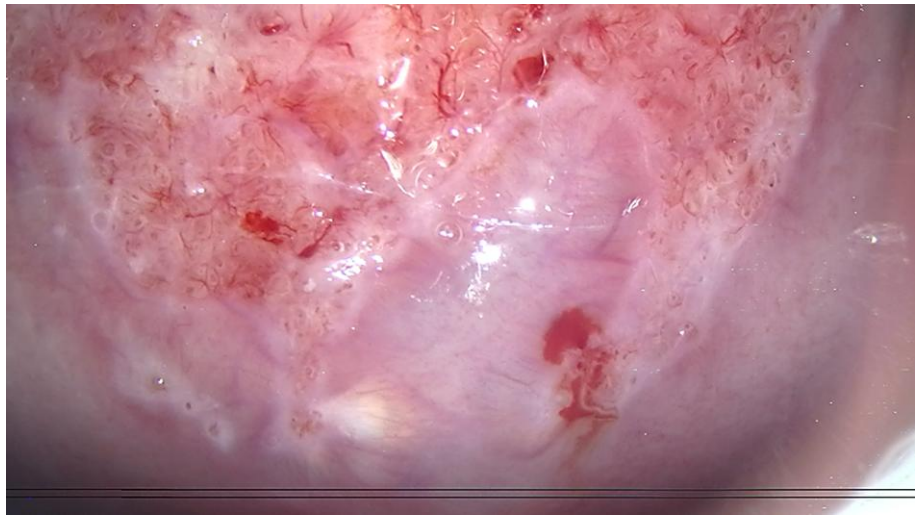

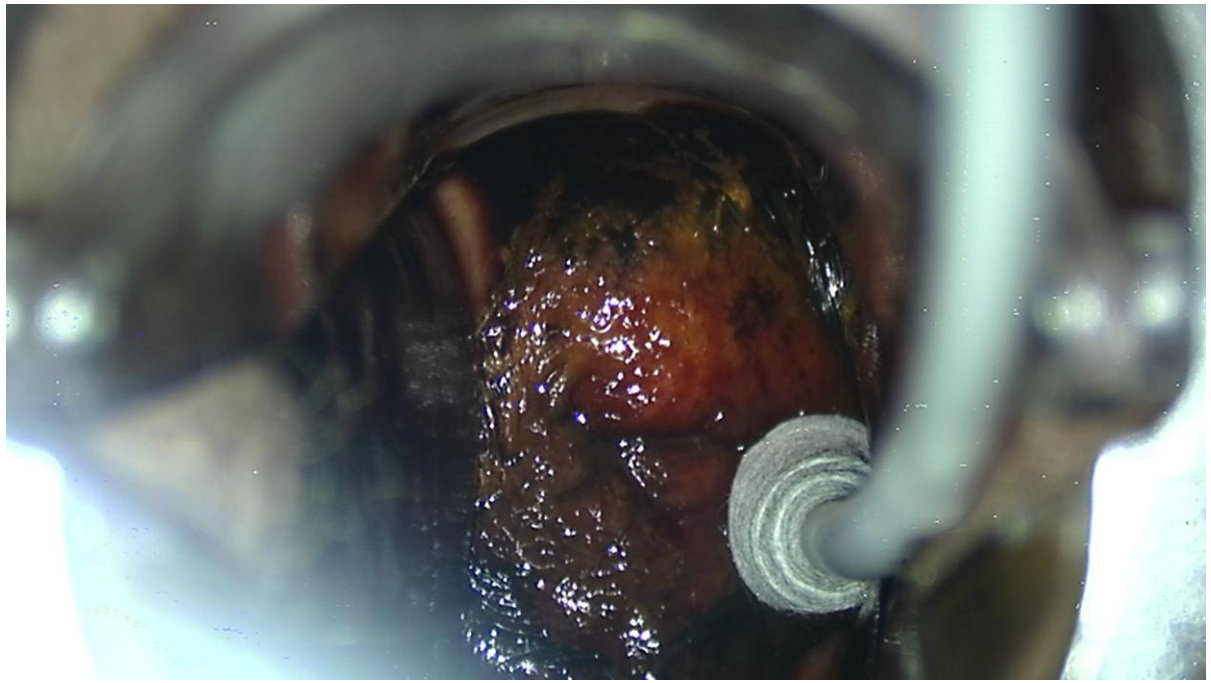

Scenario 4 histology

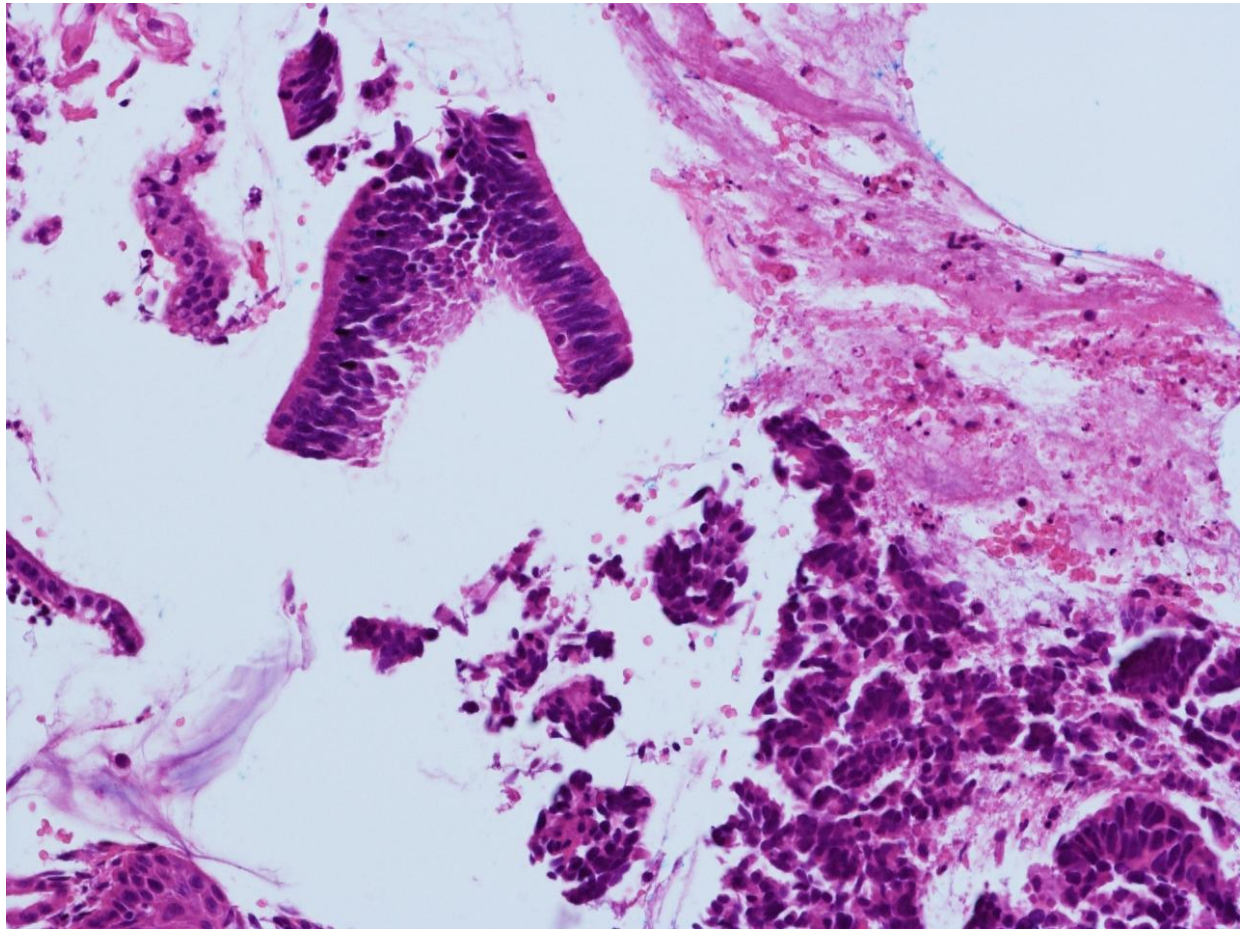

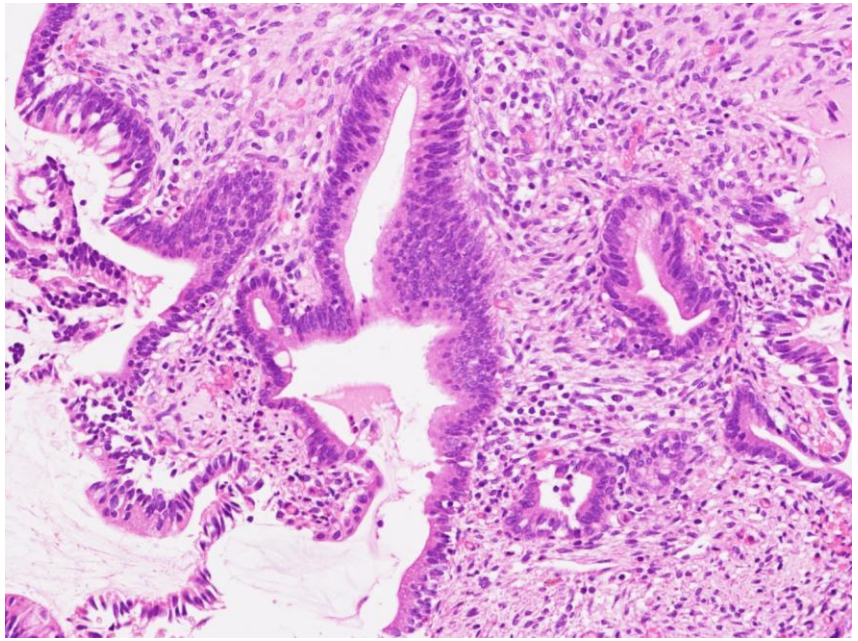

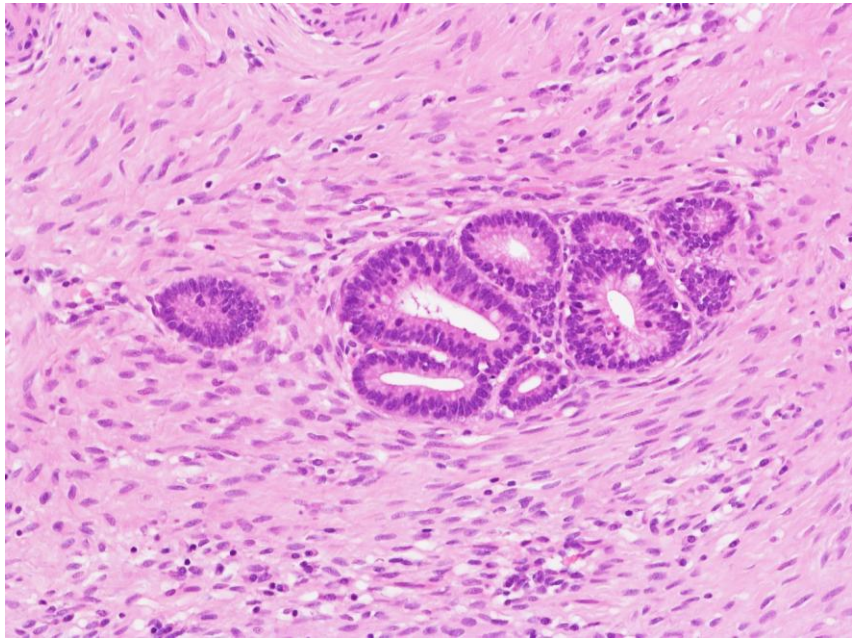

Scenario 4 histology $p16^{INK}$

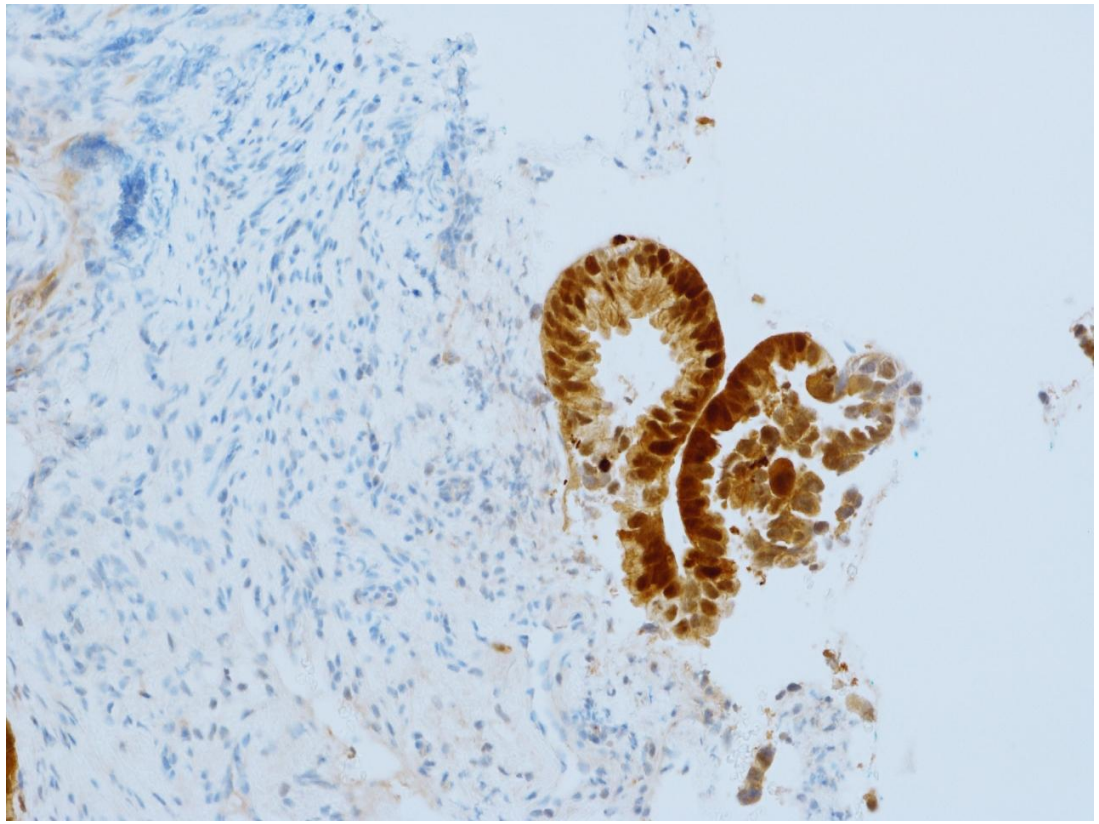

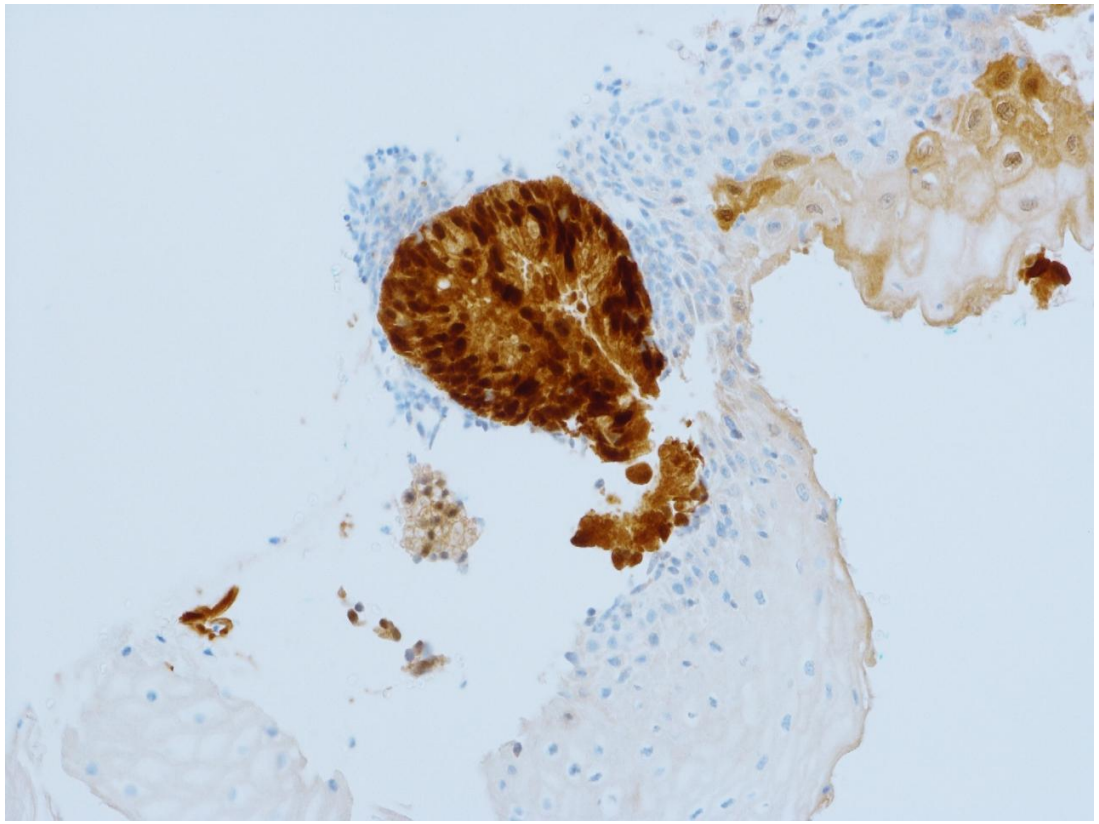

Scenario 4 histology SMILE +CIN3

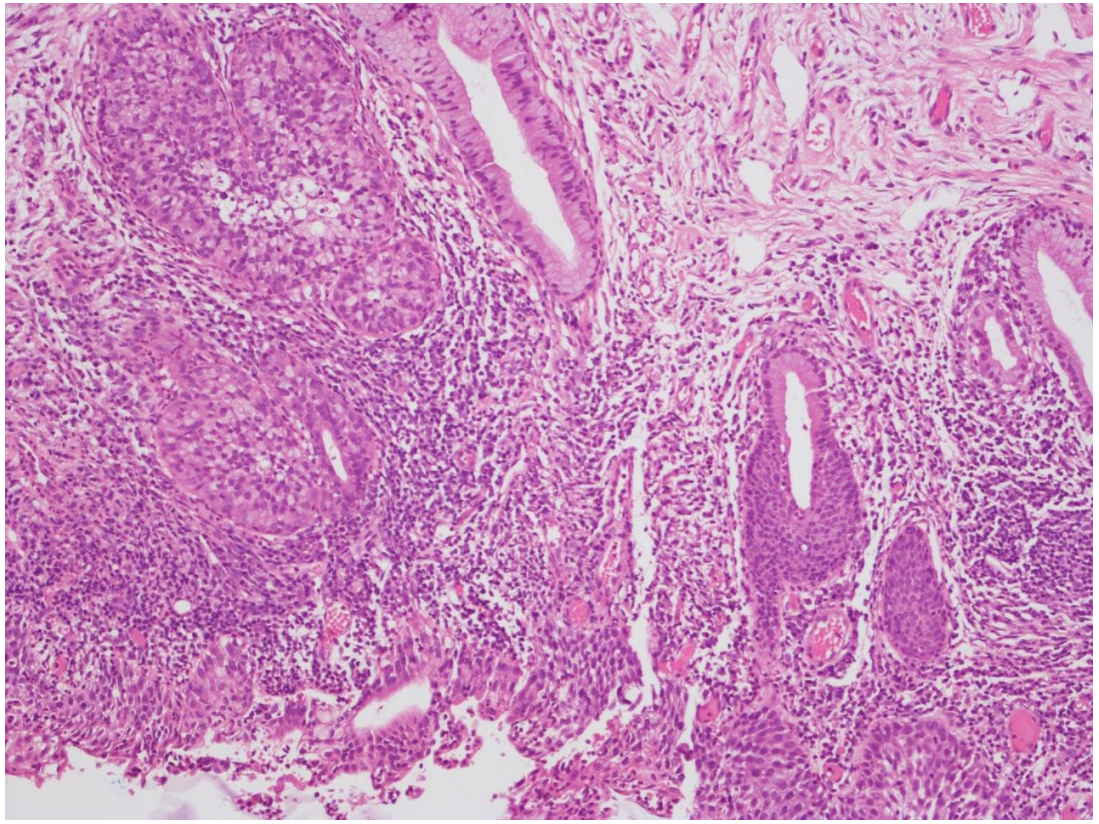

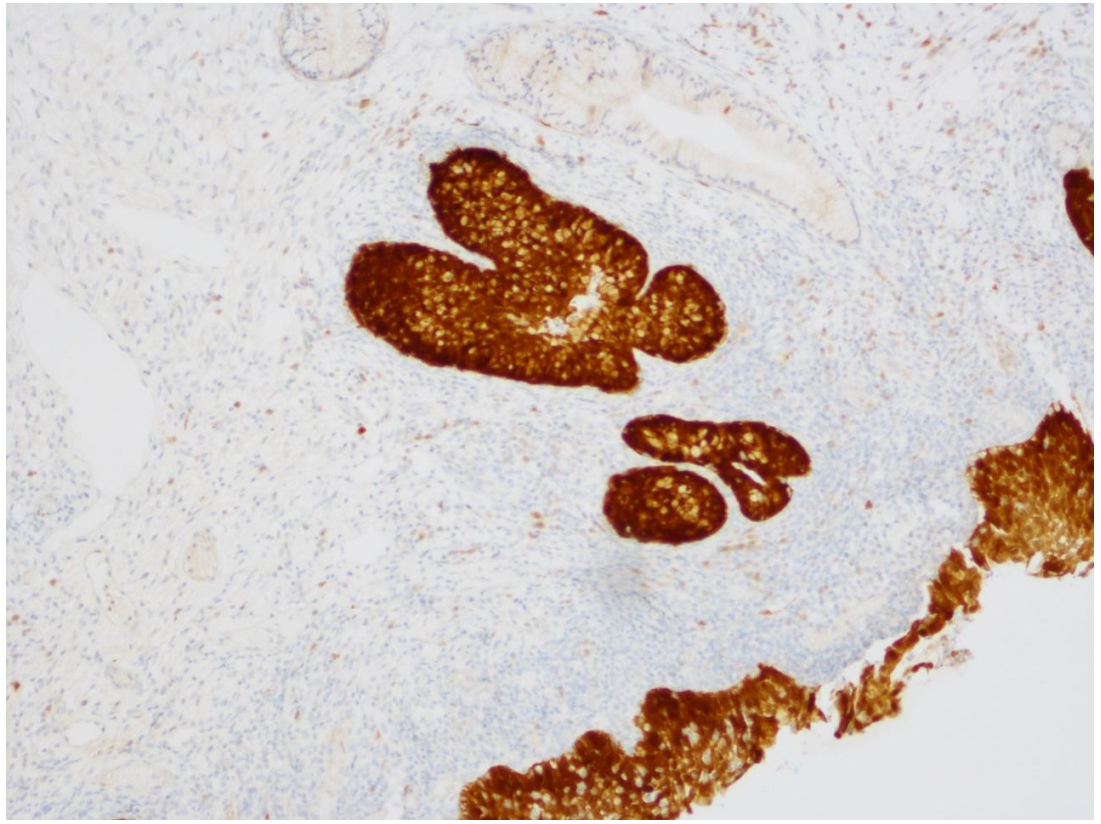

Poll 4 – How would you manage this patient?

- Follow up with cervical sample 6-12 months
- Follow up in 4/6 months with colp and cervical sample
- Follow up in 12 months with colp and cervical sample
- Thermal ablation/cold coagulation
- Cryocautery
- LLETZ
- Knife/Needle/laser cone
- Hysterectomy

Scenario 4 outcome

- For excision including whole of TZ and at least 10mm endocervix above SCJ
- Followed by TOC at 6 and 18 months post treatment if clear margins and no invasion otherwise 2nd excision/hysterectomy to get clear margins and exclude invasive component
- Risk of recurrence with glandular lesions (skip lesions)
- SMILE managed as for CGIN

Scenario 5 -

- 52 year old with irregular vaginal bleeding

- Lapsed attender with last cervical screen 5 years ago –
  - borderline nuclear changes in squamous cells
  - never attended for colposcopy

- Referral cytology HPV positive and ?invasive

Scenario 5 cytology

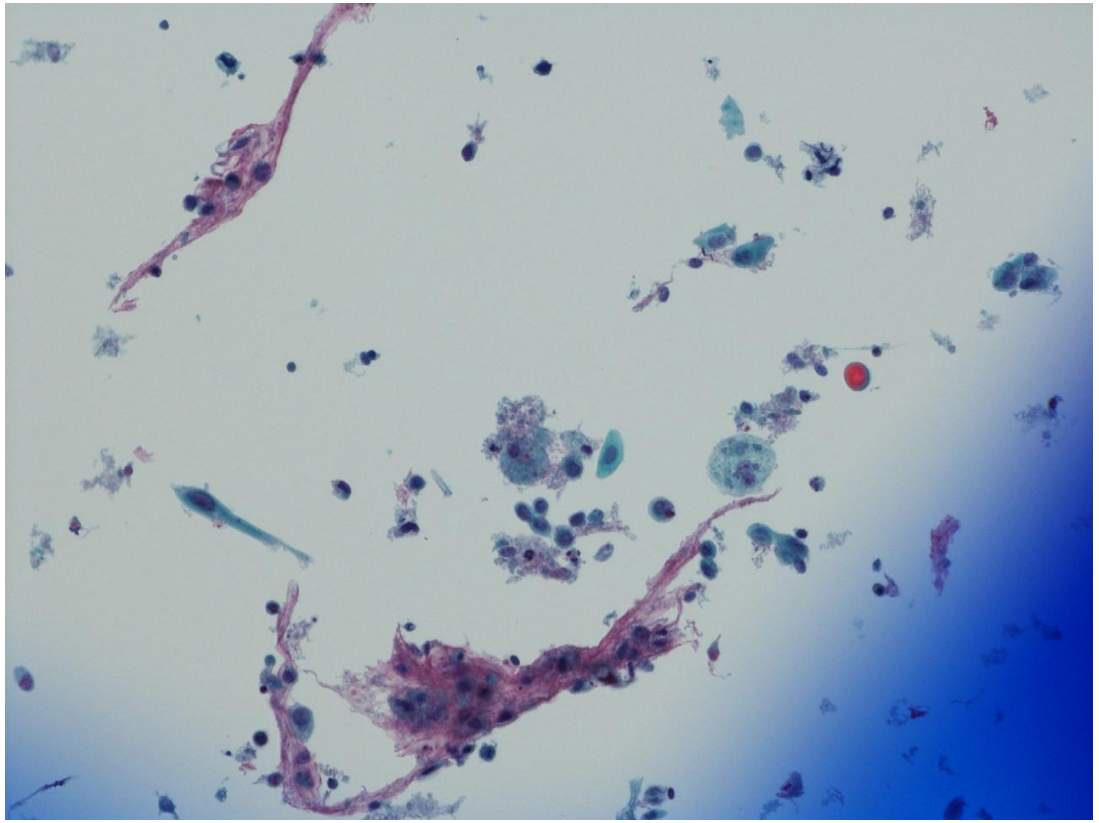

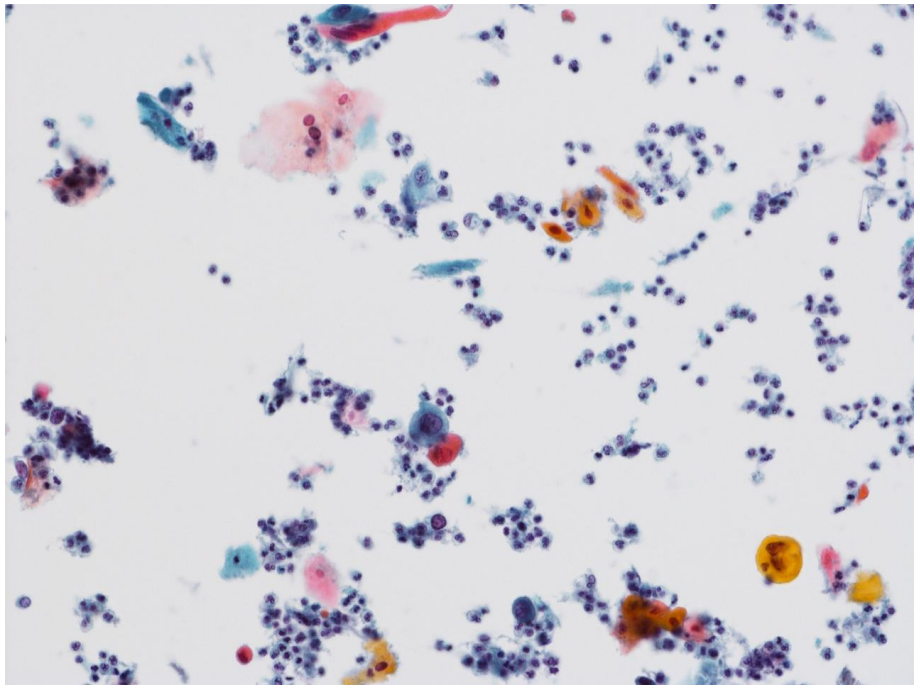

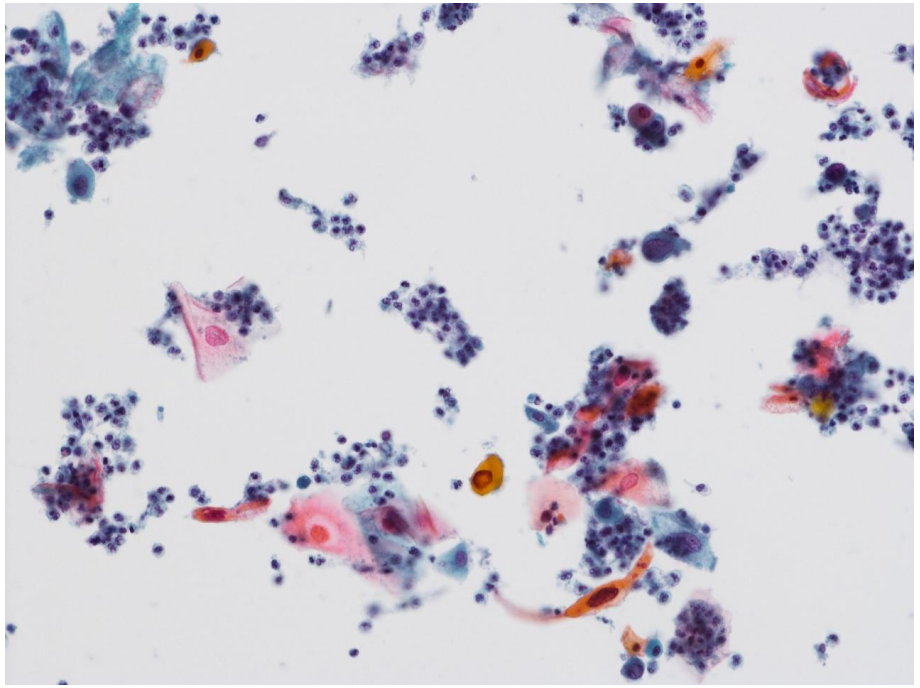

Scenario 5 colp



Scenario 5 histology

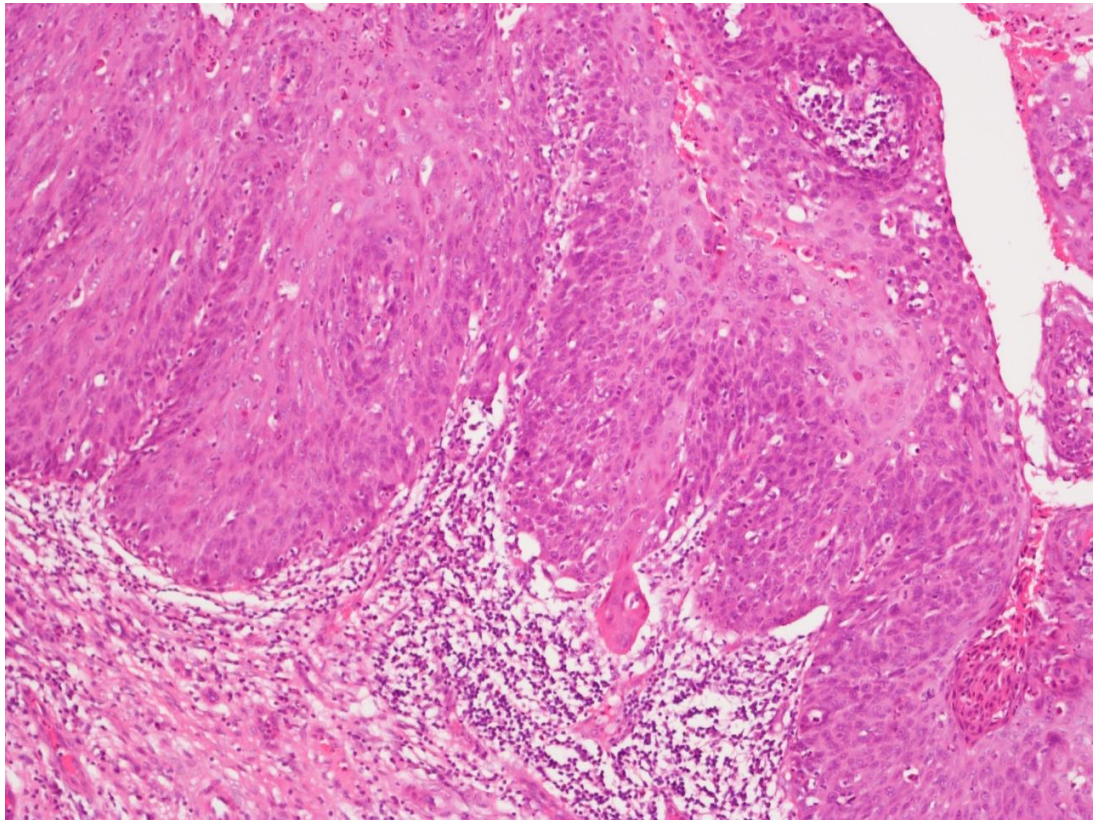

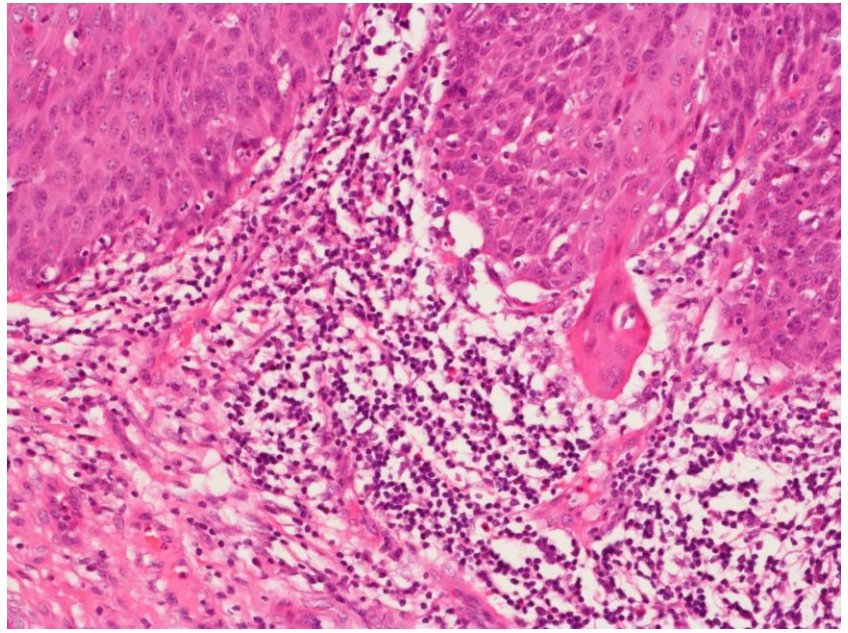

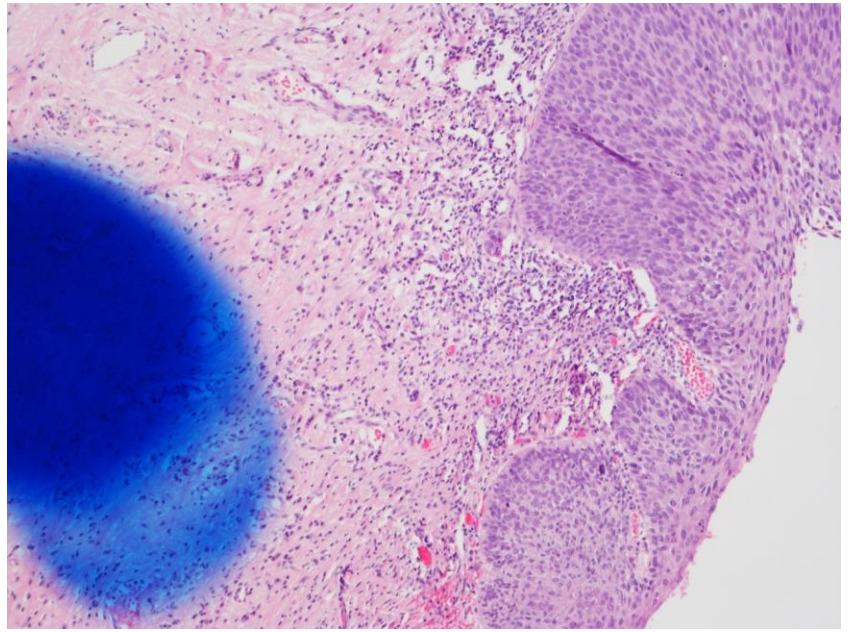

Scenario 5 histology

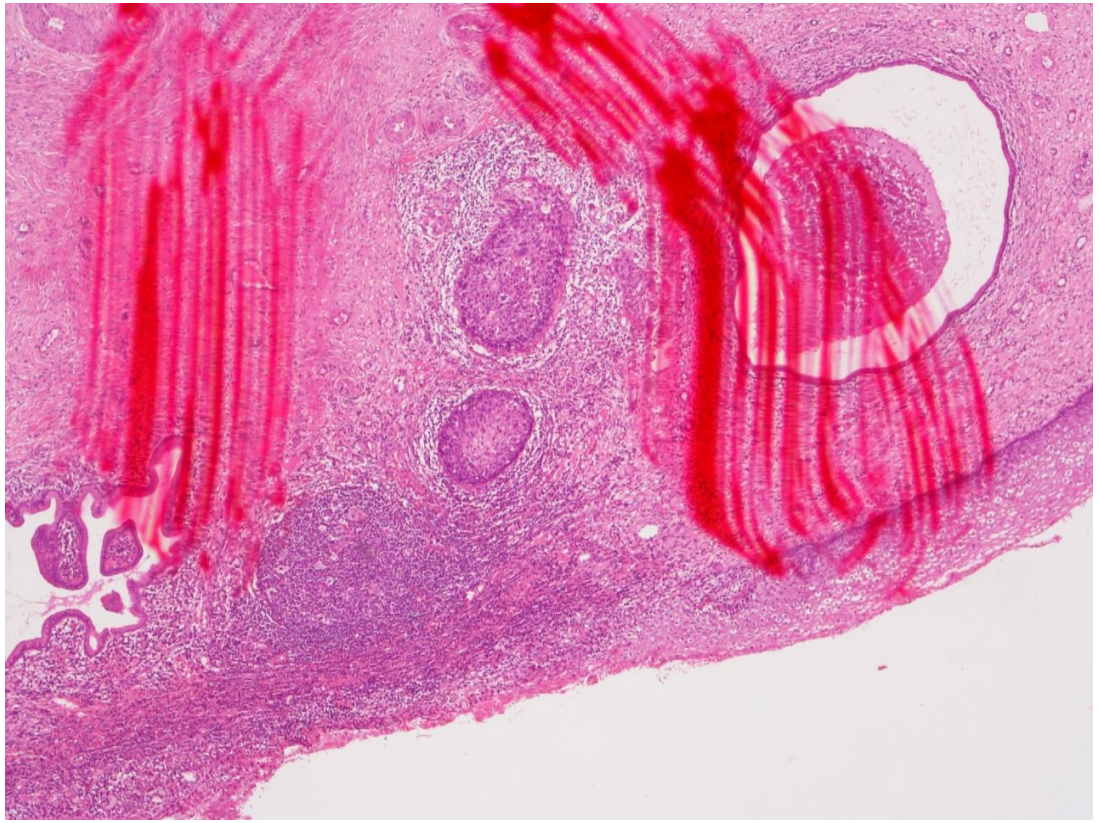

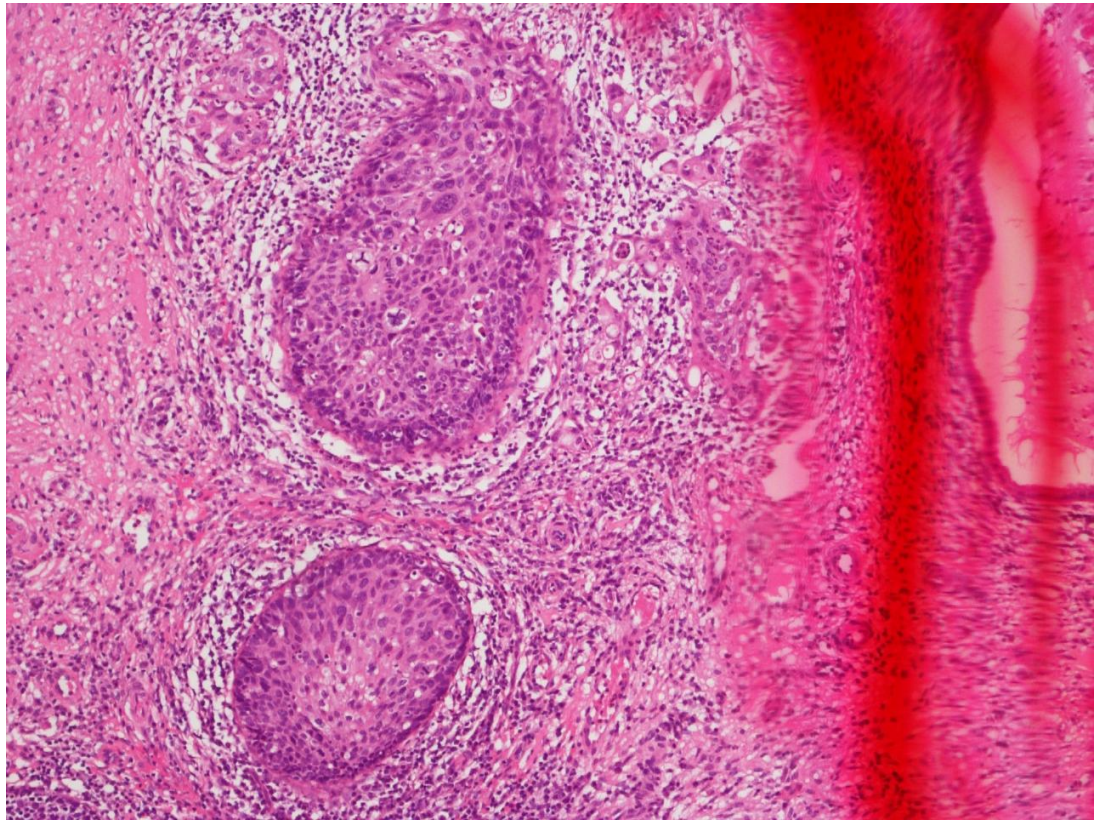

Poll 5 – How would you manage this patient?

- Follow up with cervical sample 6-12 months
- Follow up in 4/6 months with colp and cervical sample
- Follow up in 12 months with colp and cervical sample
- Thermal ablation/cold coagulation
- Cryocautery
- LLETZ
- Knife/Needle/laser cone
- Hysterectomy

Scenario 5 outcome

- Depends on staging – clinically visible, size, spread
- Discuss at gynae onc MDT with radiology and referral to gynae cancer centre for histology review
- Stage 1a1 may be treated with local excision
- Stage 1a2/1b1 managed according to the gynae onc unit
- Endocervical and radial margins should be clear of invasive and in situ disease
- TOC F/U in 6 and 12 months followed by annual surveillance
- If invasive disease clear but in situ present at endocervical or radial then for re-excision for clear margins and to exclude further invasion, if in situ at ectocervical margin re-excision not required

Scenario 6

- 35 year old, P0
- Presents with multiple itchy vulval lesions for a month
- Last cervical screen 6/12 ago HPV positive and low grade dyskaryosis
  - Colposcopy – adequate TZ fully visible, Low grade.
    - for repeat cervical screen in one year

- On examination raised hyperkeratotic lesions seen on both labia majora; most abnormal lesion biopsied

Scenario 6 Colposcopy





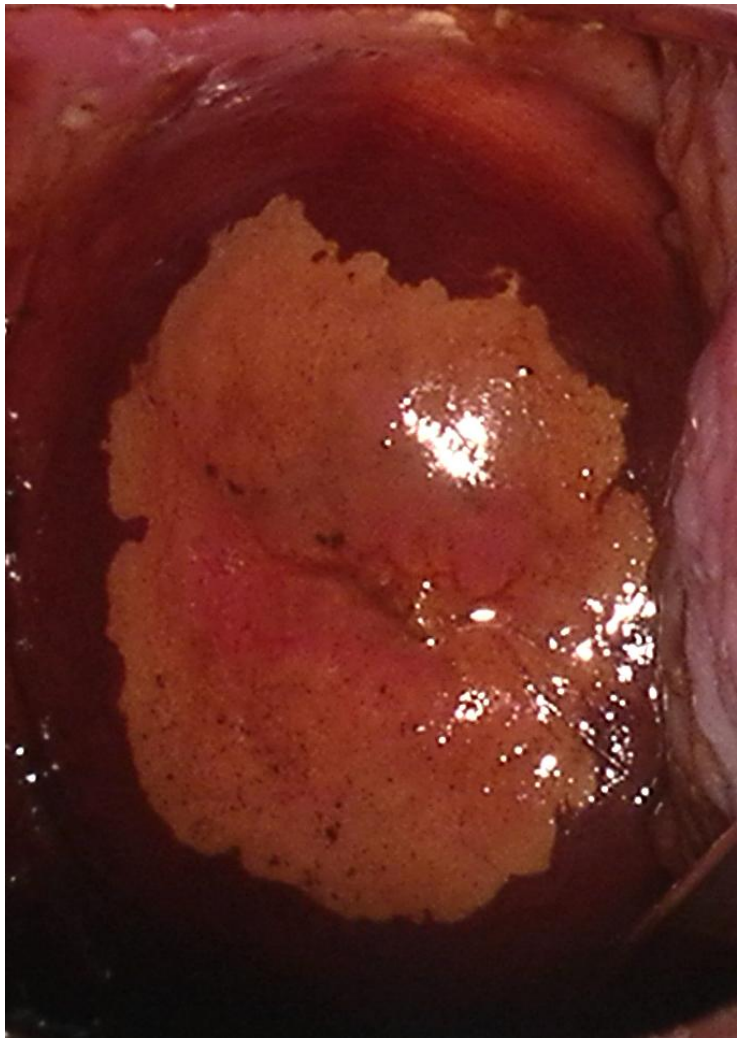

Scenario 6 vulvoscopy



Scenario 6 Histology

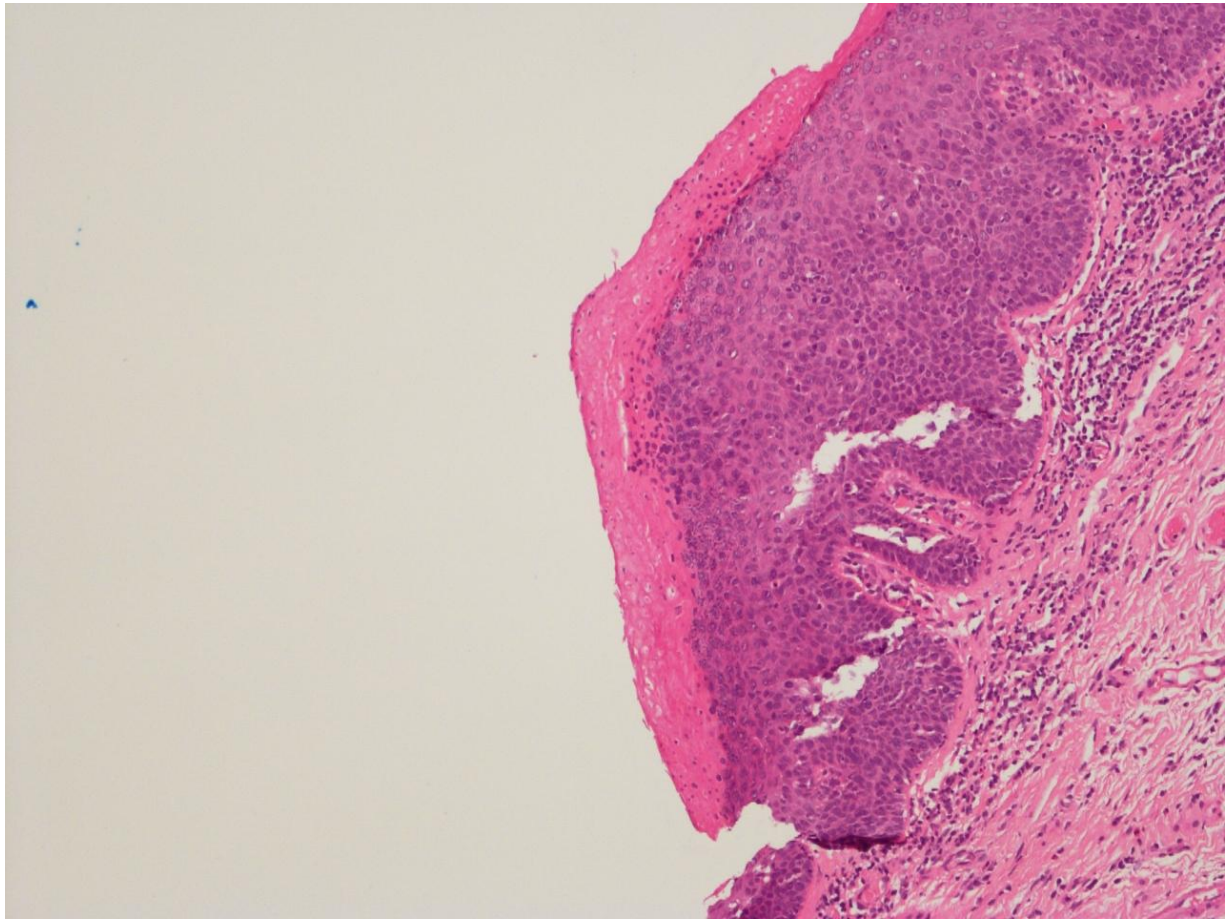

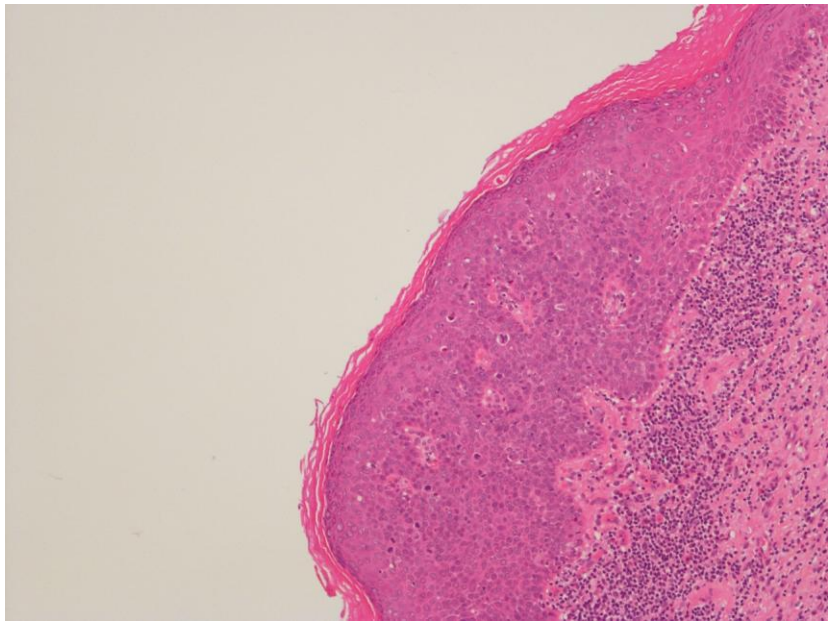

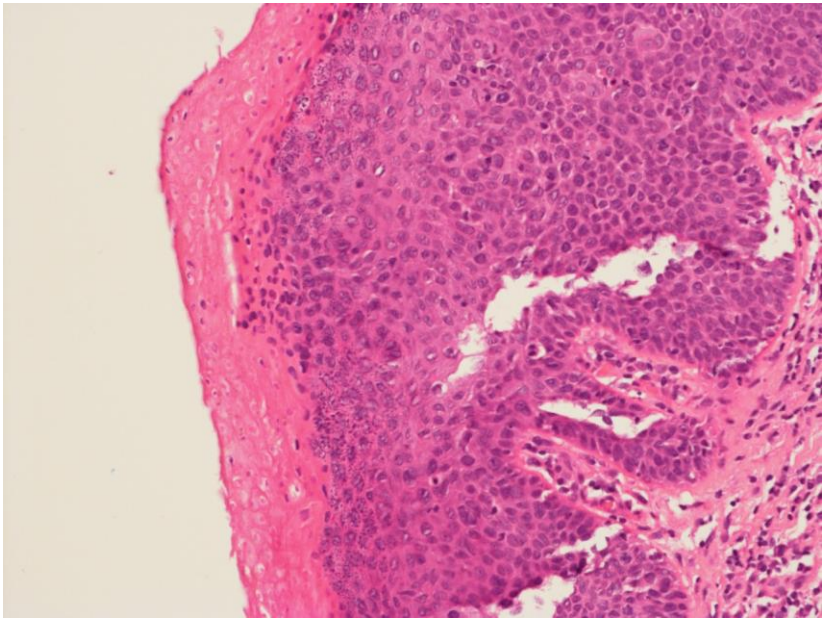

Poll 6 – How would you manage this patient?

- Apply a topical steroid +/- emollients
- 3-4 month course topical imiquimod /Cidofovir/5-Fluoruracil
- Mapping biopsies under anaesthesia
- Wide local excision
- Laser vaporisation / plasmajet ablation
- Photodynamic therapy
- Vulvectomy
- Radiotherapy

Outcome

- Mapping biopsies under anaesthesia +WLE of keratotic lesion
- (DARE advised for all women with VIN/vulval Ca)
- Trial of imiquimod for 3 months
- Re-biopsy at 3months
- Consider laser vaporisation

Scenario 7

- 56 year old with IMB
- History of previous low grade dyskaryosis in the past. Had a colposcopy , no treatment and more than 5 years since last screen due to Covid
- Recent screen HPV positive and severe dyskaryosis
- Had a ‘See & treat’ LLETZ excision

Scenario 7 colposcopy



Margins

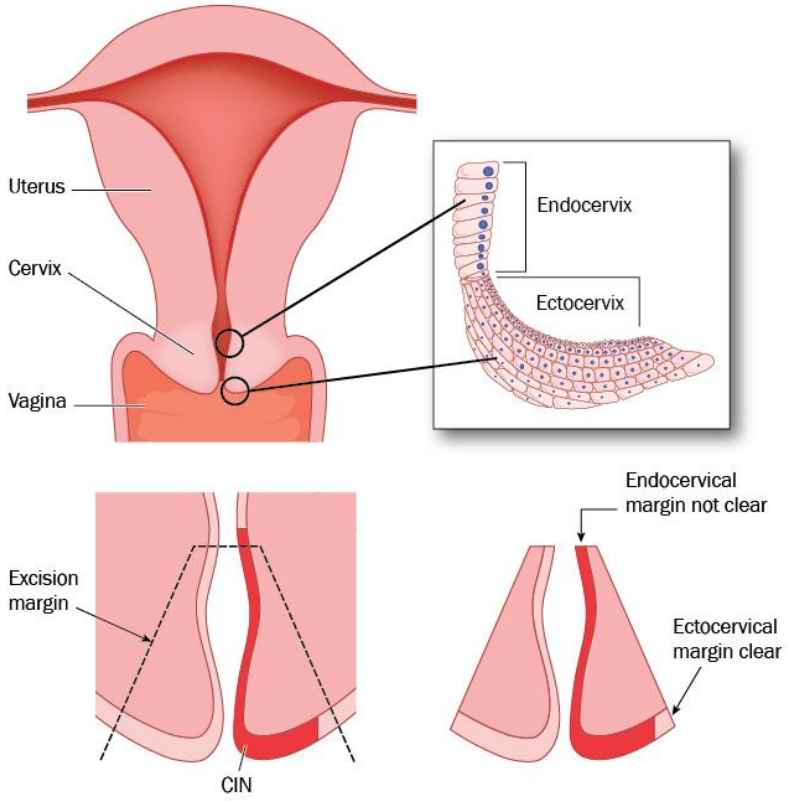
Uterus
Cervix
Vagina
Endocervix
Ectocervix
Excision margin
CIN
Endocervical margin not clear
Ectocervical margin clear

Scenario 7 – histology

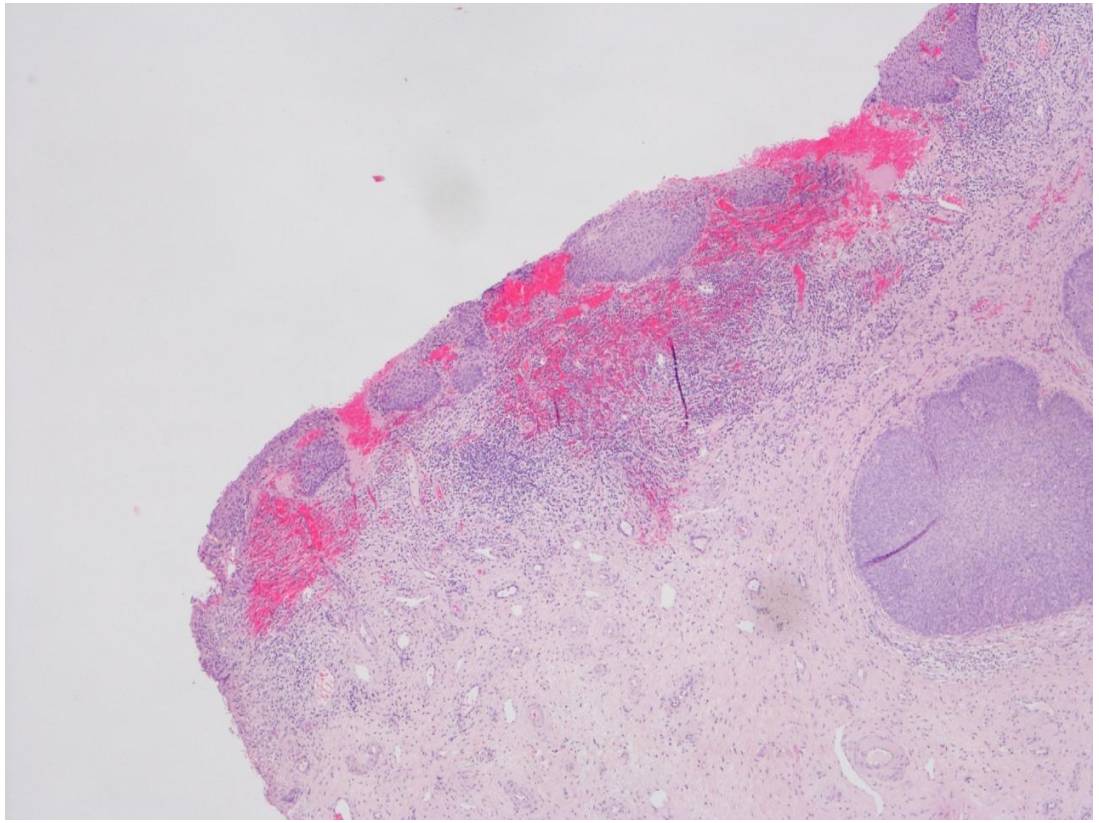

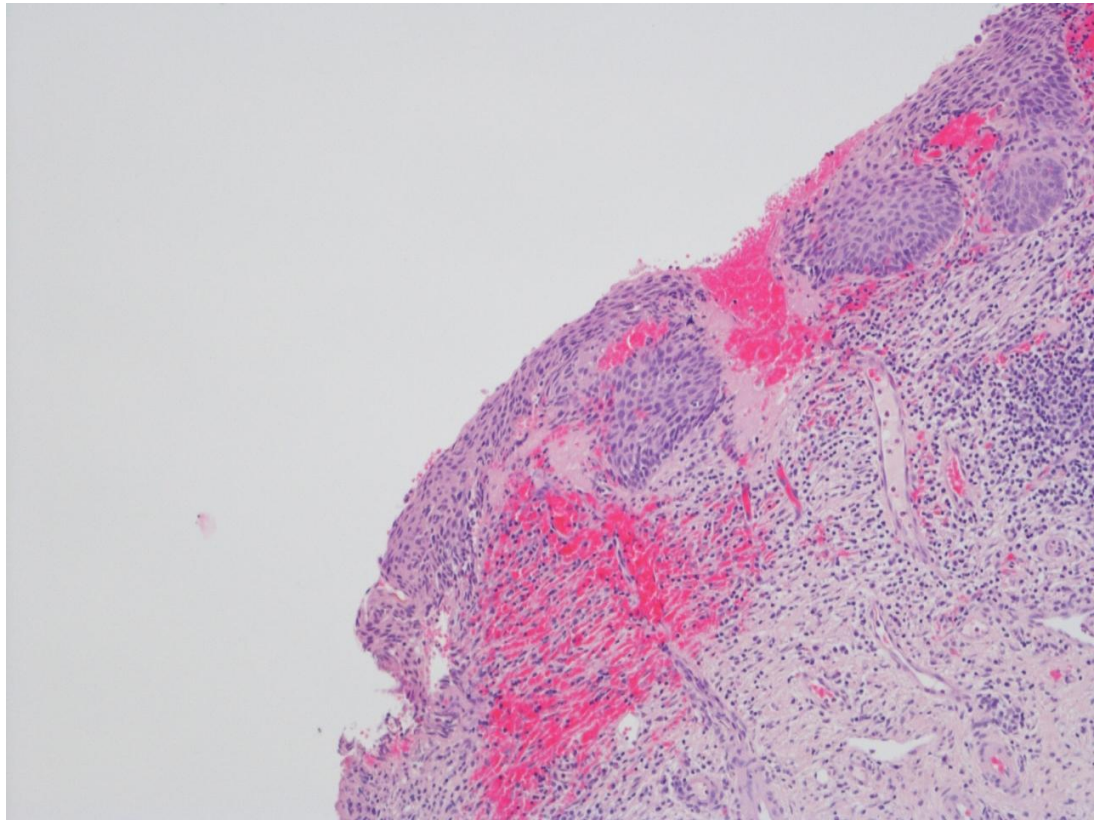

Scenario 7 -histology

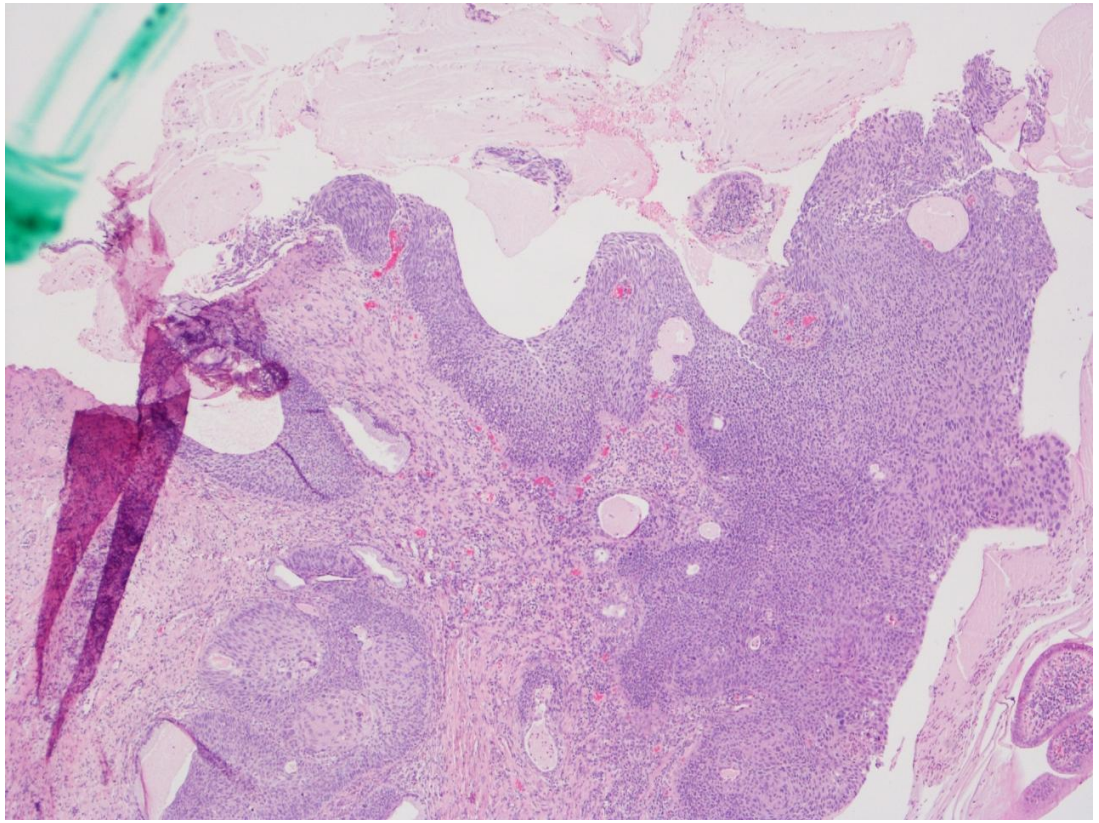

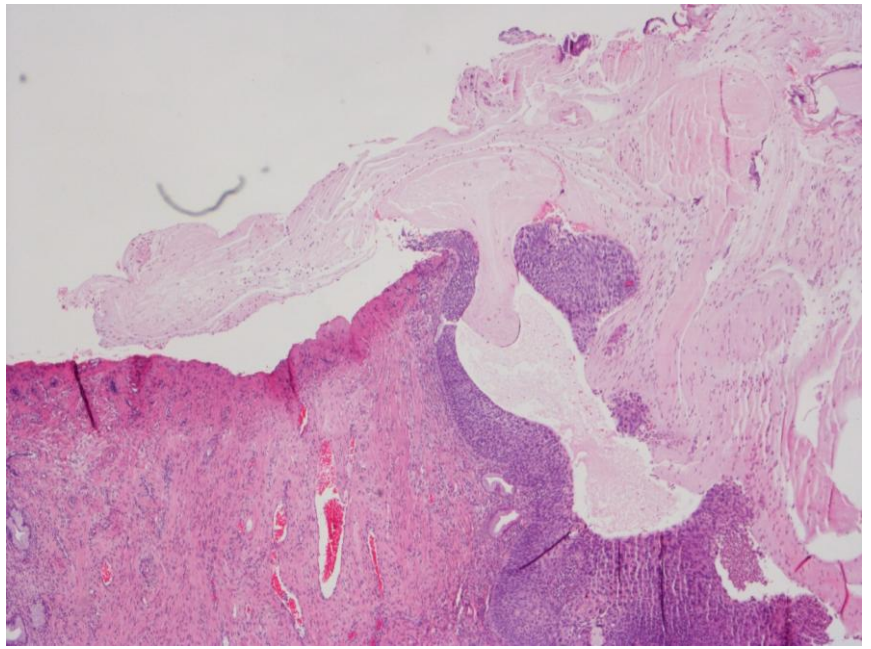

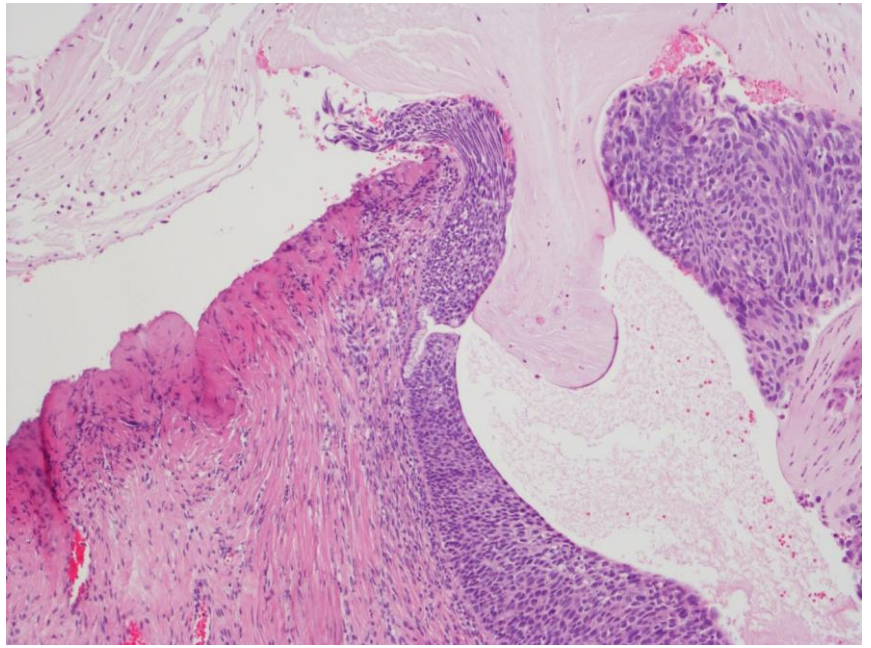

Poll 7 – How would you manage this patient?

- Follow up with cervical sample 6-12 months
- Follow up in 4/6 months with colp and cervical sample
- Follow up in 12 months with colp and cervical sample
- Thermal ablation/cold coagulation
- Cryocautery
- LLETZ
- Knife/Needle/laser cone
- Hysterectomy

Scenario 7 outcome

- As high-grade CIN at deep radial and endocervical margins in a patient >50 years for re-excision for clear margins and because is at higher risk of recurrence

Scenario 8

- 65 year old smoker, monitored for long term history of low grade dyskaryosis
- Last cervical screen in 2022 HPV+/cytology negative
- Never been keen to have hysterectomy as is a full time carer for husband
- At last colposcopy, cervix was flush with vault but looks NAD, TZ3
- Now has current cervical sample taken 2024

Scenario 8 cytology

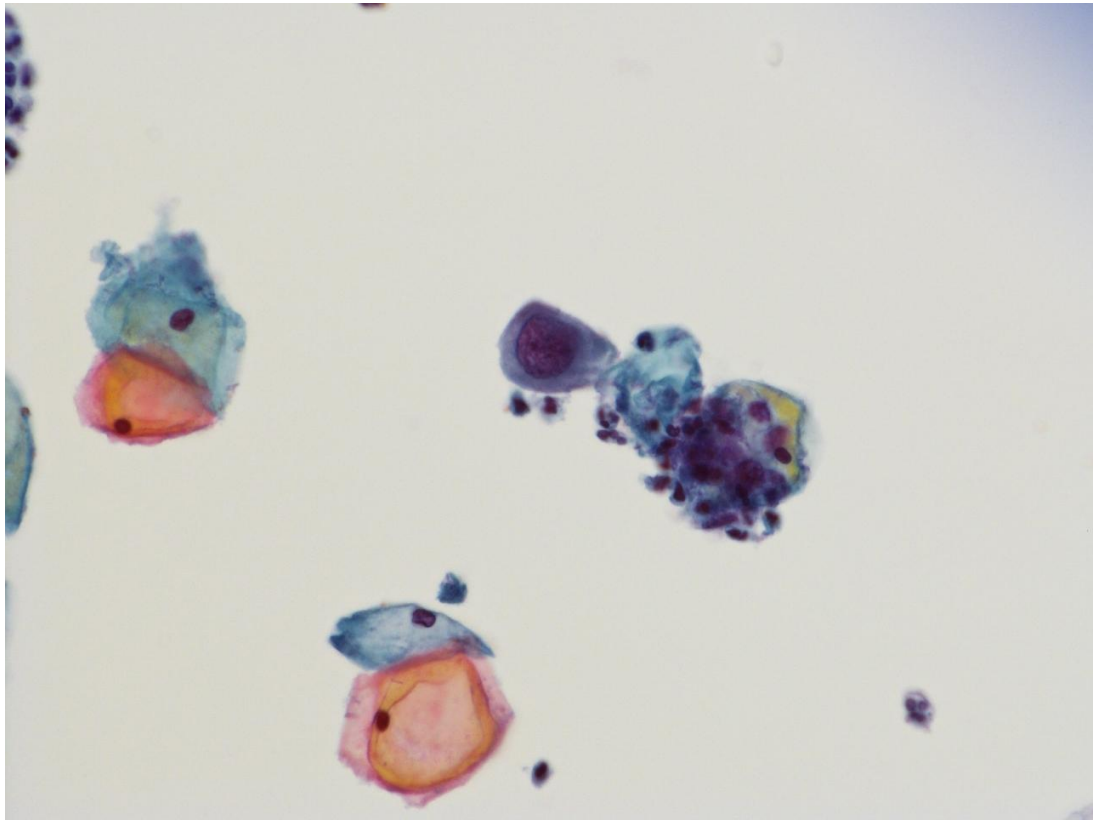

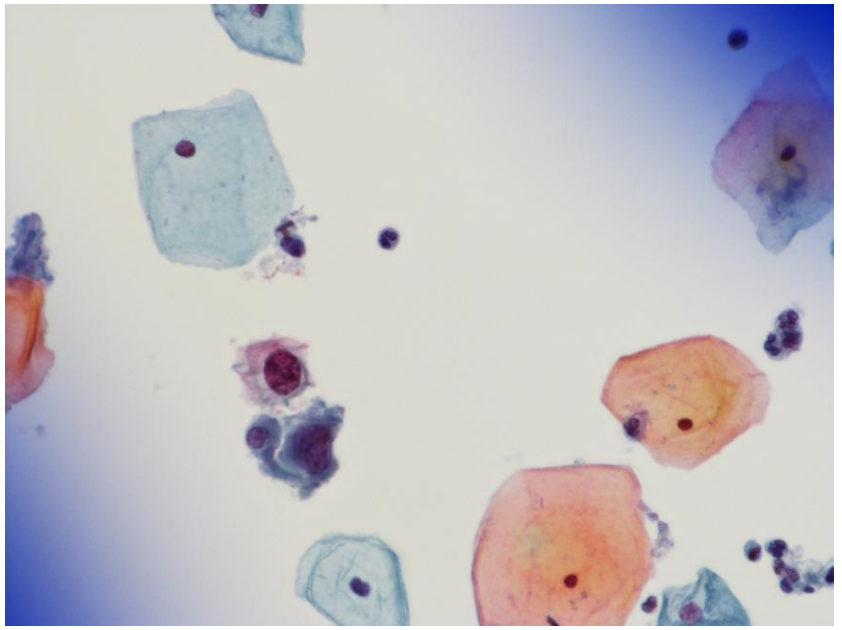

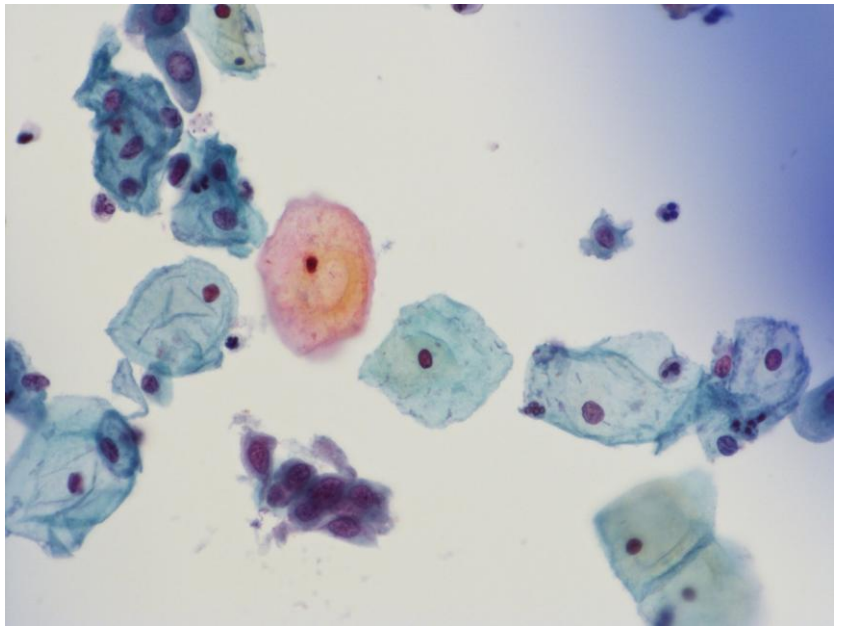

Scenario 8 colp

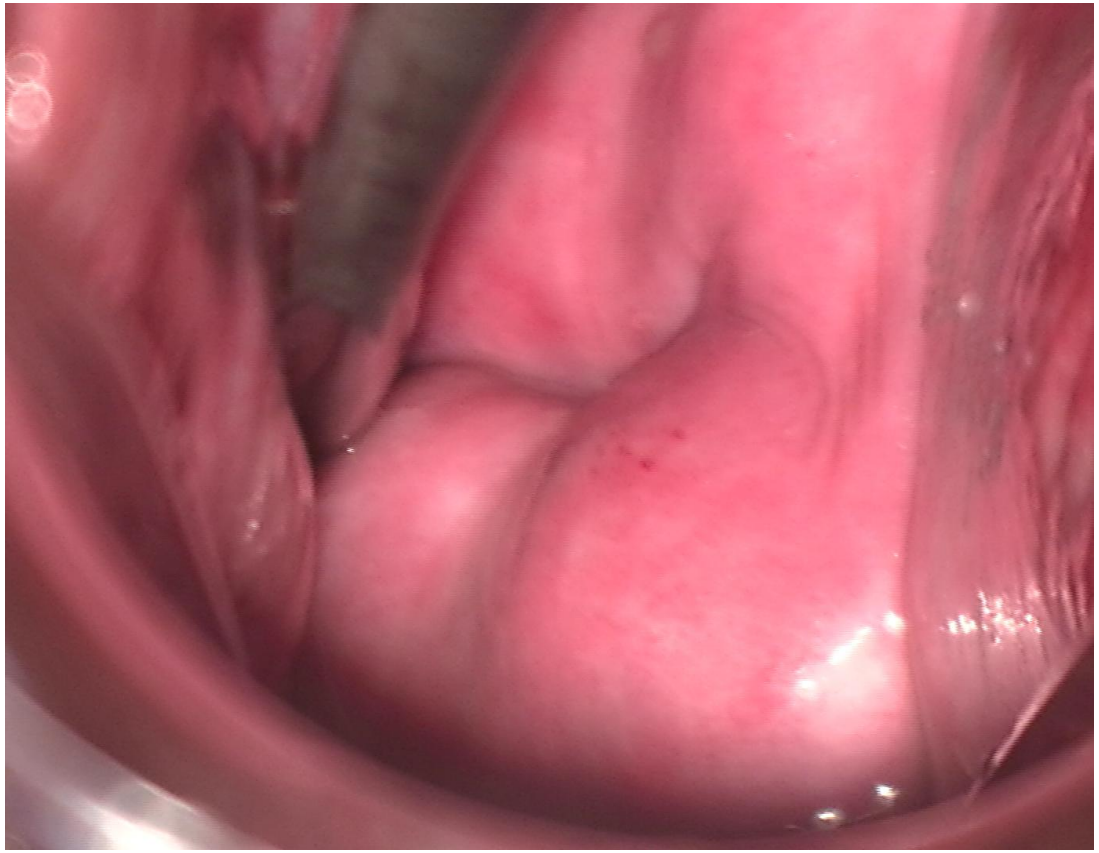

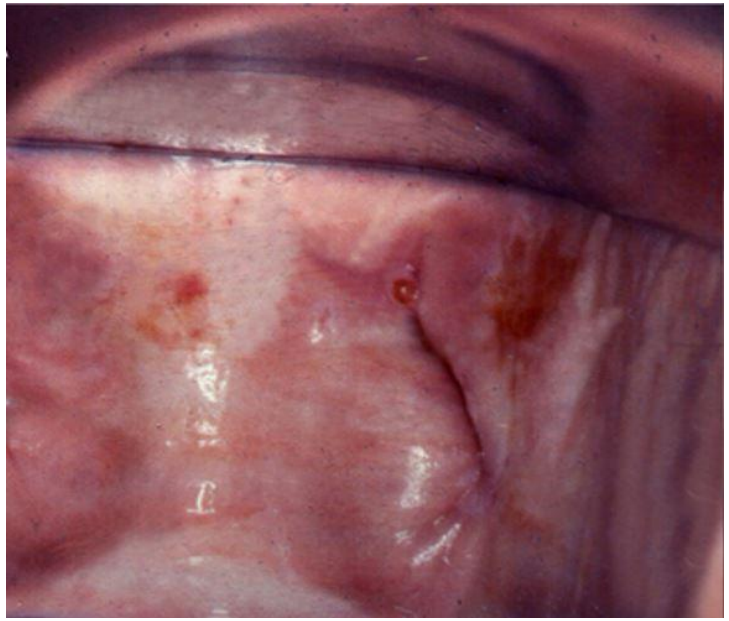

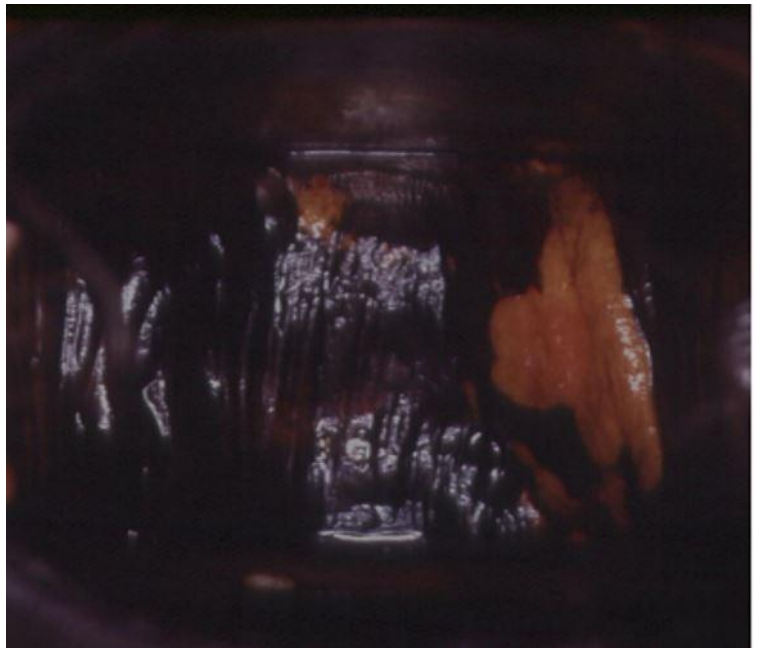

Scenario 8 histology

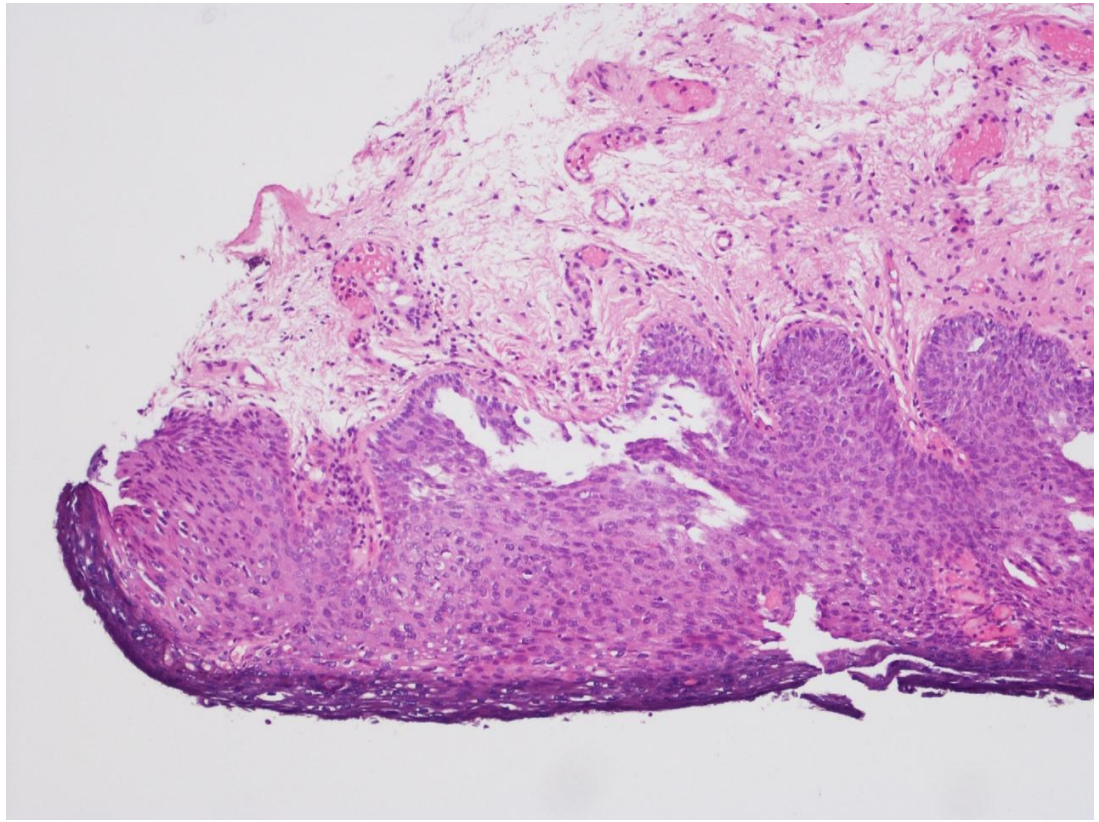

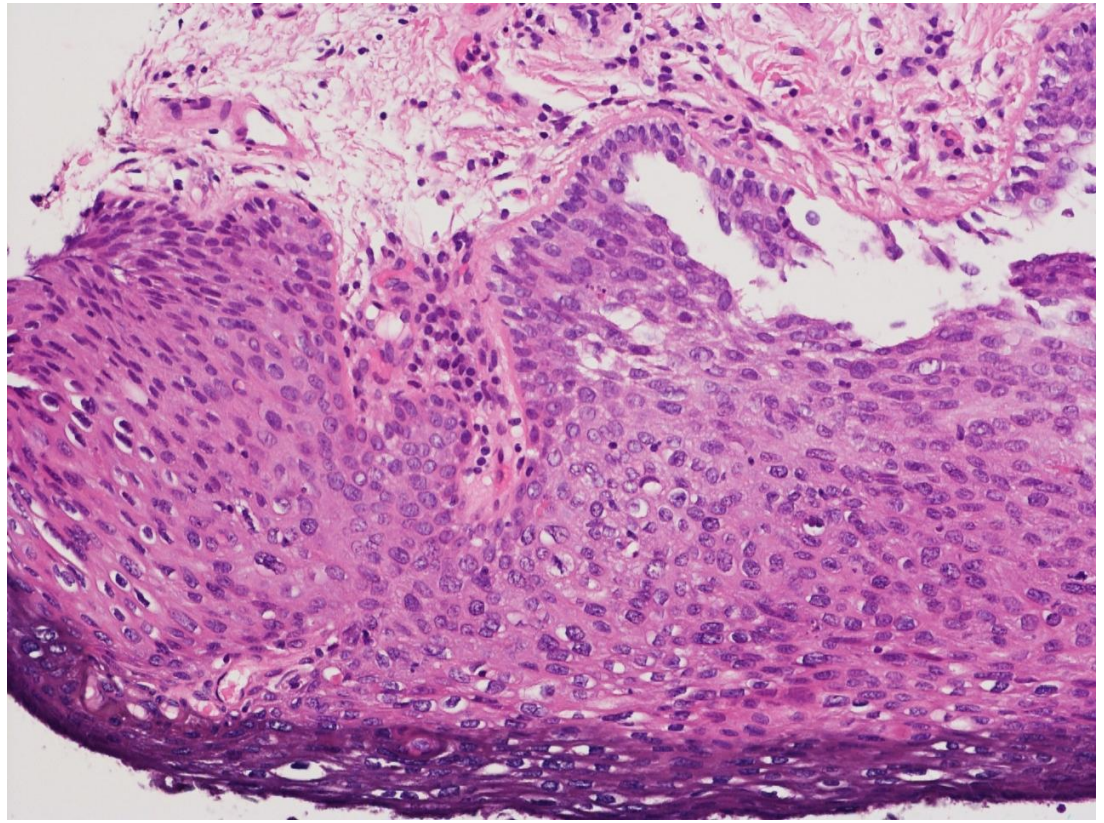

Poll 8 – How would you manage this patient?

- Follow up with cervical sample 6-12 months
- Follow up in 4/6 months with colp and cervical sample
- Follow up in 12 months with colp and cervical sample
- Thermal ablation/cold coagulation
- Cryocautery
- LLETZ
- Knife/Needle/laser cone
- Hysterectomy

Scenario 8 outcome

- Confirmed VaIN 2-3 on vaginal biopsy with a moderate dyskaryotic cytology

- Plan for NETZ/Laser cone in theatre (TZ3) with excision of vaginal area

Scenario 9 – Discordant/mismatch clin hx

- 42 year old with contact bleeding and large abnormal area on cervix noticed on taking cervical sample

- Previous cervical screen history negative

Scenario 9 cytology

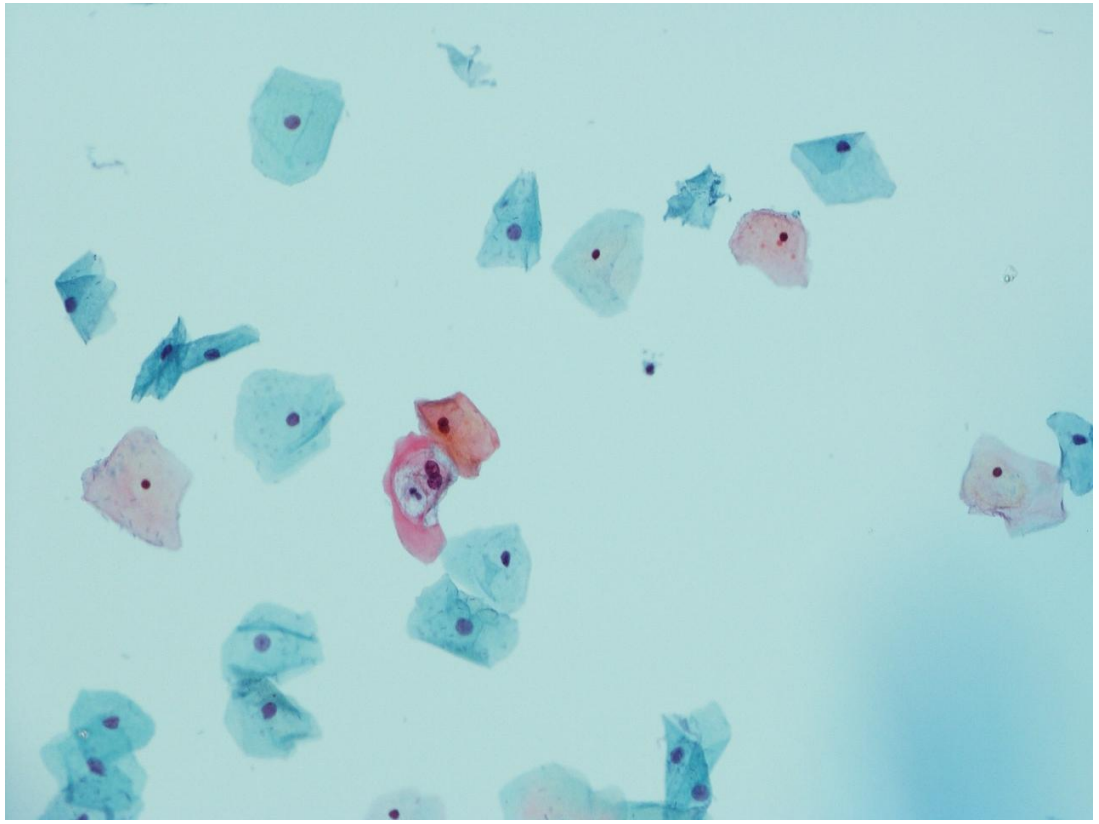

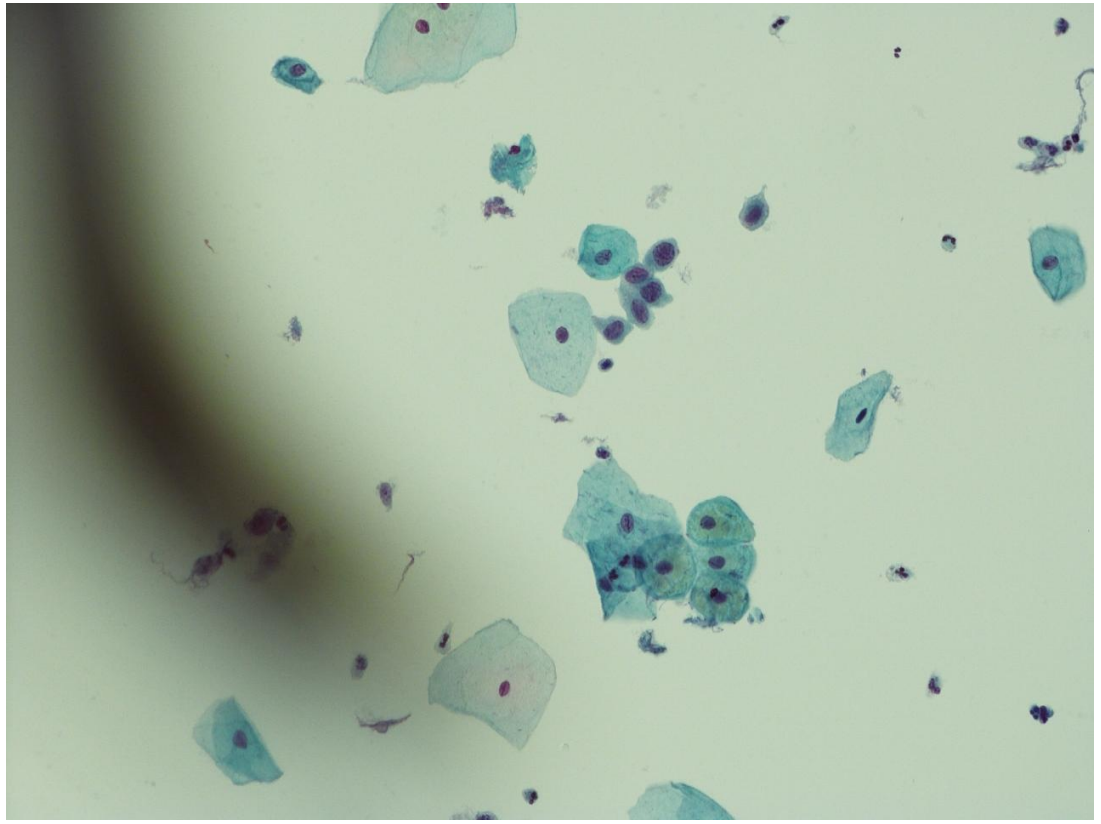

Scenario 9 colposcopy







Scenario 9 histology

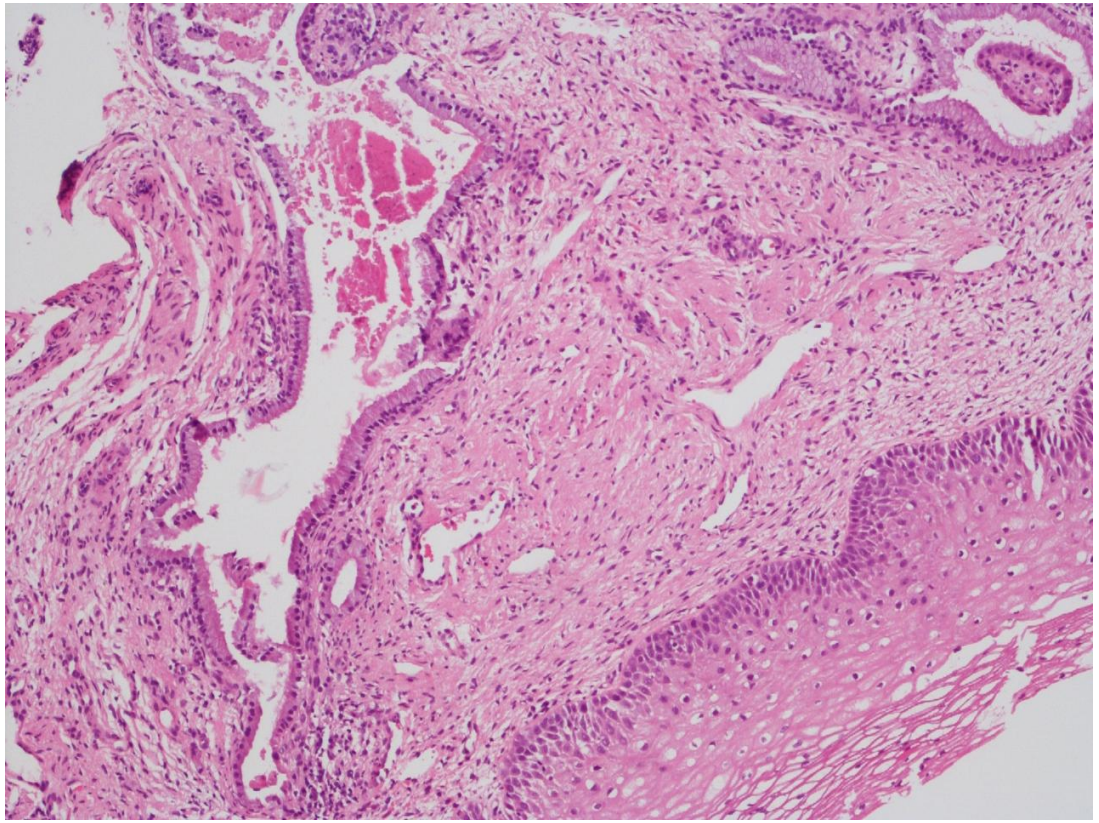

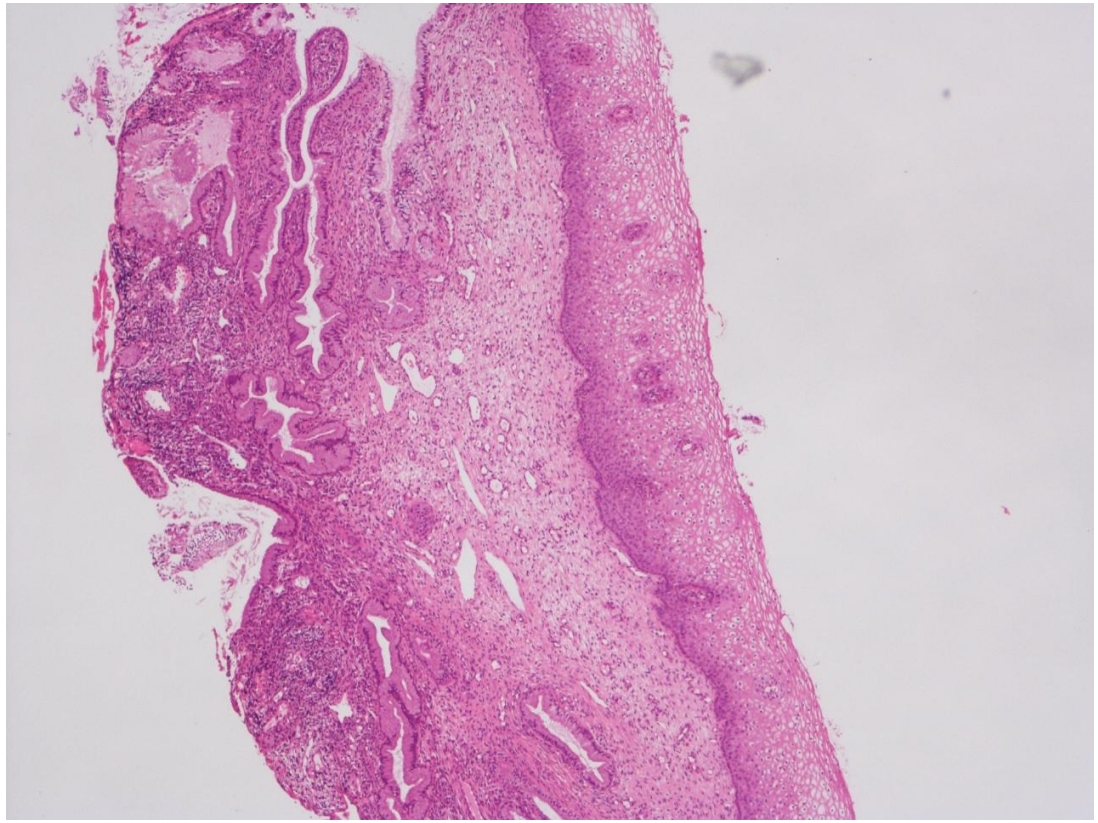

Scenario 9 - histology

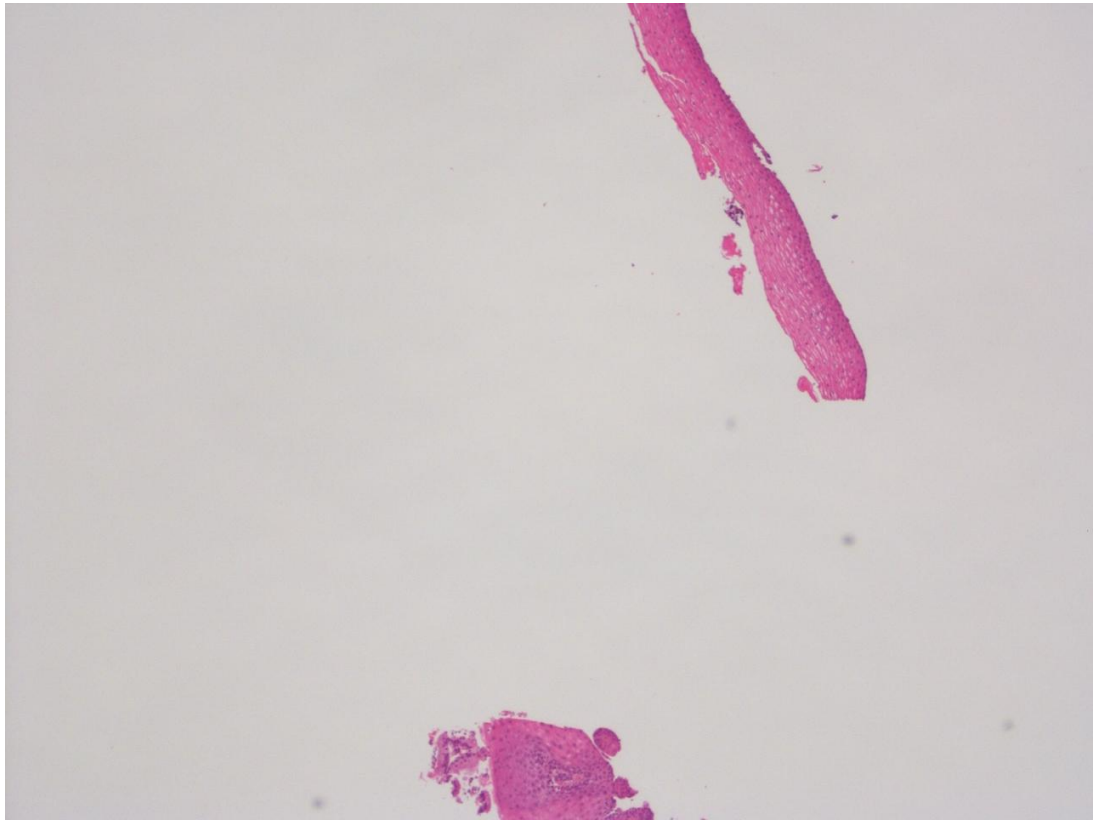

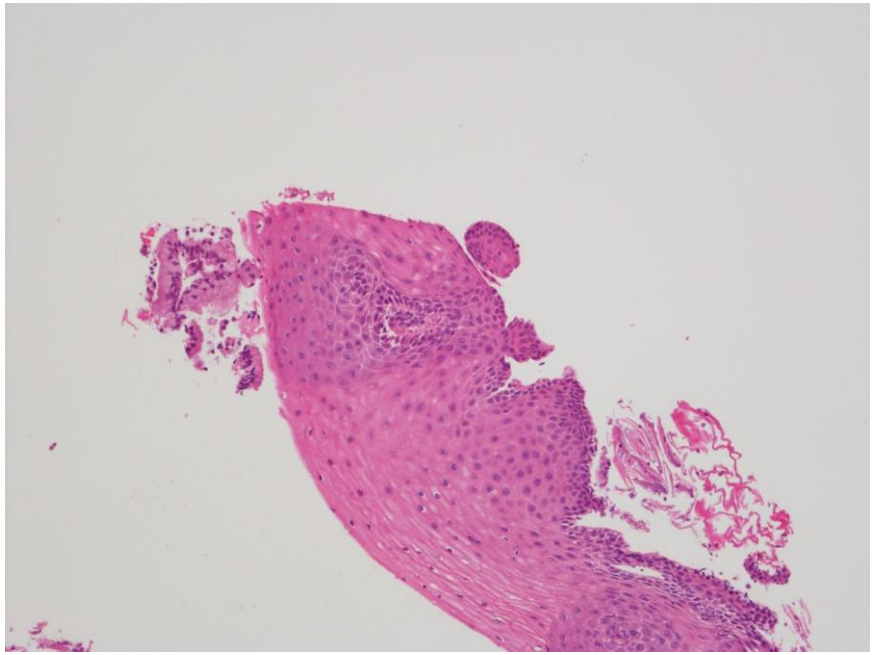

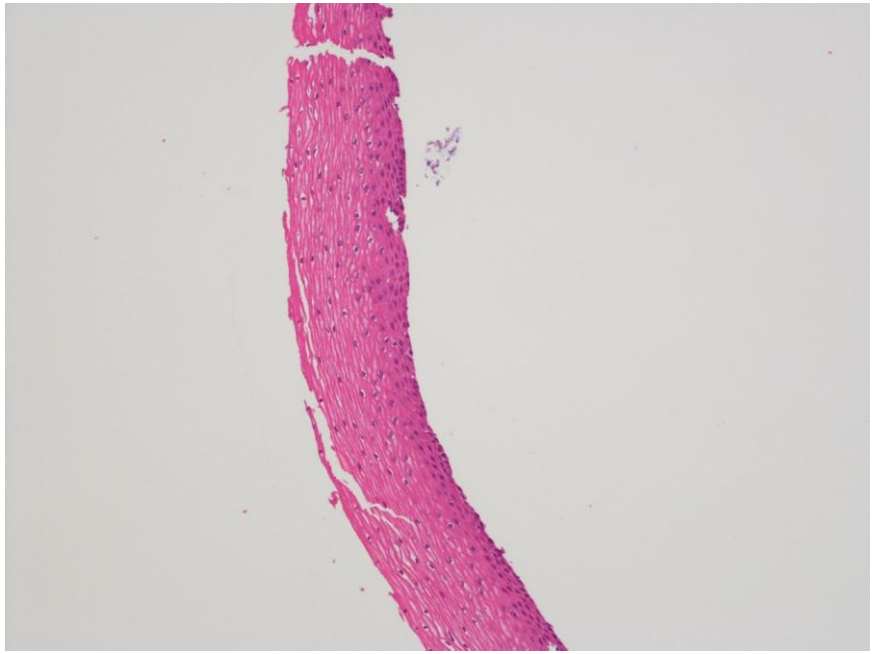

Poll 9 – How would you manage this patient?

- Follow up with cervical sample 6-12 months
- Follow up in 4/6 months with colp and cervical sample
- Follow up in 12 months with colp and cervical sample
- Thermal ablation/cold coagulation
- Cryocautery
- LLETZ
- Knife/Needle/laser cone
- Hysterectomy

Scenario 9 outcome

- Abnormality at colposcopy and high grade cytology confirmed
- Histology (normal) at least 2 grades different from cytology
- For diagnostic LLETZ biopsy


THANK YOU!


QUESTIONS