The British Association of Gynaecological Pathologists

Lecturer – Dr Rachna Khera



Consultant Histopathologist specialising in Gynaecological Pathology at Manchester Royal Infirmary, Manchester University NHS Foundation Trust

The British Association of Gynaecological Pathologists

Gynae Mock Exam

- Title: Macro and OSPE
- Speaker: Dr Rachna Khera
- Affiliation: Manchester University NHS Foundation Trust
- Date: 24 September 2025

The British Association of Gynaecological Pathologists

Speaker disclosures

I have no financial conflicts of interest to disclose

MACRO 1

WHAT IS BEING ASSESSED

- Overall approach to the macroscopic examination
- Ability to select blocks
- Understanding of cancer datasets
- Demonstrate approach to nonneoplastic conditions

62 years female, vulvectomy specimen

Q.1 Describe the specimen and the likely indication for this procedure.

Q.2 Which surgical margins must be examined in this specimen and why?

Q.3 Which macroscopic features in this specimen help determine FIGO stage?

Q.4 Name one common mistake in handling these specimens during grossing.

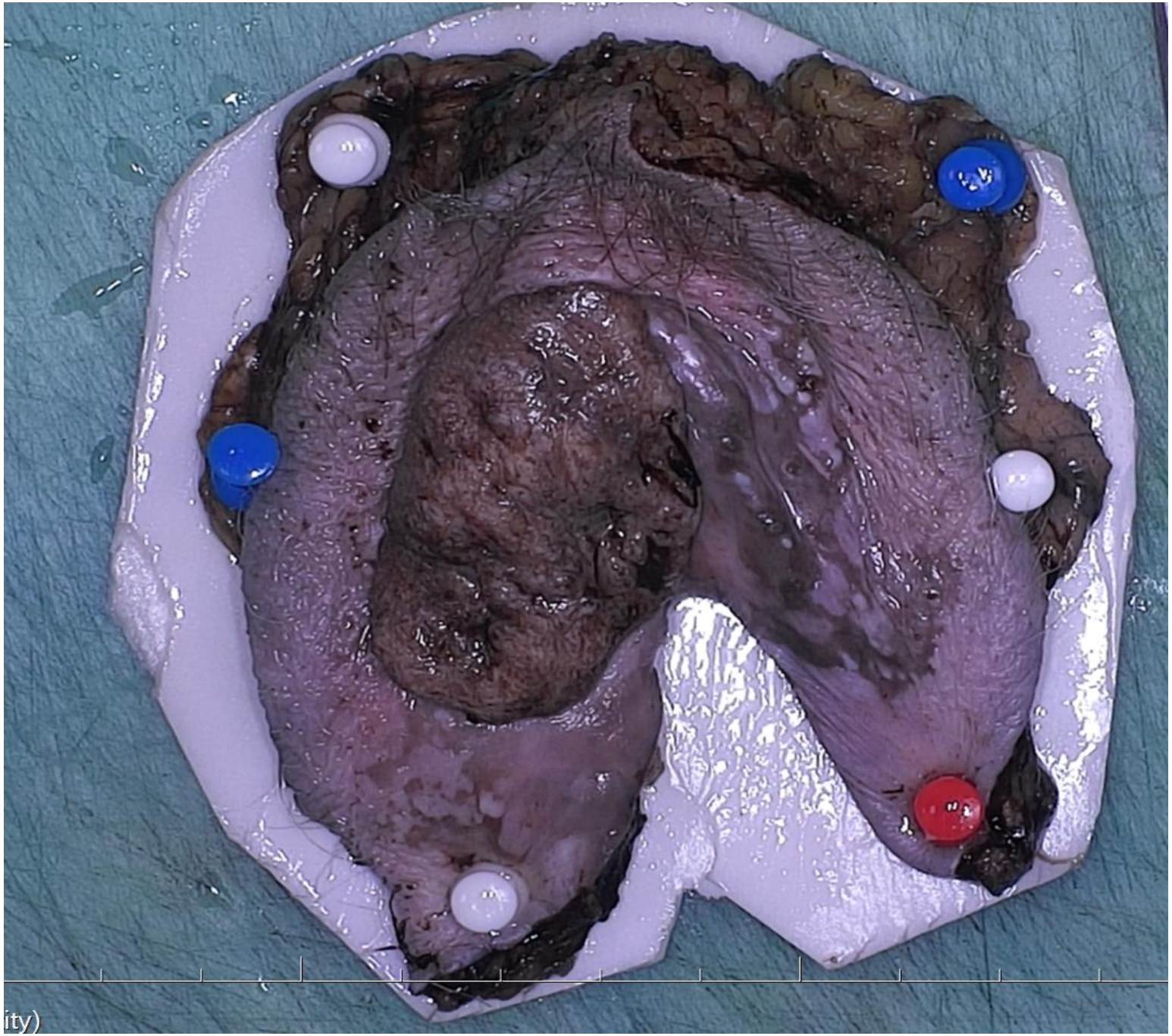

Q.1 Describe the specimen and the likely indication for this procedure.

- This is a Radical vulvectomy specimen mounted on a board, with coloured pins (white, blue and Red)
- It includes vulval skin, mucosa and underlying soft tissue
- Specimen measures *114 x 85 x 24mm*
- There is an *exophytic/ulcerated tumour visible, grey-brown in colour, involving the vulval mucosa.*
- The lesion approximately *52 mm* in maximum dimension
- Note satellite nodules, multifocality, background dermatosis (Lichen sclerosus, VIN)- *surrounding skin shows areas of discoloration and possible dysplasia*

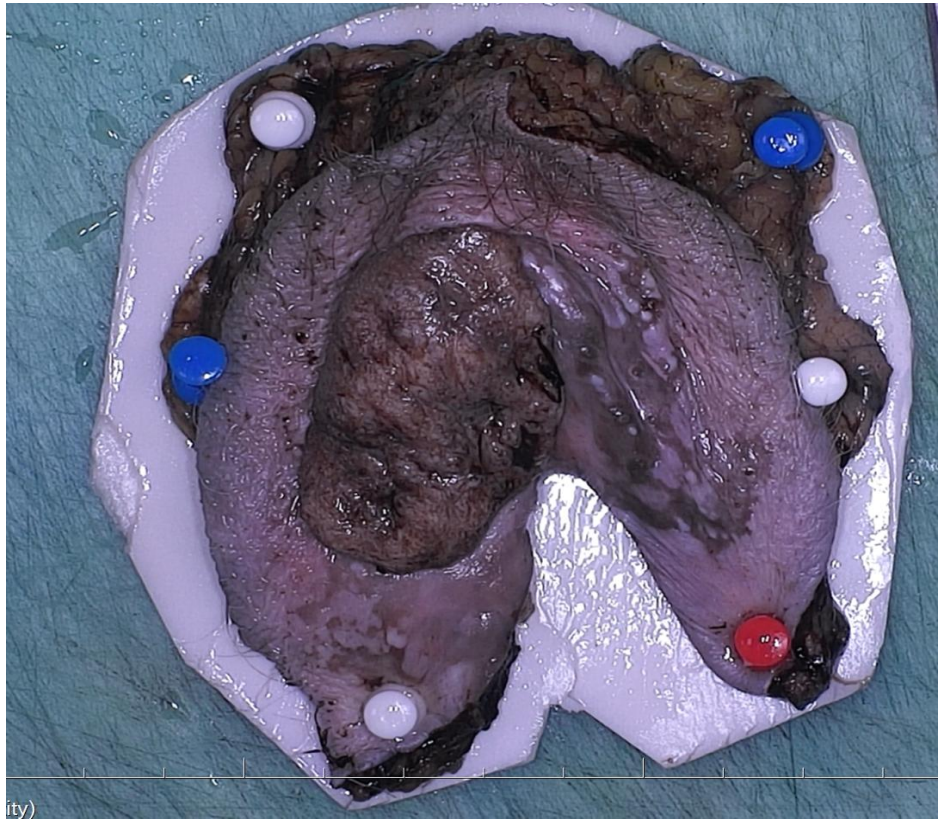

- **Likely Indication:** Most likely Squamous cell carcinoma

- Differential may also include melanoma, Bartholin gland carcinoma, Paget's disease (depending on clinical context)

International Journal of Gynecological Pathology
41:S8–S22, Lippincott Williams & Wilkins, Baltimore
Copyright © 2022 by the International Society of Gynecological Pathologists

Review Article

Data Set for the Reporting of Carcinomas of the Vulva: Recommendations From the International Collaboration on Cancer Reporting (ICCR)

Lynn Hoang, M.D., Fleur Webster, M.Sc., Tjalling Bosse, M.D., Ph.D., Gustavo Focchi, M.D., Ph.D., C. Blake Gilks, M.D., Brooke E. Howitt, M.D., Jessica N. McAlpine, M.D., Jaume Ordi, M.D., Naveena Singh, F.R.C.Path., Richard Wing-Cheuk Wong, F.R.C.P.A., Sigurd F. Lax, M.D., and W. Glenn McCluggage, F.R.C.Path.

Dataset for histopathological reporting of vulval carcinomas

November 2023

Authors: Dr Asma Faruqi, Barts Health NHS Trust, London
Dr Brian Rous, Cambridge University NHS Foundation Trust, Cambridge

CORE DATA ITEMS

TABLE 1. *Core data elements for pathological reporting of resection specimens of primary carcinomas of the vulva*

Clinical	Macroscopic	Microscopic	Other
Clinical information	Specimen dimensions	Histologic tumor type	Ancillary studies
History of previous cancer	Tumor site*	Lymphovascular invasion	p16 immunohistochemistry and/or HPV testing for squamous cell carcinoma
Prior neoadjuvant therapy	Tumor dimensions	Margin status	
Operative procedure	Maximum horizontal tumor dimension	Margin status and distances for invasive tumor	
	Depth of invasion	Margin status for precursor lesion†	
		Lymph node status	
		Sentinel and nonsentinel lymph nodes	
		Number of nodes examined	
		Number of positive nodes	
		Size of maximum tumor deposit	
		Extracapsular spread	
		Coexistent pathology/precursor lesions	
		Low-grade squamous intraepithelial lesion	
		High-grade squamous intraepithelial lesion	
		Vulval intraepithelial neoplasia, HPV-independent	
		Lichen sclerosus	
		Pathologically confirmed distant metastasis	
		Provisional pathologic staging	
		FIGO or TNM staging (UICC/AJCC 8th edition)	

*Specification of tumor site as left vulva, right vulva, midline, and extension into adjacent structures is considered core; subdivision of the right and left vulva into labium majus, labium minus and Bartholin gland is considered noncore (Table 2).
†For the precursor lesion, status of the margin (involved vs. not involved) is a core element, the distance of the precursor to the margin is considered noncore (Table 2).

International Journal of Gynecological Pathology 41:S8–S22, Lippincott Williams & Wilkins, Baltimore Copyright © 2022 by the International Society of Gynecological Pathologists

Rcpath dataset 2023

Specimen dimensions

- Documentation of specimen size in 3 dimensions in millimetres allows correlation between clinical appearances of the specimen, macroscopic assessment and microscopic assessment, reducing the risk of laboratory error.
- It also gives clinicians dealing with the patient an indication as to how radical the resection was.

Tumour site

- The report should include the anatomical subsites involved, the laterality **(left/right/midline) and the extension into any adjacent structures:** CORE

- Specification of tumour site as right vulva, left vulva, midline and the extension into adjacent structures is considered core, subdivision into left labium majus, minus, and Bartholin gland is non-core

Tumour dimensions

Maximum horizontal dimension
Size is an important prognostic factor and is included in FIGO staging.

For large specimens, it may not be practical to measure microscopic size across multiple slides; in these circumstances, the macroscopic size may be more accurate.

The maximum horizontal dimension is measured parallel to the skin and/or mucosal surface. *All measurements should be in millimetres*.

The final pathology report should contain only 1 set of measurements after correlation between both macroscopic and microscopic assessment, with gross examination being more important for some tumor measurements and microscopic examination for others.

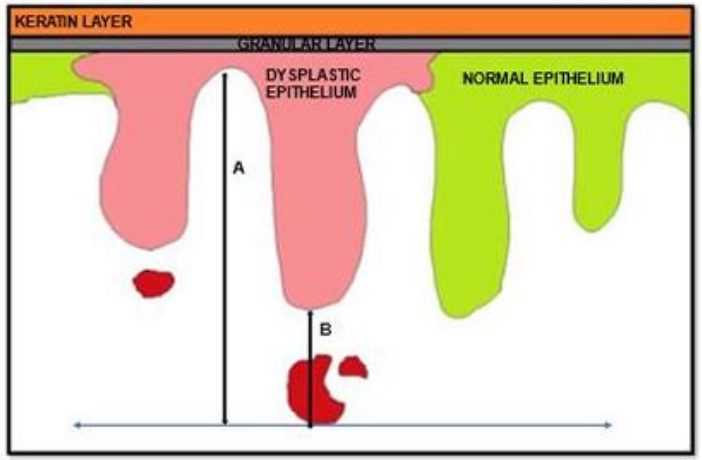

Figure 2: Measurement of depth of invasion in vulval carcinoma. A. Conventional method (FIGO, 2009): from the adjacent most superficial dermal papilla to the deepest point of invasion. B. Recommended method (FIGO, 2021): from the basement membrane of the deepest adjacent dysplastic rete peg to the deepest point of invasion.

[Level of evidence B – Depth of invasion is an independent prognostic factor.][20,41,42]

Sampling

Block selection (RCPATH)

This should include:

- ❑ adequate tumour sampling (a representative megablock may be helpful). *One block/10mm of tumour.* Tumour blocks: include deepest invasion, ulcer edge, and surface epithelium
- ❑ sampling of the closest margin(s) to the tumour
- ❑ representative blocks of any non-neoplastic epithelial abnormality
- ❑ any other incidental abnormality.

Q.2 Which surgical margins must be examined in this specimen and why?

To assess completeness of excision and risk of recurrence

Peripheral mucocutaneous margins:

- Involvement of a peripheral (skin, mucosal) surgical margin by tumor should be recorded and the margin specified if possible.
- The minimum distance from invasive carcinoma to the peripheral margin should be reported and the margin specified if possible.

Deep soft tissue margin: The minimum distance of invasive tumor to the deep soft tissue margin should also be recorded.

In general, this should be measured from the deepest infiltrating tumor nest to the deep soft tissue margin.

However, if the deep margin is irregular, the closest deep margin may not necessarily be at the point of deepest invasion; in such cases, this should be taken into account when providing this measurement.

ICCR

- This peripheral surgical margin should be roughly perpendicular to the skin/mucosal surface; this includes the epithelial surface and deeper soft tissue.
- The peripheral margin should be measured toward the peripheral stromal edge or surface-epithelial edge, whichever is shorter.
- The minimum peripheral margin should be measured through tissue and preferably in a straight uninterrupted line; however, in some situations (collarette), a composite measurement including separate linear measurements joined at an angle may be required.
- Measuring the distance to the margin by a curved line in the context of an irregular surface, which is now possible due to the increased use of digital pathology, is not recommended, unless this is felt to represent a truer measurement, for example, when a length of uninvolved skin is embedded curved/folded in order to fit into a paraffin block.
- Involvement of a peripheral margin by a high-grade precursor lesion [HPV-associated high-grade squamous intraepithelial lesion (HSIL) or HPV independent vulval intraepithelial neoplasia (VIN)] should be recorded and the margin specified if possible; p53 immunohistochemical staining may be of value in assessing margin involvement by HPV-independent VIN
- Margin involvement by a low-grade precursor lesion [low-grade squamous intraepithelial lesion (LSIL)] does not need to be recorded
- The minimum distance of invasive tumor to the deep soft tissue margin should also be recorded. In general, this should be measured from the deepest infiltrating tumor nest to the deep soft tissue margin. However, if the deep margin is irregular, the closest deep margin may not necessarily be at the point of deepest invasion; in such cases, this should be taken into account when providing this measurement.

Q.3 Which macroscopic features in this specimen help determine FIGO stage?

- Tumour size (</=2cm vs >2cm)
- Depth of invasion
- *Involvement of adjacent structures (urethra, vagina, anus)*
- Presence of lymph nodes with metastasis

FIGO stage	FIGO 2018 Description	FIGO 2021 Description
I	Tumor confined to the vulva	Tumor confined to the vulva
IA	Lesions ≤2 cm in size, confined to the vulva or perineum and with stromal invasion ≤1.0 mm, no nodal metastasis	Tumor size ≤2 cm and stromal invasion ≤1 mm
IB	Lesions >2 cm in size or with stromal invasion >1.0 mm, confined to the vulva or perineum, with negative nodes	Tumor size >2 cm or stromal invasion >1 mm
II	Tumor of any size with extension to adjacent perineal structures (lower third of urethra, lower third of vagina, anus) with negative nodes	Tumor of any size with extension to lower one-third of the urethra, lower one-third of the vagina, lower one-third of the anus with negative nodes
III	Tumor of any size with or without extension to adjacent perineal structures (lower third of urethra, lower third of vagina, anus) with positive inguinofemoral nodes	Tumor of any size with extension to upper part of adjacent perineal structures, or with any number of nonfixed, nonulcerated lymph node
IIIA	1. With 1 lymph node metastasis (≥5 mm), or 2. With 1–2 lymph node metastasis(es) (<5 mm)	Tumor of any size with disease extension to upper two-thirds of the urethra, upper two-thirds of the vagina, bladder mucosa, rectal mucosa, or regional lymph node metastases ≤5 mm
IIIB	1. With 2 or more lymph node metastases (≥5 mm), or 2. With 3 or more lymph node metastases (<5 mm)	Regional lymph node metastases >5 mm
IIIC	With positive nodes with extracapsular spread	Regional lymph node metastases with extracapsular spread
IV	Tumor invades other regional (upper 2/3 urethra, upper 2/3 vagina), or distant structures	Tumor of any size fixed to bone, or fixed, ulcerated lymph node metastases, or distant metastases
IVA	1. Tumor invades any of the following: upper urethral and/or vaginal mucosa, bladder mucosa, rectal mucosa, or fixed to pelvic bone, or 2. Fixed or ulcerated inguinofemoral lymph nodes	Disease fixed to pelvic bone, or fixed or ulcerated regional lymph node metastases
IVB	Any distant metastasis including pelvic lymph nodes	Distant metastases

MAJOR CHANGES

Method used to measure stromal invasion has changed

Stage III now includes involvement of upper perineal structures, bladder mucosa & rectal mucosa [previously designated as stage IV]

Stage III now considers only size of lymph node metastases (≤5 mm or >5 mm), the number of lymph nodes is no longer considered

Imaging can be used to assign stage, and is given the prefix (r)

FIG. 2. Changes between FIGO 2018 and 2021 staging systems. FIGO indicates International Federation of Obstetricians and Gynaecologists.

Q.4 Name one common mistake in handling these specimens during grossing.

- Not orienting the specimen correctly before sectioning
- Failing to ink margins before cutting
- Not measuring tumour to margins distances

MACRO 2

Total hysterectomy from a 59-year-old woman

1. Describe the specimen.
2. What are the likely presenting symptoms?
3. What is the likely diagnosis?
4. How many blocks would you sample?
5. Where would you take the blocks from?

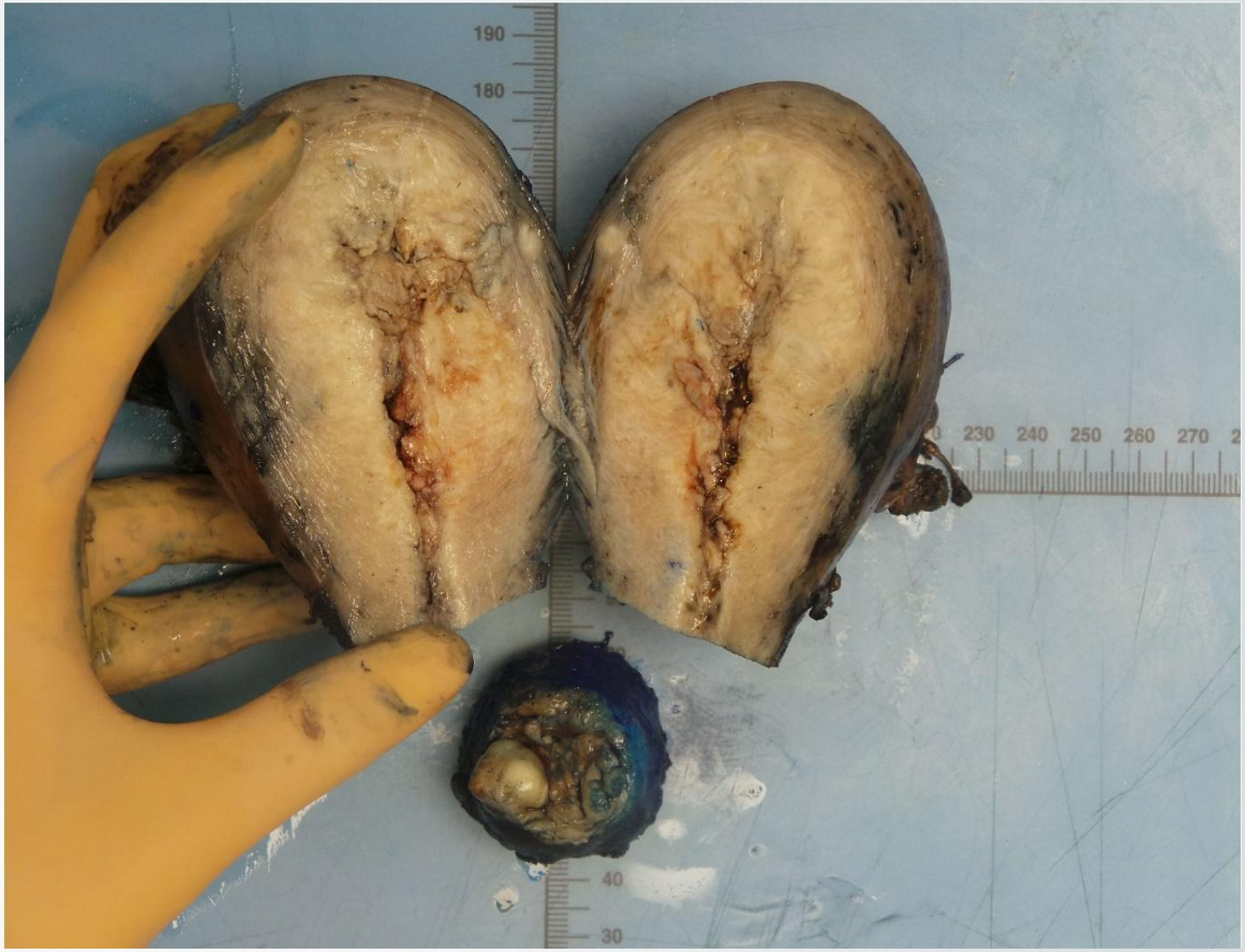

TABLE 1. *Core data elements for pathological reporting of carcinoma of the endometrium*

Clinical	Macroscopic	Microscopic	Other
Operative procedure	Specimen(s) submitted	Histologic tumor type*	Ancillary studies†
		Histologic tumor grade	Mismatch repair testing
		Myometrial invasion‡	
		Lymphovascular invasion	
		Extent of lymphovascular invasion	
		Cervical stroma§	
		Parametria	
		Vagina	
		Omentum	
		Peritoneal biopsies	
		Site(s) of involvement	
		Uterine serosa	
		Adnexa	
		Site(s) of involvement	
		Margin status‖	
		Margin status for paracervical soft tissue margin	
		Margin status for ectocervical/vaginal cuff margin	
		Lymph node status	
		Maximum dimension of largest deposit in regional node	
		Sentinel, pelvic and para-aortic regional node(s)	
		Laterality	
		Number of nodes examined	
		Number of positive nodes	
		Degree of involvement	
		Pathologically confirmed distant metastasis	
		Provisional pathologic staging	
		FIGO or TNM staging (UICC/AJCC 8th edition)	

*Histologic tumor type is core; neuroendocrine carcinoma subtype, epithelial and sarcomatous percentage, homologous or heterologous is considered noncore.

†Reporting of whether ancillary studies were performed, and any mismatch repair testing undertaken is a core element; reporting of other immunohistochemistry, molecular findings, the Cancer Genome Atlas (TCGA)-based molecular classification, other tests and representative blocks for ancillary studies are considered noncore (Table 2).

‡Specification of presence or absence of myometrial invasion and whether $<50\%$ or $\geq 50\%$ is core; pattern of myometrial invasion, absolute percentage of myometrial wall thickness invaded by carcinoma and distance of myoinvasive tumor to serosa are considered noncore (Table 2).

§Cervical stromal involvement is core; depth of cervical stromal invasion and percentage of cervical stromal invasion are considered noncore (Table 2).

‖Involvement of paracervical soft tissue margin and ectocervical/vaginal cuff margin is core; the distance of tumor to the closest margin is considered noncore (Table 2).

Pathological core data: macroscopic data items

- Details of hysterectomy specimen; attached anatomical structures may include vaginal cuff, ovaries, fallopian tubes or parametria

- Accompanying specimens:
  - The omentum, if received, should be measured and the presence and dimensions of the largest visible deposit recorded.
  - Lymph nodes : sentinel lymph nodes, pelvic and para-aortic lymph nodes
  - Peritoneal washings
  - Peritoneal biopsies from various sites

Pathological core data: macroscopic data items

Tumour details:

- Maximum dimension
- Myometrial invasion
- Serosal surface involvement.
- Cervical involvement
- Parametrial involvement

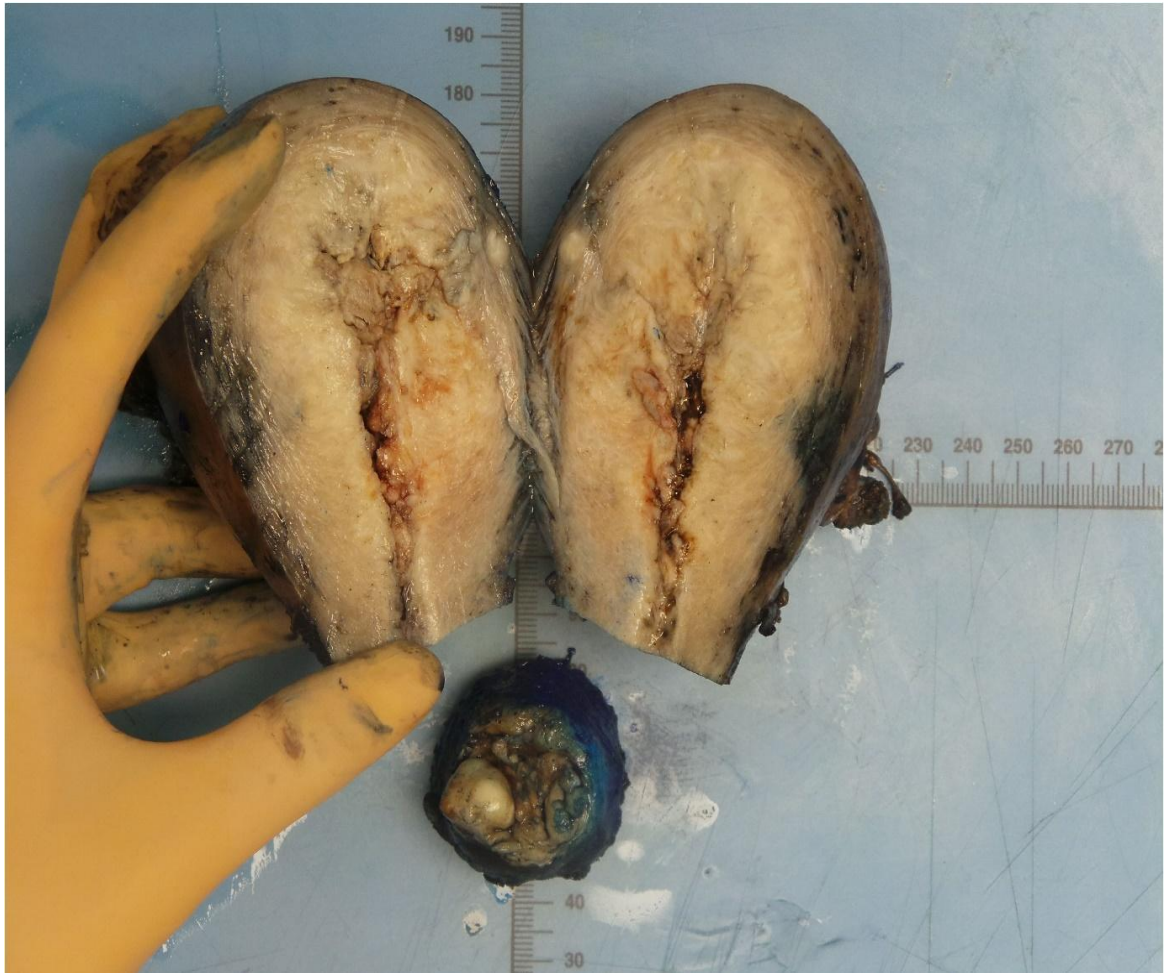

Macroscopic non-core data items

- Specimen weight and measurements

- Location of tumour: LUS/isthmus, body, fundus or cornu.

    - Approximately 14% of endometrial carcinomas arise in the LUS/isthmus. An isthmic location is seen more commonly in association with hereditary non-polyposis colorectal cancer syndrome/Lynch syndrome.
    - LUS involvement has also been shown to be an independent prognostic factor in conferring a higher risk of adverse outcomes including distant recurrence and death

A word about margins

- Parametrium
- Vaginal cuff margins- if tumour invades cervix
- Serosa is not a ‘true margin’ but is important for Staging

- *Inking of peritoneal and/or nonperitoneal surfaces is recommended in hysterectomy specimens and is essential in radical hysterectomy specimens in which a vaginal cuff is present*.

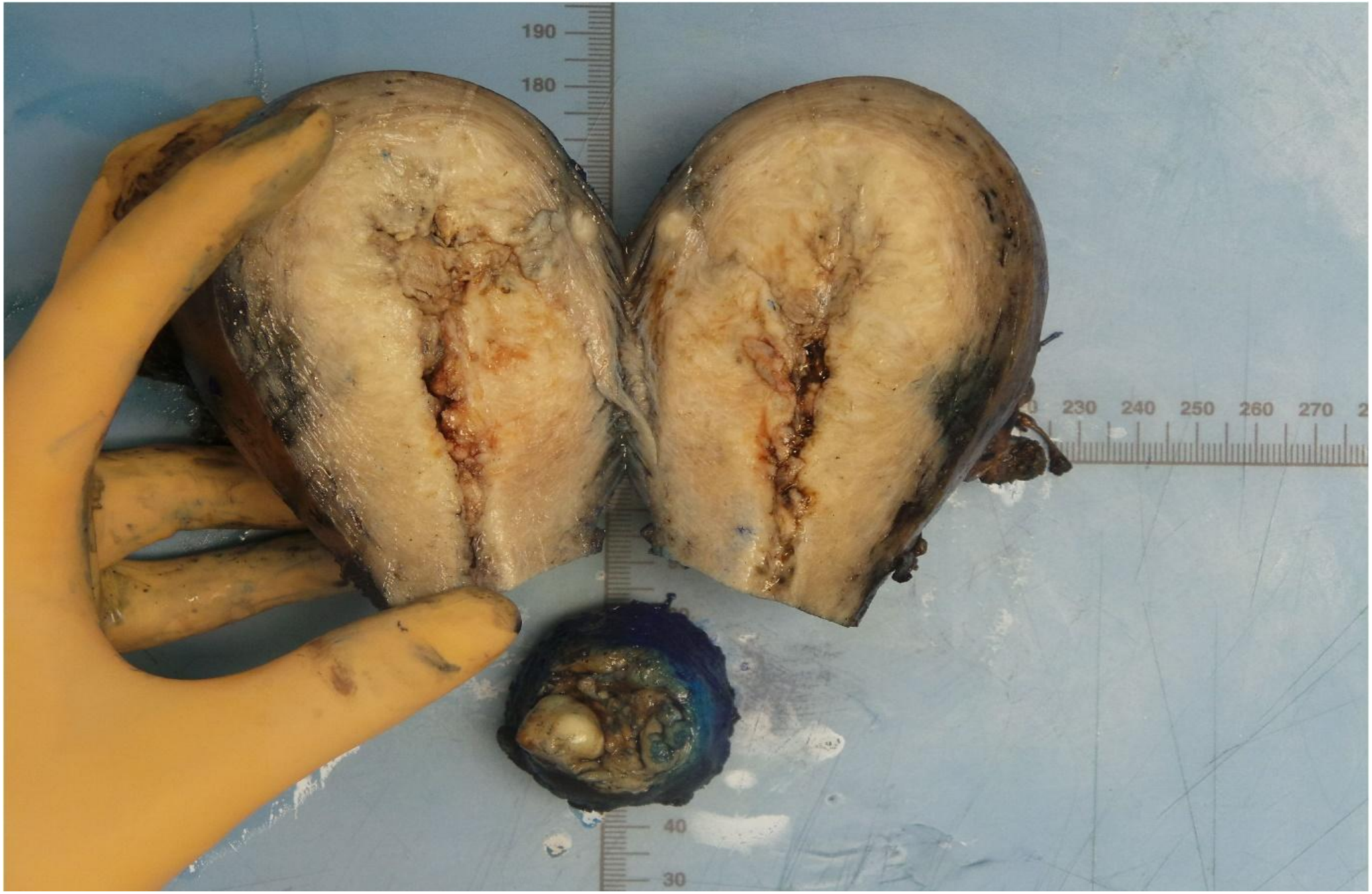
190
180
230
240
250
260
270
40
30

2. What are the likely presenting symptoms?

- The most common symptom of women with EC is postmenopausal bleeding

- Symptoms that suggest advanced disease at presentation include abdominal pain, distention, bloating, change in bowel or bladder habits or new cough.

3. What is the likely diagnosis?

- Endometrial carcinoma, involving the cervix



4. How many blocks would you sample?
5. Where would you take the blocks from?

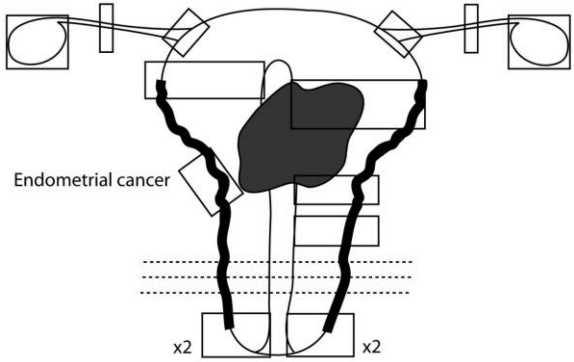

- Tumour – one section per 10 mm, considering the largest tumour dimension/at least four blocks of tumour must be sampled.
  - These blocks should include the **full thickness of the uterine wall and the serosa at the site of deepest myometrial invasion.** This may be as a number of conventional sized blocks or one big/mega block.
- At least one block of isthmus/lower uterine segment (LUS) should be taken in all cases.
- The parametrial tissue should be blocked in its entirety
- Two longitudinal blocks each including a lip of the cervix should be submitted.
  - The blocks should include the **entire length of the endocervical canal.**
  - Additional blocks may be needed to include **the vaginal cuff** if present
- One or two blocks each of both ovaries and tubes should be submitted if grossly normal. The tubal blocks should include the fimbria.

OSPE

What is being assessed

- OSPE 1 The aim is to assess you as a manager – and most scenarios are based on some kind of crisis management
- Overall-
  - Identify
    - Impact
    - Patient safety
  - Communication
  - Patient Safety
    - Damage limitation, prioritisation
  - Short time solutions
  - Long term solutions
    - Incident reporting/documentation, clinical governance, assess outcome, staff, funding, Duty of candour process

OSPE 2 is usually a often involving molecular/ancillary aspects, image-based tasks, data interpretation,

OSPE

You are the pathologist at a multidisciplinary team (MDT) meeting for a patient with newly diagnosed advanced ovarian cancer. You have been asked to present and interpret the HRD test results and discuss implications for treatment.

Case information:
57-year-old woman
Presented with abdominal distension, ascites
CT: extensive peritoneal disease, enlarged pelvic nodes
Laparoscopic biopsy- high grade serous ovarian carcinoma (HGSC), p53 aberrant diffuse nuclear staining, WT-1 positive, Stage IIIC

Molecular report
Germline BRCA1/2: Negative
Tumour BRCA1: c5266dupC pathogenic variant, allelic fraction 48%
HRD Genomic instability score: 46 (HRD positive)

What is meant by ‘homologous recombination deficiency’ (HRD) and how it predisposes to cancer.

Homologous recombination is the technique which cells use to repair double-strand DNA breaks.

HRD is the state in which cells have a dysfunctional homologous recombination system. Cells with HRD cannot repair double-strand DNA breaks.

They therefore accumulate severe DNA damage which cannot be repaired and can be passed on to their daughter cells. This may eventually result in cancer

Relationship between pathogenic *BRCA1/2* variants and HRD

Pathogenic *BRCA1/2* variants result in HRD.

However, HRD may result from phenomena other than pathogenic *BRCA1/2* variants.

If the variant is detected in non-neoplastic tissue, the variant is considered germline

if no variant is detected in non-neoplastic tissue, the variant detected in the tumour is likely somatic.

OSPE

You are the pathologist at a multidisciplinary team (MDT) meeting for a patient with newly diagnosed advanced ovarian cancer. You have been asked to present and interpret the HRD test results and discuss implications for treatment.

Case information:
57-year-old woman
Presented with abdominal distension, ascites
CT: extensive peritoneal disease, enlarged pelvic nodes
Laparoscopic biopsy- high grade serous ovarian carcinoma (HGSC), p53 aberrant diffuse nuclear staining, WT-1 positive, Stage IIIC

Molecular report
Germline BRCA1/2: Negative
Tumour BRCA1: c5266dupC pathogenic variant, allelic fraction 48%
HRD Genomic instability score: 46 (HRD positive)

Q.1 Interpret the HRD results and classify the mutation (germline vs somatic)

Confirm diagnosis: HGSOC, FIGO stage IIIc, p53-aberrant, WT1+, high tumor cellularity.

Germline BRCA1/2 negative → no inherited mutation identified.

Tumor shows a pathogenic somatic BRCA1 mutation (c.5266dupC).HRD score above threshold → HRD-positive.

Somatic (tumor-only) BRCA1 mutation — not present in germline → no direct hereditary implication.

HRD-positive due to both BRCA1 mutation and high genomic instability score.

Q.2 Discuss the clinical significance in terms of prognosis and treatment

- Predictive: Likely to benefit from platinum-based chemotherapy and PARP inhibitor maintenance therapy (e.g., olaparib, niraparib).
- Prognostic: HRD-positive tumours tend to have better initial responses to treatment.
- Therapeutic eligibility: Meets NICE/ESMO criteria for PARP inhibitor use in first-line maintenance

Q.3 Address implications for family members

- As the mutation is somatic, no automatic increased risk to relatives — genetic counselling not mandatory but optional discussion could be offered given family history.



Q.4 If the patient relapses after PARP inhibitor therapy, would HRD testing be repeated?

- HRD status may change over time, especially after exposure to PARP inhibitors or platinum (e.g., via BRCA reversion mutations restoring HR function).
- Repeat testing can be considered, especially in the research setting, but is not yet standard NHS practice.
- Functional assays or ctDNA may become important in the future.

OSPE

You are in the cut-up room, performing the macroscopic description and dissection of a wide local excision specimen of vulva for a squamous cell carcinoma.

Three pots are received:

Pot A – main specimen: WLE specimen with skin ellipse and underlying soft tissue.

Pot B- Right sentinel lymph node

Pot C- Left sentinel lymph node

During handling, one of the sentinel lymph node slips from the forceps and accidentally falls into the sink.

Q.1 Outline your approach to handling the sentinel nodes, including block selection.

Macroscopic handing

Macroscopic handling of the SLN is the same across all cancers.

- Examine the lymph node and adherent fat.
- Record the presence and colour of any visible dye.
- Lymph nodes up to 2mm can be embedded whole. Nodes 2-4mm in size should be bisected and both halves submitted. Nodes that are 4 mm or more in largest dimension should be bisected or sliced at 2 mm intervals, in a plane perpendicular to the longest axis (Figure 1).

Figure 1: Embedding of lymph nodes in SLN_US

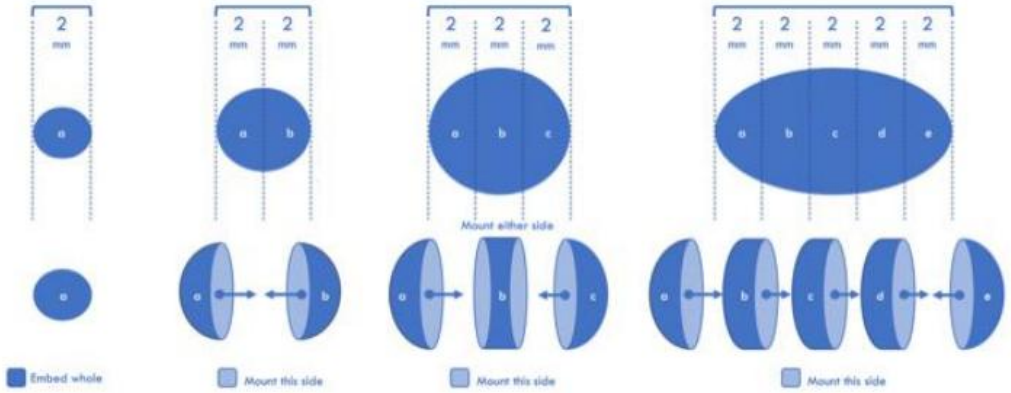

Q.2 Following this incident, outline the immediate and subsequent steps you would undertake.

- ❑ Stop work immediately.
- ❑ Attempt retrieval if safe and possible (mesh trap, sink filter).
- ❑ If irretrievable:

❖ Inform senior BMS/consultant.
❖ Document in cut-up record and pathology worksheet: which node, how lost, attempts to retrieve.
❖ Inform the reporting pathologist and clinical team (surgeon/MDT coordinator).
❖ Flag in final pathology report that one sentinel lymph node was not available for histology.

Q.3 Identify the potential adverse clinical consequence that may arise as a result of this loss.

- Sentinel node status is critical for staging and management in vulval SCC (FIGO and TNM).

- Loss may:

  - Reduce accuracy of staging.
  - Prompt re-operation or more extensive lymphadenectomy in some cases.

- Must be transparently communicated to avoid false-negative nodal staging.

Q.4 Propose measures that could be implemented in the cut-up room to minimise the risk of similar incidents occurring in the future.

- **Process improvements:**

- Always work over a dissecting board or tray with raised edges.
- Avoid working directly over sinks; ensure plugs or mesh traps are in place.
- Use forceps with good grip and place small tissue pieces directly into labelled cassettes.

- **Training & awareness:**
- Reinforce safe handling procedures during cut-up training.
- Ensure new staff are supervised when handling small or friable specimens.

- **Equipment & workflow:**

- Use fine-mesh specimen sieves for small nodes.
- Keep each specimen pot on a stable surface and handle one at a time.
- Ensure cut-up benches are tidy and free of obstructions.

- **Documentation culture:**
- Encourage prompt, honest recording of any lost tissue with full traceability.
- Review incidents in departmental governance meetings to identify systemic fixes.

Thank you for your attention!