The British Association of Gynaecological Pathologists

Lecturer – Dr Rachna Khera

Consultant Histopathologist specialising in Gynaecological Pathology at the Royal Liverpool University Hospital

I am currently co-lead for Gynaecological Pathology services at Liverpool Clinical Laboratories, RLUH, Liverpool, UK



The British Association of Gynaecological Pathologists

Mock Exam

- Dr Rachna Khera
- Royal Liverpool University Hospital, LUHFT
- 25 September 2024

MACRO 1

Total hysterectomy from a 77-year old woman

1. Describe the specimen.
2. What are the likely presenting symptoms?
3. What is the likely diagnosis?
4. How many blocks would you sample?
5. Where would you take the blocks from?



WHAT IS BEING ASSESSED

- Overall approach to the macroscopic examination
- Ability to select blocks
- Understanding of cancer datasets
- Demonstrate approach to nonneoplastic conditions

Pathological core data: macroscopic data items

- Details of hysterectomy specimen; attached anatomical structures may include vaginal cuff, ovaries, fallopian tubes or parametria
- Accompanying specimens:

    - The omentum, if received, should be measured and the presence and dimensions of the largest visible deposit recorded.
    - Lymph nodes
    - Peritoneal biopsies

Pathological core data: macroscopic data items

Tumour details:

- Maximum dimension
- Myometrial invasion
- Serosal surface involvement.
- Cervical involvement
- Parametrial involvement

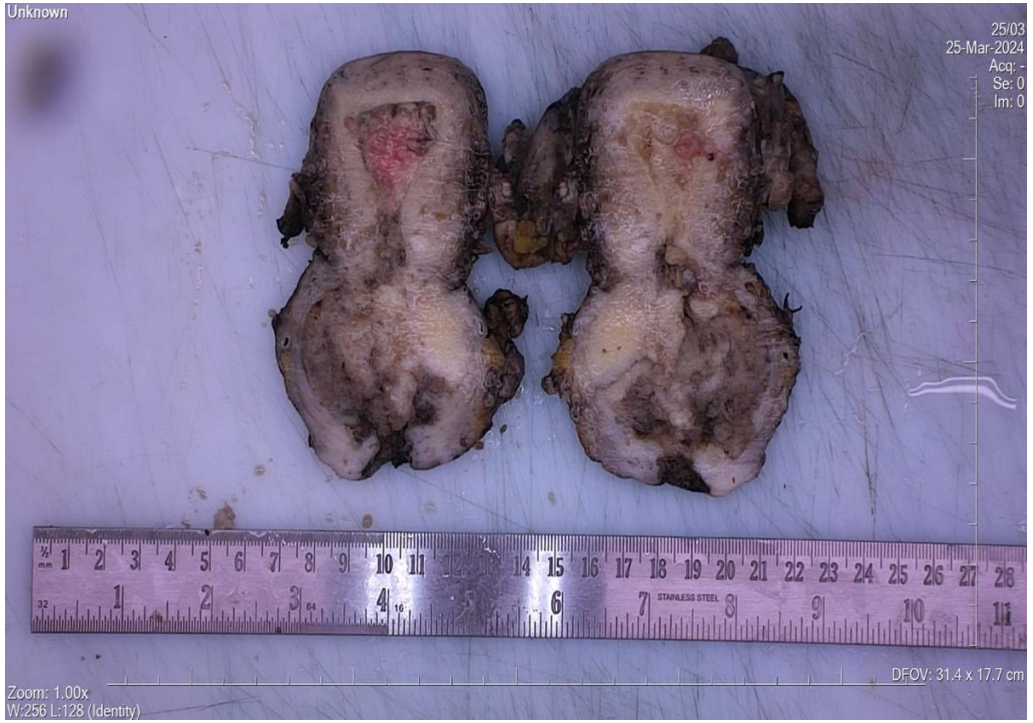

Macroscopic non-core data items

- Specimen weight and measurements

- Location of tumour: LUS/isthmus, body, fundus or cornu.

    - Approximately 14% of endometrial carcinomas arise in the LUS/isthmus. An isthmic location is seen more commonly in association with hereditary non-polyposis colorectal cancer syndrome/Lynch syndrome.
    - LUS involvement has also been shown to be an independent prognostic factor in conferring a higher risk of adverse outcomes including distant recurrence and death

A word about margins

- Parametrium
- Vaginal cuff margins- if tumour invades cervix
- Serosa is not a ‘true margin’ but is important for Staging


Unknown
25/03
25-Mar-2024
Acq: -
Se: 0
Im: 0
STAINLESS STEEL
DFOV: 31.4 x 17.7 cm
Zoom: 1.00x

2. What are the likely presenting symptoms?

- The most common symptom of women with EC is postmenopausal bleeding
    - EC should be suspected in premenopausal women with persistent intermenstrual or heavy menstrual bleeding, especially if there is a background of irregular, dysfunctional menstruation that suggests anovulation.
- Symptoms that suggest advanced disease at presentation include abdominal pain, distention, bloating, change in bowel or bladder habits or new cough.

3. What is the likely diagnosis?

- Endometrial carcinoma, involving the cervix



4. How many blocks would you sample?
5. Where would you take the blocks from?

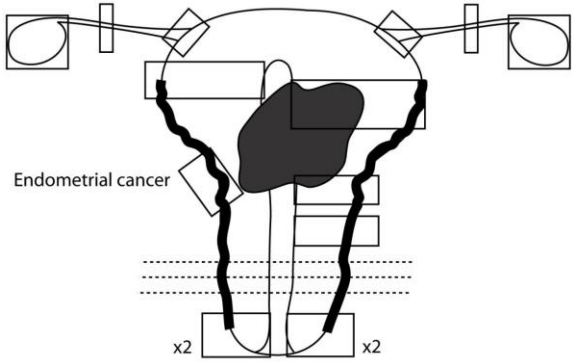

- Tumour – one section per 10 mm, considering the largest tumour dimension/at least four blocks of tumour must be sampled.
  - These blocks should include the full thickness of the uterine wall and the serosa at the site of deepest myometrial invasion. This may be as a number of conventional sized blocks or one big/mega block.
- At least one block of isthmus/lower uterine segment (LUS) should be taken in all cases.
- The parametrial tissue should be blocked in its entirety
- Two longitudinal blocks each including a lip of the cervix should be submitted.
  - The blocks should include the entire length of the endocervical canal.
  - Additional blocks may be needed to include **the vaginal cuff** if present
- One or two blocks each of both ovaries and tubes should be submitted if grossly normal. The tubal blocks should include the fimbria.

MACRO 2

56 year old female unilateral salpingoophrectomy sent for frozen section

1. Describe the specimen briefly and indicate how you would handle it in the cut up room.
2. What are the likely presenting symptoms?
3. What is the likely diagnosis?
4. Where would you take the blocks from?
5. Comment on the tumour stage.

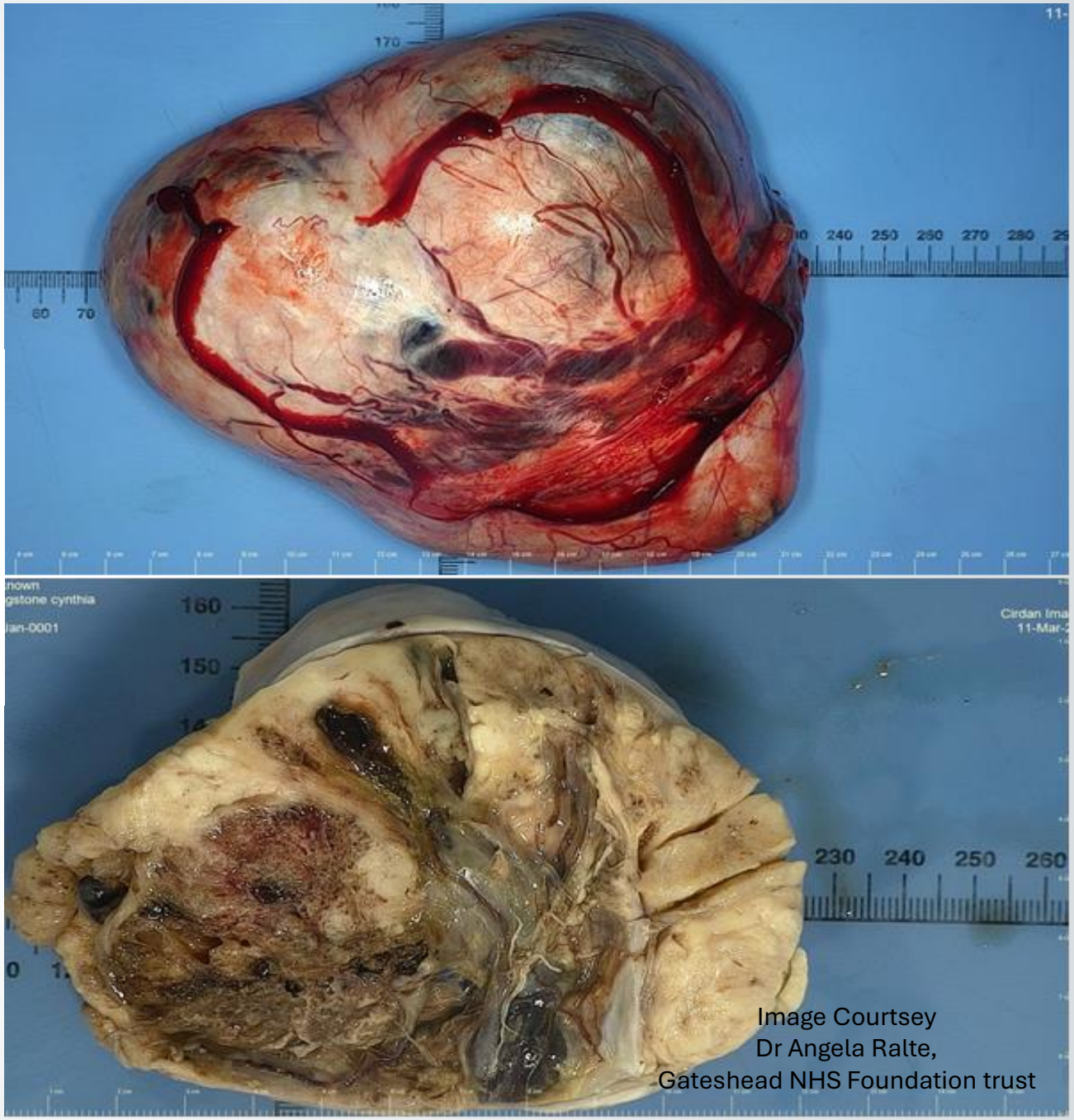

Image Courtsey
Dr Angela Ralte,
Gateshead NHS Foundation trust

1. Describe the specimen briefly and indicate how you would handle it in the cut-up room.

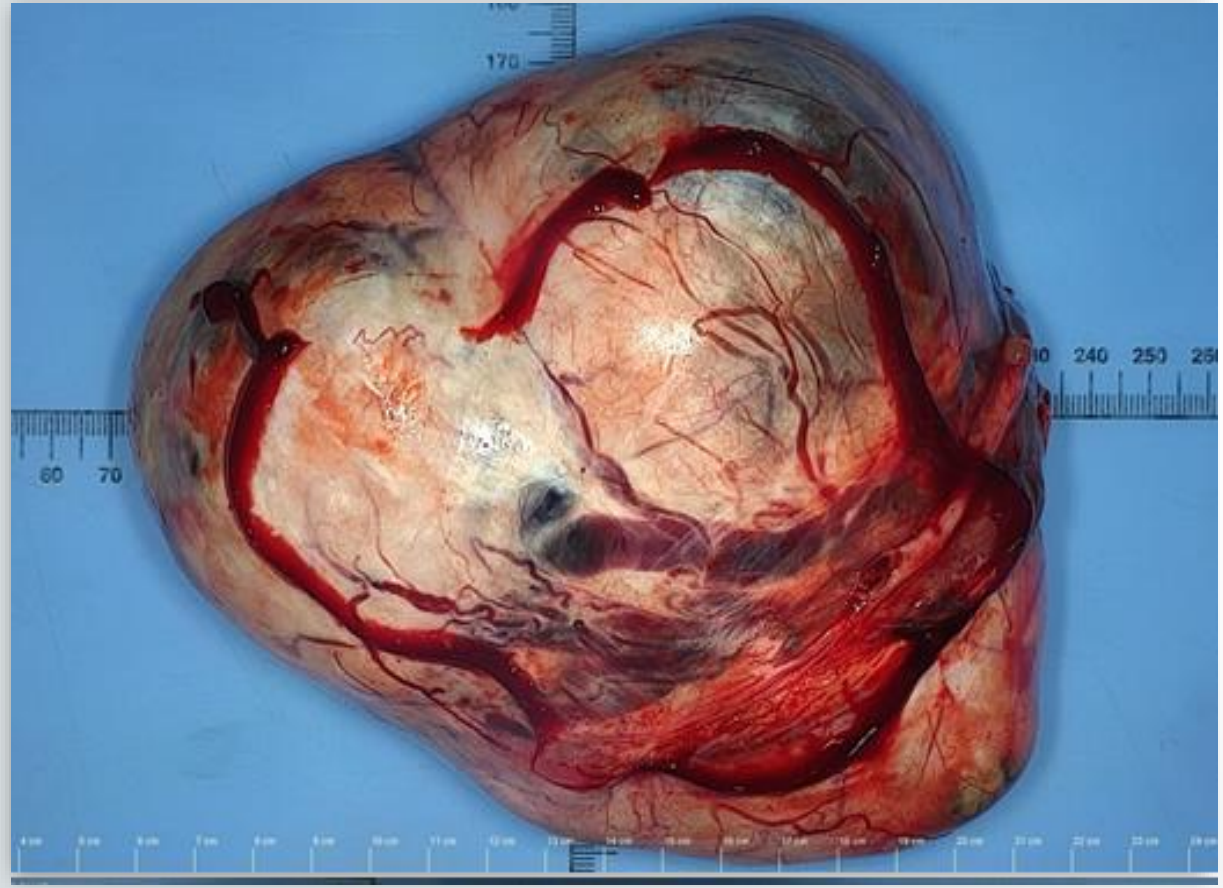

- Careful examination of the capsular surface of the ovary for any capsular breaches/tears, surface papillary or solid projections must be recorded and measured (**Disruption Adhesions Deposits-** adhesions may indicate site of rupture)

- Avoid excessive handling of the surface to prevent abrasion of the delicate covering mesothelium)

- Measure the ovary in three dimensions; weight may be recorded if desired.

- It is important to determine whether the ovarian capsule is intact. If rupture is identified, discussion at the MDTM or reference to the operation notes may be helpful in concluding whether this occurred at or prior to surgery.

- Inking and slicing of the neoplasm only be undertaken following careful examination of the capsular surface of the ovary.

- Inking of the capsular surface may help guide later microscopic assessment of capsular breach.

The presence and appearance of the fallopian tube should be recorded,

The ovarian mass should be sliced and its cystic or solid nature noted, as well as the presence and size of papillary excrescences.

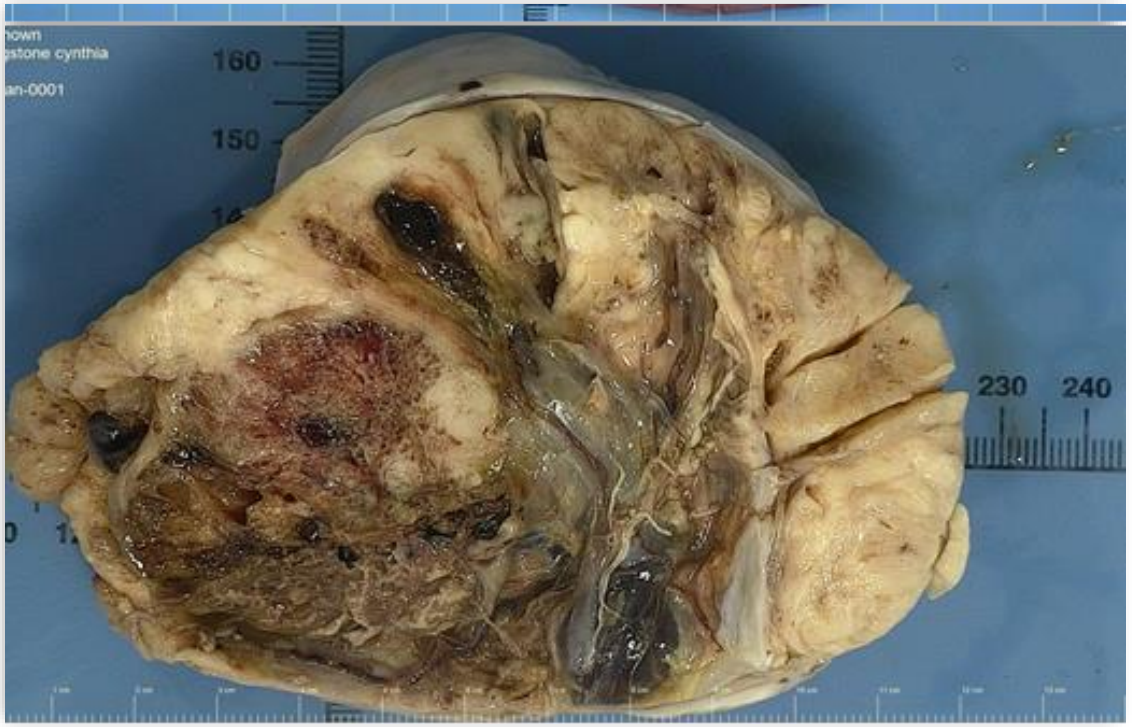

Specimen handling and block selection: Core data items

- Specimen type: This allows confirmation that the specimen received is correct, and prompts identification of any structures mentioned on the request form. Laterality should also be given if applicable.
- Capsule status
- Macroscopic tumour site
- Macroscopic description of omentum

Non-core data items

- Tumour dimensions

- Block identification key

2. What are the likely presenting symptoms?

- Patients typically present with symptoms related to a pelvic mass, or the mass may be an incidental finding.

- Sometimes, associated with paraneoplastic hypercalcaemia and venous thromboembolism

3. What is the likely diagnosis?

- Malignant ovarian tumour

4. Where would you take the blocks from?

- one block per 10 mm of maximum tumour diameter in solid tumours.
    - In addition, it is recommended that two blocks per 10 mm should be taken in borderline tumours >10 cm in size,
    - However, with a large homogenous neoplasm or a simple, thin-walled cystic lesion without capsular thickening or papillary processes, more limited sampling may be appropriate with the option of further sampling should this be indicated.

- Sampling should be centred on any papillary and solid areas, in addition to thin-walled cystic components

- Ovarian cysts that are entirely thin walled may be rolled up analogous to a ‘membrane roll’ in placentas, to enable a higher surface area to be represented in a single block

5. Comment on the tumour stage.

- Clear cell carcinoma
- Provisional FIGO Stage IA

OSPE

OSPE 1

- You are preparing for the Gynae MDT. A young woman was diagnosed with grade 1 endometrioid endometrial adenocarcinoma on pipelle biopsy; on immunohistochemistry, all four-mismatch repair (MMR) proteins: MLH1, PMS2, MSH6, MSH2 are retained and p53 is reported as mutant type. You review the immunohistochemistry and find that carcinoma shows wild type staining with p53.

What are the reasons for performing P53 and MMR testing on this case?

TCGA (The Cancer Genome Atlas,2013)

- In 2013, The Cancer Genome Atlas Research (TCGA) network performed a comprehensive genomic and transcriptomic analysis of endometrioid and serous carcinomas
- 370 different endometrial carcinomas, with corresponding clinical features and outcomes
- Grouped endometrial cancers into 4 main categories that appeared to have prognostic and therapeutic significance

Nature 2013:497(67-73)

- **Proactive Molecular Risk Classifier for Endometrial Cancer (ProMisE)** to replicate the TCGA classification in clinical practice, but without the need for the labor-intensive and cost-prohibitive genomic methodology.

- Combination of targeted sequencing for pathogenic POLE mutations and IHC for MMR and p53 status, to assign EC to one of four molecular subtypes; **POLEmut, MMRd, p53abn, and NSMP (no specific molecular profile).**

Liverpool Clinical Laboratories

NHS Liverpool University Hospitals NHS Foundation Trust

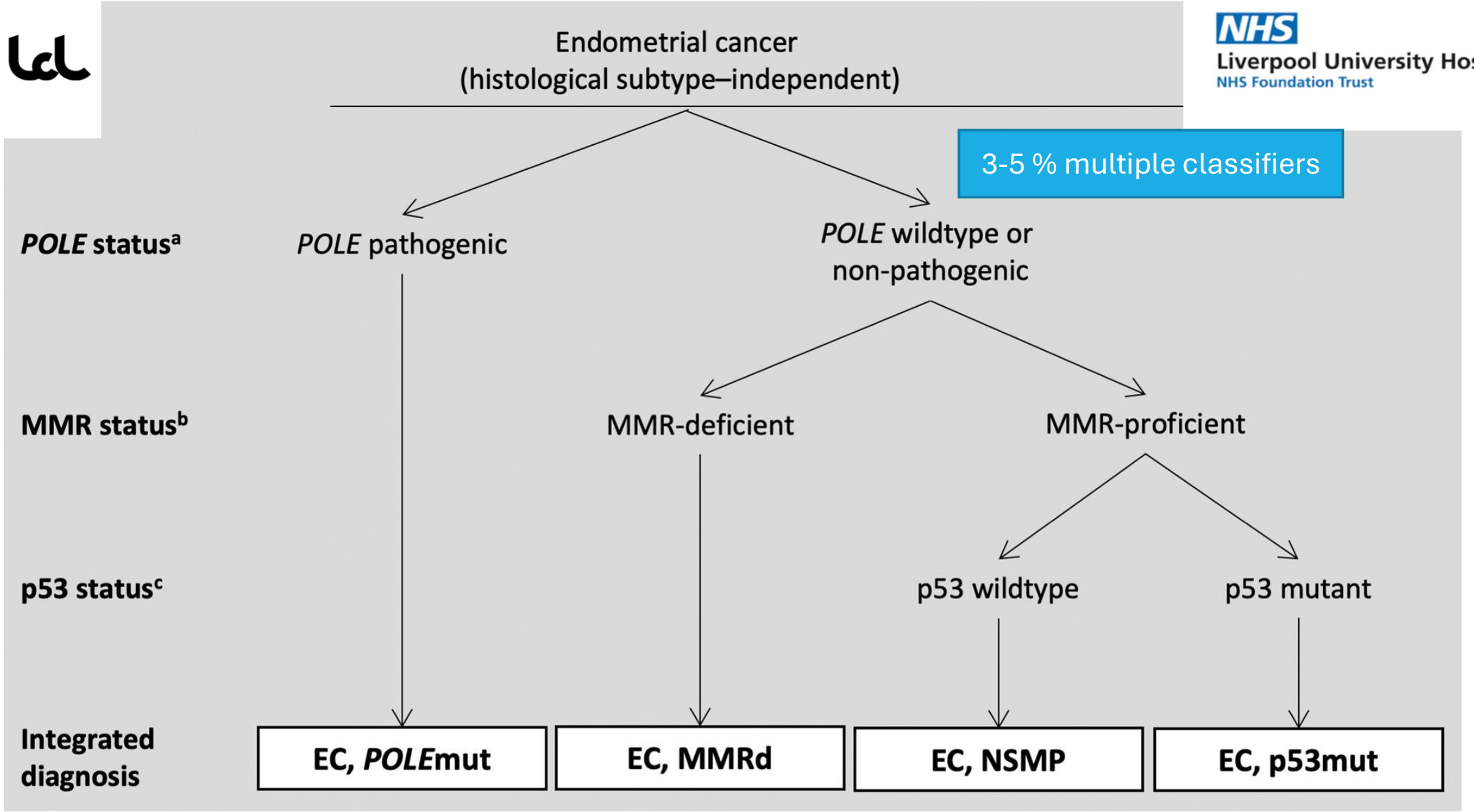

TCGA clusters can be replicated in routine clinical practice using just 3 tests: • MMR IHC • p53 IHC • POLE sequencing (Sanger or NGS)

WHO 2020

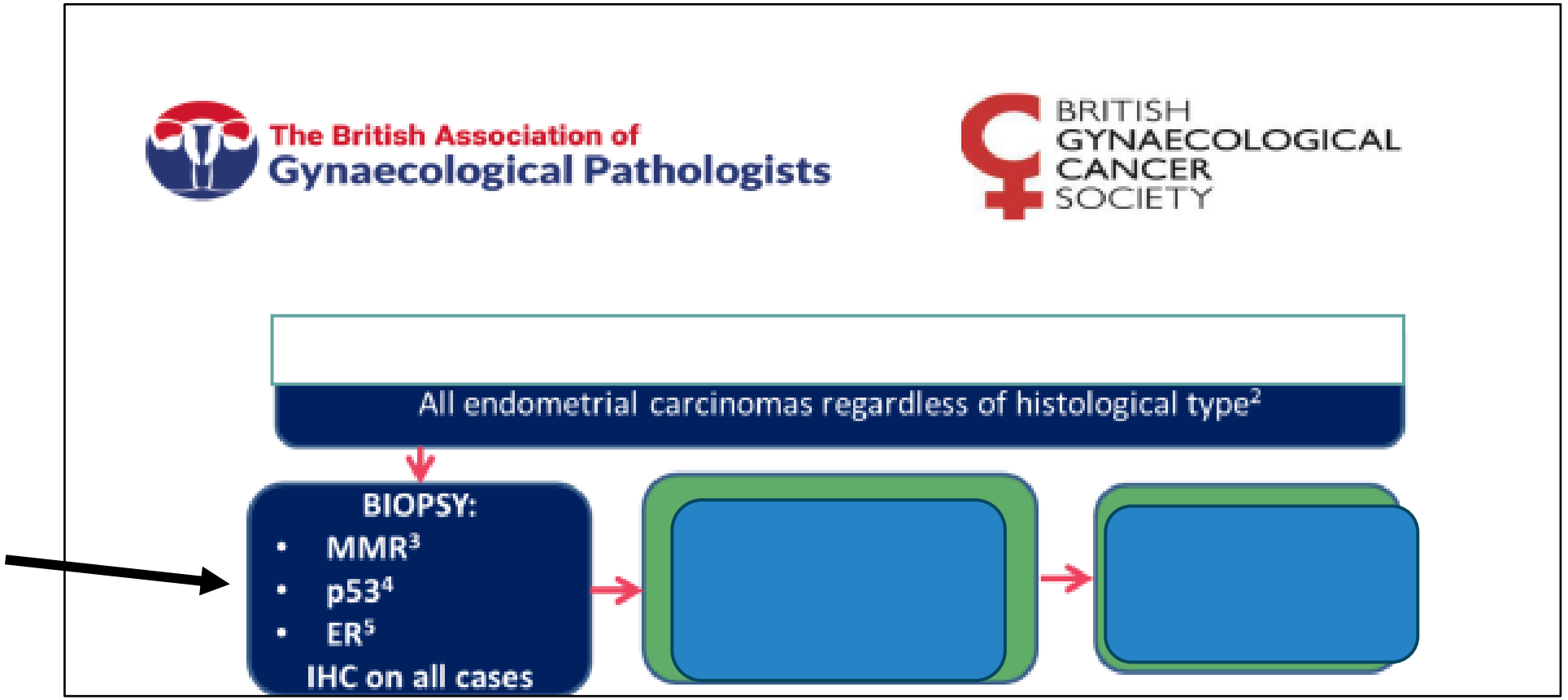

BAGP POLE NGS testing guidance, v1.1, dated 8 April 2022

MMR IHC should be performed on all endometrial cancers

- Lynch Syndrome screening
- Molecular classification; prognosis
- Immune checkpoint inhibitor Rx

p53 IHC should be performed on all endometrial cancers

p53abn EC represent the most aggressive molecular subtype, and account for majority of EC mortality.

P53 IHC is an excellent surrogate maker for TP53 mutational status as determined by sequencing in EC biopsies .

Recent evidence has shown the p53abn molecular subtype is found in up to 5-10% of grade 1 and 2 endometrioid ECs .

- What will you do to confirm your interpretation?

- OPTIMIZED PROTOCOL

  - DO7 clone but there are several other high-quality p53 antibodies available.
  - protocol with high sensitivity and specificity using appropriate controls (both internal and external controls)

- Aware of guidance BAGP/UKNEQAS/CIQC guidelines for interpretation of p53 staining

p53 staining patterns

Normal wild-type

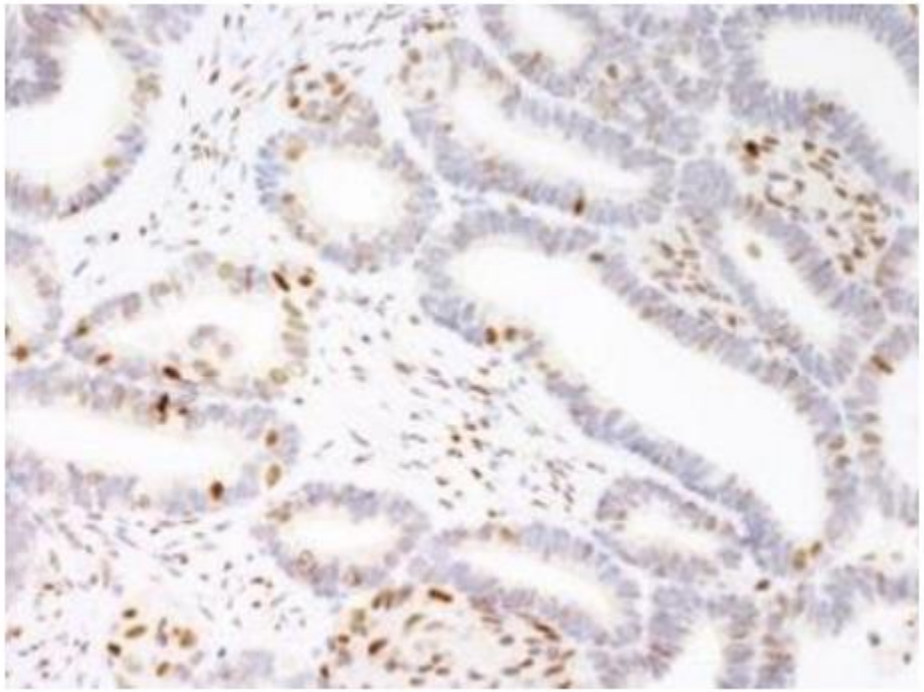

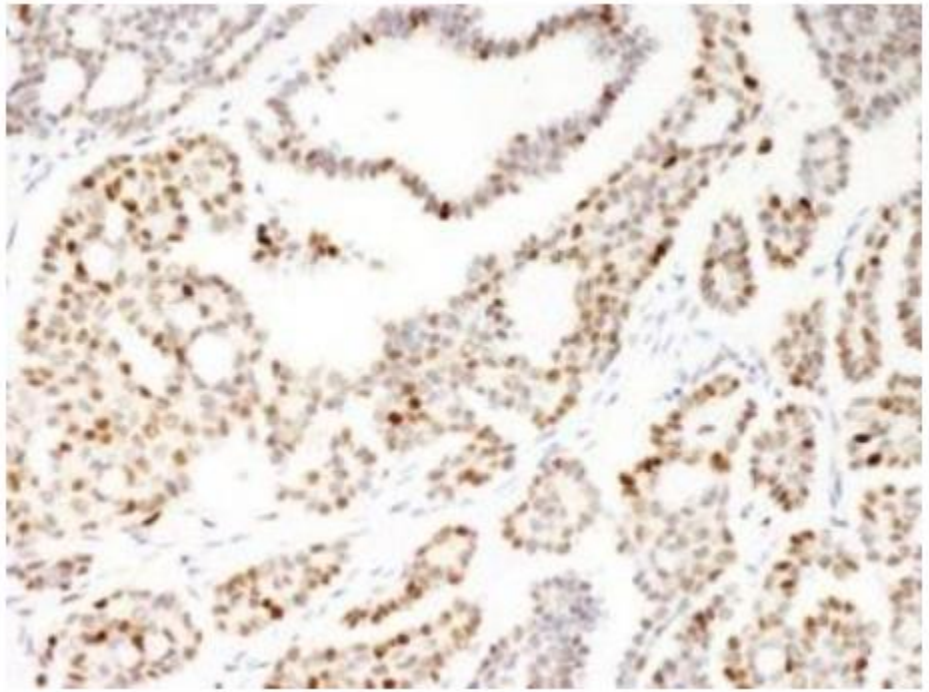

The distribution of nuclear staining in a 'wild type' pattern ranges from a few positive cells to almost all cells staining, but with variable intensity.

http://www.thebagp.org/download/bagp-ukneqas-project-p53-interpretation-guide-2016/

p53 staining patterns

Abnormal : overexpression (66%)

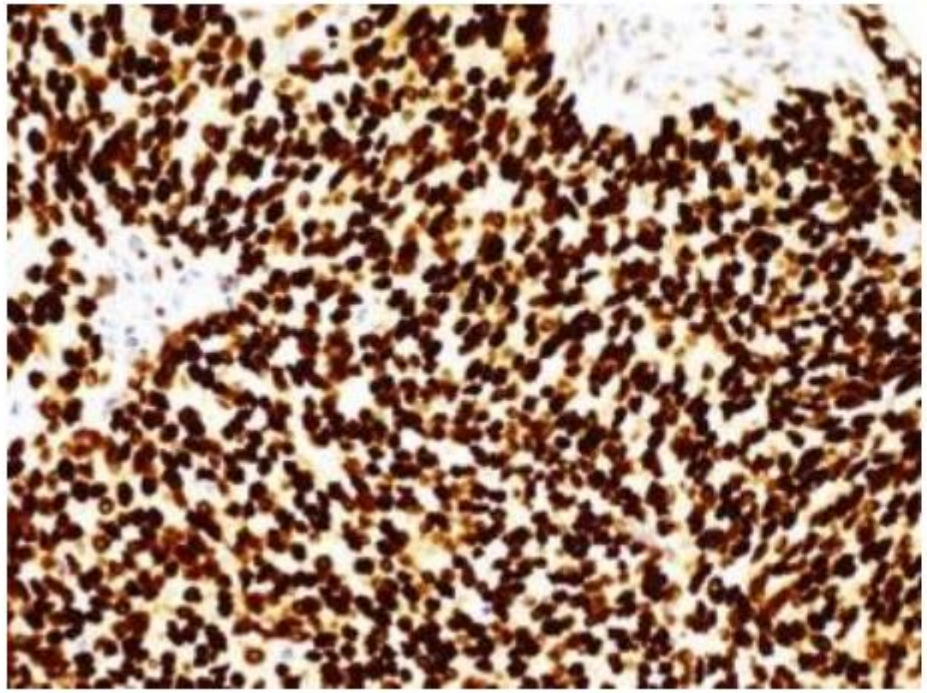

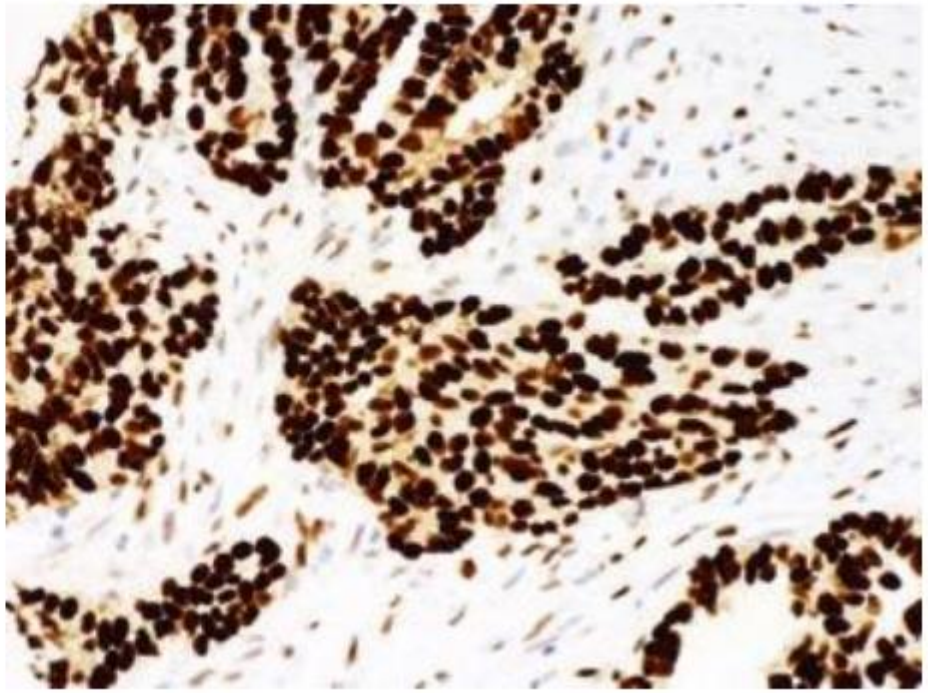

Overexpression is defined as strong nuclear staining in at least 80% of tumor cell nuclei (usually 100% tumor cell nuclei, the 80% cut-off accounts for technical artifacts and the rare mosaic pattern.

http://www.thebagp.org/download/bagp-ukneqas-project-p53-interpretation-guide-

p53 staining patterns

Abnormal: complete absence or null pattern (25%)

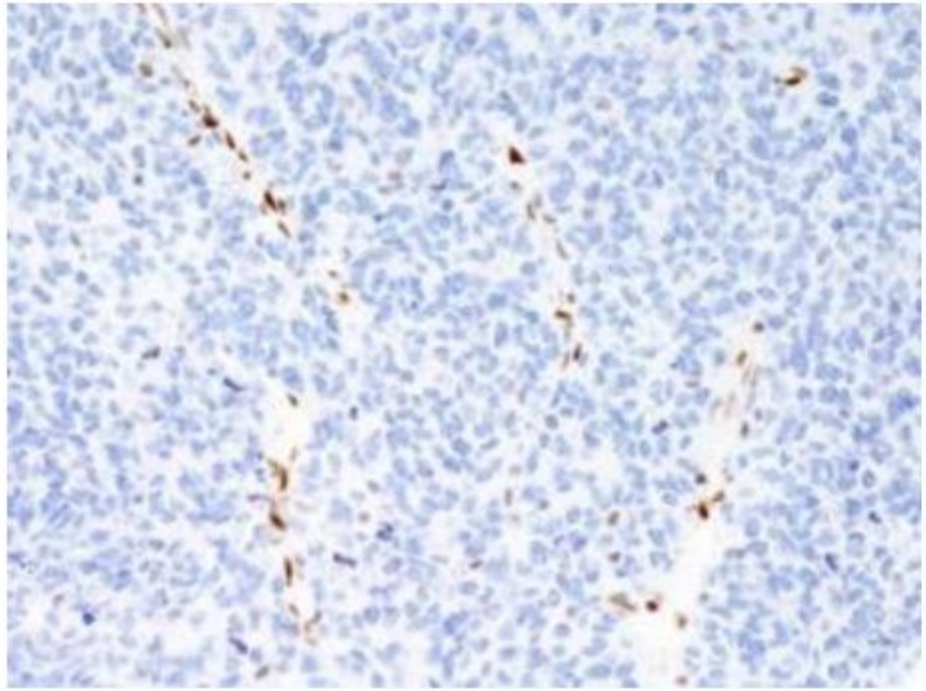

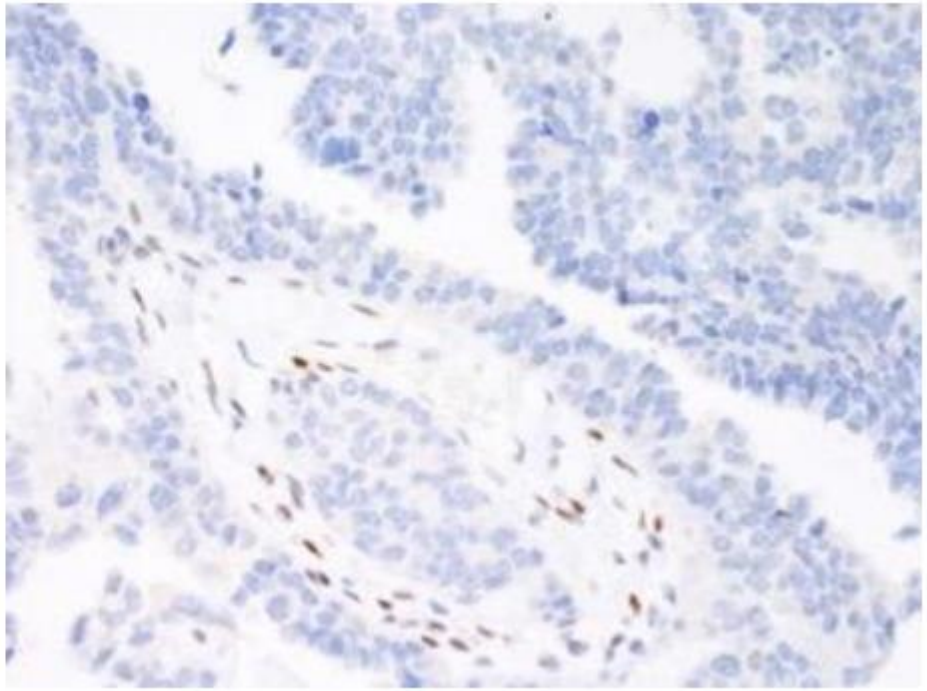

Complete absence is defined as no staining in tumor cell nuclei in the presence of ‘wild-type’, ie variable, staining in normal background cells (intrinsic control present).

http://www.thebagp.org/download/bagp-ukneqas-project-p53-interpretation-guide-

p53 staining patterns

Abnormal: cytoplasmic (4%)

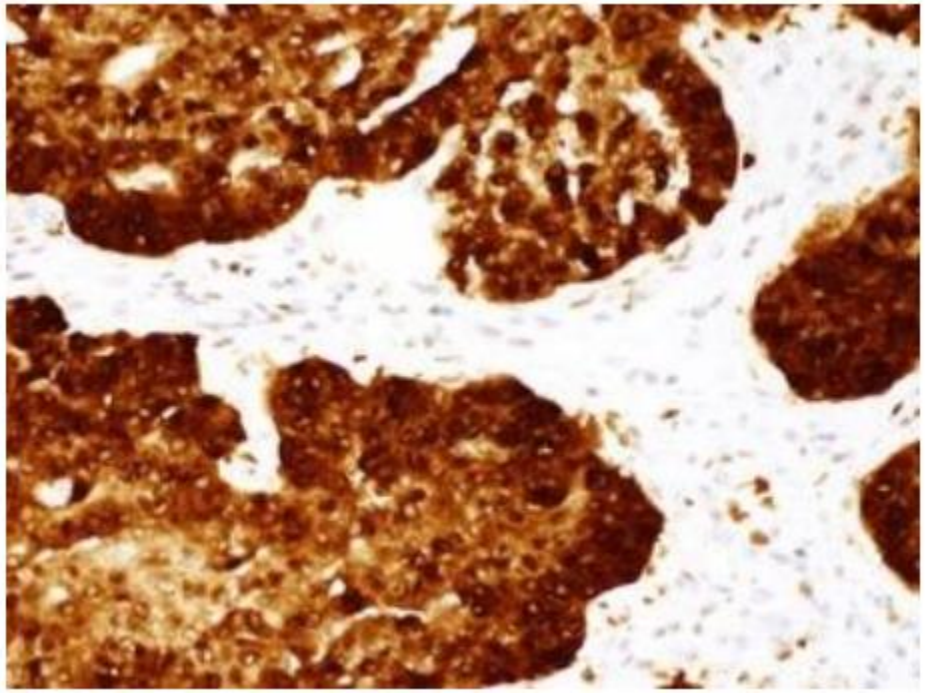

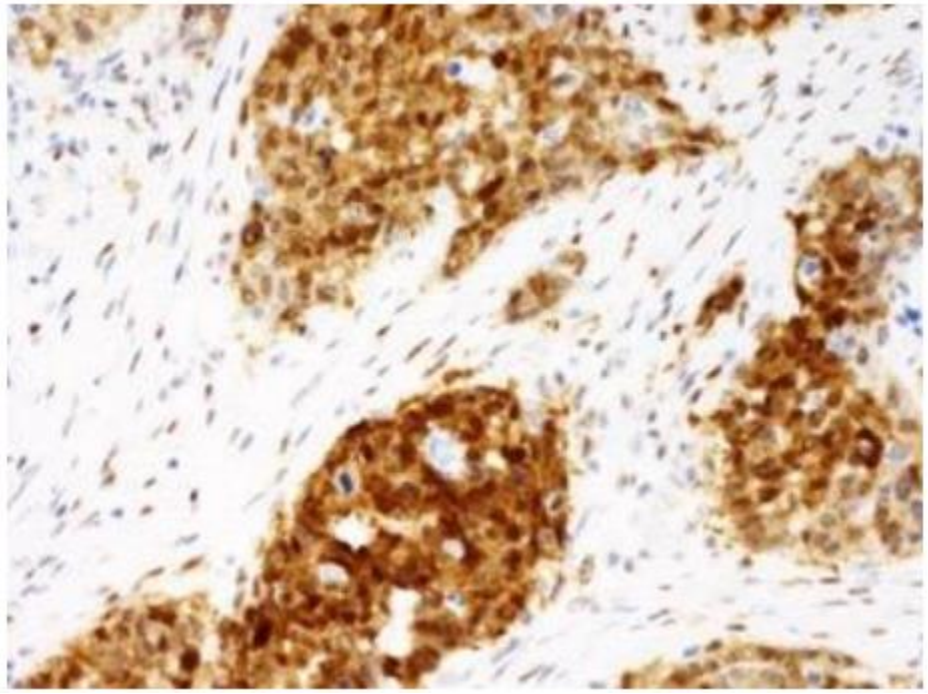

Cytoplasmic staining is defined as predominant cytoplasmic staining in the absence of strong nuclear staining in >80% of tumor cell nuclei, i.e. the nuclear staining can be absent or weak and variable.

http://www.thebagp.org/download/bagp-ukneqas-project-p53-interpretation-guide-2016/

INTERPRETATIONAL DIFFICULTIES: NORMAL WILD-TYPE VERSUS ABNORMAL OVEREXPRESSION

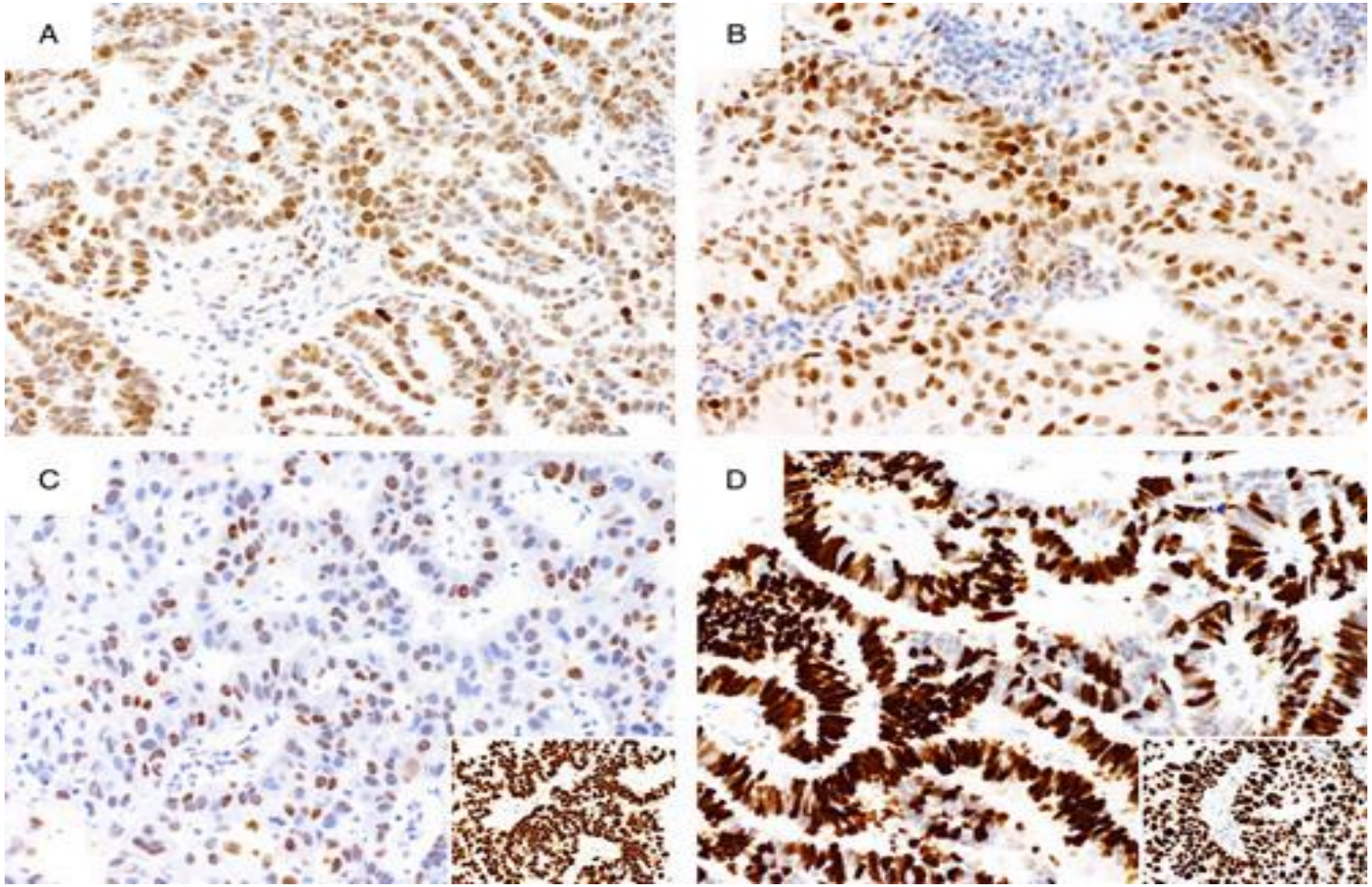

The reporting pathologist disagrees with your interpretation- what do you do?

- Don’t undervalue your own opinion but ask reporting consultant to look at the case with you to assure you of his interpretation.
- You shouldn’t simply issue a separate report changing the diagnosis/interpretation which will create confusion in the clinical team.
- Telling the MDTM you disagree with the original report is acceptable but it would be better to express uncertainty and find a solution in the form of a review/further testing rather than baldly stating your disagreement.
    - Pathology is another opinion-based part of medicine.
    - Mis-interpretation/misdiagnosis should be dealt with by openness admitting the mistake and correcting in a timely fashion
- Show to other colleagues
- TP53 sequencing

What are the implications of these results?



Practice Guideline > Int J Gynecol Cancer. 2021 Jan;31(1):12-39. doi: 10.1136/ijgc-2020-002230. Epub 2020 Dec 18.

ESGO/ESTRO/ESP guidelines for the management of patients with endometrial carcinoma

Nicole Concin [1 2], Xavier Matias-Guiu [3 4], Ignace Vergote [5], David Cibula [6], Mansoor Raza Mirza [7], Simone Marnitz [8], Jonathan Ledermann [9], Tjalling Bosse [10], Cyrus Chargari [11], Anna Fagotti [12], Christina Fotopoulou [13], Antonio Gonzalez Martin [14], Sigurd Lax [15 16], Domenica Lorusso [12], Christian Marth [17], Philippe Morice [18], Remi A Nout [19], Dearbhaile O'Donnell [20], Denis Querleu [12 21], Maria Rosaria Raspollini [22], Jalid Sehouli [23], Alina Sturdza [24], Alexandra Taylor [25], Anneke Westermann [26], Pauline Wimberger [27], Nicoletta Colombo [28], François Planchamp [29], Carien L Creutzberg [30]

Affiliations + expand

PMID: 33397713 DOI: 10.1136/ijgc-2020-002230

Free article

Liverpool Clinical Laboratories

NHS Liverpool University Hospitals NHS Foundation Trust

Table 2 Definition of prognostic risk groups

Risk group	Molecular classification unknown	Molecular classification known*†
Low	► Stage IA endometrioid + low-grade‡ + LVSI negative or focal	► Stage I–II ***POLEmut*** endometrial carcinoma, no residual disease ► Stage IA **MMRd/NSMP** endometrioid carcinoma + low-grade‡ + LVSI negative or focal
Intermediate	► Stage IB endometrioid + low-grade‡ + LVSI negative or focal ► Stage IA endometrioid + high-grade‡ + LVSI negative or focal ► Stage IA non-endometrioid (serous, clear cell, undifferentiared carcinoma, carcinosarcoma, mixed) without myometrial invasion	► Stage IB **MMRd/NSMP** endometrioid carcinoma + low-grade‡ + LVSI negative or focal ► Stage IA **MMRd/NSMP** endometrioid carcinoma + high-grade‡ + LVSI negative or focal ► Stage IA **p53abn** and/or non-endometrioid (serous, clear cell, undifferentiated carcinoma, carcinosarcoma, mixed) without myometrial invasion
High–intermediate	► Stage I endometrioid + substantial LVSI regardless of grade and depth of invasion ► Stage IB endometrioid high-grade‡ regardless of LVSI status ► Stage II	► Stage I **MMRd/NSMP** endometrioid carcinoma + substantial LVSI regardless of grade and depth of invasion ► Stage IB **MMRd/NSMP** endometrioid carcinoma high-grade‡ regardless of LVSI status ► Stage II **MMRd/NSMP** endometrioid carcinoma
High	► Stage III–IVA with no residual disease ► Stage I–IVA non-endometrioid (serous, clear cell, undifferentiated carcinoma, carcinosarcoma, mixed) with myometrial invasion, and with no residual disease	► Stage III–IVA **MMRd/NSMP** endometrioid carcinoma with no residual disease ► Stage I–IVA **p53abn** endometrial carcinoma with myometrial invasion, with no residual disease ► Stage I–IVA **NSMP/MMRd** serous, undifferentiated carcinoma, carcinosarcoma with myometrial invasion, with no residual disease
Advanced metastatic	► Stage III–IVA with residual disease ► Stage IVB	► Stage III–IVA with residual disease of any molecular type ► Stage IVB of any molecular type

*For stage III–IVA *POLE*mut endometrial carcinoma and stage I–IVA MMRd or NSMP clear cell carcinoma with myometrial invasion, insufficient data are available to allocate these patients to a prognostic risk group in the molecular classification. Prospective registries are recommended.
†See text on how to assign double classifiers (eg, patients with both *POLE*mut and p53abn should be managed as *POLE*mut).
‡According to the binary FIGO grading, grade 1 and grade 2 carcinomas are considered as low-grade and grade 3 carcinomas are considered as high-grade.
LVSI, lymphovascular space invasion; MMRd, mismatch repair deficient; NSMP, non-specific molecular profile; p53abn, p53 abnormal; *POLE*mut, polymerase-mutated.

2020 risk stratification, molecular classification known:

MMRd/NSMP:

- Histotype
- Grade
- Stage
- LVSI

P53 abn:

- High-risk except for rare Stage IA without myoinvasion

POLEmut stage I/II

- Low-risk

If p53 is mutational type, what other testing would be required in this case?

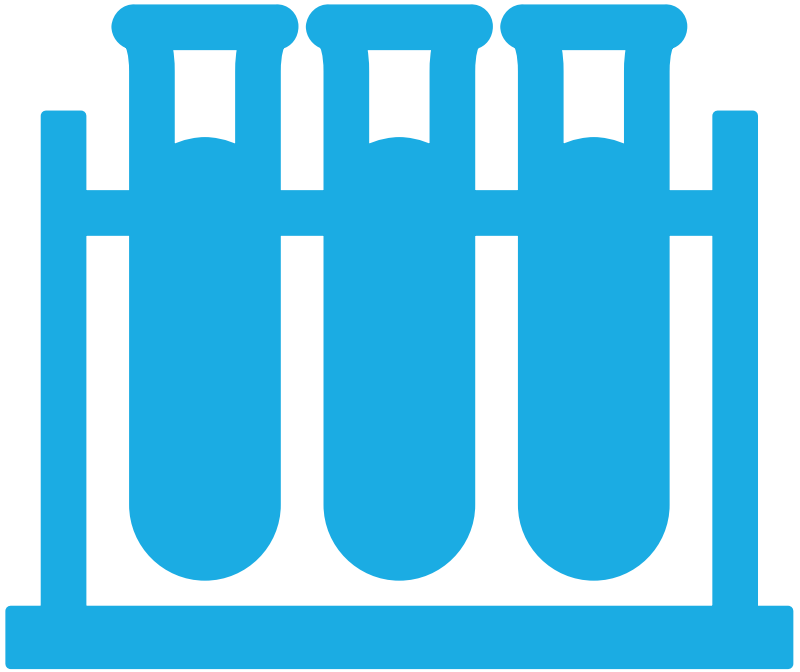

The British Association of Gynaecological Pathologists

BRITISH GYNAECOLOGICAL CANCER SOCIETY

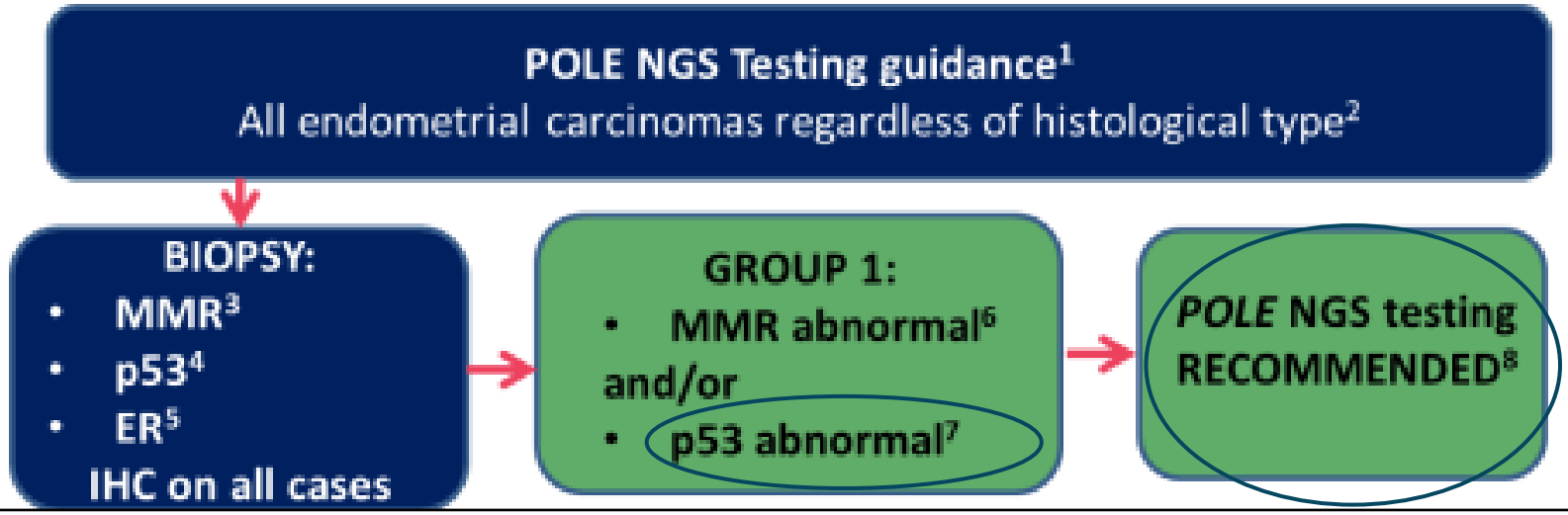

OSPE 2

- You are working in a tertiary referral centre (Hospital A) which receives histology samples from another nearby hospital (Hospital B) via courier service. The Hospital A's pathology lab received calls from several clinicians (Hospital B) asking for reports for the histology samples sent on 11th May. The lab cannot find any evidence of any sample sent on that date. Usually about 25 samples are received from hospital B on a routine day. Specimen reception staff note that the specimens are often transported in large black plastic bags (resembling garbage bags) and not in the specimen transfer boxes.

What might have happened?



DISCARDED



LOST IN TRANSIT



NOT SENT

How would you deal with the situation?

- Investigate and seek more information
- Call lab meeting
- Call courier company and check
- Check the discarded bags
- Check with clinicians (Ask endoscopist or staff for list of patients)
- Check with staff and check log register (Chain of custody).
- CCTV footage
- Incidence reporting

Who needs to be informed?

- Lab manager and staff
- Clinicians and OT staff
- Clinical lead and head
- Medical director
- Courier company

What are the possible consequences?

- Patient safety and confidentiality compromised
- Delay in diagnosis and treatment
- Disease progression or death
- Repeat procedure/precious sample
- Legal and financial implications
- Environmental safety

What can be done to prevent this in the future

- Check SOPS and amend (separate colored boxes)
- Specimen transfer boxes, Tracking system, bar coding
- Staff training
- Promote whistleblowing system
- Audit/reaudit after 6 -12 months.

Thank you for your attention!