The British Association of Gynaecological Pathologists

Lecturer – Dr Mahfooz Basha Mohamed



Consultant Gynaecological Pathologist, University College London Hospitals NHS Foundation Trust, London.

Council member, British Association of Gynaecological Pathologists

The British Association of Gynaecological Pathologists

Gynae Mock Exam

Long Cases

Dr Mahfooz Basha Mohamed

University College London Hospitals NHS Foundation Trust, London

24-09-2025

The British Association of Gynaecological Pathologists

Speaker disclosures

Choose one

- ❑ I have no financial conflicts of interest to disclose

Long case 1

63 F

Debulking for ovarian mass

1 HE and 8 IHC



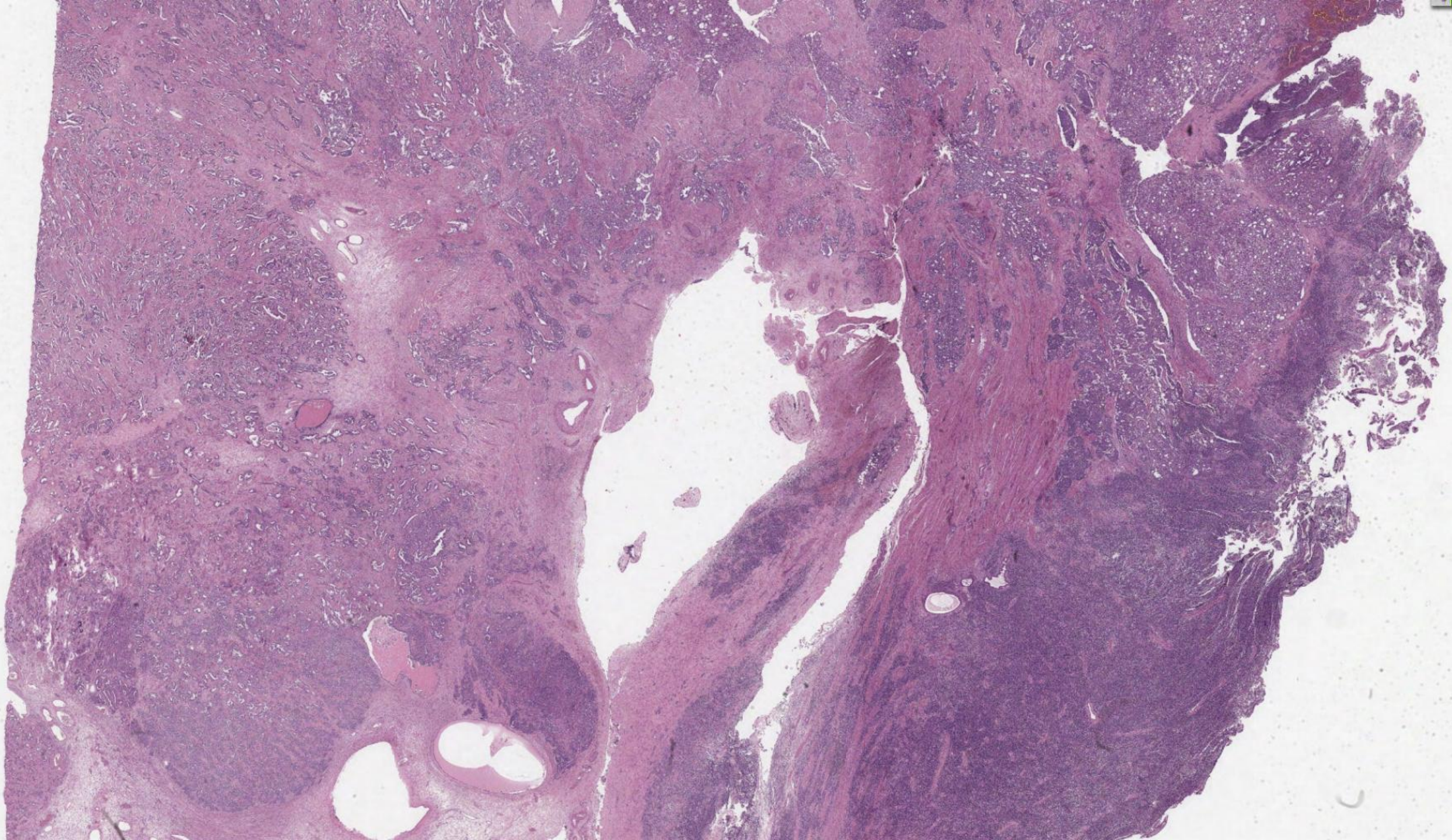

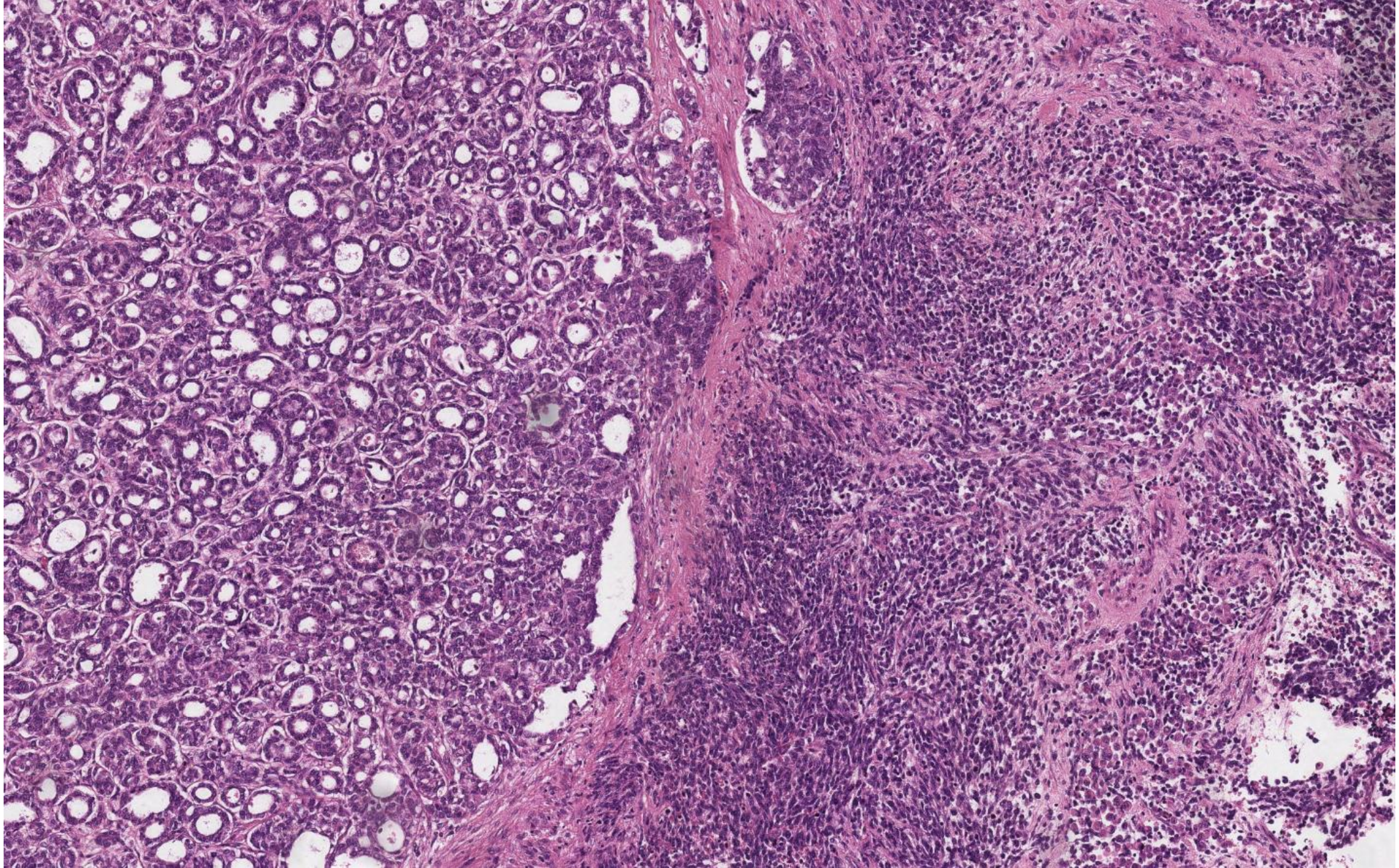

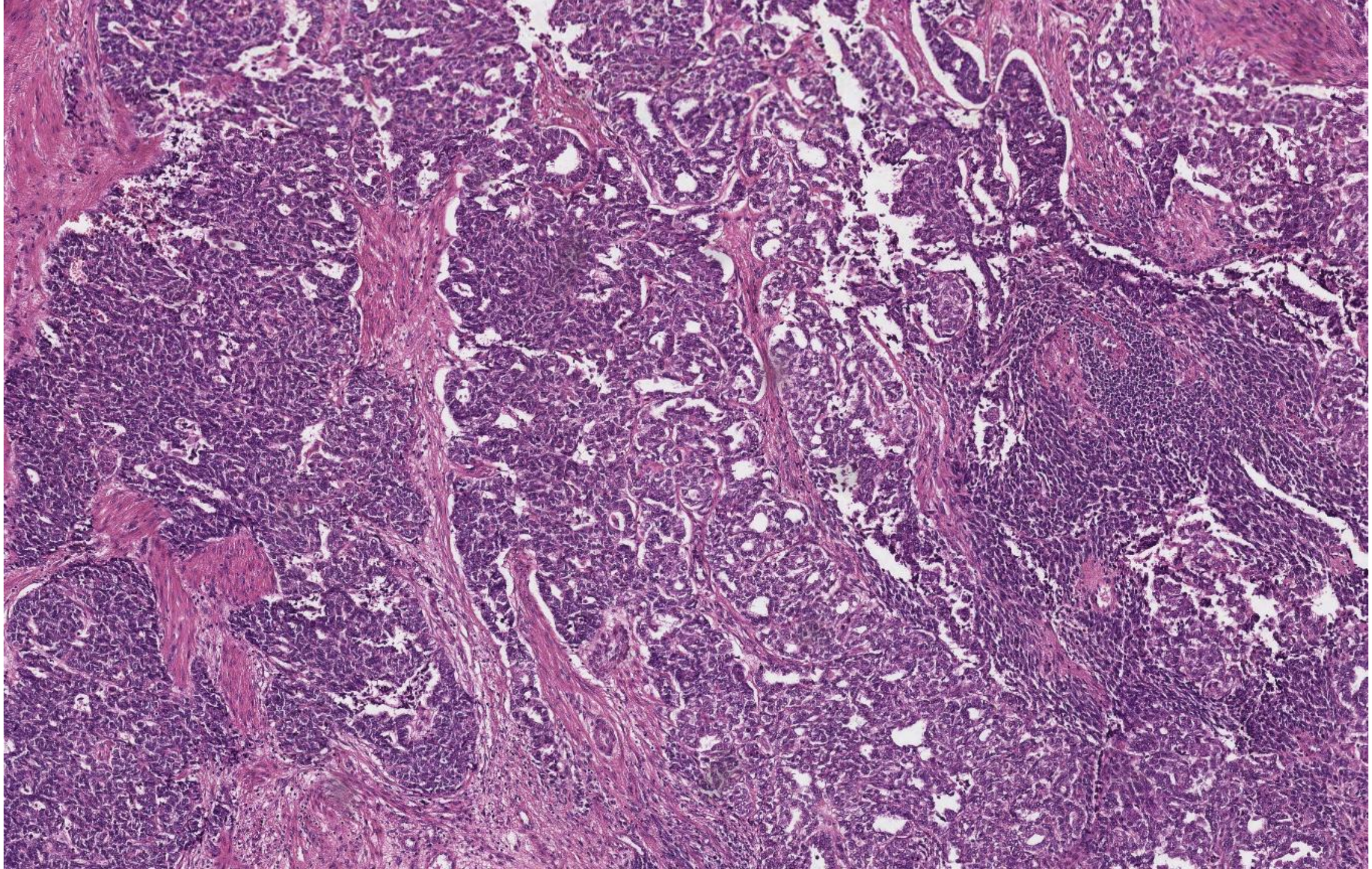

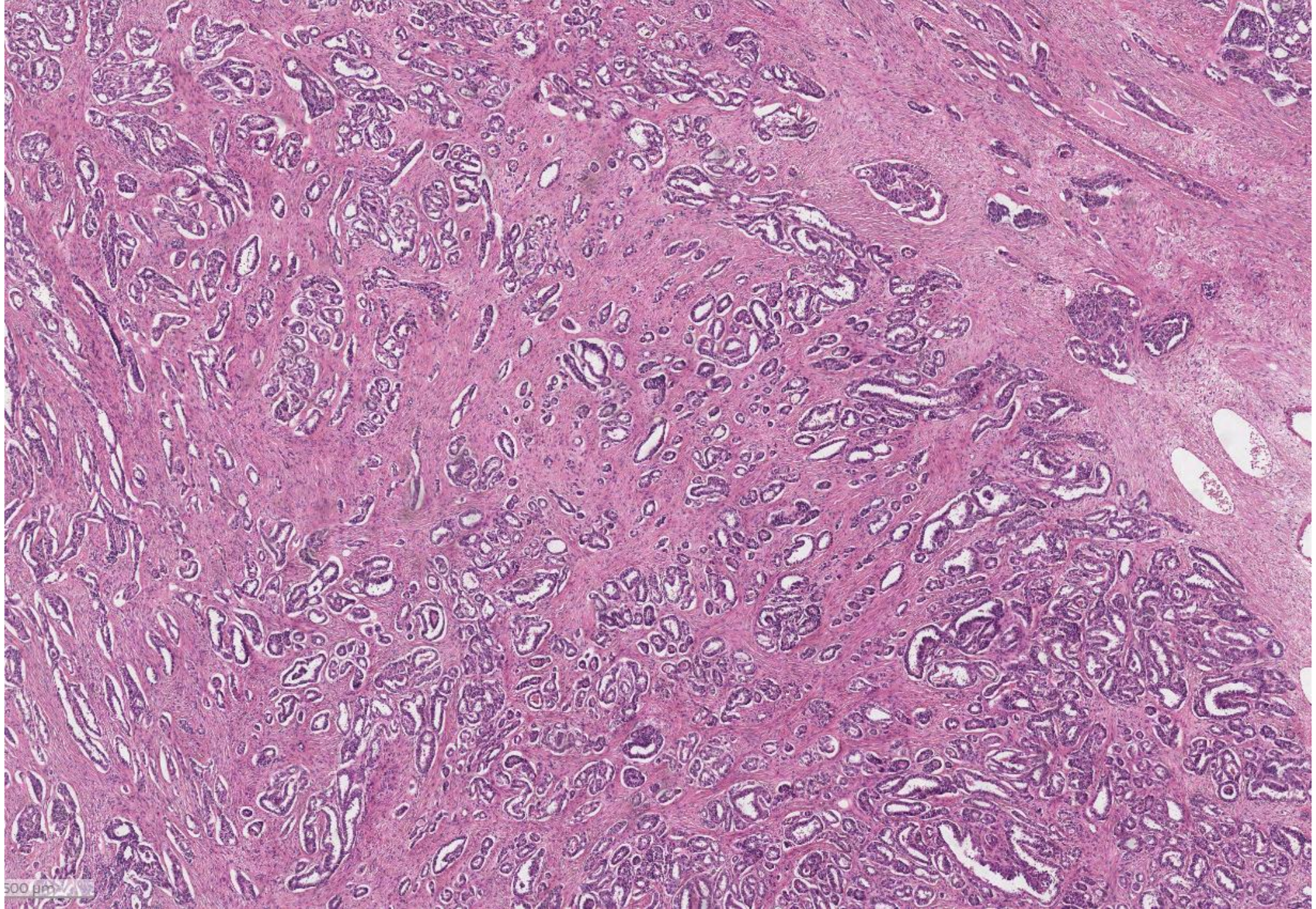
500 µm

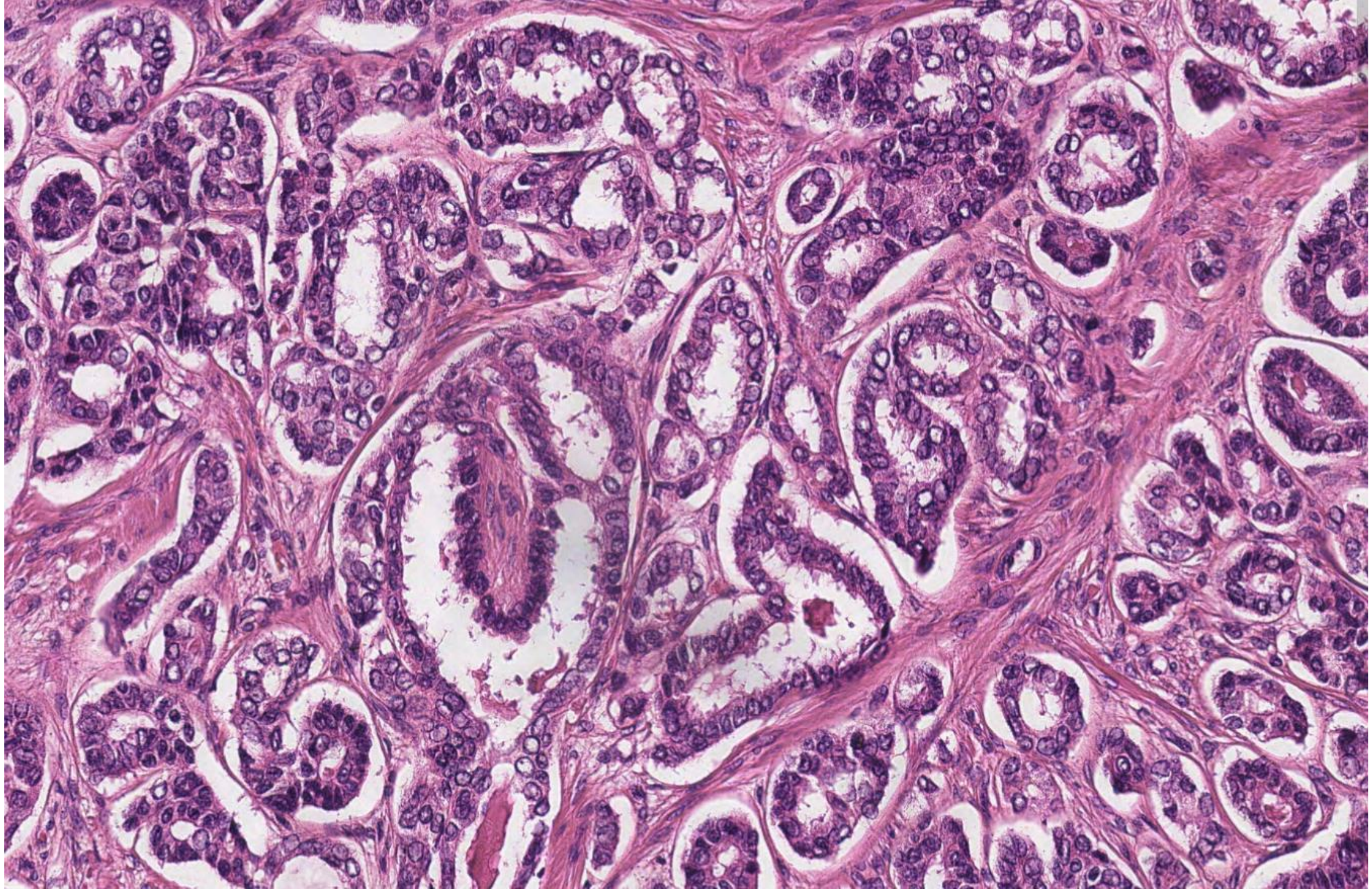

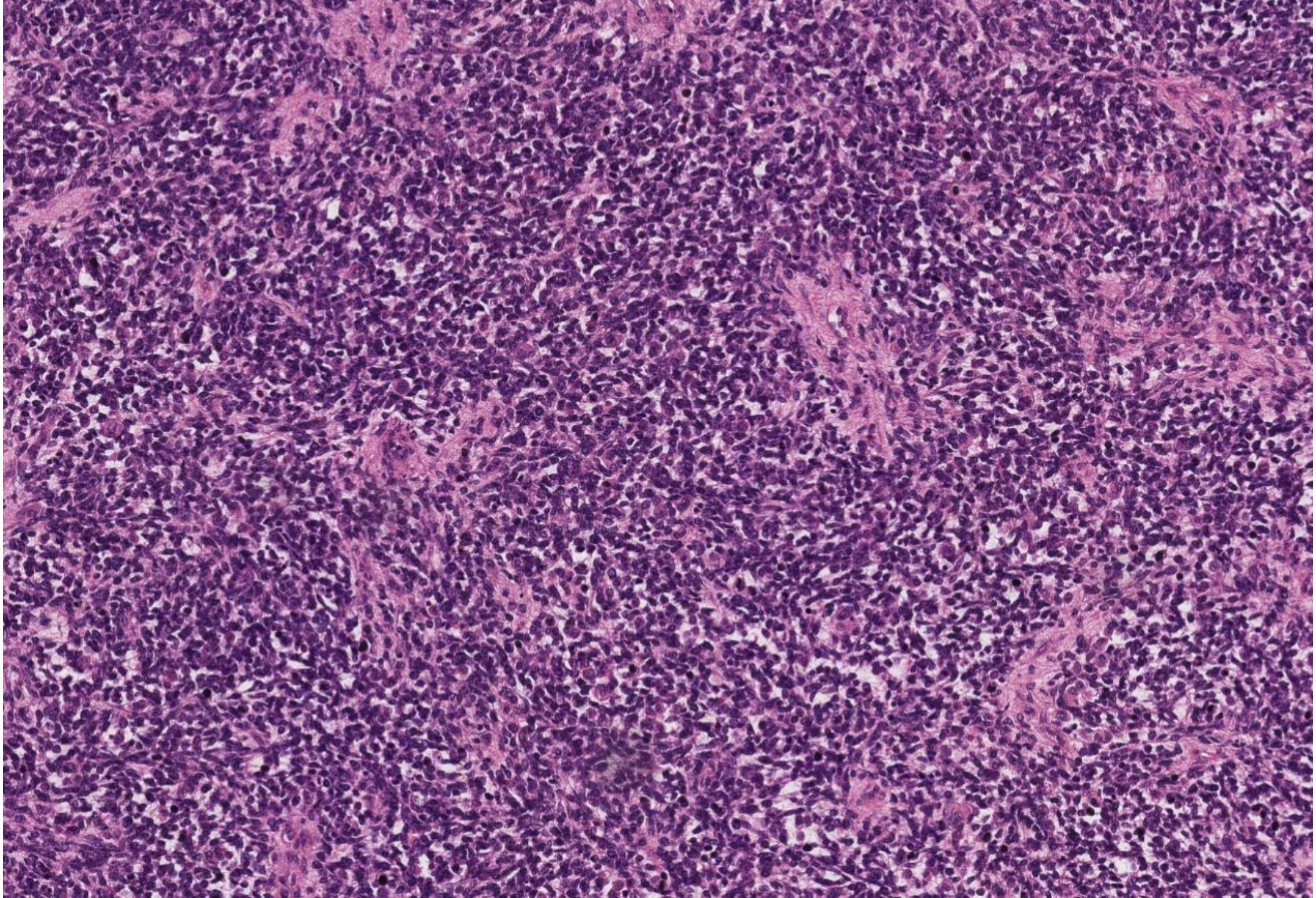

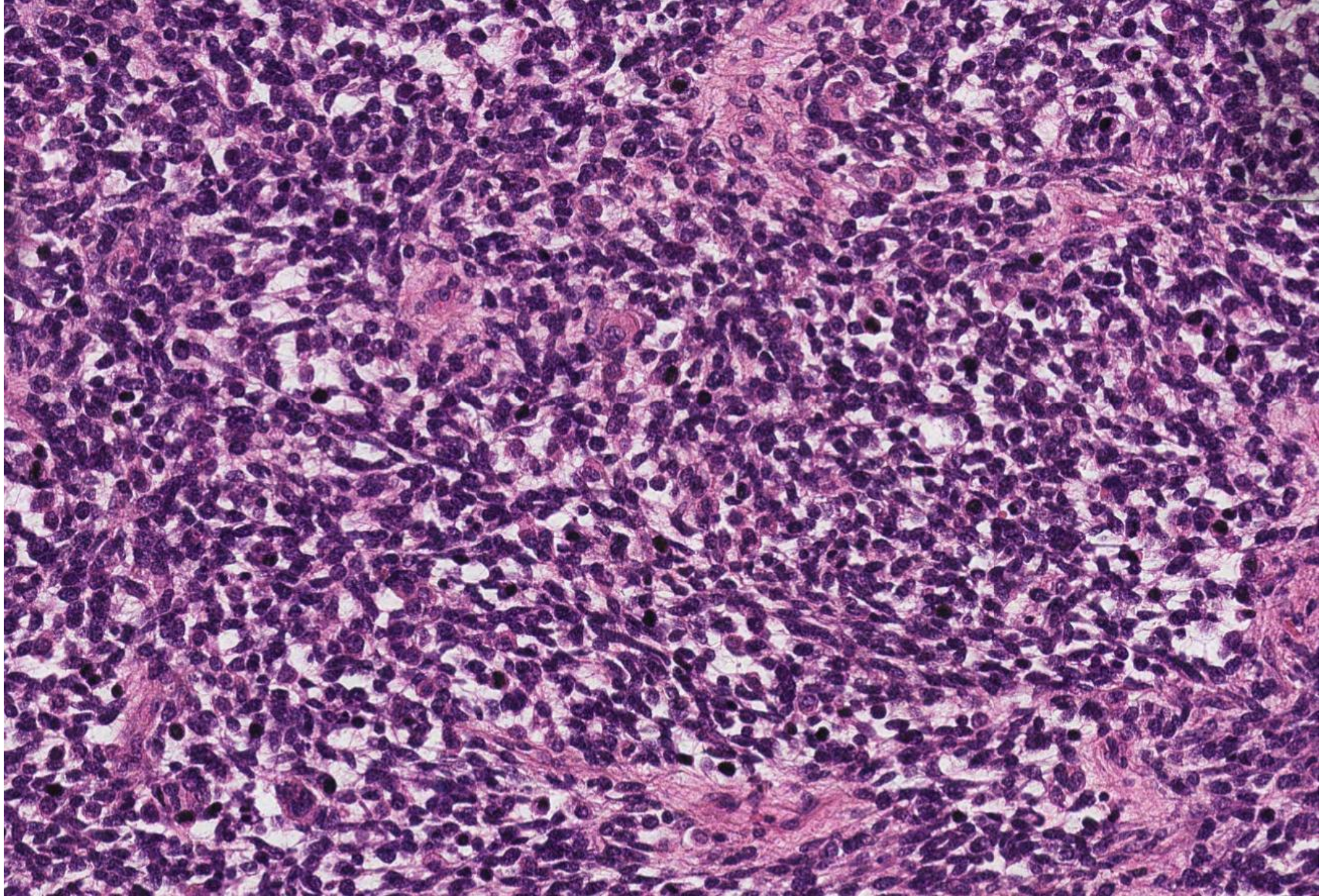

Microscopic examination

- Section of ovarian mass

- Malignant tumour with biphasic morphology

- One component:

Acini, tubules, glands, papillae
Uniform mild degree of nuclear atypia
Vesicular appearance of nuclei
No squamous morules/background endometriosis

- Another component:

Solid sheets, high N;C ratio
Hyperchromatic nuclei
Round, ovoid, spindled nuclei

Provisional diagnosis

-**Carcinosarcoma**

d/d Endometrioid adenocarcinoma with dedifferentiated component

Immunohistochemistry

- Epithelial component:

Positive: PAX8, TTF-1, ER (not diffuse), GATA 3

Negative: WT-1, PR, Desmin

p53: wild type

- Sarcomatous component:

Positive: Desmin

Negative: PAX 8, TTF -1, WT-1, ER, PR, GATA 3

p53: wild type

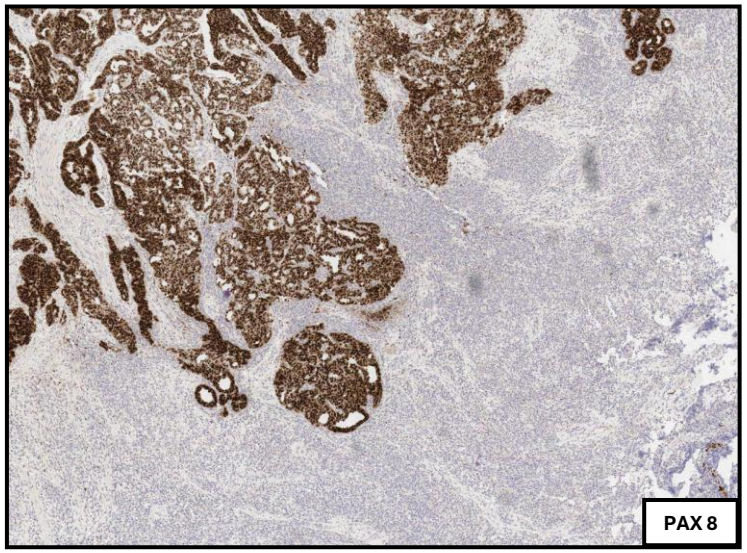

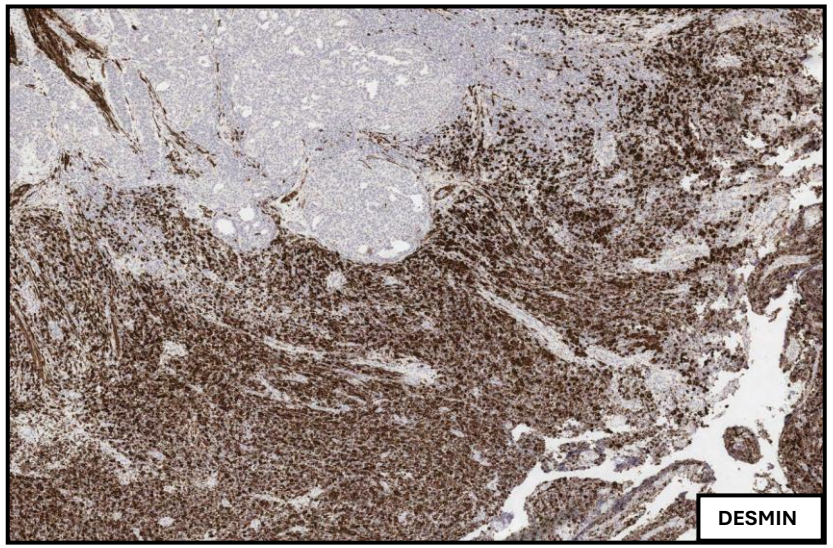

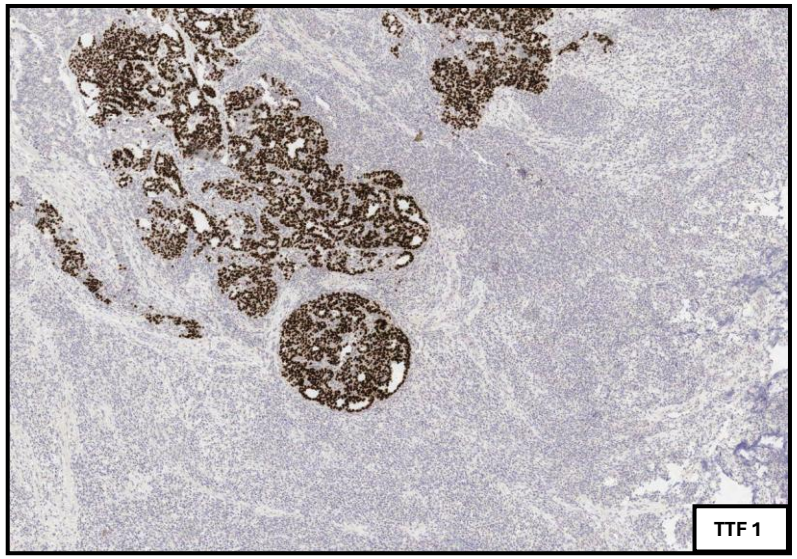

Immunohistochemistry

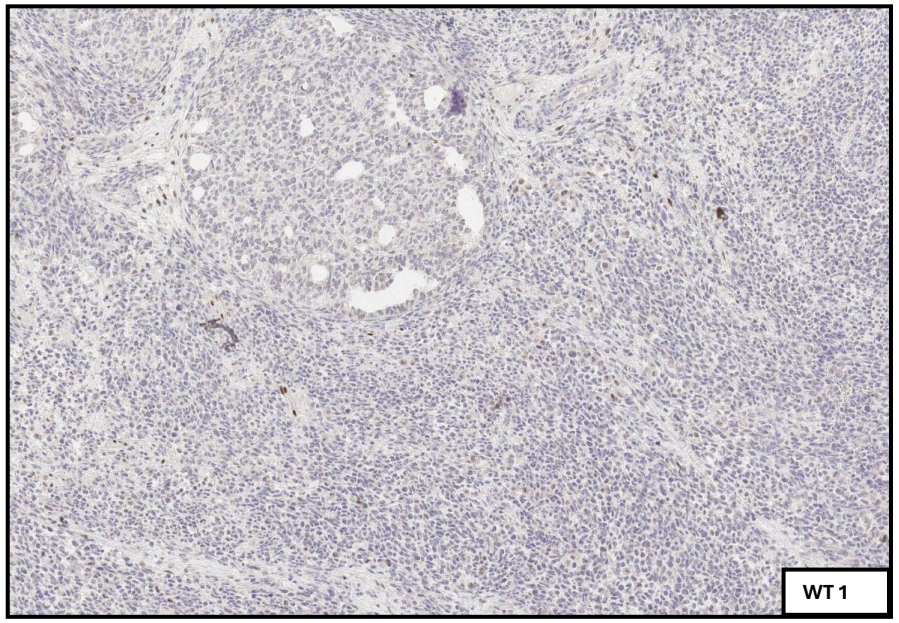

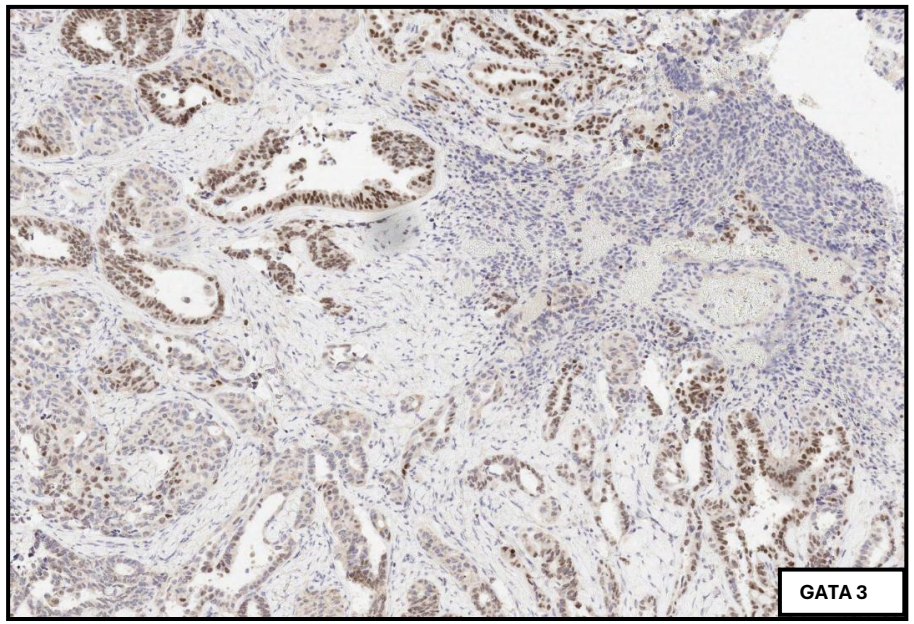

- GATA 3 – focal + in epithelial areas, neg in sarcomatous areas

Immunohistochemistry

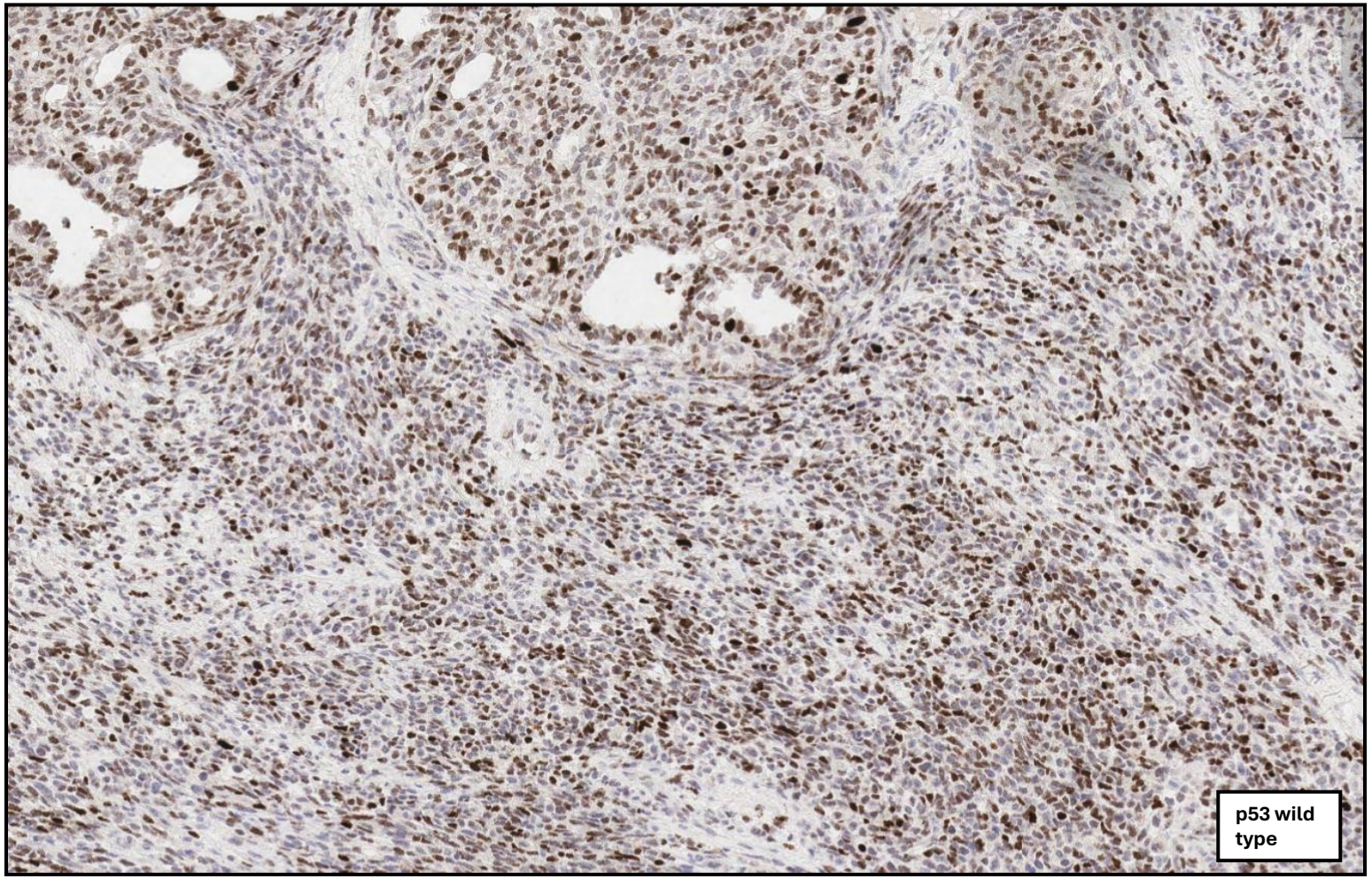

- Wild type
- Mutant

Immunohistochemistry

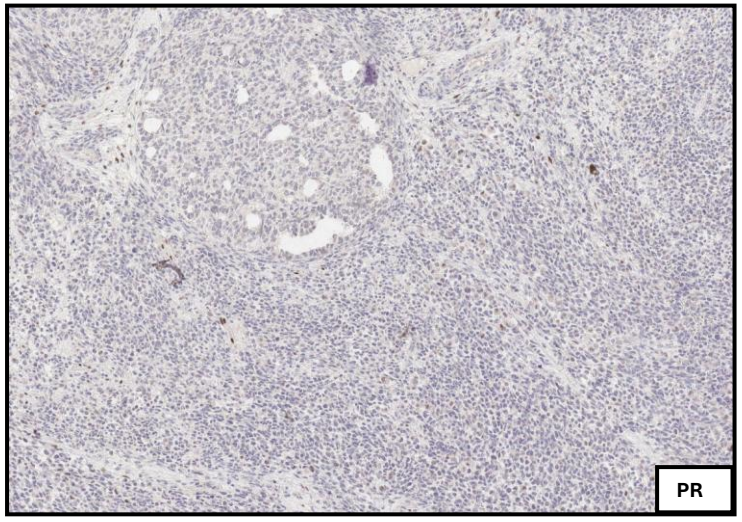

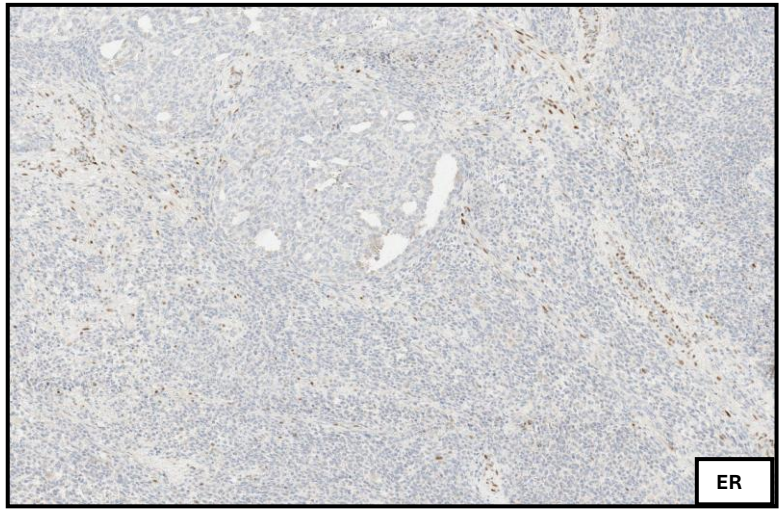

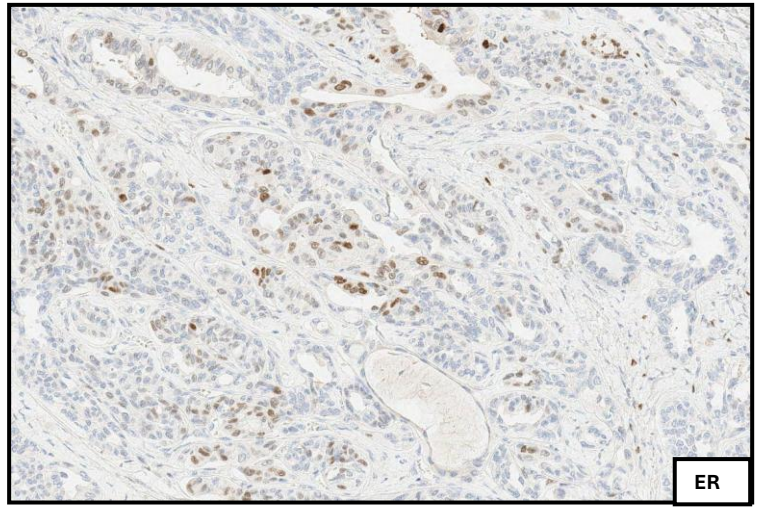

PR: negative (0/8)
ER : + epithelial component (5/8), neg in sarcomatous component

Allred score * for estrogen and progestrone receptor evaluation.

ER Status (Positive Cells %)	Proportion Score	Intensity	Intensity Score
0	0	None	0
<1	1	Weak	1
1 to 10	2	Intermediate	2
11 to 33	3	Strong	3
34 to 66	4		
≥67	5		

Discussion

Diagnosis:

- Carcinosarcoma (high grade by definition)
- Carcinoma- MLA (70%)
- Sarcoma (30%) could be RMS- myogenin, Myo D1

See comments

- Capsule status comment- appears breached- could be IC disease, to correlate with macroscopic findings, block key. Intra op notes correlation may be needed.
- BRCA HRD testing
- MMR status

TNM 7	TNM 8	FIGO stage	Descriptor
T – Primary tumour			
TX	TX		Primary tumour cannot be assessed
T0	T0		No evidence of primary tumour
T1	T1	I	Tumour limited to the ovaries or fallopian tube
T1a	T1a	IA	Tumour limited to one ovary (capsule intact) or fallopian tube, no tumour on ovarian or fallopian tube surface; no malignant cells in ascites or peritoneal washings
T1b	T1b	IB	Tumour limited to one or both ovaries (capsule intact) or fallopian tubes, no tumour on ovarian or fallopian tube surface; no malignant cells in ascites or peritoneal washings
T1c	T1c	IC	Tumour limited to one or both ovaries or fallopian tubes with or without any of the three criteria below:
	T1c1	IC1	• Surgical spill
	T1c2	IC2	• Capsule ruptured before surgery or tumour on ovarian or fallopian tube surface
	T1c3	IC3	• Malignant cells in ascites or peritoneal washings
T2	T2	II	Tumour involves one or both ovaries or fallopian tubes with pelvic extension (below the pelvic brim) or primary peritoneal carcinoma
T2a	T2a	IIA	Extension and/or implants on uterus and/or fallopian tube(s) and/or ovaries
T2b	T2b	IIB	Extension to other pelvic tissues, including bowel serosa within the pelvis
T3 and/or N1	T3 and/or N1	III	Tumour involves one or both ovaries or fallopian tubes or primary peritoneal carcinoma with microscopically confirmed peritoneal metastases outside the pelvis and/or regional lymph node metastasis (includes liver capsular metastasis)
T3a	T3a	IIIA2	Microscopic peritoneal metastasis beyond pelvis, with or without retroperitoneal lymph node involvement
T3b	T3b	IIIB	Macroscopic peritoneal metastasis beyond pelvis, 2 cm or less in greatest dimension, with or without retroperitoneal lymph node involvement, including bowel involvement
T3c and/or N1	T3c	IIIC	Peritoneal metastasis beyond pelvis more than 2 cm in greatest dimension with or without retroperitoneal lymph node involvement
M1	M1	IV	Distant metastasis (excludes peritoneal and liver

- What more dataset related info can I provide?
- What more ancillary tests are needed or may be needed?
- Anything regarding the specimen macro/sampling?
- What would I discuss in the MDT?
- Is there something to say to show depth of knowledge, eg: molecular events?

Additional information

Percentage of components, mention provisional pre-MDT stage

Importance of adequate sampling- establishing components present- 1 block per cm.

Debulking specimen- look for metastasis elsewhere to determine stage.

Check other potential sites origin-endometrium.

If omentum is involved, mention CRS to be given if applicable.

MMR status.

BRCA HRD testing.

Comment on prognosis of carcinosarcoma. Heterologous differentiation- could have worse prognosis. MDT discussion.

LC1:Carcinosarcoma (MLA and possibly rhabdomyosarcoma components)

Mark	Features
1-7	Fails to diagnose
8-9	Basic description, does not confidently state diagnosis
10	Just adequate description with confident diagnosis but no additional information
11-14	Good description, includes some of the additional comments
15-16	Good description + additional comments, shows knowledge of molecular events

Long case 2

13 F

Core biopsy of pelvic mass, USS: appears to be in uterine wall

1 HE and 8 IHC





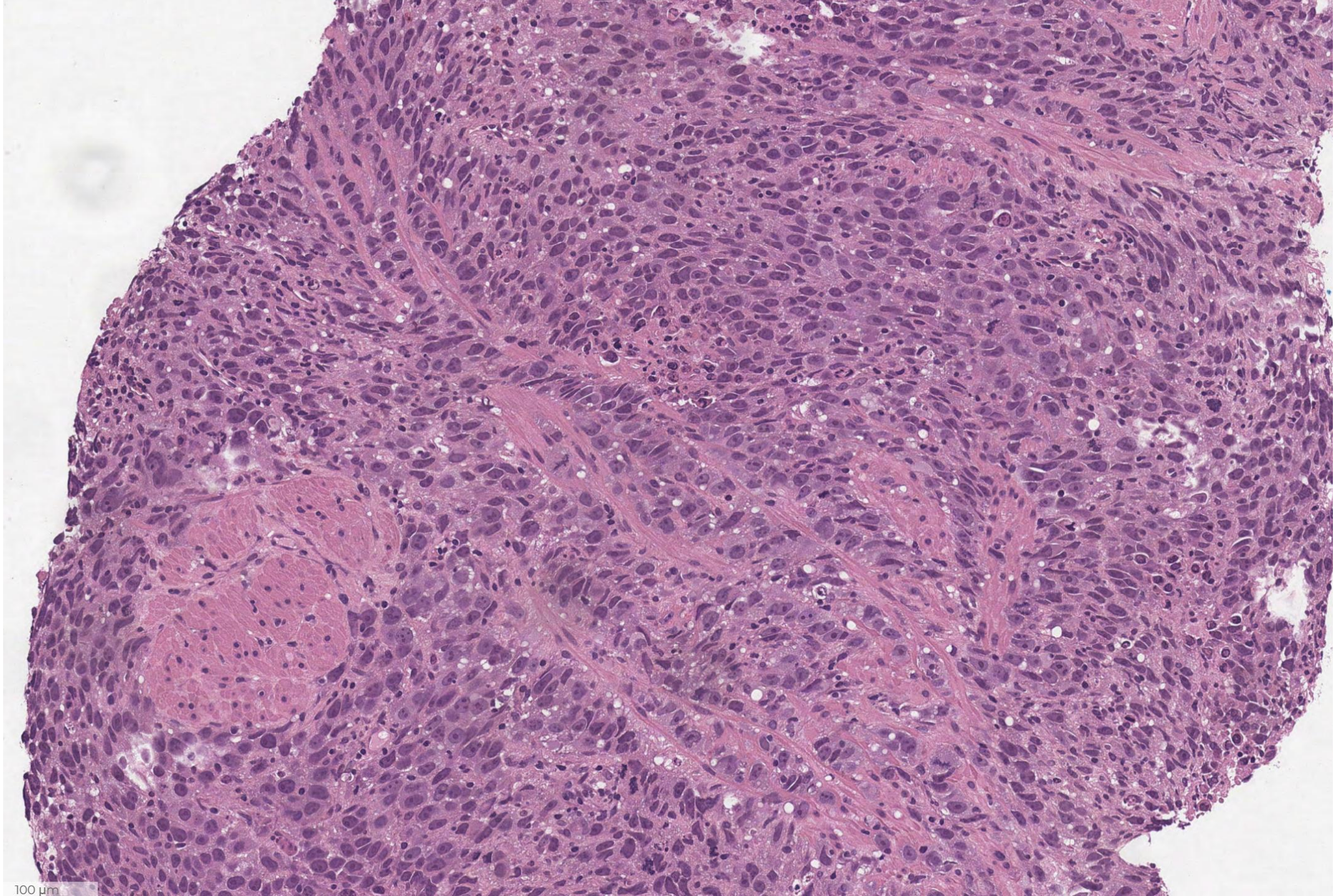
100 µm

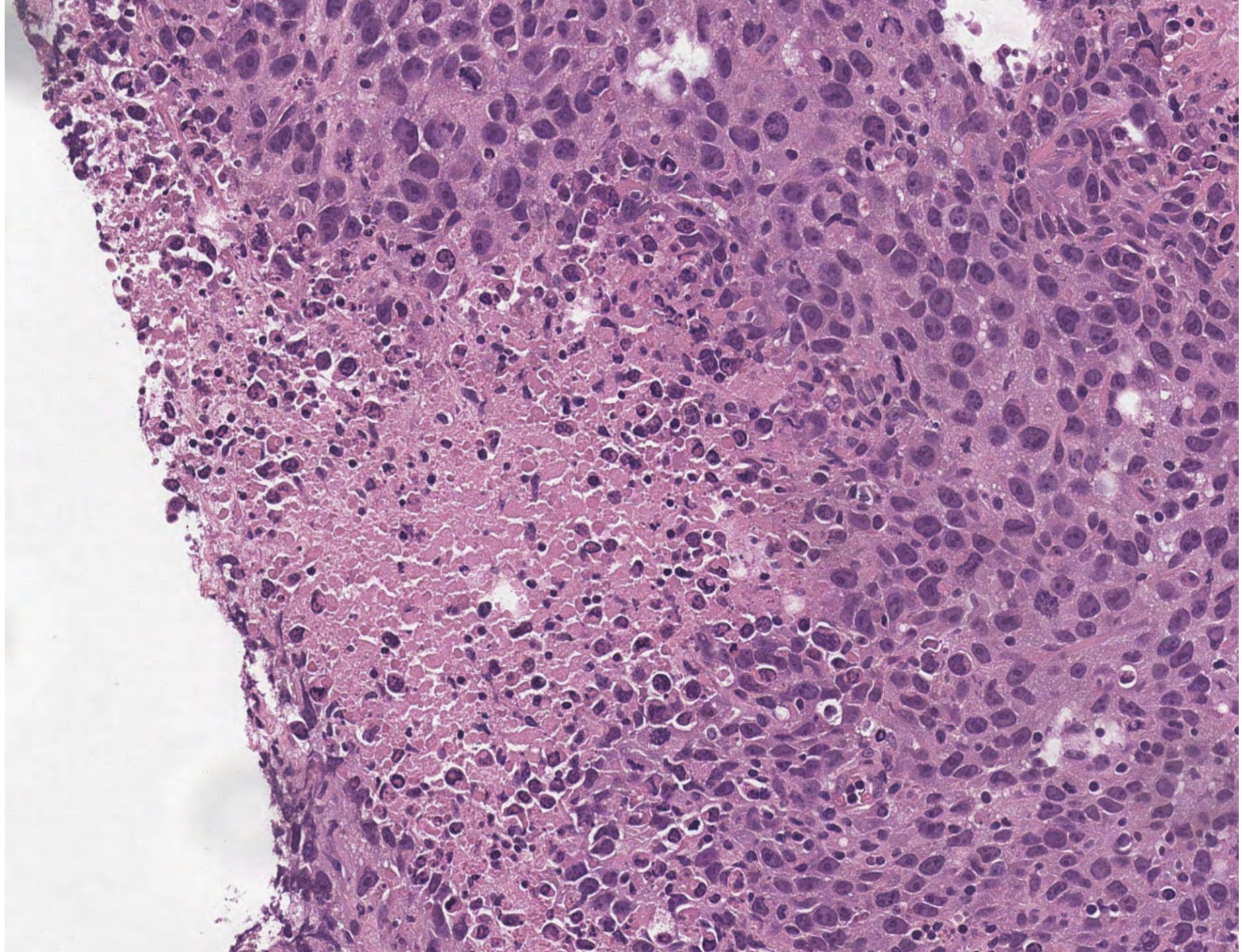

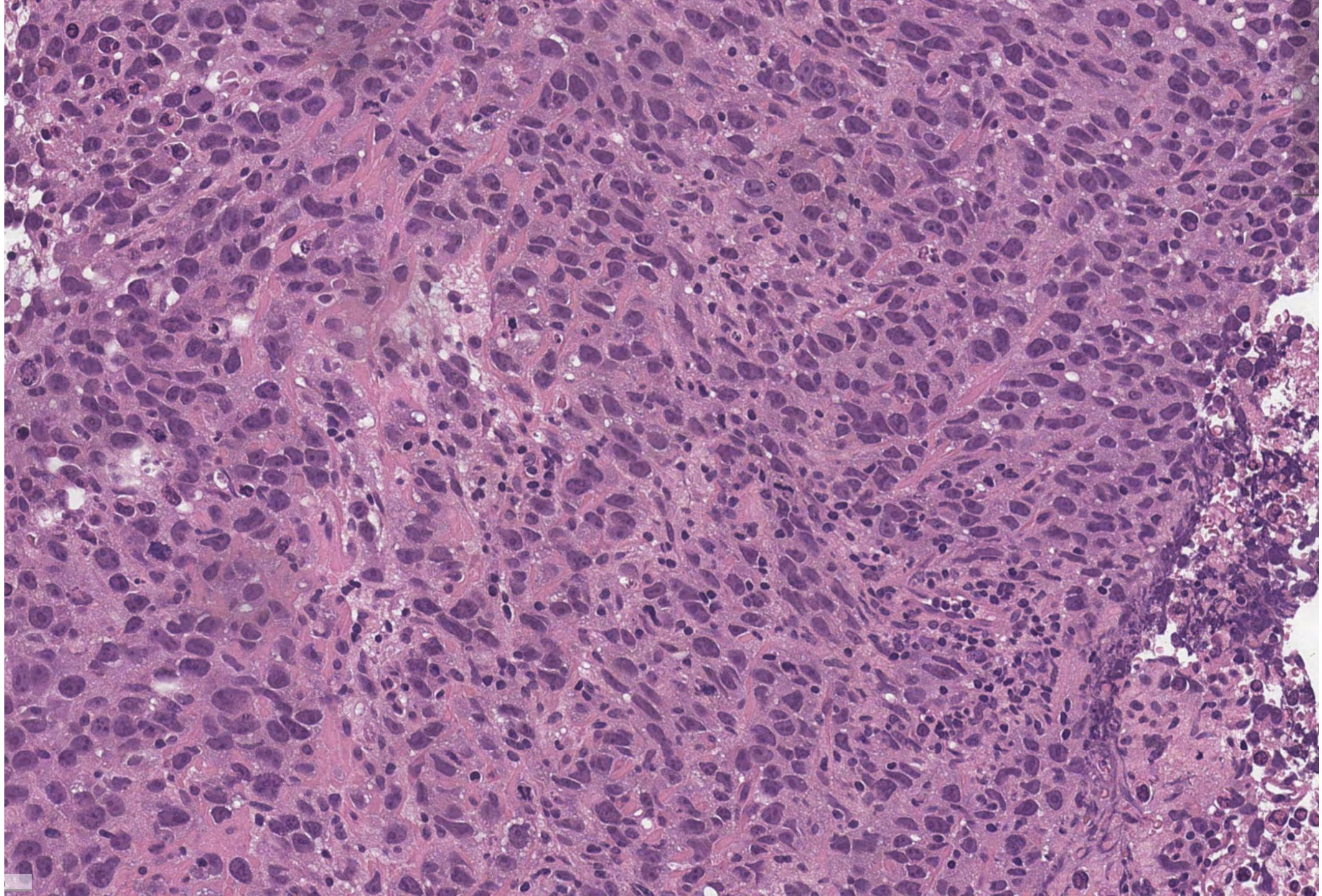

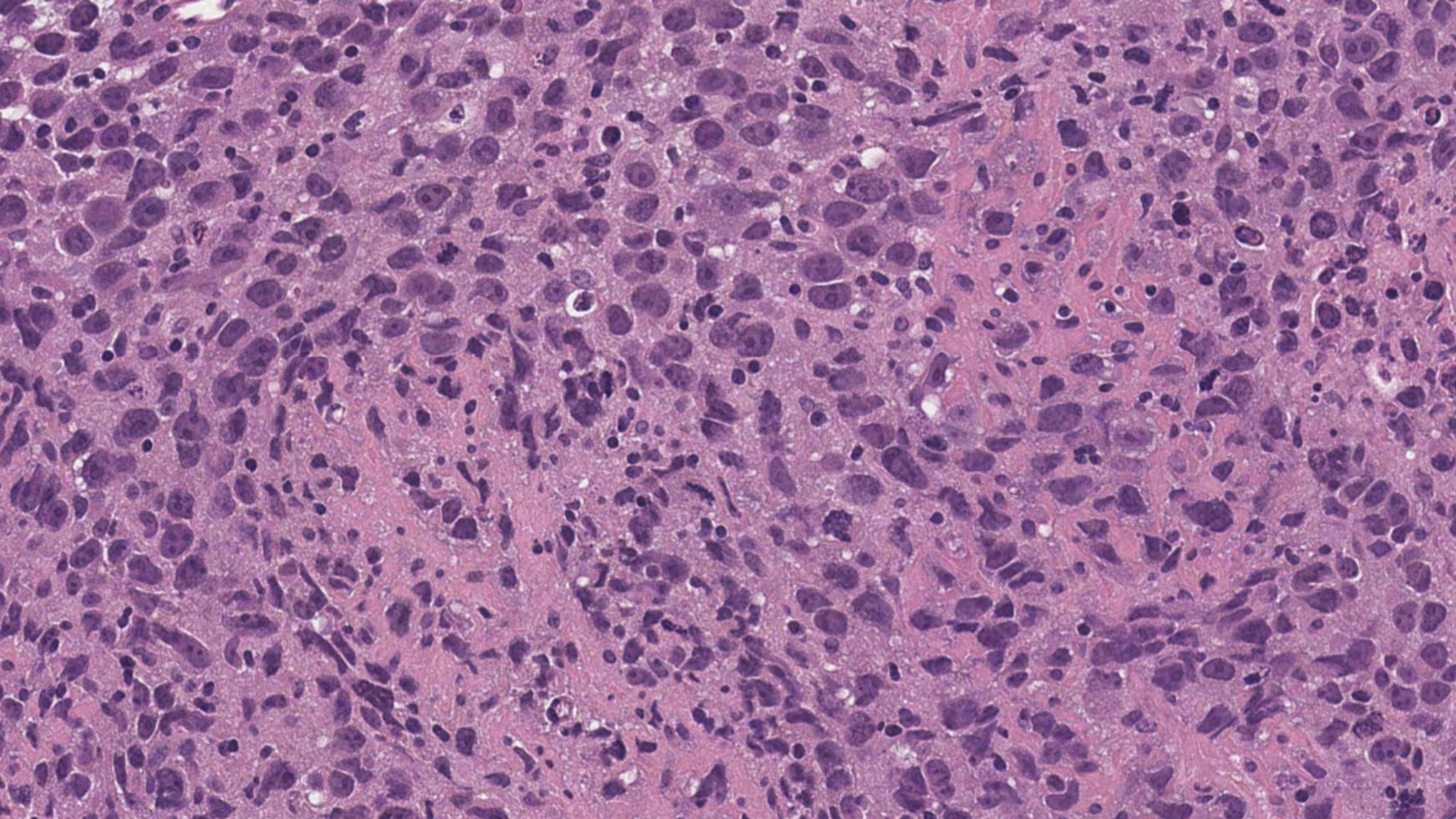

Microscopic examination

- Cores of smooth muscle tissue infiltrated by a malignant tumour

- Cellular sheets, foci of necrosis
- Medium to large sized polygonal cells
- Uniform appearance
- Angulated, squared off nuclei, single to multiple nucleoli
- Intervening fibrous septa with lymphocytes
- No syncytio trophoblastic giant cells

Provisional diagnosis

- Malignant germ cell tumour, favour dysgerminoma

- d/d: Embryonal carcinoma, YST, small cell carcinoma of hypercalcemic type (large cell variant), lymphoma

Immunohistochemistry

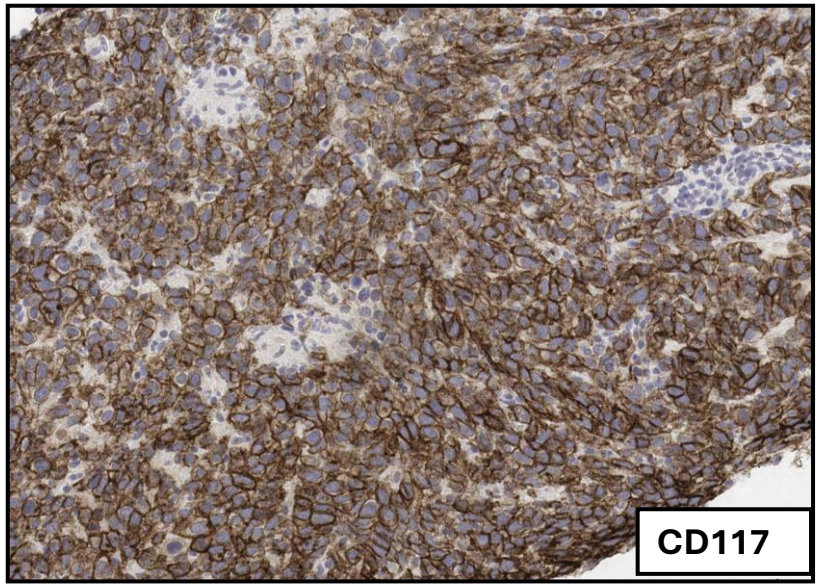

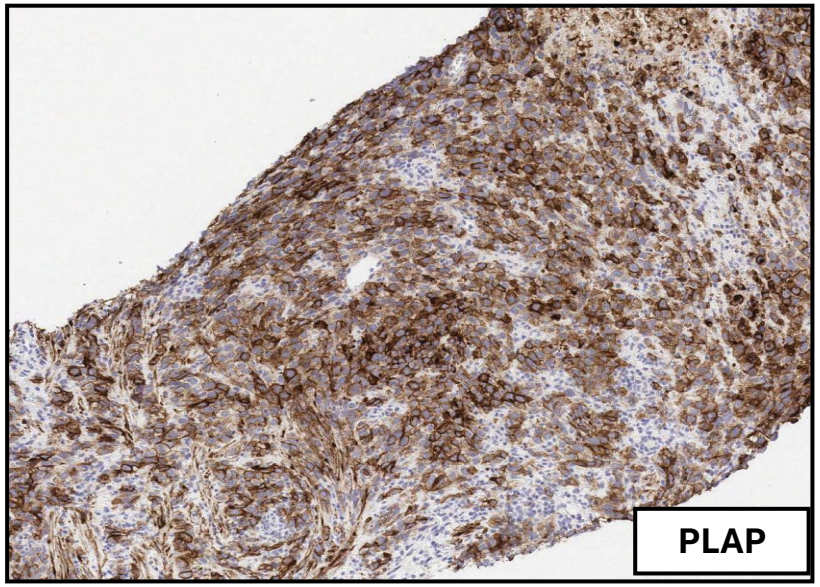

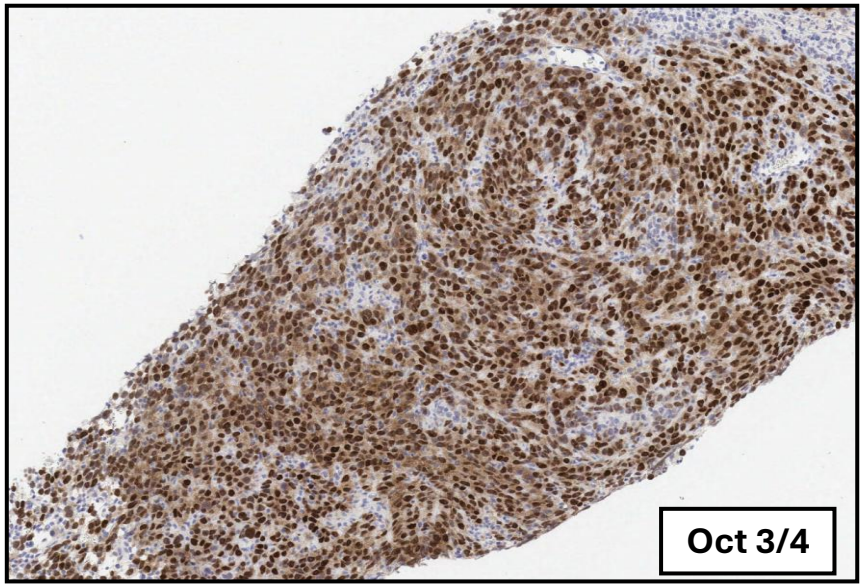

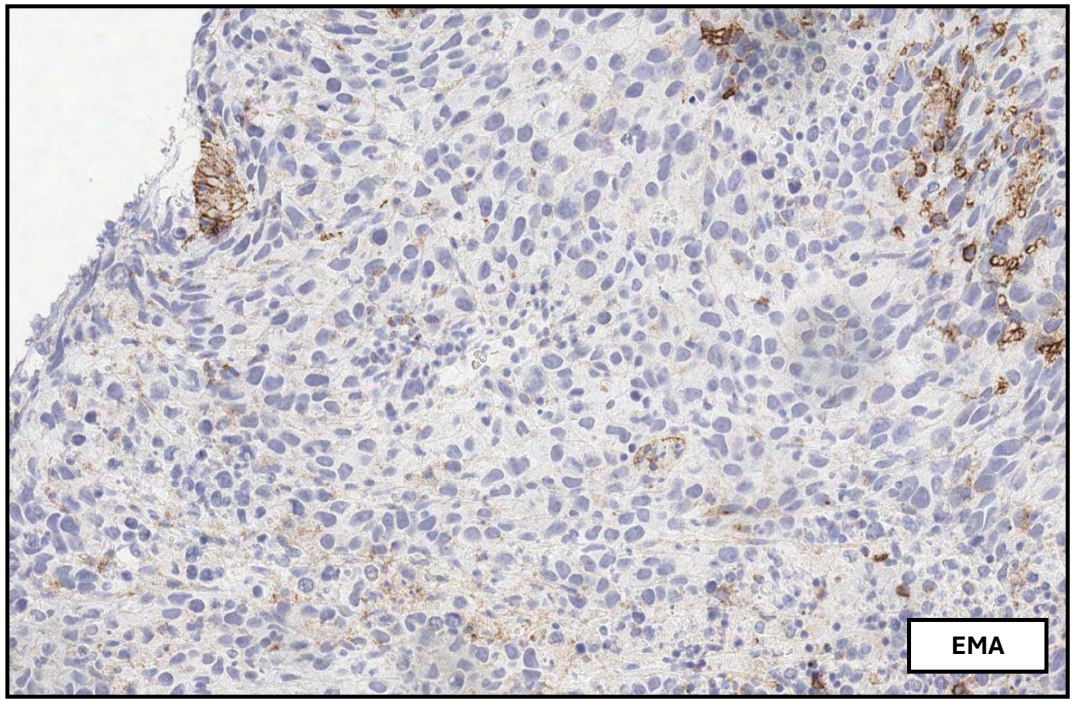
EMA

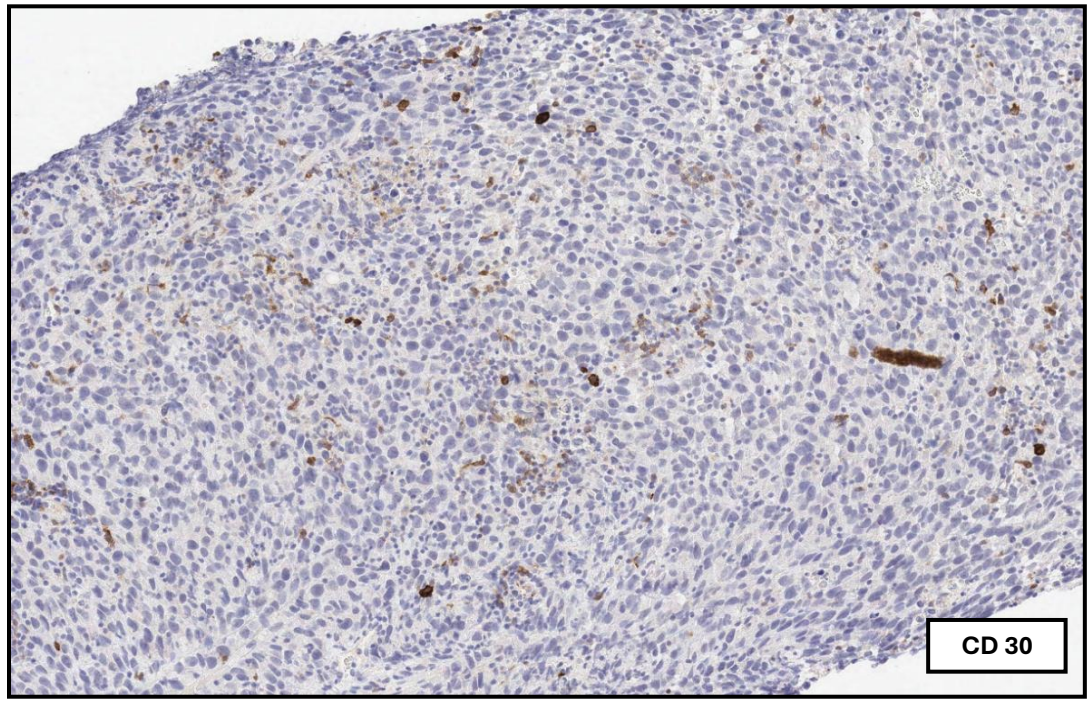
CD 30

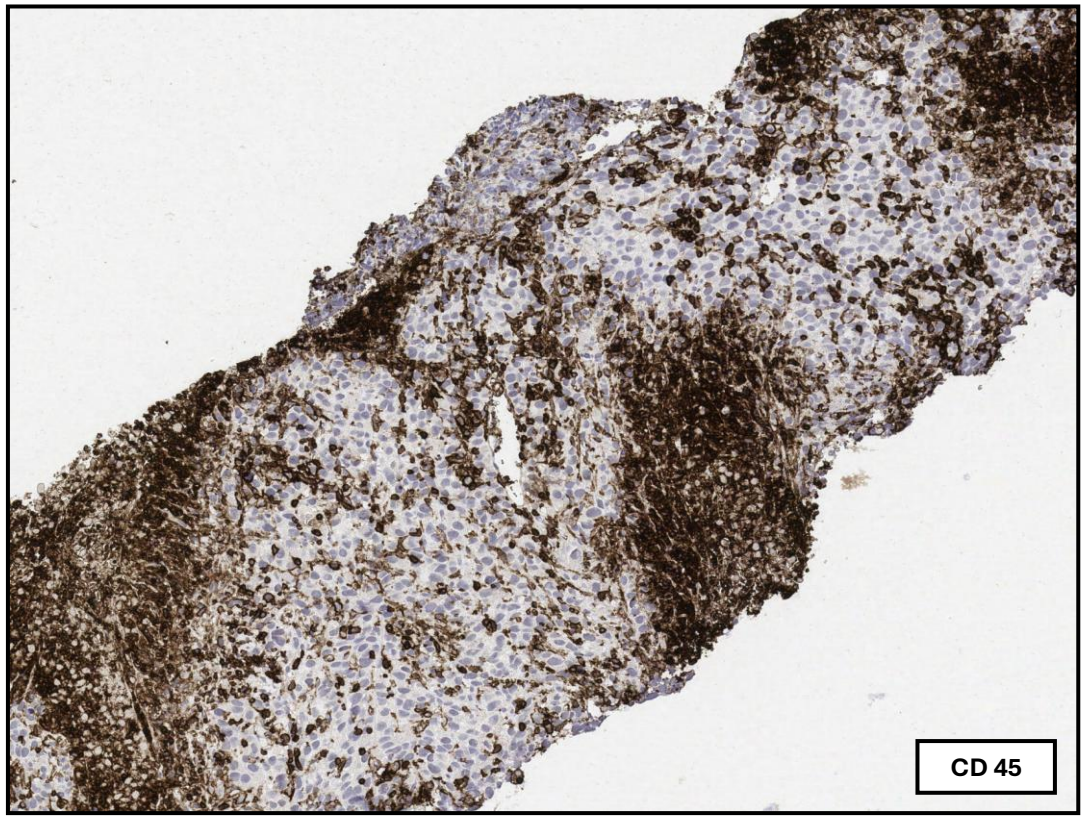
CD 45

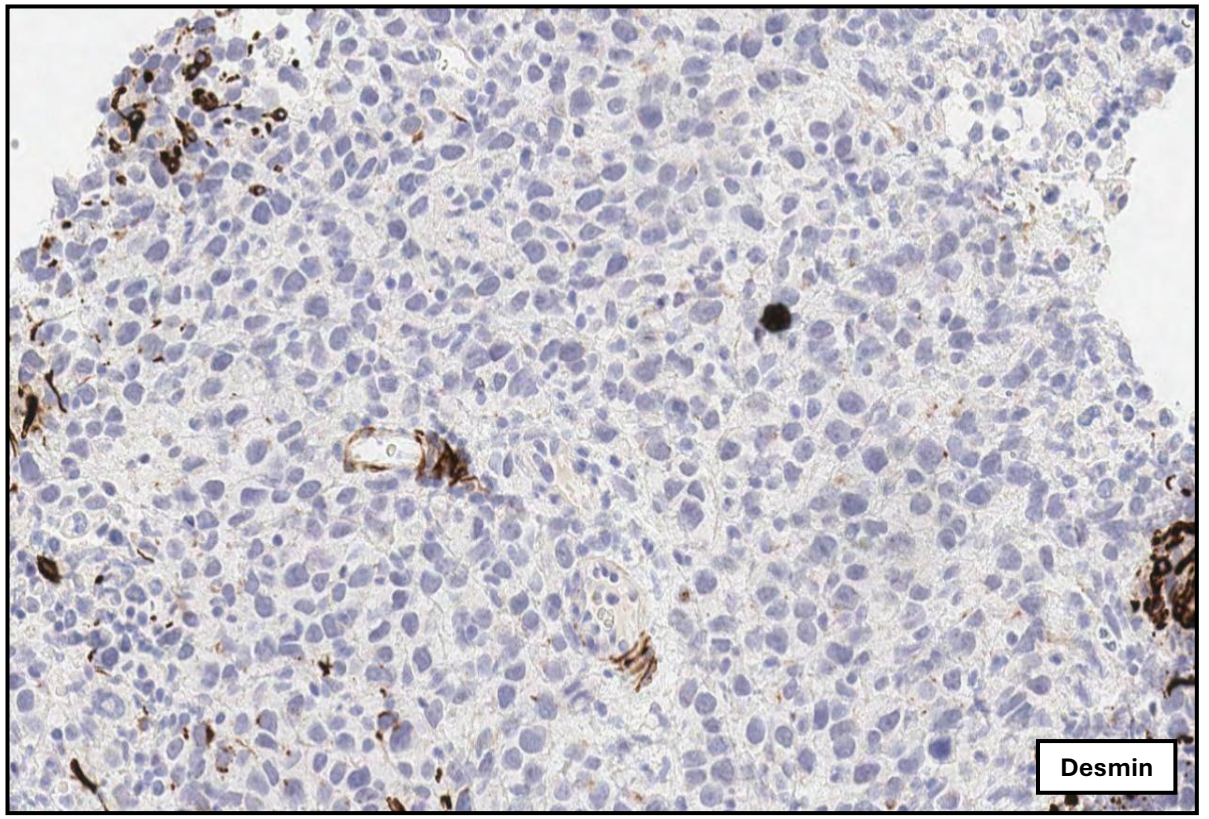
Desmin

Immunohistochemistry

Positive:

- CD117 (membranous)
- PLAP (membranous + cytoplasmic)
- OCT 3 / 4 (nuclear)

Negative:

- EMA
- CD30
- CD45
- Desmin

Table 1.03 Immunohistochemical profile of ovarian germ cell tumours

Tumour type	Immunohistochemistry									
	SALL4	LIN28	OCT4	KIT (CD117)	D2-40	CD30	SOX2	AFP	Glypican-3 (GPC3)	hCG
Dysgerminoma	+	+	+	+	+	–	–	–	–	–[a]
Yolk sac tumour	+	+	–	–/+	–	–	–	+	+	–
Embryonal carcinoma	+	+	+	–	–	+	+	–	–	–[a]
Choriocarcinoma	+/–	+/–	–	–	–	–	–	–	–	+
Immature teratoma	+/–	+/–	–	–	–	–	+/–	–	–/+	–[a]

[a] ... they are hCG-positive

Discussion

- Diagnosis
- Dysgerminoma, no other germ cell component seen in this specimen, see comments.

Additional information

Origin – extra ovarian rare, possible myometrial infiltration from ovarian tumour.

Staging as per TNM/FIGO, this is main prognostic factor.

Most common malignant germ cell tumour of ovary.

Excellent prognosis, >90 % survival.

Macro-calcified areas- gonadoblastoma.

Diagnosis can be challenging at metastatic sites, as poorly formed granulomas can occur that obscure the tumour cells.

Tumour marker status-expect elevated LDH.

hCG can be elevated (syncytio trophoblast giant cells).

AFP is not increased in pure dysgerminoma.

Karyotyping – chromosome 12 abnormalities.

KIT mutation/amplification.

MDT discussion.

There can be other germ cell components, limitation of core biopsy.

LC 2: Dysgerminoma

Mark	Features
1-7	Fails to diagnose
8-9	Basic description, does not confidently state diagnosis
10	Just adequate description with confident diagnosis but no additional information
11-14	Good description, includes some of the additional comments
15-16	Good description + additional comments, shows knowledge of molecular events

Long case 3

14 F

Right oophorectomy 230mm mass, normal fallopian tube

1 HE and 5 IHC



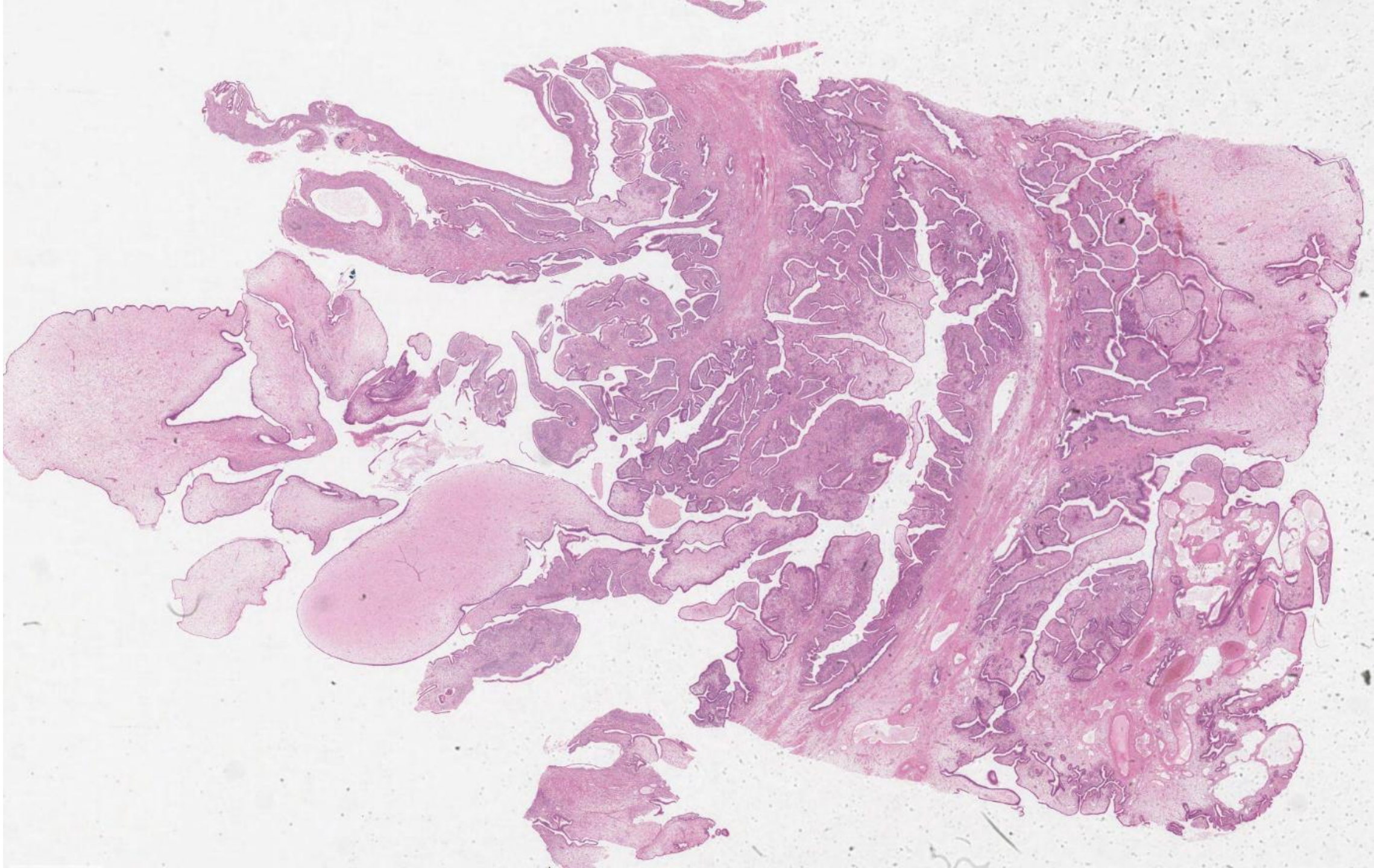

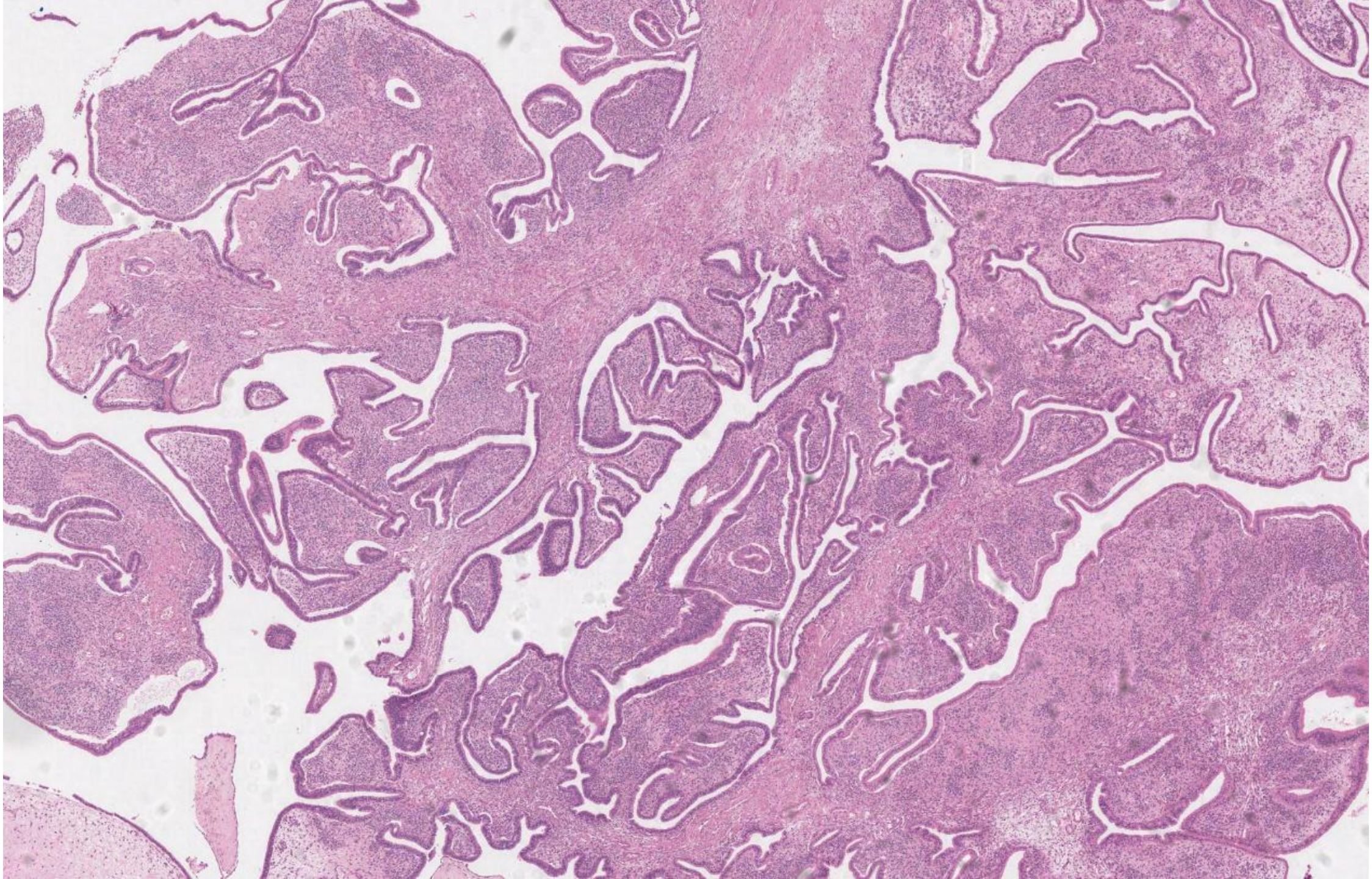

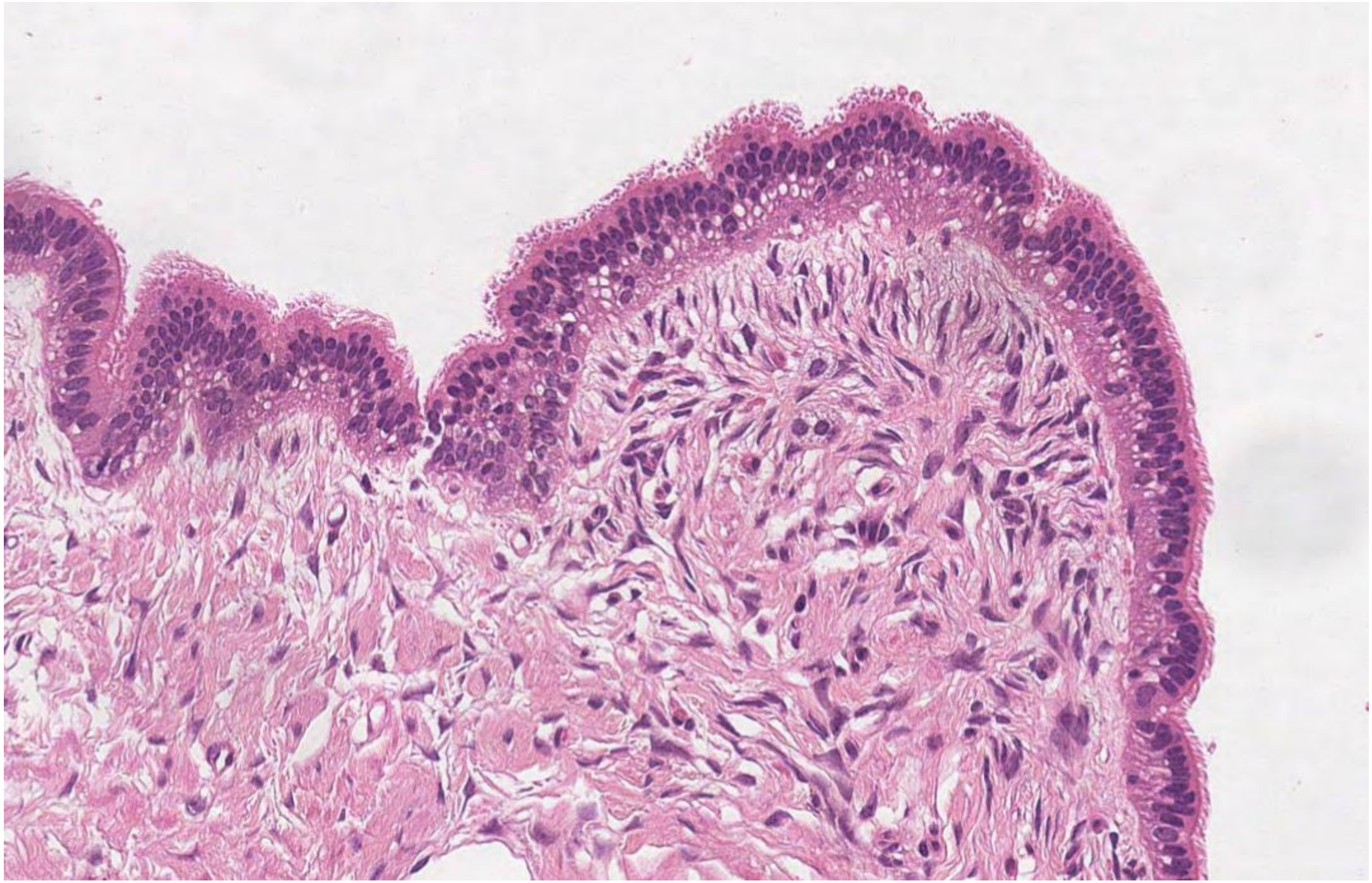

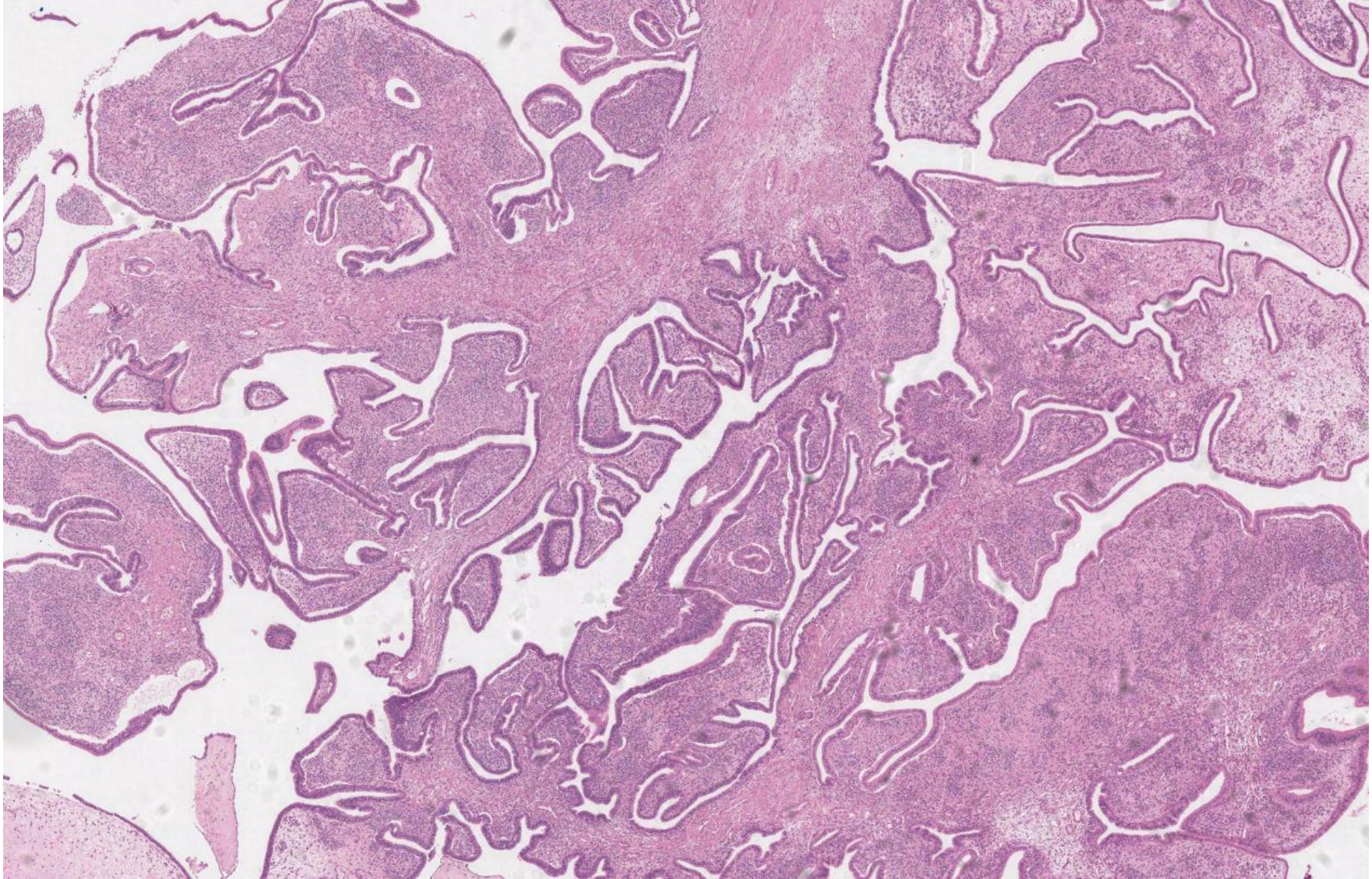

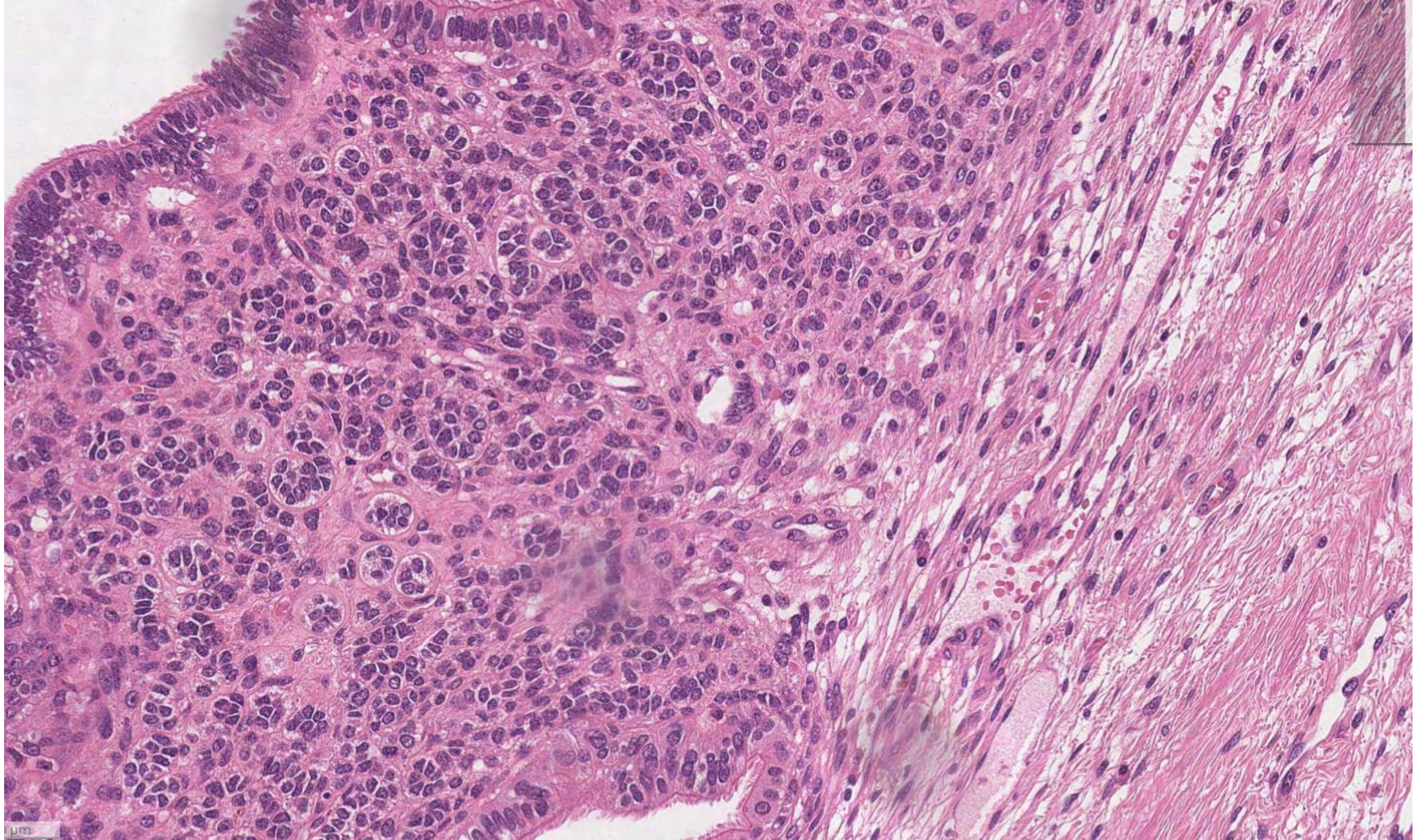

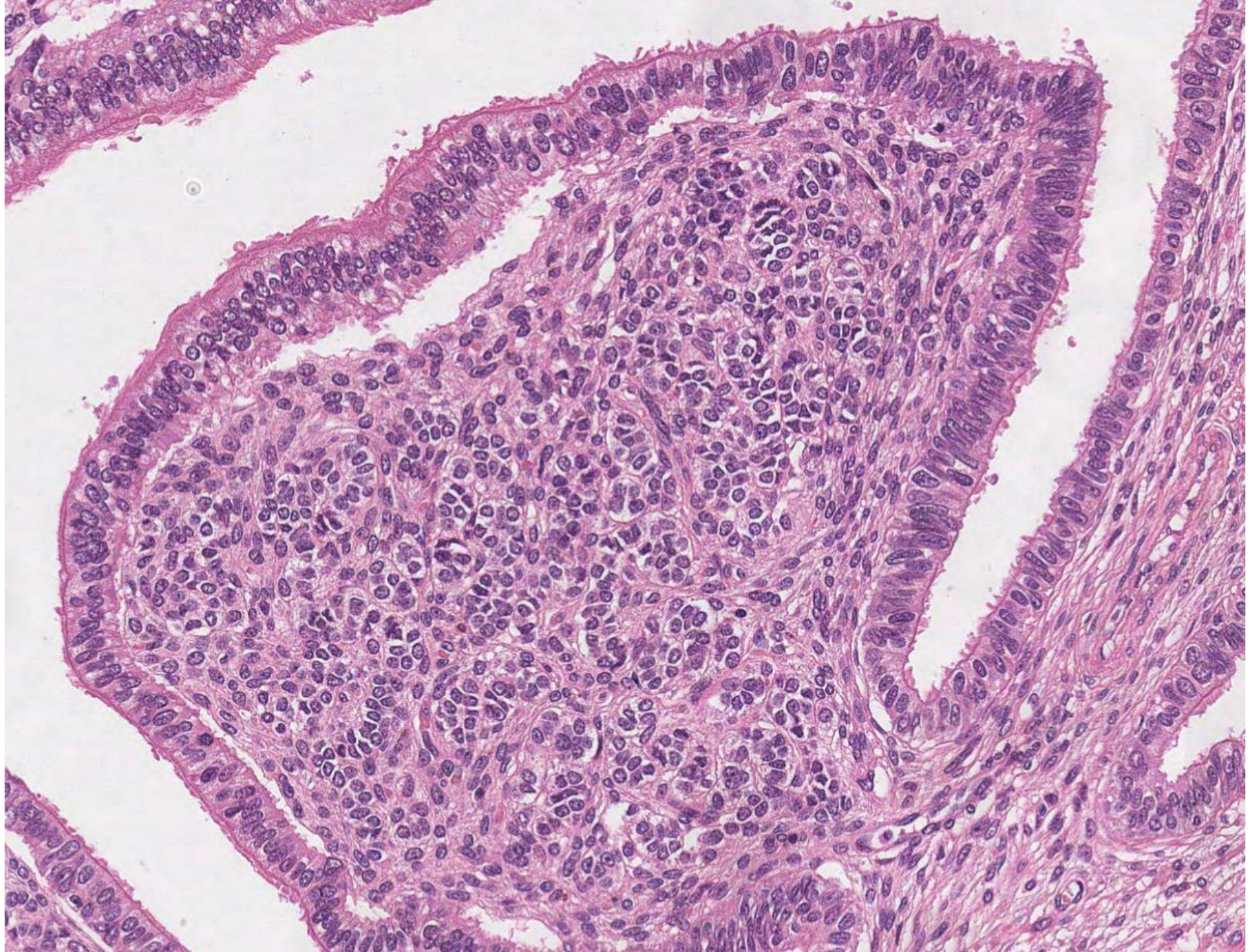

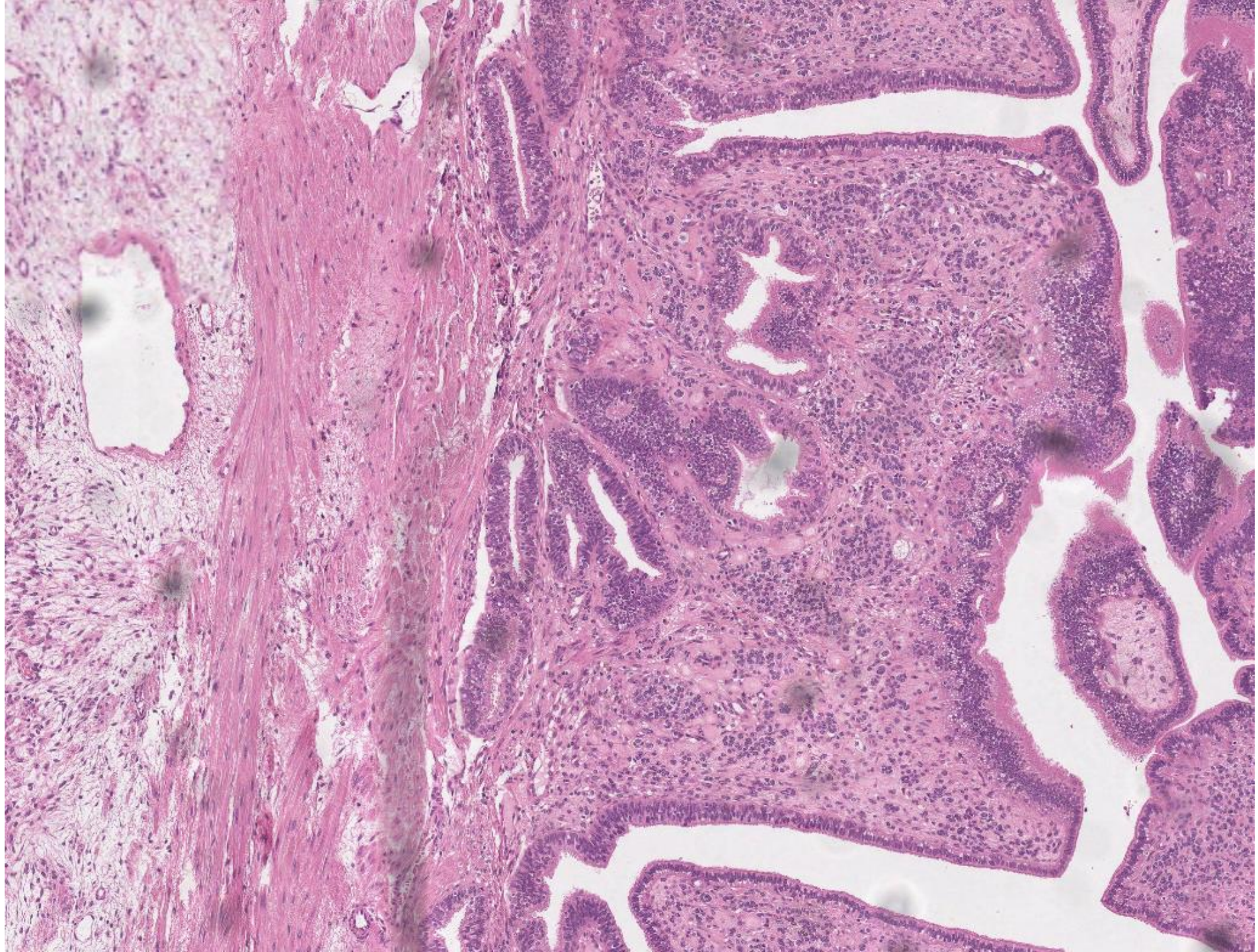

Microscopic examination

- Cystic lesion with papillary projections lined by epithelium.
- Leaf like architecture noted.
- Broad papillae.
- Lining cells- ciliated columnar epithelium, single layered, no atypia, no hierarchical branching.
- Stroma is fibrous- but contains a prominent population of cells with nested/tubular pattern, uniform cells, no significant atypia, increased mitotic activity. Increased cellularity closer to the epithelium.

Provisional diagnosis

- Neoplasm with uncommon morphology, may need referral for diagnosis, await IHC findings.

D/D:

- Serous cystadenofibroma with sex cord elements.
- Adenosarcoma with sex cord differentiation.

Immunohistochemistry

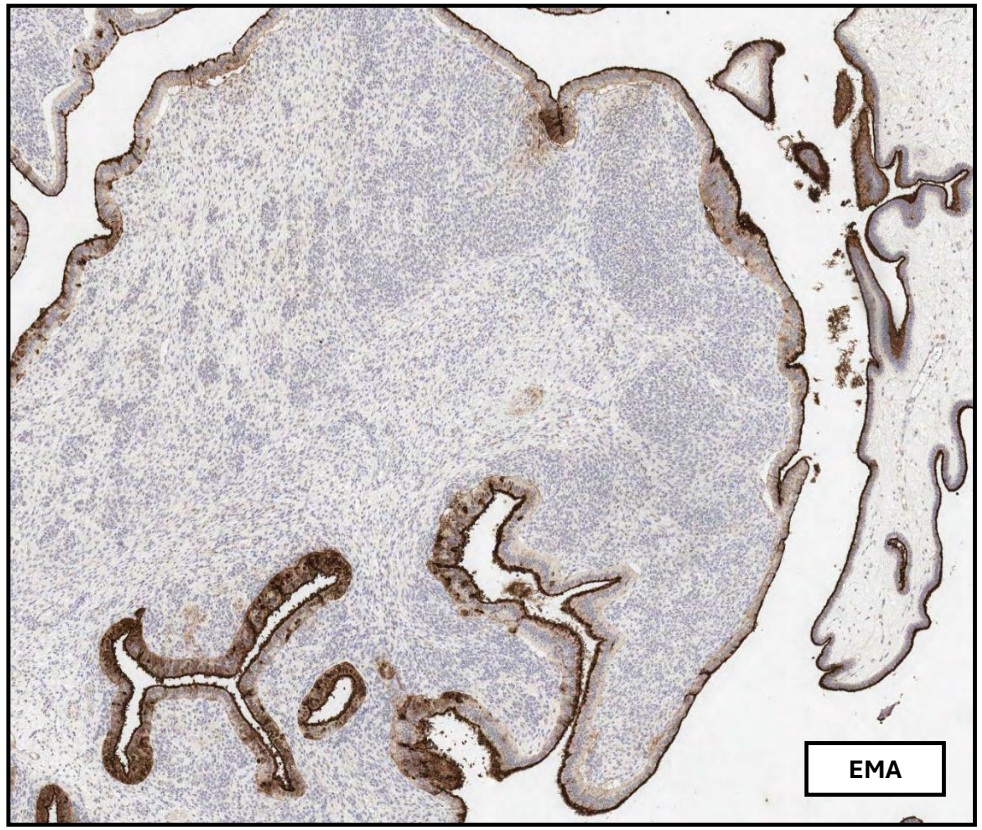

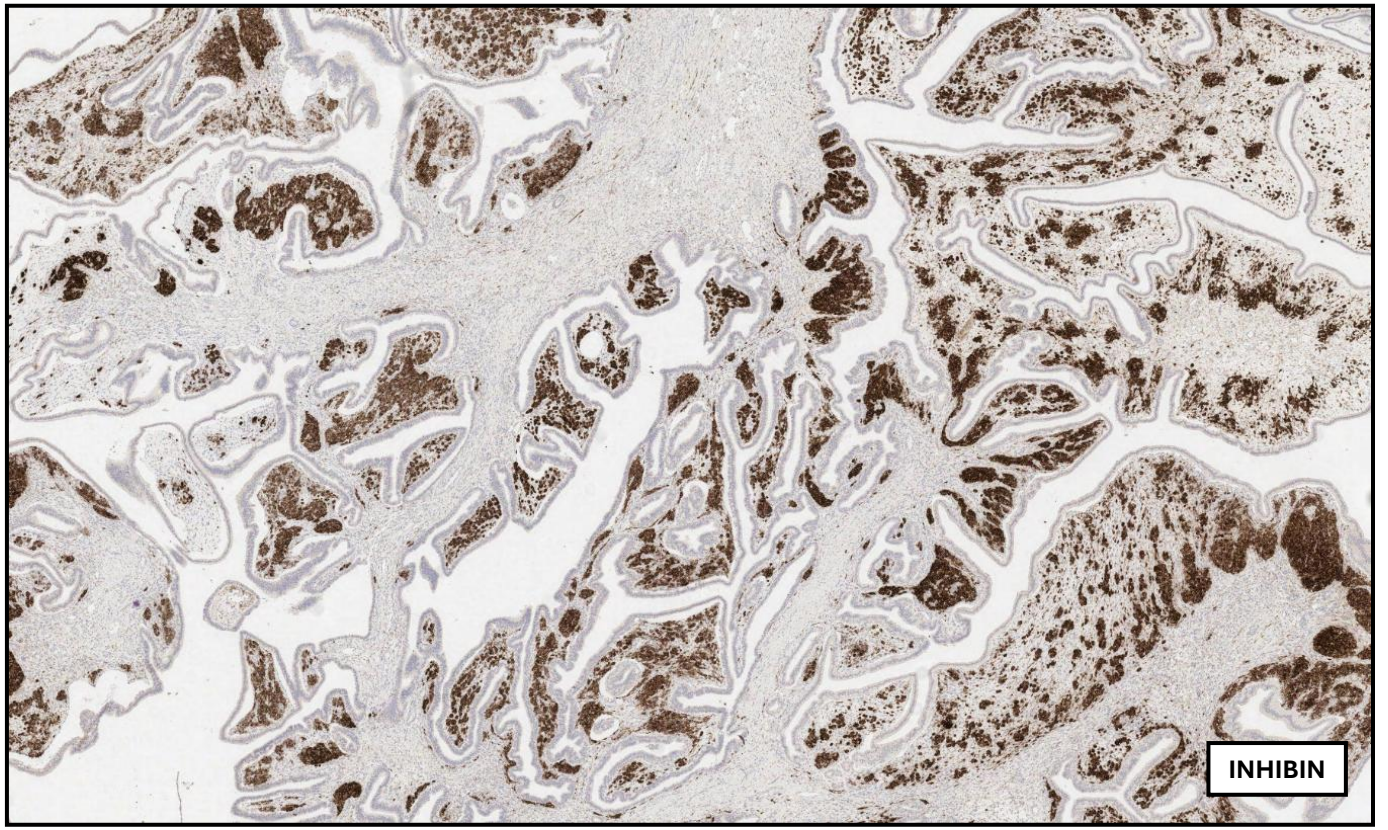

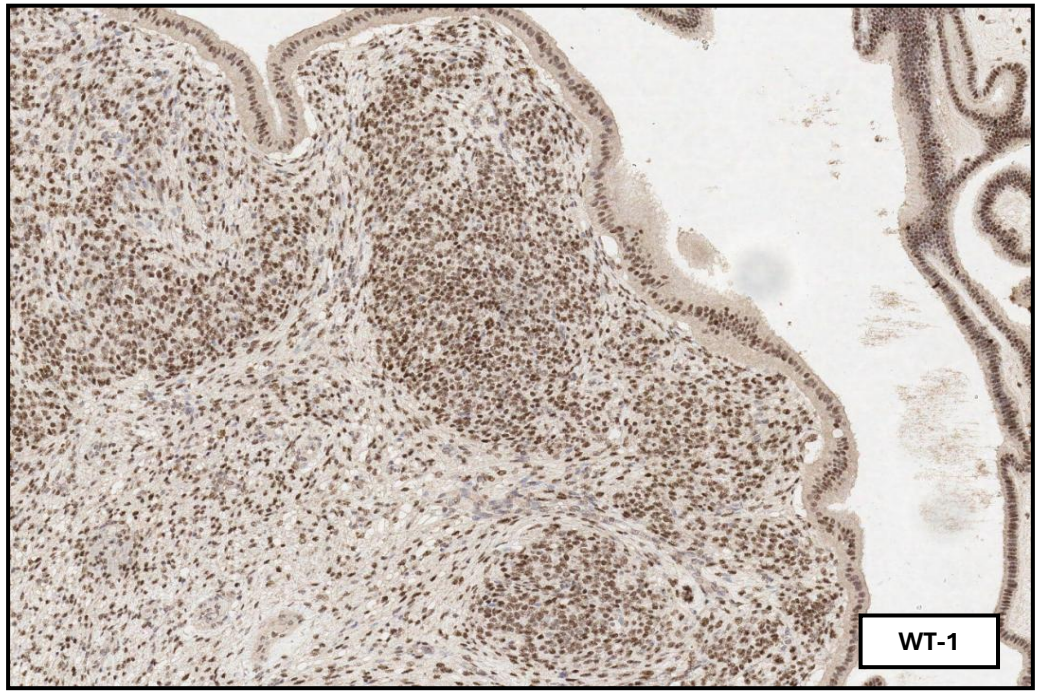
WT-1

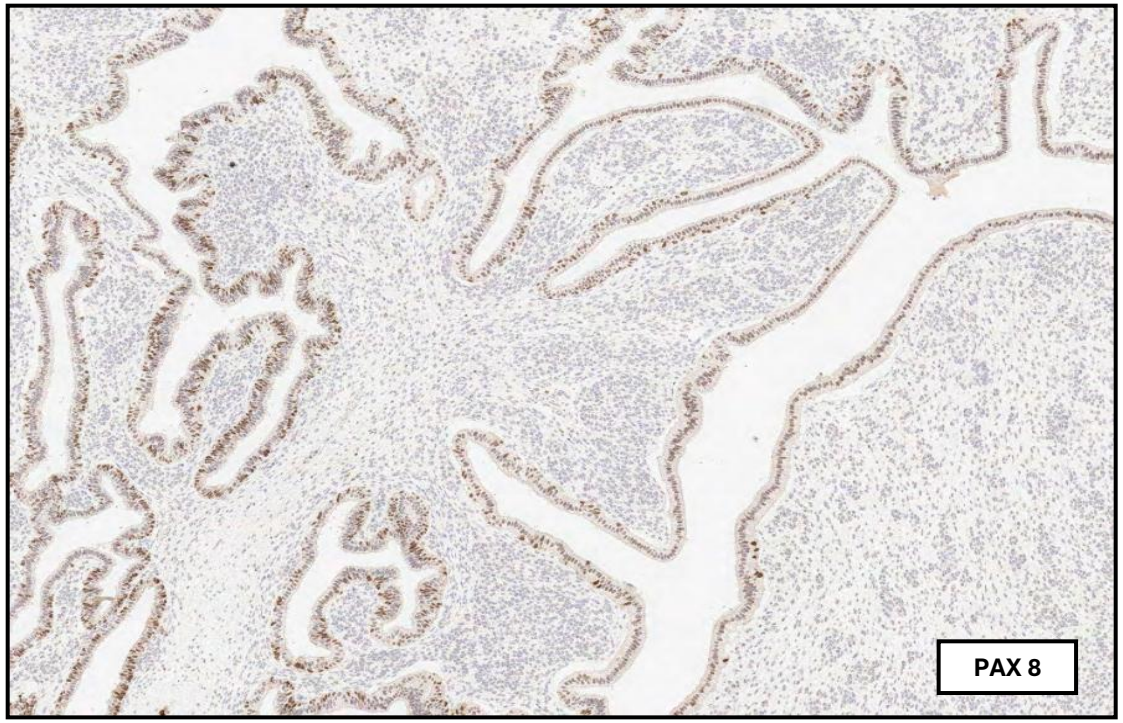
PAX 8

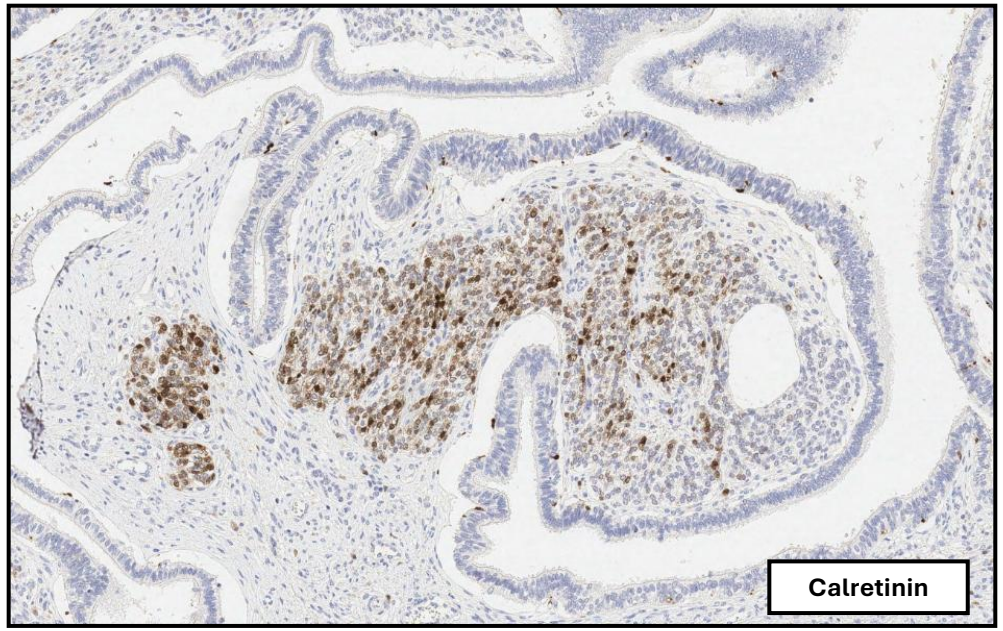
Calretinin

Immunohistochemistry

Epithelial lining:

- Positive: EMA, PAX8, WT-1.
- Negative: calretinin, inhibin.

Cells in stroma:

- Positive: Inhibin, WT-1, Calretinin.
- Negative: EMA, PAX8.

Discussion

- Diagnosis:

- Adenosarcoma with sex cord differentiation.

Acceptable:

- Neoplasm, NOS- needs expert opinion/consensus/discussion with colleague/molecular workup.

Additional information

Difficult case/ uncommon morphology

Extra sampling for more clues, check capsule status

Seek expert help, consensus, discussion

Low grade, no sarcomatous overgrowth or high-grade stroma.

Age is uncommon, check for mutations

(DICER 1 +)

MDT discussion

LC 3: Adenosarcoma with sex cord stromal differentiation

Mark	Features
1-7	Suboptimal description, offers totally inaccurate diagnosis
8-9	Basic description but not confident about what to do next, offers inaccurate diagnosis
10	Adequate description, offers reasonable D/D but doesn't say what to do next
11-14	Good description, provides plan of action to reach diagnosis, provides some additional information
15-16	Good description + additional information, shows knowledge of molecular events

Long case 4

58 F

Endometrial polyp: Incidental finding of thickened endometrium

1 HE and 7 IHC



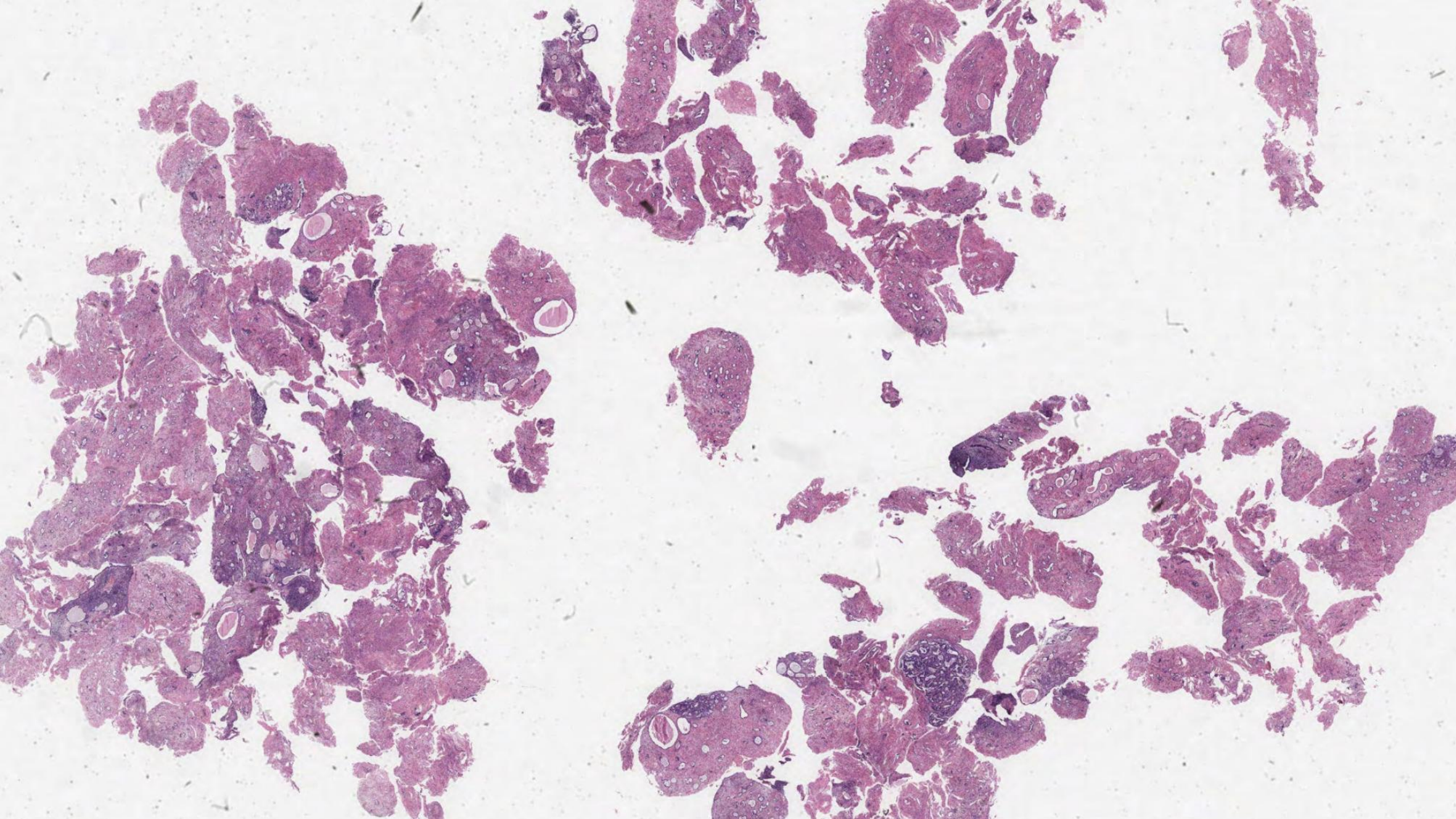

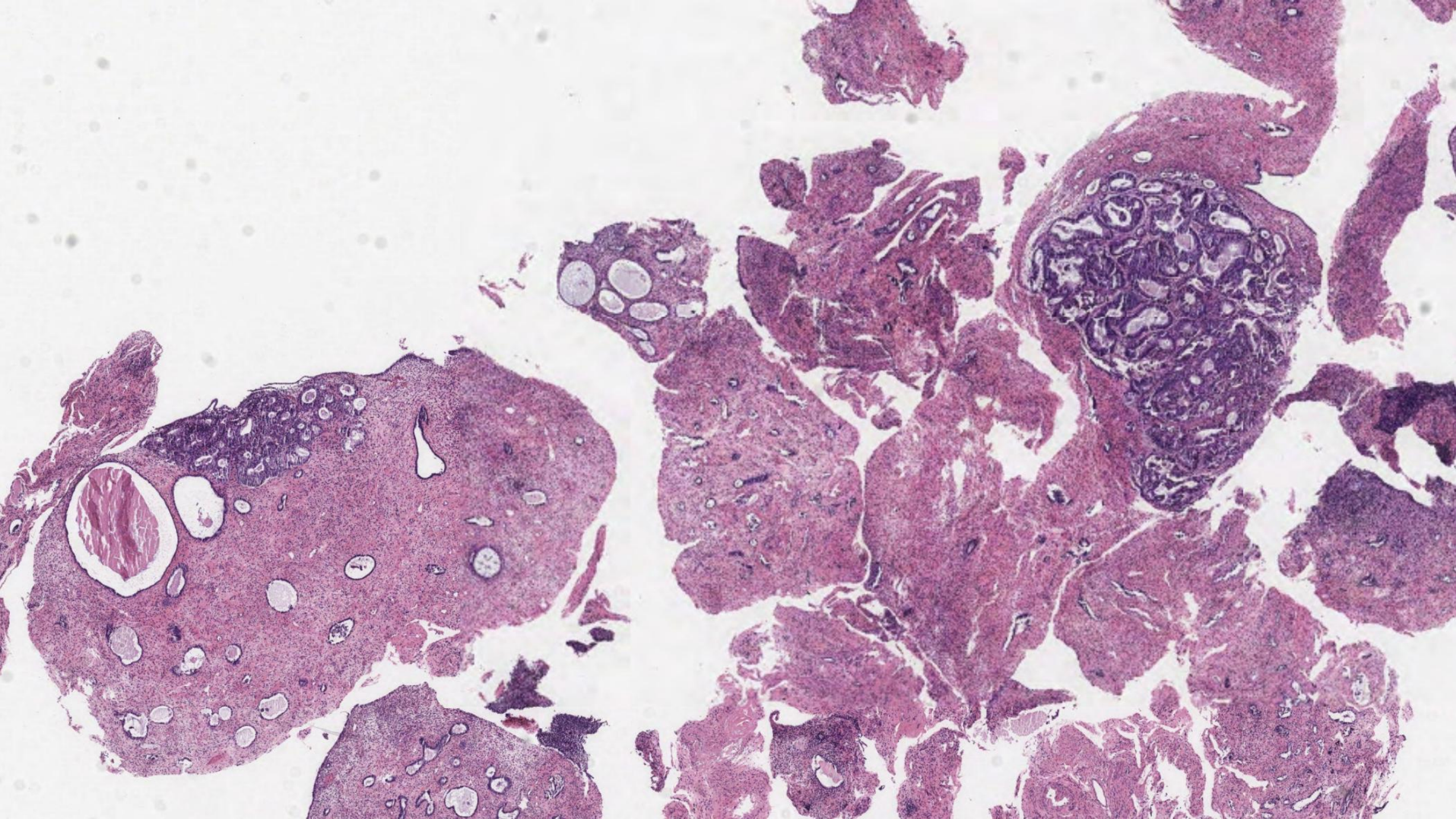

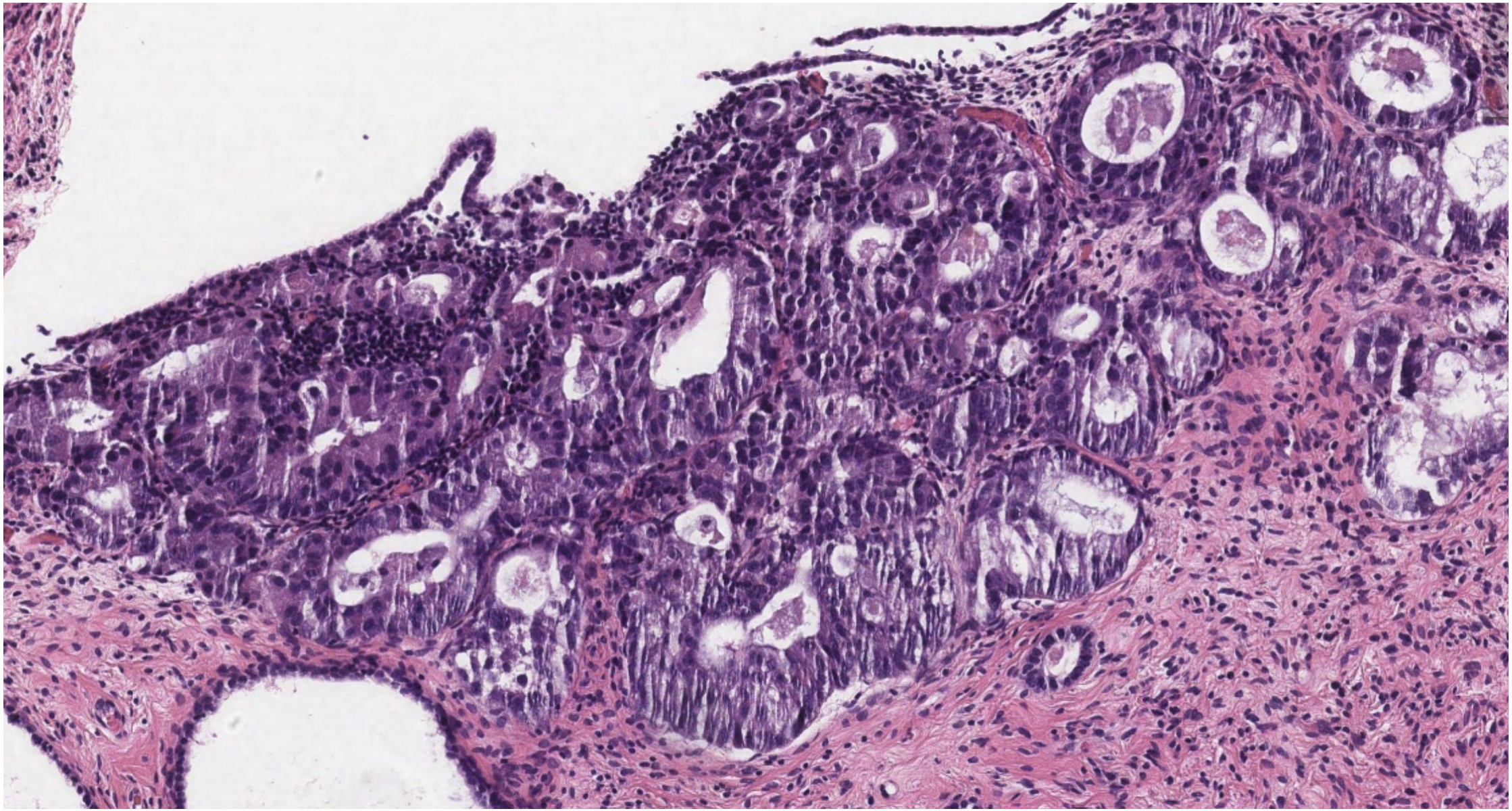

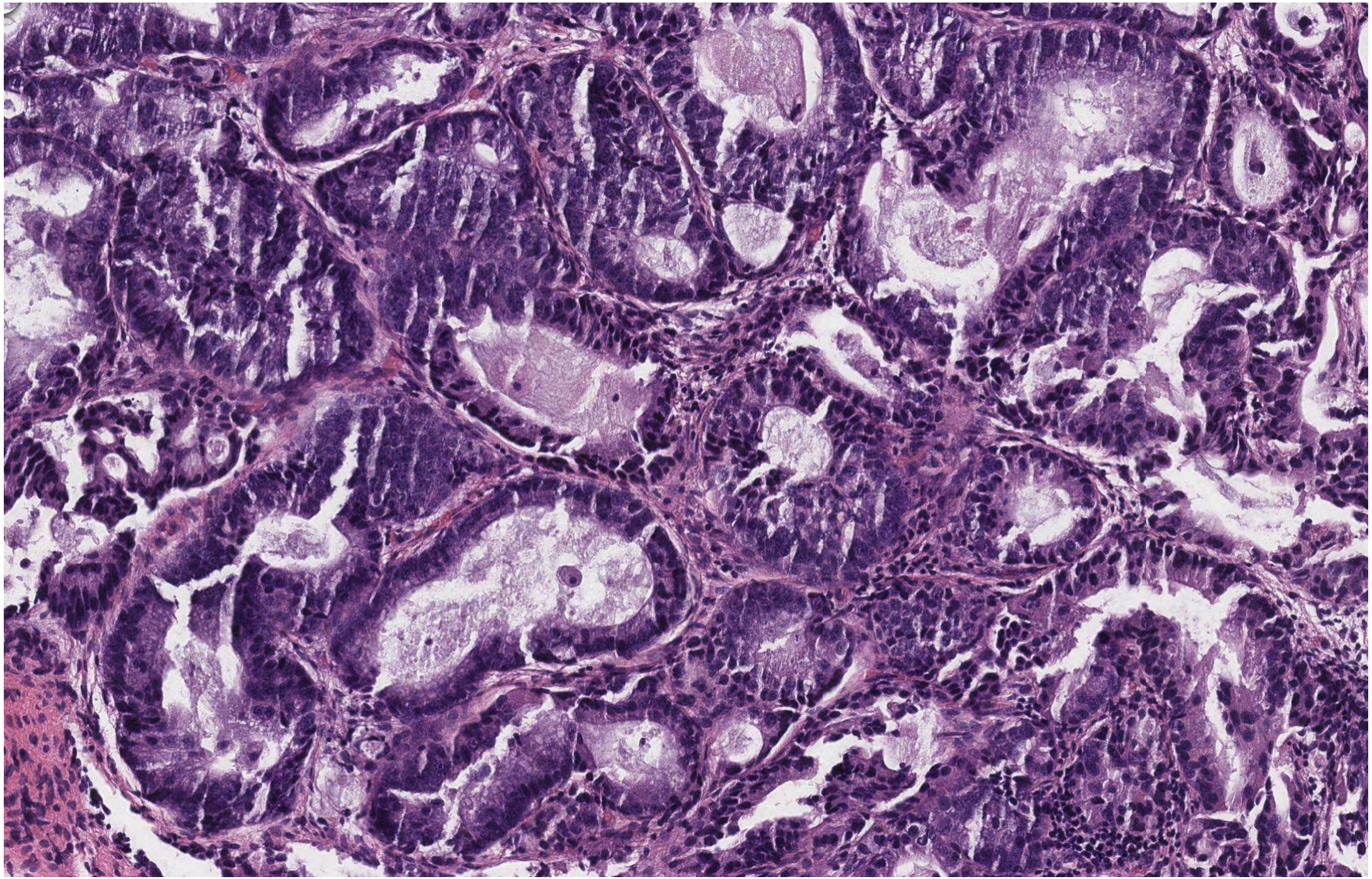

Microscopic examination

- Fragments of endometrial tissue
- Polypoid, fibromuscular stroma
- Inactive glands
- Small foci of crowded glands with nuclear atypia

- No background hyperplasia, no stromal atypia, no squamous morules, no clear cells, no signet ring morphology/mucin pools, no intra epithelial carcinoma.

Provisional diagnosis

- Adenocarcinoma, NOS

- D/D: ? Atypical endometrial hyperplasia

Immunohistochemistry

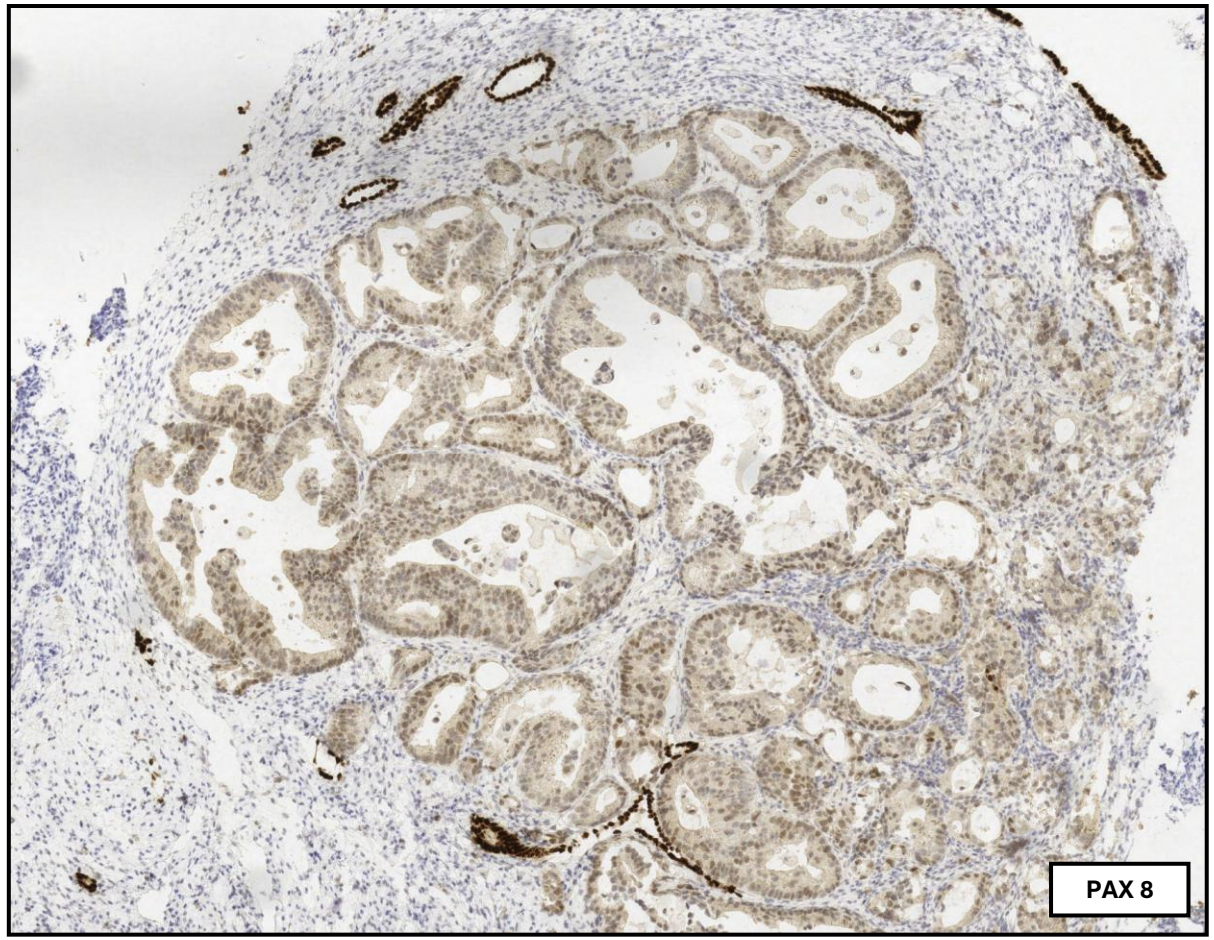

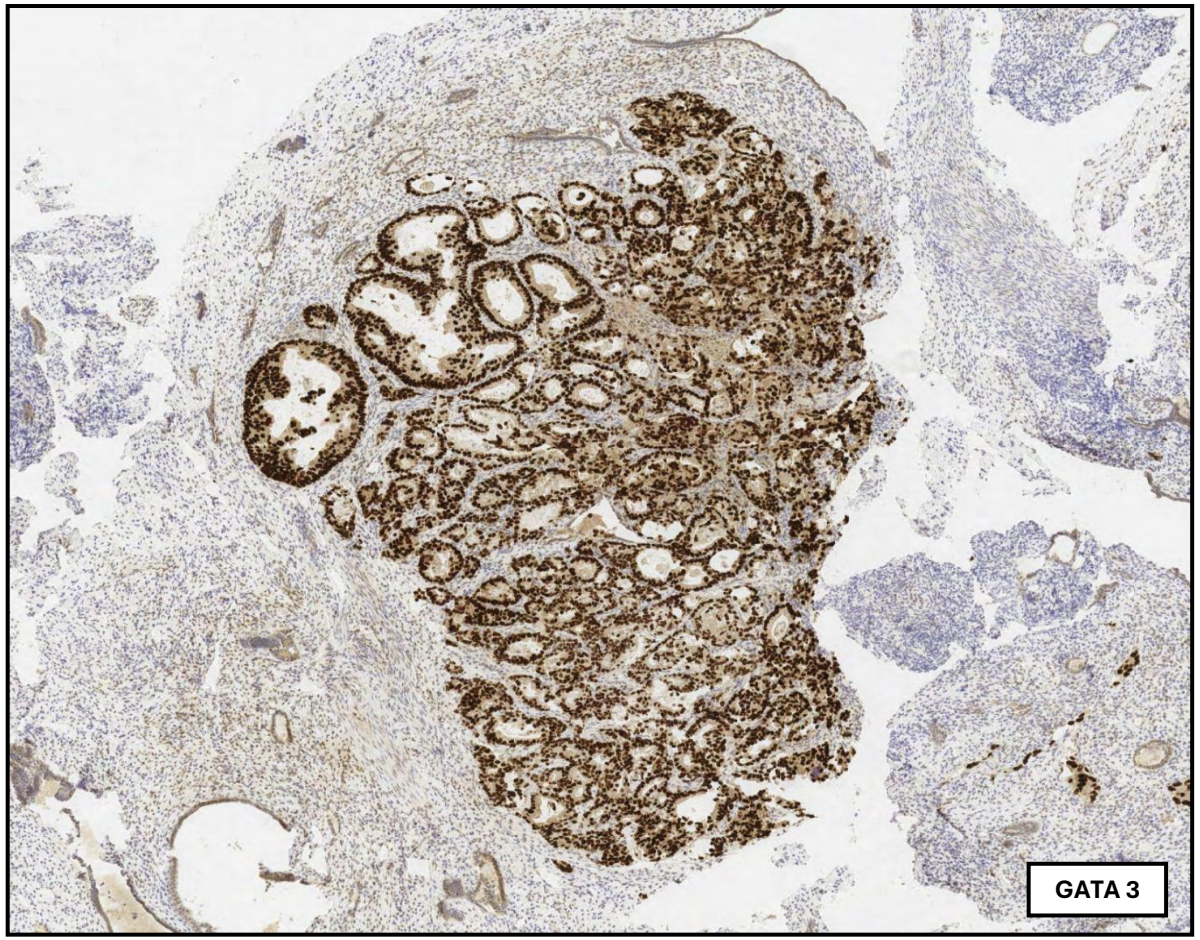

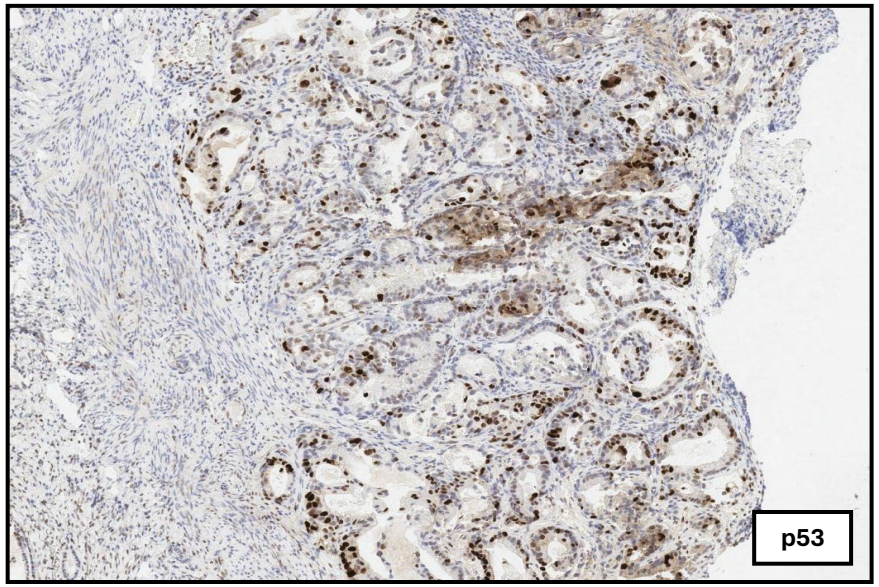
p53

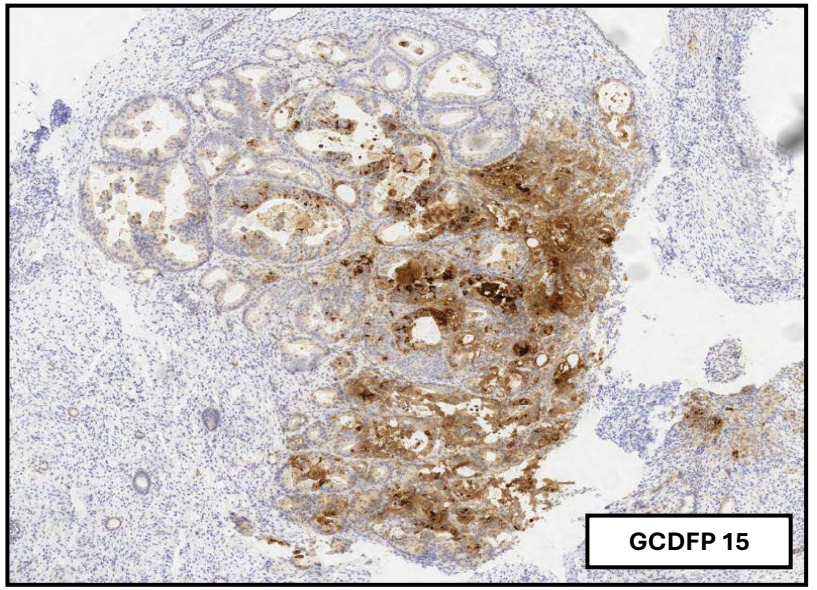
GCDFP 15

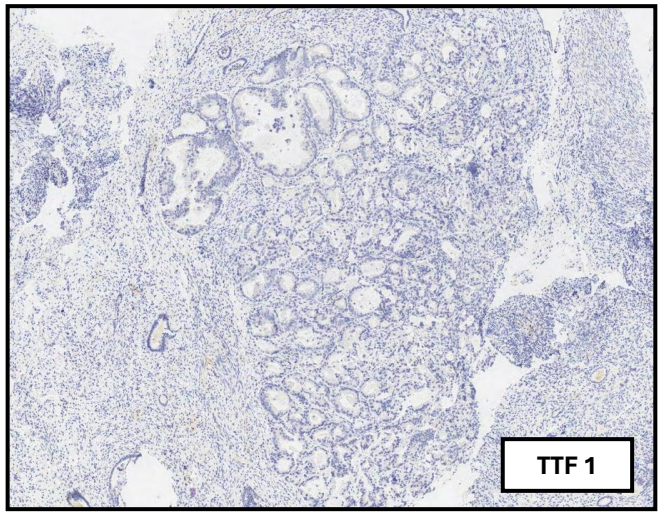
TTF 1

Immunohistochemistry

Atypical glands:

- Positive: GATA3, GCDFP 15
- Negative: PAX 8, TTF 1
- p53: Wild type

Discussion

- Diagnosis;
- Metastatic adenocarcinoma, favour breast primary.

Additional information

Check clinical history, contact clinician, advanced stage

Cross specialty opinion

MDT discussion

ER, PR, Her 2 IHC for prognostic information

Comment on subtype, grade

LC 4: Metastatic adenocarcinoma, breast primary

Mark	Features
1-7	Fails to diagnose
8-9	Basic description, does not confidently state diagnosis
10	Just adequate description with confident diagnosis but no additional information
11-14	Good description, includes some of the additional comments
15-16	Good description + additional comments- may have a chance!



Good luck for the exam!