The British Association of Gynaecological Pathologists

21st Annual Meeting in Collaboration with ISGyP

5th and 6th June 2025

Lessons Learned from Professor McCluggage, MBE

Rupali Arora, UCLH, UK

and

Karen Talia
The Royal Women's and the Royal Children's Hospital
Melbourne, Australia

5th June 2025

The British Association of Gynaecological Pathologists

Speaker disclosures

- ❑ I have no financial conflicts of interest to disclose

Lessons Learnt from Prof Glenn McCluggage

Rupali Arora

UCLH

June 2025

Case 1

- 69-year-old woman
- Underwent TLHBSO
- Macroscopy : 60mm endometrial mass infiltrating deep into myometrium. Macroscopically normal cervix.
- Microscopy: Tumour was arranged in diffuse sheets ,occasional ill formed trabeculae and rosette-like structure, with extensive LVSI. Large areas of necrosis.

IHC:

Positive :CAM5.2 (diffuse),CD56 (diffuse),P16 (block),AE1/3 (cytoplasmic dot), synaptophysin (focal), chromogranin(v occasional cells)

Negative: CK7,CK20,PAX8, WT1,ER,PR, CK20,calretinin,GATA3,

Others: P53 mutational overexpression , proliferation fraction >90%,MMRp, SMARCA4 and SMARCB1 retained,

Case 1

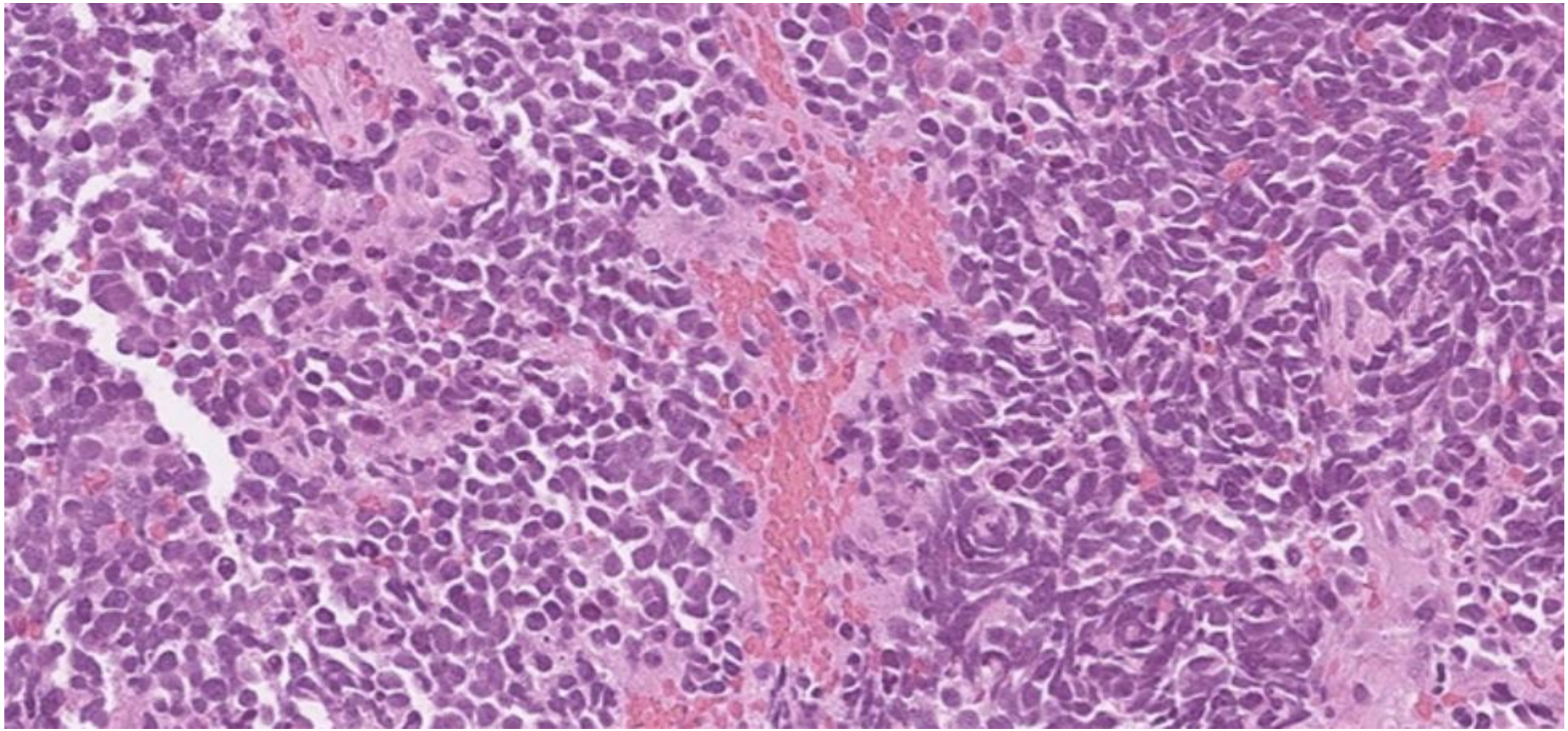

Case1

- IHC: Myo D1, myogenin and desmin all showed focal strong positive staining.
- Entire cervix was sampled and showed no malignancy.

- DD: Carcinosarcoma with heterologous skeletal muscle differential was considered but no convincing sarcomatous foci seen.

Provisional diagnosis : Primary endometrial high grade neuroendocrine carcinoma.

Sent for expert opinion due to :

- odd IHC of negative CK7 and PAX8,
- focal strong positive staining with Myo D1, myogenin and desmin.

Case1

- Final diagnosis : High grade neuroendocrine endometrial carcinoma with aberrant skeletal muscle differentiation.

Reference :

Small Cell Neuroendocrine Carcinoma With Skeletal Muscle Differentiation-Report of Three Cases

Eusebi, Vincenzo M.D.; Damiani, Stefania M.D.; Pasquinelli, Gianandrea M.D.; Lorenzini, Paolo M.D.; Reuter, Victor E. M.D.; Rosai, Juan M.D.

American Journal of Surgical Pathology 24(2):p 223-230, February 2000.

CASE 2

- 13-year-old girl
- Presented with early onset puberty followed by amenorrhea
- Underwent ovarian cystectomy
- Macroscopy : 140mm opened cyst with wall thickness between 1-4mm. Smooth inner surface.
- Micro: Cystic lesion with a fibrous capsule. Focally the inner lining shows thick band of monomorphic cells with vesicular nuclei and occasional grooves. No cytological atypia but abundant mitosis. Smaller nodules of lesional cells are seen in cyst wall. Occasional follicle like formations are seen.
- NGS: No FOXL 2 mutation detected

CASE 2

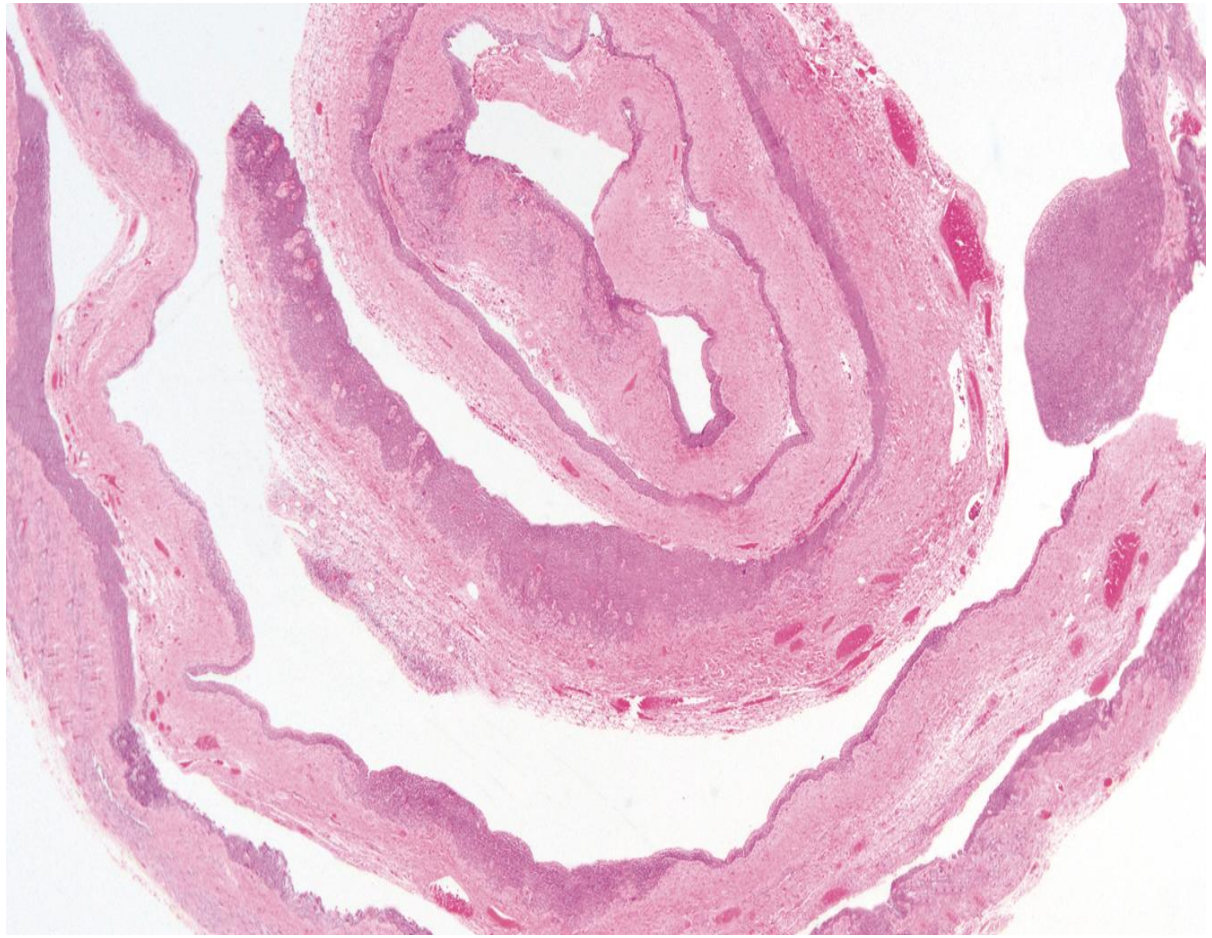

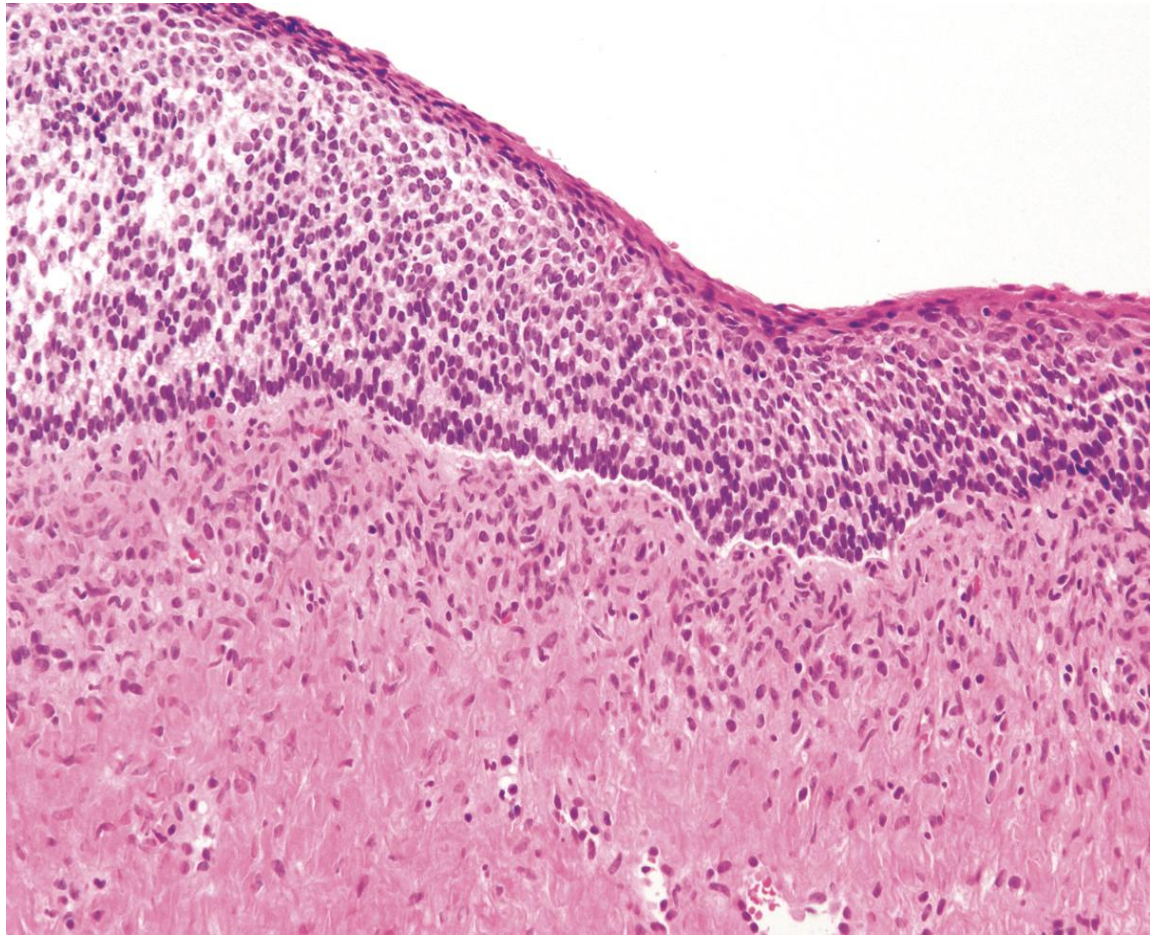

CASE 2

Provisional diagnosis:

- DD between a large follicular cyst and cystic sex cord tumour (favored due to large size and extent of proliferation)
- Favoring adult granulosa cell tumour over juvenile granulosa cell tumour

Sent for expert opinion due to:

- extent of proliferation,
- young age of patient
- morphology favoring adult granulosa cell tumour but FOXL2 wild type result.

CASE 2

- FINAL DIAGNOSIS: Cystic adult granulosa cell tumour.

Factors favoring this diagnosis:

- Thickness of cyst lining with similar nodules in cyst wall.
- Morphology not typical of juvenile granulosa cell tumour
- Absence of FOXL2 mutation is common in cystic adult granulosa cell tumour.

Reference:

Cystic Granulosa Cell Tumors of the Ovary: An Analysis of 80 Cases of an Often Diagnostically Challenging Entity. Baris Boyraz,et al *Arch Pathol Lab Med* (2022) 146 (12): 1450–1459.

Case 2 Learning points

- AGCT can have a wide age range
- AGCT can be purely cystic
- Absence of FOXL2 mutation commonly seen in cystic AGCT- may be due to false-negative result because of the limited number of cells present.

CASE 3

- 71-year-old woman
- Underwent primary debulking surgery for 210 mm ovarian mass
- Macroscopy : 210 mm ovarian mass with capsular breach. Cut surface shows necrotic solid tumour with cystic and hemorrhagic areas
- Microscopy: Partly necrotic tumour with nested pattern. Nests separated by fibrous septae and composed of packed spindle cells with pleomorphic vesicular nuclei and focal glandular differentiation.

CASE 3

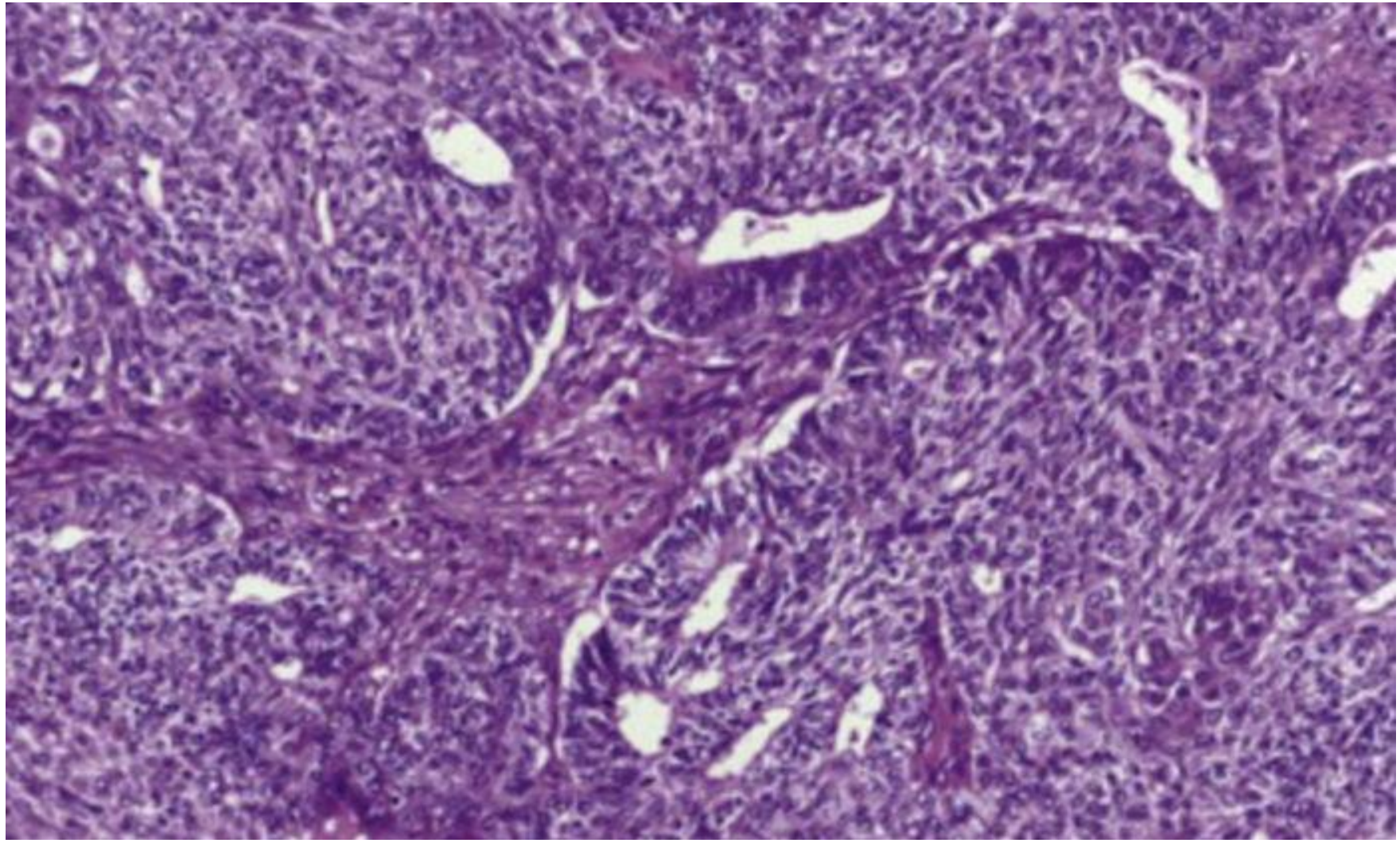

CASE 3

- IHC:
- Positive: AE1/3, MNF116,EMA (strong and diffuse), ER,PR, very patchy CK7, WT1, and CDX2. CD10 shows patchy luminal staining.
- Negative: PAX8,GATA3, TTF1,Napsin, synaptophysin, chromogranin, CK20, SALL4,AFP, inhibin, calretinin
- Other: P53 wild type, p16 (non block),MMRp
- NGS: BRCA1 and 2 wild type

- Provisional diagnosis : Poorly differentiated tumour involving right ovary and tube, suggestive of malignant Wolffian tumour (FATWO) due to PAX8 negativity.
- Sent for expert opinion due to rarity of tumour

CASE 3

- Final diagnosis: Grade 3 endometroid adenocarcinoma.

Factors favoring the diagnosis:

- ER and PR positivity supports endometroid origin
- Diffuse staining with EMA,
- Aberrant immunophenotype not uncommon in endometroid adenocarcinoma.

Case 3 Learning points

Ovarian endometroid adenocarcinoma have propensity to exhibit aberrant immunophenotype including negative staining for PAX8 and positive staining for CDX2 and WT1.

McCluggage WG. Endometriosis-related pathology: a discussion of selected uncommon benign, premalignant and malignant lesions. Histopathology. 2020 Jan;76(1):76-92. doi: 10.1111/his.13970.

CASE 4

- 70-year-old woman
- presented with PMB
- Underwent TLHBSO
- Macroscopy: 110 mm polypoid endometrial mass reaching the external os. No other gross lesion.
- Microscopy :

Endometrium: Mixed endometrial carcinoma comprising of serous intraepithelial carcinoma and poorly differentiated carcinoma with neuroendocrine differentiation.

Left fallopian tube: STIC ,no invasive carcinoma

Left ovary and right parametrium: High grade serous adenocarcinoma

CASE 4

IHC in poorly differentiated endometrial carcinoma :

- Positive: CK7,AE1/3 (diffuse), E-cadherin and synaptophysin (patchy),**p16(non block),**chromogranin (focal)
- Negative: ER,PR,GATA3,TTF1,**WT1**, PAX8
- **P53 wild type**

IHC in serous endometrial intraepithelial carcinoma :

P53 : mutant type overexpression, p16 block +, WT1 negative

IHC in fallopian tube and ovary:

P53 : mutant type overexpression, p16 block +, WT1 positive

CASE 4

- Provisional diagnosis : Synchronous mixed carcinoma of endometrium (comprising serous intraepithelial carcinoma and poorly differentiated carcinoma with neuroendocrine differentiation) and high-grade serous carcinoma of tubo-ovarian origin.

CASE 4

NGS in both endometrial and tubo-ovarian components : Identical.

- PIK3CA p(Arg108His)C.323G>A,COSM27497
- T53 p(Tyr220Cys),c.659A>G,COSM10758

- Sent for expert opinion due to different immunoprofile but identical molecular profile of the endometrial and ovarian carcinoma.

CASE 4

- Final diagnosis : Primary endometrial serous carcinoma with metastasis to the fallopian tube (STIC like) and ovary.

Factors favoring this diagnosis:

- Involvement of fallopian tube mucosa by endometrial serous carcinoma can result in STIC like lesions.
- The differential expression of WT1 in the endometrial tumour (negative) and extrauterine tumour (diffusely positive) can occasionally occur.
- Two independent high grade serous carcinomas with identical TP53 mutations would be highly unlikely.

Reference:

Kommoss F, Faruqi A, Gilks CB, Lamshang Leen S, Singh N, Wilkinson N, McCluggage WG. **Uterine Serous Carcinomas Frequently Metastasize to the Fallopian Tube and Can Mimic Serous Tubal Intraepithelial Carcinoma**. Am J Surg Pathol. 2017 Feb;41(2):161-170.

CASE 6 : STIC like metastasis

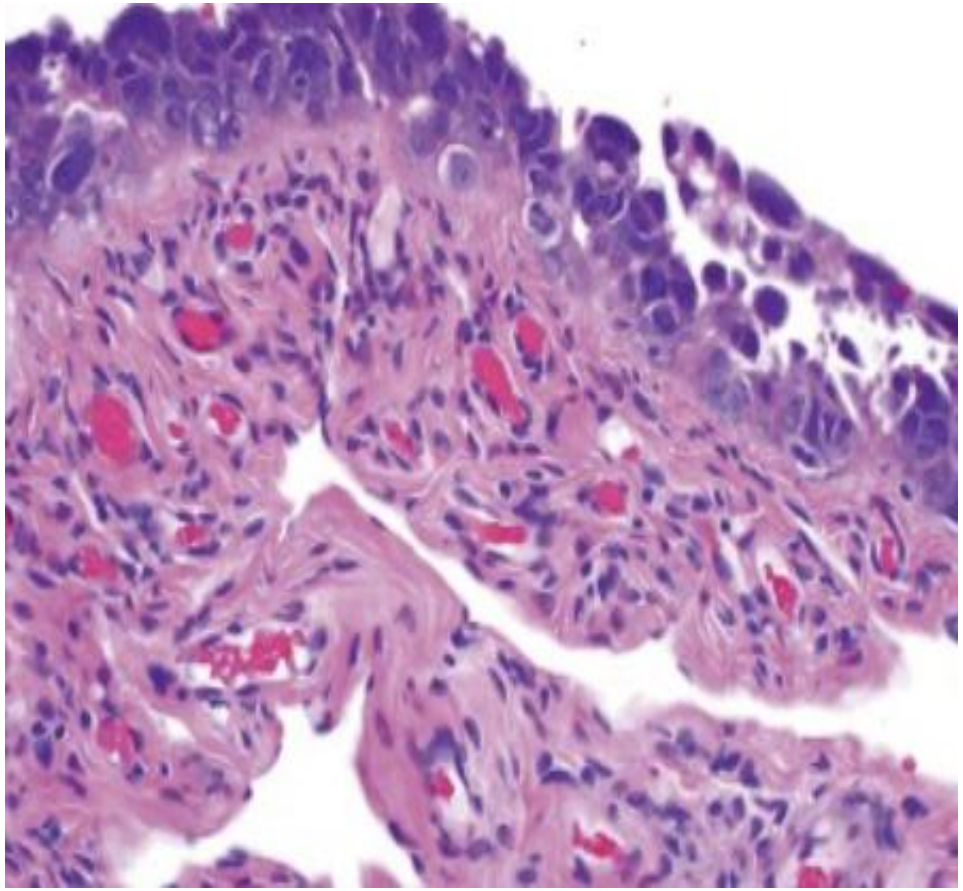

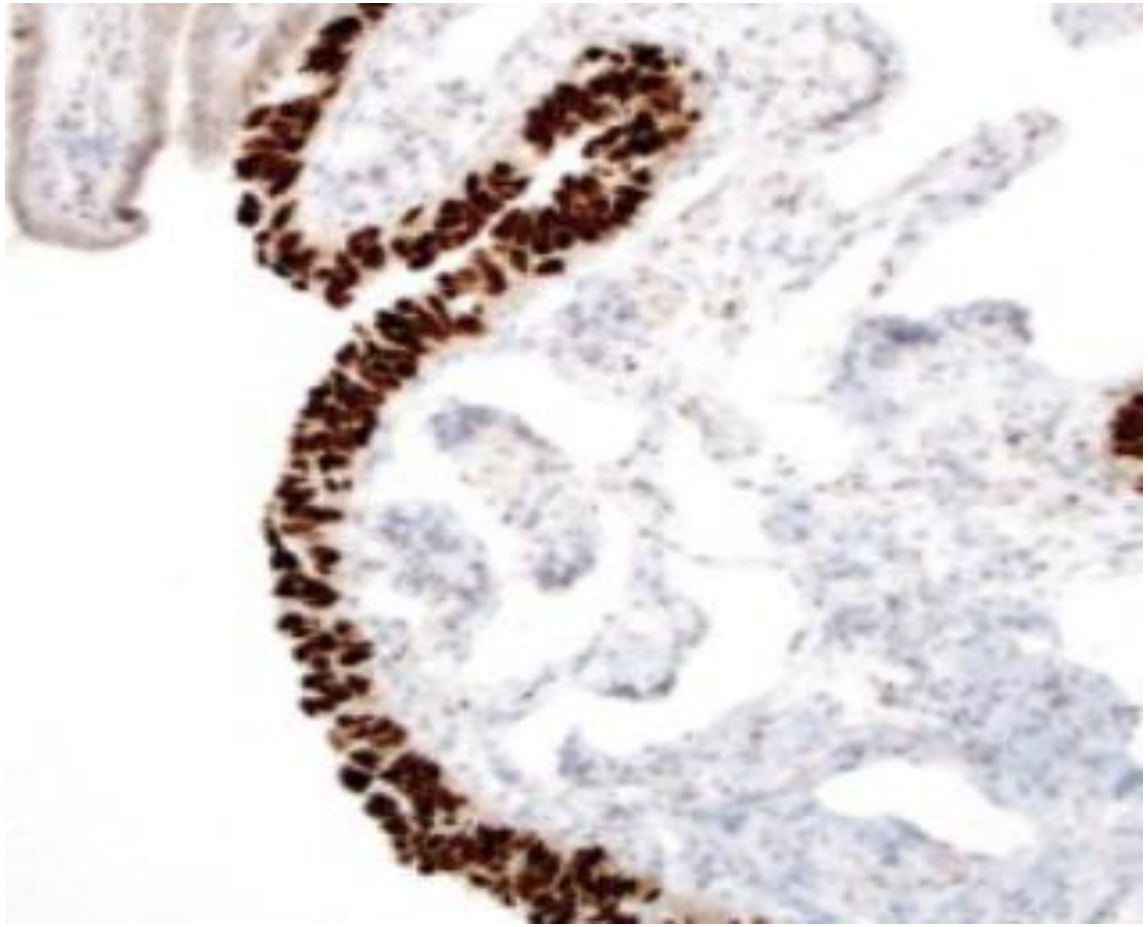

Case 4 Learning points

- Molecular identity trumps morphological divergence
- Recognizing STIC-like metastasis is critical to avoid over diagnosing synchrony.

Impact of these referrals

- Confirmed complex diagnosis for optimal patient care
- Provided references to key literature
- Provided prognostic insight
- Provided diagnostic nuance and reassurance
- Some culminated in publications

Diagnostic wisdom from Prof Glenn McCluggage

- 85 cases referred to Prof Glenn McCluggage since 2008.
- Majority: ovarian cases
- Others: endometrial and cervical cases
- Occasional: myometrial cases

Typical review comment:

- '*Many thanks for asking me to look at this interesting and difficult case*'
- '*Many thanks for asking me to look at this **most** interesting and difficult case*'
- '*Many thanks for asking me to look at this **most** interesting and **exceedingly** difficult case*'
- *'(Extensive) immunohistochemistry has been performed which has been largely noncontributory'.*

A hallmark of Glenn's style –humble, thoughtful and generous.

Joint case reports

1. " Early" clear cell proliferations (clear cell carcinoma in situ) in ovarian endometriotic cysts: report of a case series with recommendations for terminology.Karunadhas NS, Catherwood M, Stringfellow H, **Arora R**, **McCluggage WG.***Am J Surg Pathol. 2025 May 6*. Online ahead of print.

We suggest that these proliferations be termed "CCC in situ" and identification of such a lesion should prompt extensive sampling in order to exclude an invasive CCC component within the stroma outside the endometriotic cyst lining.

2. Mullerian polyp of the vagina: report of three cases of a previously undescribed lesion with discussion of the differential diagnosis.**Arora R**, **McCluggage WG.**Int J Gynecol Pathol. 2024 Jan 1;43(1):102-107

We report 3 previously undescribed primary vaginal polypoid lesions bearing a striking morphologic resemblance to benign endocervical or endometrial polyps and we suggest the designation Mullerian polyp of the vagina.

Joint case papers

3. Precursor lesions of cervical clear cell carcinoma: evidence for origin from tubo-endometrial metaplasia.Talia KL, **Arora R**, **McCluggage WG.**Int J Gynecol Pathol. 2022 Mar 1;41(2):105-112.

We propose tubo-endometrial metaplasia as a precursor to sporadic cervical CCC, with possible progression via an "atypical" transitional phase to malignancy.

4. Mixed endometrioid adenocarcinoma and müllerian adenosarcoma of the uterus and ovary: clinicopathologic characterization with emphasis on its distinction from carcinosarcoma.El Hallani S, **Arora R**, Lin DI, Måsbäc A, Mateoiu C, **McCluggage WG**, Nucci MR, Otis CN, Parkash V, Parra-Herran C, Longacre TA.Am J Surg Pathol. 2021 Mar 1;45(3):374-383.

We report endometrioid adenocarcinomas that arise in close spatial association with Müllerian adenosarcoma appear to be clonally related to the sarcoma. Unlike carcinosarcomas, these tumours are usually early stage at presentation. The prognosis appears to be driven by the sarcomatous component.

Further Lessons Learnt from Prof McCluggage – Soft Skills & Professionalism

- **Highly Organized**

Maintains a structured and methodical approach to case reviews and presentations.

- **Academically Thorough**

Consistently incorporates relevant literature and references to support his insights.

- **Resource-Ready**

Has access to high-quality pathological images that enhance understanding.

- **Prompt**

Responds quickly and consistently, enabling efficient communication.

- **Generously Available**

Always makes time to offer guidance, even with a demanding schedule.

- **Exemplary Professionalism**

Sets a high standard through his conduct, precision, and commitment to excellence.

THANK YOU

35th Annual Scientific Meeting
Australasian Division of the IAP
Sydney, June 2010

2010

Speaker	Convenor	Subject
Professor W Glenn McCluggage, Belfast, Northern Ireland, UK		Gynaecological Pathology
Dr Philip E LeBoit, San Francisco, California, USA		Dermatopathology
Master Class Presenter Saturday Dr Felicity Frost		Fine Needle Aspiration of the Breast
Master Class Presenter Sunday Dr Anthony Gill		Endocrine Pathology



Karen Talia

Gynaecological Pathology

A Slide Seminar

W. Glenn McCluggage

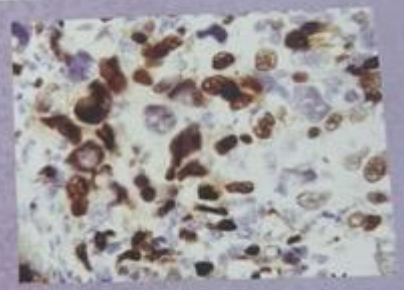

Australasian Division of the International Academy of Pathology Ltd
35th Annual Scientific Meeting
June 4 - 6, 2010

Slide seminars

In 1999 he began his career as a presenter of slide seminars on "Gynaecological Pathology" at the British Division of the International Academy of Pathology (IAP) in Sheffield.
Since then he has presented slide seminars in many countries including the International Congress of the IAP in Brisbane in 2004.
These commitments have increased each year since 1999.
He is a reviewer of pathology sections for National and International anti cancer drug trials. He is one of a small number of pathologists engaged in these reviews.

Publications

He has published over 200 papers
And written many invited review articles and editorials.

Summarised by Robin Cooke



Glenn McCluggage

Glenn McCluggage is President of the British Association of Gynaecological Pathologists from 2007, and from 2009 President of the International Society of Gynaecological Pathologists.

Present Job Description

He graduated from Queen's University of Belfast in 1987 and did all his postgraduate training in Belfast. In 1998 he was appointed to his present position, and immediately threw himself into a very busy schedule of surgical pathology, concentrating particularly on gynaecological pathology and cytology. He soon became involved in local and international lecturing activities.
He has a heavy teaching commitment to undergraduate medical students and science students. He is particularly proud of the 12 week course that he conducts for third year medical students on clinical pathology in which students are introduced to the work and life of being a pathologist.
He coaches postgraduate students for examinations of the Royal Colleges of Surgeons and Pathologists. He plays an active role in the administrative activities of the RC Path and is an examiner for the College.
His research interests are in the application of immunohistochemistry in the diagnosis of gynaecological tumours. His group has published particularly on the use of anti-inhibin antibodies.

Journals

He is Secretary of the International Journal of Gynaecological Pathologists.
He is on the editorial boards of 3 other journals.

Books

World Health Organisation Classification of Tumours – Pathology and Genetics of Tumours of the Breast and Female Genital Tracts, Lyon 2004. He wrote 4 of the chapters.
Synopsis of Pathology for Surgeons third edition co-author with R Spence (surgeon) and J M Sloan (pathologist)
Author of Royal College of Pathologists datasets for histopathological reporting of tumours of the female genital tract, 2008.

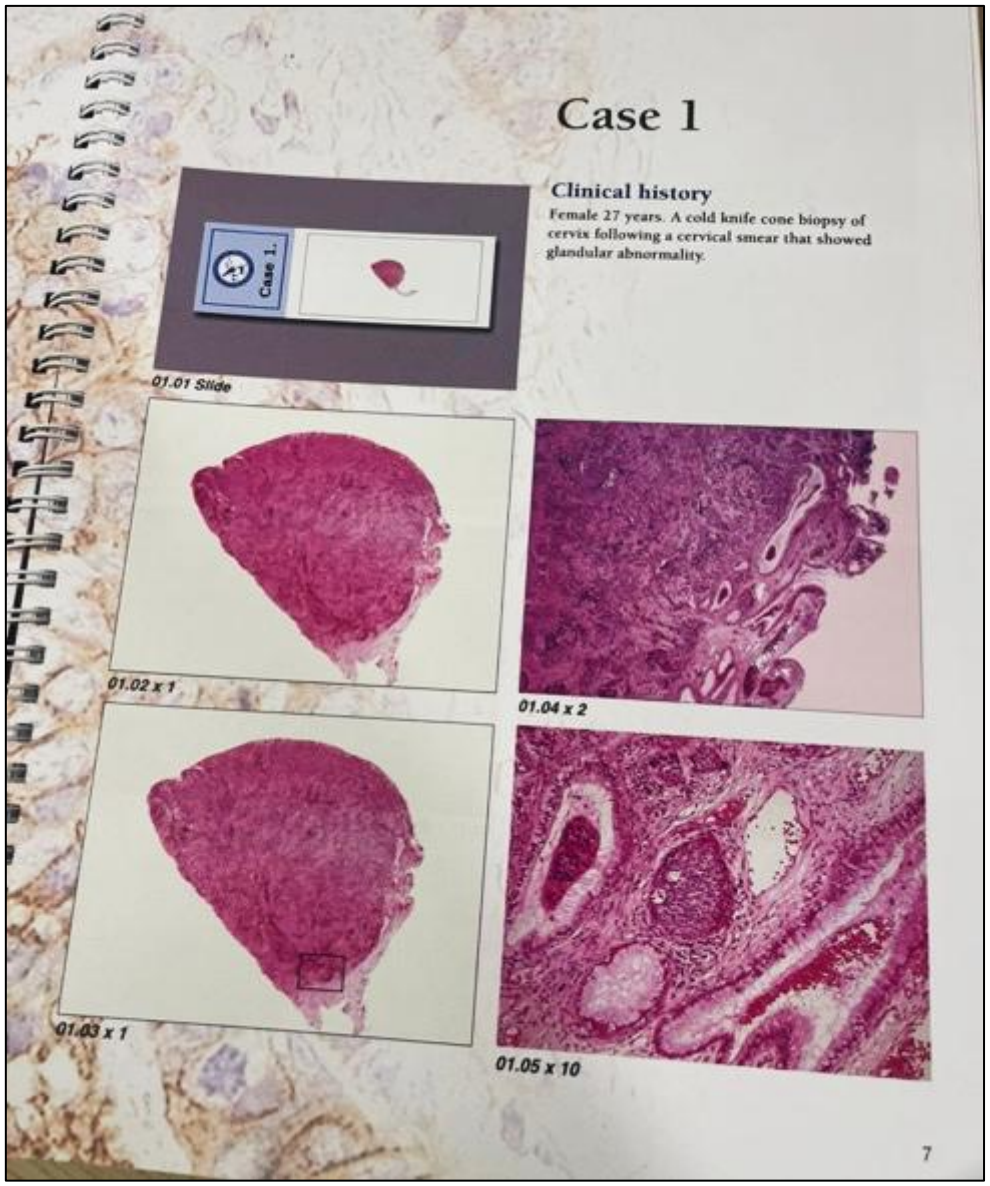

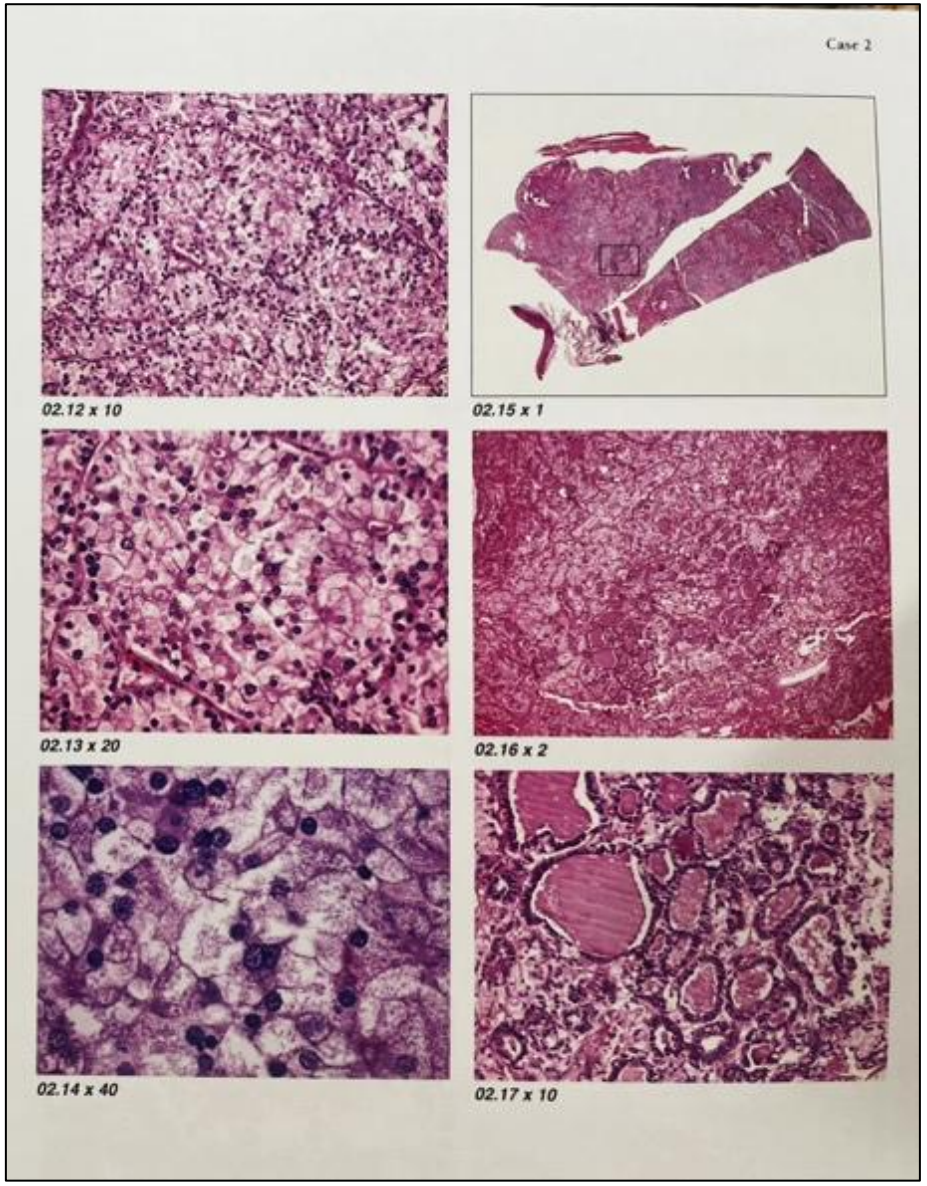

116 pages
extensively illustrated,
annotated, referenced

Lesson #1
Don't do things by halves
If you're going to prepare a handout, do it properly and create a book

41yo. Uterus didelphys vaginal and vaginal mass
Unusual atypical epithelial alteration in cervix and vagina

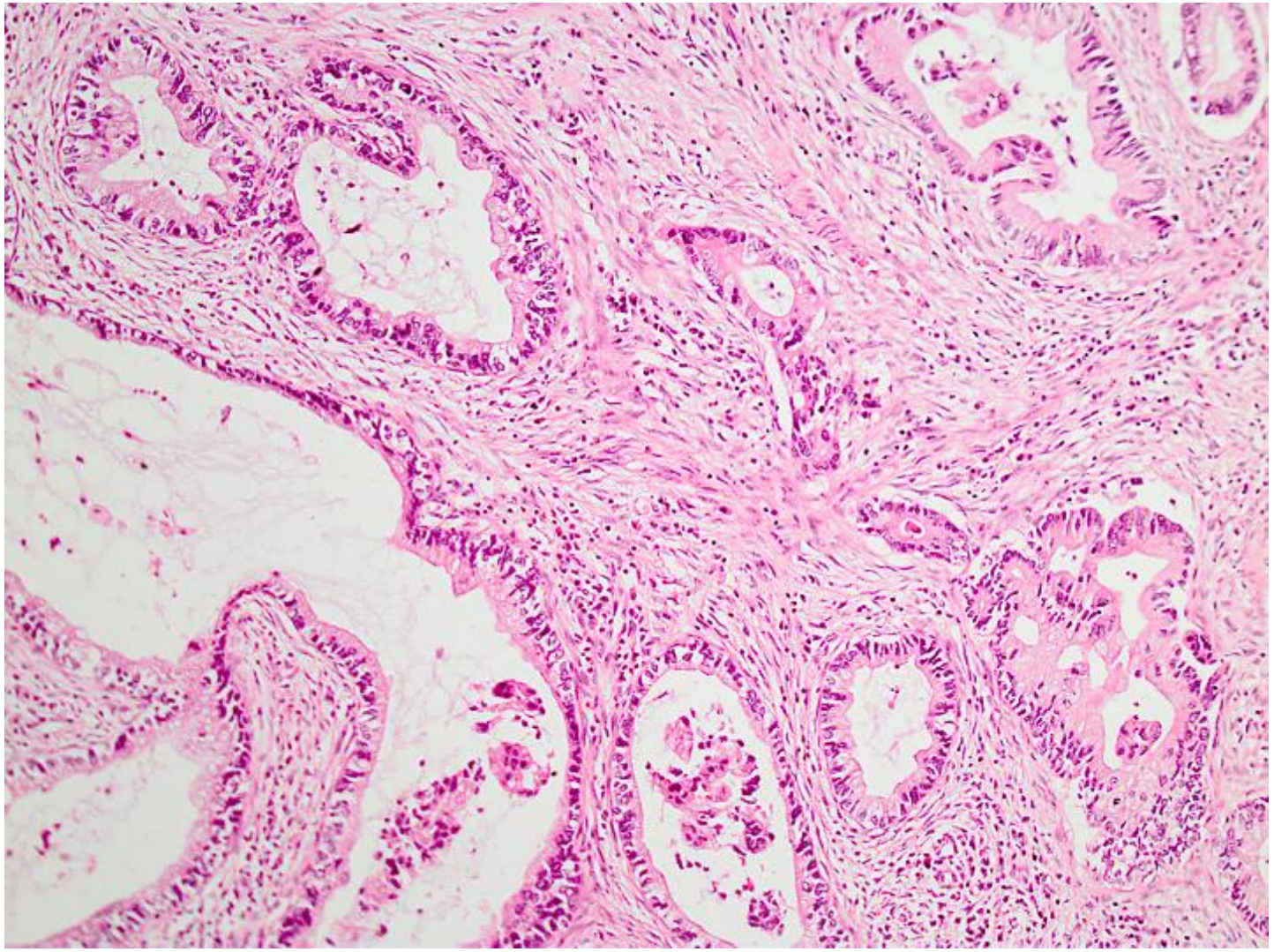

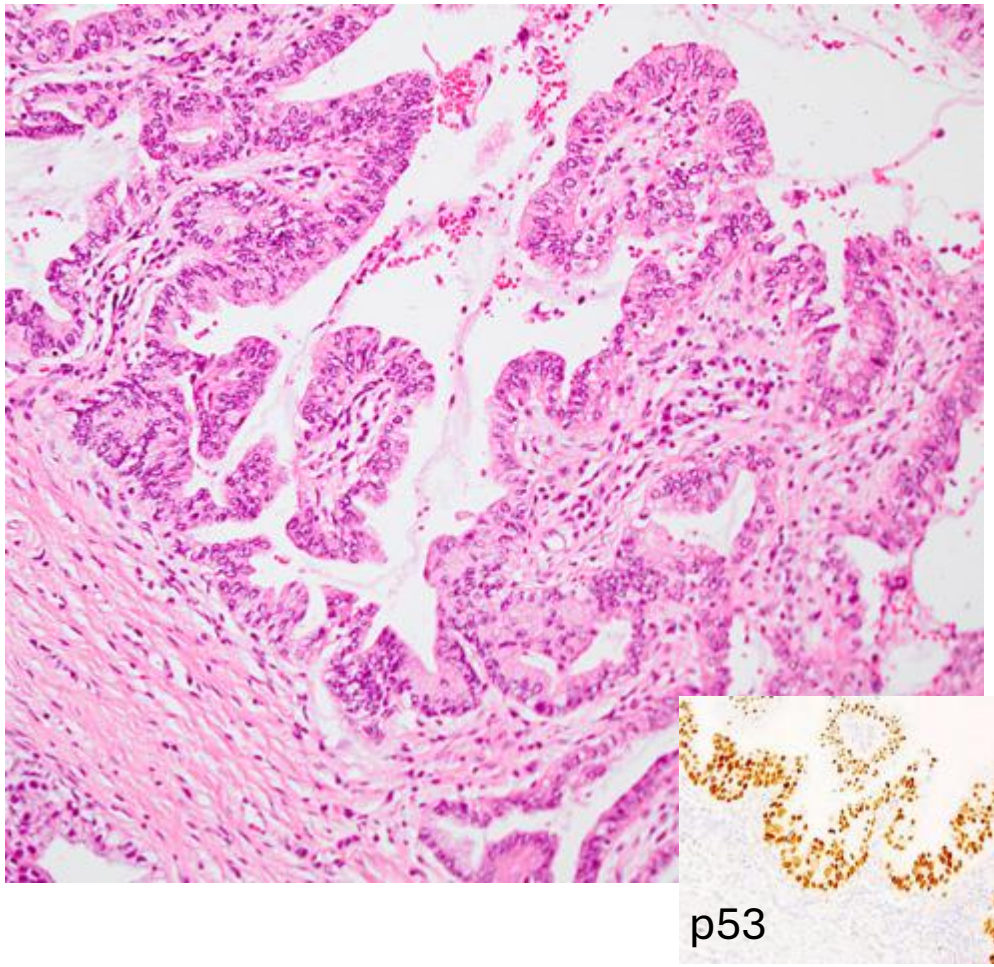

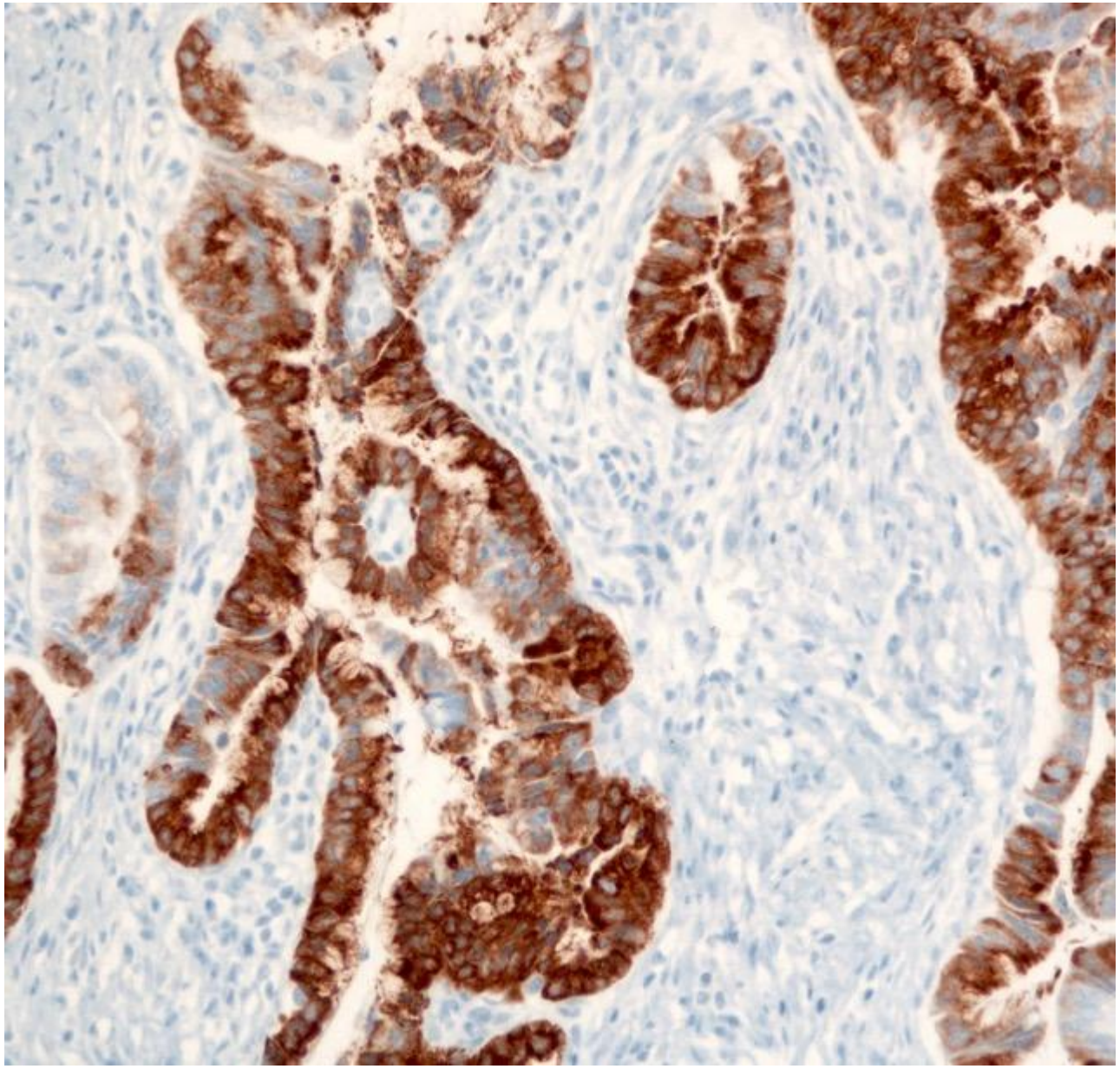

MUC6

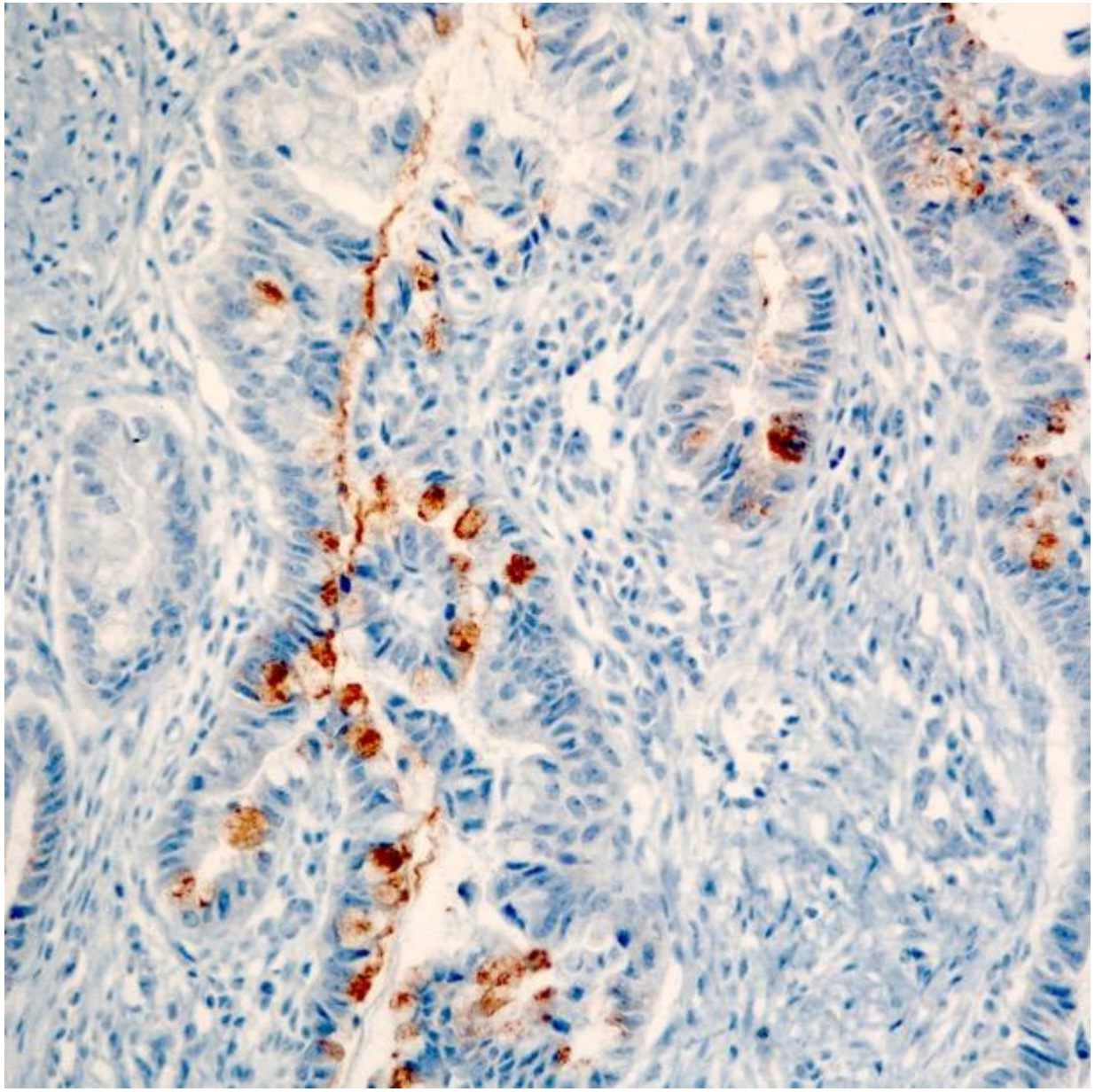

HIK1083 - courtesy of Yoshiki Mikami

Lesson #2

If you have a hunch diagnostically, pursue it because you might be right

… even if it's someone else's case and it involves sending out for IHC

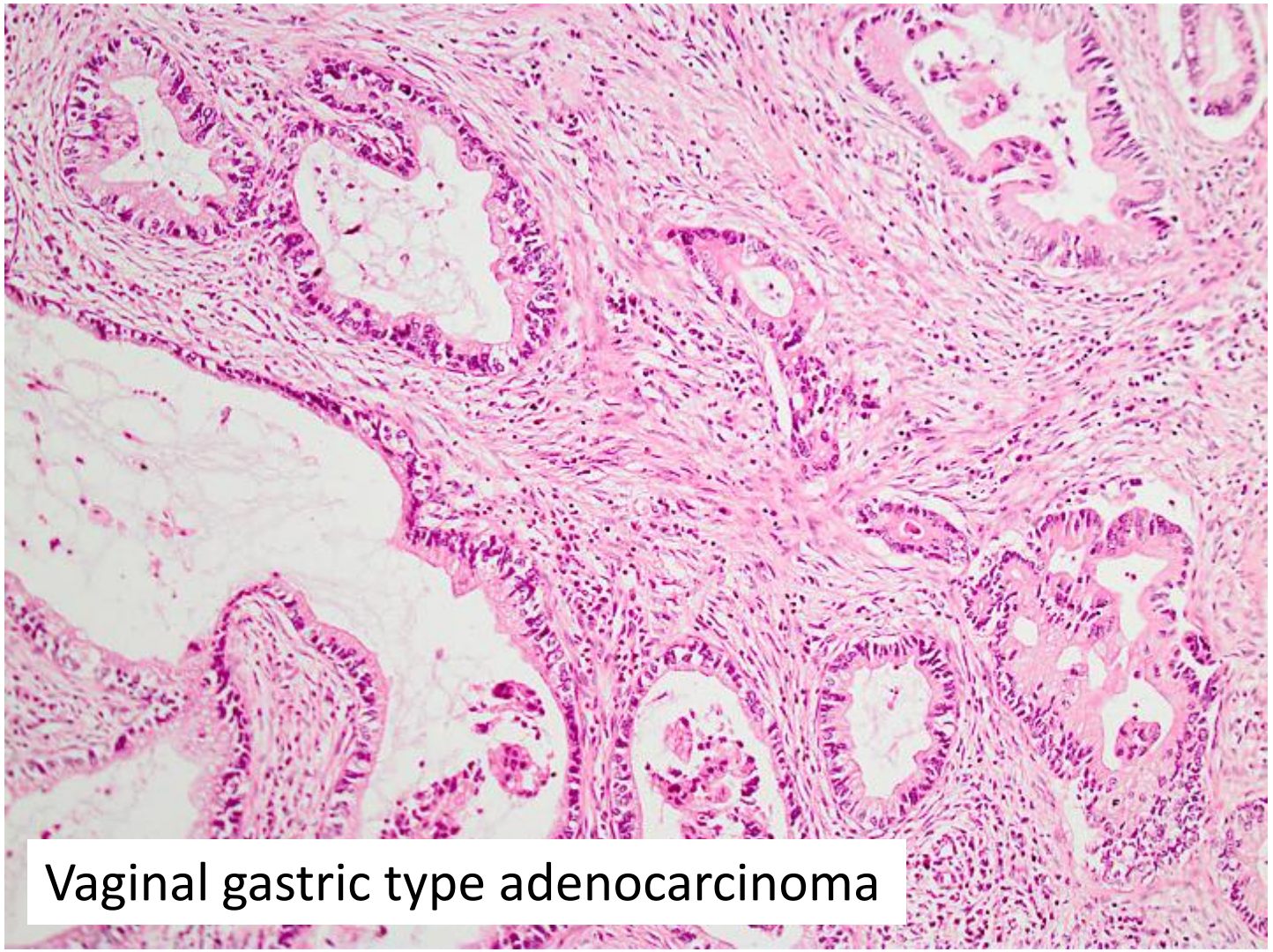

Vaginal gastric type adenocarcinoma

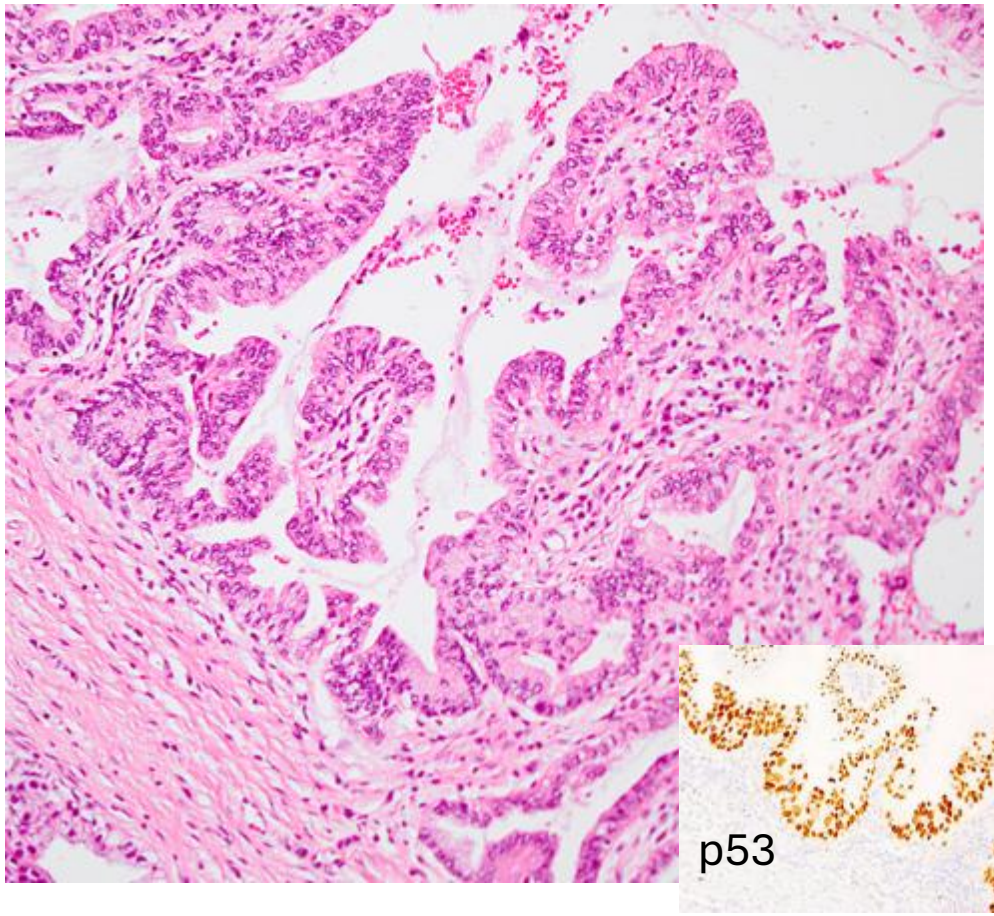

Atypical adenosis, gastric type

Should we write this up?



Lesson #3

How to write

Writing something is better than nothing so just make a start

It doesn't have to be perfect but make sure you pay attention to the grammar!

Case Report

Primary Vaginal Mucinous Adenocarcinoma of Gastric Type Arising in Adenosis: A Report of 2 Cases, 1 Associated With Uterus Didelphys

Karen L. Talia, F.R.C.P.A., James Scurry, F.R.C.P.A., Thomas Manolitsas, F.R.A.N.Z.C.O.G., and W. Glenn McCluggage, F.R.C.Path.

2012

Published!

HPV42

A Common Low-Risk HPV Type Associated With Distinctive Cervicovaginal and Cutaneous Neoplasia

Karen L. Talia, David Hawkes, PhD,†‡§ Gloria Zhang, MD,‖ Jackie Jamison, DRCPath,¶ Jennifer Shanks, MSc,¶ Bin Yang, MD, PhD,‖ Robert Soslow, MD,‖ and W. Glenn McCluggage#*

2025

Paper 32!

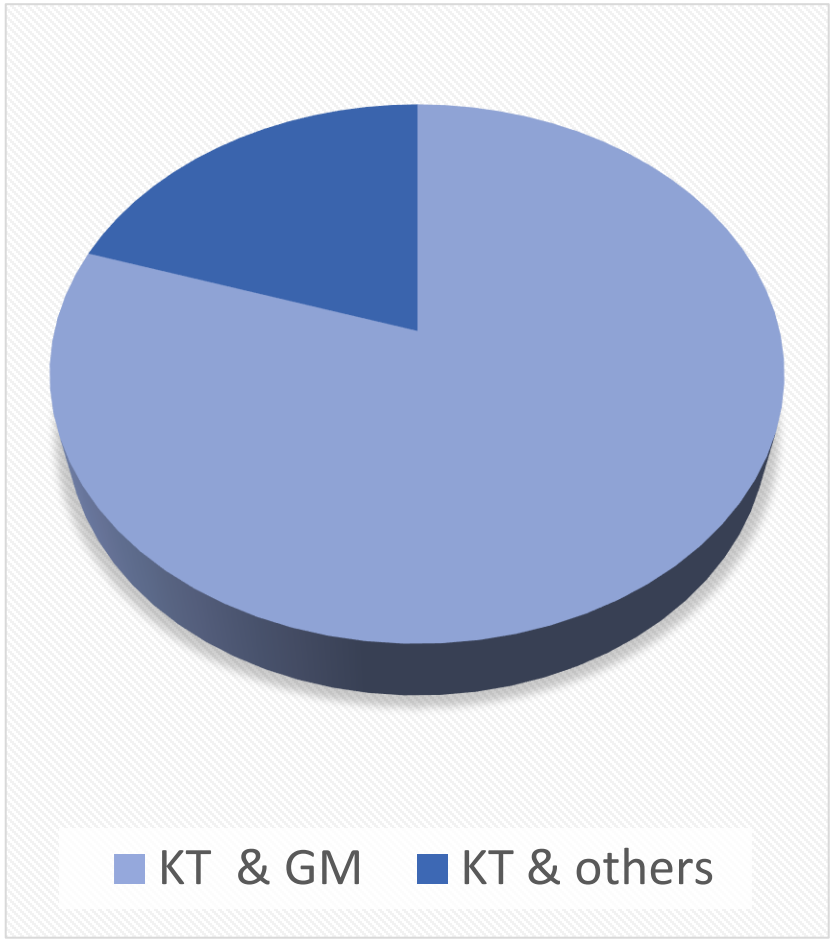

KT papers

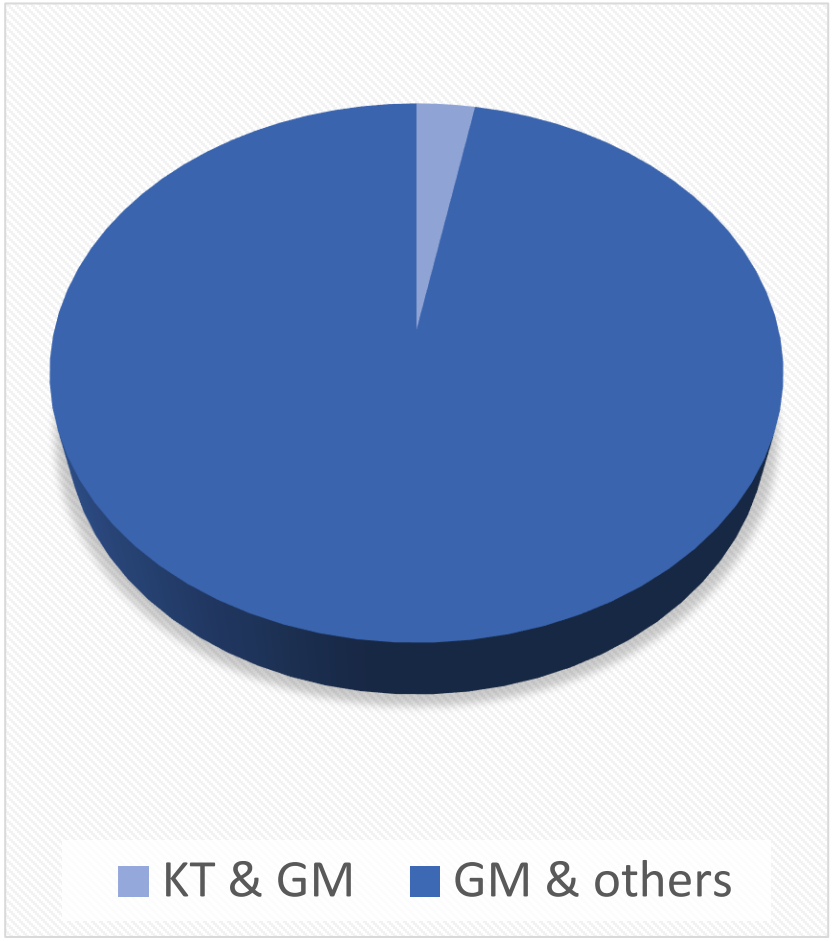

GM papers:
670+ and counting

Lesson #4
The impact and importance of mentorship


Royal
Victoria
Hospital
H
A&E


15
ZONE







Lesson #5

How to see new things

Build an enormous consultation practice – willingly see everyone's difficult cases.

Be organised - photograph and file cases, keep recuts and spares, order extra IHC.

Write detailed second opinion letters – creates a teaching resource for others and creates a record for future research.

Have a great memory.

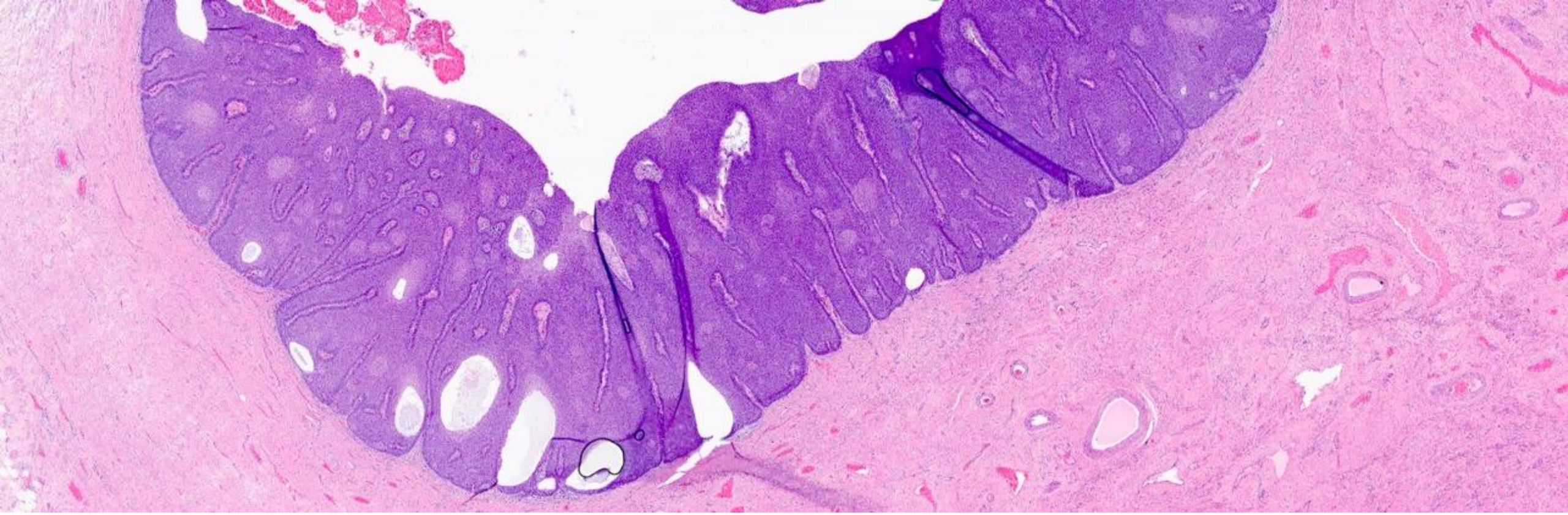

Seborrheic Keratosis-like Lesions of the Cervix and Vagina

Report of a New Entity Possibly Related to Low-risk Human Papillomavirus Infection

Karen L. Talia, FRCPA, MBBS and W. Glenn McCluggage, FRCPath†*

HPV42

A Common Low-Risk HPV Type Associated With Distinctive Cervicovaginal and Cutaneous Neoplasia

Karen L. Talia, David Hawkes, PhD,†‡§ Gloria Zhang, MD,‖ Jackie Jamison, DRCPath,¶ Jennifer Shanks, MSc,¶ Bin Yang, MD, PhD,‖ Robert Soslow, MD,‖ and W. Glenn McCluggage#*

Seborrheic-keratosis like lesion

Case Report

HPV42-associated Seborrhoeic Keratosis-like Lesion of the Cervix: First Reported Case With High-grade Morphology

Karen L. Talia, F.R.C.P.A., Siavash Rahimi, F.R.C.Path., David Hawkes, Ph.D., and W. Glenn McCluggage, F.R.C.Path.

ORIGINAL ARTICLE

HPV-negative Gastric Type Adenocarcinoma In Situ of the Cervix

A Spectrum of Rare Lesions Exhibiting Gastric and Intestinal Differentiation

Karen L. Talia, FRCPA, Colin J.R. Stewart, FRCPA,† Brooke E. Howitt, MD,‡ Marisa R. Nucci, MD,‡ and W. Glenn McCluggage, FRCPath§*

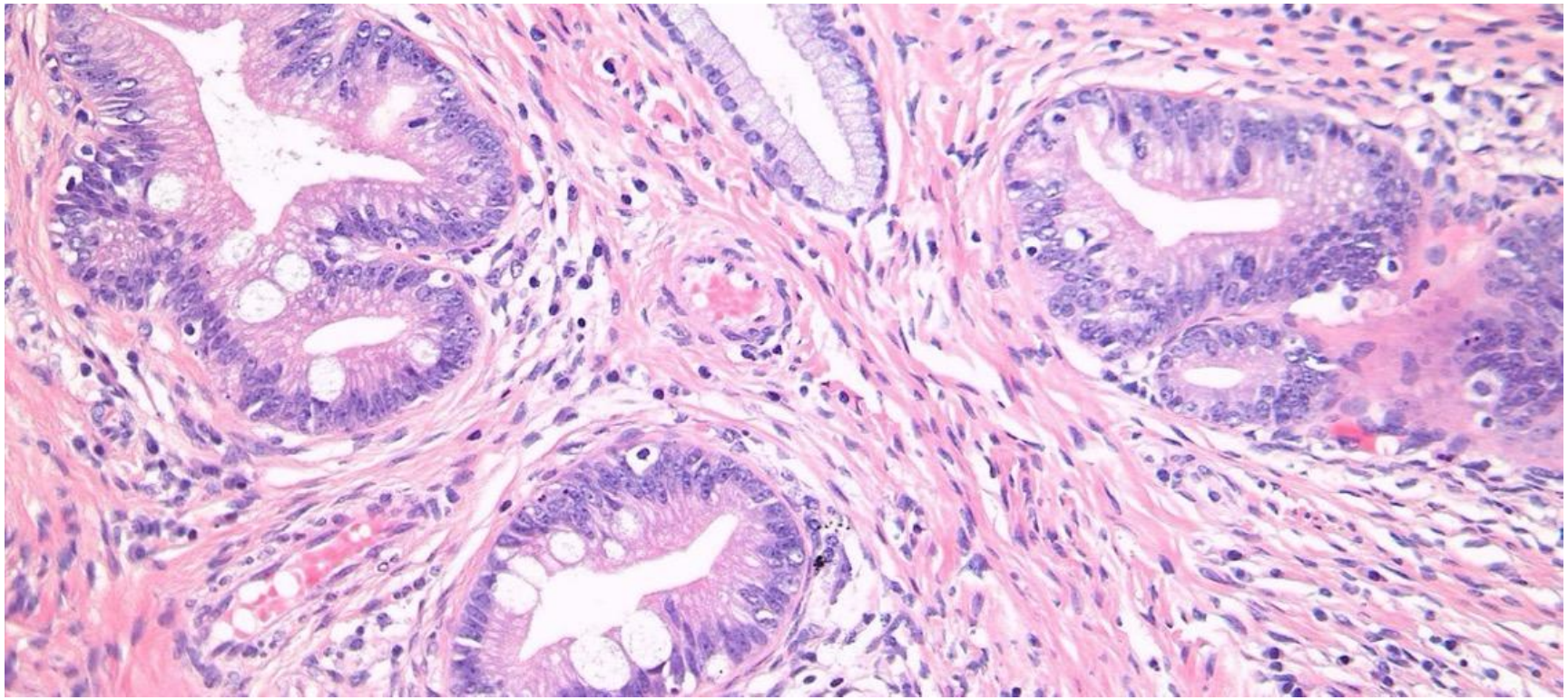

Gastric-type AIS of the cervix

Cervical Adenoid Basal Carcinoma With High-grade Squamous Component

True Mixed Carcinoma or Colonization of Adenoid Basal Carcinoma by High-grade Squamous Intraepithelial Lesion?

Karen L. Talia, MBBS(Hons), FRCPA and W.Glenn McCluggage, FRCPath†*

Colonisation of adenoid basal carcinoma of the cervix by HSIL

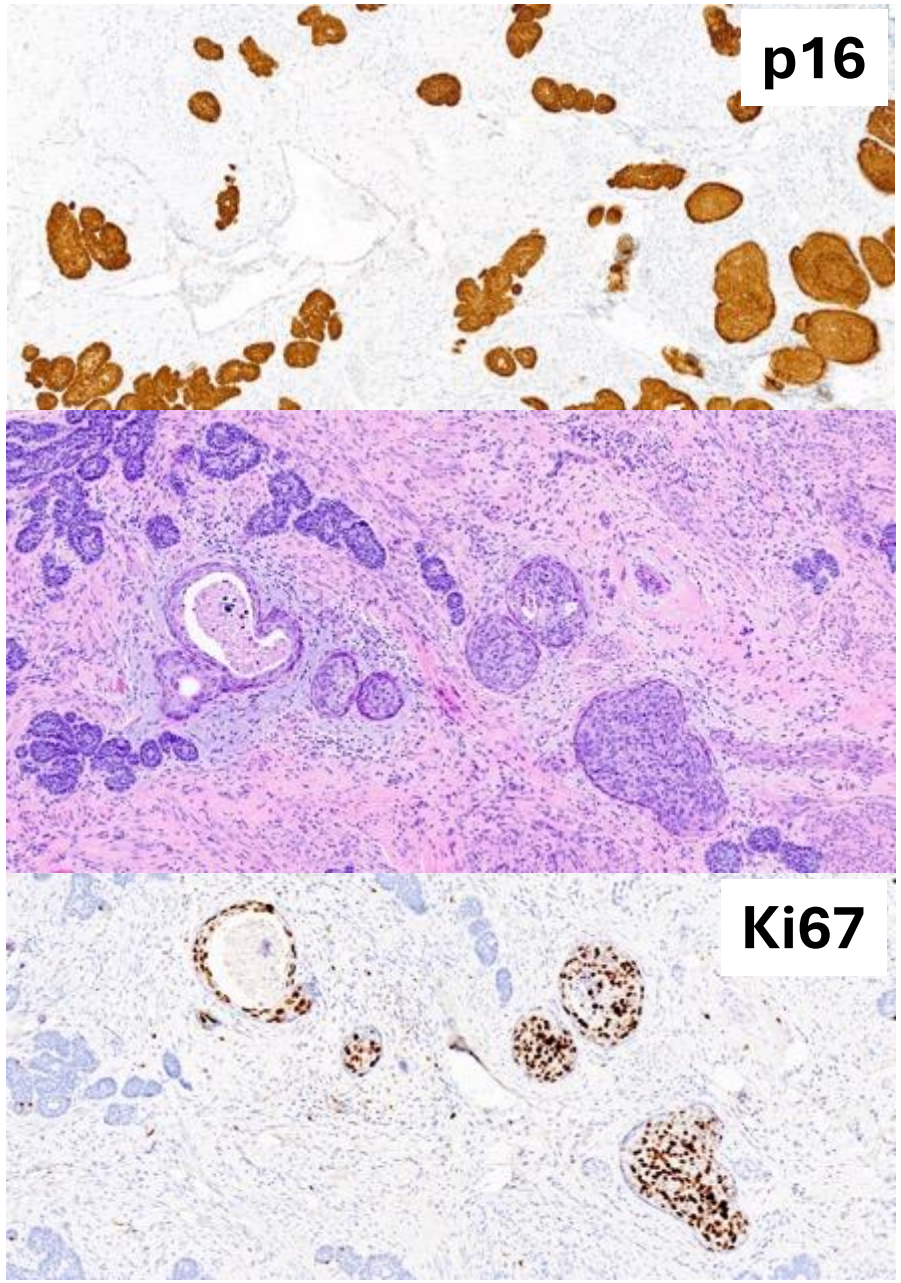

The diverse morphology and immunophenotype of ovarian endometrioid carcinomas

Karen L. Talia[1], W. Glenn McCluggage[2]

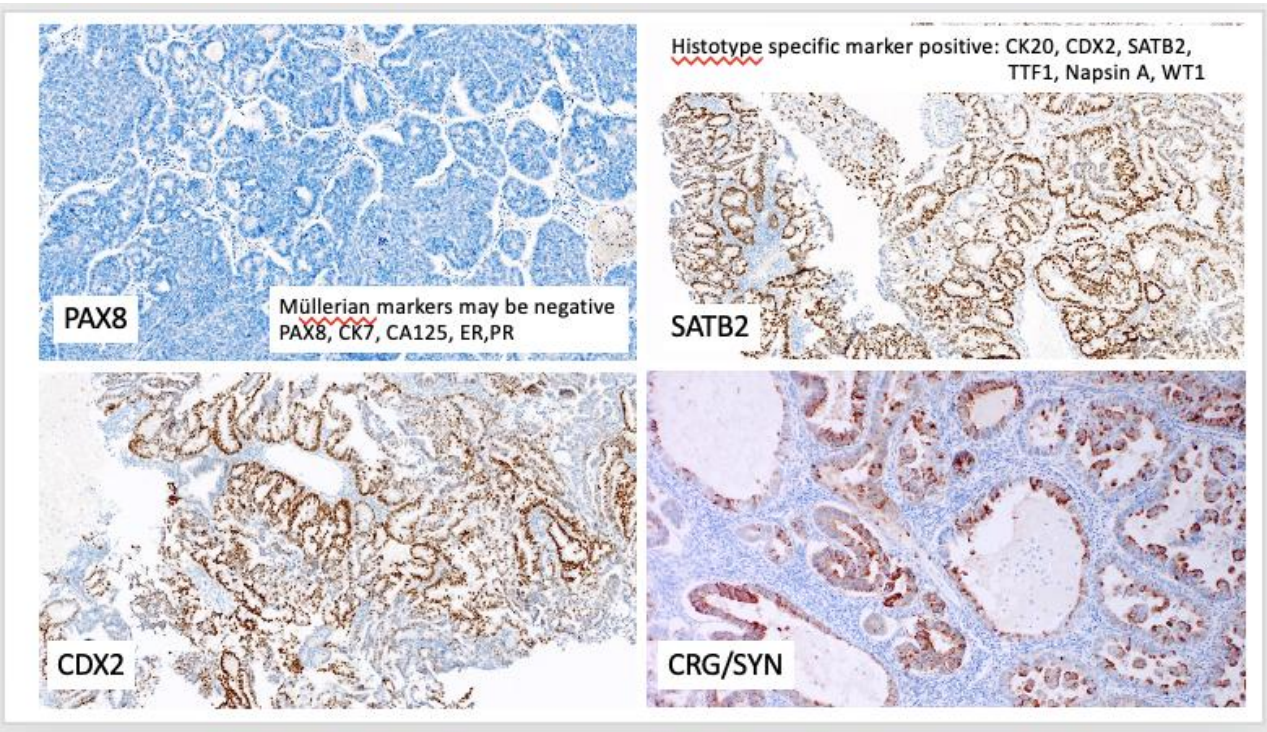

REVIEW

Ovarian mucinous and seromucinous neoplasms: problematic aspects and modern diagnostic approach

Karen L Talia,[1,*] Carlos Parra-Herran[2,*] & W Glenn McCluggage[3,*]

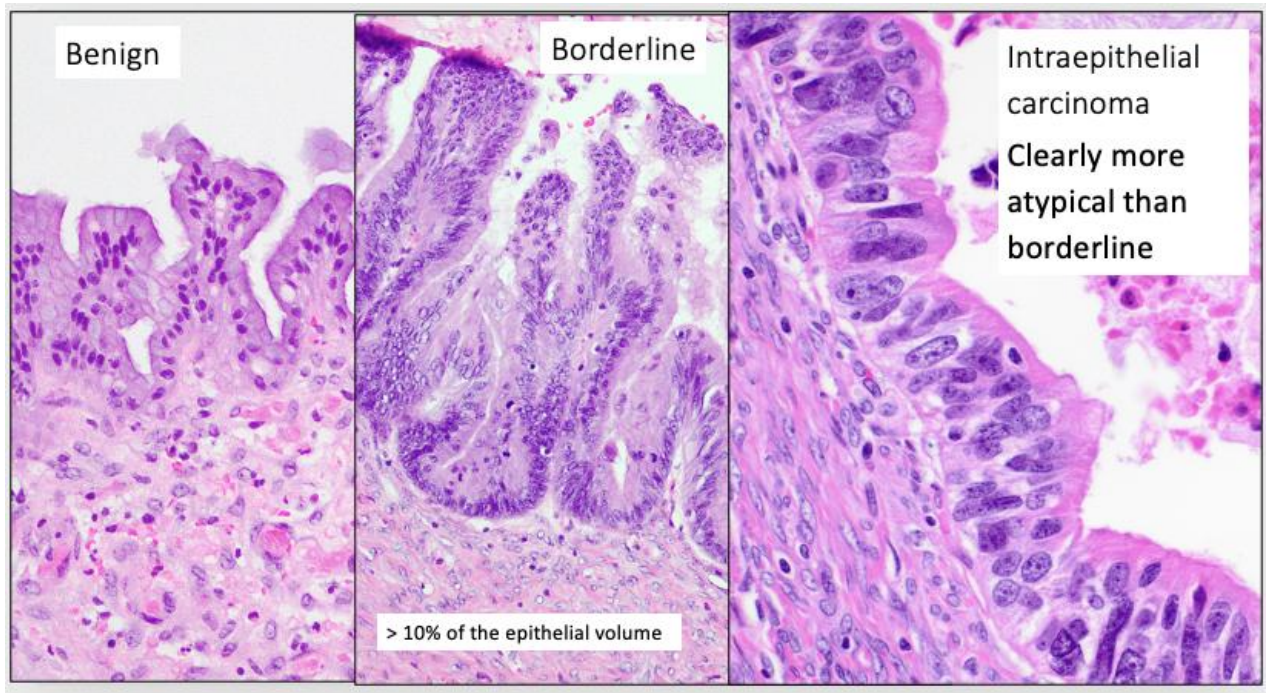







Lesson #6

Always find time to help others

Source: iStock, shutterstock, outdoorsafety.rocks

LARNE RFC

Lesson #7

Maintain some balance

Be amazing at other stuff too

1998 - First Silverware returns to the club for some time

In the 1997/8season the 1st XV has held its own in the First Division of the Qualifying League whilst the 3rd XV, with a strong complement of "mature" players distinguished themselves by winning the Foster Plater. Beating Academy III XV by 10-8 in the final at Ravenhill.

Apart from pieces won at Sevens Tournaments, the silver plate brought back to Larne by the victorious 3rd XV was the first silverware to adorn the Trophy Cabinet at Glynn for many a year.





Past President
Glenn McCluggage



Lesson #8

How to be more like Glenn

Aim high, work hard, treat people well

Be courteous and humble

Nothing is ever too much trouble

Maintain an intellectual curiosity

Have amazing stamina

Heartfelt thanks from all of us