The British Association of Gynaecological Pathologists

Lecturer – Prof W Glenn McCluggage



I am a consultant Histopathologist in Belfast Health and Social Care Trust, Belfast and an Honorary Professor in Gynaecological Pathology of Queen's University of Belfast. I have published over 680 papers in peer reviewed journals, including original publications and many invited editorials and reviews. I am on the Editorial Board of several major pathology journals (Modern Pathology, Human Pathology, Advances in Anatomic Pathology, International Journal of Gynecological Pathology, Virchows Archives), a member of the International Advisory Board of Journal of Clinical Pathology and associate editor of Histopathology. I am past President of International Society of Gynecological Pathologists and was previously secretary of this society. Previously I was President of the British Association of Gynaecological Pathologists. I have an extremely busy referral practice and receive numerous consultation cases from all over the world. I have been invited to lecture at numerous national and international meetings. I have authored or coauthored the various Royal College of Pathologists datasets in United Kingdom on reporting of gynaecological malignancies and have chaired the ICCR (International Collaboration on Cancer Reporting) panels developing international guidelines for reporting endometrial, ovarian, cervical, vulval and vaginal carcinomas. I am also the ICCR series champion for gynaecological neoplasms. I have been part of the last four World Health Organization (WHO) groups formulating the classification of Tumours of the Female Genital Tract and am one of the editors on the upcoming 2025/2026 WHO Classification.

The British Association of Gynaecological Pathologists

BAGP 21ST ANNUAL MEETING

- ❑ WHAT'S NEW IN WHO 2025
- ❑ W GLENN MCCLUGGAGE
- ❑ 5/6/2025

The British Association of Gynaecological Pathologists

Speaker disclosures

I have undertaken some paid work for GSK

TO DISCUSS

- Process of generating 6th edition WHO 2025 Classification
- General changes in new Blue Book from 5th edition 2020 Blue Book
- Specific changes in individual chapters (mainly cervix, vagina, non-epithelial ovary)
- Some specific examples of “new entities/ concepts”
- THE BOOK IS NOT YET PUBLISHED AND MORE MEETINGS TO COME SO ANYTHING I SAY IS PRELIMINARY AND NOT SET IN STONE

PMID 39293942

Histopathology

Histopathology 2025, 86, 839–844. DOI: 10.1111/his.15325

Editorial

WHO Classification of Tumours: moving towards the sixth edition

DOI: 10.1111/his.15325

histopathology-based classification. The nomination of standing members of the WCT editorial committee was by global scientific and academic organisations together with the International Agency for Research on Cancer (IARC).[6] Expert editorial committees were appointed for each volume, including experts from other relevant disciplines (https://whobluebooks.

6TH EDITION- MAINLY REVIEW AND UPDATE

Shortening the update interval is a considerable challenge, but given the rapid pace of advancement in cancer biology and pathology, we recognize the need to adapt the publication schedule accordingly. Our vision is therefore to reduce the production time, giving authors and editors less time than was afforded for previous editions as the 6th edition is planned mainly in "review and update mode" with "rewriting only when essential for existing content". The newly included section of course will need to be written new. We always depend on the goodwill of our contributors, who generously volunteer their time and expertise and this is much appreciated. Each contributor gets a free copy of the book, and their name on a major publication, as we do recognize that this is a demanding (though prestigious) process.

BLUE BOOK DEVELOPMENT PROCESS

Fig. 1: Production process for the WHO Classification of Tumours 5th edition

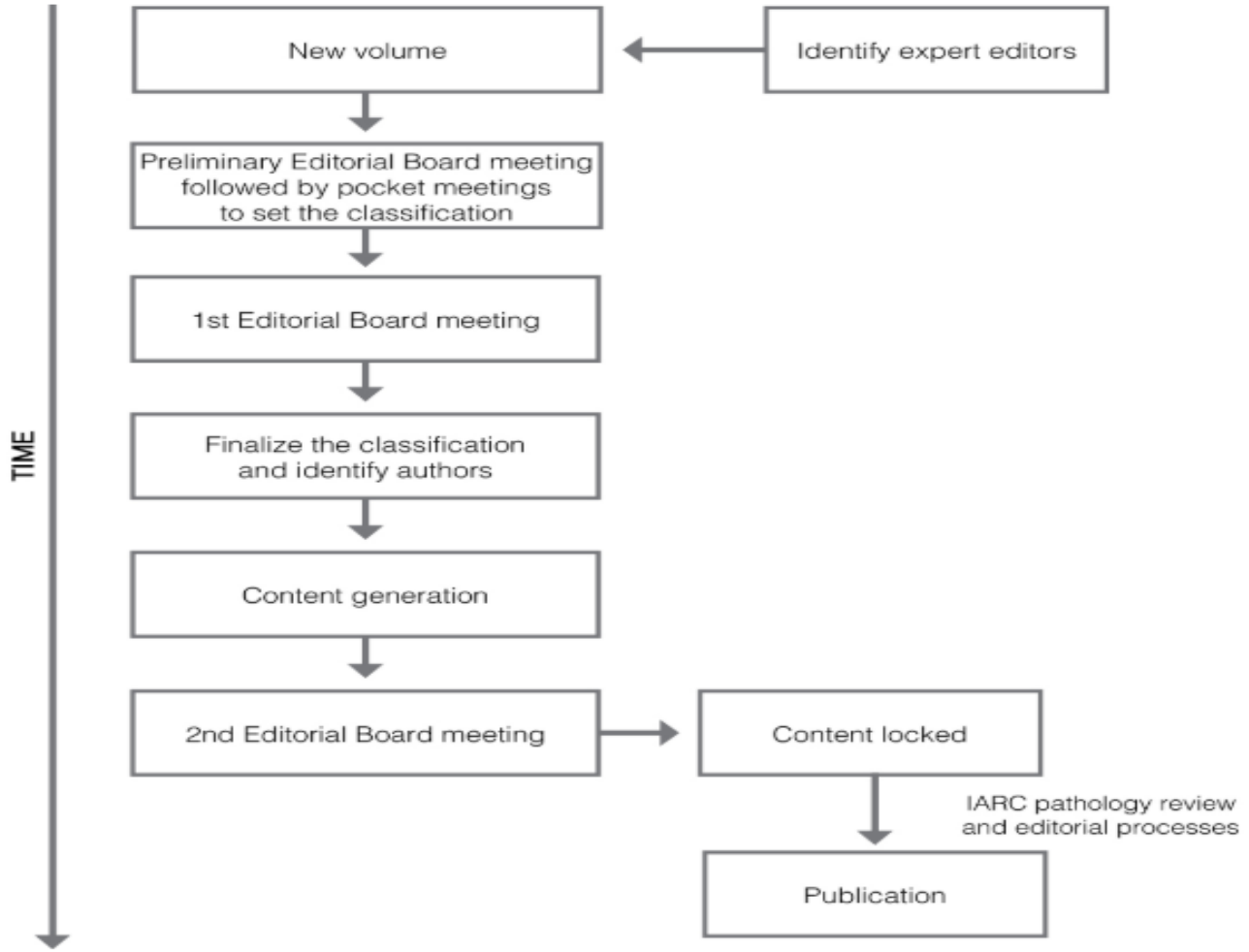

BLUE BOOK DEVELOPMENT PROCESS

- Editors (n= 14 in 6th edition female genital tract tumours) are chosen by IARC based on bibliography and other factors
- Editors formulate classification (chapters and classification)
- Each chapter has a RESPONSIBLE EDITOR and 1 or more COEDITORS
- Each individual section (write-up) within a chapter has a RESPONSIBLE AUTHOR and 1 or more COAUTHORS
- Authors chosen by editors (depending on publication history; known interests; ensure each author does not have too many sections; geographical representation; authors cannot work in same institution as an editor; responsible editors cannot be authors in the same section)
- Authors and editors work on individual write-ups and illustrations

PROCESS

- Following selection of authors and acceptance, editors met online with authors
- Explained process and deadlines
- Provided update on what editors thought needed updating
- New images needed for all write-ups (with rare exceptions)
- WSI to be included for all write-ups (if possible)

INSTRUCTIONS PROVIDED

General instructions and responsibilities for writing a WHO Blue Book section

Instructions for responsible authors

- Contact your coauthors promptly to assign specific tasks as appropriate, taking into account the suggestions made by the editors.
- Review and update or rewrite the text as decided by the EB and reviewing text written by your coauthors.
- Ensure that the entire section text, with figures and references are endorsed by the responsible editor (Close communication with the responsible editor will be necessary for this purpose), and is submitted to IARC via the online submission system (BBOSS3) by the submission deadline.
- All subsections must contain content.
- If the information is unknown or not relevant, this should be stated and ideally referenced.
- See "Subsection headings and definitions" for further instructions.

Contact the IARC/WCT office (asantea@iarc.fr) if you do not hear from one of the authors or if you have any other issues.

NOMENCLATURE

Box 3: Definitions of tumour type and subtype for the WHO Blue Books

Type *(formerly known as "entity"): A tumour type is a separate entity in which multiple parameters (e.g. clinical, location, histopathological, and/or molecular) differ from those of other types.*

Subtypes *refer to a tumour that is recognized as being different in at least one dimension from the main tumour type (clinical, histological or genetic), preferably resulting in a different treatment or outcome.*
The word ***"variant"*** *should be reserved for the meaning "genetic variant", as in an alteration in the most common DNA nucleotide sequence. The term "variant" can be used to describe an alteration that is benign, pathogenic, or of unknown clinical significance.*

Patterns *differ from subtypes in morphological aspects only, but not in underlying biological/molecular features, treatment or outcome.*

TUMOUR SUBTYPES

- WHO subtype definition implies an important clinically actionable lesion that is key to patient management beyond grade/differentiation/stage
- Example: 2020 Blue book lists cellular fibromas as a subtype of fibroma but this is just a morphological pattern and not a subtype in WHO 2025
- Example: *POLE* mutated, MMR deficient, p53abn, NSMP could be regarded as subtypes of endometrioid carcinoma

ESSENTIAL VERSUS DESIRABLE CRITERIA

- Essential criteria= salient histological features which allow diagnosis to be made; can also include immunohistochemistry and molecular which is essential to make diagnosis
- Desirable criteria= other features (morphology, immunohistochemical, molecular) which will support/ refine the diagnosis

PMID 40436071: GLOBAL GAP

MODERN PATHOLOGY

Access provided by USCAP in this session.

RESEARCH ARTICLE · Articles in Press, 100798, May 25, 2025 Download Full Issue

International Feasibility of Applying Diagnostic Essential Criteria of the 5th Edition World Health Organization Classification of Female Genital Tumors: Evidence for a Global Gap in Health Care Equity

Joseph T. Rabban, MD MPH [1] · Reubina Wadee, MD [2] · Anna Plotkin, MD [3] · Alp Usubutun, MD [4] · Divya Midha, MD [5] · Simona Stolnicu, MD [6] · Gustavo Focchi [7] · Matthew A. Price, PhD [8] · Marisa R. Nucci, MD [9] Show less

Affiliations & Notes Article Info

CHAPTERS IN 6th EDITION BLUE BOOK

- INTRODUCTION
- TUMOURS OF THE VULVA
- TUMOURS OF THE VAGINA
- TUMOURS OF THE UTERINE CERVIX
- TUMOURS OF THE UTERINE CORPUS
- TUMOURS OF THE BROAD LIGAMENT AND OTHER UTERINE LIGAMENTS
- TUMOURS OF THE FALLOPIAN TUBE
- EPITHELIAL TUMOURS OF THE OVARY
- NON-EPITHELIAL TUMOURS OF THE OVARY
- MESENCHYMAL TUMOURS
- PERITONEAL MESOTHELIAL TUMOURS
- GESTATIONAL TROPHOBLASTIC DISEASE
- NEUROENDOCRINE NEOPLASIA
- HAEMATOLYMPHOID PROLIFERATIONS AND NEOPLASIA
- MELANOCYTIC LESIONS
- METASTASIS
- GENETIC TUMOUR SYNDROMES OF THE FEMALE GENITAL TRACT

DIFFERENCES FROM PRIOR CLASSIFICATION/ WRITE-UPS

- Order of chapters changed
- 2 ovarian chapters (epithelial and non epithelial)
- Mesenchymal tumours all covered in single chapter
- Some write-ups amalgamated; for example, many primary vaginal adenocarcinomas are included in the corresponding cervical adenocarcinoma sections
- All non-neoplastic lesions removed
- No discussion of differential diagnosis
- Planned that non-neoplastic entities will be covered in stand-alone reviews/ special issue of IJGP

GENERAL INTRODUCTION

- Guidance provided on terminology to use for p53 immunohistochemical staining: mutation-type; wild-type
- Guidance provided on terminology to use for p16 immunohistochemical staining: block-type; negative/ non-block-type
- Guidance provided on terminology to use for MMR immunohistochemical staining

CERVIX CHAPTER

4.0: Tumours of the uterine cervix

4.1: Tumours of the uterine cervix: Introduction

4.2: Squamous cell tumors and precursors

- 4.2.0.1: Squamous intraepithelial lesions
- 4.2.0.2: Cervical intraepithelial neoplasia, HPV-independent
- 4.2.0.3: Squamous cell carcinoma, HPV-associated
- 4.2.0.4: Squamous cell carcinoma, HPV-independent
- 4.2.0.5: Squamous cell carcinoma NOS

4.3: Glandular tumours and precursors

- 4.3.0.1: Endocervical polyp
- 4.3.1: Adenocarcinomas
  - 4.3.1.1: Adenocarcinoma in situ, HPV-associated
  - 4.3.1.2: Adenocarcinoma, HPV-associated
  - 4.3.1.3: Adenocarcinoma in situ, HPV-independent
  - 4.3.1.4: Adenocarcinoma, HPV-independent, gastric type
  - 4.3.1.5: Adenocarcinoma, HPV-independent, clear cell type
  - 4.3.1.6: Adenocarcinoma, HPV-independent, mesonephric type
  - 4.3.1.7: Other adenocarcinomas

4.4: Other epithelial tumours

- 4.4.0.1: Carcinosarcoma
- 4.4.0.2: Adenosquamous carcinoma, HPV associated
- 4.4.0.3: Adenosquamous carcinoma, HPV-independent
- 4.4.0.4: Adenoid basal carcinoma
- 4.4.0.5: Carcinoma, unclassifiable

4.5: Neuroendocrine neoplasms

- 4.5.1: Neuroendocrine tumors
- 4.5.2: Neuroendocrine carcinoma

CERVIX CHAPTER- CHANGES FROM 5TH EDITION

- All non-neoplastic entities gone (lot of squamous and glandular lesions gone)
- New category of “CERVICAL INTRAEPITHELIAL NEOPLASIA, HPV INDEPENDENT”
- Other adenocarcinomas- HPV independent category (mainly endometrioid; detailed discussion as to why serous carcinoma removed)
- Adenosquamous carcinoma (now HPV-associated and HPV-independent); mucoepidermoid carcinoma gone
- Neuroendocrine neoplasms now included (NETs and NECs)

SQUAMOUS INTRAEPITHELIAL LESION (SIL) SECTION

- LSIL: discussion of papillary immature metaplasia (PIM) and seborrheic keratosis-like lesion (SKLL) as morphological patterns of LSIL
- HSIL: discussion about importance of classifying as CIN 2 or CIN 3, especially in younger patients (CIN 2 can be treated conservatively)
- Discussion of value of p16

PMID 40387309

ORIGINAL ARTICLE

HPV42

A Common Low-Risk HPV Type Associated With Distinctive Cervicovaginal and Cutaneous Neoplasia

Karen L. Talia, David Hawkes, PhD,†‡§ Gloria Zhang, MD,‖ Jackie Jamison, DRCPath,¶ Jennifer Shanks, MSc,¶ Bin Yang, MD, PhD,‖ Robert Soslow, MD,‖ and W. Glenn McCluggage#*

PMID 40387309

- 17 cases of SKLL
- 13 HPV42-associated (sometimes with other HPV types)

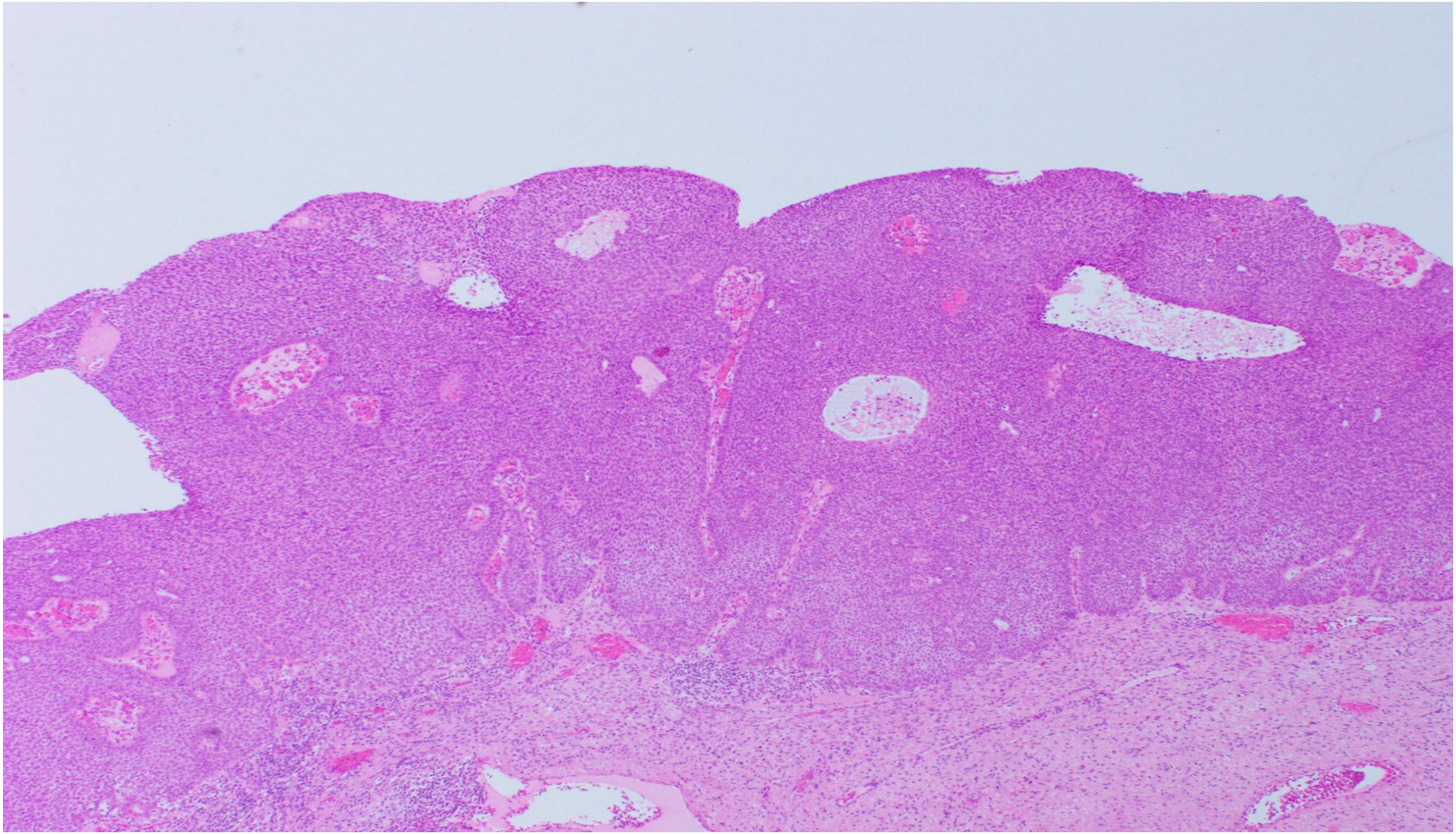

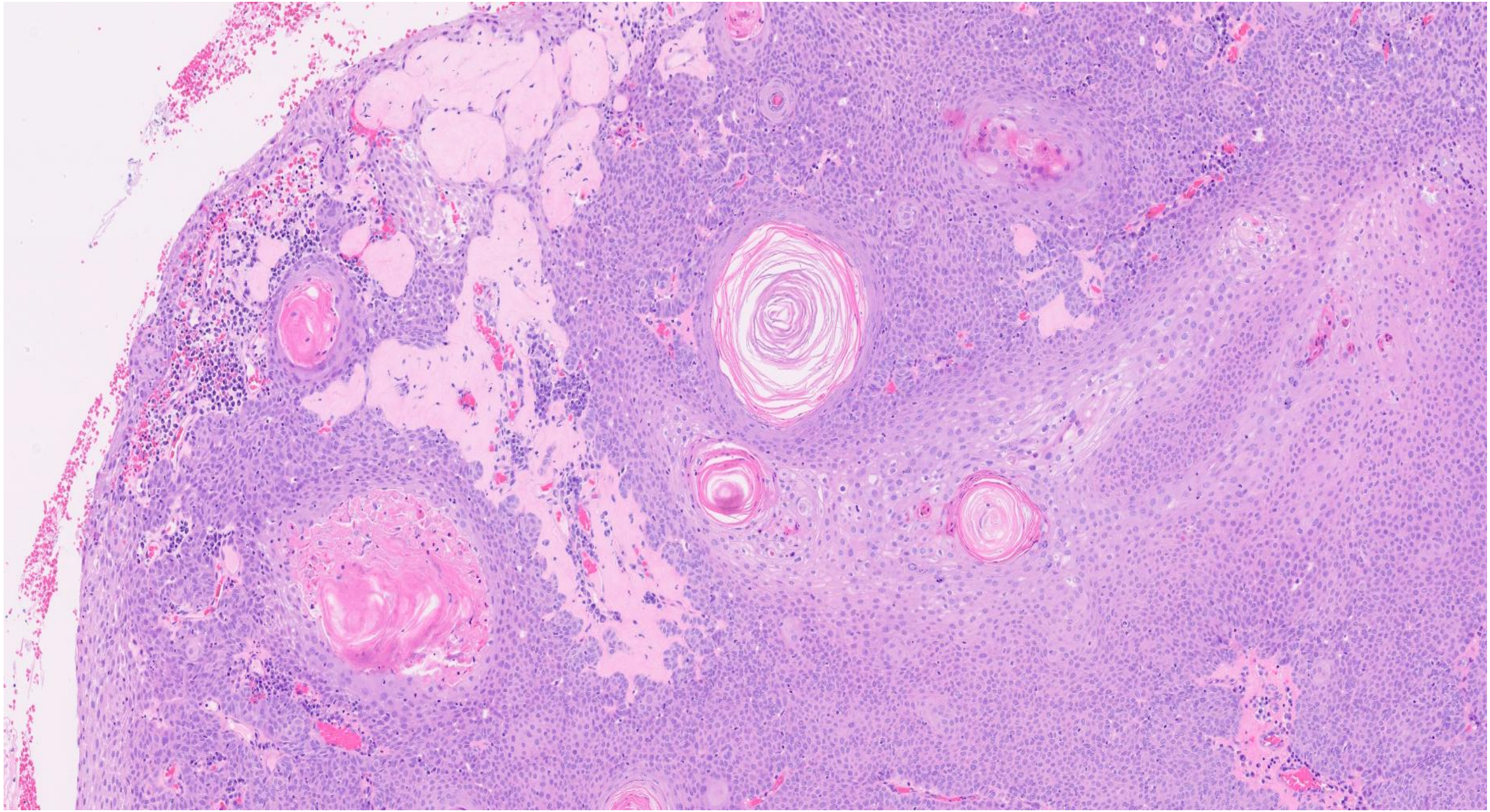

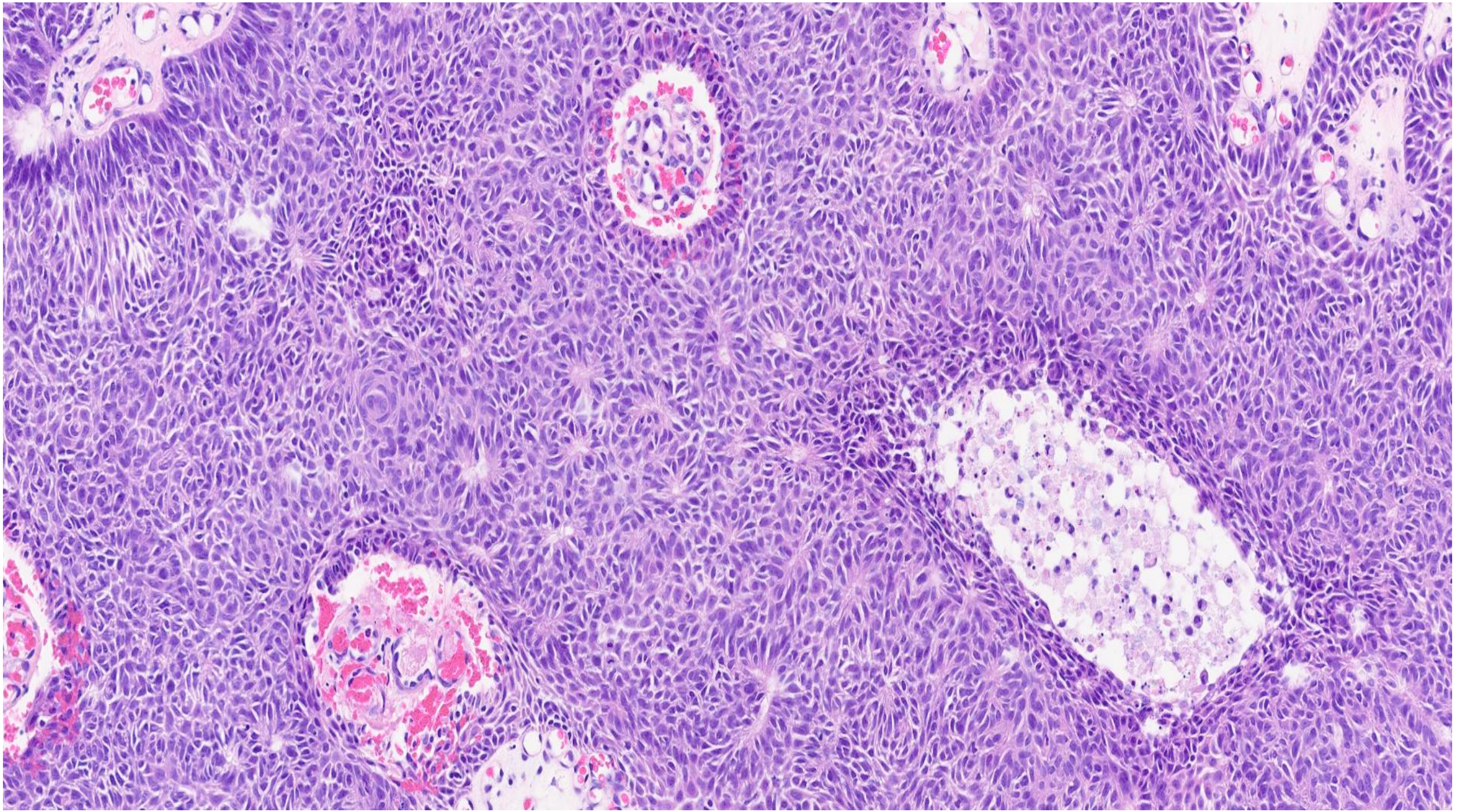

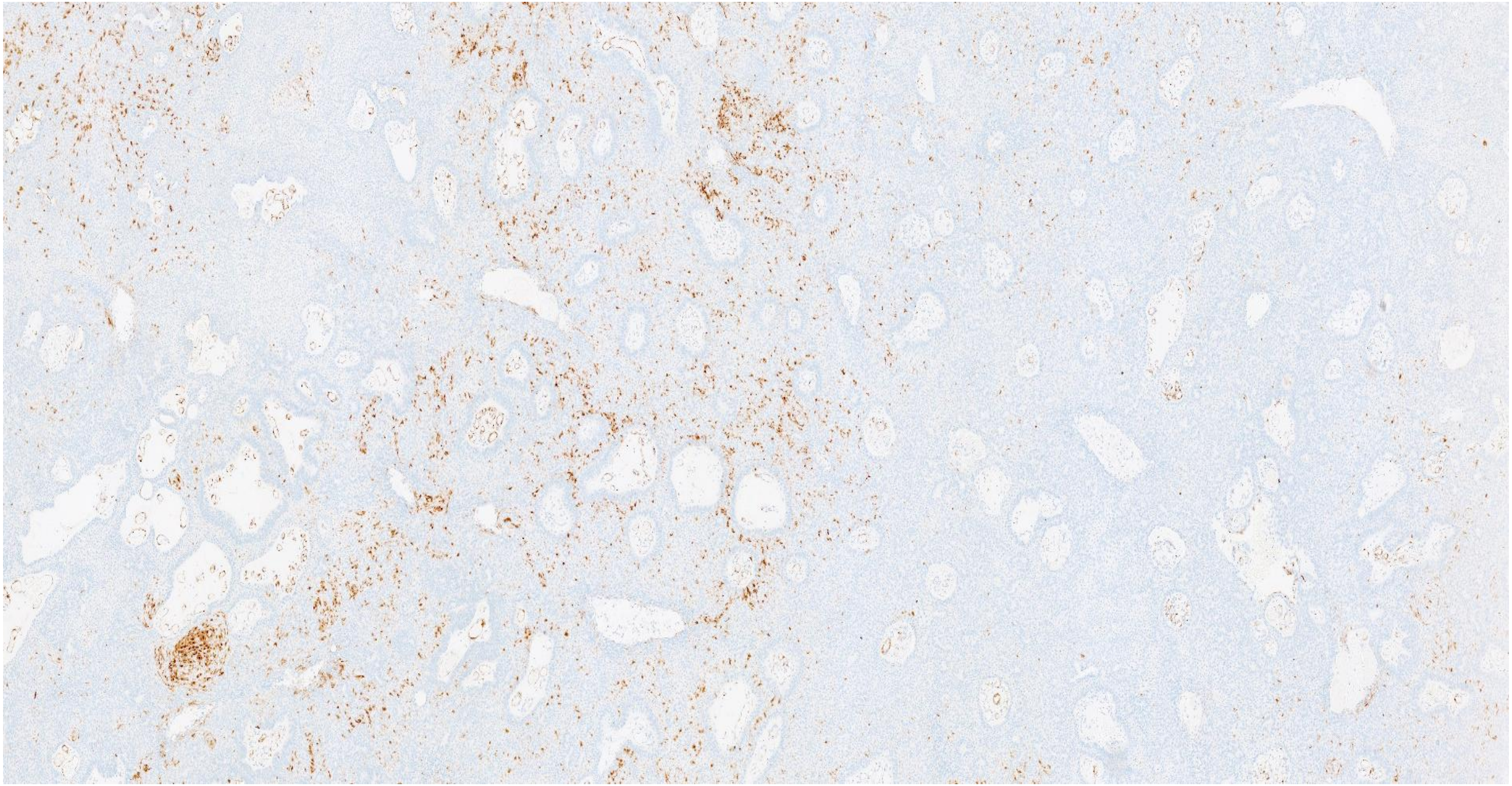

p16

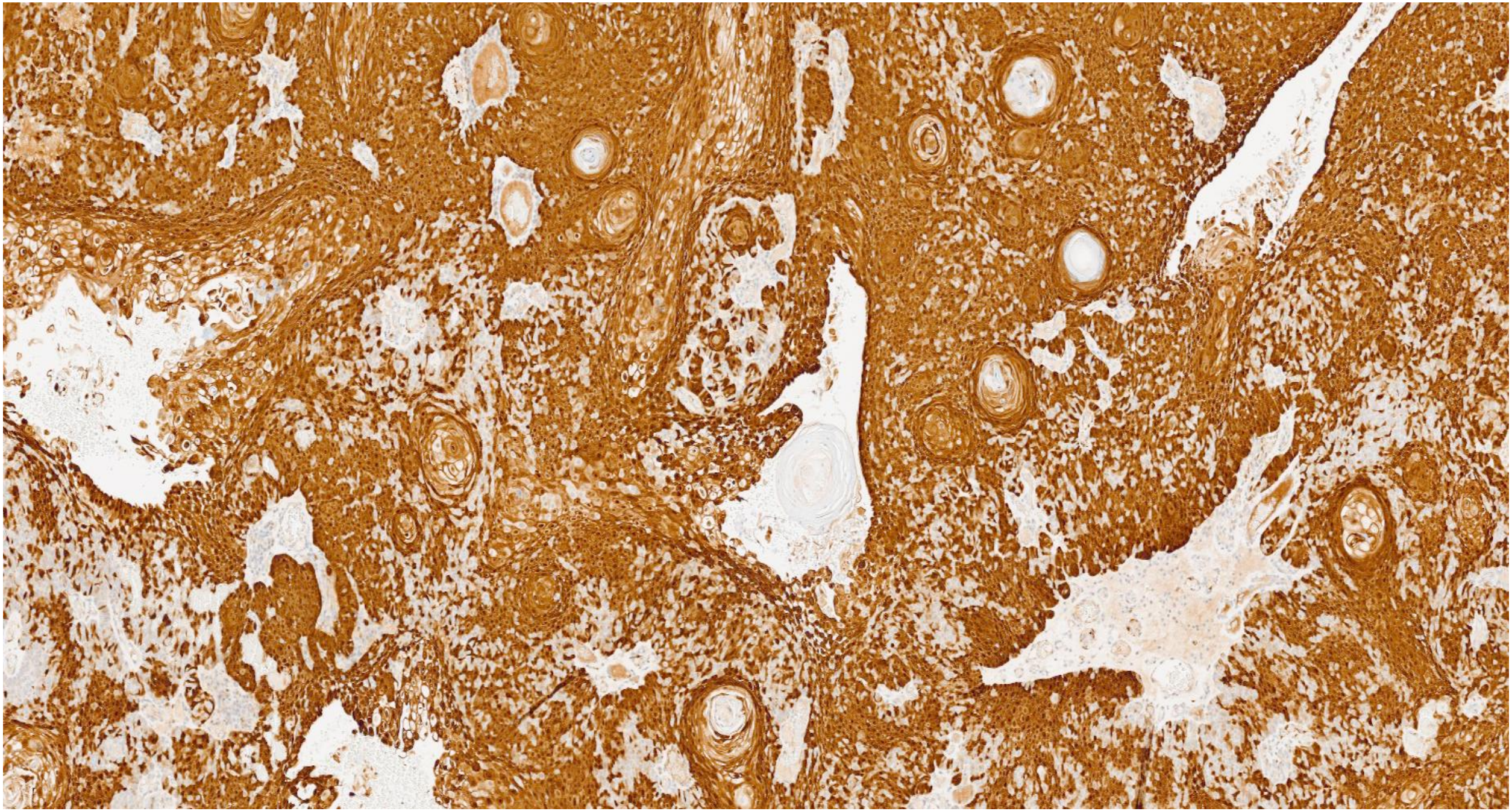

p16

PMID 35538210

USCAP

www.nature.com/modpathol

ARTICLE

Check for updates

Association of HPV42 with digital papillary adenocarcinoma and the use of in situ hybridization for its distinction from acral hidradenoma and diagnosis at non-acral sites

Chad Vanderbilt[1], Thomas Brenn[2], Andrea P. Moy[1], Gordon Harloe[3], Charlotte Ariyan[4], Edward Athanasian[4] and Klaus J. Busam[1]✉

© The Author(s), under exclusive licence to United States & Canadian Academy of Pathology 2022

PAPILLARY IMMATURE METAPLASIA (PIM)

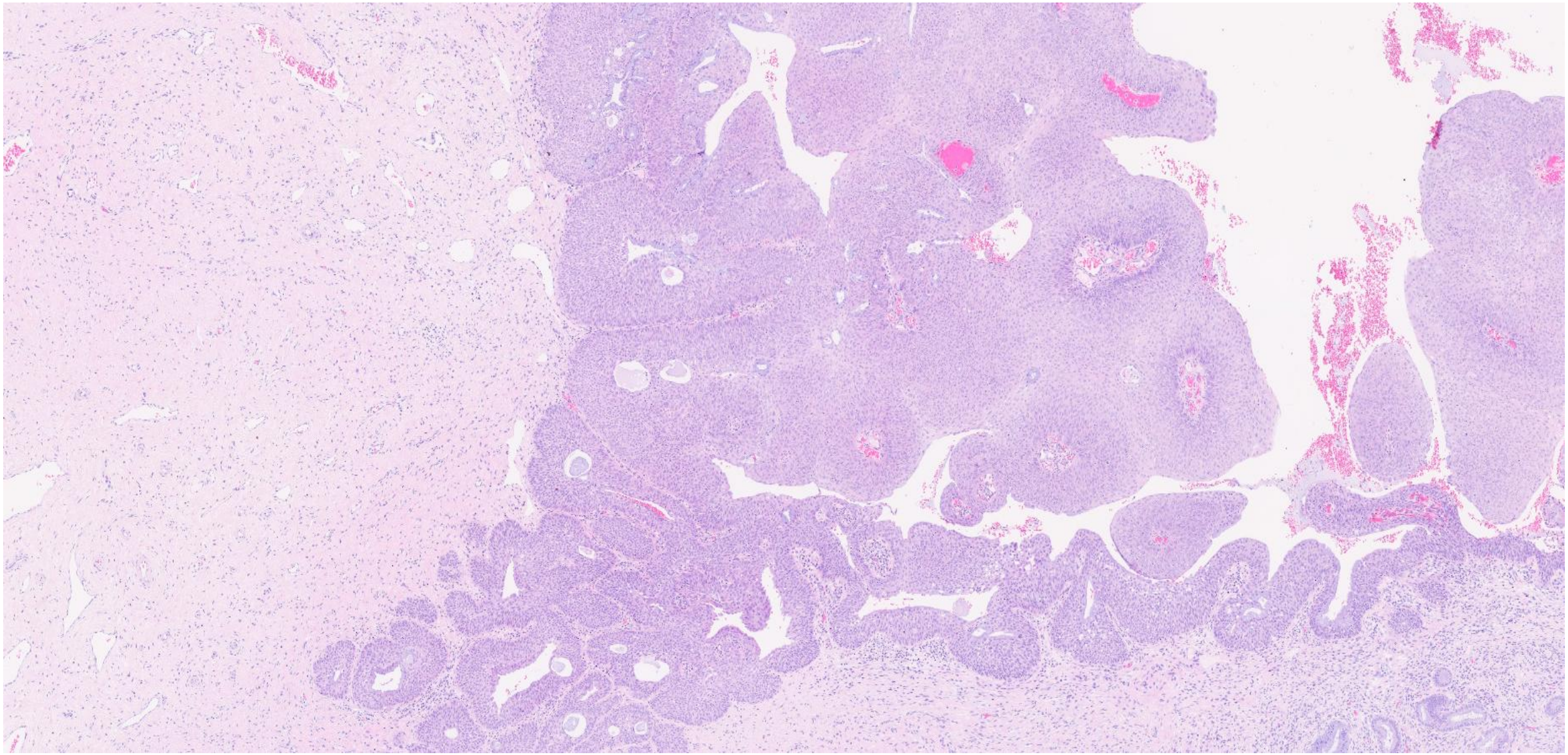

PAPILLARY IMMATURE METAPLASIA (PIM)

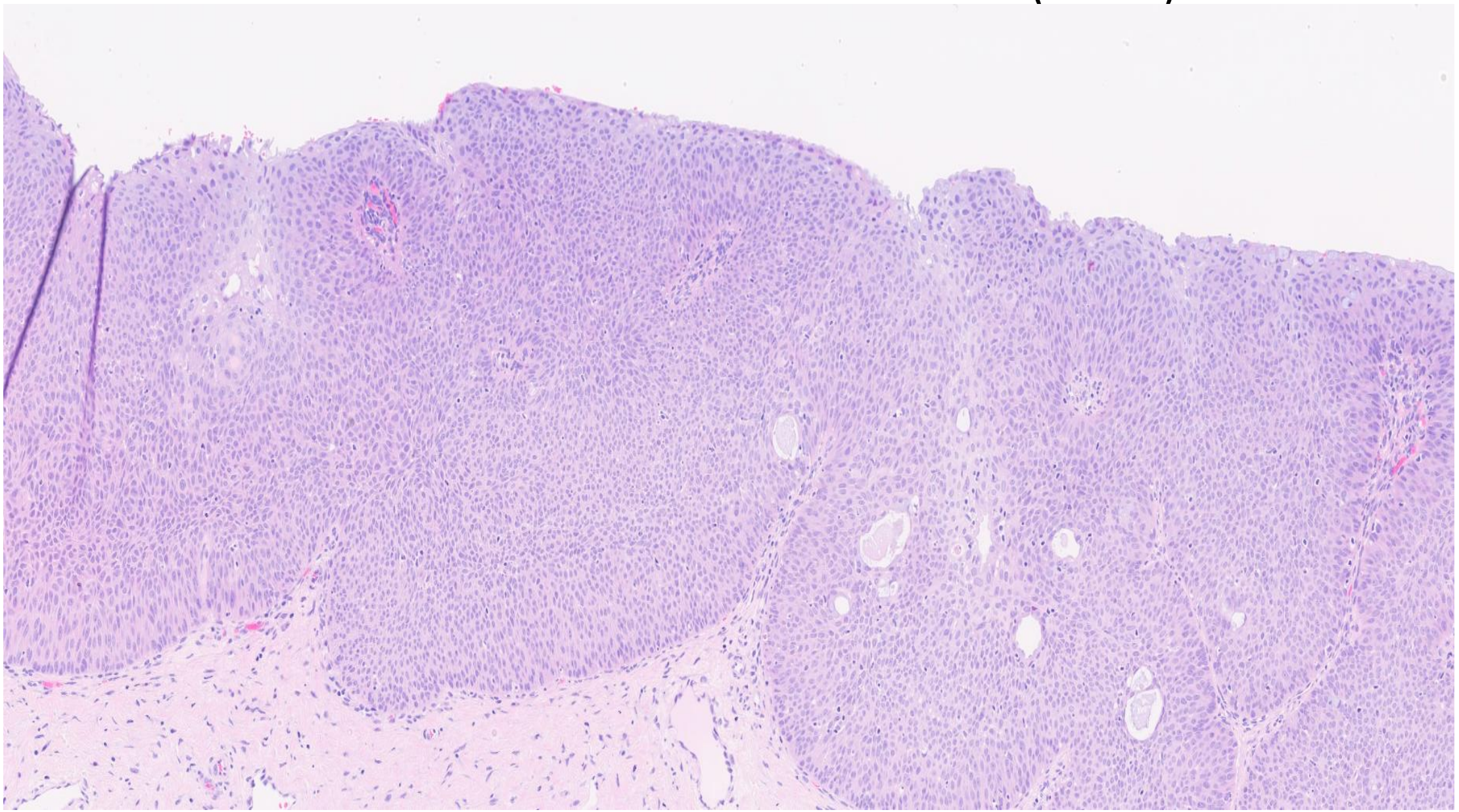

CERVICAL INTRAEPITHELIAL NEOPLASIA, HPV INDEPENDENT

- Lot of discussion as to whether should be included
- Very few cases reported and mostly in association with HPV-independent SCCs
- Various morphologies; some are *TP53* mutated and some *TP53* wild-type
- Parallels with vulvar precursors (3 types based on HPV-association and p53 status)

CERVICAL INTRAEPITHELIAL NEOPLASIA, HPV INDEPENDENT

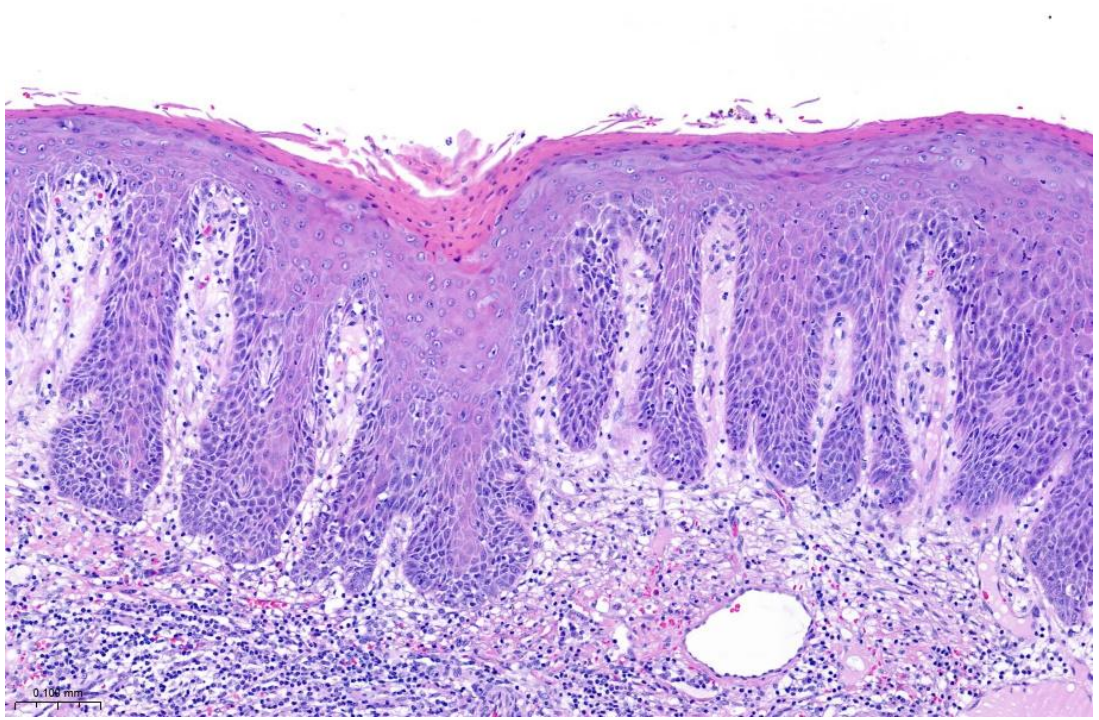

p53 mutation-type staining: looks like differentiated VIN

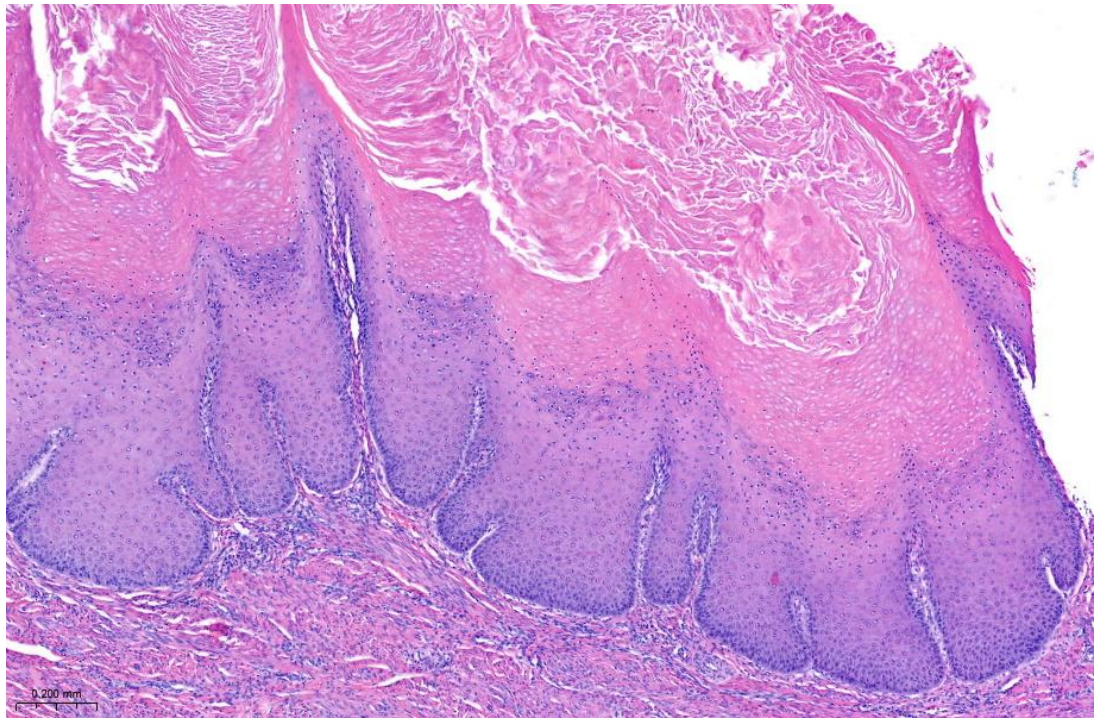

p53 wild-type staining: looks like vaVIN/ DEVIL/ VAAD

SQUAMOUS CELL CARCINOMA, HPV-ASSOCIATED: ESSENTIAL AND DESIRABLE CRITERIA

- *Essential:* infiltrating, angulated, irregularly sized and shaped nests, anastomosing cords, and solid sheets of atypical squamous cells; nuclear pleomorphism and prominent mitotic activity; a desmoplastic or inflammatory stroma; **strong and diffuse p16 IHC overexpression as an acceptable surrogate marker of HPV association (occasional exceptions)**
- *Desirable (in selected cases):* **positive direct HPV testing (in cases where p16 IHC is negative or equivocal)**

METHODS FOR DETECTING HPV

- Neither p16 nor molecular methods 100% reliable (but p16 is a good surrogate marker in the correct context)
- Most laboratories will just do p16 immunohistochemistry
- Can rarely get total/ partial loss of p16 in HPV-associated neoplasms secondary to methylation
- Some other carcinomas can exhibit diffuse block-type p16 staining
- Currently best recommended molecular method for HPV is HPV RNA in situ hybridisation (HPV RISH); can also do PCR

CERVICAL SCC CASE- HPV 16 POSITIVE ON PCR

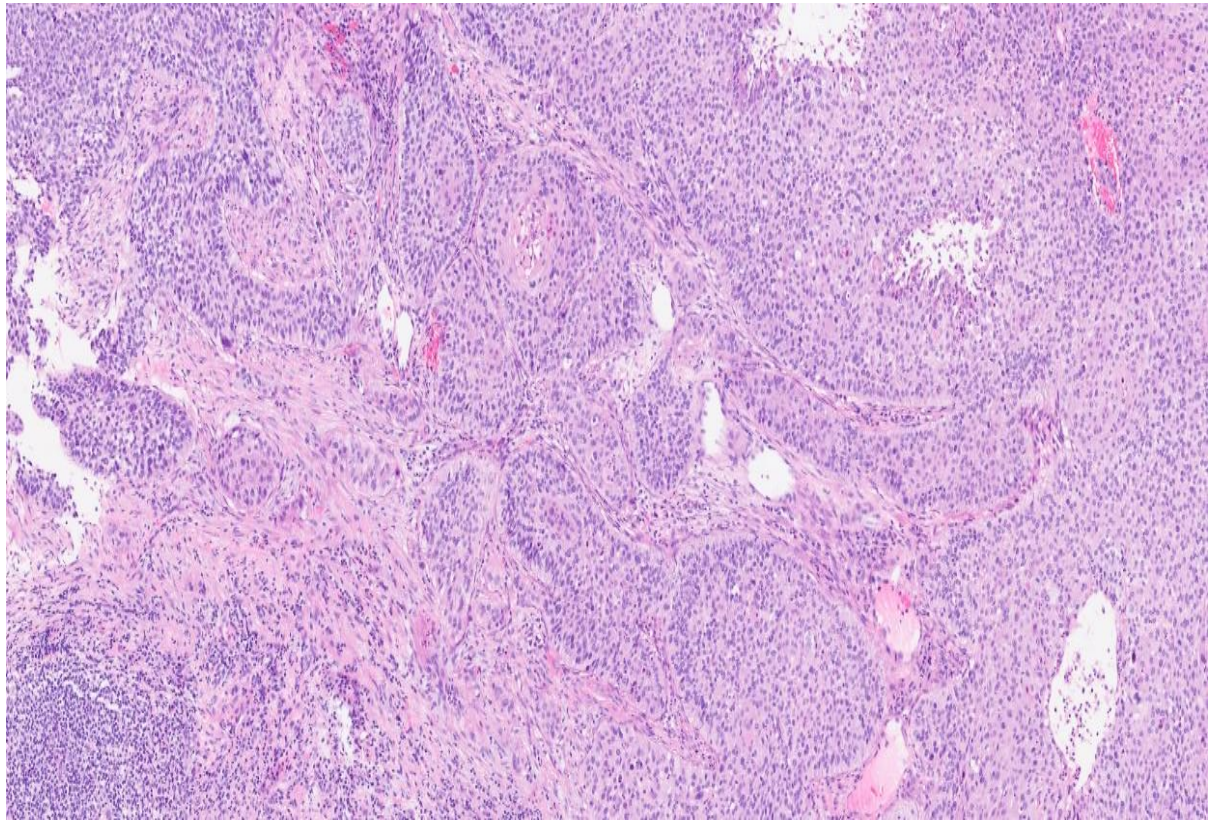

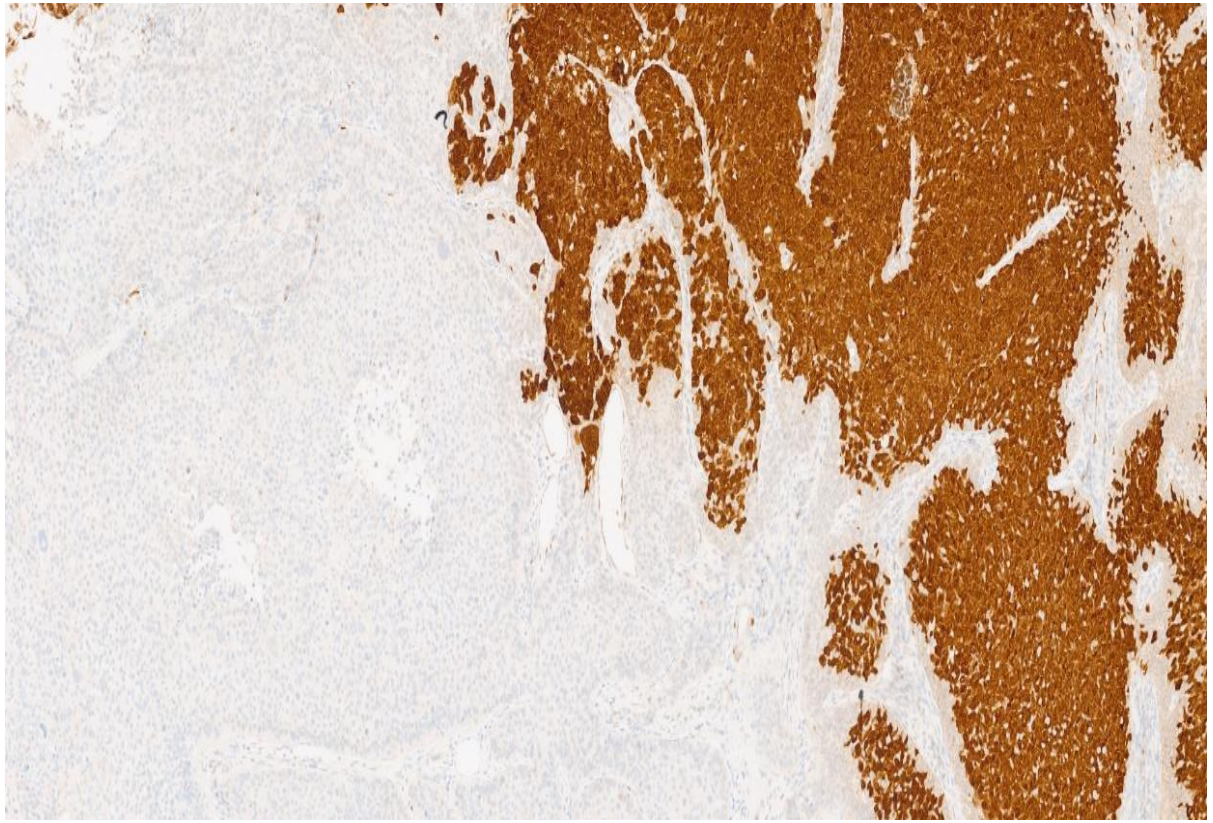

p16

“LOSS” OF p16 IN HPV-ASSOCIATED CERVICAL ADENOCARCINOMA

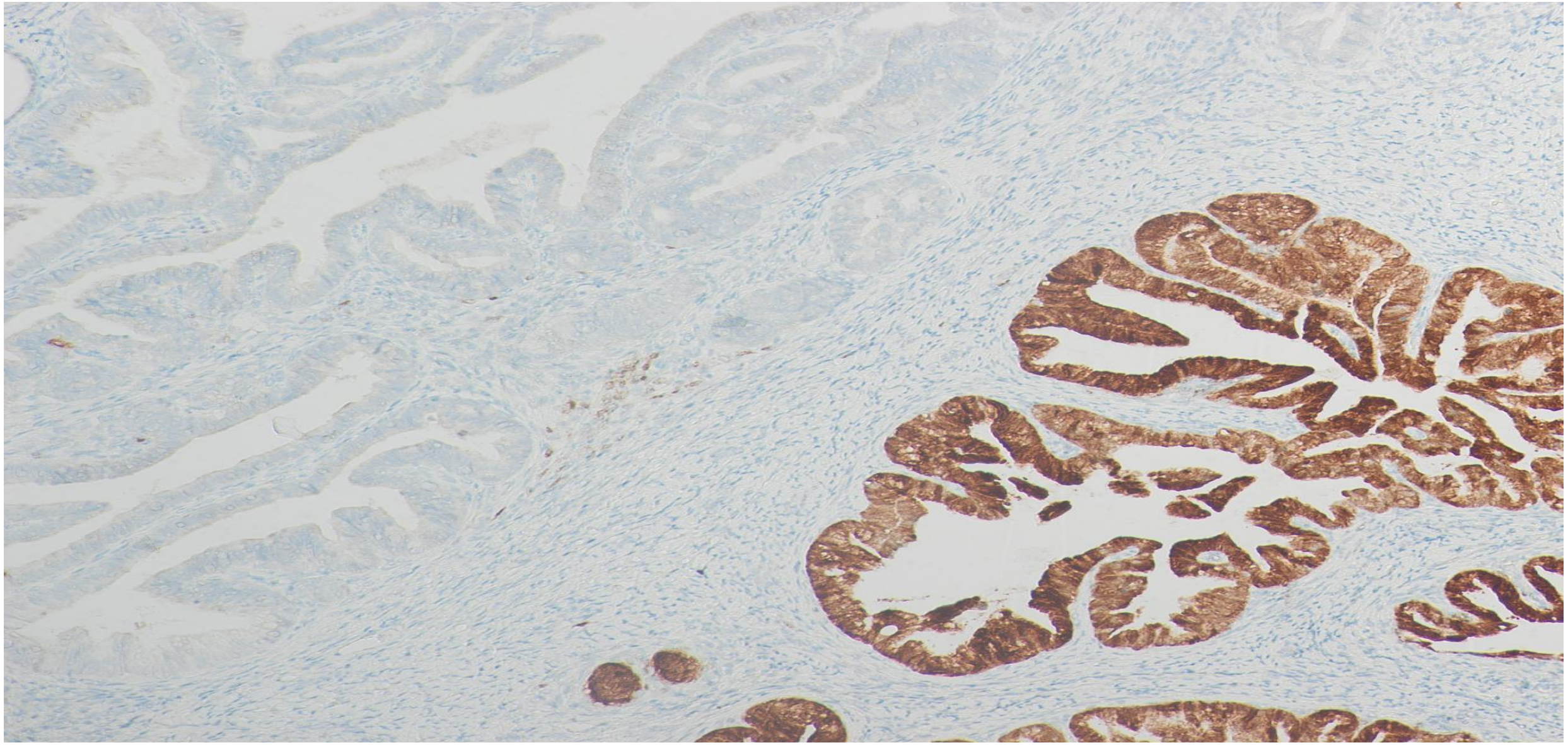

p16 “NEGATIVE” HPV-ASSOCIATED ADENOCARCINOMA

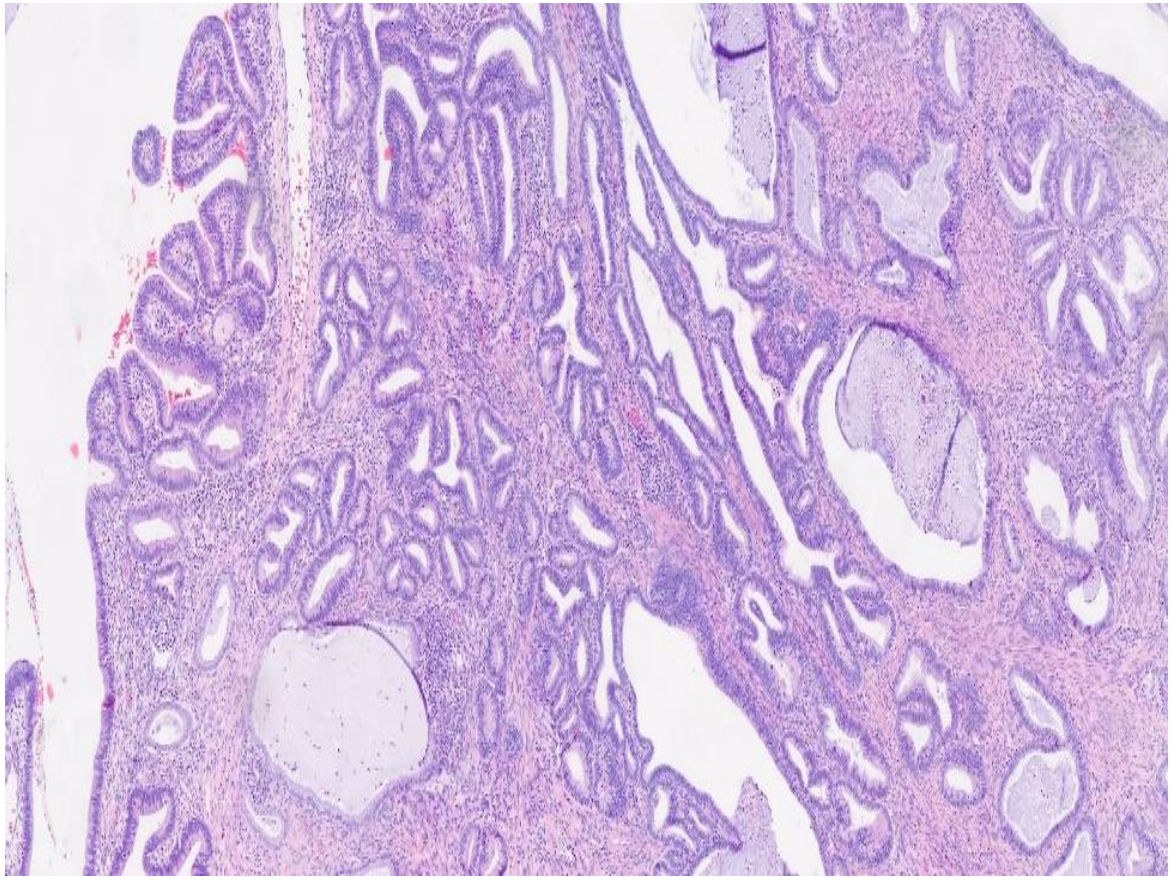

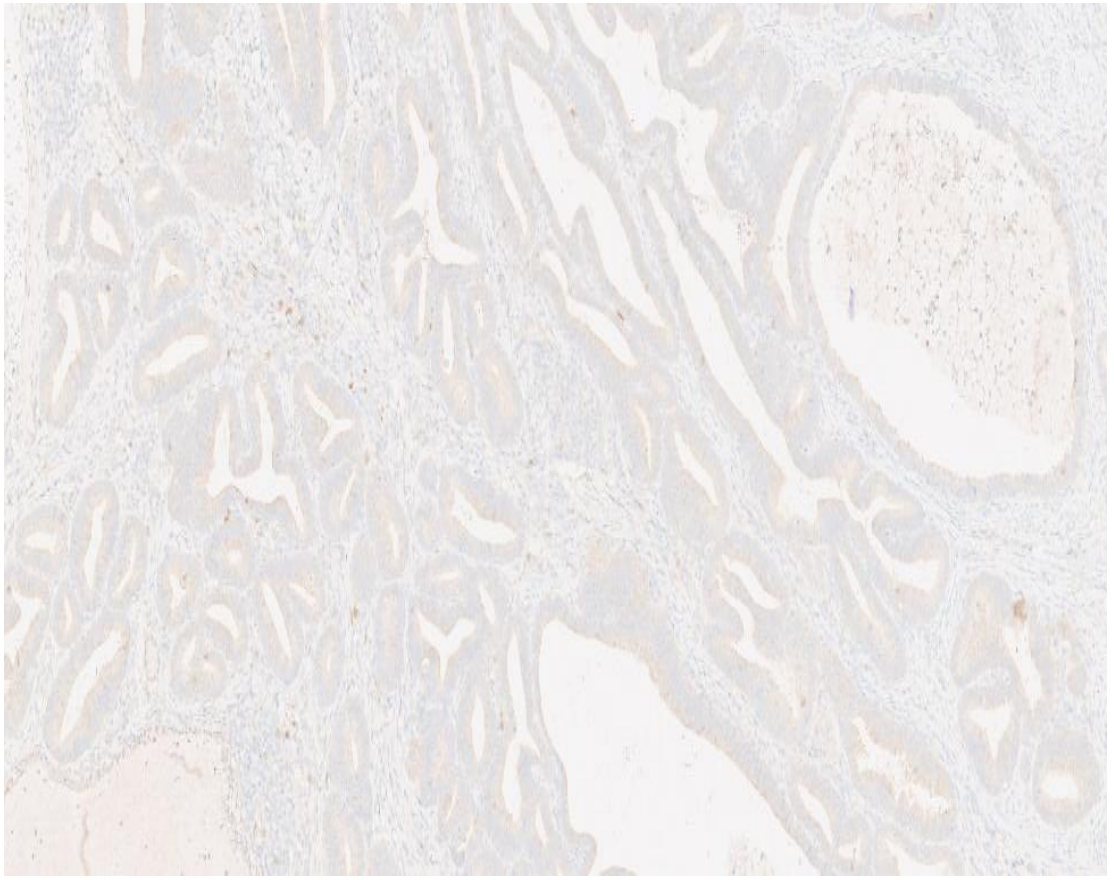

SQUAMOUS CELL CARCINOMA, HPV-INDEPENDENT: ESSENTIAL AND DESIRABLE CRITERIA

Essential diagnostic criteria: invasive carcinoma with squamous differentiation and **negative/ focal p16 immunohistochemistry and negative HPV testing**

Need negative p16 and HPV testing to take account of fact that occasional cases of HPVA SCC are p16 negative

Suggested that there may be *TP53* wild-type and mutation-type examples (like in vulva)

Could recommend to do p53 staining as well as p16 in all HPV-independent cervical SCCs

PMID 40010435

MODERN PATHOLOGY

USCAP UNITED STATES AND CANADIAN ACADEMY OF PATHOLOGY
Advancing Pathology Together

Journal homepage: https://modernpathology.org/

Research Article

Cervical Human Papillomavirus—Independent Squamous Cell Carcinoma: A Clinicopathological Review and Outcomes Analysis Compared With Human Papillomavirus—Associated Squamous Cell Carcinoma

Simona Stolnicu[a,*], Natalia Rakislova[b,c,d], Alba Morató[b,d], Douglas Allison[e], Nuria Carreras Dieguez[b], Lien Hoang[f], Andrei Patrichi[a], Antonio Ieni[g], Ana Felix[h], Anna Pesci[i], Claudia Mateoiu[j], Esther Guerra[k], Rouba Ali-Fehmi[l,m], Mira Kheil[l,m], Andres Roma[n], Oluwole Fadare[n], Gulisa Turashvili[o,p], Esther Oliva[p], Kyle M. Devins[p], Carlos Parra-Herran[q], Ahmet Erbagci[r], Gozde Kir[r], Anne Mills[s], Sigrid Regauer[t], Jaume Ordi[b,c,d], Gian Franco Zannoni[u], Lars-Christian Horn[v], W Glenn McCluggage[w], Robert A. Soslow[x]

HPV-INDEPENDENT CERVICAL SCC

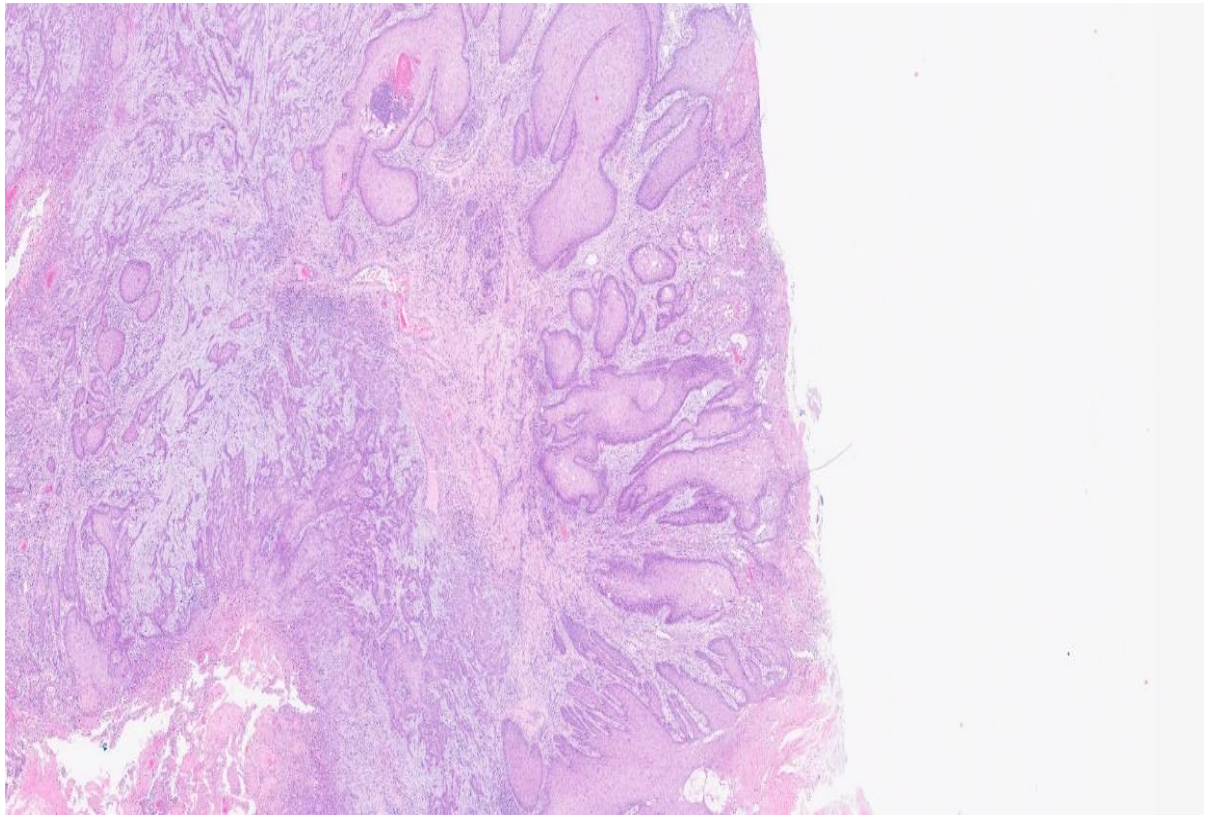

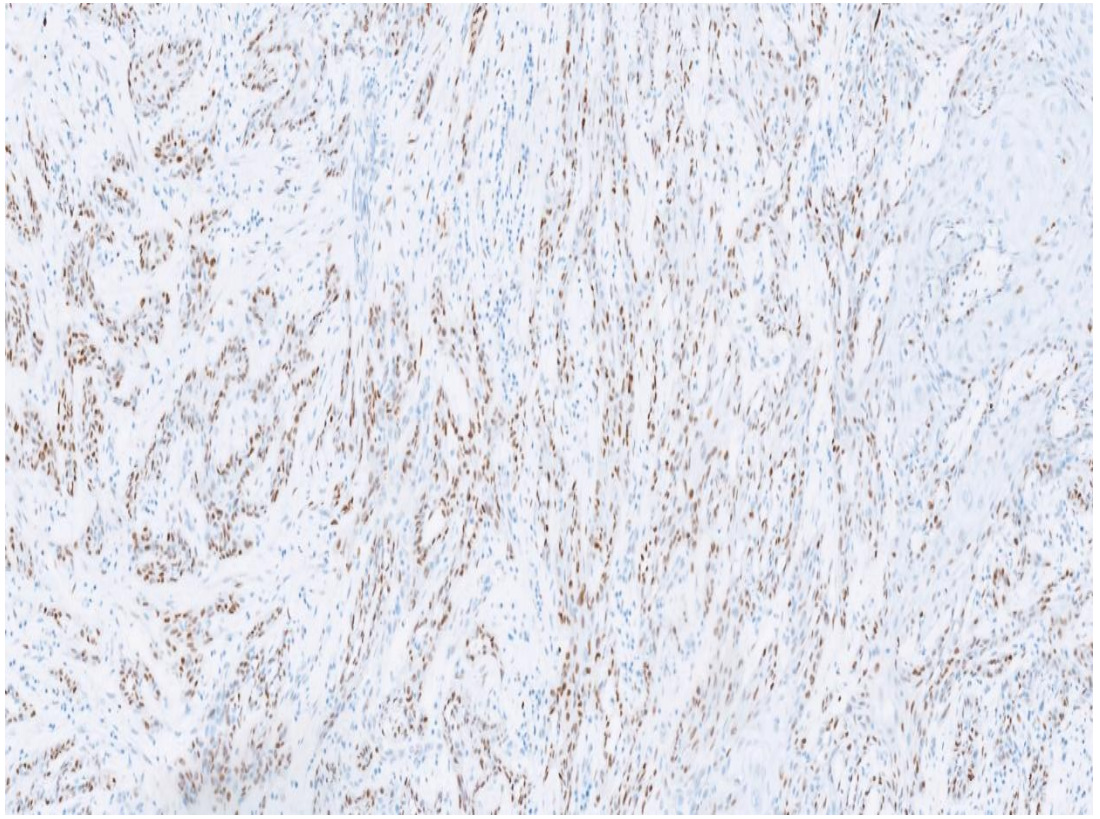

p53 wild-type

HPV-INDEPENDENT CERVICAL SCC

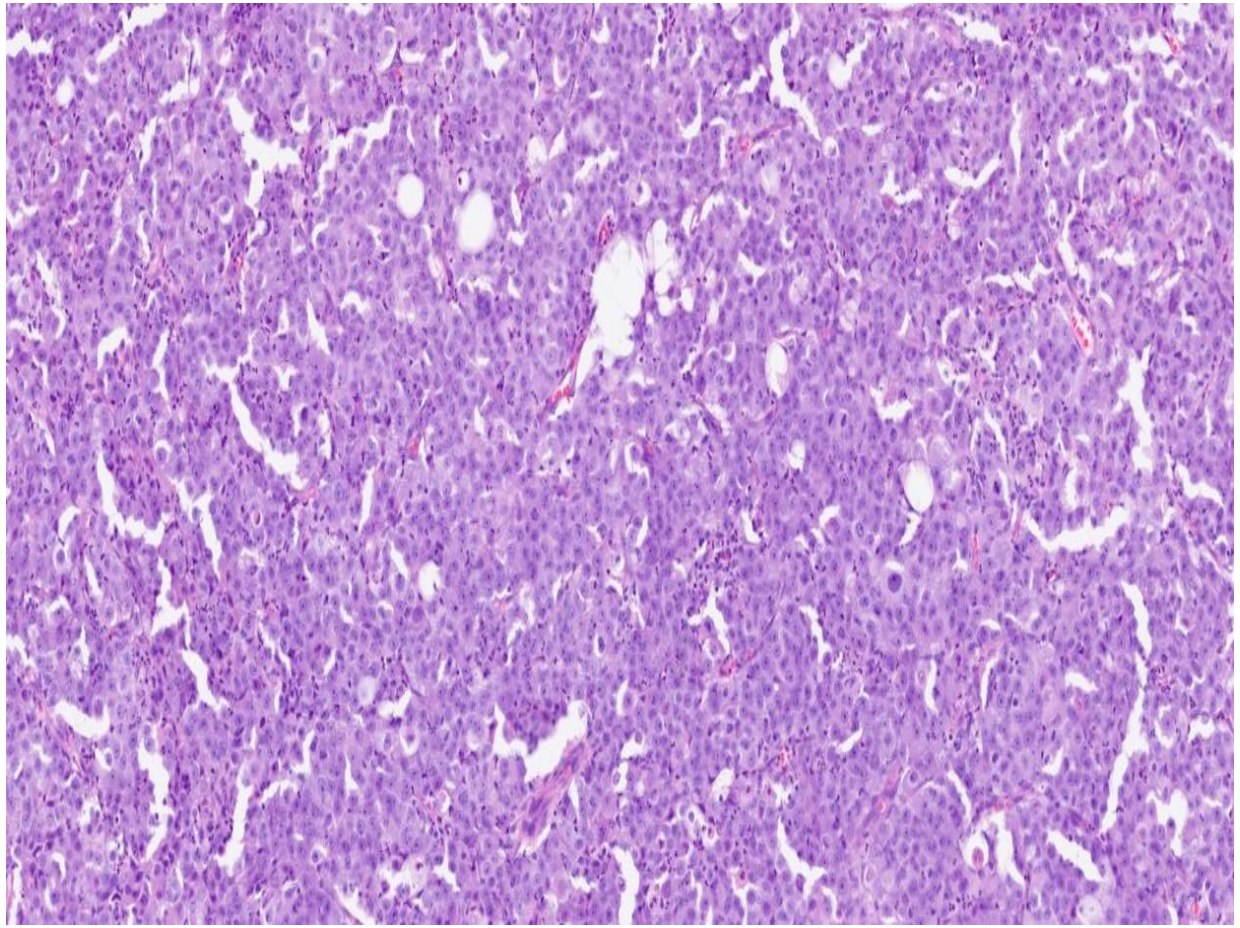

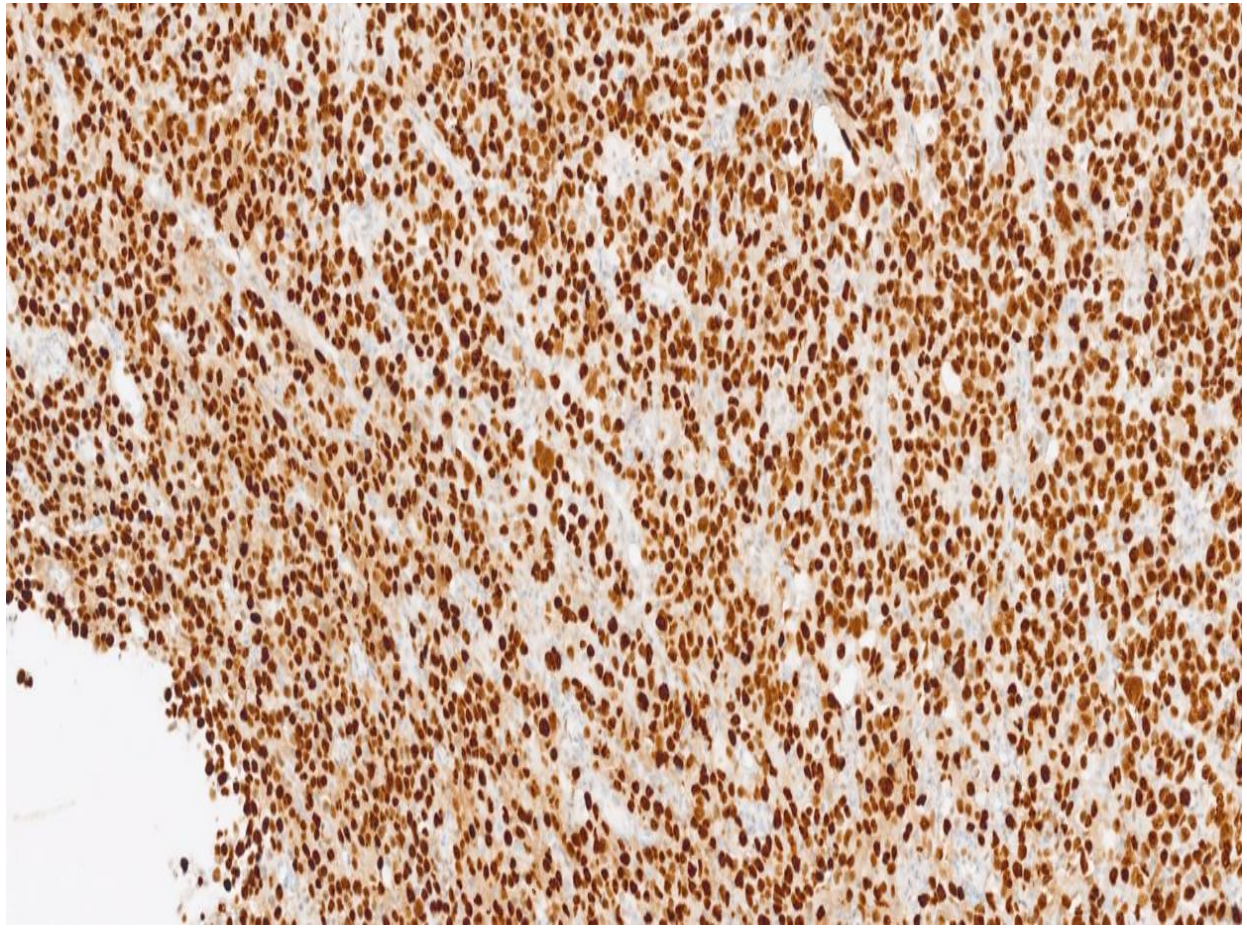

p53 mutation-type

SQUAMOUS CELL CARCINOMA, NOS

Cervical squamous cell carcinoma should be classified according to HPV status by ancillary testing (such as p16 immunohistochemistry, and HPV testing by in situ hybridization or other molecular techniques) since the morphological features are not predictive of HPV association {37638549}. In cases where ancillary testing of the tumour tissue is not feasible, the p16 results are inconclusive, or HPV status from testing of a proximate cervical cytology or tissue sample is not available, the designation squamous cell carcinoma, not otherwise specified (NOS) is used. It is important to note that the majority of these tumours are likely to be HPV-associated, reflecting the central role of HPV in the pathogenesis of cervical squamous cell cancer. {37702216; 25410654; 30911077}.

CERVICAL SQUAMOUS CELL CARCINOMAS IN GENERAL

- Discussed that no validated grading system as of yet exists, although discusses some recent proposals
- Grading recommendations (not to grade) in line with ICCR recommendations

ADENOSQUAMOUS CARCINOMA

- Now HPV-associated and HPV-independent
- Mucoepidermoid carcinoma gone (even though some reported cervical cases with *CRTC1-MAML2* fusion)
- Some previously reported cases might represent invasive stratified mucin producing carcinomas
- Need p16 and/ or HPV testing
- HPV-independent cases often have gastric-type glandular component

HPV-INDEPENDENT ADENOSQUAMOUS CARCINOMA

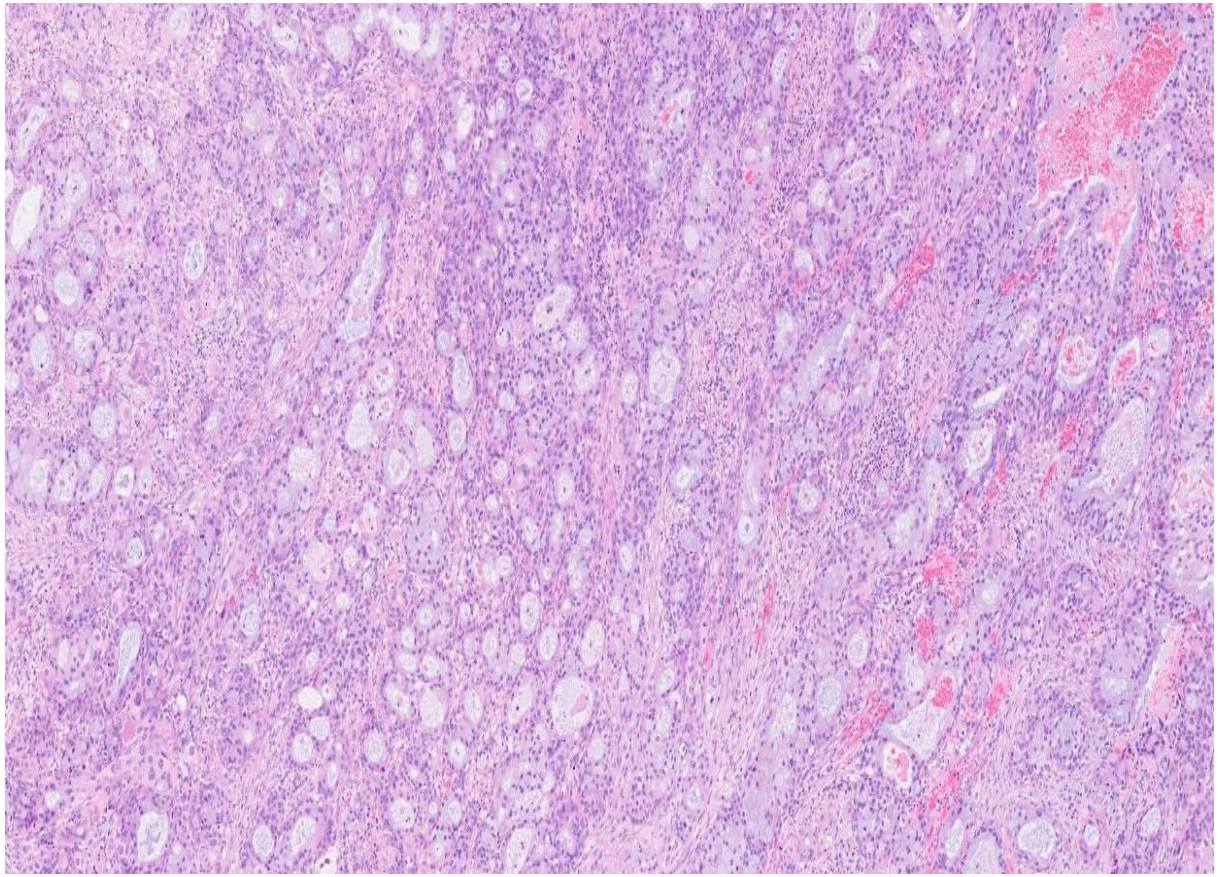

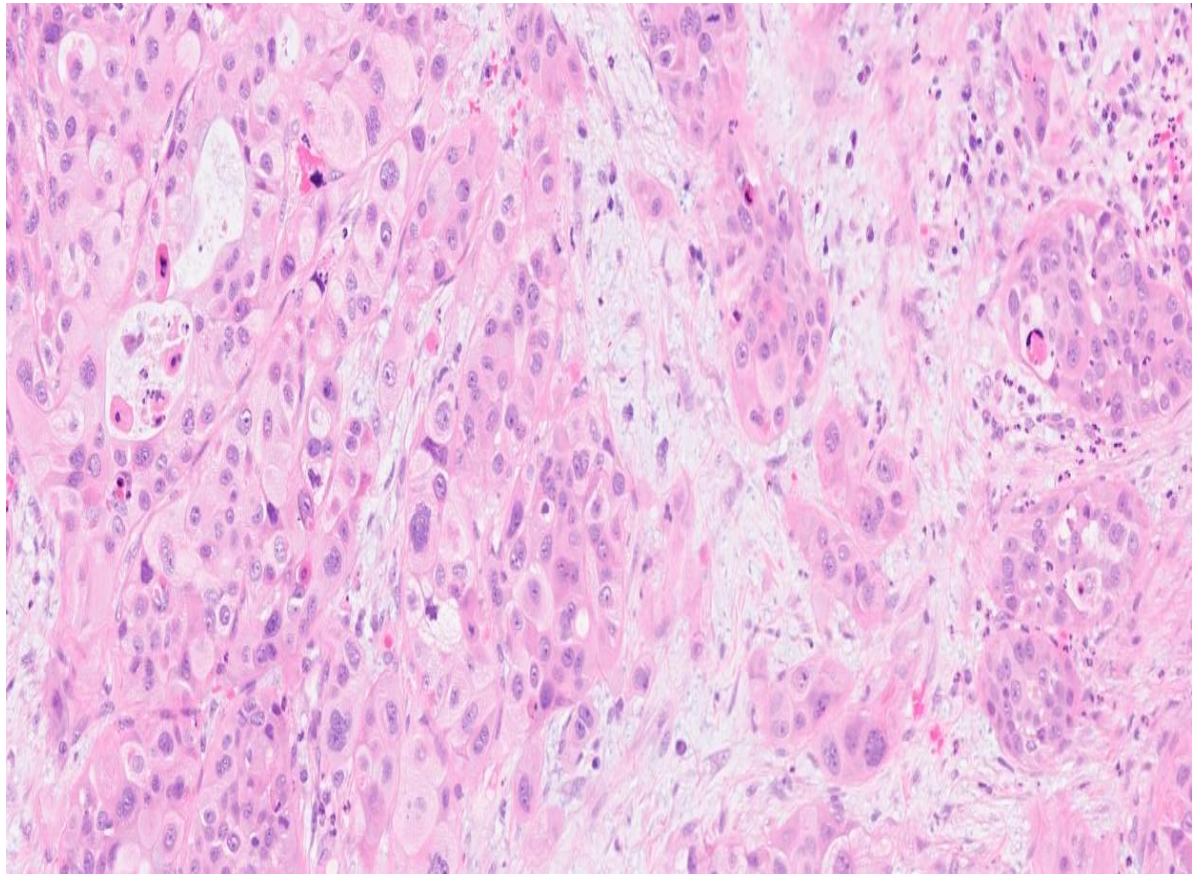

HPV-INDEPENDENT ADENOSQUAMOUS CARCINOMA

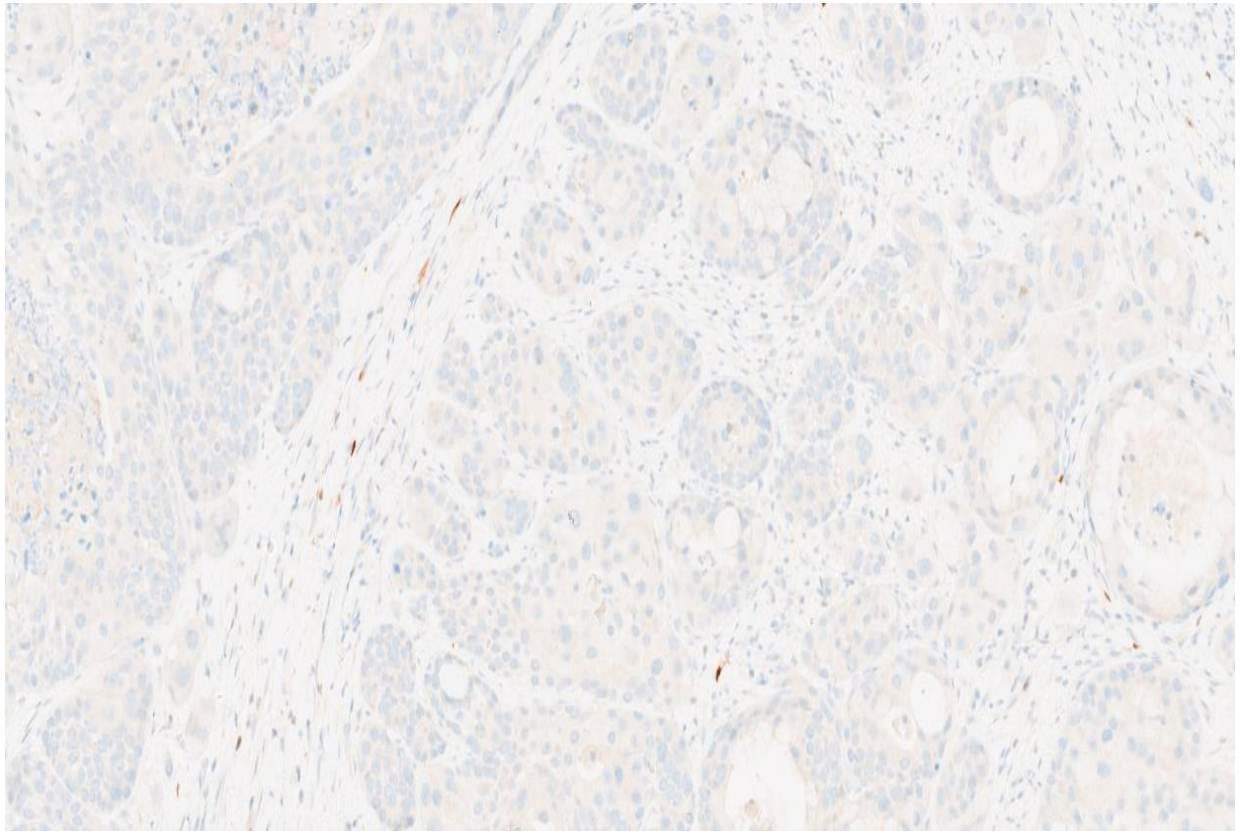

p16

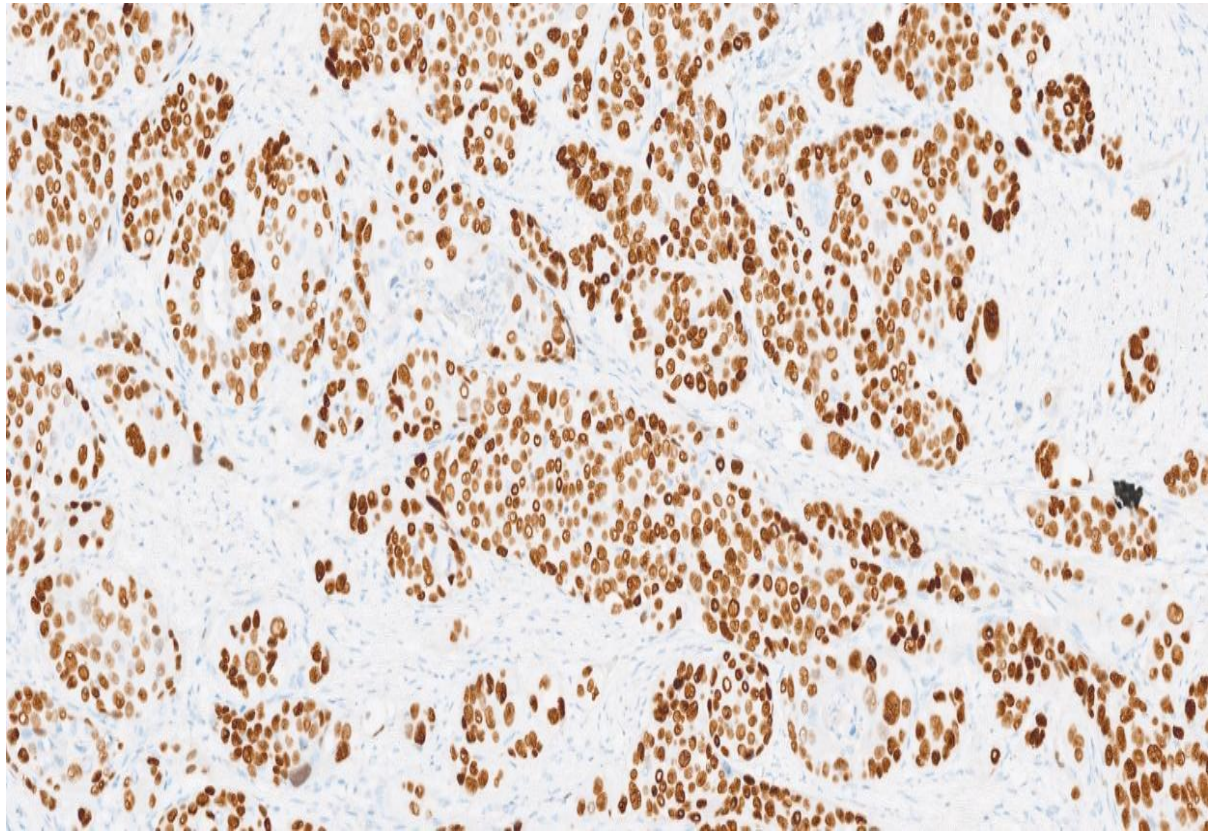

p63

NEUROENDOCRINE NEOPLASMS

- Brought back into cervical chapter; previously all neuroendocrine neoplasms were discussed in same chapter (except ovary)
- Terms neuroendocrine tumour (NET) and neuroendocrine carcinoma (NEC) used
- NET (grade 1 or 2; rather than carcinoid and atypical carcinoid); no grade 3 NET; no known value of Ki67 proliferation indices; NETs are extremely rare
- Term mixed neuroendocrine and non-neuroendocrine neoplasm (MiNEN)/ combined small cell or large cell neuroendocrine carcinoma both used
- Can be HPV-associated or HPV-independent

PMID 35075048

International Journal of Gynecological Pathology
00:1–10, Lippincott Williams & Wilkins, Baltimore
Copyright © 2022 by the International Society of Gynecological Pathologists

Original Article

Low-grade Neuroendocrine Tumor of The Cervix: Report of 3 Cases of a Rare Neoplasm With Review of The Literature

Shatrughan Sah, F.R.C.Path., Pallavi V. Borkar, M.D., Catherine Wight, F.R.C.Path., Paul Kelly, F.R.C.Path., Kay J. Park, M.D., and W. Glenn McCluggage, F.R.C.Path.

LOW-GRADE NEUROENDOCRINE TUMOUR (NET) OF THE CERVIX: REPORT OF THREE CASES OF A RARE NEOPLASM WITH REVIEW OF THE LITERATURE

- PMID 35075048
- Case 1- pure grade 2 NET with nodal metastasis (FIGO stage IIIC1); HPV-independent
- Case 2- grade 1 NET associated with HSIL, AIS and HPV-associated adenocarcinoma (FIGO stage IA1); HPV-associated
- Case 3- chemoradiation for FIGO stage IIIC1 (radiology) NEC; salvage hysterectomy residual tumour was grade 1 NET; HPV-associated; may be maturation effect secondary to chemoradiation

CERVICAL LOW-GRADE NET (HPV-INDEPENDENT)

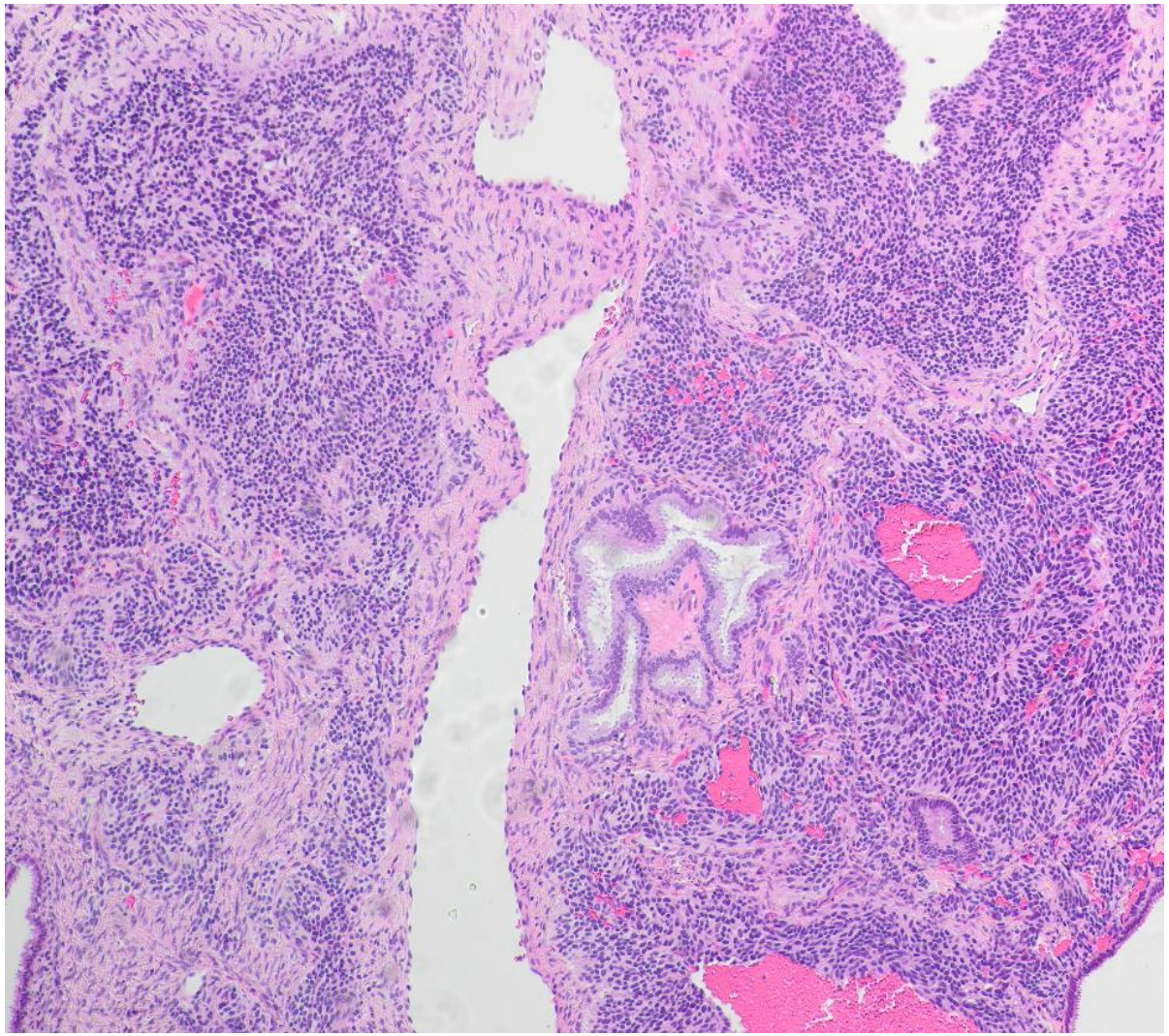

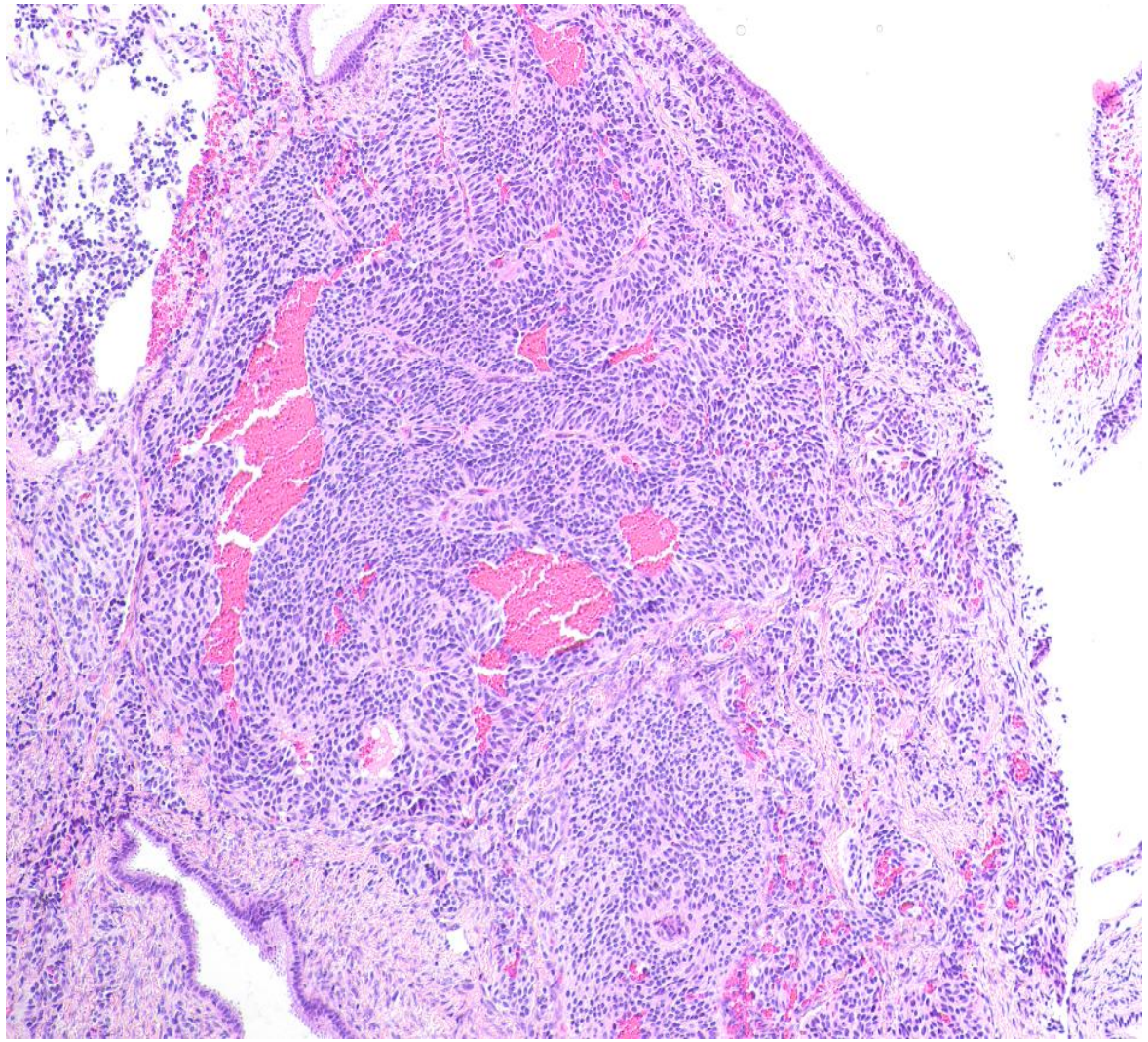

CERVICAL LOW-GRADE NET (HPV-INDEPENDENT)

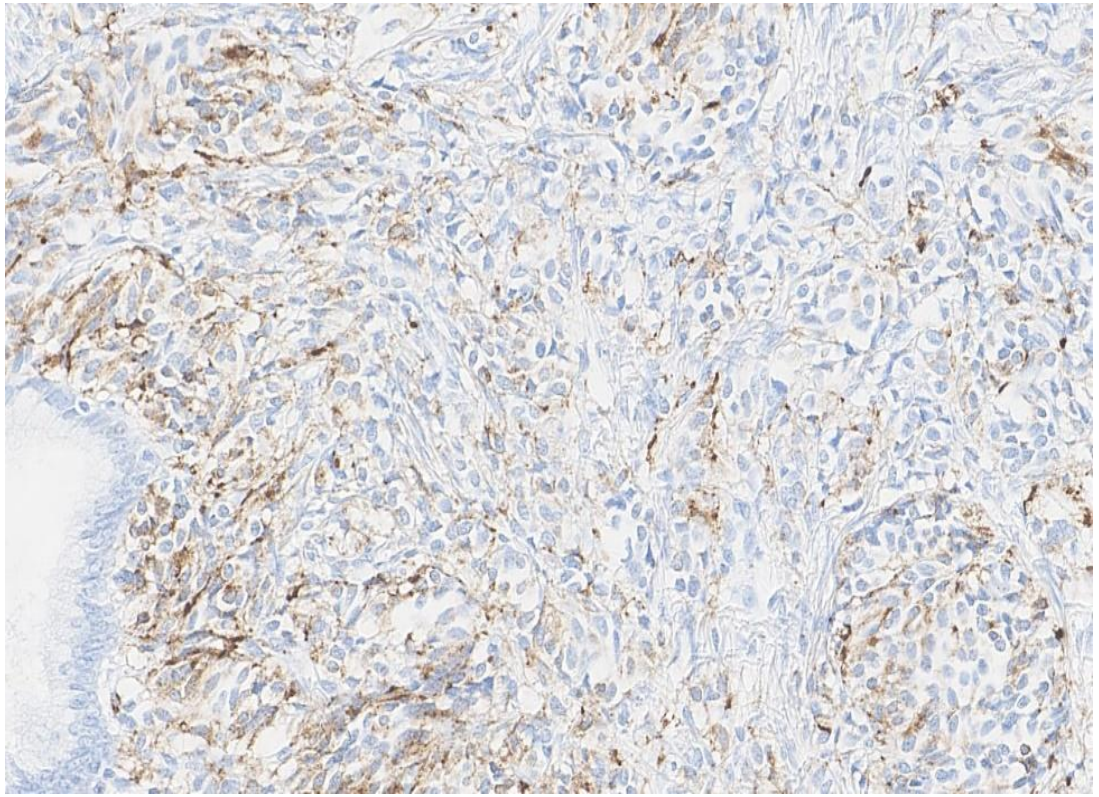

p16

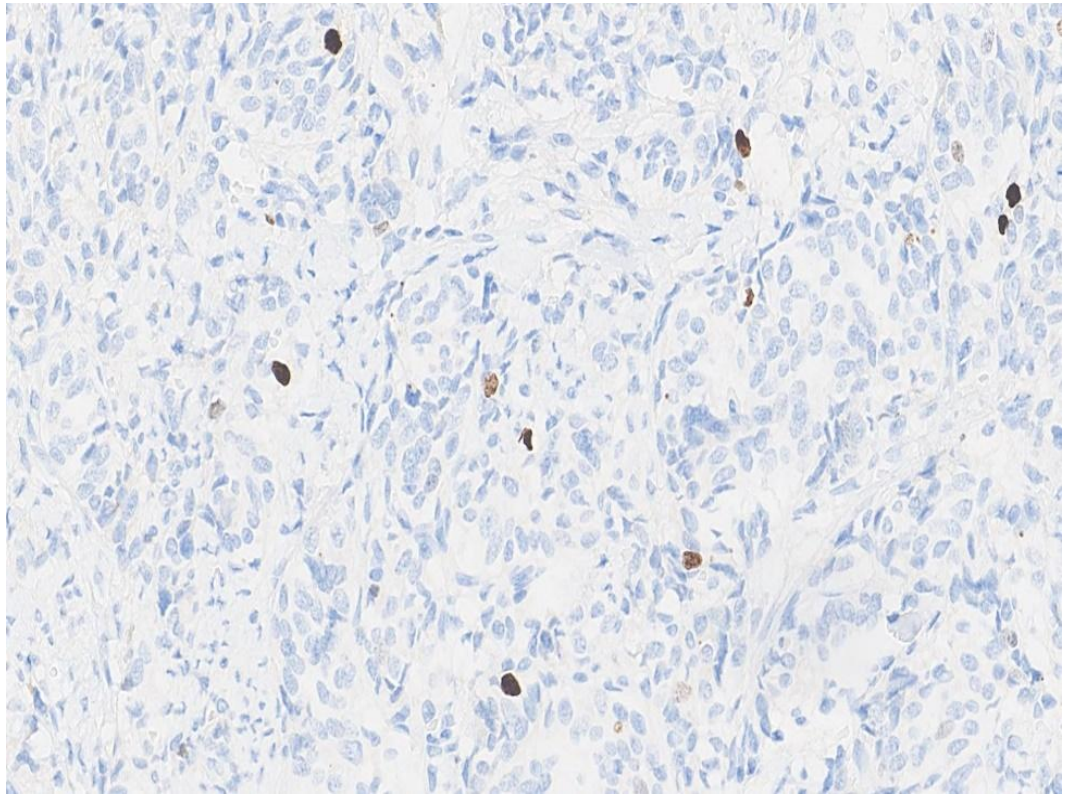

Ki67/ MIB1

CERVICAL LOW-GRADE NET (HPV-INDEPENDENT)

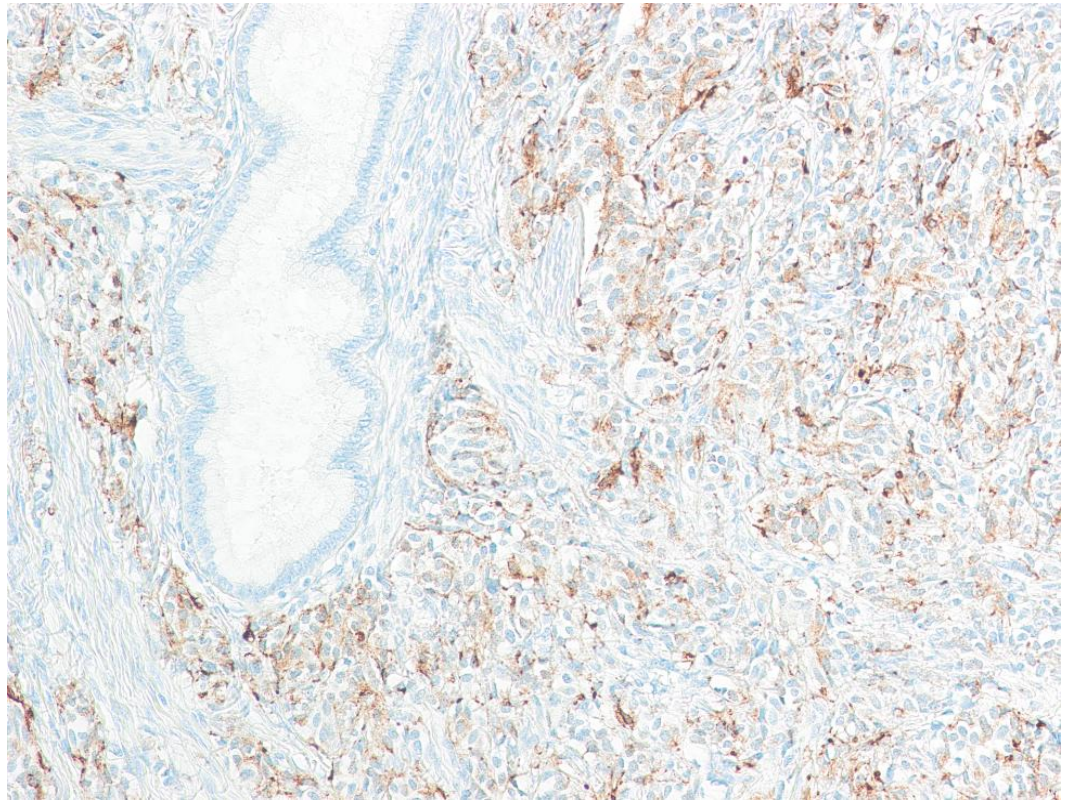

chromogranin

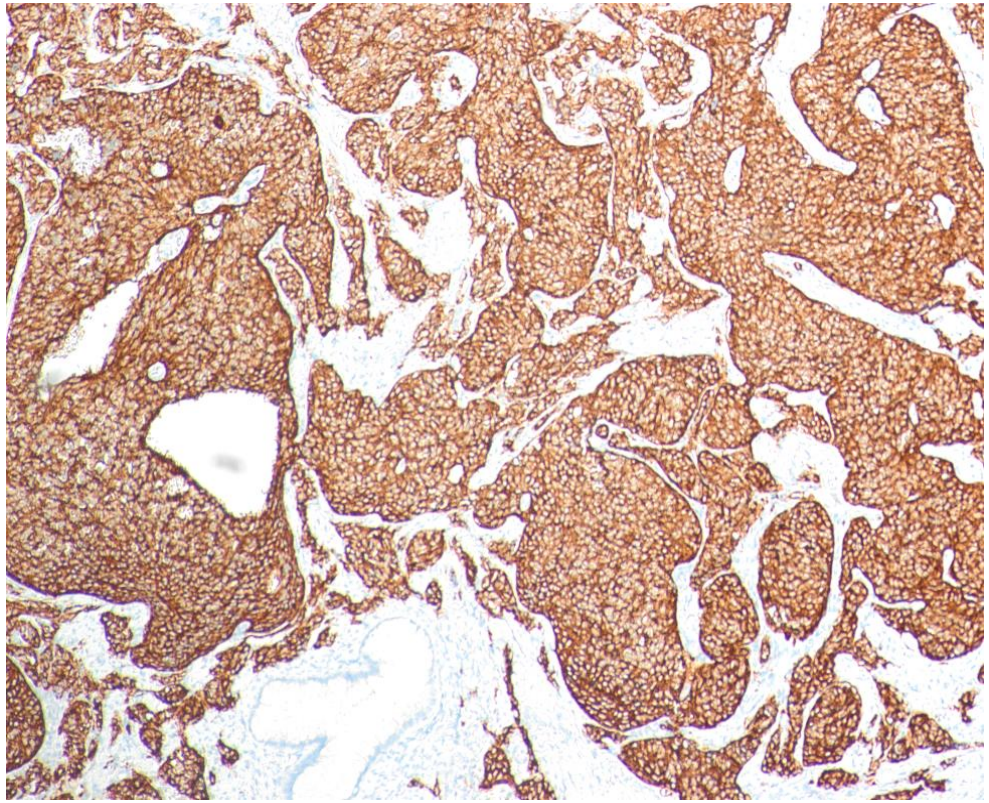

synaptophysin

VAGINA CHAPTER

3.0: Tumours of the vagina

- **3.1: Tumours of the vagina: Introduction**
- **3.2: Epithelial tumours**
  - 3.2.1: Squamous cell tumours and precursors
    - 3.2.1.1: Squamous intraepithelial lesions
    - 3.2.1.2: Squamous cell carcinoma, HPV-associated
    - 3.2.1.3: Squamous cell carcinoma, HPV-independent
    - 3.2.1.4: Squamous cell carcinoma NOS
  - 3.2.2: Benign glandular lesions
    - 3.2.2.1: Villous adenoma
  - 3.2.3: Other epithelial tumours
    - 3.2.3.1: Mixed tumour
    - 3.2.3.2: Adenocarcinoma of Skene gland origin
    - 3.2.3.3: Adenocarcinoma, intestinal-type
- **3.3: Miscellaneous tumours**
    - 3.3.0.1: Mullerian papilloma
    - 3.3.0.2: Fibroepithelial stromal polyp

VAGINA CHAPTER- CHANGES FROM 5TH EDITION

- All non-neoplastic entities gone (lot of squamous and glandular lesions gone)
- Benign neoplasms like villous adenoma, mixed tumour, Mullerian papilloma and fibroepithelial stromal polyp (FESP) retained in this chapter
- Most vaginal adenocarcinomas and adenosquamous carcinoma covered in cervical write-ups (exceptions are adenocarcinoma, intestinal-type and adenocarcinoma of Skene gland origin)
- Same as cervix and vulva: SCCs (HPV-associated; HPV-independent; NOS)
- Unlike in cervix and vulva- no category of VAIN, HPV-independent
- Removal of adenoid basal carcinoma

NON-EPITHELIAL OVARY CHAPTER

9.0: Non-epithelial tumors of the ovary

9.1: Non-epithelial tumors of the ovary: Introduction

9.2: Sex cord-stromal tumours

9.2.1: Pure stromal tumours
- 9.2.1.1: Ovarian fibroma
- 9.2.1.2: Thecoma
- 9.2.1.3: Luteinized thecoma associated with sclerosing peritonitis
- 9.2.1.4: Sclerosing stromal tumour
- 9.2.1.5: Microcystic stromal tumour
- 9.2.1.6: Signet-ring stromal tumour
- 9.2.1.7: Leydig cell tumour
- 9.2.1.8: Steroid cell tumour

9.2.2: Pure sex cord tumours
- 9.2.2.1: Adult granulosa cell tumour
- 9.2.2.2: Juvenile granulosa cell tumour
- 9.2.2.3: Sertoli cell tumour
- 9.2.2.4: Sex cord tumour with annular tubules

9.2.3: Mixed sex cord-stromal tumours
- 9.2.3.1: Sertoli-Leydig cell tumour
- 9.2.3.2: Sex cord-stromal tumour NOS
- 9.2.3.3: Gynandroblastoma

9.3: Germ cell tumours
- 9.3.0.1: Dysgerminoma
- 9.3.0.2: Yolk sac tumour
- 9.3.0.3: Embryonal carcinoma
- 9.3.0.4: Non-gestational choriocarcinoma
- 9.3.0.5: Mixed germ cell tumour
- 9.3.0.6: Immature teratoma

9.3.1: Mature teratomas
- 9.3.1.1: Mature teratoma (including somatic neoplasms arising from teratoma)
- 9.3.1.2: Struma ovarii
- 9.3.1.3: Ovarian carcinoid
- 9.3.1.4: Other monodermal teratomas

9.3.2: Germ cell-sex cord-stromal tumours
- 9.3.2.1: Gonadoblastoma
- 9.3.2.2: Mixed germ cell-sex cord-stromal tumour, unclassified

9.4: Miscellaneous tumours
- 9.4.0.1: Ovarian myxoma
- 9.4.0.2: Rete cystadenoma, adenoma
- 9.4.0.3: Solid pseudopapillary tumour
- 9.4.0.4: Small cell carcinoma of the ovary, hypercalcaemic type
- 9.4.0.5: Wilms tumour

NON-EPITHELIAL OVARY CHAPTER- CHANGES FROM 5TH EDITION

- All non-neoplastic entities gone
- Fibrosarcoma removed (most examples reported likely to be mitotically active cellular fibromas, diffuse AGCTs, poorly differentiated SLCTs, other sarcomas)
- Much more discussion of molecular events in sex cord-stromal tumours (introduction and in individual chapters)
- Somatically derived YST (and trophoblastic differentiation in epithelial tumours) discussed in HGSC section; minimal/ no mention in 5th edition Blue Book
- Slight change to germ cell tumour categorisation
- Discussion about well-differentiated SLCTs being unrelated to other types of SLCT
- More guidance about when/ when not to use the term gynandroblastoma
- More discussion about sex cord-stromal tumour (NOS)
- Mesenchymal tumours removed to own chapter (except for myxoma)
- Rete adenocarcinoma removed (still have adenomas and cystadenomas)
- Wolffian tumour removed to broad ligament section

PMID 39492459

REVIEW ARTICLE

Ovarian Sex Cord-Stromal Neoplasms: An Overview of Molecular Events and How to Correlate Morphology With Molecular Findings

Joseph T. Rabban, MD, and W. Glenn McCluggage, FRCPath†*

PMID 39492459

TABLE 1. Molecular Events in Ovarian Sex Cord-Stromal Tumors

Tumor	Recurrent molecular events (useful in diagnosis)	Other molecular events (may be useful in prognostication)	Tumor syndrome
AGCT	*FOXL2* (somatic missense C134W mutation)	*TP53, TERT, CDKN2A, KMT2D, MED12*	None
JGCT	None	*TERT, AKTC, GNAS, KMT2C*	Olliers disease and Maffucci syndrome
Steroid cell tumor	None	Genomic instability in malignant tumors	None
SCTAT	*STK11* mutations in Peutz-Jeghers-associated cases		Peutz-Jeghers syndrome
SLCT	*DICER1* variants (except well-differentiated SLCT). *FOXL2* variants in some tumors in older patients		DICER1 syndrome
Sclerosing stromal tumor	*FHL2 : GLI2* fusion		None
MST	*CTNNB1* and *APC* mutations		Familial adenomatous polyposis

AGCT indicates adult granulosa cell tumor; JGCT, juvenile granulosa cell tumor; MST, microcystic stromal tumor; SCTAT, sex cord tumor with annular tumors; SLCT, Sertoli Leydig cell tumor.

CHANGES TO GERM CELL TERMINOLOGY

9.3: Germ cell tumours

- 9.3.0.1: Dysgerminoma
- 9.3.0.2: Yolk sac tumour
- 9.3.0.3: Embryonal carcinoma
- 9.3.0.4: Non-gestational choriocarcinoma
- 9.3.0.5: Mixed germ cell tumour
- 9.3.0.6: Immature teratoma
- 9.3.1: Mature teratomas
  - 9.3.1.1: Mature teratoma (including somatic neoplasms arising from teratoma)
  - 9.3.1.2: Struma ovarii
  - 9.3.1.3: Ovarian carcinoid
  - 9.3.1.4: Other monodermal teratomas
- 9.3.2: Germ cell-sex cord-stromal tumours
  - 9.3.2.1: Gonadoblastoma
  - 9.3.2.2: Mixed germ cell-sex cord-stromal tumour, unclassified

MINOR CHANGES

- Teratoma-associated mucinous neoplasms with lower intestinal morphology and immunophenotype should be considered somatic tumours arising from teratomas
- Clarification that any immature neural elements in a teratoma qualifies for a diagnosis of immature teratoma

SERTOLI-LEYDIG CELL TUMOUR

- Well-differentiated (very uncommon)
- Moderately-differentiated (previously called intermediate differentiation) (most common)
- Poorly-differentiated
- Retiform (pure or associated with moderately and poorly differentiated tumours)
- With heterologous elements (in moderately differentiated, poorly differentiated, retiform)
- WELL-DIFFERENTIATED USUALLY OCCUR IN PURE FORM; MODERATELY AND POORLY DIFFERENTIATED (WITH OR WITHOUT RETIFORM AND HETEROLOGOUS ELEMENTS) OFTEN PART OF A SPECTRUM

WELL-DIFFERENTIATED SLCT

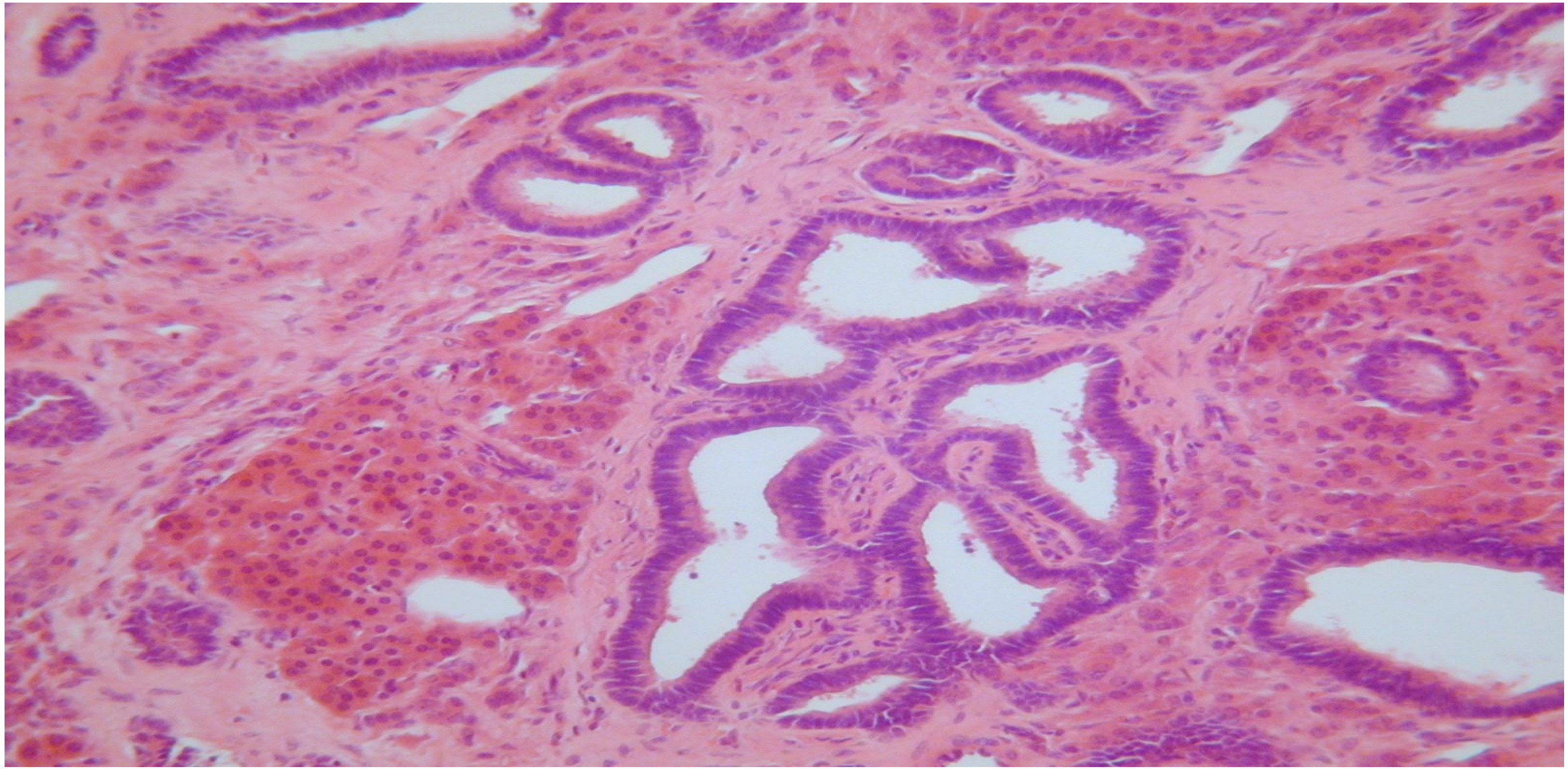

MODERATELY-DIFFERENTIATED SLCT

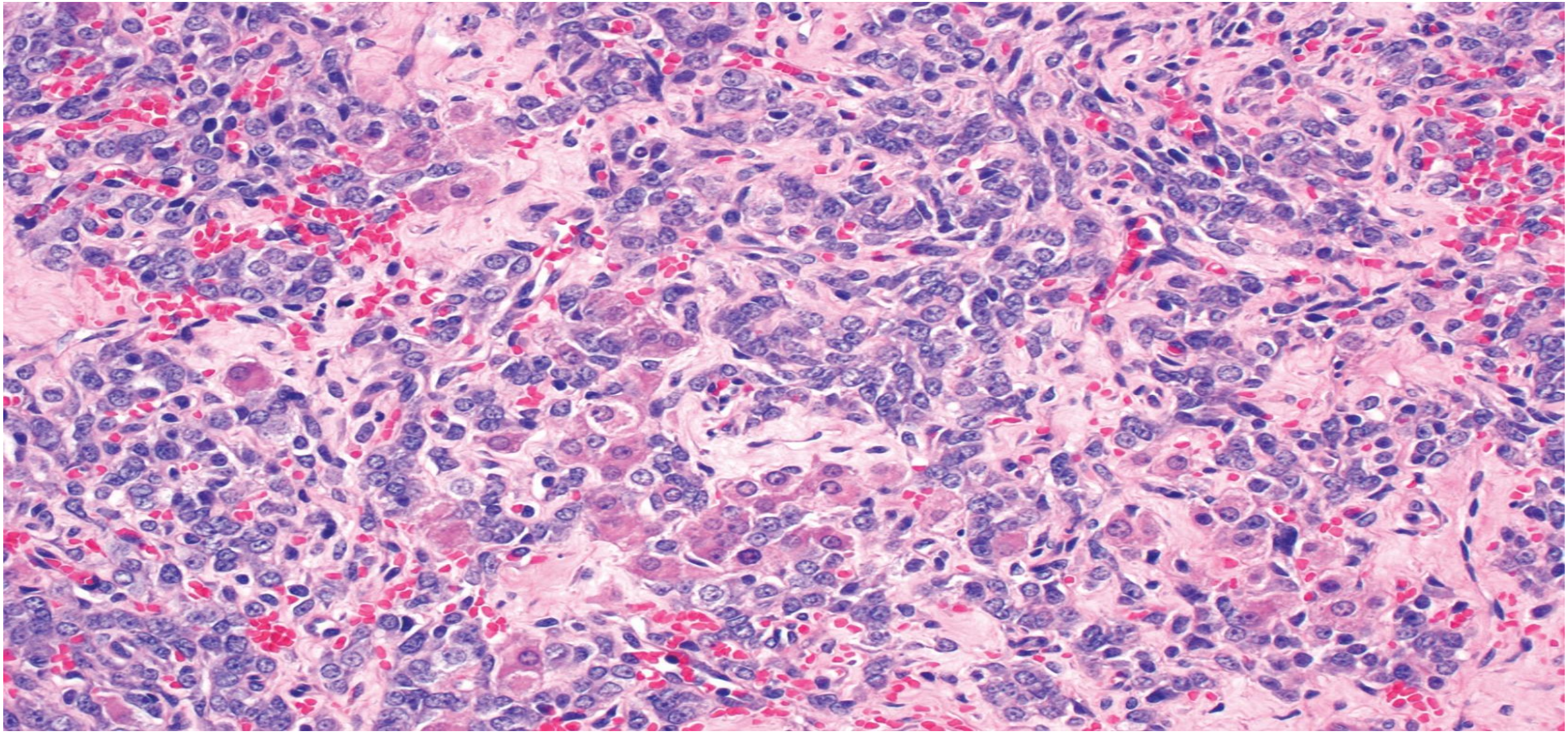

POORLY-DIFFERENTIATED SLCT

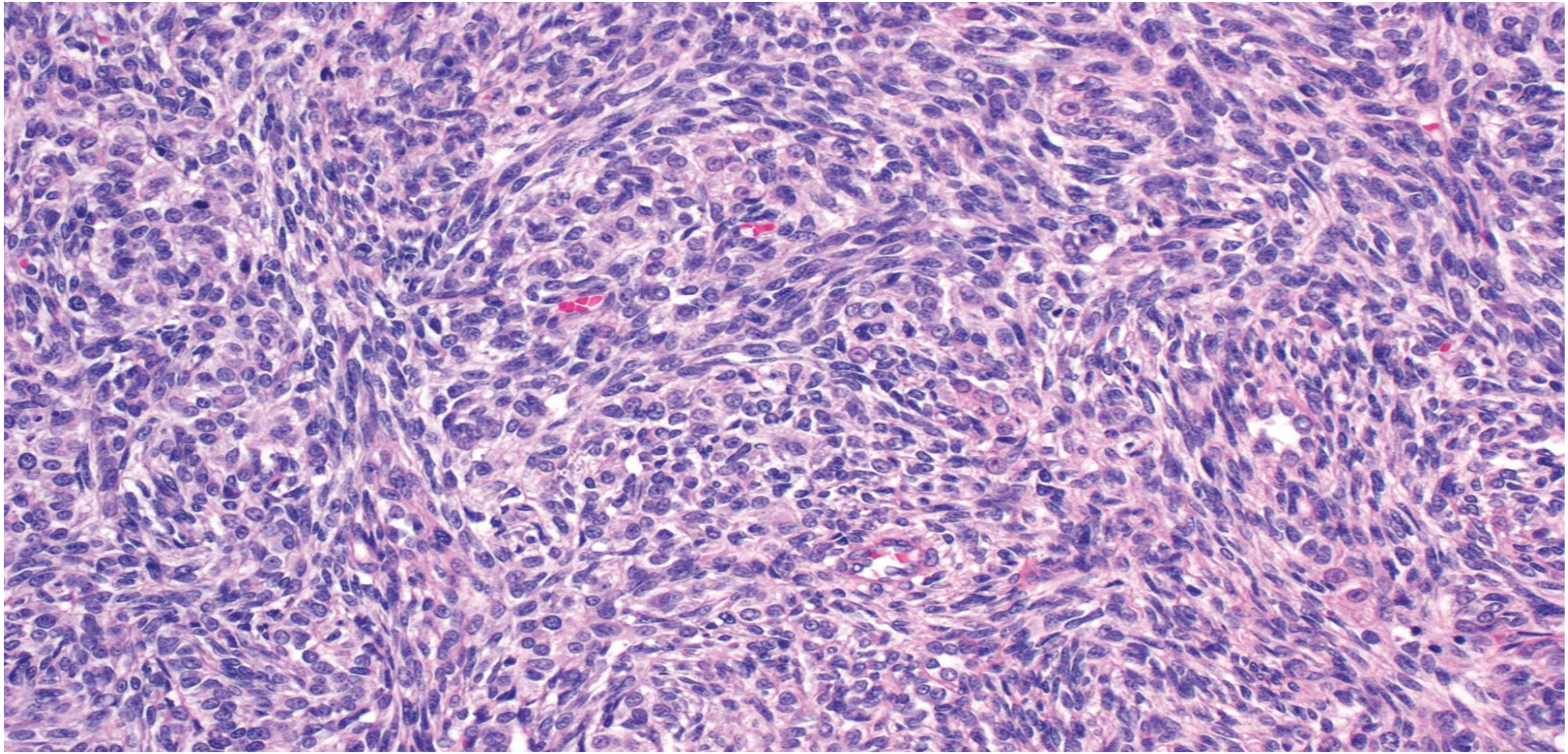

PMID 28654437

ORIGINAL ARTICLE

DICER1 Mutations are Consistently Present in Moderately and Poorly Differentiated Sertoli-Leydig Cell Tumors

Leanne de Kock, B-Tech,† Tatjana Terzic, MD, FRCPC,‡ W. Glenn McCluggage, FRCPath,§*
Colin J.R. Stewart, MBChB, FRCPath, FRCPA,‖ Patricia Shaw, MD,‡
William D. Foulkes, MBBS, PhD,†¶ and Blaise A. Clarke, MBBCh, FRCPC‡*

AJSP 2017;41;1178-1187; PMID 28654437

- All 30 moderately/ poorly differentiated SLCTs had *DICER1* mutations (18 of 26 (69%) had germline mutations- almost certainly overestimate due to referral bias)
- All 4 well differentiated SLCTs were *DICER1* wild-type
- Suggested that well differentiated and moderately/ poorly differentiated SLCT are fundamentally two different tumour types
- Suggested that all patients with SLCTs should undergo *DICER1* germline mutation testing; could also do tumour testing and if positive, refer to genetics
- PATHOLOGIST PLAYS KEY ROLE IN GENETIC REFERRAL IN SLCTs AND OTHER RARE NEOPLASMS

PMID 36583307

ORIGINAL ARTICLE

Well-differentiated Sertoli-Leydig Cell Tumors (SLCTs) Are Not Associated With *DICER1* Pathogenic Variants and Represent a Different Tumor Type to Moderately and Poorly Differentiated SLCTs

W. Glenn McCluggage, FRCPath, Barbara Rivera, PhD,†‡ Anne-Sophie Chong, PhD,†*
Blaise A. Clarke, MD,§ Kris Ann P. Schultz, MD,‖ Louis P. Dehner, MD,¶
*Nairi Tchrakian, FRCPath,# Maria Apellaniz-Ruiz, PhD,** C. Blake Gilks, MD,††*
Friedrich Kommoss, MD,‡‡ Colin J.R. Stewart, FRCPA,§§ and William D. Foulkes, MBBS, PhD‖‖

OTHER THINGS ABOUT SLCT

- Admixture of moderately/ poorly differentiated SLCT and JGCT not to be called gynandroblastoma
- Some discussion of *FOXL2* mutated SLCTs (moderately/ poorly differentiated; older age; no heterologous elements; oestrogenic manifestations): strongly consider morphologically unusual AGCT

GYNANDROBLASTOMA

- mixed sex cord-stromal tumour with “male” and “female” elements
- dropped from WHO 2014 (mistake); reintroduced in WHO 2020
- uncommon neoplasms
- androgenic or oestrogenic manifestations
- some have *FOXL2* mutations and some have *DICER1* mutations
- SOME MAY BE PURE NEOPLASMS WITH MORPHOLOGICAL MIMICRY

TRUE GYNANDROBLASTOMA

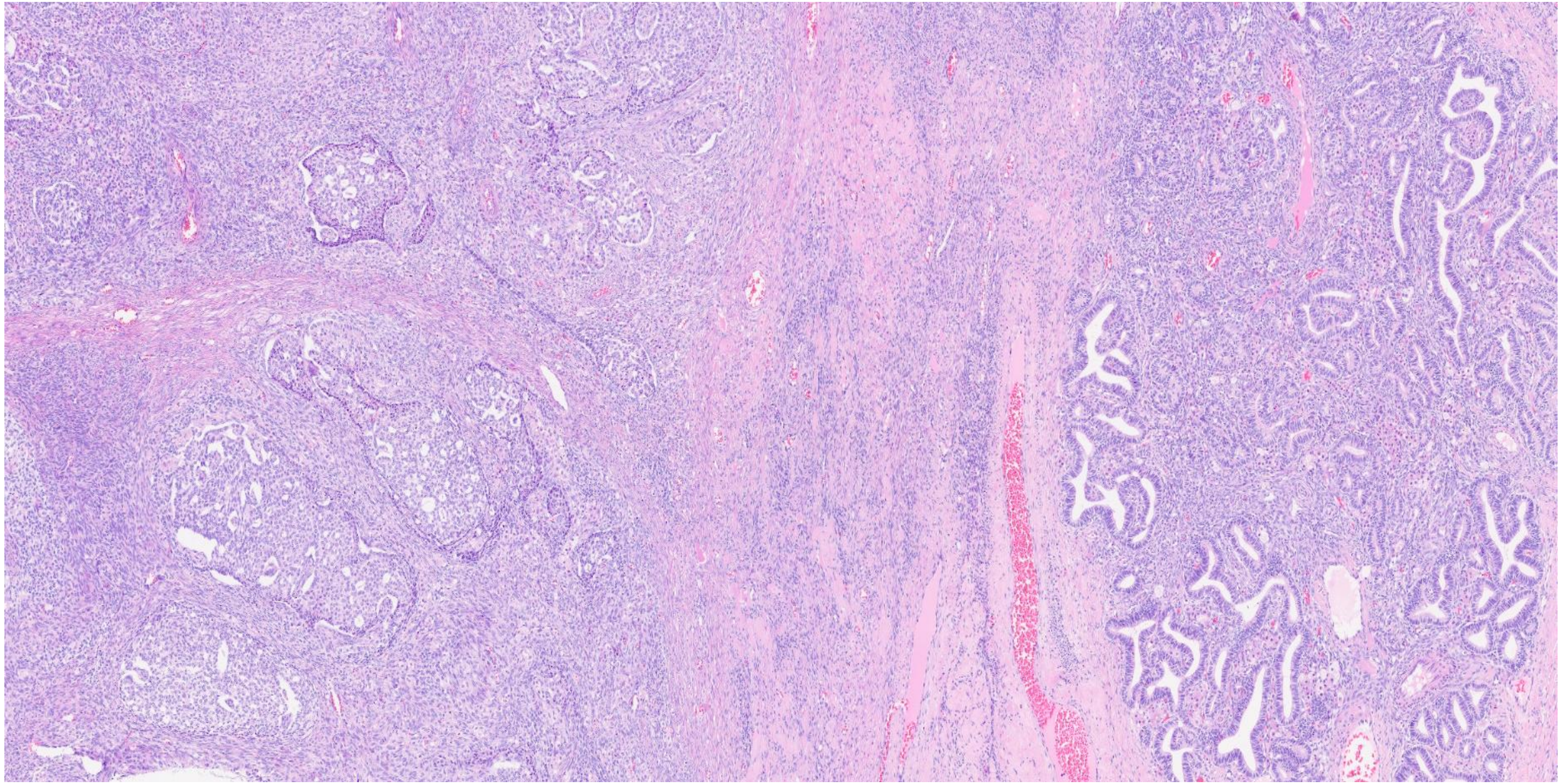

TRUE GYNANDROBLASTOMA

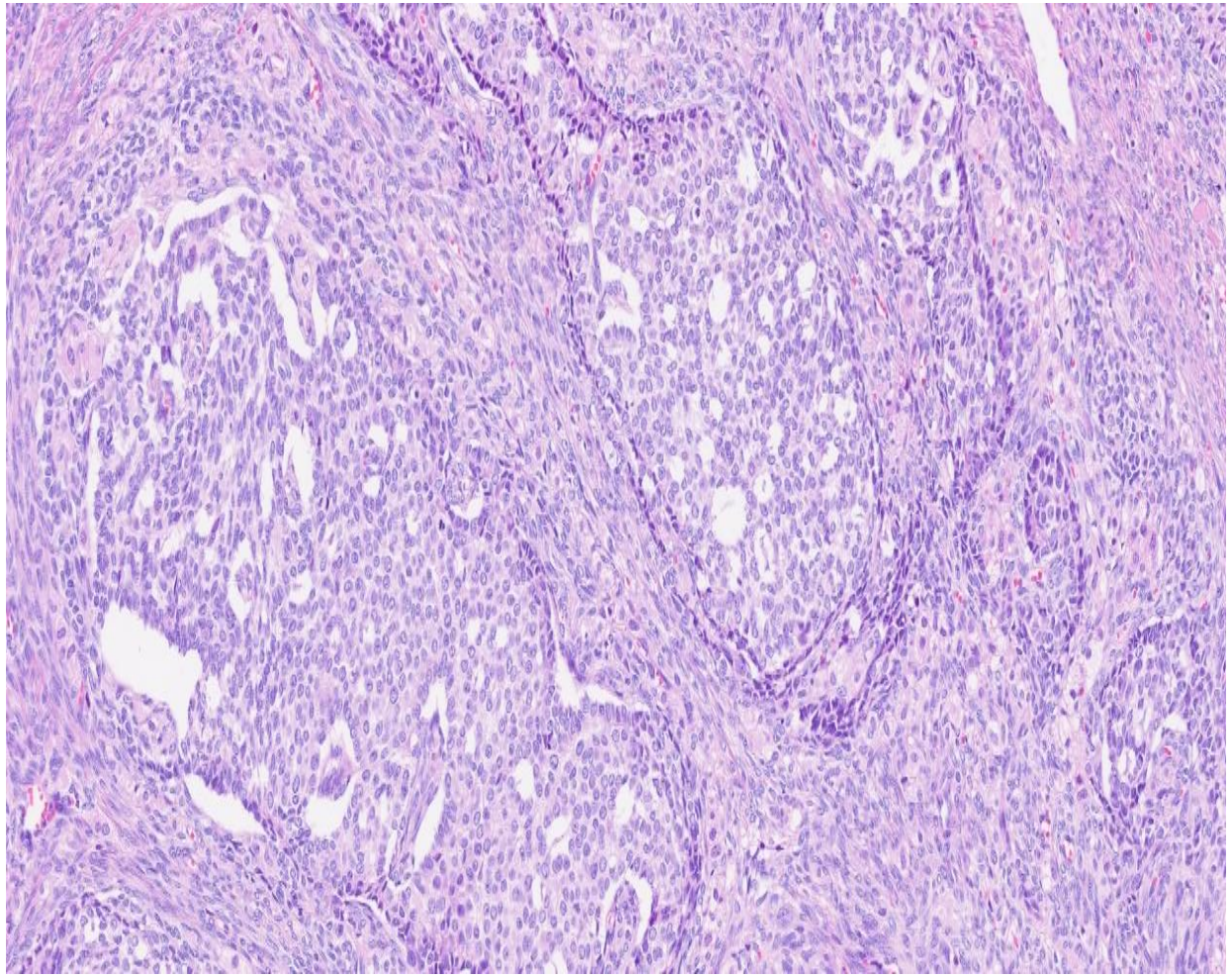

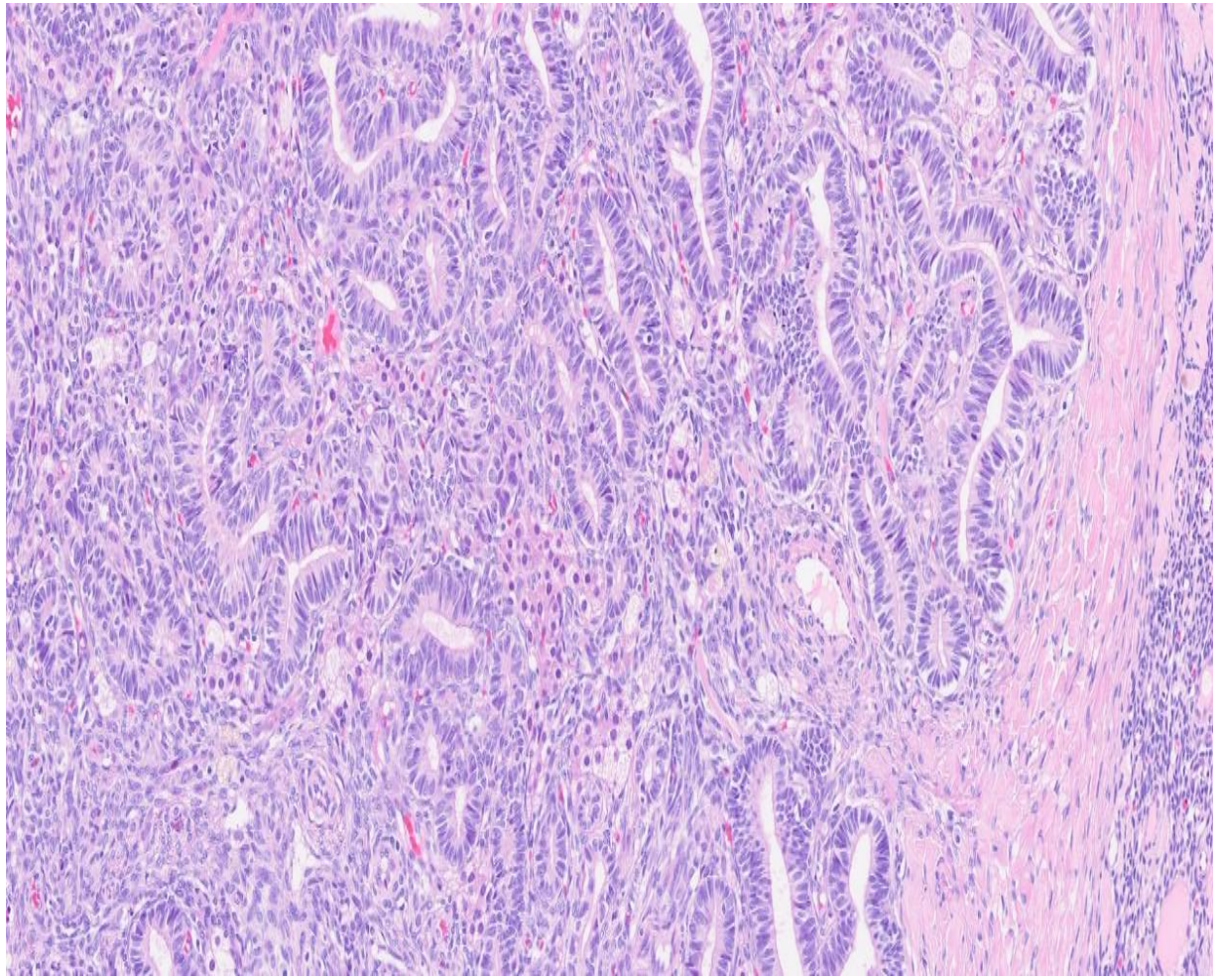

RECOMMENDATIONS IN GYNANDROBLASTOMA SECTION

- Tumours with areas of moderately to poorly differentiated SLCT and JGCT represent SLCT
- Tumours with AGCT and tubular areas (out of context in keeping with Sertoli cell tumour) represent AGCT
- Category of gynandroblastoma is likely to diminish if exclude pure tumours with “morphologic mimicry”

HISTOPATHOLOGY 2018;73;306-313. PMID 29660837

16 cases of gynadroblastoma

DICER1 mutations in 3 cases

All 3 with mutations were moderately/ poorly differentiated SLCT with JGCT; probably best regarded as SLCT with areas resembling JGCT

No *FOXL2* mutations

AREAS IN SLCTs MAY CLOSELY RESEMBLE JGCT- PMID 32815828

Sertoli-Leydig Cell Tumors of the Ovary With Follicular Differentiation Often Resembling Juvenile Granulosa Cell Tumor

A Report of 38 Cases Including Comments on Sex Cord-Stromal Tumors of Mixed Forms (So-called Gynandroblastoma)

Zehra Ordulu, MD and Robert H. Young, MD, FRCPath

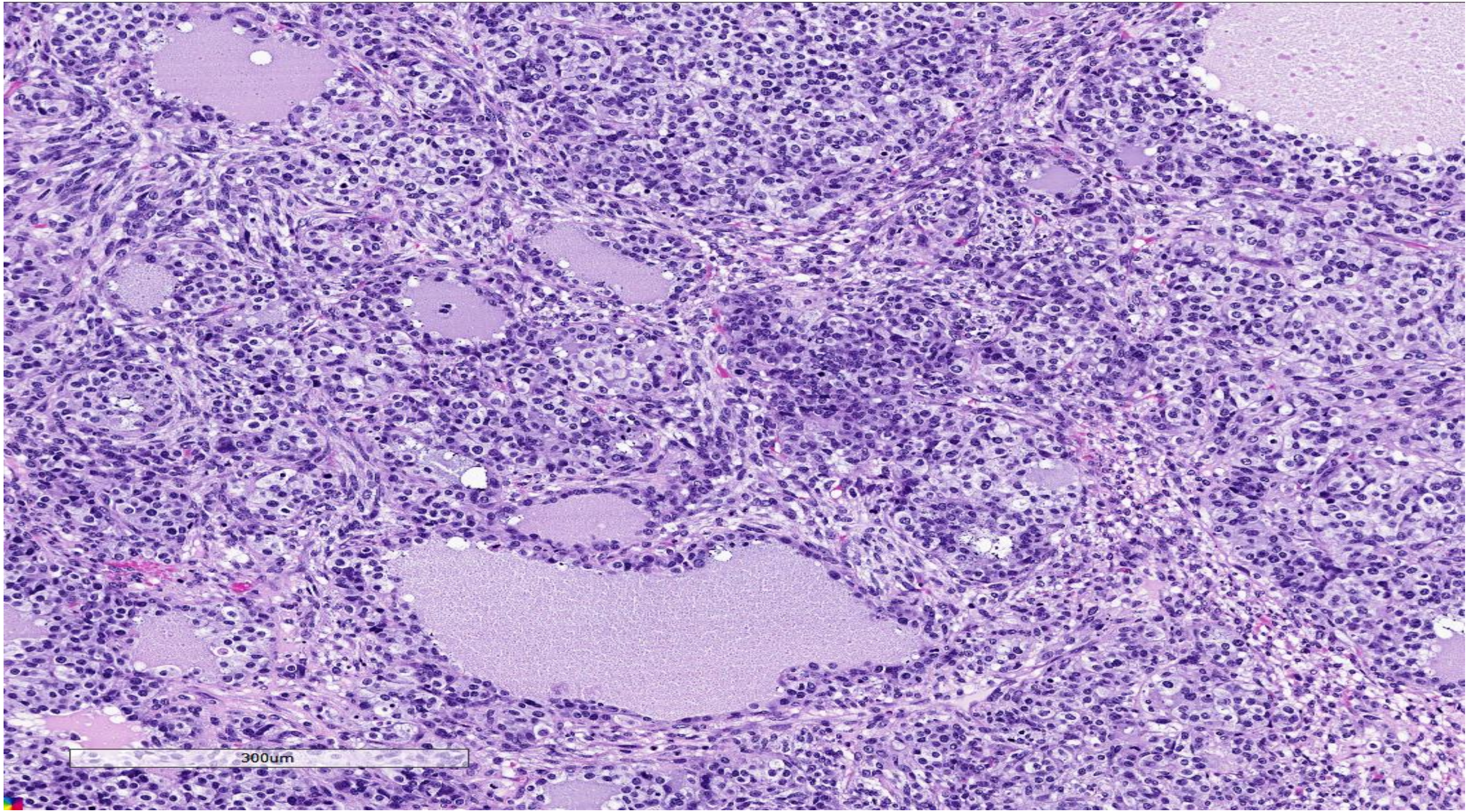
300um

PMID 40326456

ORIGINAL ARTICLE

Adult Granulosa Cell Tumors of the Ovary With Tubular Differentiation

A Report of 80 Examples of an Underemphasized Feature With Clinicopathologic and Genomic Differences From Other Sex Cord-Stromal Tumors

Lauren J. Ray, MD, Robert H. Young, MD, Mark F. Sabbagh, MD, PhD, Adam S. Fisch, MD, PhD, Esther Oliva, MD, and Kyle M. Devins, MD

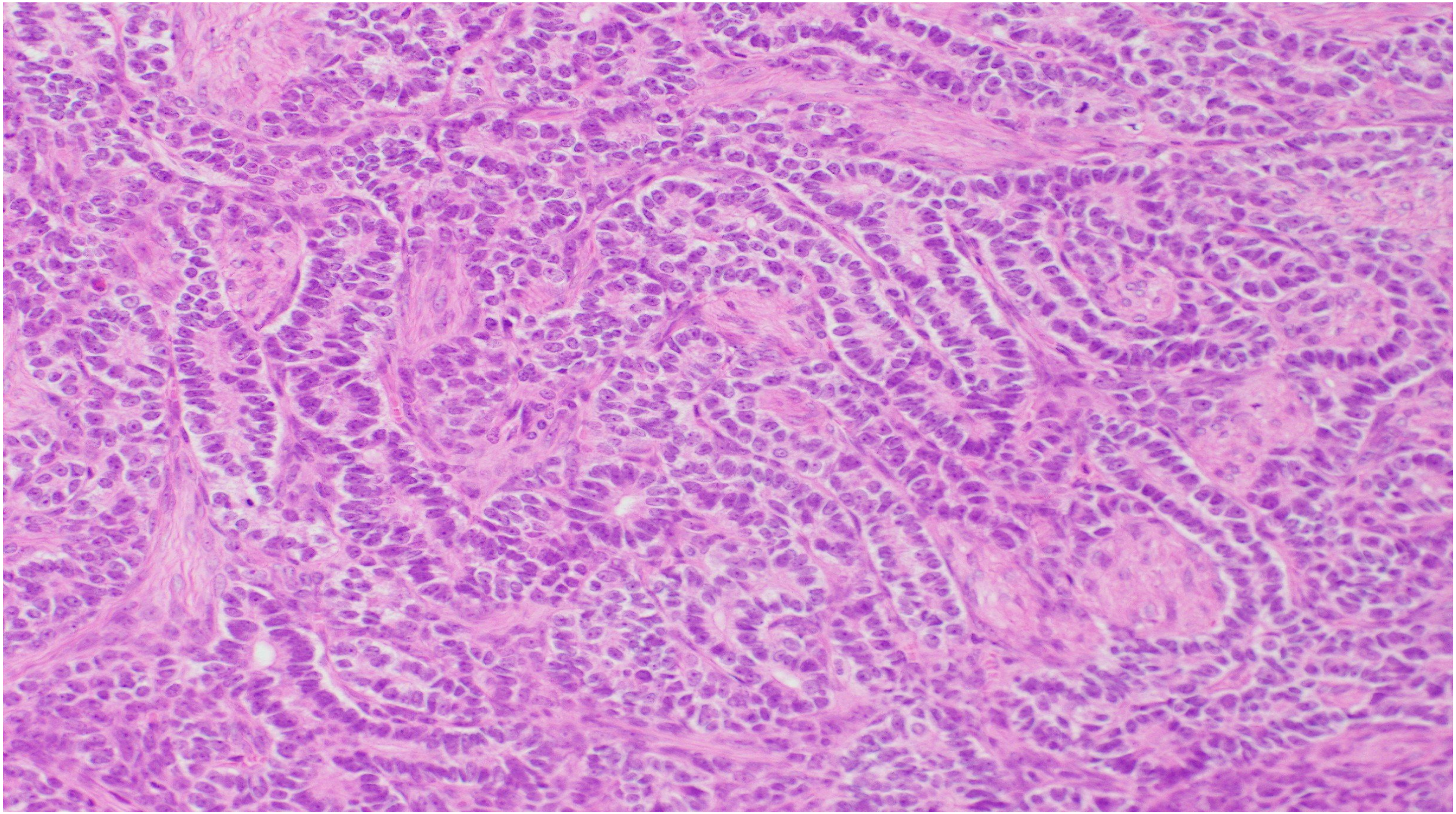

SEX CORD-STROMAL TUMOUR (NOS)

- Proposed definition in 6th edition Blue Book: Sex cord-stromal tumour, not otherwise specified (SCST, NOS) is a neoplasm which lacks definitive characteristics of a specific tumour type but shows pathological evidence supporting sex cord-stromal lineage
- Lot of interobserver variability
- Molecular testing may help in assignment to a specific tumour type, but demonstration of a particular molecular event does not automatically result in reclassification
- Absence of a characteristic molecular event in a prototypical tumour does not result in reclassification into SCST, NOS group
- Need to correlate all parameters
- Diminishing tumour category
- Fusions and other molecular events being reported (GLI1- fusion tumour; *FGFR1* mutations in AGCT; STK11 adnexal tumour)
- Encourage molecular testing (wide RNA and DNA panel)

SEX CORD-STROMAL TUMOUR (NOS)

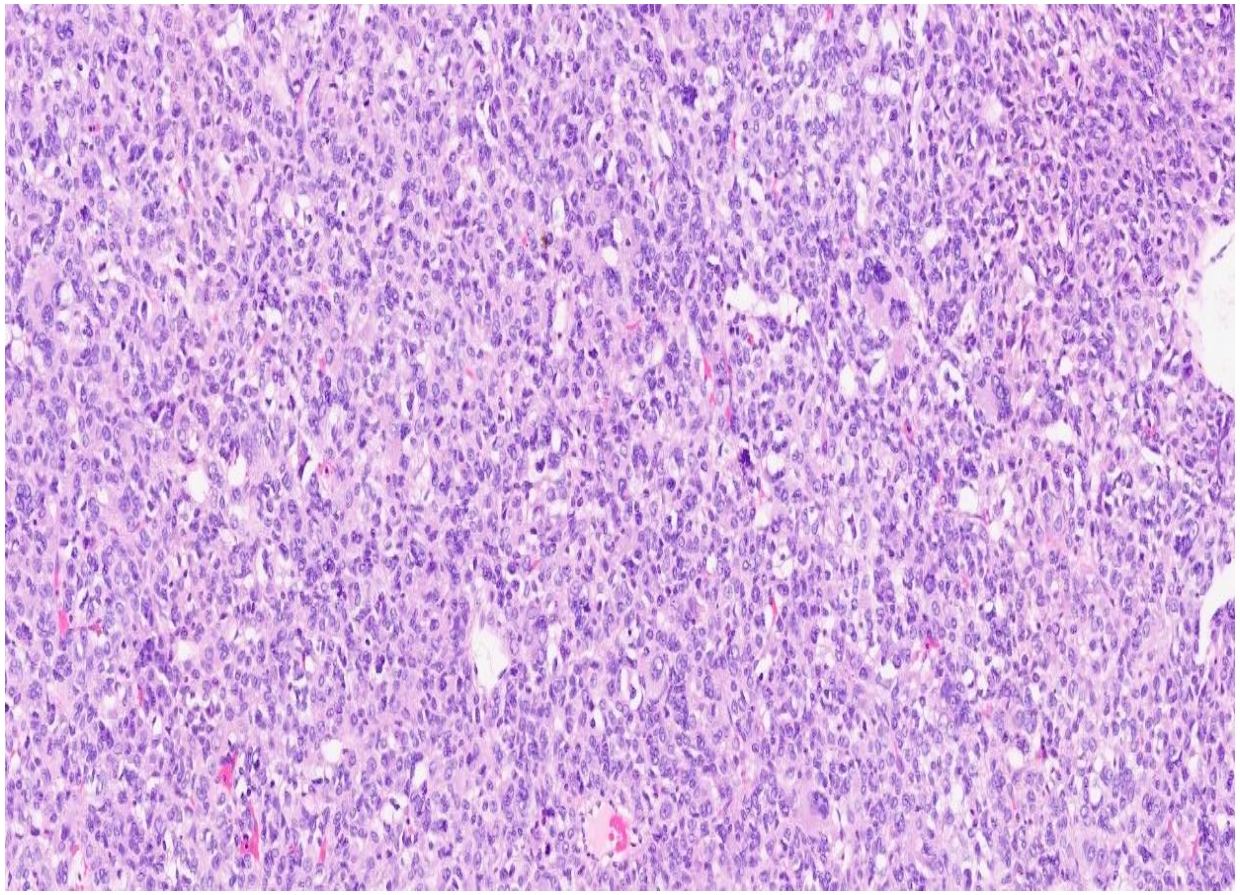

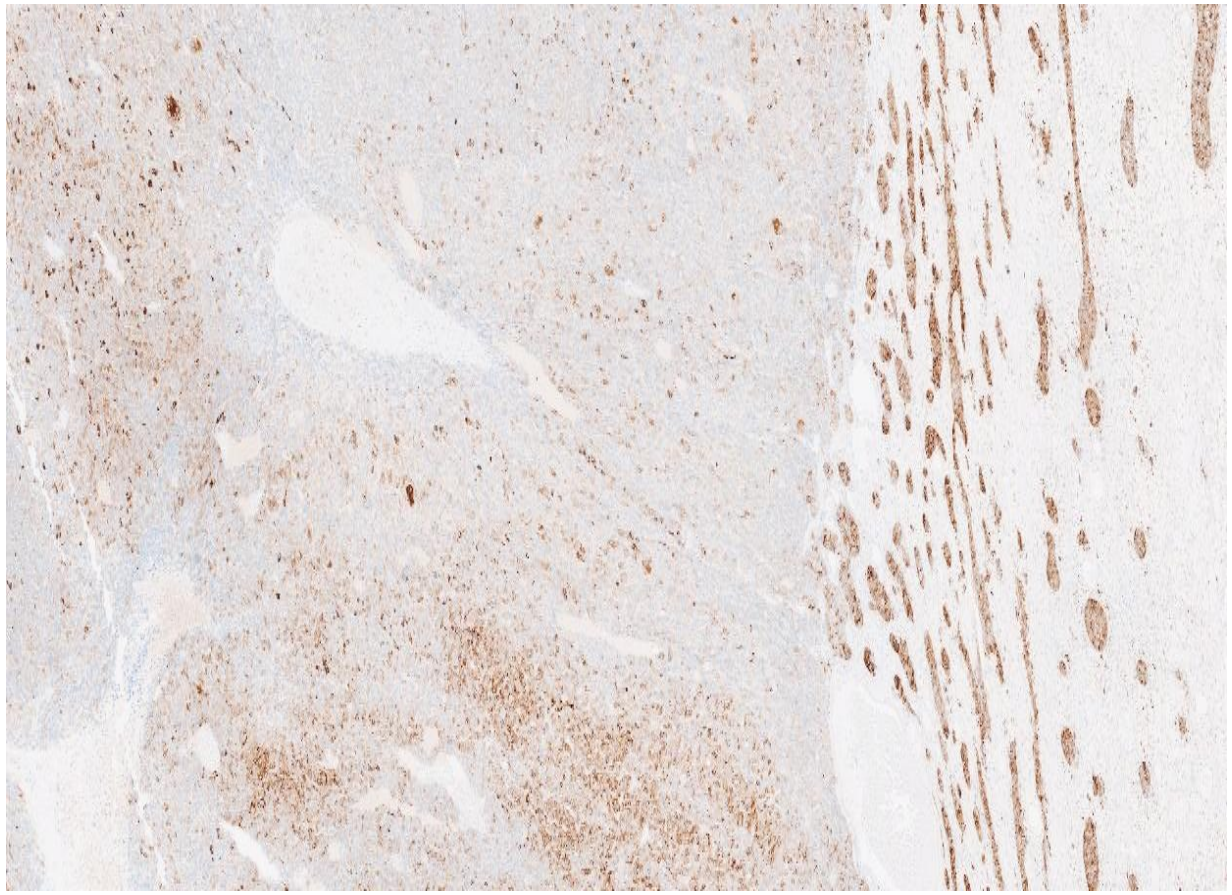

inhibin

MESENCHYMAL TUMOURS CHAPTER

- All mesenchymal tumours covered in single chapter
- Mixed epithelial and mesenchymal tumours also here (endometrial polyp, adenomyoma, APA, adenosarcoma)
- Several new entities
  - *NTRK* rearranged spindle cell neoplasm (in fibroblastic and myofiboblastic tumour section)
  - *SMARC* deficient sarcoma (in miscellaneous tumour section)
  - Category of *SMARCB1* deficient vulvar neoplasm added
  - Other mesenchymal tumours (in miscellaneous tumour section; some other entities discussed- synovial sarcoma, low-grade fibromyxoid sarcoma)

MESENCHYMAL TUMOURS CHAPTER

10.1: Mesenchymal tumours: Introduction

10.1.1: Smooth muscle tumours
- 10.1.1.1: Leiomyoma
- 10.1.1.2: Smooth muscle tumour of uncertain malignant potential
- 10.1.1.3: Leiomyosarcoma
- 10.1.1.4: Intravenous leiomyomatosis
- 10.1.1.5: Metastasizing leiomyoma
- 10.1.1.6: Leiomyomatosis peritonealis disseminata

10.1.2: Endometrial stromal and related tumours
- 10.1.2.1: Endometrial stromal nodule
- 10.1.2.2: Low-grade endometrial stromal sarcoma
- 10.1.2.3: High-grade endometrial stromal sarcoma

10.1.3: Mixed epithelial and mesenchymal tumours
- 10.1.3.1: Endometrial polyp
- 10.1.3.2: Adenomyoma
- 10.1.3.3: Atypical polypoid adenomyoma
- 10.1.3.4: Adenosarcoma

10.1.4: Adipocytic tumours
- 10.1.4.1: Lipoma
- 10.1.4.2: Lipoblastoma-like tumour
- 10.1.4.3: Liposarcoma

10.1.5: Fibroblastic and myofibroblastic tumours
- 10.1.5.1: Prepubertal fibroma
- 10.1.5.2: Myofibroblastoma
- 10.1.5.3: Cellular angiofibroma
- 10.1.5.4: Angiomyofibroblastoma
- 10.1.5.5: Solitary fibrous tumour
- 10.1.5.6: Dermatofibrosarcoma protuberans
- 10.1.5.7: NTRK-rearranged spindle cell neoplasm

10.1.6: Vascular tumours
- 10.1.6.1: Kaposi sarcoma
- 10.1.6.2: Angiosarcoma

10.1.7: Skeletal muscle tumours
- 10.1.7.1: Rhabdomyoma
- 10.1.7.2: Rhabdomyosarcoma

MESENCHYMAL TUMOURS CHAPTER CONTINUED

- 10.1.8: Peripheral nerve sheath tumours
  - 10.1.8.1: Benign peripheral nerve sheath tumours
  - 10.1.8.2: Granular cell tumour
  - 10.1.8.3: Malignant peripheral nerve sheath tumours
- 10.1.9: Miscellaneous mesenchymal tumours
  - 10.1.9.1: Superficial angiomyxoma
  - 10.1.9.2: Deep (aggressive) angiomyxoma
  - 10.1.9.3: SMARC deficient sarcoma
  - 10.1.9.13: SMARCB1-deficient vulvar neoplasms
  - 10.1.9.4: Alveolar soft part sarcoma
  - 10.1.9.5: Uterine tumour resembling ovarian sex cord tumour
  - 10.1.9.6: Perivascular epithelioid cell tumour (PEComa)
  - 10.1.9.7: Inflammatory myofibroblastic tumour
  - 10.1.9.8: Desmoplastic small round cell tumour
  - 10.1.9.9: Embryonic type neuroectodermal tumor
  - 10.1.9.10: Ewing sarcoma
  - 10.1.9.11: Undifferentiated uterine sarcoma
  - 10.1.9.12: Other mesenchymal tumours

TUMOURS OF THE VULVA

- 5th Edition, SCC and precursors were classified on basis of HPV association (HPV-associated or HPV-independent)
- 6th Edition, HPV-independent SCC and precursors further stratified on basis of p53 status (usually using p53 immunohistochemistry); recommended that both p16 and p53 immunohistochemistry performed
- Rarely get block-type p16 and mutation-type p53; p53 usually over-rides p16 (but not always) but advise to do HPV molecular testing
- SCC, NOS can be used when ancillary testing not available

HPV-ASSOCIATED SCC VULVA

- *Essential:* infiltrating, angulated, irregularly sized and shaped nests, anastomosing cords, and solid sheets; nuclear pleomorphism and mitoses; a desmoplastic or inflammatory stroma; p16 block-type immunoreactivity and/or positive molecular testing for HPV.

HPV-ASSOCIATED SQUAMOUS CELL CARCINOMA VULVA

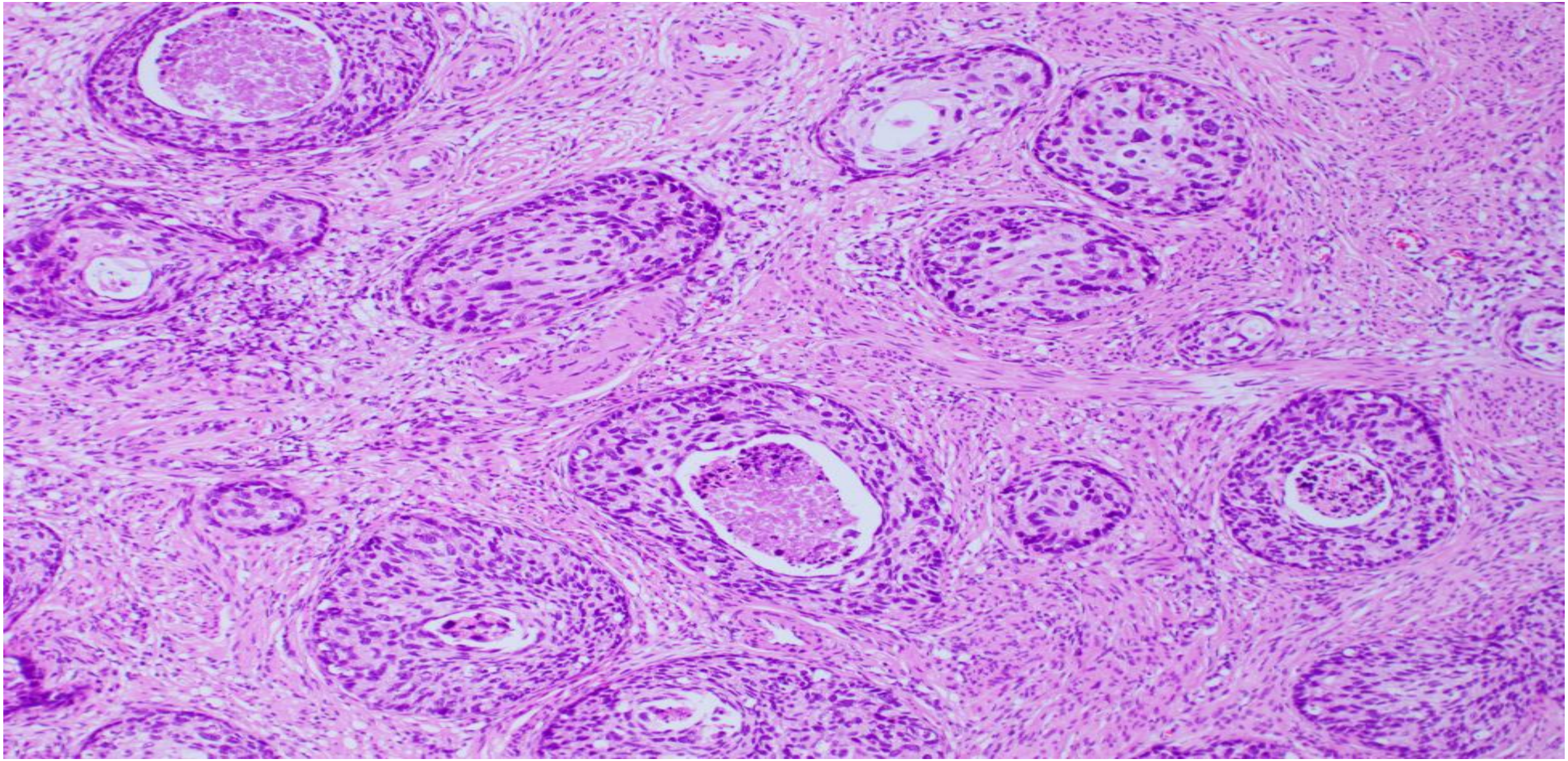

HPV-ASSOCIATED SQUAMOUS CELL CARCINOMA

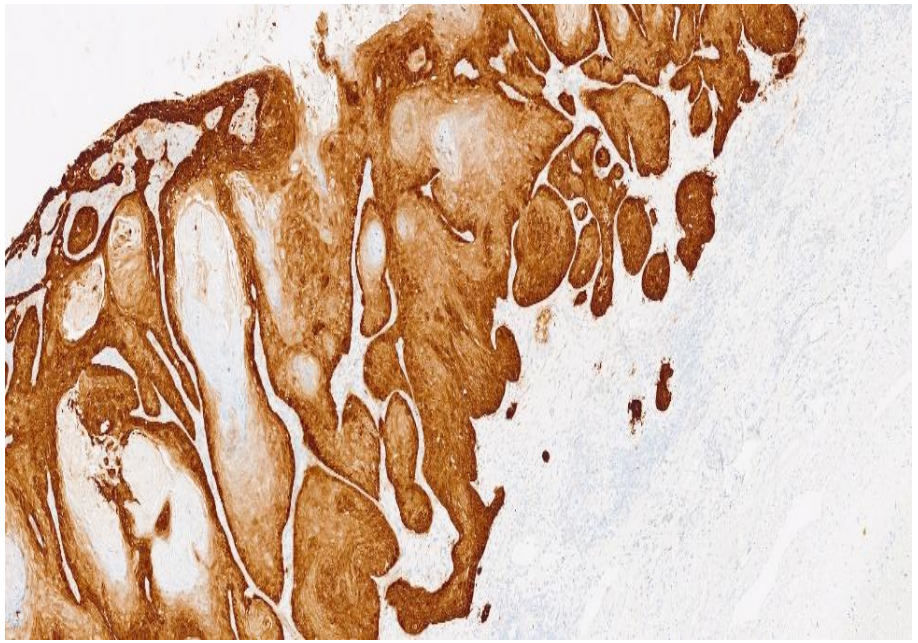

p16

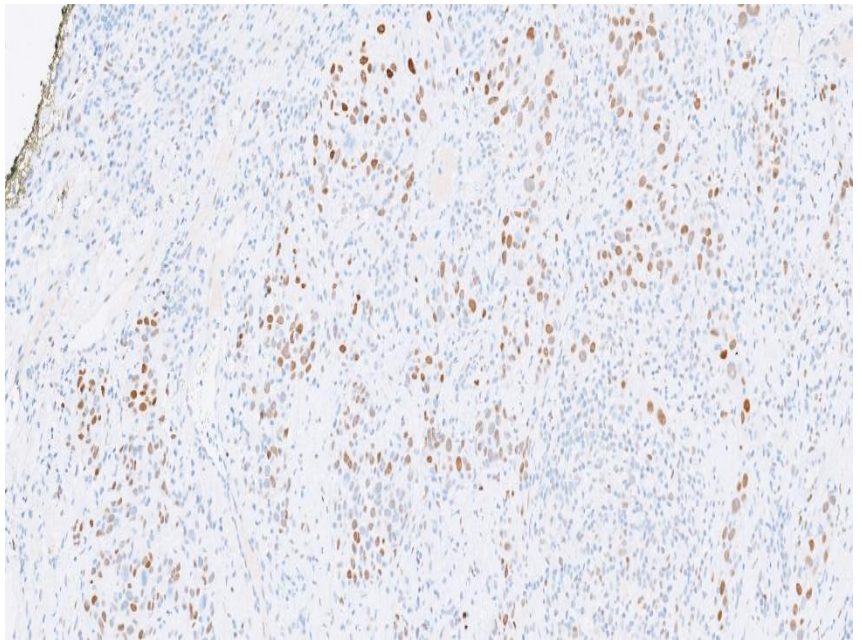

p53

HPV-INDEPENDENT SCC VULVA

Essential: infiltrating, angulated, irregularly sized and shaped nests, anastomosing cords, and solid sheets; nuclear pleomorphism and mitoses; a desmoplastic or inflammatory stroma; p16 negativity and/or negative HPV molecular testing.

- *Desirable:* p53 IHC (or *TP53* gene analysis). The presence of an HPV-independent precursor or inflammatory lesion in the adjacent epithelium.

HPV-INDEPENDENT SQUAMOUS CELL CARCINOMA VULVA: *TP53* MUTATED

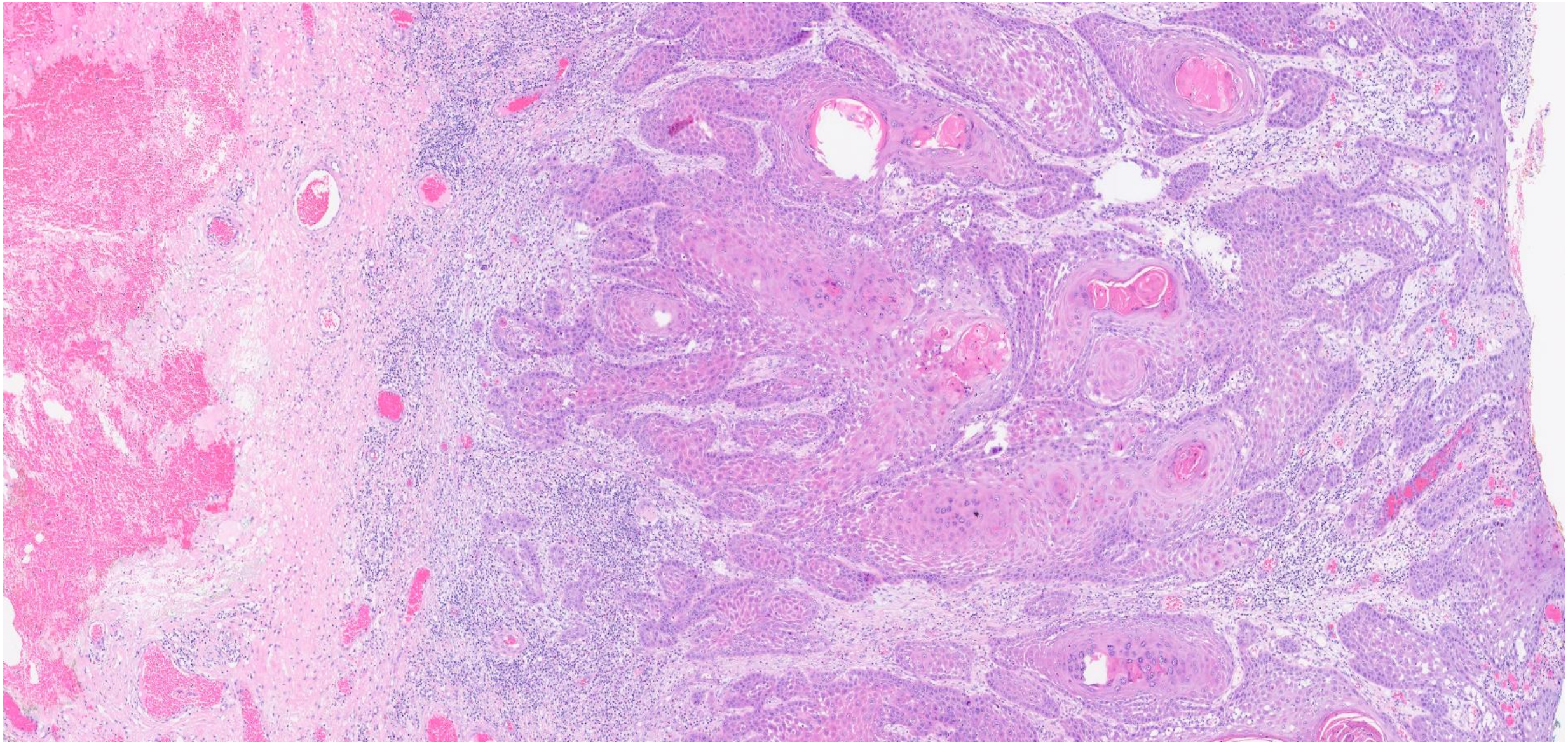

IMMUNOHISTOCHEMISTRY: HPV-INDEPENDENT SQUAMOUS CELL CARCINOMA VULVA: *TP53* MUTATED

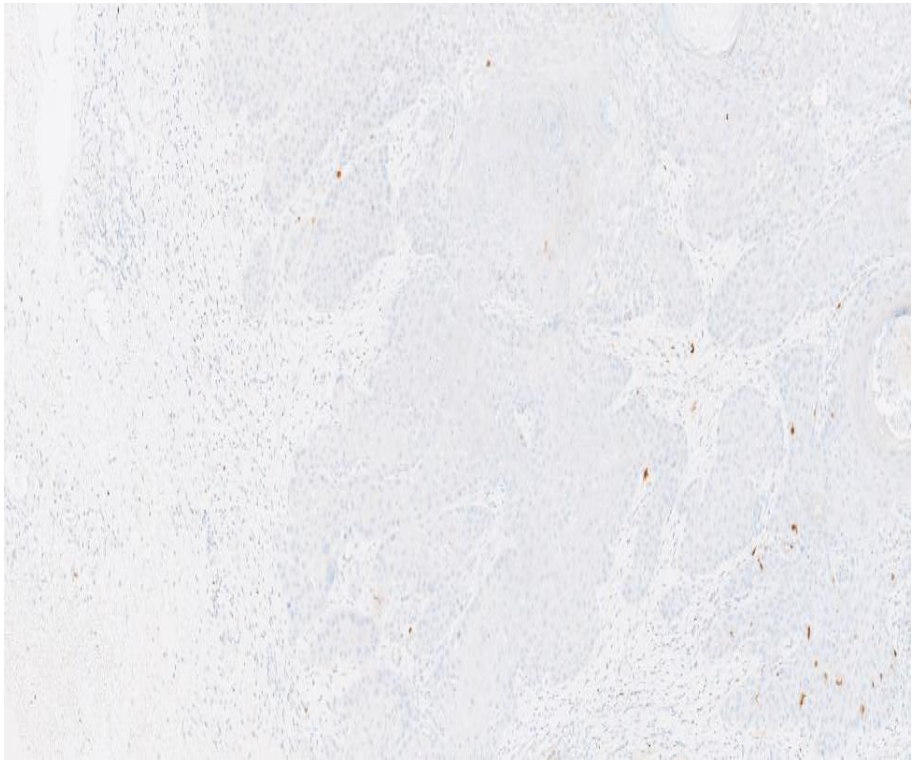

p16

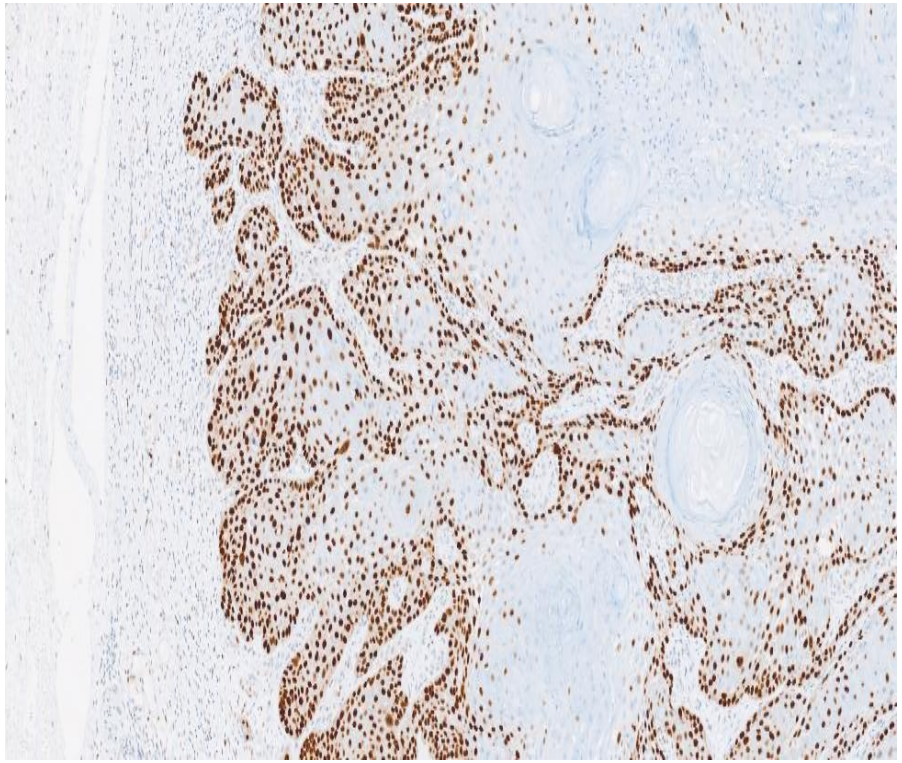

p53

VULVAL SCC (HPV 16 POSITIVE)

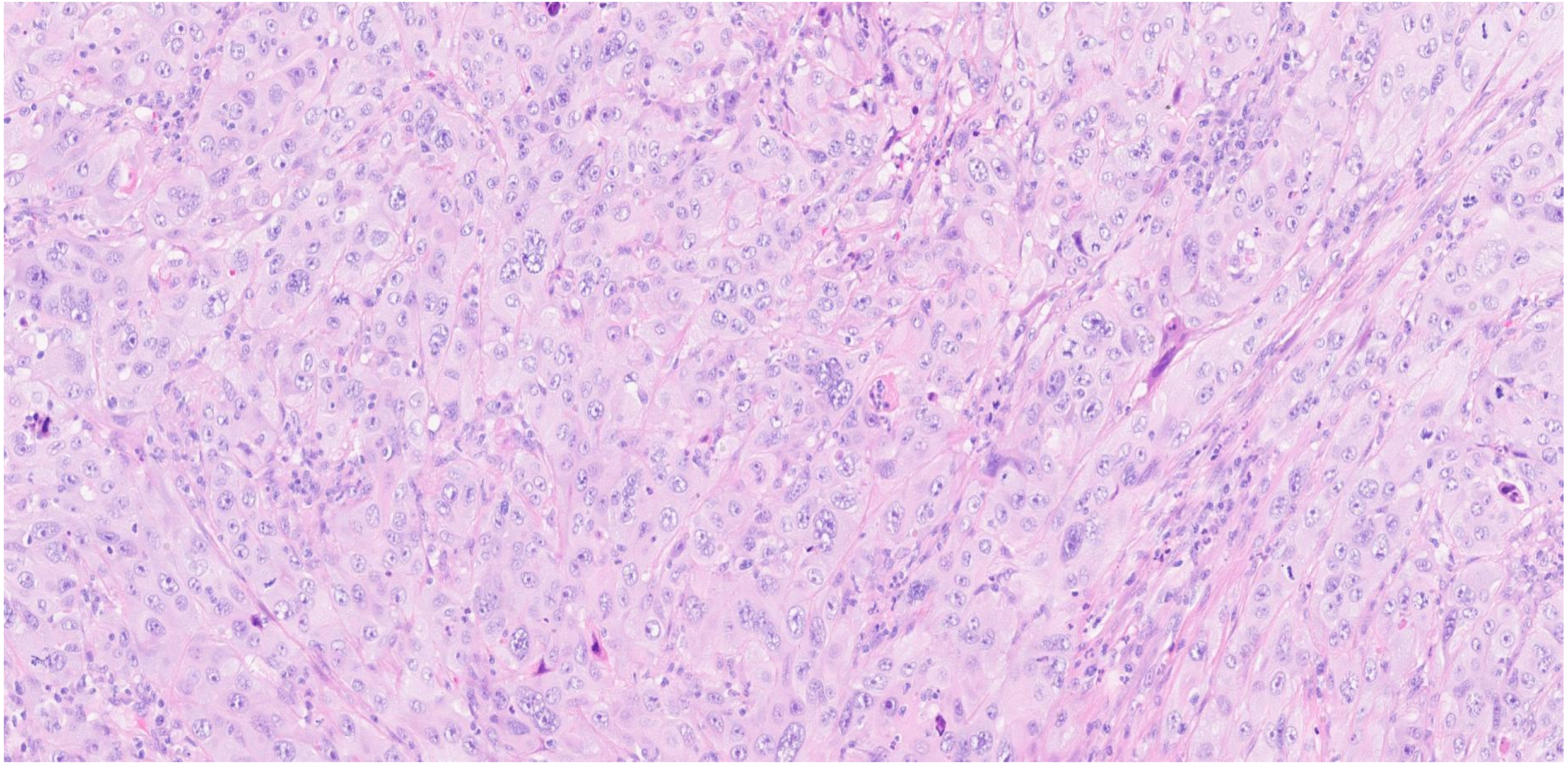

VULVAL SCC (HPV 16 POSITIVE)

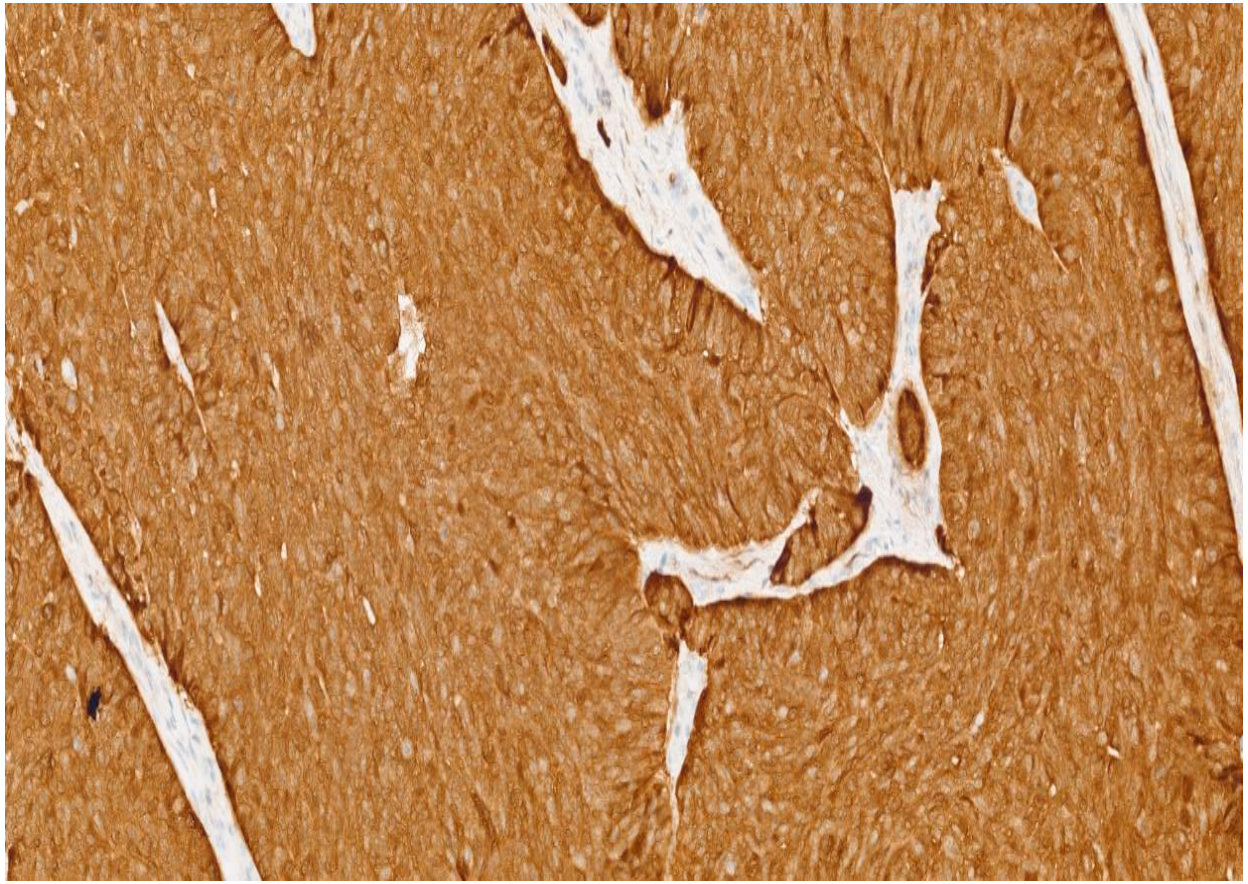

p16

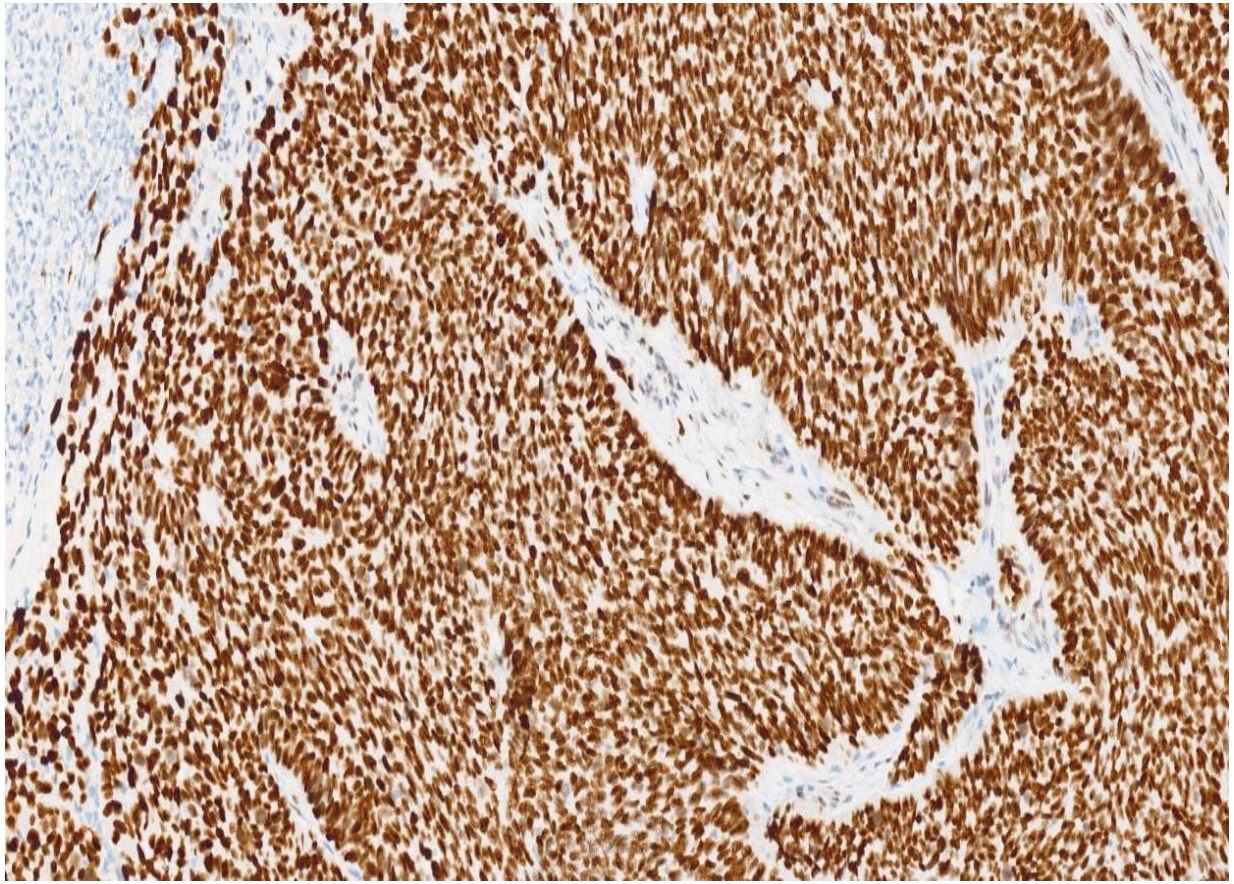

p53

HPV-INDEPENDENT, *TP53* WILD-TYPE SCC

- About 13% of vulval SCC
- Intermediate prognosis between HPV-associated and HPV-independent *TP53* wild-type SCC
- In some cases, can be difficult to diagnose and distinguish from “reactive” squamous lesions/ pseudoepitheliomatous hyperplasia (don’t have useful marker such as p16 or p53)
- Think twice, especially if very bland, and exclude other things (Treponema, fungi, HSV etc) before making diagnosis
- Associated with *PIK3CA* mutations and abnormalities in *PI3K/ AkT/ mTOR* pathway

HPV-INDEPENDENT, *TP53* WILD-TYPE SCC

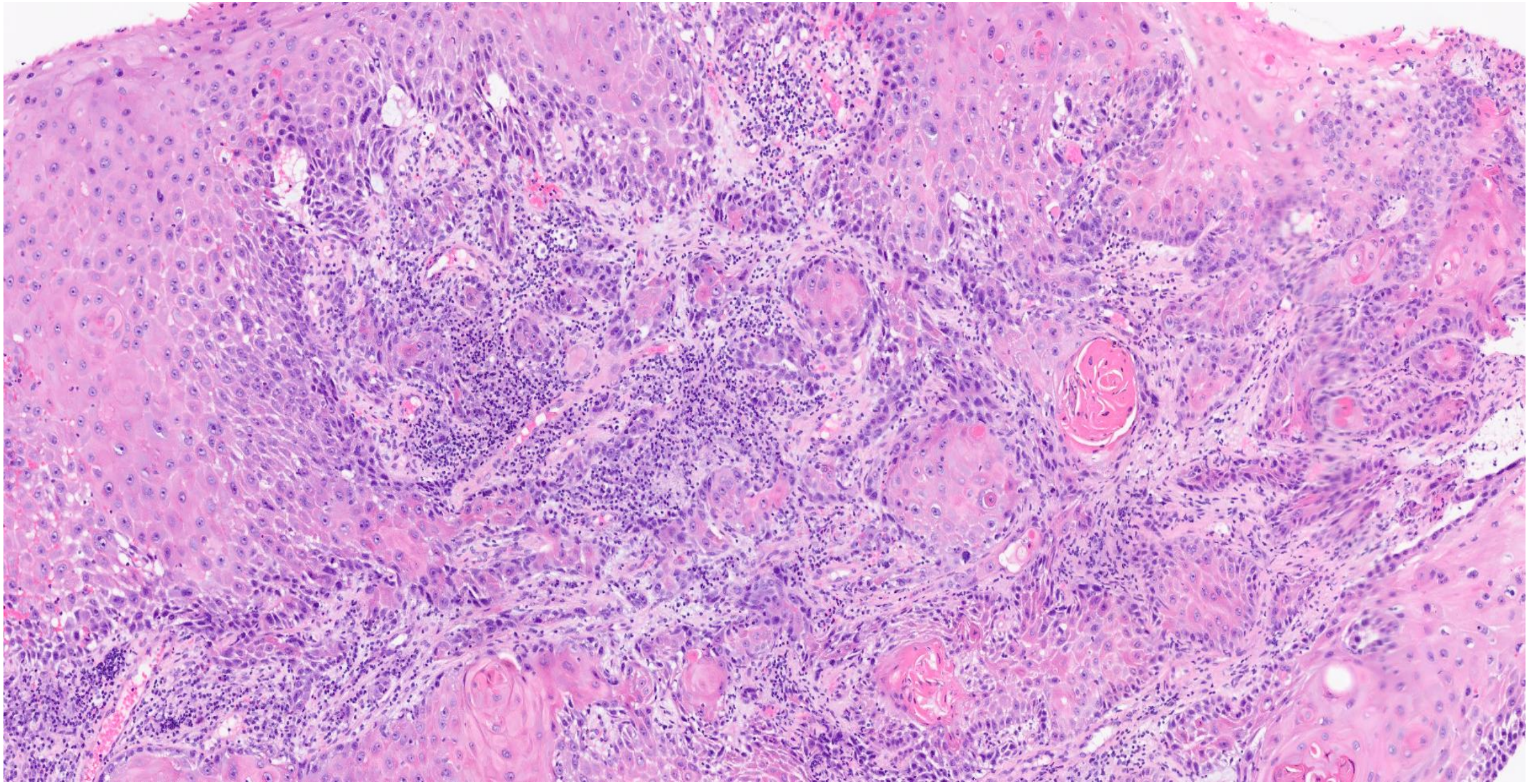

HPV-INDEPENDENT, *TP53* WILD-TYPE SCC



p16

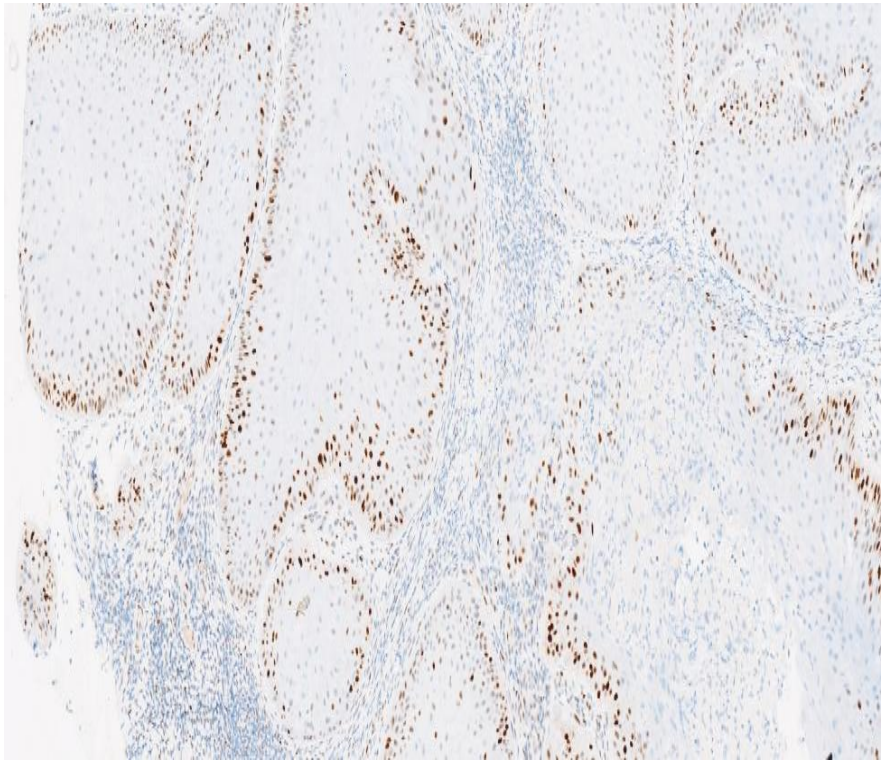

p53

ANOTHER HPV-INDEPENDENT, *TP53* WILD-TYPE SCC

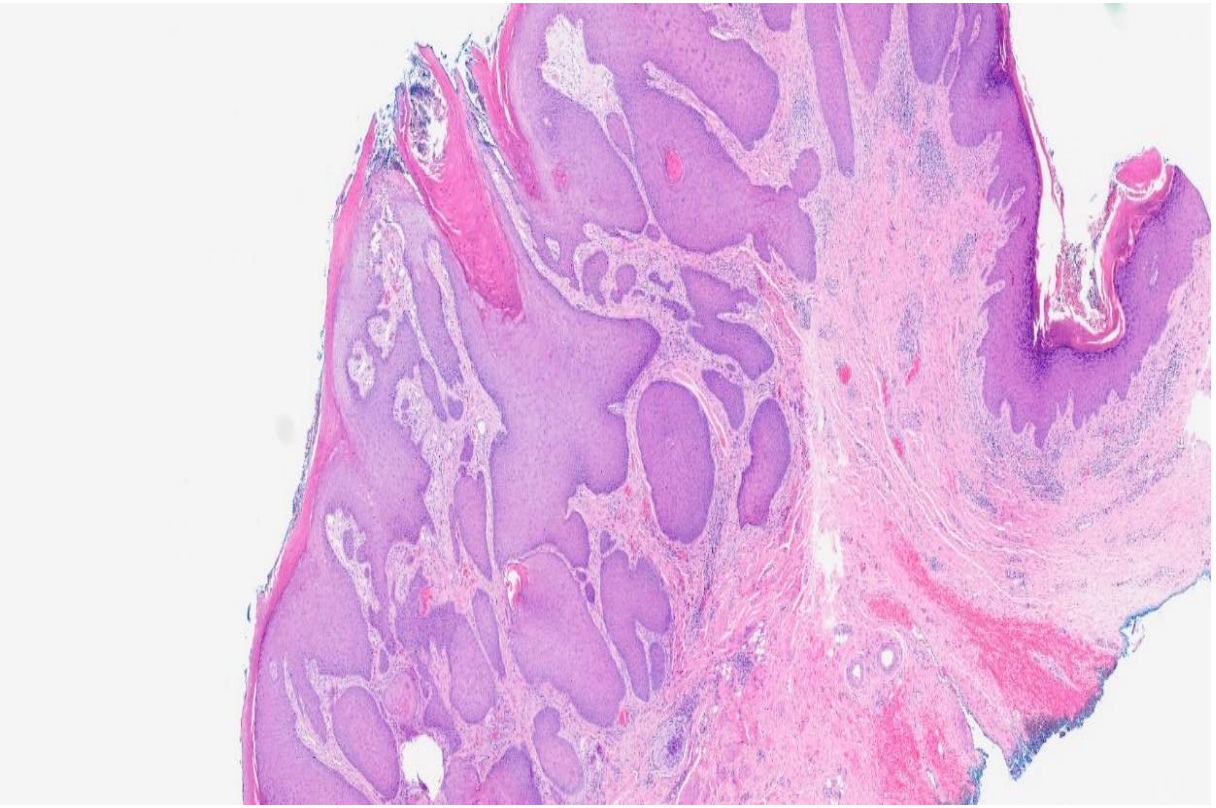

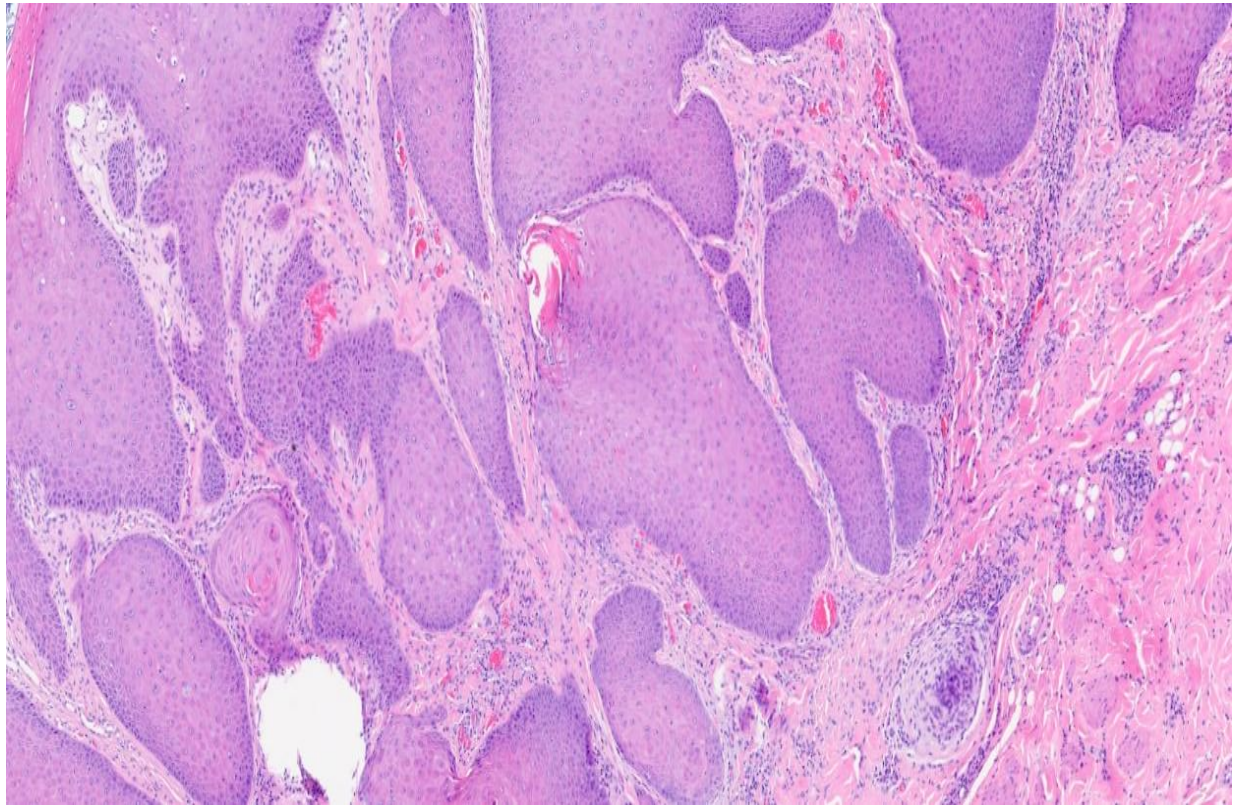

ANOTHER HPV-INDEPENDENT, TP53 WILD-TYPE SCC

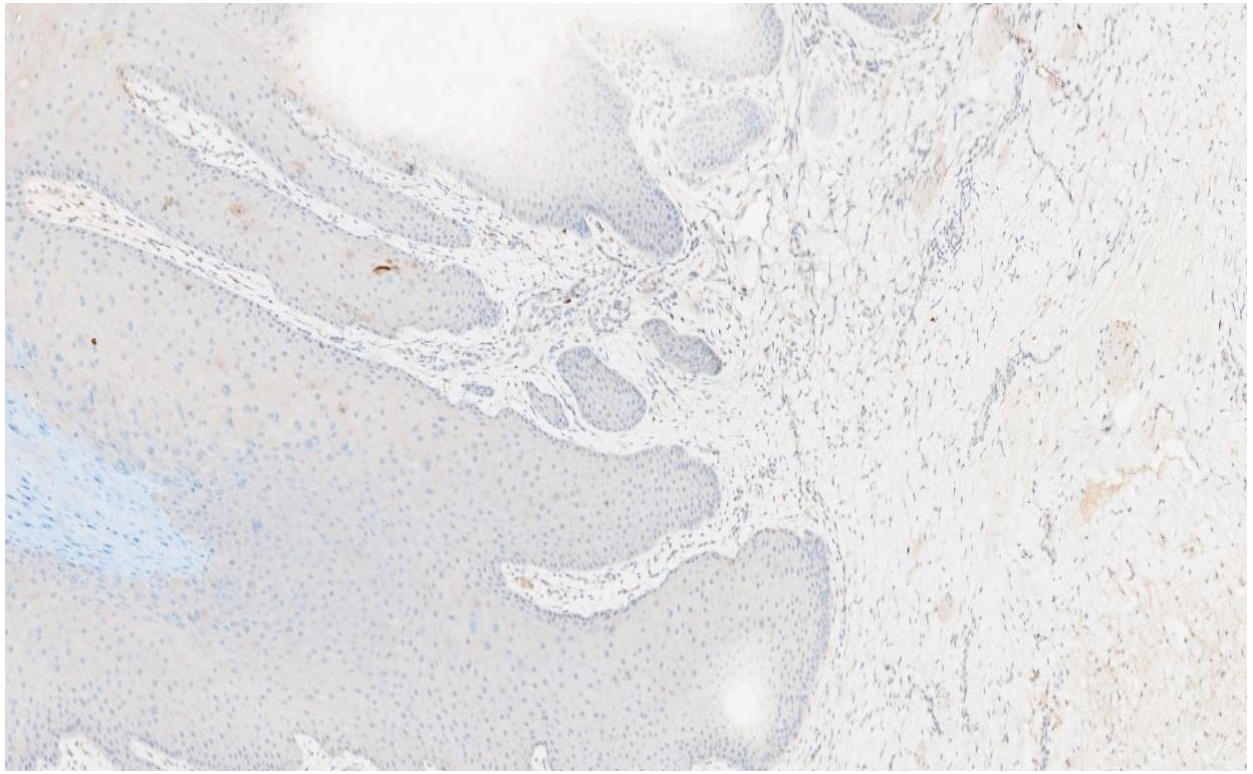

p16

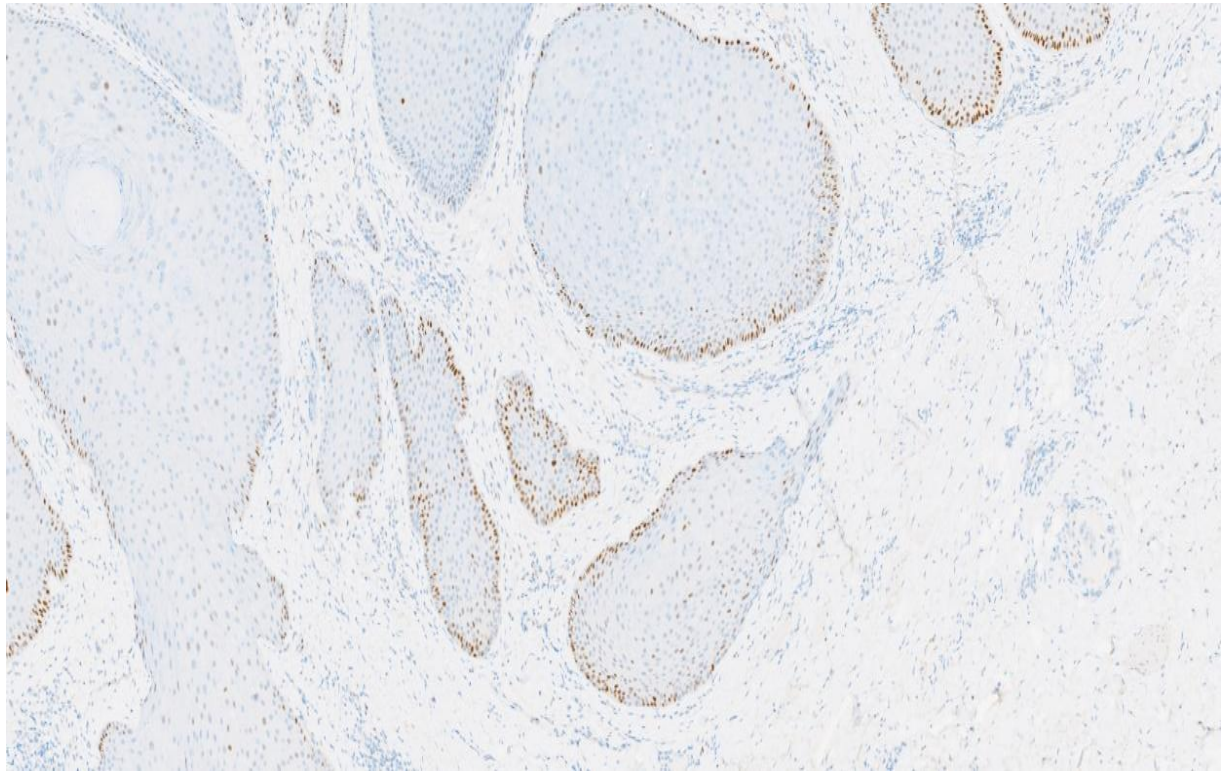

p53

TUMOURS OF THE UTERINE CORPUS

- Sarcomas (including adenosarcoma) now included in separate chapter
- Non-neoplastic lesions not covered
- Mesonephric-like adenocarcinoma now has its own listing (not covered with other carcinomas)
- Detailed coverage of TCGA categories in introduction

EPITHELIAL TUMOURS OF THE OVARY

- Non-neoplastic lesions not covered but endometriosis mentioned where relevant
- Serous surface papilloma removed
- Endometrioid cystadenoma removed
- Teratoma-associated mucinous neoplasms with lower intestinal morphology and immunophenotype should be considered somatic tumours arising from teratomas

EPITHELIAL TUMOURS OF THE OVARY

- Renaming of foci of “microinvasion” (<5 mm) in association with SBT and MBT; **removing of terms microinvasion and microinvasive carcinoma**; microinvasion (SBT/ MBT with eosinophilic stromal cells; no evidence that adverse prognosis; biologically inert cells with a terminally differentiated or senescent phenotype); microinvasive carcinoma (measure and call focal LGSC/ mucinous carcinoma arising from SBT/ MBT: significance uncertain; stress that extensive sampling should be performed to exclude a larger invasive tumour)
- Consider “invasive implant” and “extraovarian LGSC” as synonymous

SBT WITH MICROINVASION

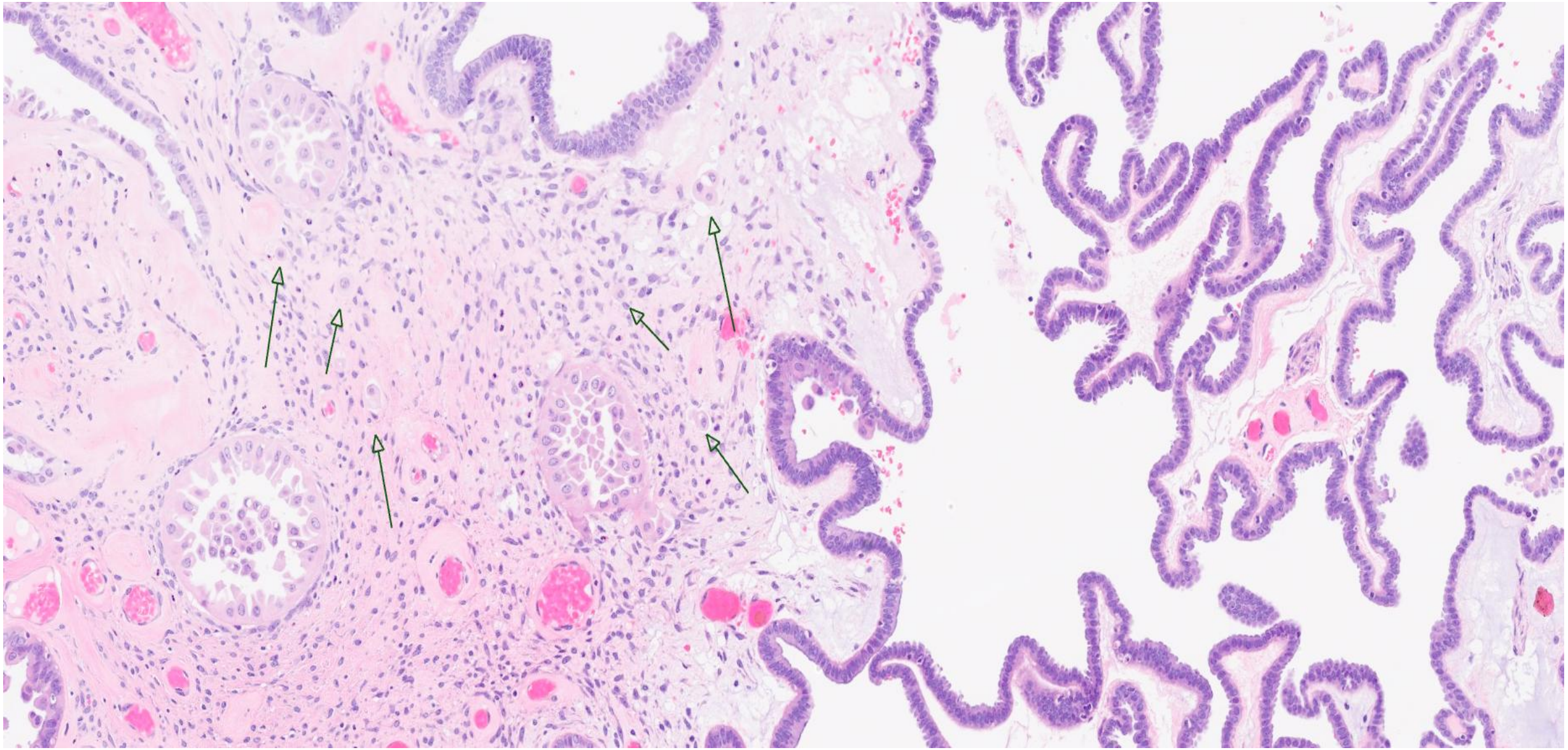

IMPLANTS

- I know that you are currently working on the 6th WHO classification that is currently in progress. I am writing you to rise a specific clinical issue that, I hope, will be clarified and modified in this new edition. We were together in different meetings and congreses and you know my opinions about the current confusional wording of the 'previous' invasive implants (according to the Bell & Scully description and then Scully, Young & Clement AFIP in 1998) so-called since the last but one WHO edition in 2014, 'extra ovarian LGSC'. This 'new' wording (used then since 1 decade) is clinically non-relevant and disconnected from its impact of such wording because patients with 'invasive' implants are managed differently from 'real' stage II or III LGSC: Some of them could be managed conservatively (what is not the case of LGSC > stage I disease)Invasive implants are not treated with adjuvant treatment (except in case of multiple invasive implants), which is a standard of care in stage II/III LGSC. At least, the survival of patients with (few) invasive implants is different from stage > I LGSC. For sure, a patient with several/multiple sites of invasive implants and a SBOT with stromal micro-invasion and MPP should be considered clinically, and probably pathologically, as a LGSC (requiring then a radical debulking surgery and an adjuvant treatment). But a patient with few (or a single) invasive implant(s) mixed with different sites of non-invasive invasive implants and a real ovarian SBOT should not be considered and treated as LGSC. Many of clinicians, skilled in SBOT, within the ESGO are on the same line (and we wrote it in the OCCC in Milan and the last one in Valencia). So my current request is whether to consider to come back to the previous classification non-invasive/invasive implants or to consider to use the both wordings (WHO 2014/2020 and AFIP 1998/2003) for the 2 types when the pathologist finalize its report:
- -**Implants/non-invasive implants**
- **-Extraovarian LGSC/invasive implants**

REMEMBER

- THE BOOK IS NOT YET PUBLISHED AND MORE MEETINGS TO COME SO ANYTHING I SAY IS PRELIMINARY AND NOT SET IN STONE