Vulvar carcinomas: an update

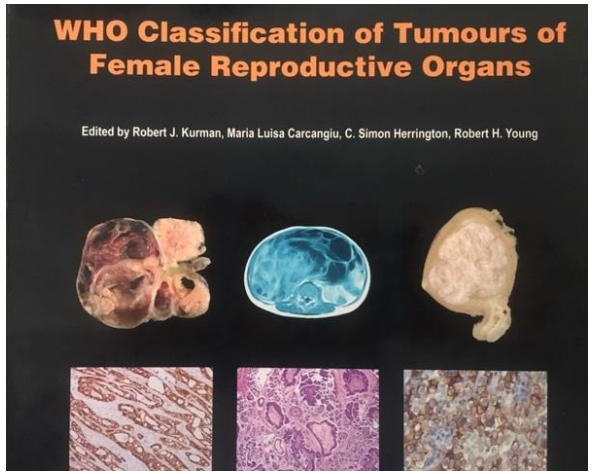

Jaume Ordi M.D., Ph.D.

Senior consultant. Gynecological pathology.
Hospital Clínic
Professor of Pathology. University of Barcelona
Research Professor. ISGlobal
jordi@clinic.cat



Carcinoma of the vulva

- Infrequent (<5% Gyn cancers)
- **95% squamous cell carcinomas (VSCC)**
- **Subset of VSCC associated with HPV** (Toki T, et al. *Int J Gynecol Pathol* 1991; 10: 107-125; Kurman RJ, et al. *Am J Surg Pathol* 1993; 17: 133-145)
- A **precursor lesion** can be identified in a significant proportion of these tumors

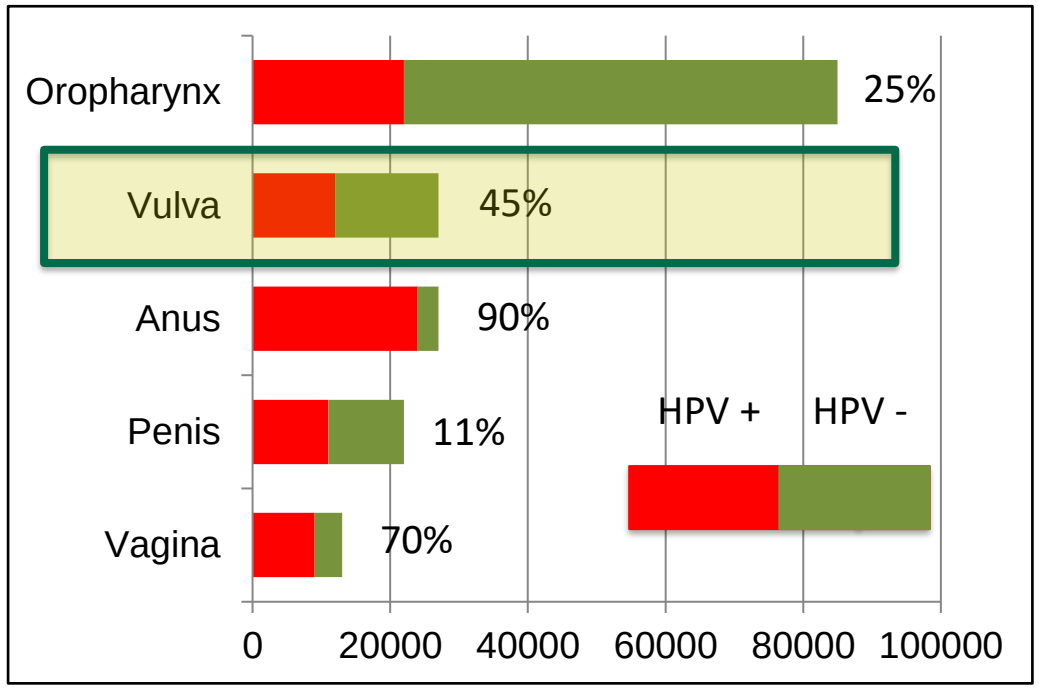

Forman D, et al. *Vaccine* 2012; 30 Suppl 5. F12-F23

Outline

1. Identification of HPV in vulvar tumors
2. Invasive squamous cell carcinomas of the vulva
3. Precursors of VSCC
4. Molecular aspects of VSCC

Outline

1. **Identification of HPV in vulvar tumors**
2. Invasive squamous cell carcinomas of the vulva
3. Precursors of VSCC
4. Molecular aspects of VSCC

Detection of HPV: direct methods

PCR-based techniques

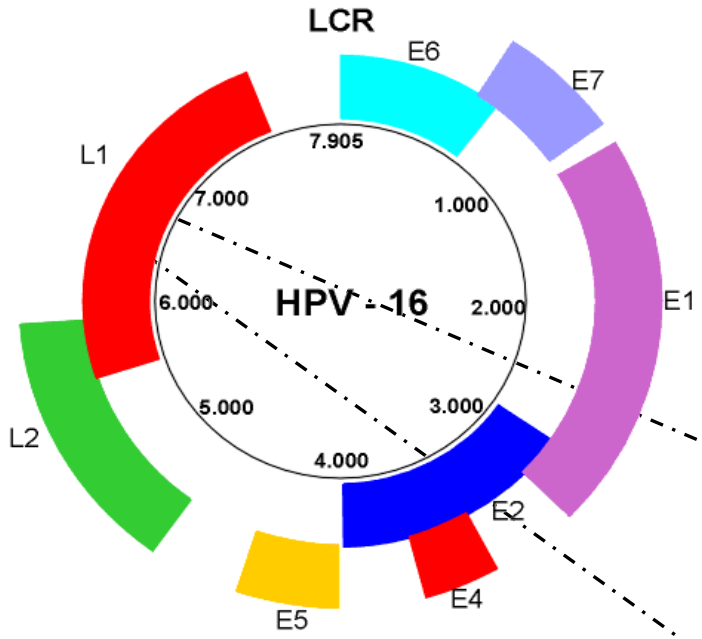



Amplimer Size

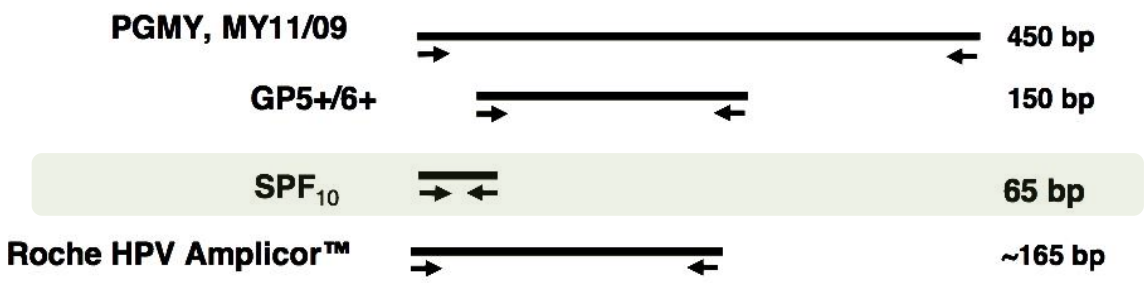



ISH mRNA E6 HPV

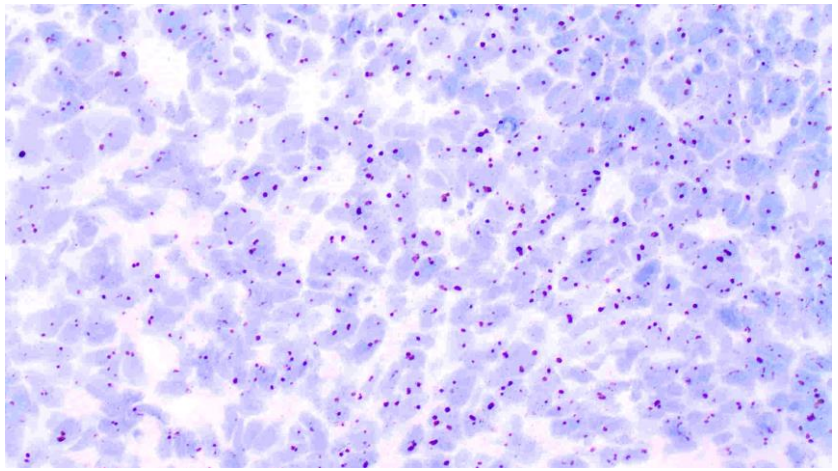

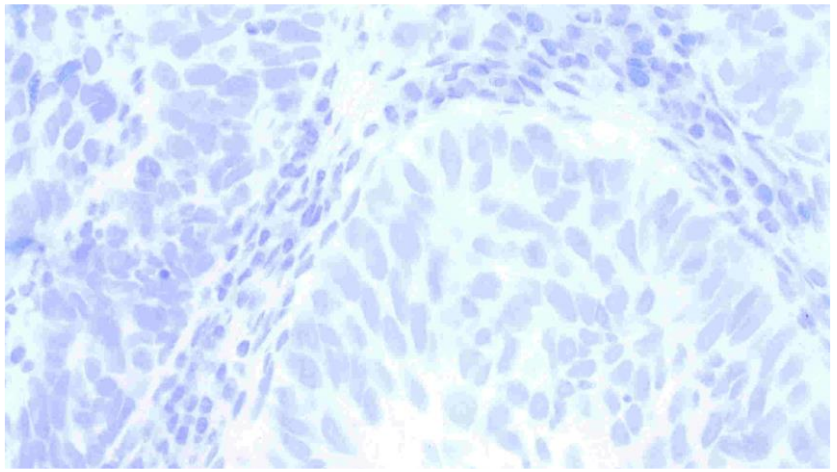

Detection of HPV: indirect method

IHC	HPV-associated	HPV-independent
p16	100%	1.3%
p53	6.2%	64.5%

Santos M, et al. *Int J Gynecol Pathol*. 2004;23:206-14
Santos M, et al. *Am J Surg Pathol* 2006; 30:1357-56

p16

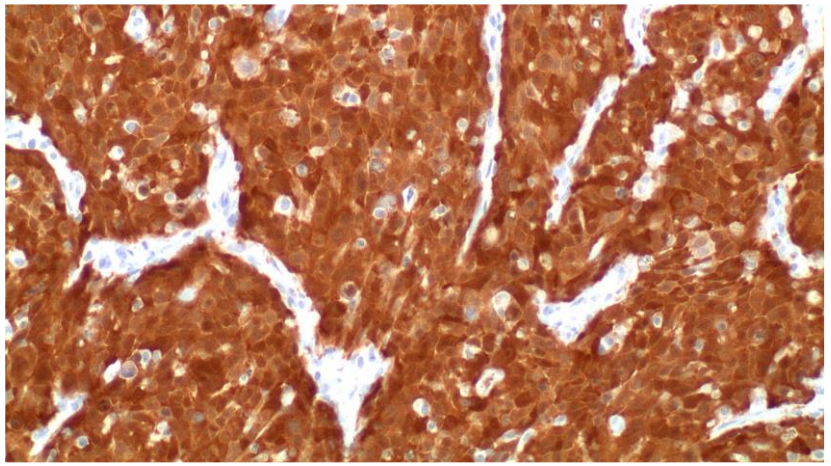

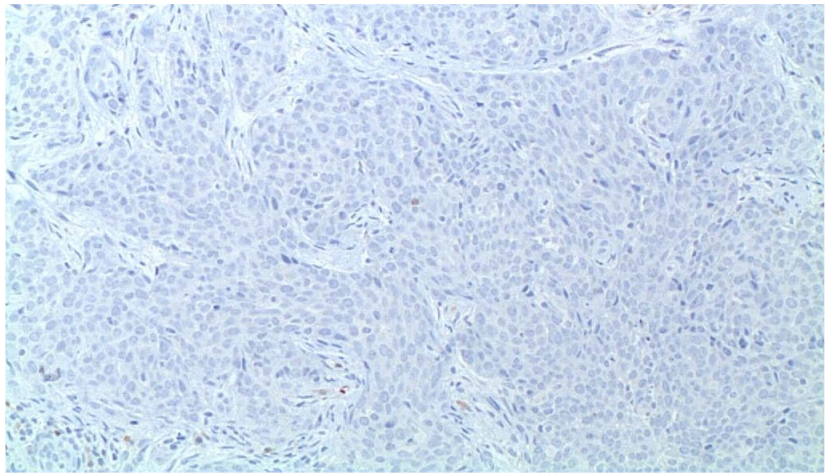

Outline

1. Identification of HPV in vulvar tumors
2. **Invasive squamous cell carcinomas of the vulva**
3. Precursors of VSCC
4. Molecular aspects of VSCC

Histological types. WHO 2014

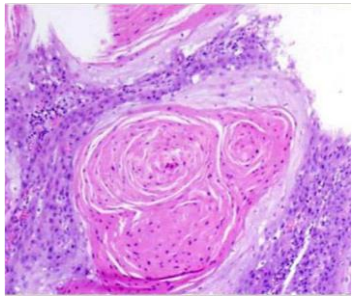

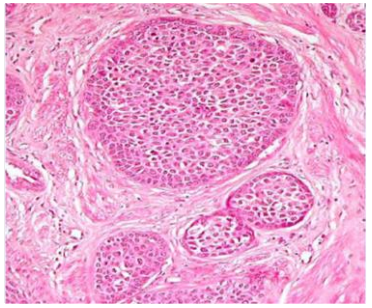

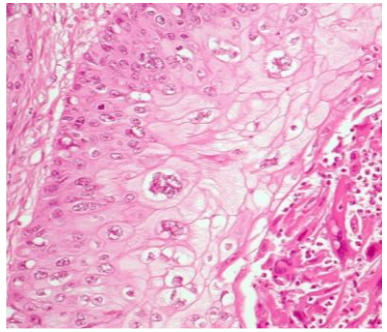

- Keratinizing
- Non keratinizing
- Basaloid
- Warty
- Verrucous
- Spindle cell

Histological types. HPV association

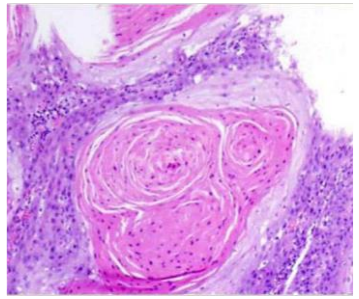

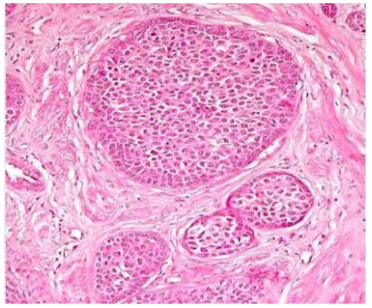

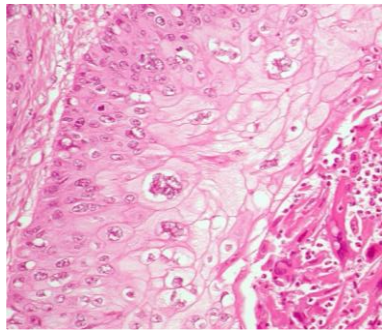

- Keratinizing → HPV negative
- Non keratinizing
- Basaloid
- Warty

} HPV positive

- Verrucous
- Spindle cell

Toki T, et al. *Int J Gynecol Pathol* 1991; 10: 107-125

Kurman RJ, et al. *Am J Surg Pathol* 1993; 17: 133-145

VSCC. Histological types, HPV and p16

	Gold standard groups	
	HPV DNA+ p16+ ($n = 367$) *n* (%)	HPV DNA− p16− ($n = 1,060$) *n* (%)
Keratinizing	134 (36.5)	861 (81.2)
Non-keratinizing	49 (13.4)	124 (11.7)
Basaloid	152 (41.4)	27 (2.5)
Warty	31 (8.4)	29 (2.7)
Verrucous	0 (0.0)	15 (1.4)
Spindle cell	1 (0.3)	4 (0.4)
Age range [min–max]	[22–97]	[18–104]
Mean age (SD)	*61.7 (16.7)*	*71.7 (13.4)*

1594 VSCC

Rakislova N, et al. *Int J Cancer* 2018; 42:828-35

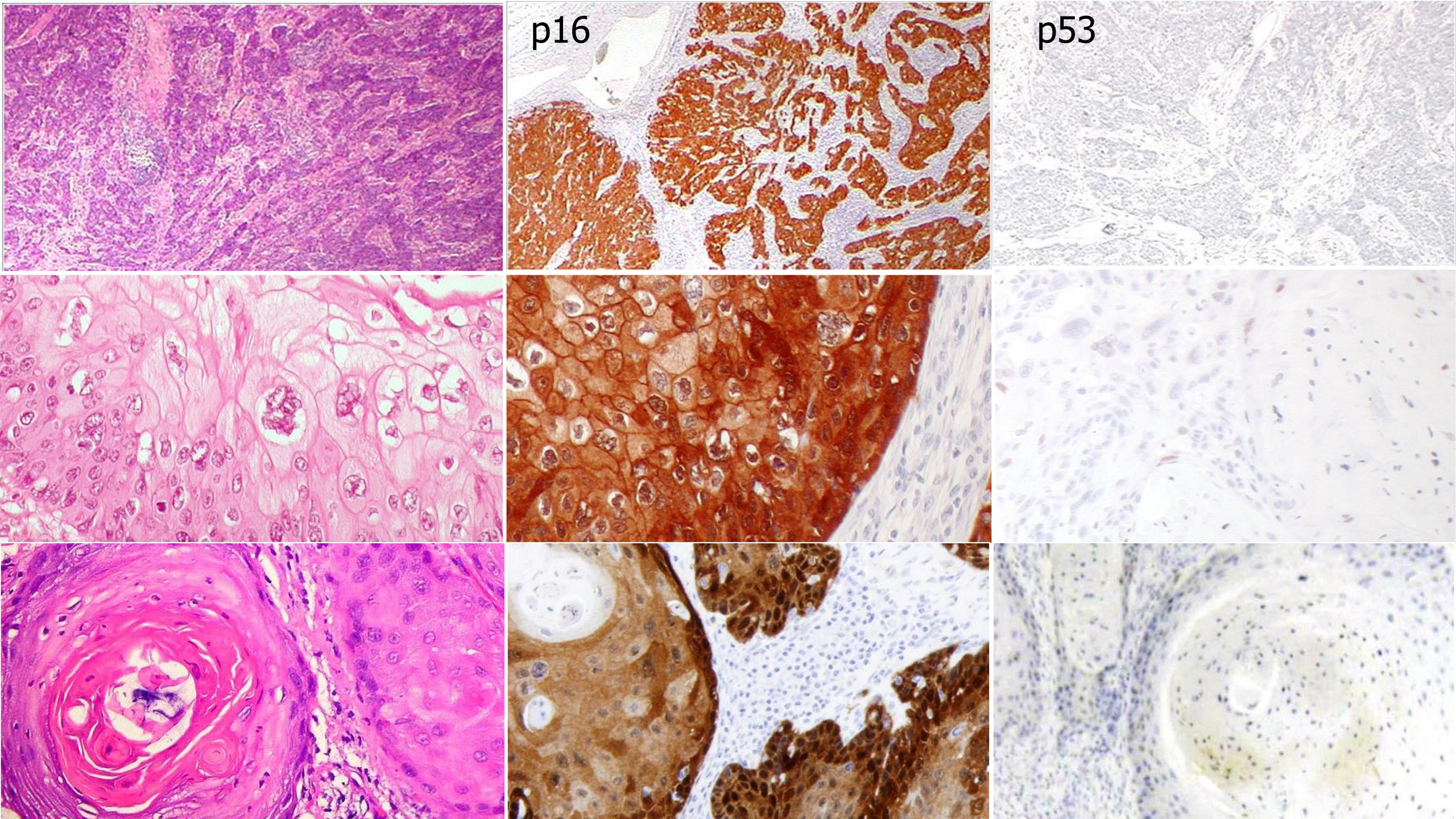
p16
p53

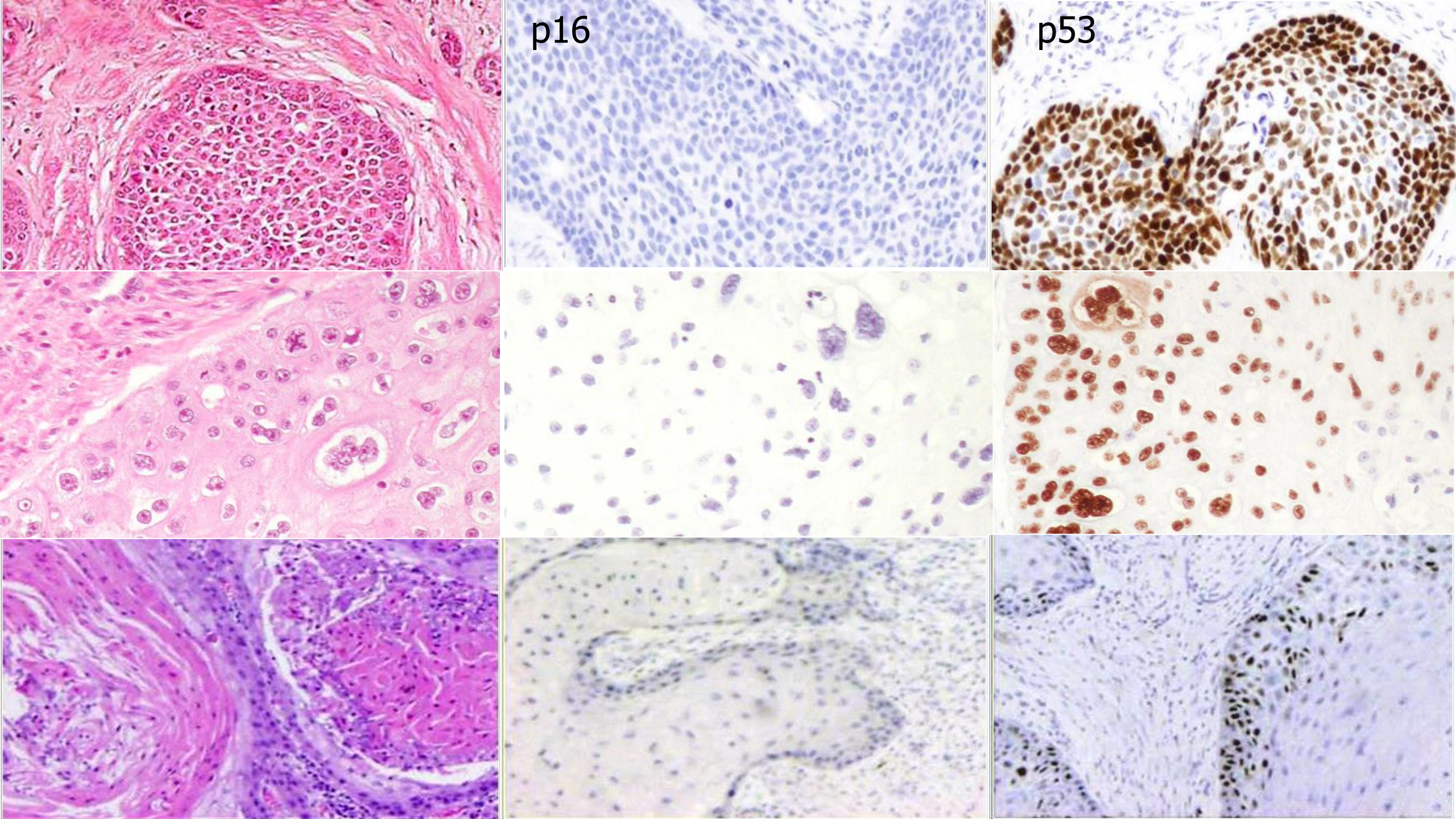
p16
p53

VSCC. Histological types, HPV and p16

	Gold standard groups		Non-conclusive groups		
	HPV DNA+ p16+ ($n = 367$) n (%)	HPV DNA− p16− ($n = 1{,}060$) n (%)	HPV DNA− p16+ ($n = 93$) n (%)	HPV DNA + p16− ($n = 74$) n (%)	p-Value[1]
Keratinizing	134 (36.5)	861 (81.2)	44 (47.3)	51 (68.9)	**0.000**
Non-keratinizing	49 (13.4)	124 (11.7)	17 (18.3)	7 (9.5)	0.403
Basaloid	152 (41.4)	27 (2.5)	28 (30.1)	8 (10.8)	**0.000**
Warty	31 (8.4)	29 (2.7)	4 (4.3)	7 (9.5)	**0.000**
Verrucous	0 (0.0)	15 (1.4)	0 (0.0)	1 (1.4)	0.016
Spindle cell	1 (0.3)	4 (0.4)	0 (0.0)	0 (0.0)	1.000
Age range [min–max]	[22–97]	[18–104]	[24–94]	[33–92]	
Mean age (SD)	61.7 *(16.7)*	71.7 *(13.4)*	64.8 *(15.0)*	68.8 *(14.4)*	**0.000**

Rakislova N, et al. *Int J Cancer* 2018; 42:828-35

VSCC. Histological types, HPV and p16

	Gold standard groups		Non-conclusive groups		
	HPV DNA+ p16+ ($n = 367$) n (%)	HPV DNA− p16− ($n = 1{,}060$) n (%)	HPV DNA− p16+ ($n = 93$) n (%)	HPV DNA + p16− ($n = 74$) n (%)	p-Value[1]
Keratinizing	134 (36.5)	861 (81.2)	44 (47.3)	51 (68.9)	**0.000**
Non-keratinizing	49 (13.4)	124 (11.7)	17 (18.3)	7 (9.5)	0.403
Basaloid	152 (41.4)	27 (2.5)	28 (30.1)	8 (10.8)	**0.000**
Warty	31 (8.4)	29 (2.7)	4 (4.3)	7 (9.5)	**0.000**
Verrucous	0 (0.0)	15 (1.4)	0 (0.0)	1 (1.4)	0.016
Spindle cell	1 (0.3)	4 (0.4)	0 (0.0)	0 (0.0)	1.000
Age range [min–max]	[22–97]	[18–104]	[24–94]	[33–92]	
Mean age (SD)	61.7 *(16.7)*	71.7 *(13.4)*	64.8 *(15.0)*	68.8 *(14.4)*	**0.000**

Rakislova N, et al. *Int J Cancer* 2018; 42:828-35

HPV and prognosis

- HPV-associated carcinomas have an improved prognosis compared with HPV-independent cancers

Head and neck

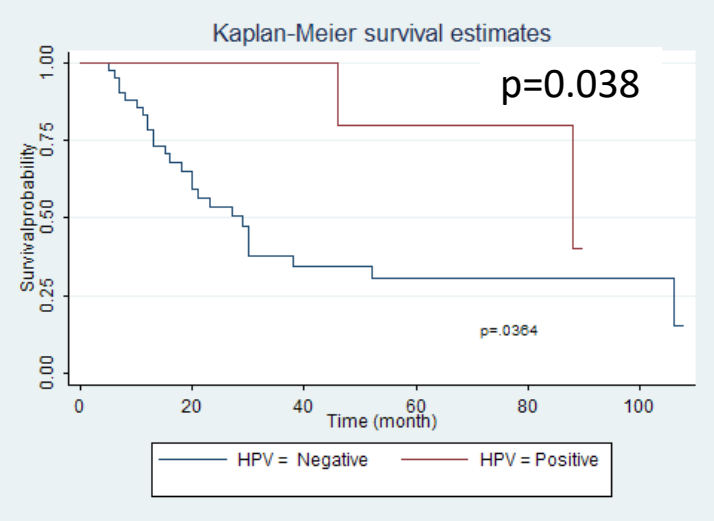

Alos L, et al. *Cancer* 2009; 115: 2701-9
Larque AB, et al. *Mod Pathol* 2014; 27: 343-51

Vagina

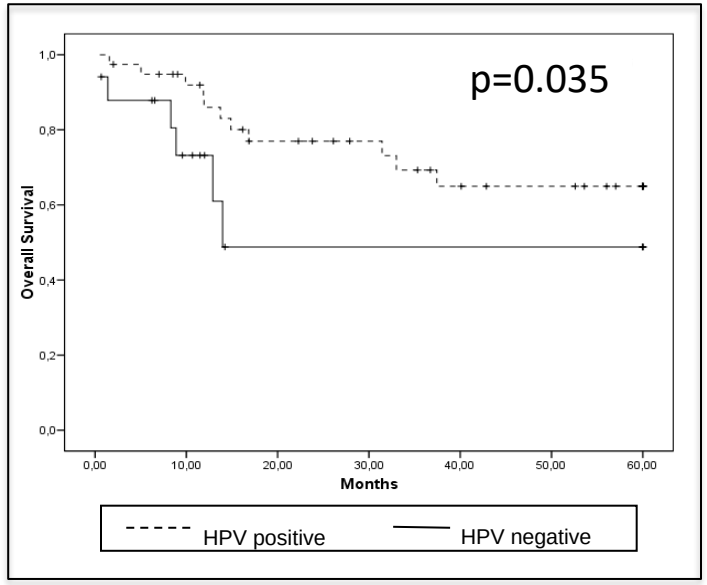

Alonso I, et al. *Gynecol Oncol* 2012; 125: 194-9

Uterine cervix

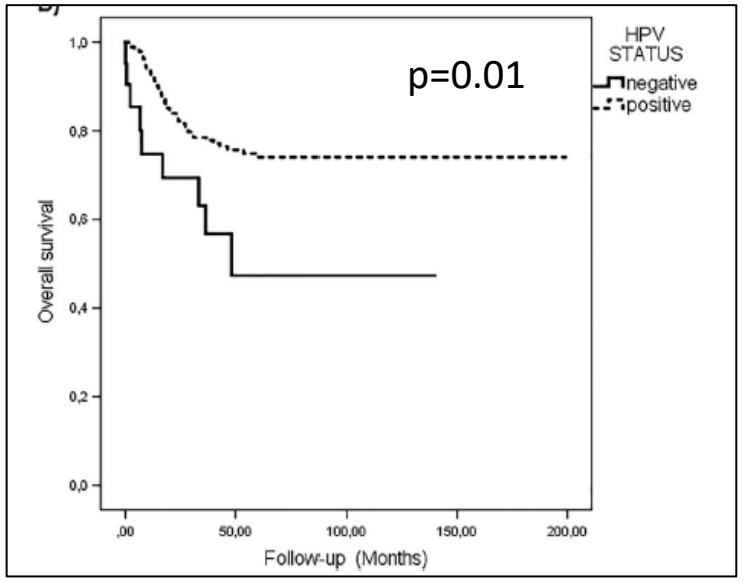

Nicolas I, et al. *Mod Pathol* 2019; 32:1189-96

Vulval carcinoma: HPV and prognosis

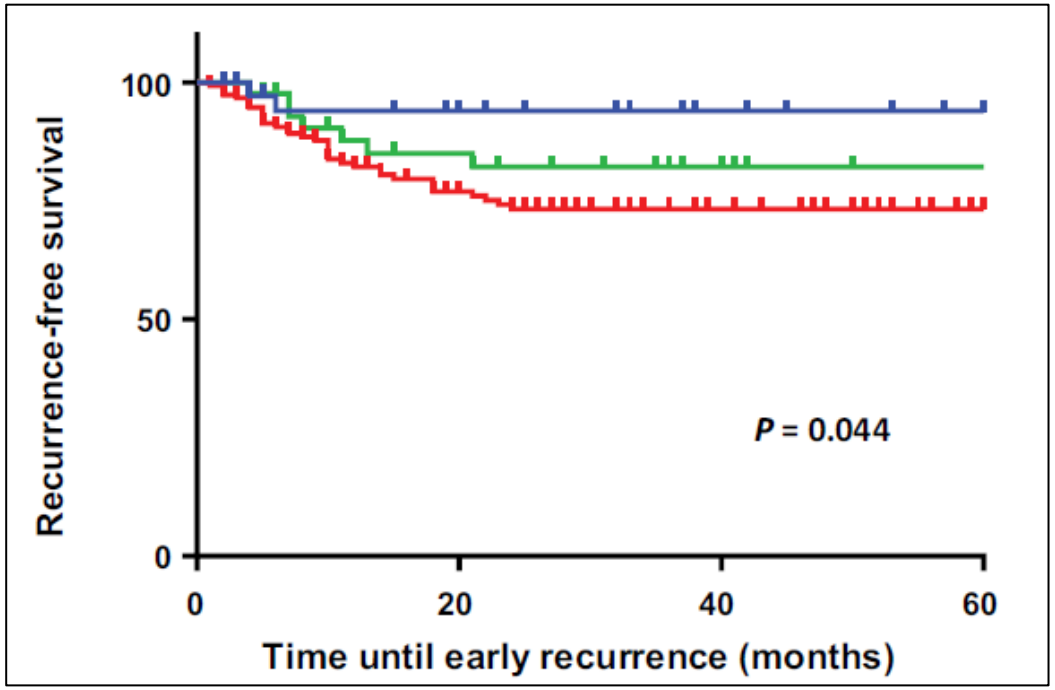

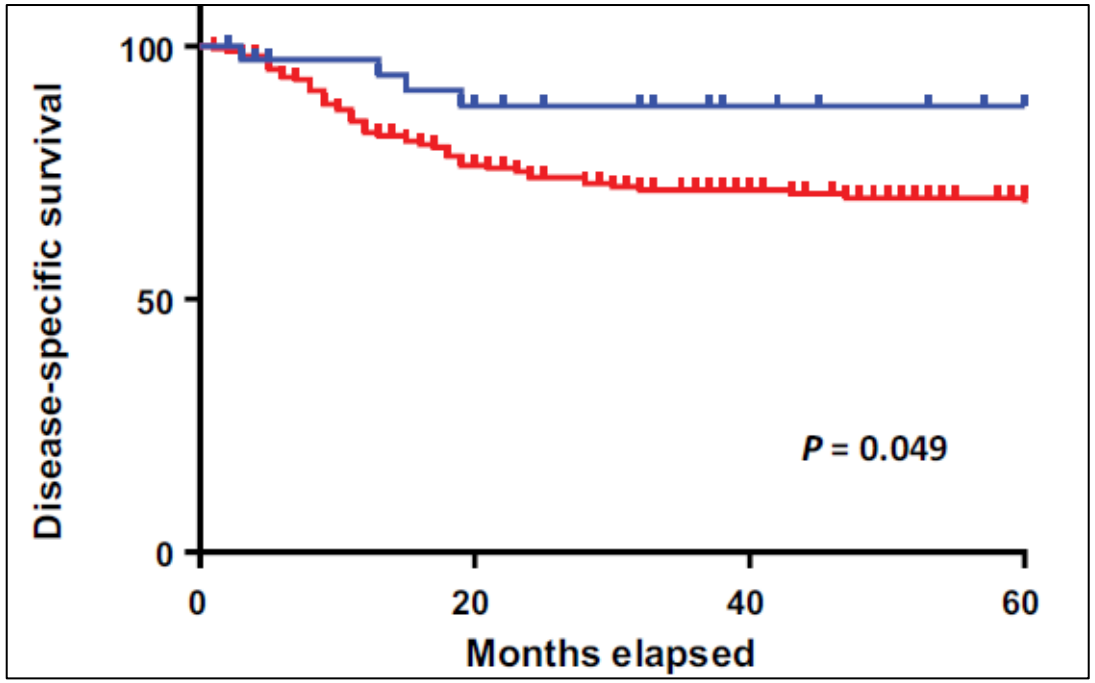

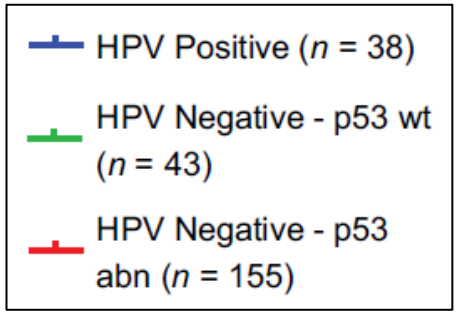

Nooij LS, et al. *Clin Cancer Res* 2018; 23(22); 6781–9

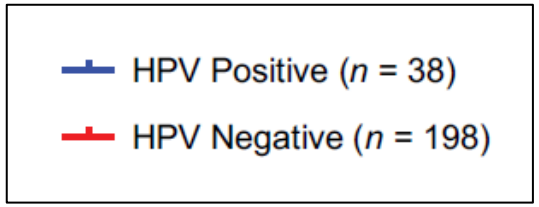

WHO 2020 classification

1. **Squamous cell carcinoma HPV-associated**

2. **Squamous cell carcinoma HPV-independent**

3. Squamous cell carcinoma NOS

Outline

1. Identification of HPV in vulvar tumors
2. Invasive squamous cell carcinomas of the vulva
3. **Precursors of VSCC**
4. Molecular aspects of VSCC

Precursors of VSCC

- Most VSCC originate in intraepithelial lesions
- Epithelial disorders found adjacent to VSCC in 50-70% of patients

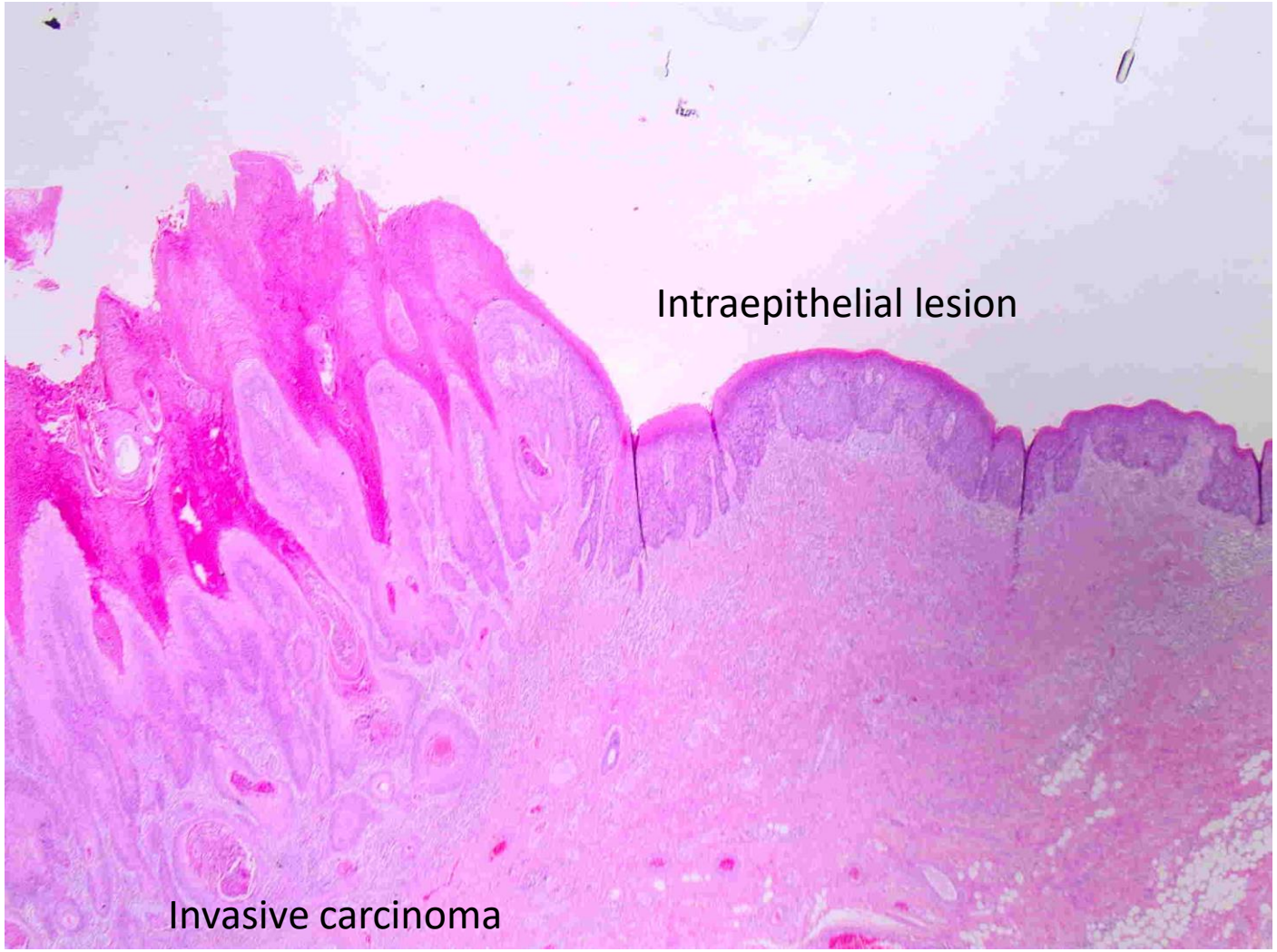

WHO 2020 classification. Precursors

1. **HPV-associated precursor: squamous intraepithelial lesion (SIL)**

2. **HPV-independent precursors**

    a. **Differentiated VIN**

    b. Other precursors (vulvar acanthosis with altered differentiation [VAAD], differentiated exophytic vulvar intraepithelial lesion [DEVIL])

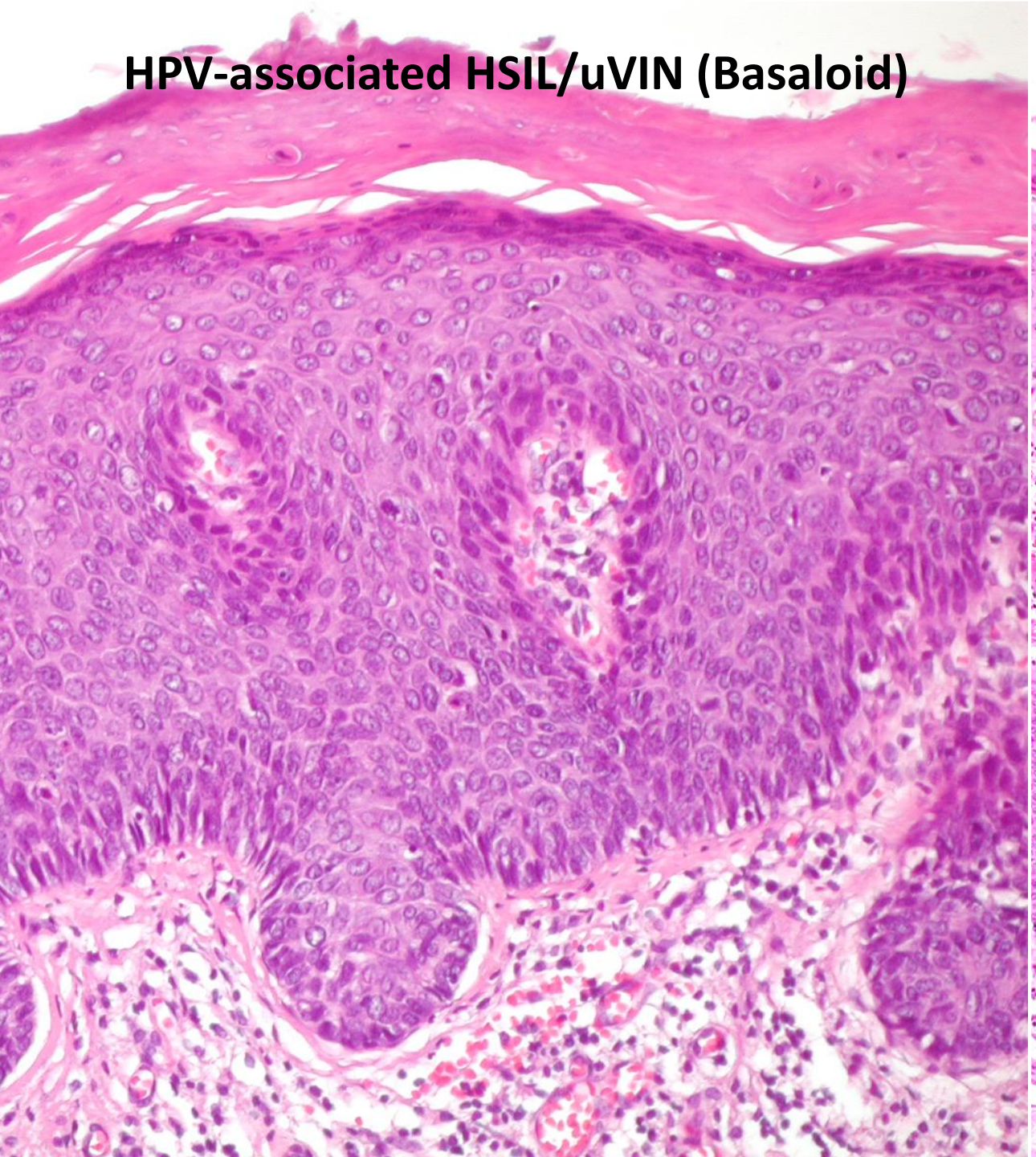
HPV-associated HSIL/uVIN (Basaloid)

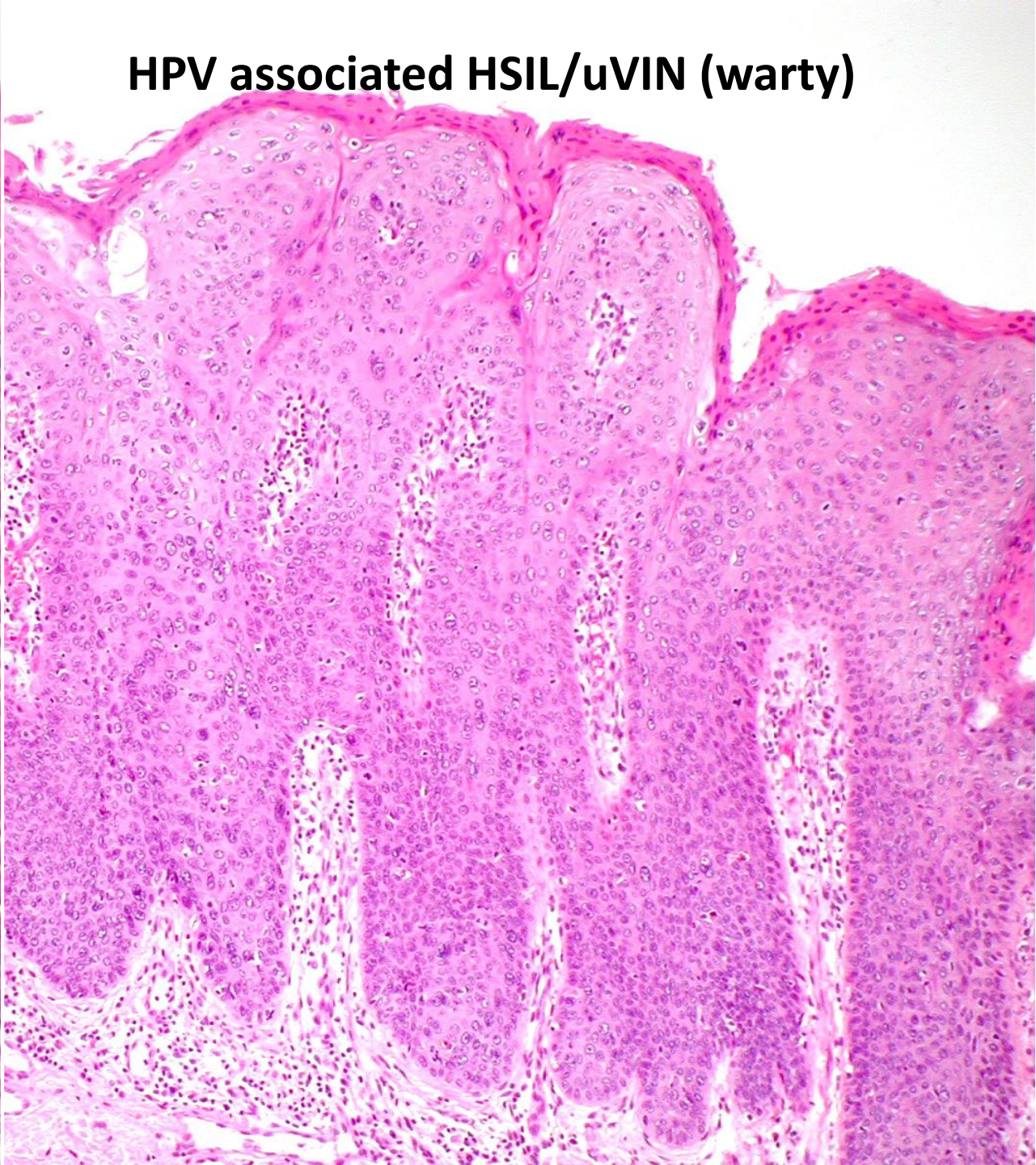
HPV associated HSIL/uVIN (warty)

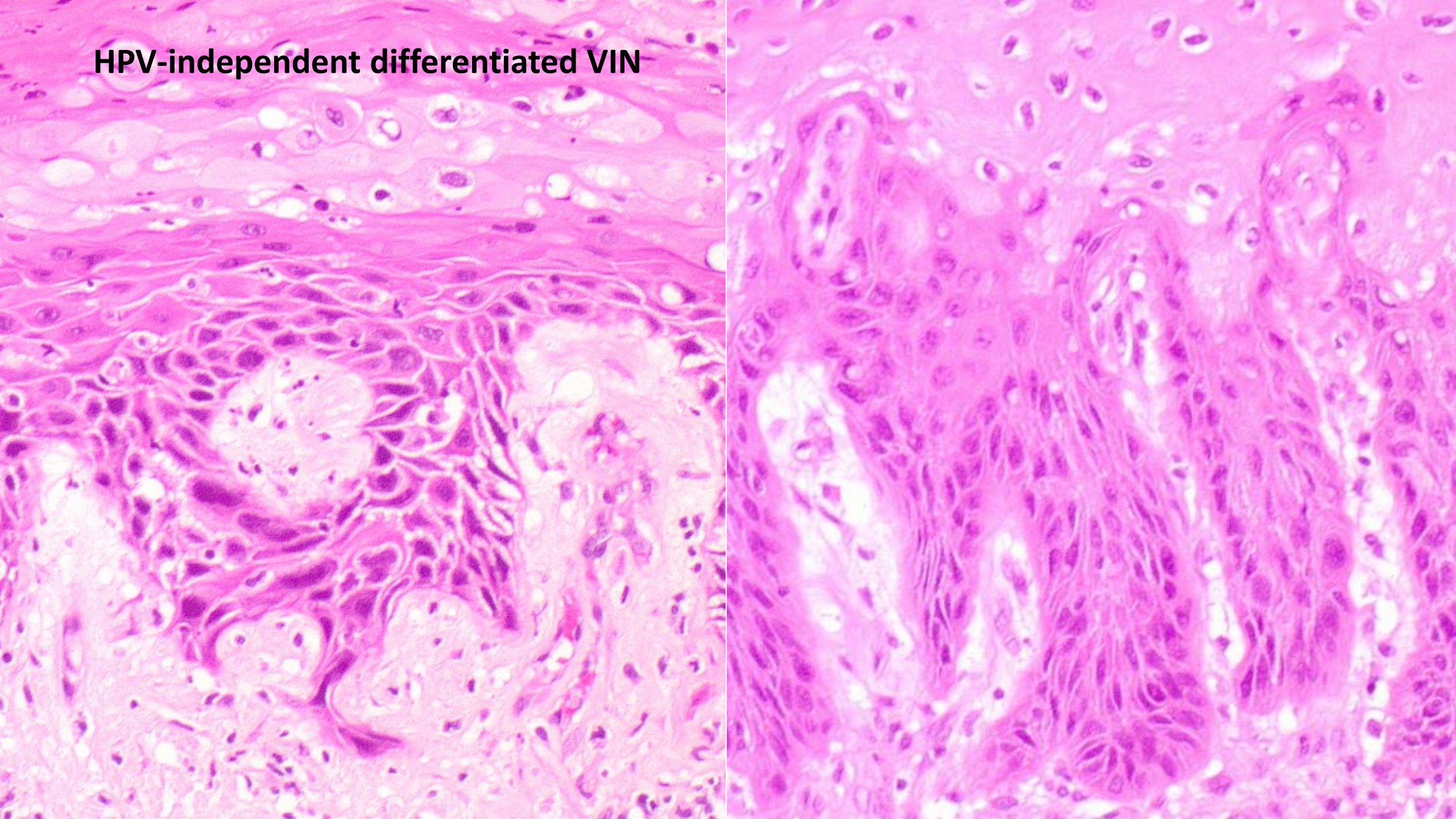
HPV-independent differentiated VIN

Differentiated VIN and LS

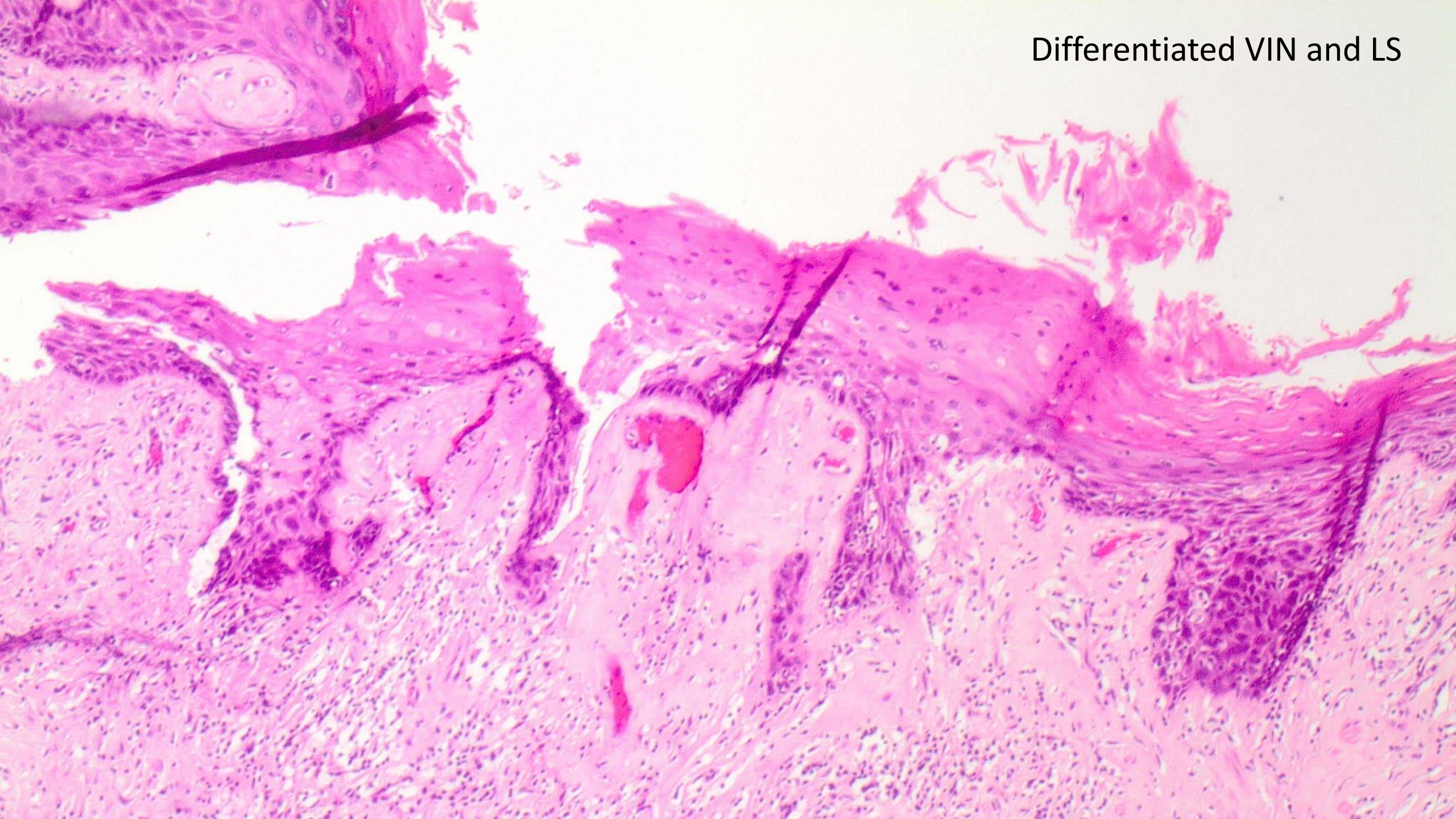

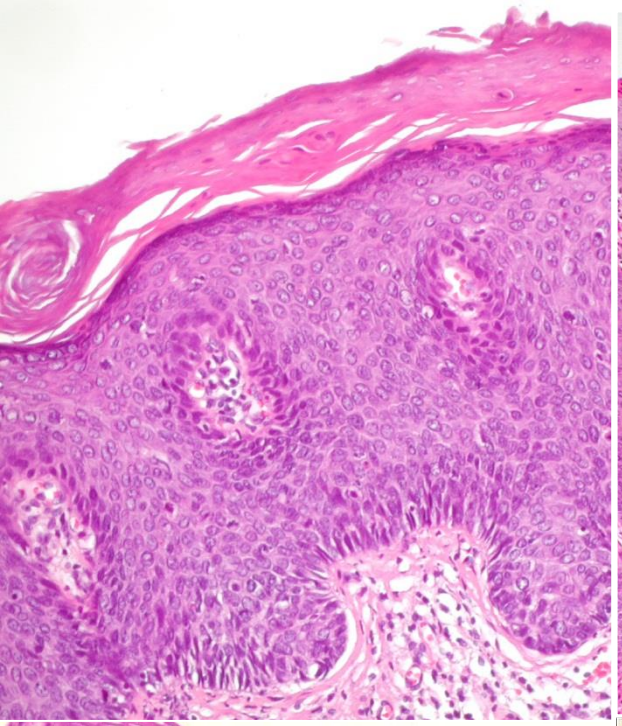
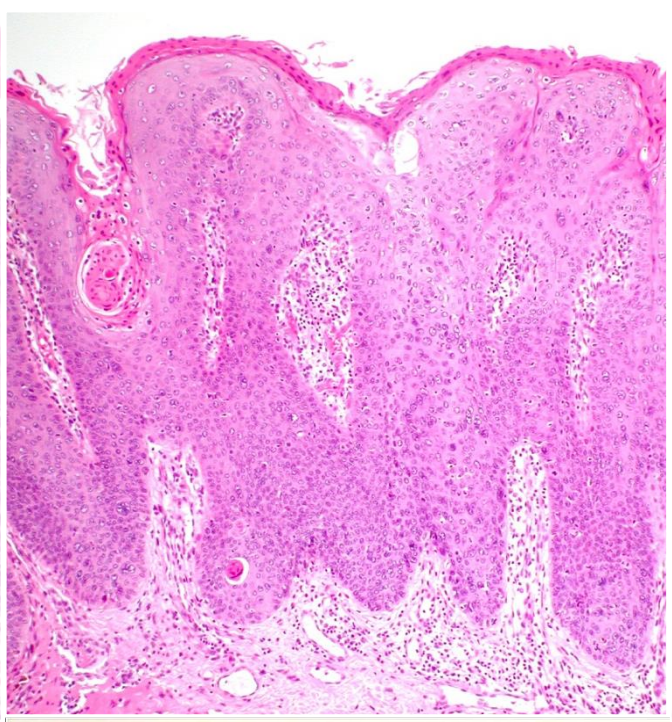
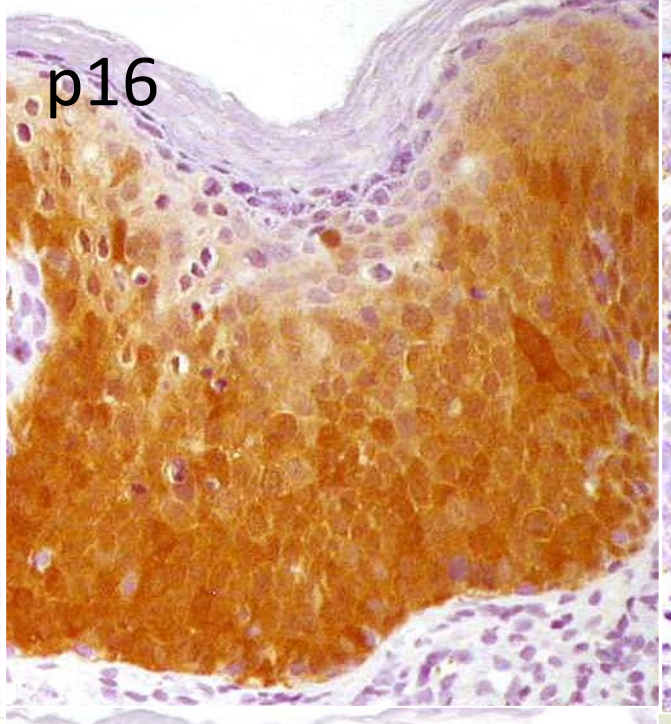
p16
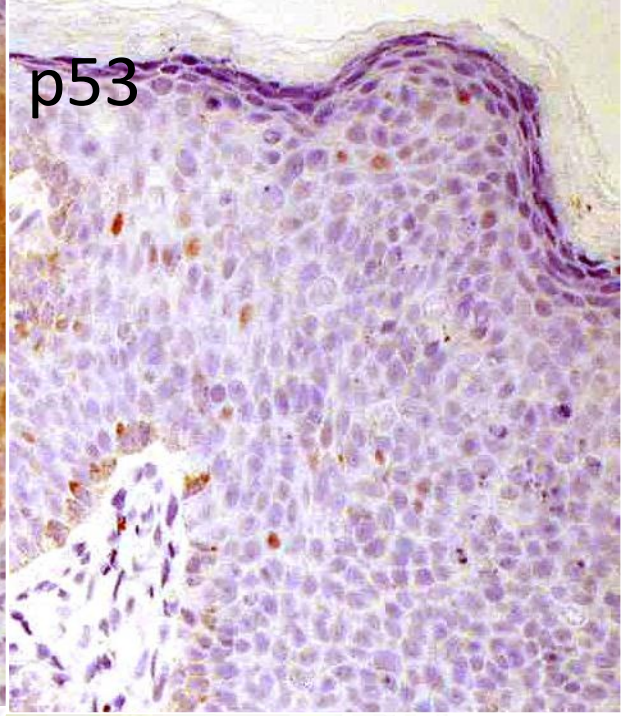
p53
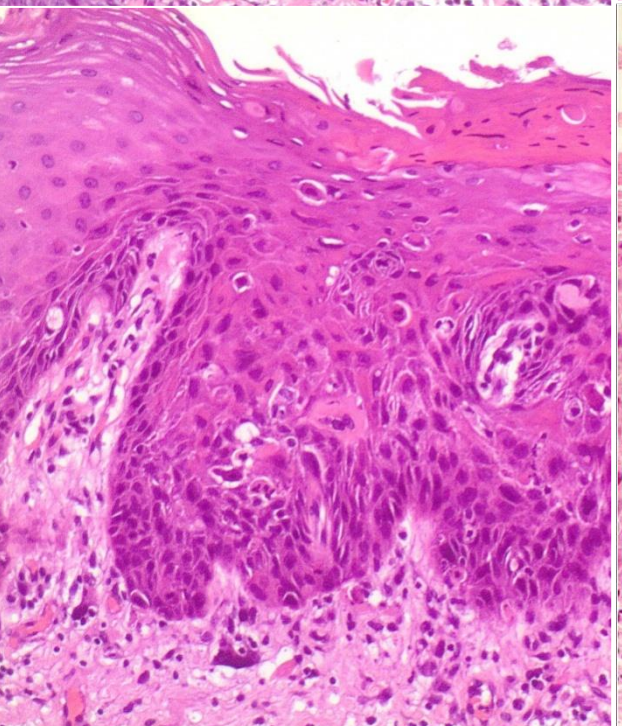
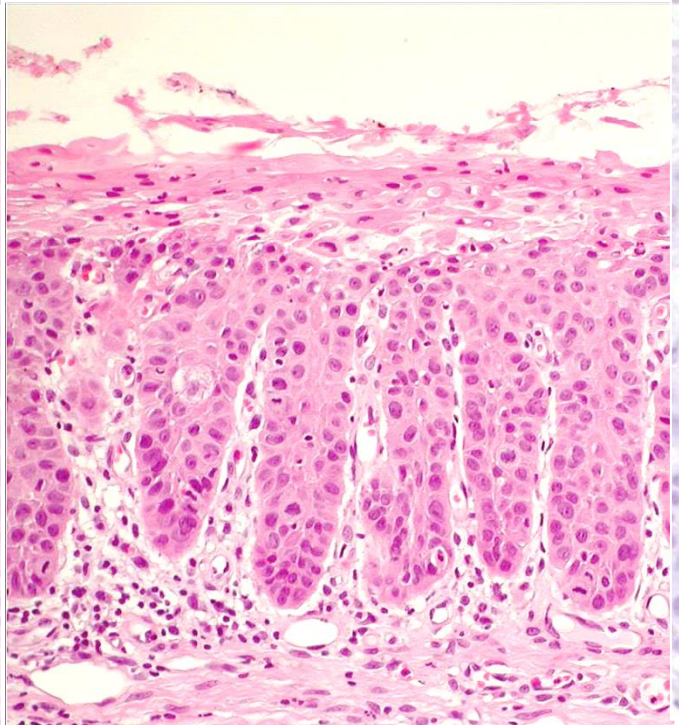
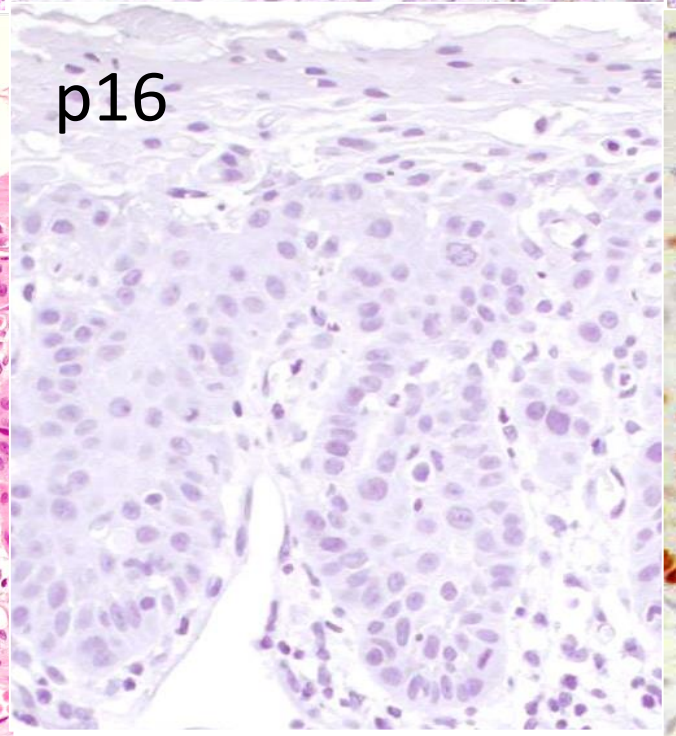
p16
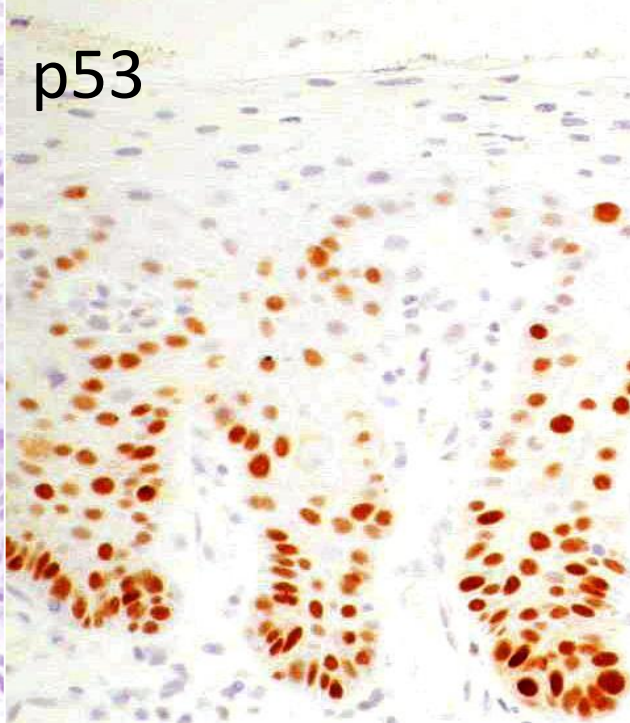
p53

Precursors of VSCC and HPV

	HPV-associated (HSIL)	HPV-independent (dVIN)
Other names	uVIN, Basaloid , warty VIN, Bowen's disease, bowenoid papulosis	Simplex VIN
Associated lesions	Tumors or premalignant lesions of cervix, vagina, anus (71%)	Lichen sclerosus
Immunohistochemistry	p16	p53
Risk of progression	**Low** (≈5% in untreated patients) (Jones et al, *Obstet Gynecol* 2005, 106:1319-26)	**High** (Bigby et al, *Int J Gynecol Pathol* 2016; 35: 574-84; Eva et al, *Int J Gynecol Cancer* 2009; 19: 741)

Rakislova N, et al. *Adv Anat Pathol* 2017; 24:201-14

Precursors of VSCC: Controversies

1. How reliable is the differentiation between HSIL and dVIN?
2. How reproducible is the diagnosis of dVIN and VAAD?
3. Does LSIL /VIN1 exist in the vulva?
4. Precursor lesions other than dVIN

Precursors of VSCC: Controversies

1. **How reliable is the differentiation between HSIL and dVIN?**
2. How reproducible is the diagnosis of dVIN and VAAD?
3. Does LSIL /VIN1 exist in the vulva?
4. Precursor lesions other than dVIN

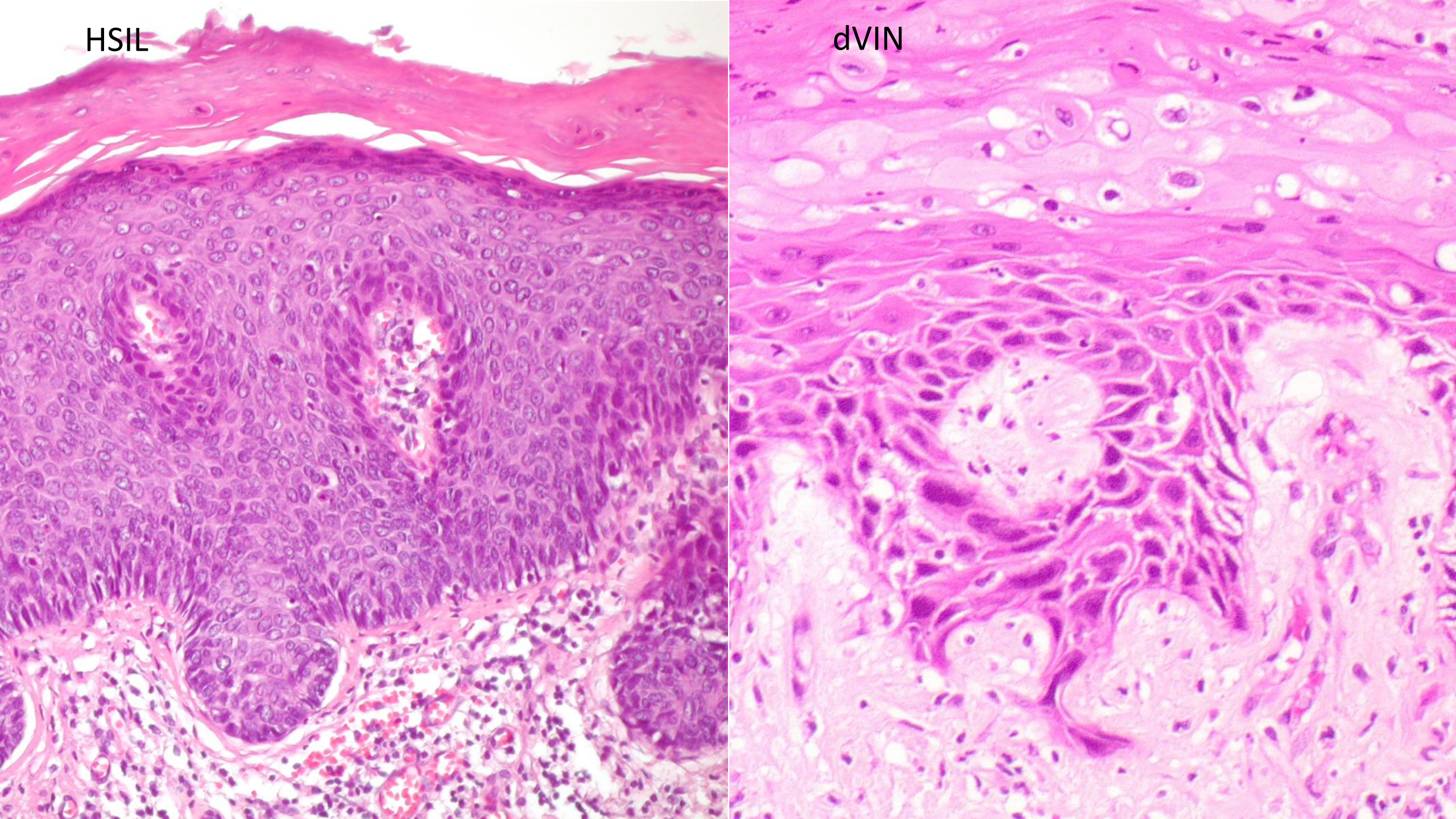
HSIL
dVIN

HSIL/dVIN?

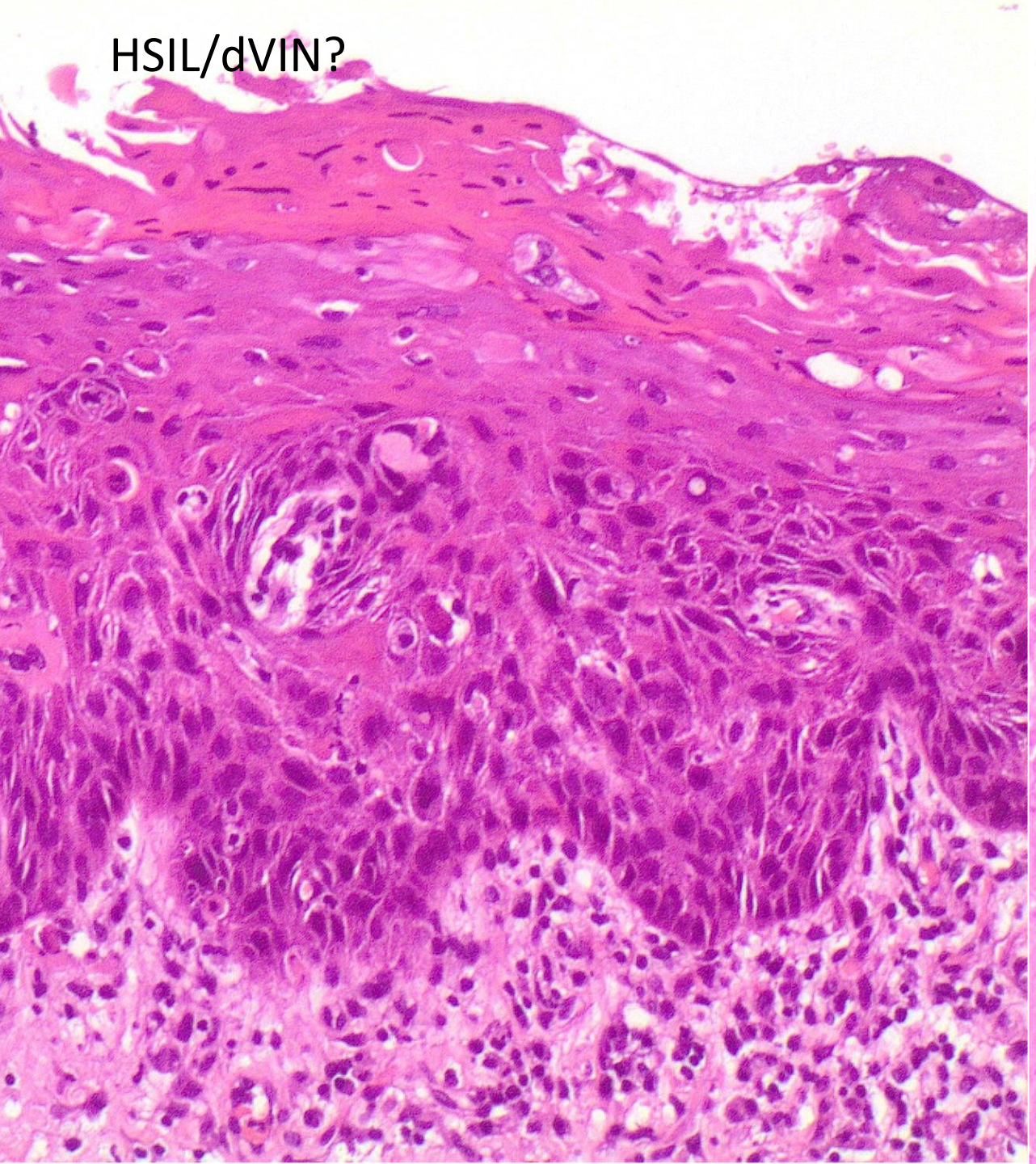

HSIL/dVIN?

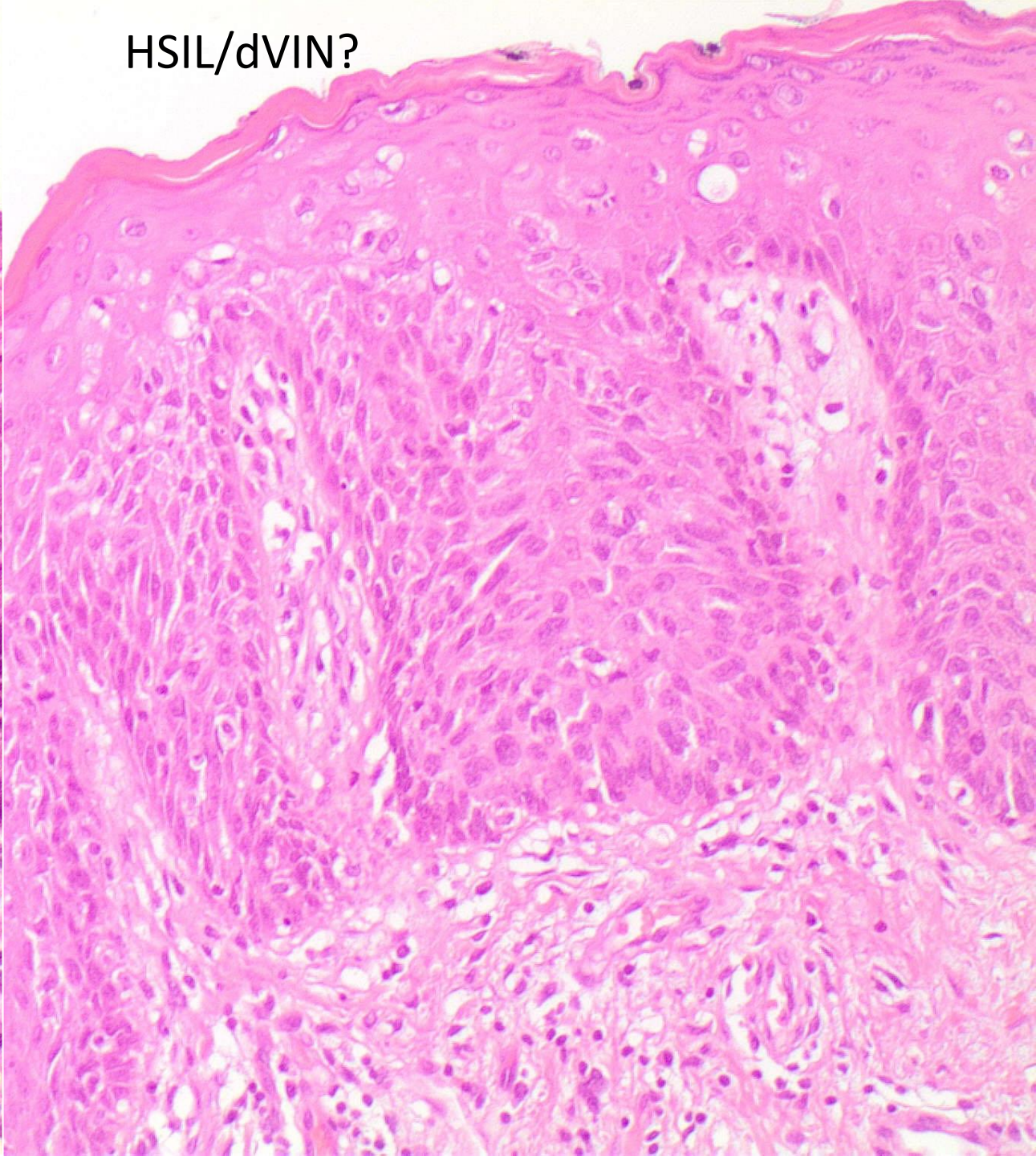

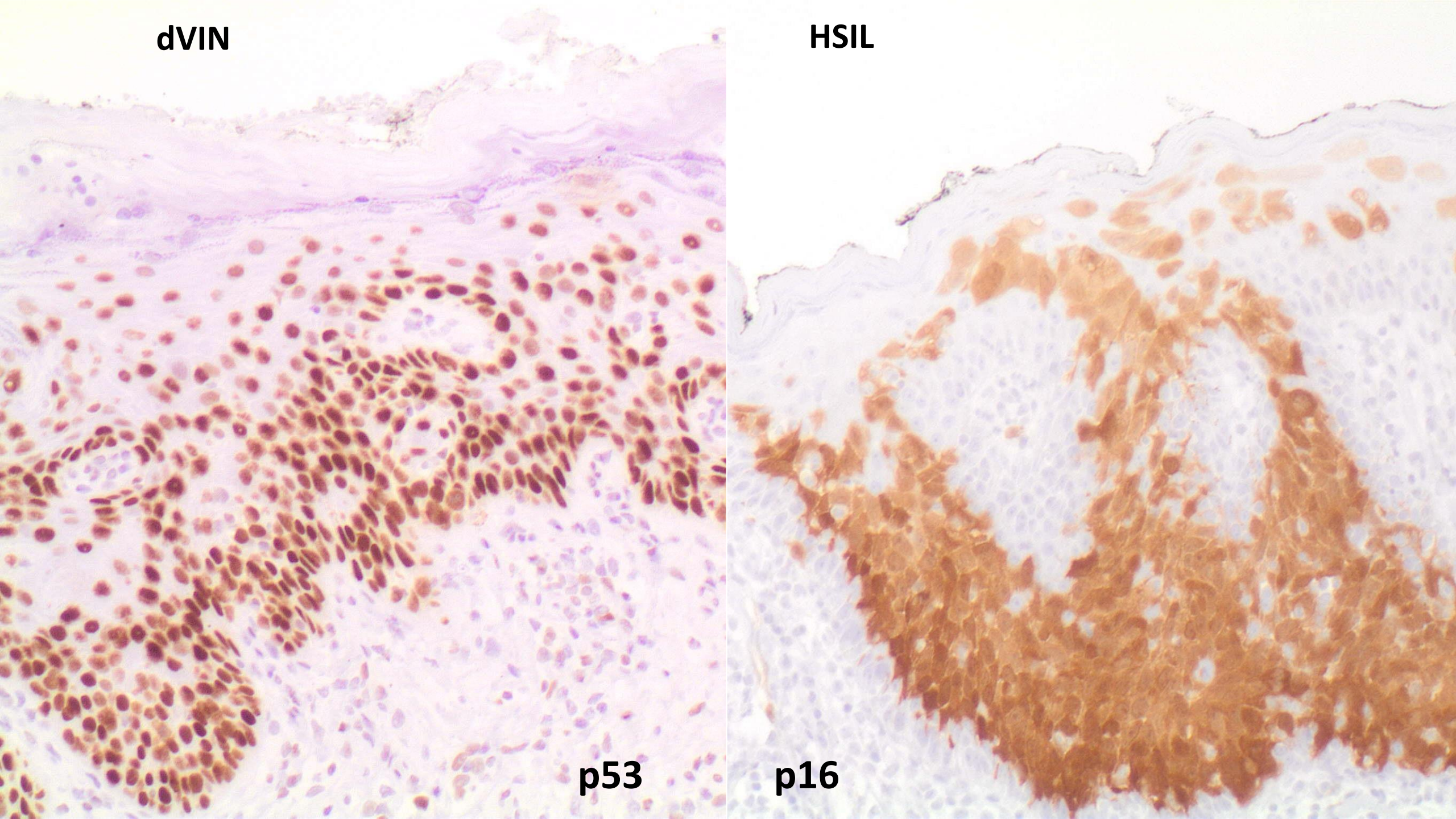
dVIN
p53
HSIL
p16

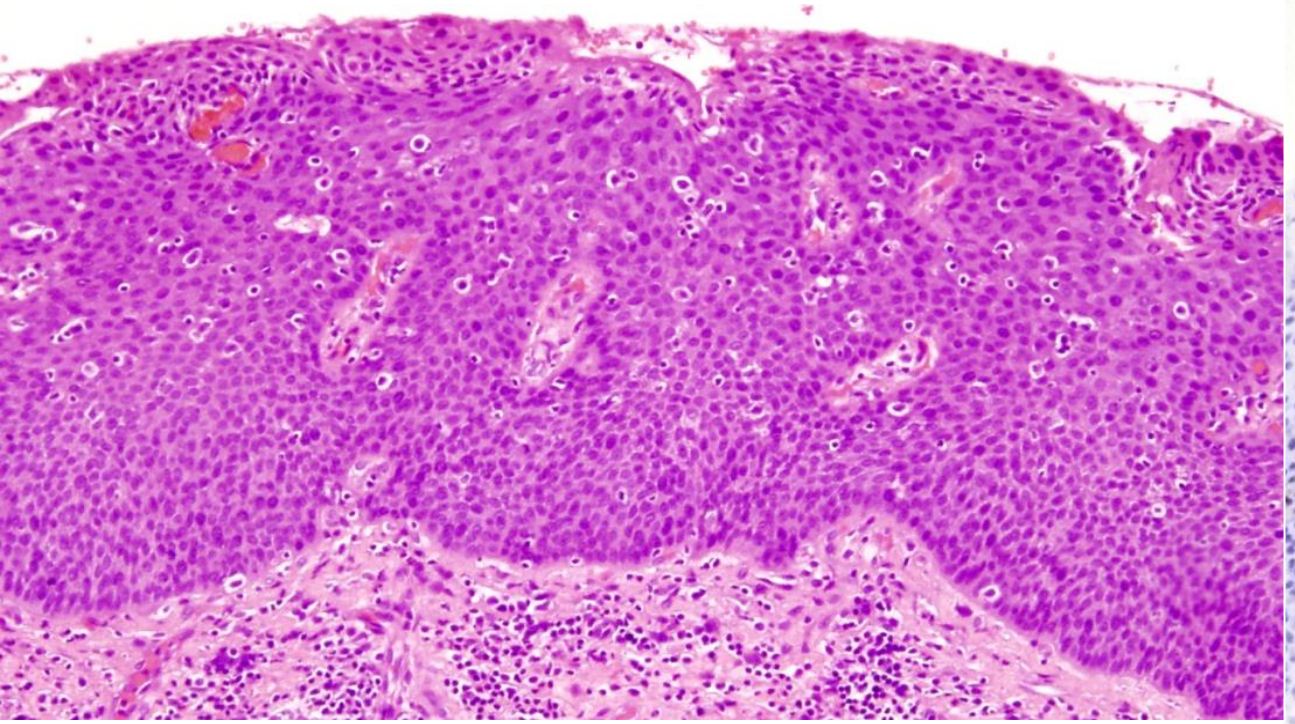

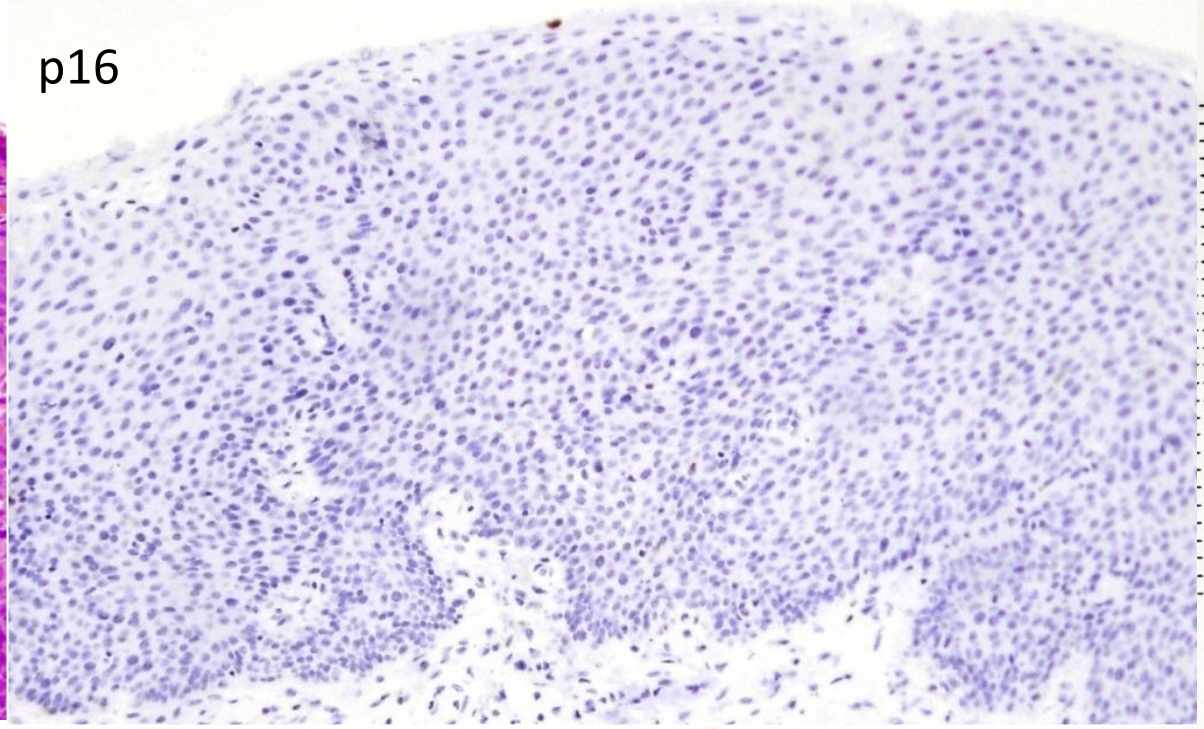
p16

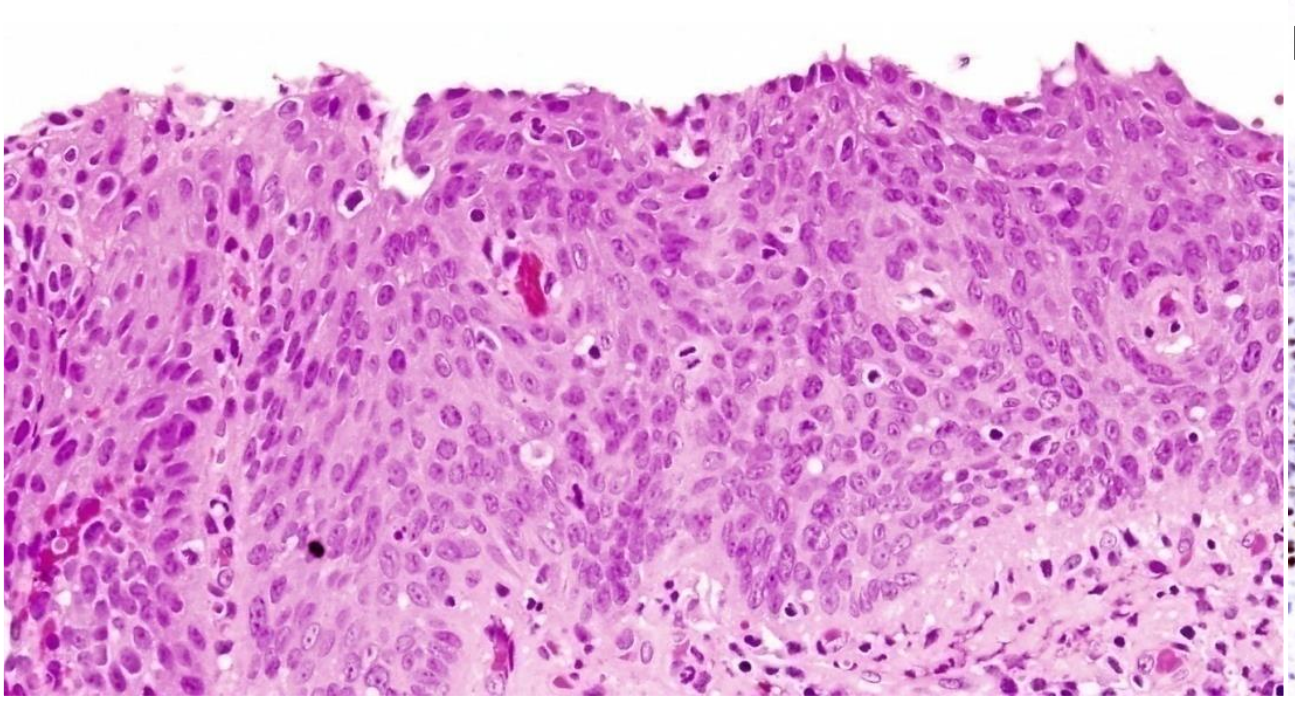

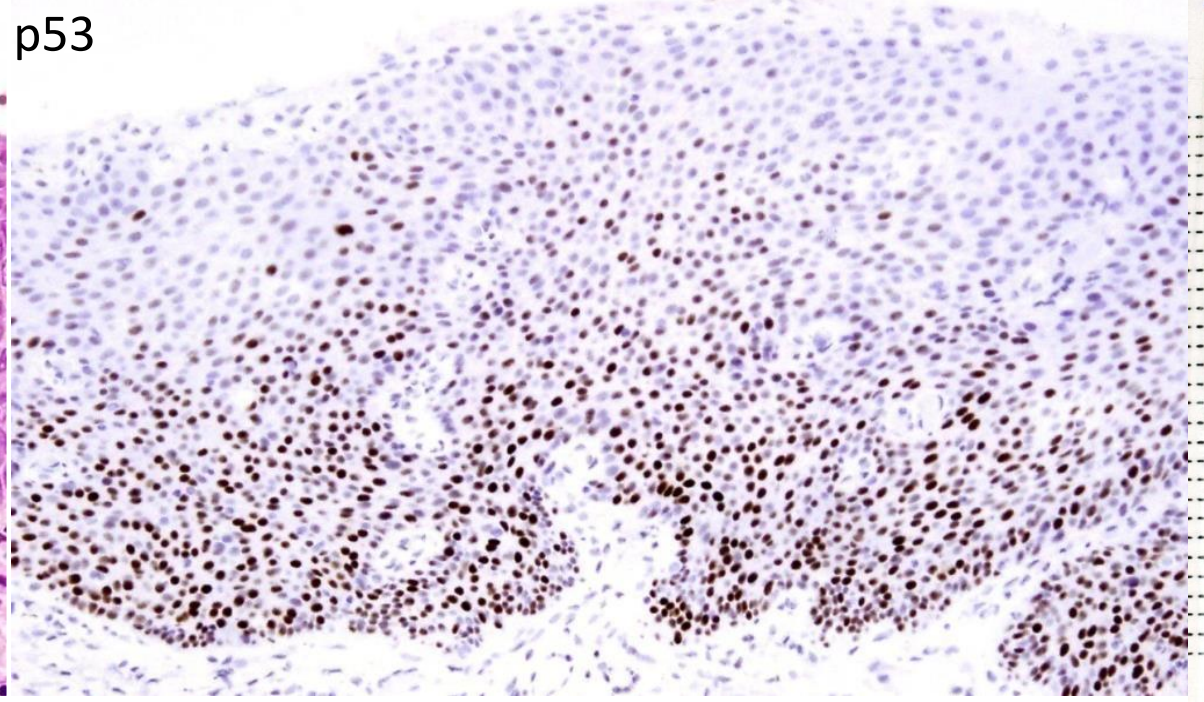
p53

dVIN with basaloid features

- 8 % of differentiated VIN

Case	Age	p16	Invasive carcinoma
1	60	Lichen sclerosus	Basaloid
2	62	-	Keratinizing
3	76	Lichen simplex chronicus	Keratinizing
4	45	Lichen simplex chronicus	Keratinizing

Ordi J, et al. *Am J Surg Pathol* 2009; 33:1659-65
Rakislova N, et al. *Int J Mol Sci* 2020;21:8091


dVIN basaloid-like

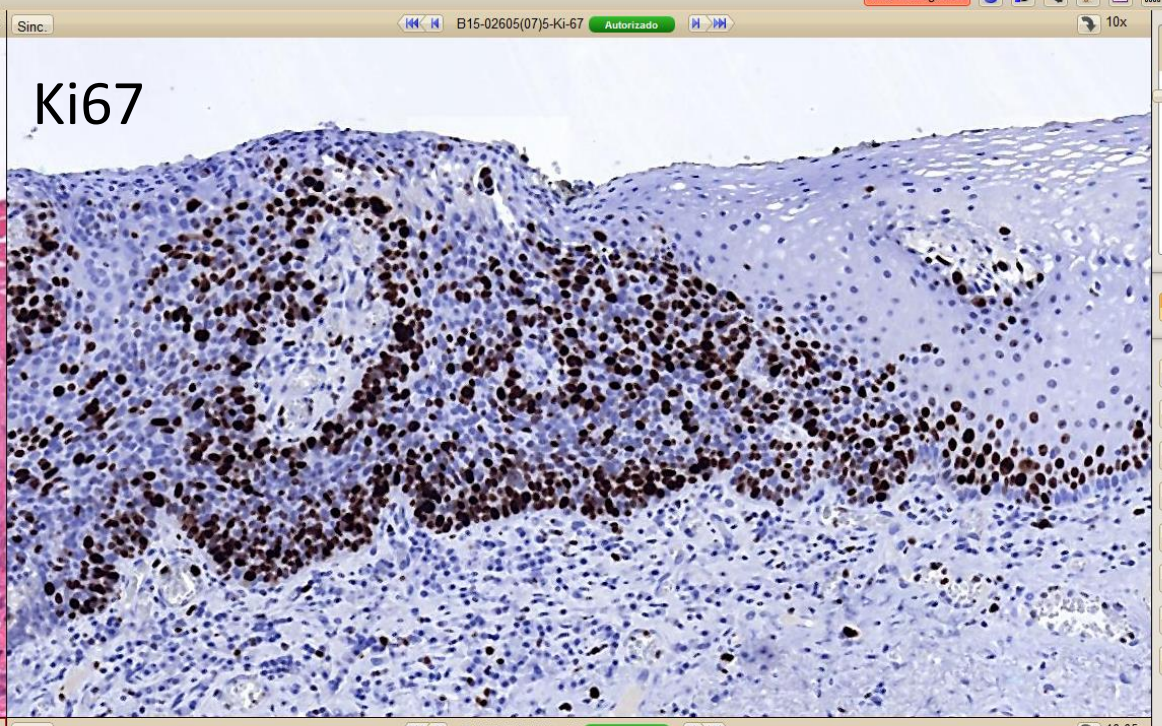
Ki67

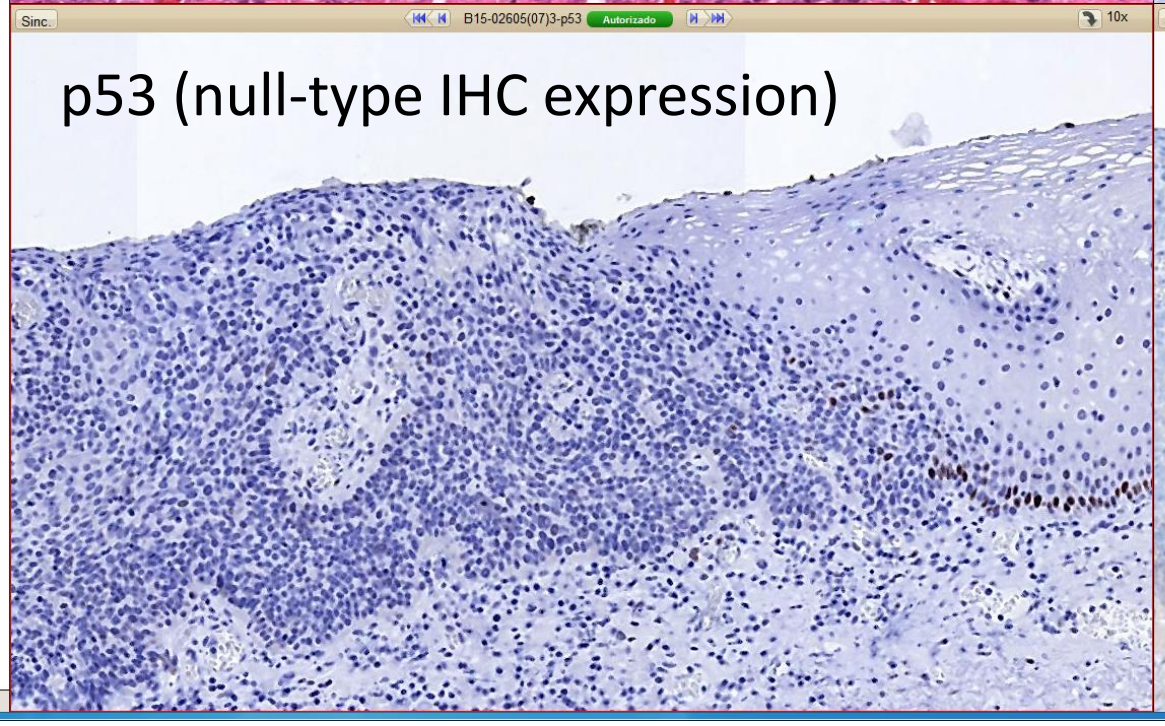
p53 (null-type IHC expression)

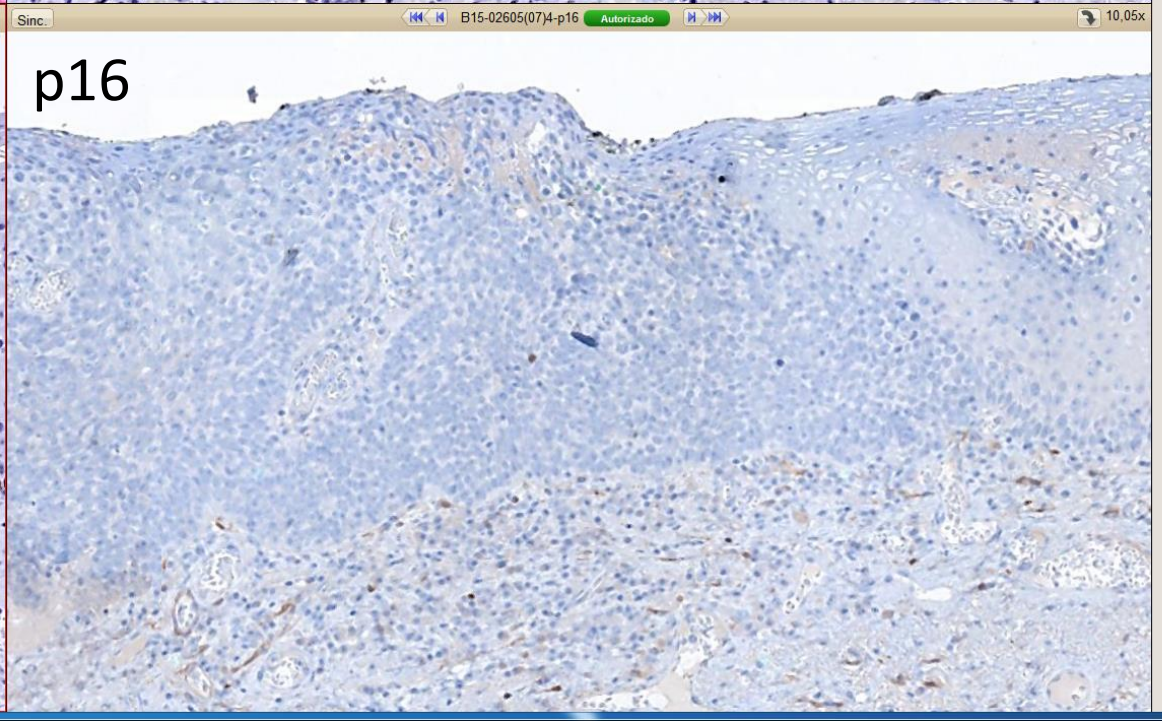
p16


dVIN warty-like

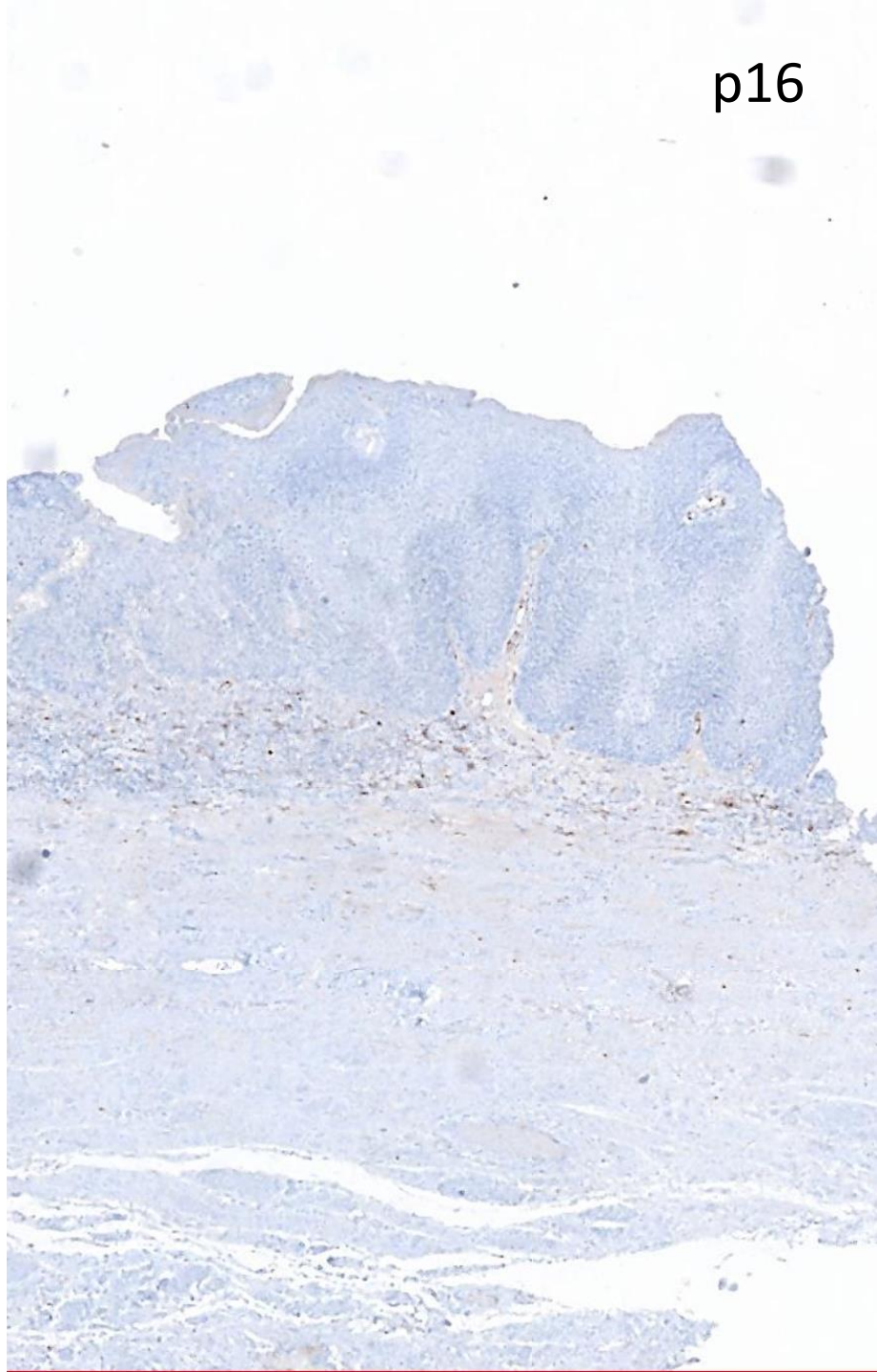
p16

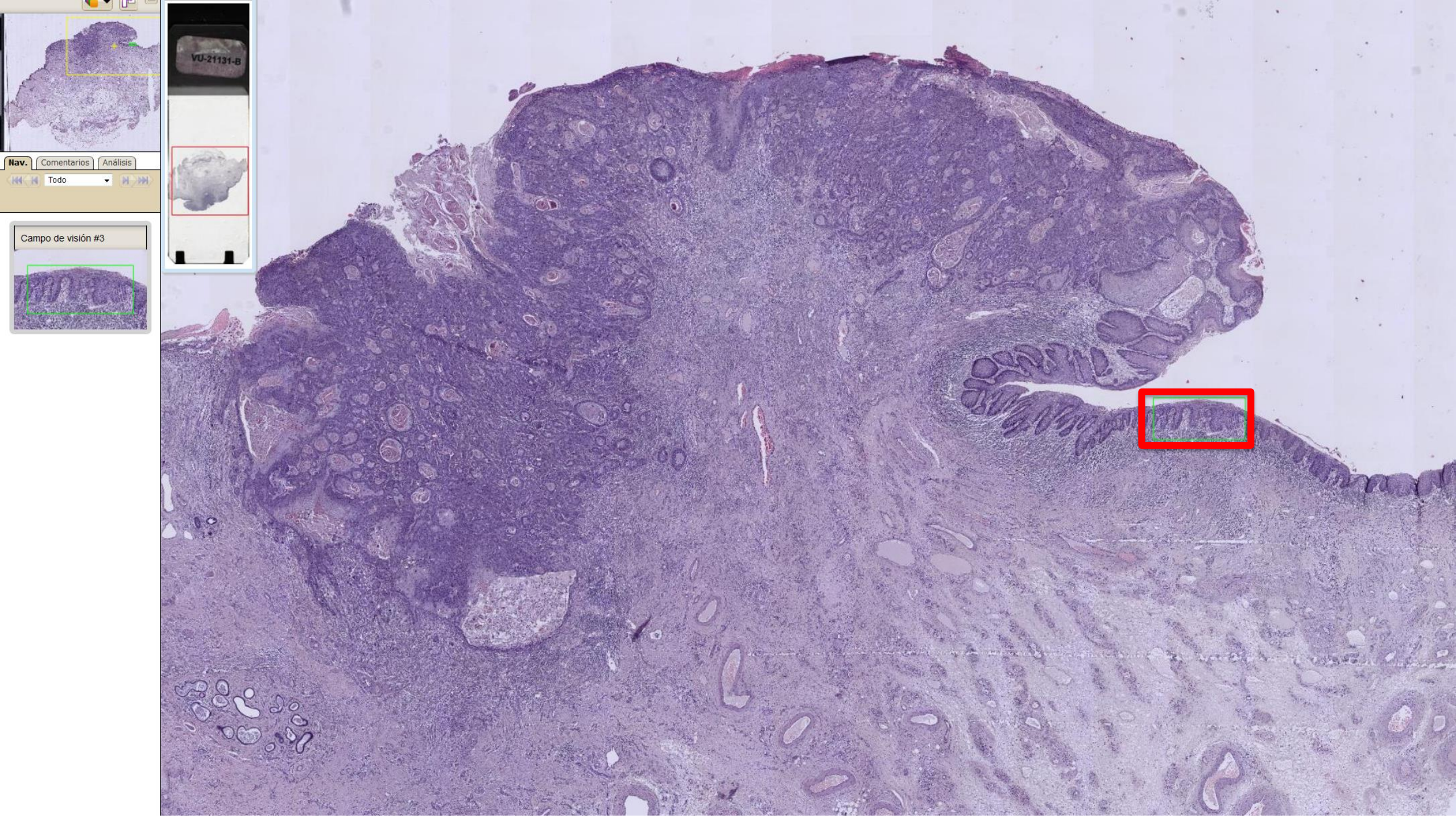
VU-21131-B
Nav.
Comentarios
Análisis
Todo
Campo de visión #3

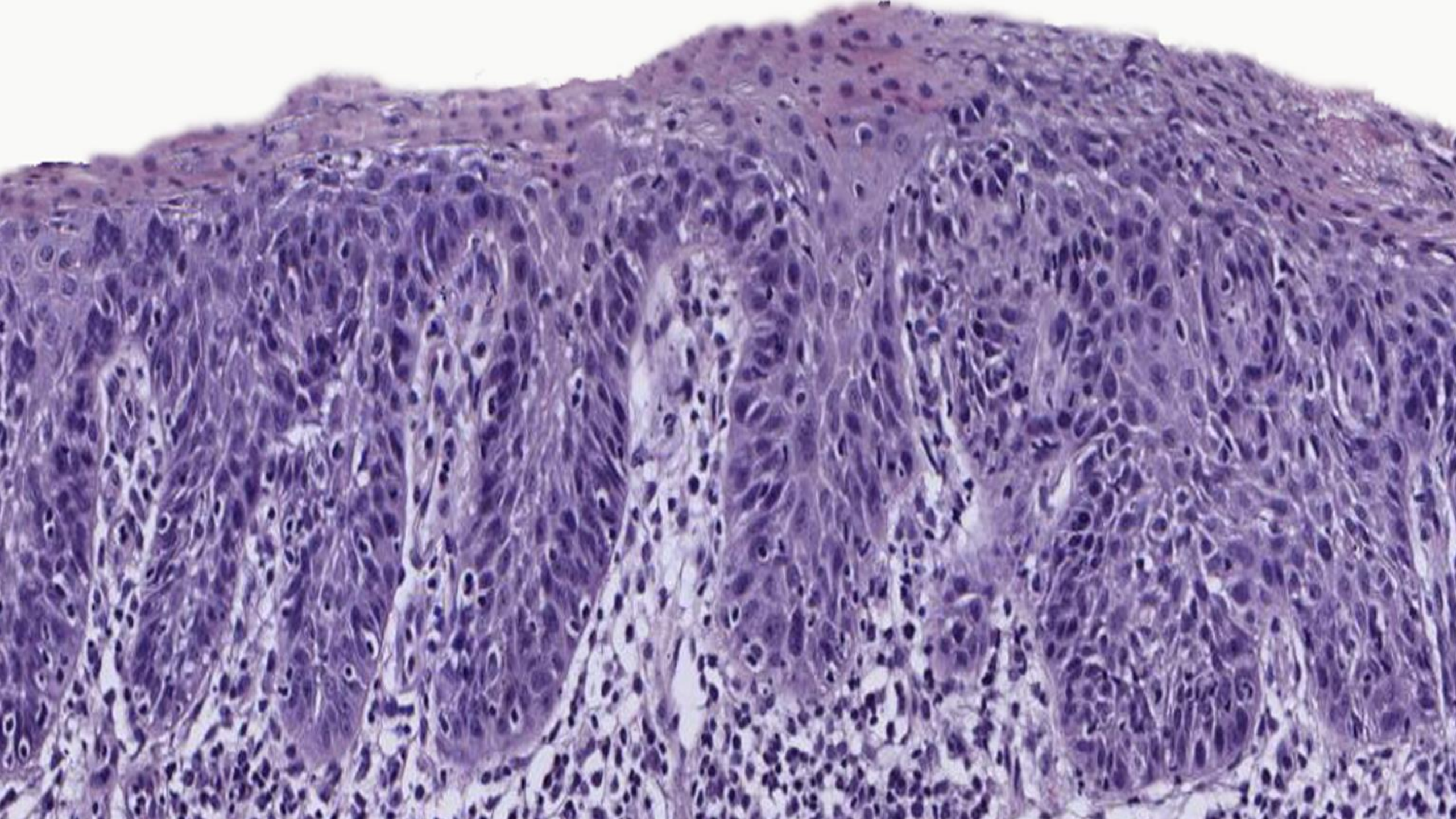

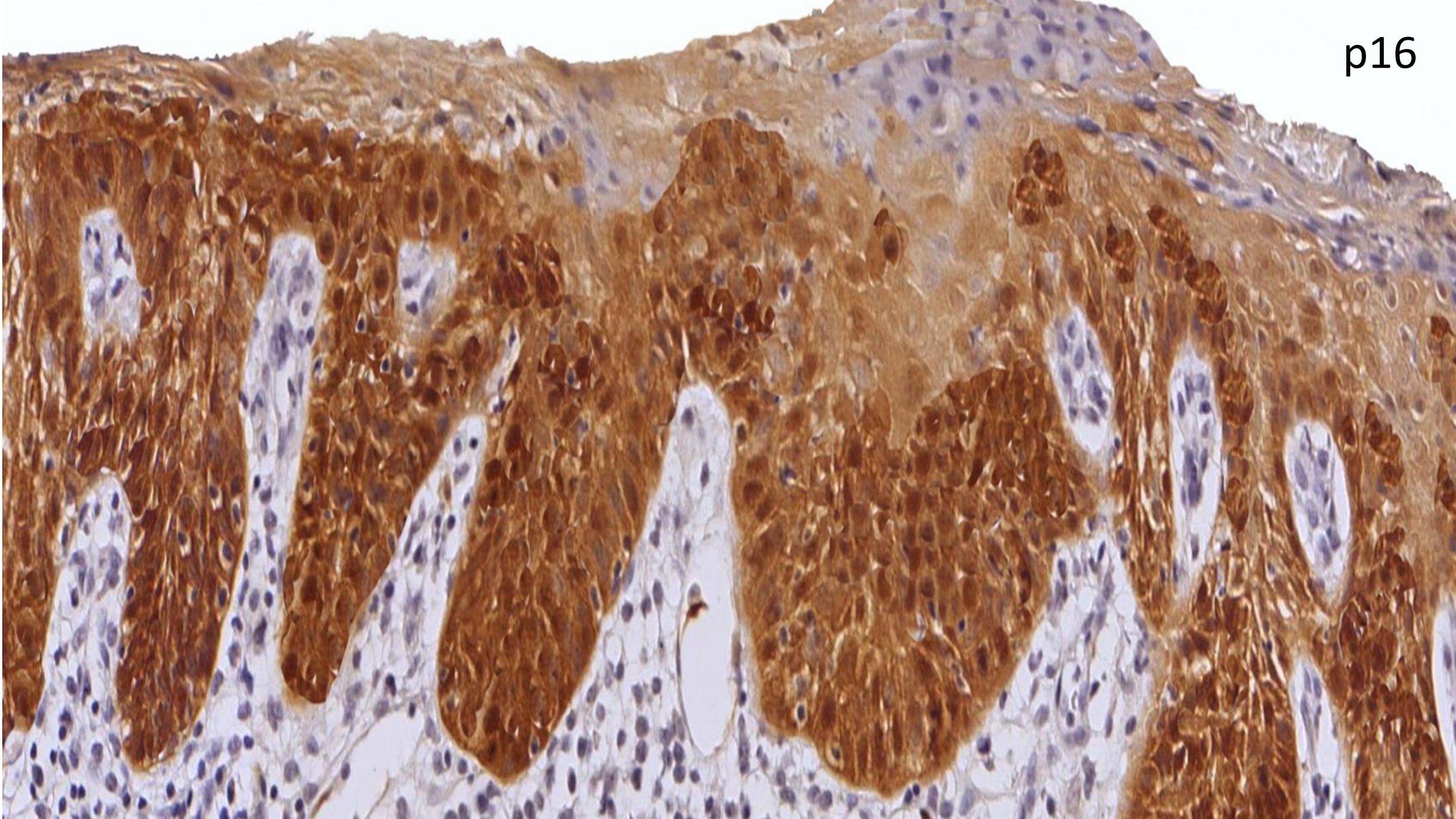
p16

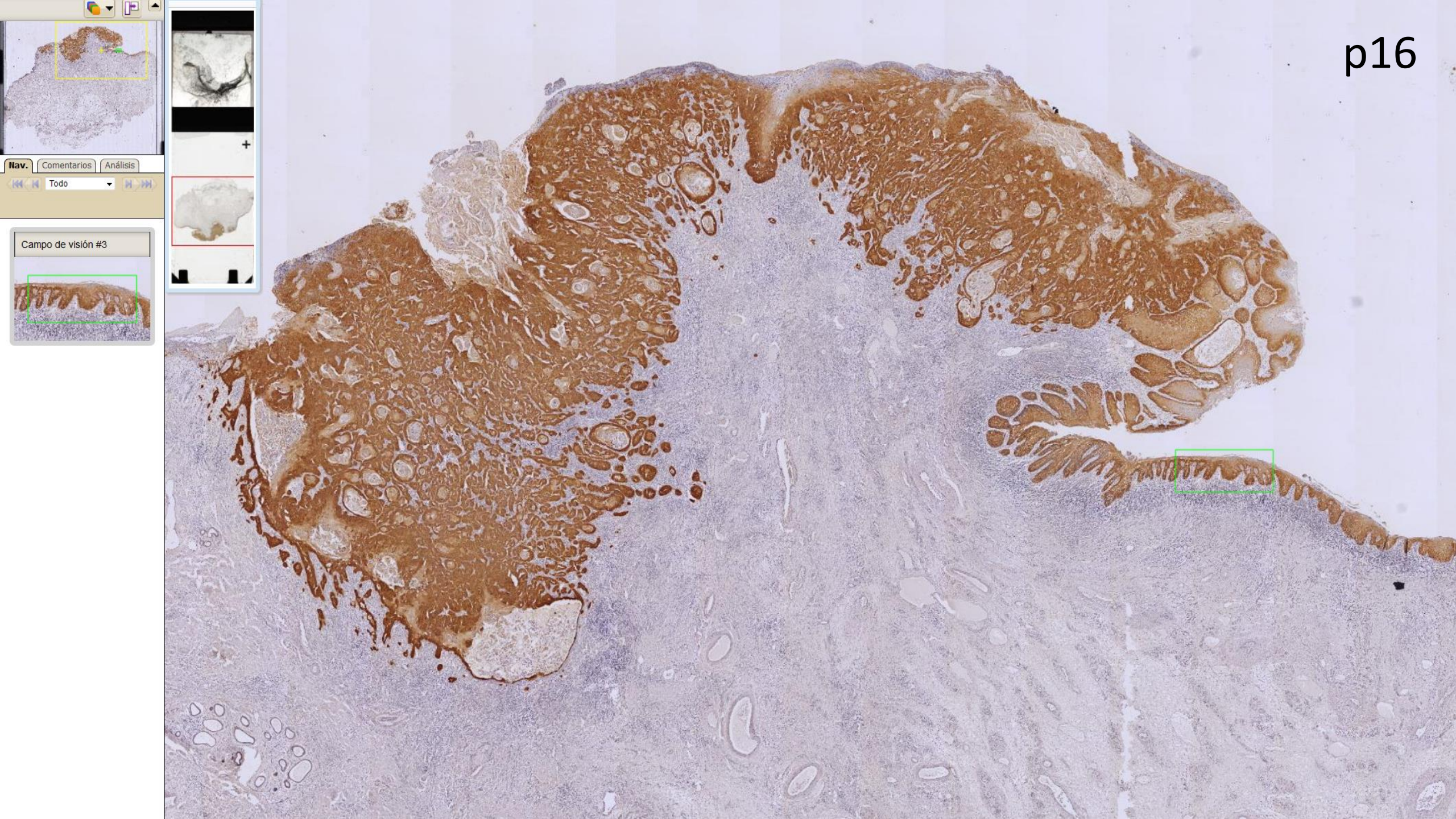
p16
Nav.
Comentarios
Análisis
Todo
Campo de visión #3

HSIL mimicking dVIN/lichen sclerosus

Case	Intraepith. lesion	HPV type	E6 mRNA	p16	Invasive carcinoma
1	dVIN	16	+	+	Keratinizing
2	dVIN	16	+	+	Keratinizing
3	dVIN	16	+	+	Warty
4	dVIN/LS	16	+	+	Non-Keratinizing

(2% of the intraepithelial lesions in HPV-associated vulvar carcinomas)

Rakislova N, et al. *Am J Surg Pathol* 2018; 423:828-835

HSIL mimicking dVIN/lichen sclerosus

Case	Intraepith. lesion	HPV type	E6 mRNA	p16	Invasive carcinoma
1	dVIN	16	+	+	Keratinizing
2	dVIN	16	+	+	Keratinizing
3	dVIN	16	+	+	Warty
4	dVIN/LS	16	+	+	Non-Keratinizing
5	LS	16	+	+	Keratinizing
6	LS	16	+	+	Warty

(2% of the intraepithelial lesions in HPV-associated vulvar carcinomas)

Rakislova N, et al. *Am J Surg Pathol* 2018; 423:828-835

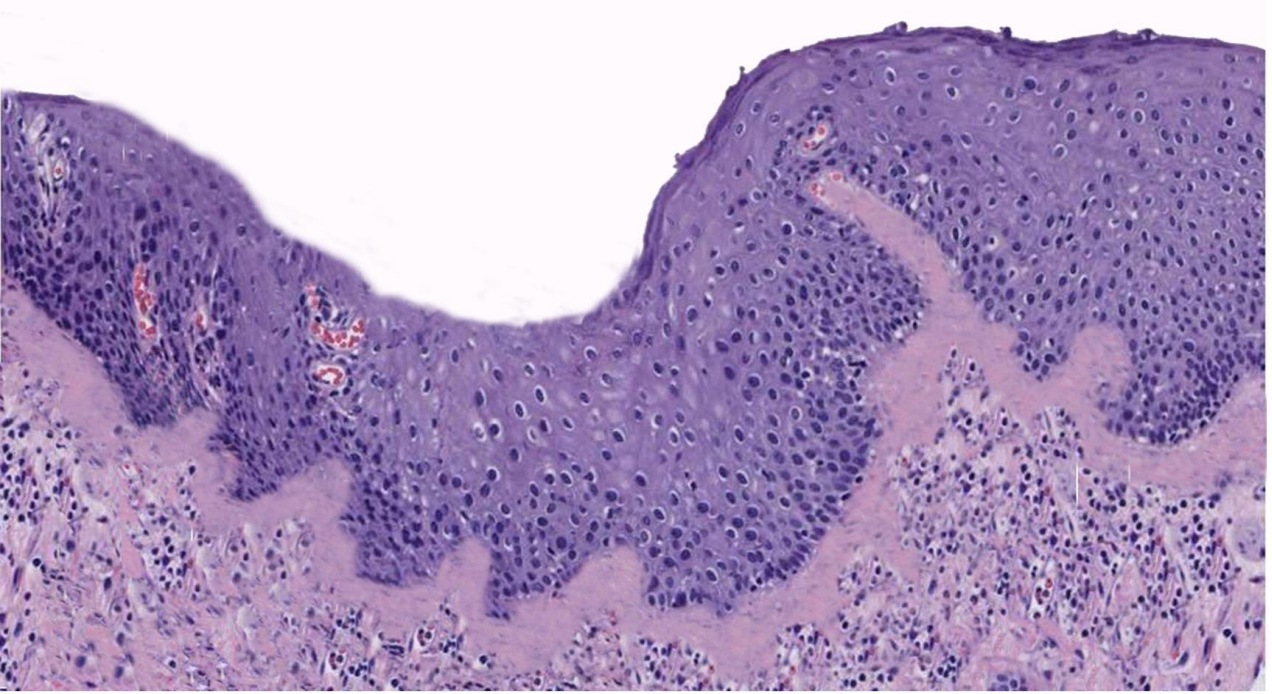

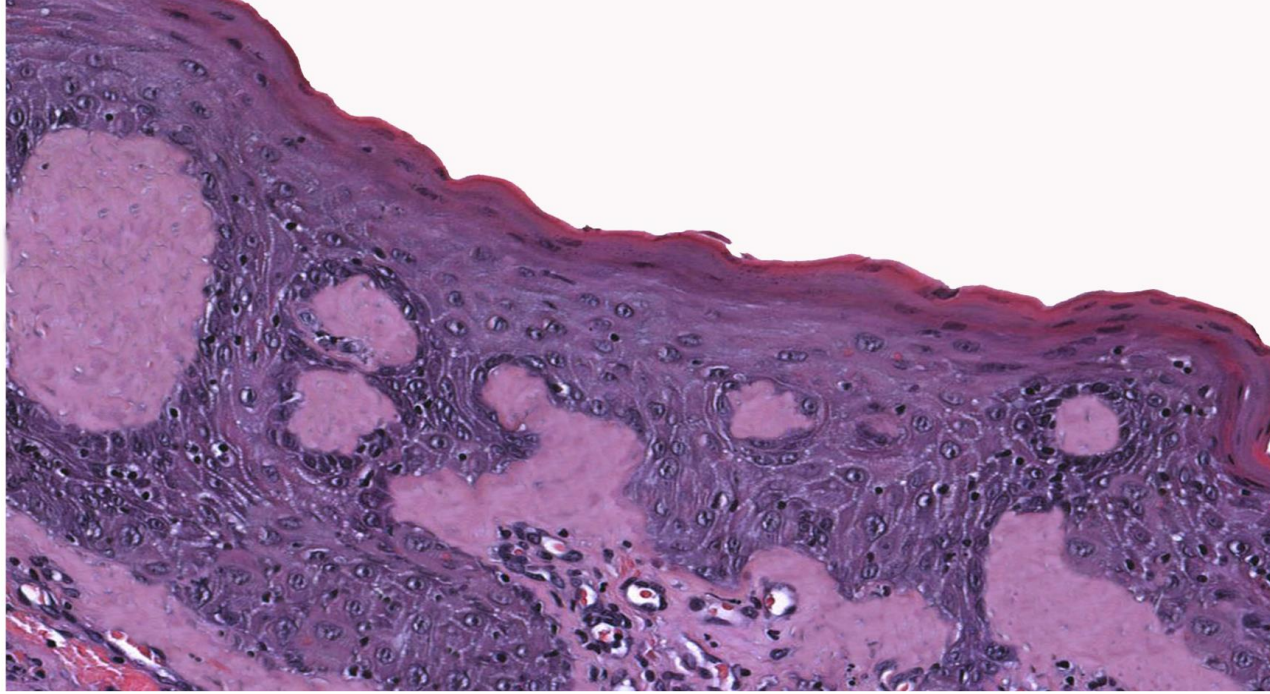

p16

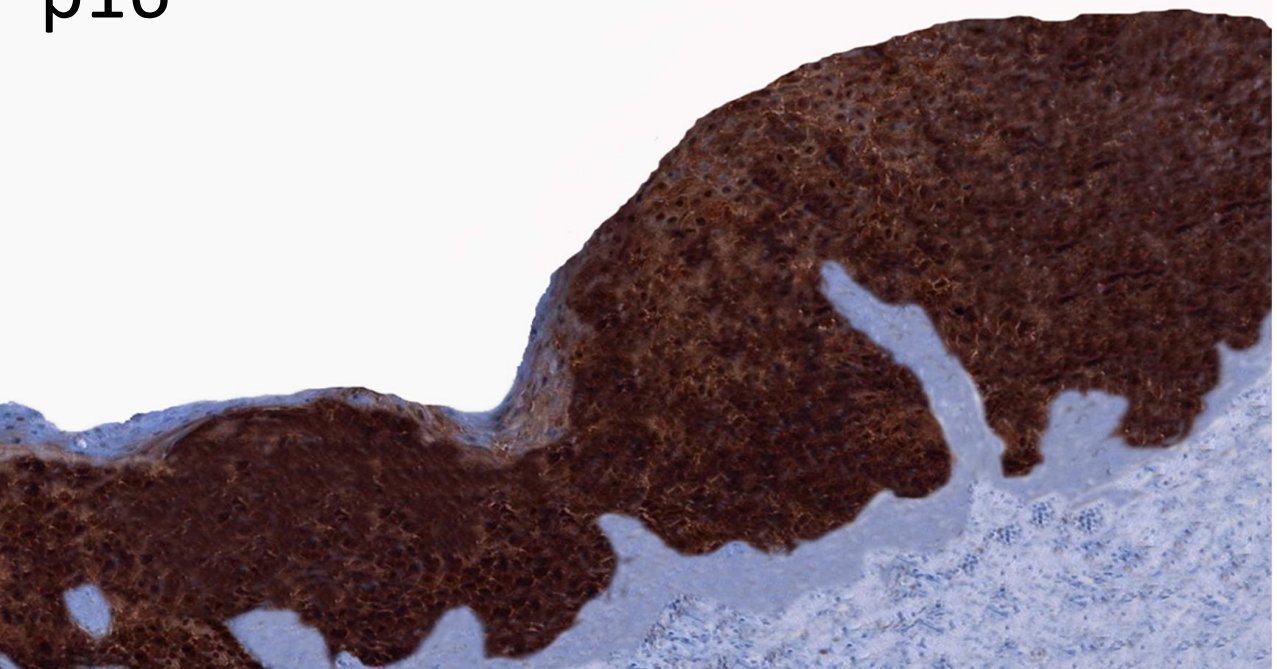

p16

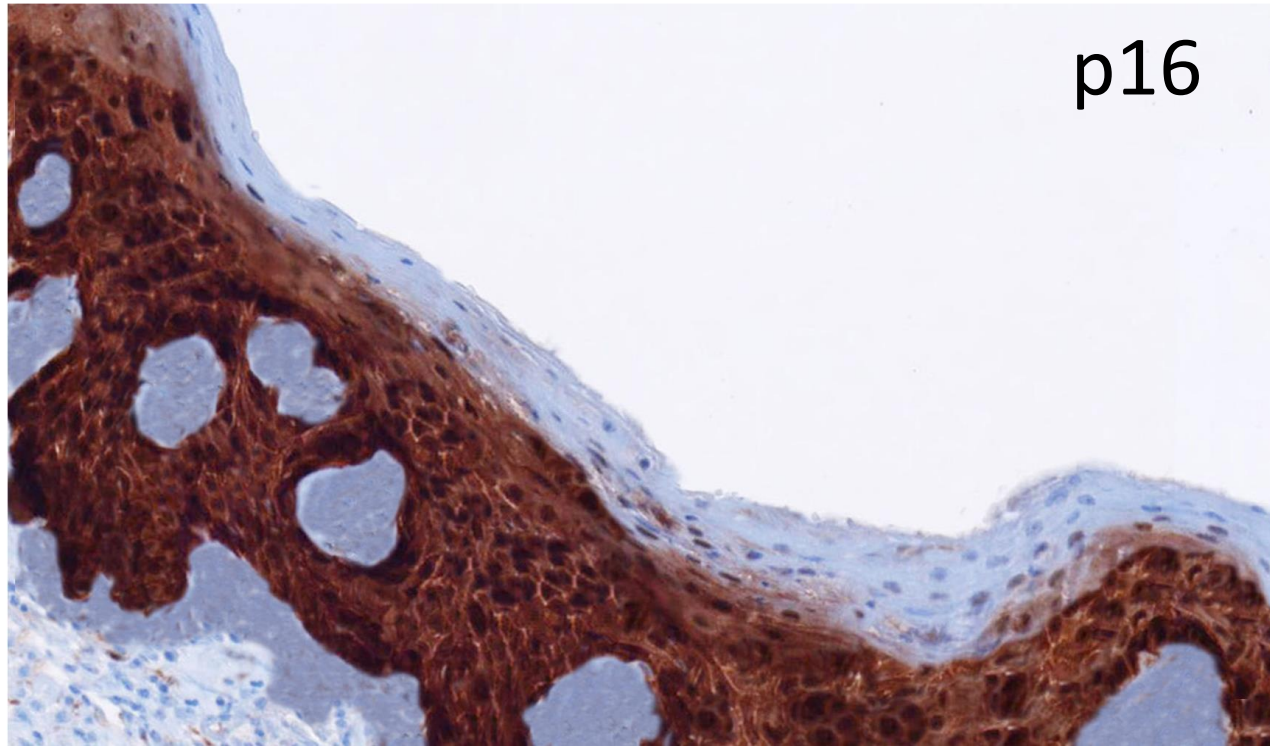

Precursors of VSCC: Controversies

1. How reliable is the differentiation between HSIL and dVIN?
2. **How reproducible is the diagnosis of dVIN and VAAD?**
3. Does LSIL /VIN1 exist in the vulva?
4. Precursor lesions other than dVIN

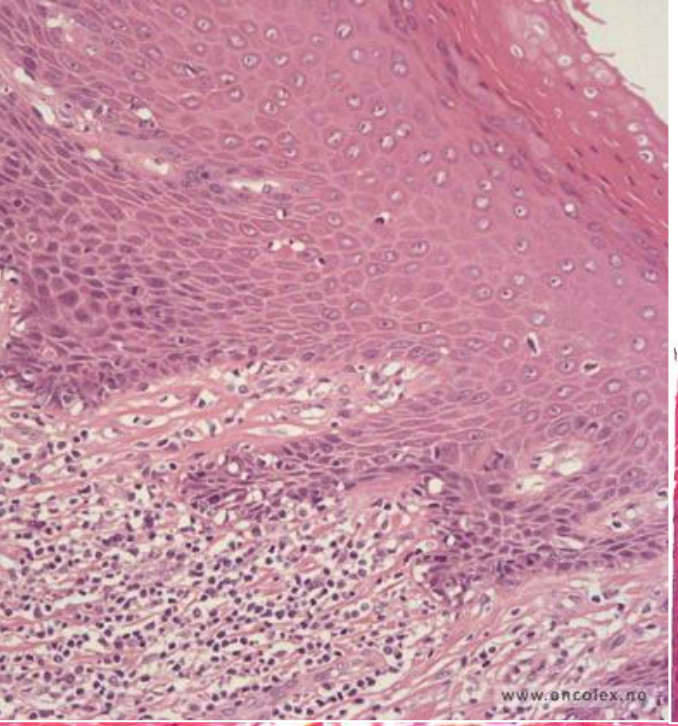
www.oncolex.no

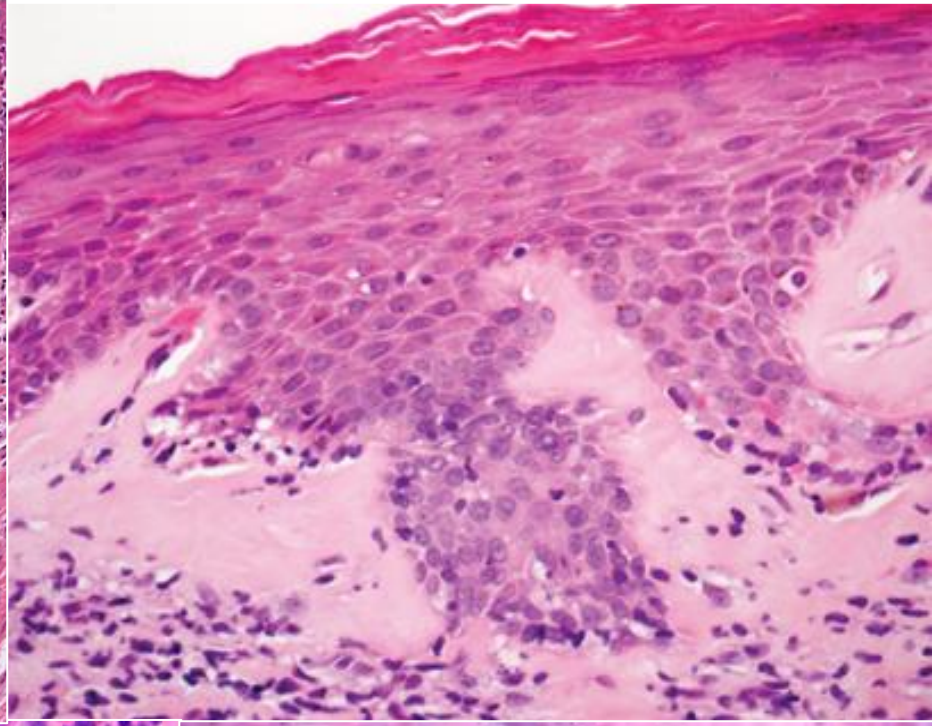
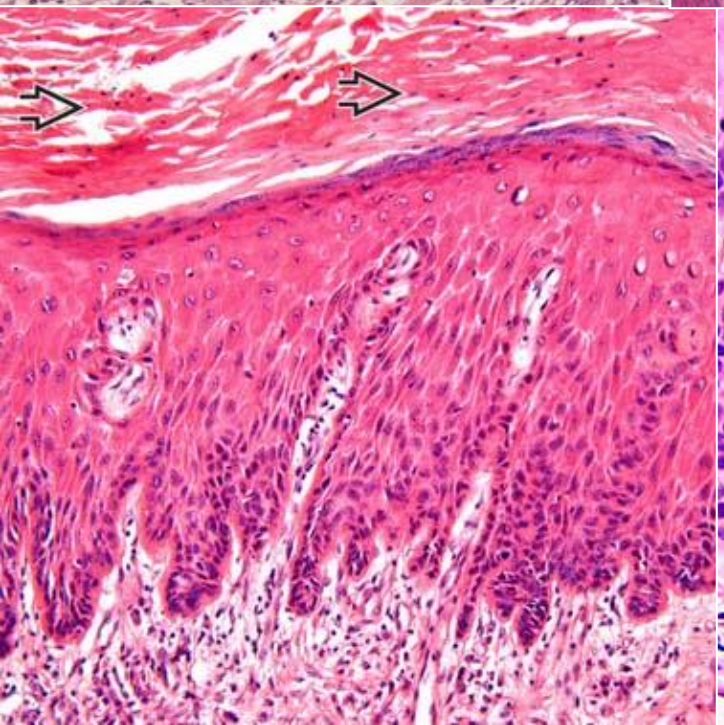
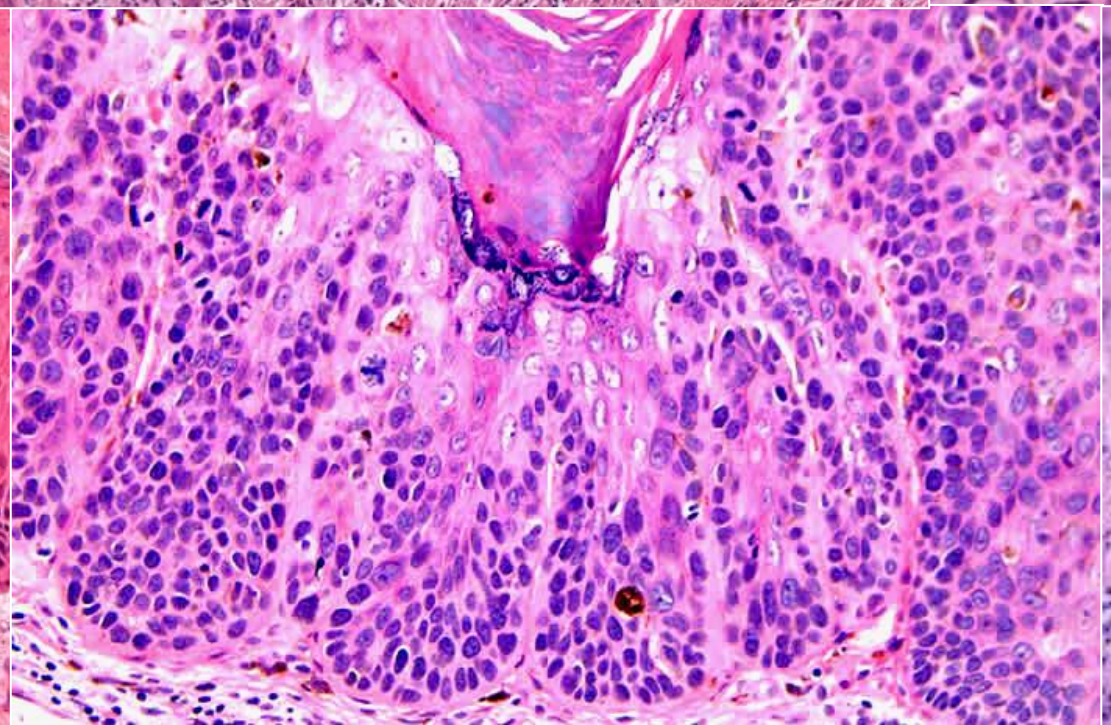
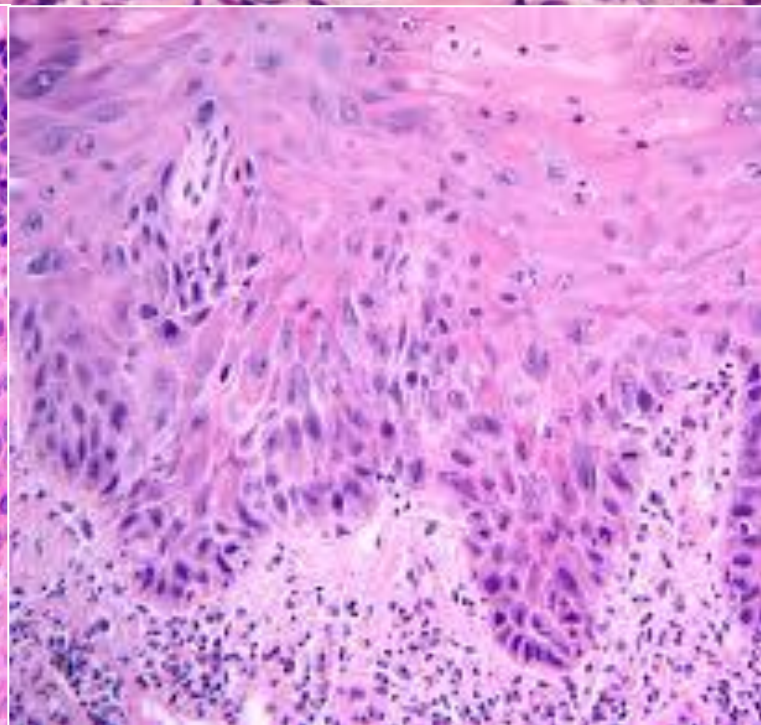

Reproducibility of dVIN diagnosis

- Poor reproducibility of dVIN diagnosis (van den Einden, et al. *Mod Pathol* 2013; 26:874-80)

	Pathologist	*Session 1*	
		Agreement with consensus[a], N *(%)*	*Kappa (95% CI)*
Pathologist in training	A	26/34 (77)	0.45 (0.16–0.75)
	B	24/34 (71)	0.32 (0.00–0.63)
General pathologist	C	24/34 (71)	0.27 (0.01–0.53)
	D	21/34 (62)	0.30 (0.06–0.55)
Gynecologic pathologist	E	26/34 (77)	0.54 (0.28–0.80)
	F	23/34 (68)	0.34 (0.03–0.66)

- Only basal cell atypia has enough consensus to define dVIN (Reutter et al. *J Low Genit Tract Dis* 2016; 20:261-6)


HSIL. Papules


HSIL. White lesions


HSIL. Pigmented lesions




HSIL. Red lesions


Lichen sclerosus

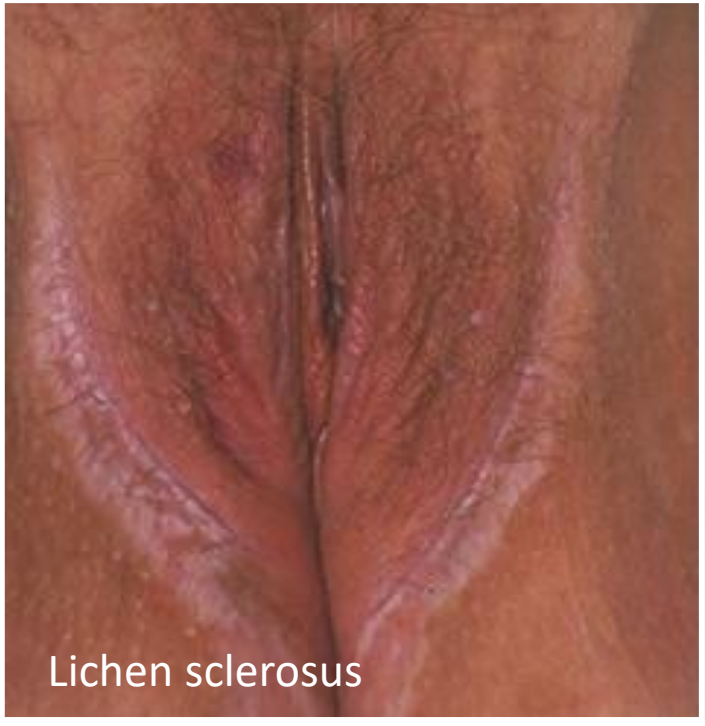
Lichen sclerosus


Lichen sclerosus


dVIN

HPV prevalence in VIN

	Year	n	Area	HPV
Trimble	1996	54	North America	89%
Carter	2001	18	North America	91%
Smith	2009	65	North America	98%
Garland	2009	62	Oceania	84%
Van der Nieuwenhof	2009	13	Europe	100%
Alonso	2011	48	Europe	83%
Gargano	2011	66	North America	94%

del Pino M, Rodriguez-Carunchio L, Ordi J. *Histopathology* 2013; 62: 161-75

Lesion	Number	HPV positive	(%)
Invasive carcinoma	1709	427	(24.9%)
VIN	587	506	(86.2%)

de Sanjosé S, Alemany L, Ordi J, et al. *Eur J Cancer* 2013; 49:3450-61

Precursors of VSCC: Controversies

1. How reliable is the differentiation between HSIL and dVIN?
2. How reproducible is the diagnosis of dVIN and VAAD?
3. **Does LSIL /VIN1 exist in the vulva?**
4. Precursor lesions other than dVIN

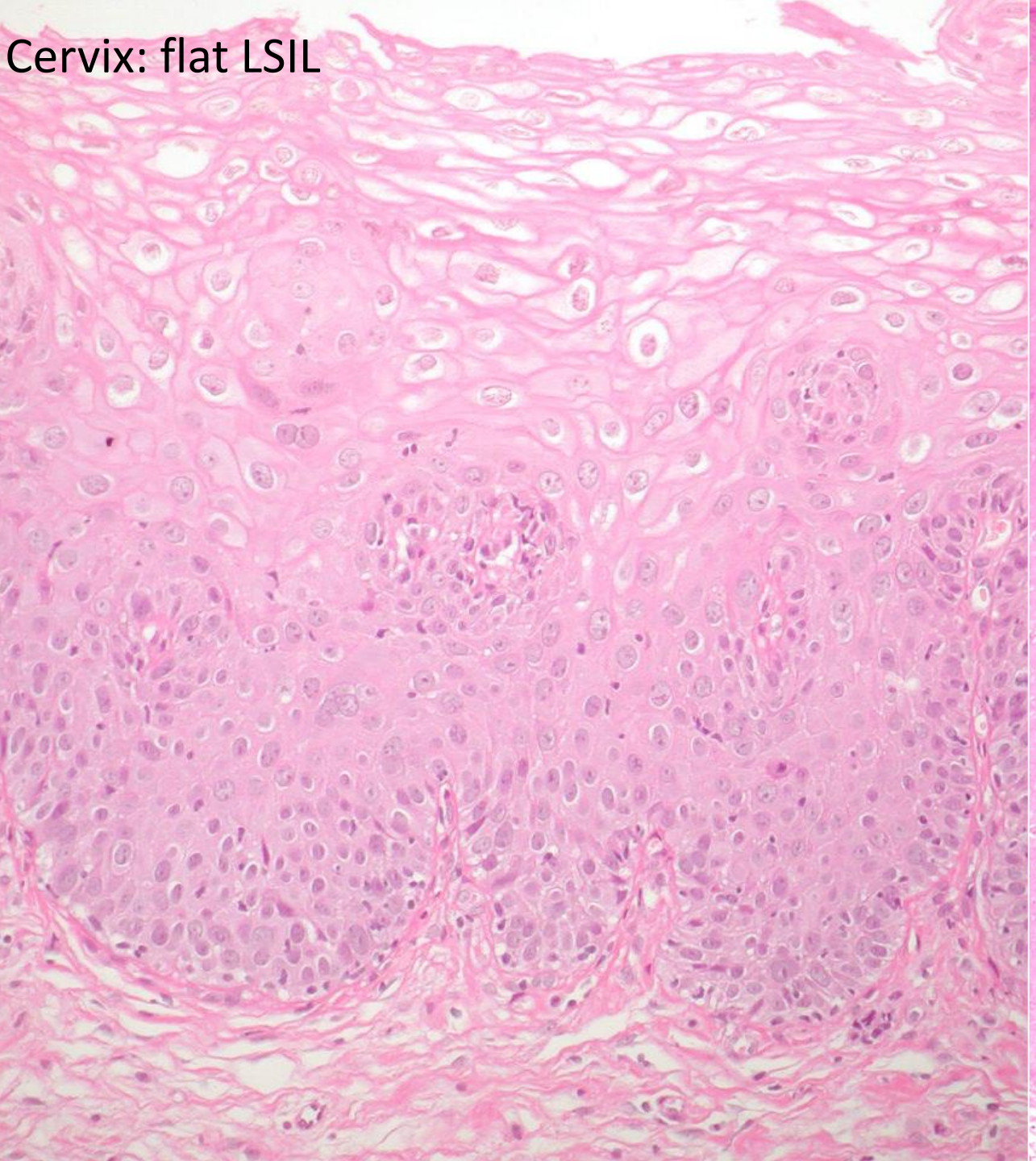
Cervix: flat LSIL

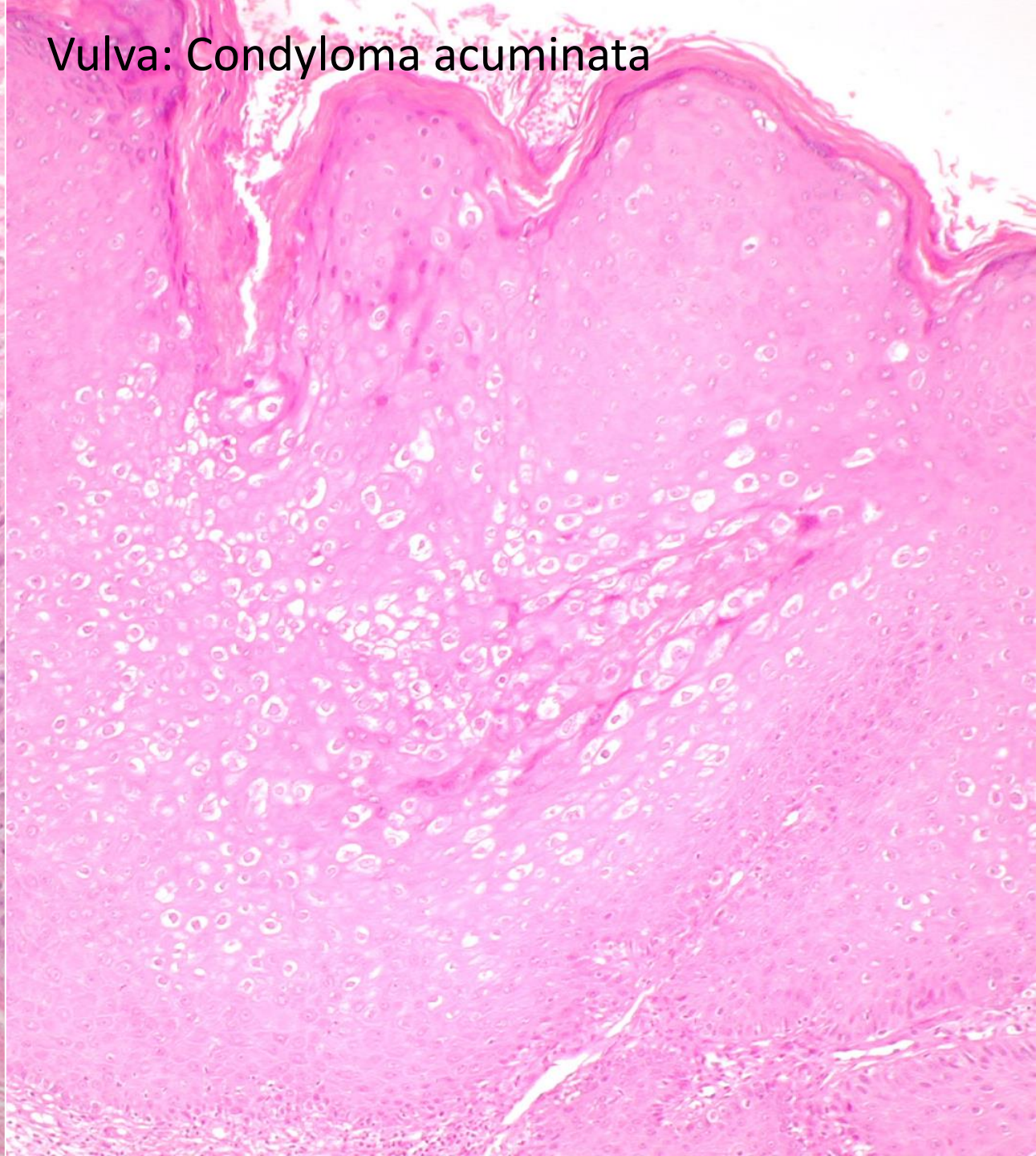
Vulva: Condyloma acuminata

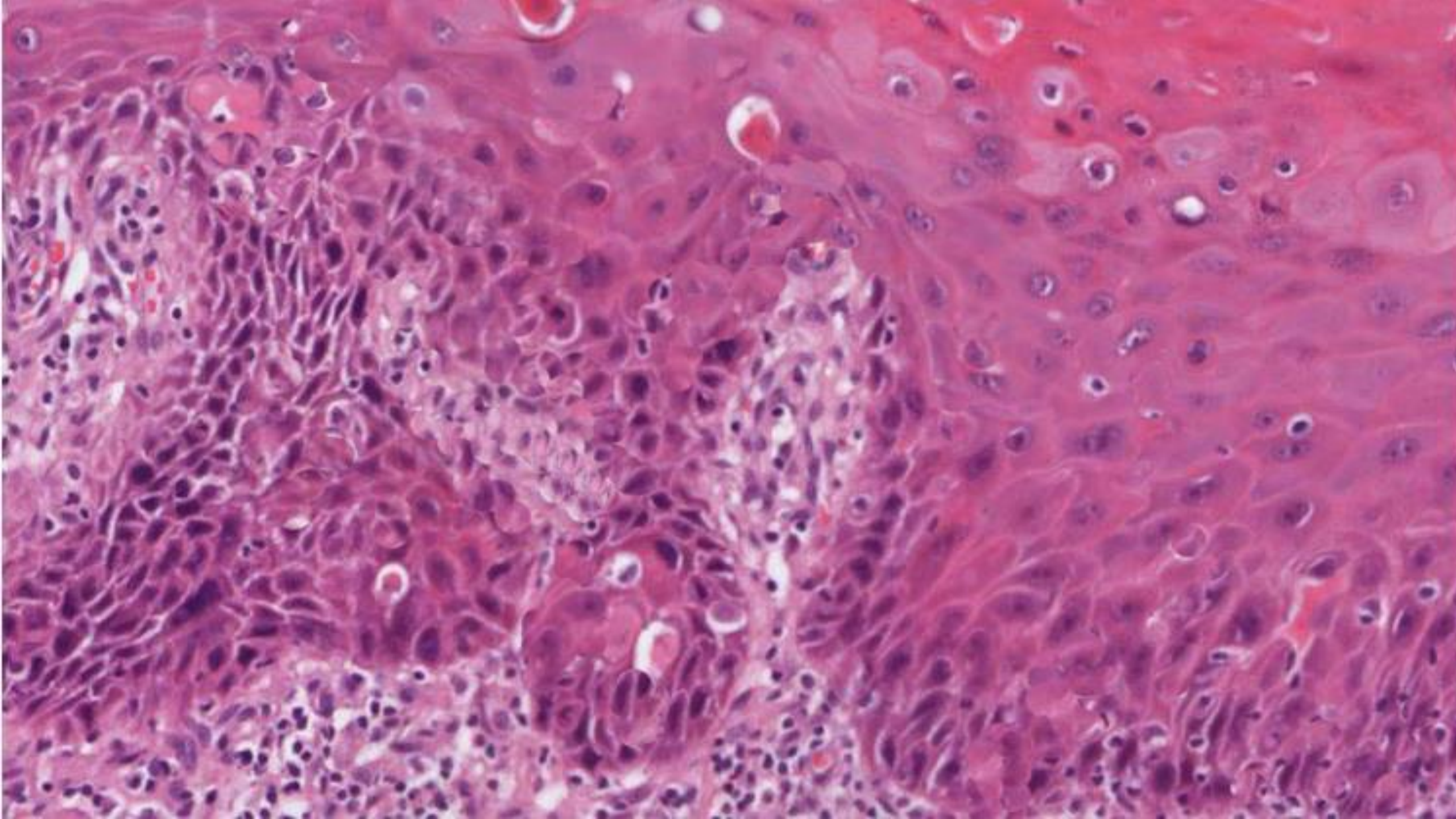

Precursors of VSCC: Controversies

1. How reliable is the differentiation between HSIL and dVIN?
2. How reproducible is the diagnosis of dVIN and VAAD?
3. Does LSIL /VIN1 exist in the vulva?
4. **Precursor lesions other than dVIN**

Precursor lesions other than dVIN

- **Differentiated exophytic vulvar intraepithelial lesion (DEVIL)**
- **Vulvar acanthosis with altered differentiation (VAAD)**
- Precursors of verrucous carcinoma.
- Mutations of PIK3A

Nascimento AF, et al, *Am J Surg Pathol* 2004; 28:638-43
Watkins JC et al, *Mod Pathol* 2017; 30:448-58
Akbari A, Et al, *Mod Pathol* 2020; 33:2011-8
Tessier-Cloutier B, etbal. *Mod Pathol* 2021; 34:508-18

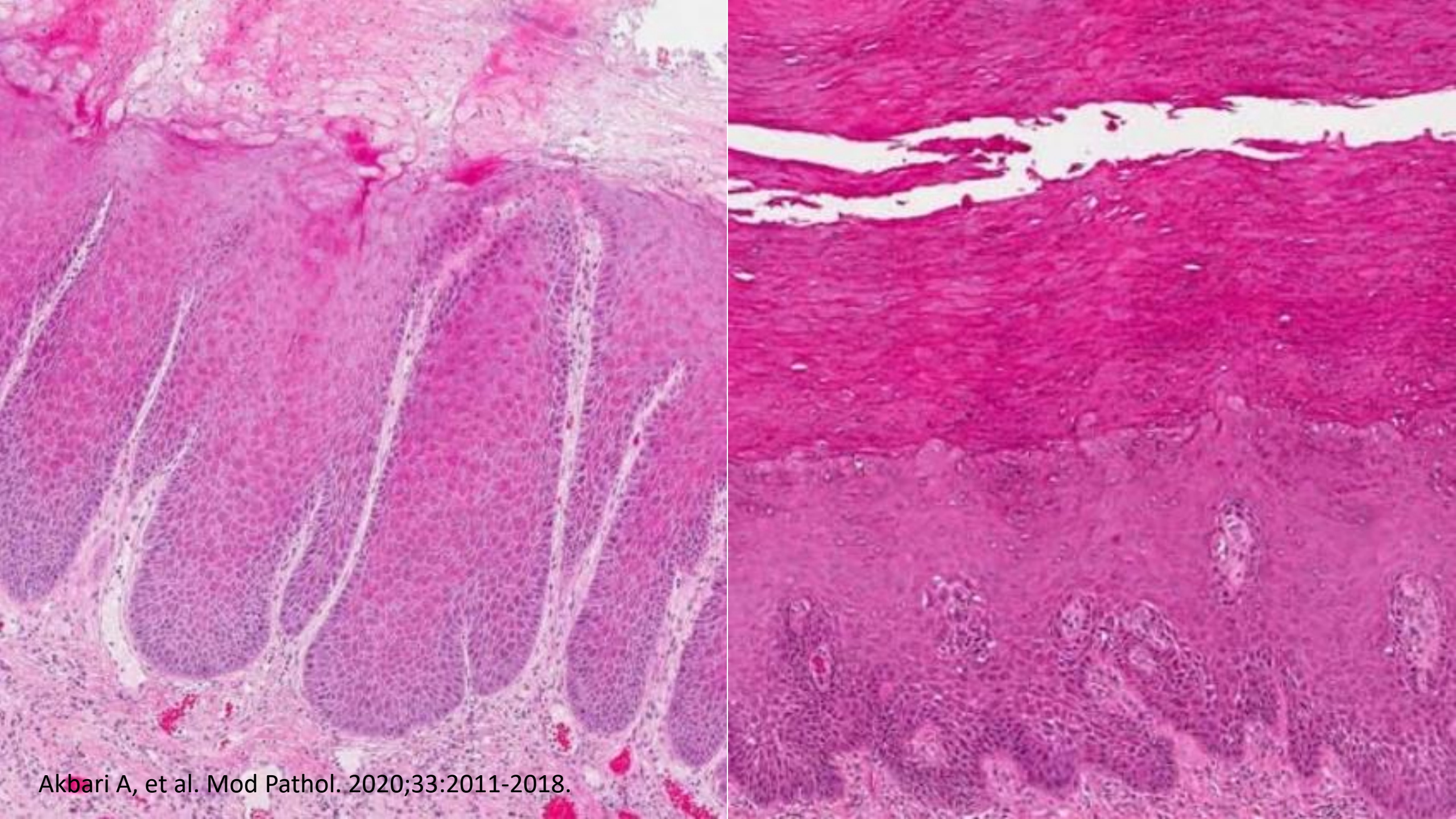

Akbari A, et al. Mod Pathol. 2020;33:2011-2018.

p53 IHC expression in VSCC precursors

Lesion	n	Abnormal	Wild type
Intraepithelial lesions			
dVIN	186	69%	31%
HSIL like lesion	46	78%	22%
VAAD/DEVIL	22	41%	59%
Inflammatory lesions			
Lichen sclerosus	36	25%	75%
Other inflammatory lesions	160	18%	82%

Rakislova N, et al. *Int J Mol Sci.* 2020; 21:8091

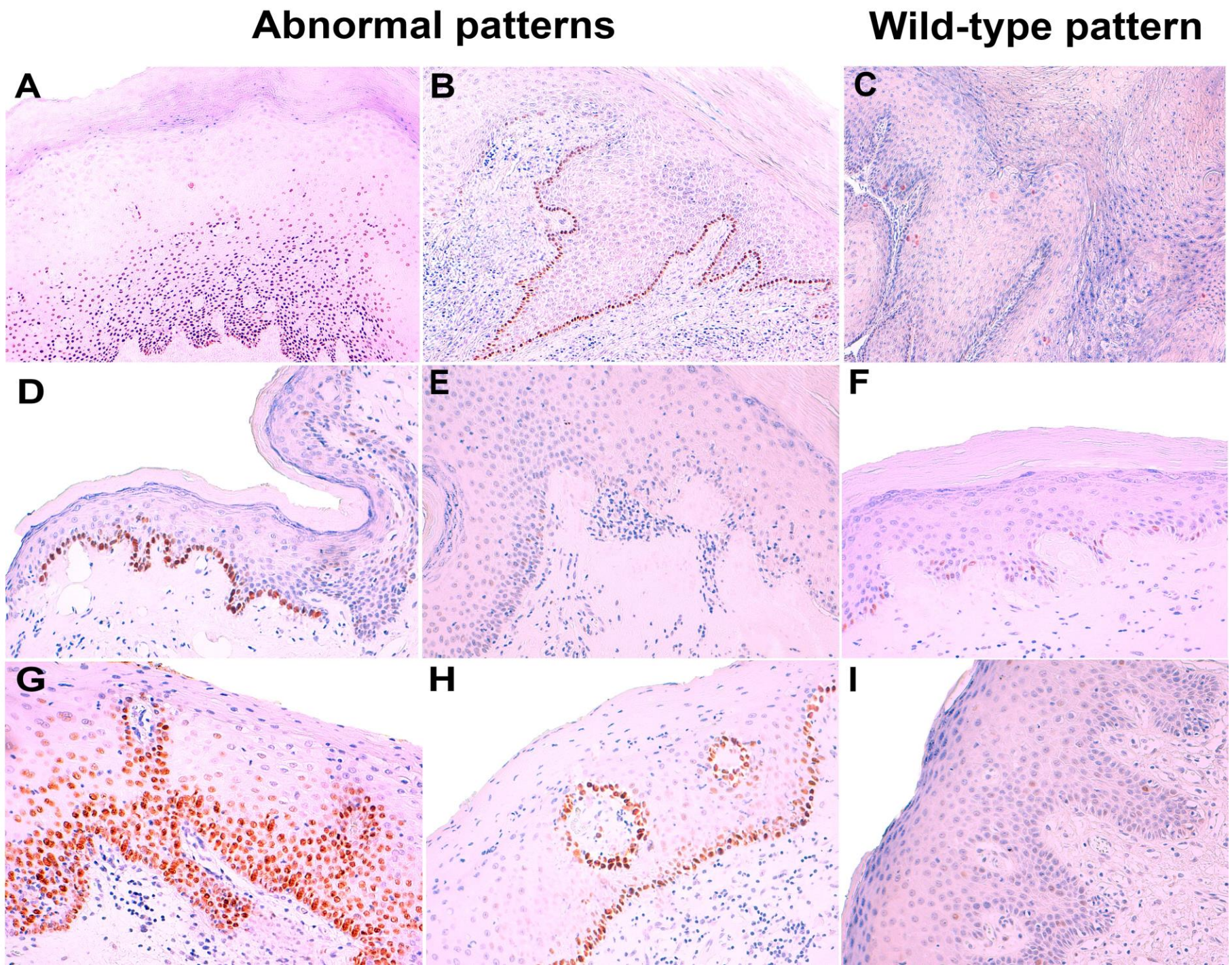

Rakislova N, et al. *Int J Mol Sci.* 2020 Oct 29;21(21):8091.

Outline

1. Identification of HPV in vulvar tumors
2. Invasive squamous cell carcinomas of the vulva
3. Precursors of VSCC
4. **Molecular aspects of VSCC**

Mutations in VSCC

	Year	Technique	TP53	PICK3CA	CDKN2A	PTEN	HRAS	FBXW7	KIT	APC	FGFR3	ATM	FAT1	NOTCH 1	KRAS
Trietsh	2014	Sanger	■	■	■	■	■								■
Nooij	2017	NGS	■	■		■	■			■			■	■	■
Weberpals	2017	NGS	■	■	■	■	■		■	■	■	■			■
Watkins	2017	NGS	■	■	■		■	■	■						
Han	2018	WES	■	■	■		■	■		■		■	■	■	
Zieba	2018	NGS	■	■	■	■	■	■	■		■	■			
Zieba	2020	NGS	■	■	■	■		■	■	■	■	■	■		■
Tessier-Cloutier	2020	NGS	■	■		■	■	■							
Prieske	2020	WES	■	■	■	■		■	■	■	■	■	■	■	
Williams	2020	CGP	■	■	■	■		■			■		■	■	

“Take home” messages

- H&E criteria cannot confidently differentiate HPV-associated and independent lesions of the vulva
- **p16** overexpression is highly sensitive to detect HPV positive lesions (probably more reliably than HPV) and **can be used to classify them into HPV-associated and HPV-independent**
- **HPV-associated vulvar carcinomas have better prognosis than HPV-independent cancers**
- Molecular studies are providing relevant data, which can be helpful to design targeted therapies


Thank you for your attention!