The British Association of Gynaecological Pathologists



Issues in the diagnosis of cervical carcinoma

Simona Stolnicu, UMFST, Romania

Simona Stolnicu is a professor of pathology at University of Medicine, Pharmacy, Sciences and Technology (UMFST) Targu Mures, Romania, with a special interest in gynecologic and breast pathology and cytology and in particular in cervical pathology. She authored over 150 peer-reviewed scientific publications and 30 medical books as editor and/or main author (including the latest WHO 2020 Blue Book on Tumors involving Female Genital Tract). She is the Past-Chair of the Gynecologic Pathology Working Group (European Society of Pathology- ESP). She is a member of the Board of Directors, International Society of Gynecological Pathologists (ISGyP) and a member of ISGyP Global Advisory Network. She is a member of the expert panel of International Collaborative on Cancer Reporting (ICCR) Carcinoma of the Cervix dataset.

The British Association of Gynaecological Pathologists

Everyday Dilemmas in Gynaecological Pathology

Issues in the diagnosis of cervical carcinoma

Simona Stolnicu

UMFST, Targu Mures, Romania

Friday 7th March 2025

The British Association of Gynaecological Pathologists

Speaker disclosures

I have no financial conflicts of interest to disclose

Outline

- Review updates on the WHO 2020 clasification of endocervical adenocarcinomas (ECAs) and squamous cell carcinomas (SCCs)
- Cover updates on the squamous and glandular precursor lesions
- Summarize relevant ancilary studies to help the differential diagnosis
- Discuss histologic grading methods and prognostic relevance in SCCs and ECAs
- Update on pattern based (Silva) classification in ECAs

1. Endocervical adenocarcinoma (ECA)

- Spectrum of tumors
- Increased incidence in the last decades (25% of all cervical cancers)
- Significant recent changes regarding classification, based on numerous publications
- WHO, 2014: ECAs were classified by vague and descriptive **morphologic features** (specifically cytoplasmic) assessed on H&E-stained slides lacking clinical and/or pathogenetic correlations

Issues with 2014 WHO classification (based on morphology alone)

Histologic type	Related diagnostic issues
Usual type	The most common type of cervical invasive adenocarcinoma, characterized by relative mucin depletion but no specific quantitative criteria on how much mucin to differenciate from mucinous or endometrioid type were provided
Mucinous type	Included HPV-associated (like intestinal and signet ring cell type) as well as HPV-independent (like gastric type) adenocarcinomas
Serous type	Defined as morphologically identical to endometrial or adnexal serous carcinomas but included HPV-positive “serous-like” tumors developed in younger patients and *TP53* mutant tumors affecting older patients
Endometrioid type	Defined as a tumor resembling with endometrial endometrioid adenocarcinomas, but no criteria for differentiating from usual type based on morphology alone

International Endocervical Adenocarcinoma Criteria and Classification (IECC)

A New Pathogenetic Classification for Invasive Adenocarcinomas of the Endocervix

Simona Stolnicu, MD, Iulia Barsan, MD,* Lien Hoang, MD,† Prusha Patel, MPH,‡ Cristina Terinte, MD,§ Anna Pesci, MD,‖ Sarit Aviel-Ronen, MD,¶ Takako Kiyokawa, MD,# Isabel Alvarado-Cabrero, MD,** Malcolm C. Pike, PhD,‡ Esther Oliva, MD,†† Kay J. Park, MD,‡ and Robert A. Soslow, MD‡*

HPVA
HPV-Associated

→ **Apical mitotic figures and apoptotic bodies at scanning magnification (82%)**

HPVI
HPV-Independent

→ **No easily identified/absent mitoses and apoptosis at scanning magnification (18%)**

HPVA-ECA

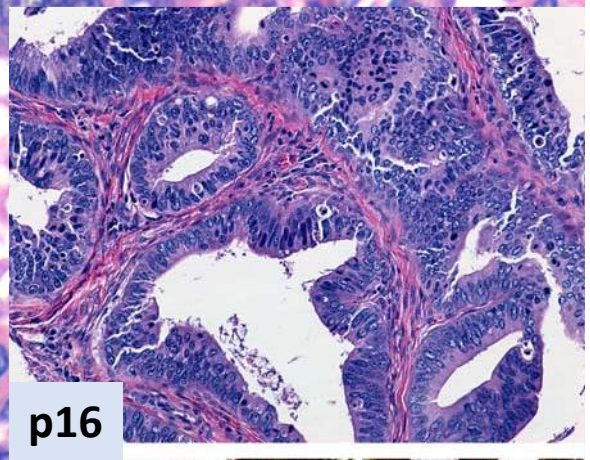

HPVI-ECA

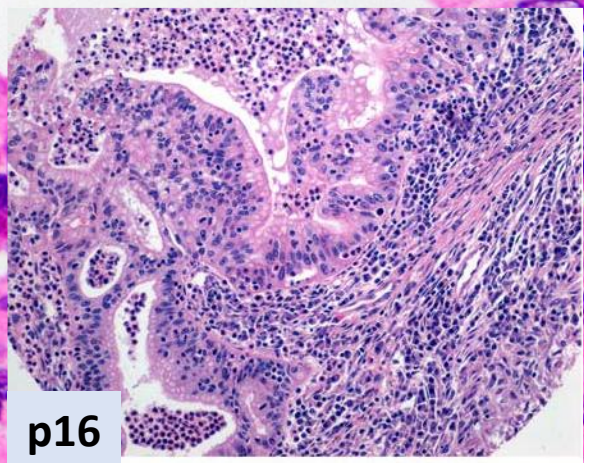

IECC classification 2018

The validity of the HPVA and HPVI categories is supported by :

- p16 expression and presence of HPV
- Clinical and demographic features
- Prognosis and response to treatment

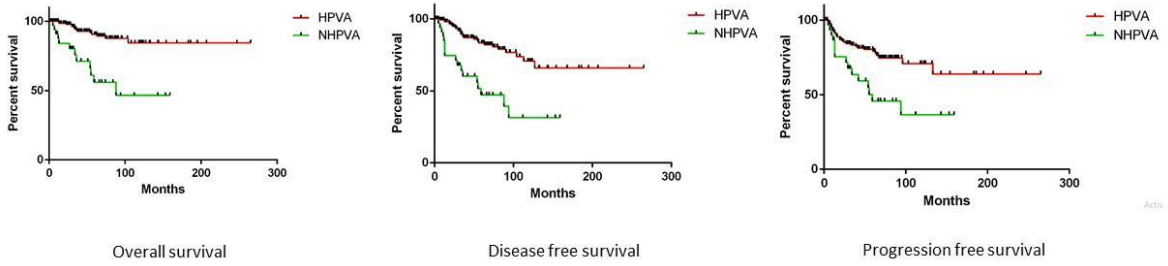

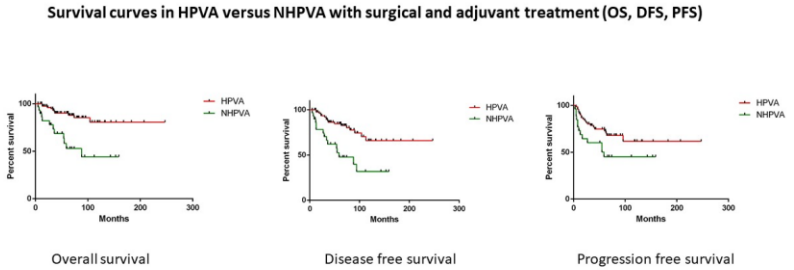

Stolnicu, 2018, 2019

	Median age (yrs)	Tumor size, median (mm)	FIGO tumor stage I (%)	p16 positivity (%)	HPV status (%)
HPVA	42	23	92	83	85
HPVI	54	38	49	37	0

IECC 2018

- Already validated by subsequent work
- Superior interobserver agreement among gynecological pathologists
- Shows high correlation with HPV molecular results and p16 expression

Hodgson, 2018, 2019; Ren, 2021; Pinar 2021; Li, 2022; Bulutay, 2022; de Carvalho, 2022

Endocervical adenocarcinoma classification: WHO 2014 and IECC 2018/WHO 2020

WHO 2014	IECC 2018/WHO 2020
Endocervical adenocarcinoma, usual type Mucinous carcinoma NOS Mucinous carcinoma, gastric type Mucinous carcinoma, intestinal type Mucinous carcinoma, signet ring cell type Villoglandular carcinoma Mesonephric carcinoma Serous carcinoma Clear cell carcinoma Endometrioid carcinoma Adenocarcinoma NOS	**HPV-associated endocervical adenocarcinoma** Usual type Mucinous type (NOS, intestinal, signet-ring cell, ISMC) Adenocarcinoma NOS **HPV-independent endocervical adenocarcinoma** Gastric type Clear cell type Mesonephric type Endometrioid type Adenocarcinoma NOS

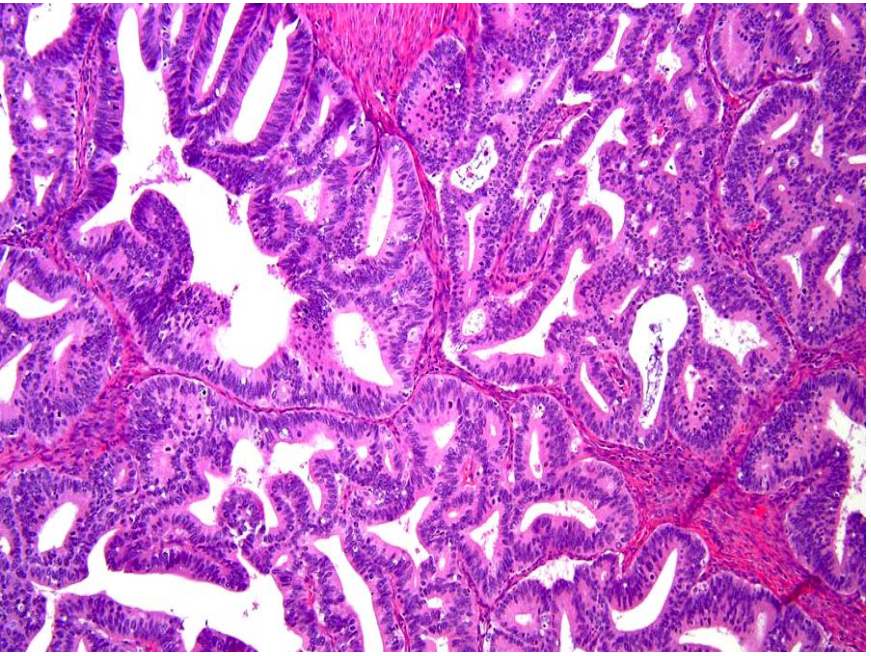

Usual

Various architecture (mostly glandular)
Columnar tumor cells, mucin depletion
0-50% of tumor cells with intracytoplasmic mucin
Good P

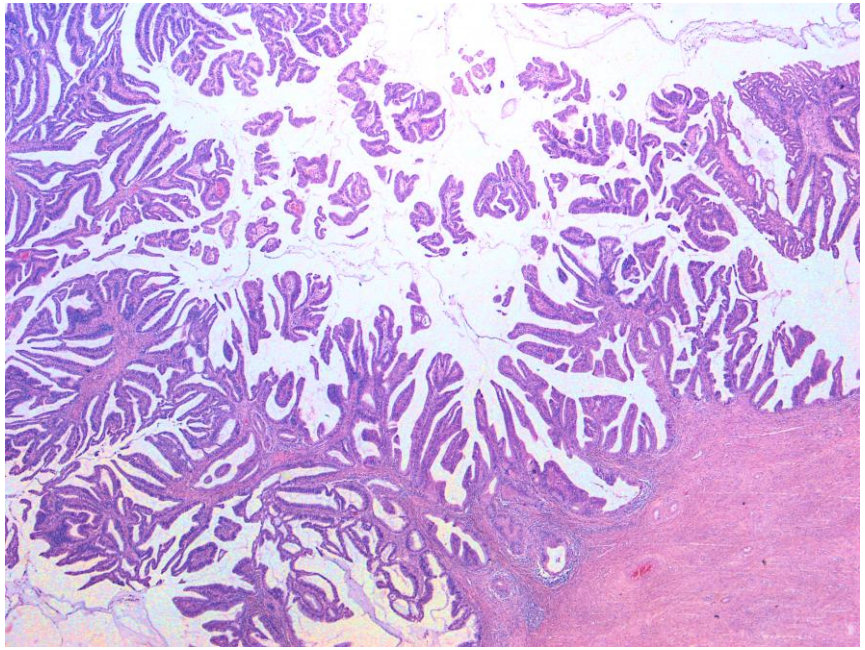

Villoglandular

Prominent exophytic papillary growth (in the superficial portion of the tumor)

Columnar pseudostratified epithelial cells, low-grade nuclear atypia

Excellent P

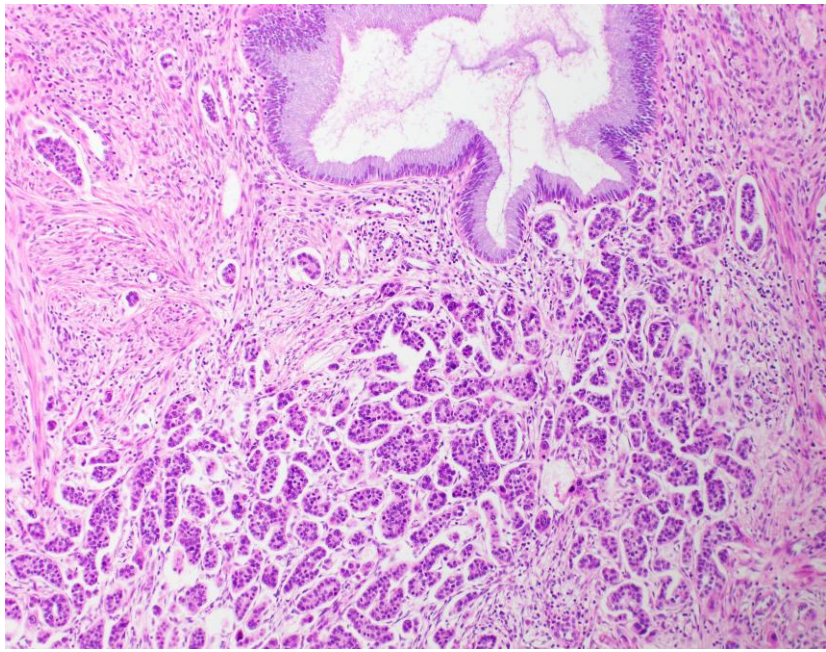

Micropapillary

Small tightly cohesive papillary-like groups (fibrous core lacking!)
Neoplastic cells with eosinophilic cytoplasm and atypical nuclei
Surrounded by clear spaces
Poor P

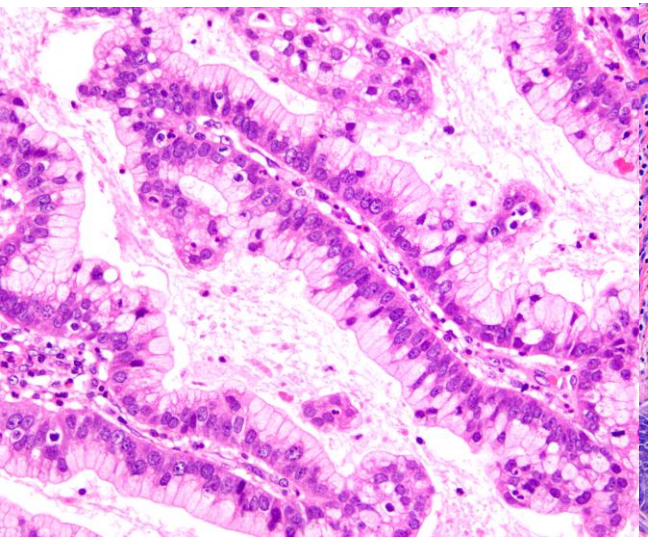

Mucinous NOS

More than 50% of tumor cells with intracytoplasmic mucin in a background of usual-type

Intermediate P

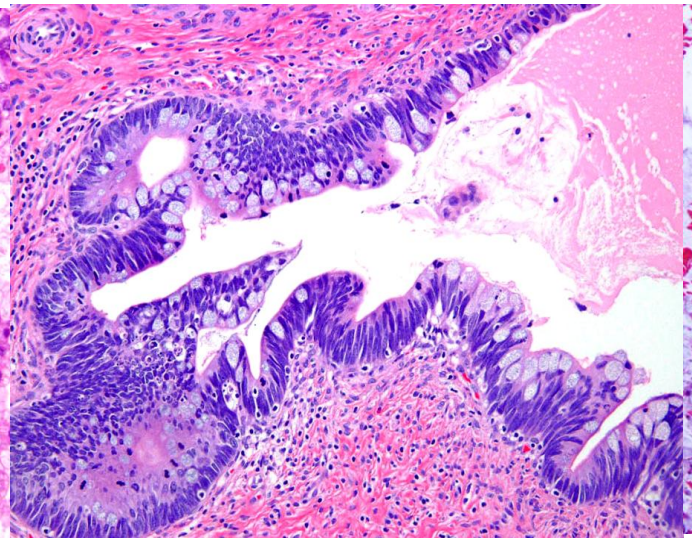

Mucinous intestinal

More than 50% of tumor cells with goblet cell morphology in a background of usual adenocarcinoma

Intermediate P

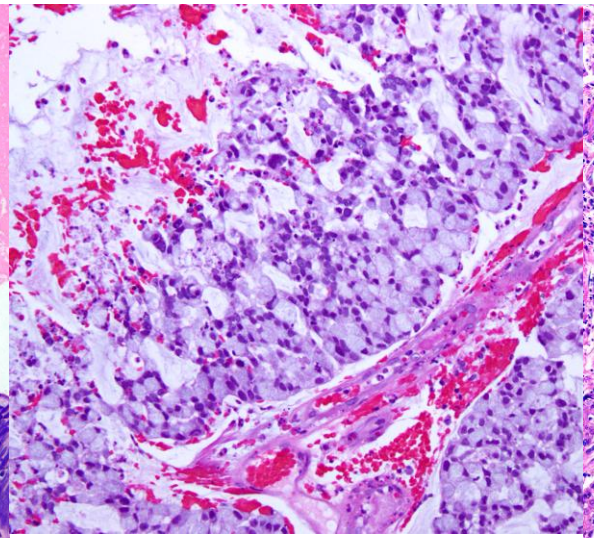

Mucinous signet-ring

More than 50% of tumor cells with signet-ring morphology, in a background of usual adenocarcinoma

Intermediate P

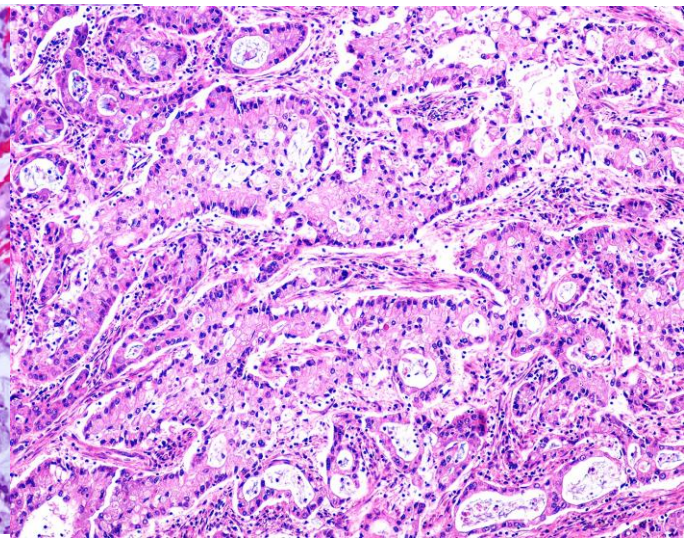

Invasive stratified mucinous carcinoma (iSMILE/ISMC)

Nests of columnar cells, variable amount of intracytoplasmic mucin, nuclear peripheral palisading

Poor P

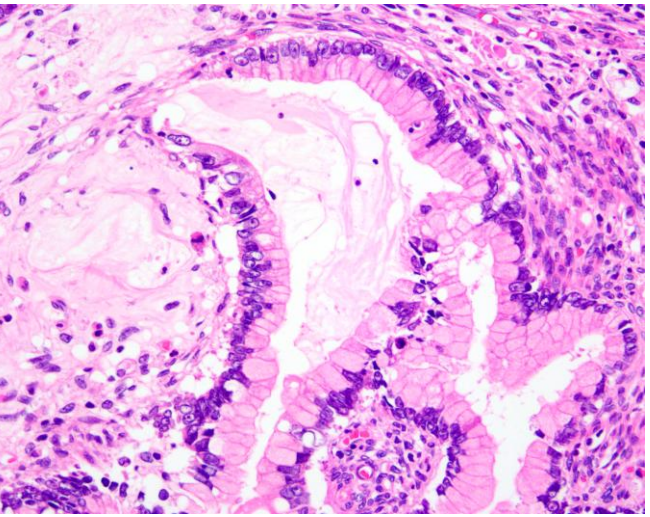

Gastric: 10-15%
Pancreato-biliary morphology
Gastric type of mucus (stains magenta- pink/red on PAS/Alcian Blue)
Tumor cells with clear/pale eosinophilic cytoplasm, distinct cytoplasmic borders, irregular basally-located nuclei
HIK1083, TFF2, Claudin 18+
Poor P

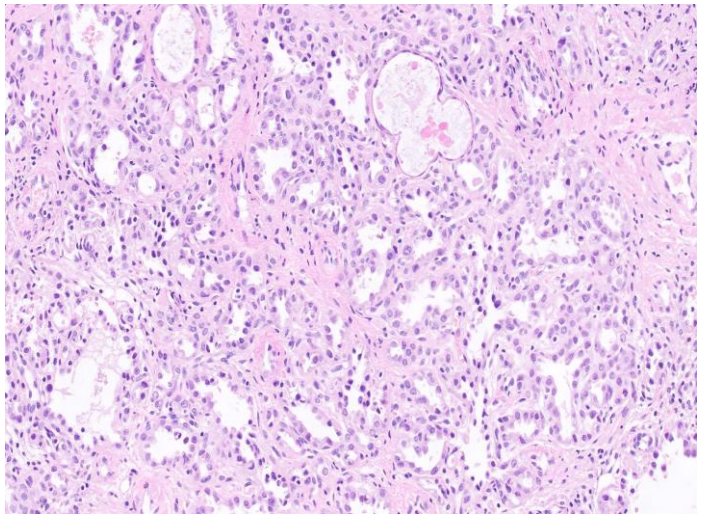

Clear cell: rare tumor (5%)

In utero DES exposure or sporadic

Characteristic morphology: solid, papillary and/or tubulo-cystic architecture

Polygonal cells and highly atypical but uniform nuclei

Clear, eosinophilic cytoplasm

HPV-, clear cell markers +

Intermediate/poor P

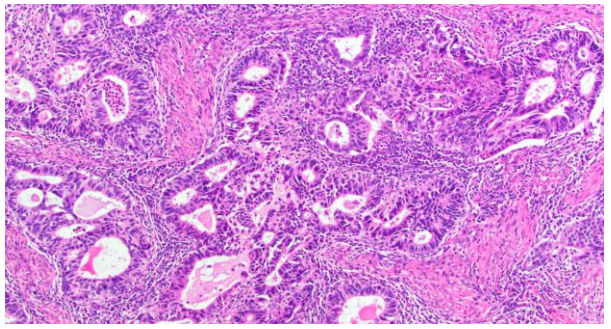

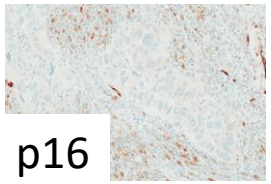

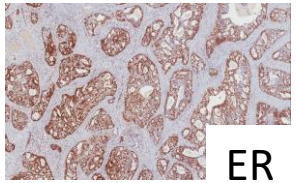

Endometrioid: extremely rare (1%)

Confirmatory endometrioid features

ER-positive in all of them

Non-diffuse type p16 expression but p16 can be positive (block-type) in high-grade

HPV- in all of them (has to be confirmed by ISH!!!)

Intermediate/poor P

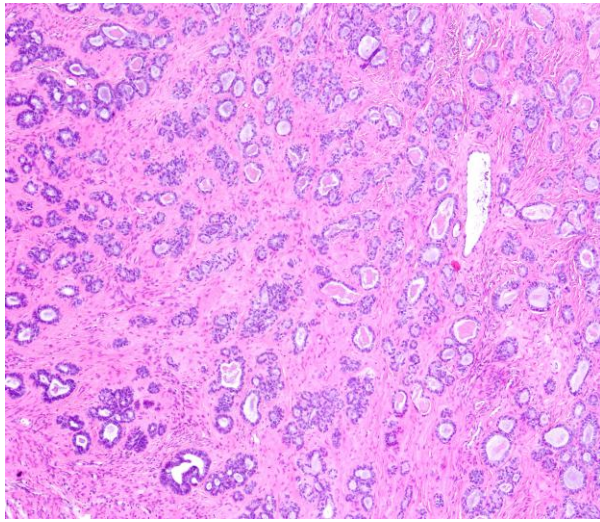

Mesonephric: extremely rare (1%)

Various architectural growth patterns

Tumor cells have scant cytoplasm and atypical hyperchromatic nuclei

May resemble papillary thyroid carcinoma (optically clear, grooved)

Mesonephric markers+

Intermediate/poor P

Usual type adenocarcinoma, HPVA

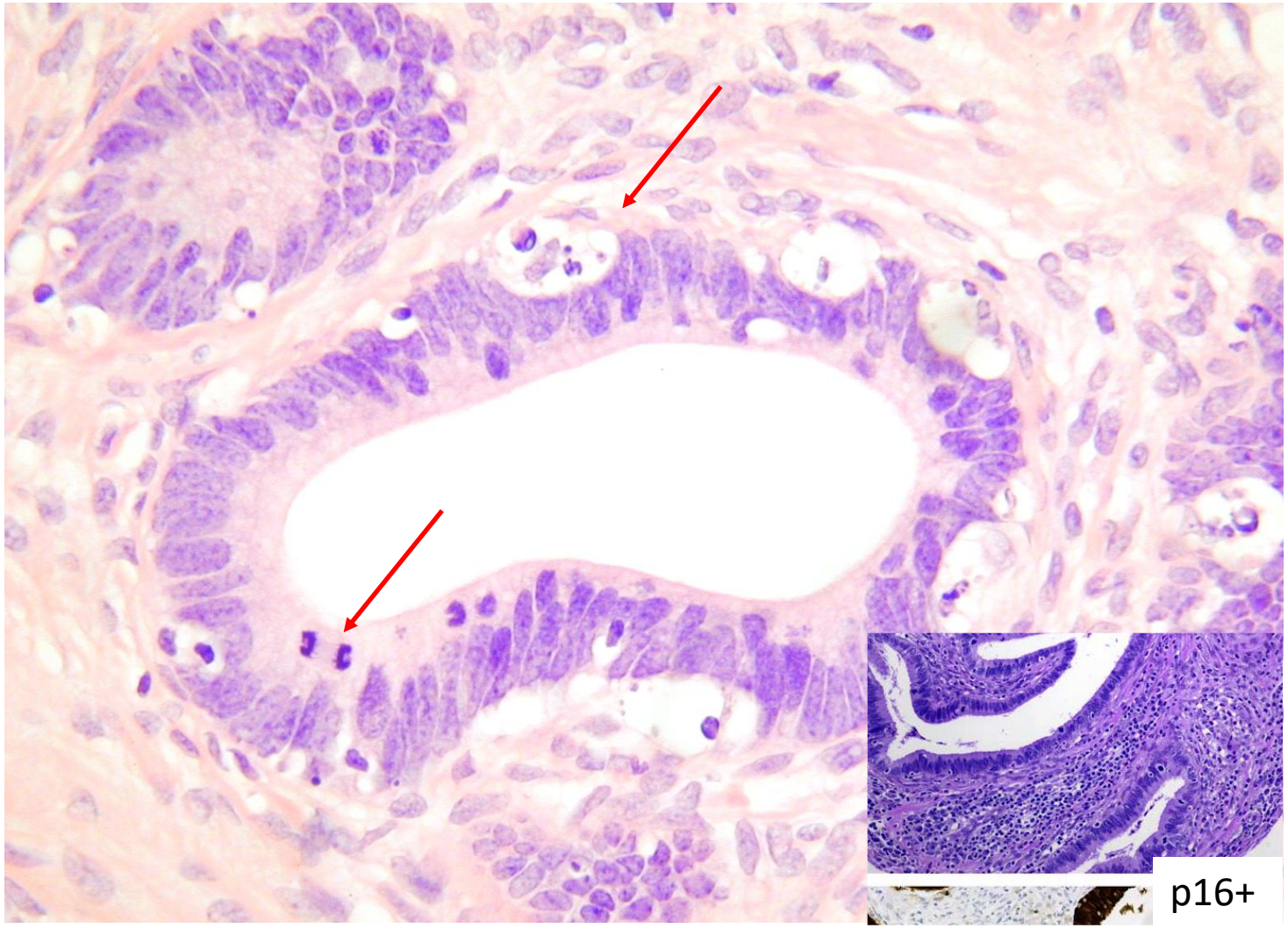

p16+

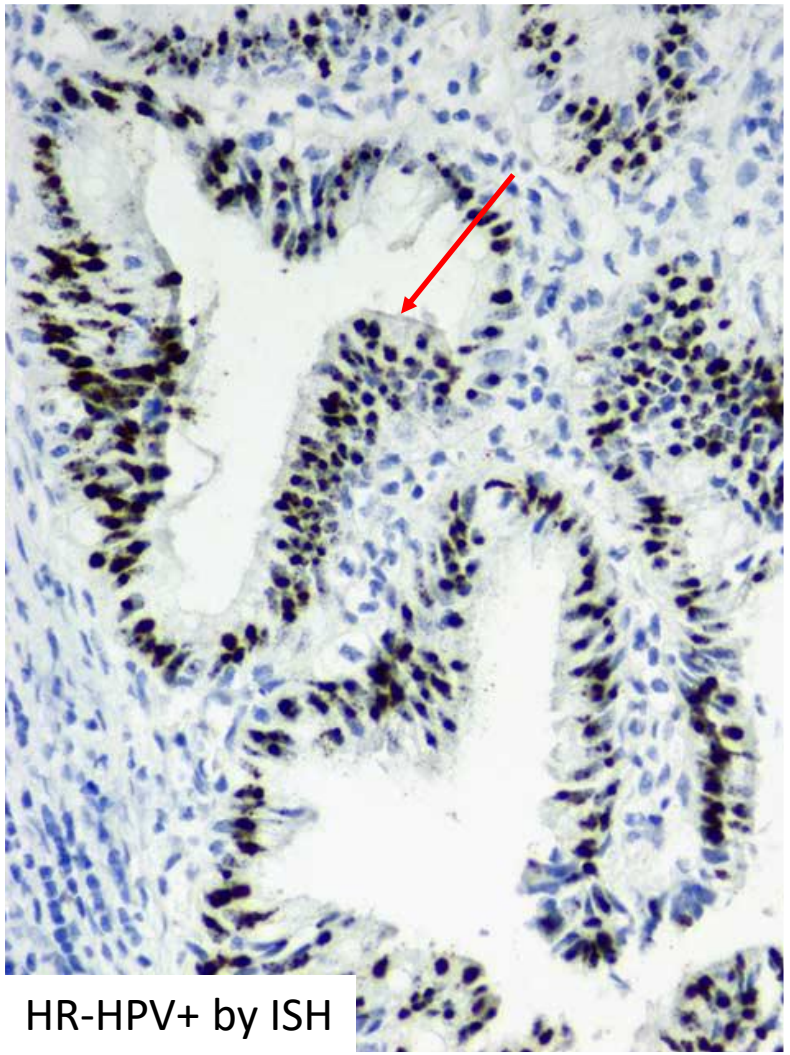

HR-HPV+ by ISH

Ancillary tests for HPVA ECAs

- These tests are expensive and are not mandatory for the diagnosis bc most cases are easy to be diagnosed
- They are not essential criteria to diagnose by WHO 2020 but only desirable criteria
- Should be performed only in difficult cases
- None of these tests is reliable 100% but p16 is a good surrogate marker of HR-HPV infection in the right context
- p16 can rarely be negative in HPVAs secondary to methylation
- Some HPVIs are block-type p16 positive (gastric type!)

HPVIs- additional ancillary studies

- HPVIs have worse survival than HPVAs
- Most studies focused on gastric type among HPVIs
- Worst prognosis, higher incidence of recurrences, mets to distant organs, need for different surgery (omental and ovaries removal) and different oncologic treatment because they do not respond to classic oncologic treatment
- Usually: suggestive morphology (lack of mitoses, apoptotic bodies), p16-, HPV-
- It is important to recognize gastric type from any other HPVA ECA (MUC6, HIK1083, TFF2, Claudin 18)

Kojima, 2007; Karamurzin, 2015; Stolnicu, 2019; Kyiokawa, 2021; Li, 2022; Fadare, 2022; Ehman, 2022

All Claudin-18 positive GAS cases showed strong and diffuse staining pattern with staining in more than 75% tumor cells; Kyiokawa et al; AmJSurgPathol, 2021

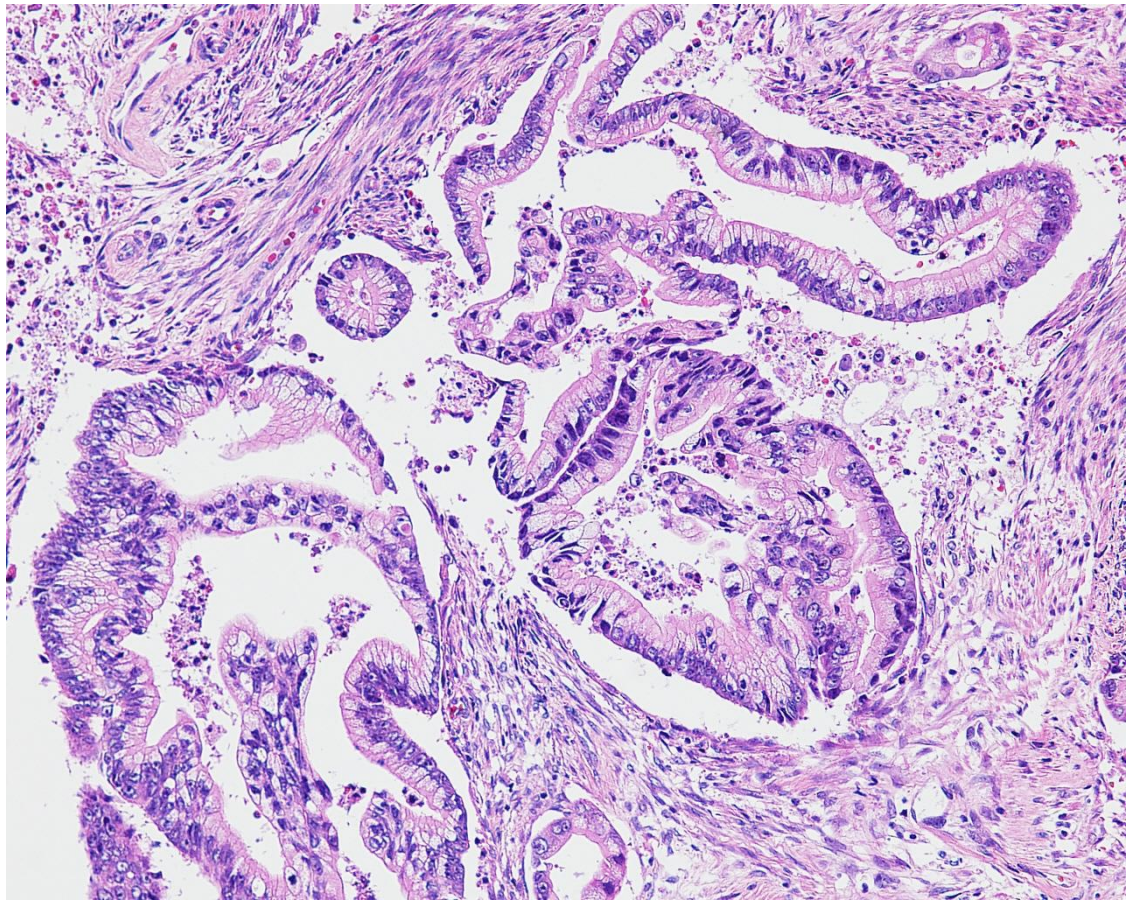

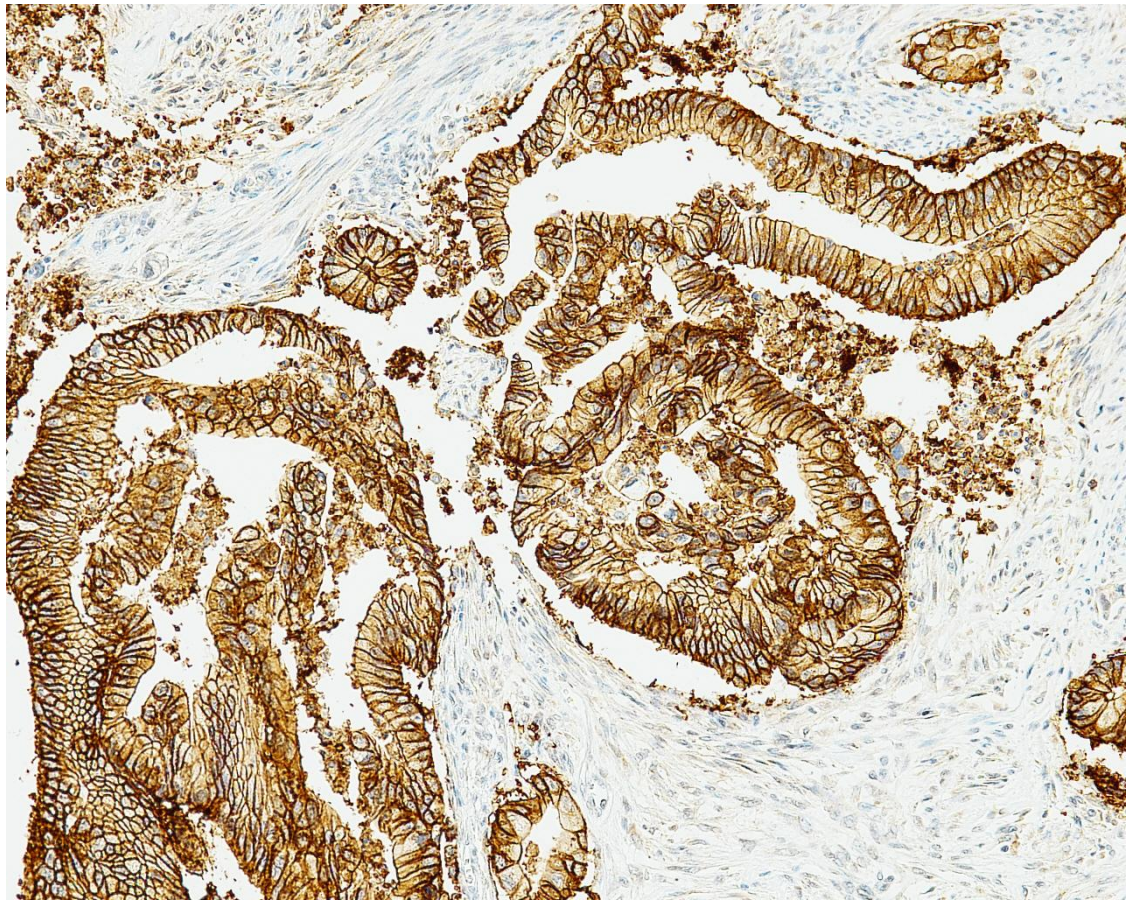

The Clinicopathological and Molecular Characteristics of Endocervical Gastric-Type Adenocarcinoma and the Use of Claudin18.2 as a Potential Therapeutic Target.

Jing Yang[a], Yang Peng[b], Yan Ding[c], Yueping Liu[c],Yuxiang Wang[a], Yan Liu[a], and Congrong Liu[a]

Mod Pathol. 2024 Oct;37(10):100569. doi: 10.1016/j.modpat.2024.100569. Epub 2024 Jul 25. PMID: 39025403.

a Department of Pathology, Third Hospital, School of Basic Medical Sciences, Peking University Health Science Center, Beijing, China
b Fourth Department of Gynecologic Oncology, Hunan Cancer Hospital/The Affiliated Cancer Hospital of Xiangya School of Medicine, Central South University, Changsha, China
c Department of Pathology, The Fourth Hospital of Hebei Medical University, Shijiazhuang, Hebei, China

- Claudin 18 is sensitive and specific for gastric type
- Normal endocervical mucosa is negative
- Very important when differenciating gastric type from HPVAs and from HPVI clear cell type (both can be sometimes positive but only focally and not strong)
- SO, strong and diffuse positivity is in favor of gastric type

961 **The Value of Claudin-18 and a Selected Immunohistochemistry Panel in the Distinction of Benign and Malignant Gastric-Type Endocervical Lesions from Benign Mullerian Endocervical Proliferations**

Lawrence Lin[1], Harsimar Kaur[2], David Kolin[2], Marisa Nucci[1], Carlos Parra-Herran[1]
[1]Brigham and Women's Hospital, Harvard Medical School, Boston, MA, [2]Brigham and Women's Hospital, Boston, MA

- The authors studied Claudin 18, STK11, p53 and SMAD4 in gastric type in situ and invasive lesions, benign gastric lesions and benign mullerian specimens
- Claudin 18 was + in 75% of gastric type lesions
- STK11 was loss in 28% of gastric type lesions
- Mutant p53 was present in 30% of gastric type
- Abnormal p53, STK11 and/or SMAD4 was present in 56% gastric type lesions
- These 3 markers can be used in a lesion with gastric morphology to support the diagnosis of GAS (an abnormal result for these markers is more common for gastric type)

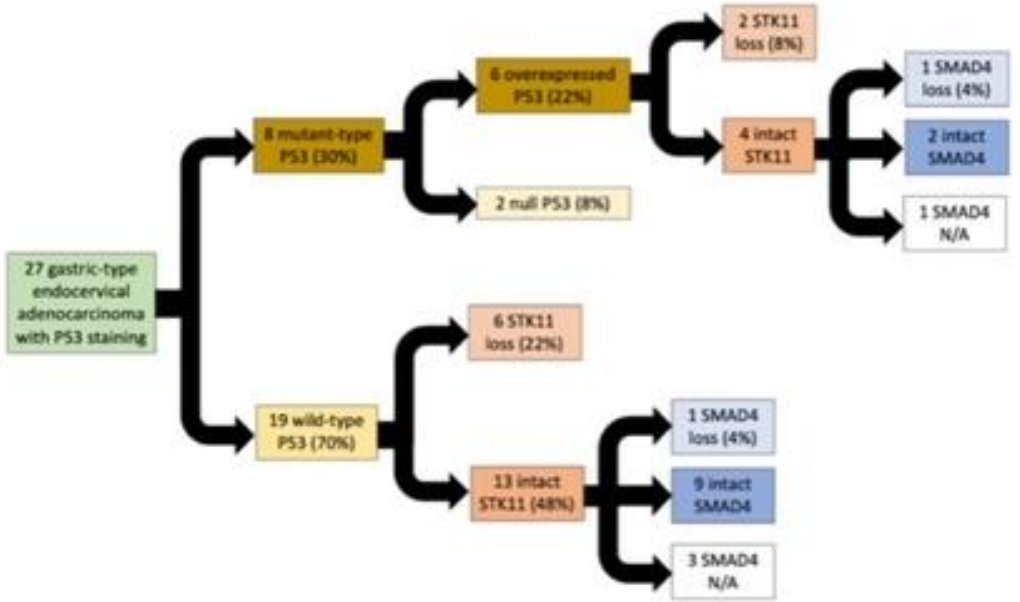

Journal Pre-proof

CLAUDIN-18.2 TESTING AND ITS IMPACT IN THE THERAPEUTIC MANAGEMENT OF PATIENTS WITH GASTRIC AND GASTROESOPHAGEAL ADENOCARCINOMAS: A LITERATURE REVIEW WITH EXPERT OPINIONCLAUDIN-18.2 testing in patients with GC and EGJA

Valentina Angerilli, Filippo Ghelardi, Floriana Nappo, Federica Grillo, Paola Parente, Sara Lonardi, Claudio Luchini, Filippo Pietrantonio, Clara Ugolini, Alessandro Vanoli, Matteo Fassan



- Zolbetuximab has been recently proposed as a new standard of care in patients with Claudin 18-positive, HER2 negative, locally advanced and metastatic gastric carcinoma and esophago-gastric junction adenocarcinomas
- The use of Claudin 18 marker to select patients whom might benefit from anti-Claudin 18 therapy is curently entering clinical practice
- Same might be applied for cervical gastric type adenocarcinomas
- Accurate biomarker assessment by the pathologist is essential!!!

WHO 2020 glandular precursor lesions: in situ adenocarcinoma

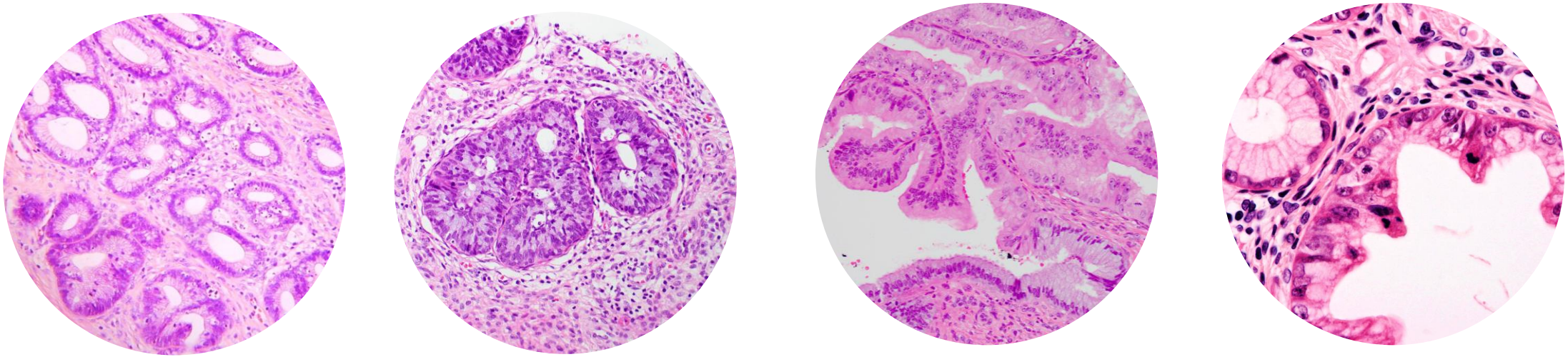

- **HPV-associated**: usual type and SMILE
- **HPV-independent**: gastric type, atypical LEGH
- Clear cell and endometrioid type (HPVI) recently described
- Precursor lesions for HPVI mesonephric type have not been described yet

WHO, 2020, Stolnicu, 2023; Zanonni 2023

Gastric type in situ adenocarcinoma

- Microscopic finding
- Preserved normal architecture but more complex (micropapille, cribriform)
- Columnar epithelium
- Clear/eosinophylic/foamy cytoplasm
- Abundant intracytoplasmic mucus
- Distinct cellular margins
- Round, basally located nuclei
- Nuclear atypia: low to high grade
- Mitotic figures and apoptotic bodies rare or absent (!)

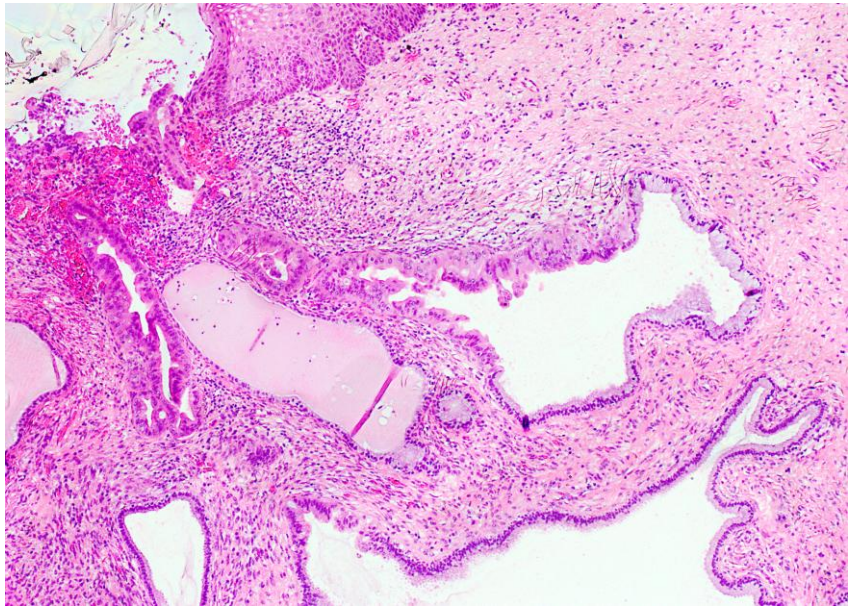

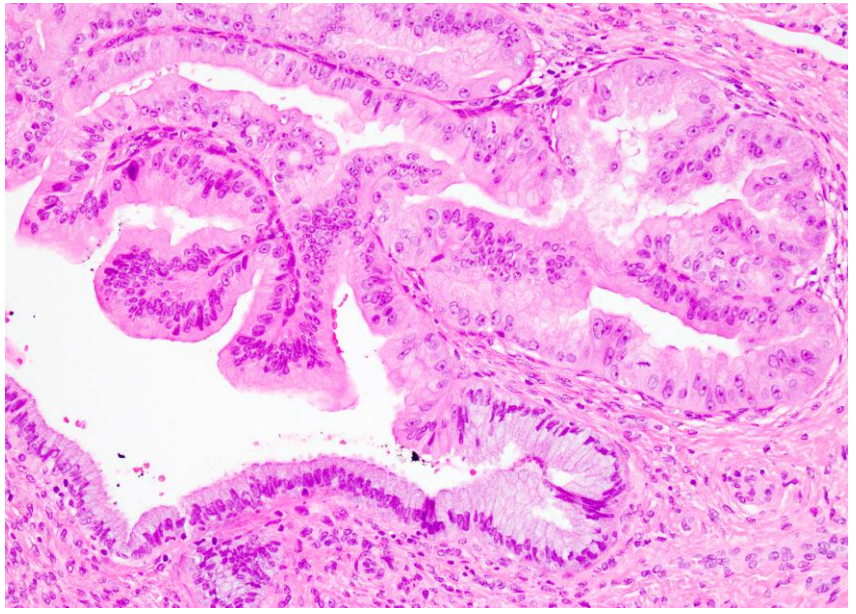

Talia, 2017

Atypical LEGH

- May form a grossly visible mass
- Location: upper endocervix
- Lobular clusters of glands aggregating around a central dilated duct
- Architectural abnormalities: short papillae projections
- Columnar cells with eosinophilic cytoplasm
- Nuclear enlargement, irregular nuclear contour, coarse chromatin
- Prominent nucleoli
- Loss of polarity
- Gastric type in situ adenocarcinoma with lobular architecture!

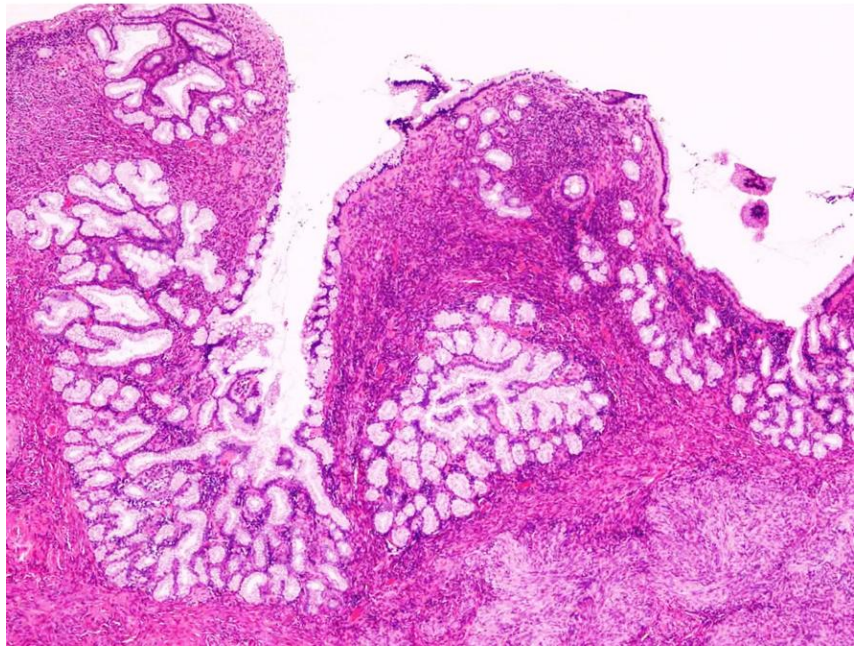

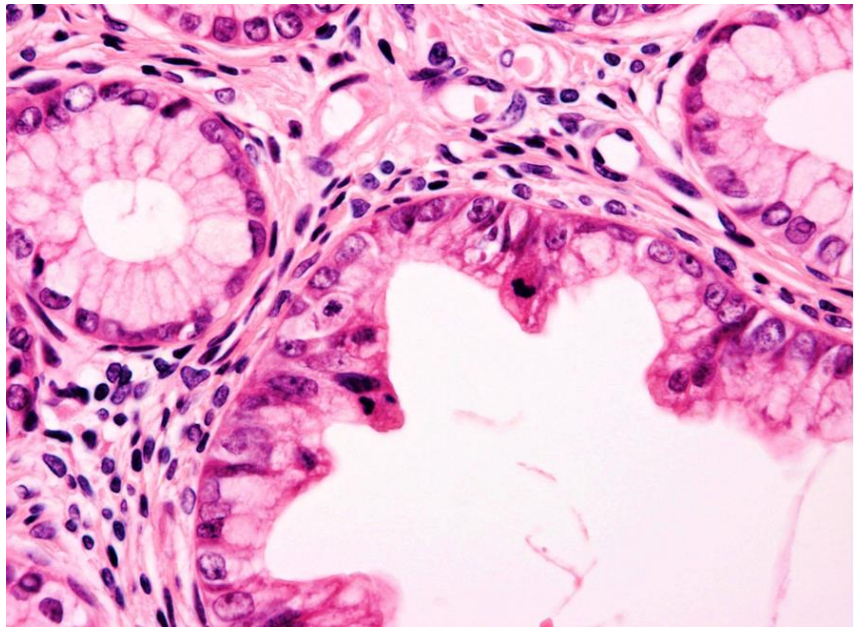

International Journal of Gynecological Pathology
40:S66–S74, Lippincott Williams & Wilkins, Baltimore
Copyright © 2021 International Society of Gynecological Pathologists. Published by Wolters Kluwer Health, Inc. on behalf of the International Society of Gynecological Pathologists.

OPEN

Article

Grading of Endocervical Adenocarcinomas: Review of the Literature and Recommendations From the International Society of Gynecological Pathologists

Karen L. Talia, M.B.B.S., F.R.C.P.A., Esther Oliva, M.D., Joseph T. Rabban, M.D., Naveena Singh, F.R.C.Path., Simona Stolnicu, M.D., and W. Glenn McCluggage, F.R.C.Path.

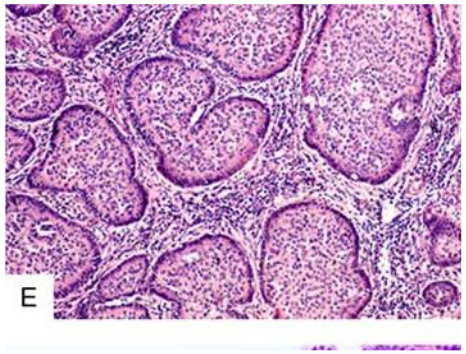

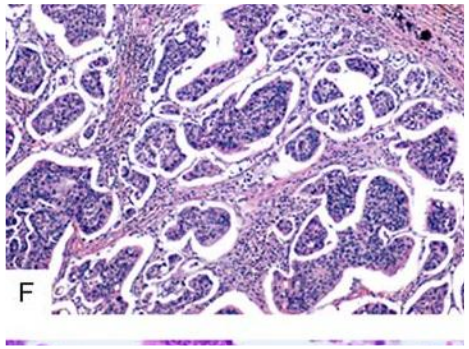

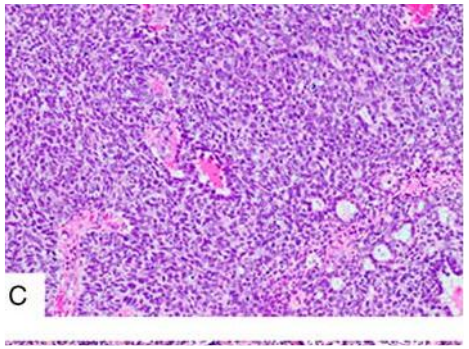

Grading in ECAs

- Prognostic significance of grading is controversial
- HPVA ECAs (with some exceptions: MP, ISMC, signet-ring) should be graded using a combination of architecture and cytology
- Modified FIGO system is recommended (using a 10% cut-off for solid component and 50% cut-off for marked nuclear atypia)
- HPVI adenocarcinomas should not be graded
- ECAs admixed with neuroendocrine carcinoma should not be graded (consider high-grade regardless of morphology)

Silva classification parameters: alternative morphologic parameters to identify early-stage patients at risk for LNM

- Tumor-stromal interface
- Presence or absence of destructive stromal invasion
- Presence or absence of LVI
- Architecture
- Grade of cytologic atypia



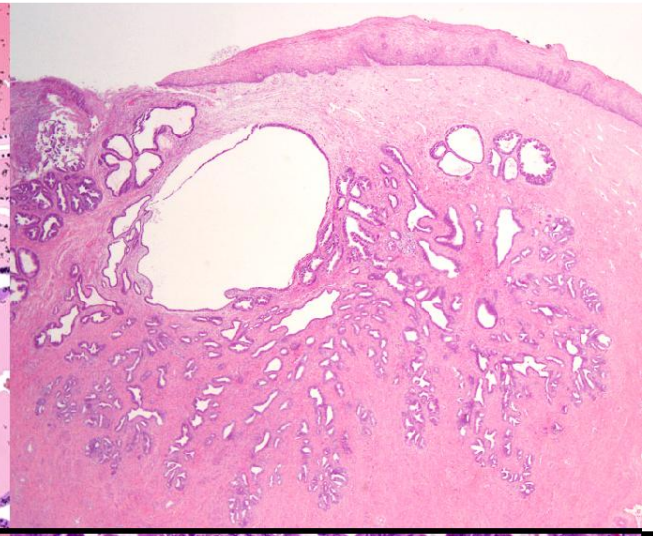

Pattern Silva A

No destructive stromal invasion

Usually preserved lobular architecture

Well-differentiated and rounded glands; may have complex endophytic intraglandular architecture (cribriform, papillae, less than 5mm in diameter); No LVI; **0% LNM**

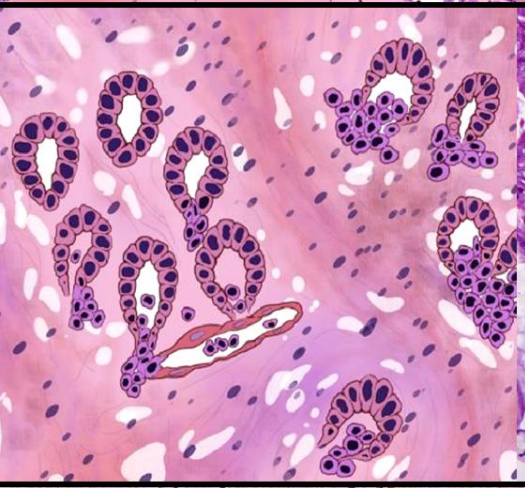

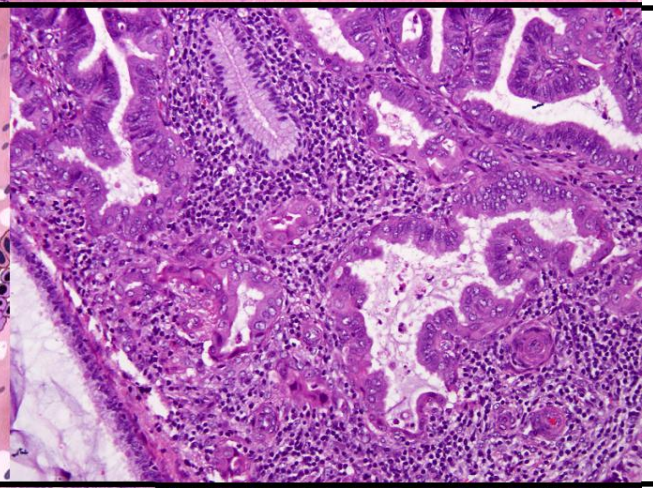

Pattern Silva B

Early (limited) destructive stromal invasion

Less than 4 x field, 5mm in diameter

Similar architecture to pattern A at low-power magnification; +/- LVI; **4.4% LNM**

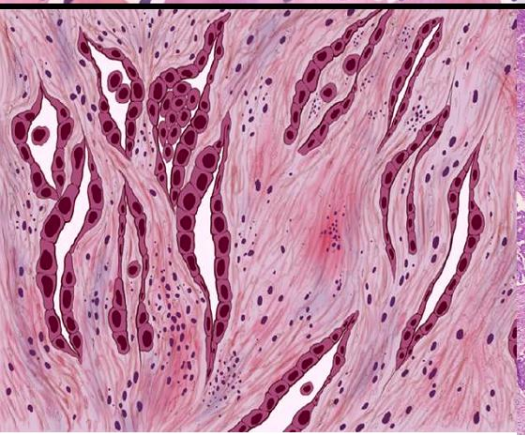

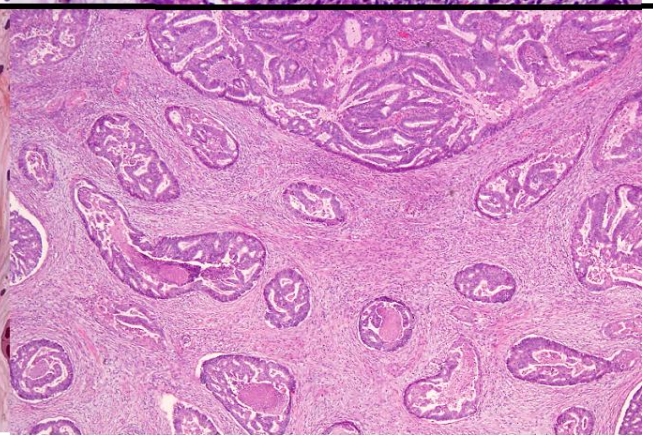

Pattern Silva C

Extensive and diffuse destructive invasion

Extensive desmoplastic stromal response

Angulated glands; high nuclear grade; +/- LVI; **23.8% LNM**

ISGyP recommendations IntJGynPathol 2022

- To include Silva pattern of invasion in pathology reports with a diagnosis of invasive HPVA ECA
- The pattern of invasion can be included as a subheading of the main diagnosis line, or in the comment section
- Report the worst pattern that you see
- To be only reported on surgical specimens (with negative margins)
- Not recommended for HPVIs (most/all of Silva C pattern)

Alvarado-Cabrero 2022; *Stolnicu, 2019*

Stolnicu et al, Pathology journal, 2022- New binary Silva system and treatment proposal

We proposed a **binary Silva system**:

- **Silva low-risk cases** (pattern A and B without LVI)
- **Silva high-risk cases** (pattern B with LVI and pattern C)

Treatment of patients could theoretically be individualised:

- Silva low-risk cases (pattern A and B without LVI): radicality can be abbreviated and LN disection can be avoided
- Silva high-risk cases (pattern B with LVI and pattern C): radical hysterectomy, lymphadenectomy (if sentinel LN+) with or without adjuvant therapy

Binary pattern based (Silva) system

- Is more prognostically informative, even in a small cohort of cases (38 cases were included)
- Silva high-risk tumors are enriched in mutations in PIK3CA, ATRX and ERBB2 comparing to Silva low-risk; provides a biologic basis for consolidating the Silva system into low-risk and high-risk categories
- Showed improved interobserver agreement (kappa=0.634) compared with the three-tier system (kappa=0.564)
- ISGyP ECA project recommends to use binary system to report ECAs

Dodington, 2024; Sharma, 2023; Zyla, 2024

2. Squamous cell carcinoma of the cervix (SCC)

- Cervical cancer is the fourth most common malignancy to affect women worldwide
- SCC represents 75% of all cervical cancers
- The incidence as well as the associated mortality are still increasing in low- and middle-income countries (Africa, Asia, South America, Est Europe)
- In contrast to many advances in ECAs, less information on SCCs has been published recently
- Traditionally: all SCCs were thought to be linked with HPV infection
- In the past: HPV-negativity was attributed to low sensitivity techniques

Lancet Global Health, 2020; WHO, 2020

Issues with 2014 WHO classification: (based on morphology alone)

Usual/Classic type	keratinizing and non-keratinizing types, based on the presence of keratin pearls formation; clear cutoff regarding the extend of keratinization required to diagnose a keratinizing SCC was not defined
Keratinizing and non-keratinizing types	prognostic significance of each tumor type was debatable
Other histologic subtypes	basaloid, verrucous, warty, papillary, squamo-transitional and lymphoepithelioma-like carcinoma; all thought to be HPV-driven and with various morphology; prognosis is debatable

Reproducibility in recognition of SCC tumor types; Stolnicu, 2024

- WHO 2014: provided insufficient data to enable reproducibility among tumor types
- 10 international centers, including 670 SCCs; original tumor type vs consensus tumor type based on WHO 2014 (2 expert pathologists, by consensus)
- Most cases (47%) were keratinizing by original tumor type and nonkeratinizing (51%) by consensus tumor type
- Kappa agreement between original and consensus tumor type was low (0.572)
- Predictive values for original and consensus tumor types regarding OS and PFS were low

SCC –recent developments

- Recently: HR-HPV in 90-95% of cases; few studies and case reports indicating that LR-HPV and HPV-independent SCCs even rare, can exist
- 3 cases of HPVIs in a Swedish cohort, 6 cases in Austrian cohort and 12 cases in a Spanish cohort

HPV-negative Tumors in a Swedish Cohort of Cervical Cancer

Malin Kaliff, M.Sc., Mats G. Karlsson, M.D., Ph.D., Bengt Sorbe, M.D., Ph.D.,
Louise Bohr Mordhorst, M.D., Ph.D., Gisela Helenius, Ph.D., and Gabriella Lillsunde-Larsson, Ph.D.

HPV-negative Squamous Cell Carcinomas of the Cervix
With Special Focus on Intraepithelial Precursor Lesions

Sigrid Regauer, MD, Olaf Reich, MD,† and Karl Kashofer, PhD**

HPV-negative tumors of the uterine cervix

Inmaculada Nicolás[1,2] · Lorena Marimon[2,3] · Esther Barnadas[2,3] · Adela Saco[3] · Leonardo Rodríguez-Carunchio[3] · Pere Fusté[1] · Cristina Martí[1] · Adriano Rodriguez-Trujillo[1] · Aureli Torne[1] · Marta del Pino[1] · Jaume Ordi[2,3]

Comparison of WHO 2014 and 2020 classification on SCCs

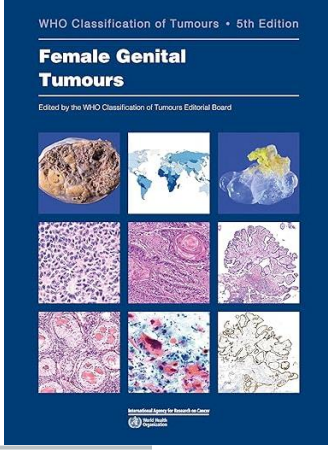

2014 WHO classification	2020 WHO classification
Squamous cell carcinoma usual type	Squamous cell carcinoma, HPV-associated
Keratinizing	Squamous cell carcinoma, HPV-independent
Non-keratinizing	Squamous cell carcinoma, NOS
Papillary	
Basaloid	
Warty	
Verrucous	
Squamo-transitional	
Lymphoepithelioma-like	

SCC –recent developments

- Histologic types have become histologic patterns with no prognostic significance (WHO, 2020)
- HPV status is a prognostic and predictive factor (only few studies!!)
- Questions unanswered regarding morphology of HPVIs and ancillary tests!!
- WHO 2020 does not include HPVI squamous precursor lesions

Rodriguez-Carunchio, 2015; Nicolas, 2019; Kaliff, 2020; WHO 2020; Regauer, 2022

Incidence and Clinicopathologic Characteristics of Human Papillomavirus–independent Invasive Squamous Cell Carcinomas of the Cervix

A Morphologic, Immunohistochemical, and Human Papilloma-Virologic Study of 670 Cases

Simona Stolnicu, MD, PhD, Douglas Allison, MD,† Aaron M. Praiss, MD,‡ Basile Tessier-Cloutier, MD,† Amir Momeni Boroujeni, MD,† Jessica Flynn, MS,§ Alexia Iasonos, PhD,§ Rene Serrette, BS,† Lien Hoang, MD,‖ Andrei Patrichi, MD,* Cristina Terinte, MD,¶ Anna Pesci, MD,# Claudia Mateoiu, MD,** Ricardo R. Lastra, MD,†† Takako Kiyokawa, MD,‡‡ Rouba Ali-Fehmi, MD,§§ Mira Kheil, MD,§§ Esther Oliva, MD,‖‖ Kyle M. Devins, MD,‖‖ Nadeem R. Abu-Rustum, MD,‡¶¶ and Robert A. Soslow, MD†*

- Negative for HR-HPV (ISH) and p16: 10 cases (out of 376 early-stage SCCs that were tested)
- Older patients: mean 72y (versus 50y HPVAs); higher FIGO stage (most diagnosed in stage 3 and 4)
- Keratinizing, nonkeratinizing
- 2/10 cases were p53 aberrant
- 1/10 had metastases in pelvic organs, 2/10 presented distant recurrences (lung, bone, liver) and 3/10 died of disease

Cervical Human Papillomavirus-independent squamous cell carcinoma: a clinicopathological review and outcomes analysis in comparison to Human Papillomavirus-associated squamous cell carcinoma

Stolnicu et al, Mod Pathol, 2025

- 49 cases of HPV-/p16- SCCs were compared to 363 HPVA SCCs
- HPVIs patients were older, with larger tumors, in higher stage; 7 had uterine prolapse
- HPVIs were more frequently of keratinizing histology and p53 abnormal
- HPVIs recurred more frequently and had worse survival than HPVAs
- HPVI p53 abnormal had higher risk of recurrence and death of disease than HPVI p53 wild type and HPVAs

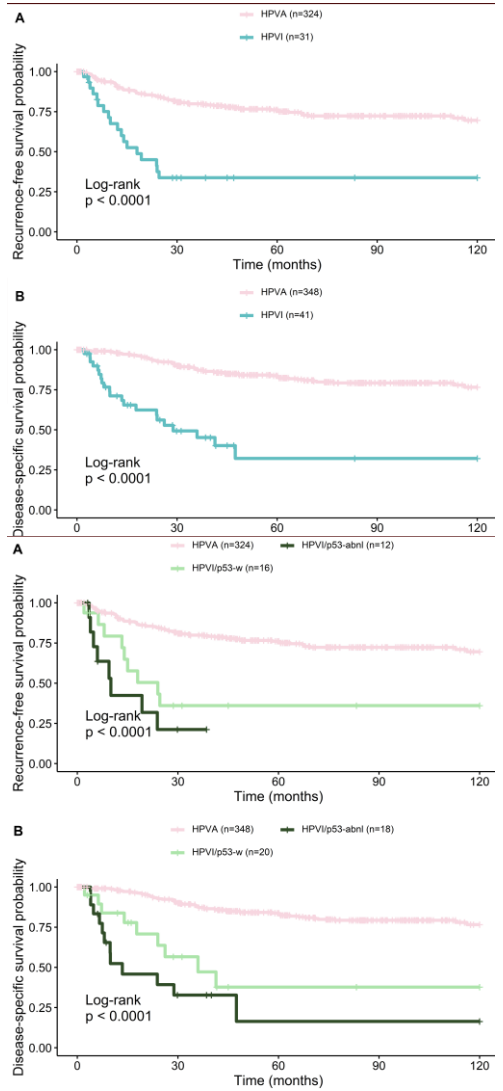

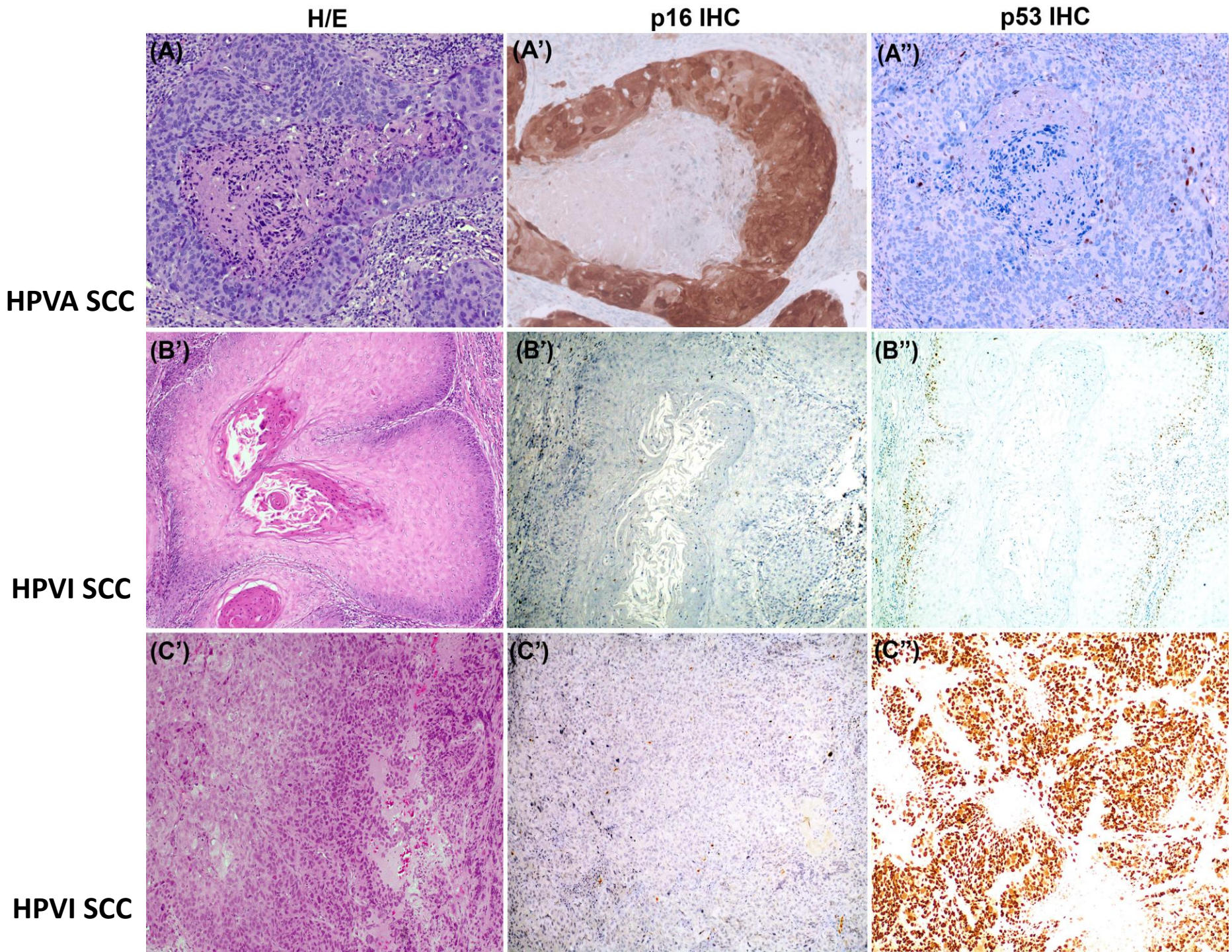
H/E
p16 IHC
p53 IHC
HPVA SCC
HPVI SCC
HPVI SCC
(A)
(A')
(A")
(B')
(B')
(B")
(C')
(C')
(C")

SCC HPVI - role of immuno and HPV status

- True HPVIs: HPV (ISH) and p16 (IHC) negative!!
- HR HPV ISH shows higher sensitivity and specificity when compared to PCR method
- HPV ISH may be negative in LR HPV or other HPV types not captured by the test
- p16: surrogate marker for the presence of HR HPV infection; strongly and diffusely block-like positive in HPVAs
- p16 can be sometimes negative even in HPVAs, due to various technical issues, paraffin block tissue or association with LR HPV (6, 11 etc)
- p53 is of help to further classify HPVIs (accepted as a surrogate marker for the *TP53* mutation)
- p53 immune staining interpretation using criteria from the vulva

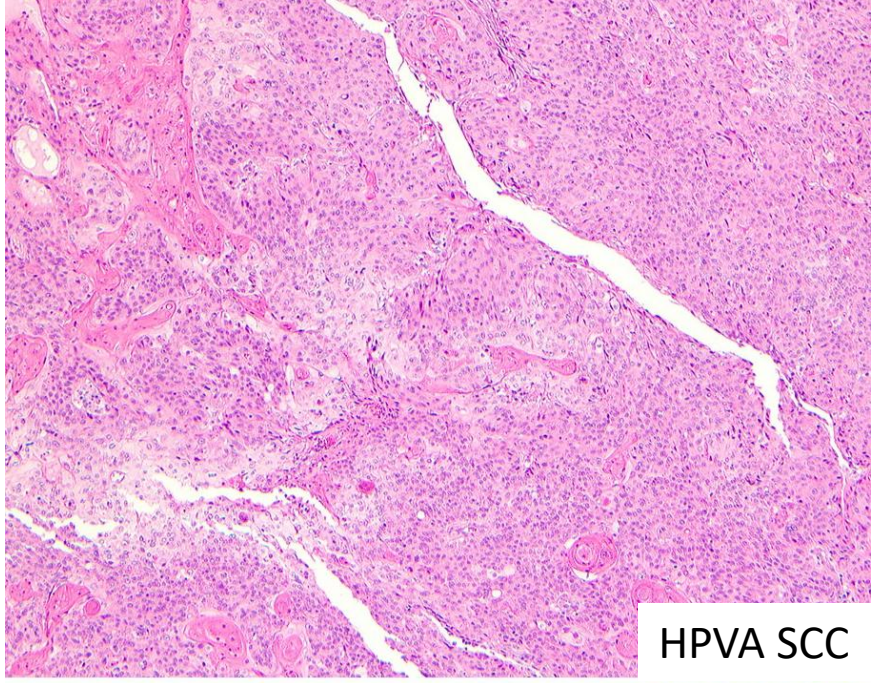

HPVA SCC

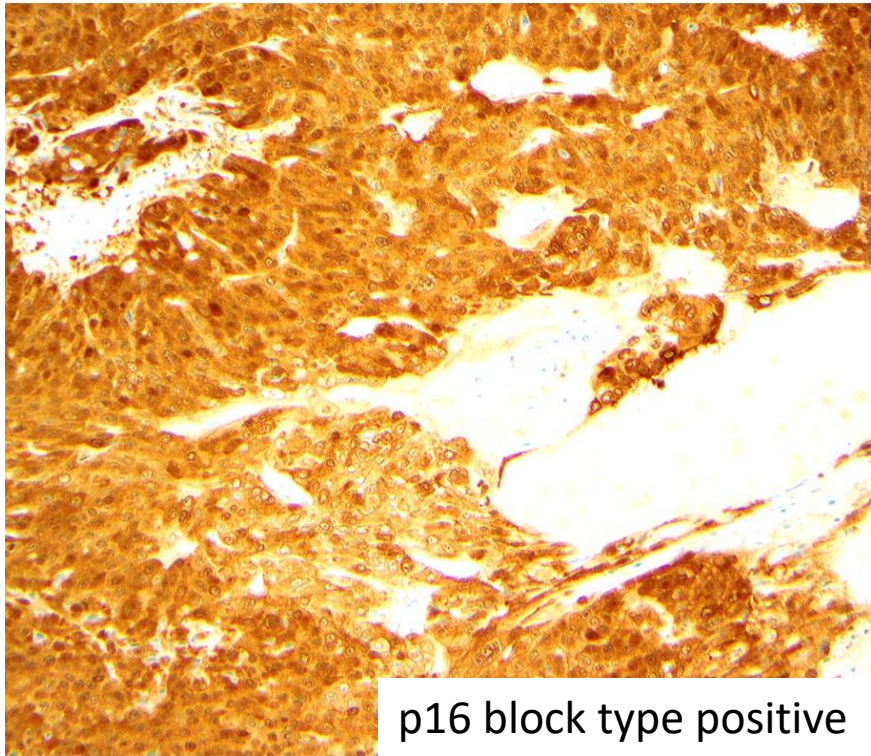

p16 block type positive

Tessier-Cloutier et al: abnormal vs wild type staining in precursor and invasive component

- **a) p53-abnl**: continuous strong nuclear expression at the periphery of invasive tumor cell nests with or without extension towards the center of the nests
- **b) p53-abnl**: null expression (complete absence of positivity in the tumor)
- **c) p53-abnl**: cytoplasmic expression (cytoplasmic or both cytoplasmic and nuclear staining)
- p53-w: scattered pattern (marked reduced staining, significantly attenuated, with weak intensity in >70% of tumor cells) or showed discontinuous staining at the periphery of tumor cell nests (mid-epithelial, basal sparing)

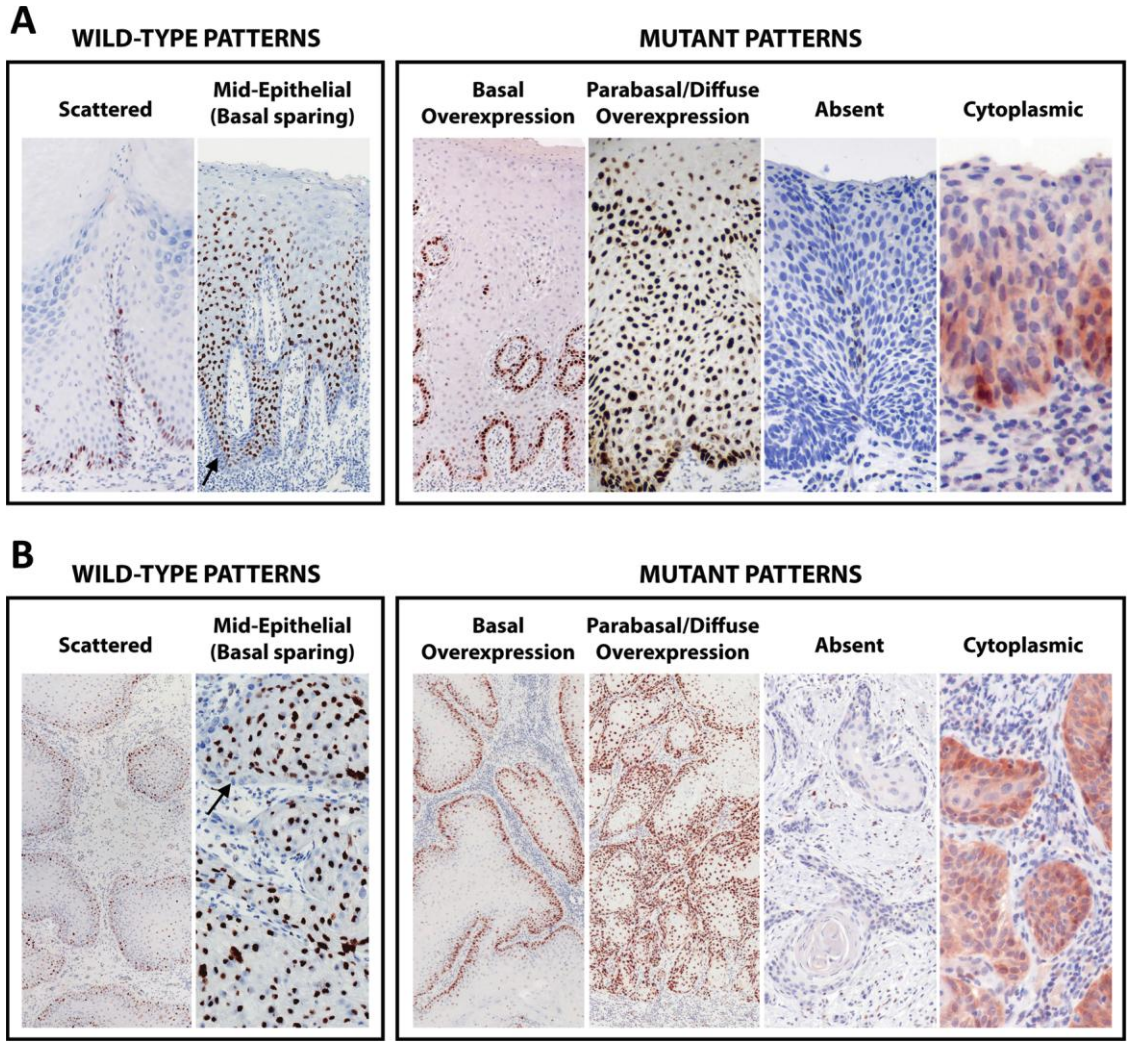

Various grading systems in SCCs: poor reproducibility and limited predictive accuracy for SCC

TABLE 1. *Consensus Broders grading system*

Grade	Presence of keratin pearls	Tumor cells	Mitotic figures
Grade 1 (well-differentiated)	Numerous	Mature, with abundant eosinophilic cytoplasm, intercellular bridges, and large but uniform nuclei	<3 mitotic figures per 10 HPF
Grade 2 (moderately differentiated)	Rare	Pleomorphic nuclei (even focally), with less abundant cytoplasm, indistinct intercellular bridges	3–10 mitotic figures per 10 HPF
Grade 3 (poorly differentiated)	Very rare/absent	Hyperchromatic and very pleomorphic nuclei, scant cytoplasm	>10 mitotic figures per 10 HPF

TABLE 2. *Jesinghaus grading system*

Grade	No. buds*	Size of buds	Novel grade score†
1	0	>15 tumor cells (large)	2–3 score: Grade 1 (G1, well-differentiated)
2	1–14	5–15 tumor cells (intermediate)	4–5 score: Grade 2 (G2, moderately differentiated)
3	>15	2–4 tumor cells (small)	6–7 score: Grade 3 (G3, poorly differentiated)
4	—	Single-tumor cell detached within the stroma	—

*The number of buds is determined by the highest budding activity (hotspot), in 10 high-power fields.
†The sum of tumor budding and cell cluster size score generates a final grading score ranging from 2 to 7.

International Journal of Gynecological Pathology
00:1–12, Lippincott Williams & Wilkins, Baltimore
Copyright © 2023 by the International Society of Gynecological Pathologists

Original Article

Proposal of Novel Binary Grading Systems for Cervical Squamous Cell Carcinoma

Simona Stolnicu, M.D., Ph.D., Aaron M. Praiss, M.D., Douglas Allison, M.D., Basile Tessier-Cloutier, M.D., Jessica Flynn, M.S., Alexia Iasonos, Ph.D., Lien Hoang, M.D., Cristina Terinte, M.D., Anna Pesci, M.D., Claudia Mateoiu, M.D., Ricardo R. Lastra, M.D., Takako Kiyokawa, M.D., Rouba Ali-Fehmi, M.D., Mira Kheil, M.D., Esther Oliva, M.D., Kyle Devins, M.D., Nadeem Abu-Rustum, M.D., and Robert A. Soslow, M.D.

- Incorporating tumor stroma morphology (myxoid vs fibrous) into Broders' and Jesinghaus grading systems expressed as low or high-grade better predicted OS, RFS and the presence of LNM when compared with existing schemes

Binary low grade

- Broders/Jesinghaus grade 1
- Broders/Jesinghaus grade 2, with fibrous stroma

Binary high grade

- Broders/Jesinghaus grade 2, with myxoid stroma
- Broders/Jesinghaus grade 3

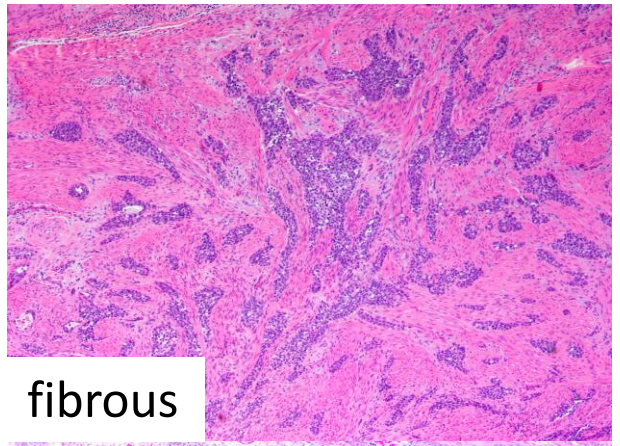

fibrous

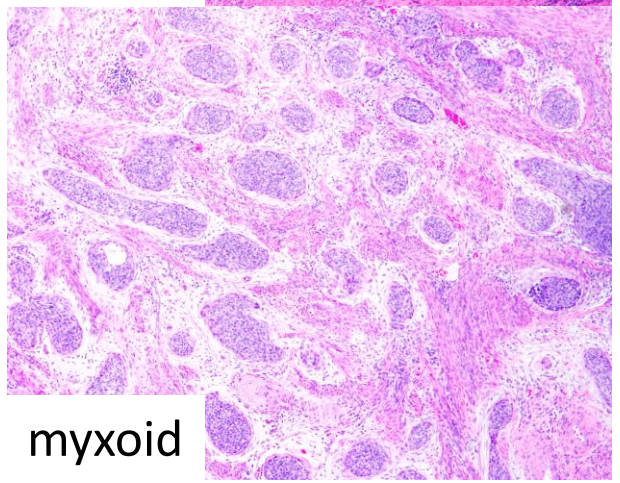

myxoid

HSIL/CIN 2

retained maturation and mitoses 2/3 thickness

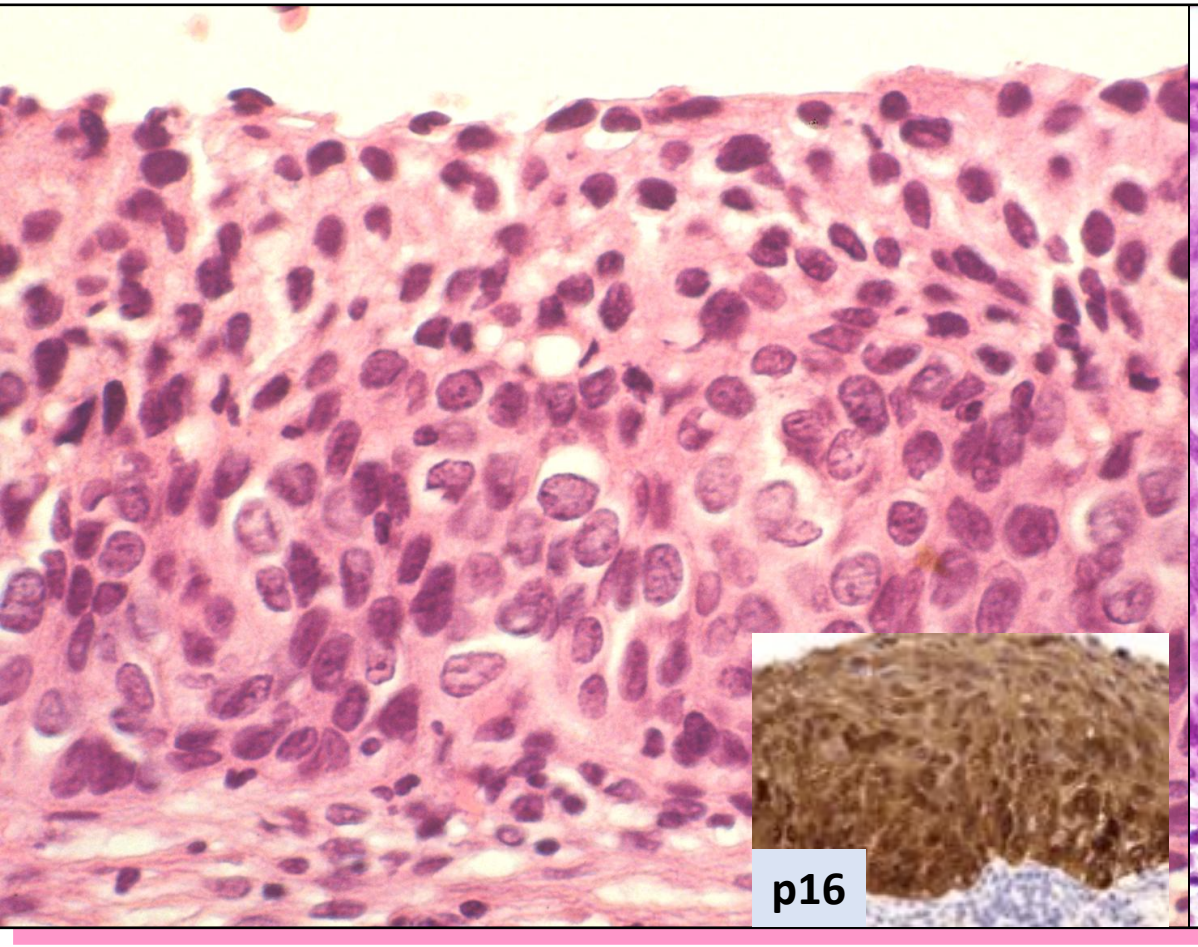

HSIL/CIN 3

complete/ subtotal lost of maturation and mitoses full thickness

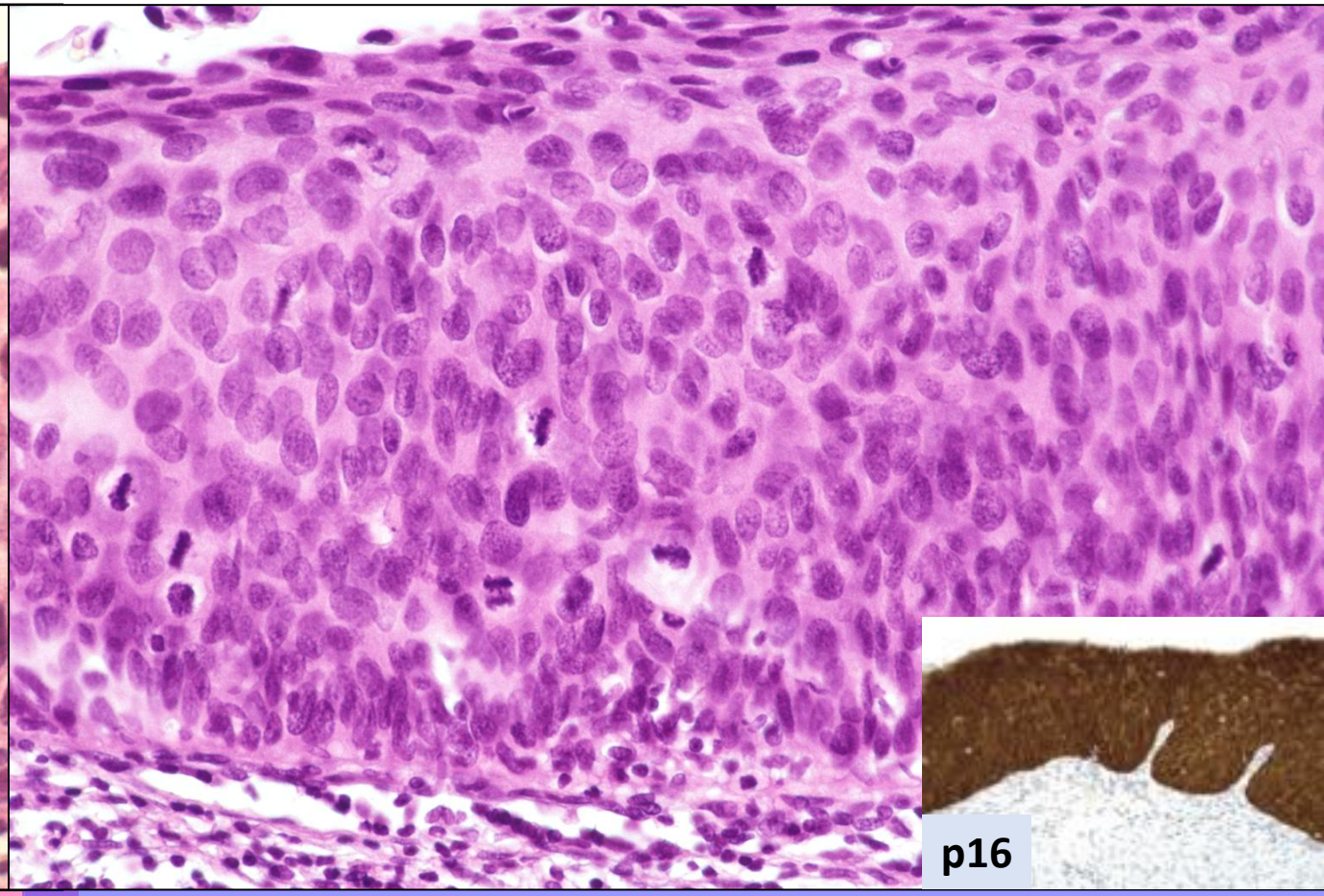

HPV-negative Squamous Cell Carcinomas of the Cervix With Special Focus on Intraepithelial Precursor Lesions

Sigrid Regauer, MD, Olaf Reich, MD,† and Karl Kashofer, PhD**

- First characterisation of 3 HPVI precursor lesions
- All occurred in the transformation zone
- Morphology: undifferentiated basaloid or highly differentiated keratinizing (simiar to d-VIN, vaVIN)
- Can be p16+ block-like!!
- HPV testing is mandatory for morphologic diagnosis
- Mutant and wild type p53 expression (some correlation with TP53 mutation status)

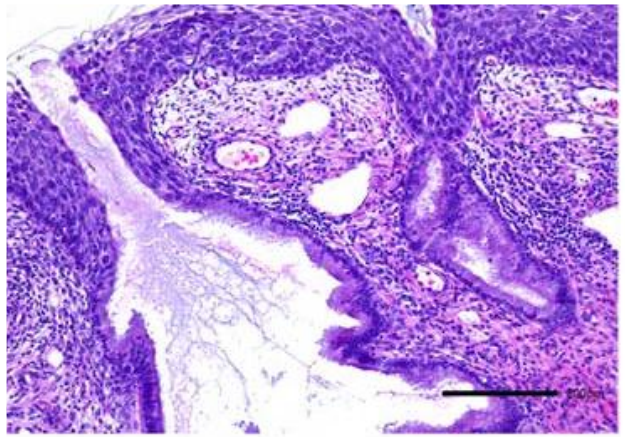

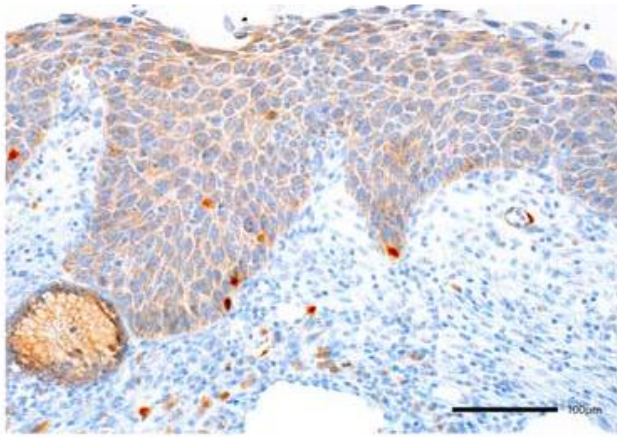

Basaloid type; p16+; HPV-

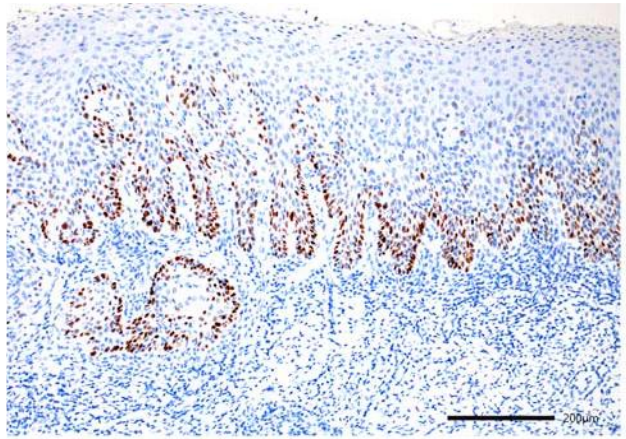

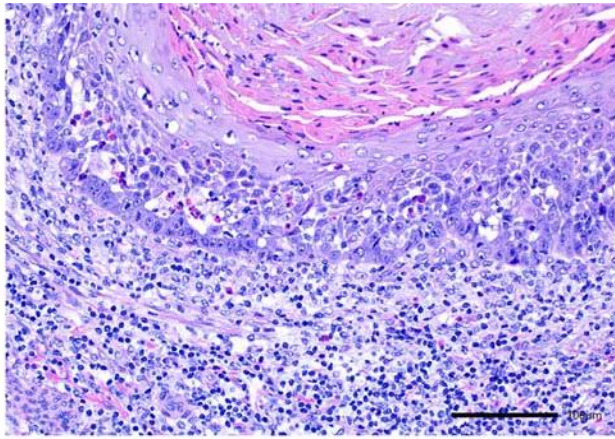

Keratinized (dVIN) type; HPV-

Cervical Human Papillomavirus-independent squamous cell carcinoma: a clinicopathological review and outcomes analysis in comparison to Human Papillomavirus-associated squamous cell carcinoma

Stolnicu et al, Mod Pathol, 2025



Basaloid-like

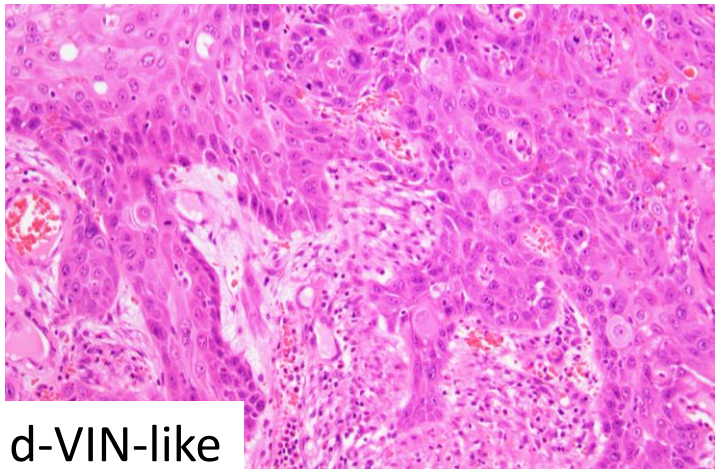

d-VIN-like

Precursor lesions	HPVAs	HPVIs
None	34 (9.5%)	15 (42.9%)
HSIL	322 (89.7%)	0 (0%)
Basaloid-like (p53-abnl and p53-w)	0 (0.0%)	**11 (31.4%)**
AIS/SMILE	1 (0.3%)	0 (0.0%)
dVIN-like (p53-abnl)	0 (0.0%)	**6 (17.1%)**
vaVIN-like (VAAD/DEVIL) (p53-w)	0 (0.0%)	**3 (8.6%)**
Mixed (HSIL/AIS)	2 (0.6%)	0 (0.0%)
Unknown	4	14

HPVI squamous precursor lesions

- Can have either differentiated (d-VIN-like or va-VIN-like) or basaloid-like morphology
- Both p53-abnl and p53-w varieties exist
- All p53-abnl precursors are associated with p53-abnl invasive SCC carcinomas, and all p53-w precursors are associated with p53-w SCC invasive carcinomas
- It is recommended these precursors be classified as **HPVI cervical intraepithelial neoplasia (CIN)** and further categorized as **p53-abnl** or **p53-w**
- Difference in treatment, prognosis, follow-up between HPVI CIN and HSIL??? How about screening? How about local conditions to lead to the progress to cancer? Work in progress…

New classification proposal for cervical SCCs
Stolnicu et al, Mod Pathol, 2025

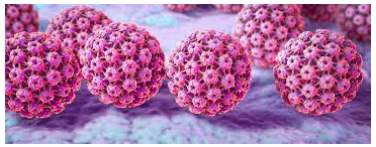

→ HPVA HSIL p16/HPV+ → SCC HPV-Associated (HPVA) p16/HPV+

Local conditions
??????????

→ HPVI CIN p16/HPV- p53 w (vaVIN-like, Basaloid-like) → SCC HPV-Independent (HPVI) p16/HPV-, p53 w

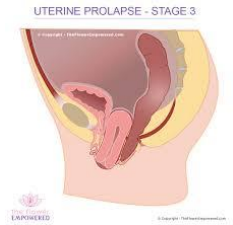

→ HPVI CIN p16/HPV- p53 abnl (dVIN-like, Basaloid-like) → SCC HPV-Independent (HPVI) p16/HPV-, p53 abnl

Thank you

www.patologia.ro, simonastolnicu@icloud.com

@simostol