The British Association of Gynaecological Pathologists



Charles Matthew Quick, M.D.
University of Arkansas for Medical Sciences
Little Rock, Arkansas, United States

Dr. Charles “Matt”hew Quick is a professor and clinical educator in the Department of Pathology at UAMS in Little Rock, Arkansas. He completed fellowships in surgical pathology at UAMS and Women’s & Perinatal pathology at Harvard Medical School, Brigham & Women’s Hospital. Dr. Quick serves as the Vice Chair of Anatomic Pathology, Director of Gynecologic Pathology, and the Surgical Pathology Fellowship.

He has published numerous research publications and review articles, and has authored and co-edited multiple textbooks, including “High-Yield Pathology: Gynecologic and Obstetric Pathology,” and the two-volume text book “Gynecologic and Obstetric Pathology.” Dr. Quick serves on the Education committee and is the chair of the Interactive Microscopy section for the USCAP Education Committee. He has taught numerous interactive microscopy courses for the USCAP at both annual meetings and the new teaching complex located in Palm Springs, California. He serves as a member of the Editorial boards of the American Journal of Surgical Pathology and the International Journal of Gynecologic Pathology. Dr. Quick’s research interests include the study of endometrial precancers, vulvar squamous carcinogenesis and the impact of epithelial-mesenchymal transition on tumor behavior. He lives in Little Rock, Arkansas with his wife Shelly and their three children Dexter, Bernice and Alice, as well as their energetic family dog, Zelda.

The best activity he ever took part in was to become a “Cub Master” for Cub Scout Pack 29 which has led to numerous outdoor adventures for all 3 of his children and wife. He still serves in this role to this day.

The British Association of Gynaecological Pathologists

Everyday Dilemmas in Gynaecological Pathology

Issues In Endometrial Cancer Staging

Charles Matthew Quick, M.D.

University of Arkansas for Medical Sciences

Friday, 7th March 2025

The British Association of Gynaecological Pathologists

Speaker disclosures

I have no financial conflicts of interest to disclose

Outline

- **Stage 1:**
  - **PITFALL: Adenomyosis and DOI**
  - **PITFALL: Fallopian tube ostia**
  - **Specific Caveats**

- **Stage 2:**
  - **Cervical Involvement?**

- **Stage 3:**
  - **Tubal Issues**
  - **Serosal Involvement**

Adenomyosis

- Tumor in Adenomyosis
  - Round contour
  - Endometrial stroma
  - Normal glands
  - Uninvolved foci of adenomyosis
  - Don’t trust CD10!
- Adenomyosis-like invasion
  - Irregular (yet smooth) contours
  - Single glands (runners)
  - +\- Desmoplasia
  - No normal glands or stroma

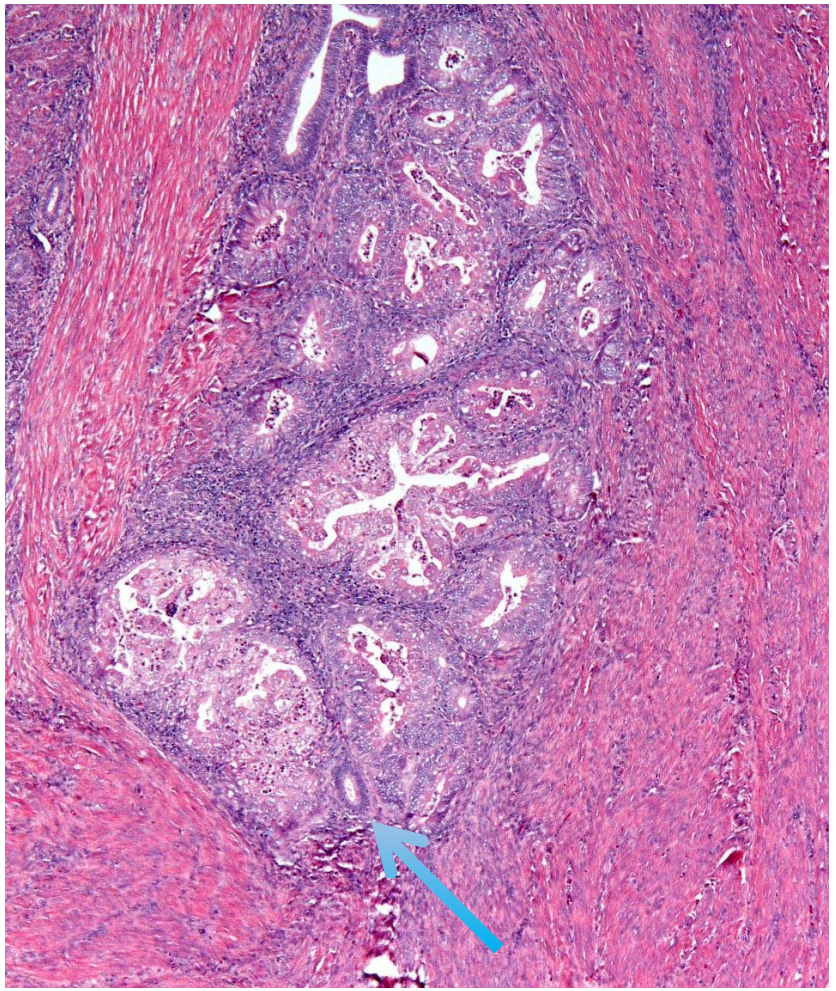

Adenomyosis-like invasion with smooth yet irregular contours, single glands, and desmoplasia

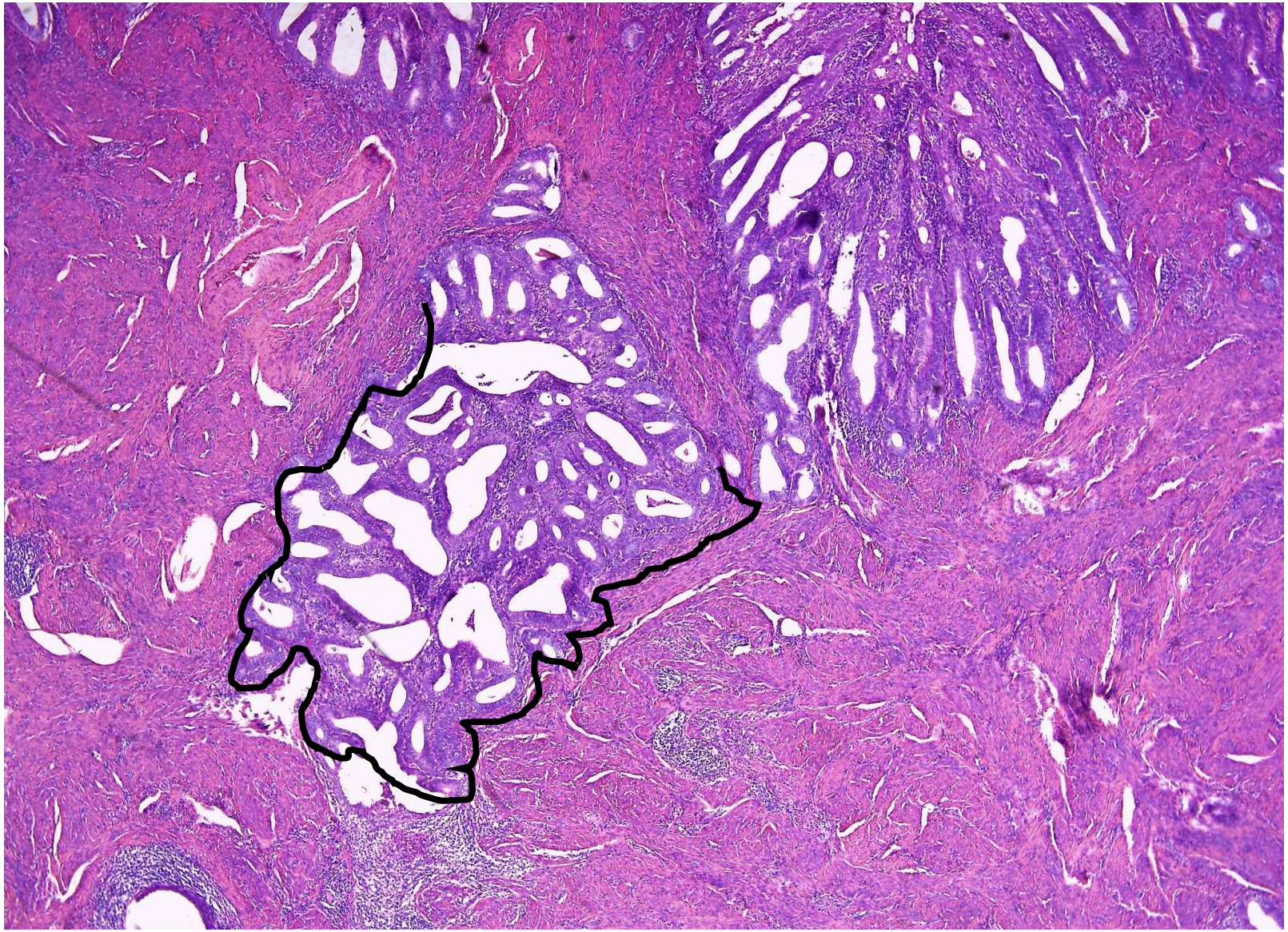

Invasion from Adenomyosis

- Recommendations from the 2018 ISGYP consensus article support measurement of the deepest focus regardless of if it arises from adenomyosis or not (Method A)
- Method A was felt to be more reproducible and less error prone
- Method B was felt to have too much potential to under-stage a carcinoma with deep invasion
- **If the adenomyosis and invasion is in the outer half then recommendations support staging as 1b with a note that there could be an overestimation of the actual depth of invasion.**

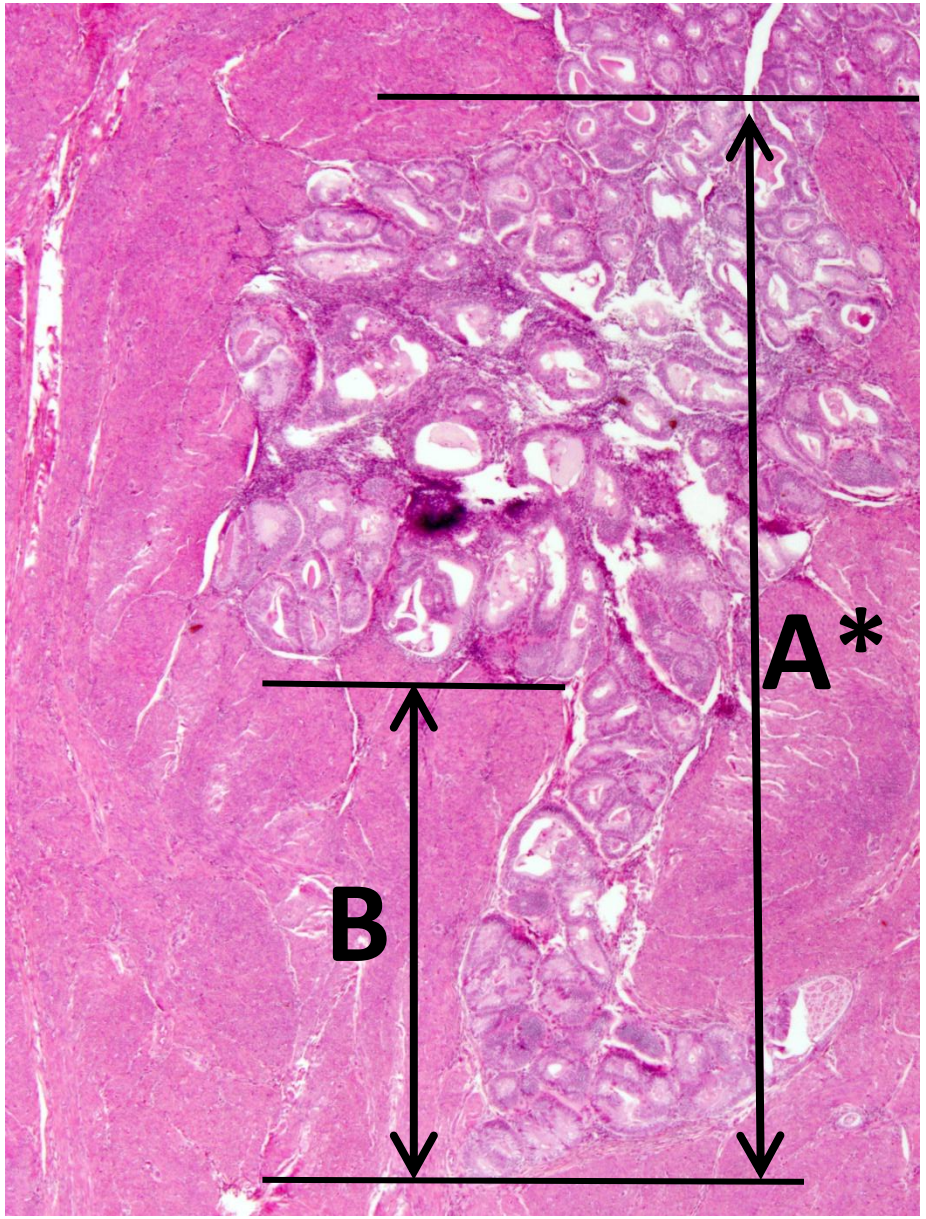

Beware the Tubal Ostia!

- The tubal ostia may become colonized by tumor
- Tangential sectioning may appear to be deeply invasive
- Preventing error begins at the gross dissection, describe the location of the section in the gross description!
- Features such as a wedge like contour, tubal epithelium and a smooth muscle coat (oval) can help

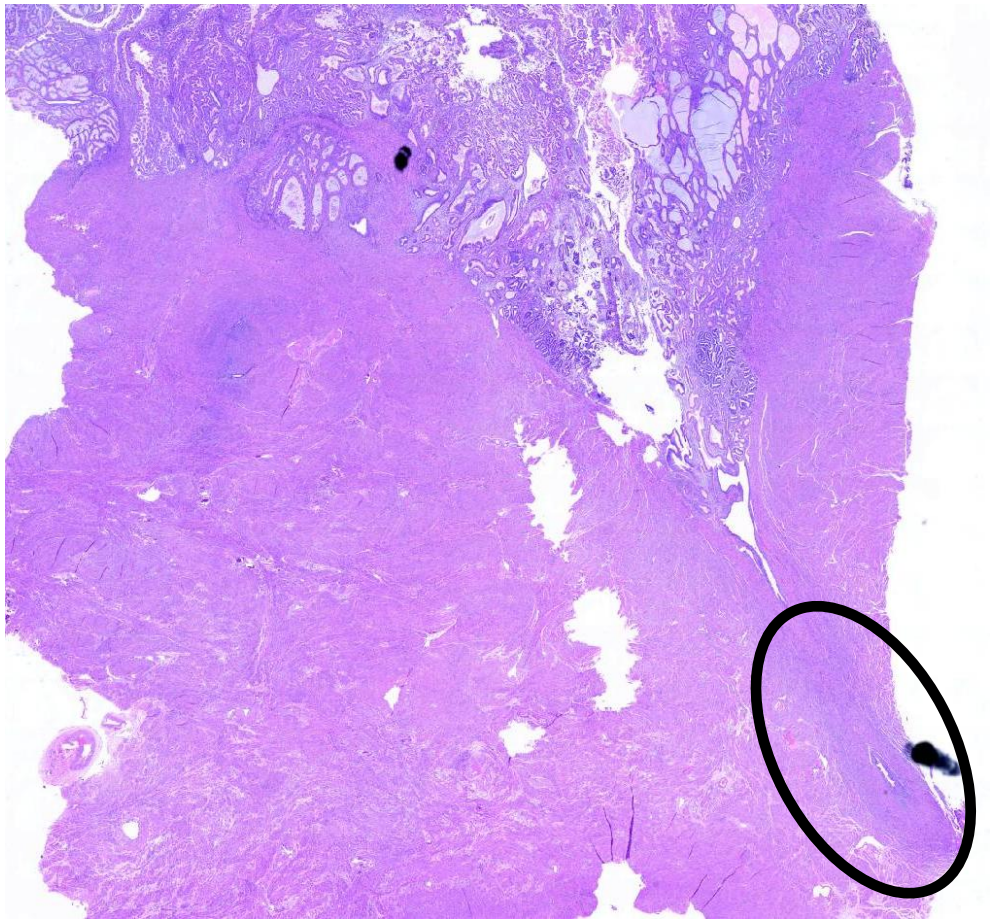

Myometrial Invasion – Specific Caveats

- **Lower Uterine Segment: treat the same as fundal tumors**
- **If a leiomyoma is involved: the thickness in that specific area counts!**
- **Desmoplasia alone should not be counted as invasion (but you can try keratins)**
- **Lymph-vascular space invasion below invasive tumor does NOT count**
- **Polyp invasion can be described, but should not be measured**

Outline

- **Stage 1:**
  - **PITFALL: Adenomyosis and DOI**
  - **PITFALL: Fallopian tube ostia**
  - **Specific Caveats**

- **Stage 2:**
  - **Cervical Involvement?**

- **Stage 3:**
  - **Tubal Issues**
  - **Serosal Involvement**

Cervical Involvement

- Stromal invasion = upstage to stage 2
- Usually straightforward, but can be complicated by endocervical gland involvement
- What's the cervical boundary line?
  - Epithelial: most proximal endocervical mucinous crypt
  - Other: Look at the underlying radial tissue edge, if cut/cauterized then likely cervical
- Desmoplasia is present in 50% of cases

Other Indicators of Cervical Invasion

- In the absence of desmoplasia these features suggest stromal invasion:
  - **Glands in the outer half of the cervix***
  - Confluent glandular growth
  - Malignant glands in-between or deeper than endocervical glands
  - Absence of superficial involvement
  - Dilated or abnormally small glands

*** When desmoplasia is lacking, malignant glands in the inner 1\3 likely represents superficial (non-invasive) disease**

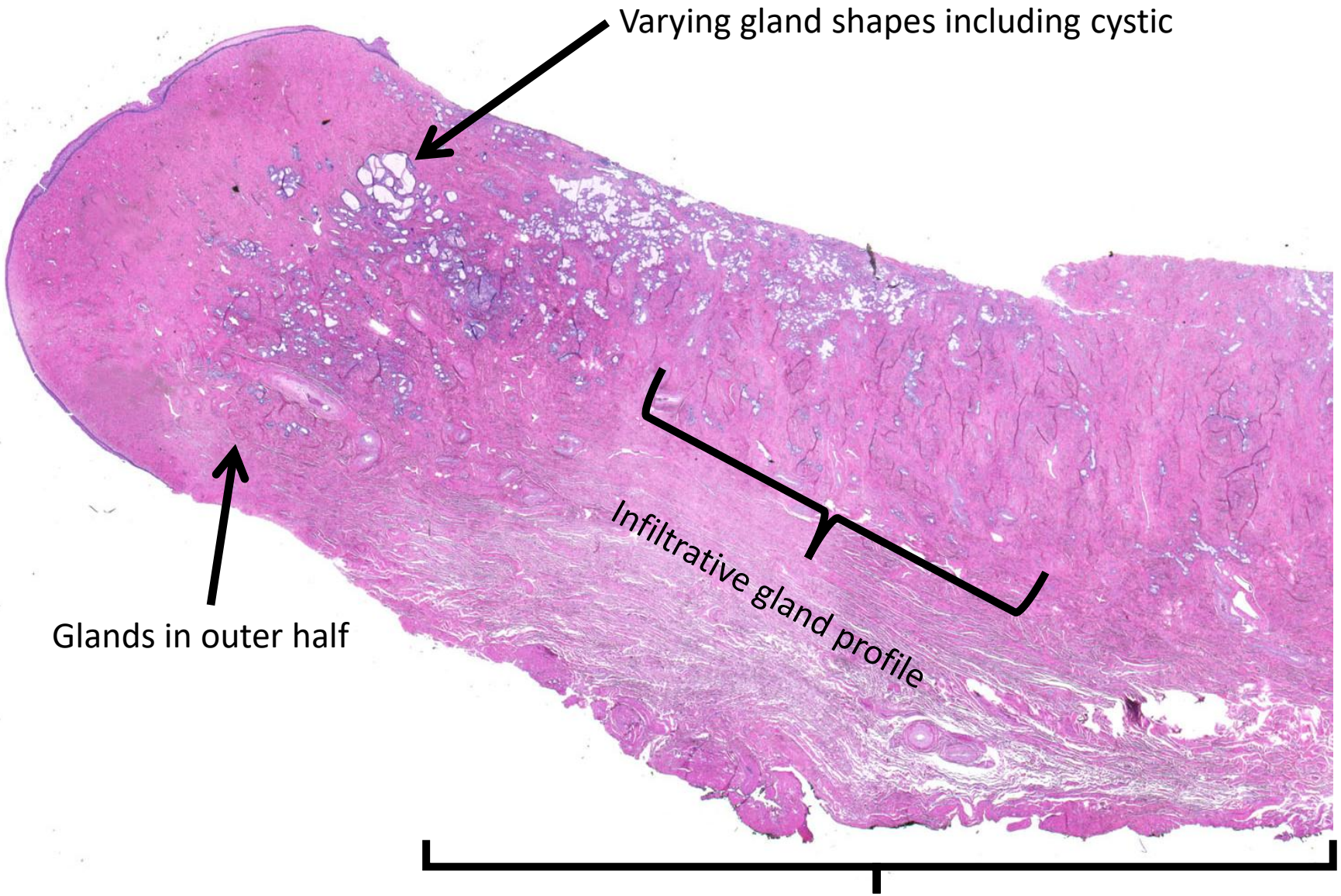
Varying gland shapes including cystic
Glands in outer half
Infiltrative gland profile
Cauterized outer surface

PITFALL ALERT

- **In certain cases cervical glands show a dramatic shift in morphology within the cervical stroma**

- Appear bland and “mesenephroid” with eosinophilic secretions

- Look for:
  - Haphazard arrangement
  - Cribriforming
  - Mitotic figures

Endometrial carcinoma in the cervix with no desmoplasia or significant nuclear atypia

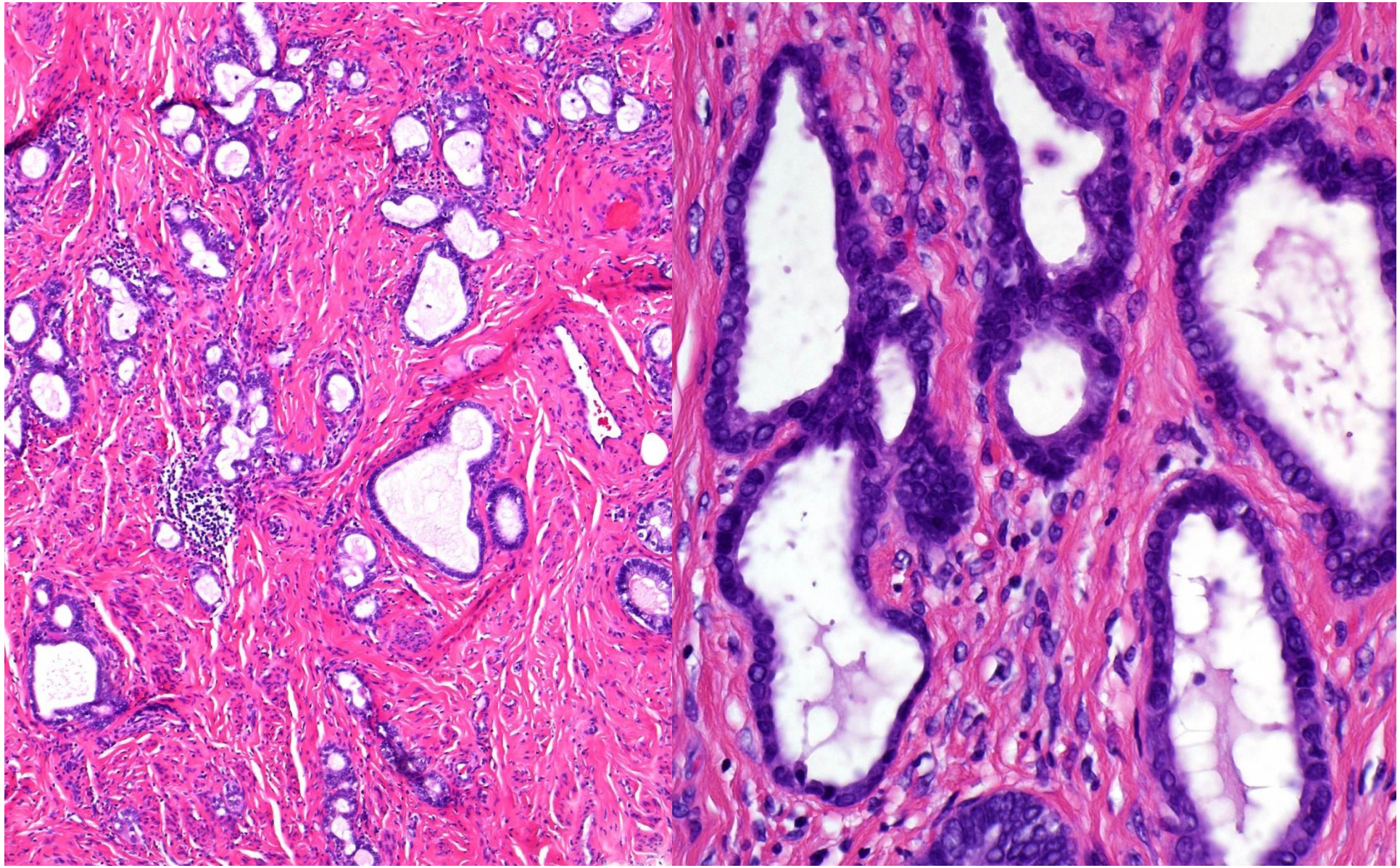

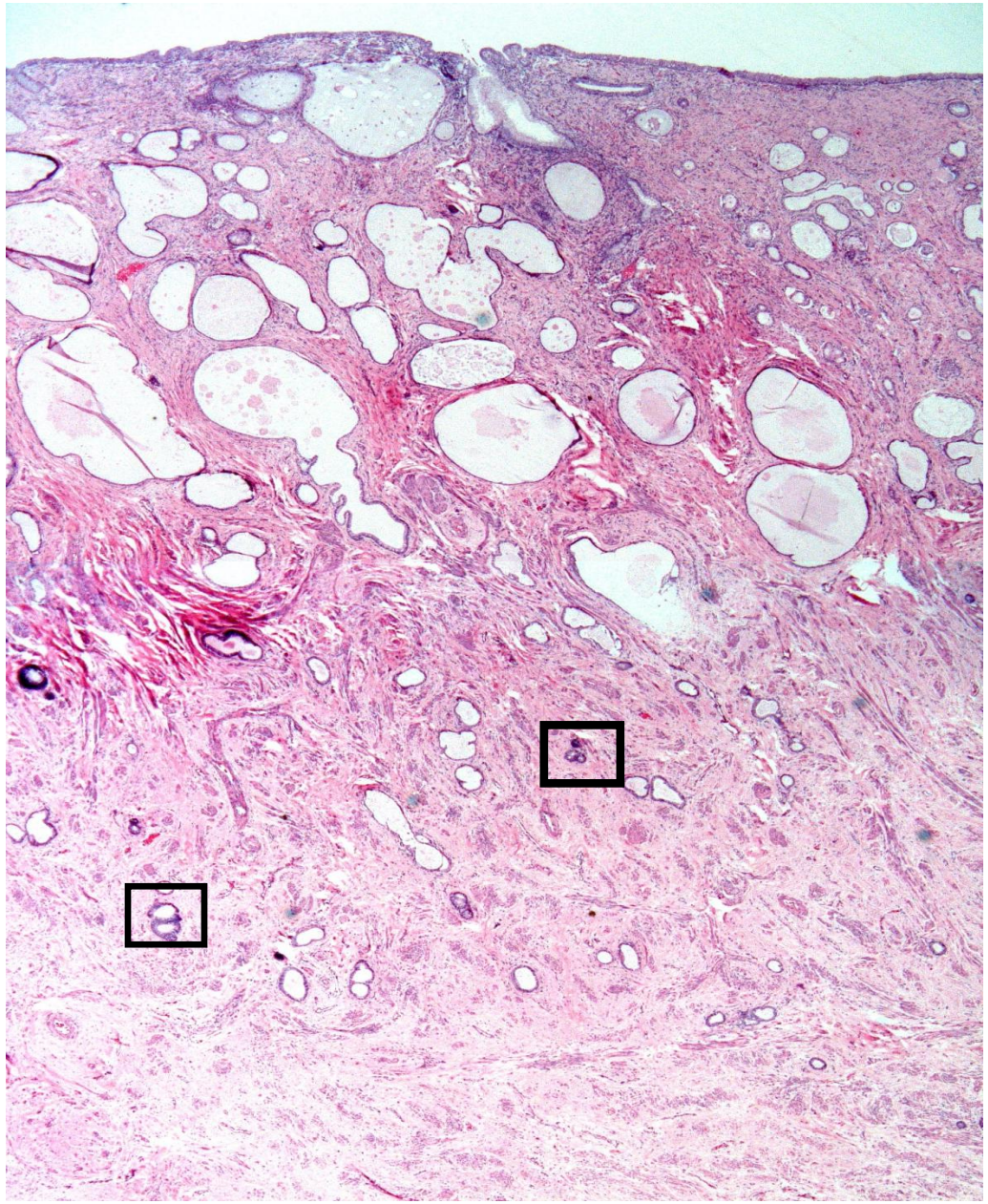

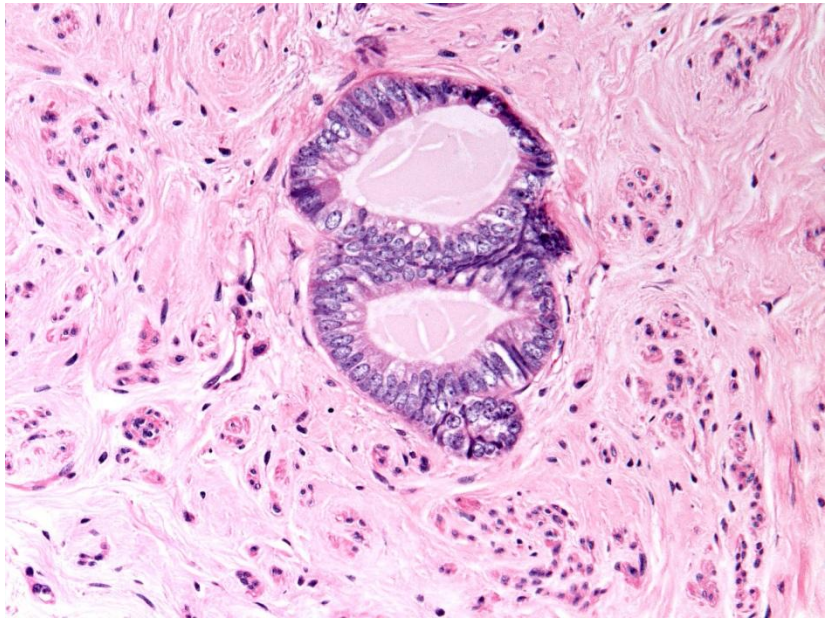

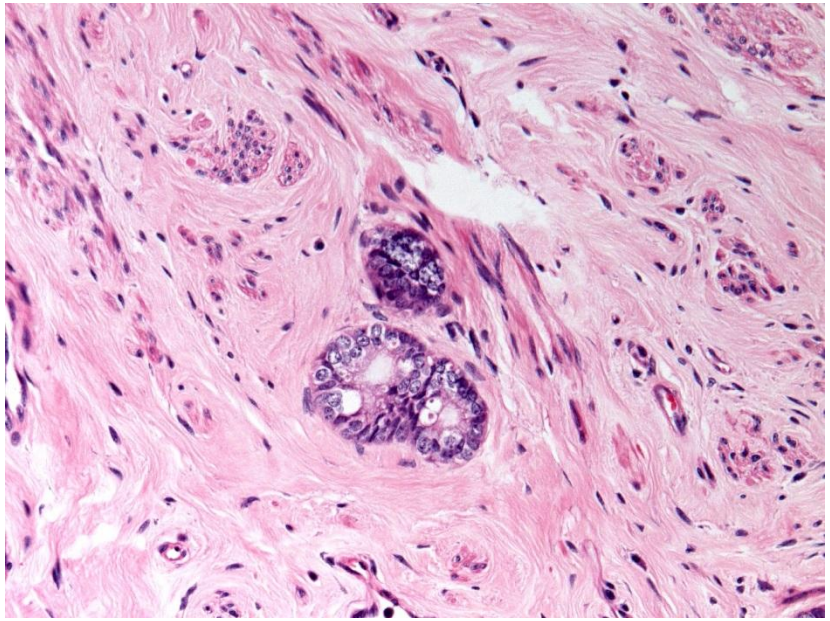

If cervical invasion is present…

- Radial and distal margins should be reported!
  - In stage 1 uterine tumors margins are not necessary to report
- Depth of invasion should be measured and stated as well
- Distance to the closest radial margin should be measured

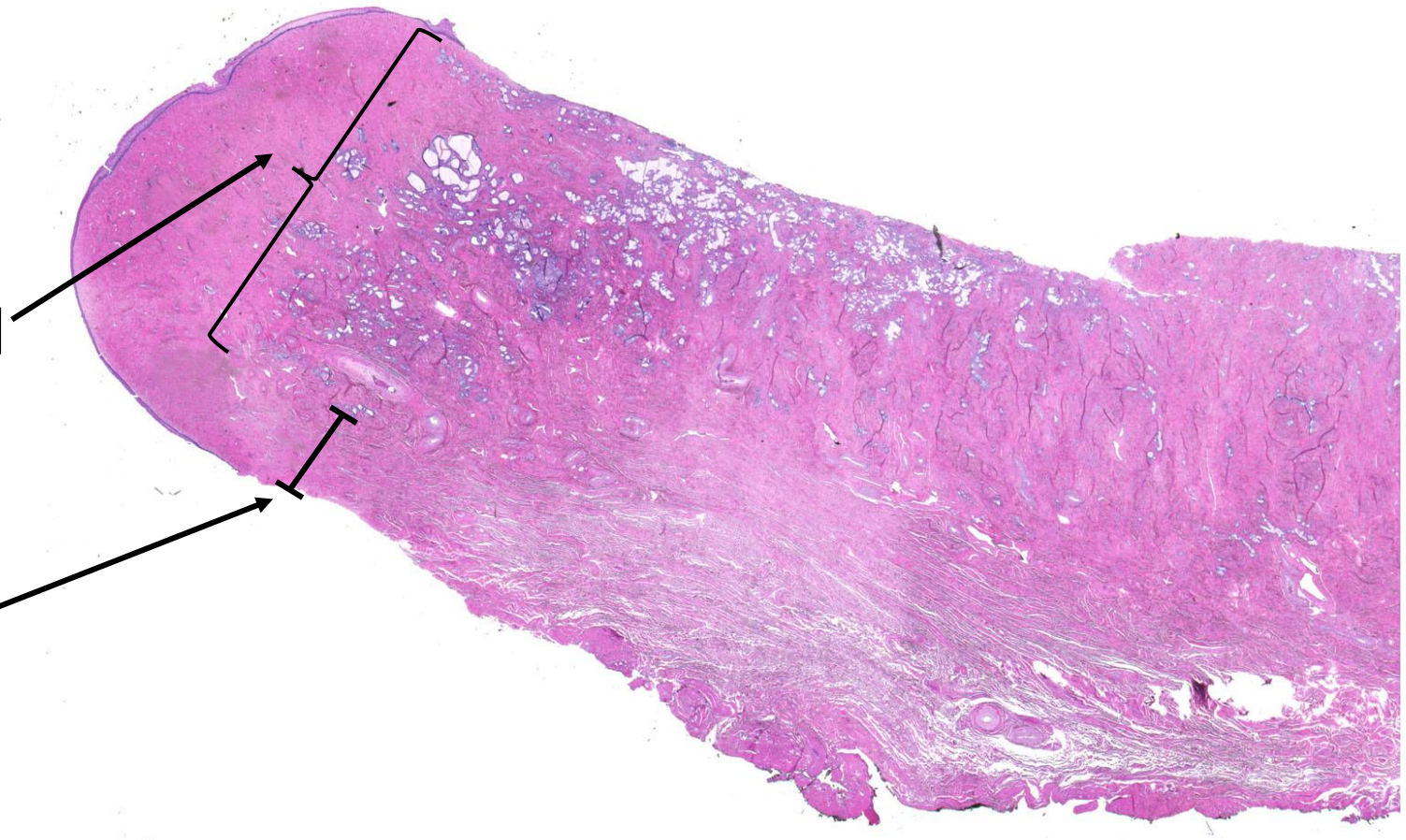

Outline

- **Stage 1:**
  - **PITFALL: Adenomyosis and DOI**
  - **PITFALL: Fallopian tube ostia**
  - **Specific Caveats**

- **Stage 2:**
  - **Cervical Involvement?**

- **Stage 3:**
  - **Tubal Issues**
  - **Serosal Involvement**

Tubal Metastasis

- In general identification is straightforward for endometrioid and clear cell carcinoma

- Location of metastasis should be described:
  - Mucosal
  - Serosal
  - Mural

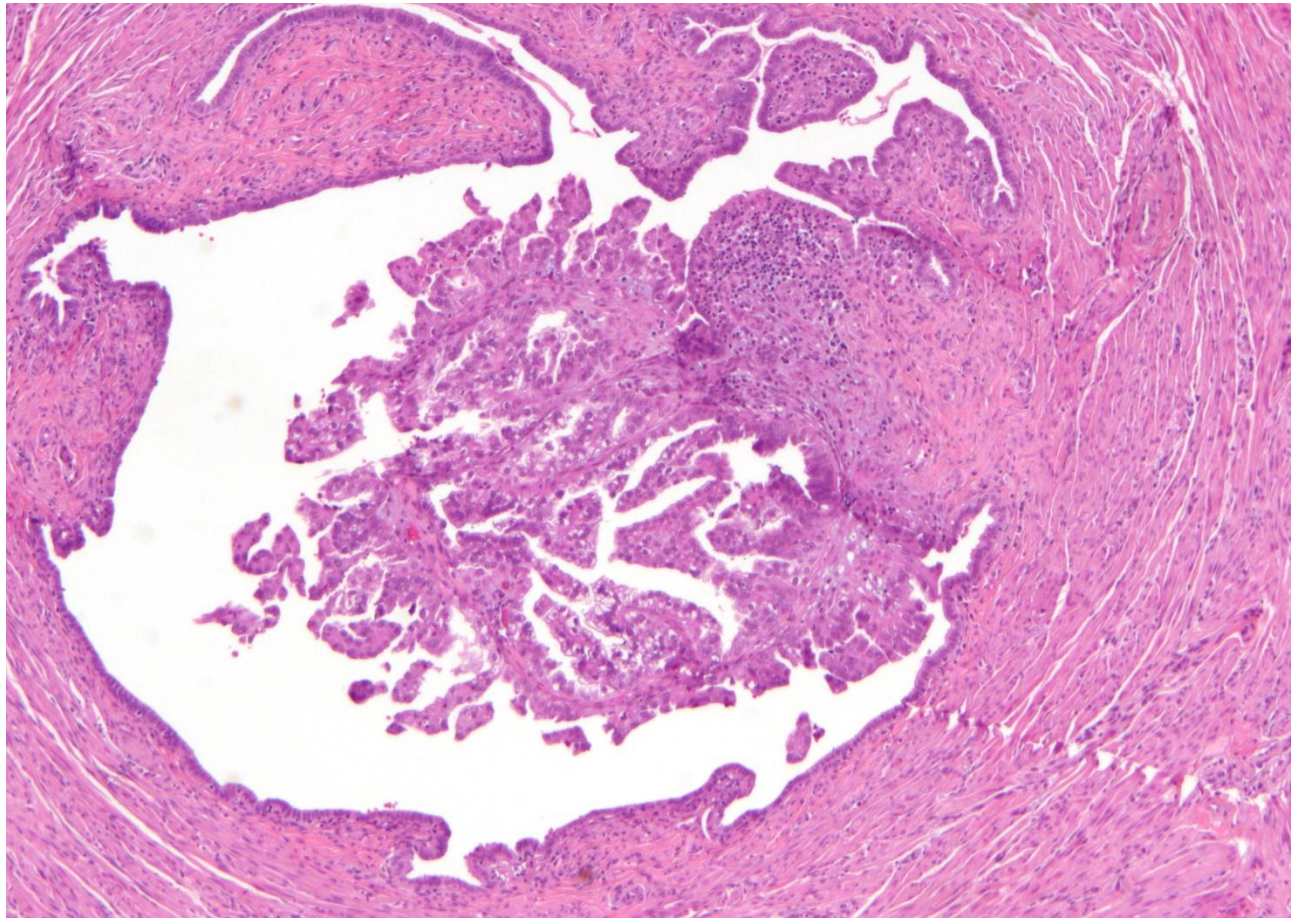

Mucosal metastasis of clear cell carcinoma of the endometrium

Tubal Exceptions!

- Things That **DO NOT COUNT** toward up-staging:
  - Detached luminal tumor fragments (you should still describe their presence)
    - No adverse outcome in endometrioid or clear cell
    - **Adverse outcome in serous carcinoma, therefore must be documented!**
  - Isolated lymph vascular space involvement

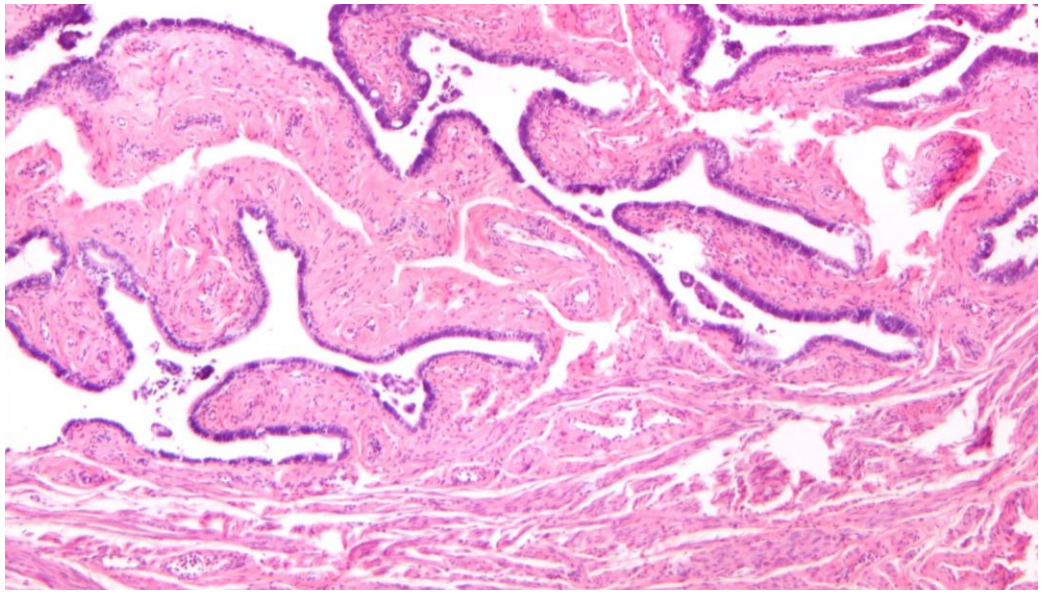

Luminal tumor above and tumor in lymphatics below

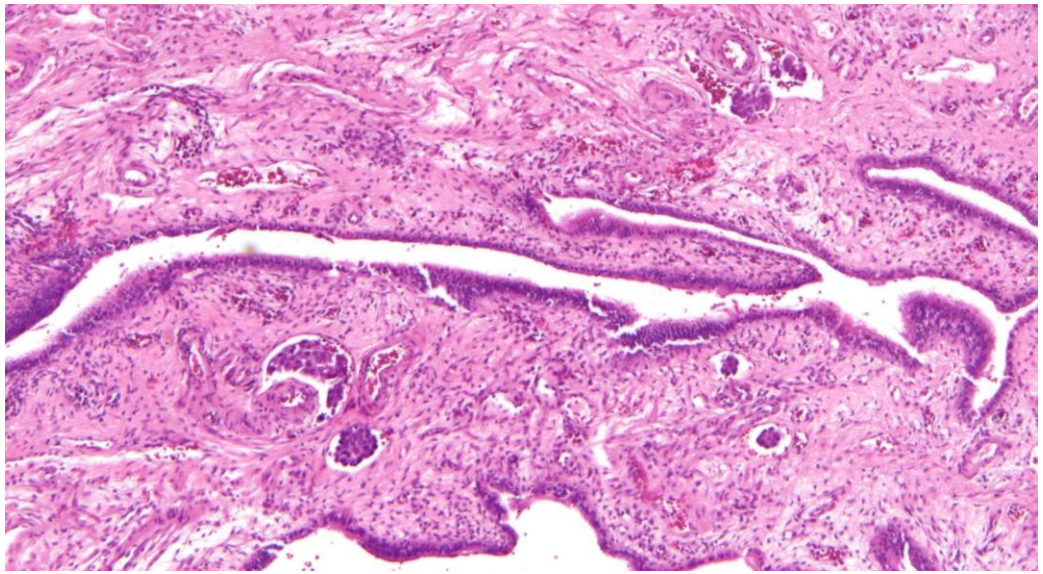

The Serous Exception

- When serous carcinoma is noted in the tubal mucosa AND in the endometrium WT-1 staining can help to localize the primary (maybe)

- WT-1 is positive in the majority of adnexal serous carcinoma negative in “most” endometrial serous carcinoma

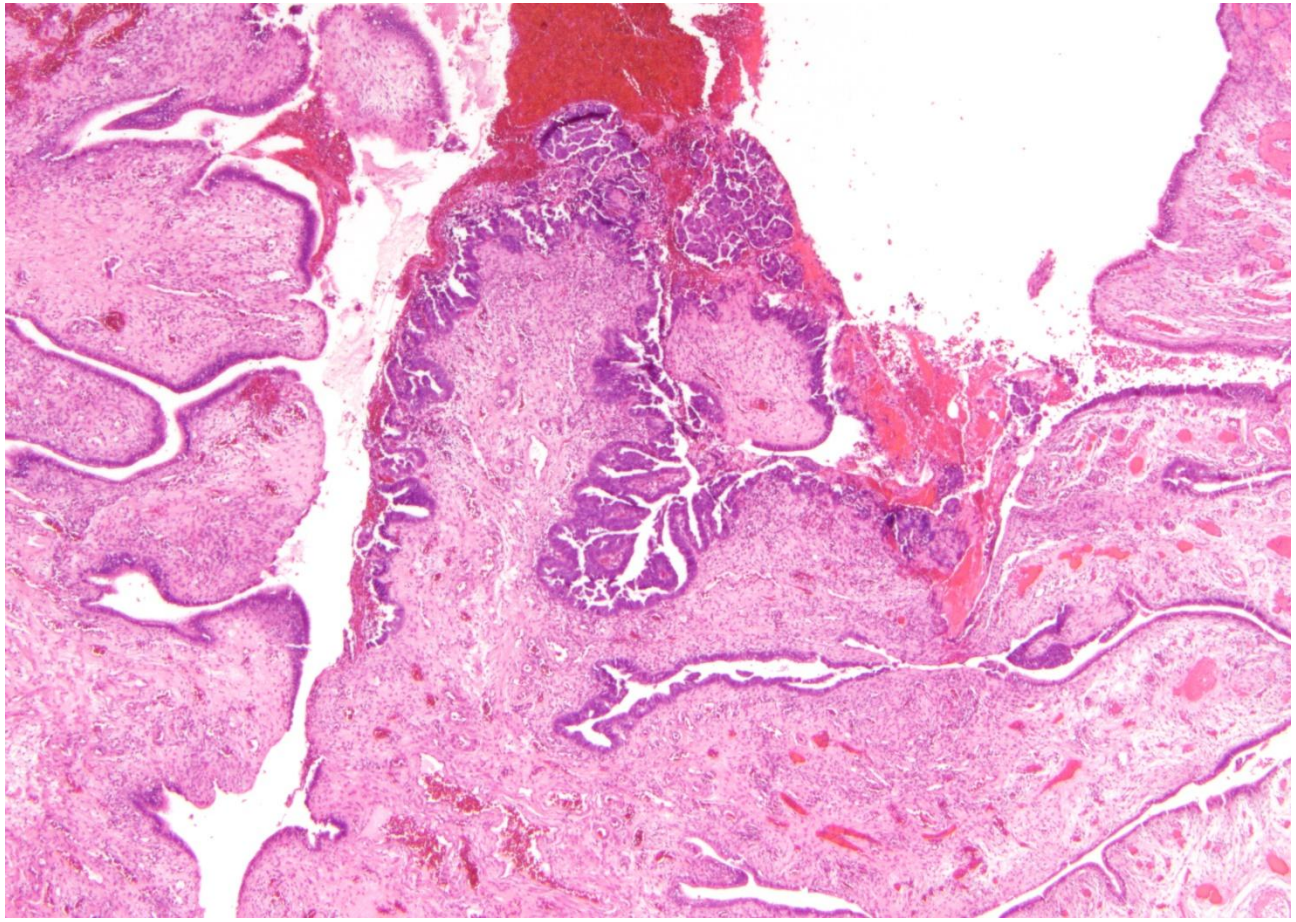

Serosal Involvement

- NOT THE SAME AS IN COLON!
- In the uterus the mesothelial lining and sub-mesothelial connective tissues are very thin
- Involvement of the sub-mesothelial connective tissues constitutes “serosal involvement” and should be staged as pT3a

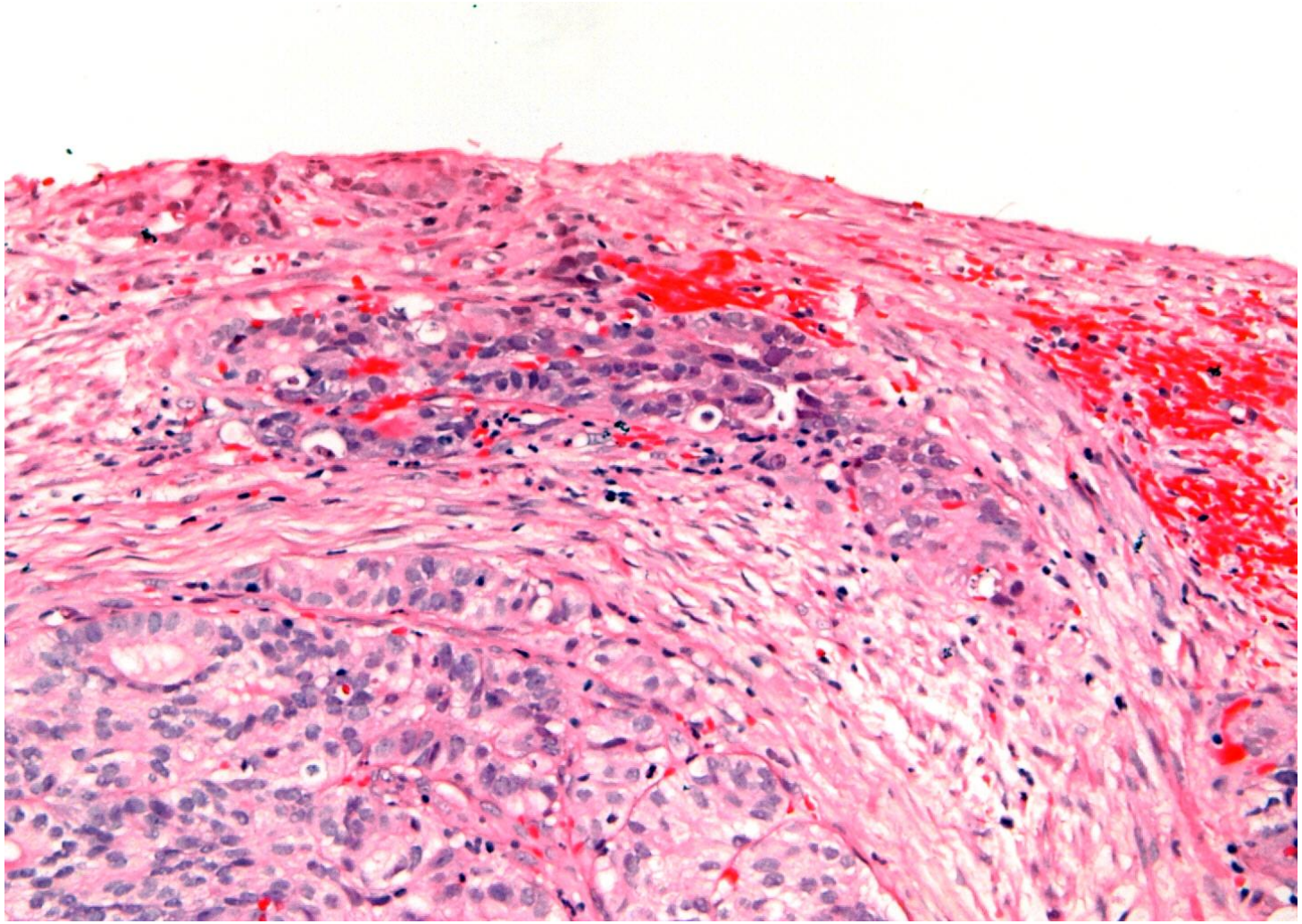

Questions?

Quickcharlesm@uams.edu

UAMS

The British Association of Gynaecological Pathologists