The British Association of Gynaecological Pathologists

21st Annual Meeting in Collaboration with ISGyP

5th and 6th June 2025

- **CBD:** Inflammatory Vulval Dermatoses – "A Case of Two Vulvas".
- **Speaker:** Dr Lucy Grant - Consultant Histopathologist.
- **Affiliation:** Birmingham Women's Hospital + Black Country Pathology Services, Birmingham, UK.
- **Acknowledgements:** Dr R Ganesan and Dr R Muc .
- **Date:** Friday 6th June 2025

The British Association of Gynaecological Pathologists

Speaker disclosures

Choose one

- ❑ I have no financial conflicts of interest to disclose
- ~~❑ I have the following to disclose~~

Inflammatory Vulval Dermatoses: Case Based Discussion

Clinical Suspicion - Neoplastic vs Inflammatory ?

Unfortunately, vulval inflammatory dermatoses **rarely** “Picture Perfect”!

Need **Clinical Correlation** to diagnose.

A Tale of Two Vulvas …

both with "**hidradenitis**" theme.



"It was the best of times, it was the worst of times."

Hidradenitis Suppurativa (HS):

- **Aetiology: Follicular occlusion disorder**

RFs: Genetic, Autoimmune, Hormones, + Environmental

- **Onset:** typically 20-40 years,

- **Defined by:** **<u>Chronic</u>, painful, <u>follicular lesions</u>**

(comedones, pustules, abscesses, sinus tracts + scarring) occurring in **<u>typical distribution</u>** (e.g axillae, groin, chest, face).

- **Vulva HS not uncommon** but rarely reported in literature.

- **Histology:** 1) Follicular hyperkeratosis + hyperplasia,
  - 2) + Cysts +/- sinus tracts,
  - 3) Inflammation (+/- MNGCs) + scarring.



Clinical Appearance - Hurley Score

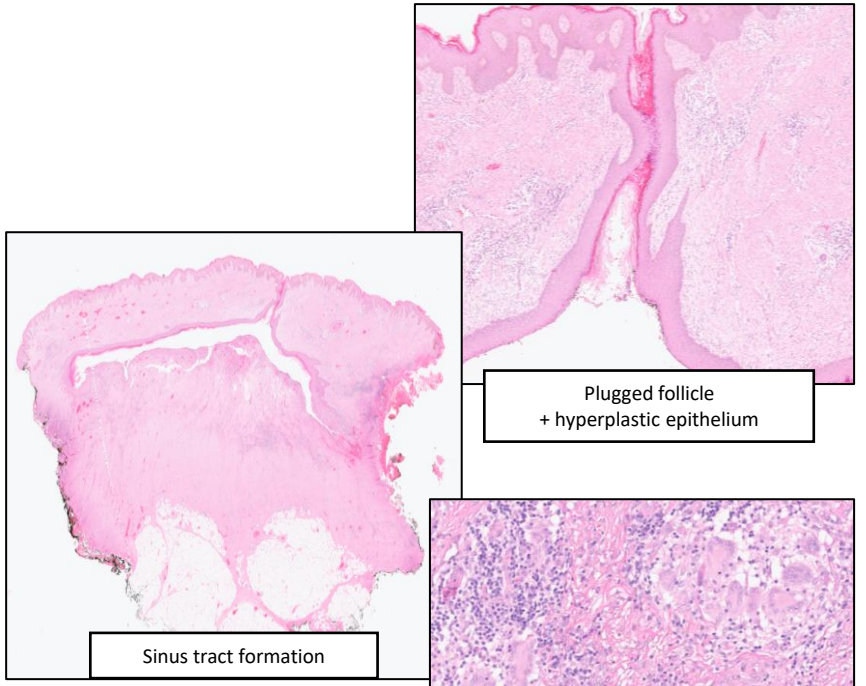

Case 1:

- Patient in **early forties.**
- Non-smoker. **BMI 45**.
- **> 8-year history of hidradenitis suppurativa,**

  diagnosed on initial vulva + buttock excision.
- **Symptoms worsened despite multiple treatments.**
- Opted for **radical vulvectomy** + excision

  of '**pendulous mass'** affecting mons.
- **Clinical differential:** pannus vs atypical lipomatous tumour.





Clinical Question: Neoplastic or Inflammatory?

Macroscopy:

Total Vulvectomy Specimen

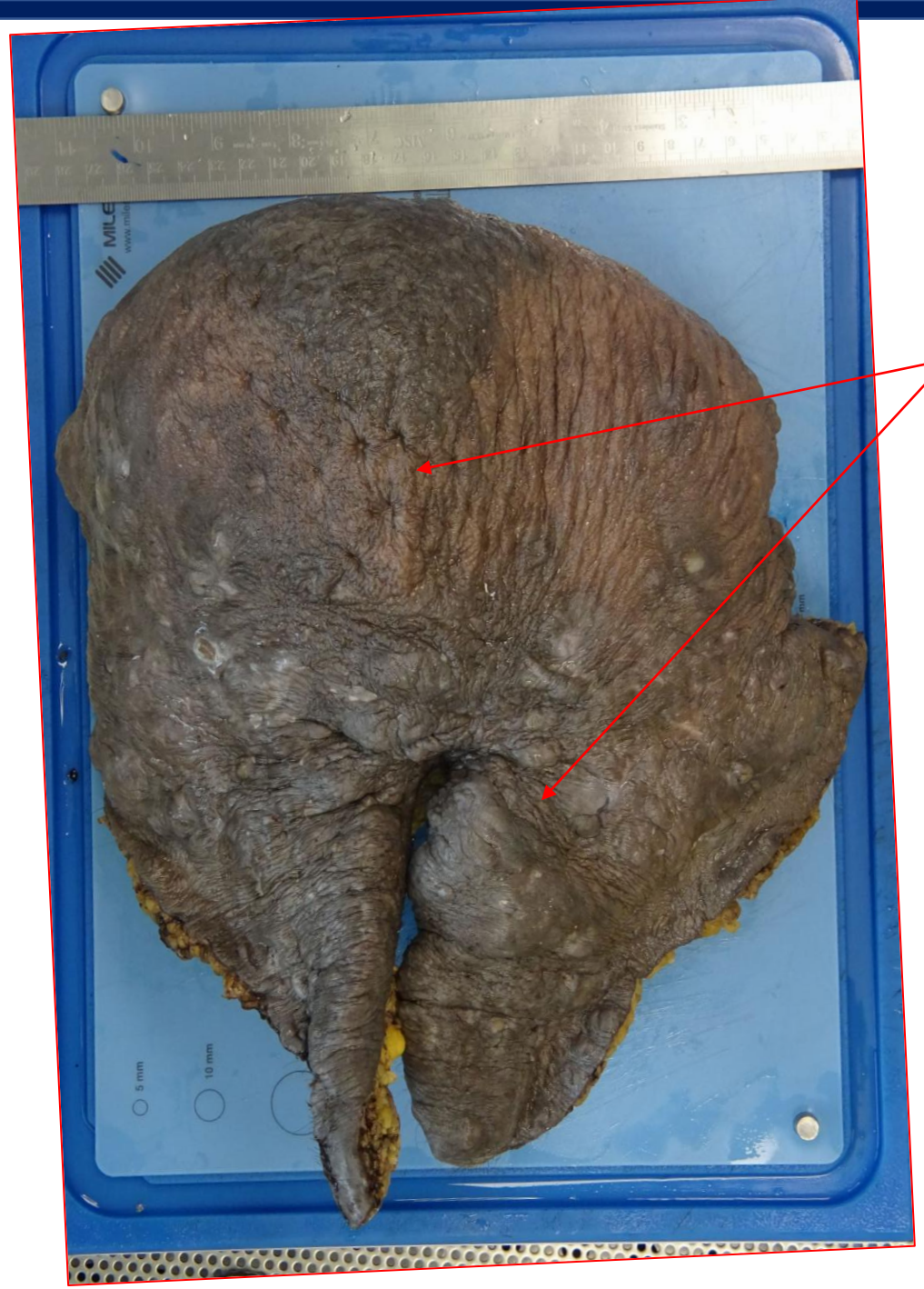

Polypoid, ‘pannus-like’ lesion
220 x 170 x 13mm

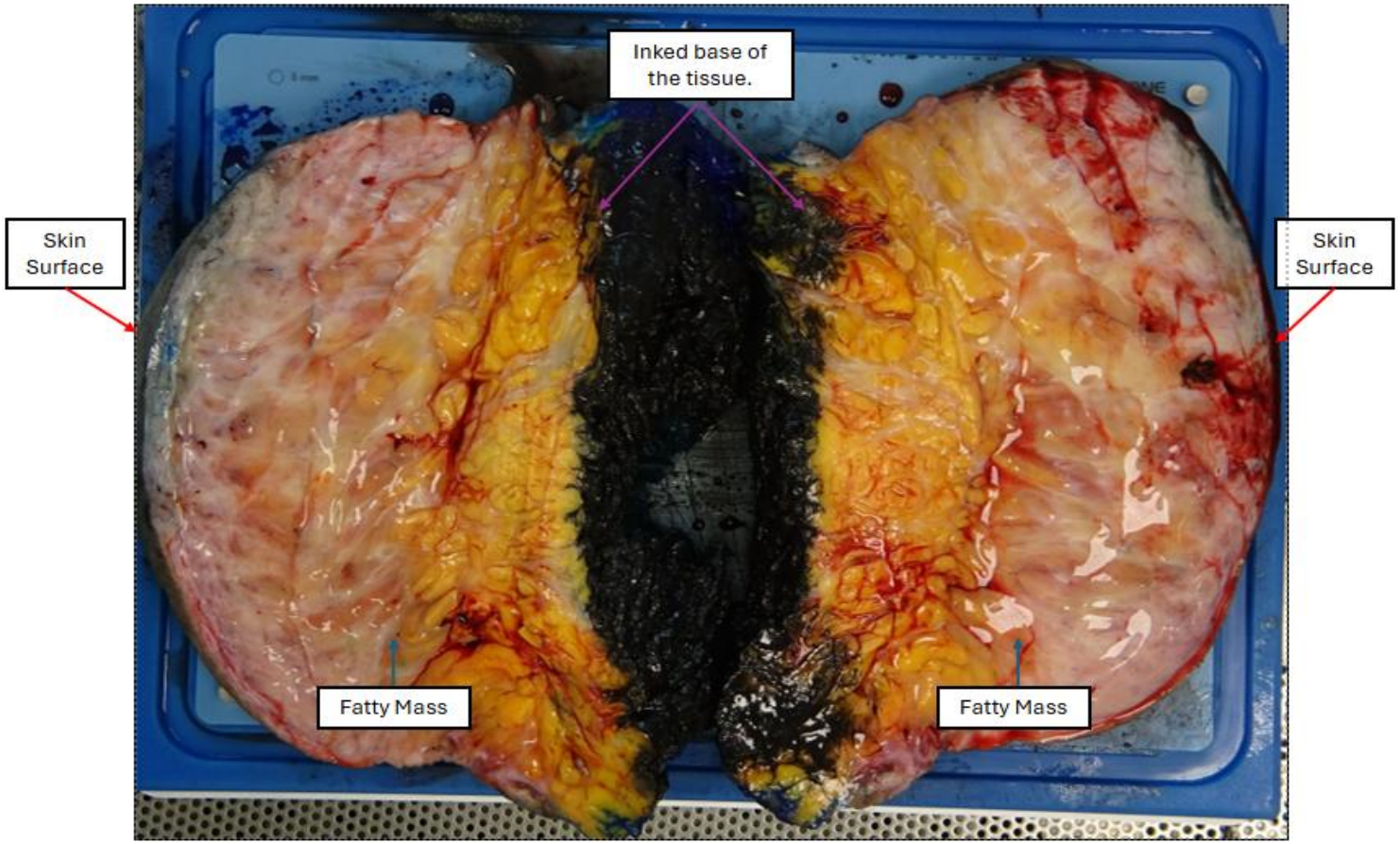

Microscopy:

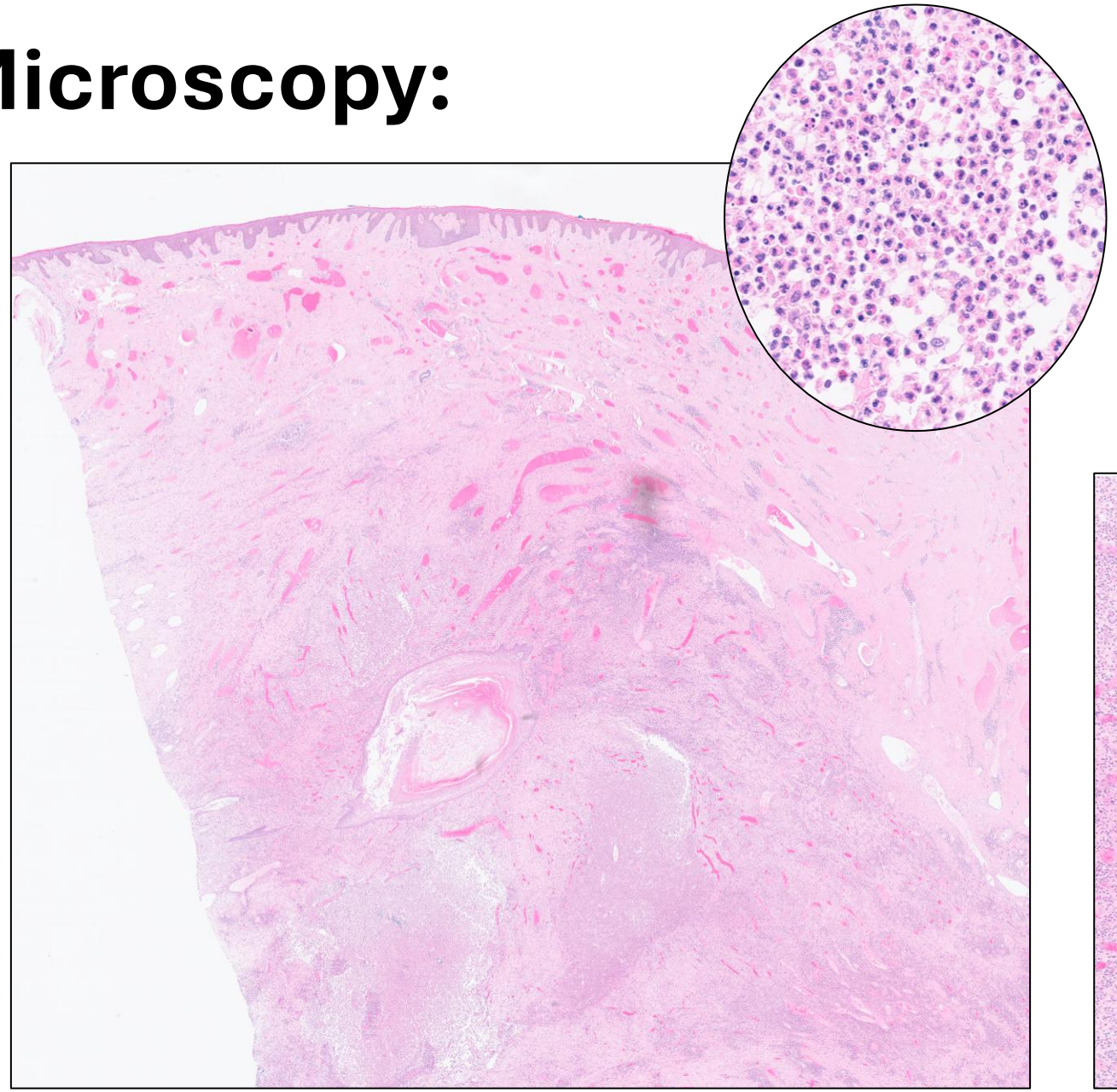

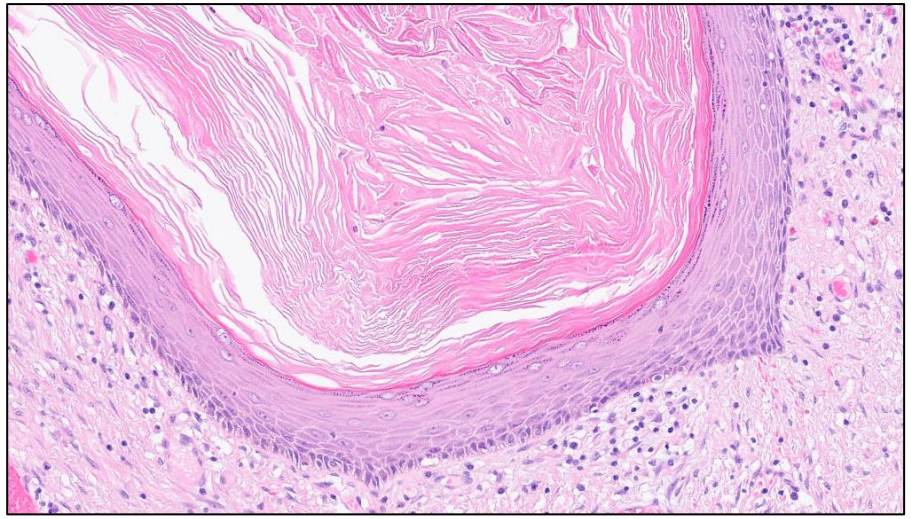

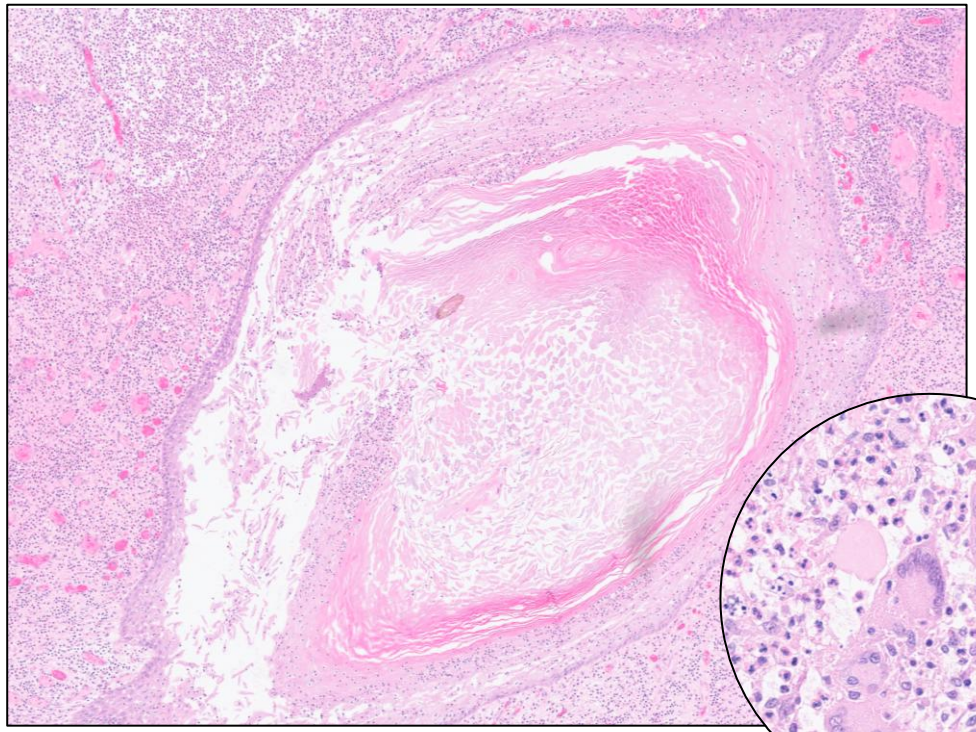

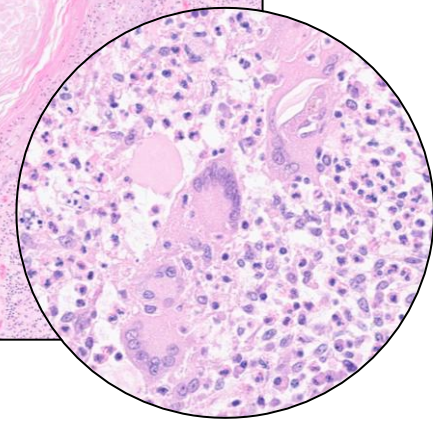

1) Entrapped Dermal Follicular Sinus

2) Dermal inflammation

3) Scarring.

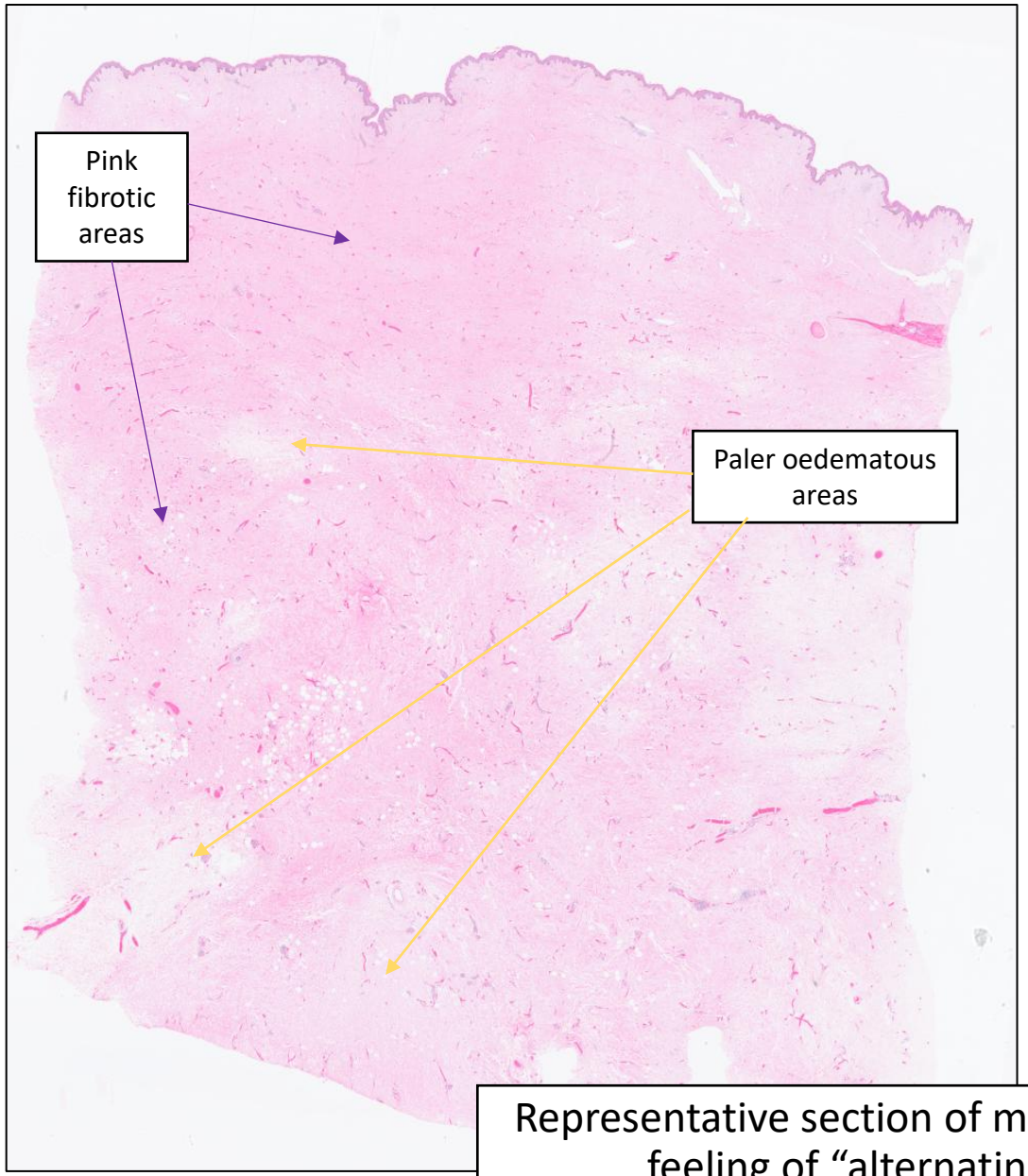

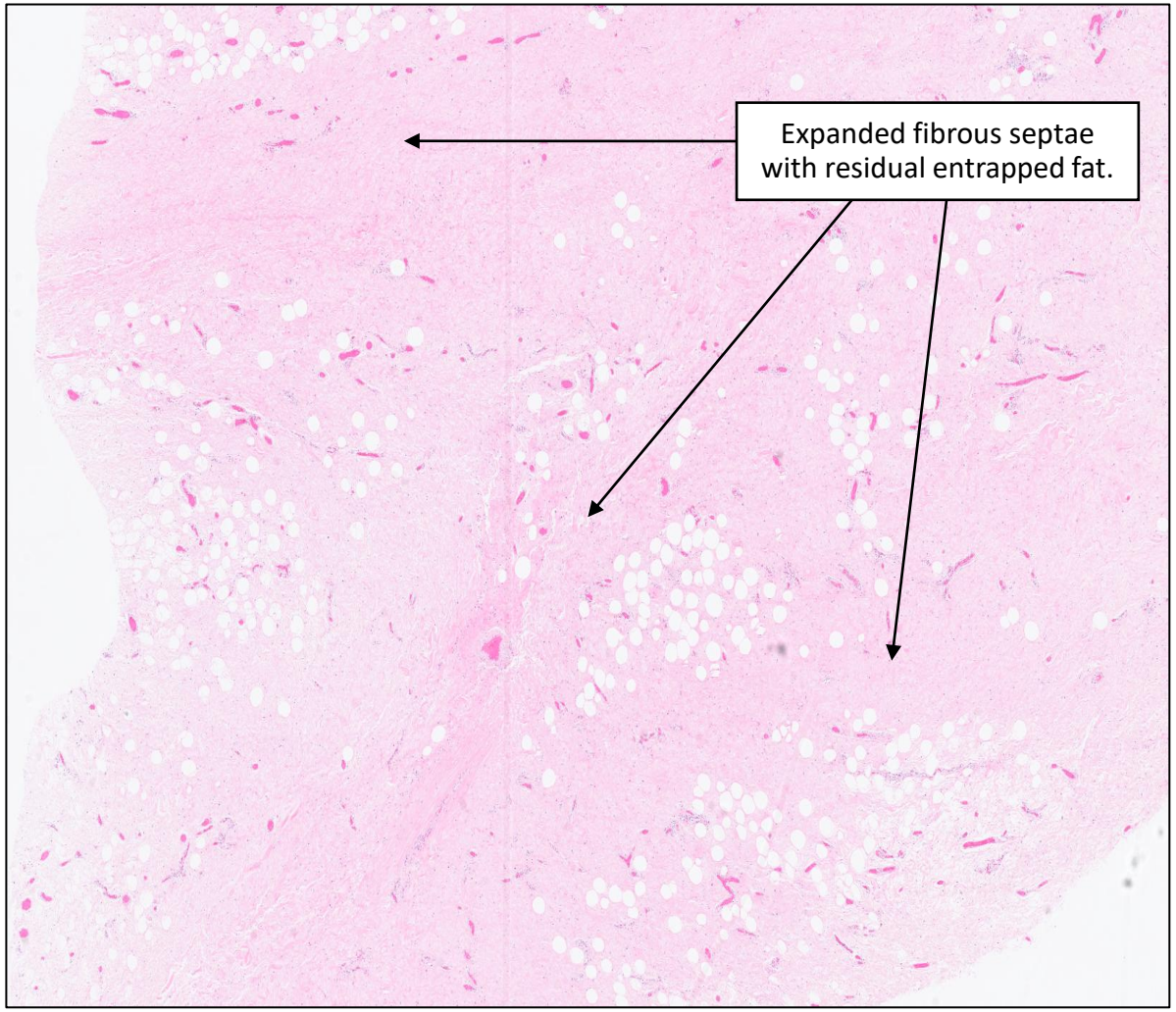

Representative section of mass lesion. On low power there is a vague feeling of “alternating” oedematous and fibrotic areas.

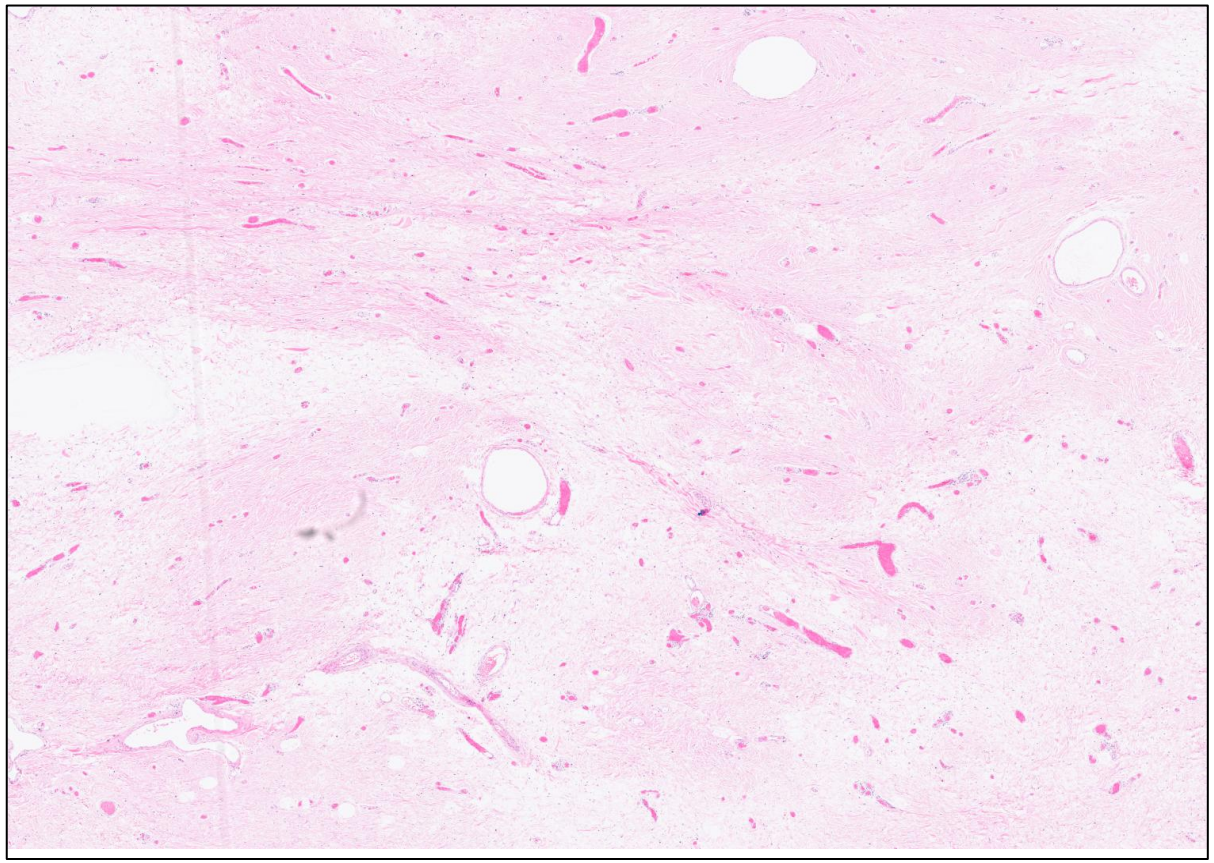

Within the fibrosis, ectatic lymphatics can be seen.

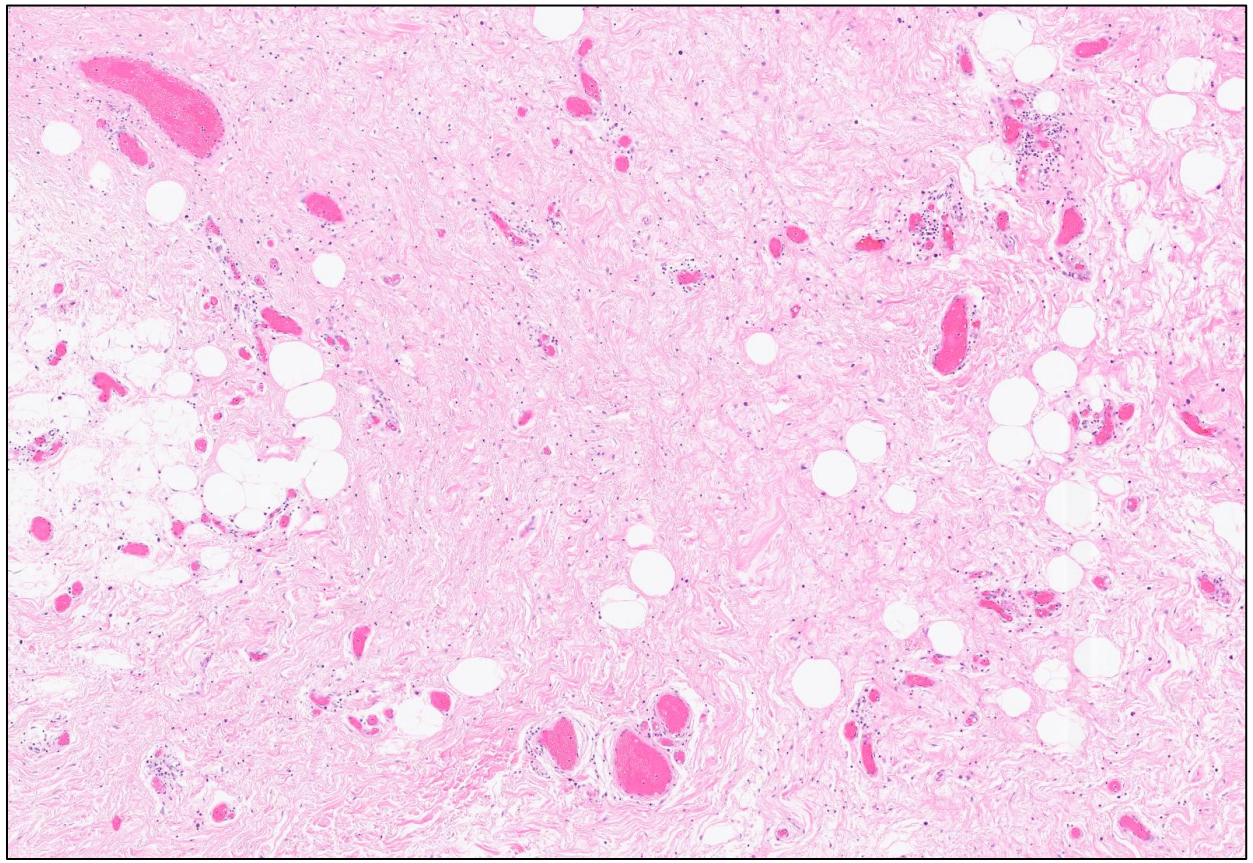

Also capillary proliferations, more prominent at fibroadipose interface.

No significant adipose/fibroblast atypia or excess mitotic activity.

FISH for **MDM2** (performed for clinical concern) was **negative.**

FINAL DIAGNOSIS:

Massive Localised Lymphoedema

+ background **Hidradentitis Suppurativa.**

Massive Localised Lymphodema (MLL):

- **“Complication of morbid obesity”.**
- **“Tumefactive pseudosarcomatous condition”**.
- **Aetiology**: Obstructed lymphatic flow.
- **Clinical:** Pendulous mass, dependent areas.
- **Macro:** Peau d’orange + oedematous/fibrous cut surface,
- **Microscopy:**
    1) Alternating oedema and fibrosis,
    2) Dilated lymphatics + thick-walled vessels,
    3) +/- dystrophic calcification + ossification.



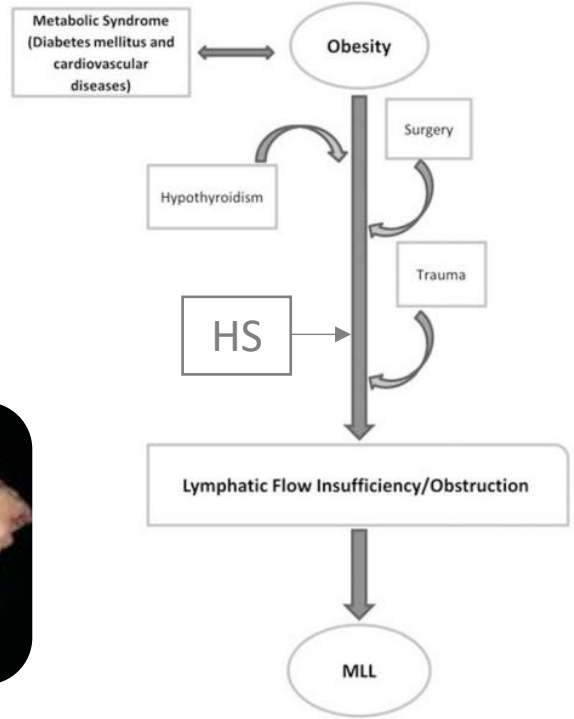

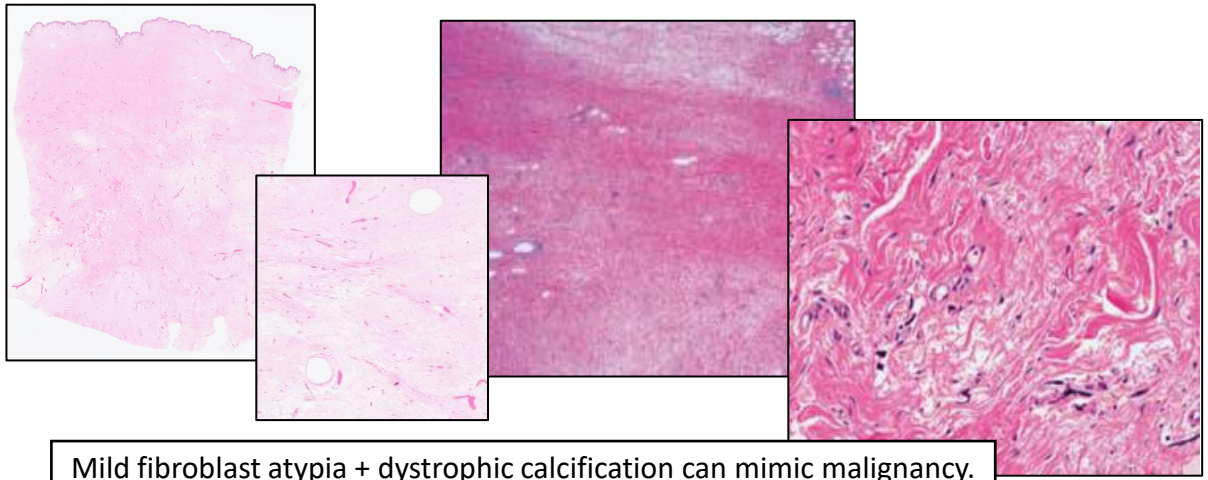

Mild fibroblast atypia + dystrophic calcification can mimic malignancy.

PMID: 26585553

Hidradenitis Associations:

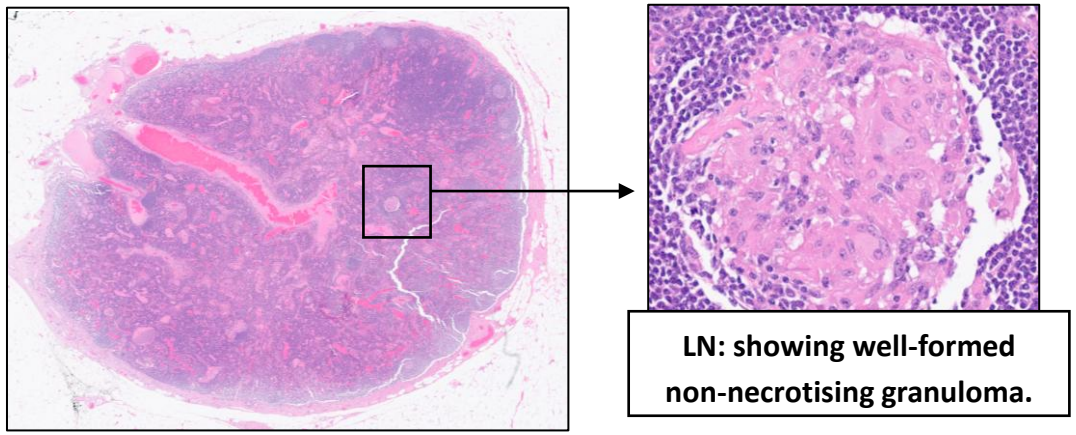

LN: showing well-formed non-necrotising granuloma.

- Wounds, Sinus/Fistulas, Scarring, **Psychosocial.**
- **Autoimmunity**
  - 50% T2DM, metabolic syndrome, PCOS,
  - Thyroid dysfunction.
  - Inflammatory Bowel Disease -> **Crohns 40%**
- **Lymphodema**

Crohns (CD)	Hidradenitis (HS)
25% also have hidradenitis	38% also have Crohns
Typically **precedes** HS	Typically occurs after CD
Usually **more ulcers, Fistulas** > sinuses.	More **follicular/comedonal**, Sinuses + scarring.
More pararectal + disease extends above **dentate line.**	Favours skin folds + "typical sites", **does not extend above dentate line.**
Faecal calprotectin positive	**Faecal calprotectin negative.**

PMID: 33890304

- ↑ **Squamous Cell Carcinomas = "typically in patients >20yrs inflammation."**

Risk Factors: smoking, immune compromise, lymphodema, **??? HPV**.

Case 2:

- Patient in **late sixties.**

- **Suspicious** lesion, labia majora, (**>1 year duration**),
  - + “ulcerated,” erythematous, “pustular”,
  - + history of weight loss + anaemia.

- **Multiple biopsies** over 18-month period.



Clinical Question:
Inflammatory, Infective or Neoplastic?

Clinical Appearance:
Erythematous ? Cobblestoned, **Pustular.** No visible comedones.

Biopsy 1:

Clinical: "Suspicious area vulva, widespread ulcer, swellings, pus + weight loss + anaemia."

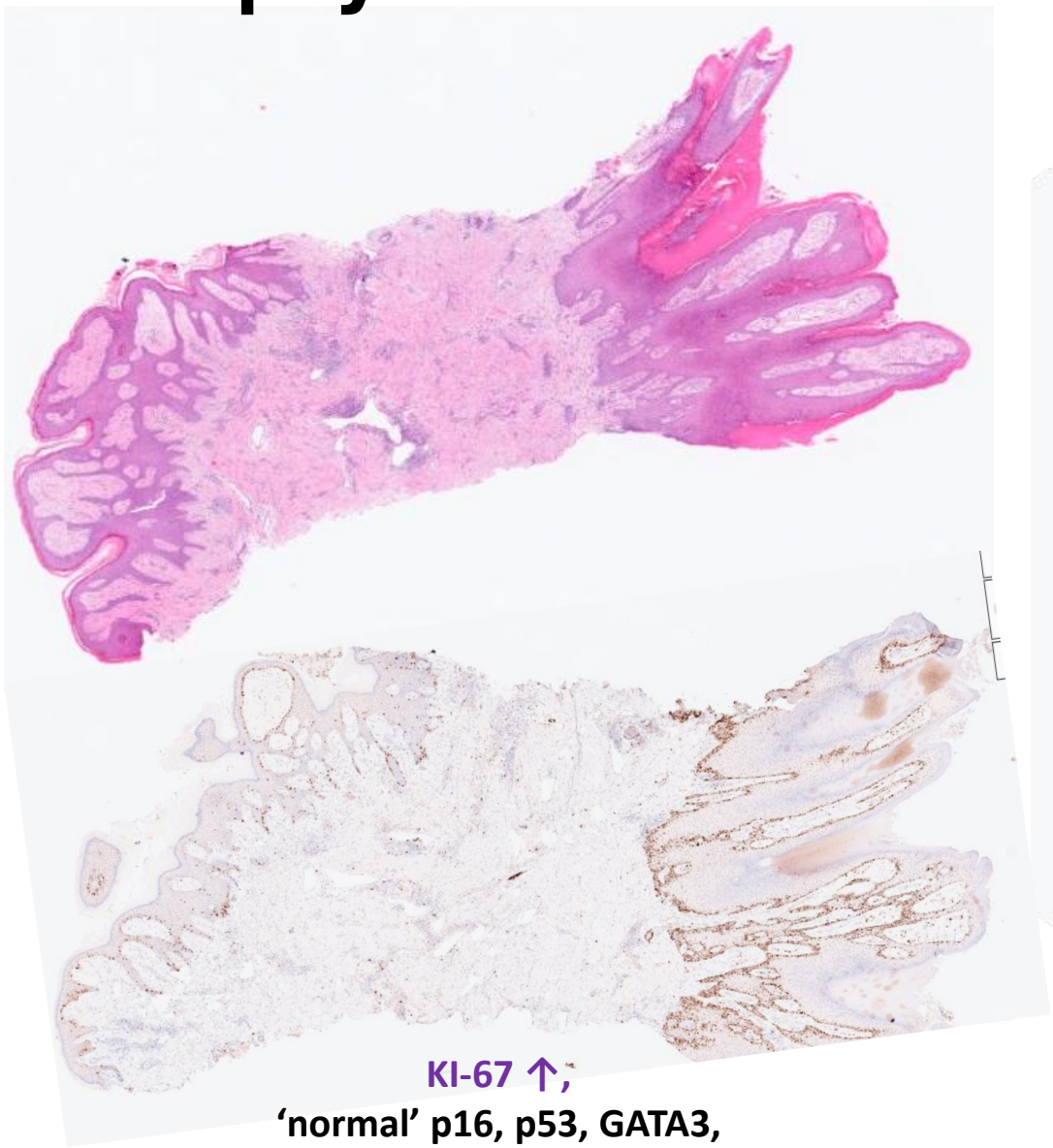

KI-67 ↑,
'normal' p16, p53, GATA3,



Histology: Squamoproliferative lesion, most likely viral wart.

Biopsy 2 (two months after first):

Clinical: "Large mass". **Macro**: "Warty" lesion.

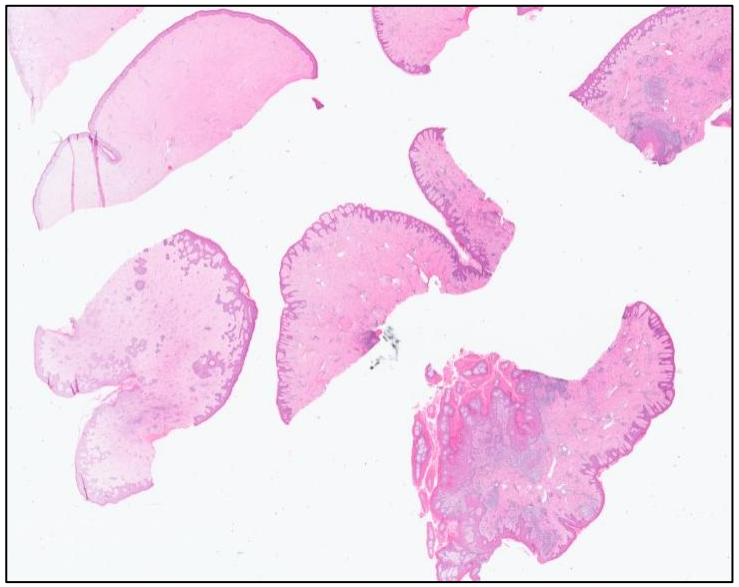

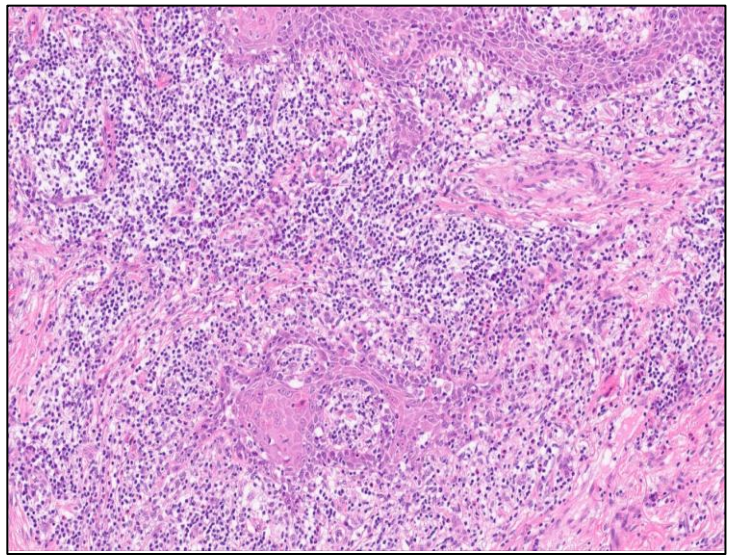

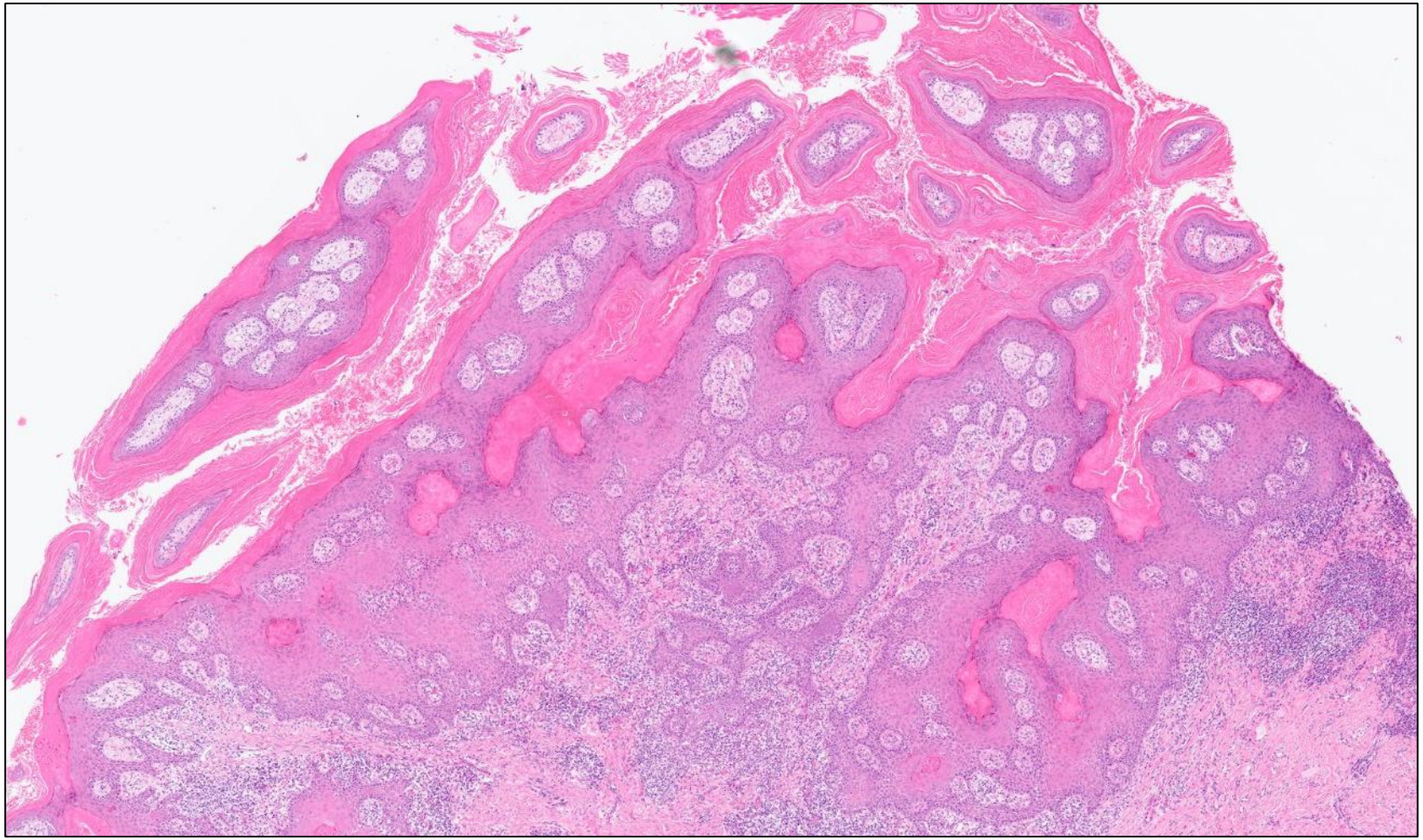

Histology: Chronic inflammatory process with hyperplasia and scarring, Suggestive of **HIDRADENITIS SUPPURATIVA**.

Imaging / MDT Correlation:

- **Initial CT = 'abnormal enhancing pelvic floor, rectum'. Favour advanced malignancy.**

- **MRI = 'diffusely thickened pelvic floor + irregular rectal wall, linear bands may represent fistula'.**

  'Marked signal change in **buttock, gluteal region + thigh**, to **presacral space and marrow**'.

- → **Suspicious for malignancy** but **could represent non-neoplastic condition** e.g. **deep actinomycosis.**

- **Micro = negative.** However, **MDT** agreed for trial of **empirical actinomyces treatment.**

- The patient improved clinically but lesion remained the same.

Biopsy 3 (six months after initial):

Clinical: “Chronic actinomyces, raised/irregular area
? Neoplastic rather than infective.”

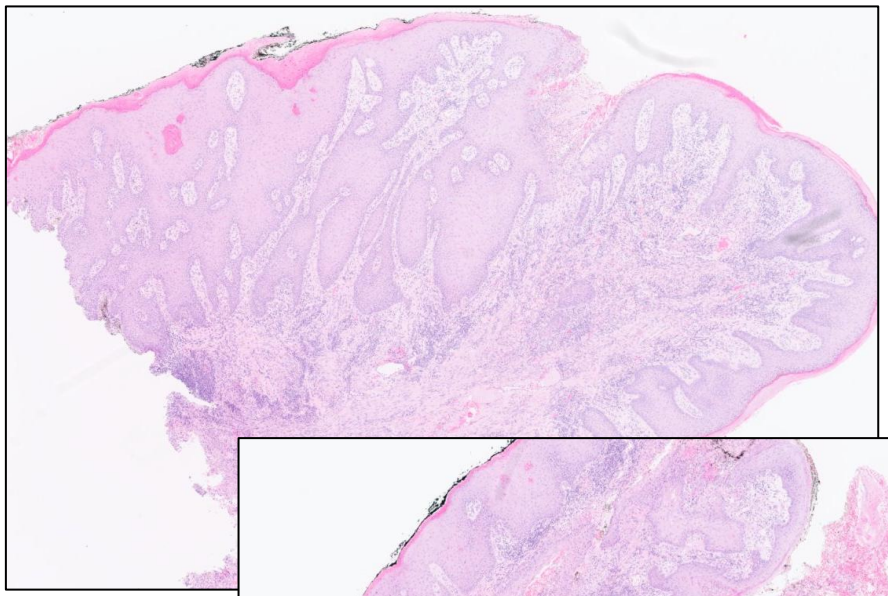

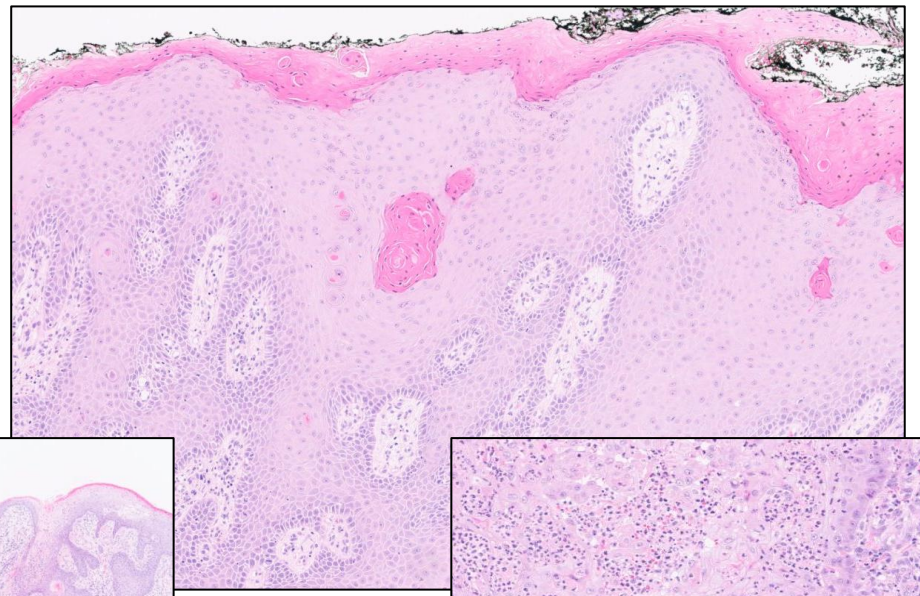

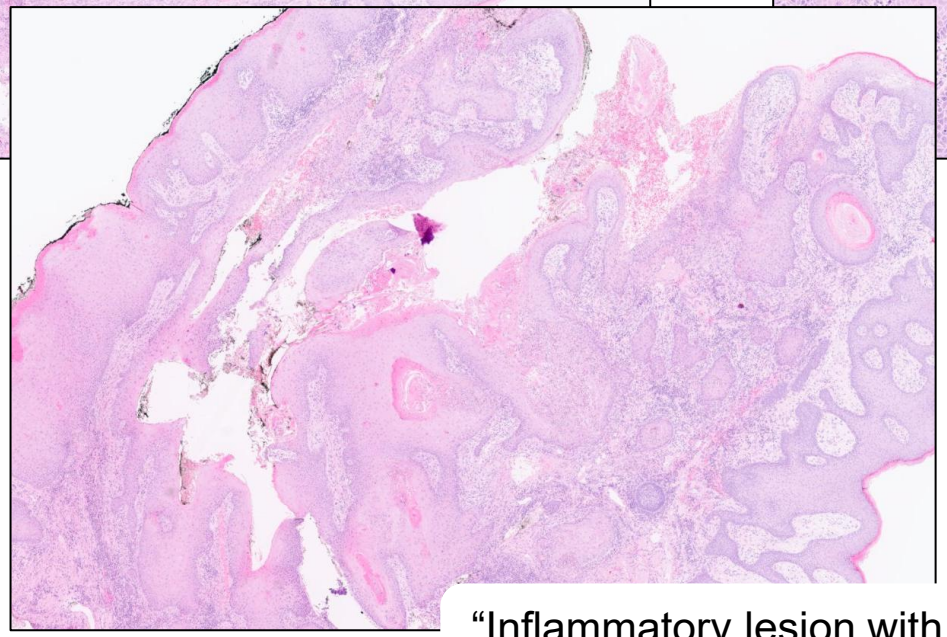

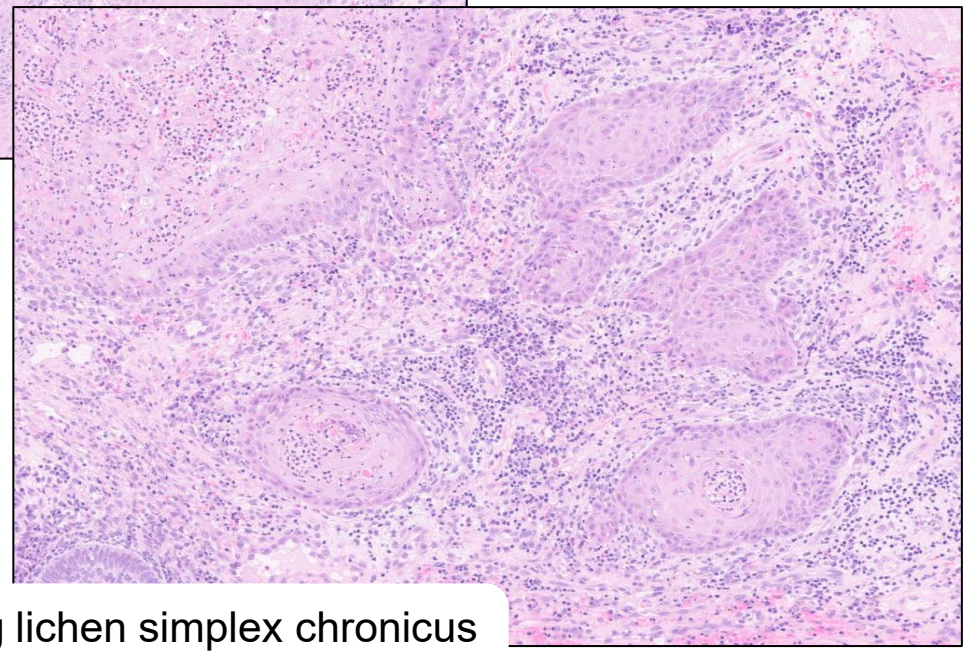

“Inflammatory lesion with ddx including lichen simplex chronicus and **hidradenitis suppurativa**. Please correlate.

Biopsy 4-5 (19 months after initial):

Clinical: "Recurrent infection (actinomyces), mild-severe inflammation with open cysts ? Chronic inflammation ? Actinomyces ? Malignant."

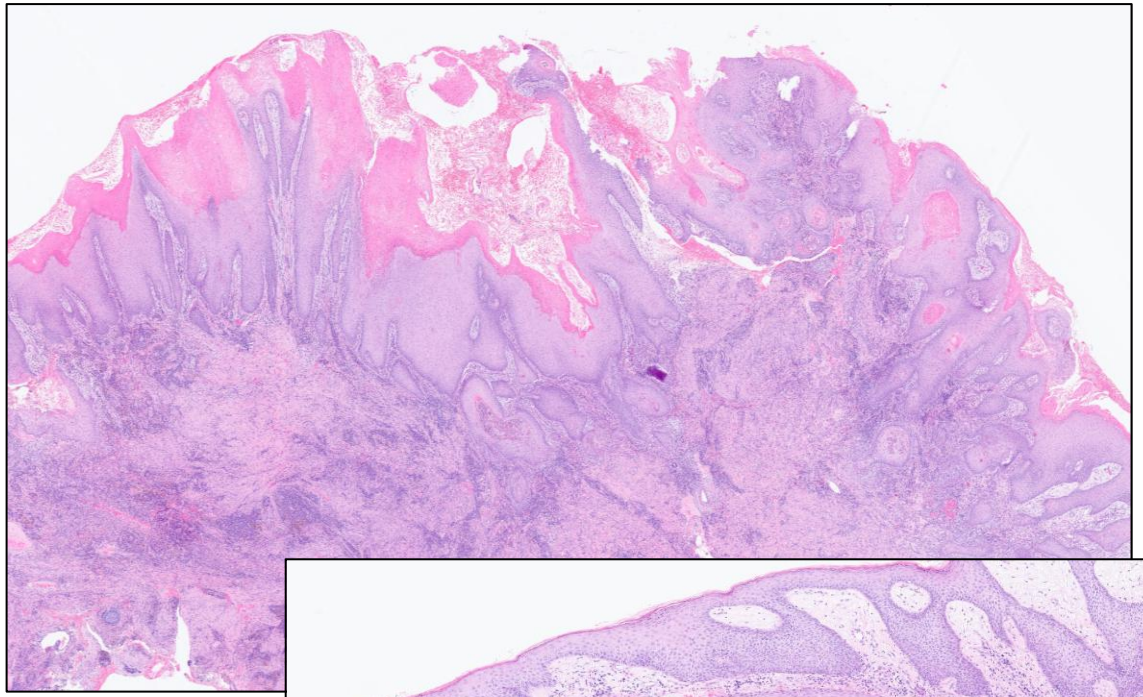

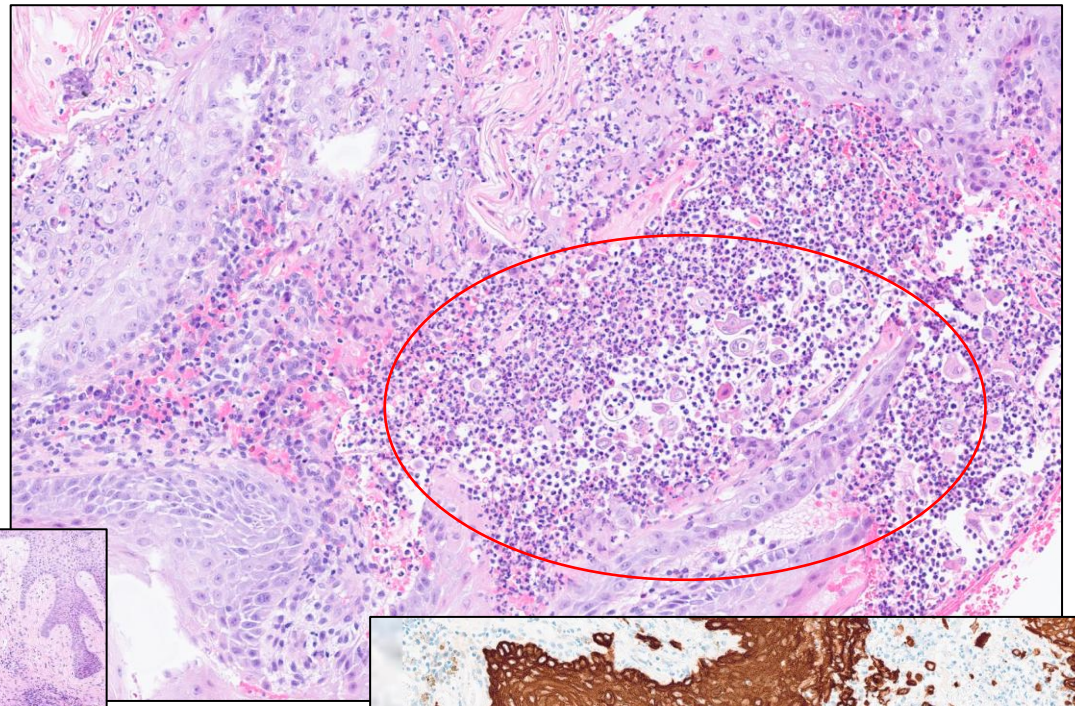

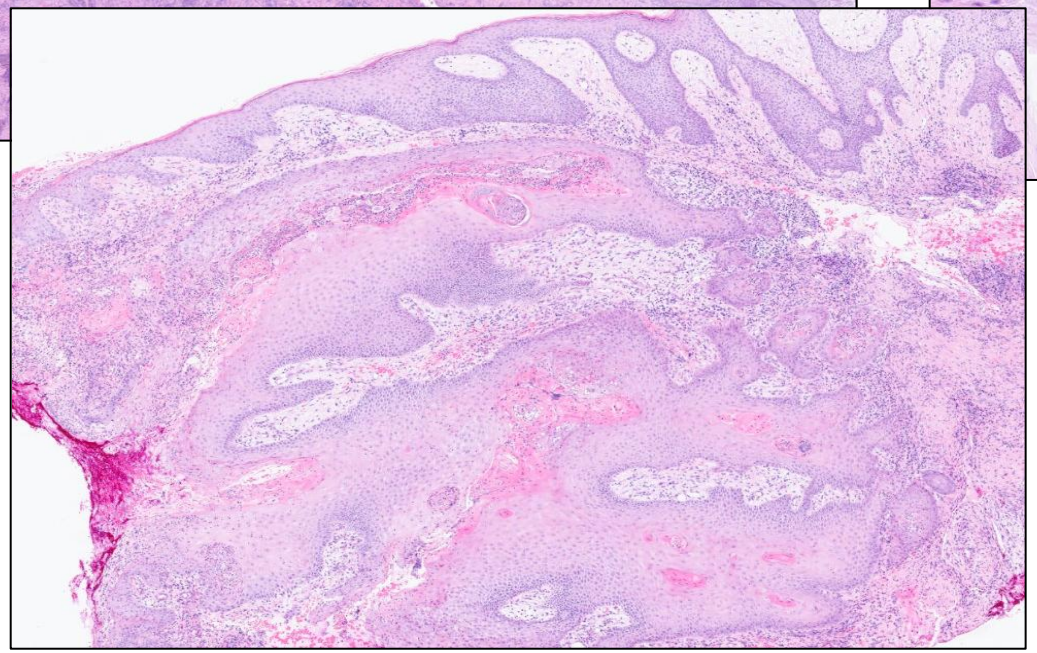

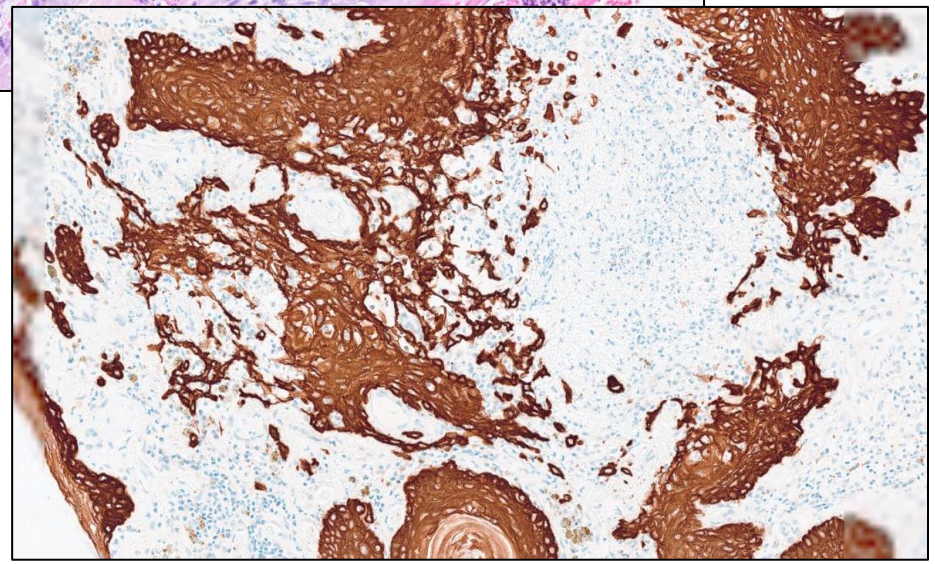

FINAL DIAGNOSIS:

HPV-independent, p53 wild-type

invasive Squamous Cell Carcinoma

[Carcinoma Cuniculatum Variant]

What is Carcinoma Cuniculatum (CC) ?

- Vulval SCC divided into **HPV-A and HPV-I (p53mx/wt)** types.
- **HPV-I squamous carcinomas** can show **variable morphology.**
- **Well-differentiated** sub-types often **bland** + **difficult** to **diagnose**.

What is Carcinoma Cuniculatum (CC) ?

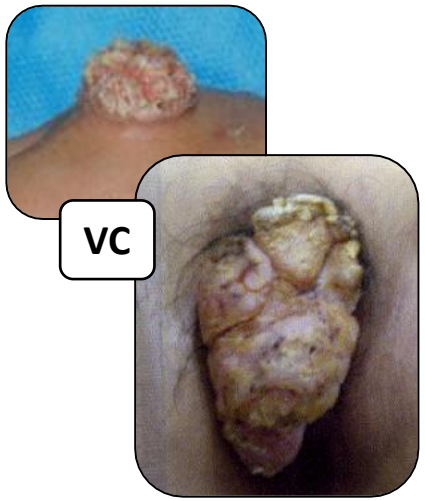

Verrucous Carcinoma (VC):

Warty, white … **EXOPHYTIC** growth pattern,

minimal atypia +/- inflammation, and **bulbous pushing**, invasive front.



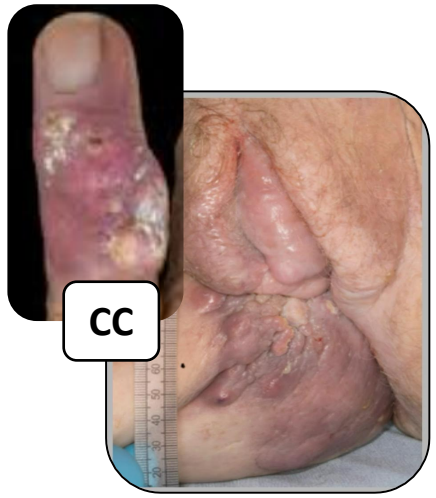

Carcinoma Cuniculatum (CC):

? **Rarer**, first described on the sole …

Pink-white, cobblestoned … predominantly **ENDOPHYTIC**,

"Cuniculus" / **"rabbit warren"** architecture,

Minimal atypia, inflammation + **"pus"** filled sinuses

Often **misdiagnosed as infective/inflammatory** (mean dx: 2-15 years).

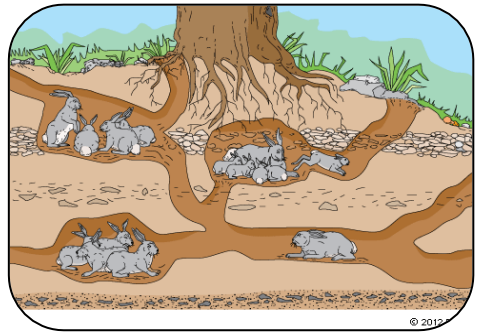

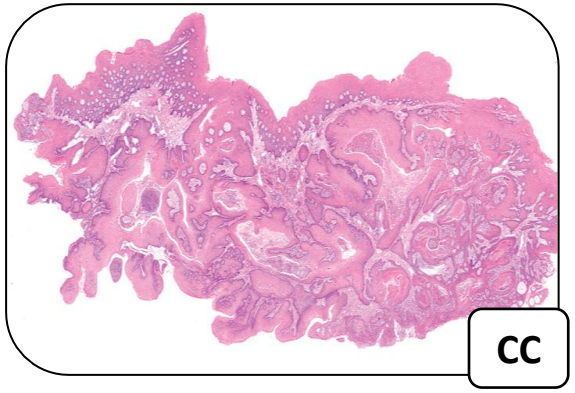

VC vs CC: The Same or Different ?

- **Similarities**:
  - **Clin:** Both **slow growing** lesions (>1yr), typically in **older patients**.
  - **Site:** Palms/soles, H+N mucosa, anogenital (inc penis/scrotum).
    In the literature: **CC: 1 x groin, cervix, vulva**.
  - **RFs:** Trauma/friction. HPV "equivocal" in anogenital lesions.
  - **Micro:** "Low grade appearance" (i.e. bland, scant mitoses)
    Can have **"inflammatory phenotype".**
    Both need **deep biopsies to diagnose.**

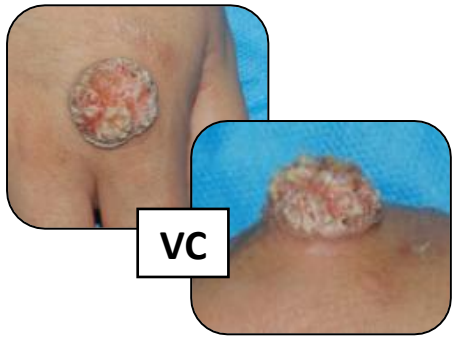



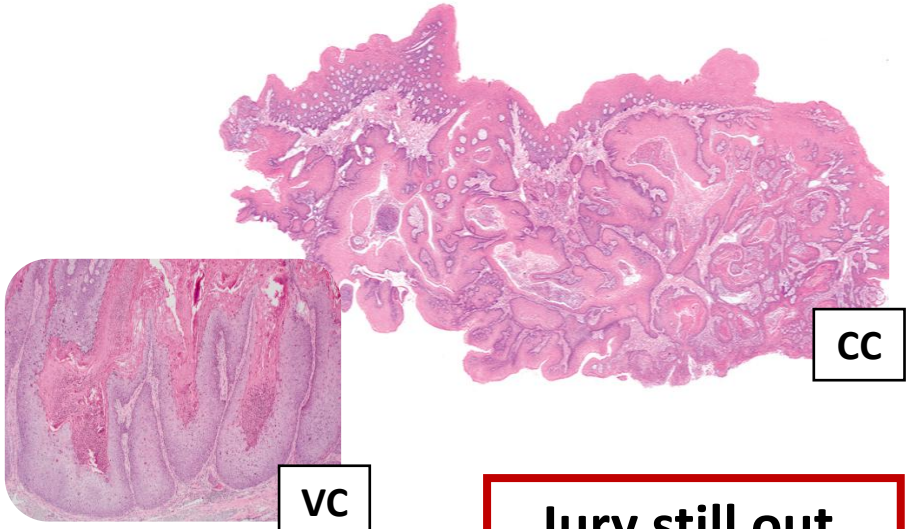

- **Differences:**
  - **VC =** white, EXOPHYTIC. **CC =** pink/pussy, **primarily ENDOPHYTIC.**
  - **VC =** broad rete, pushing, 'bull-dozing".
  - **CC =** branching, jagged, sinuses **"rabbit warren" / "maze-like".**
  - ? Associated with **Precursors.**
  - **Metastases**: "low" vs **"none"?** (or 4/41 if you read the reference).

PMID: 30607347.

Jury still out.

~20% associated "hybrid" conventional inf. SCC

Conclusions:

- **Hidradenitis Suppurative** is a **follicular occlusion disorder,** typically affects **young adults**, with a long-term **complication risk**.
- Clinically distinct but can prove diagnostically challenging.

- **Carcinoma Cuniculatum** is a **well-differentiated SCC** sub-type**,** it can be **clinically insidious**, and present with **acute inflammatory picture**.
- **May require multiple (deep) biopsies to diagnose.**

- **If possible try not to report vulval biopsies in isolation:**
  - **Requires:** **Age** of Patient, Symptoms …
  - **Clinical Scenario / Impression**. Could it be a mimic?
  - **Previous** biopsy samples? Is **follow up / CPC required?**
- **Concerning features**: age >65 years, isolated + persisting lesions.



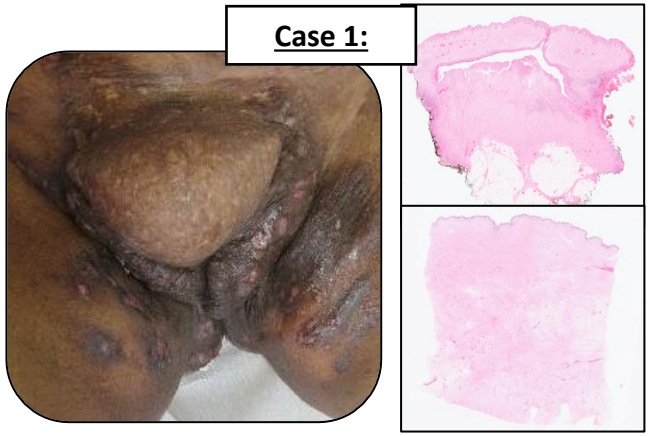

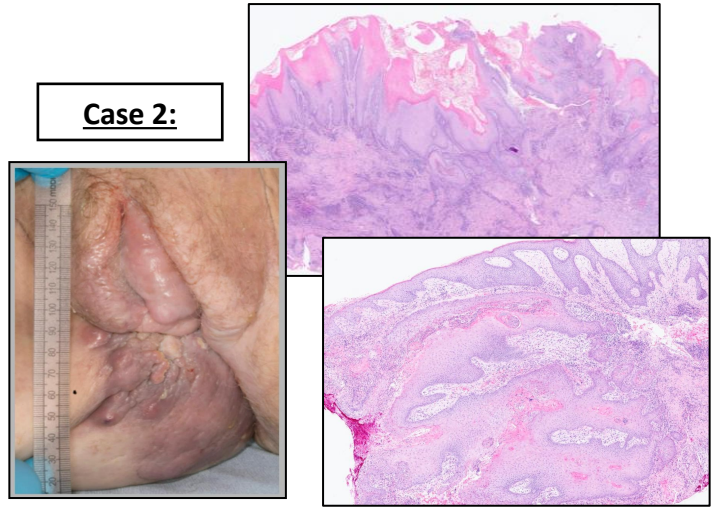

References:

1) Nowak-Liduk et al. 2023. **Hidradenitis Suppurativa: An Interdisciplinary Problem in Dermatology, Gynecology, and Surgery**-Pathogenesis, Comorbidities, and Current Treatments. *Life.* 11;13(9):1895.

2) Lopez-Llunell et al. 2020. **Vulvar hidradenitis suppurativa**: Clinical cross-sectional study of 25 patients. *J Dermatol.* 48:457-463.

3) Micieli et al. 2018. **Lymphedema in patients with hidradenitis suppurativa: a systemic review or published literature.** *The International Society of Dermatology.* 57: 1471-1480.

4) Kurt et al. 2016. **Massive localized lymphedema**: a clinicopathologic study of 46 patients with an enrichment for multiplicity. *Mod Pathol* 29, 75–82.

5) Miller et al. 2016. **Prevalence, Risk Factors, and Comorbidities of Hidradenitis Suppurativa.** *Dermatol Clin*. 34(1):7-16.

6) Preda-Naumescu et al. 2021. **Hidradenitis suppurativa: pathogenesis, clinical presentation, epidemiology, and comorbid associations**. *Int J Dermatol.* 60(11):e449-e458.

*7) [**Image**] VC hand: i). Lee DH and Lee JI. 2015. Verrucous Carcinoma on the Dorsal Aspect of the Hand. Journal of Cutaneous Medicine and Surgery. 19(4):349-351.*

*8) [I**mage**] VC vulva: ii). Iwamoto et al. 2004. Verrucous carcinoma of the vulva in Turner syndrome, Gynecologic Onclogy. 92(1)380-383.*

*9) [**Image**] CC finger: iii) Guerra et al. 2021. Carcinoma Cuniculatum with Bone Invasion Mimicking a Viral Wart. J Port Soc Vermatol Venerol. 79(3)265-268.*

10) Delahaye et al. 1994. **Le carcinome cuniculatum. 6 observations et revue de la littérature [Cuniculatum carcinoma. 6 cases and review of the literature].** *J Chir* (Paris). 131(2):73-8. French. PMID: 8207099.

11) Smyth et al. 2014. **Carcinoma cuniculatum of the cervix.** *Pathology*. 2014 46(4):353-5.

12) Mendez-Ojeda et al. 2021. **Epithelioma cuniculatum of the sole of the foot mimicking an infection.** *Acta Ortopedica Mexicana.* 35(2) 211-214.

13) Stchepinsky N. and Alkassir M. A. 2024. **Invasive Cuniculatum Carcinoma mimicking Hidradenitis Suppurativa.** *Am J Dermatopatholo*. 47(1): 79-80.

14) AbdullGaffar, A. and Ganapathy, L. R. **Carcinoma Cuniculatum of the Scrotum.** *Am J Dermatopathol.* 47(4) 330-334.

15) Farag et al. 2018. **Oral carcinoma cuniculatum, an unacquainted variant of oral squamous cell carcinoma: A systematic review.** Imaging Sci Dent. 48(4):233-244.

16) Parra-Herran et al. 2022. **HPV-independent, p53-wild-type vulvar intraepithelial neoplasia: a review of nomenclature and the journey to characterize verruciform and acanthotic precursor lesions of the vulva**. *Mod Pathol*. 35(10):1317-1326.

Acknowledgements again to: Dr R Ganesan and Dr R Muc

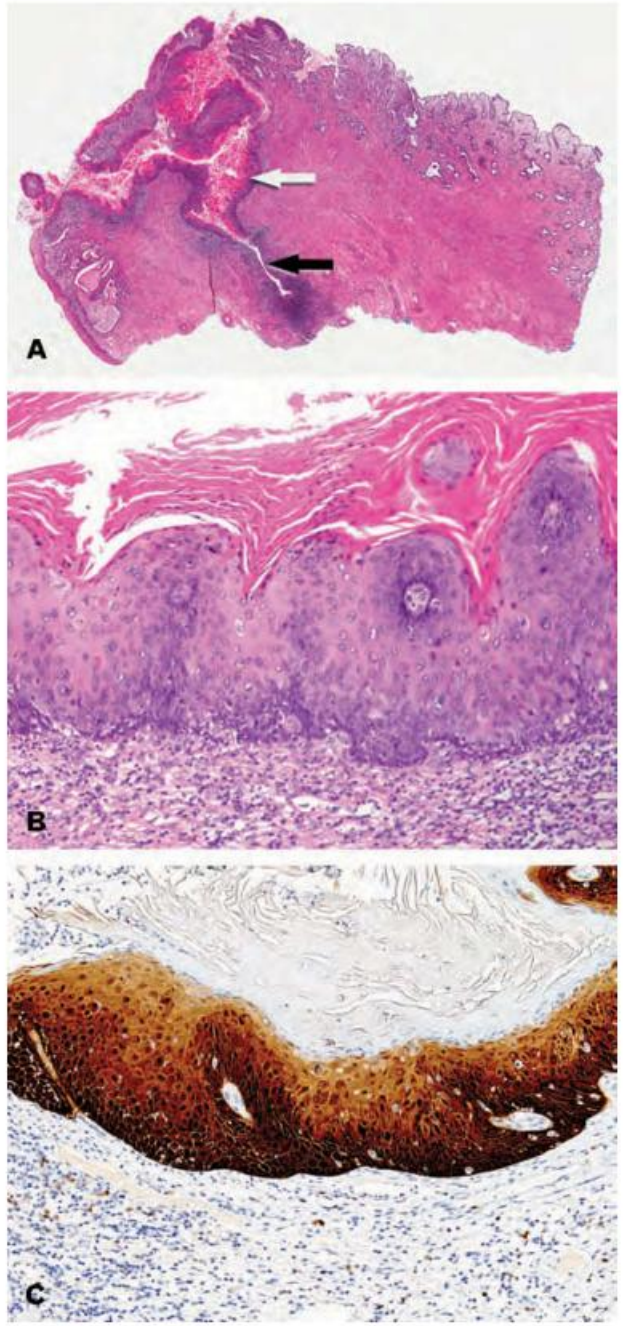

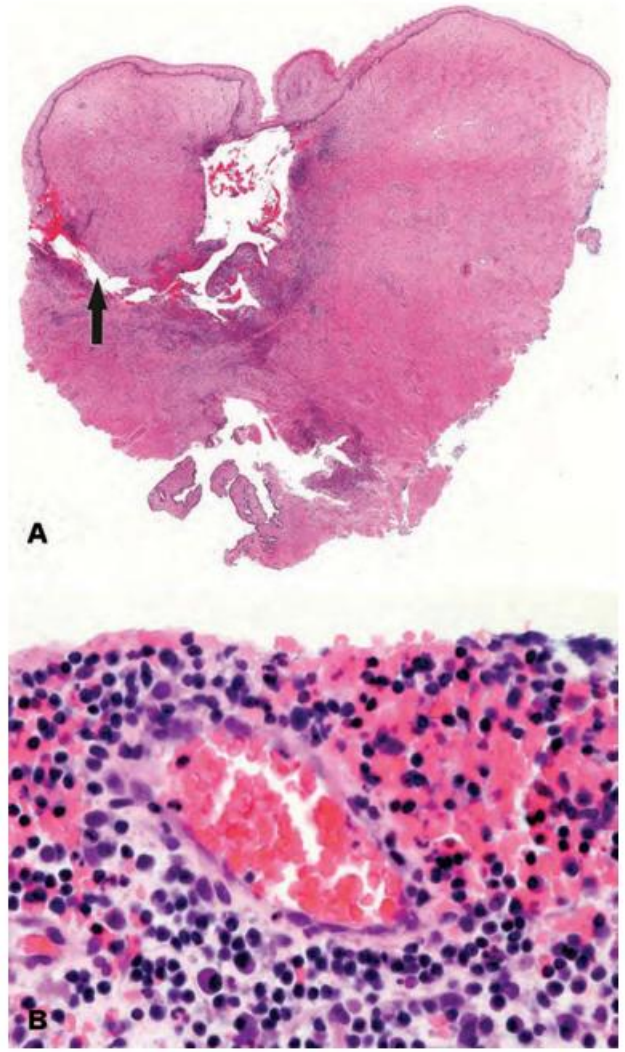

Fig. 2 Second cone biopsy. (A) Whole slide mount showing tract (black arrow); (B) tract lined by inflammation.

An early study suggested a possible role for HPV 11 in the pathogenesis of CC.[3] The only subsequent study to demonstrate the presence of HPV DNA in CC is a case of the fingers where HPV types 31 and 33 were identified.[4] PCR in our case showed HPV 18. Since CC may arise with and without HPV and when with HPV of high or low risk HPV types, it would

Smyth et al. 2014. **Carcinoma cuniculatum of the cervix.** *Pathology*. 2014 46(4):353-5.

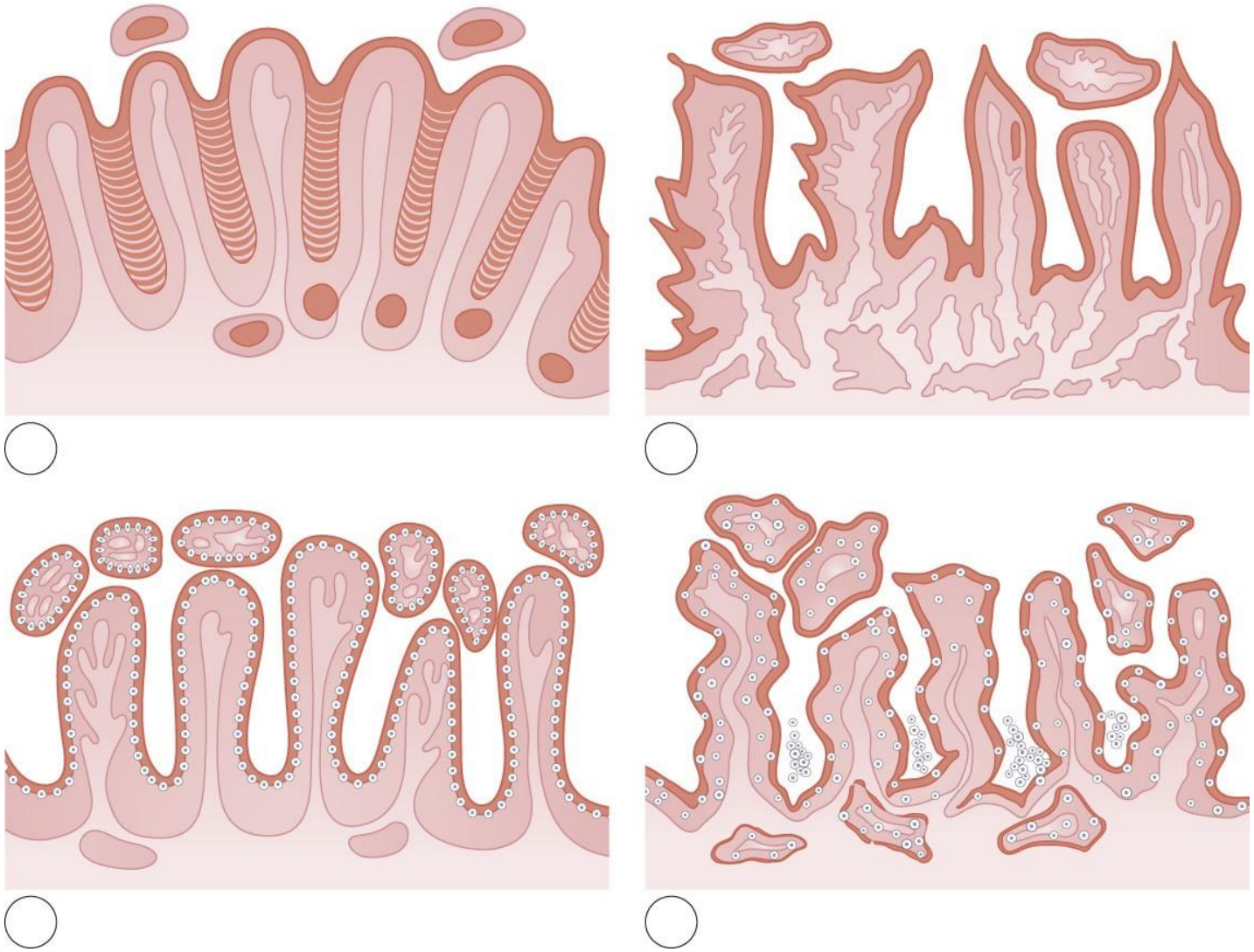

Fig. 12.215 - Usual squamous cell carcinoma: poorly differentiated (grade 3) usual SCC with prominent atypia but evidence of squamous differentiation. (**A**) Verrucous carcinoma: tight papillae separated by keratin *(in red)* . Broadly based boundaries between tumor and stroma. (**B**) Papillary carcinoma: irregular papillae without koilocytosis. Jagged tumor–stroma limits. (**C**) Giant condyloma: condylomatous papillae, surface koilocytosis *(white dots)* and broad noninvasive base. (**D**) Warty (condylomatous) carcinoma: irregular condylomatous papillae, diffuse koilocytosis and jagged boundary between tumor and stroma