The British Association of Gynaecological Pathologists

21st Annual Meeting in Collaboration with ISGyP

5th and 6th June 2025

- **Title.** Hydatidiform Moles and Practical Use of P57 Immunostain
- **Speaker.** Pei Hui, MD
- **Affiliation.** Yale University School of Medicine
- **Date.** 6th June 2025

The British Association of Gynaecological Pathologists

Speaker disclosures

I have no relevant financial conflicts of interest to disclose

Complete Hydatidiform Mole



Diagnostic Challenges Precision Solutions







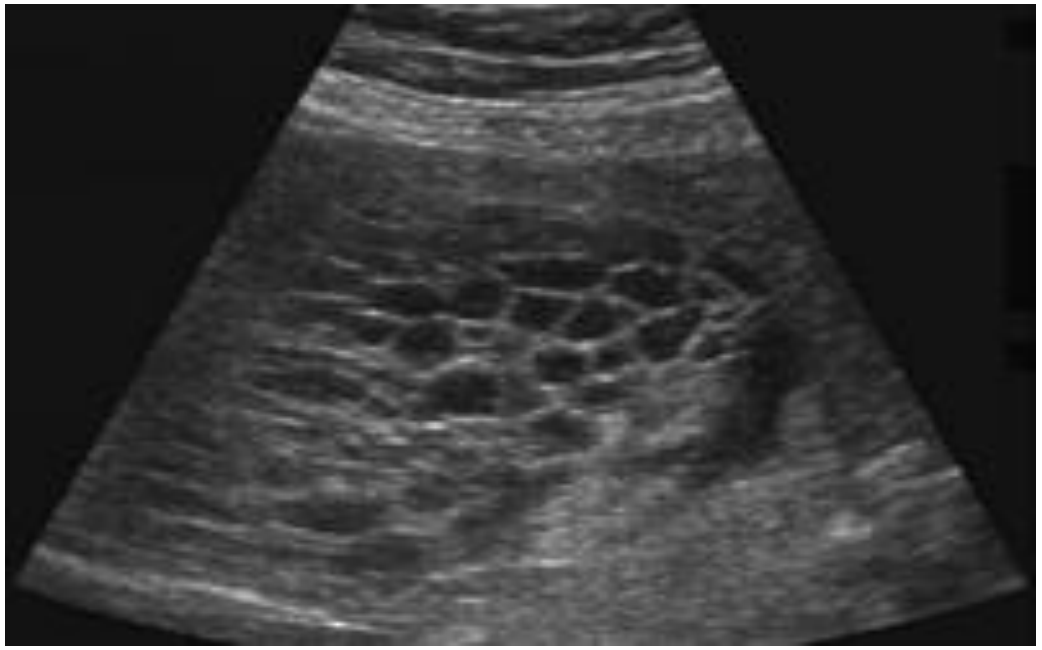

Well Developed CHM

- Vaginal bleeding during 2nd trimester
- Excessive uterine size
- Markedly elevated serum hCG (hyperemesis)
- Toxemia, hyperthyroidism
- “Snowstorm” appearance on U/S

Elsayes K M et al. Radiographics 2009; 29:1371-1391.

Complete Mole

- Villous Hydrops, Cistern Formation
- Atypical Trophoblast Hyperplasia

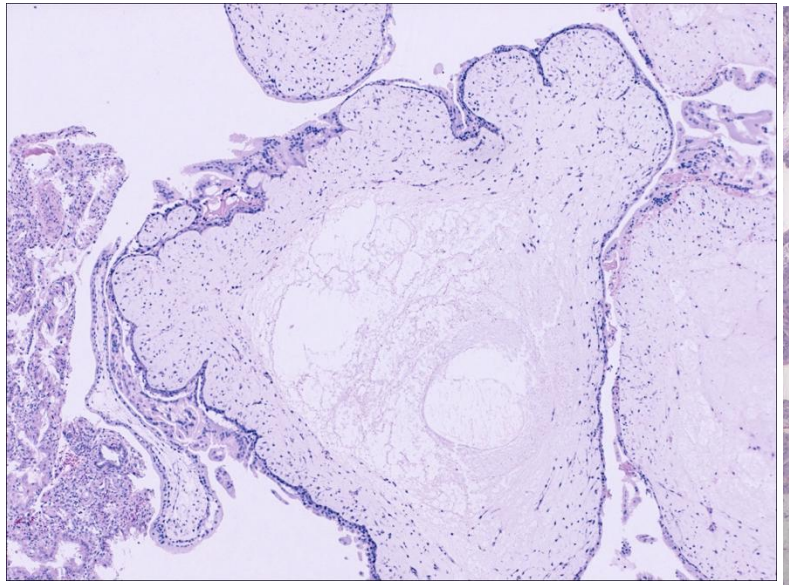
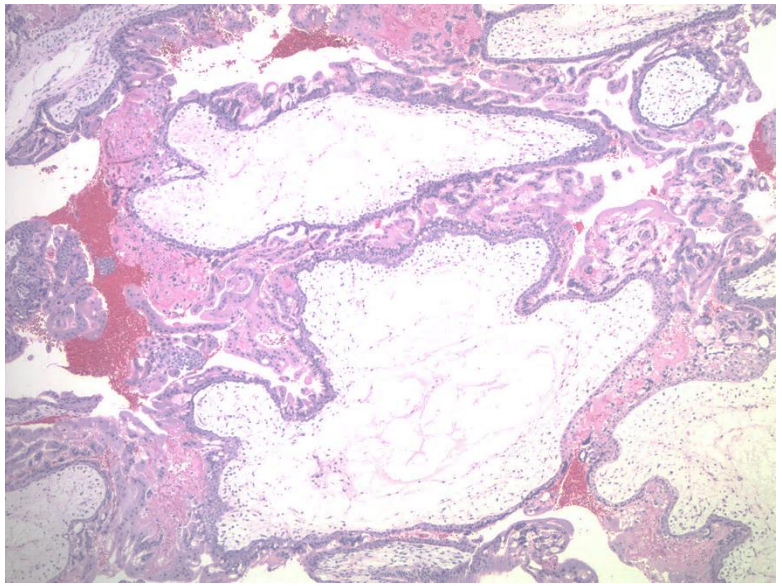
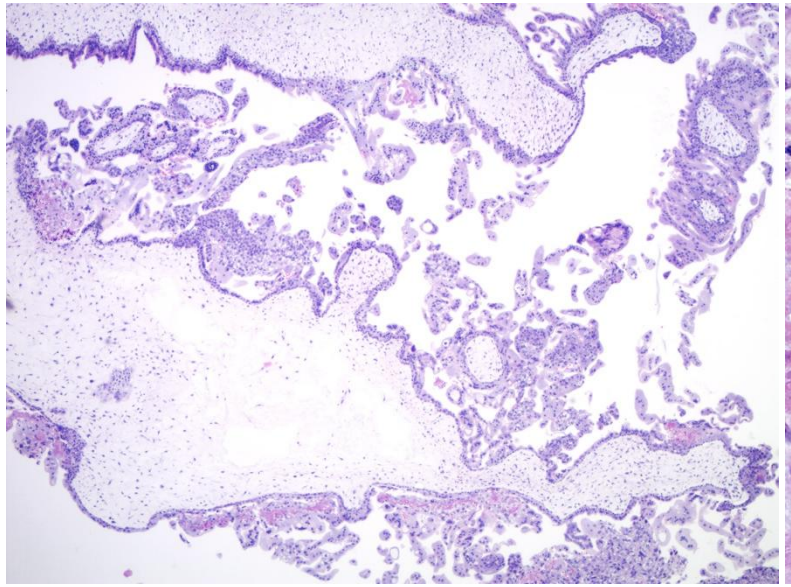
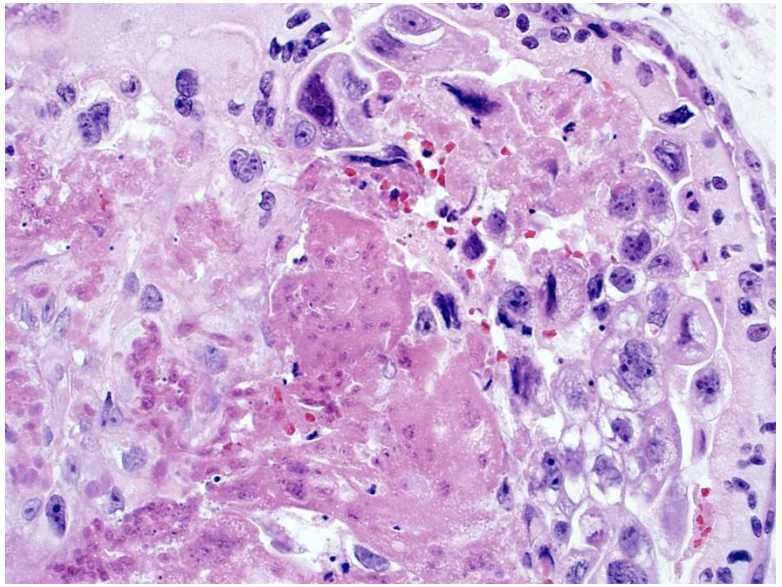

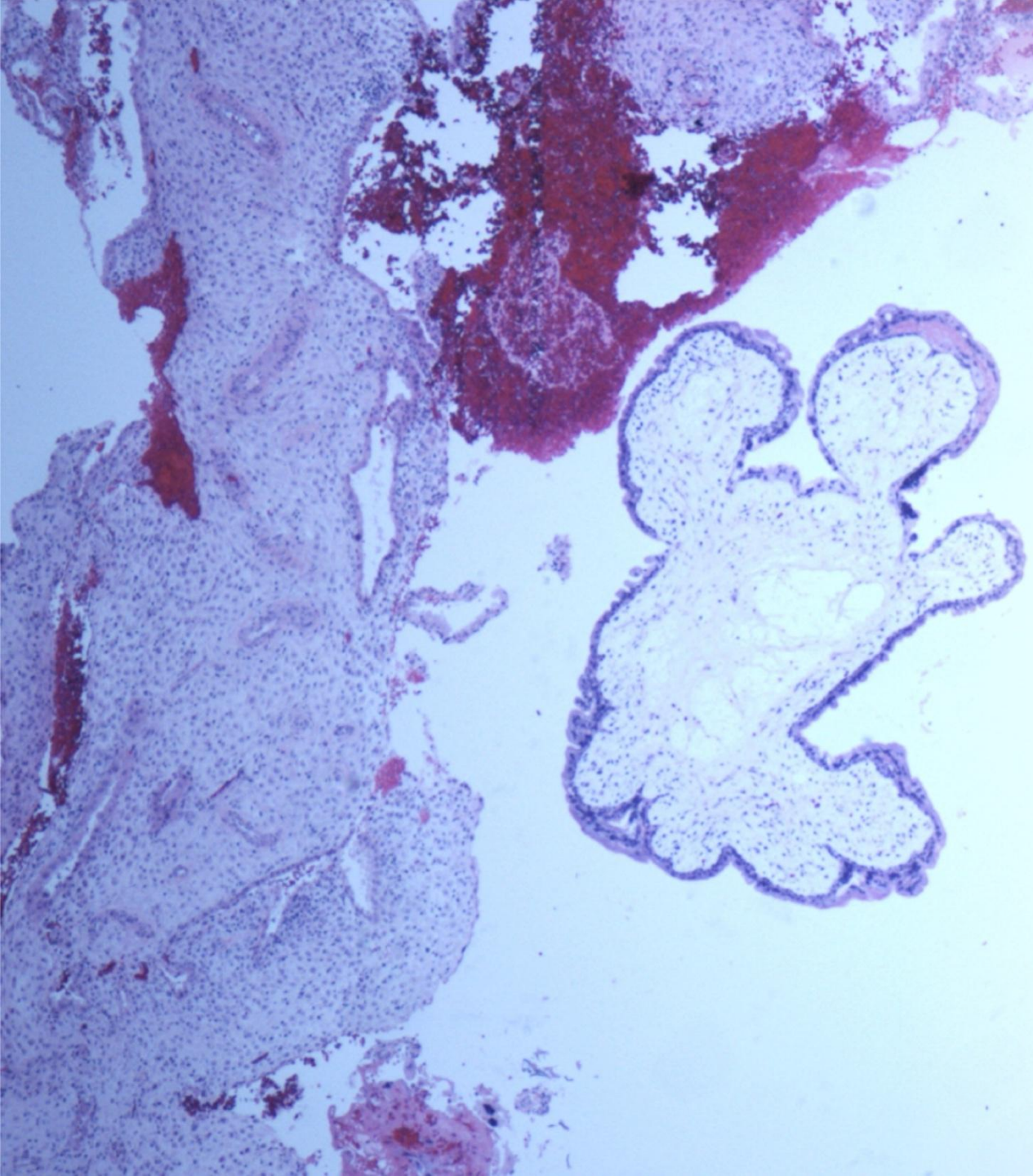

Very Early Complete Mole (VECHM)

- Lack of gross hydropic changes
- Polypoid or cauliflower-like configurations of normal sized or slightly enlarged chorionic villi
- Cellular myxoid villous stroma with prominent karyorrhexis
- Rare abnormal trophoblastic hyperplasia in random or circumferential fashion

Very early CHM

- Bulbous polypoid villi

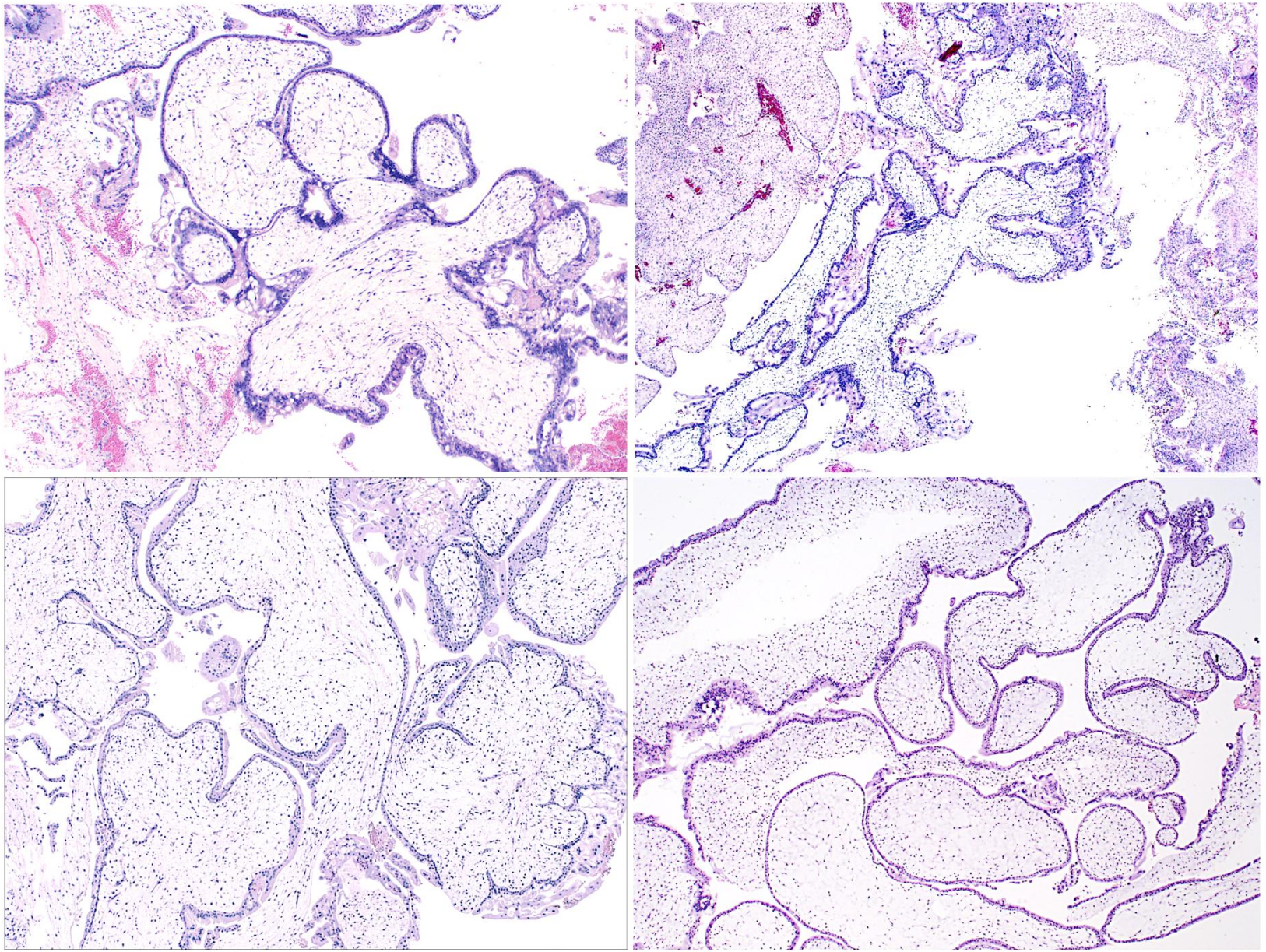

Very early CHM

- Bulbous, polypoid villi
- Cellular myxoid stroma

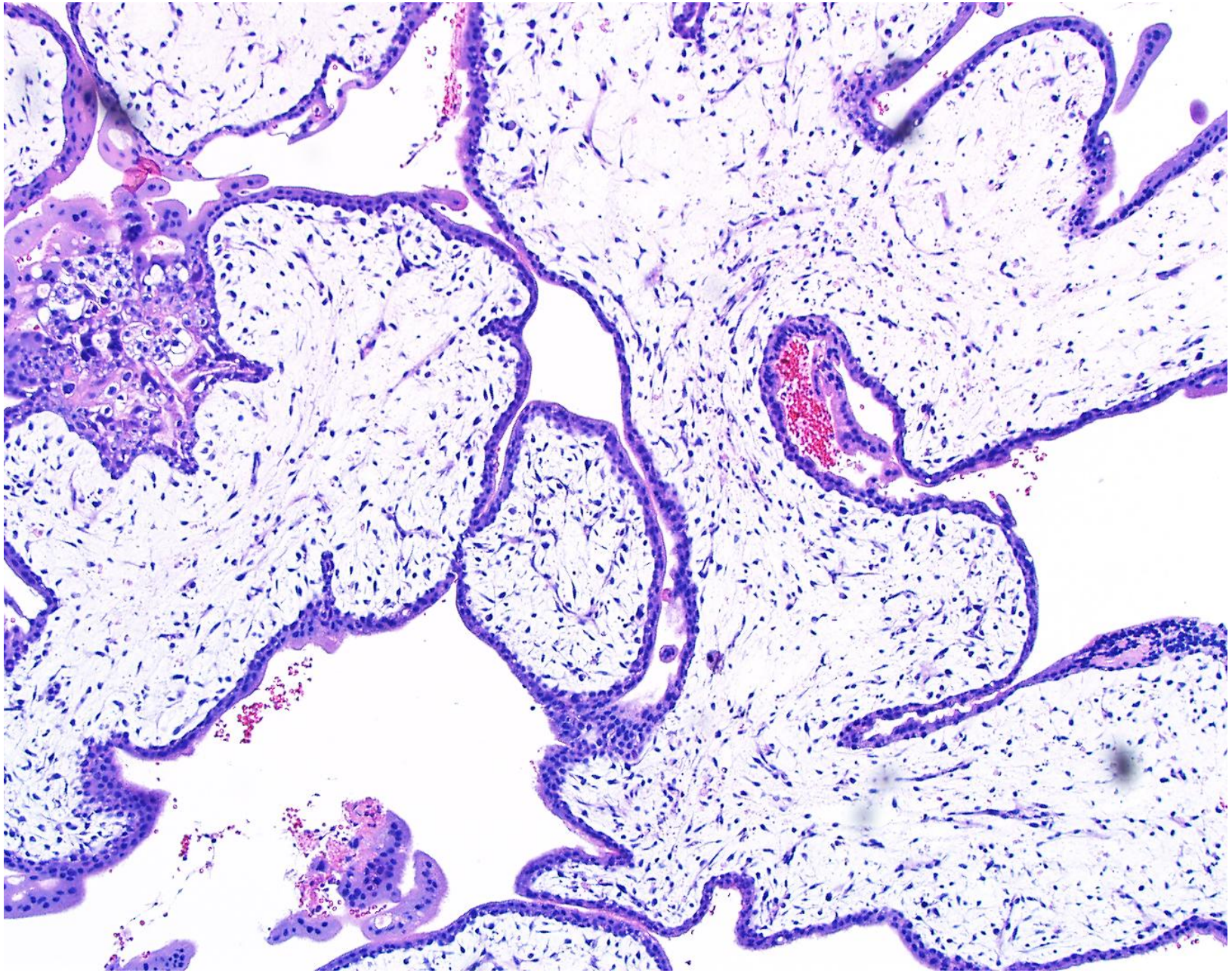

Very early CHM

- Trophoblast hyperplasia

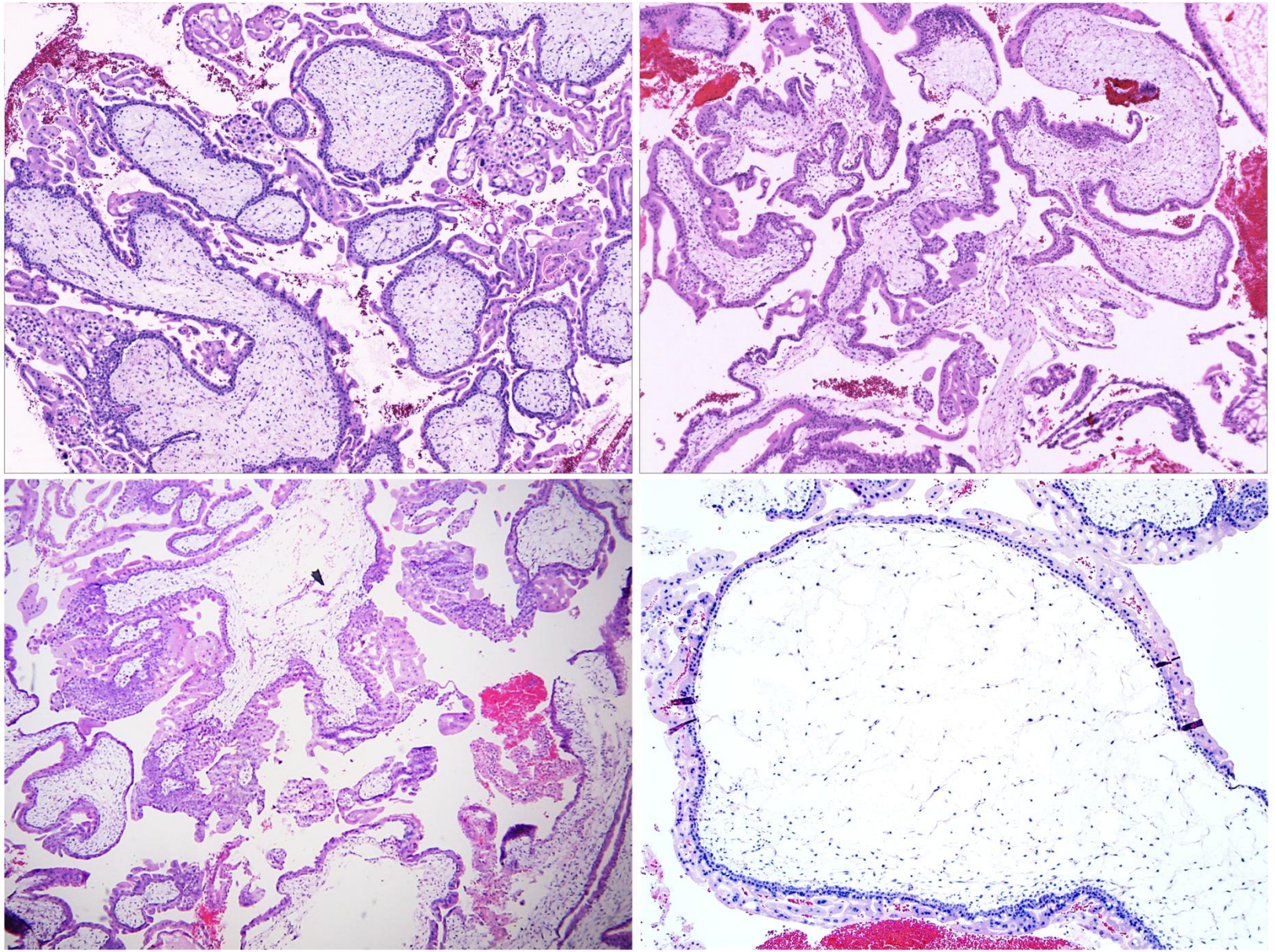

Abnormal Villous Trophoblastic Proliferation

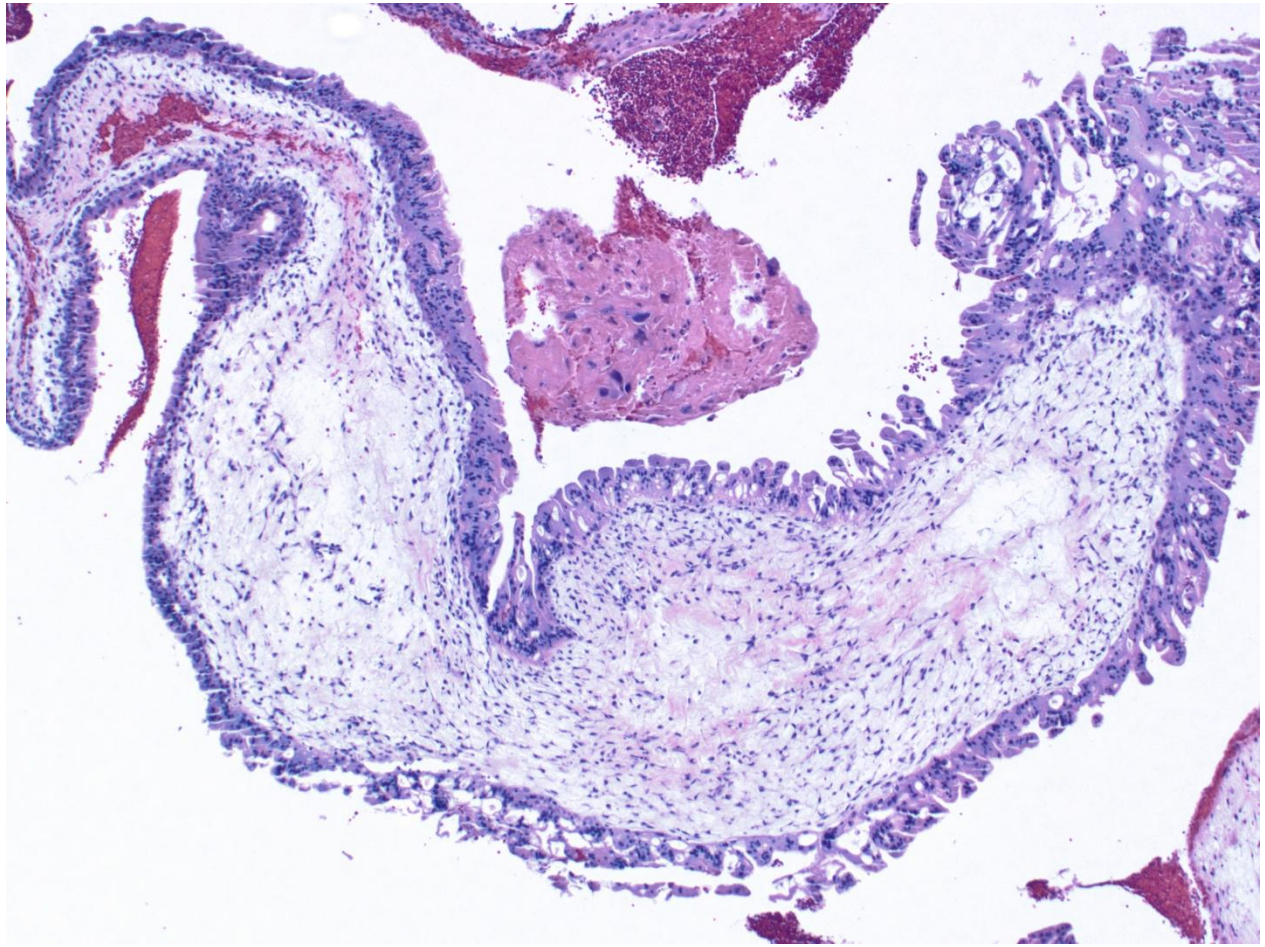

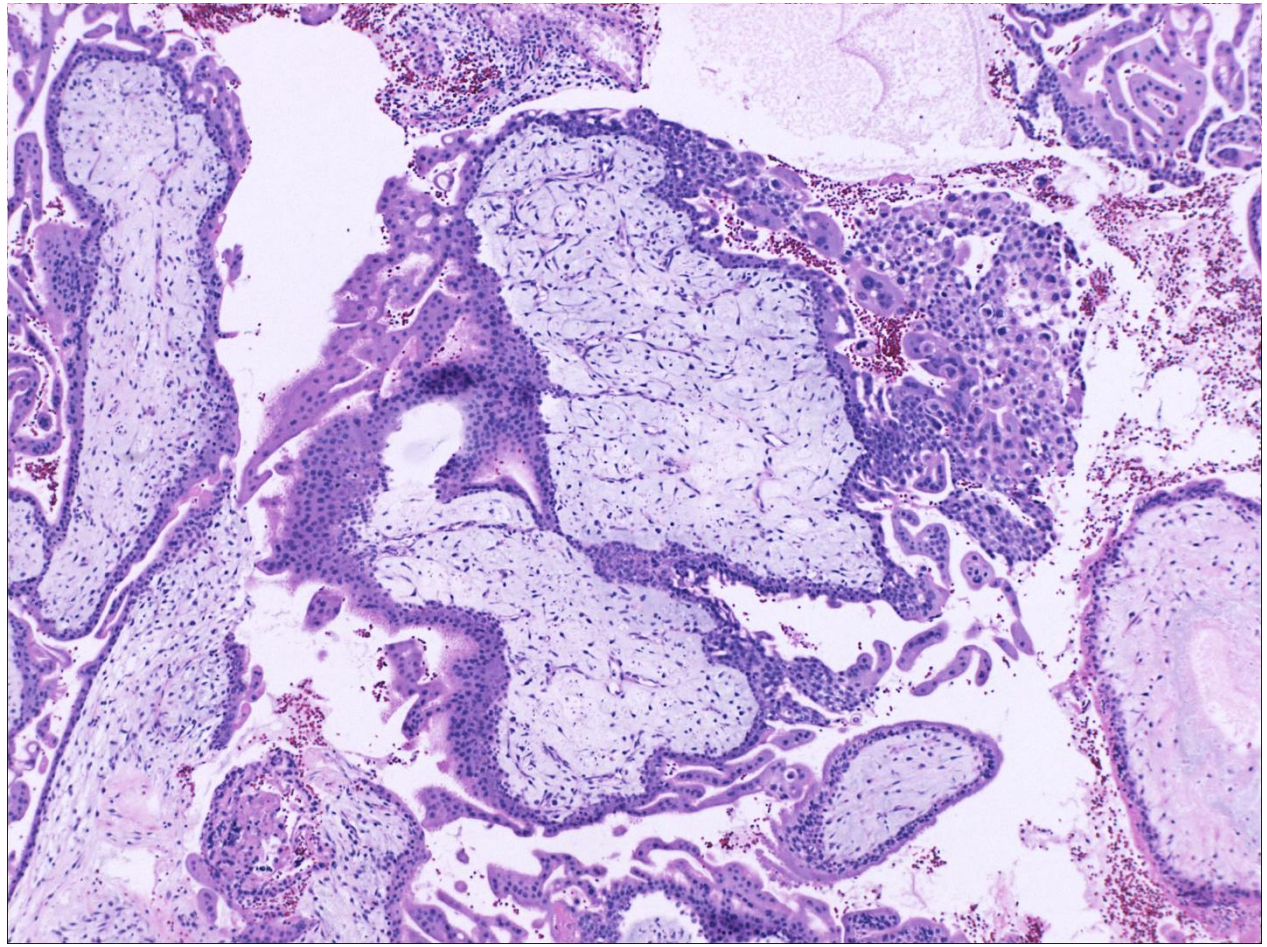

Very early CHM

- Cellular myxoid stroma
- Prominent karyorrhexis

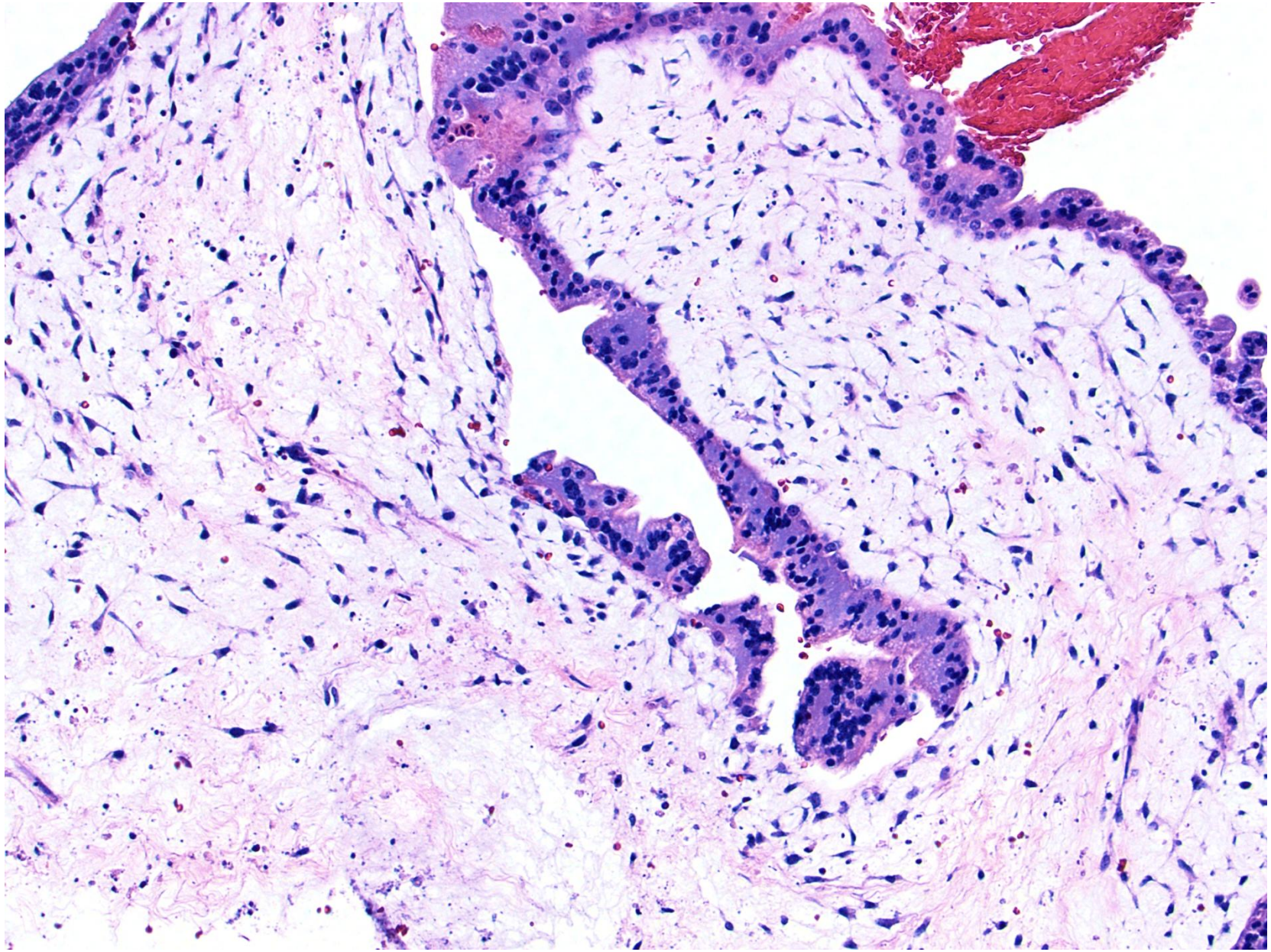

Very early CHM

- Cellular myxoid stroma
- Prominent karyorrhexis

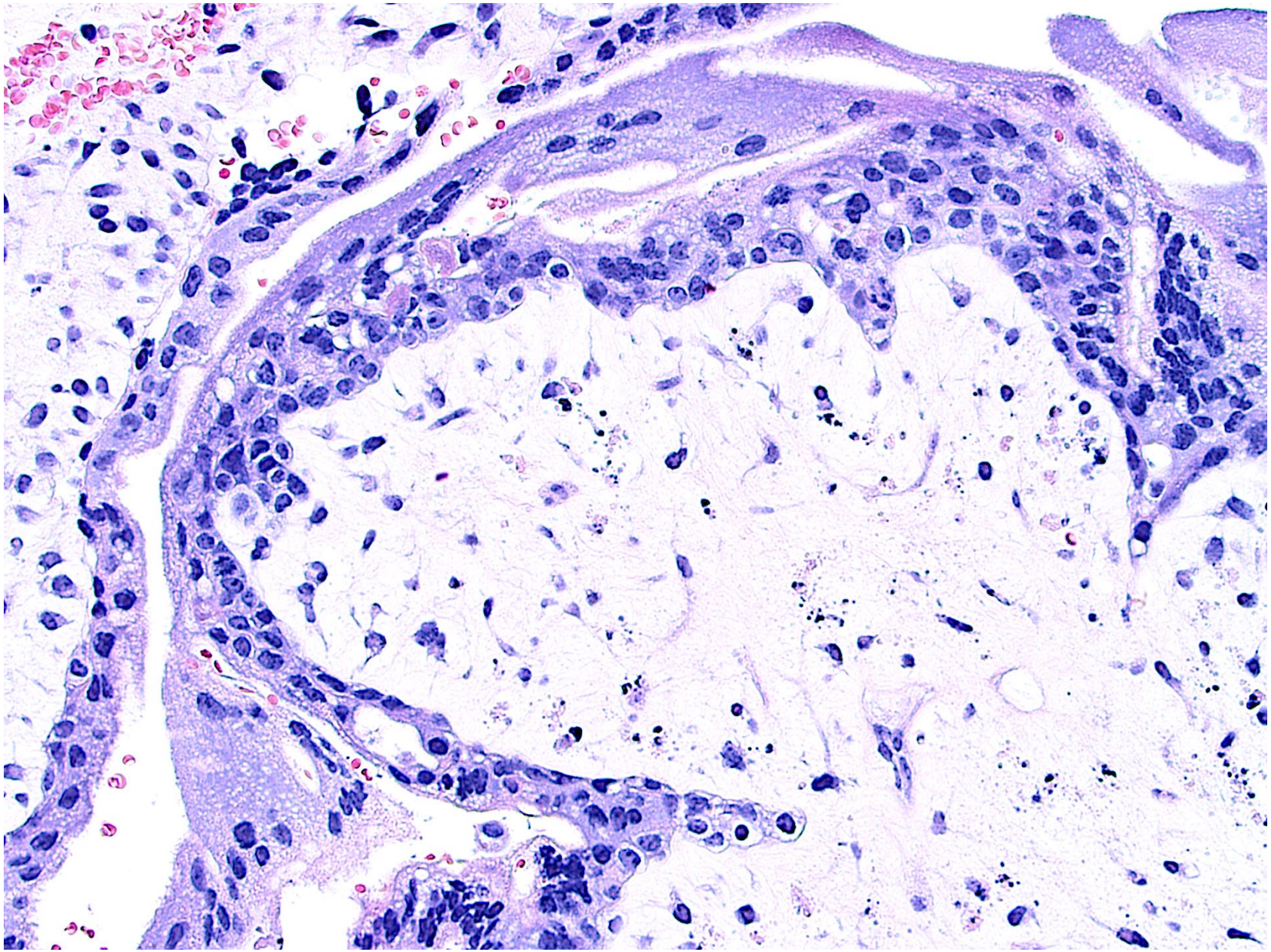

Early Complete Mole – Immature vasculature and nucleated RBC

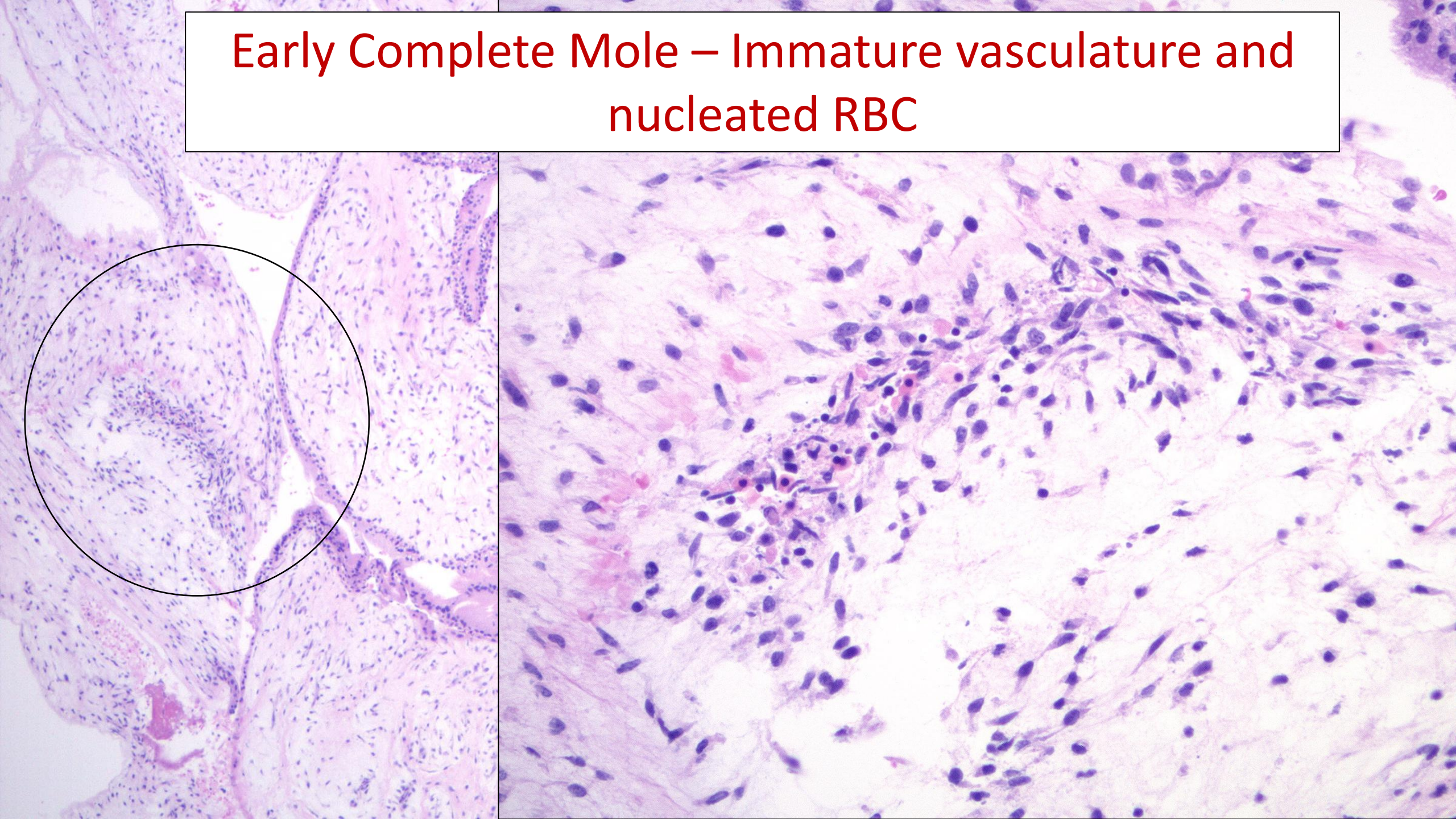

P57 IHC

Cyclin-dependent kinase inhibitor protein

Encoded on 11p15.5

Paternally imprinted – expressed only from the maternal allele

Cytogenetic band: 11p15.4 by HGNC 11p15.4 by Entrez Gene 11p15.4 by Ensembl

CDKN1C Gene in genomic location: bands according to Ensembl, locations according to GeneLoc (and/or Entrez Gene and/or Ensembl if different)

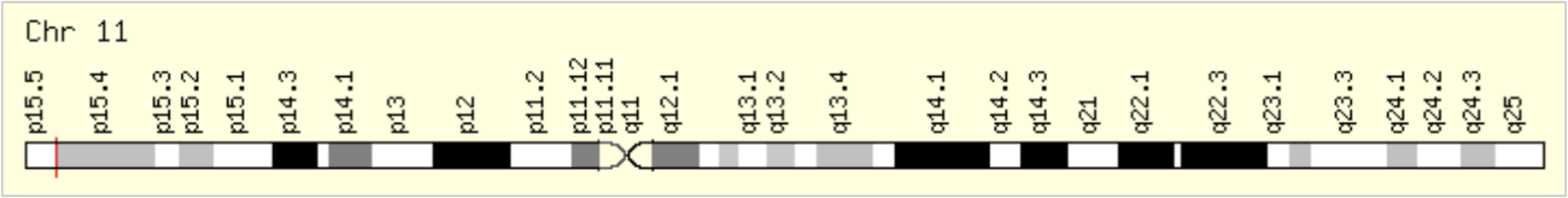

www.genecards.org

COMPLETE MOLE



Two Copies of Sperm Empty Egg

Paternal Chromosome Only (Androgenetic)

PARTIAL MOLE

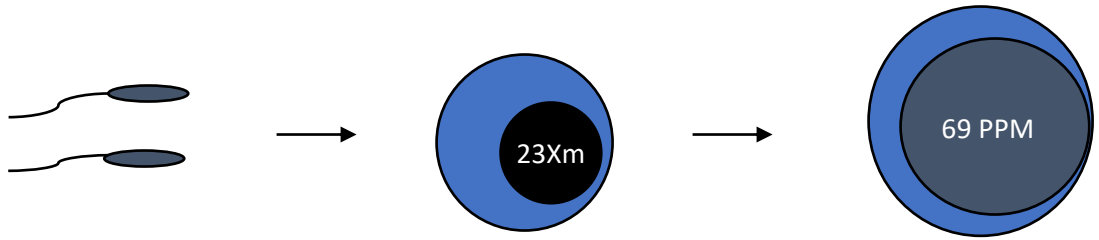

Two Copies of Sperm Egg

Paternal and Maternal Chromosome (Triploid)

CHM – P57

Negative in villous stromal cells and cytotrophoblast (<10%)

Internal (+) control intermediate trophoblasts

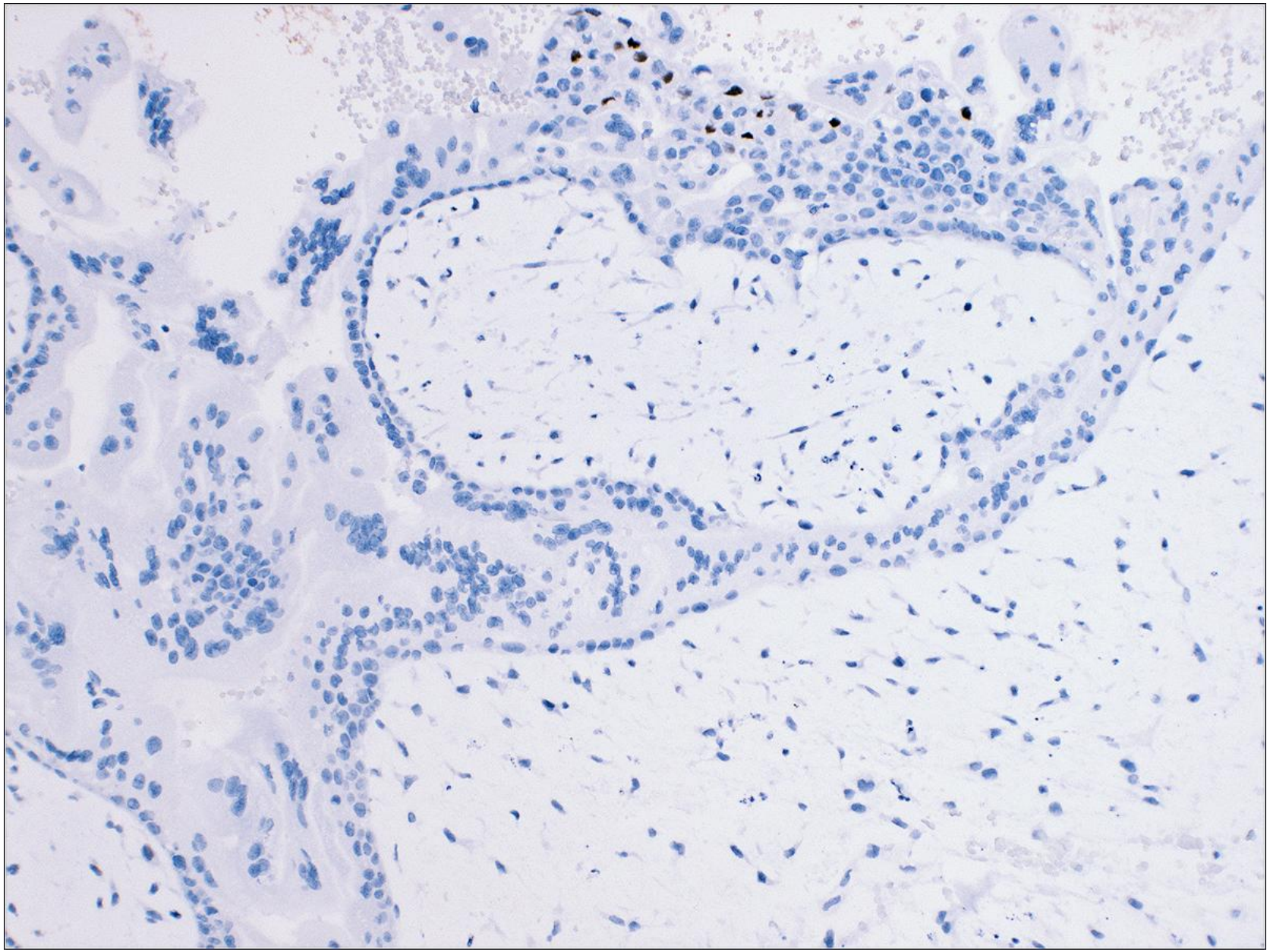

P57 Immunohistochemistry – Confirming CHM

- Positive expression in gestations containing maternal genetic material
    - PHM (Diandric triploidy)
    - Digynic triploidy
    - Non-molar hydropic abortions
    - Chromosomal trisomies

P57 Expression Patterns and Interpretations

	Histological Impression	Cytotrophoblast	Villous Stromal Cells	Interpretation
Positive	HA, PHM	+	+	Normal Expression
Negative	CHM	-	-	Consistent with CHM
Divergent	Admixed CHM and HA	+ villi and - villi	+ villi and - villi	CHM in twin gestation or androgenetic biparental gestation
Discordant	Abnormal villi	+ or -	- or +	Androgenetic biparental gestation
Contradictory	CHM or PHM	+ or -	+ or -	CHM/retained maternal chromosome 11 or PHM/loss of maternal chromosome 11

Hui P. Gestational Trophoblastic Disease: Diagnostic and Molecular Genetic Pathology. Second Edition, Springer, 2025

P57 Positive

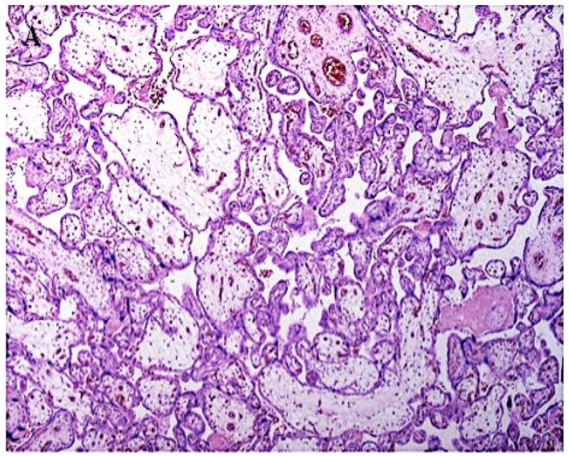

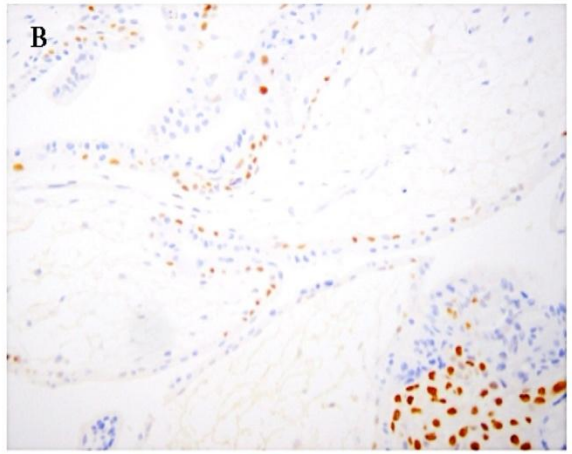

Hydropic Abortus

P57 Positive

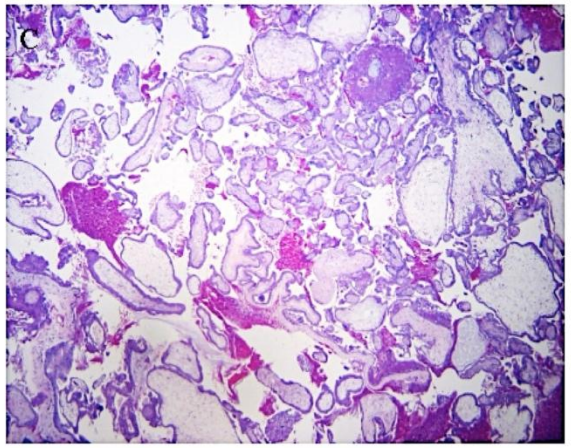

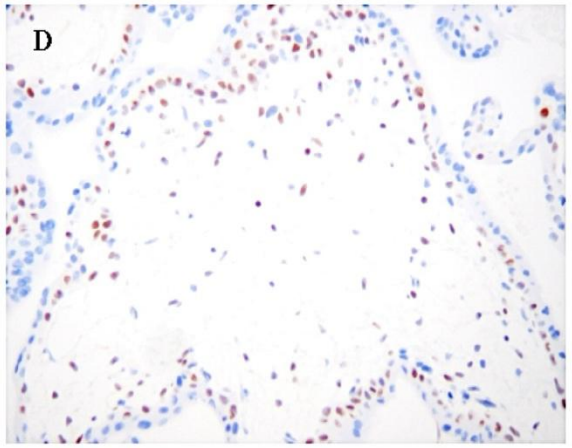

Partial Mole

P57 Negative

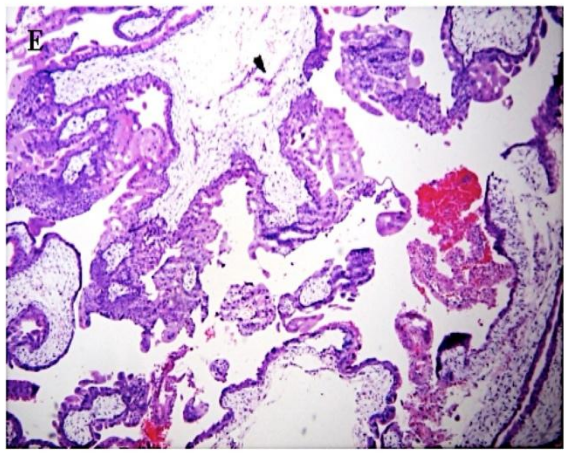

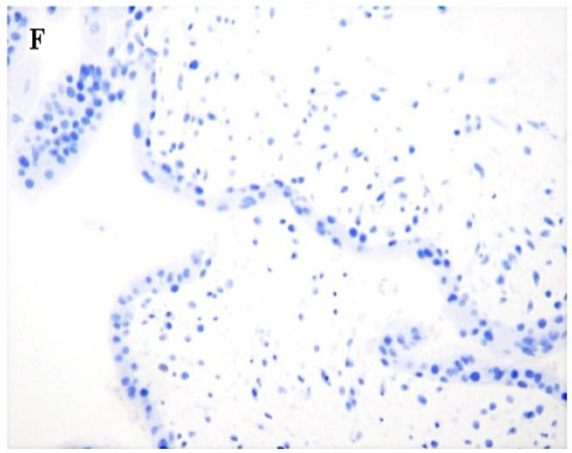

Complete Mole

Divergent P57 Expression

Twin Gestation

Complete Hydatidiform Mole and Coexisting Fetus With Gastroschisis: A Case Report Highlighting the Importance of Diagnostic Genotyping

Austin McHenry[1], Urania Magriples[2], Pei Hui[1], and Raffaella Morotti[1]

Pediatric and Developmental Pathology
2021, Vol. 24(6) 575–580
© 2021, Society for Pediatric Pathology
All rights reserved
Article reuse guidelines:
sagepub.com/journals-permissions
DOI: 10.1177/10935266211024823
journals.sagepub.com/home/pdp
SAGE

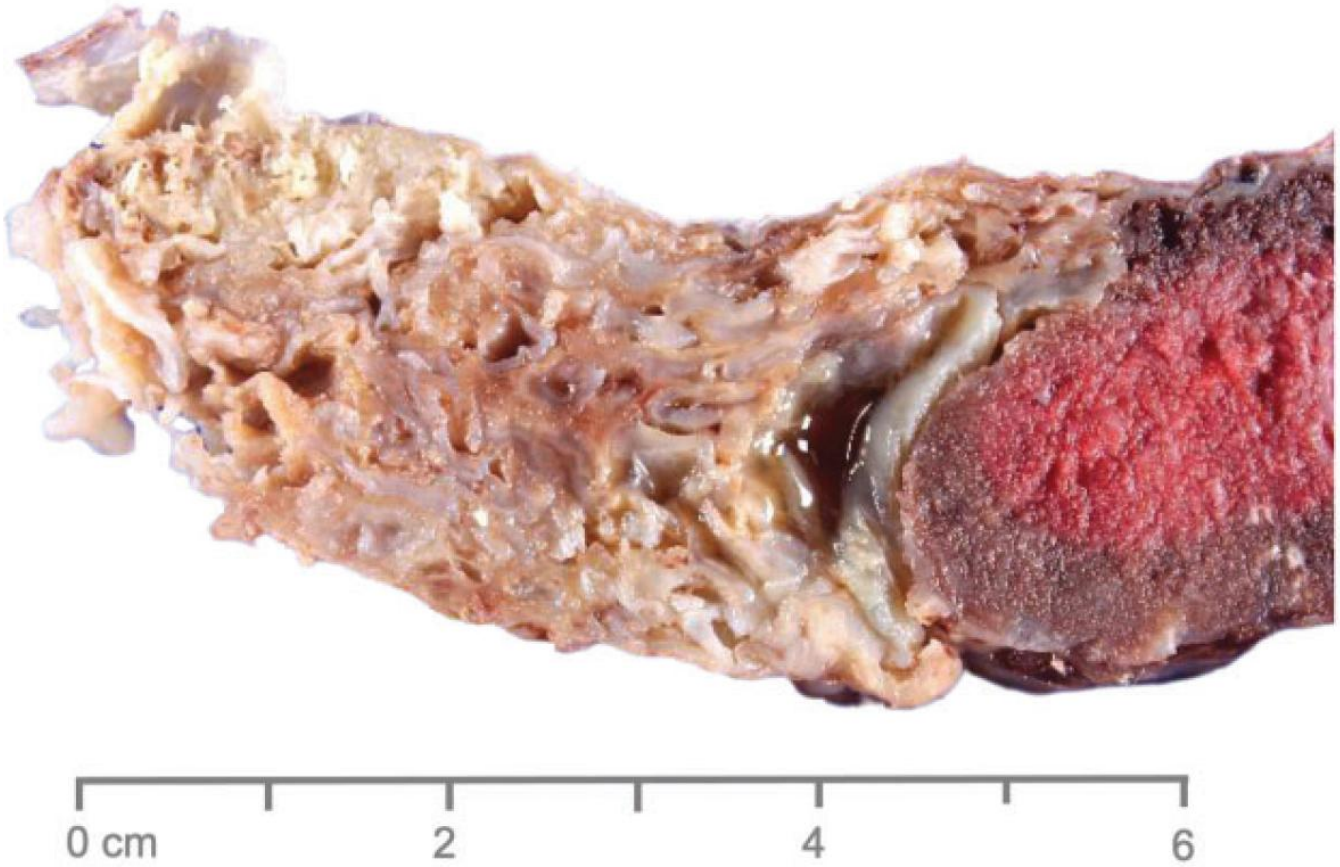

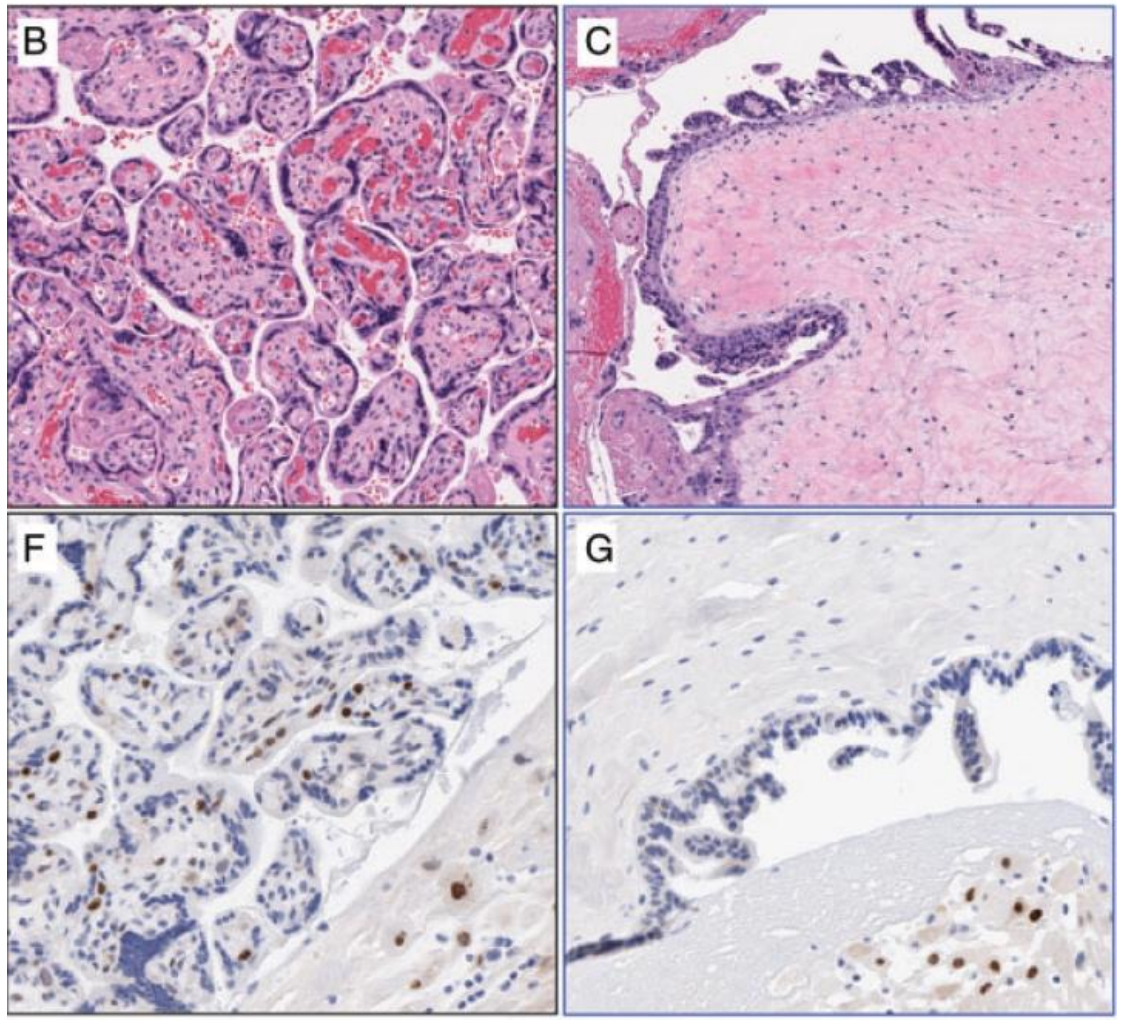

P57 Divergent VECHM in Twin

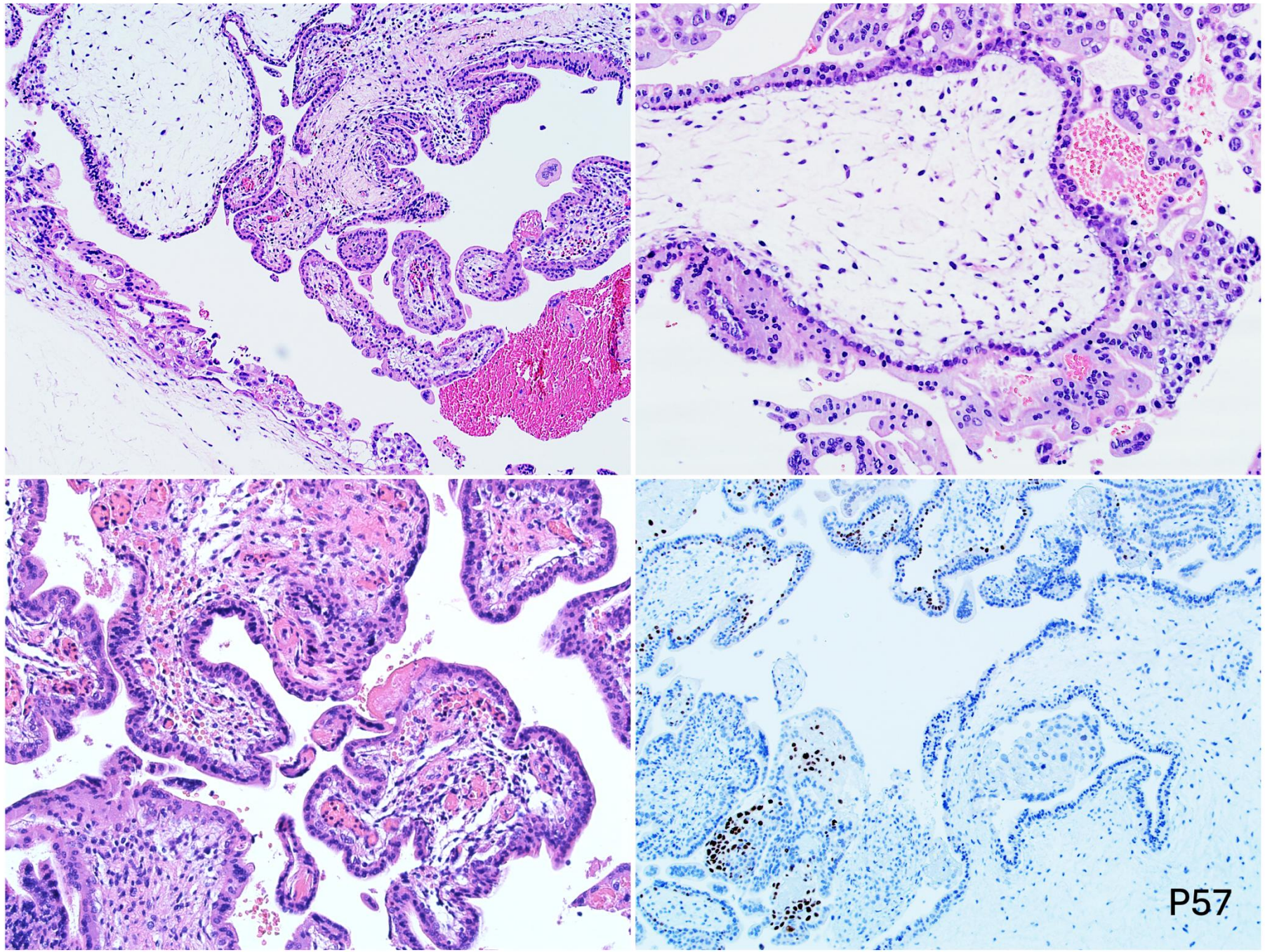

Discordant P57 Expression - Androgenetic/ Biparental Mosaic Gestations

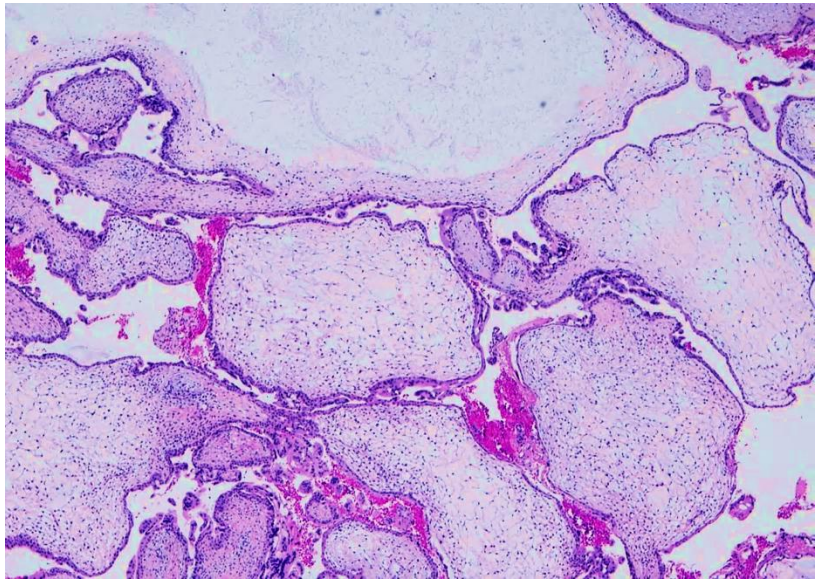

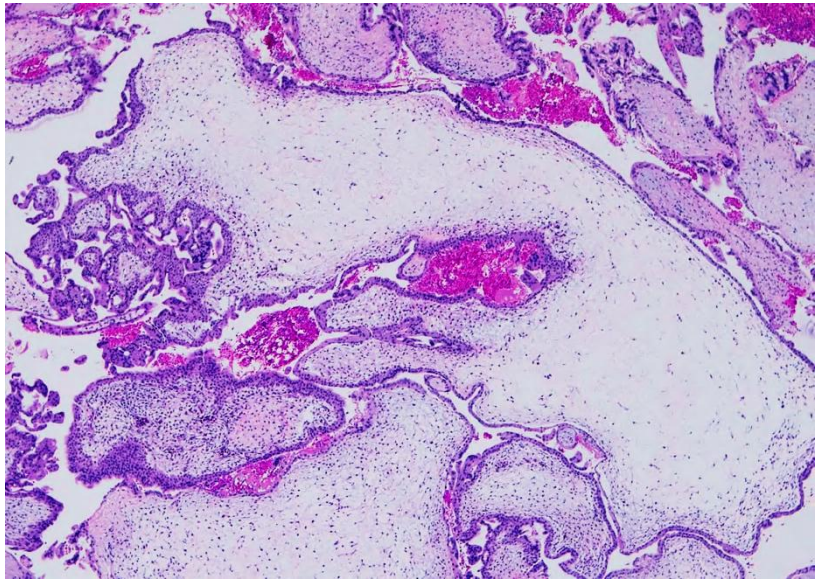

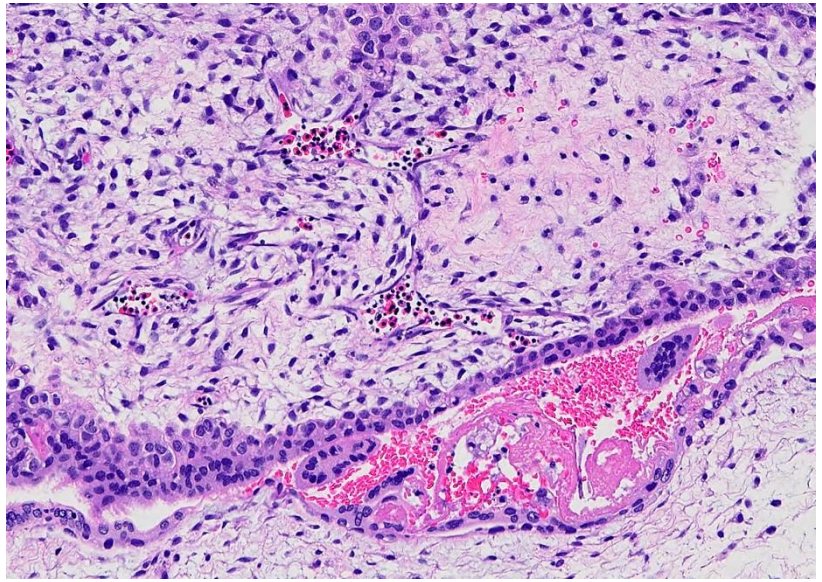

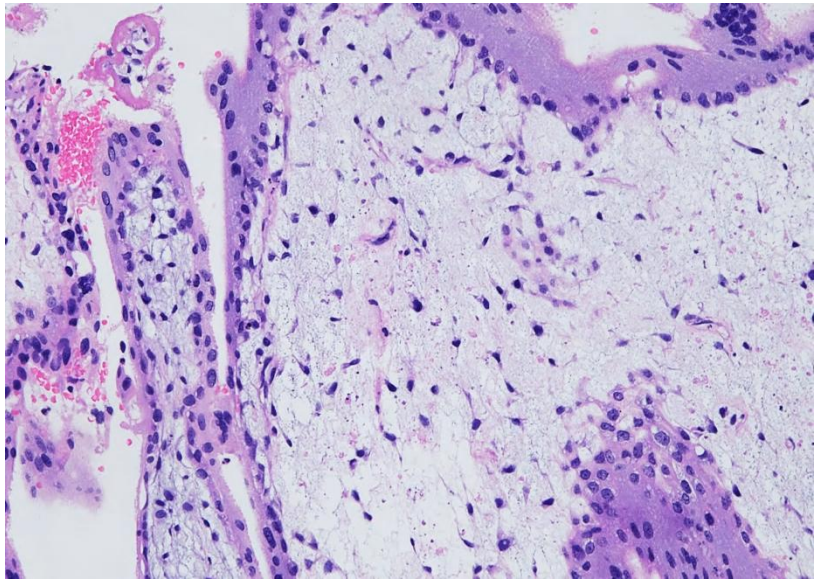

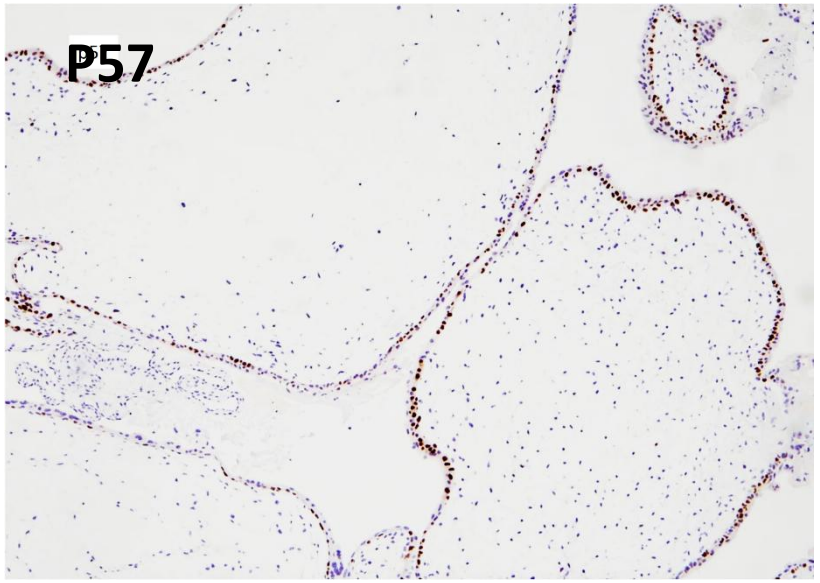

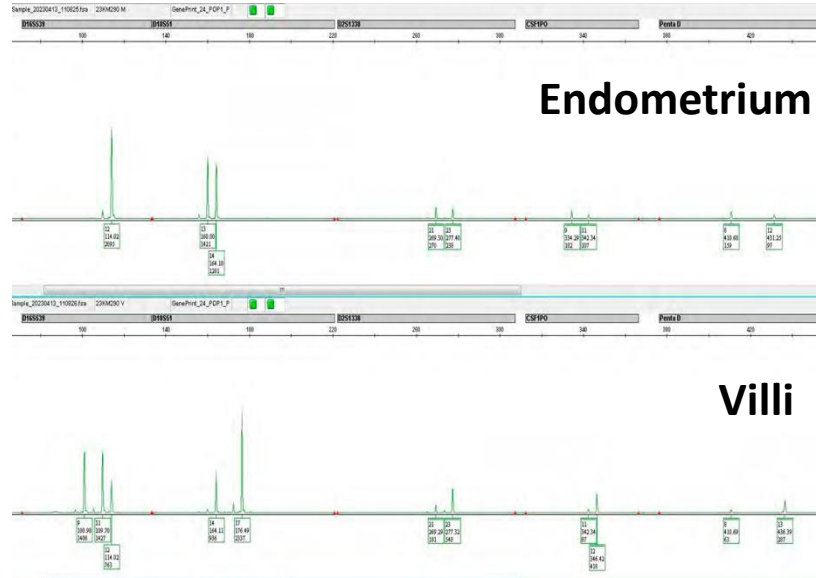

Y-GTD Case of November 2023

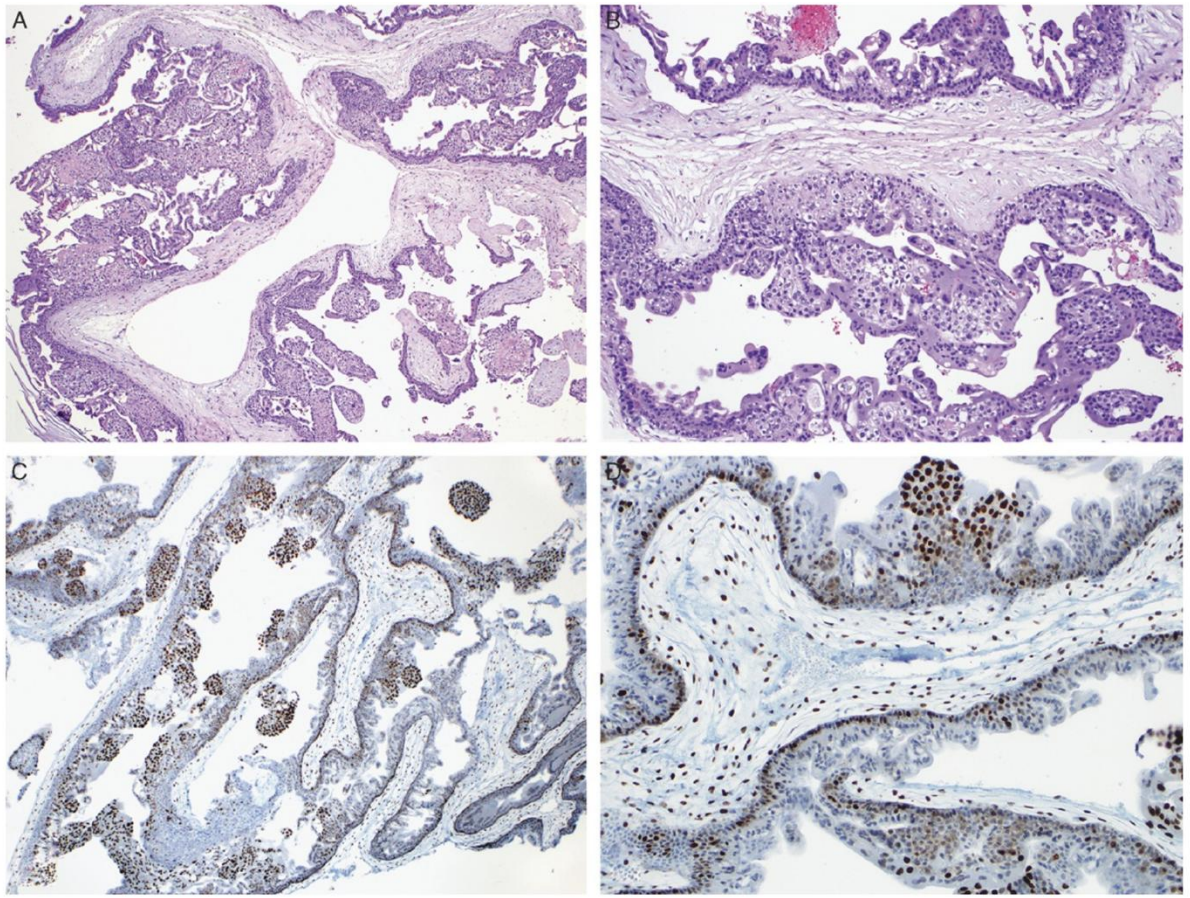

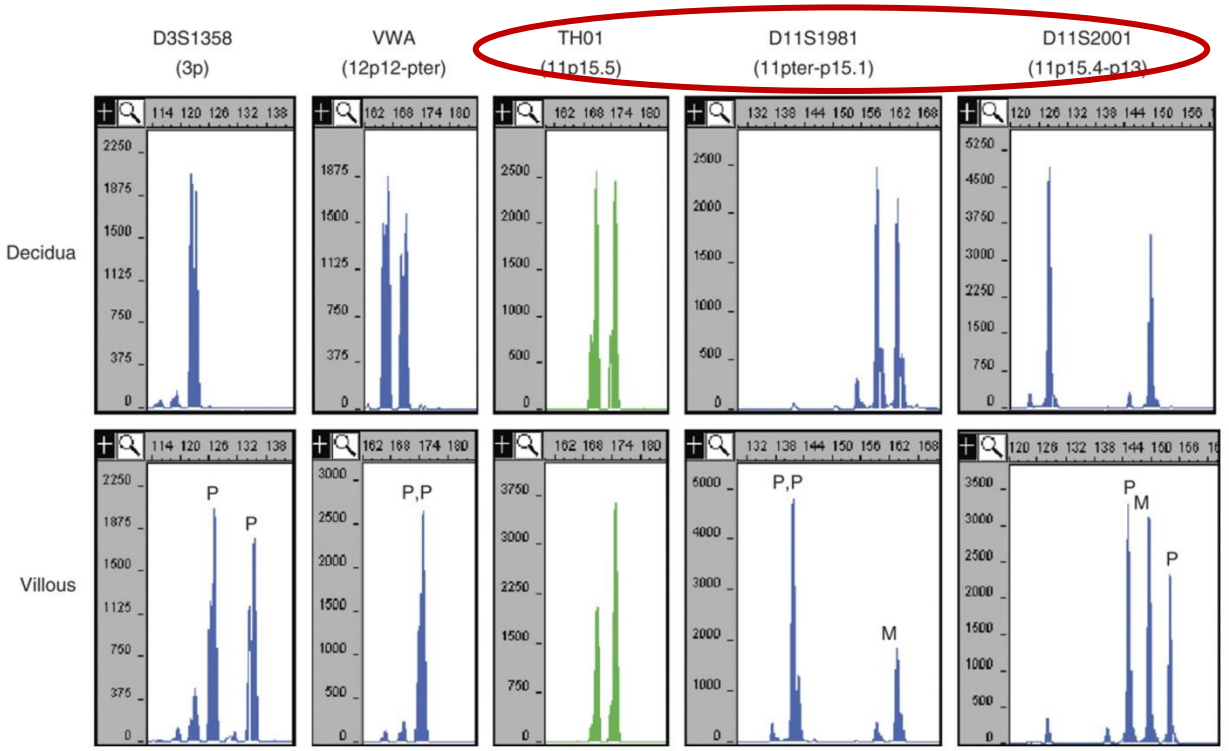

STR data. Capillary electrophoresis data for 5 STR loci (x-axis=size in bases; y-axis=fluorescence intensity). When known, the origin of the alleles in the villous tissue [maternal (M) or paternal (P)] is identified. Loci D3S1358 and vWA, located on chromosomes 3 and 12, respectively, are consistent with androgenetic diploidy. Loci THO1, D11S1981, and D11S2001, which are all located on chromosome 11, are consistent with trisomy 11 with 2 paternal and 1 maternal copies of chromosome 11. D3S1358, vWA and THO1 are part of the profiler mutiplex STRs. The additional chromosome 11 STRs were run as monoplex reactions. STR indicates short tandem repeat.

Contradictory P57 in CHM

Complete Hydatidiform Mole With Retained Maternal Chromosomes 6 and 11

Thomas G. McConnell, MD, Alexis Norris-Kirby, BS,* Jill M. Hagenkord, MD,† Brigitte M. Ronnett, MD,*‡ and Kathleen M. Murphy, PhD**

(*Am J Surg Pathol* 2009;33:1409–1415)



Negative P57 = CHM?

Katherine Grondin, MD
5-21-2025 from Quebec City, Canada

Contradictory loss of P57 in PHM

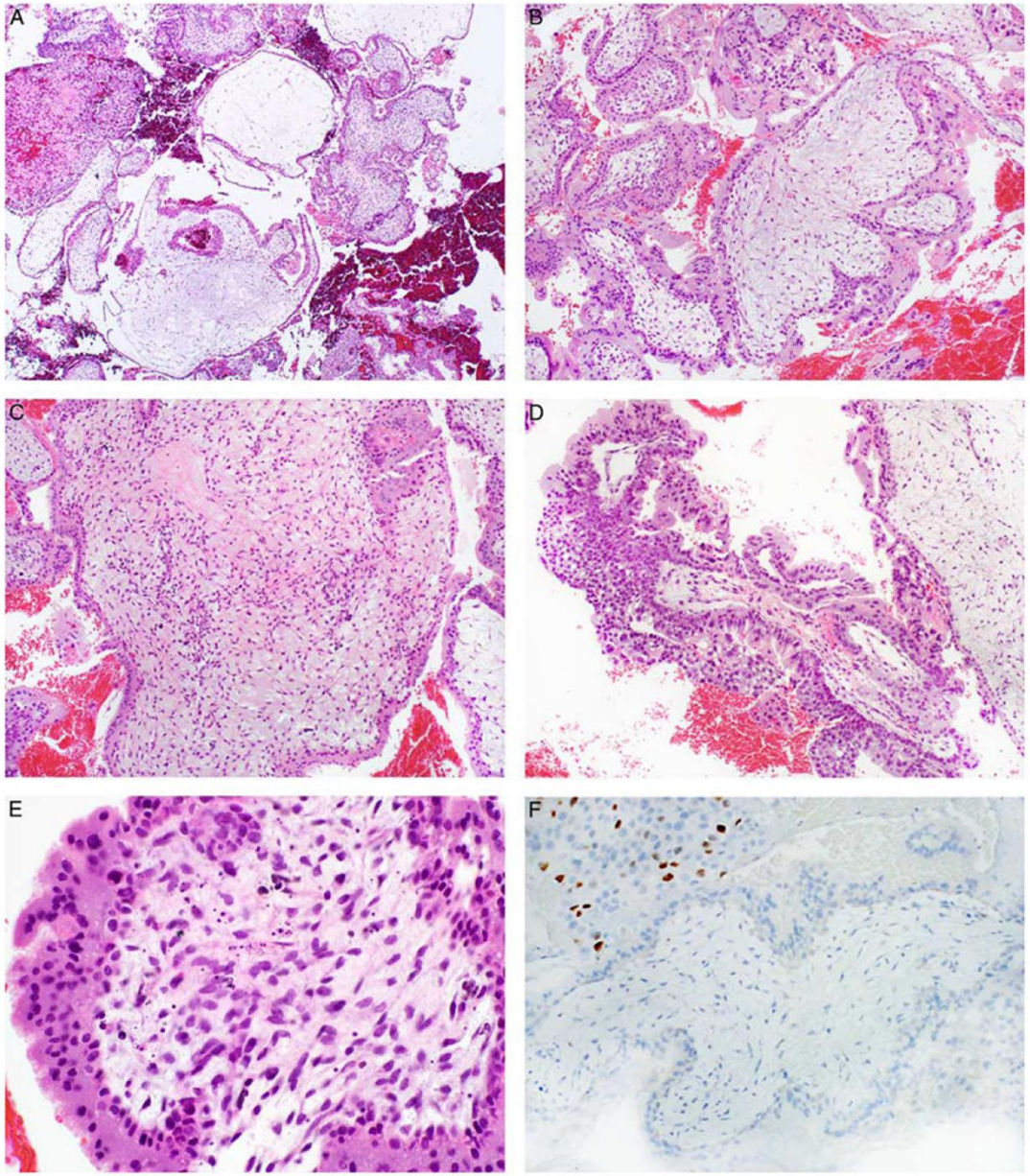

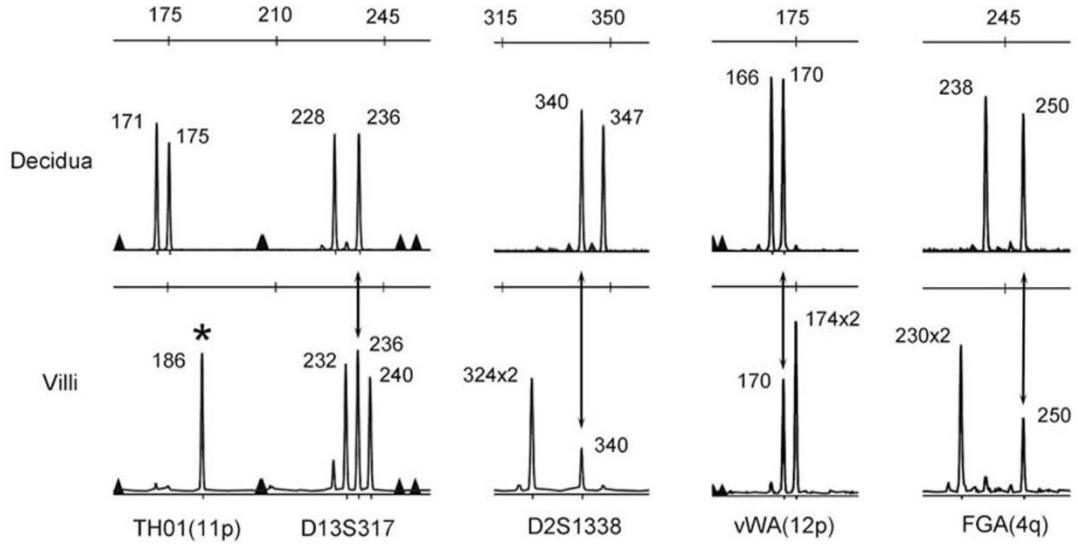

› Am J Surg Pathol. 2022 Jan 1;46(1):18-32. doi: 10.1097/PAS.0000000000001749.

Loss of p57 Expression in Conceptions Other Than Complete Hydatidiform Mole: A Case Series With Emphasis on the Etiology, Genetics, and Clinical Significance

Deyin Xing [1 2 3], Karin Miller [1], Katie Beierl [1], Brigitte M Ronnett [1 2]

Case Reports › Am J Surg Pathol. 2011 Oct;35(10):1586-91.
doi: 10.1097/PAS.0b013e31822d5cff.

Diandric triploid hydatidiform mole with loss of maternal chromosome 11

Cheryl DeScipio [1], Lisa Haley, Katie Beierl, Ashwini P Pandit, Kathleen M Murphy, Brigitte M Ronnett

Contradictory Loss of P57 in Paternal UPD11

Modern Pathology (2019) 32:1180–1188
https://doi.org/10.1038/s41379-019-0266-0

ARTICLE

Paternal uniparental isodisomy of tyrosine hydroxylase locus at chromosome 11p15.4: spectrum of phenotypical presentations simulating hydatidiform moles

Natalia Buza[1] · Stephanie M. McGregor[2] · Lisa Barroilhet[3] · Xingzheng Zheng[4] · Pei Hui[1]

Paternal UPD 11 (THO1 locus)

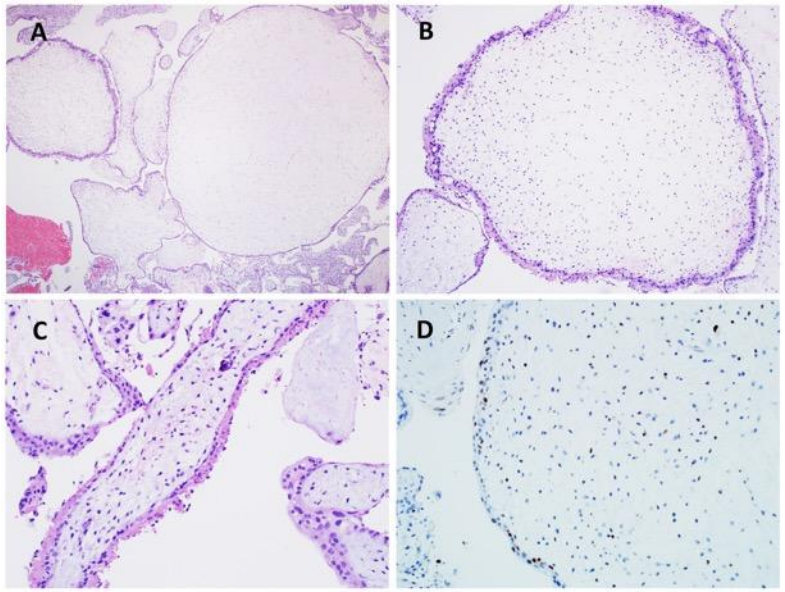

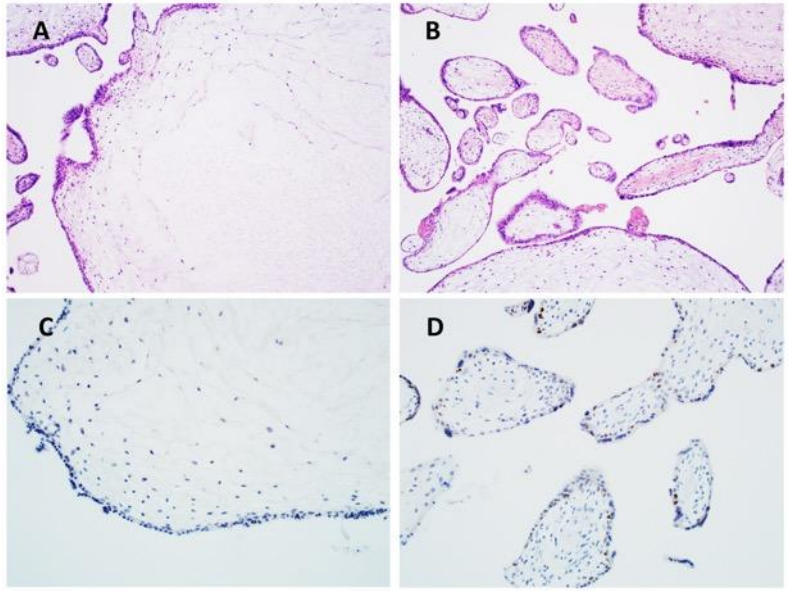

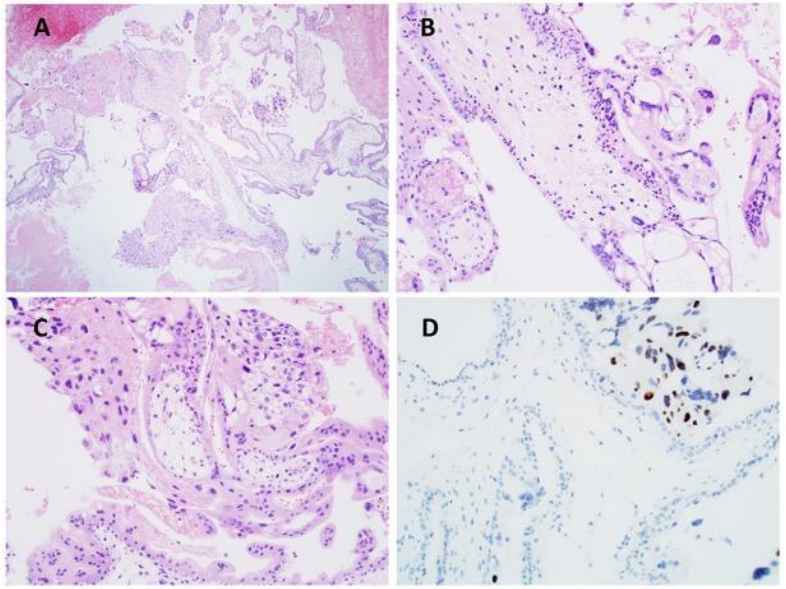

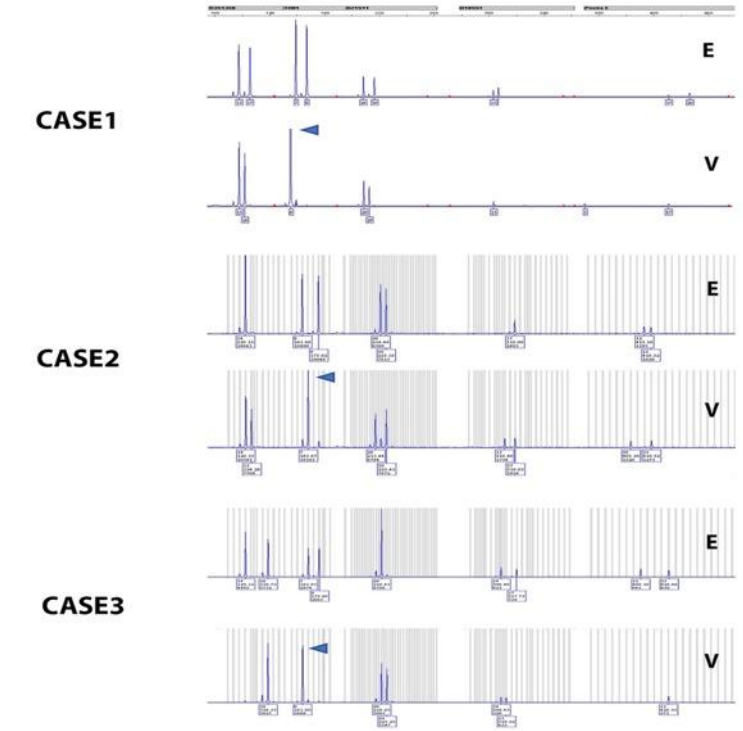

Paternal UPD 11 (THO1 Locus)

- Clinical GTN
- Chemotherapy

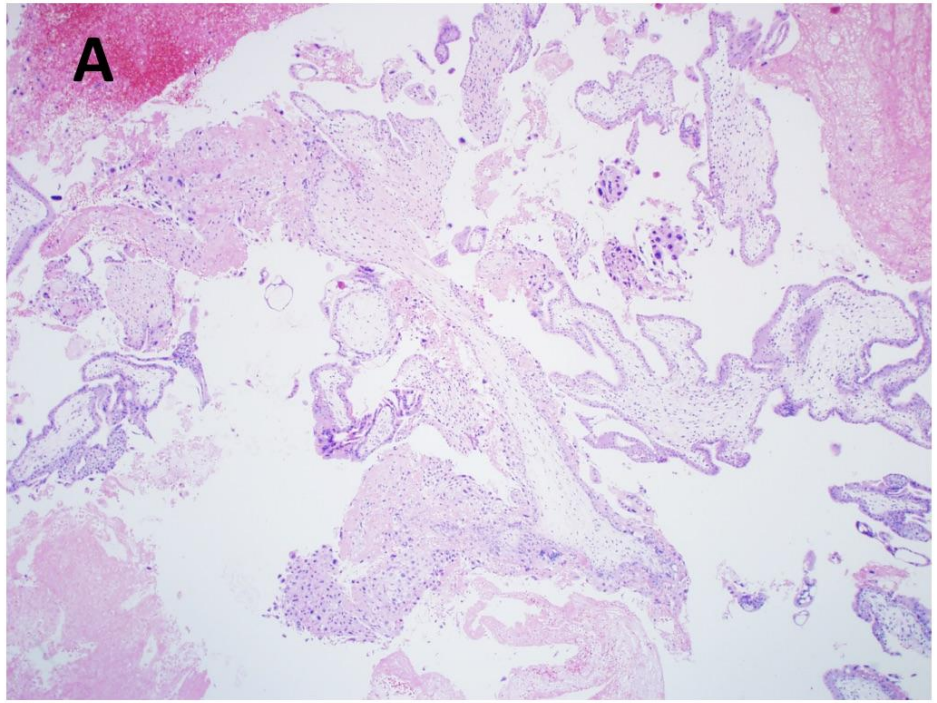

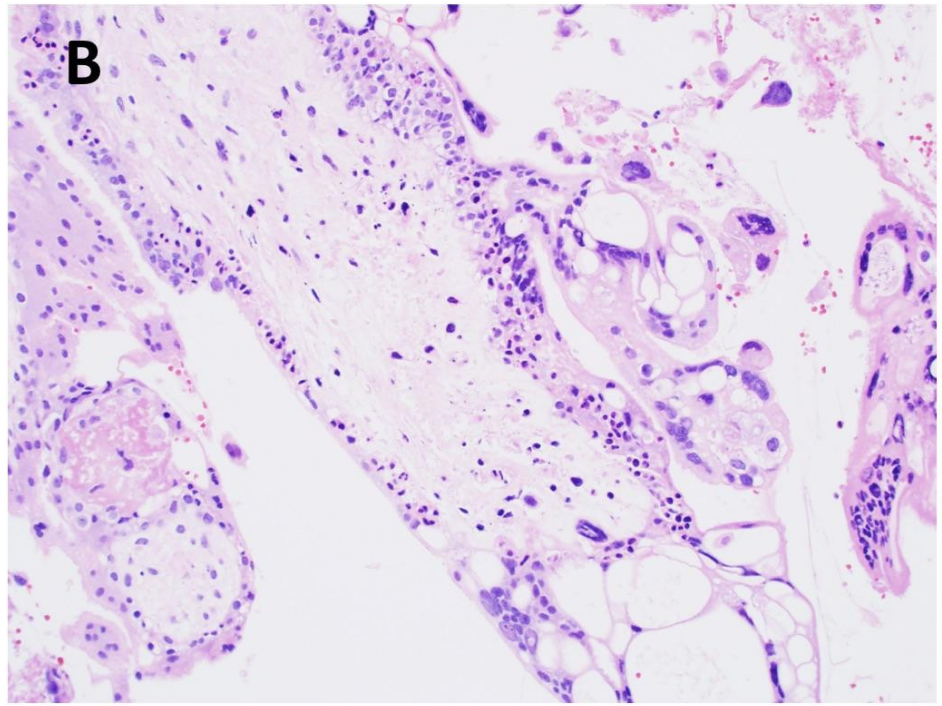

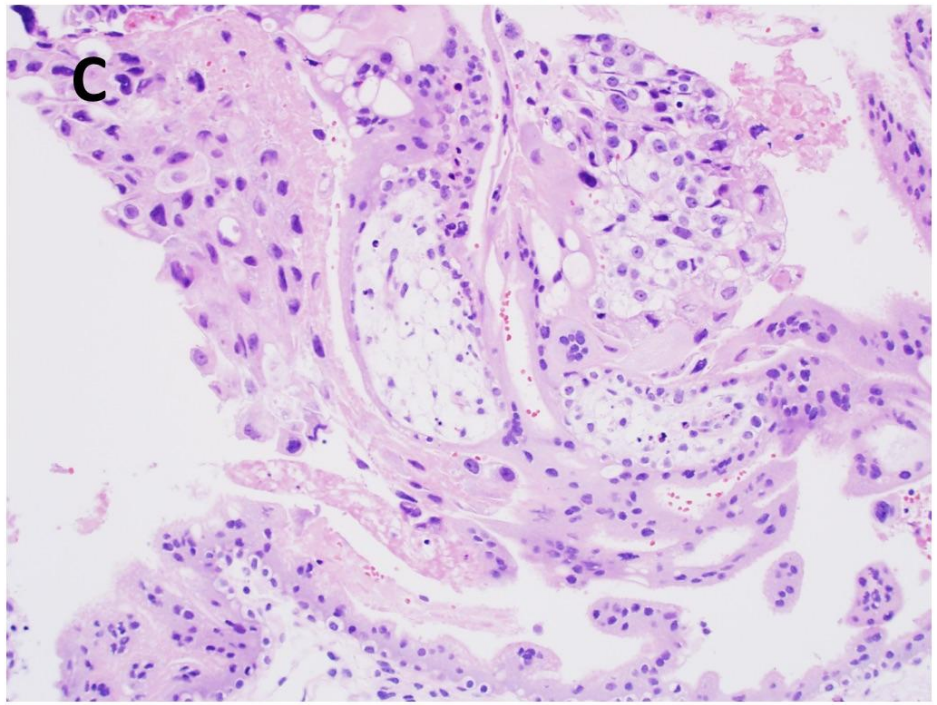

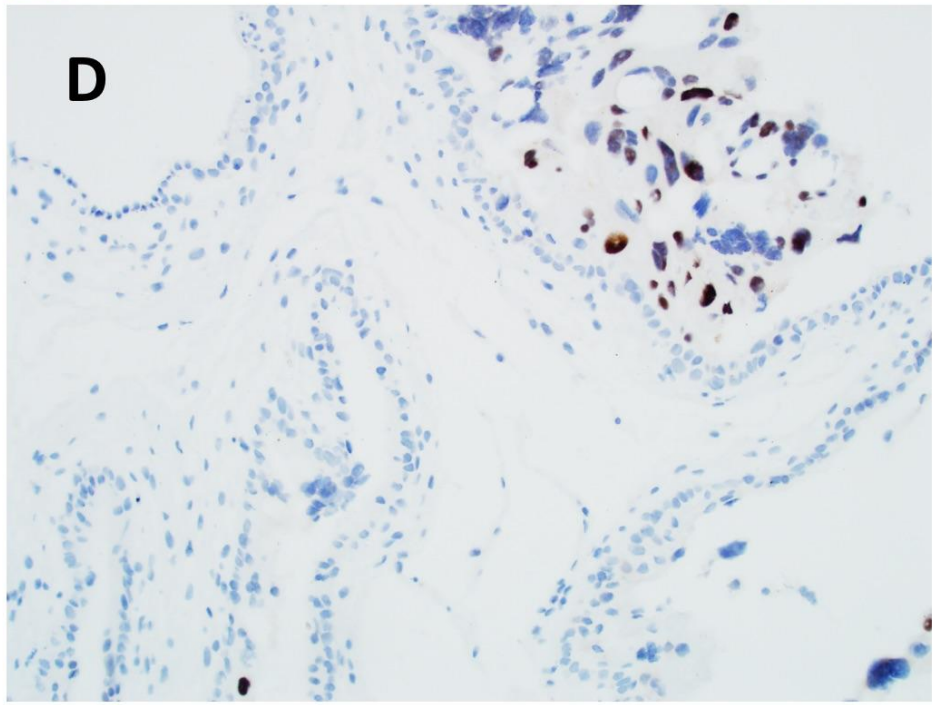

Modern Pathology
https://doi.org/10.1038/s41379-019-0266-0

USCAP

ARTICLE

Paternal uniparental isodisomy of tyrosine hydroxylase locus at chromosome 11p15.4: spectrum of phenotypical presentations simulating hydatidiform moles

Natalia Buza[1] · Stephanie M. McGregor[2] · Lisa Barroilhet[3] · Xingzheng Zheng[4] · Pei Hui[1]

Received: 5 January 2019 / Revised: 10 February 2019 / Accepted: 27 February 2019

Discordant & contradictory P57

VECHM P57+

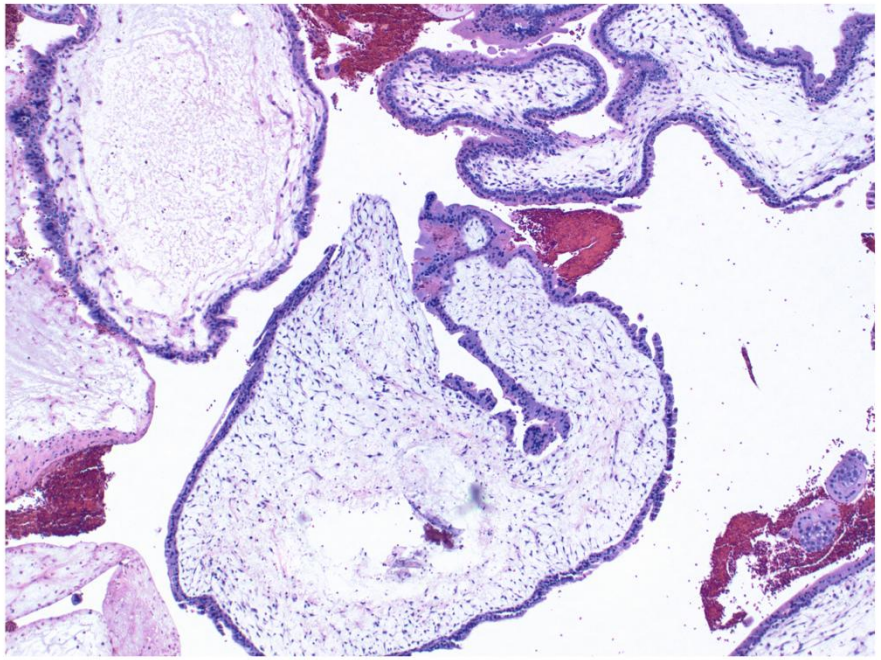

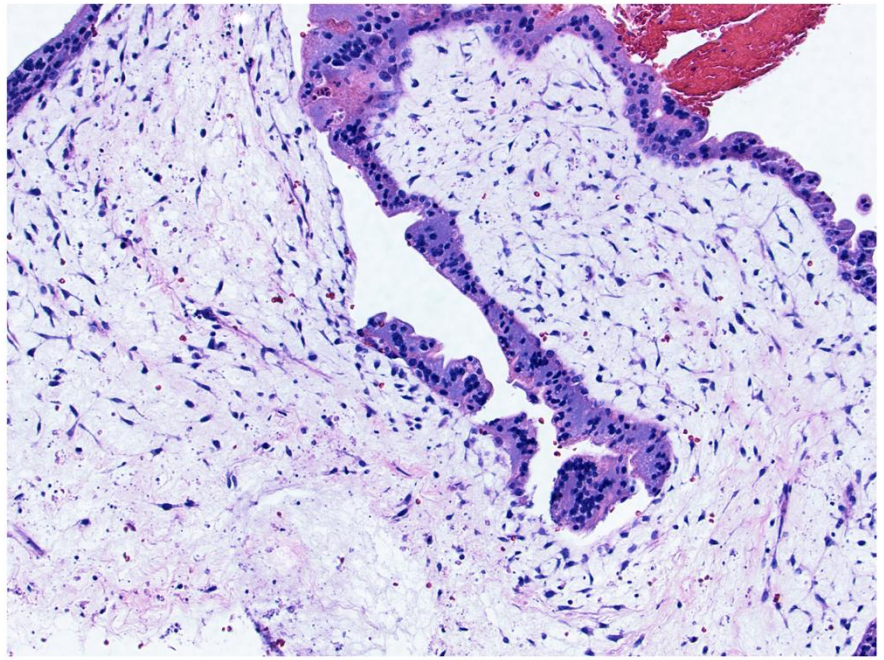

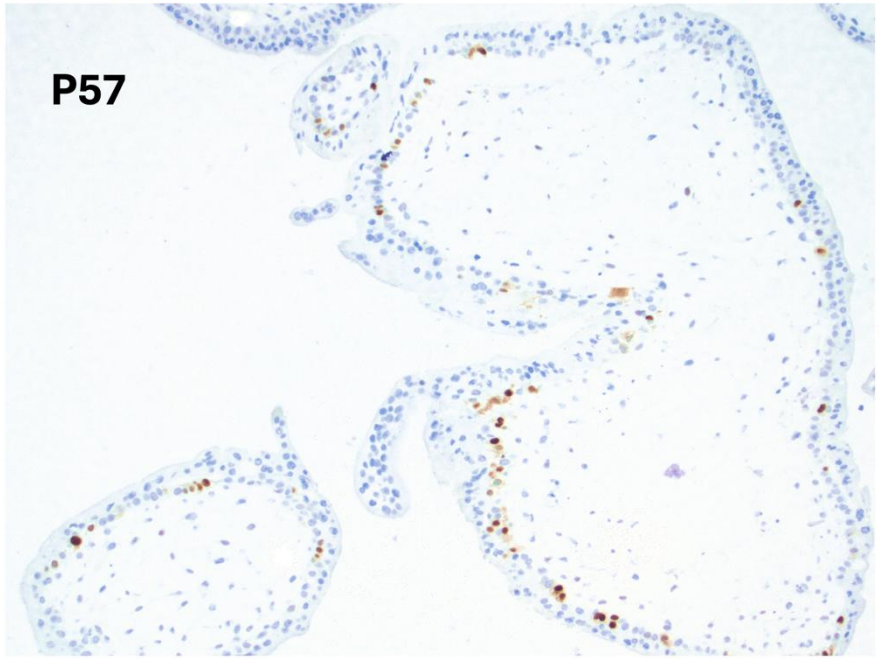

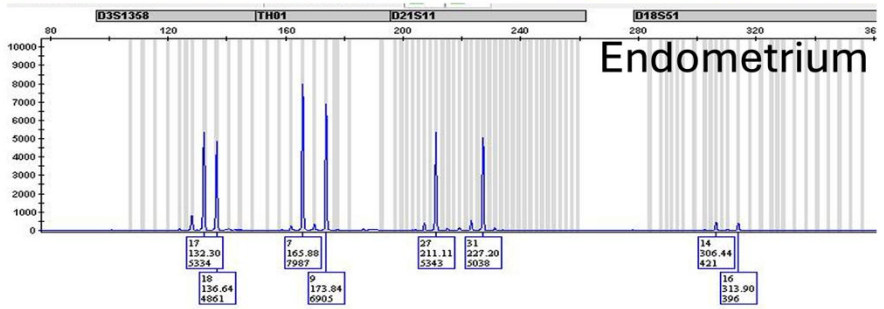

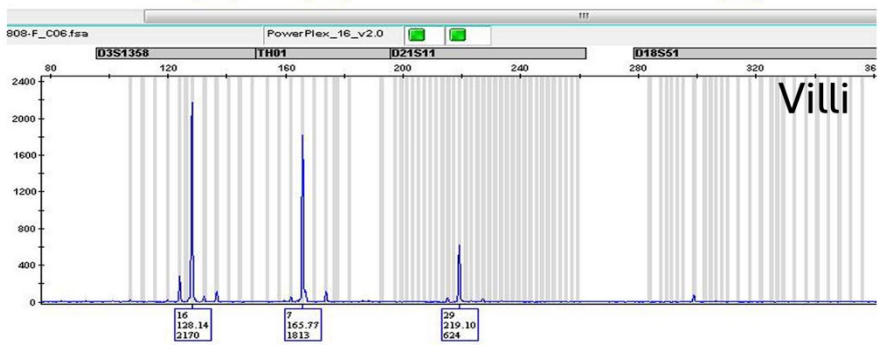

Hydatidiform moles - Differential diagnoses

- PHM: Partial mole
- VECHM: Very early complete mole
- AVM: Abnormal villous morphology
- HA: Hydropic (non-molar) abortion
- EG: Early (non-molar) gestation

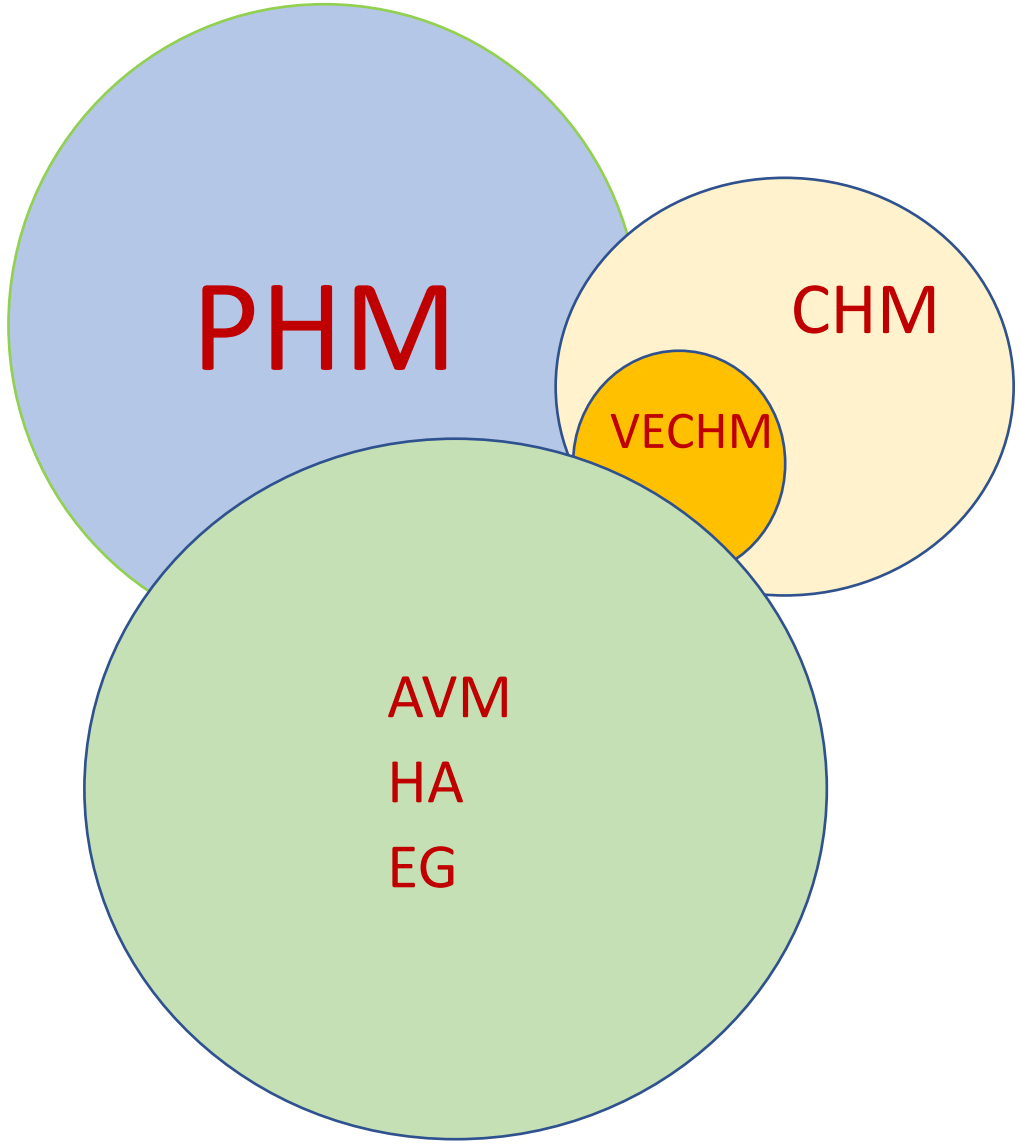

Early Gestation secondary villi mimicking VECHM

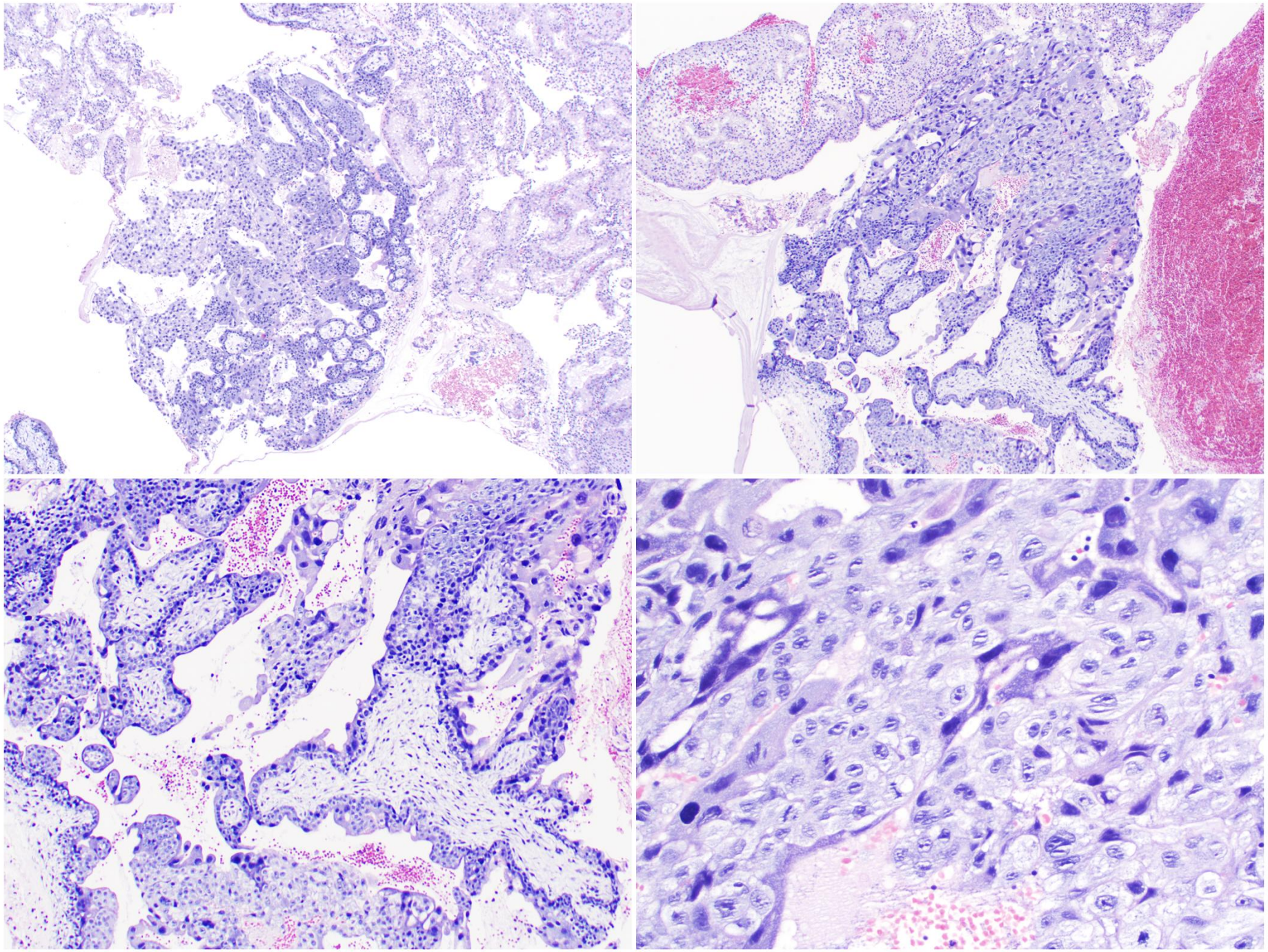

PHM mimicking VECHM

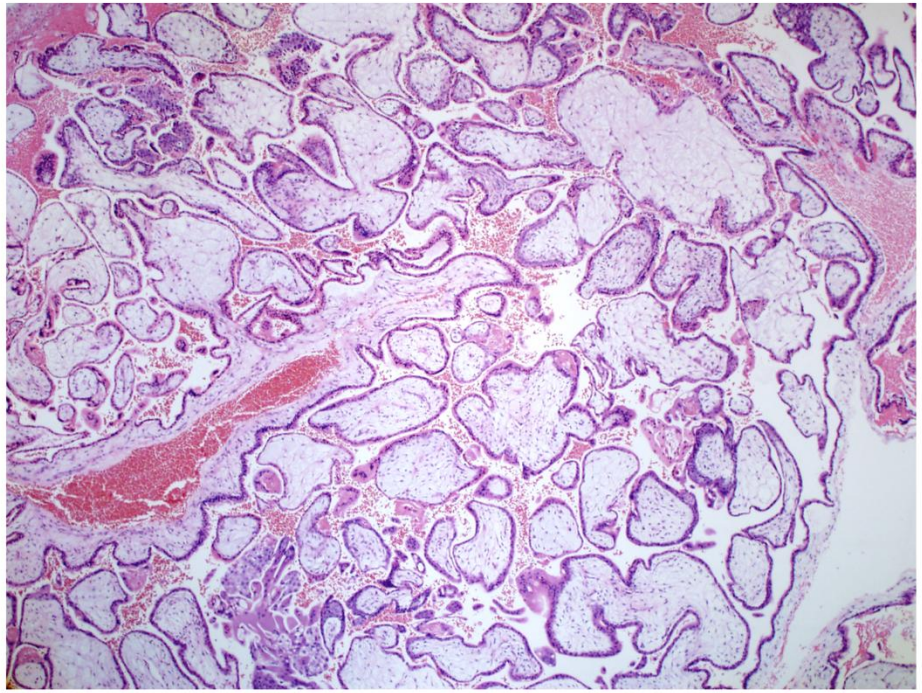

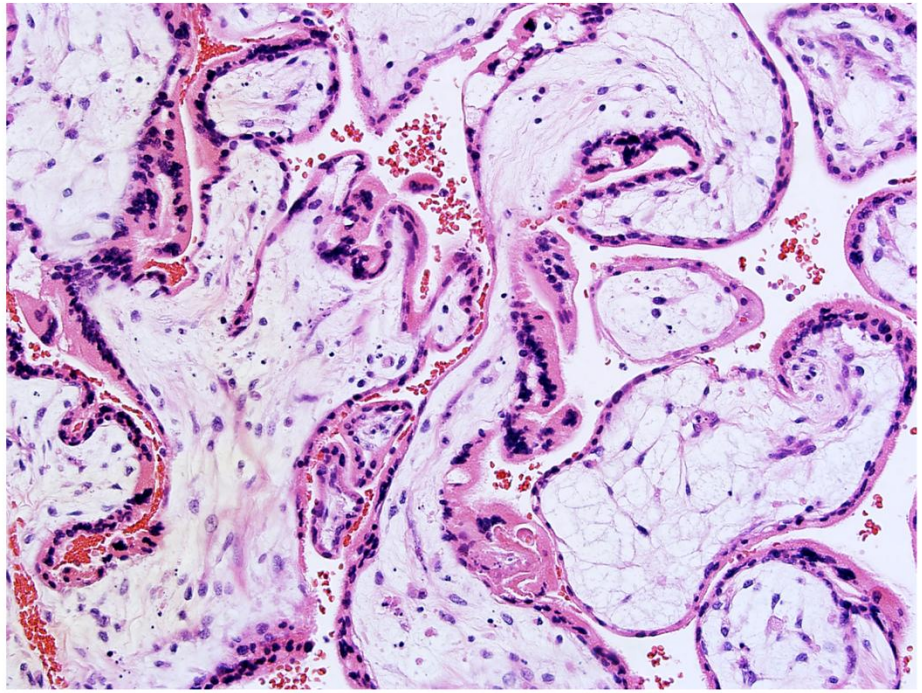

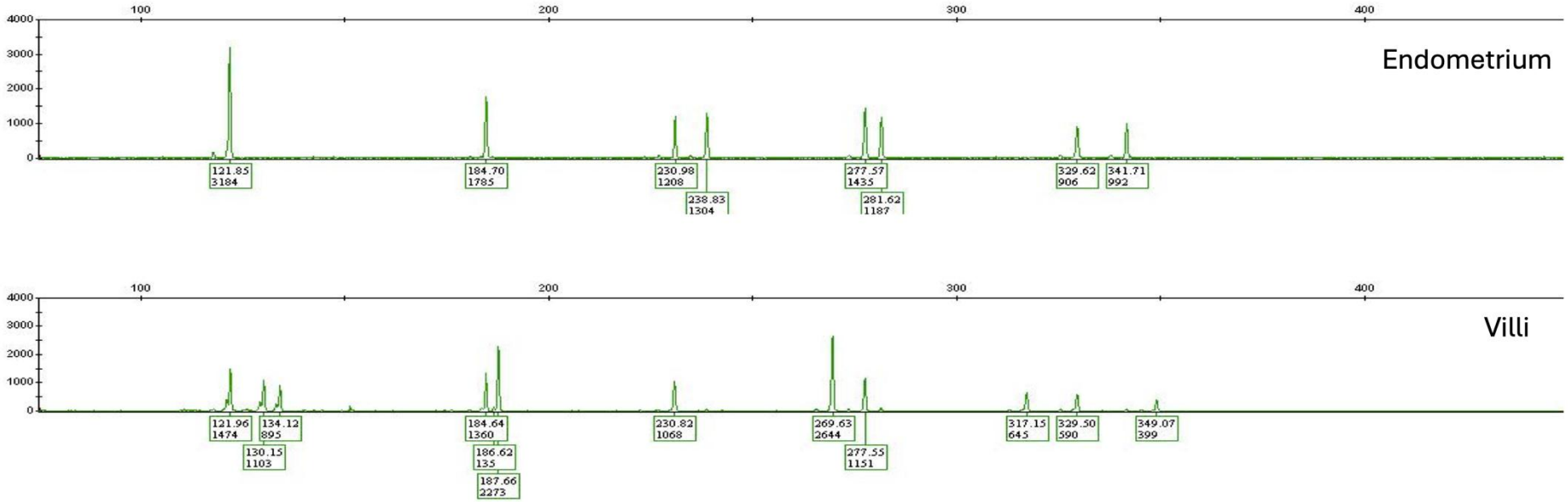

PHM mimicking VECHM

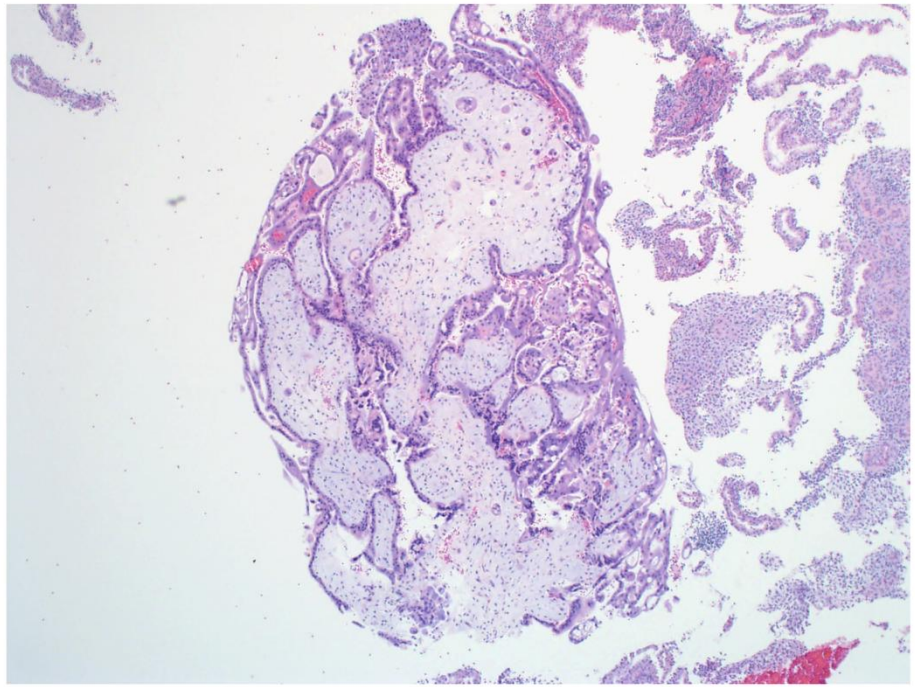

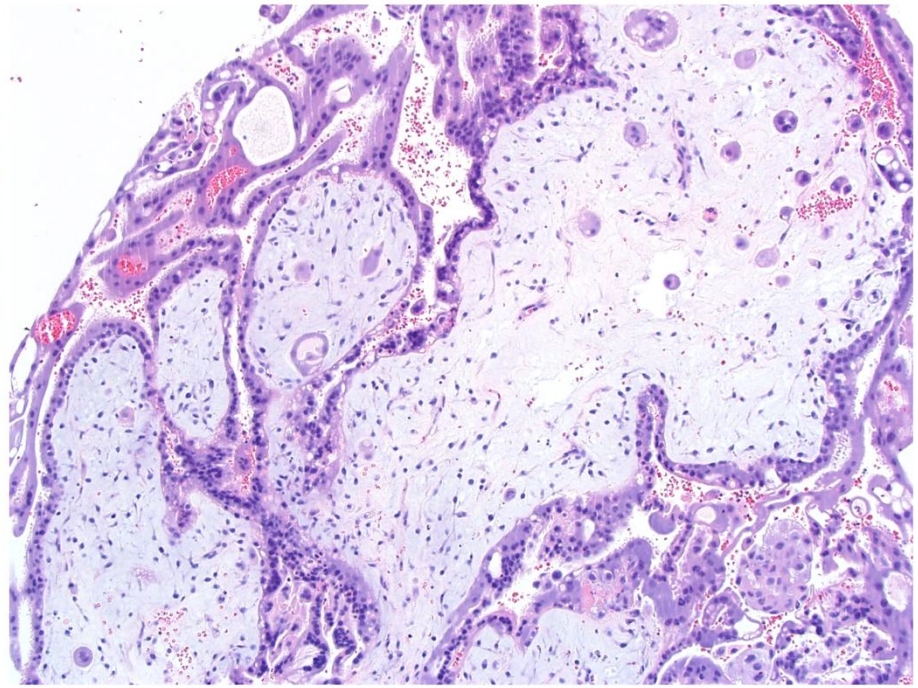

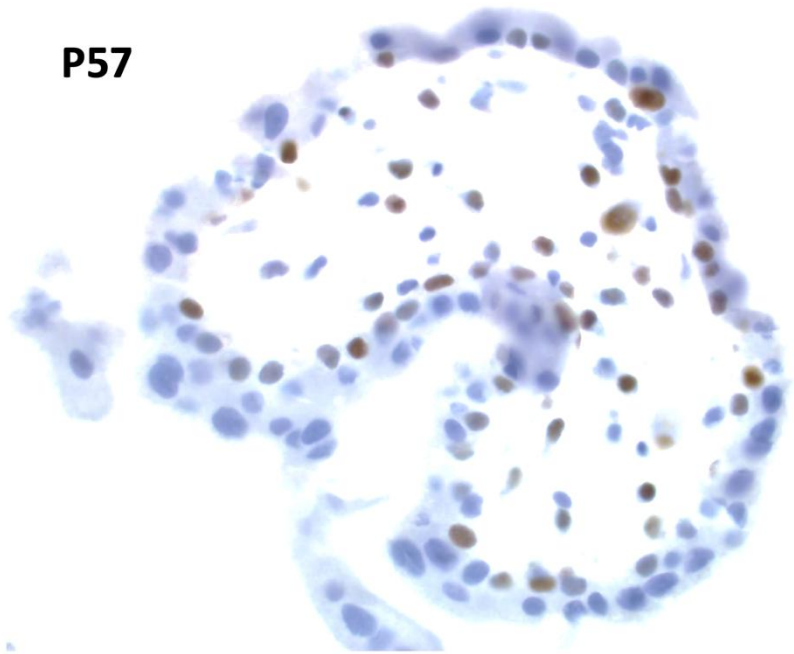

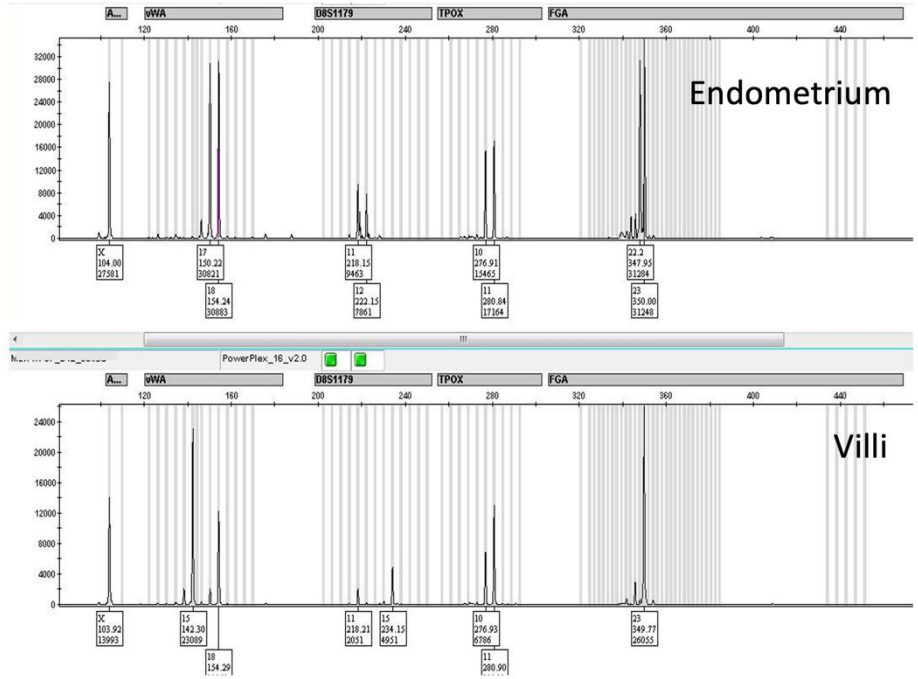

Tubal gestation mimicking VECHM

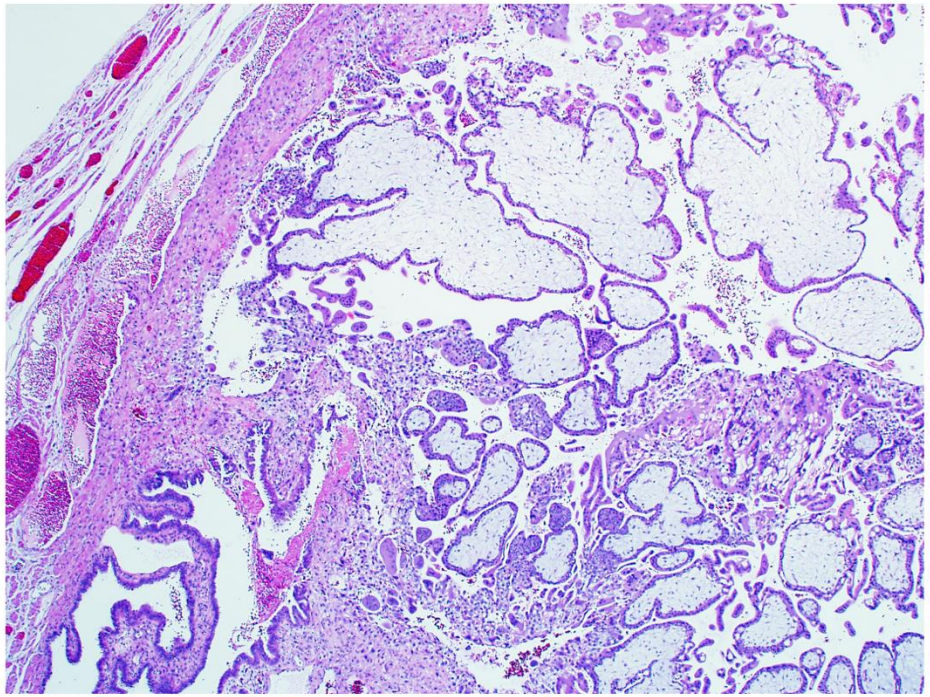

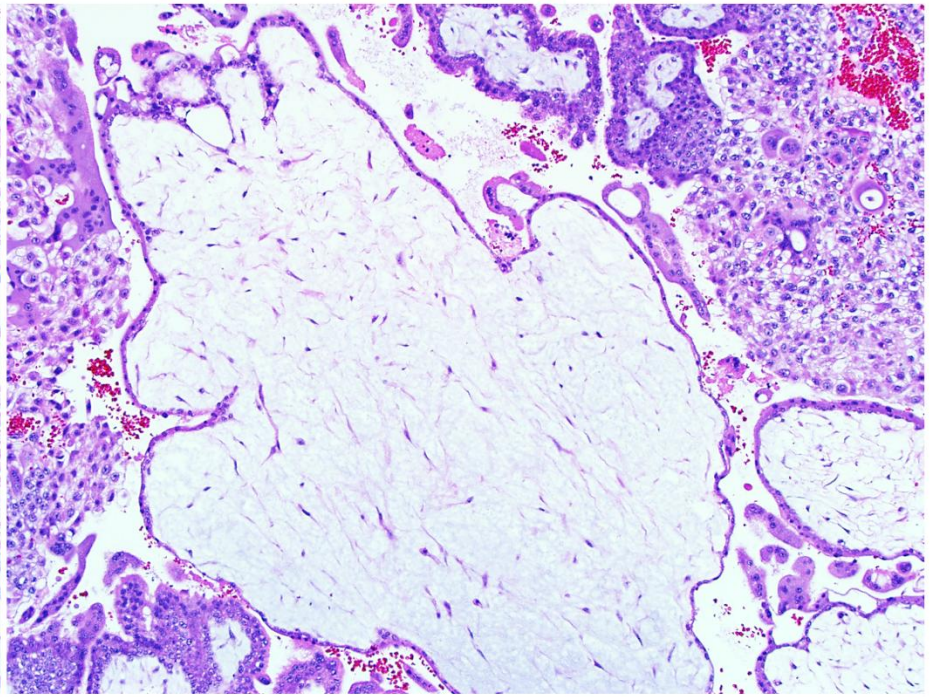

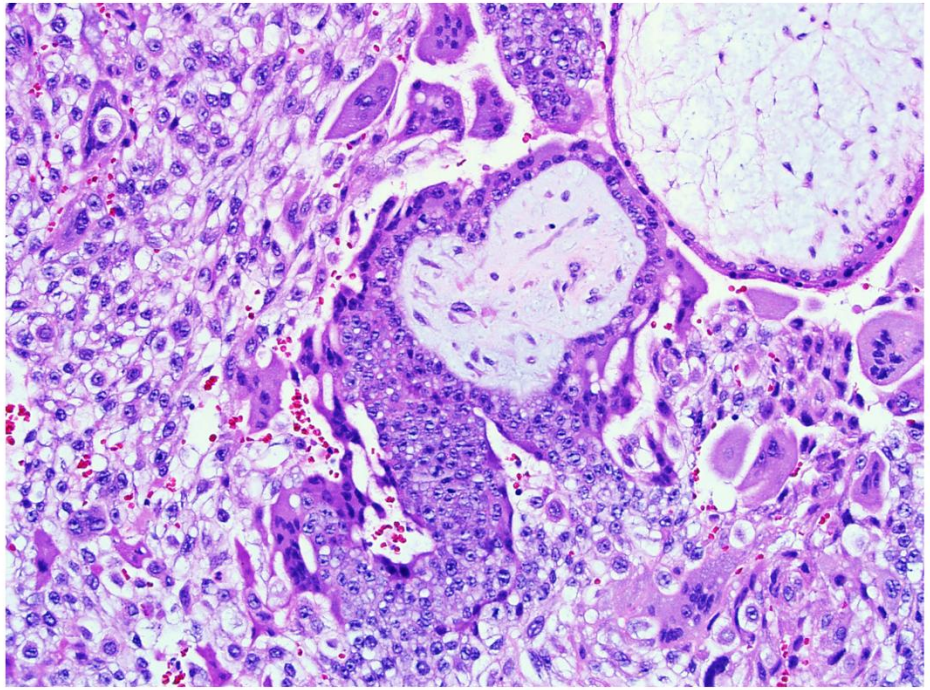



VECHM of Tubal Gestation

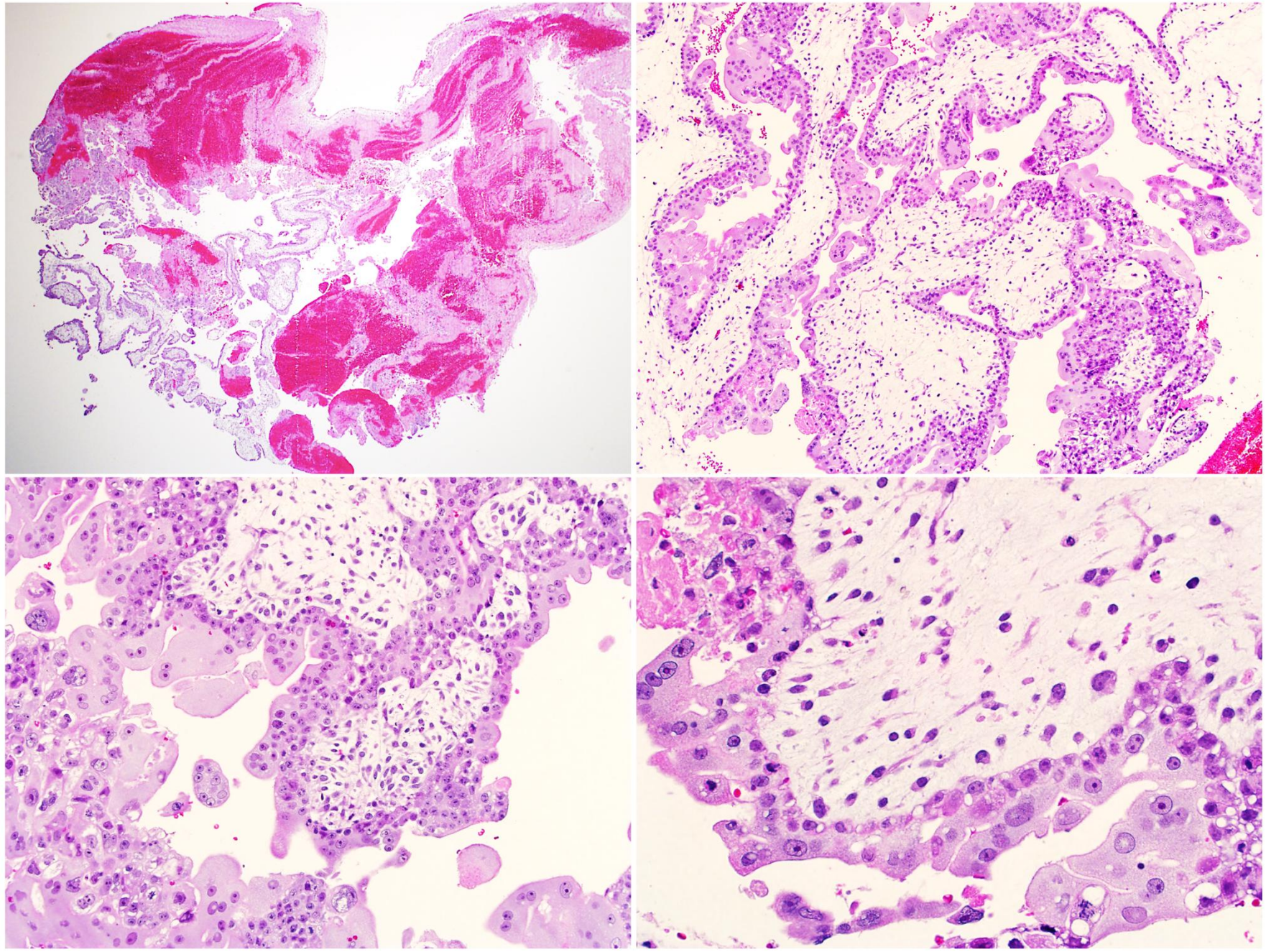

STR Genotyping – Gold Standard

Comparison of allelic patterns between maternal decidua and villous tissue

Provides information about the exact parental genetic contribution

Sporadic CHM – Genetic Basis

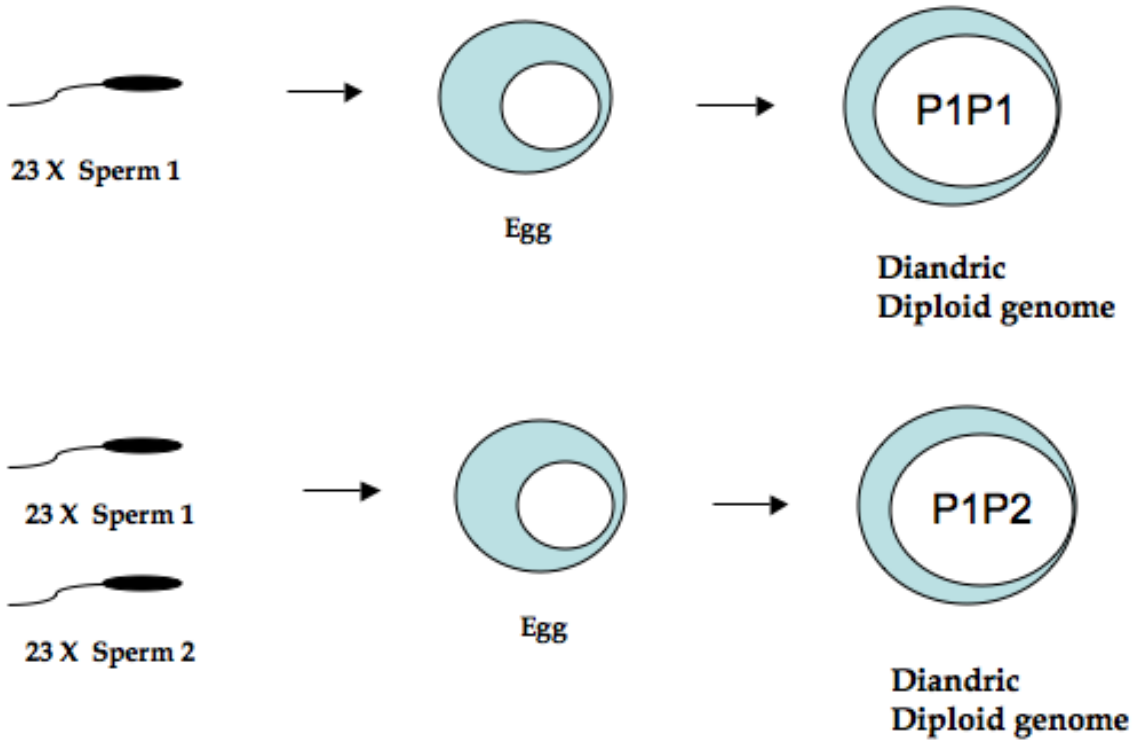

Monospermic
(Homozygous) – 90%

Dispermic
(Heterozygous) – 10%

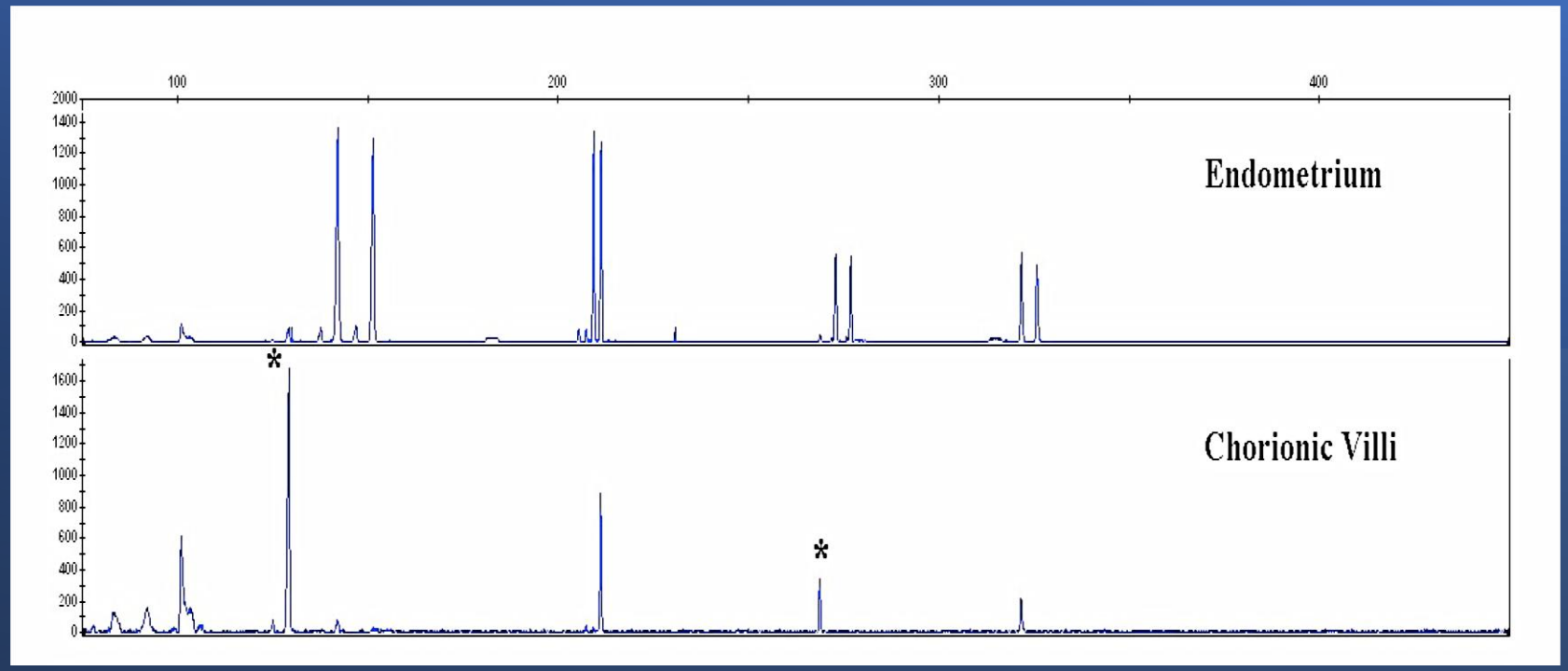

Monospermic (Homozygous) CHM

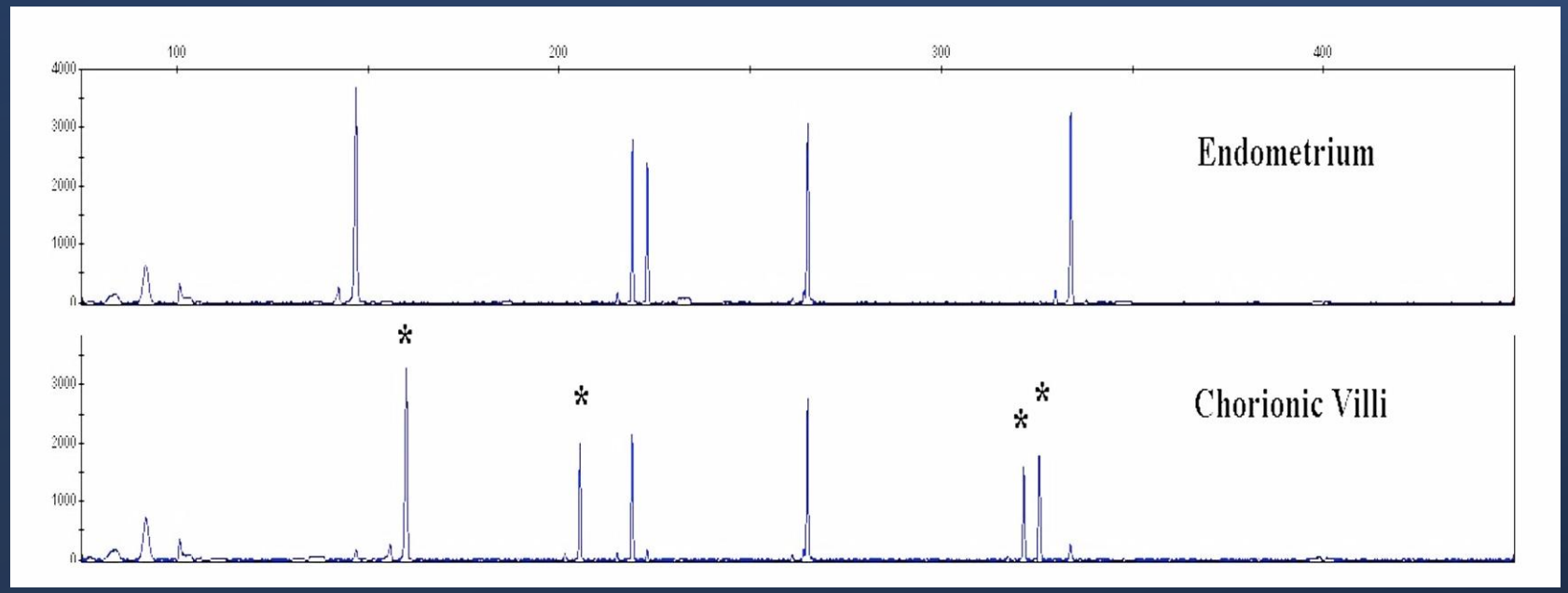

Dispermic (Heterozygous) CHM

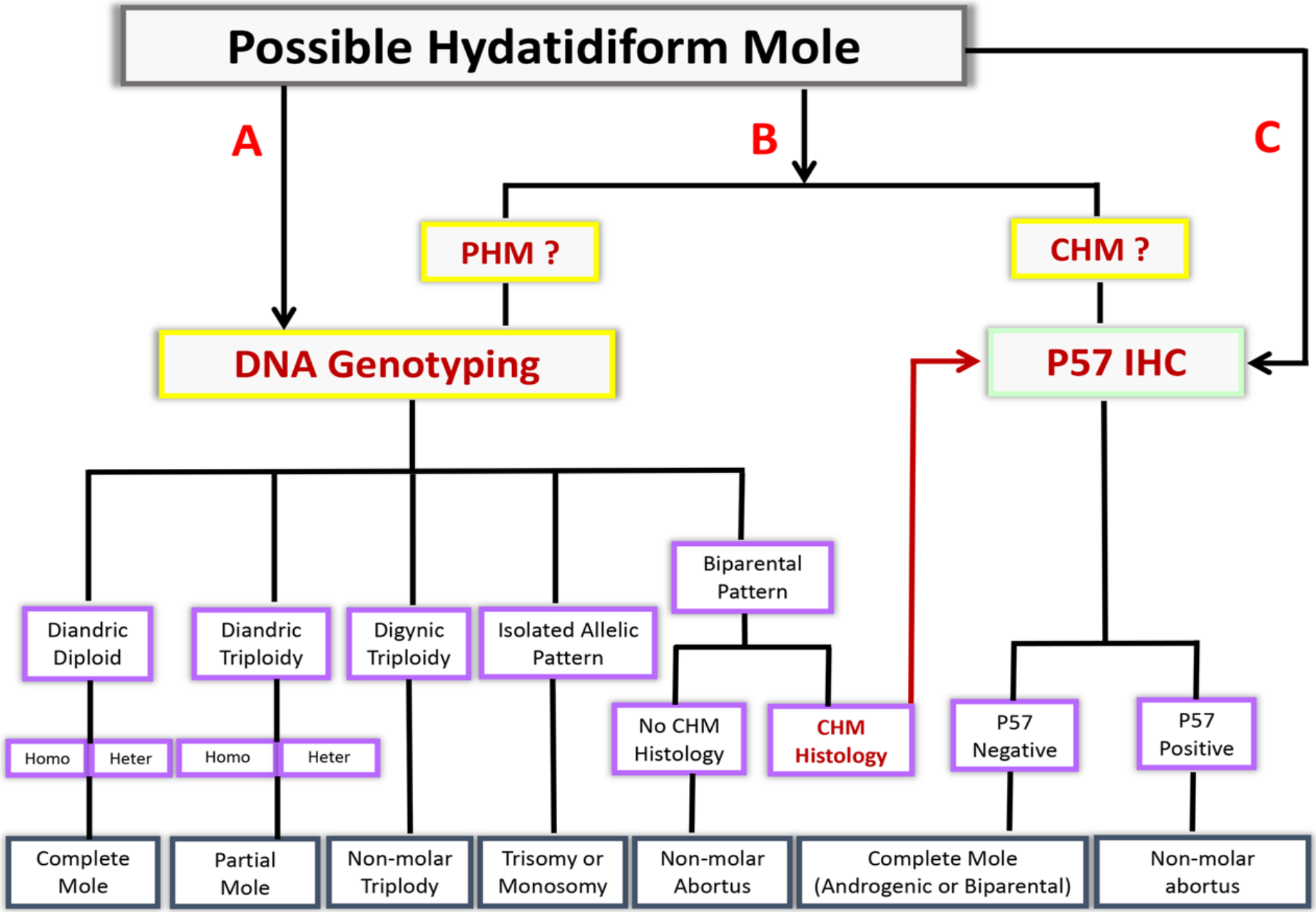

Buza and Hui, Mod Pathology, 2021,34:1658-1672

Special Diagnostic Considerations

34-year-old presented with missed abortion

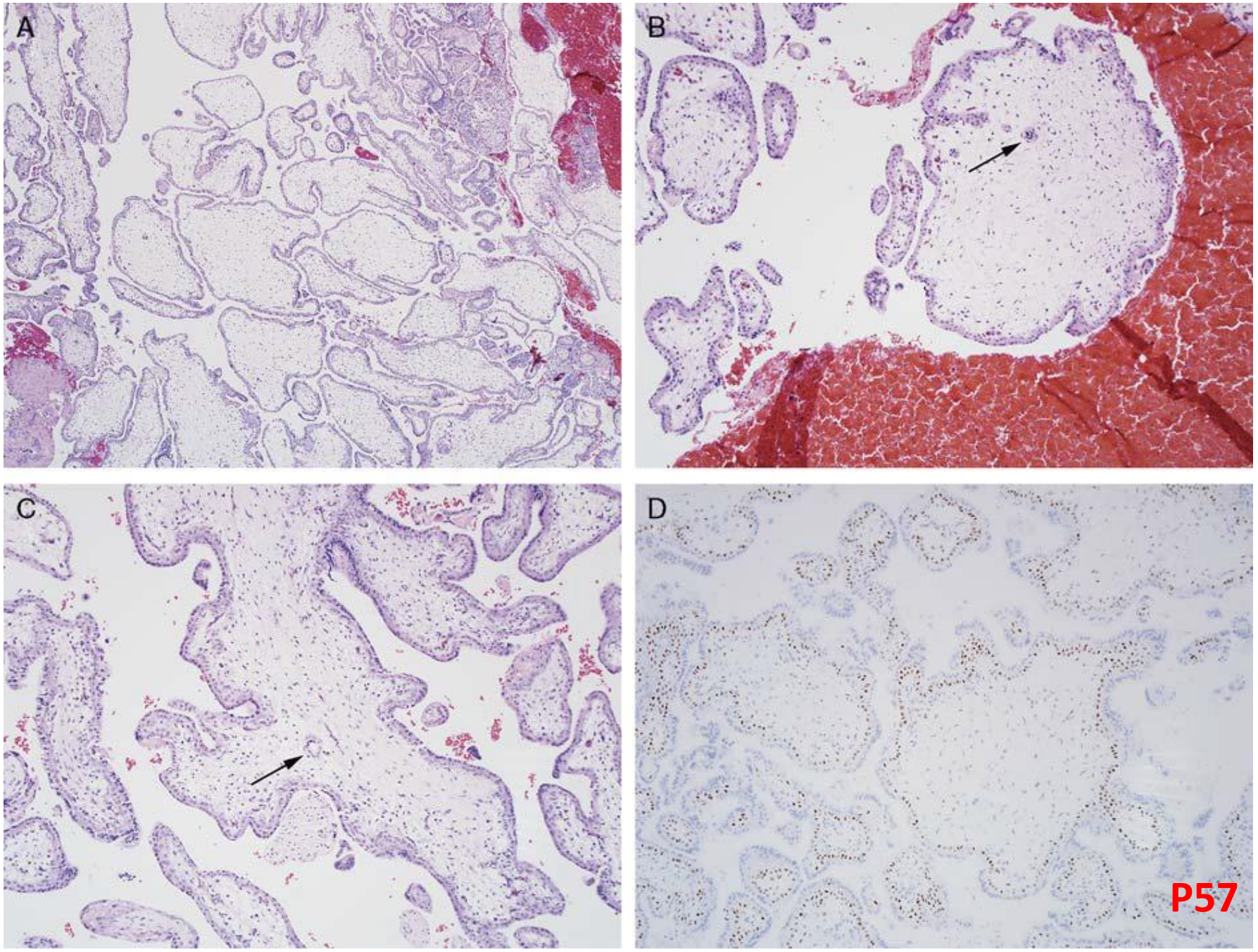

Dispermic/heterozygous Complete Mole ?

Contradictory P57 Expression

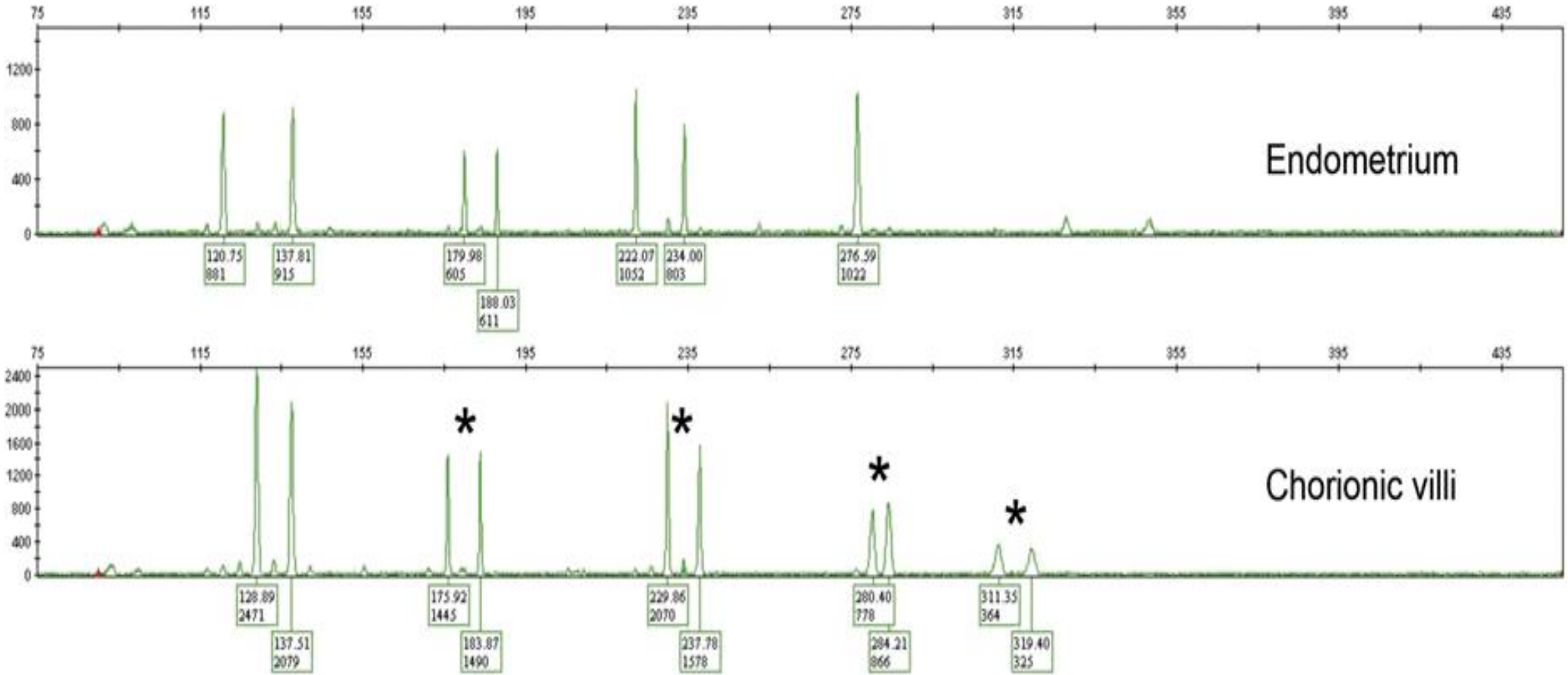

Egg Donor Pregnancy (Pseudo-Molecular Dispermic CHM)

GTN in Heterozygous Complete Mole

Table IV Follow-up studies of androgenic moles.

References	Methods	Type	Total cases	Persistent GTD	(%)	P^a
Our study	STR polymorphism (16 loci on 14 chromosomes)	Homozygous	24	6	25%	0.029
		Heterozygous	3	3	100%	
Wake *et al.* (1987)	Q-band polymorphism	Homozygous	51	7	14%	0.049
	HLA	Heterozygous	9	4	44%	
	PGM1 polymorphism	Unknown zygosity	24	4	17%	
Lawler and Fisher. (1987)	Q-band polymorphism	Homozygous	73	13	18%	0.458
	PGM1, ACP, GLO	Heterozygous	8	2	25%	
	Esterase D	No informative marker	37	7	19%	
Cho and Kim (1993)	RFLP	Homozygous	17	5	29%	0.543
		Heterozygous	2	1	50%	
Cheung *et al.* (1994)	CISH	XX mole	97	23	24%	0.451
		XY mole	6	2	33%	
Niemann *et al.* (2007)	STR polymorphism (10 loci on 4 chromosomes)	Homozygous	126	22	17%	0.373
		Heterozygous	17	4	24%	

GTD, gestational trophoblastic disease; PGM1, phosphoglucuromutase I; ACP, acid phosphatase-I; GLO, glyoxylase; RFLP, restriction fragment length polymorphisms; CISH, chromosome *in situ* hybridization, STR, short tandem repeat.
[a]Based on Fisher's exact probability.

Hum Reprod. 2010 May;25(5):1183-91. doi: 10.1093/humrep/deq052. Epub 2010 Mar 5.

The risk of post-molar gestational trophoblastic neoplasia is higher in heterozygous than in homozygous complete hydatidiform moles.

Baasanjav B[1], Usui H, Kihara M, Kaku H, Nakada E, Tate S, Mitsuhashi A, Matsui H, Shozu M.

› Mod Pathol. 2020 Oct;33(10):1979-1988. doi: 10.1038/s41379-020-0566-4.
Epub 2020 May 13.

Heterozygous/dispermic complete mole confers a significantly higher risk for post-molar gestational trophoblastic disease

Xing-Zheng Zheng [1], Xu-Ying Qin [2], Su-Wen Chen [3], Peng Wang [2], Yang Zhan [1], Ping-Ping Zhong [1], Natalia Buza [4], Yu-Lan Jin [1], Bing-Quan Wu [5], Pei Hui [6]

Table 3. Post-molar Gestational Trophoblastic Disease

Gestational Type	Informative Follow-up	Post-molar GTD	% Post-molar GTD
Homozygous CHM	138	16	11.6##
Heterozygous CHM@@	27	10	37.0##
Triploid Homozygous PHM	2	0	0
Triploid Heterozygous PHM**	214	0	0
Tetraploid Heterozygous PHM	2	0	0
Non-molar Gestation	367	0	0
Total	750	26	3.5%

CHM: complete hydatidiform mole; PHM: partial hydatidiform mole; GTD: post-molar gestational trophoblastic disease

@@: including 2 cases of diploid heterozygous CHM with trisomy 3 or trisomy 8.
**: including 2 cases of triploid heterozygous PHM with tetrasomy 8.
##: Statistically significant difference between the two groups (p = 0.0009)

Table 2 Clinicopathological data of patients with successful follow-up ($N = 750$).

Gestational type			# Cases	Patient age in years (range/average/median)	Gestational weeks (range/average/median)	Serum hCG (mIU/ml) at evacuation (range/average/median)
Hydatidiform Moles	CHM	Combined	165	19–50/31.2/30	6–14/8.2/8	5,006–1,240,000/129,954/103,266
		Homozygous CHM	138	19–50/31.6/30	6–12/8.2/8	5,006–862,307/119,246/101,217
		Heterozygous CHM	27	19–40/29.3/29	6–14/8.3/8	7,938–1,240,000/183,100/105,277
	PHM		218	19–48/31.2/31	6–14/9.6/9	4,298–510,000/80,754/58,459
Non-molar gestations	Diploid HA		305	19–45/31.9/31	6–15/8.9/9	1,091–200,000 /45,422/30,624
	Trisomies		54	25–44/32.8/33	7–13/9.1/9	2,476–10,4209 /29,490/20,518
	Other genotypes		8	28–39/32.1/30	6–9/7.3/7	13,013–52,692/32,976/37,359

CHM complete hydatidiform mole, *PHM* partial hydatidiform mole, *HA* hydropic abortus, *hCG* human chorionic gonadotropin.

› Mod Pathol. 2020 May;33(5):880-892. doi: 10.1038/s41379-019-0432-4. Epub 2019 Dec 19.

Comprehensive analysis of 204 sporadic hydatidiform moles: revisiting risk factors and their correlations with the molar genotypes

Yassemine Khawajkie [1 2 3], Nawel Mechtouf [2 3], Ngoc Minh Phuong Nguyen [2 3], Kurosh Rahimi [4], Magali Breguet [5], Jocelyne Arseneau [6], Brigitte M Ronnett [7], Lori Hoffner [8], Felicia Lazure [2], Marjolaine Arnaud [2], Fabrice Peers [4], Liane Tan [9], Basam Abu Rafea [9], Monica Aguinaga [10], Neil S Horowitz [11 12], Asangla Ao [2 3], Seang Lin Tan [13], Richard Brown [3], William Buckett [3], Urvashi Surti [8], Karine Hovanes [14], Trilochan Sahoo [14], Philippe Sauthier [15], Rima Slim [16 17 18]

	HM genotype			
	Androgenetic monospermic	Androgenetic dispermic	Triploid dispermic	Twin (HM and fetus)/mosaic
Cohort size (n = 204)	114 (55.9%)	12 (5.9%)	69 (33.8%)	9 (4.4%)
Number with known follow-up	95	12	62	7
No GTN	49	1	61	4
GTN	46 (48.4%)	11 (91.7%)	1 (1.6%)	3 (43%)
95% CI	0.38–0.59	0.62–1.0	0.0–0.087	n.a.
	57 (53.3%)			
Low risk ≤ 6	39	6	1	1
High risk ≥ 7	5 (10.9%)	3 (27.2%)	0	1
CC	2 (1.8%)	3 (25%)	0	0
95% CI	0.003–0.074	0.055–0.57	0–0.058	n.a.
Unknown risk	2	2	0	1

GTN gestational trophoblastic neoplasia, *CI* confidence interval, *CC* choriocarcinoma, *n.a.* not applicable. Categories and numbers represented in the histograms of Fig. 1 are underlined

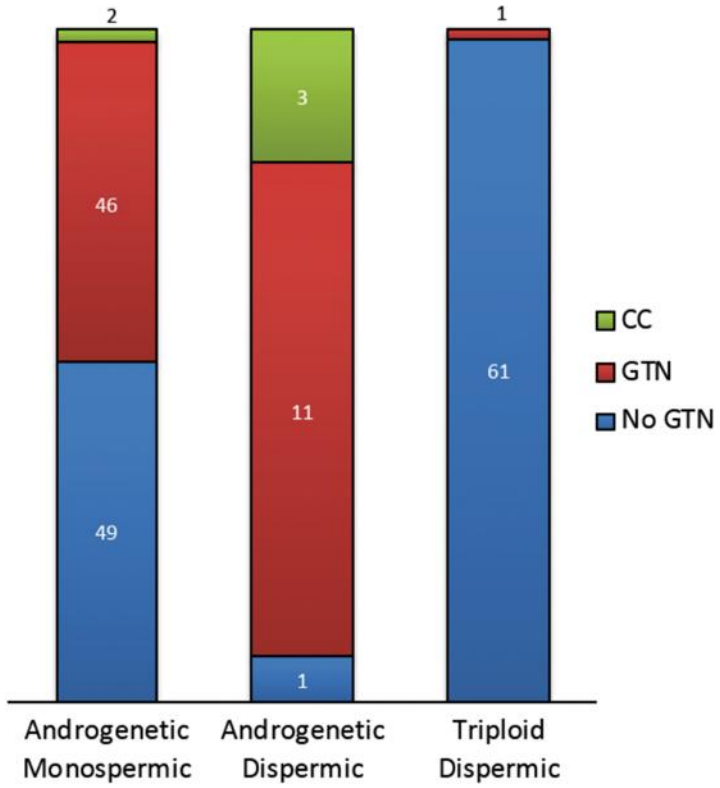

Heterozygous CHM has a significant higher risk of post-molar GTN than homozygous CHM

Genotyping is informative for such risk stratification

Y-GTD Center Case of May 2024

31-year-old patient presenting with abnormal gestation after multiple failed pregnancies; Abnormal high serum hCH; uterine mass lesion and multiple lung nodules. Undergoing hysterectomy.

Contributed by Dr. Peter Chen

Invasive Myometrial Lesion

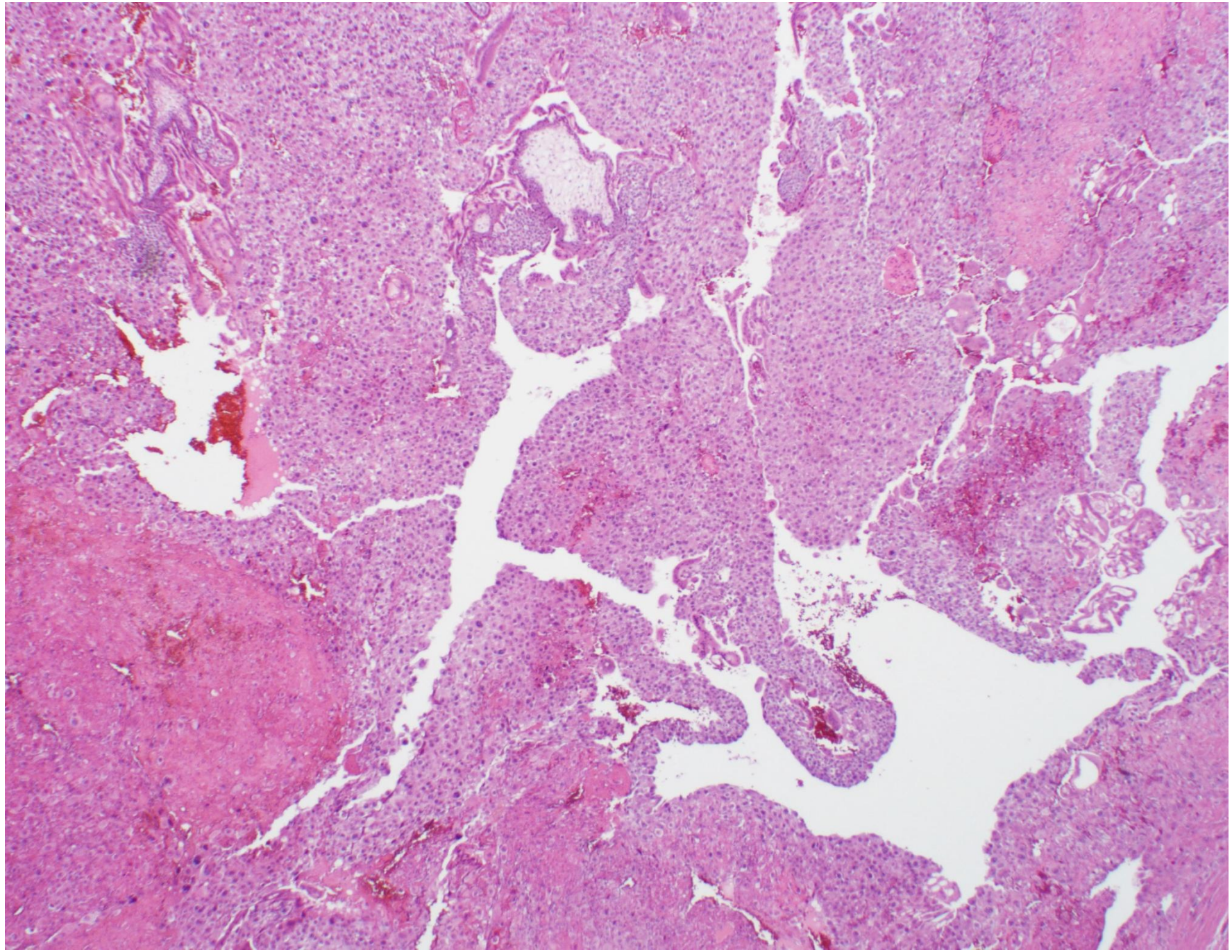

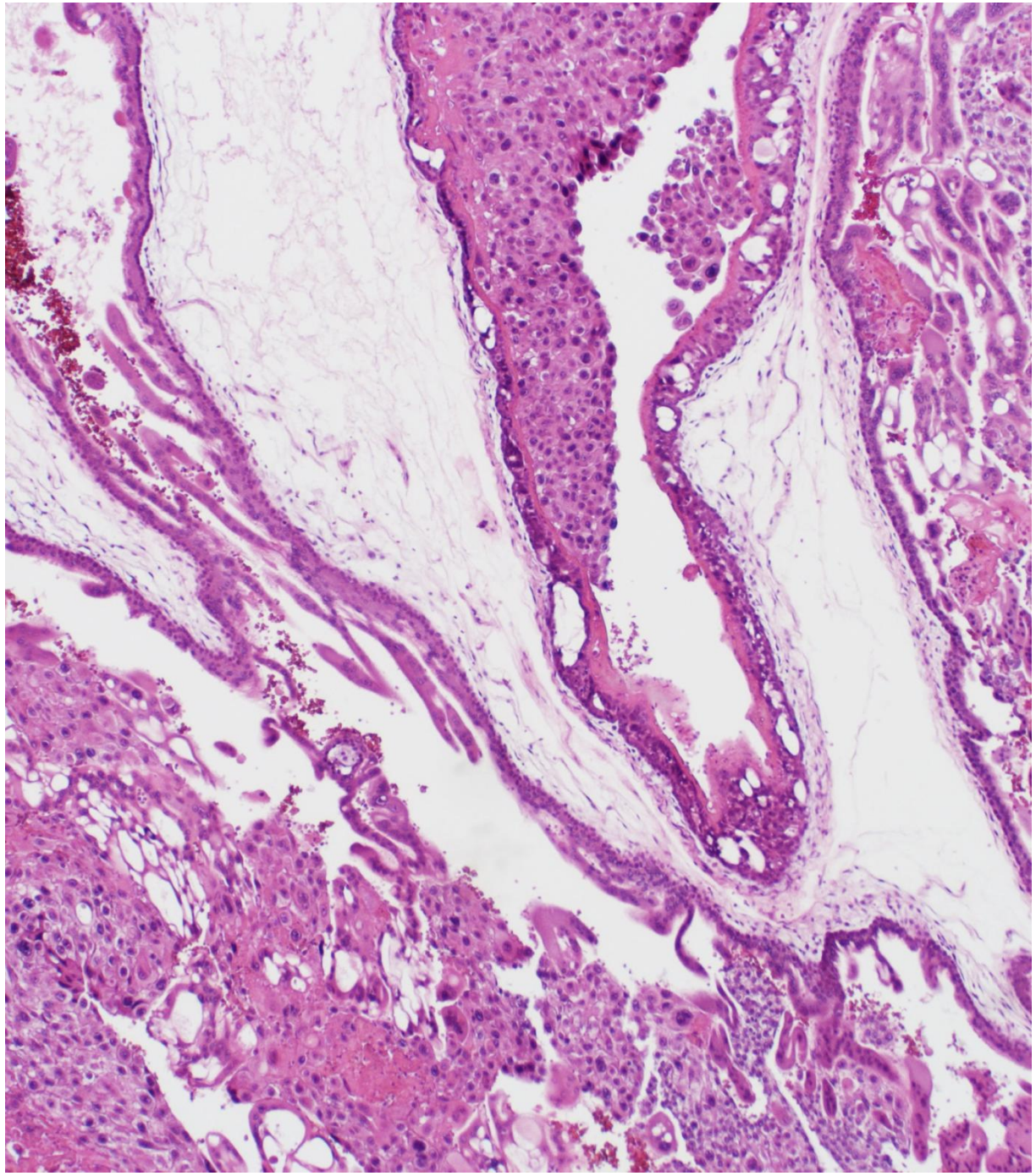

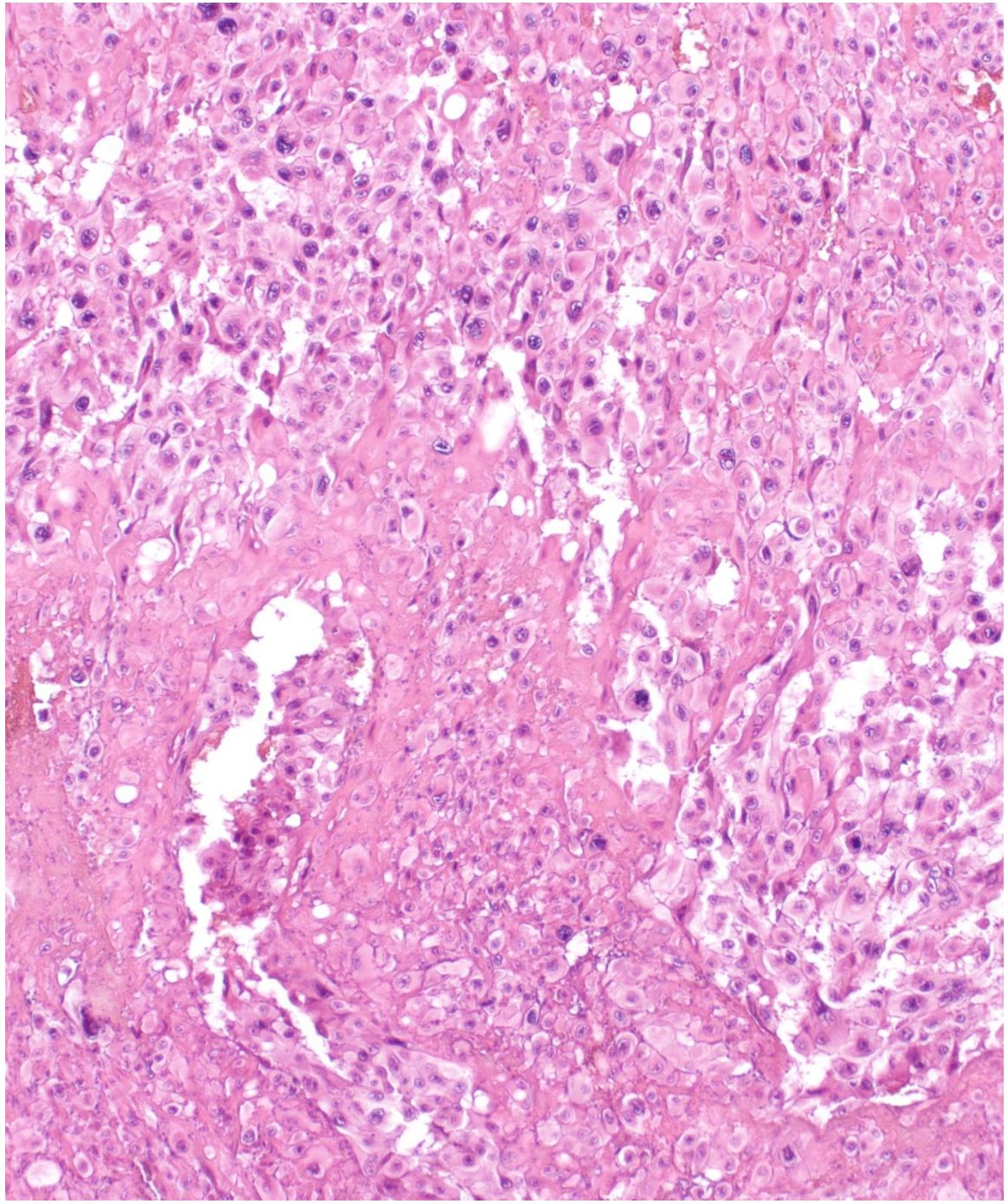

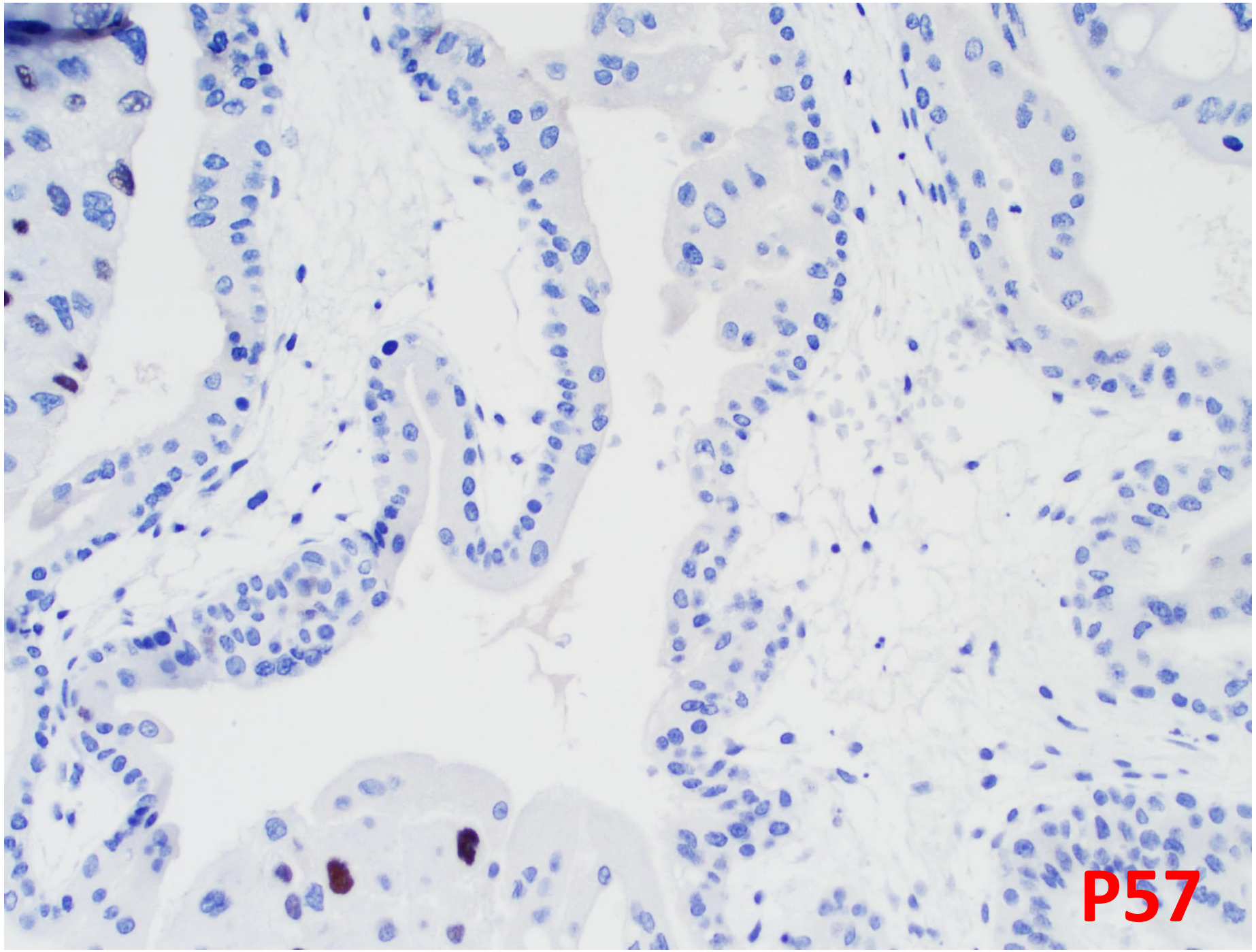
P57

Balanced Biparental Genotype – No Genetic Evidence of CHM



Is this a mole?

- Myoinvasive villi of abnormal histology
- Negative P57 expression
- Normal STR genotype

Hydatidiform Moles – Two Subtypes

- Sporadic Hydatidiform Moles (>97%)
- Familial Biparental Hydatidiform Moles

Biparental Recurrent Hydatidiform Moles

Familial recurrent hydatidiform moles represent 0.6 to 2.6% of all hydatidiform moles, among which familial biparental CHM (FBCHM) is an exceptional condition. Initially reported 40 years ago as recurrent moles in multiple pregnancies of sisters in three unrelated families, close to 300 cases of FBCHM have since been reported to date.

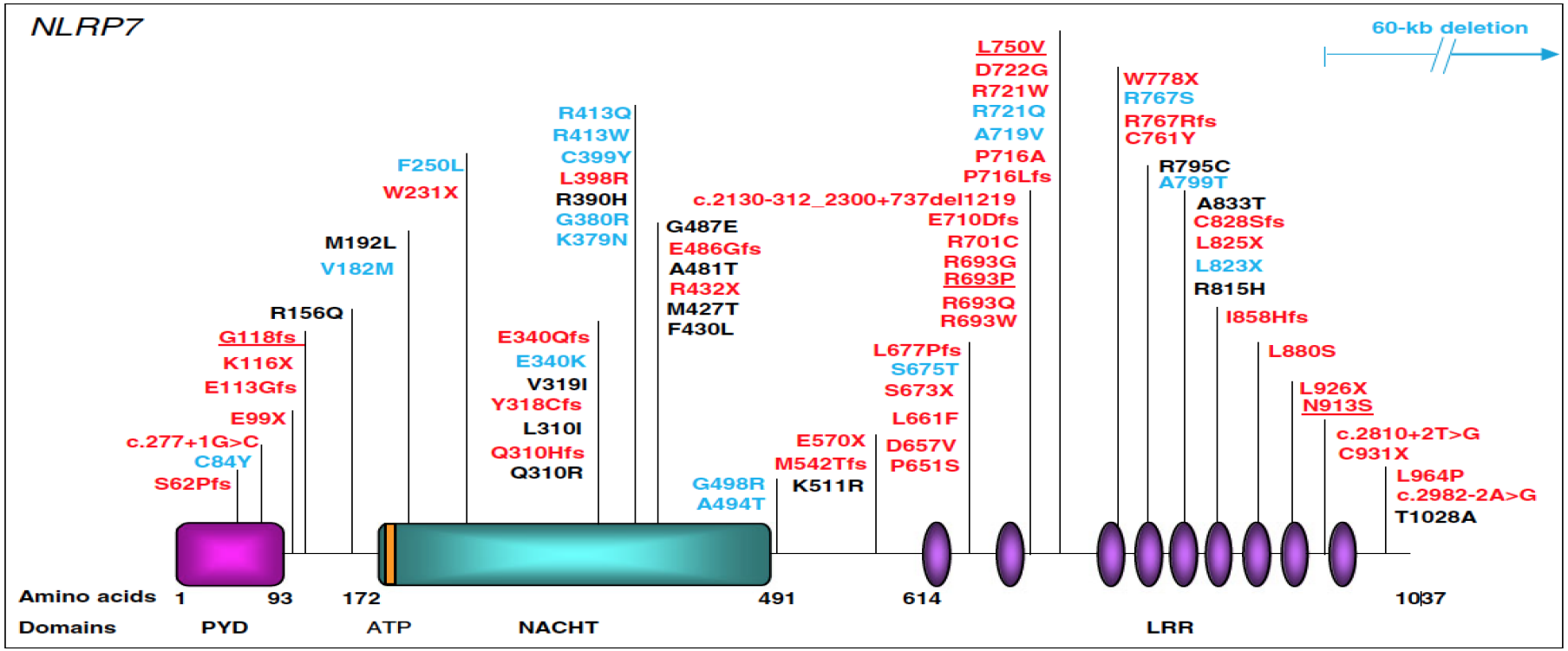

FBCHM

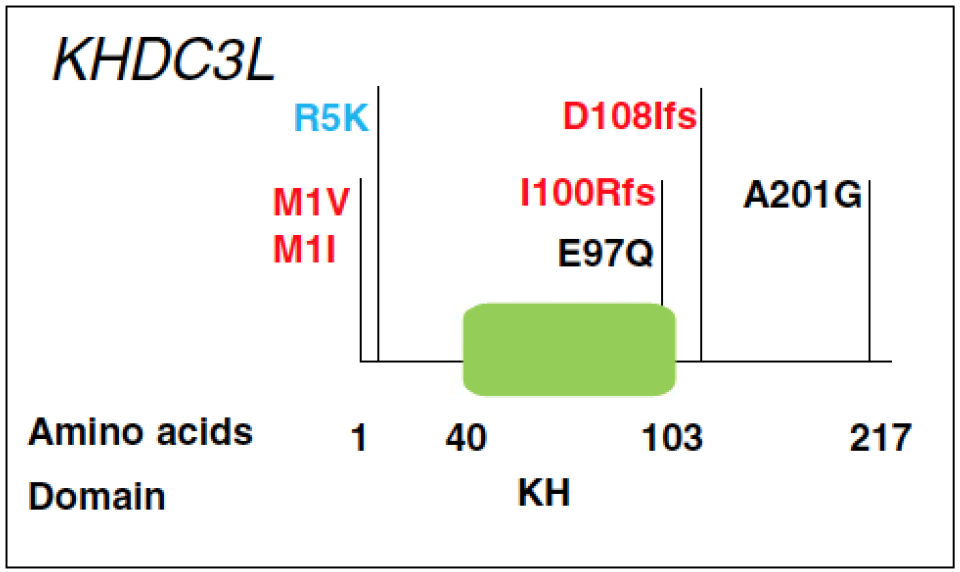

Homozygous or compound heterozygous mutations: 86 variants of *NLRP7* and 4 variants of *KHDC3L* in FBCHM patients.

Nguyen and Slim:Curr Obsete Gynecol Rep,2014.

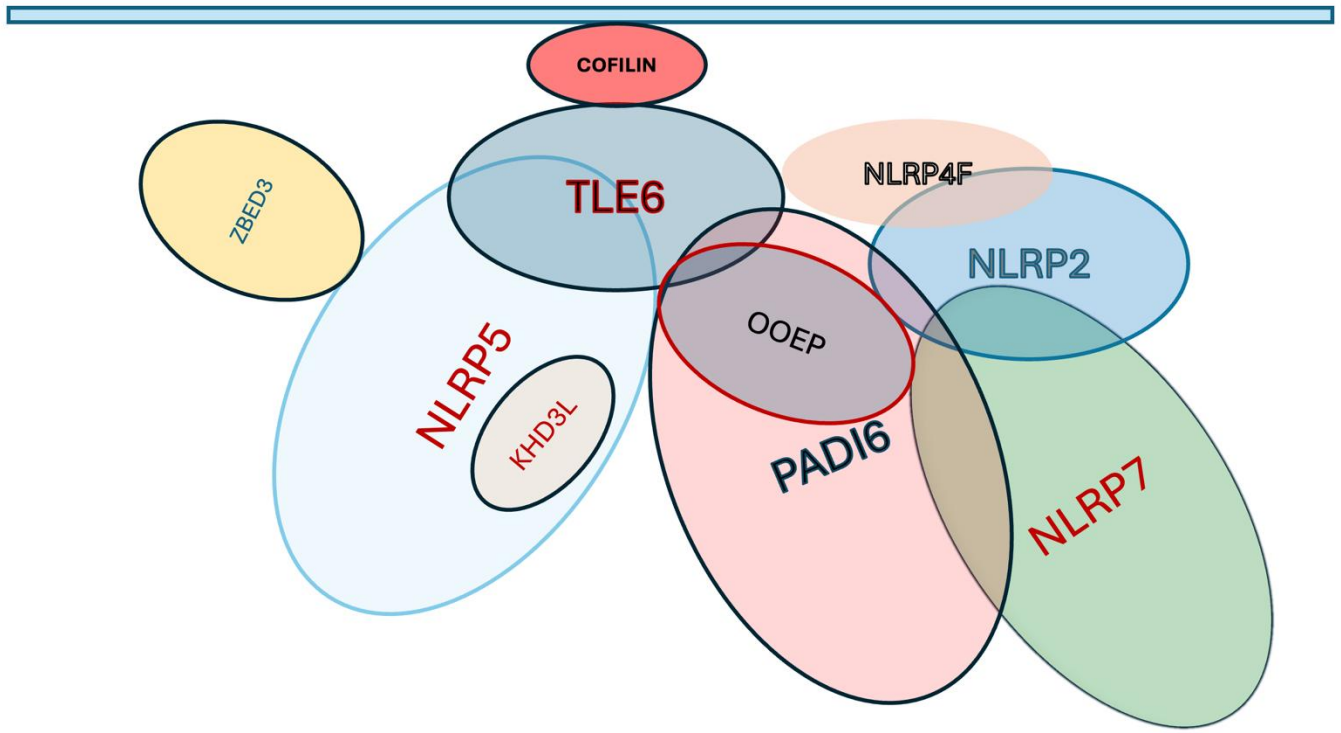

Hui P. Gestational Trophoblastic Disease: Diagnostic and Molecular Genetic Pathology. Second Edition, Springer, 2025

Maternal Decidua: Homozygous Leu750Val Mutation

Molar villi: Heterozygous Leu750Val Mutation

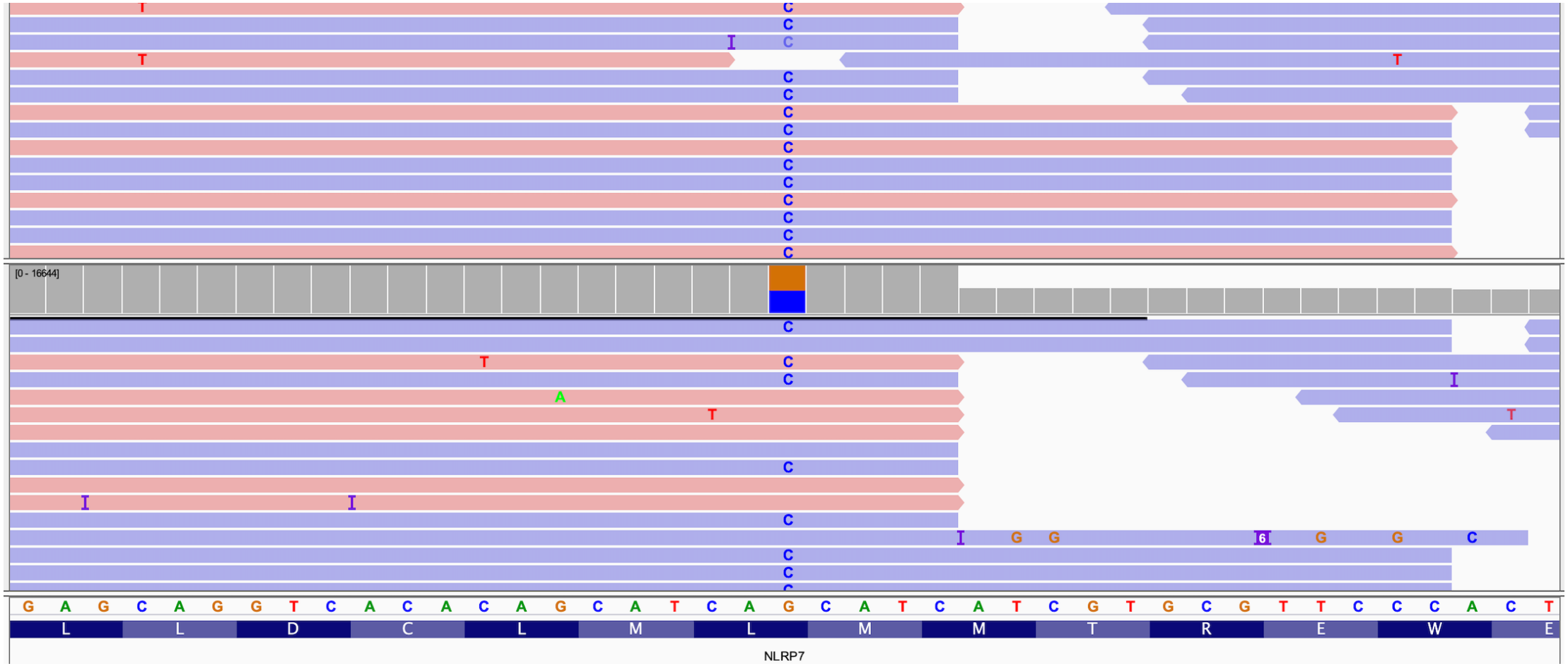

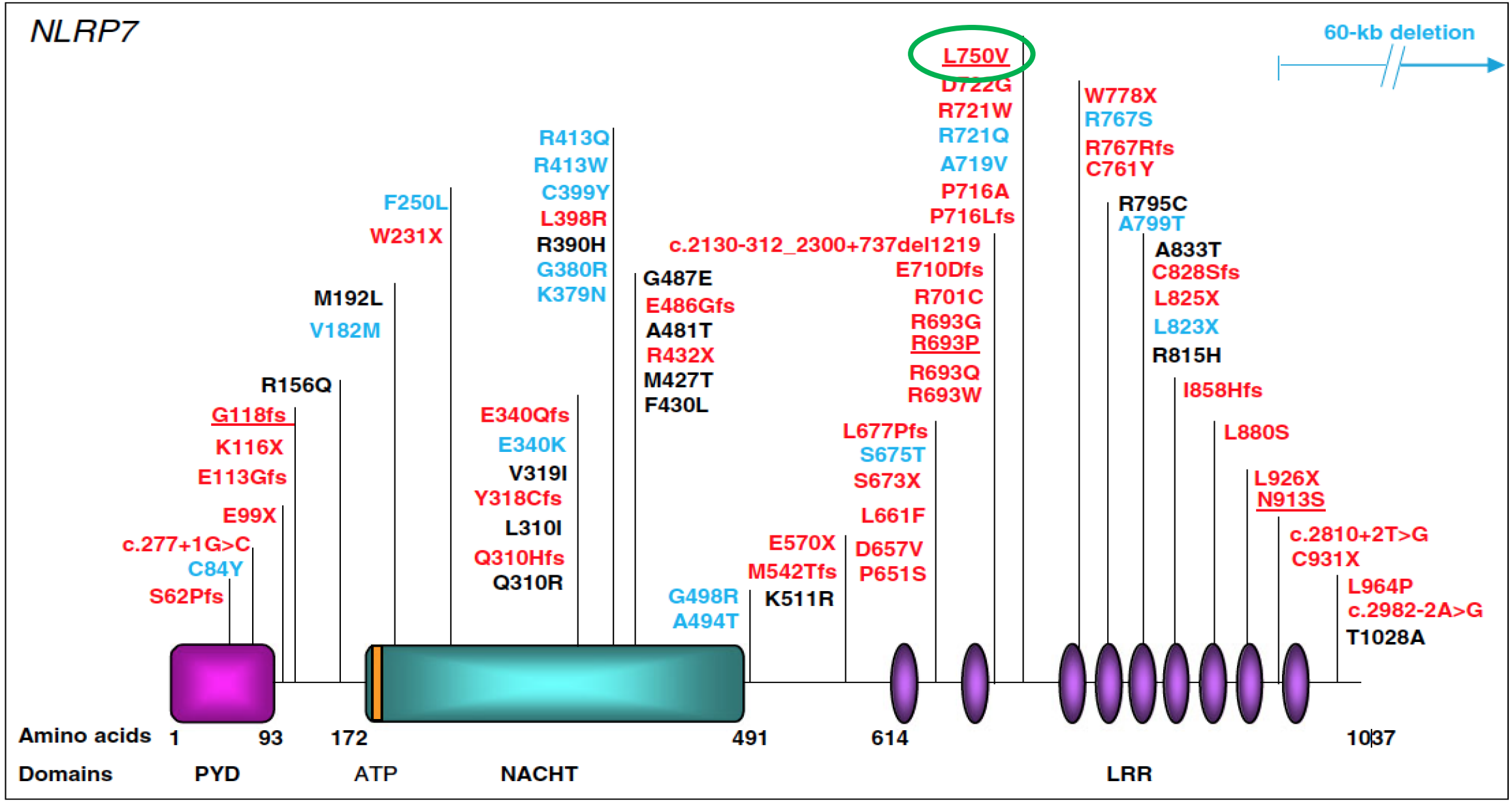
NLRP7
60-kb deletion
L750V
D722G
R721W
R721Q
A719V
P716A
P716Lfs
W778X
R767S
R767Rfs
C761Y
R795C
A799T
A833T
C828Sfs
L825X
L823X
R815H
I858Hfs
L880S
L926X
N913S
c.2810+2T>G
C931X
L964P
c.2982-2A>G
T1028A
R413Q
R413W
C399Y
L398R
R390H
G380R
K379N
F250L
W231X
M192L
V182M
R156Q
G118fs
K116X
E113Gfs
E99X
c.277+1G>C
C84Y
S62Pfs
c.2130-312_2300+737del1219
E710Dfs
R701C
R693G
R693P
R693Q
R693W
G487E
E486Gfs
A481T
R432X
M427T
F430L
E340Qfs
E340K
V319I
Y318Cfs
L310I
Q310Hfs
Q310R
L677Pfs
S675T
S673X
L661F
D657V
P651S
E570X
M542Tfs
K511R
G498R
A494T
Amino acids
1
93
172
491
614
1037
Domains
PYD
ATP
NACHT
LRR

Case Summary: Invasive Biparenal CHM/GTN

- Hysterectomy: Invasive complete mole with negative P57
- History of multiple failed pregnancies
- GTN: high hCG and multiple lung nodules
- STR genotyping: balanced biparental profile
- NGS FBCHM Panel: homozygous germline mutation of *NLRP7*
- Treatment: GTN chemotherapy
- Implications: family mutation screening and fertility planning
- Prognosis: Poor reproductive outcome (Egg donor option)

You will miss such FBCHM without genotyping

Summary

- Highly characteristic histology of VECHM
- P57 IHC - powerful confirmatory ancillary tool
- Pitfalls of P57 IHC interpretations
- Gold standard of diagnosis - STR genotyping
- STR genotyping for prognostication, and rare but important conditions

THANK YOU

