Title: Grossing issues in Gynaecological Pathology

Speaker: Angela Ralte

Affiliation

South of Tyne and Wear Pathology
Northern Gynaecological Oncology Centre Gateshead UK
Cervical Screening Centre North-East Yorkshire and Humber UK

Date: 7th March 2025

angela.ralte@nhs.net

The British Association of Gynaecological Pathologists

Speaker disclosures

Choose one

- ❑ I have no financial conflicts of interest to disclose

Grossing issues in gynaepathology









Pelvic exenteration

En-bloc resection of pelvic organs

***L**aterally **E**xtended **E**ndopelvic **R**esection **(LEER)**-more extensive procedure for tumours invading lateral pelvic walls)*

Indications

- Selected cases of **locally advanced cervical or vaginal cancer**
- **Recurrent cervical or vaginal cancer** following chemoradiotherapy
- Intent of surgery is **curative - margin assessment critical**

Anterior exenteration

Gynae organs + bladder



Posterior exenteration

Gynae organs + anorectum

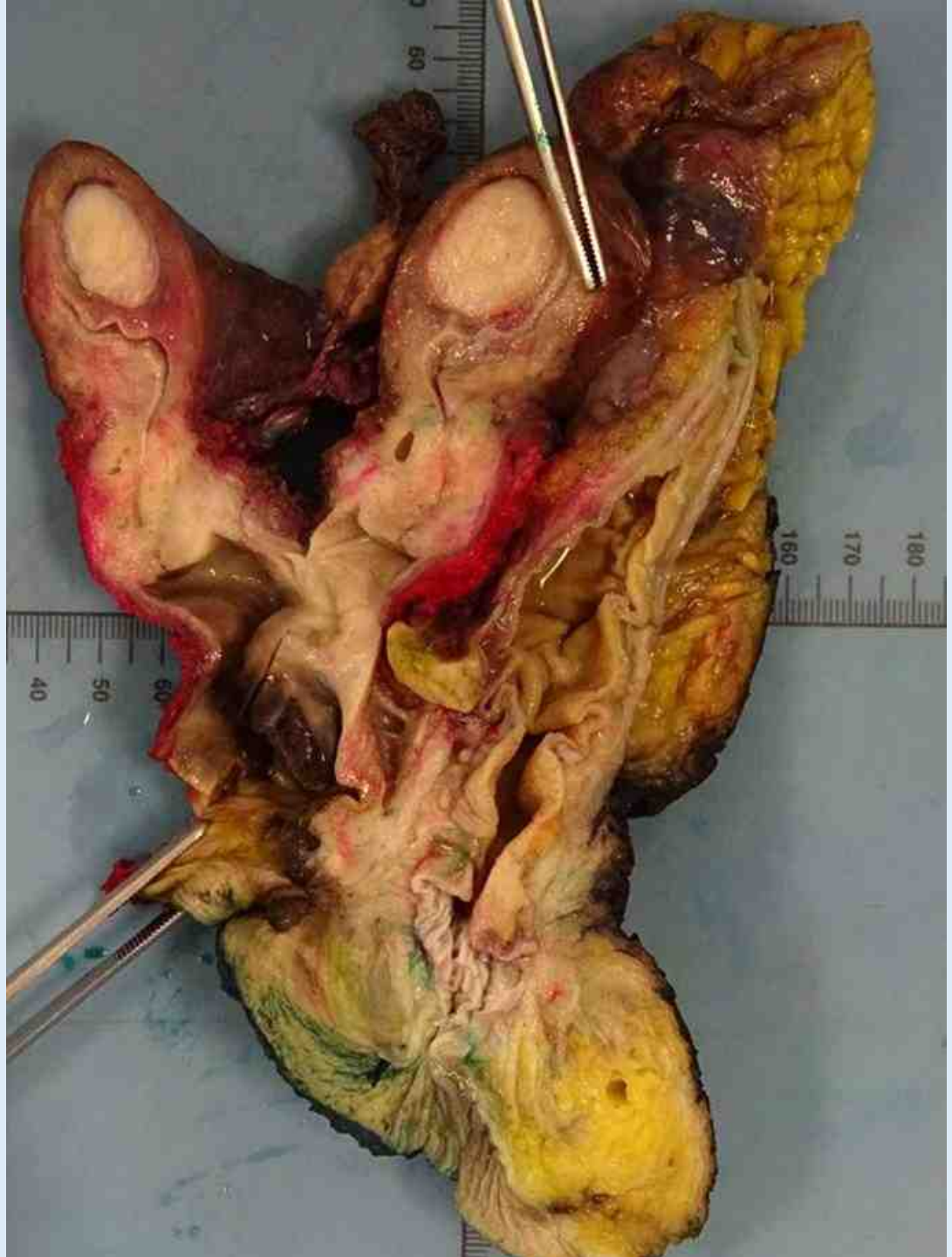

Total pelvic exenteration

Gynae organs + bladder + anorectum



Case 1



65y

2020
HPVa vaginal SCC treated with chemoradiation

2025
Anterior exenteration for recurrence
?urethral involvement


Unknown
01-Jan-0001
25HP001844
Cirdan Imaging
16-Jan-2025

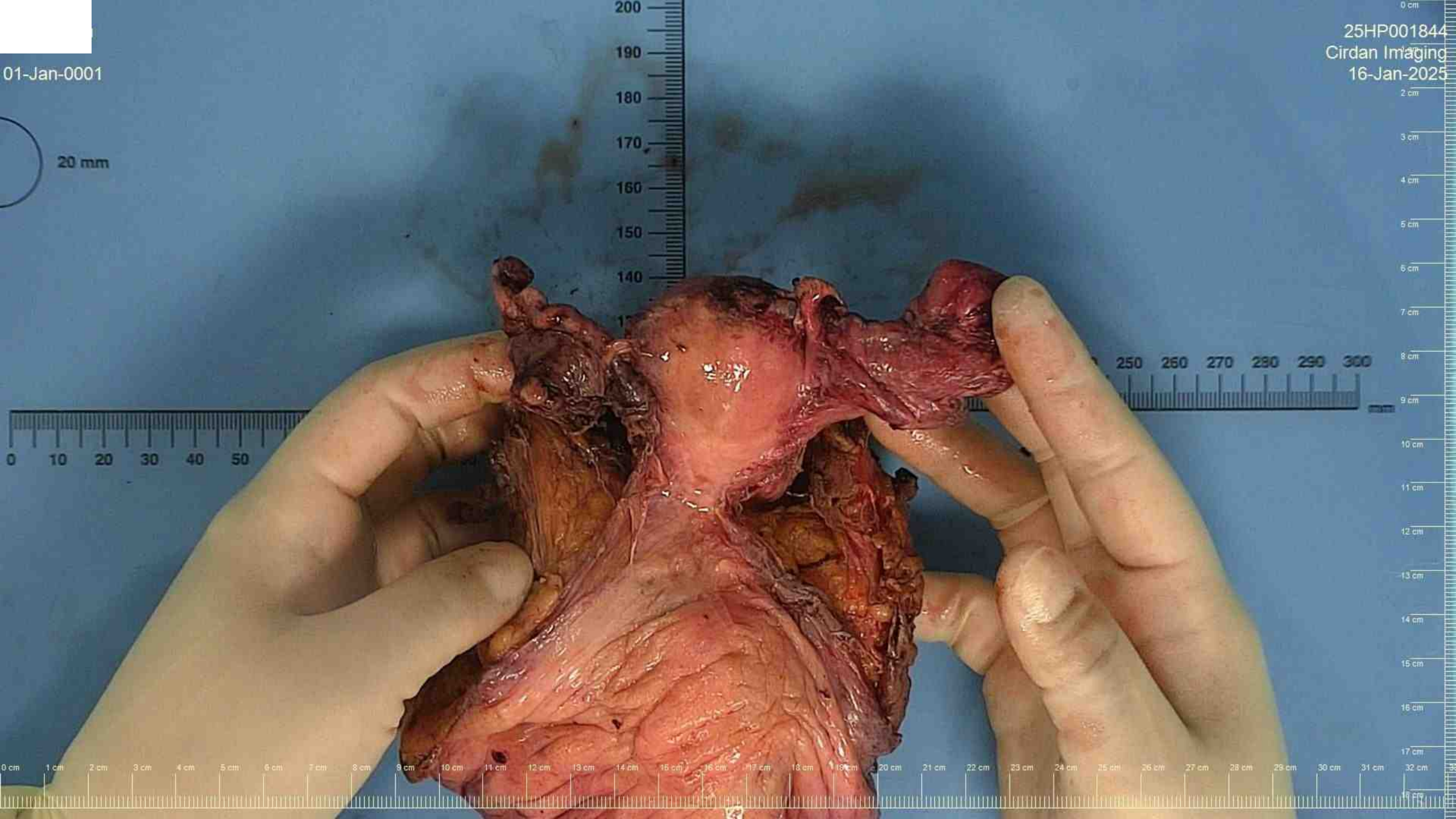
01-Jan-0001
20 mm
25HP001844
Cirdan Imaging
16-Jan-2025

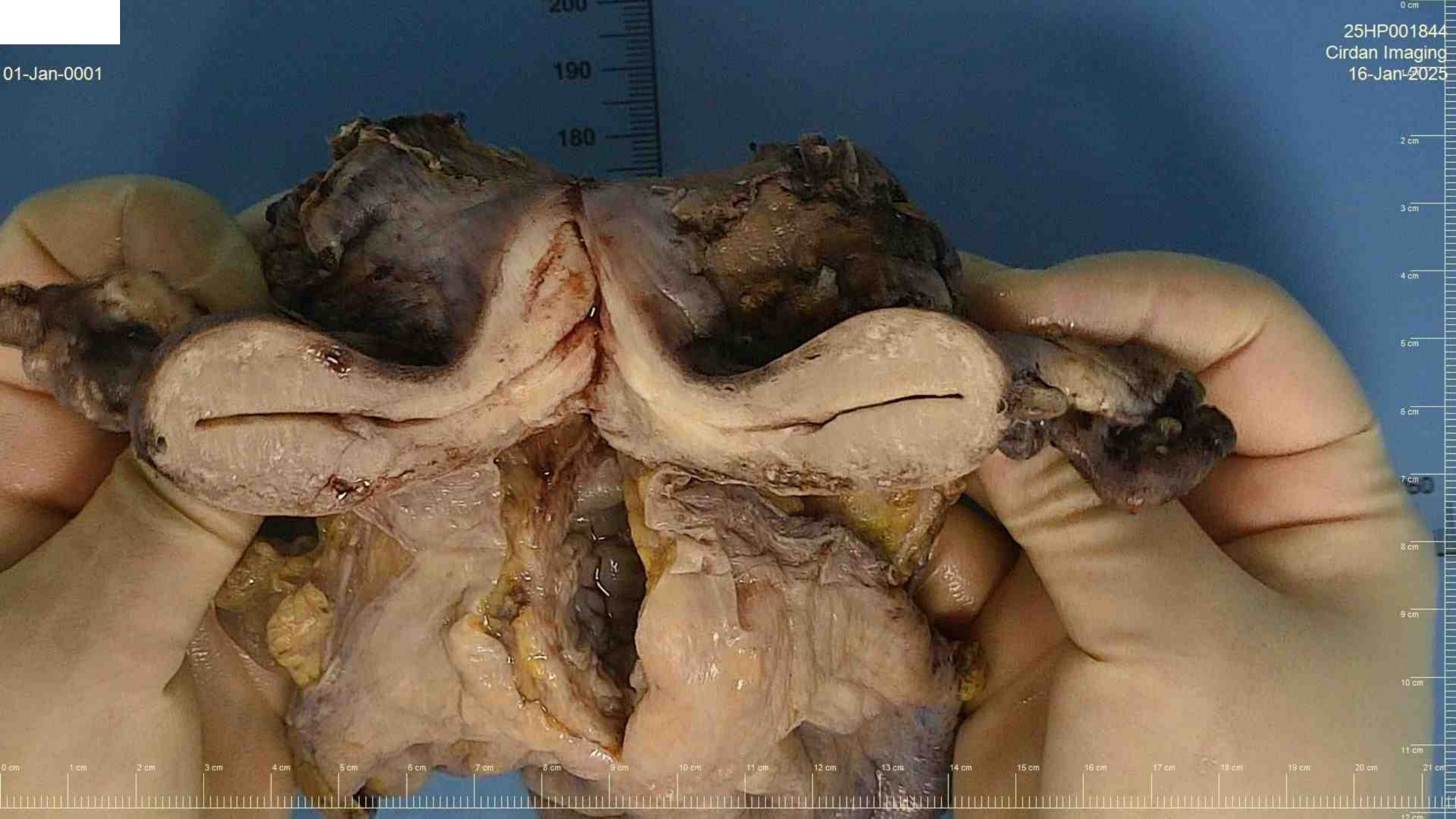
01-Jan-0001
25HP001844
Cirdan Imaging
16-Jan-2025


Unknown
01-Jan-0001
25HP001844
Cirdan Imaging
16-Jan-2025


Unknown
01-Jan-0001
25HP001844
Cirdan Imaging
16-Jan-2025
mm

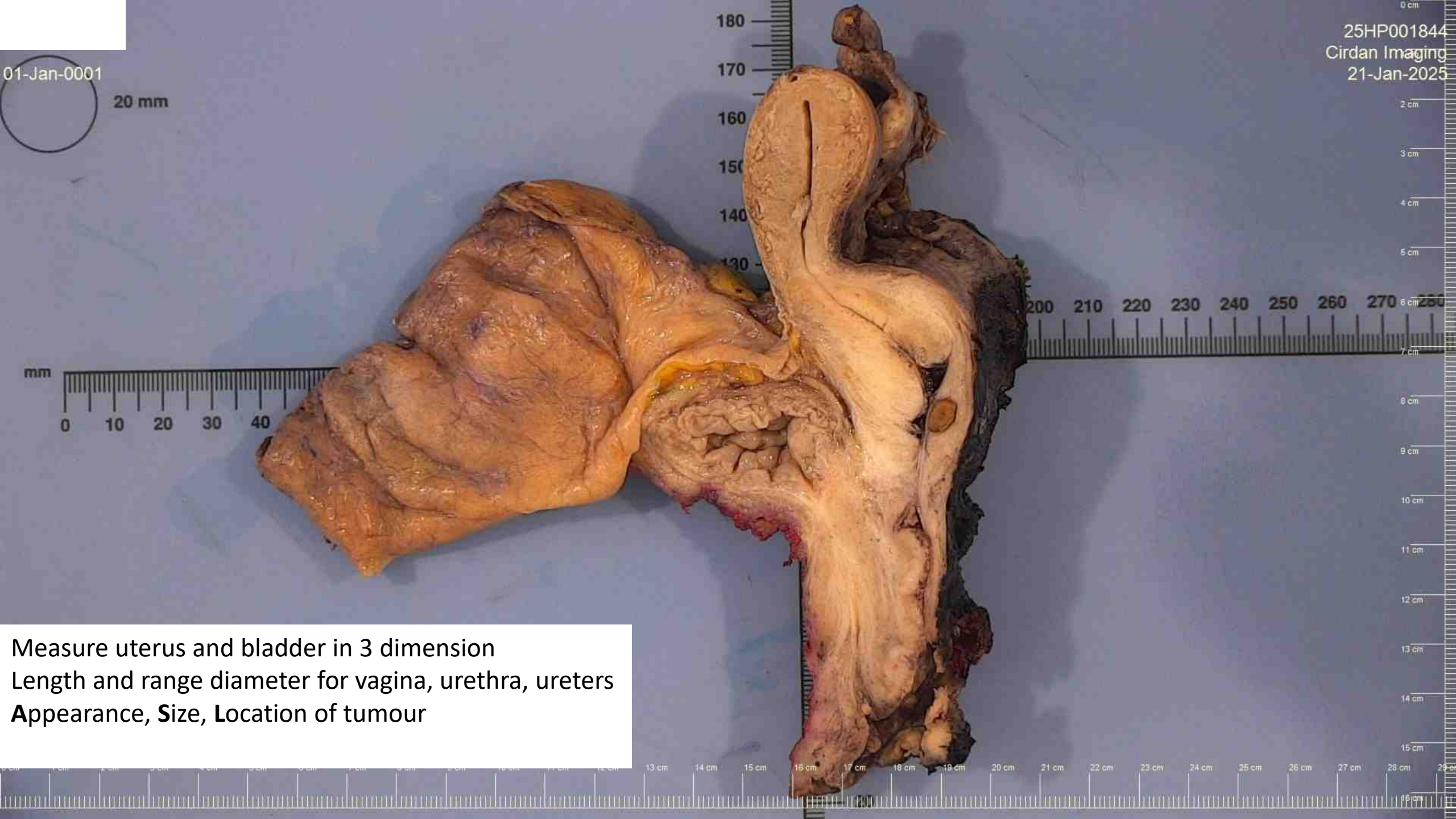

Measure uterus and bladder in 3 dimension
Length and range diameter for vagina, urethra, ureters
Appearance, **S**ize, **L**ocation of tumour

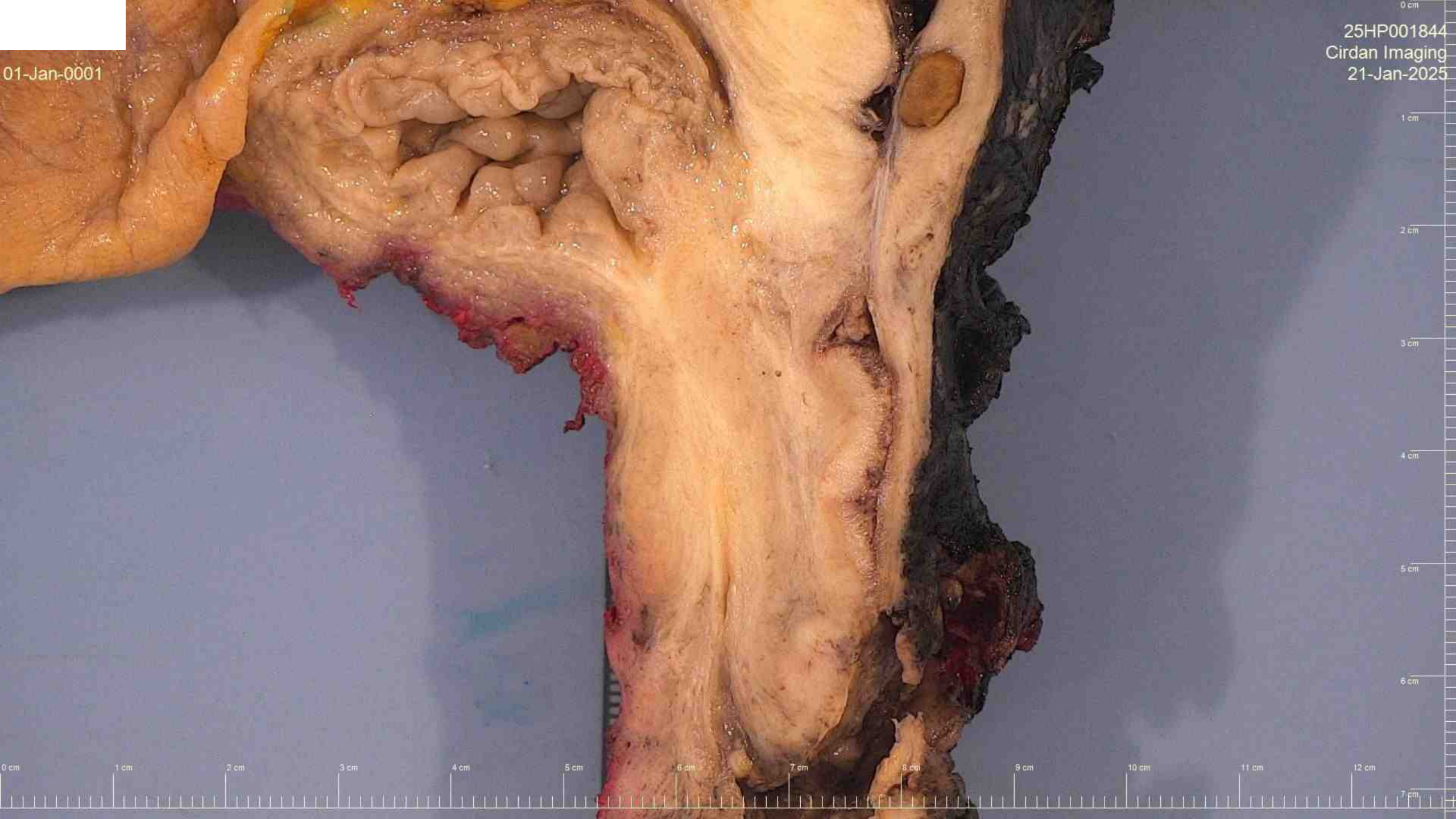
01-Jan-0001
25HP001844
Cirdan Imaging
21-Jan-2025


01-Jan-0001
25HP001844
Cirdan Imaging
21-Jan-2025
0 cm
1 cm
2 cm
3 cm
4 cm
5 cm
6 cm
7 cm
8 cm

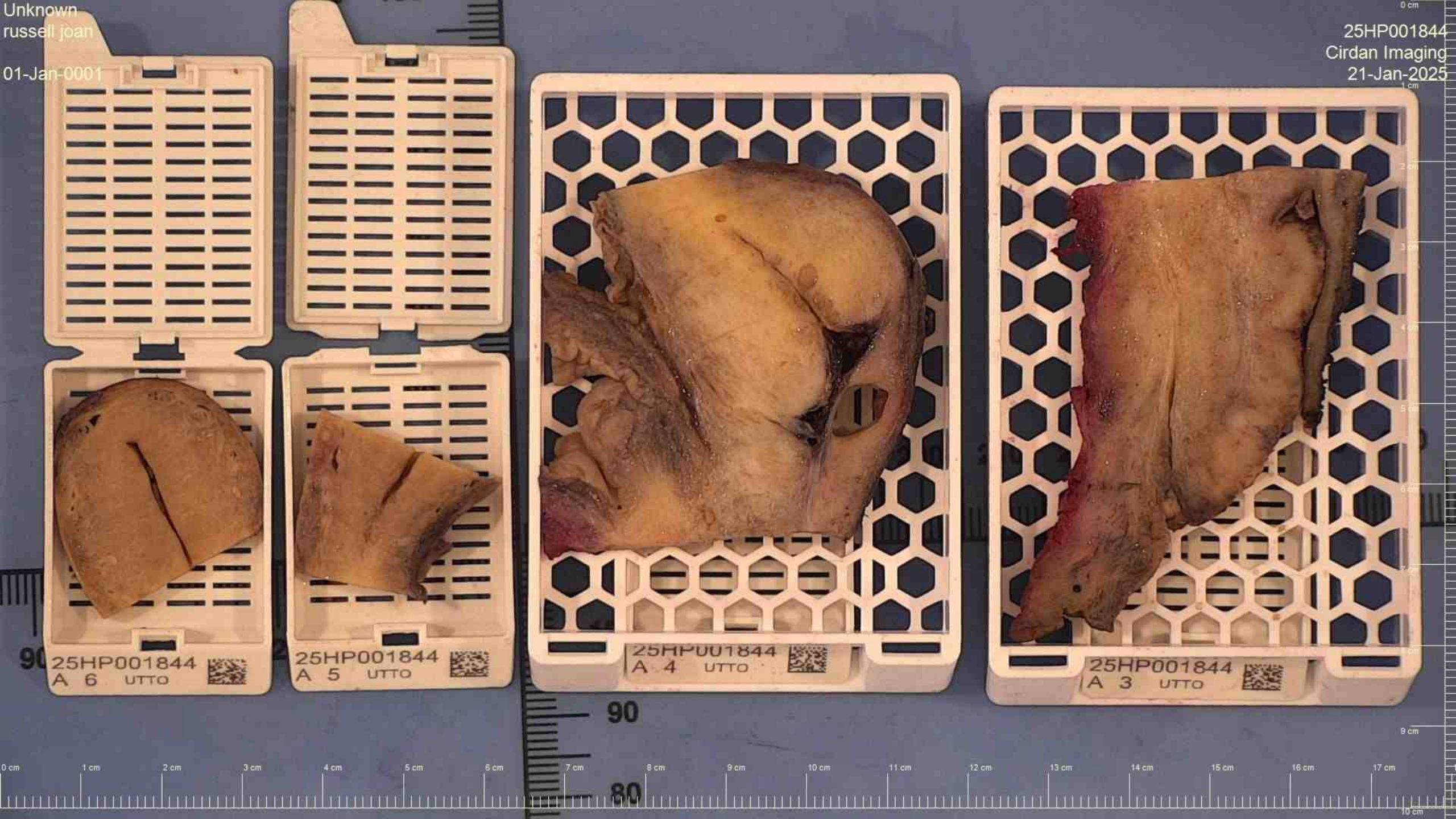
Unknown
russell joan
01-Jan-0001
25HP001844
Cirdan Imaging
21-Jan-2025
25HP001844
A 6 UTTO
25HP001844
A 5 UTTO
25HP001844
A 4 UTTO
25HP001844
A 3 UTTO




3.98 mm
10 mm


01-Jan-0001
10 mm
Uterus
Sequential slices of right half
Cervix
Ureter
Bladder
Tumour
Inferior
Posterior
25HP001844
Cirdan Imaging
21-Jan-2025

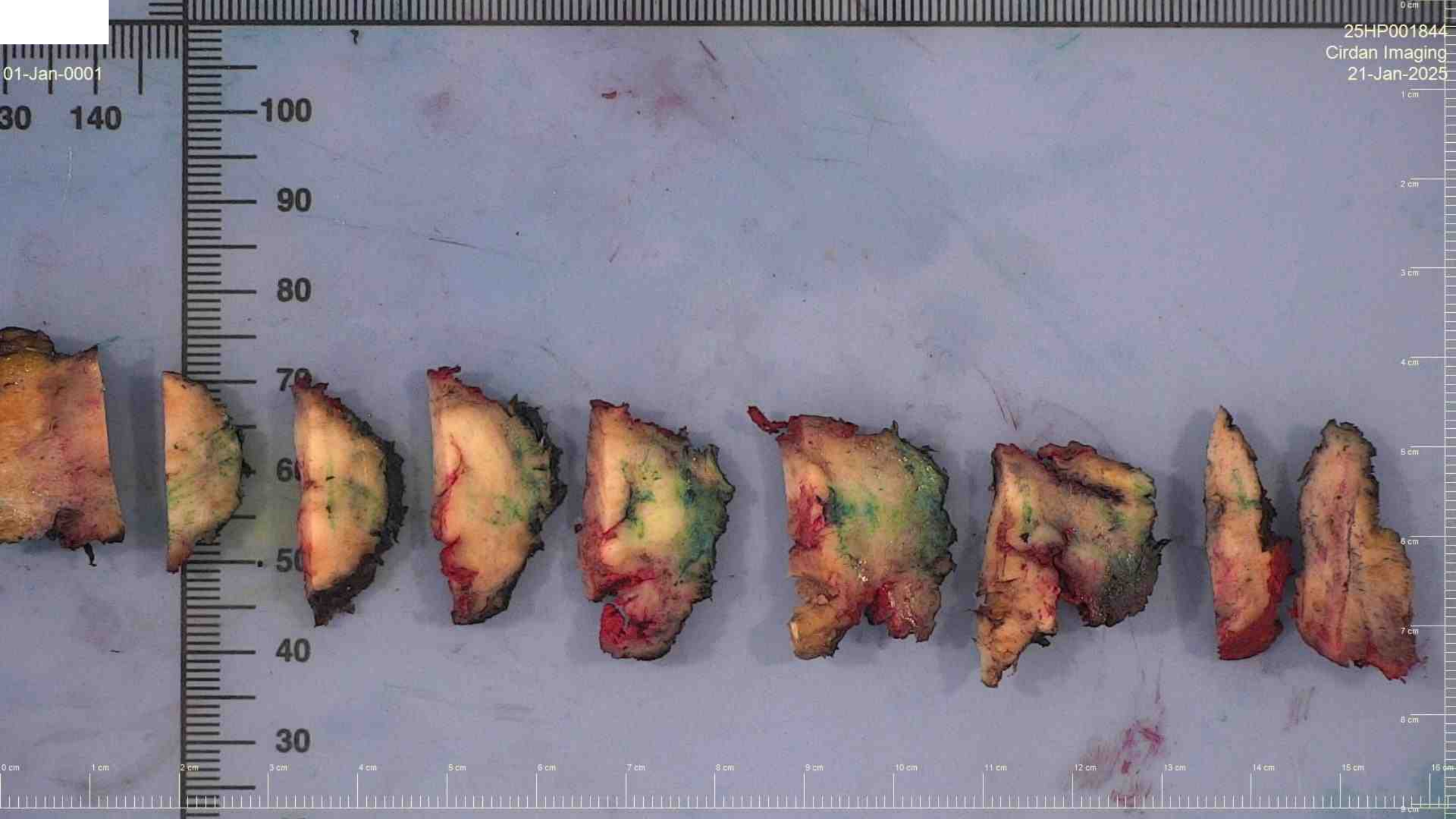
01-Jan-0001
25HP001844
Cirdan Imaging
21-Jan-2025

Unknown
russell joan

01-Jan-0001

25HP001844
Cirdan Imaging
21-Jan-2025




5.99 mm
1.68 mm
5 mm

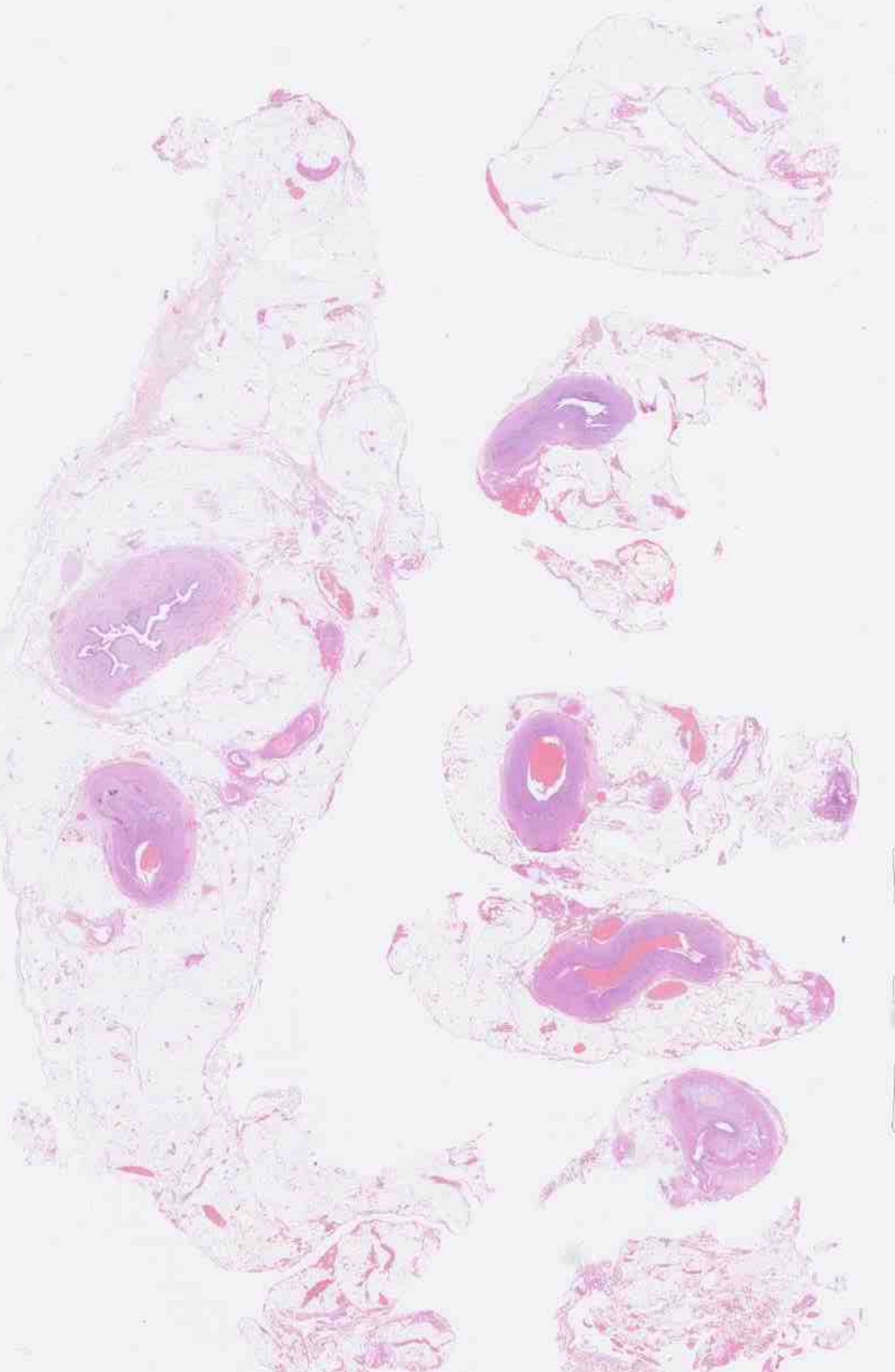

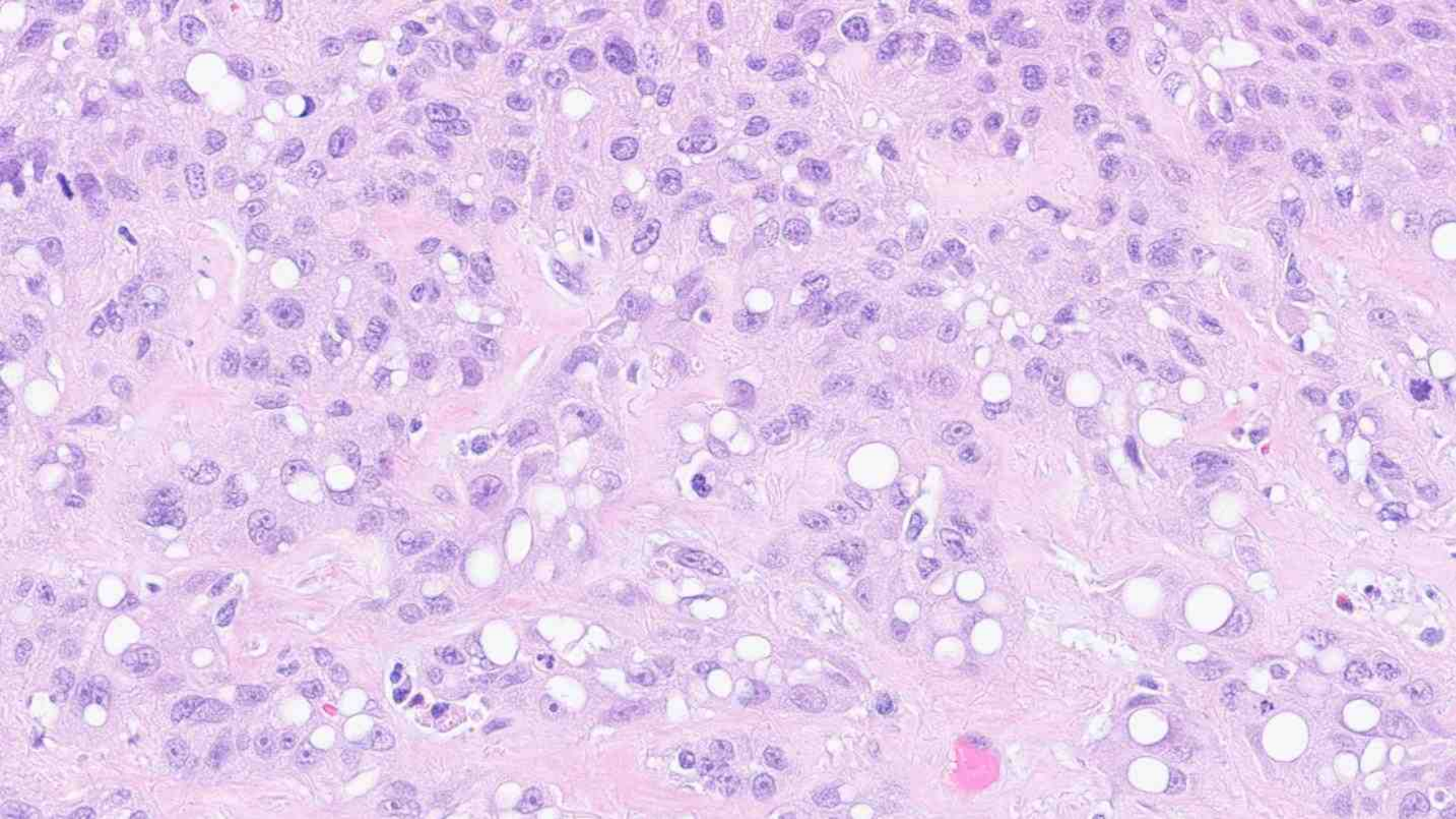


59y
2020- TAH BSO for gastric type adenocarcinoma of cervix
2023 –Total pelvic exenteration of biopsy proven recurrence in vagina
190
160
150
140
130
120
40
30
20
10


180
170
100mm


180
170
0
60
70
50
40
100mm







1:49

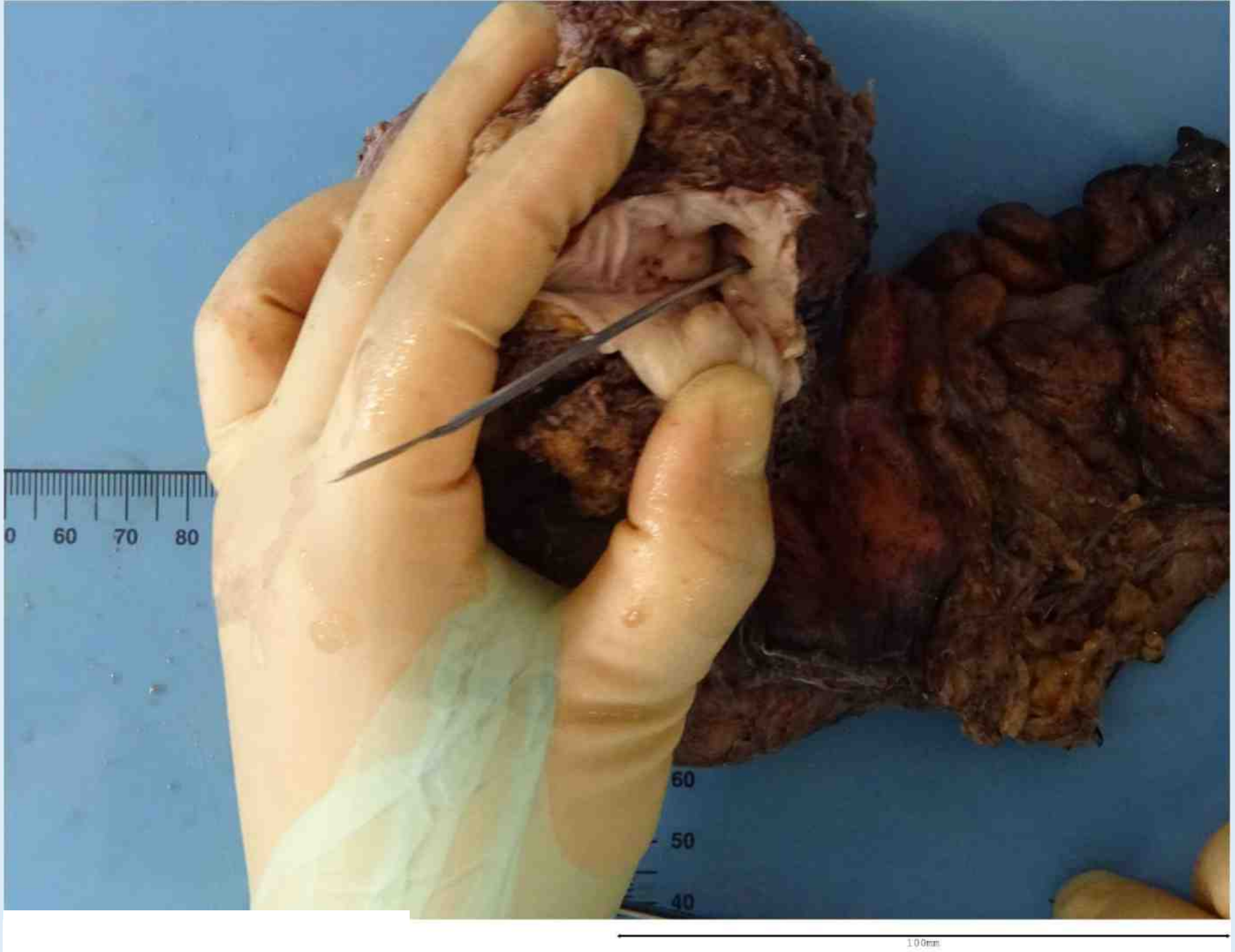
0
60
70
80
60
50
40
100mm

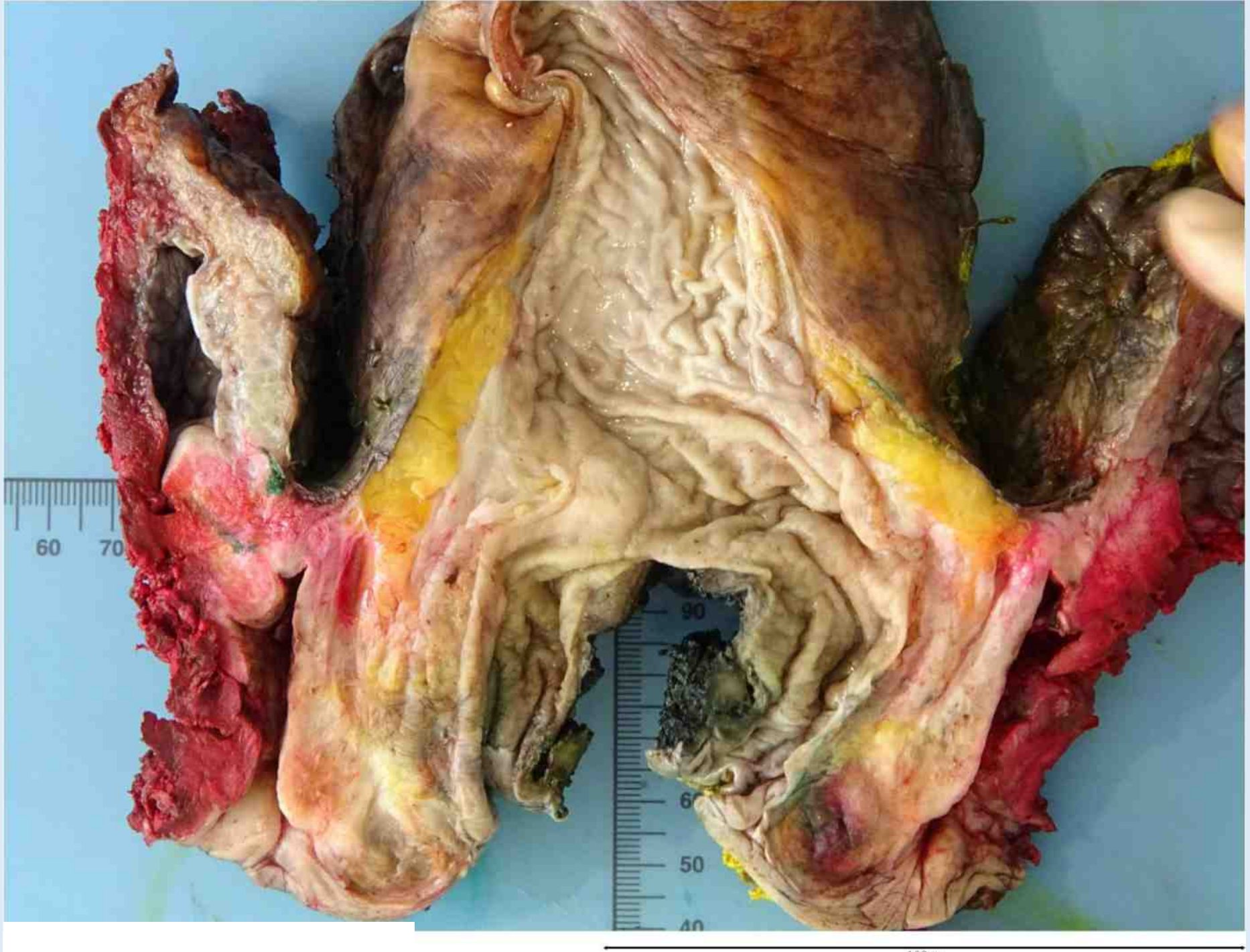
60
70
90
50
100mm

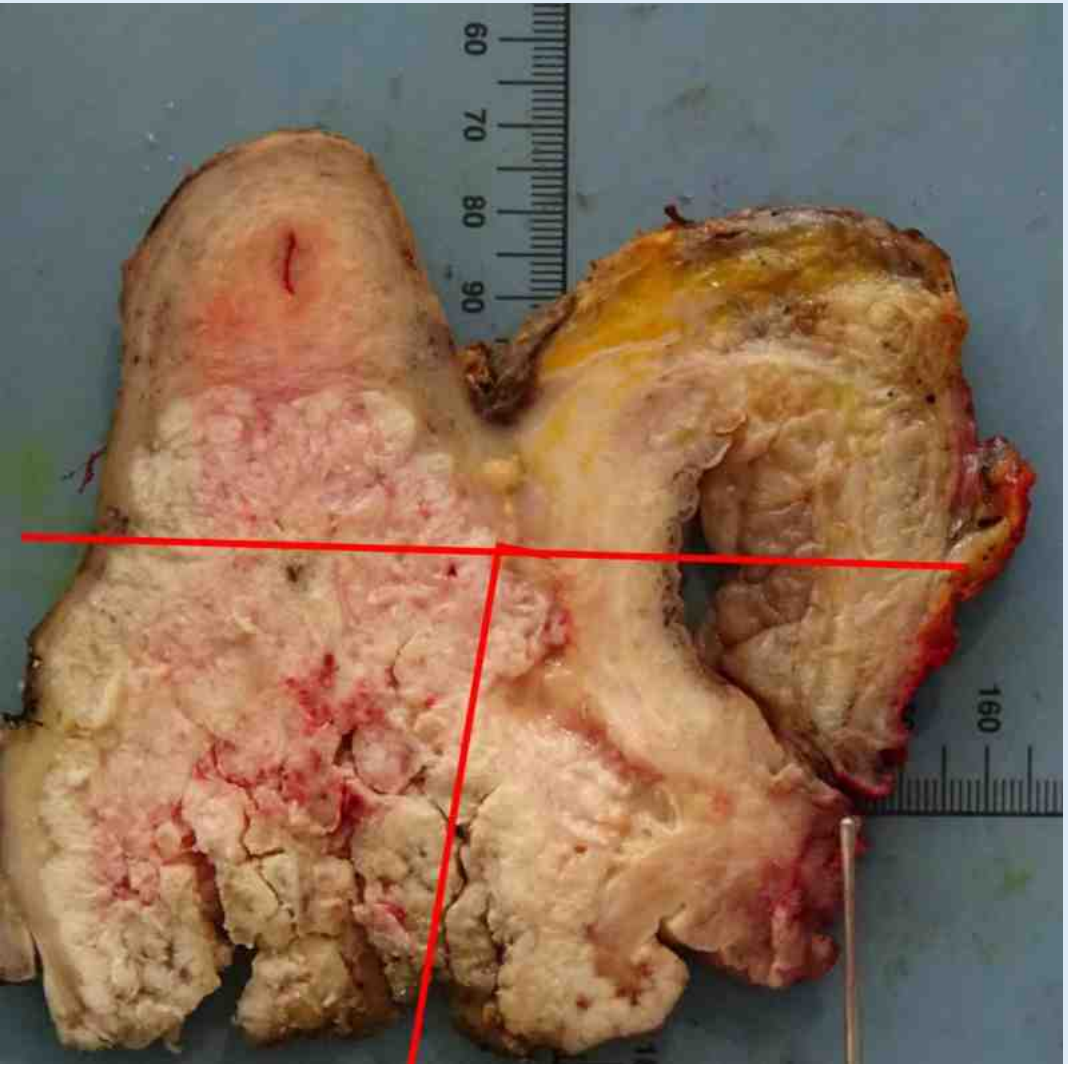

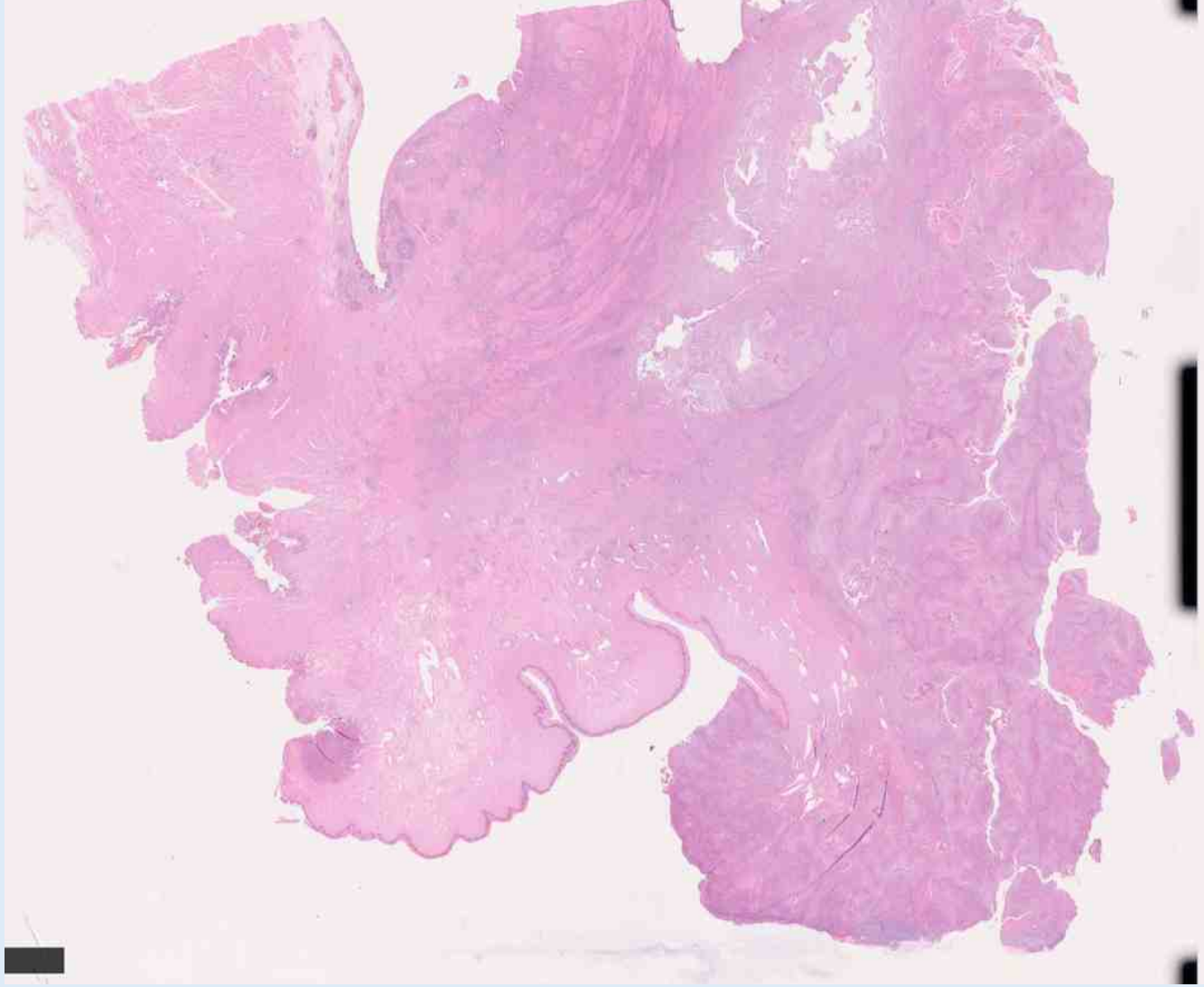

Anterior exenteration for locally advanced cervix cancer

Tumour, bladder+ tumour interface
Anterior soft tissue margin
Antero-inferior –vaginal margin
Urethral and ureteric margins

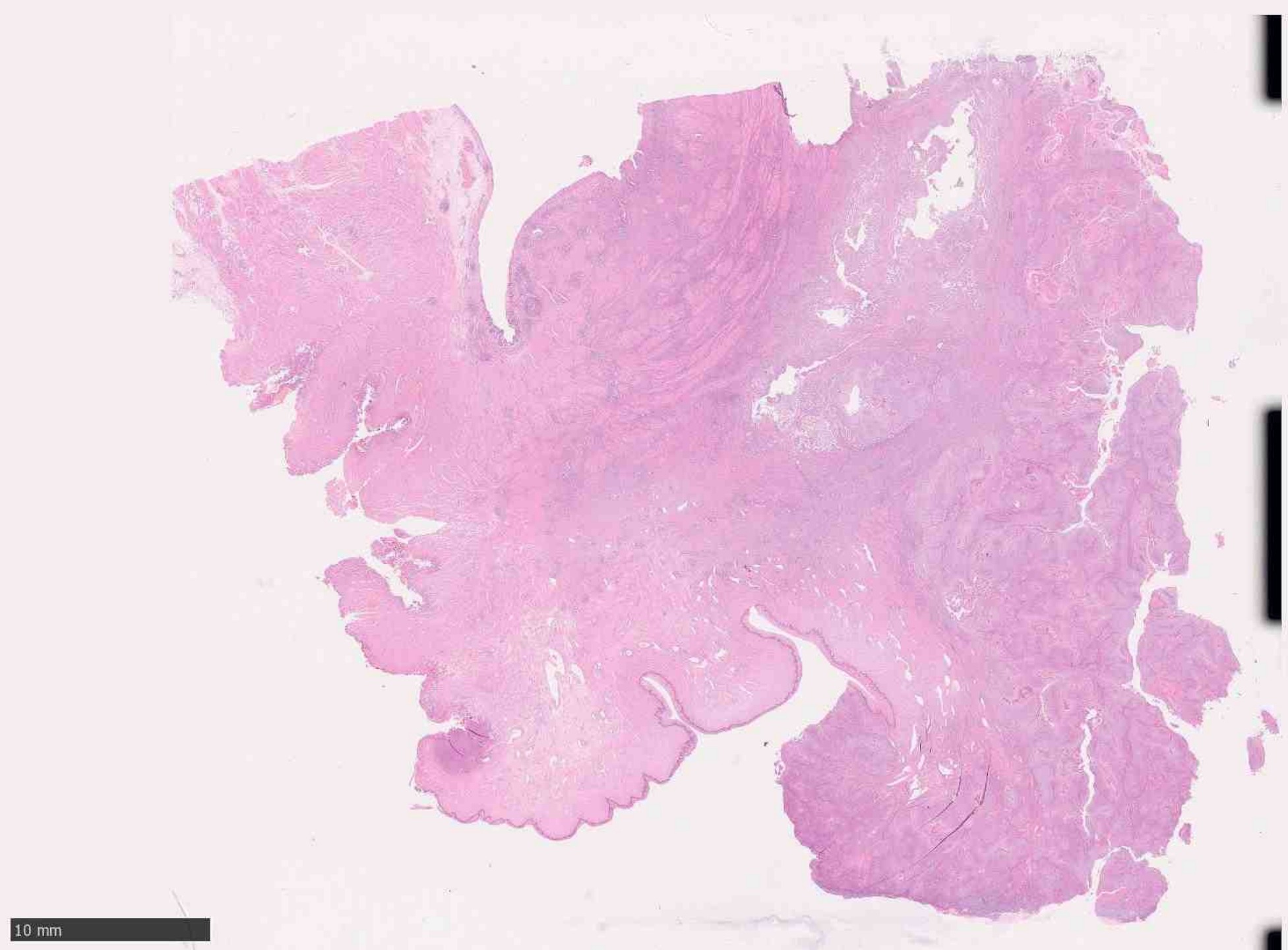
10 mm

Posterior exenteration for
Vulvo-vaginal melanoma



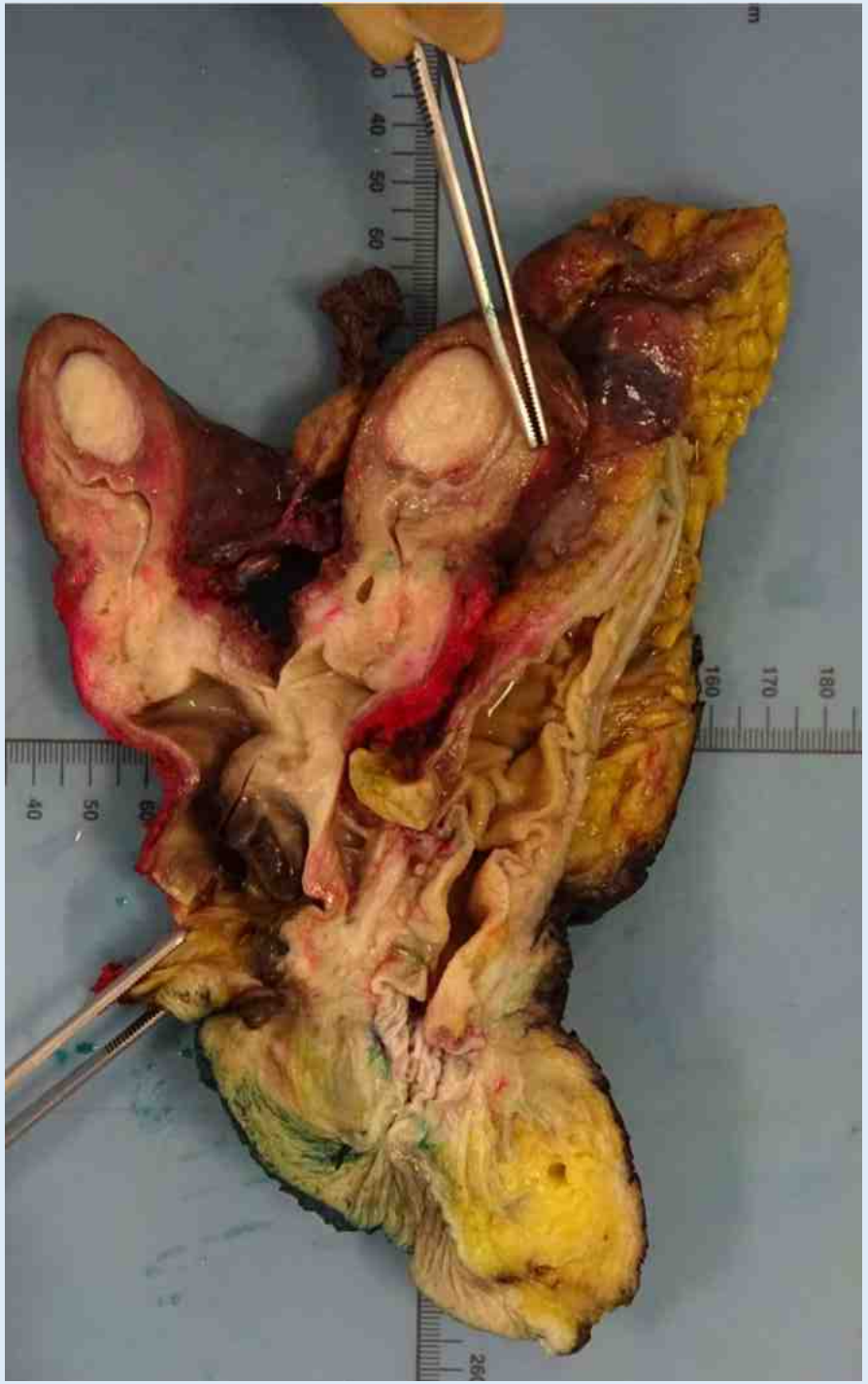

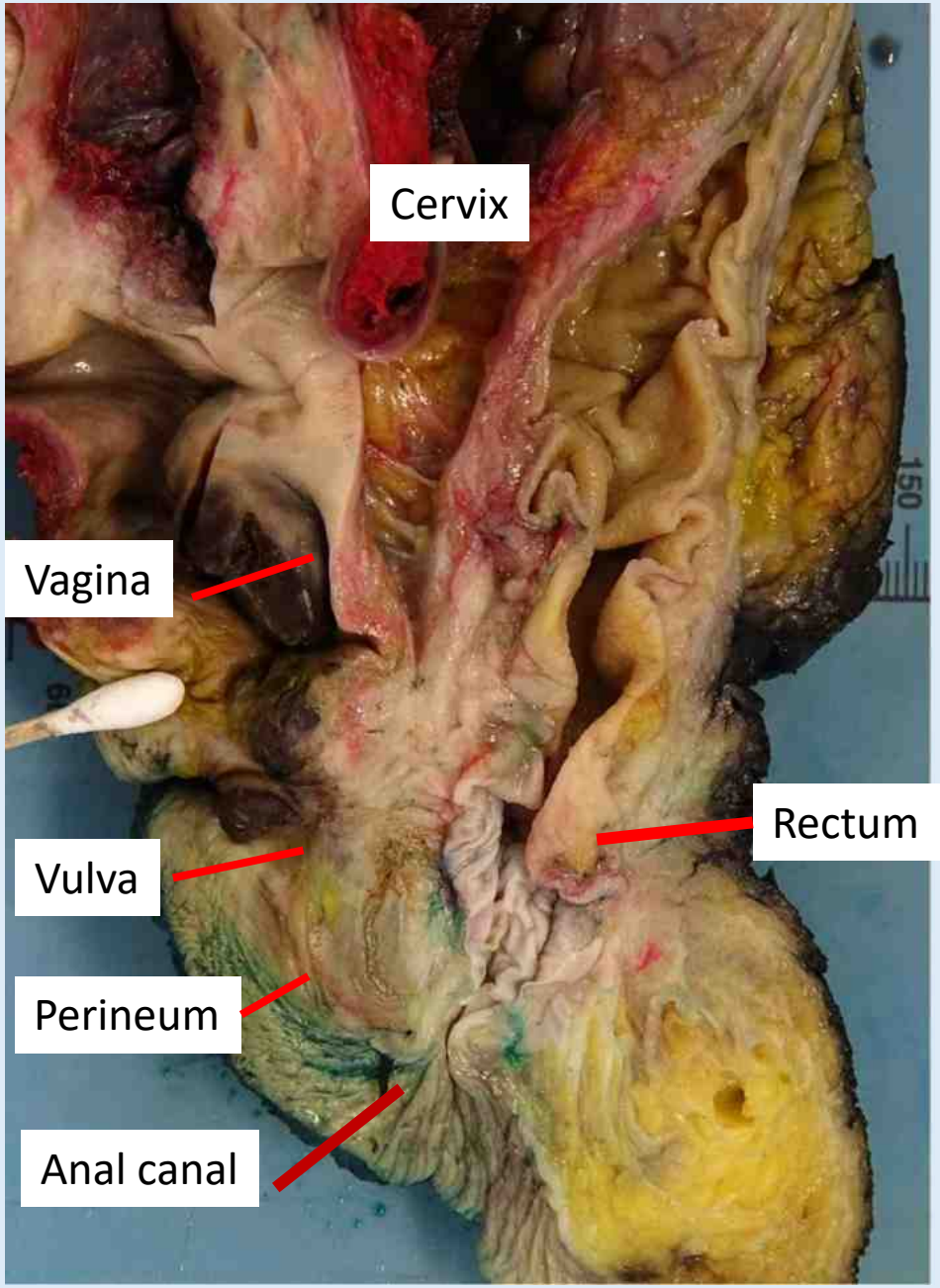
Cervix
Vagina
Rectum
Vulva
Perineum
Anal canal

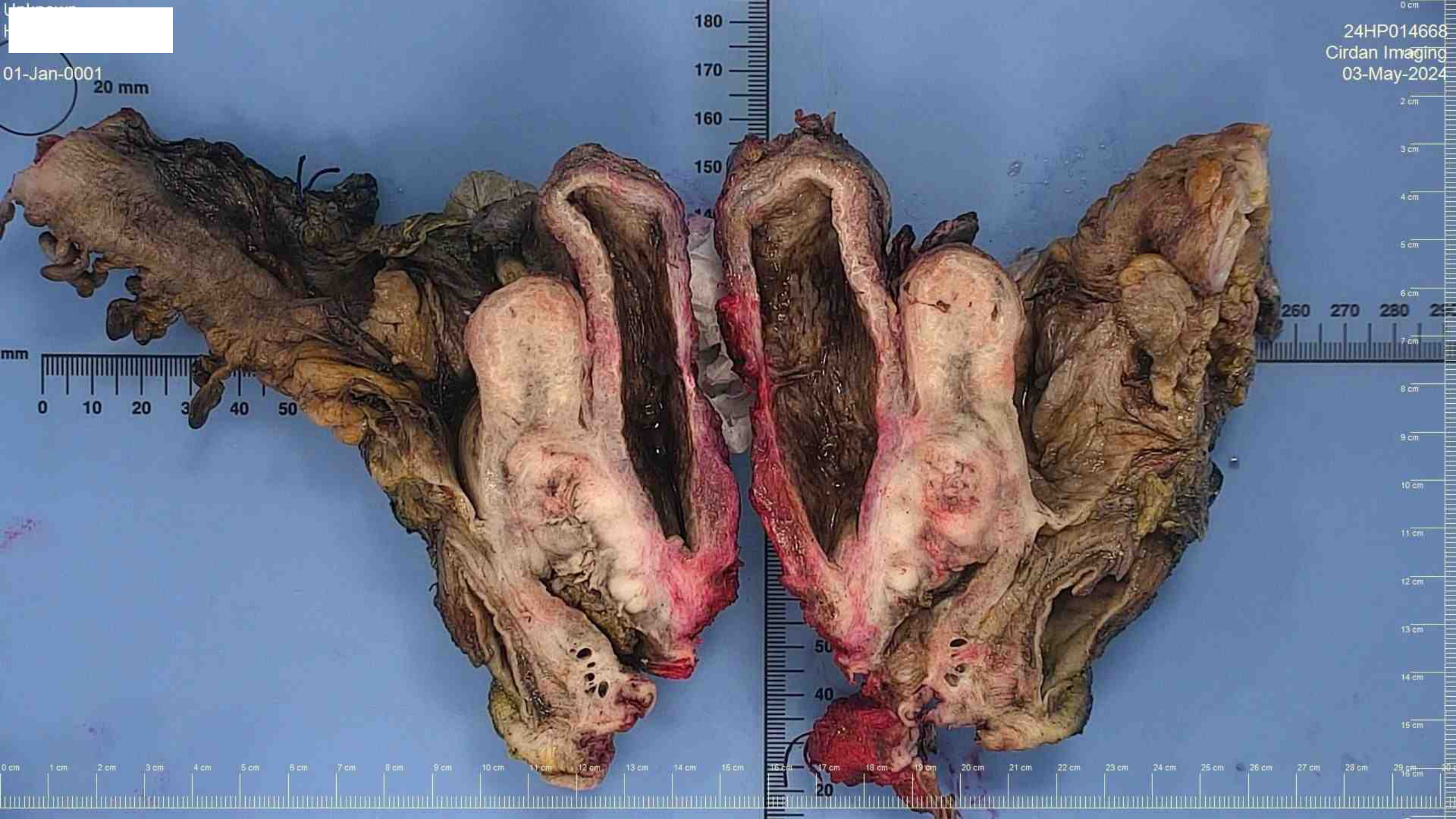
01-Jan-0001
20 mm
24HP014668
Cirdan Imaging
03-May-2024


01-Jan-0001
24HP014668
Cirdan Imaging
03-May-2024

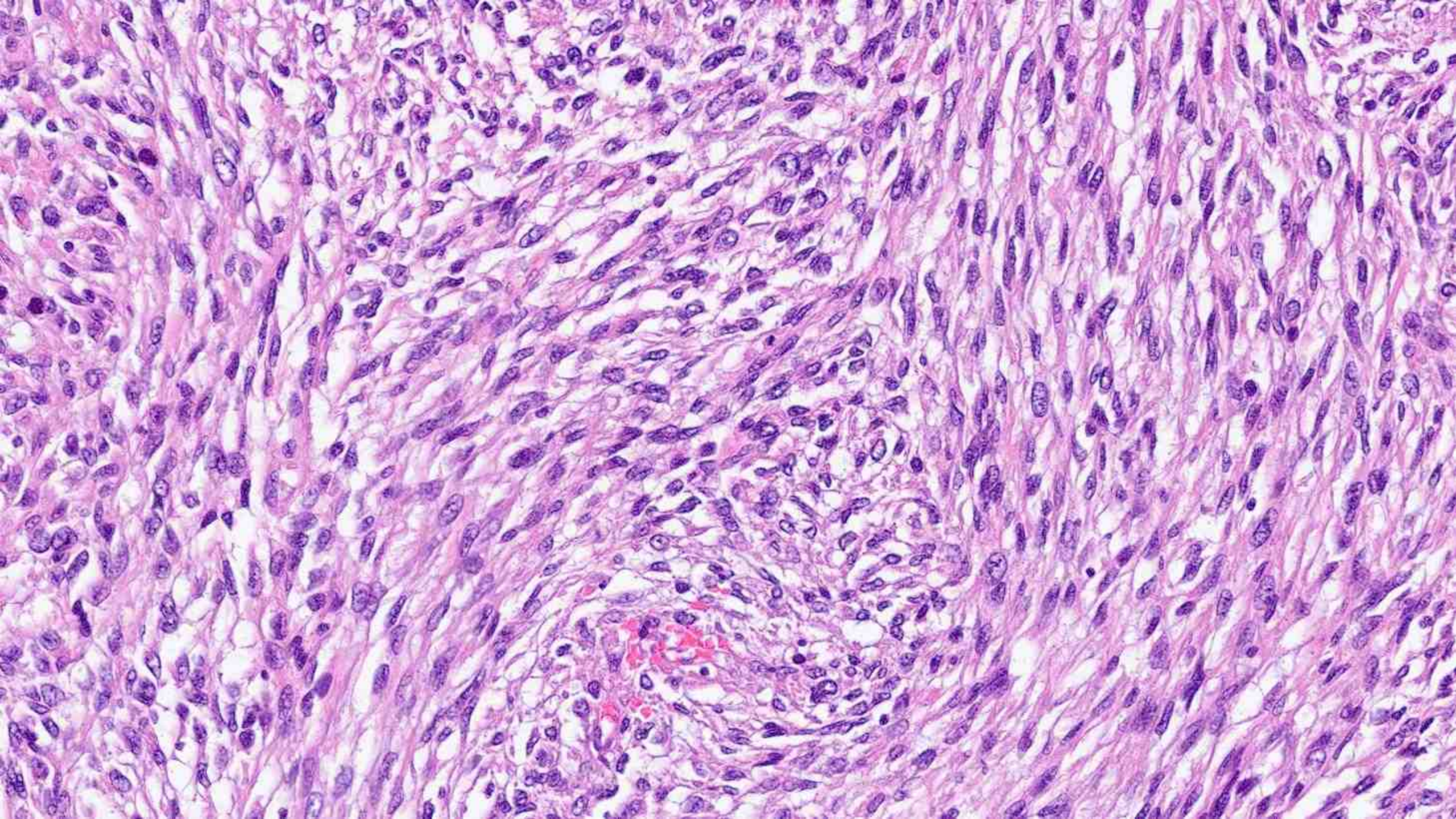

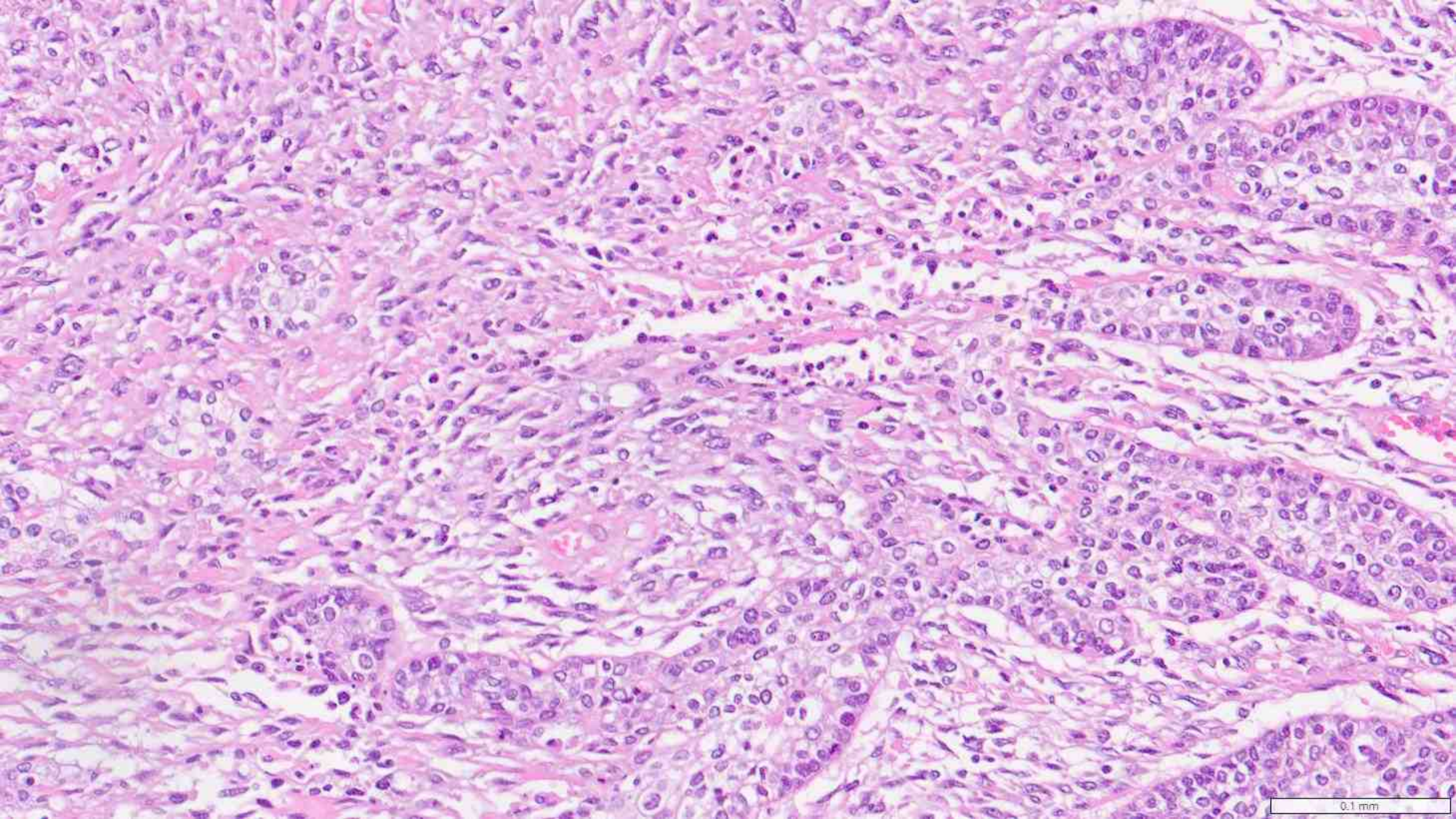
0.1 mm

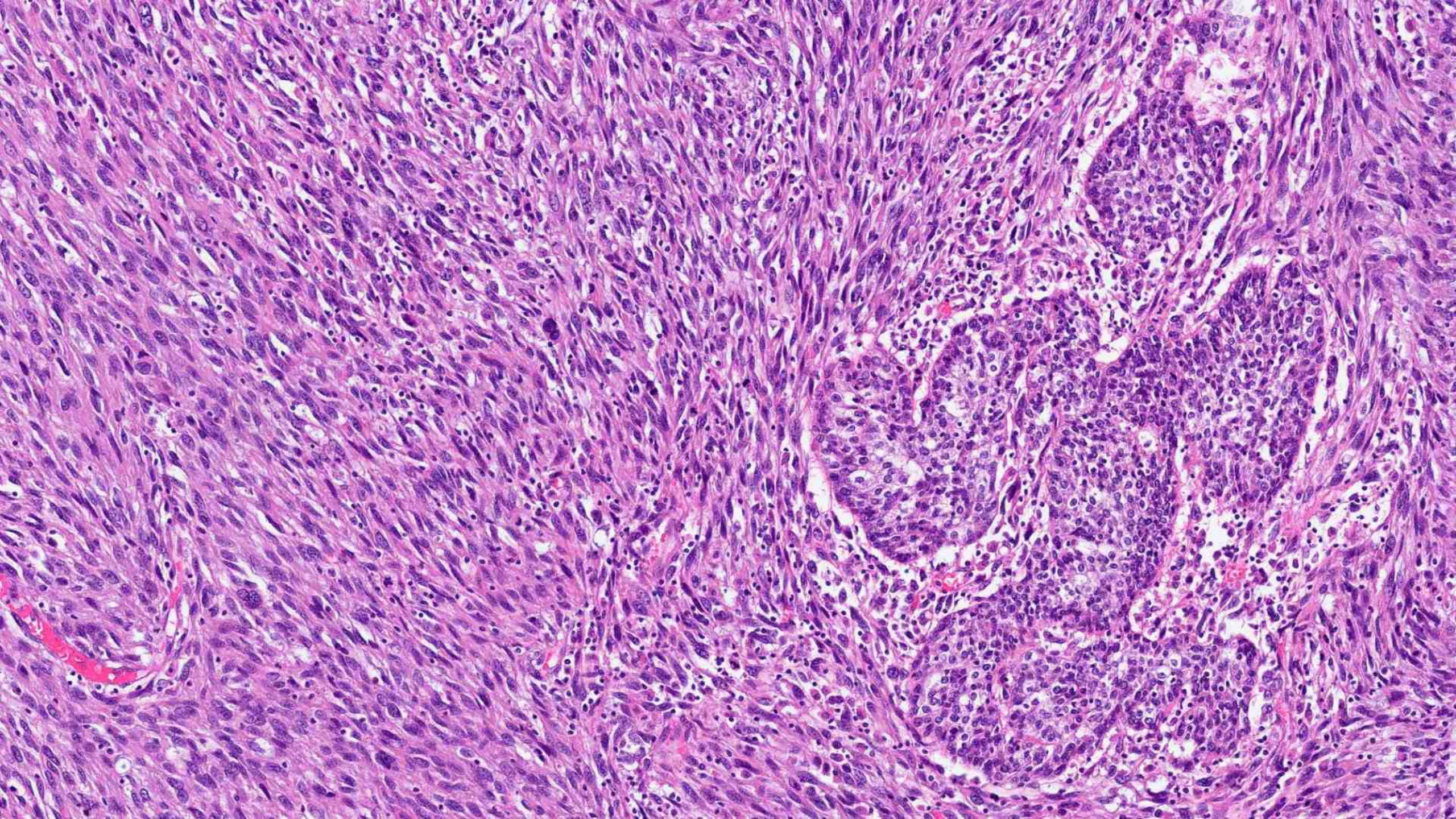

Recap- handling of pelvic exenterations

- **Identify and orientate** key structures: uterus, vagina, bladder, rectum, ureters, urethra, anal canal
- **Photograph the intact specimen** before sectioning
- **Ink margins** using different colours for radial soft tissue margins
- **Measure** uterus and bladder in 3 dimensions
- **Length and diameter** range for any tubular organ structure -rectum, vagina, ureters, urethra

Block selection –use mega blocks if possible

- **At least 4-6 sections of the tumour** including:
  - **Deepest invasion** (record depth and tissue type involved)
  - **Tumour-normal interface** to assess local spread
  - **Fistulous tract** (if present)
  - **Necrotic/fibrotic areas** to assess for treatment response in neoadj setting

- **Margin Assessment**
  - **Vaginal cuff margin** -shave or cruciate
  - **Radial soft tissue margins –** anterior, posterior, right and left lateral
  - **Rectal margins** -proximal and distal
  - **Ureteric and urethral** margins

- **Background** normal-1-2 representative sections of uterus, adnexa, rectal, bladder mucosa

Vaginectomies

Removal of vaginal cancer

Gender affirming surgery- operation notes and liaison with reconstructive surgeon


180
180 190 200 210 220 230
60 70 80 90
22HP2657 - 28 Jan 2022 17:57
100mm


170
160
180
190
200
210
220
60
70
80
90

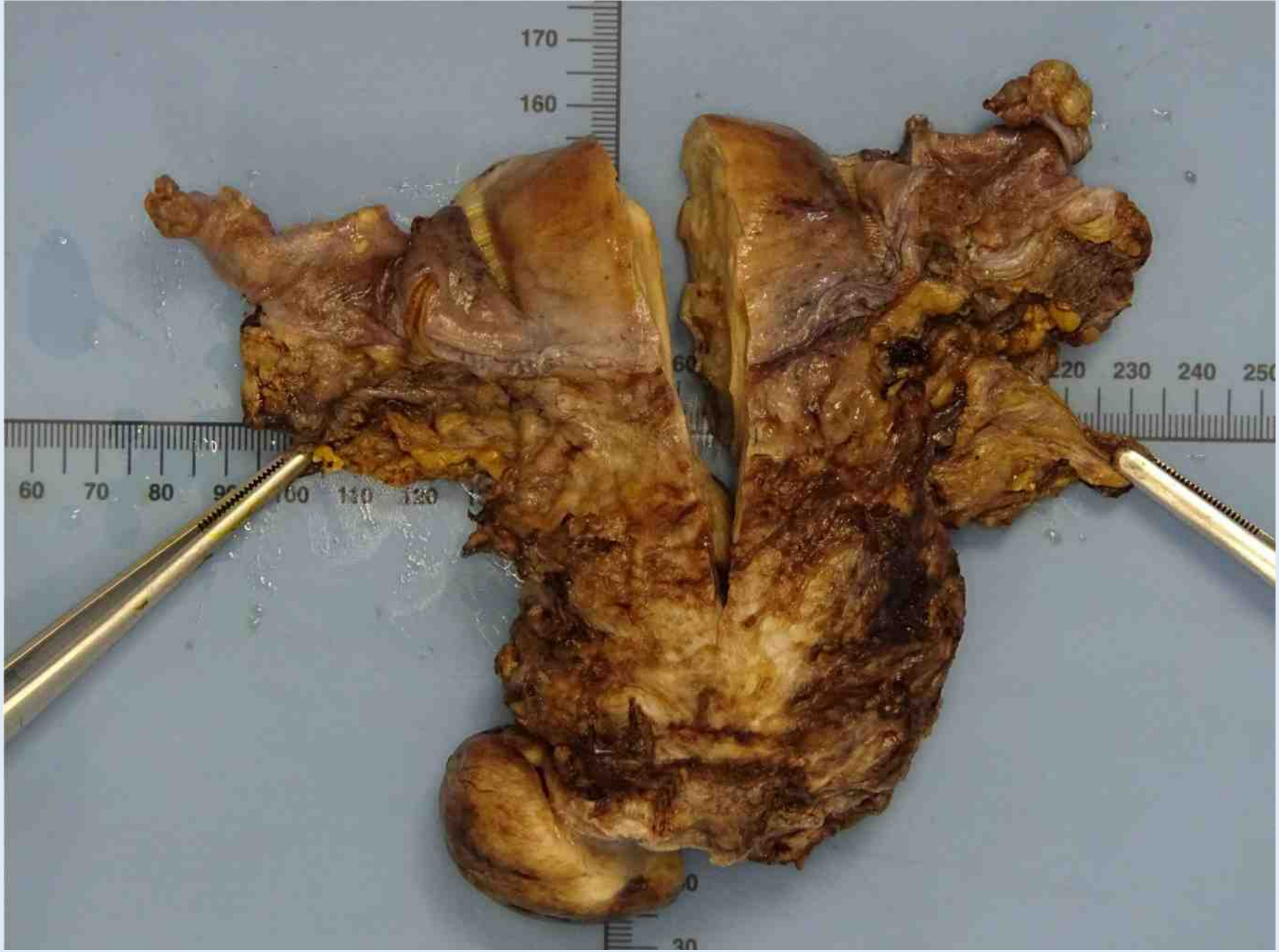
170
160
60
70
80
220
230
240


170
160
150
140
130
180
210
220
230
70
80


170
160
150
140
130
120
70
80
90
100
210
220
230
50
40

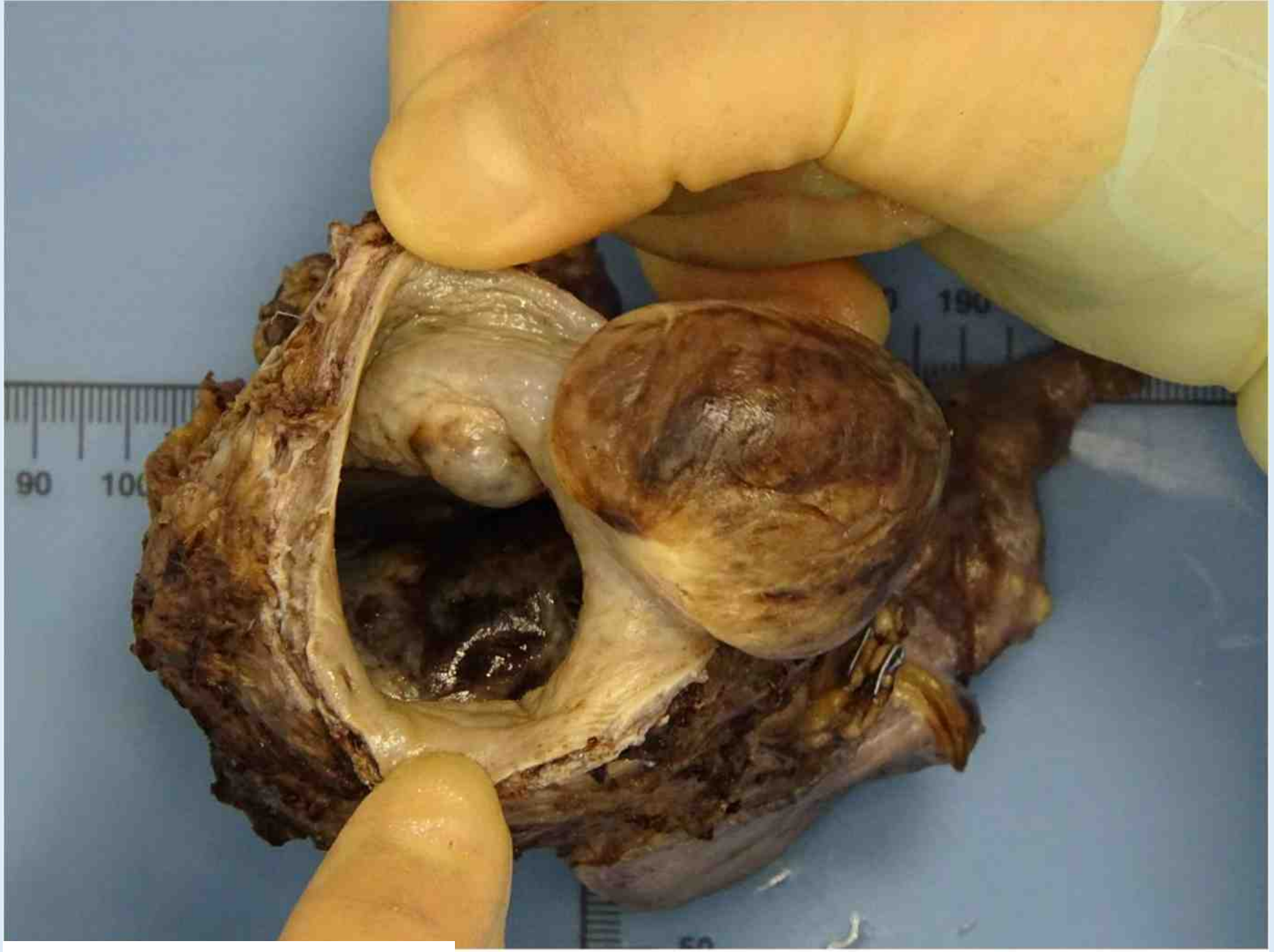
90
50mm


170
160
150
180
190
200
210
220
230
240
70
80
90
100
110
120
130


130
170
180
190
200
70

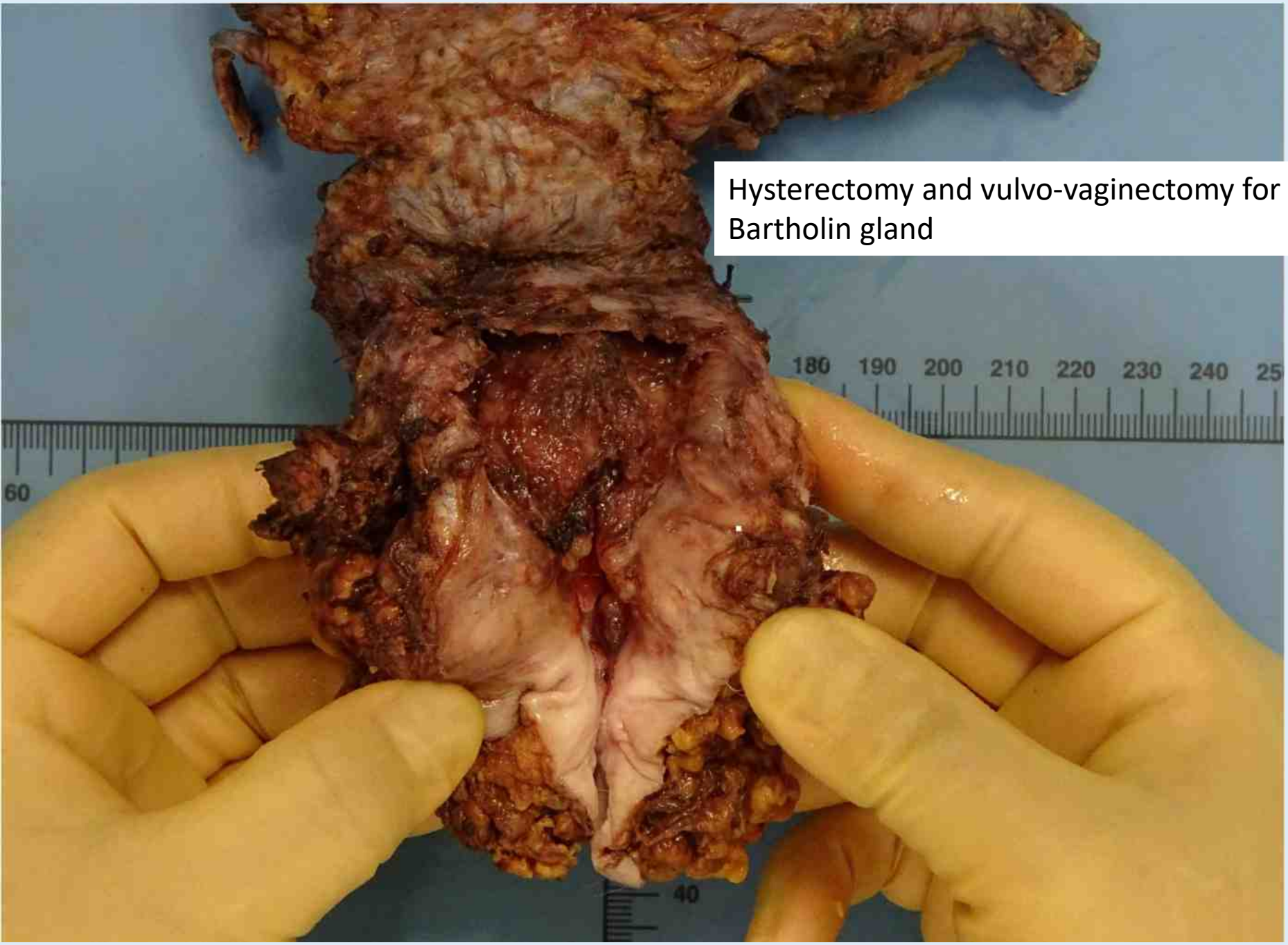

Hysterectomy and vulvo-vaginectomy for mucinous carcinoma Bartholin gland

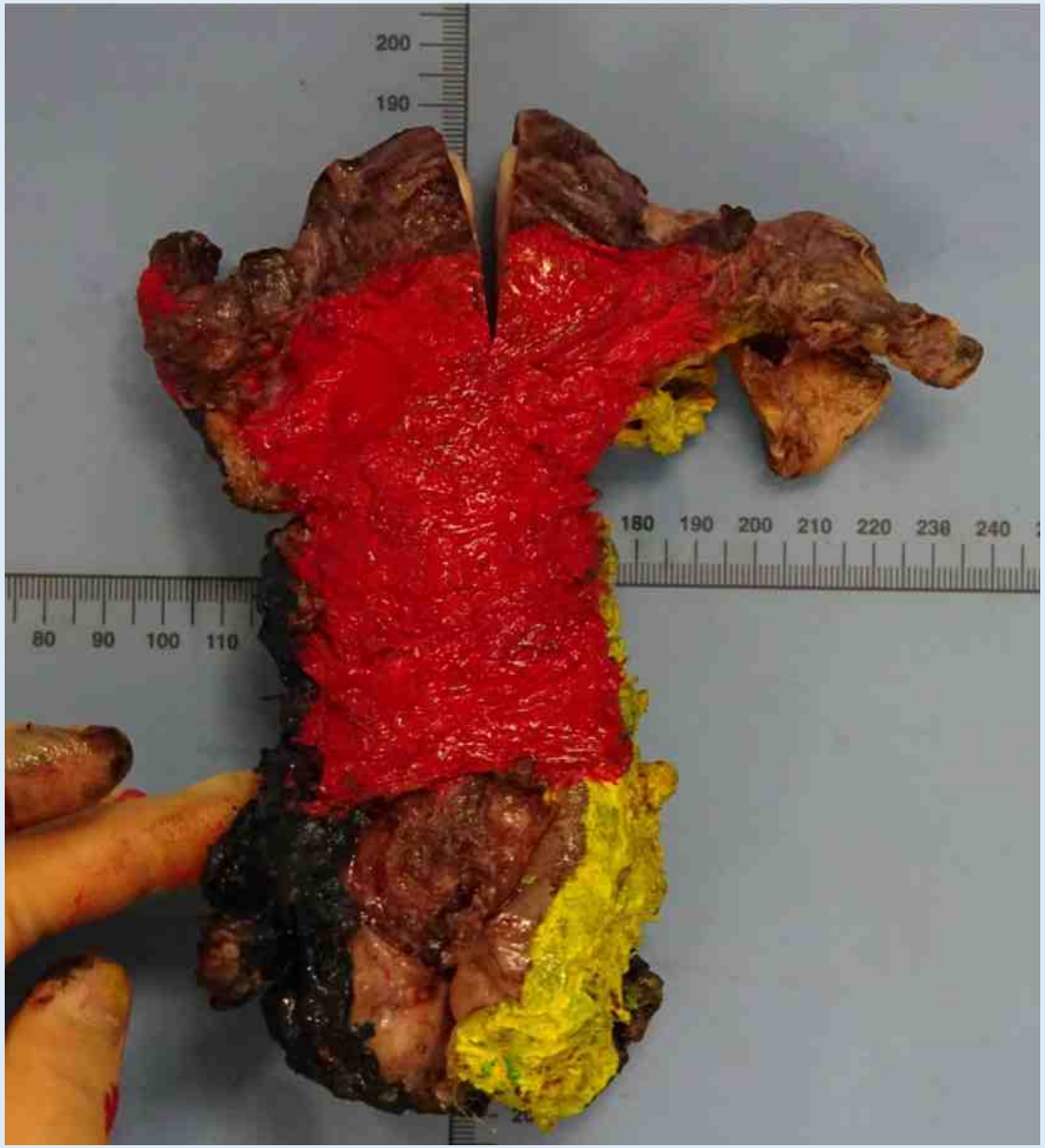
200
190
180 190 200 210 220 230 240
80 90 100 110


200
180 190 200 210 220 230
60 70 80 90 100
20



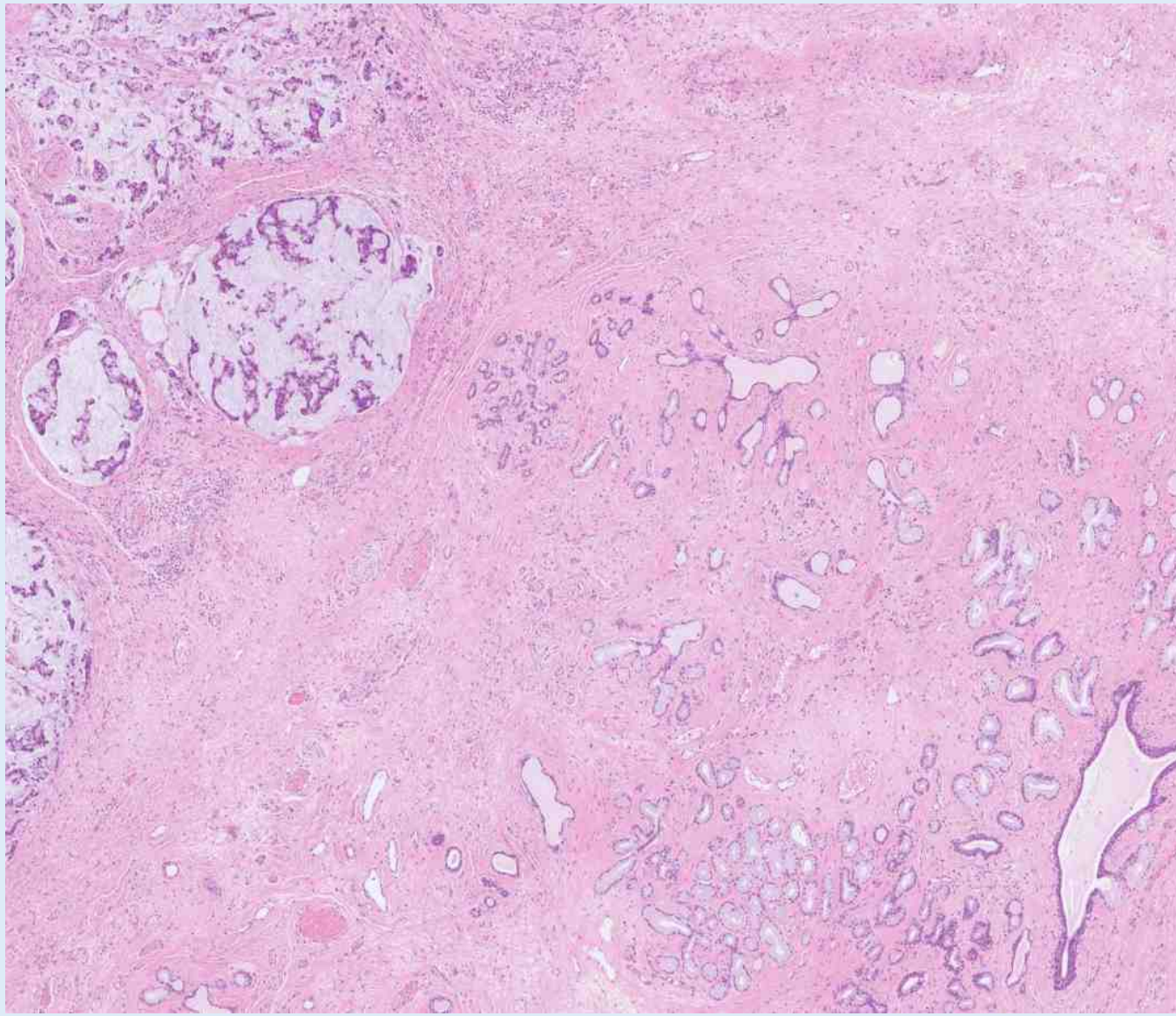

Mucinous carcinoma, Bartholin gland origin

Ovarian tumours

45y
Abdominal pain, distension, ascites and bilateral ovarian masses, raised CA125, suspicious of malignancy

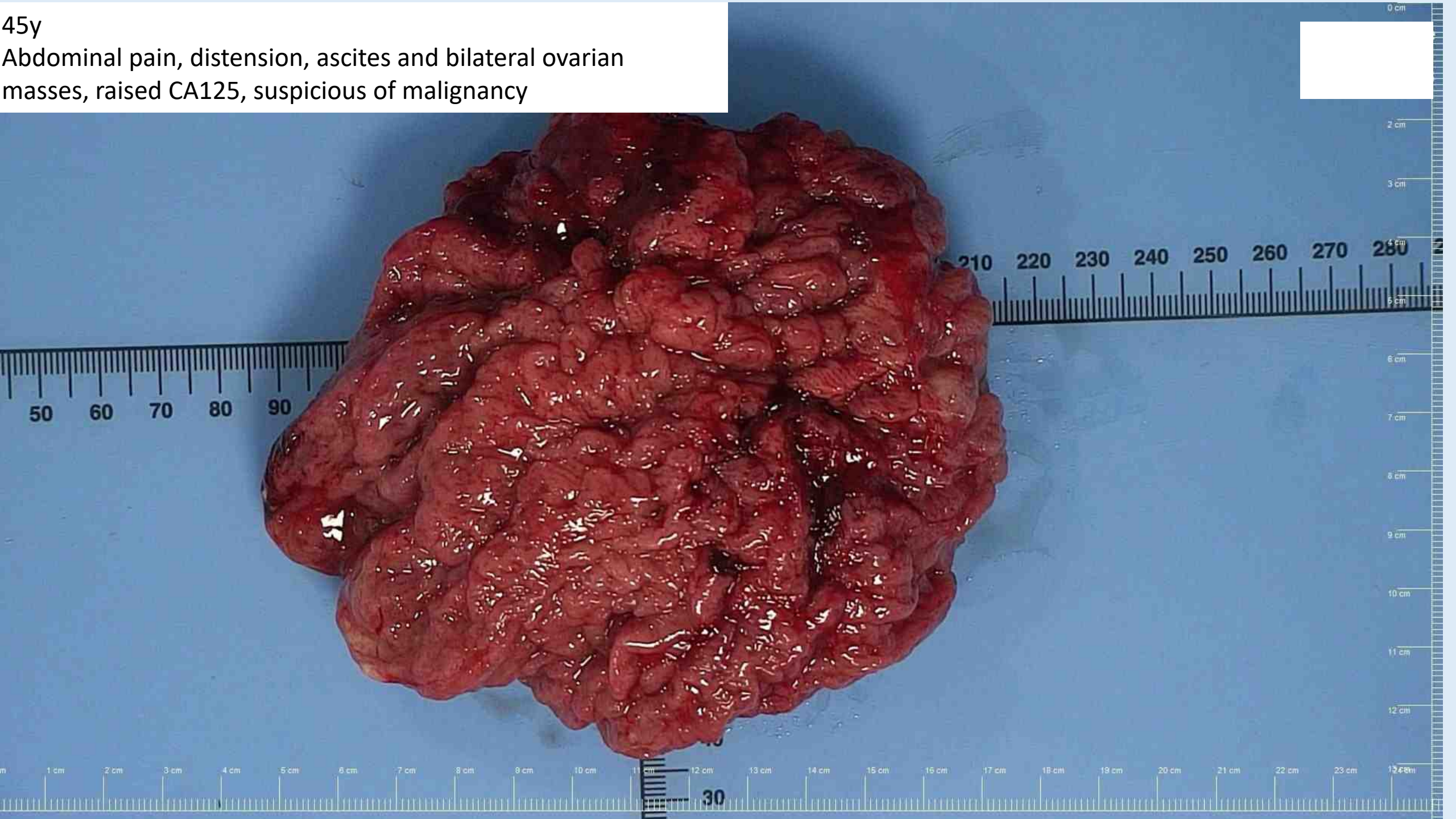

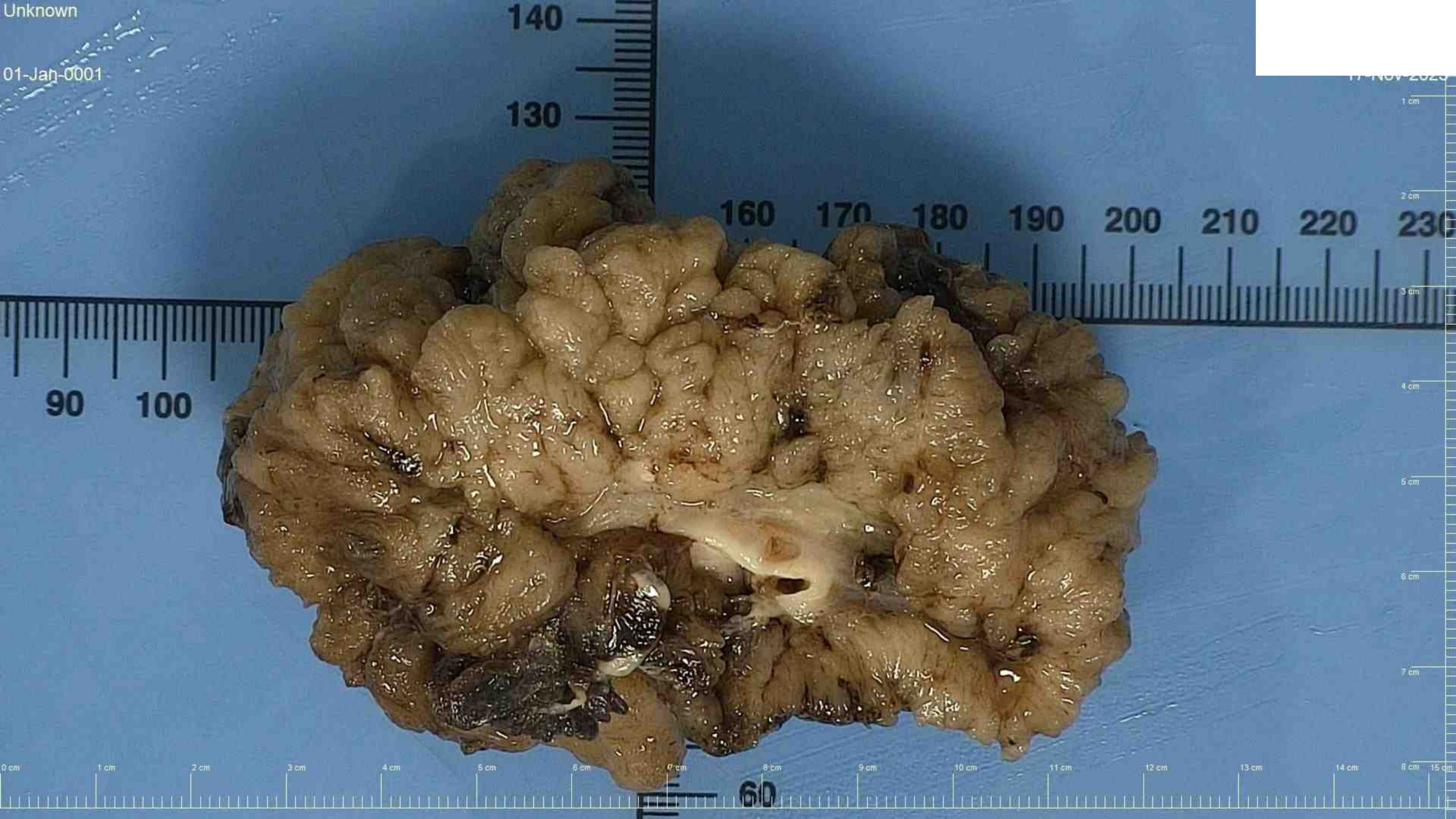
Unknown
01-Jan-0001

Gross Pathology Manual

y The University of Chicago Department of Pathology

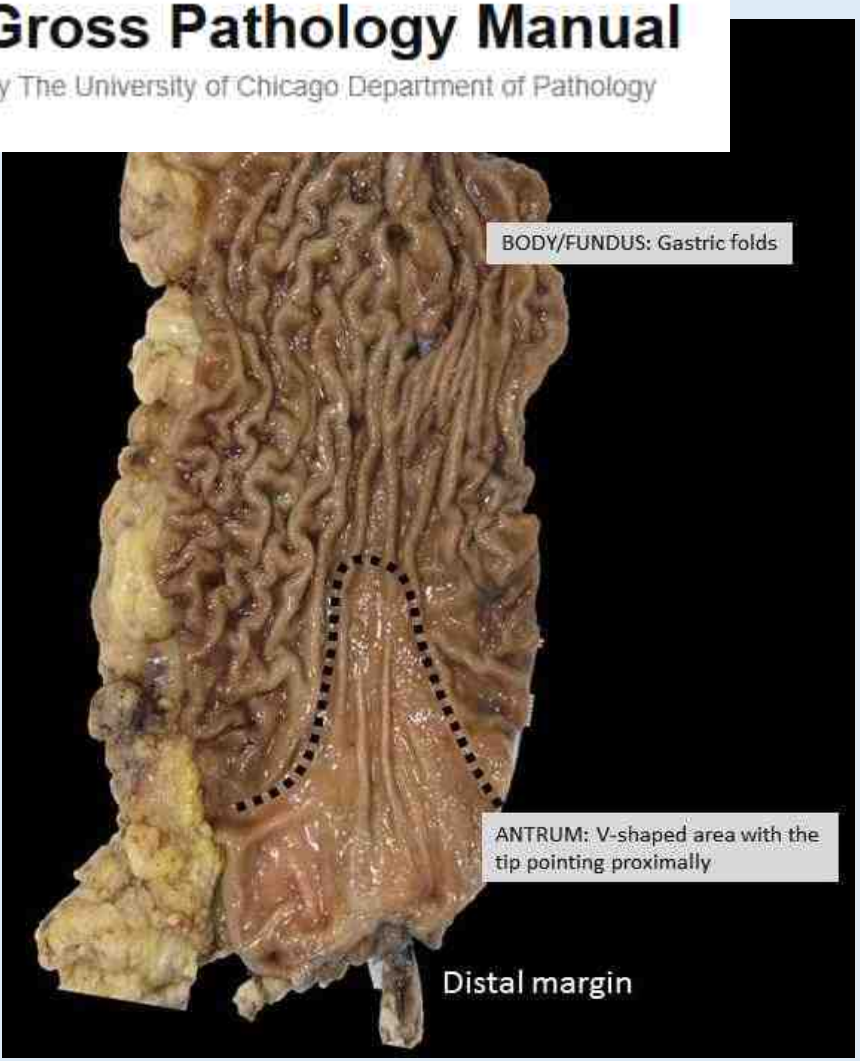



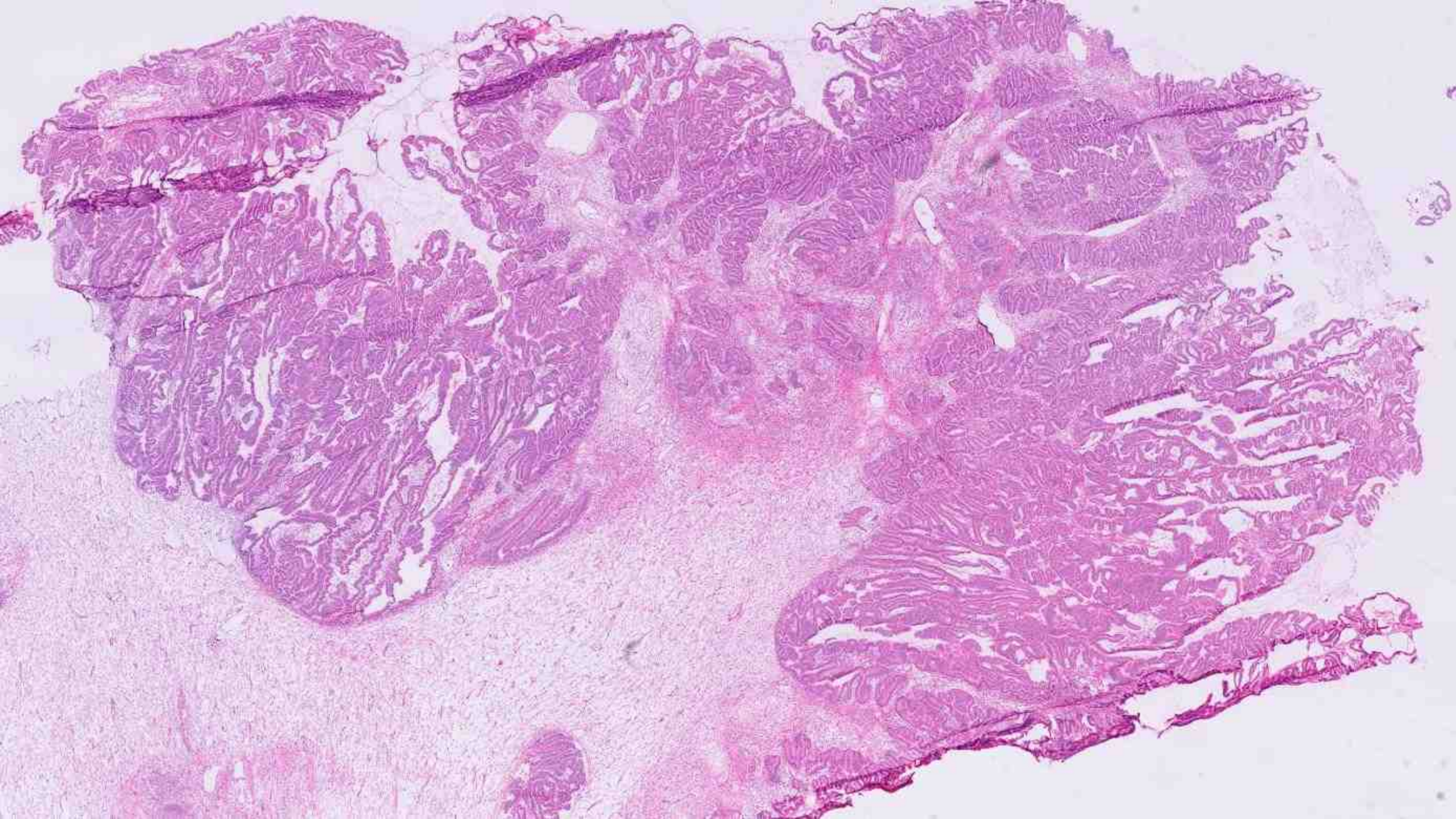

Grade 1 endometrioid ovarian adenocarcinoma

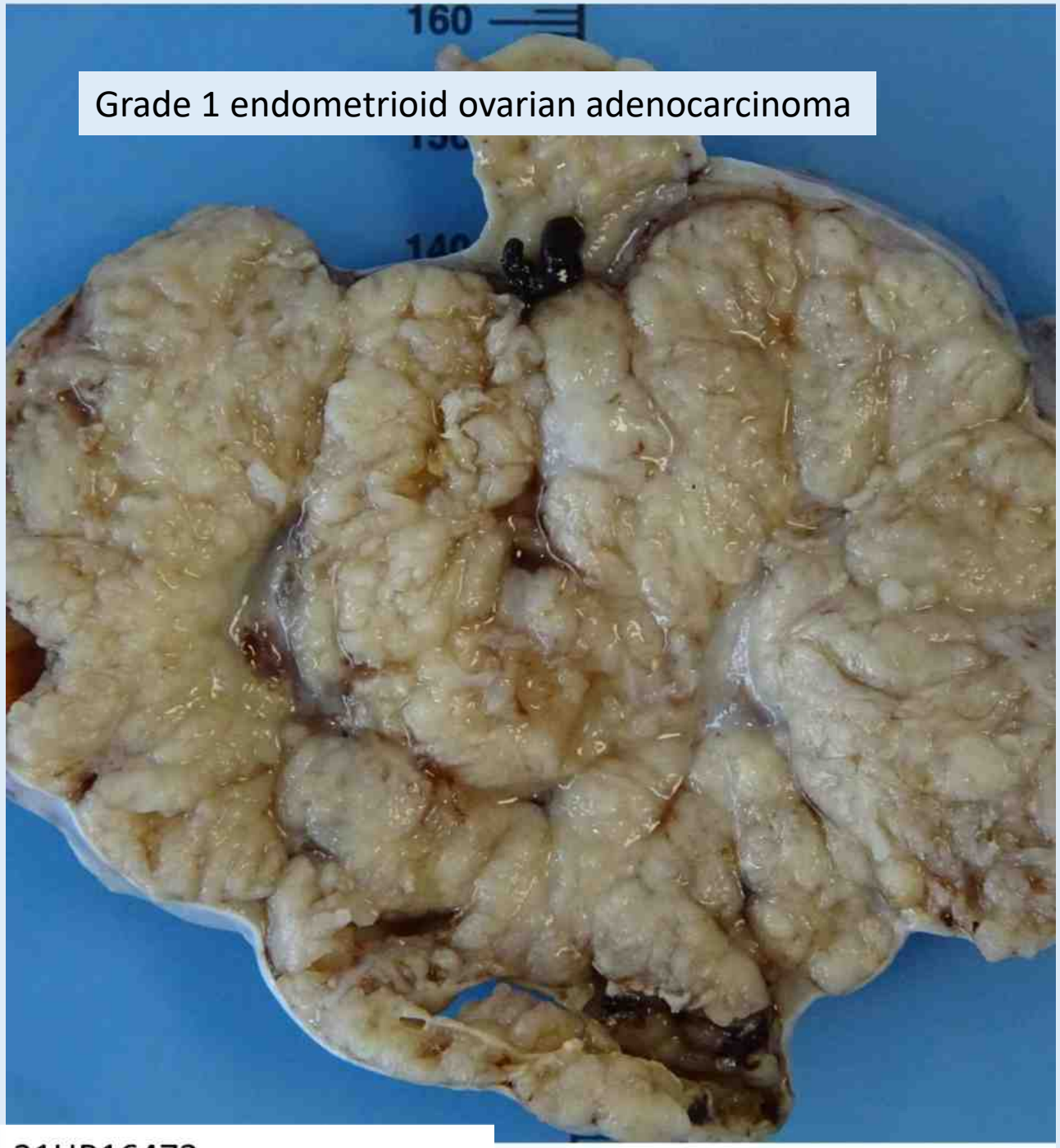



Mesonephric –like adenocarcinoma, ovary

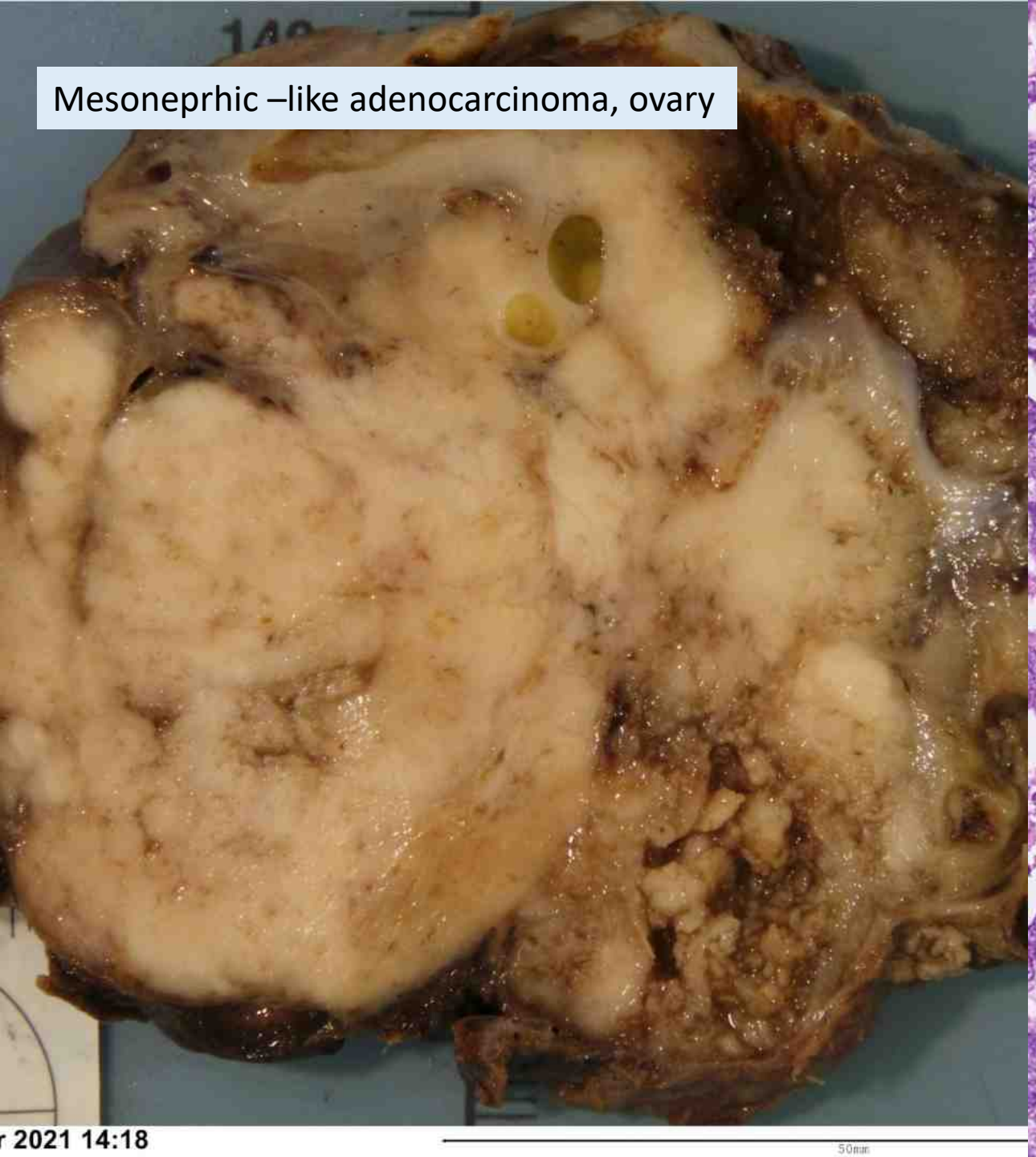

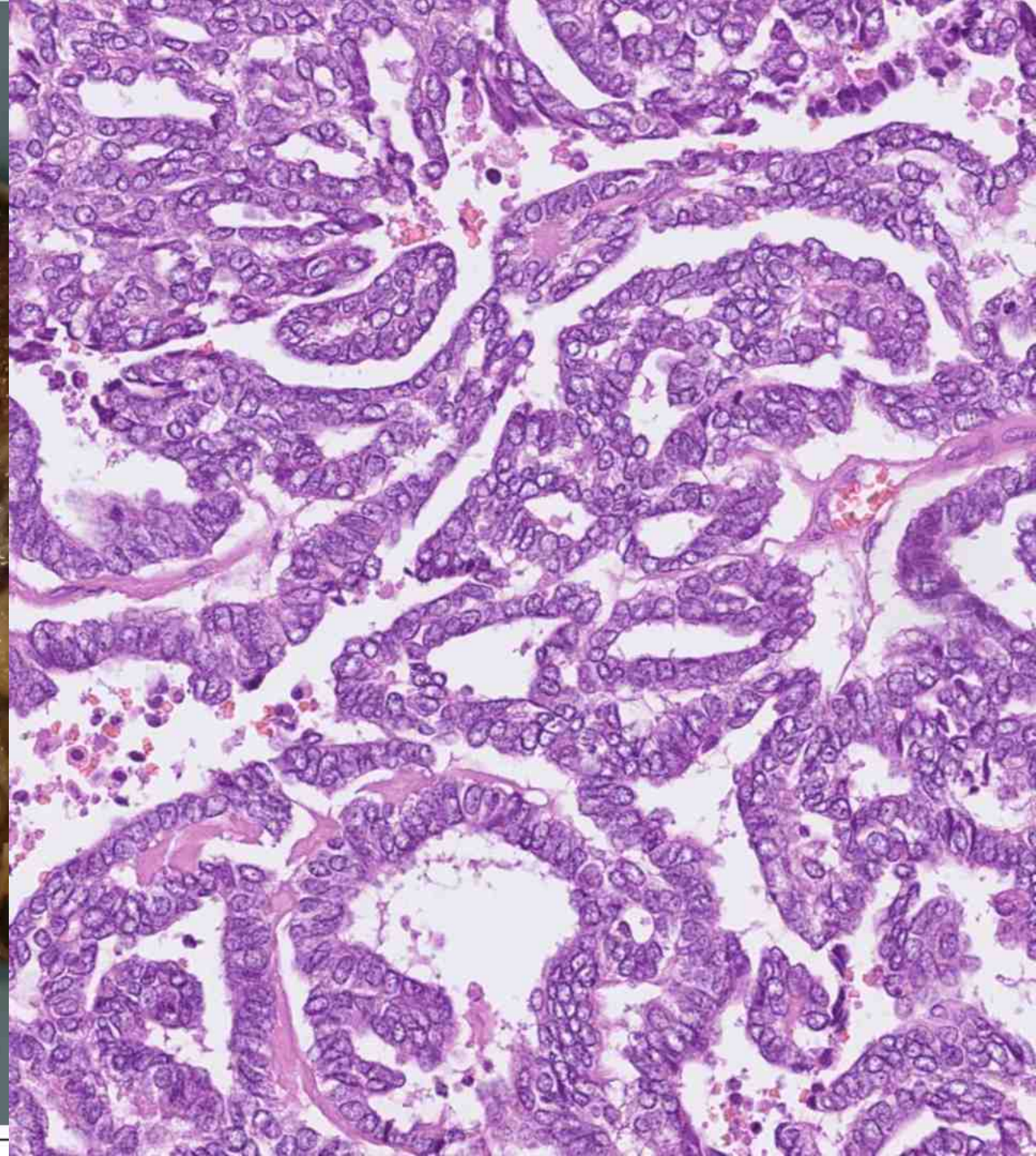

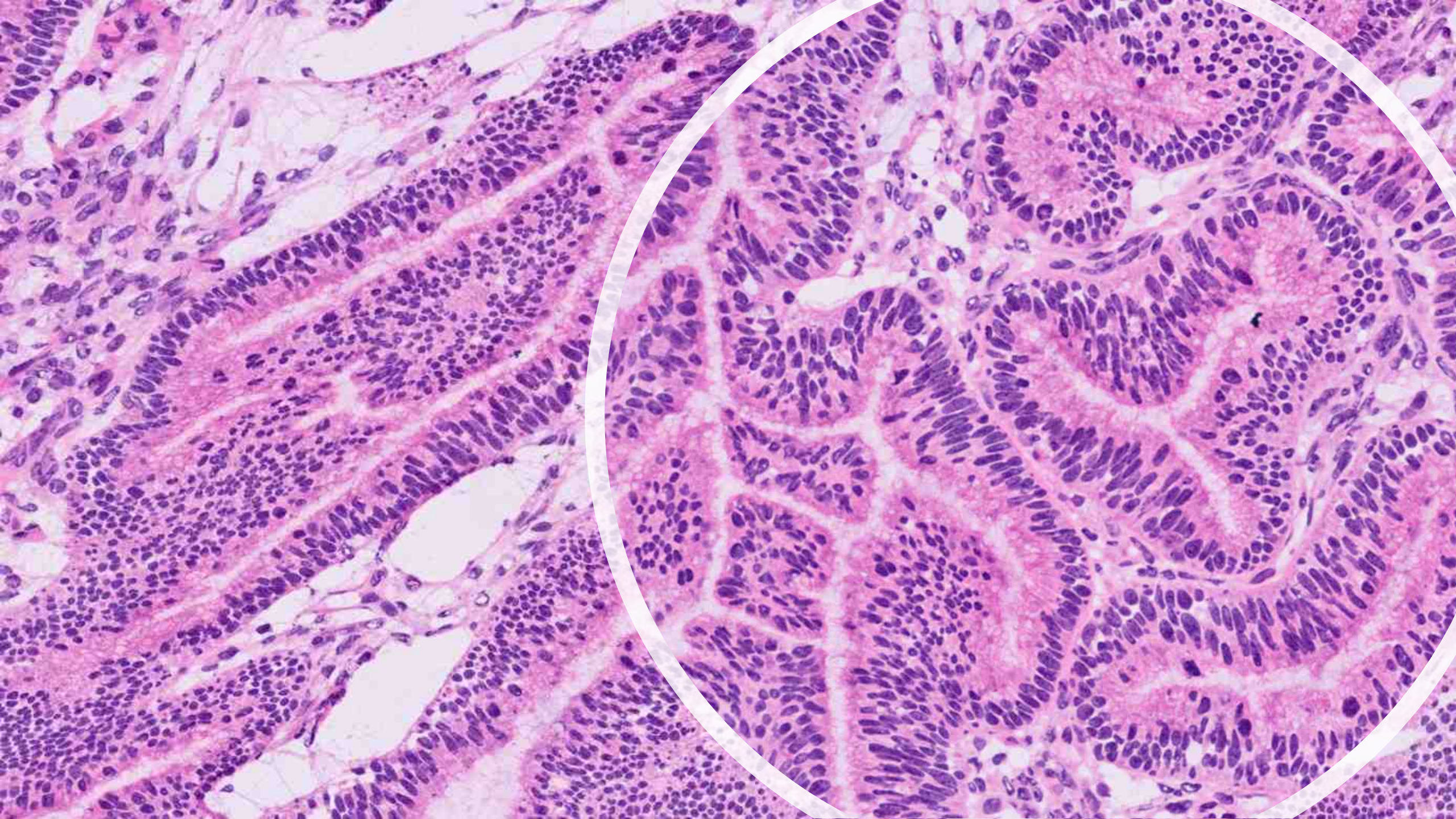


Unknown
01-Jan-0001
23HP036448
Cirdan Imaging
20-Nov-2023

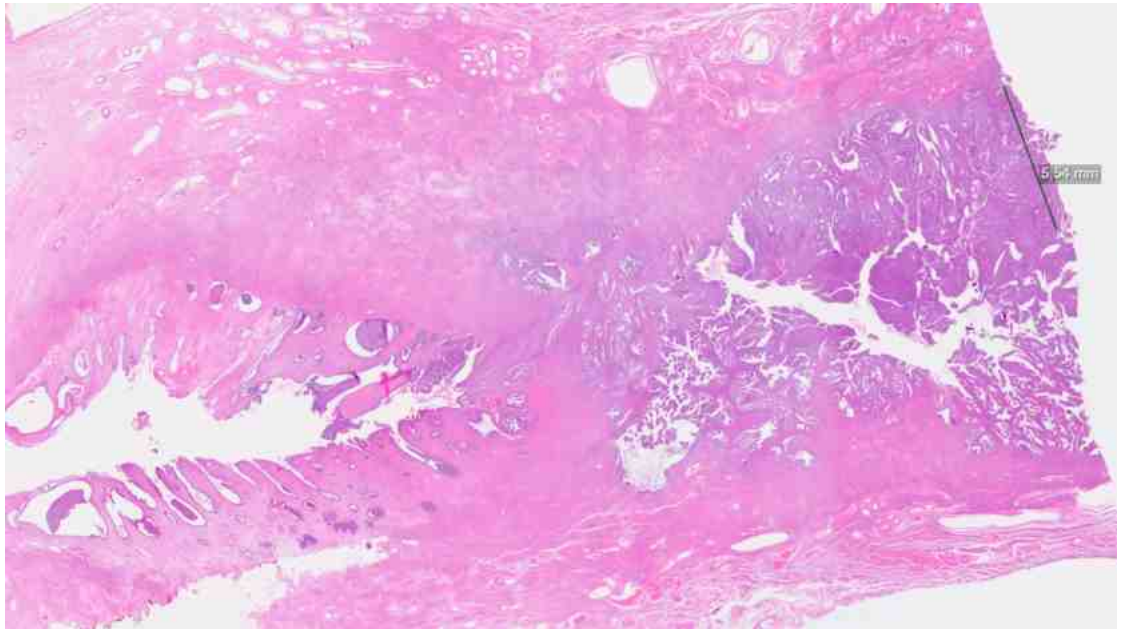

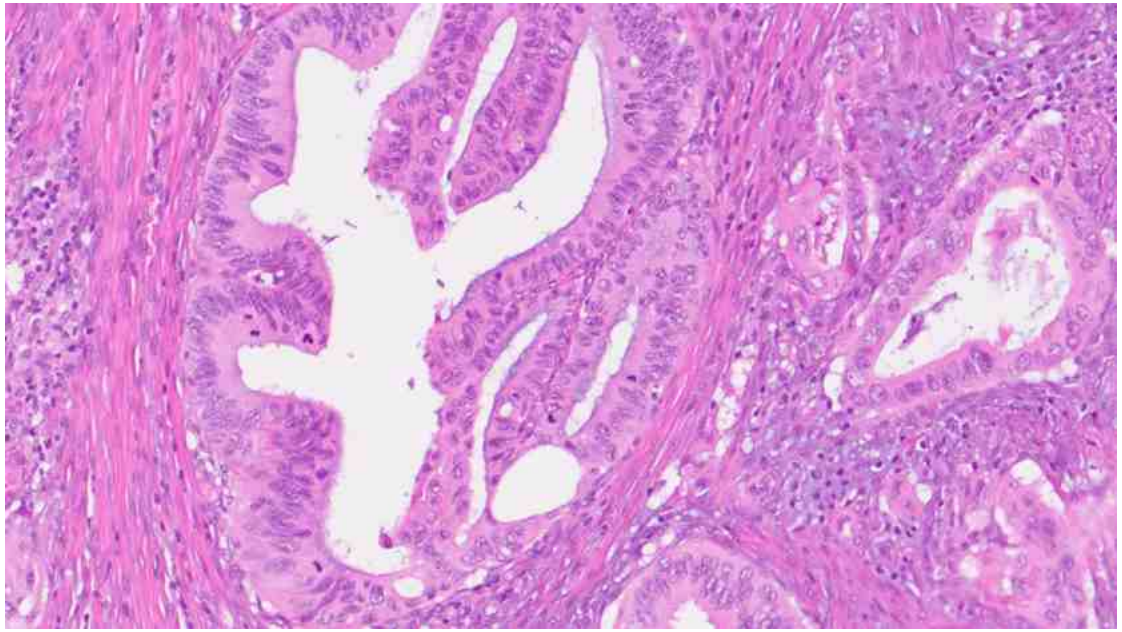

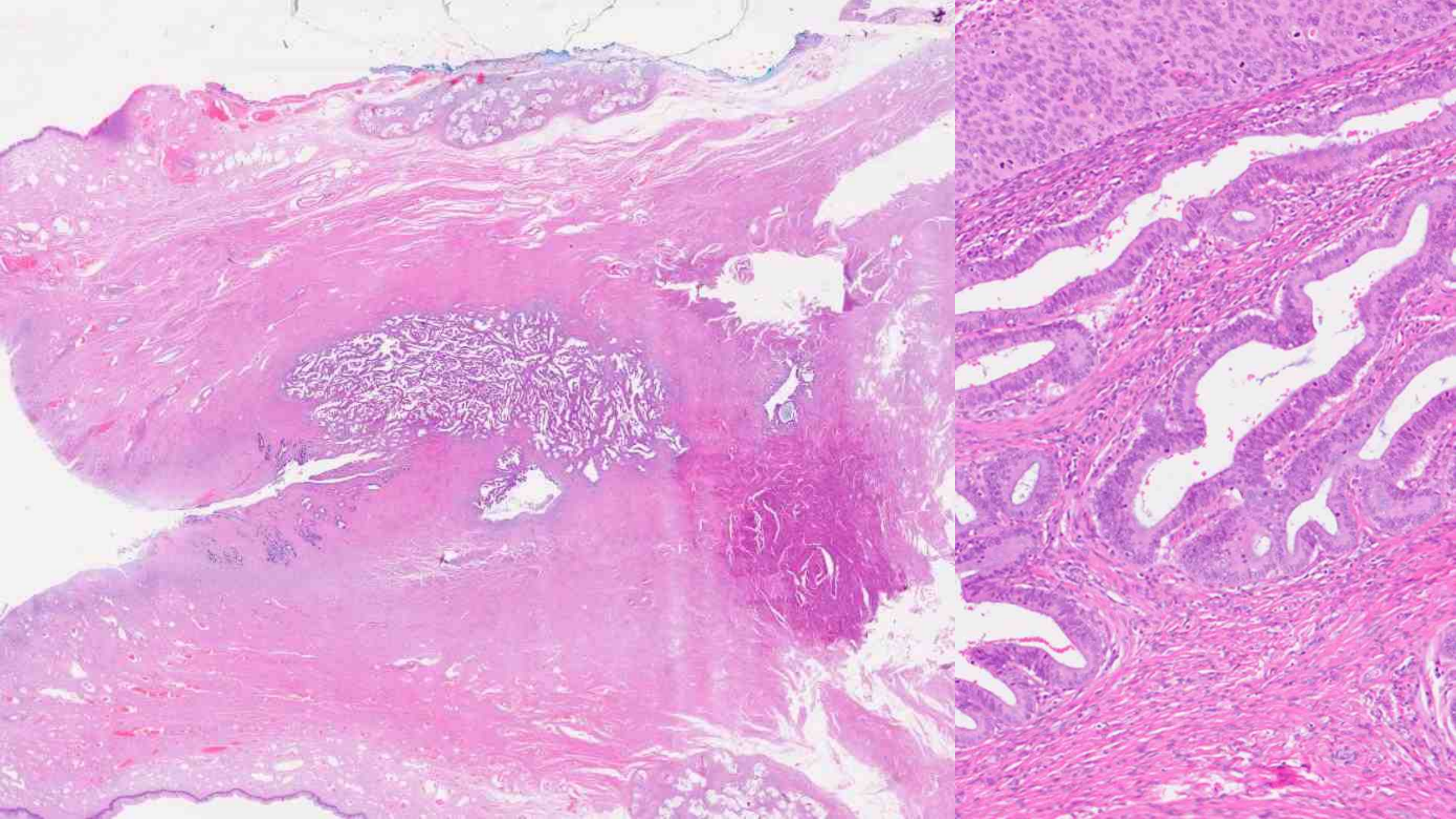

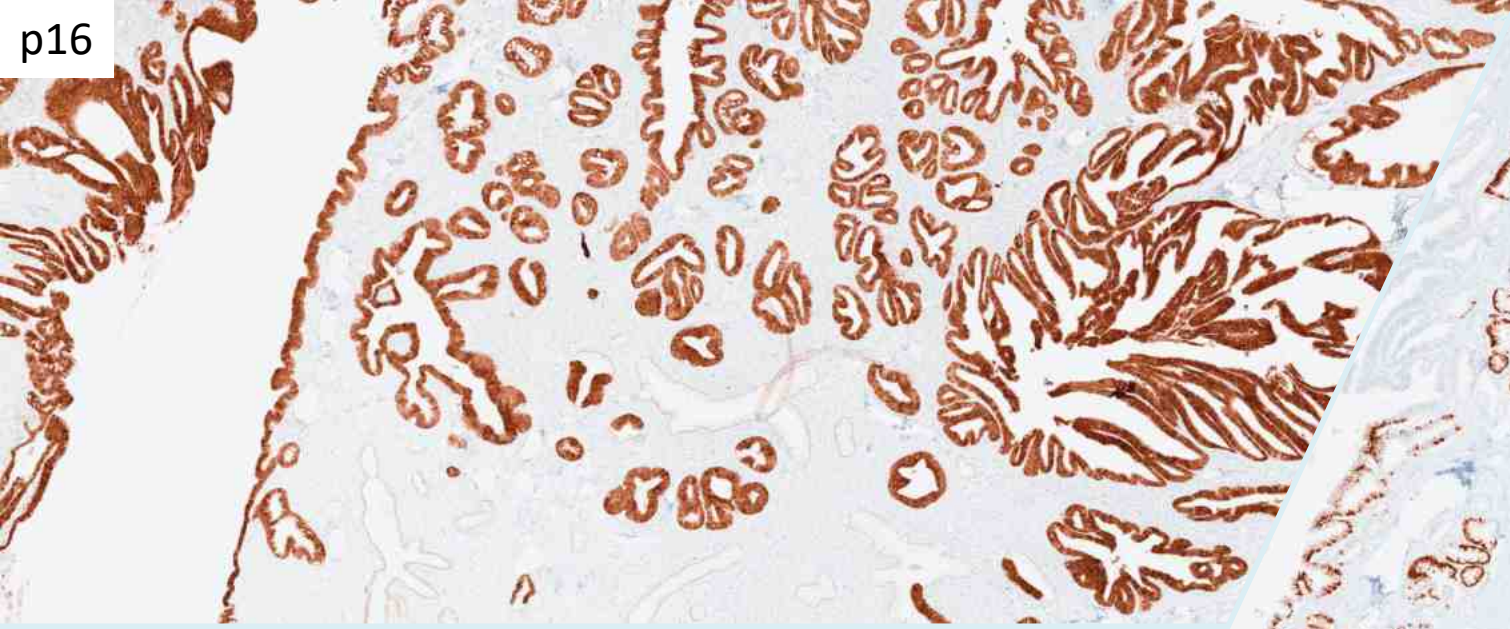
p16

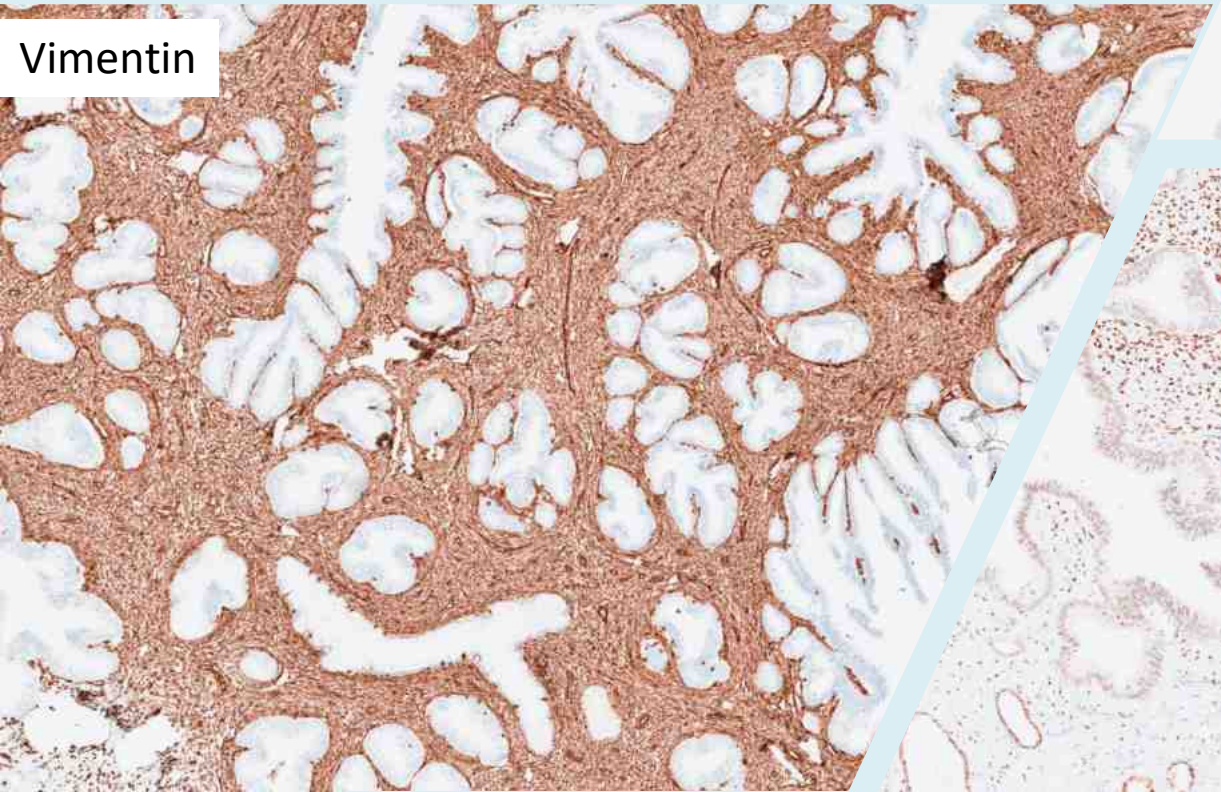
Vimentin

CDX2

Estrogen receptor

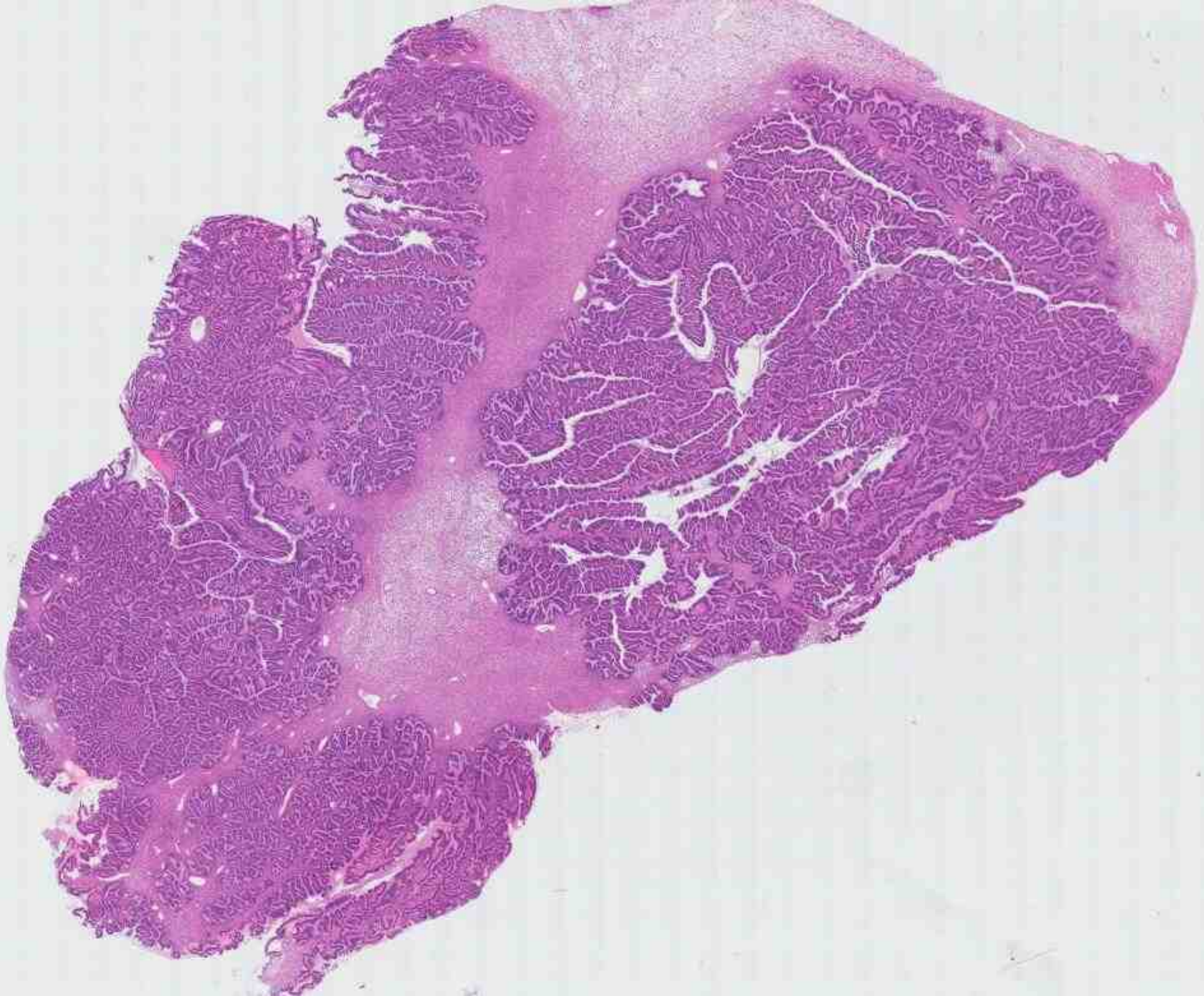

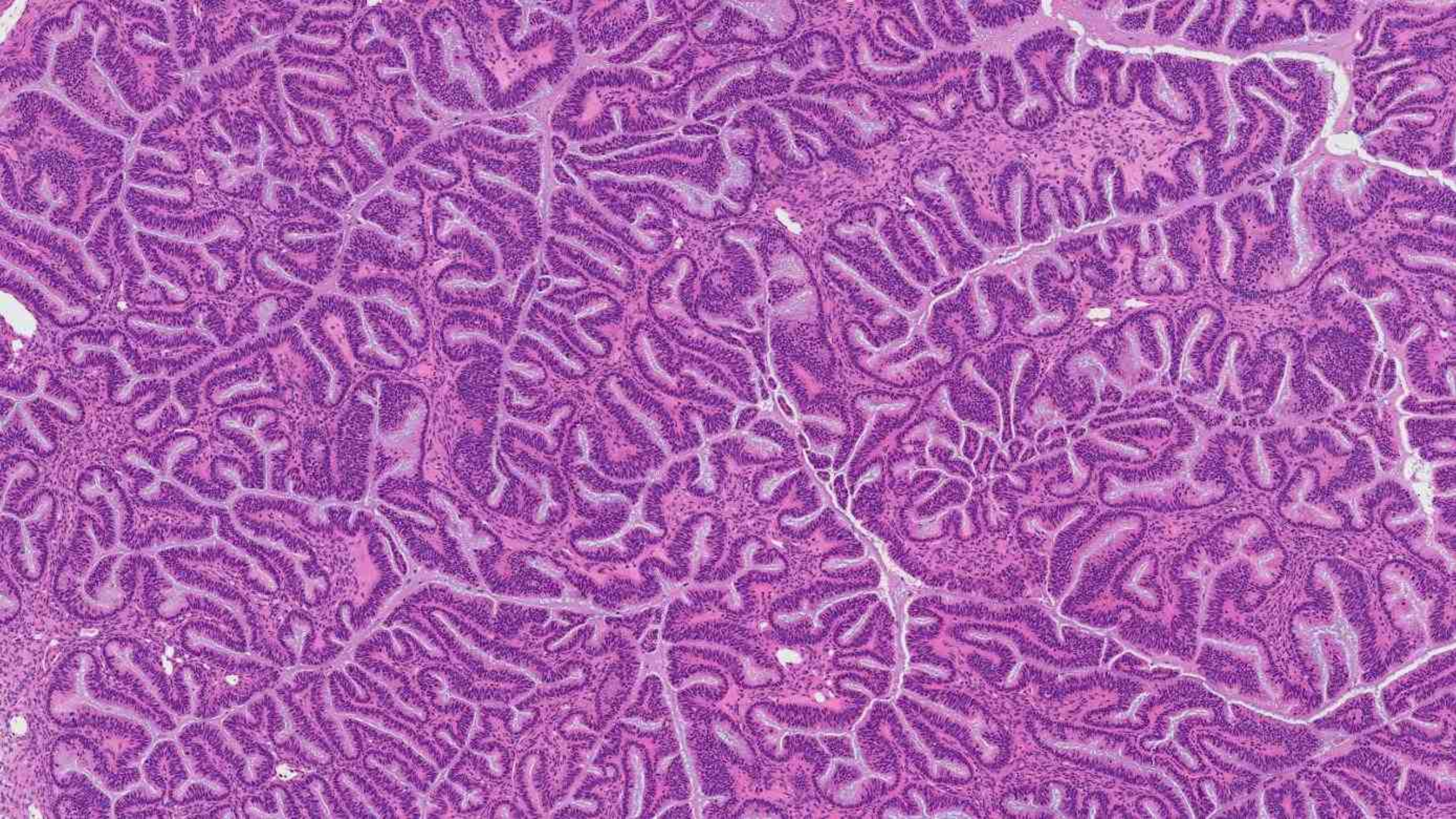

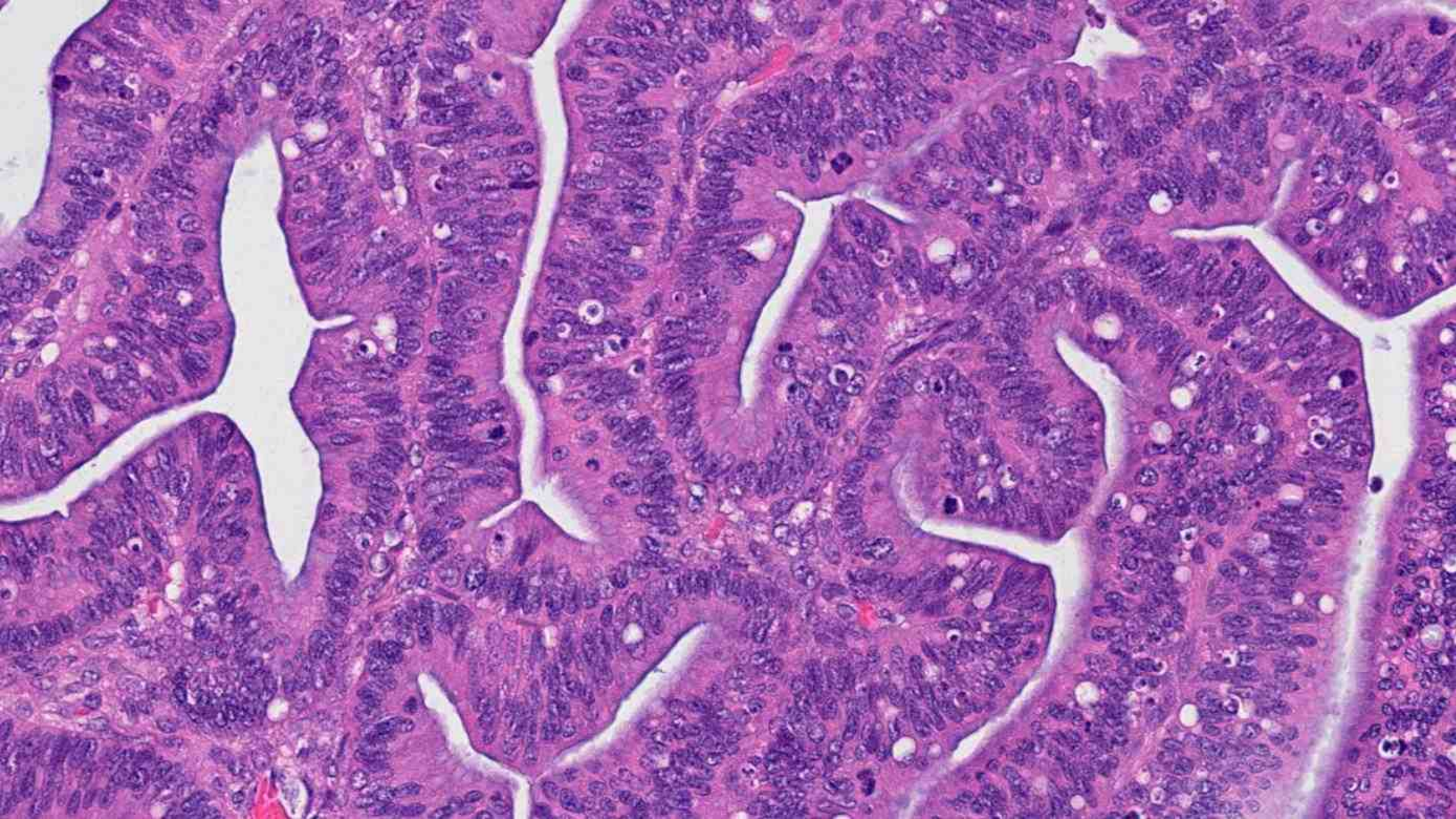

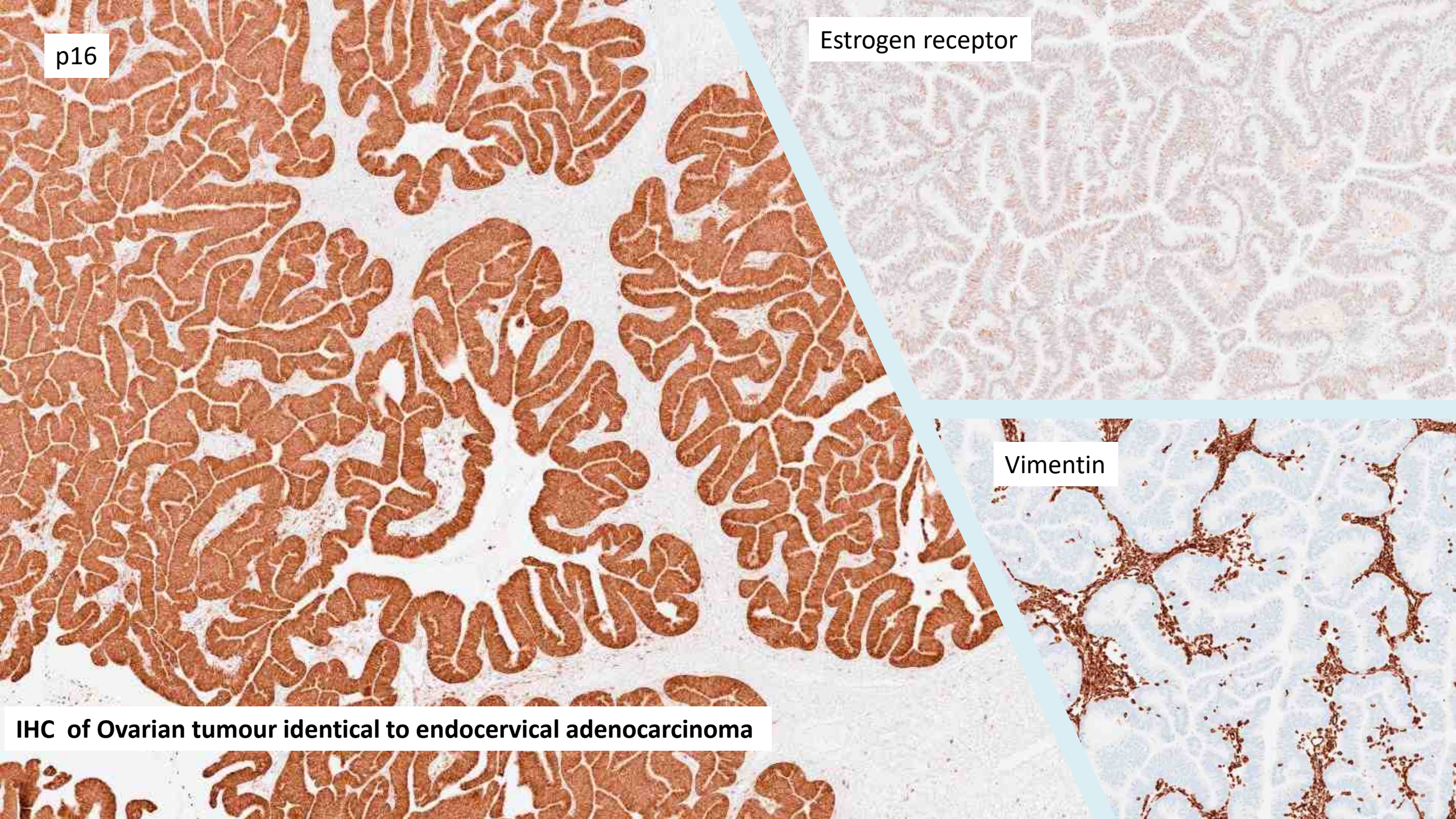

IHC of Ovarian tumour identical to endocervical adenocarcinoma

LLETZ



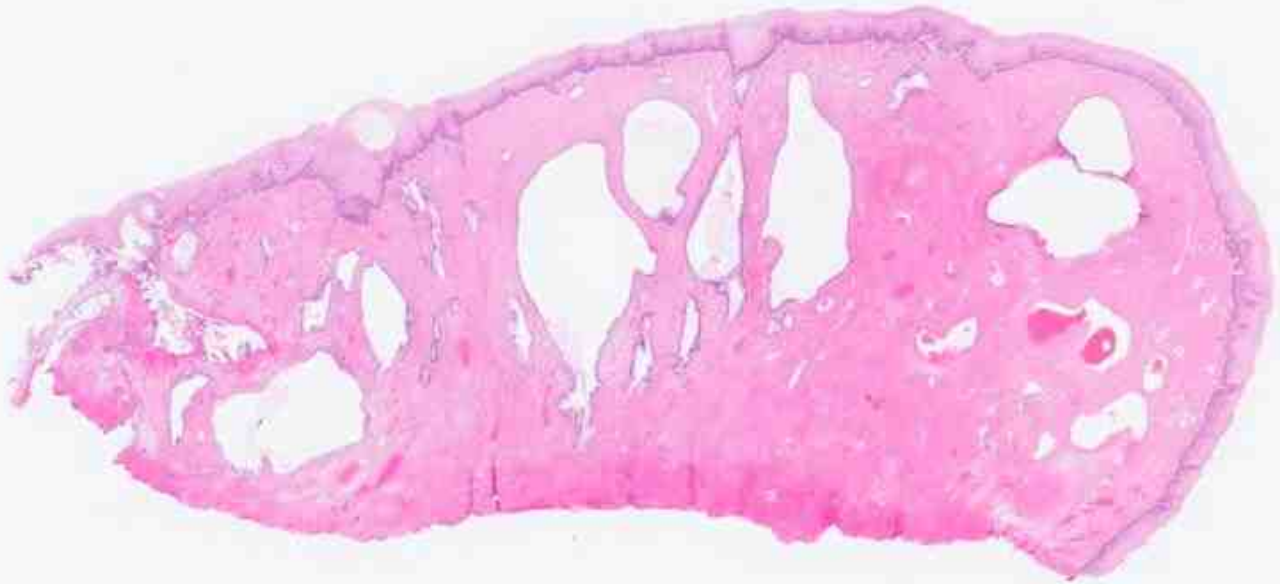

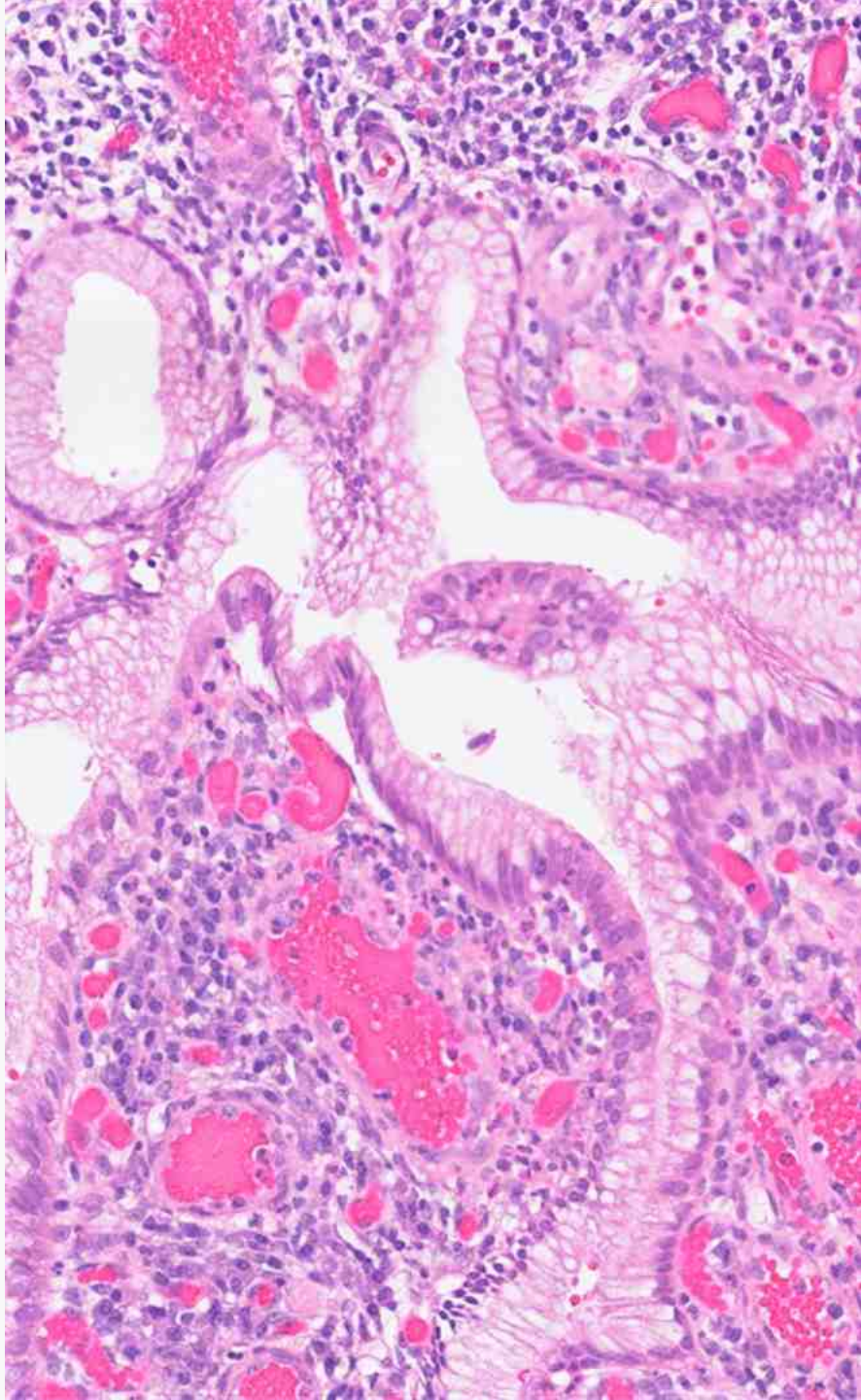



Do not remove adherent blood clot or mucus
Embed any residual blood clot or mucus in pot



2.5 mm

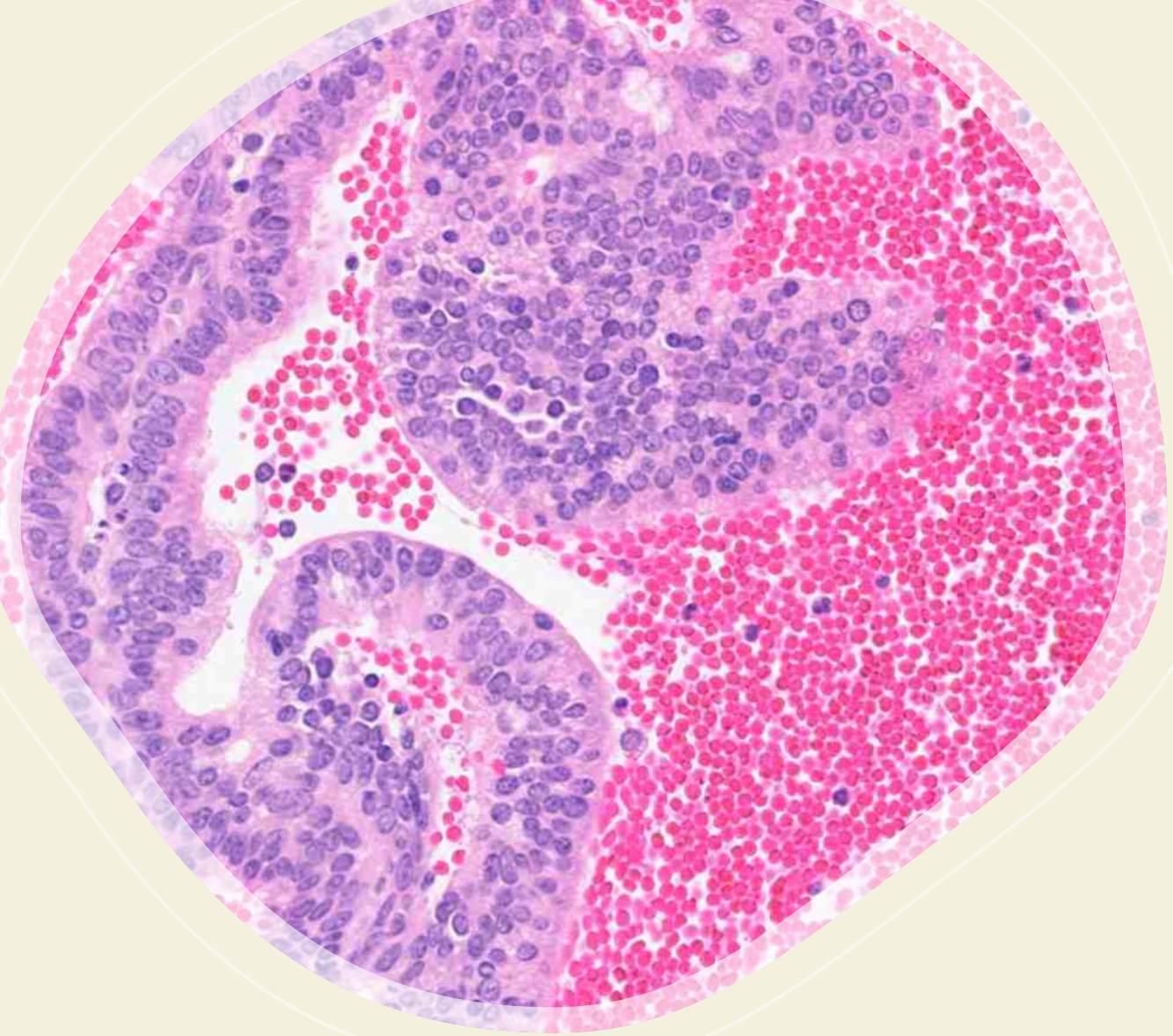

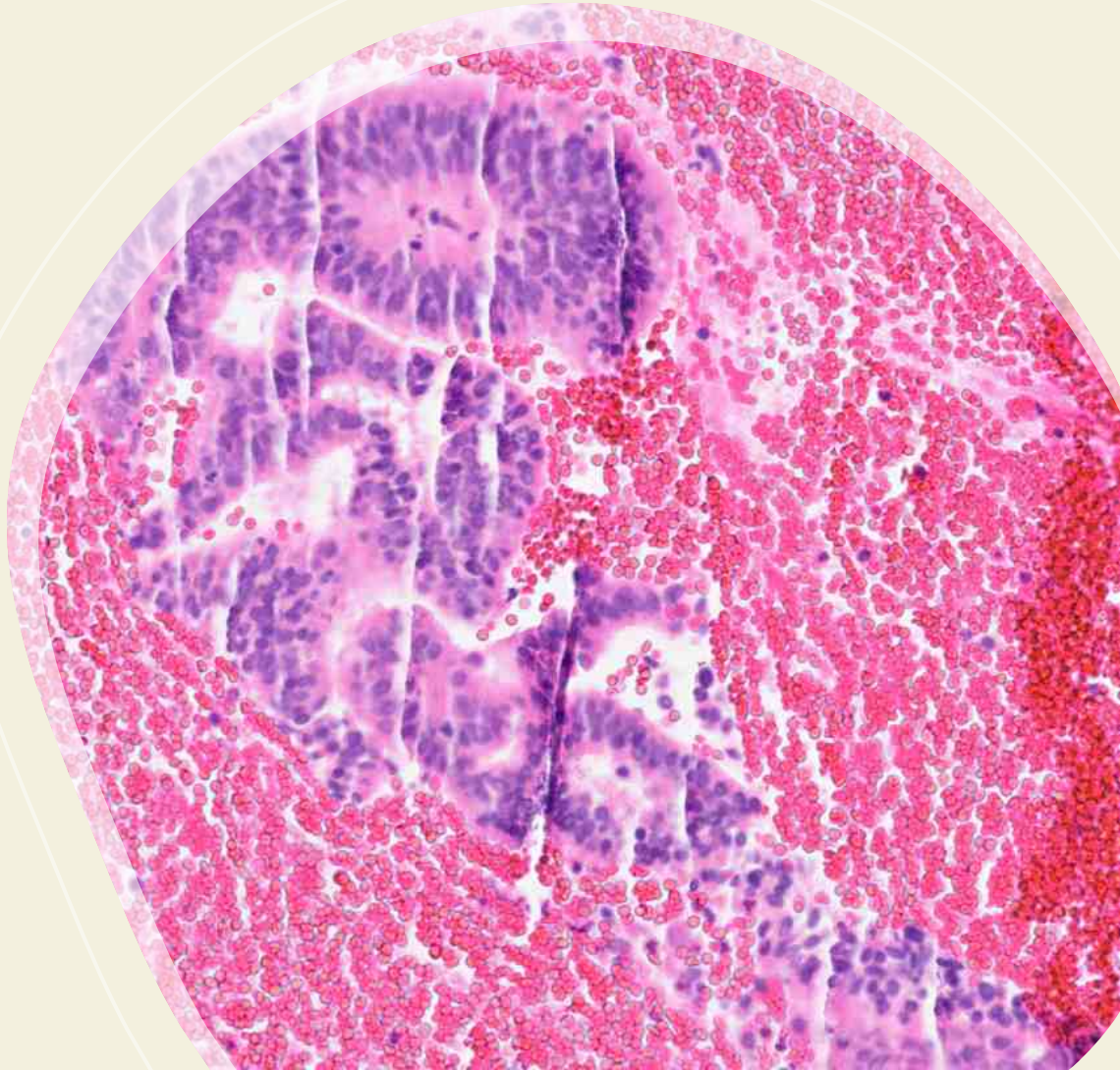

Learning points

- Cervical adenocarcinomas **may not be visible** on clinical examination or imaging
- Colposcopy Mismatch Meetings – **Go beyond a tick-box approach**; assess **LLETZ adequacy in the clinical context**
- **Canal Length Measurement** – Not mandatory but may support **better management decisions**
- **Do Not Discard/remove Adherent Blood Clots/Mucin** – Particularly in **glandular dyskaryosis** as they may contain **diagnostic clues**
- **Trust Your Gut Instinct** – If something doesn't feel right, **dig deeper** and think beyond the obvious!

Available online at www.sciencedirect.com
SCIENCE DIRECT
Gynecologic Oncology 101 (2006) 234 – 237
Gynecologic Oncology
www.elsevier.com/locate/ygyno

Ovarian metastasis in carcinoma of the uterine cervix

Muneaki Shimada [a], Junzo Kigawa [a,*], Ryuichiro Nishimura [b], Satoshi Yamaguchi [b], Kazuo Kuzuya [c], Toru Nakanishi [c], Mitsuaki Suzuki [d], Tsunekazu Kita [e], Tsuyoshi Iwasaka [f], Naoki Terakawa [a]

Background. The present study was conducted to determine the frequency and clinicopathological features of ovarian metastasis in a large population of patients with stage Ib–IIb cervical cancer.

Methods. The study population consisted of 3471 patients with stage Ib to IIb cervical cancer who underwent radical hysterectomy, including pelvic lymphadenectomy and bilateral salpingo-oophorectomy, at our six institutions between 1981 and 2000. To our knowledge, this study is the largest review of patients with ovarian metastasis from cervical cancer. We reviewed the patients' medical records to determine clinicopathological features.

Results. Fifty-two patients (1.50%) had ovarian metastases: 6 in stage Ib1, 12 in stage Ib2, 5 in stage IIa, and 29 in stage IIb. The mean age of patients with ovarian metastasis was 49.9 years (range: 29–73 years). The incidence of ovarian metastasis in patients with cervical cancer was 0.22% for stage Ib, 0.75% for stage IIa, and 2.17% for stage IIb with squamous cell carcinoma, and 3.72%, 5.26%, and 9.85%, respectively, in adenocarcinoma. Ovarian metastasis occurred more frequently among patients with adenocarcinoma than among those with squamous cell carcinoma (5.31% vs. 0.79%). Outcome for patients with ovarian metastasis was very poor and not related to FIGO stage and histological type. The presence of ovarian metastasis did not correlate with lymph node involvement or parametrial invasion.

Conclusion. Study results indicate that ovaries can be preserved in patients with stage Ib–IIa squamous cell carcinoma but removed in all patients with adenocarcinoma.

LLETZ -Large **L**oop diathermy **E**xcision of **T**ransformation **Z**one

LEEP -Loop **E**lectrosurgical **E**xcision **P**rocedure

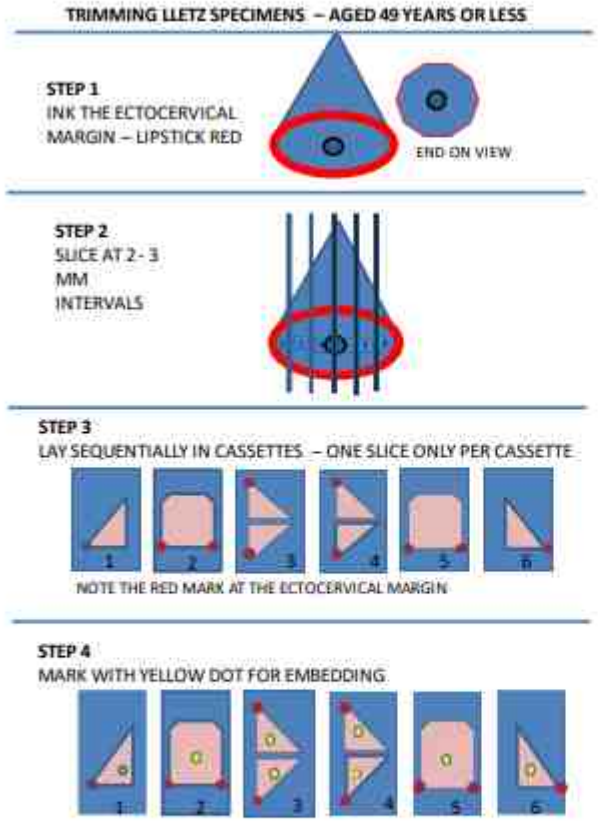

Figure 2. Trimming LLETZ specimens – aged 49 years or less. Reproduced with permission from Dr William Boyle and Dr Jason Wong.

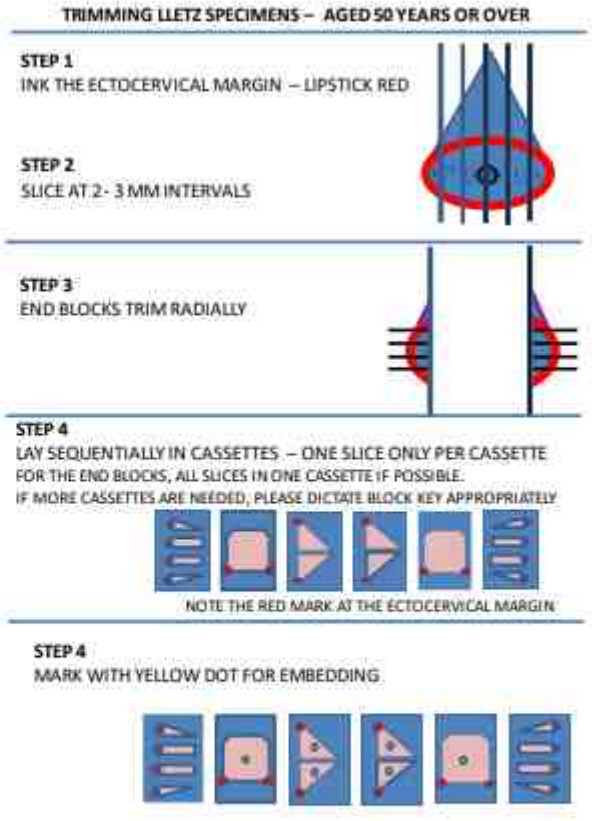

Figure 3. Trimming LLETZ specimens – aged 50 years or over. Reproduced with permission from Dr William Boyle and Dr Jason Wong.

NHSCSP guidelines update Sept 2021

CIN3 at deep lateral and endocervical margins

>50yrs – re-excision

- Margin assessment important
- Turn end blocks or take cruciates to margin of end blocks

<49yrs– re-excision not necessary

- Turning end blocks not required

Ganesan et al. Tissue Pathways for gynaecological pathology. The Royal College of Pathologists. February 2023


Unknown
01-Jan-0001
24HP043079
Cardan Imaging
31-Dec-2024
100
90


Unknown
01-Jan-0001
24HP043079
Cardan Imaging
31-Dec-2024
160
190

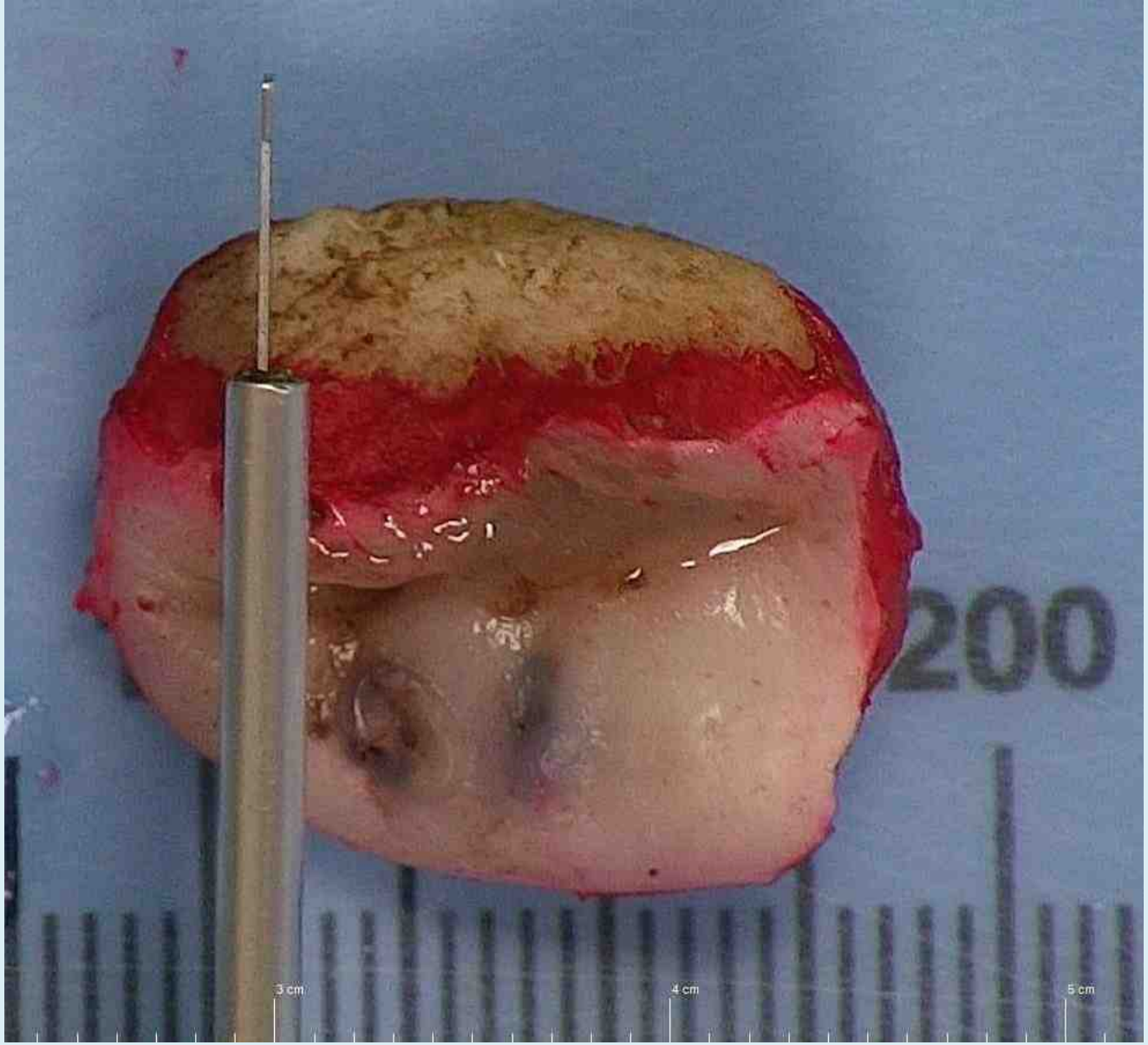
200
3 cm
4 cm
5 cm

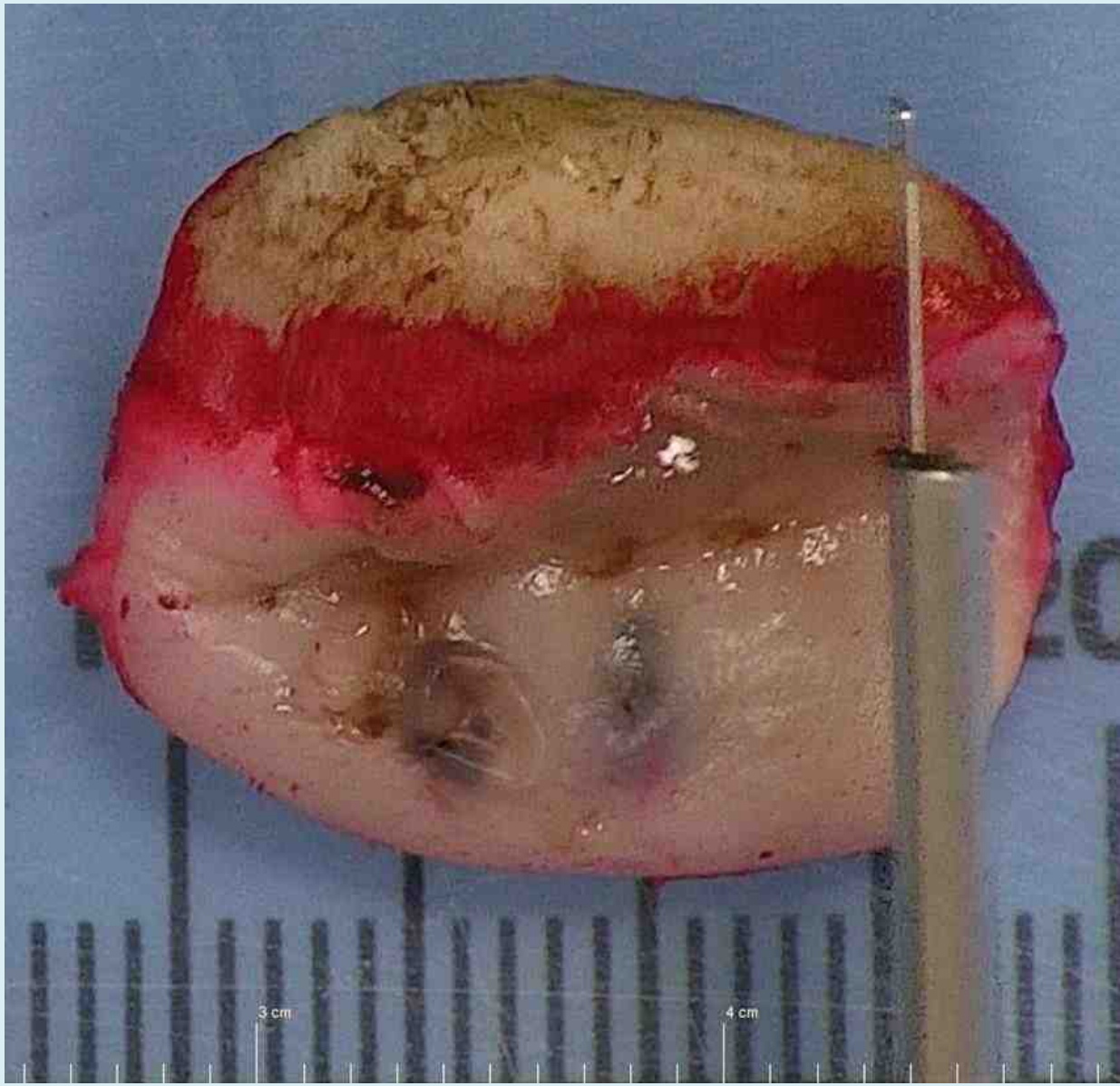
3 cm
4 cm


Unknown
01-Jan-0001
24HP043079
Cirdan Imaging
31-Dec-2024
mm
24HP043079
A 5 CONE
24HP043079
A 4 CONE
24HP043079
A 3 CONE
24HP043079
A 2 CONE
24HP043079
A 1 CONE

Cruciates to end slice



Opposite end slice embedded intact



Uterus

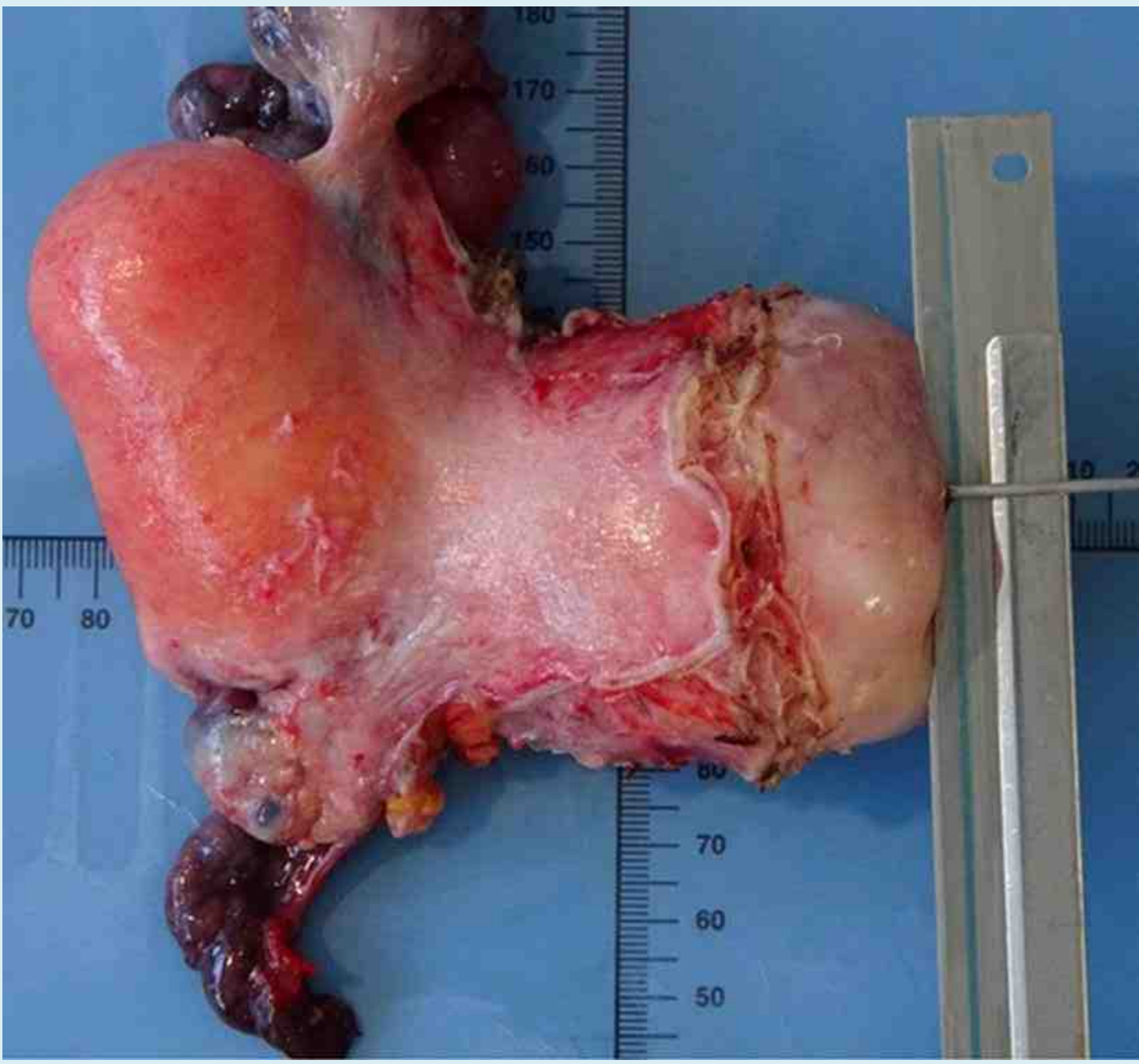
70
80
70
60
50

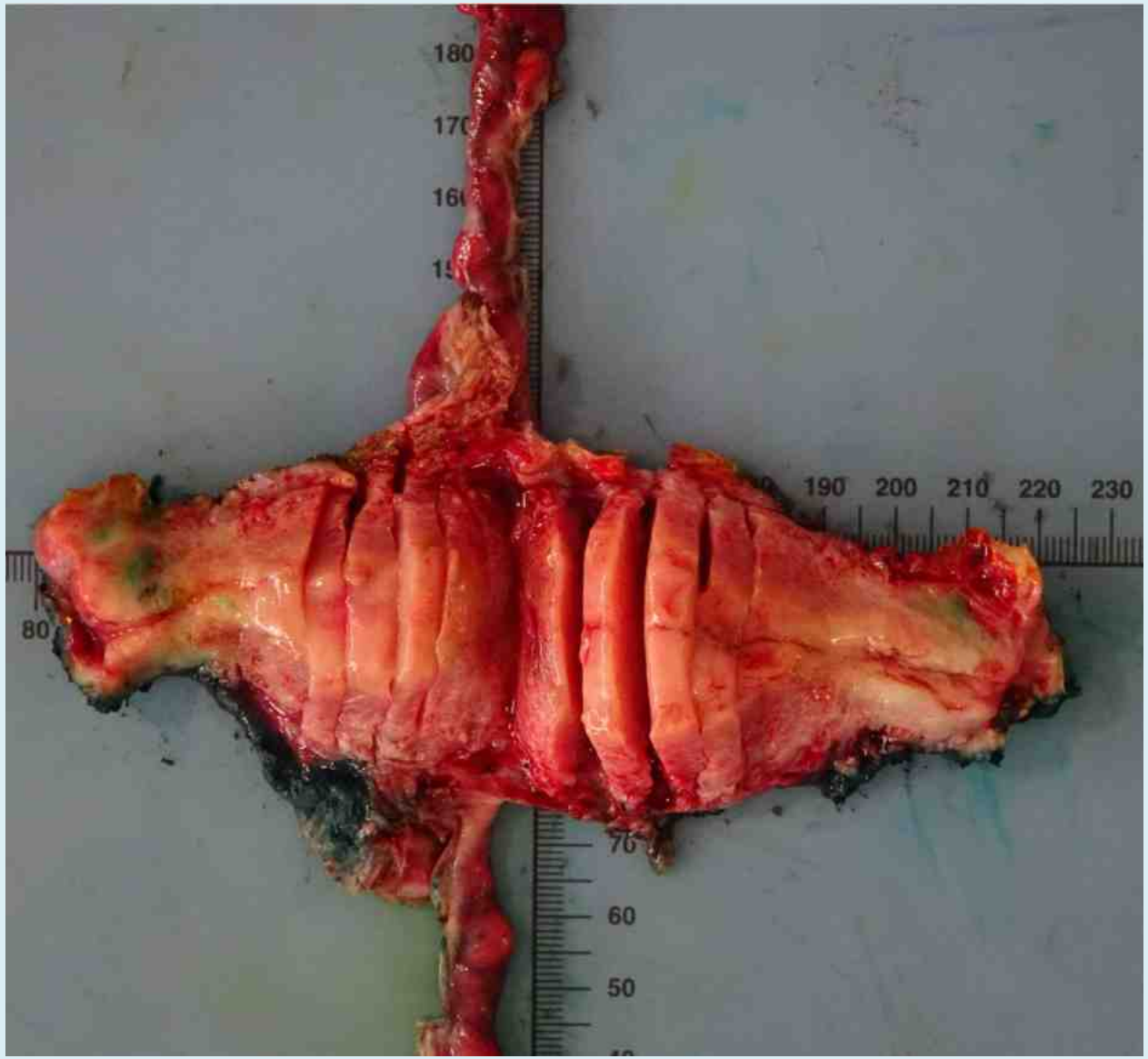
180
170
160
150
190
200
210
220
230
80
70
60
50

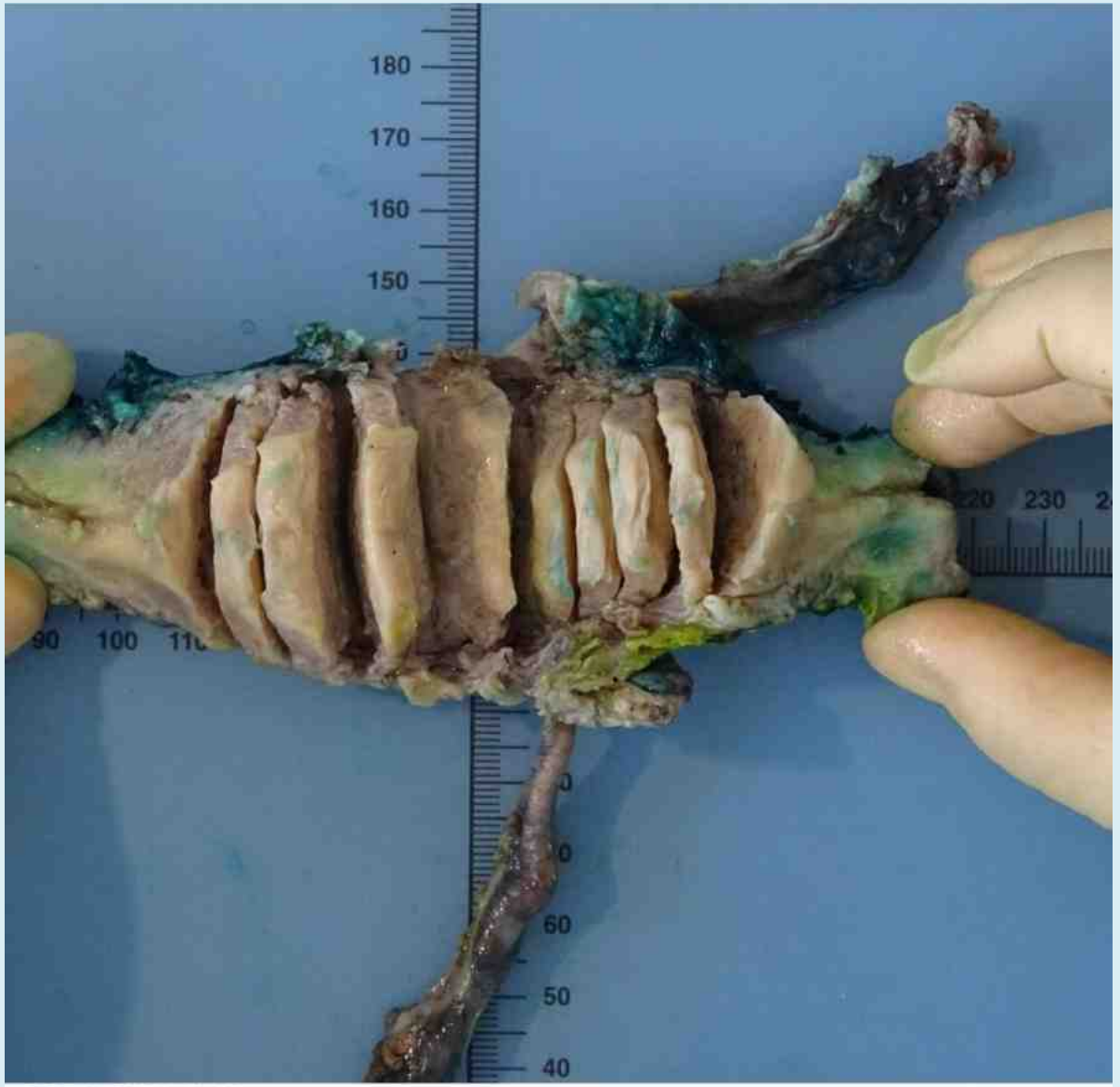
180
170
160
150
230
100
60
50
40
- 13 Feb 2023 11:18

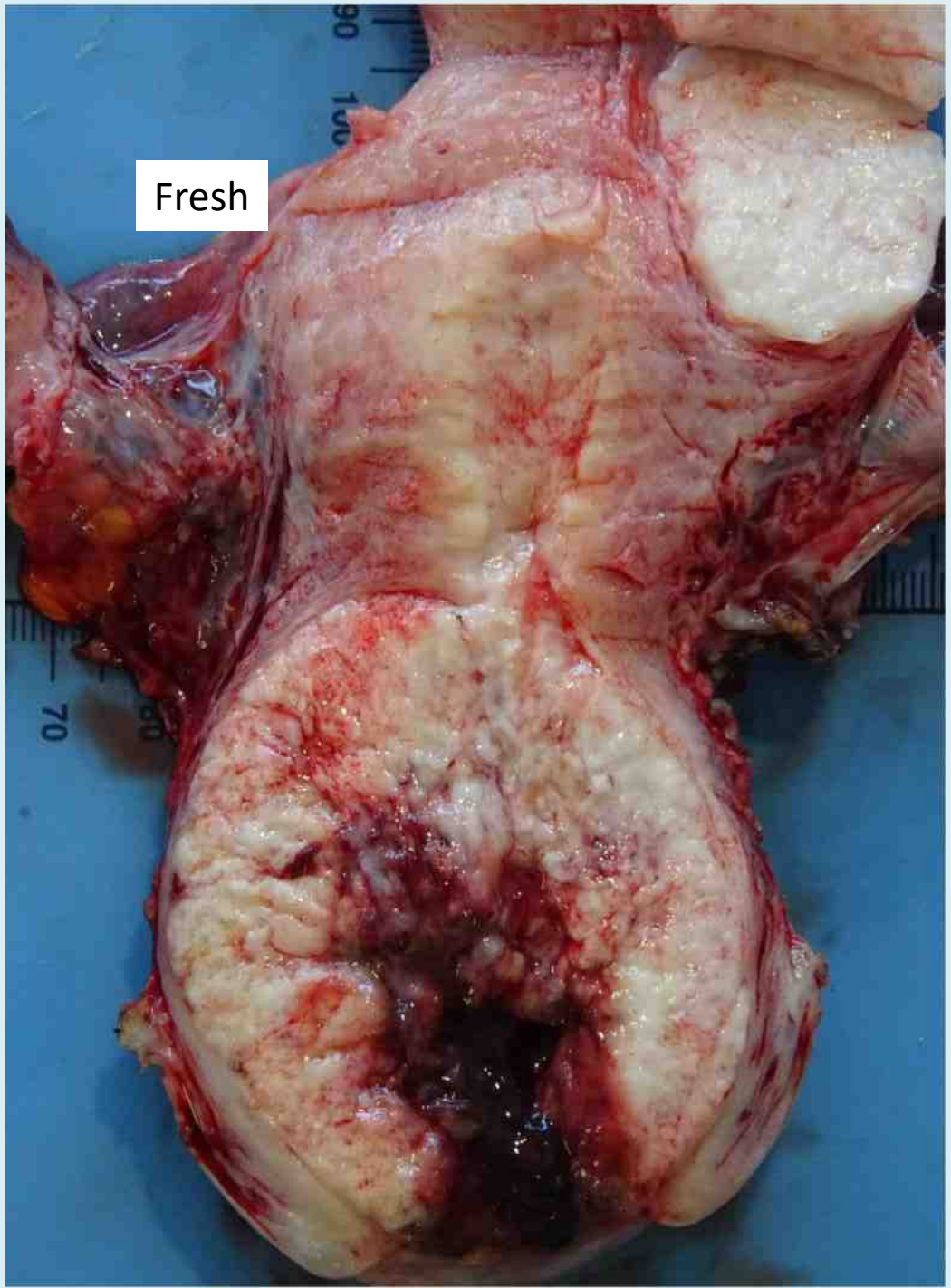
Fresh

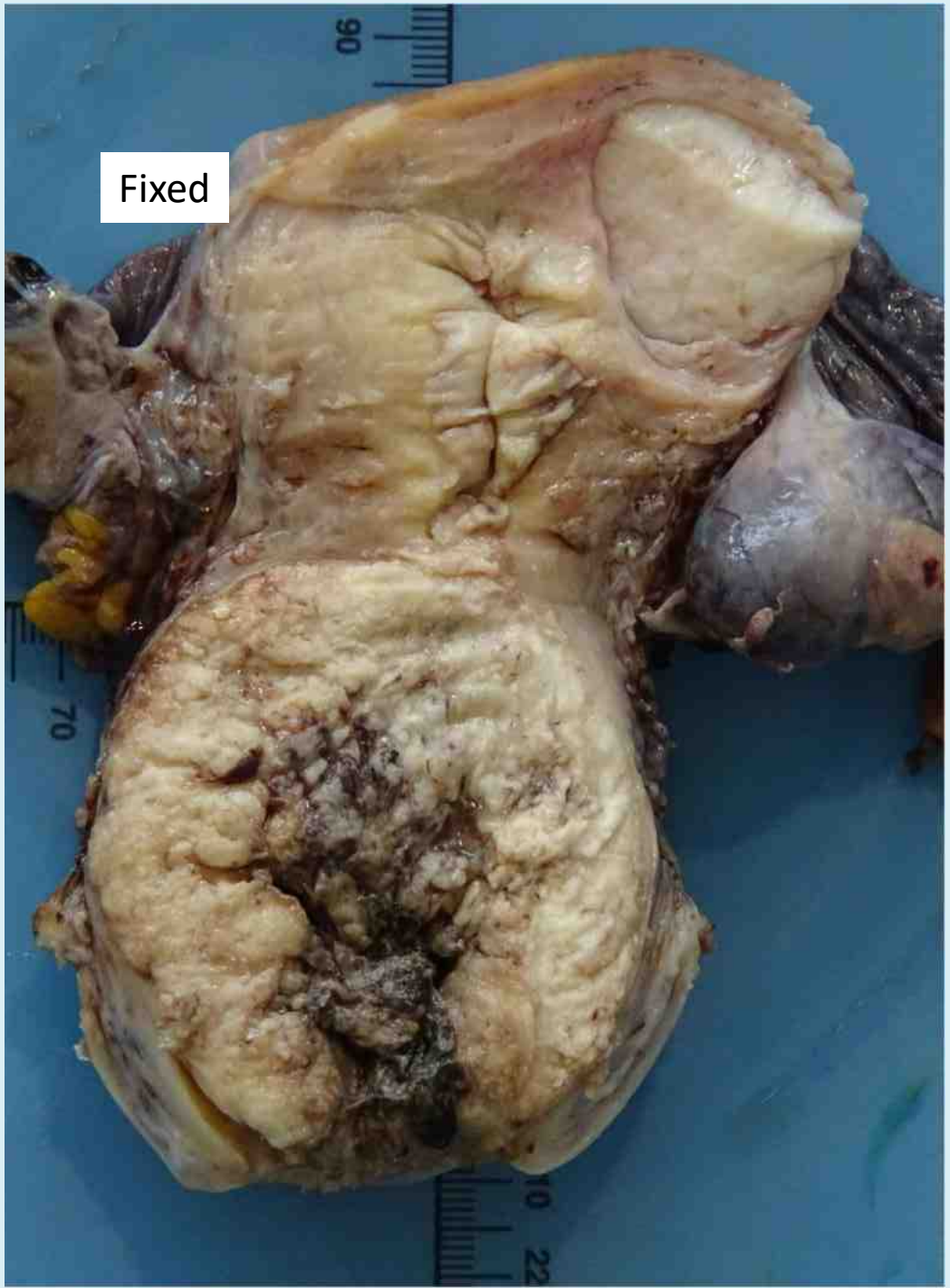
Fixed

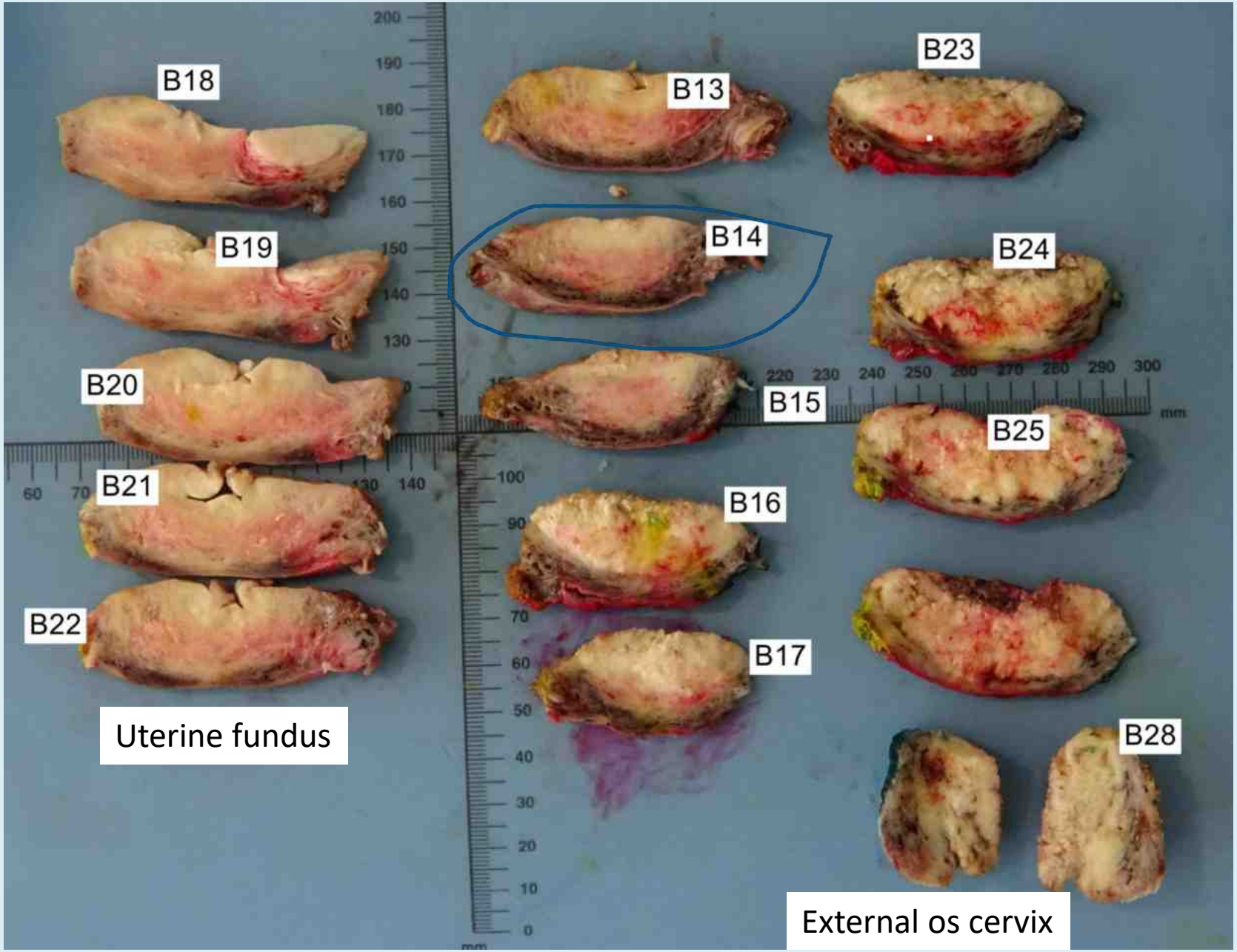
B18
B13
B23
B19
B14
B24
B20
B15
B25
B21
B16
B22
B17
B28
Uterine fundus
External os cervix

B14, LUS

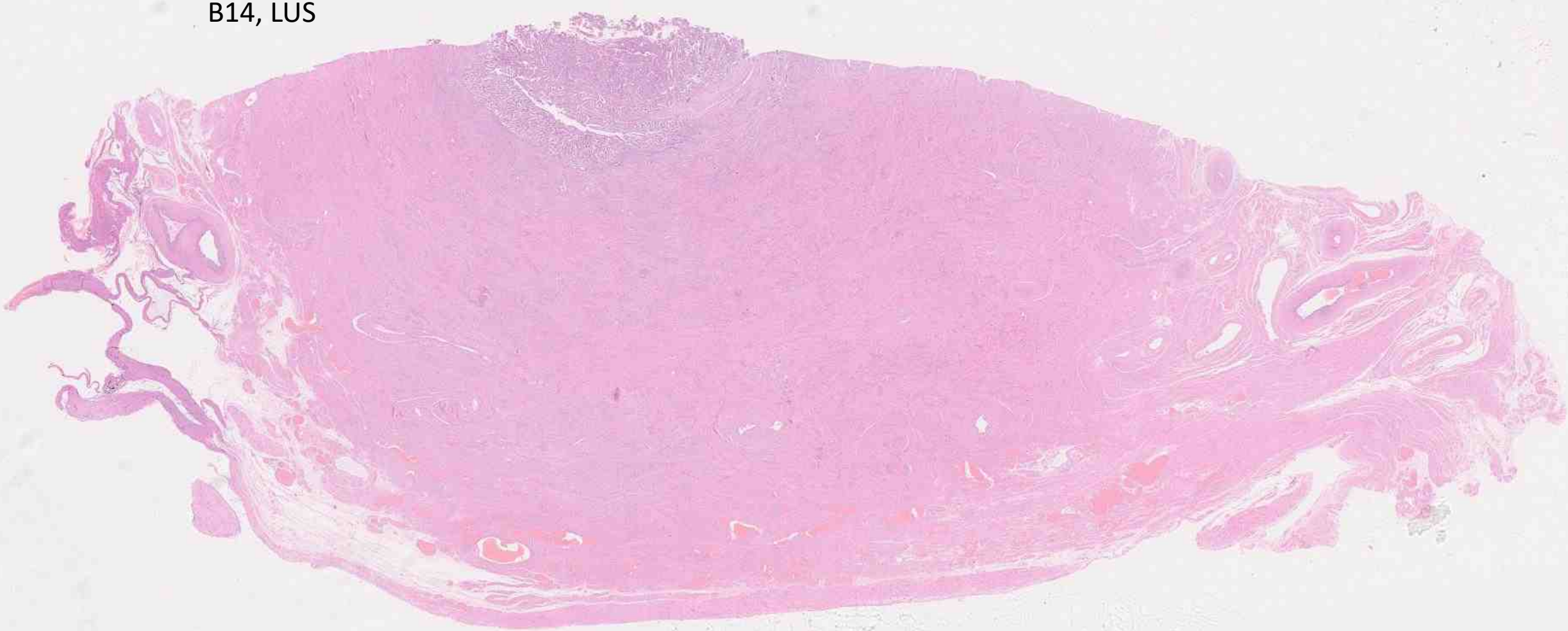

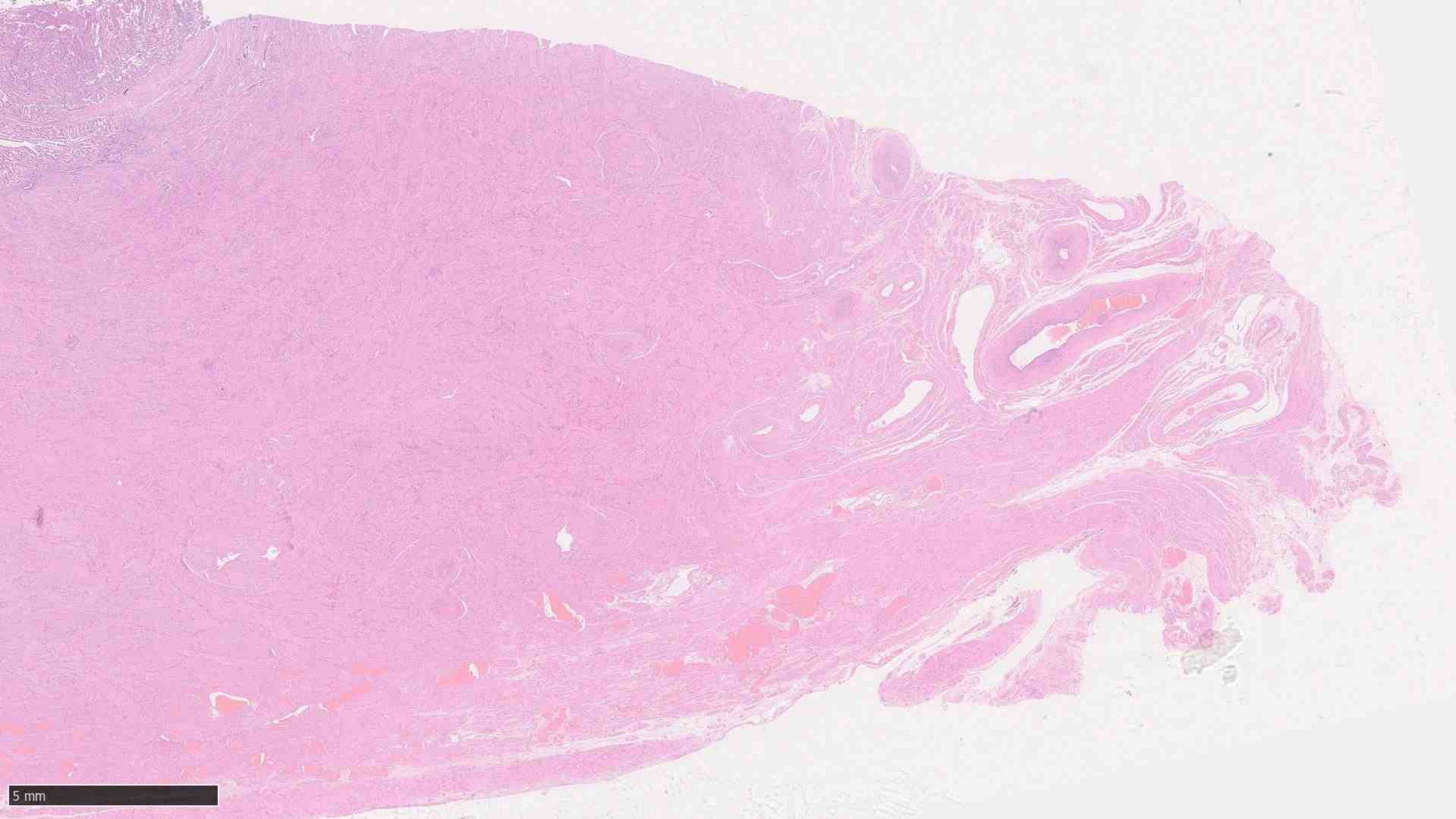
5 mm

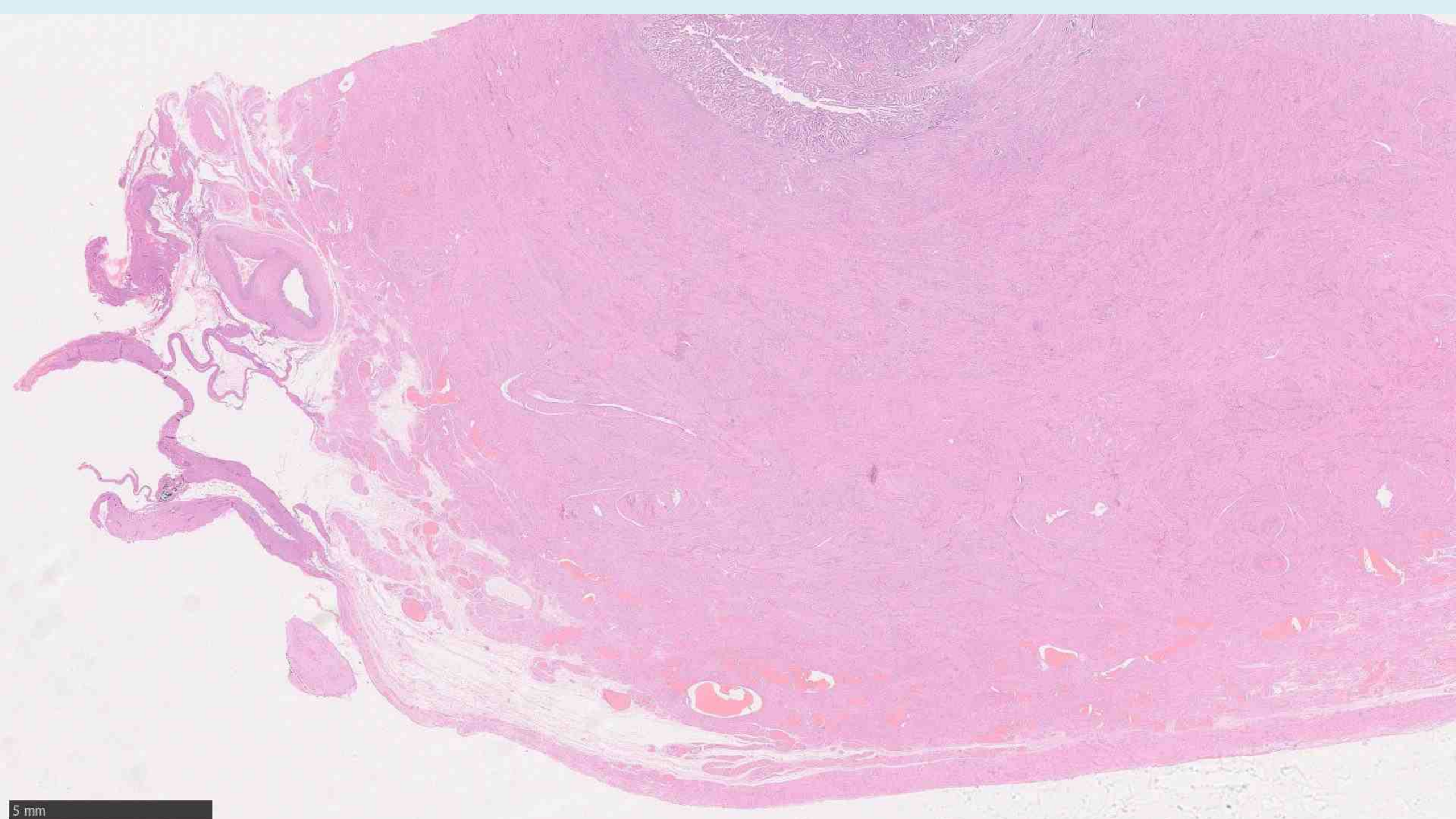
5 mm

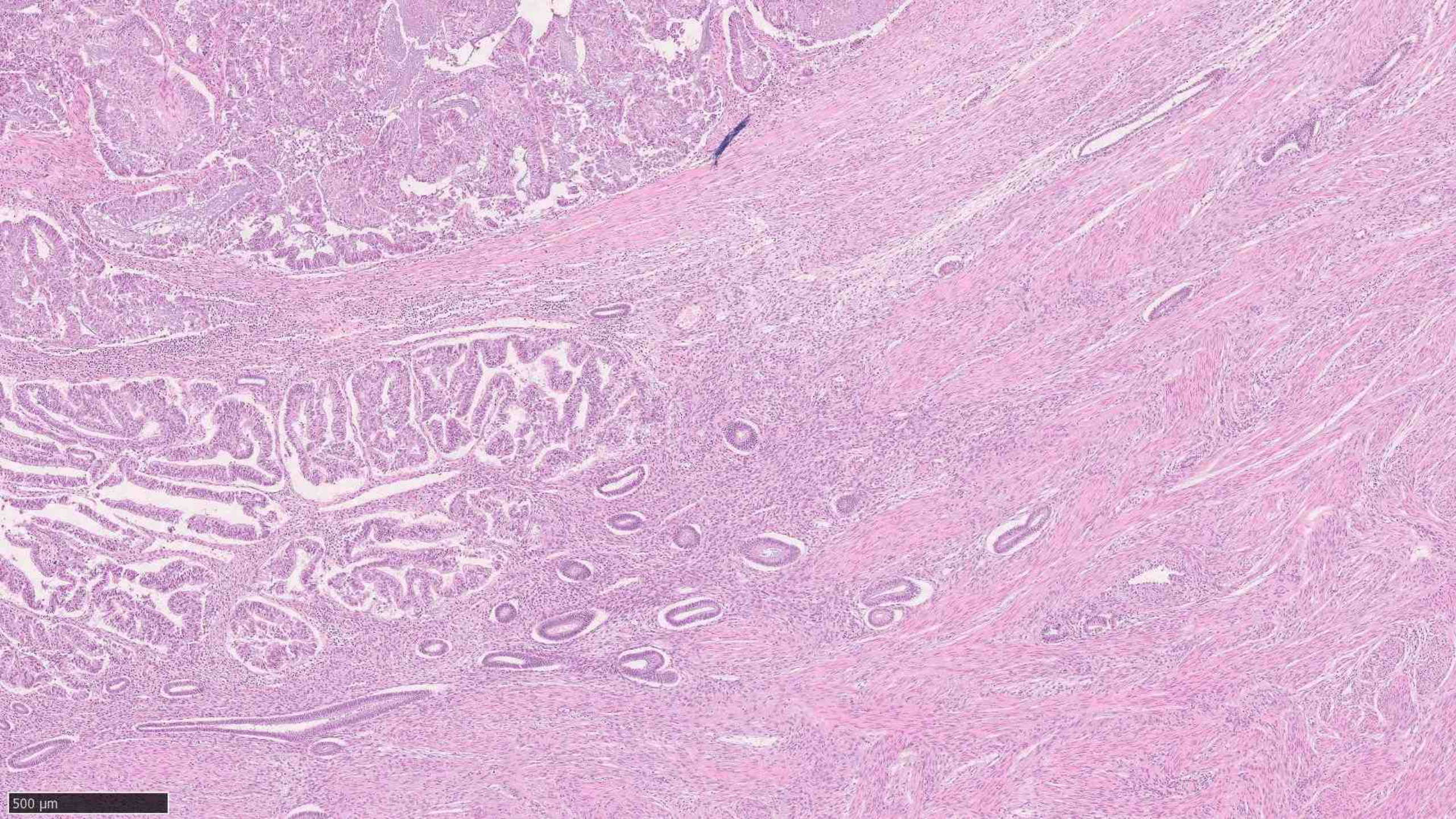
500 µm


160
150
140
130
120
130
170
180
210
220

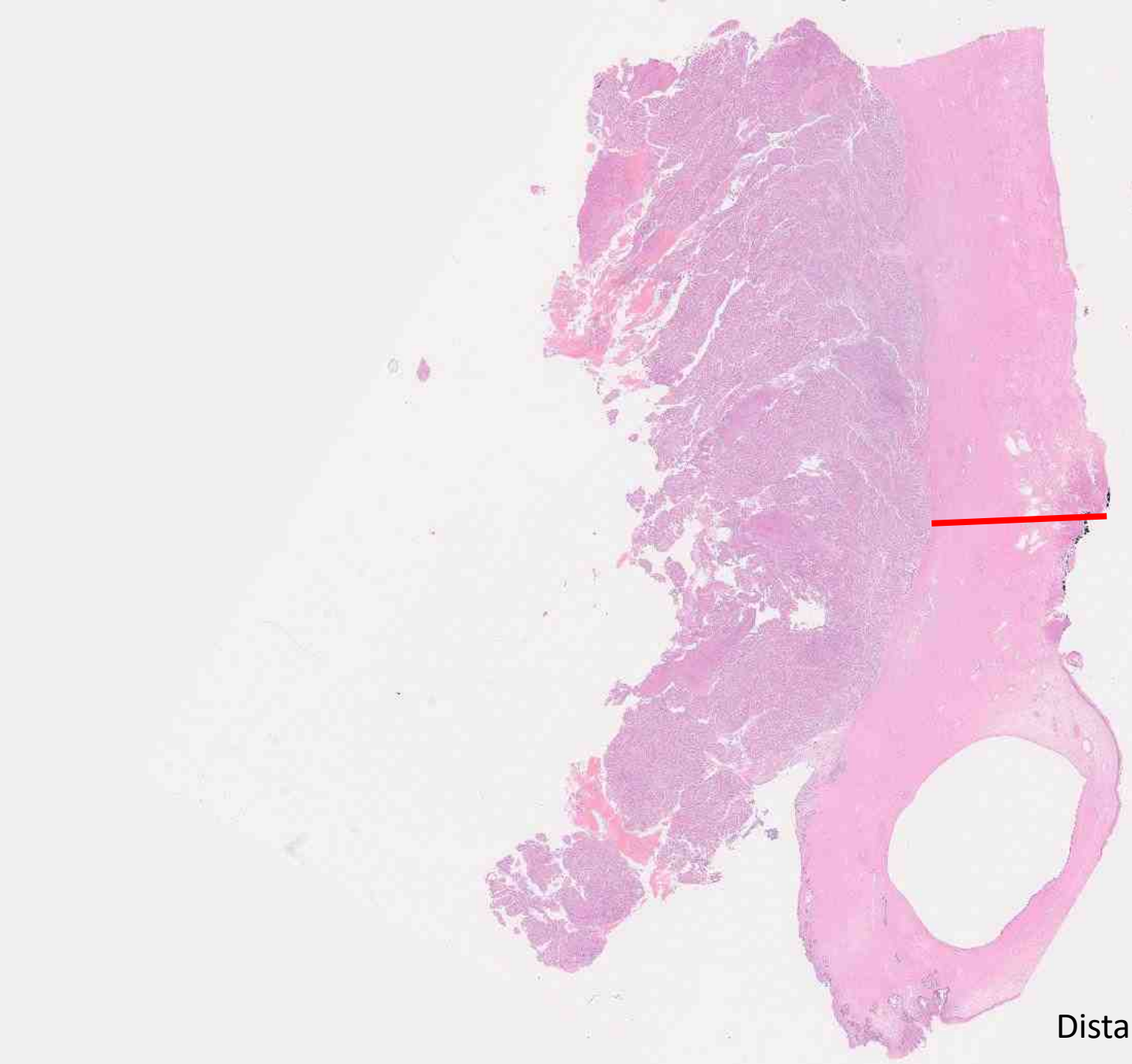
Distance to cervix posterior radial margin
Distance to ectocervix
25 mm

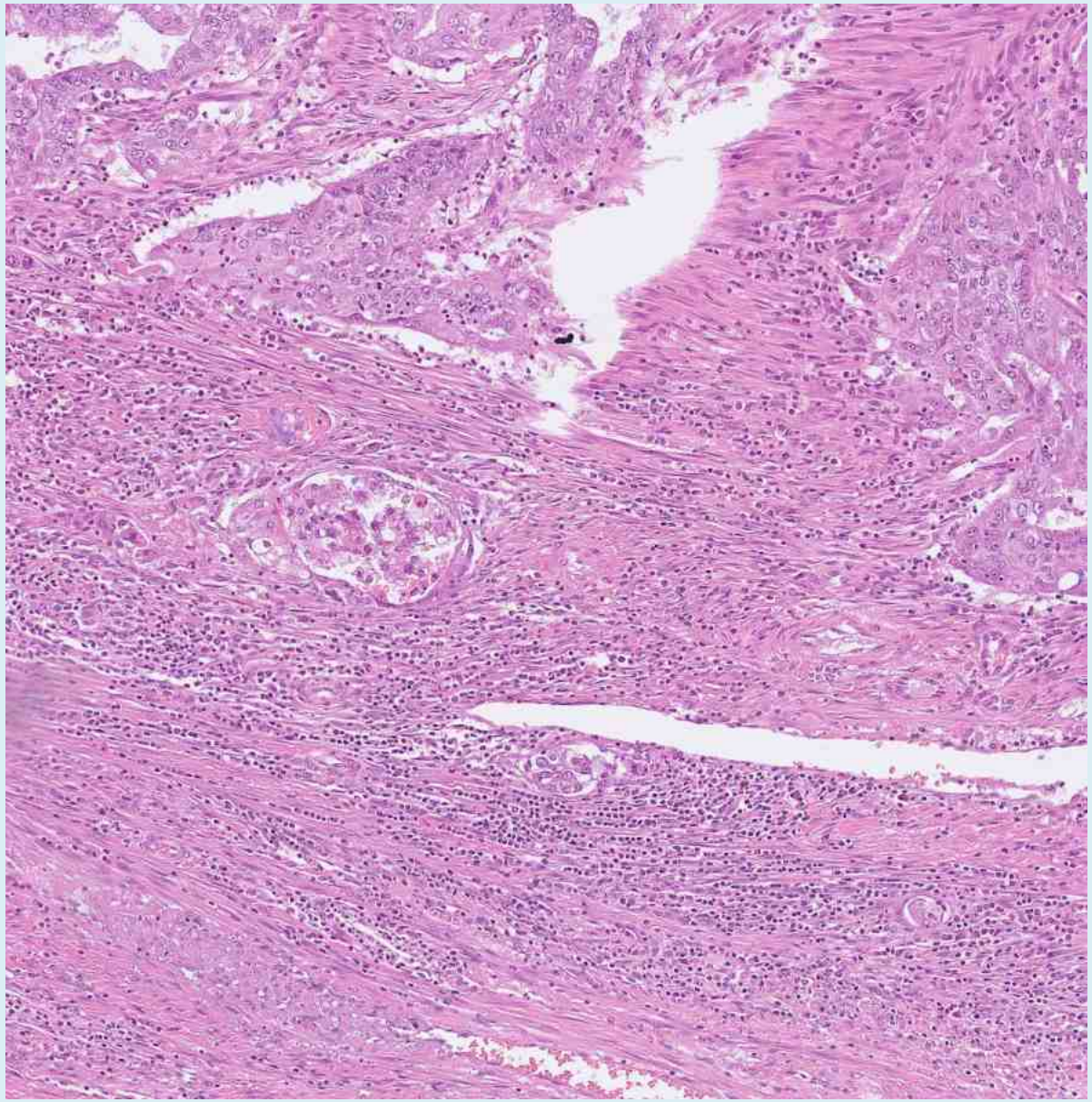

CKC/D240 dual stain

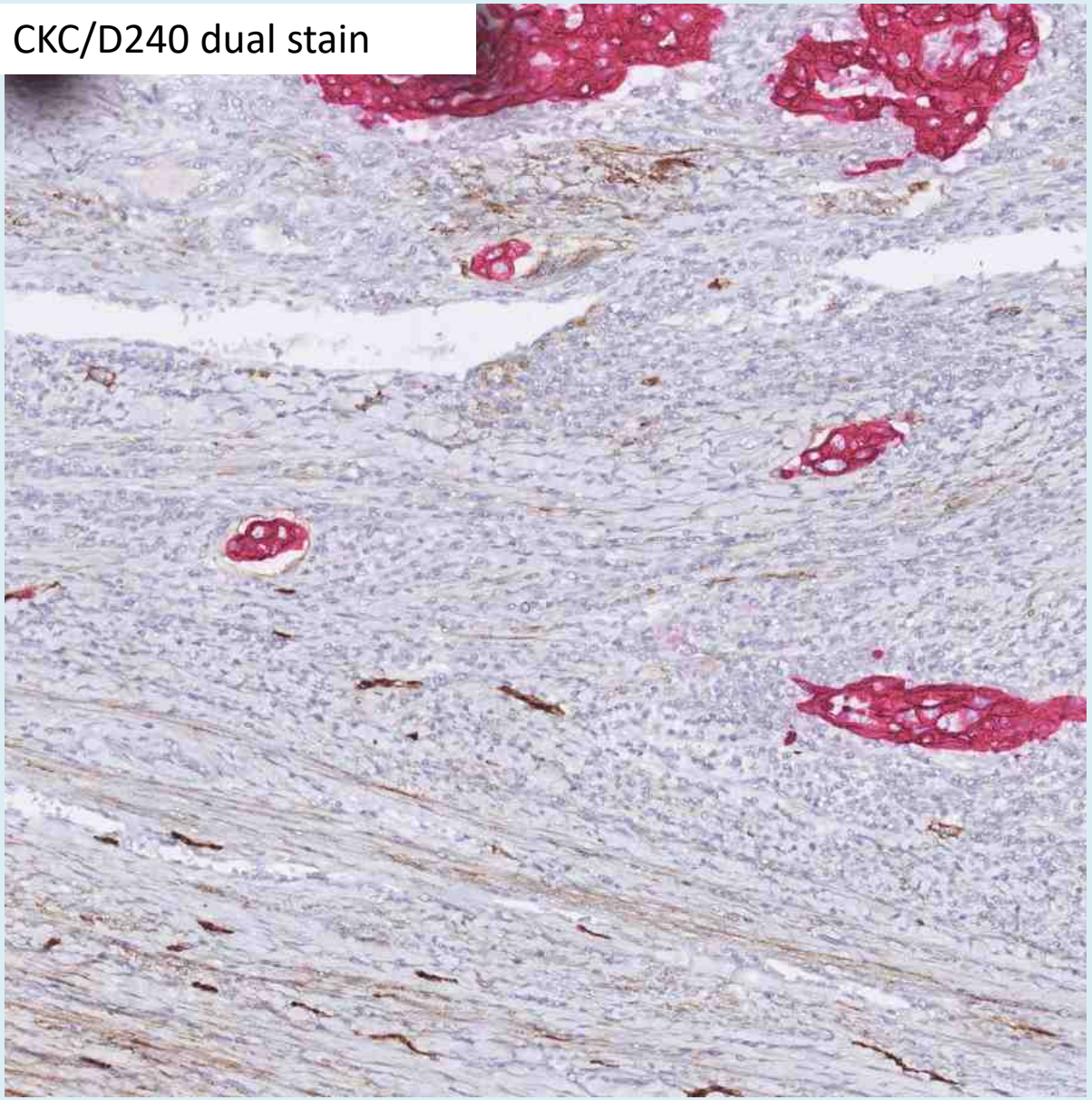

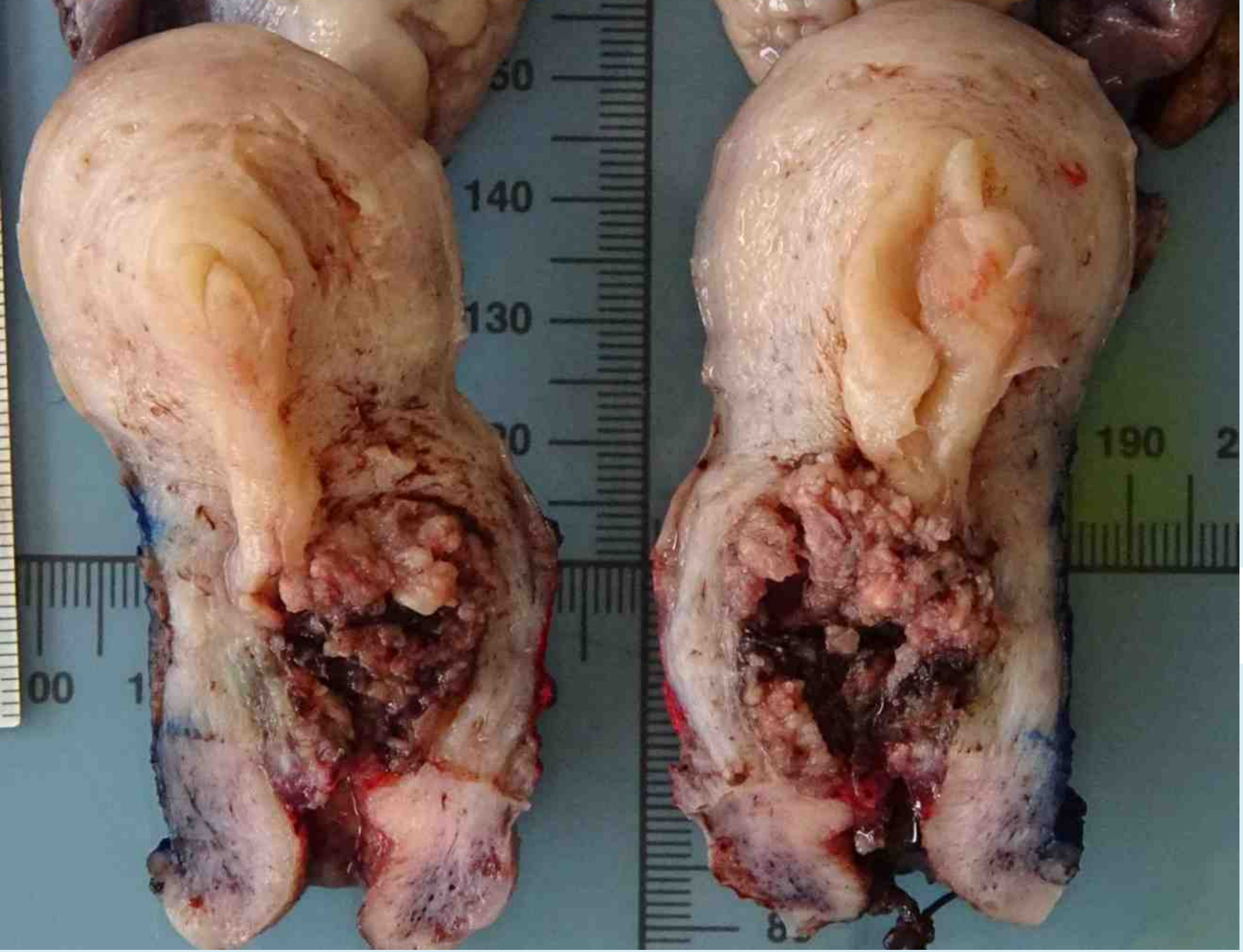

33y para 1, heavy menstrual bleeding
Bx- mixed serous and clear cell carcinom
favouring endometrial origin

Fleshy papillary tumour centred in the cervix with *normal* endometrium

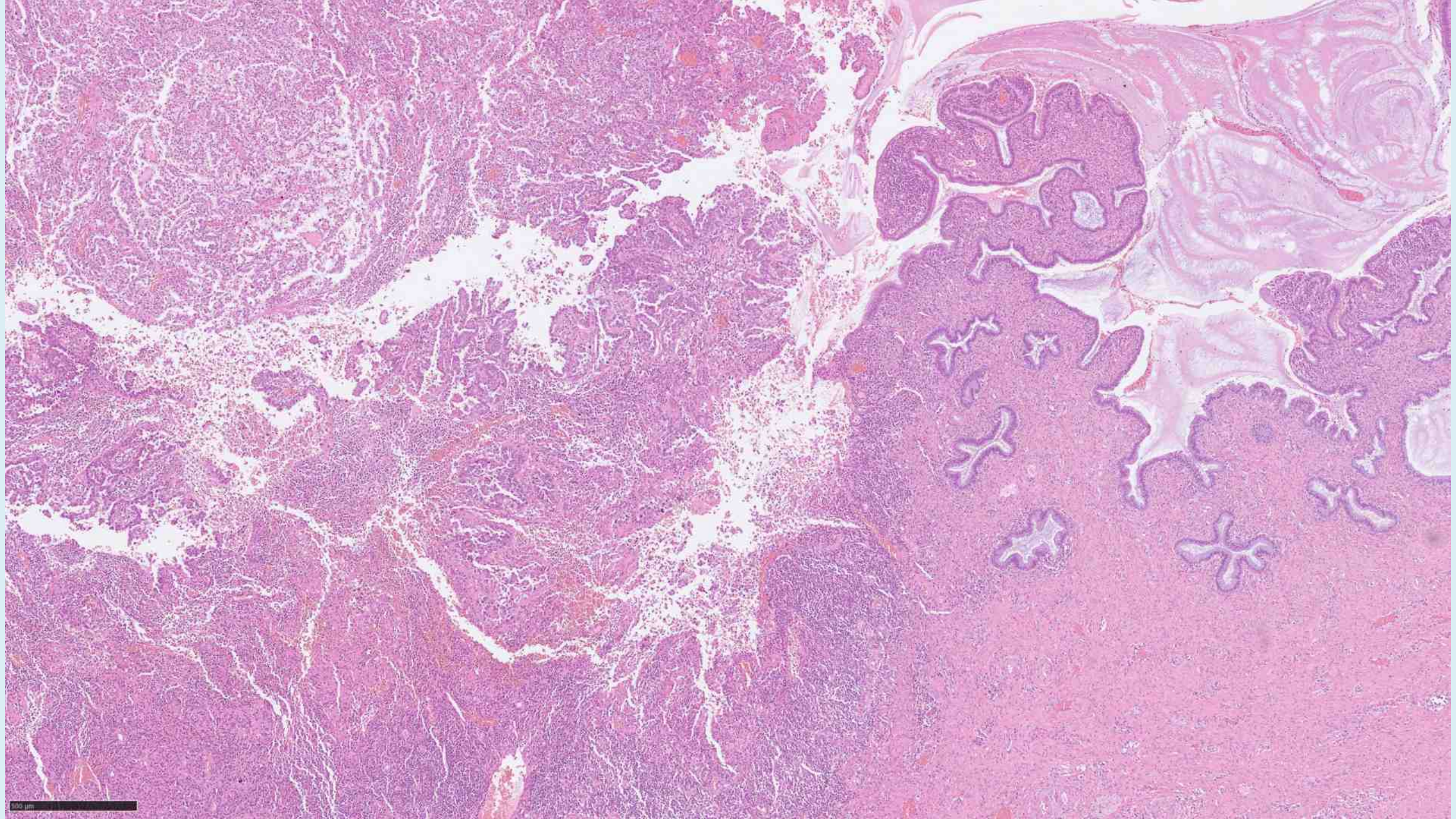
500 µm

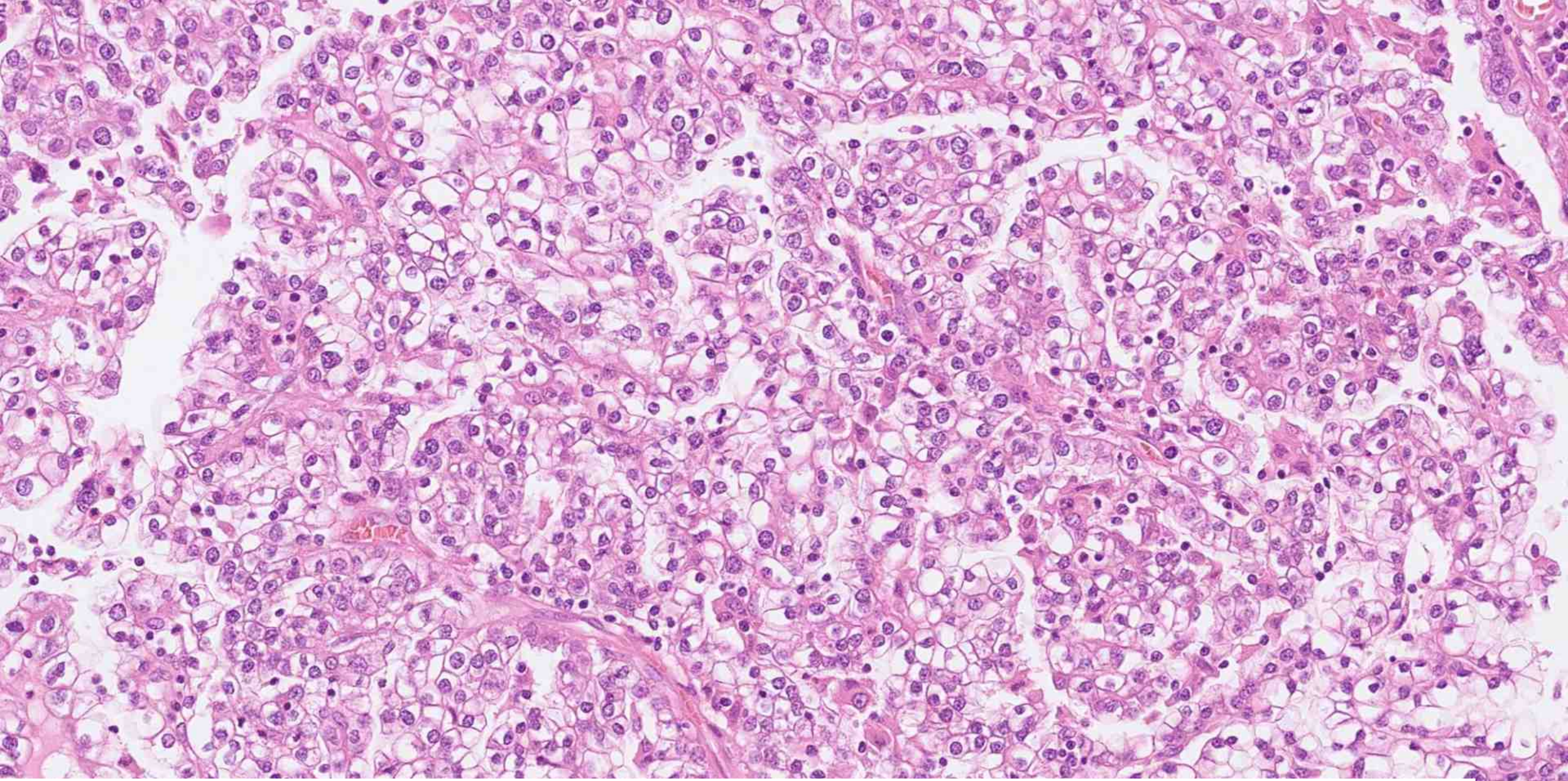

Medium power HE image of clear cell carcinoma showing clear cytoplasm with distinct cytoplasmic margins and round to raisinoid medium sized nuclei showing mild nuclear pleomorphism

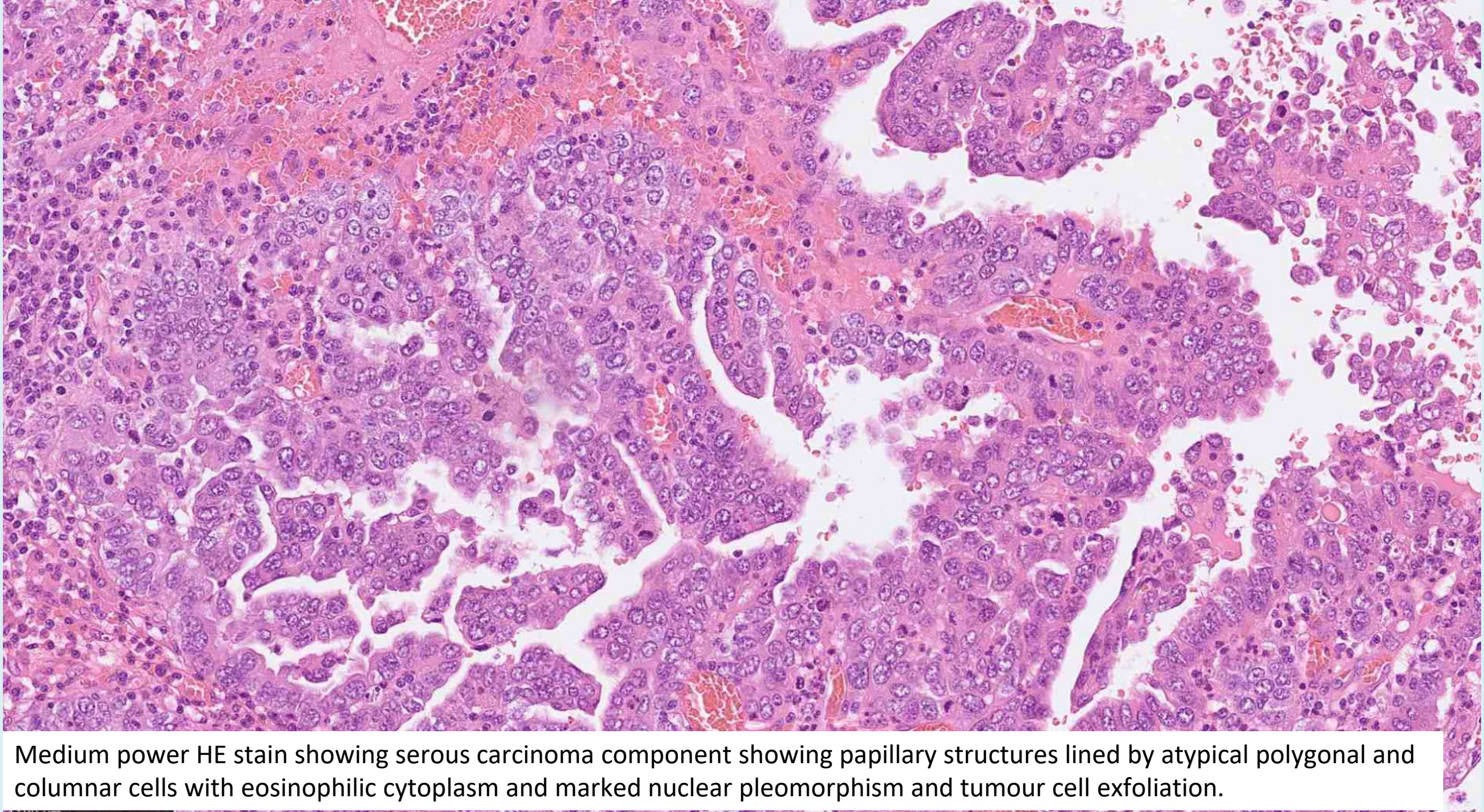

Medium power HE stain showing serous carcinoma component showing papillary structures lined by atypical polygonal and columnar cells with eosinophilic cytoplasm and marked nuclear pleomorphism and tumour cell exfoliation.

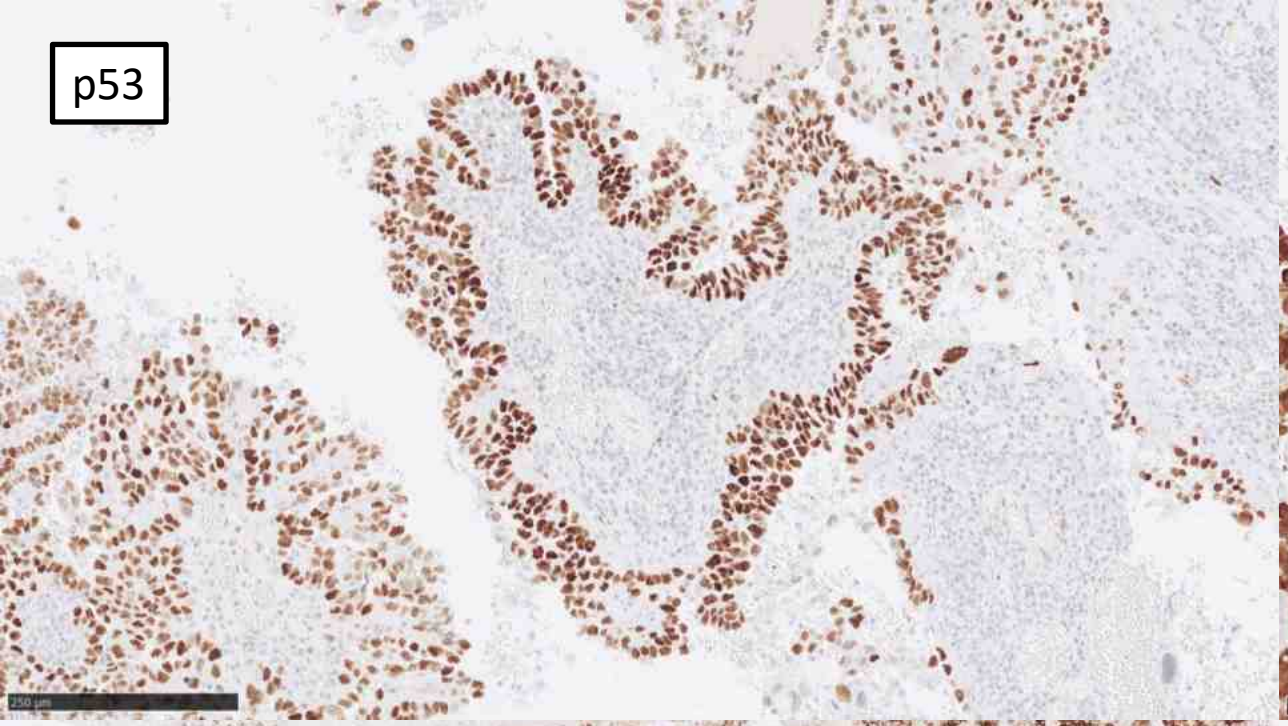
p53


p16

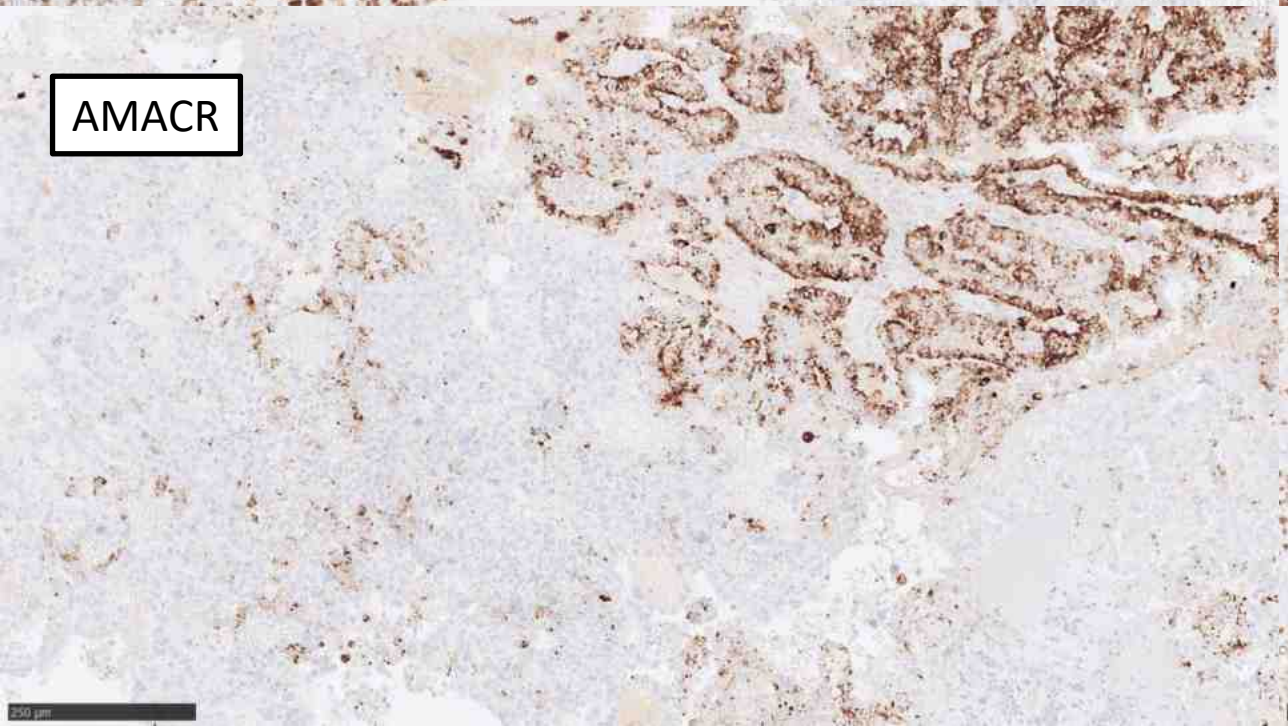
AMACR

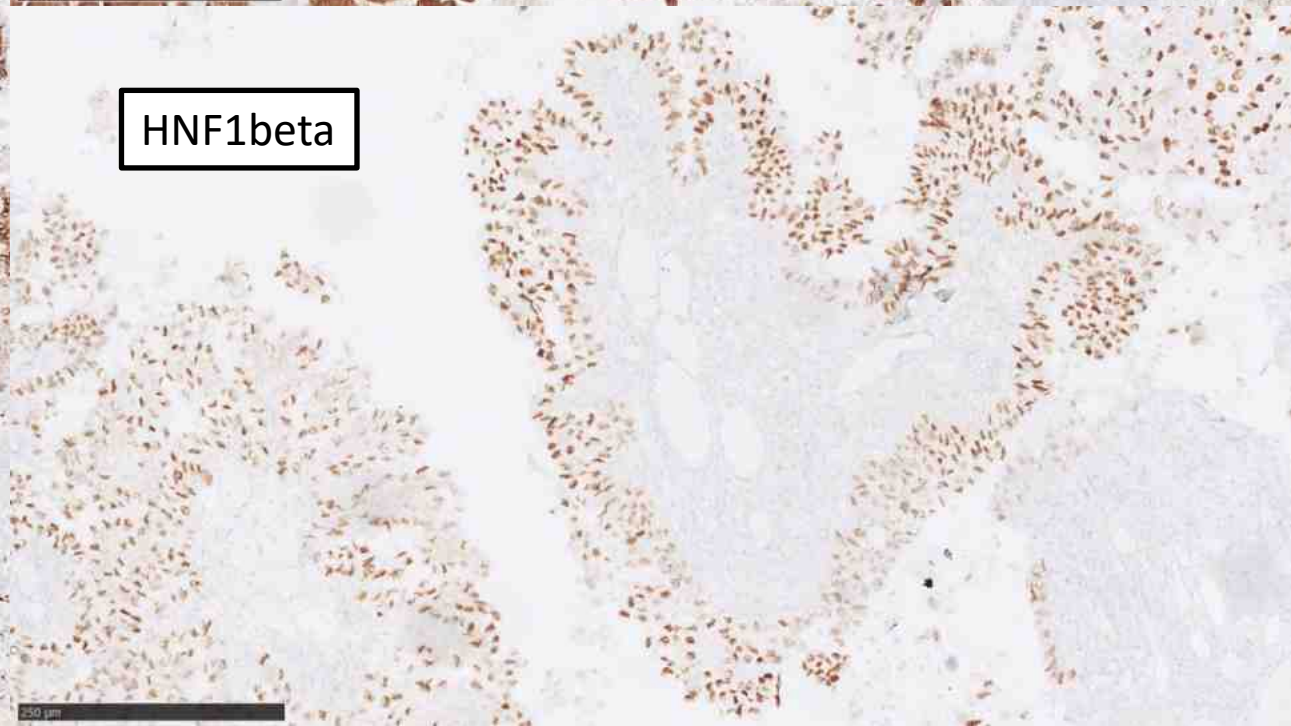
HNF1beta

Adenosarcoma

Unique staging system

Differs from other uterine sarcomas and endometrial carcinomas

Staging for Uterine Adenosarcoma

- FIGO stage 1- limited to uterus
    - 1A- limited to endometrium and/or cervix
    - 1B-Invading <=50% of myometrium
    - 1C -Invading >50% of myometrium
- FIGO stage II- extends beyond uterus


110
120
80
190
200


170


150
140
200
210
100
110
60
50mm

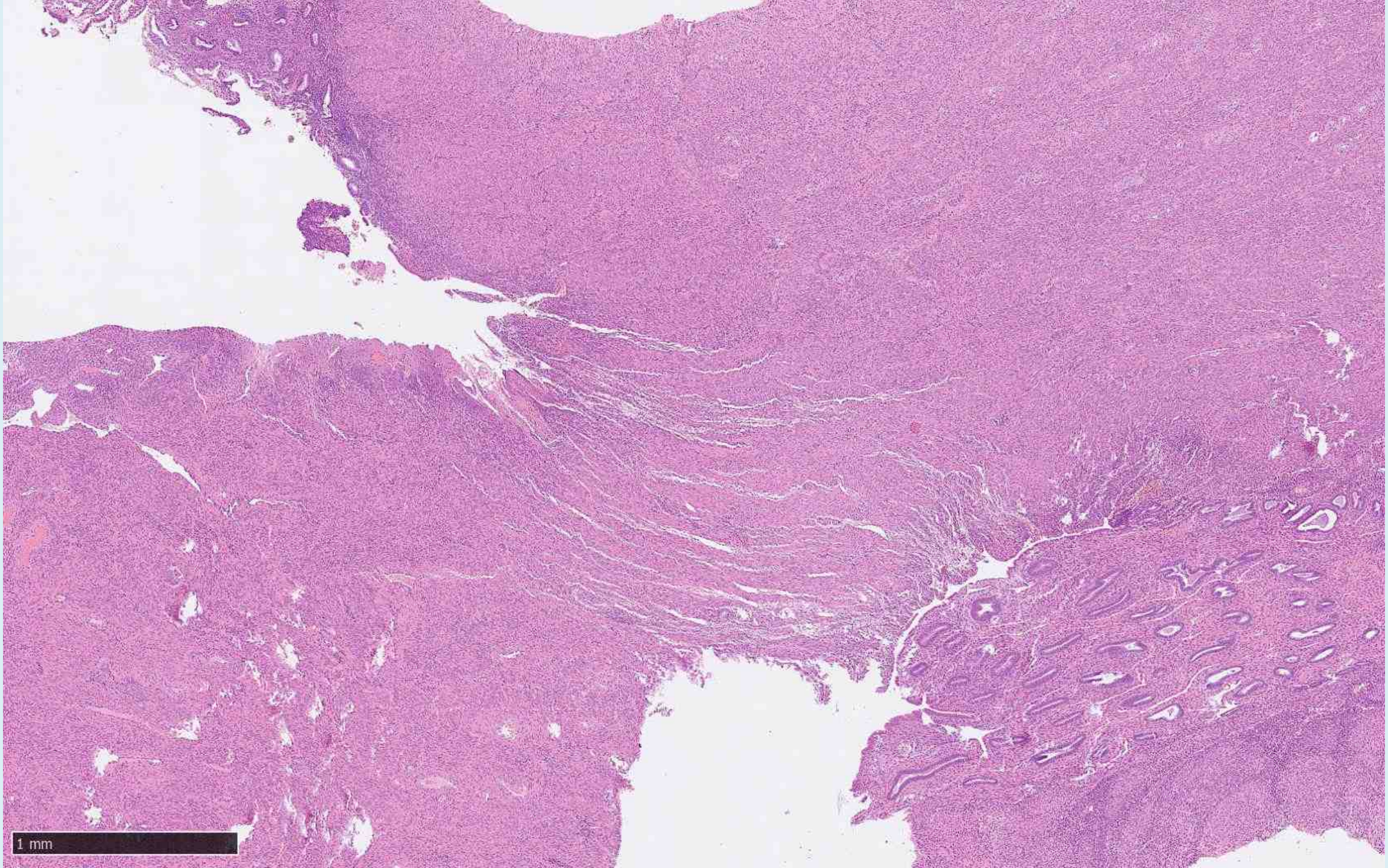
1 mm

Ovarian tumours

25y
Abdominal mass, elevated AFP,LDH
?Germ cell tumour



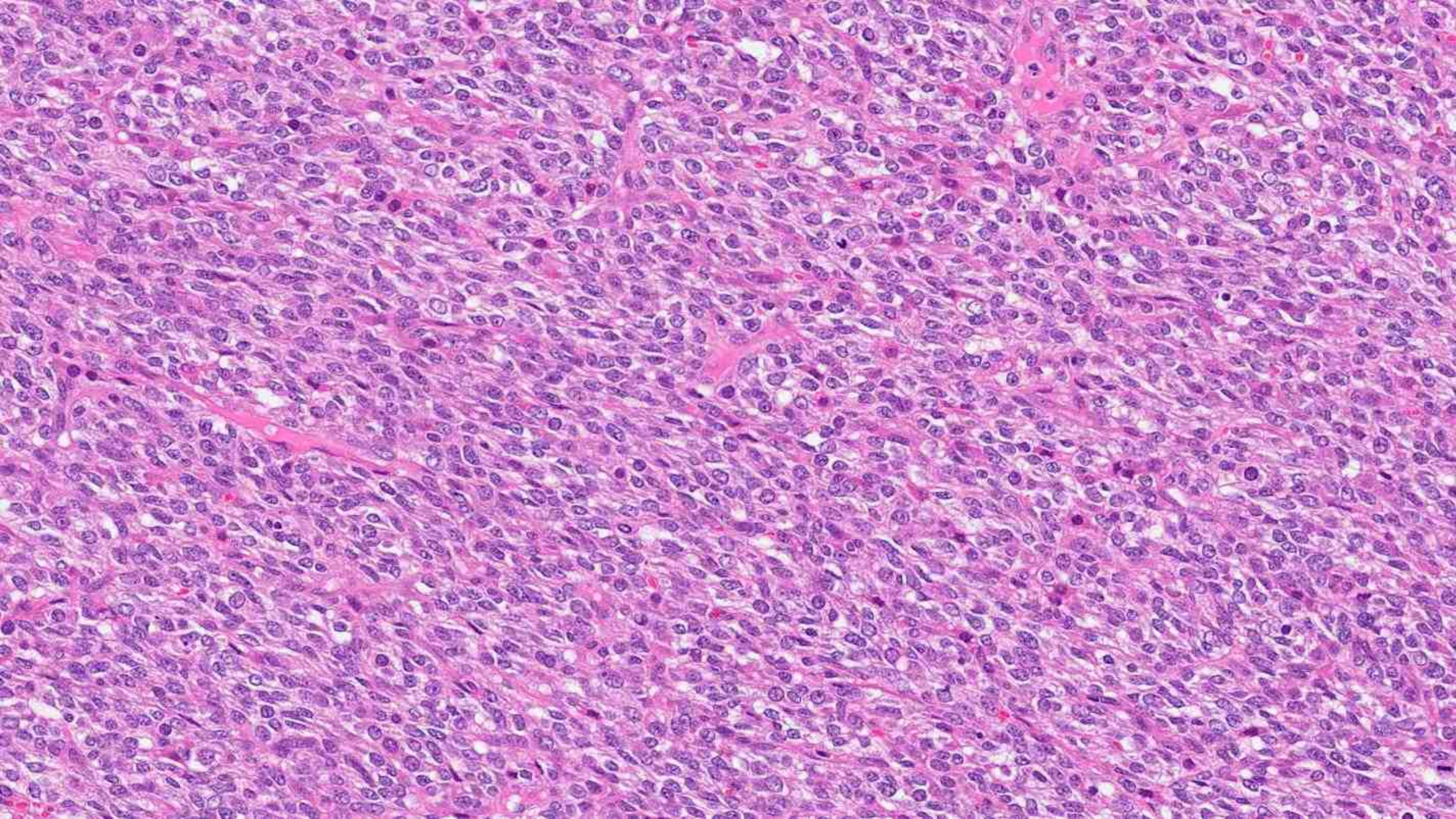

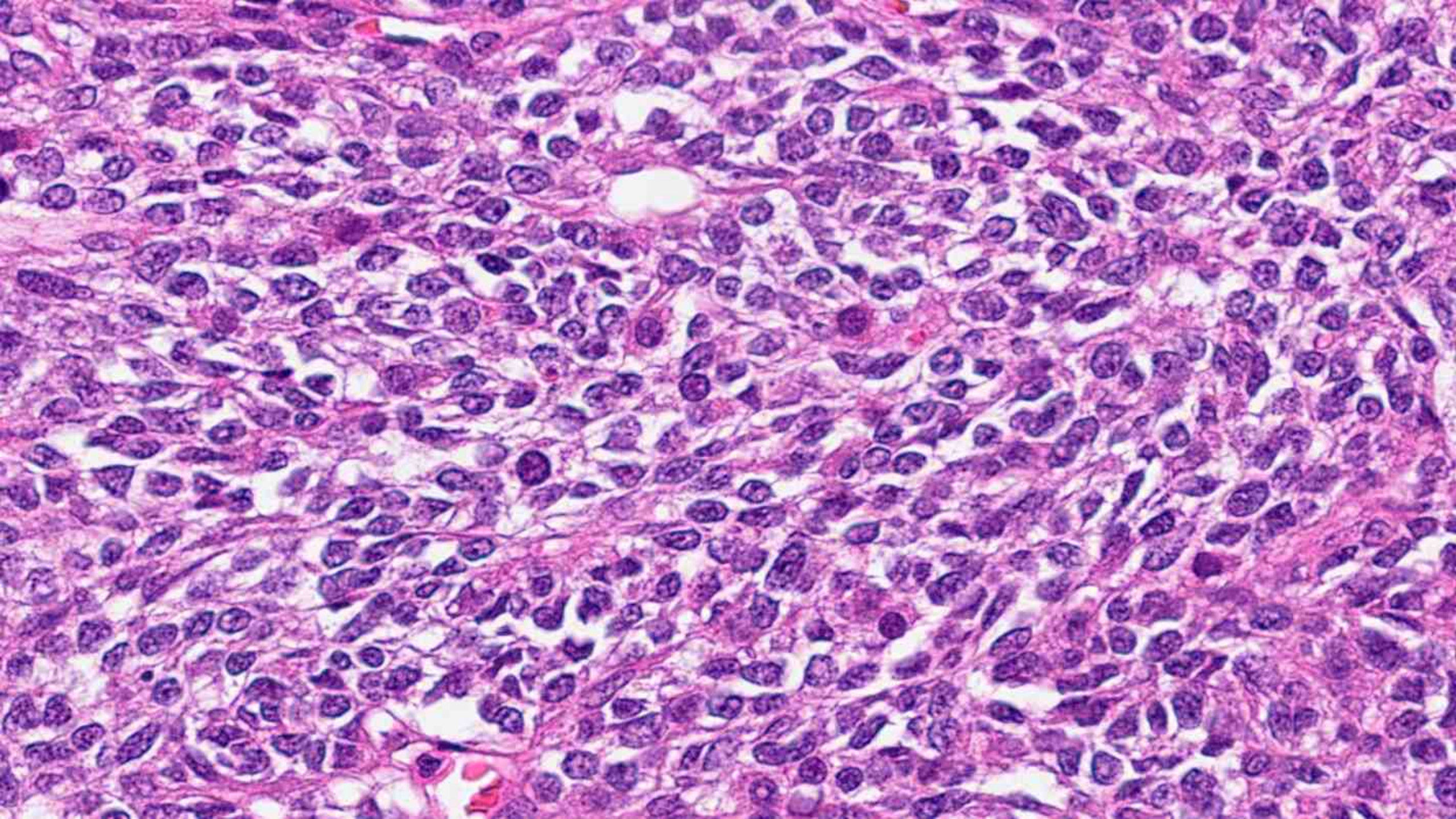

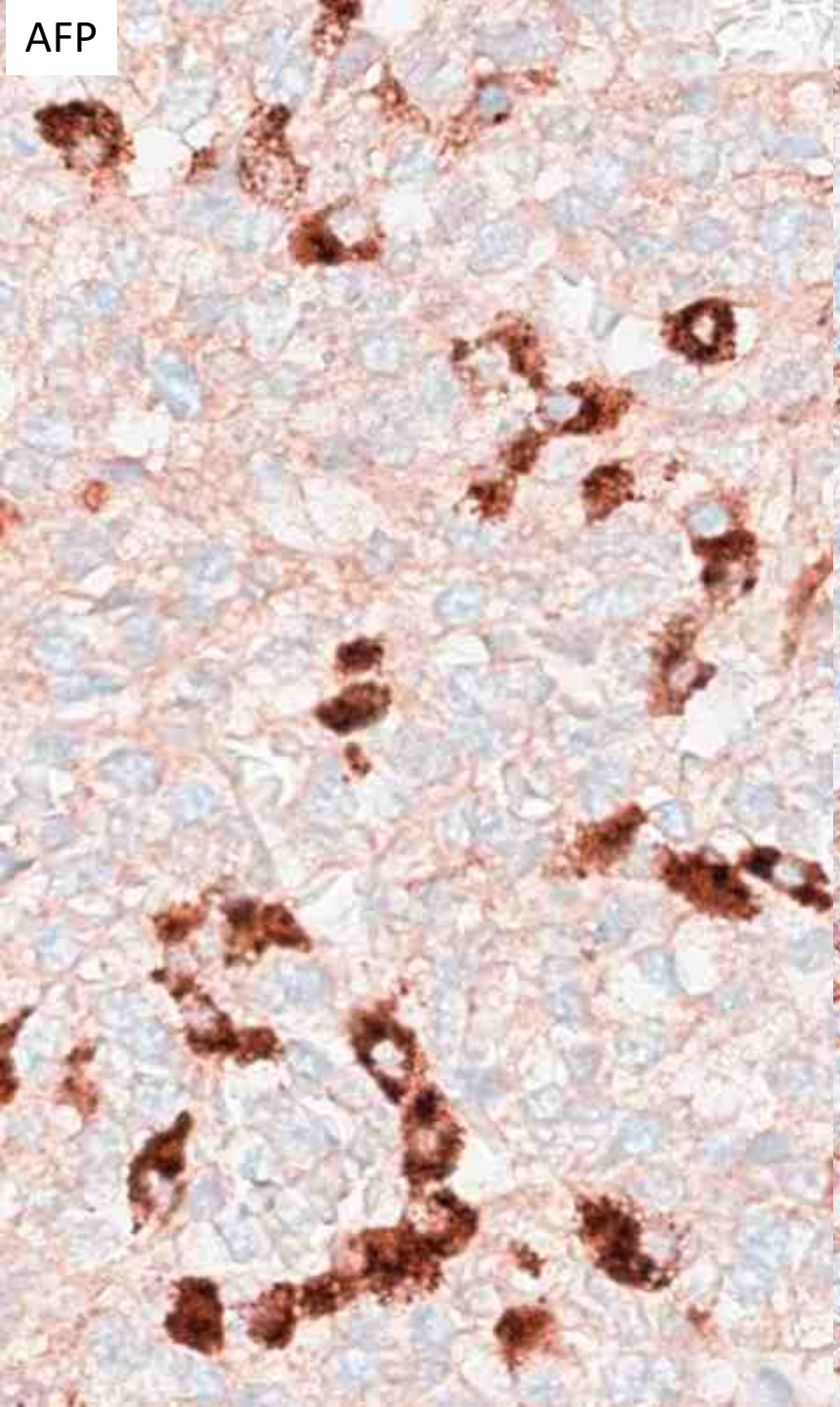
AFP

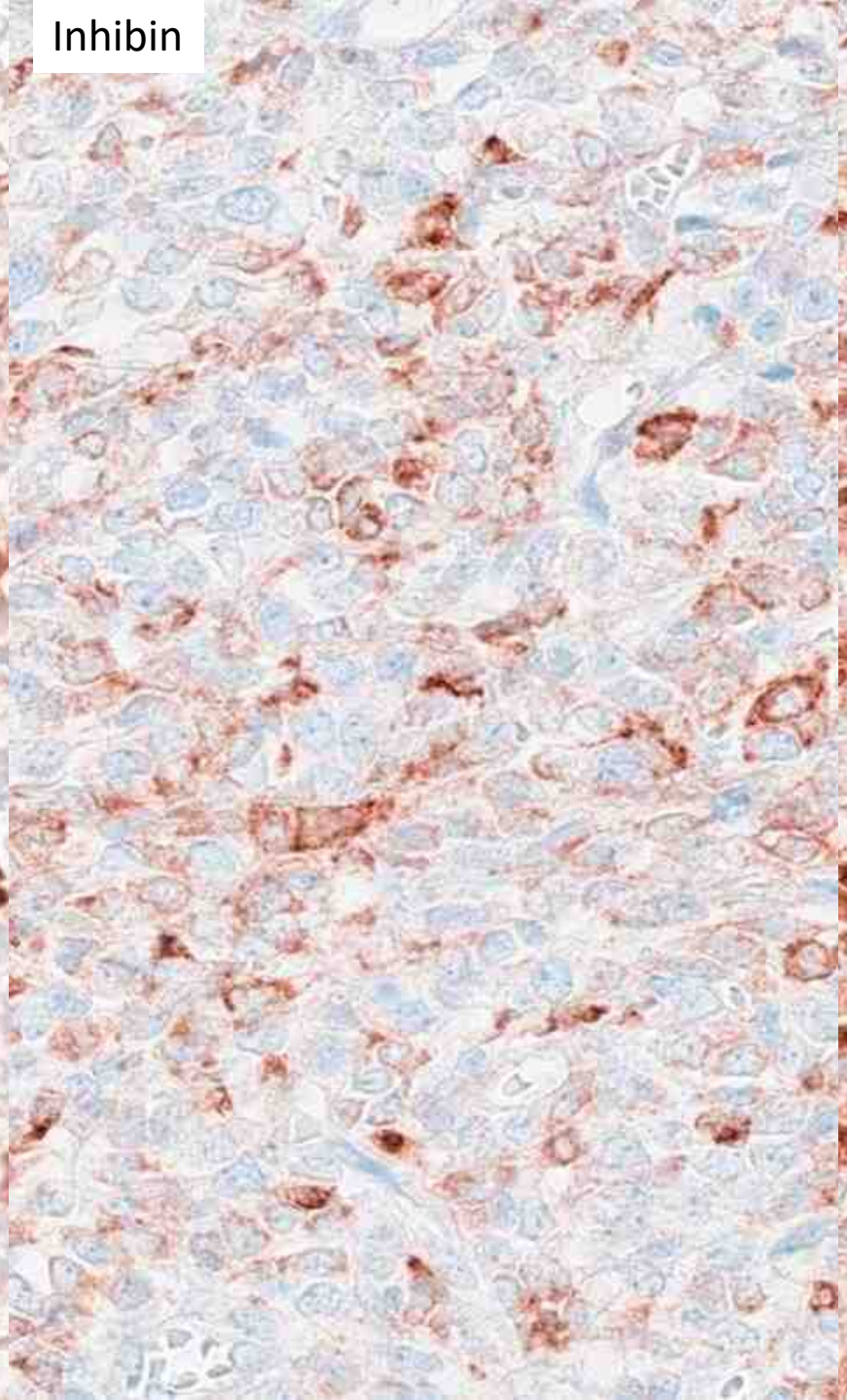
Inhibin

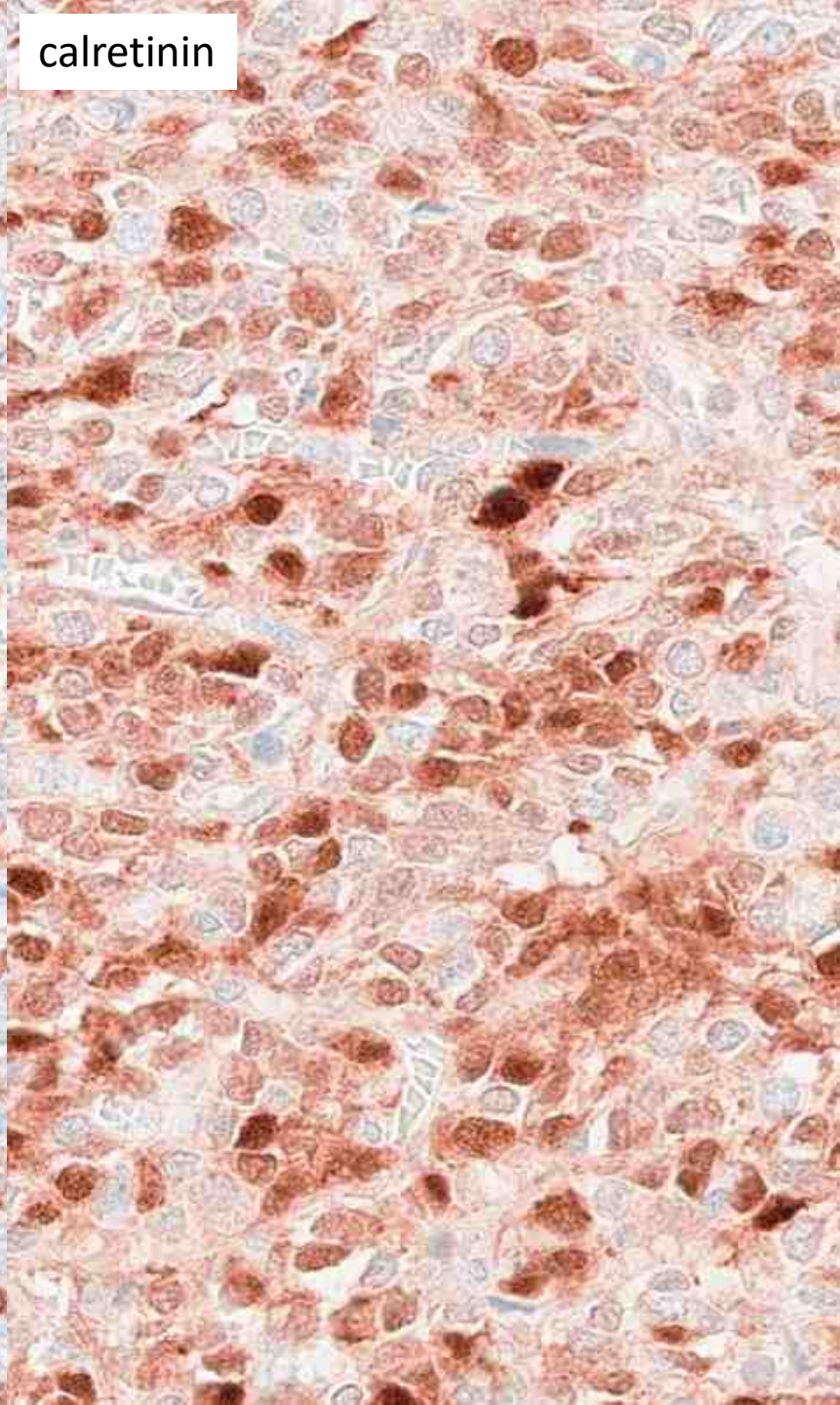
calretinin

WHO 2020
AGCT.
Esther Oliva

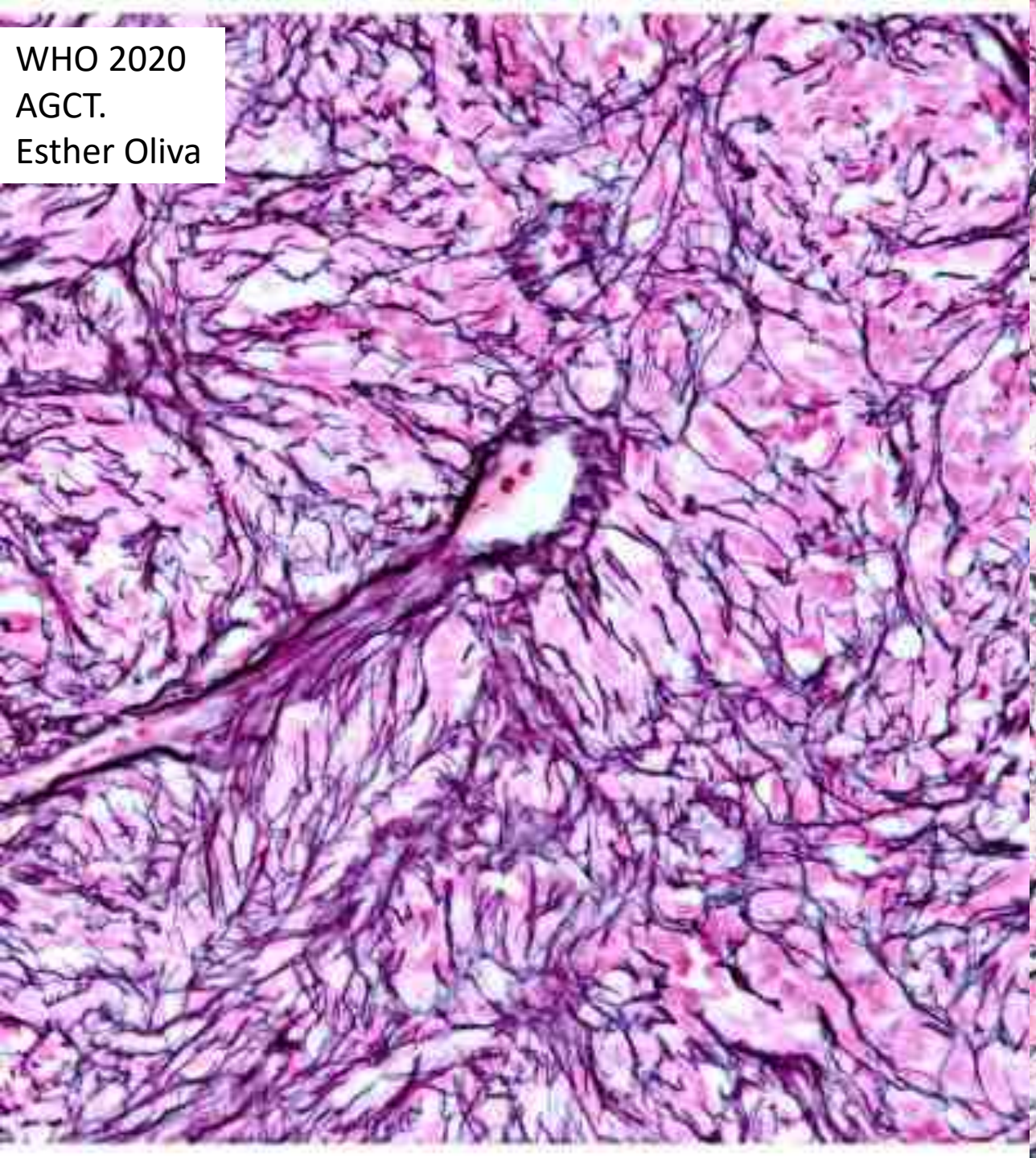

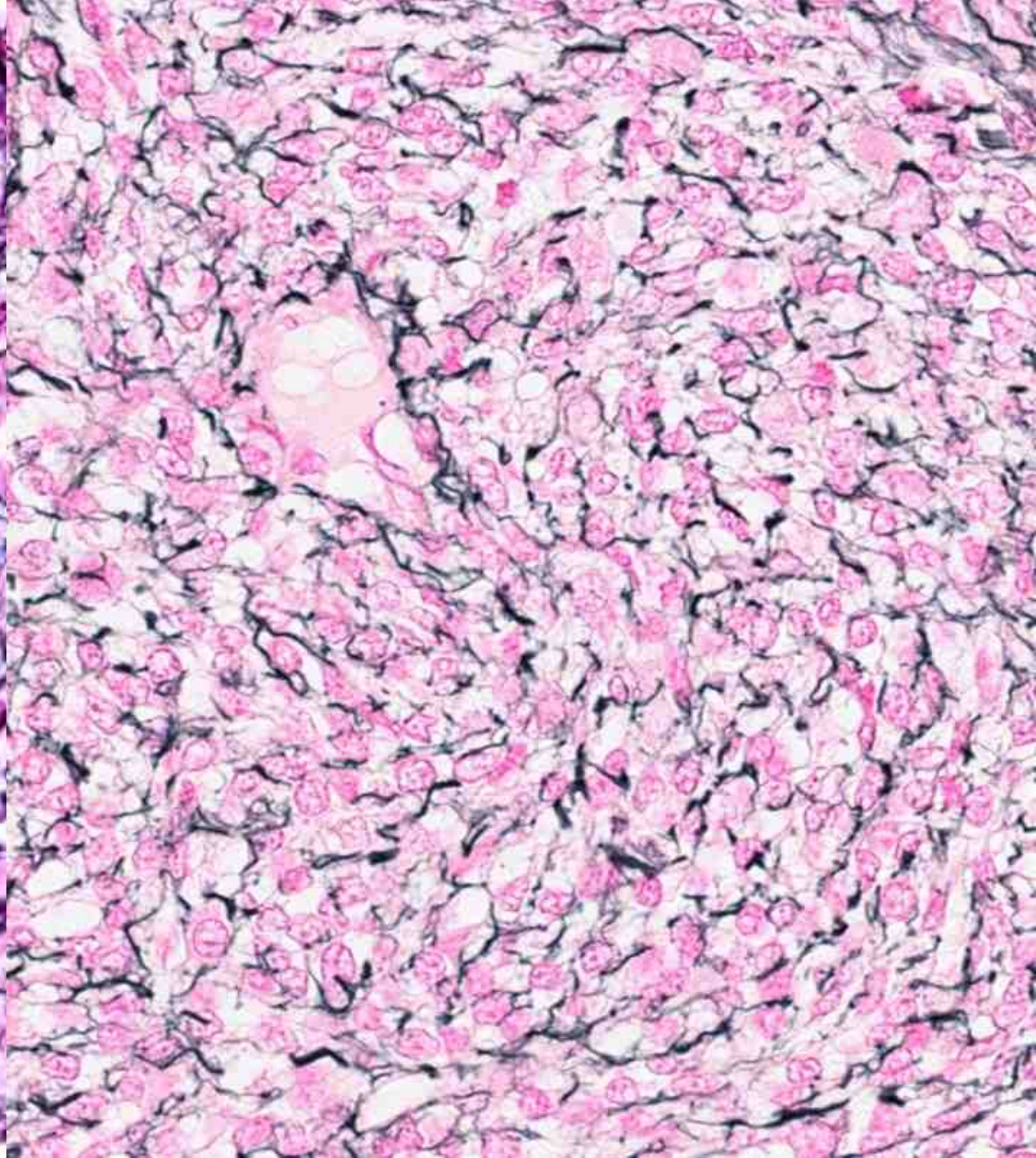


20 mm
mm
0 10 20 30
24R000109
Cirdan Imaging
06-Feb-2024

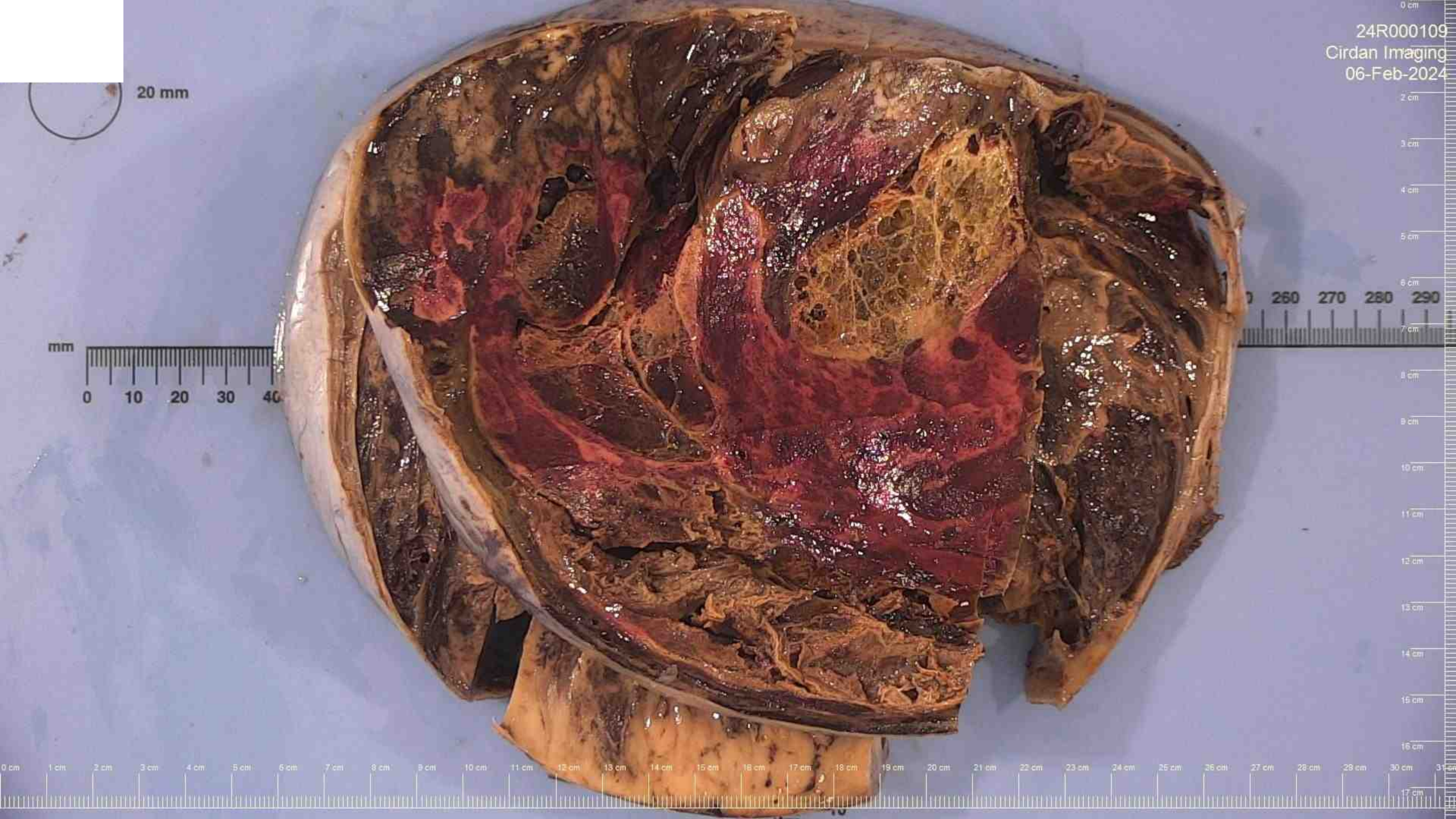
24R000109
Cirdan Imaging
06-Feb-2024
20 mm
mm
0 10 20 30 40
260 270 280 290

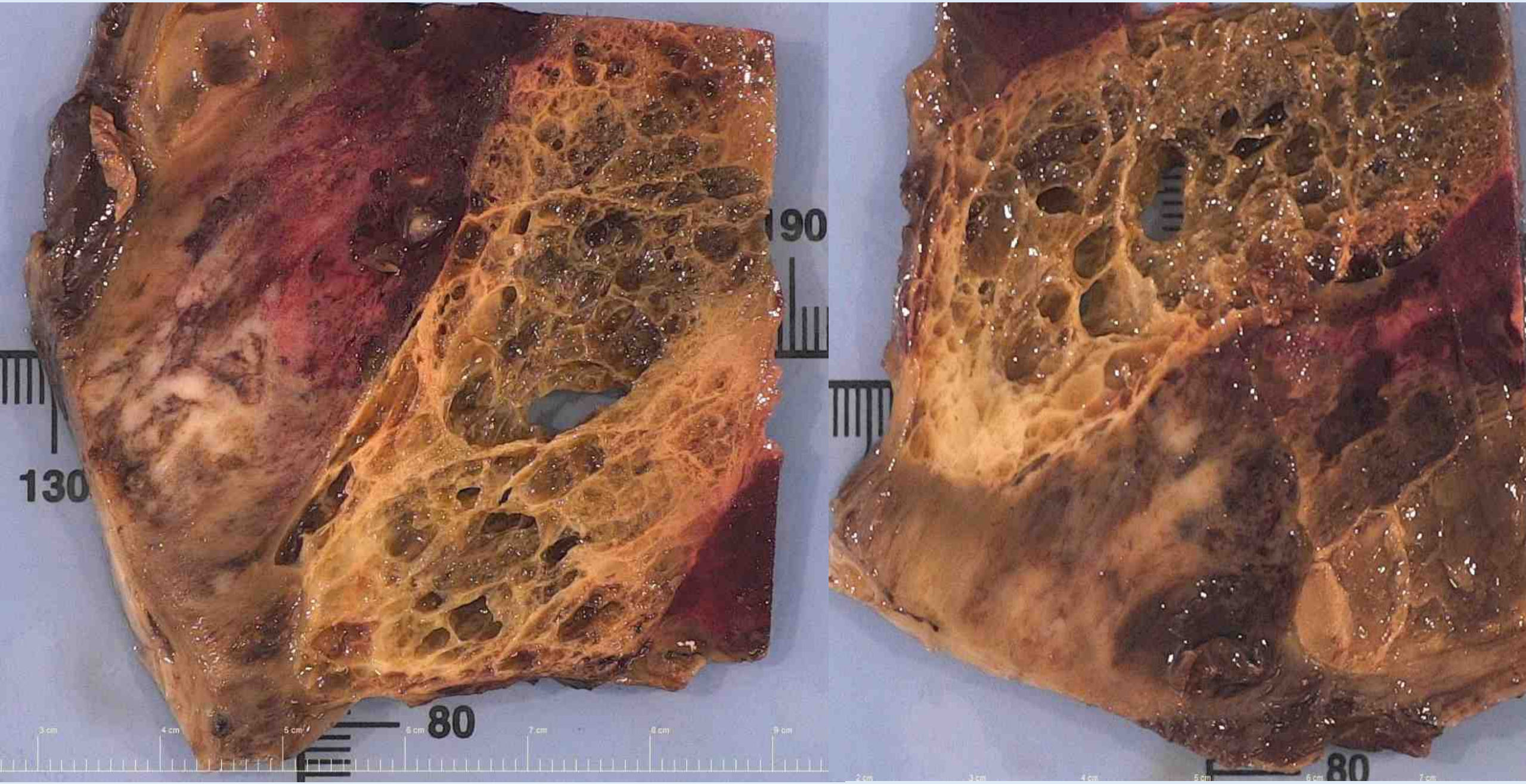
190
130
80
3 cm
4 cm
5 cm
6 cm
7 cm
8 cm
9 cm
80

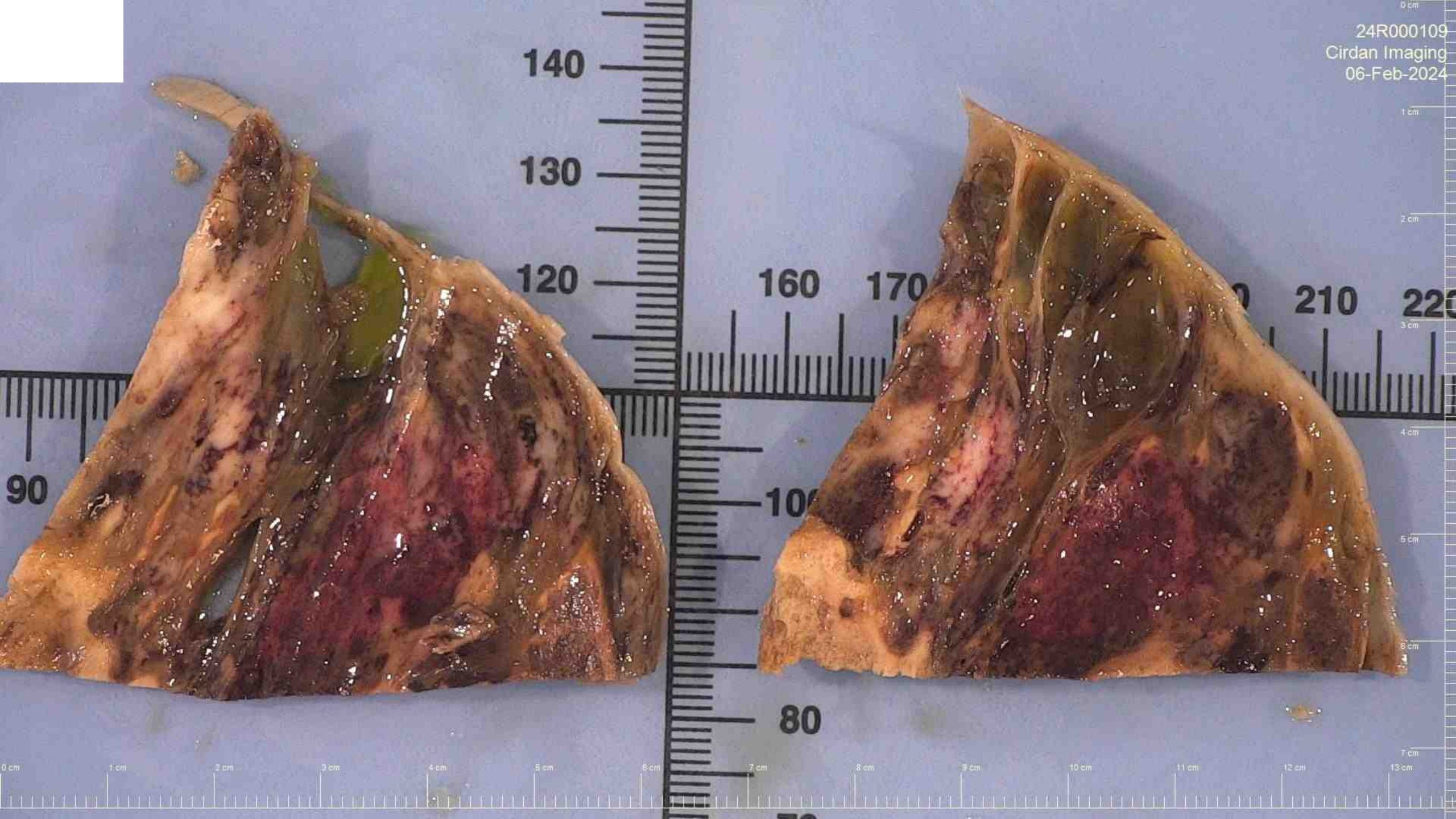
24R000109
Cirdan Imaging
06-Feb-2024

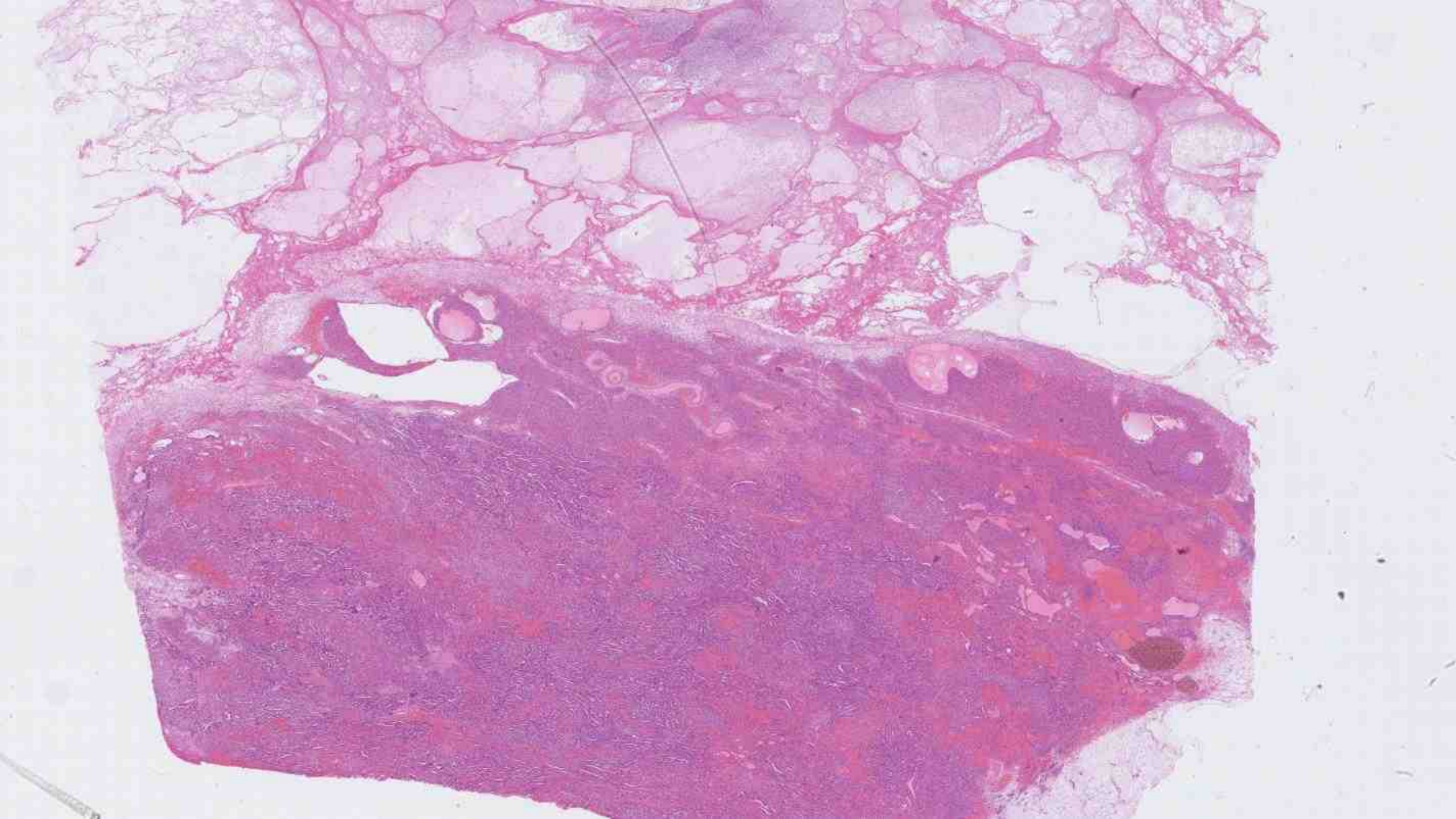

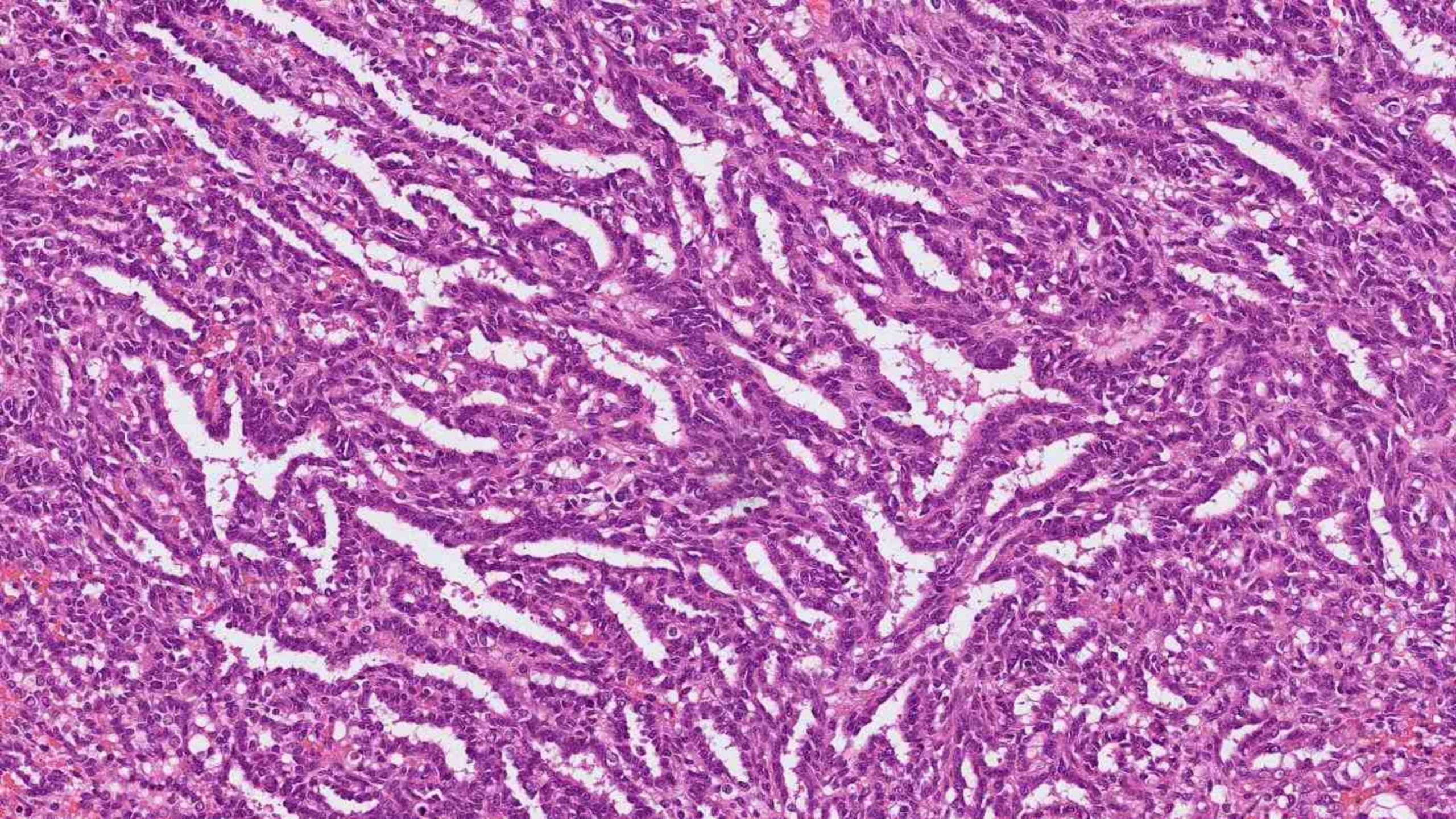

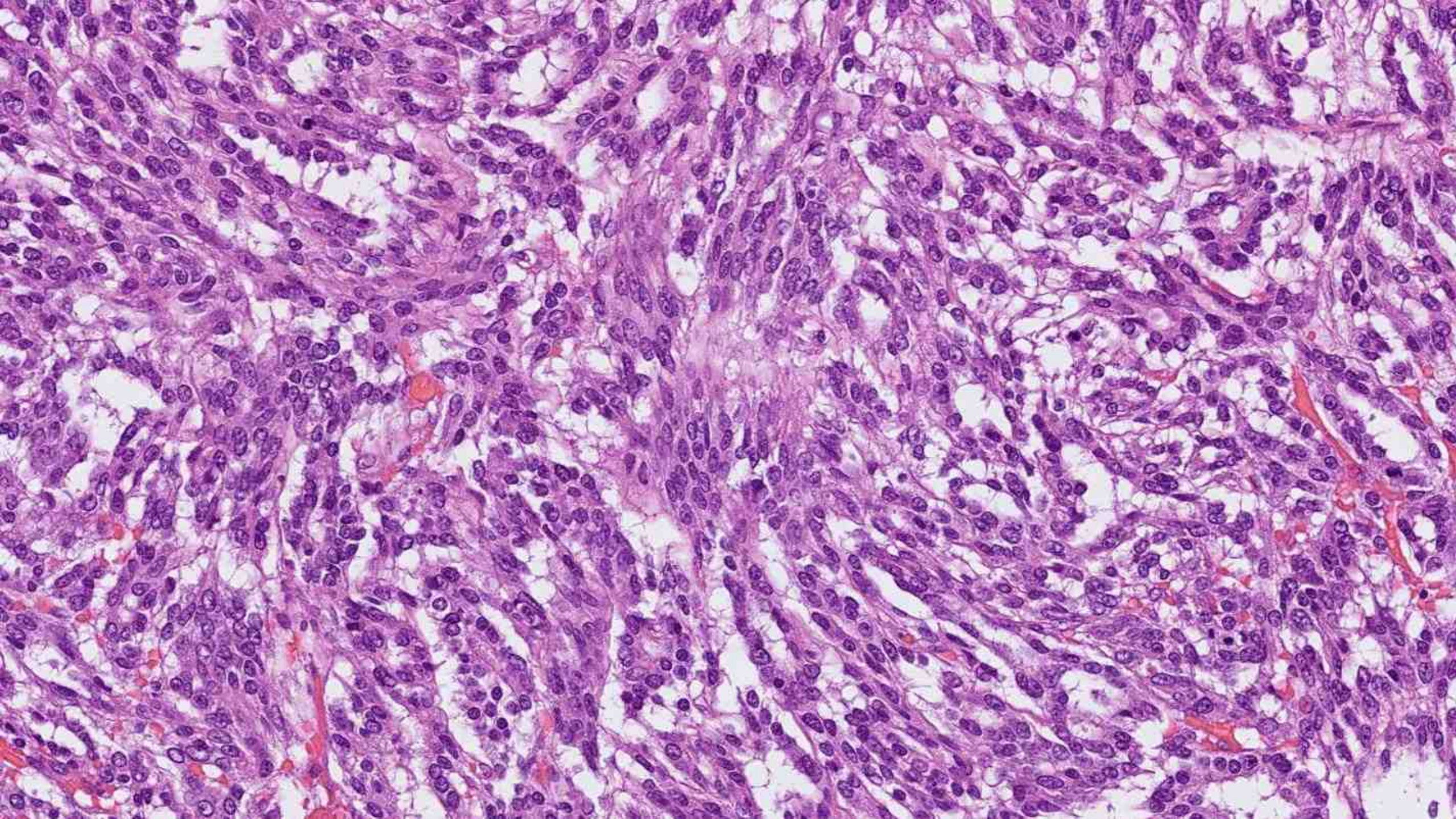

Hindawi
Case Reports in Obstetrics and Gynecology
Volume 2022, Article ID 4759826, 8 pages
https://doi.org/10.1155/2022/4759826

Case Report

15-Year-Old Patient with an Unusual Alpha-Fetoprotein-Producing Sertoli-Leydig Cell Tumor of Ovary

Kaçar Serife,[1] **Stavros Karampelas**,[2] **Nathalie Hottat**,[3] **Christine Devalck**,[4] **and Katherina Vanden Houte**[1]

[1]*Department of Pathology, Brugmann University Hospital Center, Université Libre de Bruxelles, Belgium*
[2]*Department of Gynecological Surgery, Brugmann University Hospital Center, Université Libre de Bruxelles, Belgium*
[3]*Department of Medical Imaging, Brugmann University Hospital Center, Université Libre de Bruxelles, Belgium*
[4]*Pediatric Oncology Reine Fabiola Children's University Hospital, Université Libre de Bruxelles, Belgium*

Correspondence should be addressed to Kaçar Serife; serifemedkacar@gmail.com

Received 16 September 2021; Accepted 29 March 2022; Published 12 April 2022

Learning points

- Gross appearance can give you a clue to architectural patterns-feathery/retiform pattern raises suspicion of SL tumours and DICER1 syndrome
- In unclassifiable sex cord stromal tumours – look for heterologous areas (grossly-the multicystic likely mucinous areas) as these areas are more likely harbour better differentiated areas to help clinch the diagnosis
- Careful gross examination and strategic block selection can predict molecular results, guiding diagnosis even where molecular testing is unavailable
- Keep an open mind- even when primary diagnosis reasonable, if something feels off, going back to the gross specimen could make all the difference
- Sometimes the answer is not in the sections you've been given, but in the tissue that hasn't been sampled yet!

Diagnosis

Poorly Differentiated Sertoli Leydig Cell Tumour, retiform variant

Retiform pattern highly predictive of DICER 1 mutation

Majority associated with DICER 1 syndrome

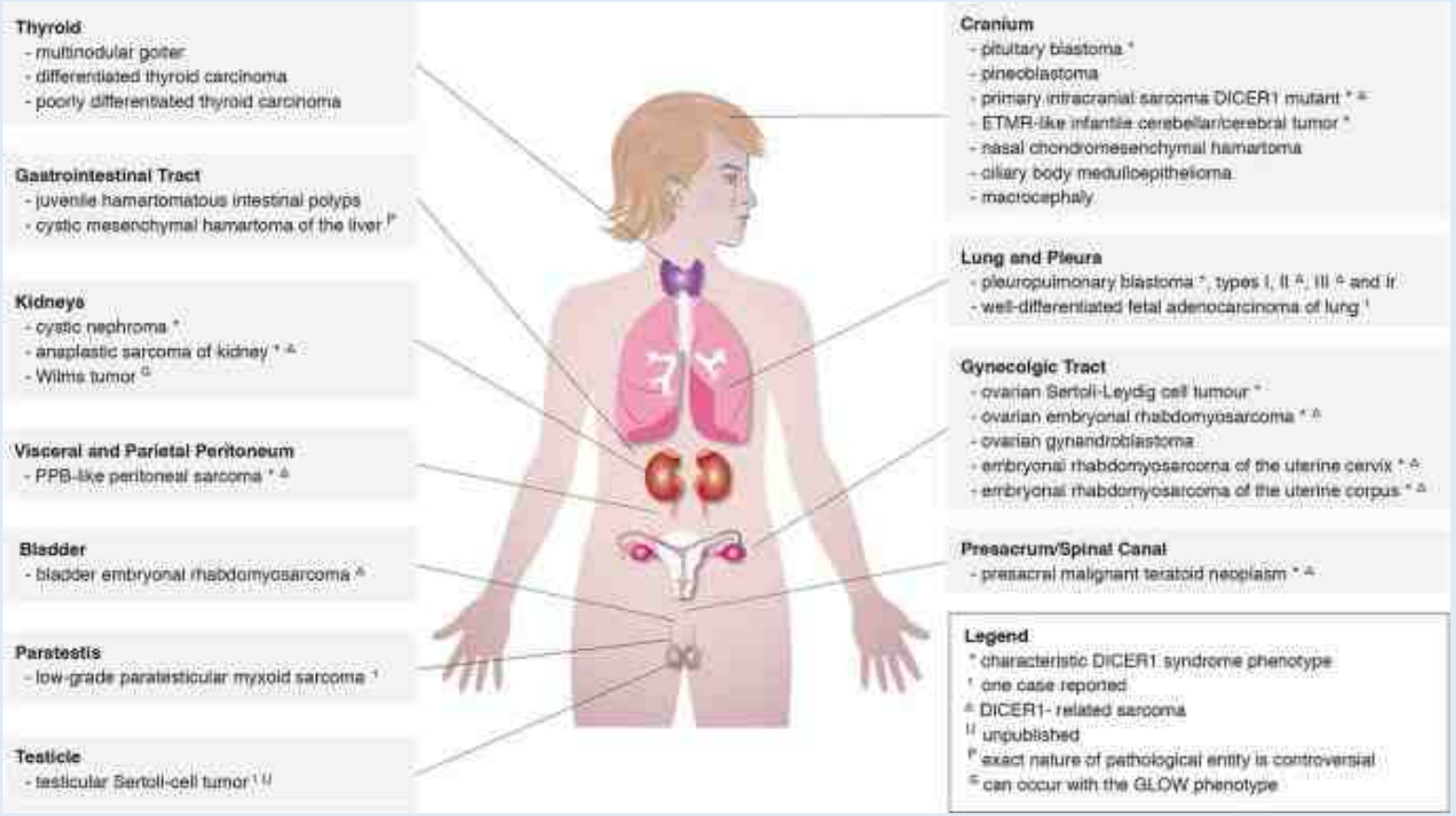

Home › The Hereditary Basis of Childhood Cancer › Chapter

DICER1 Syndrome

William D. Foulkes, Leanne de Kock & John R. Priest

Chapter | First Online: 07 September 2021

Approach to Ovarian Tumours

Weigh



Measure in 3 dimensions



Examine capsular surface for **D**isruption **A**dhesions **D**eposits

FIGO Staging in Ovarian Tumours

Strongest predictor of outcome

- Stage IA — Capsule intact, one ovary involved
- Stage IB — Capsule intact, both ovaries involved
- Stage IC1 — Surgical Spill
- Stage IC2 — Capsule rupture before surgery *or* Tumour on capsular surface
- Stage IC3 — Malignant cells in ascitic fluid/peritoneal washings

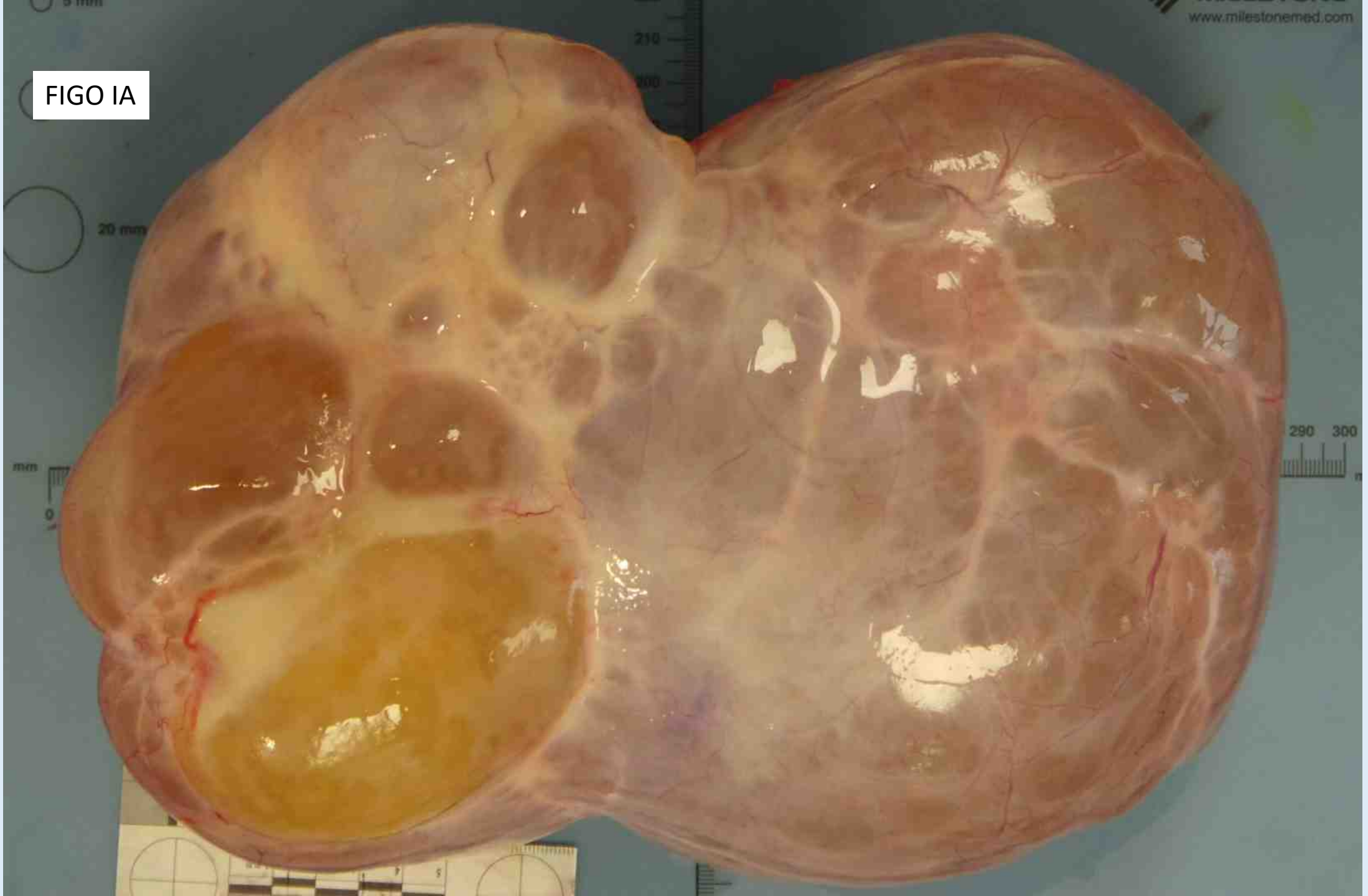
FIGO IA

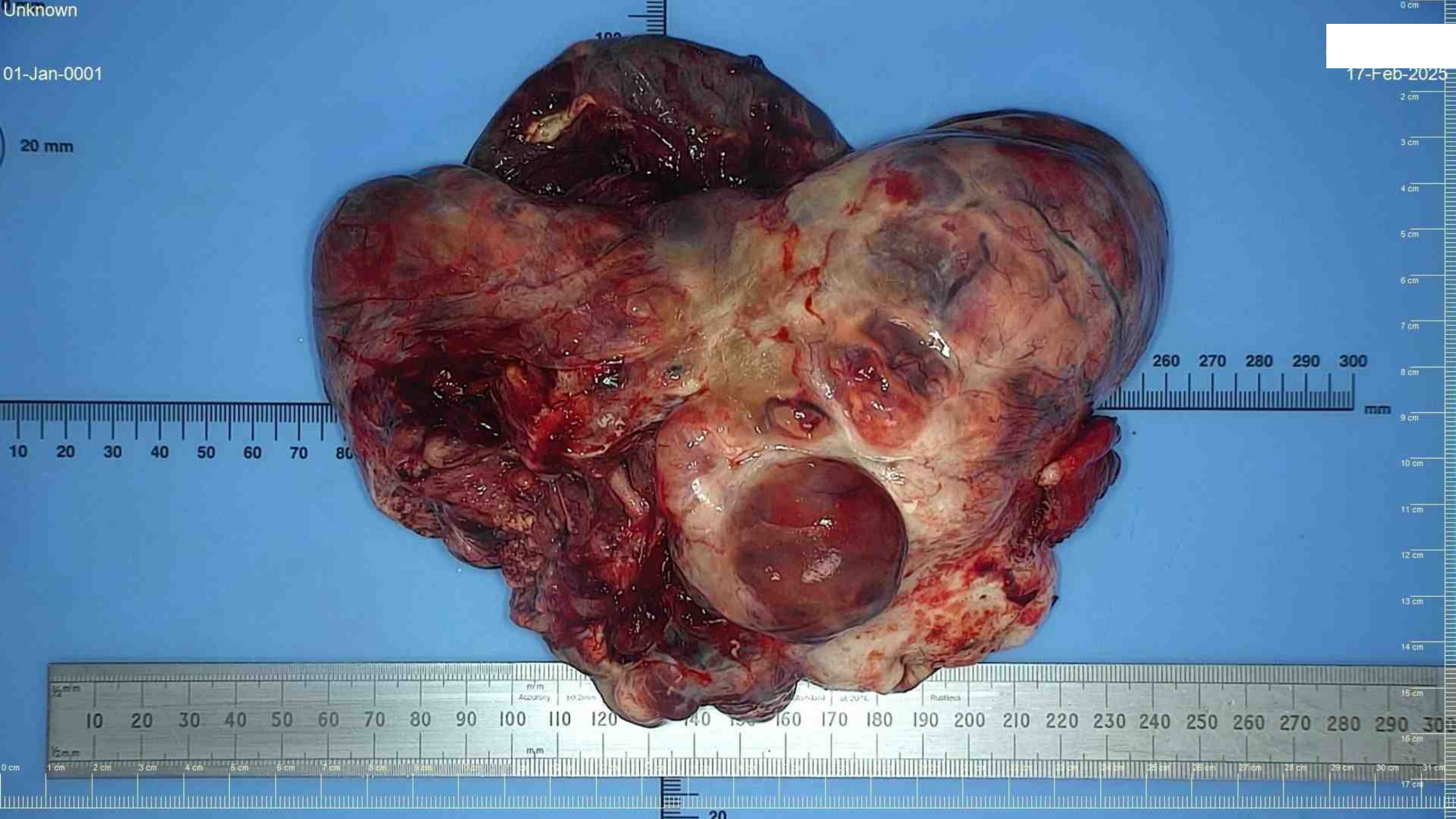
Unknown
01-Jan-0001
17-Feb-2025
20 mm

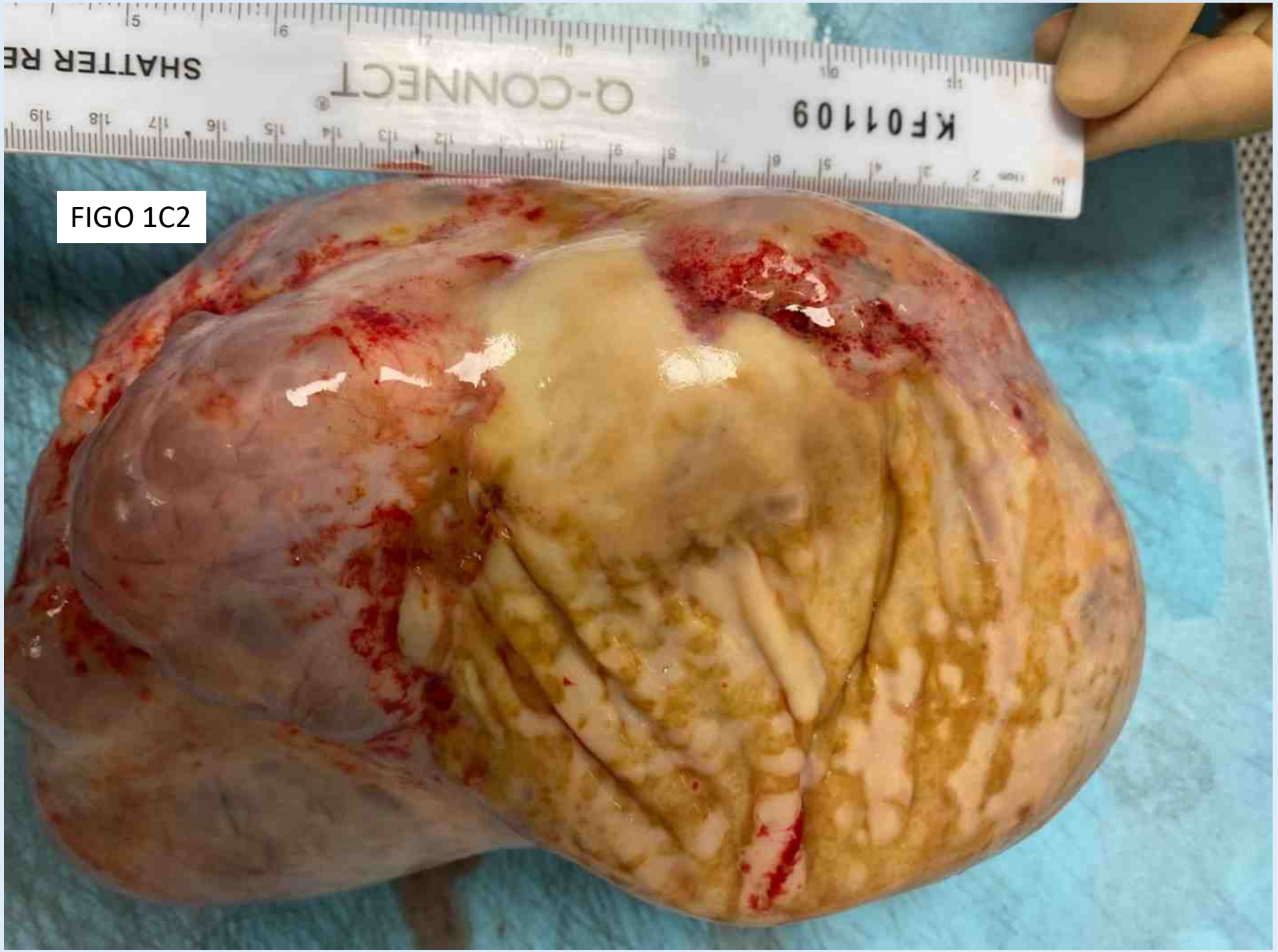
FIGO 1C2


FIGO 1C2

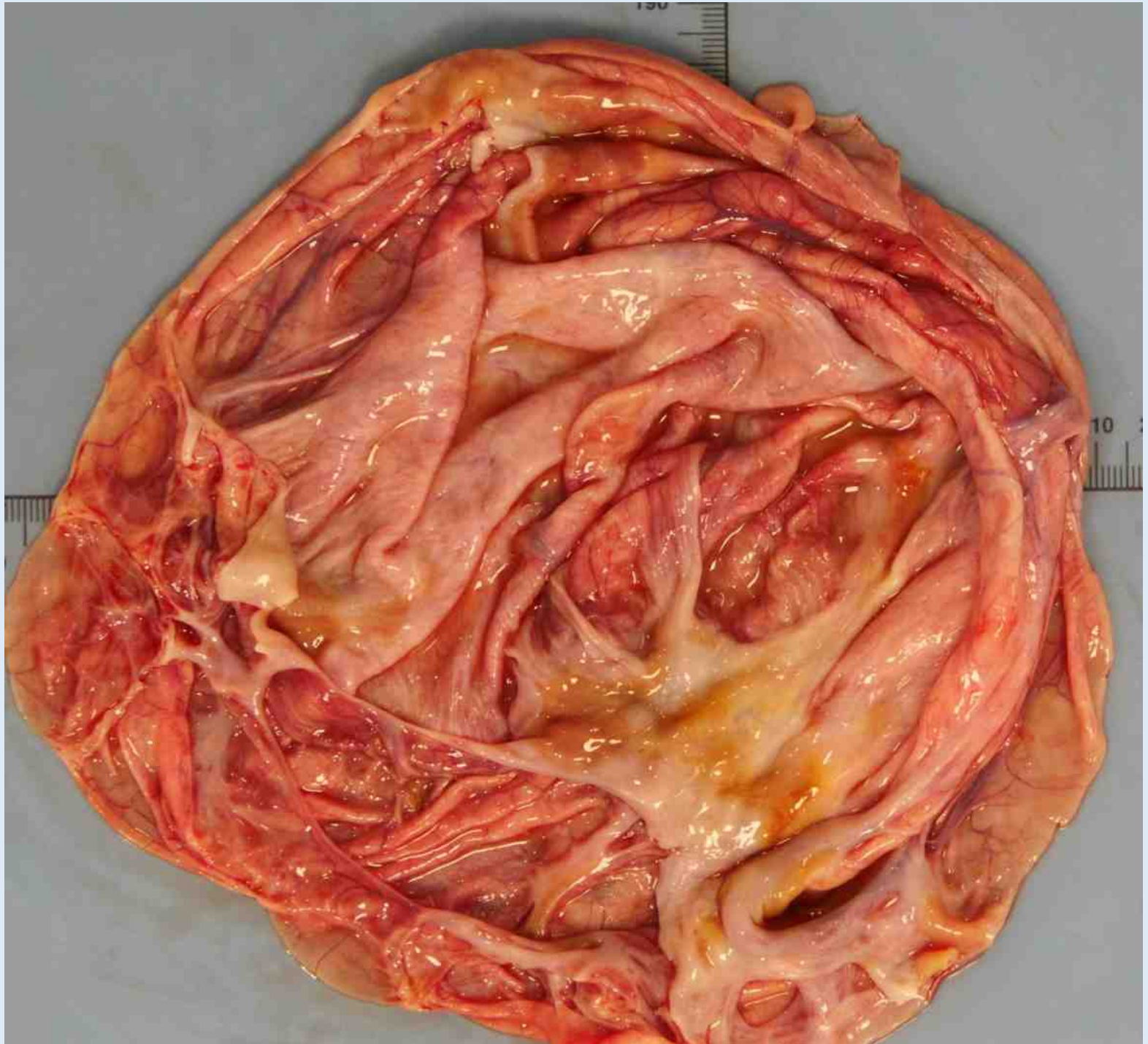

< 10cm=1 section/cm

>10cm =2 sections/cm

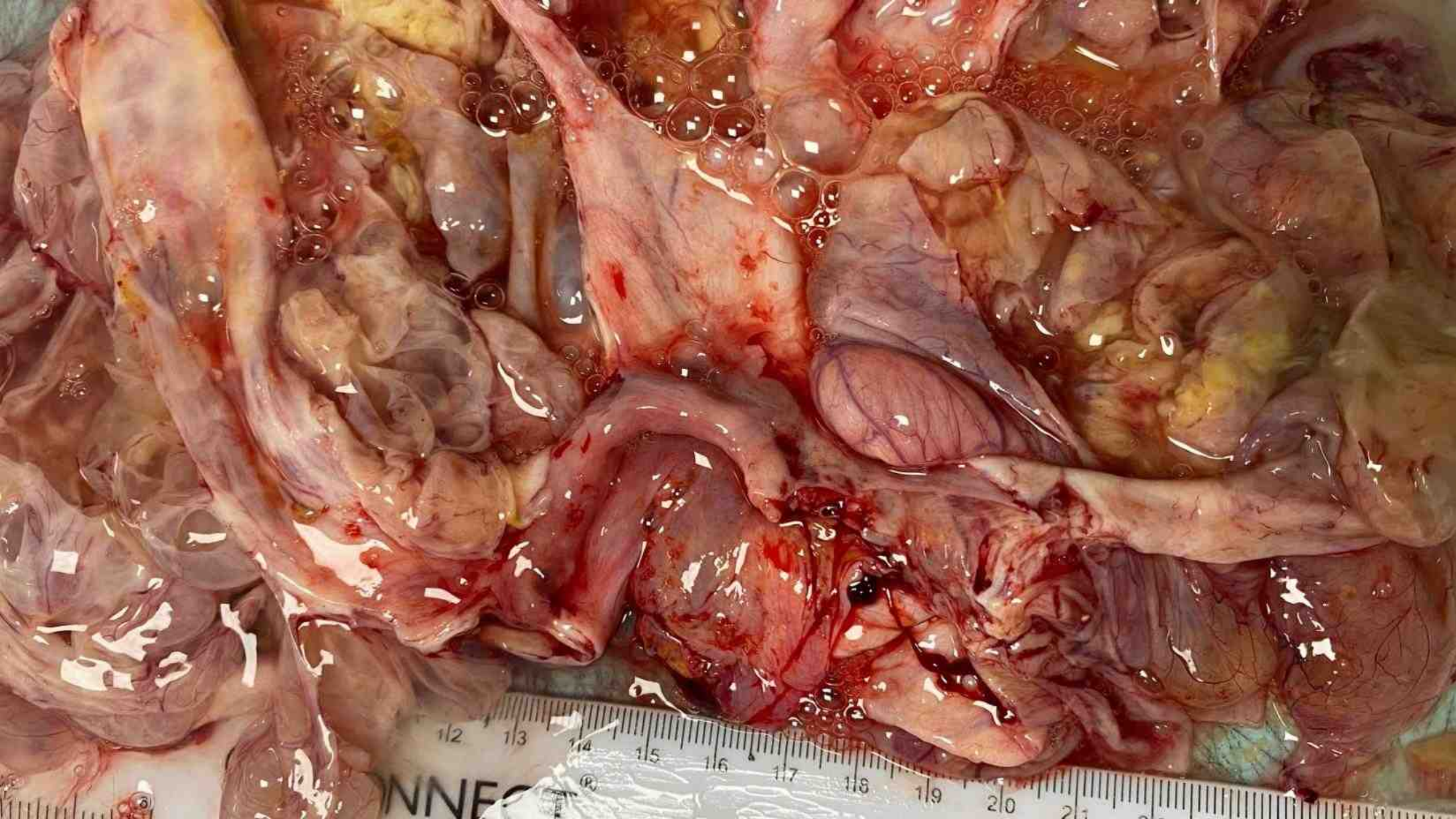



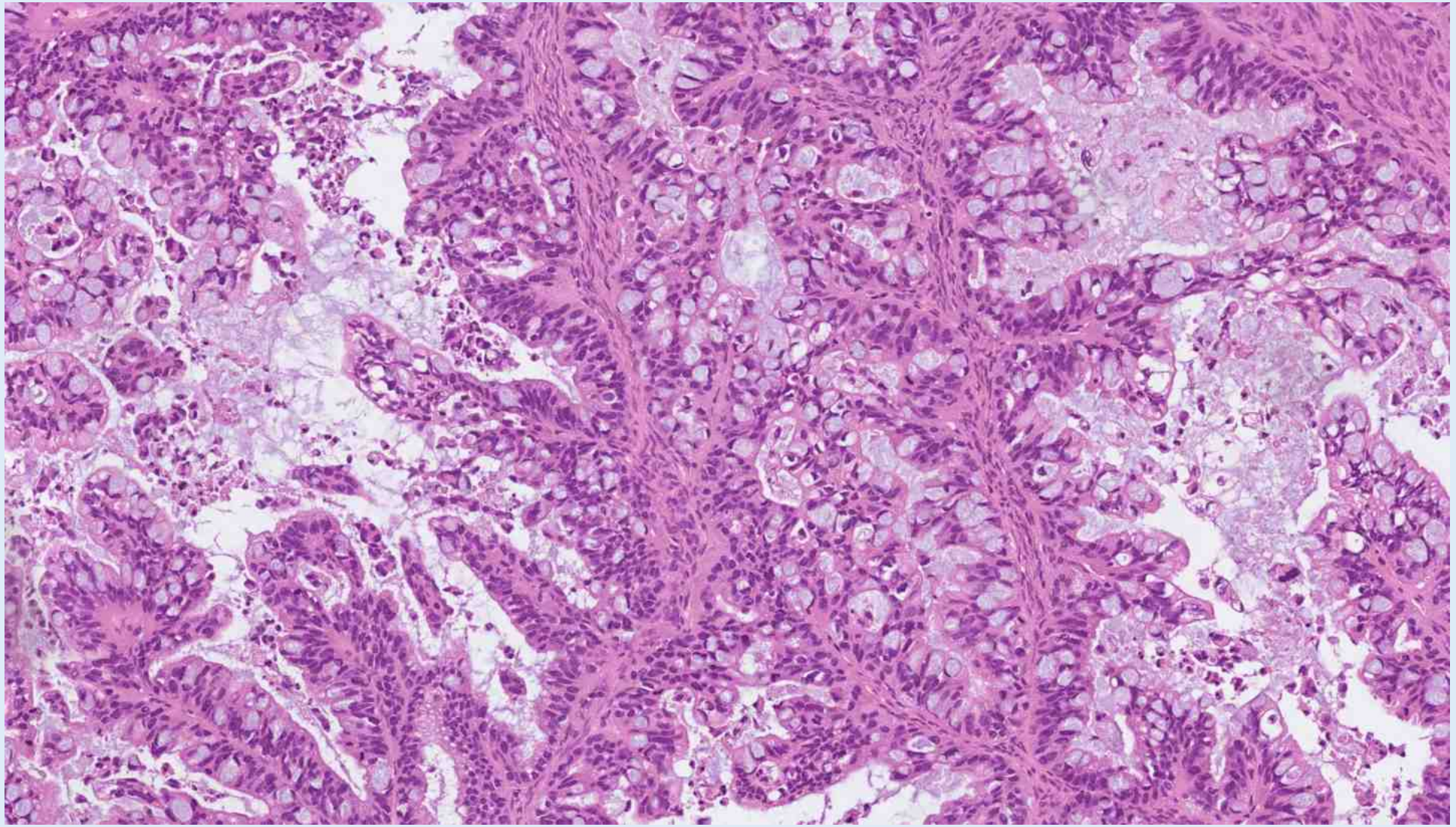

Final diagnosis: Mucinous carcinoma of the ovary

FIGO 1C1

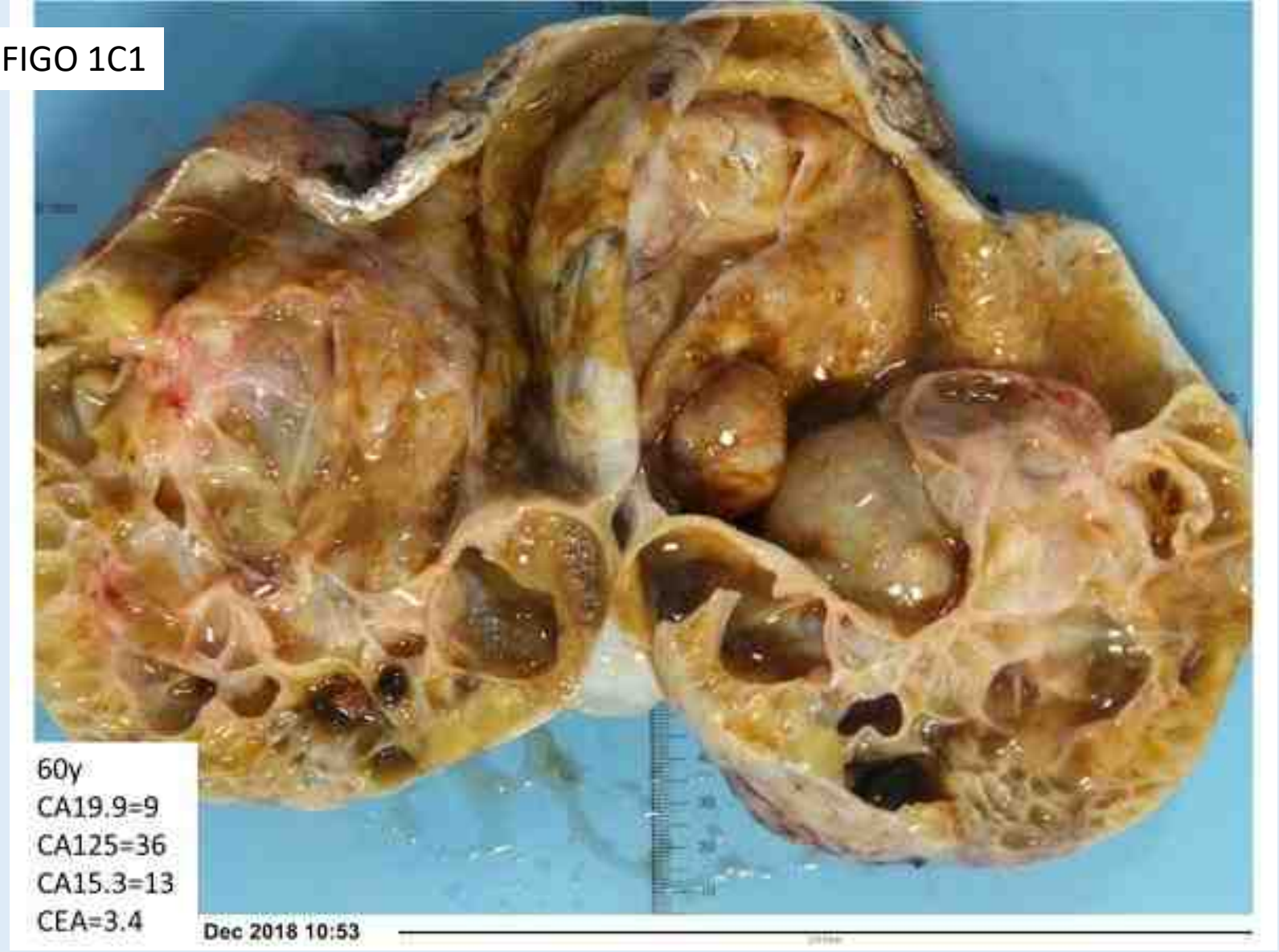

Mucinous tumour with mural nodule
Mural nodule – not always nodular
May appear like a velvety plaque
Surgical spill FIGO IC1

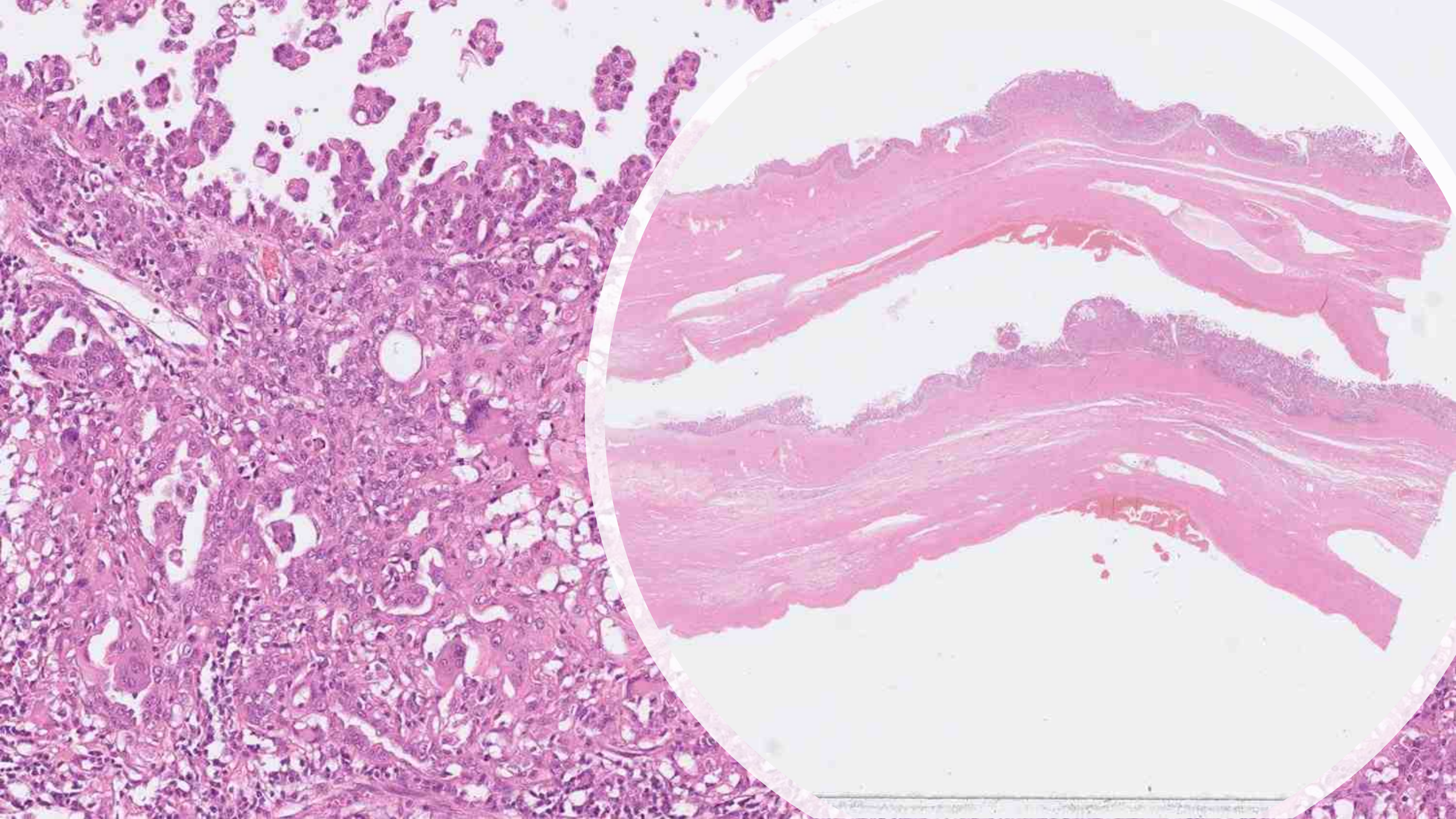

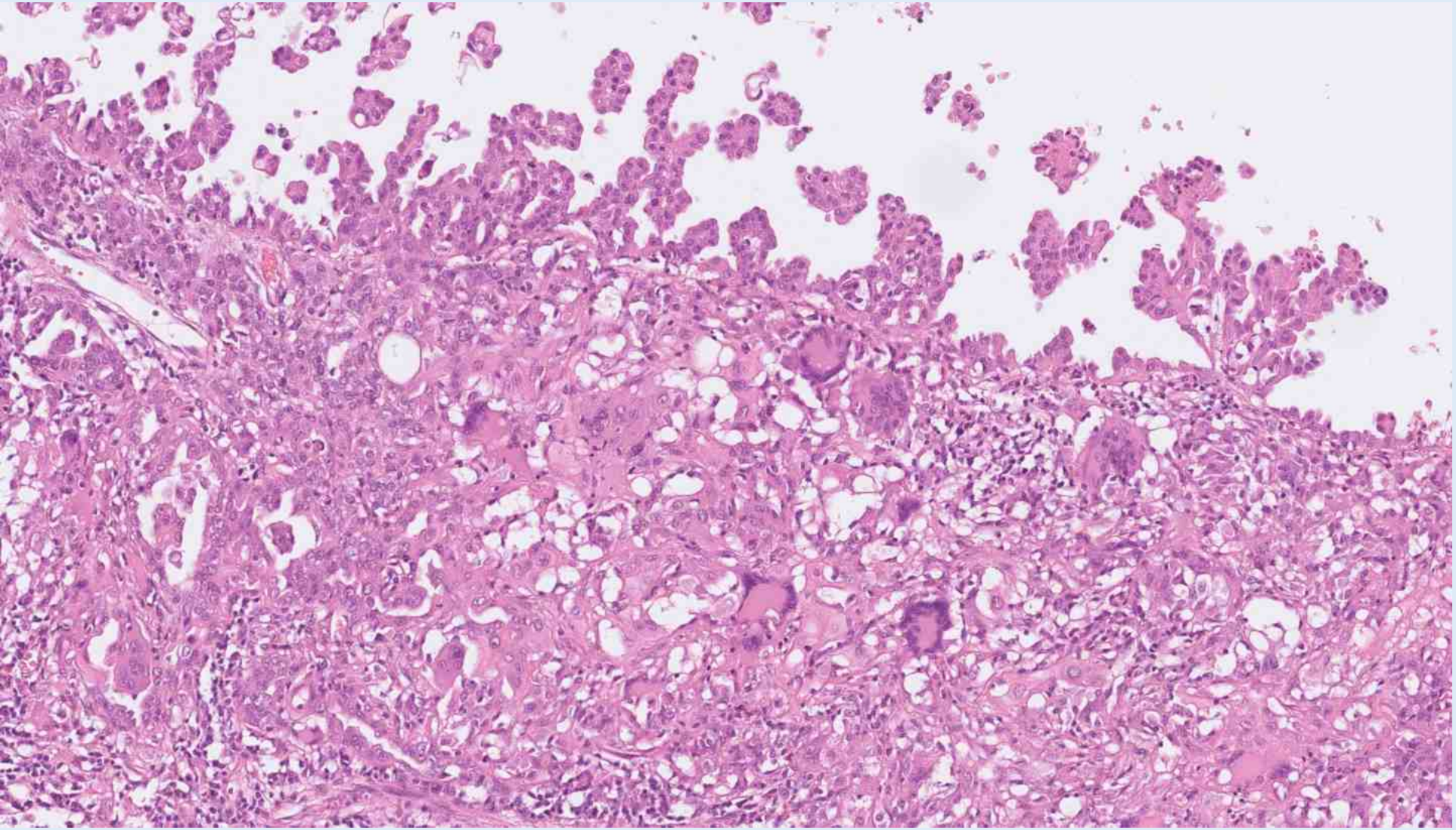

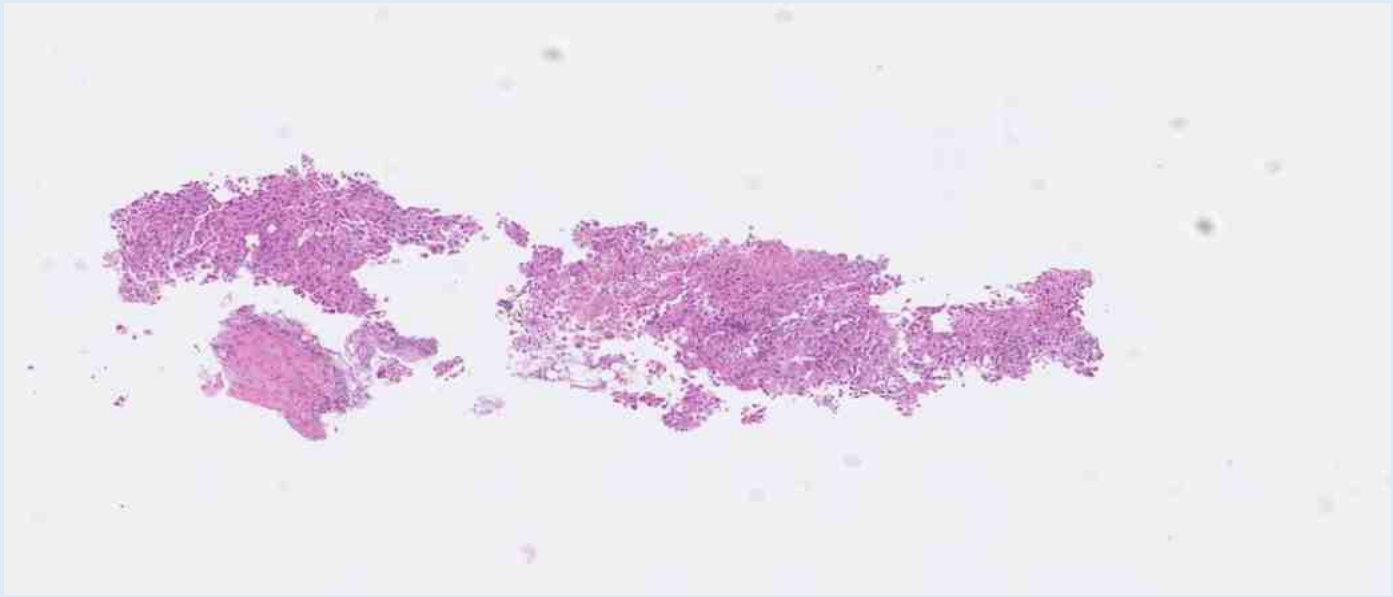

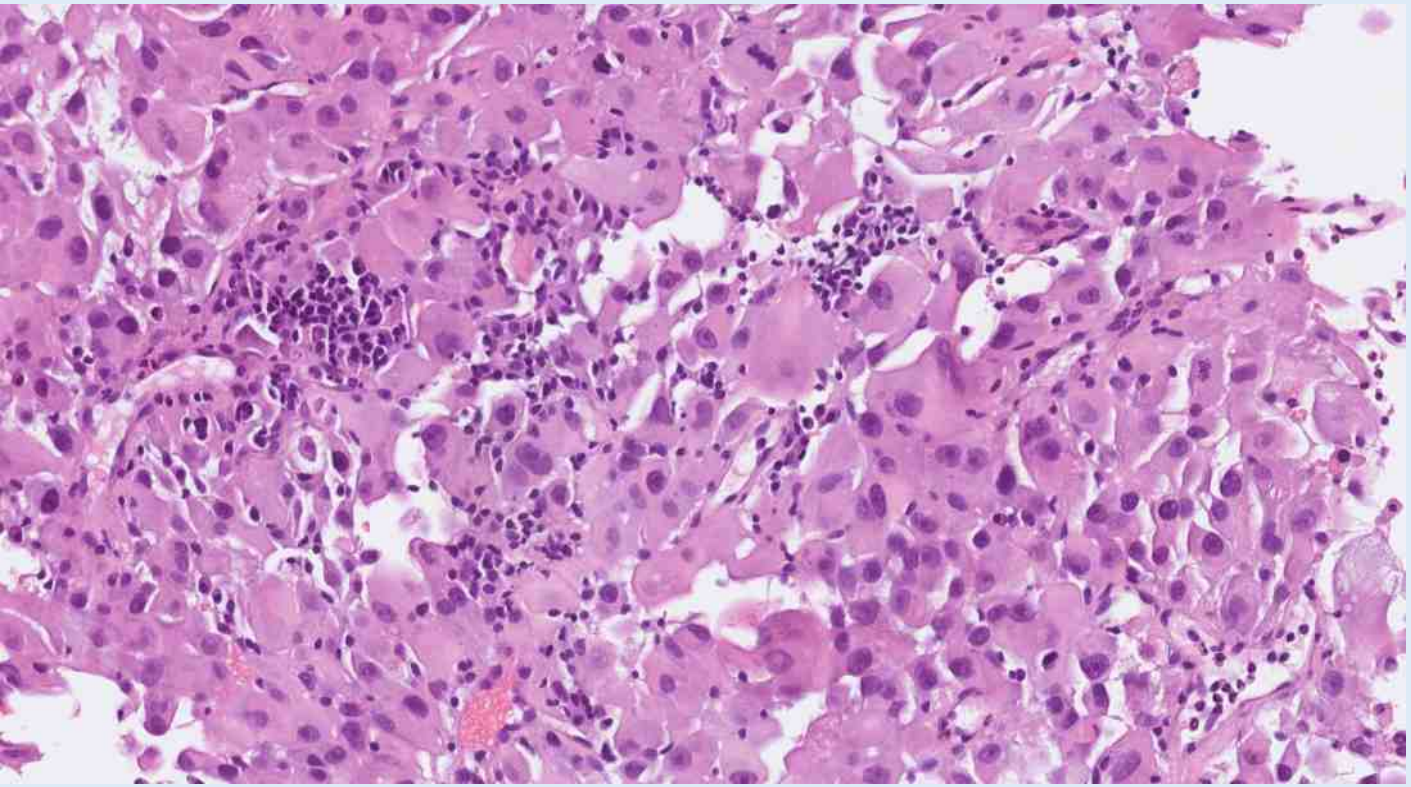

Recurrence of the mural nodule component. Inoperable.
DOD 2 yrs

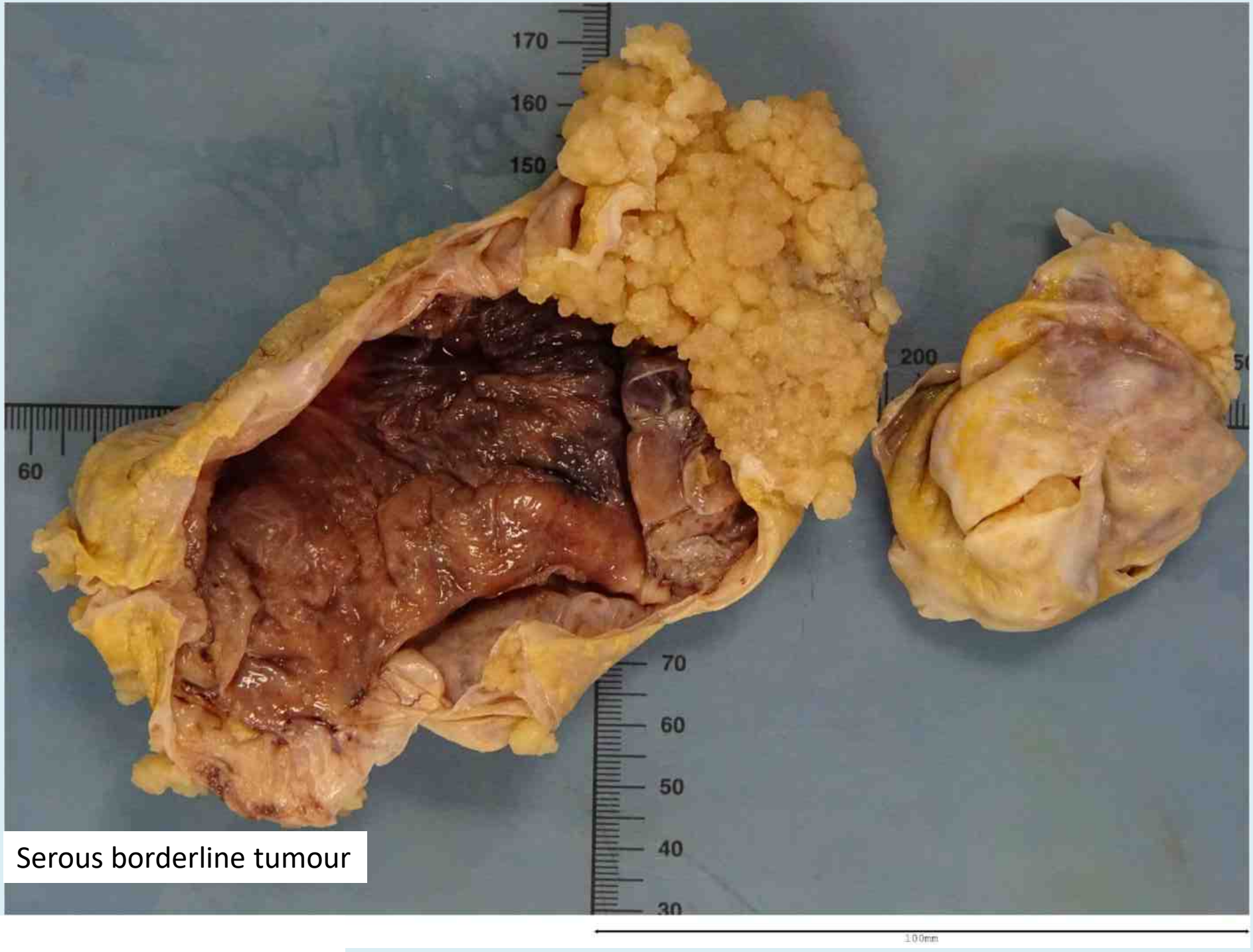

Serous borderline tumour

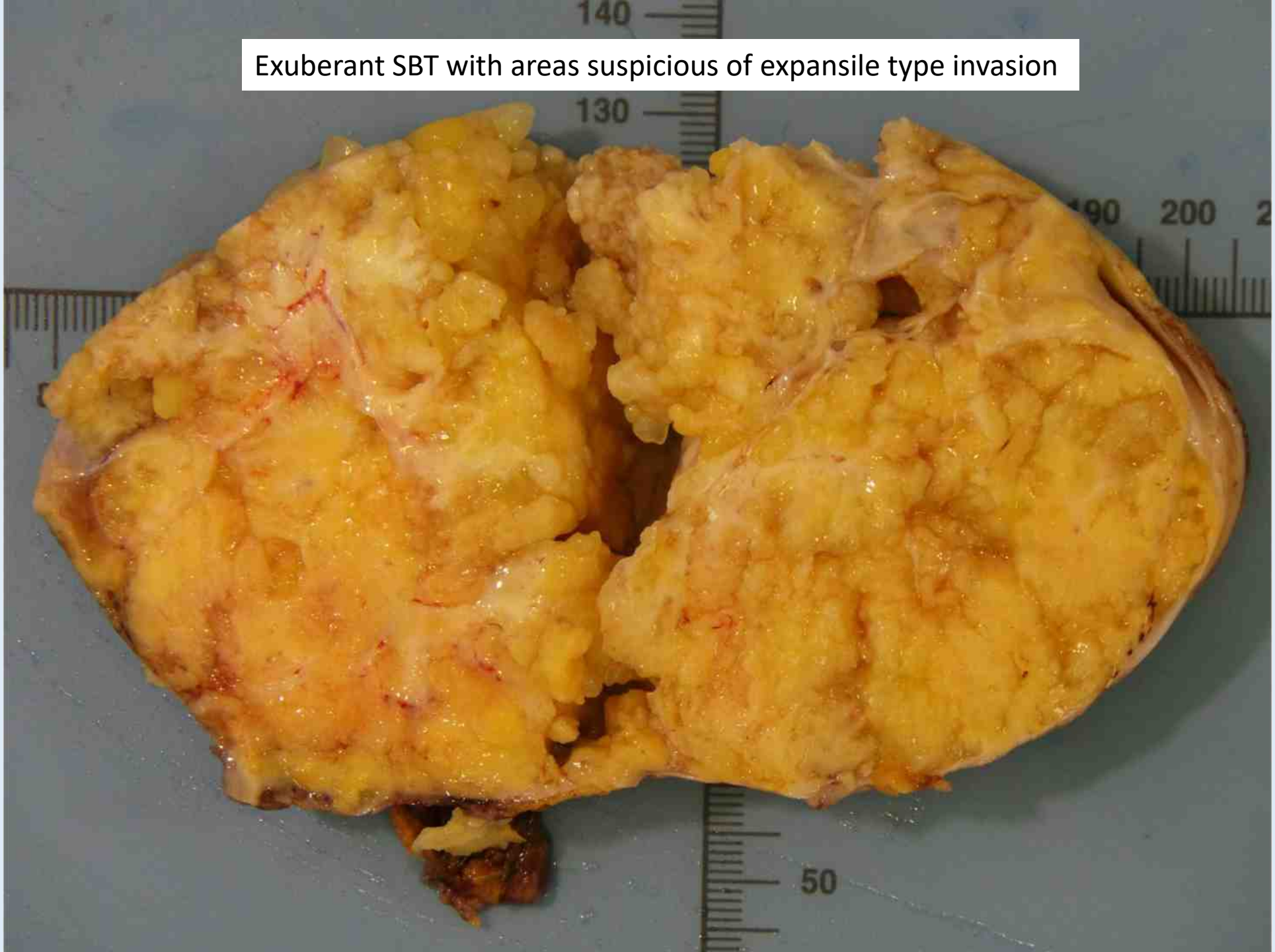
Exuberant SBT with areas suspicious of expansile type invasion
140
130
200
50

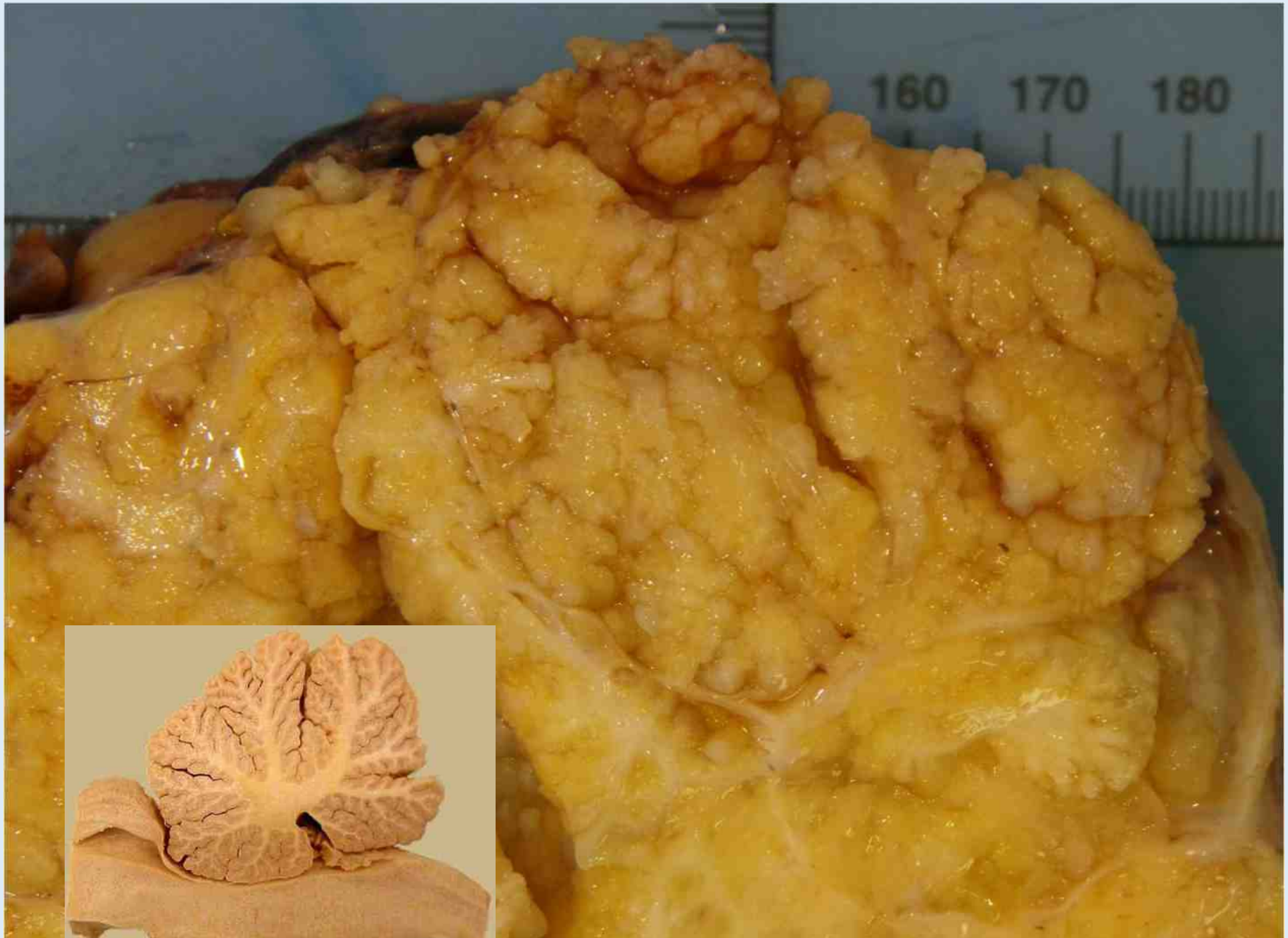
160
170
180

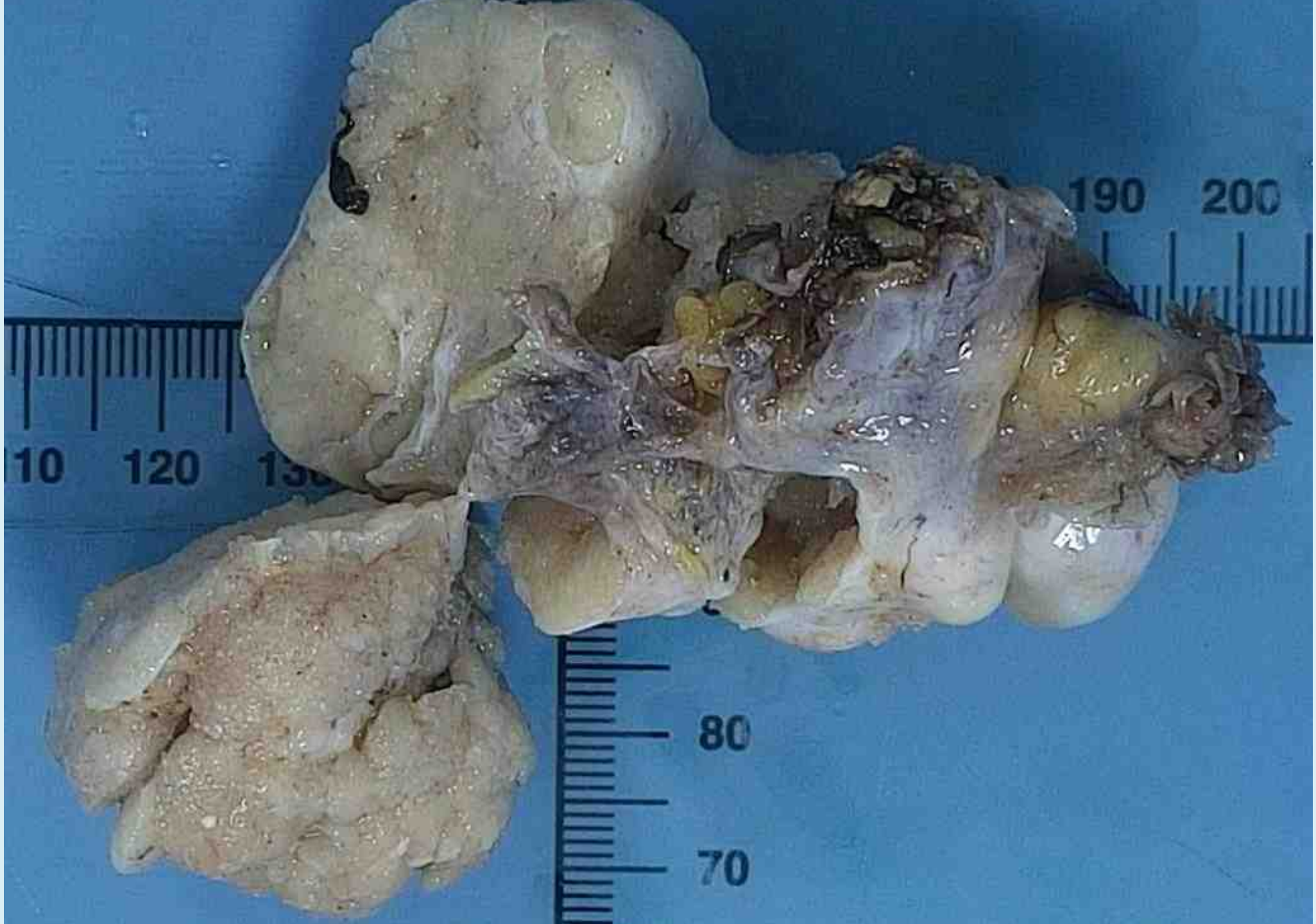
190
200
110
120
80
70

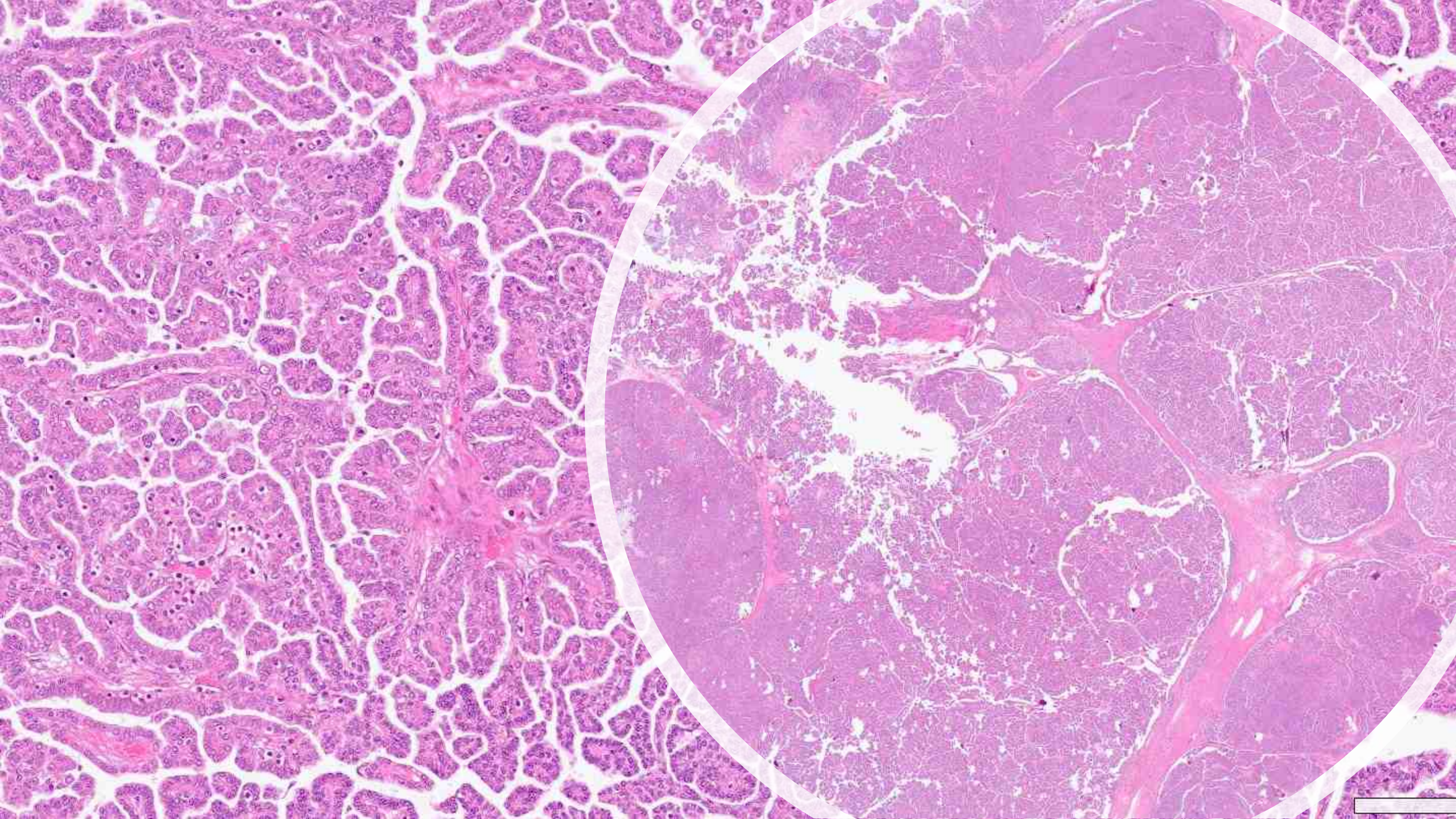

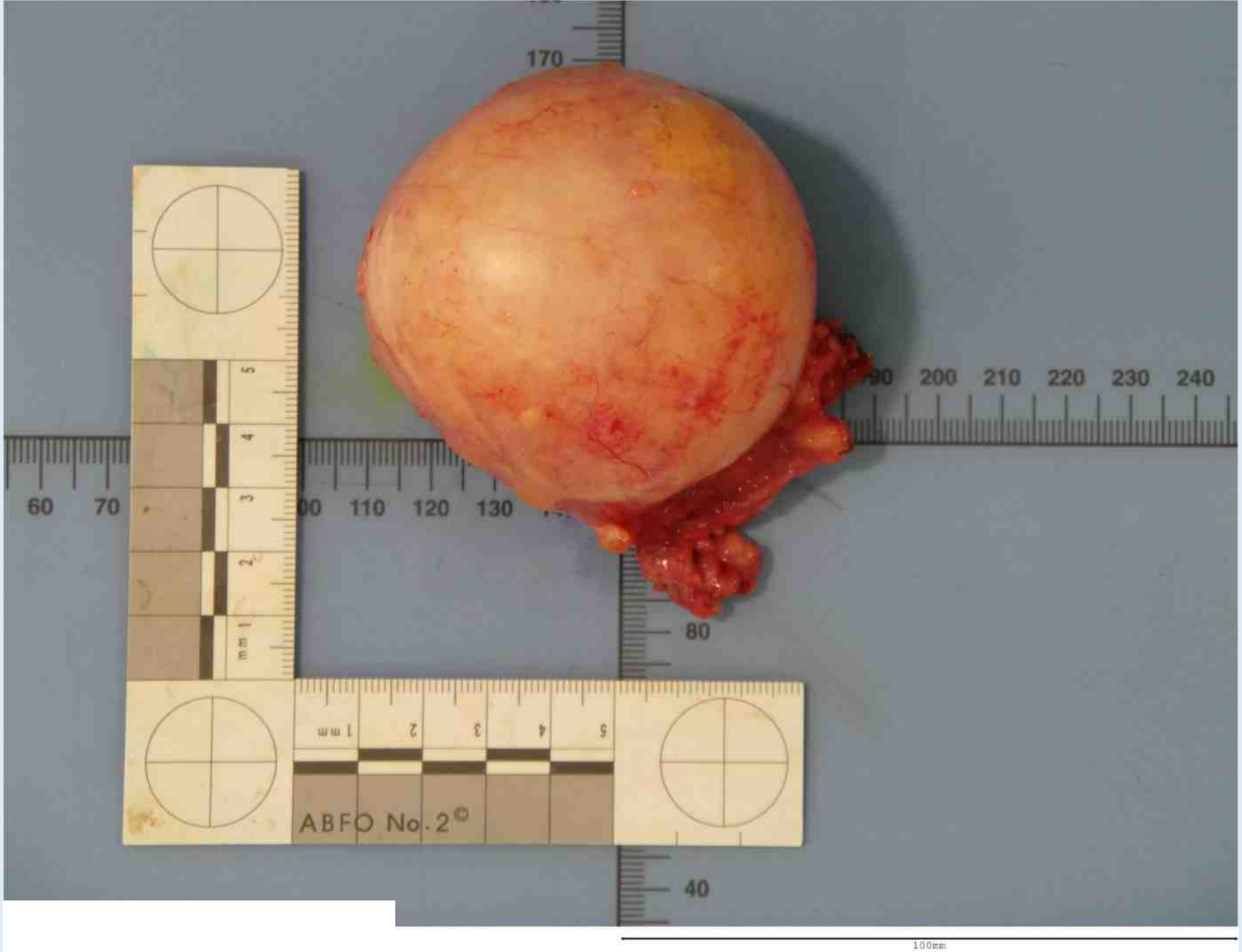
170
60
70
110
120
130
200
210
220
230
240
80
40
ABFO No. 2©
100mm

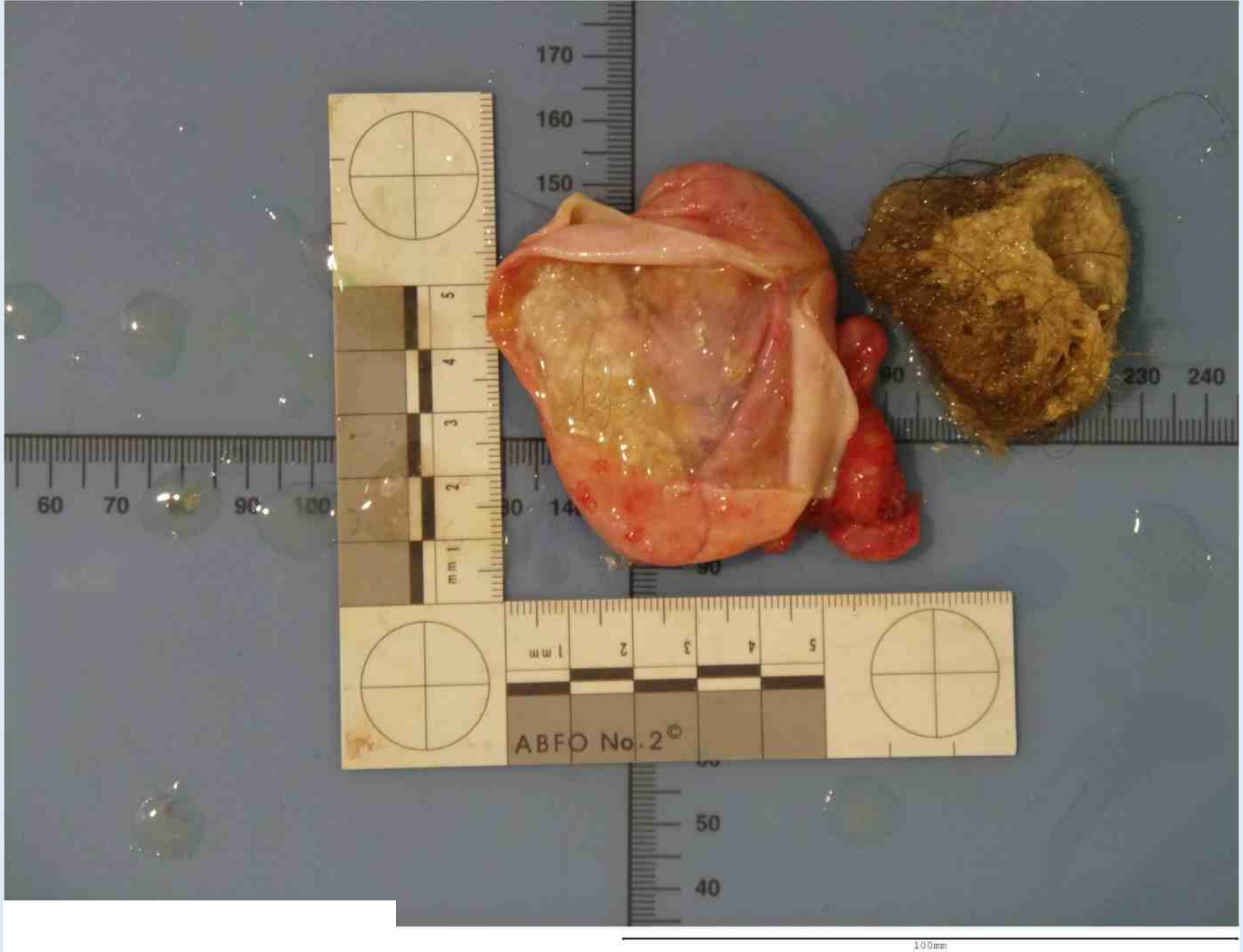
ABFO No. 2©
100mm

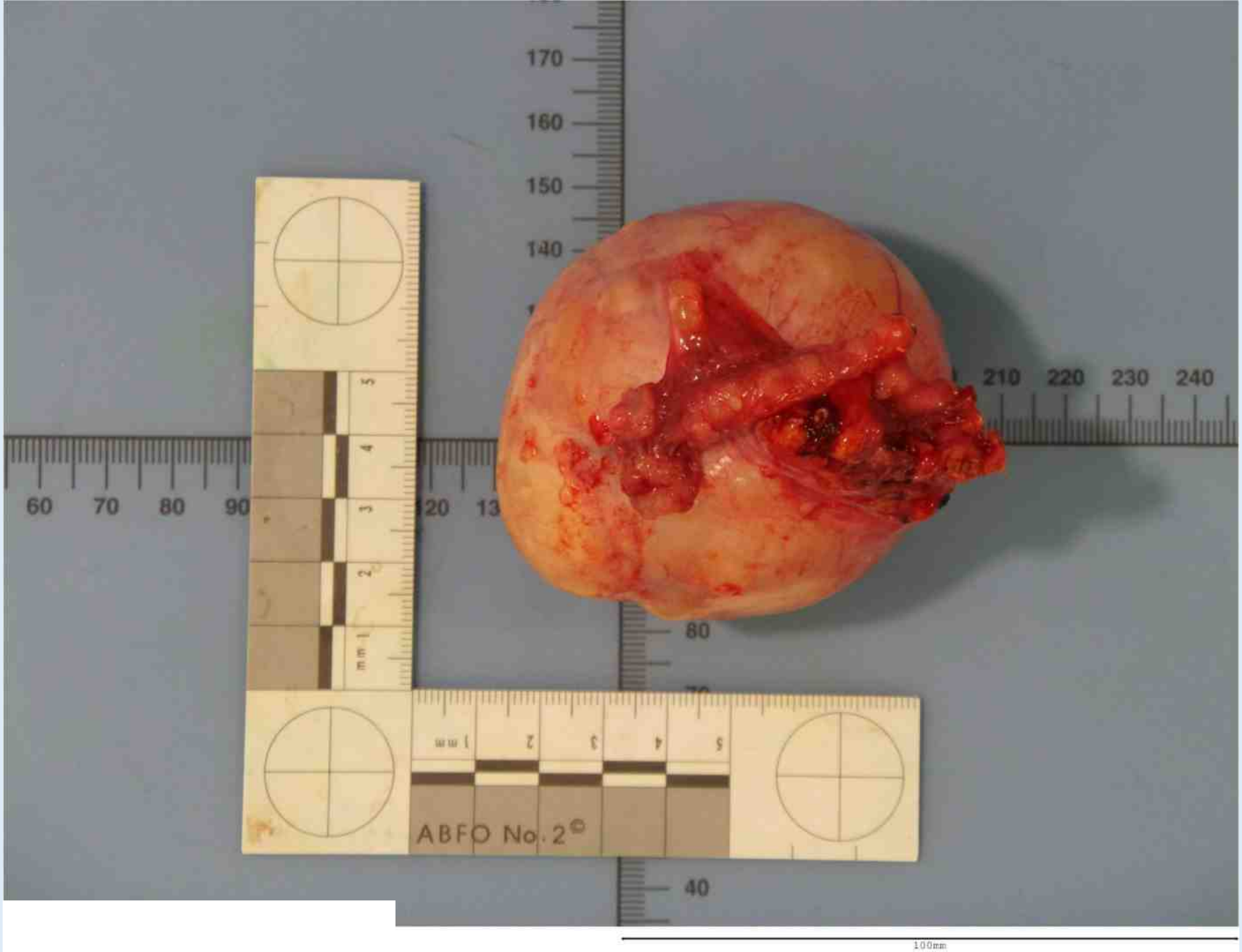
170
160
150
140
210
220
230
240
60
70
80
90
80
40
ABFO No. 2
100mm


210
ABFO No. 2©
50mm

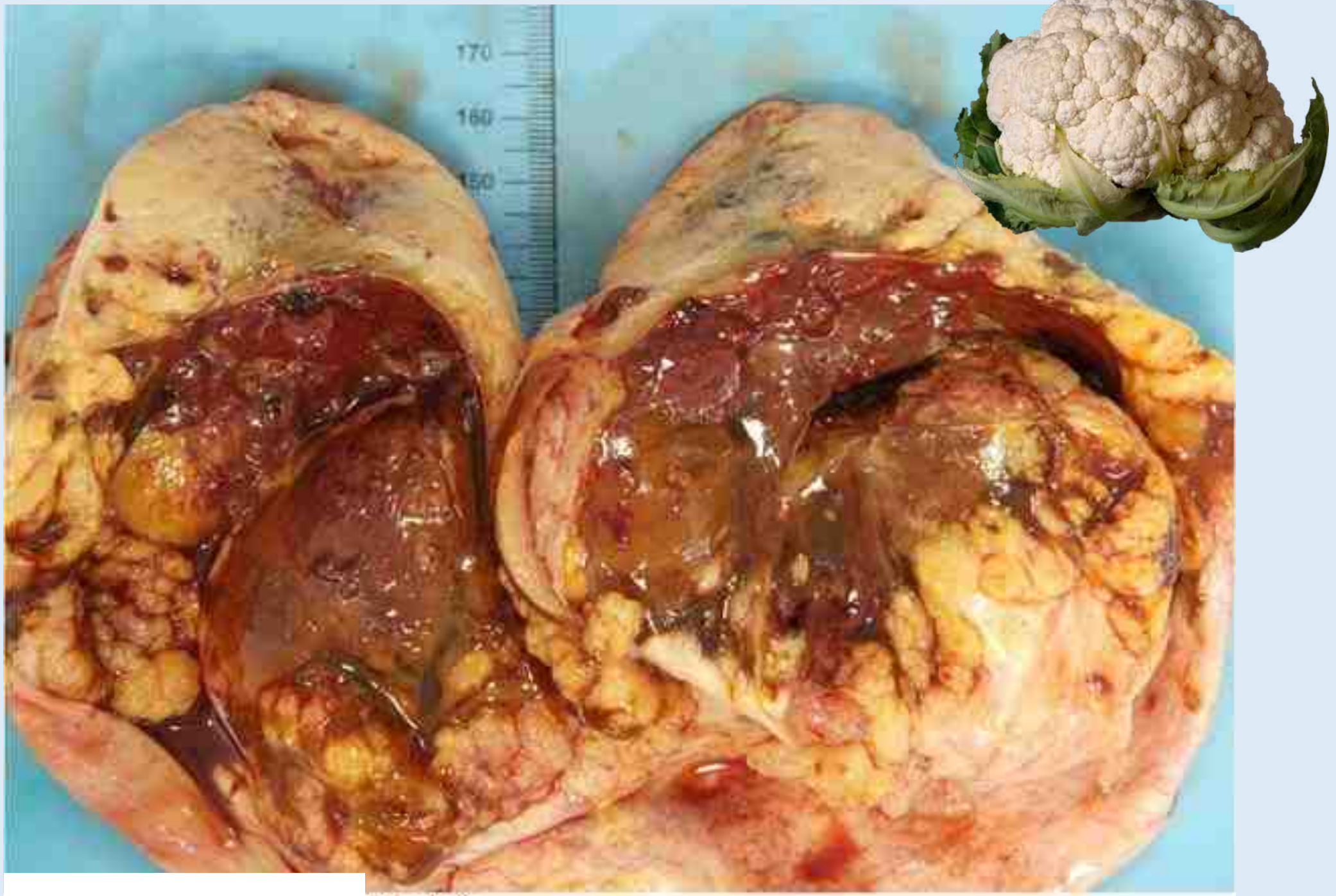
170
160
150
2020 14:36

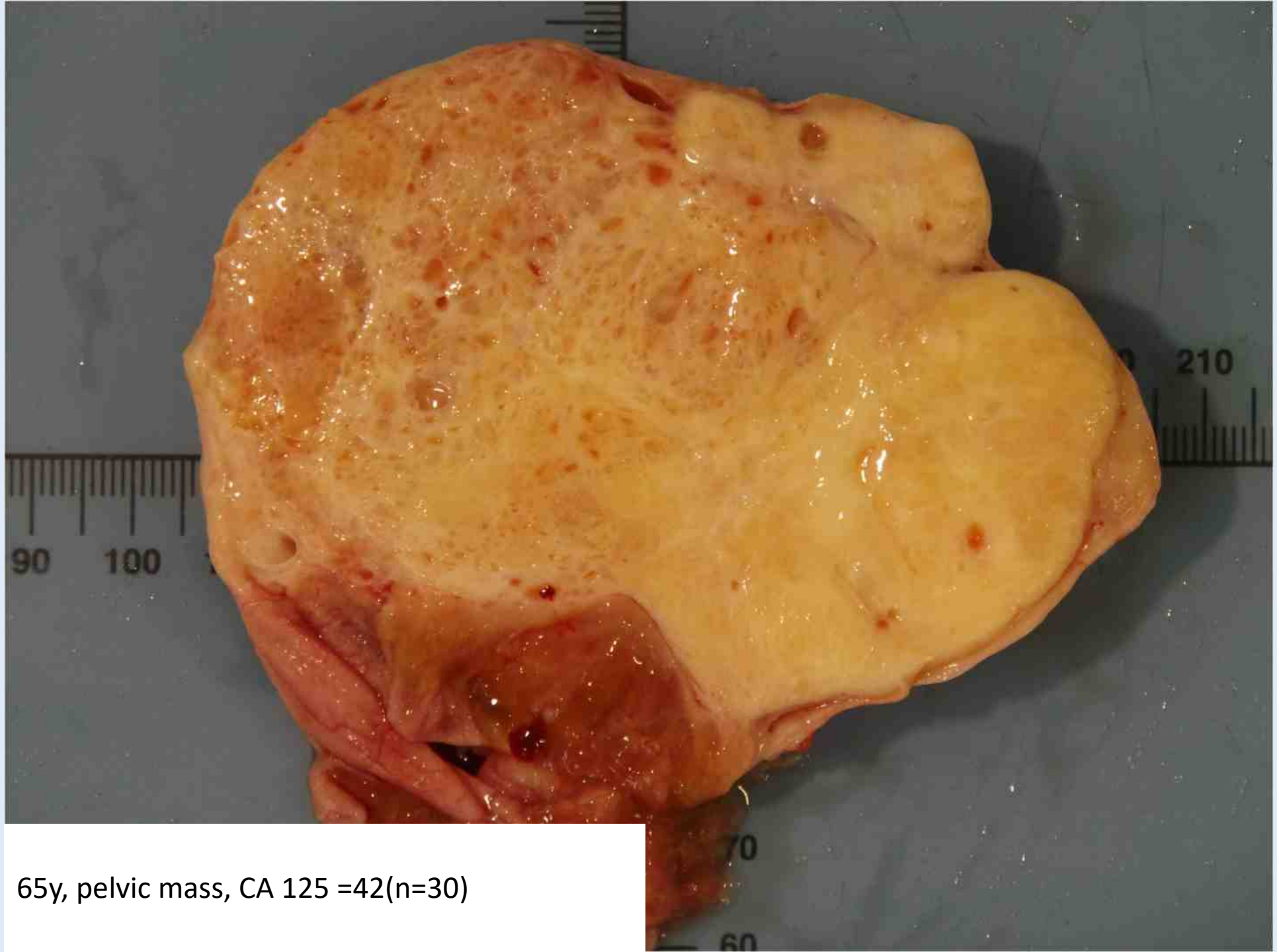

65y, pelvic mass, CA 125 =42(n=30)

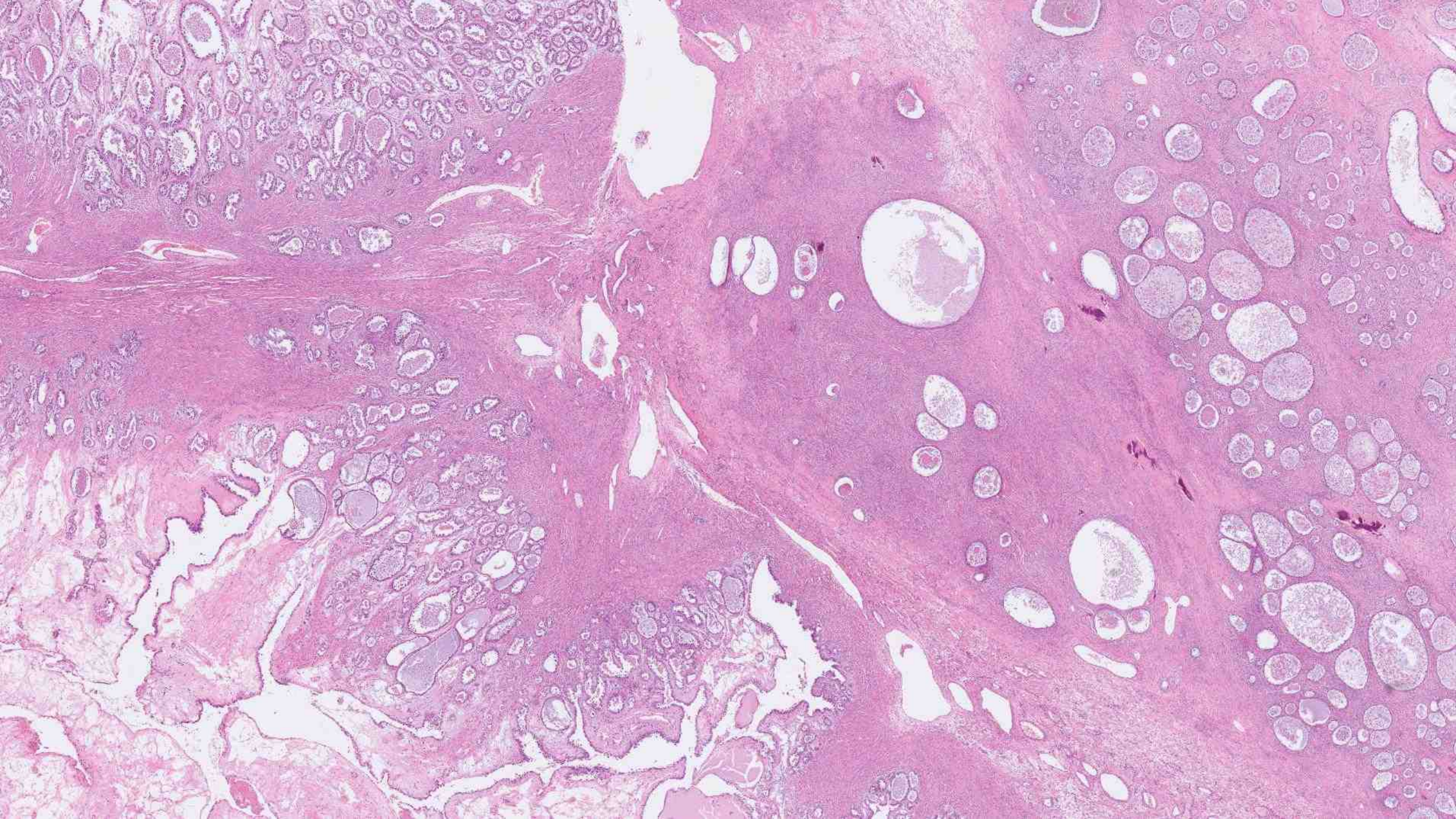

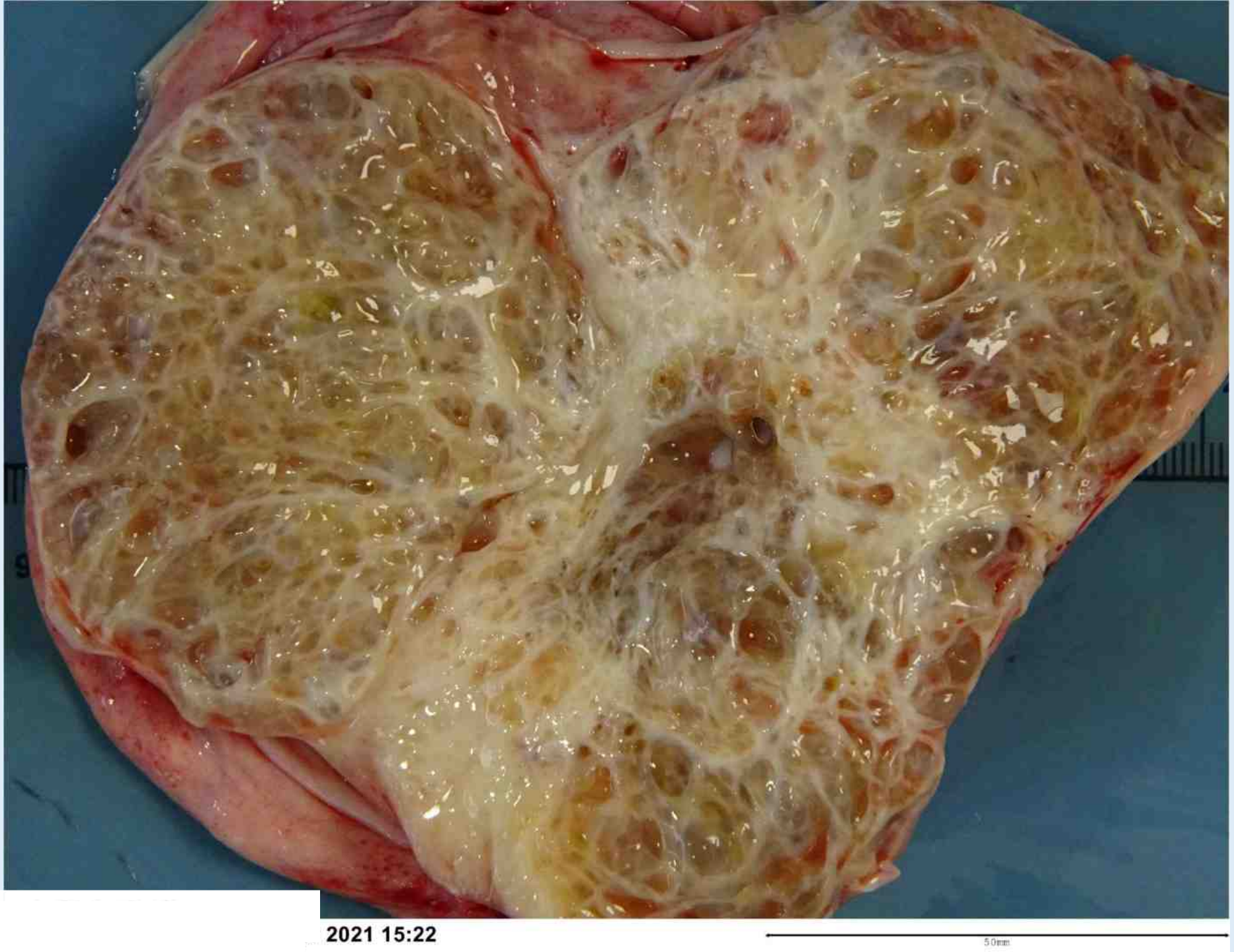
2021 15:22
50mm

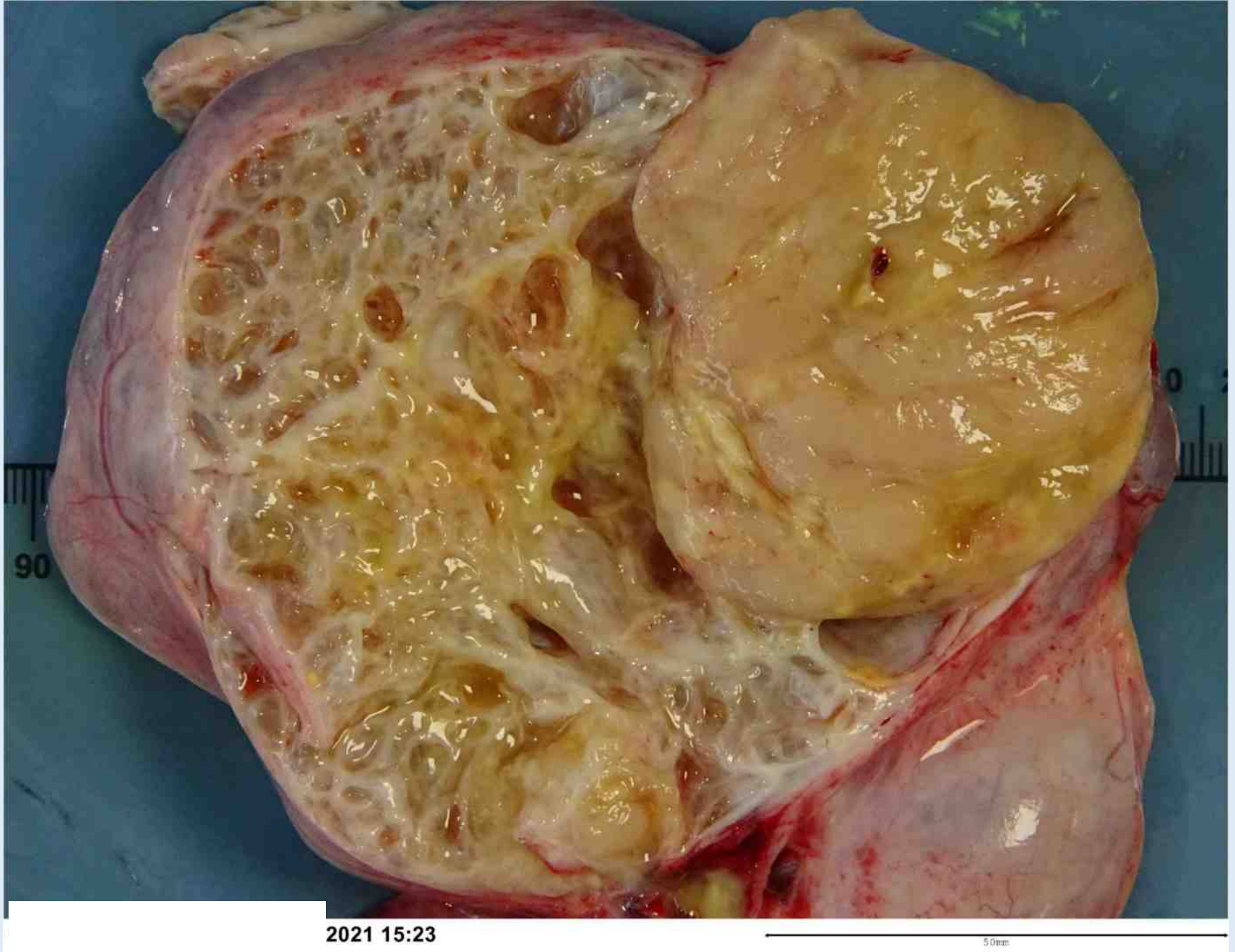
90
2021 15:23
50mm

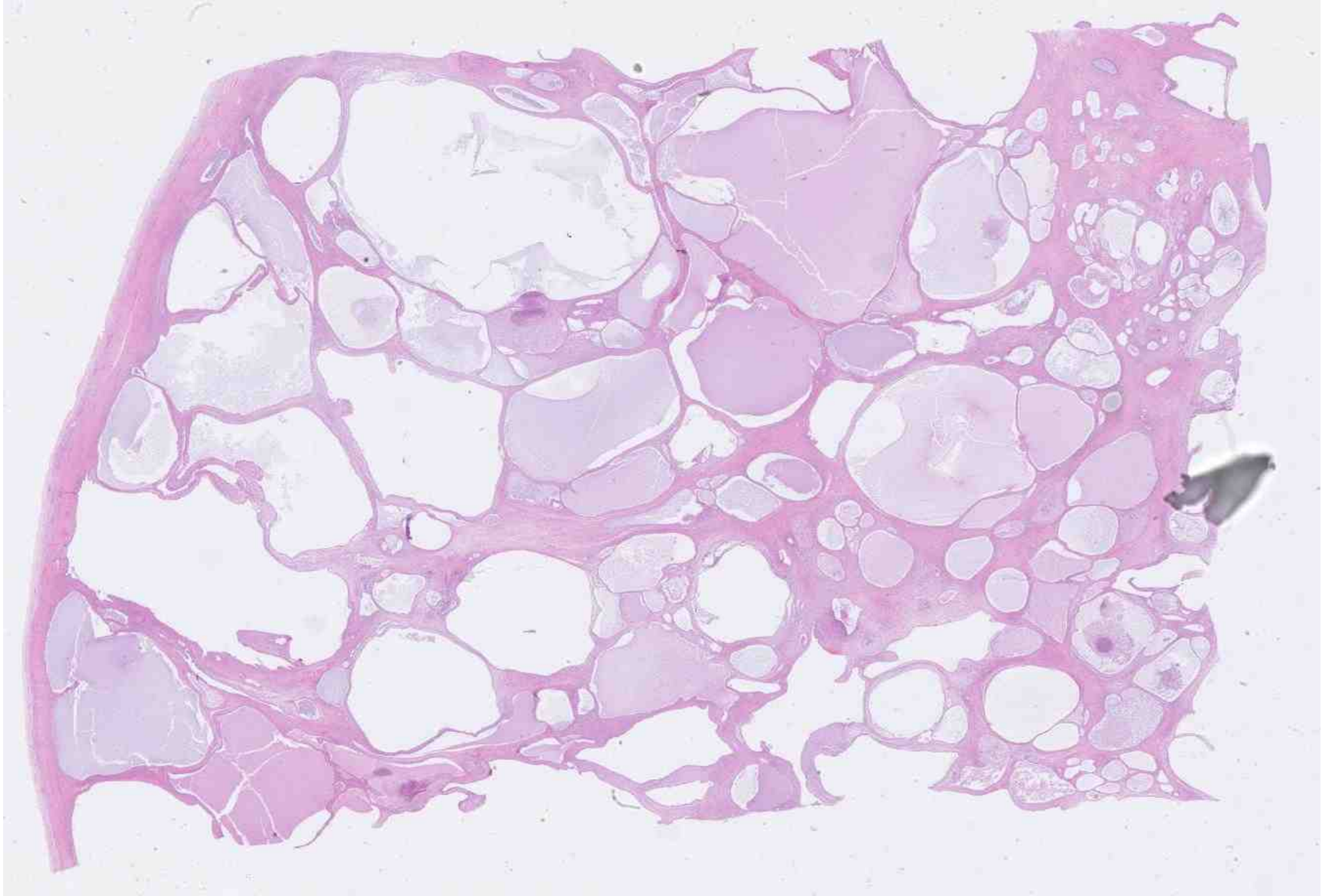

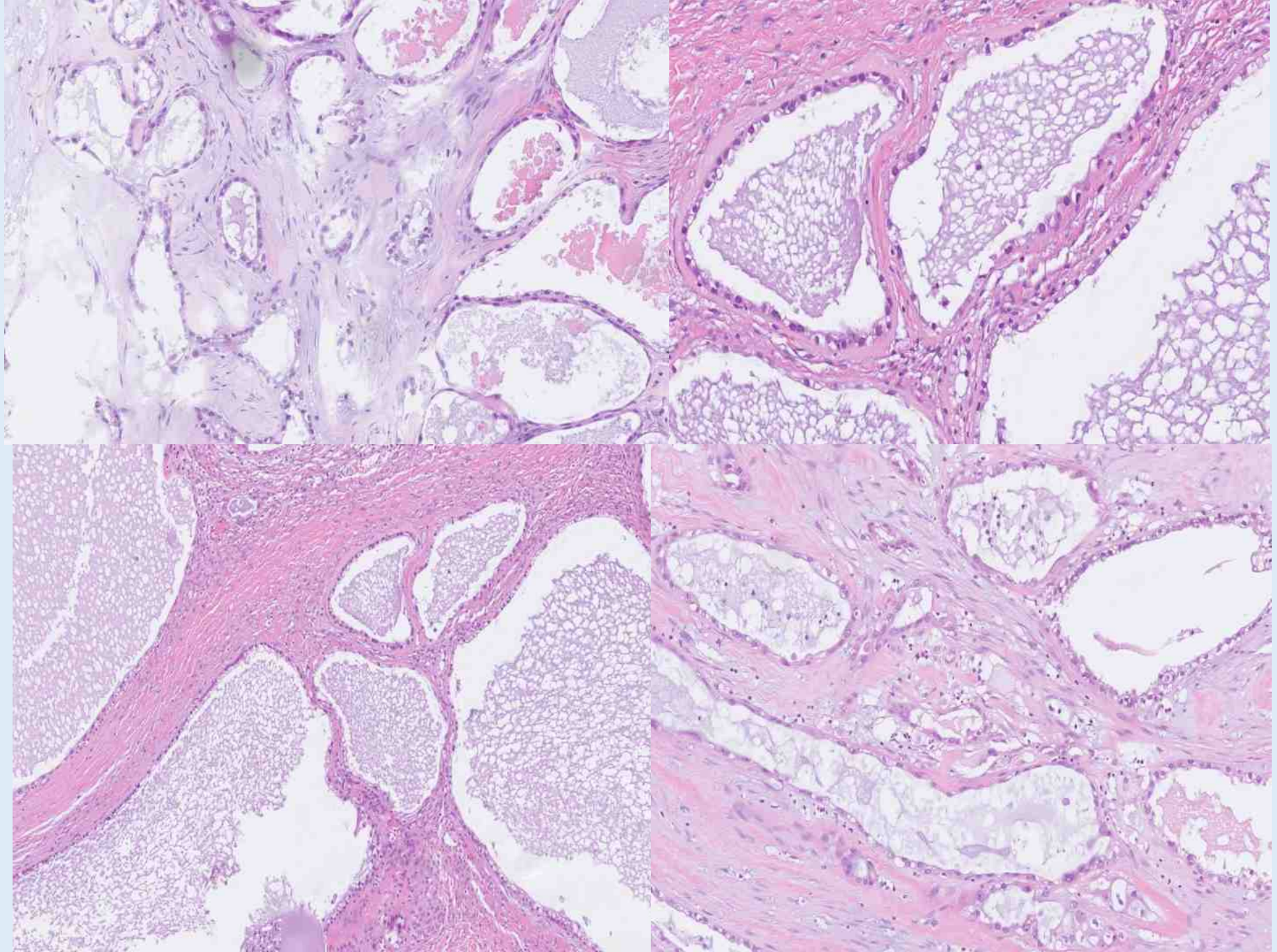

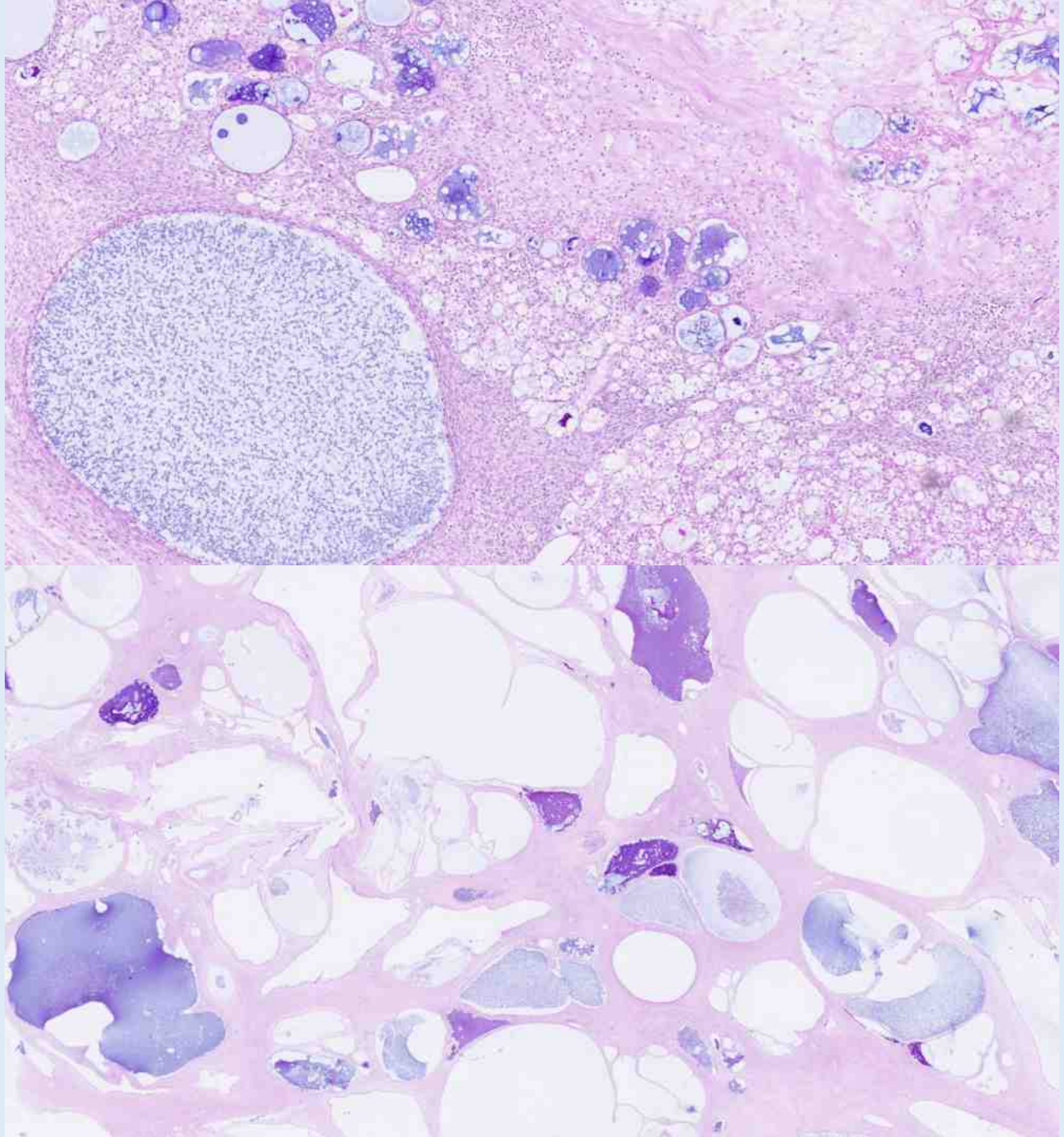

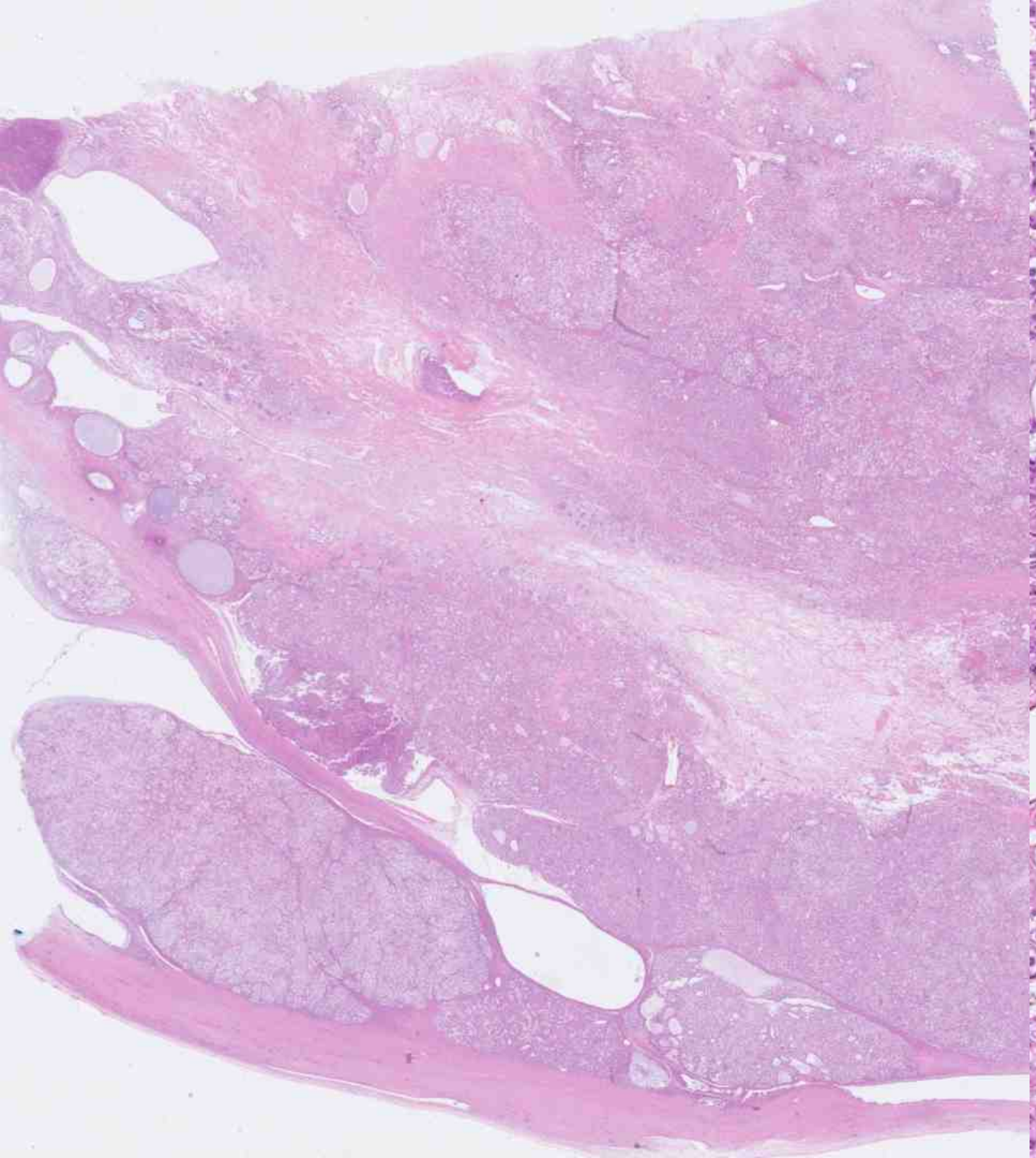

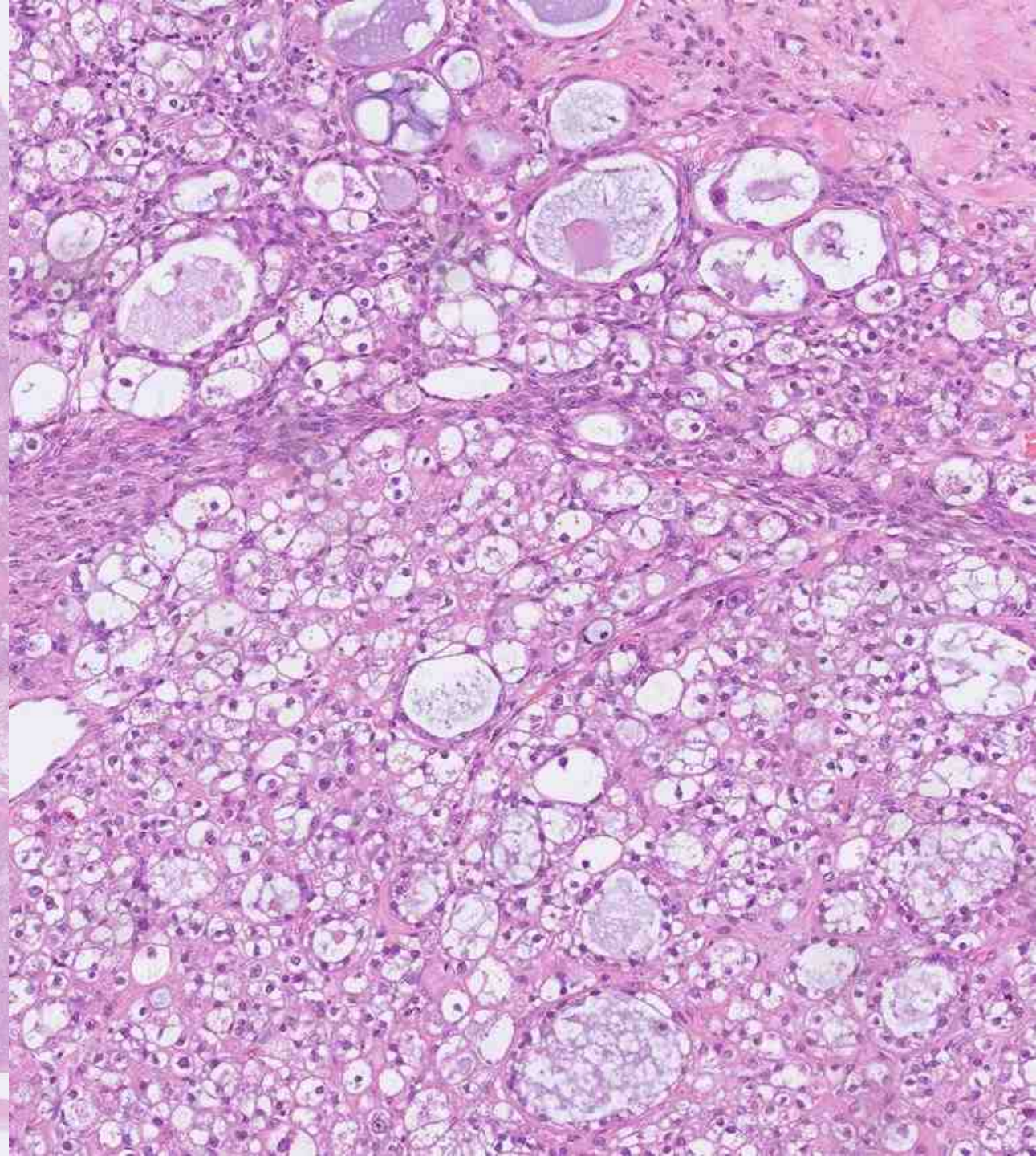

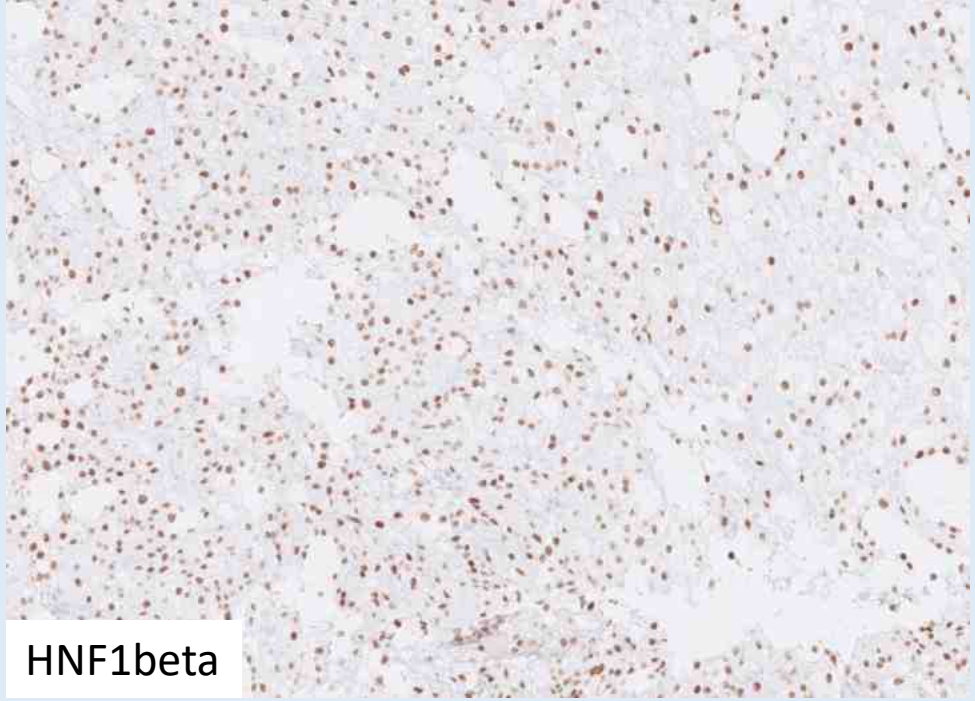
HNF1beta

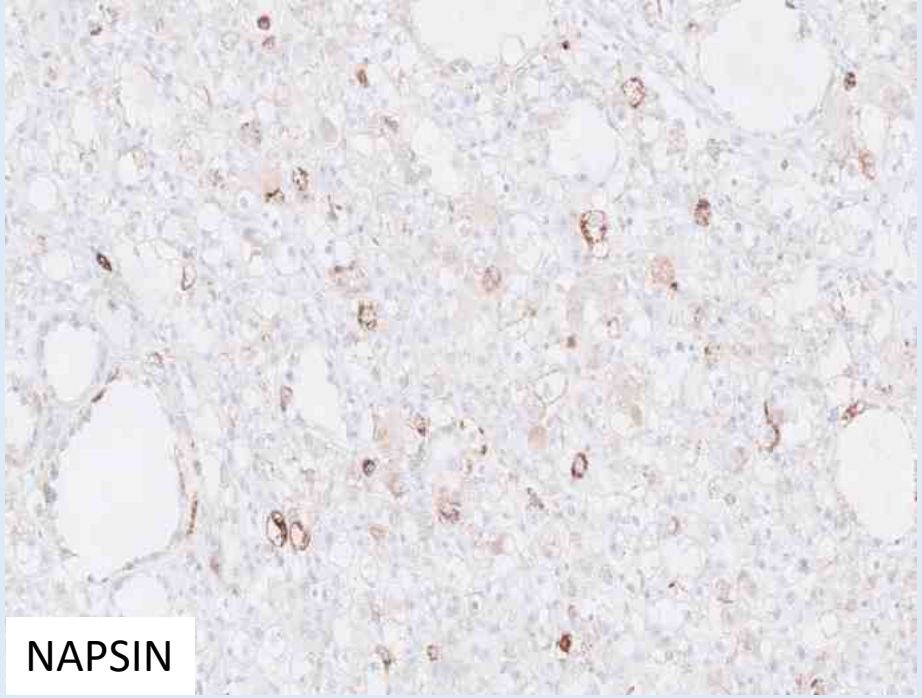
NAPSIN

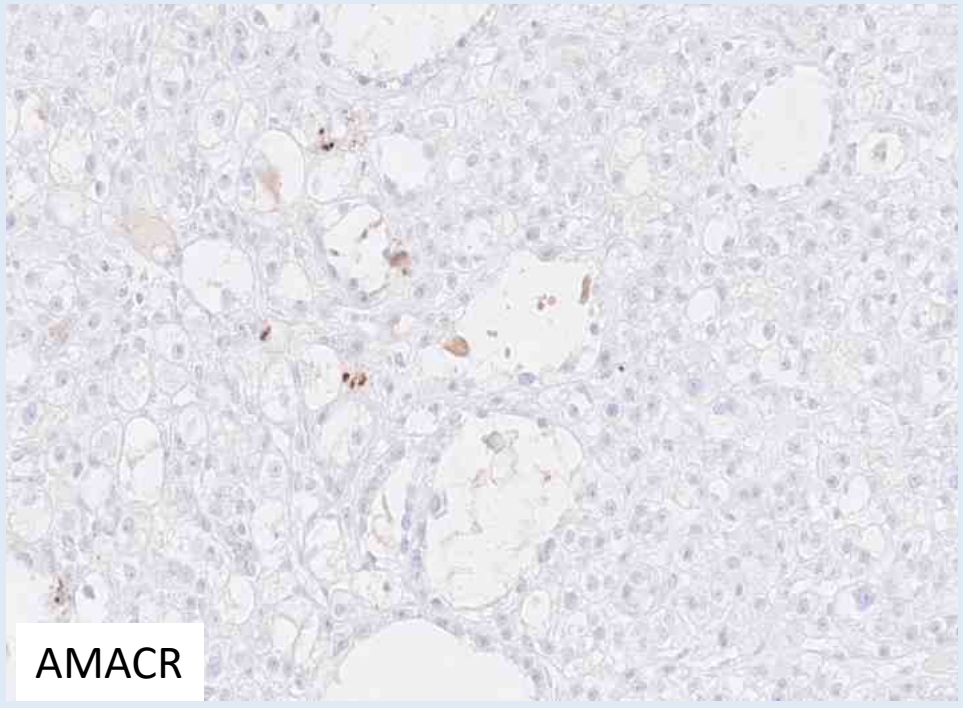
AMACR

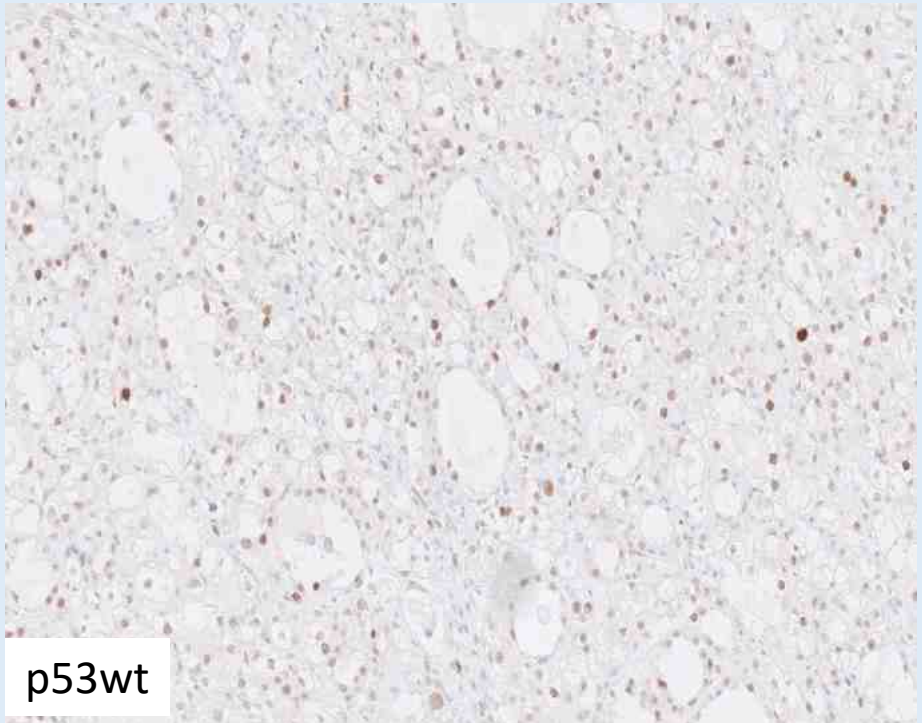
p53wt

Trachelectomy

Simple –without parametria, vaginal cuff

Radical – with parametria, vaginal cuff

TRACHELECTOMY

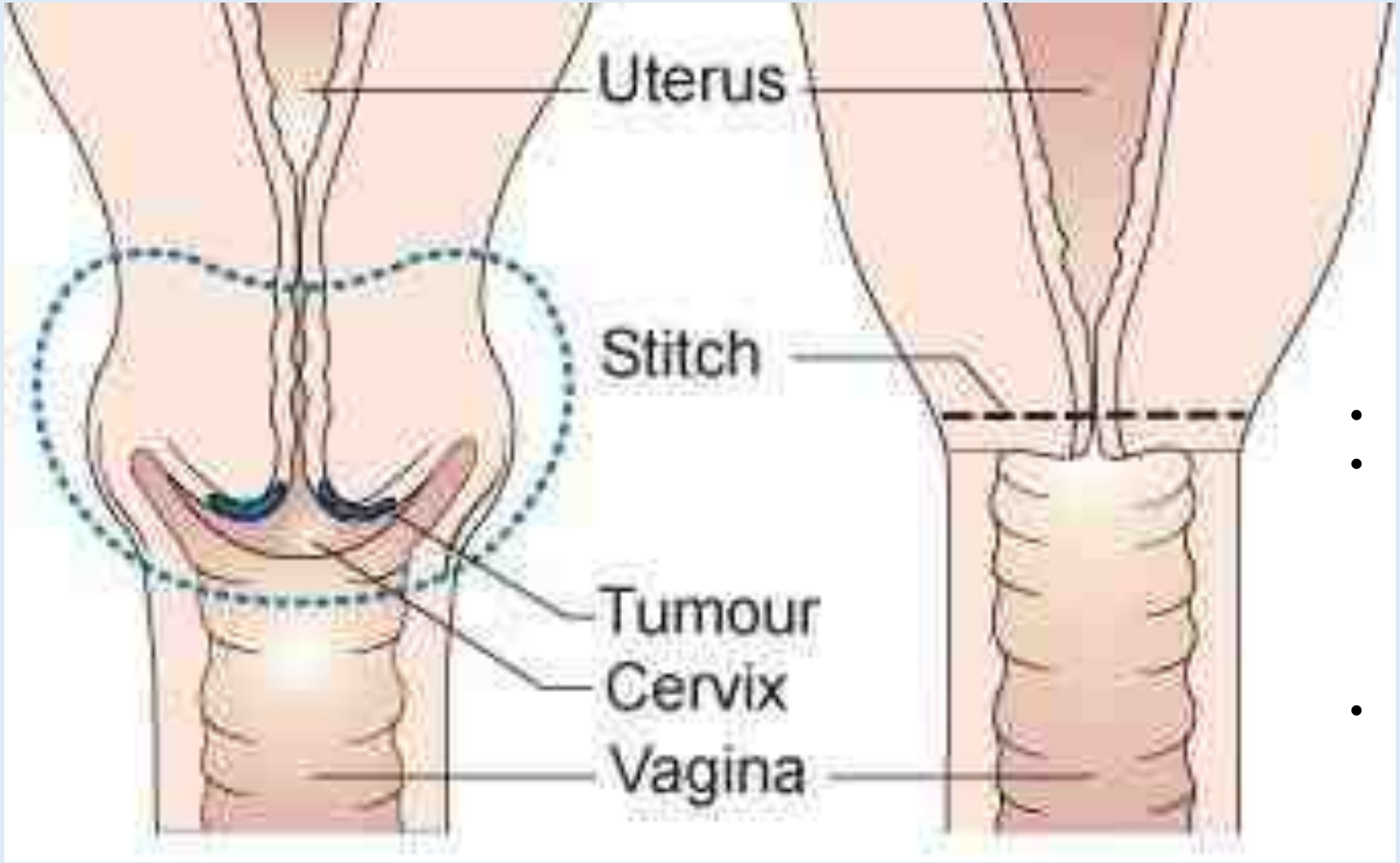

- Fertility sparing
- Selected stage 1 cervical cancers
  - Tumour less than 2cm
  - At least 1cm from internal os
  - Epicentre of tumour distal cervix
  - Clear cell, neuroendocrine excluded
- Entire cervix, parametria/paracervix, upper part of vagina removed

http://www.cancerresearchuk.org/cancer-help/type/cervical-cancer/treatment/surgery/surgery-for-cervical-cancer

Our SOP for trimming Trachelectomy specimens (issue 13/01/2011)

- Measure in three dimensions
- Weigh
- Measure cervical os
- Record if received ‘open’
- Ink to allow assessment of margins
- Photography is recommended

- Block selection: Upper canal margin x 2 (en face). 2-3mm slices parallel to os (book ending), all embedded
- Megablock may be used
- Two outside ‘lateral’ blocks in different coloured cassettes (cut from outer edge, with routine levels)

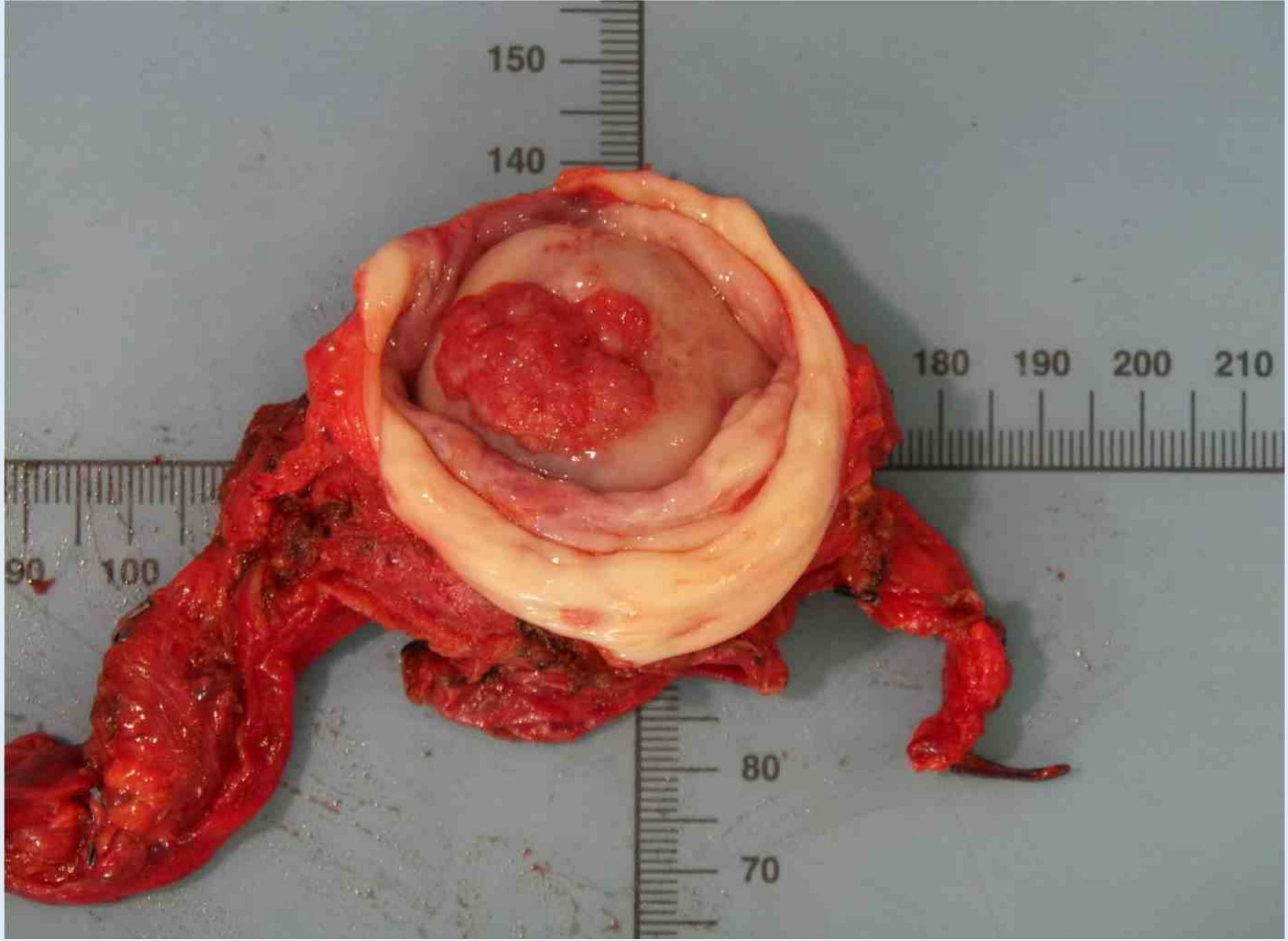
150
140
180
190
200
210
90
100
80
70


150
140
130
90
100
110
200
80

Anterior



Posterior

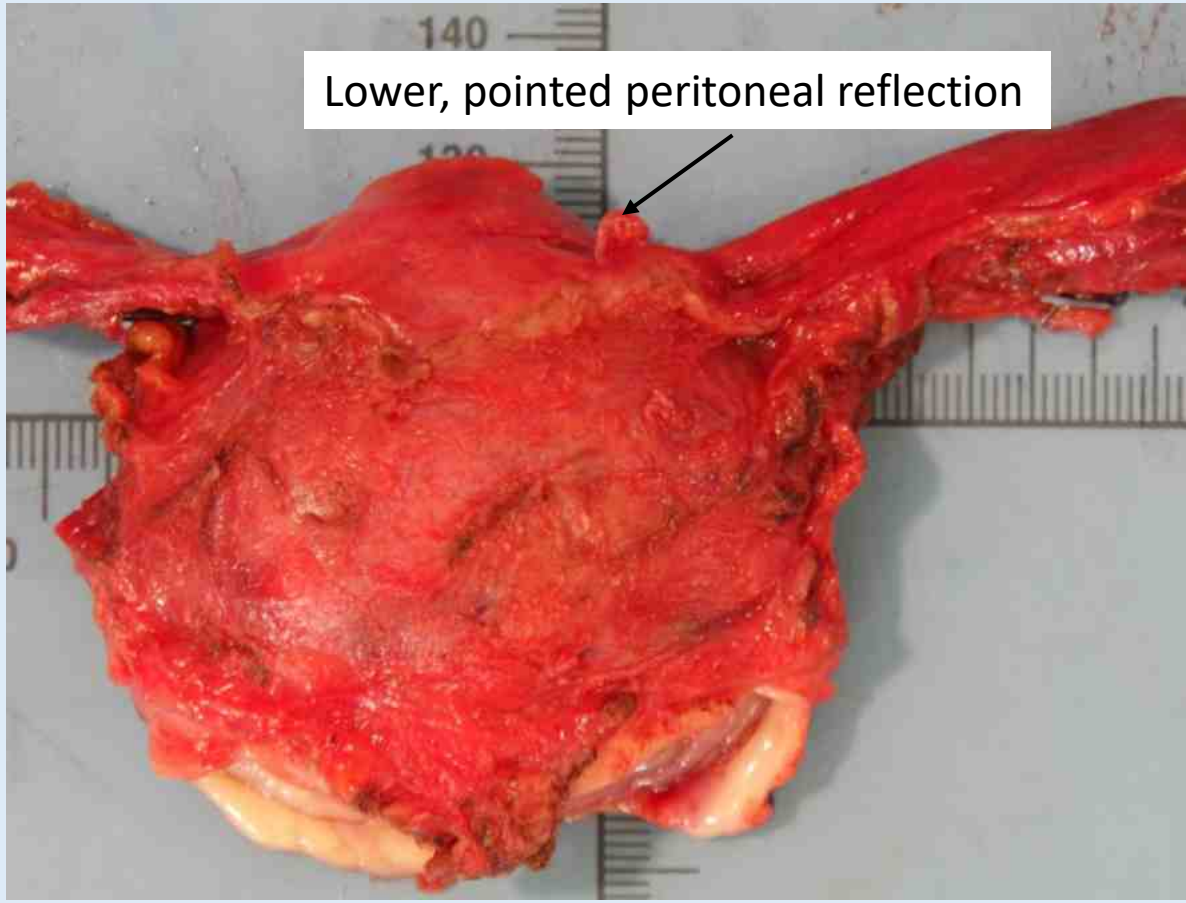

Anterior



Posterior





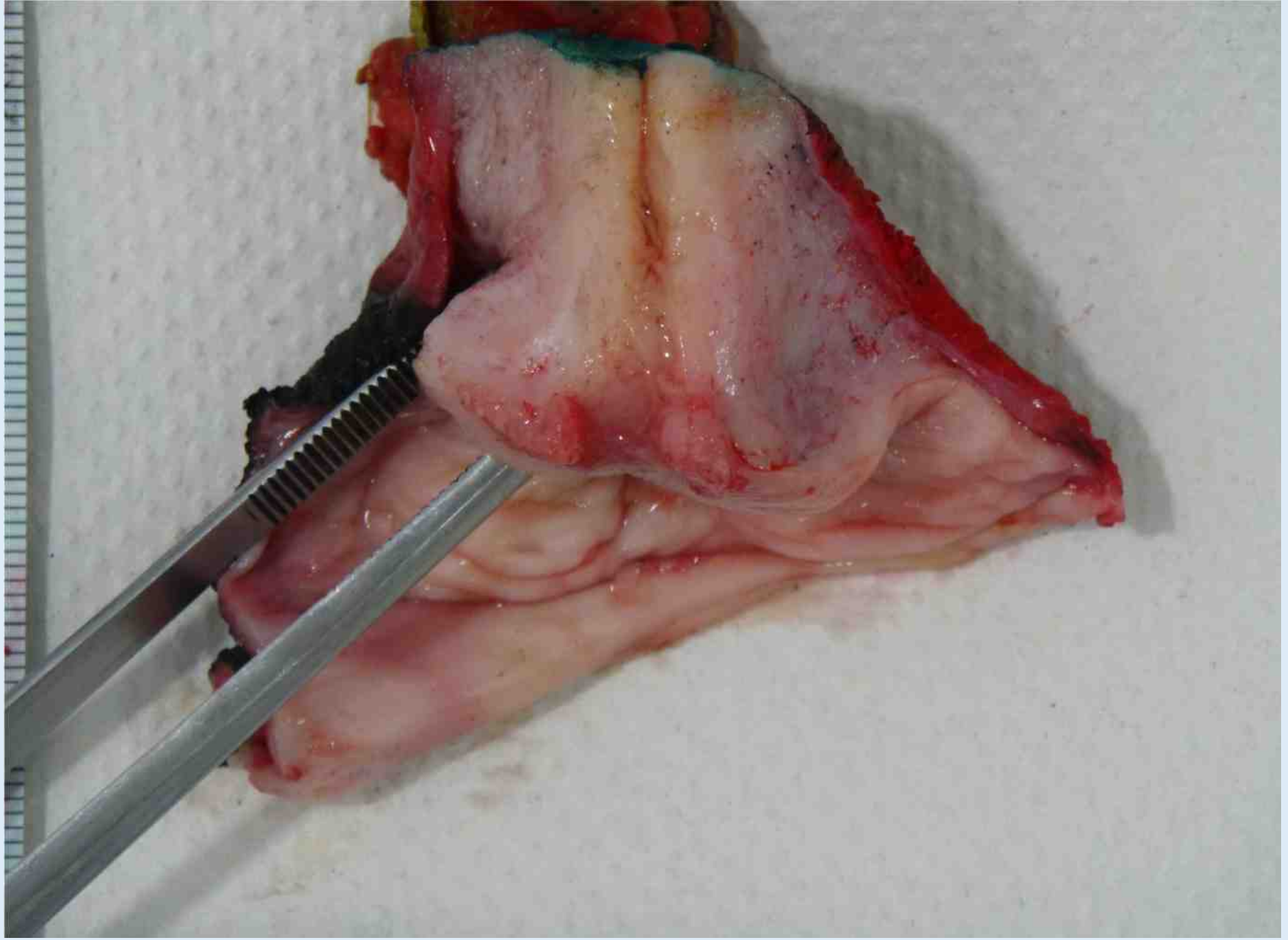

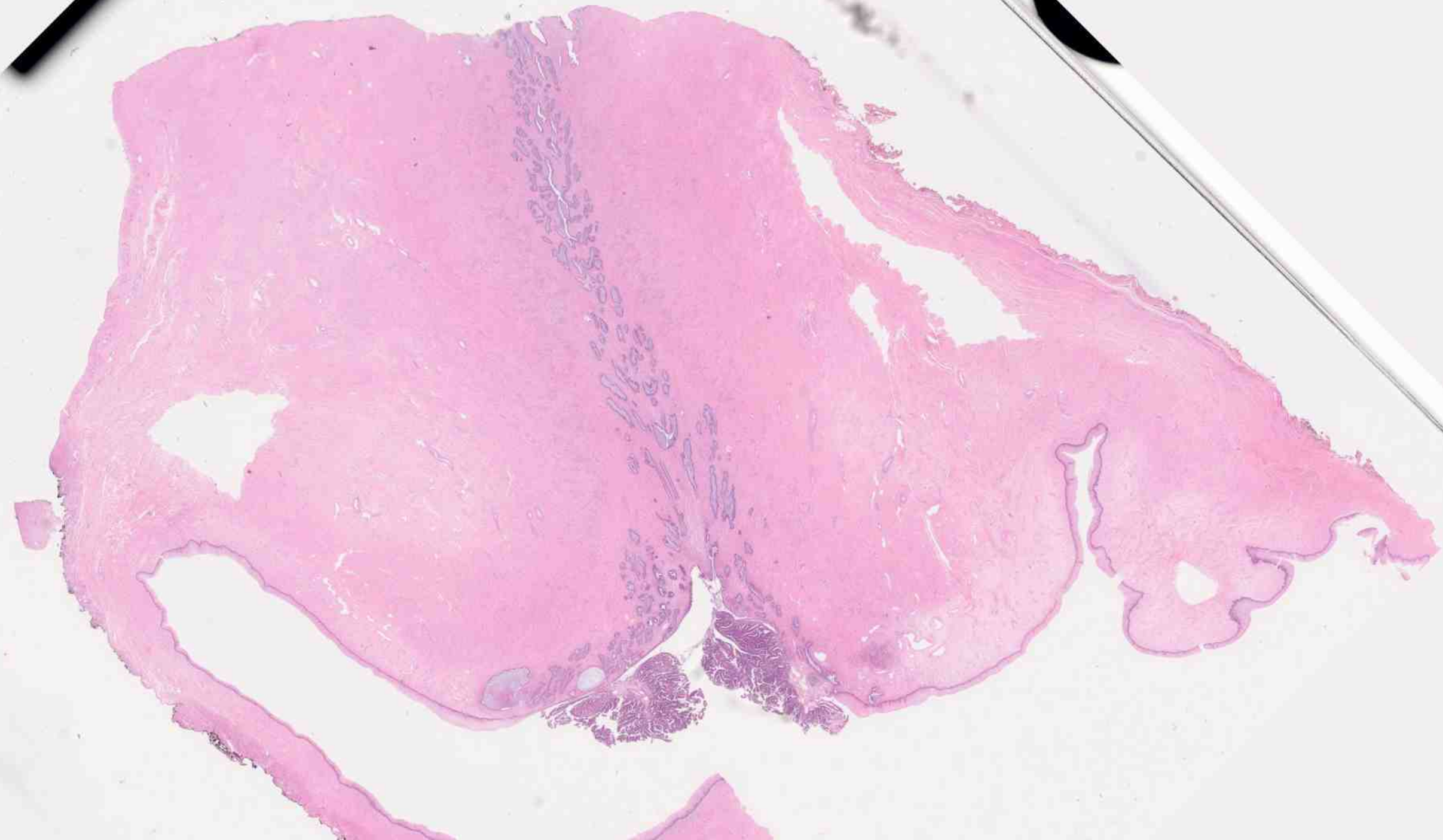



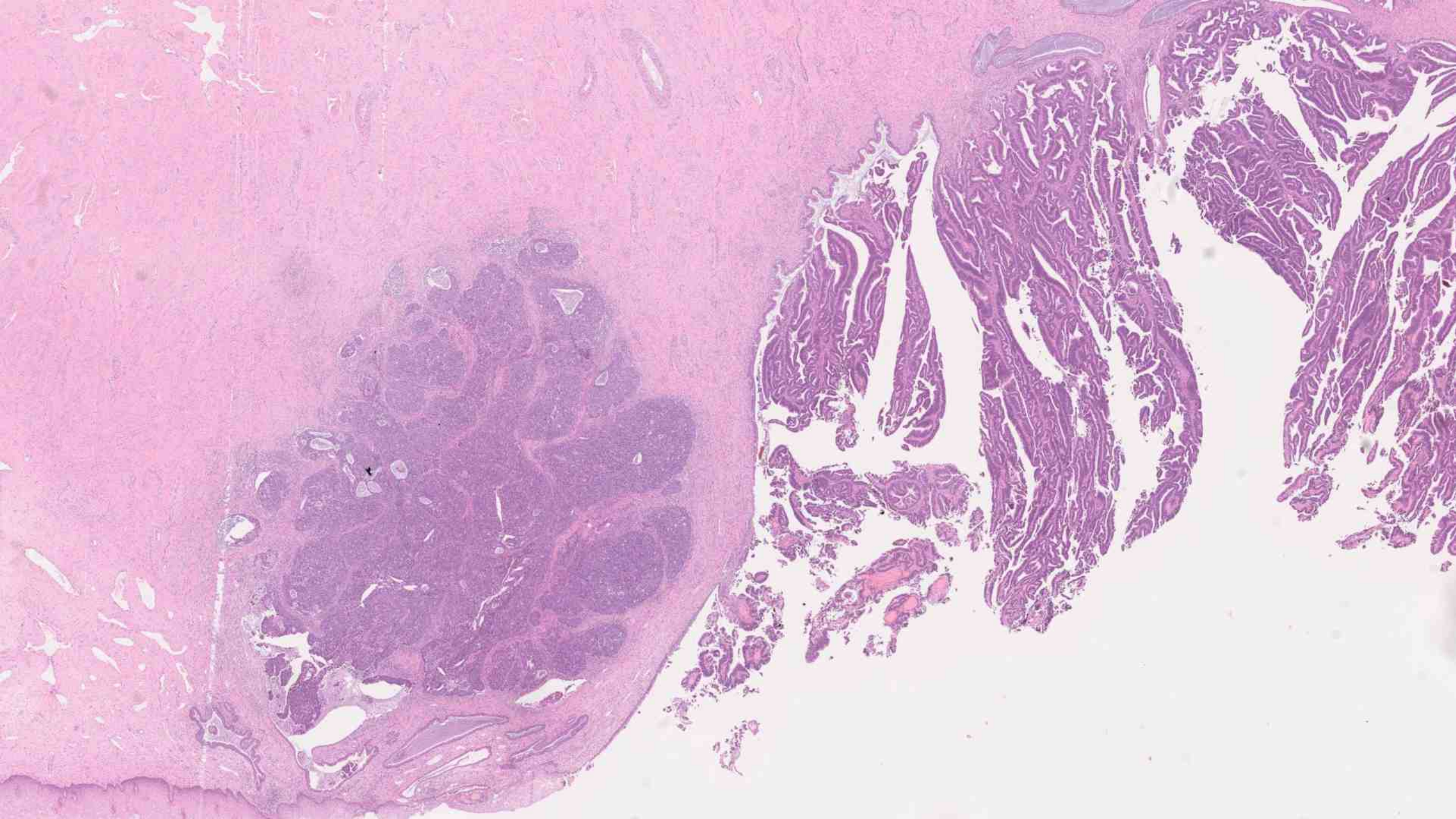

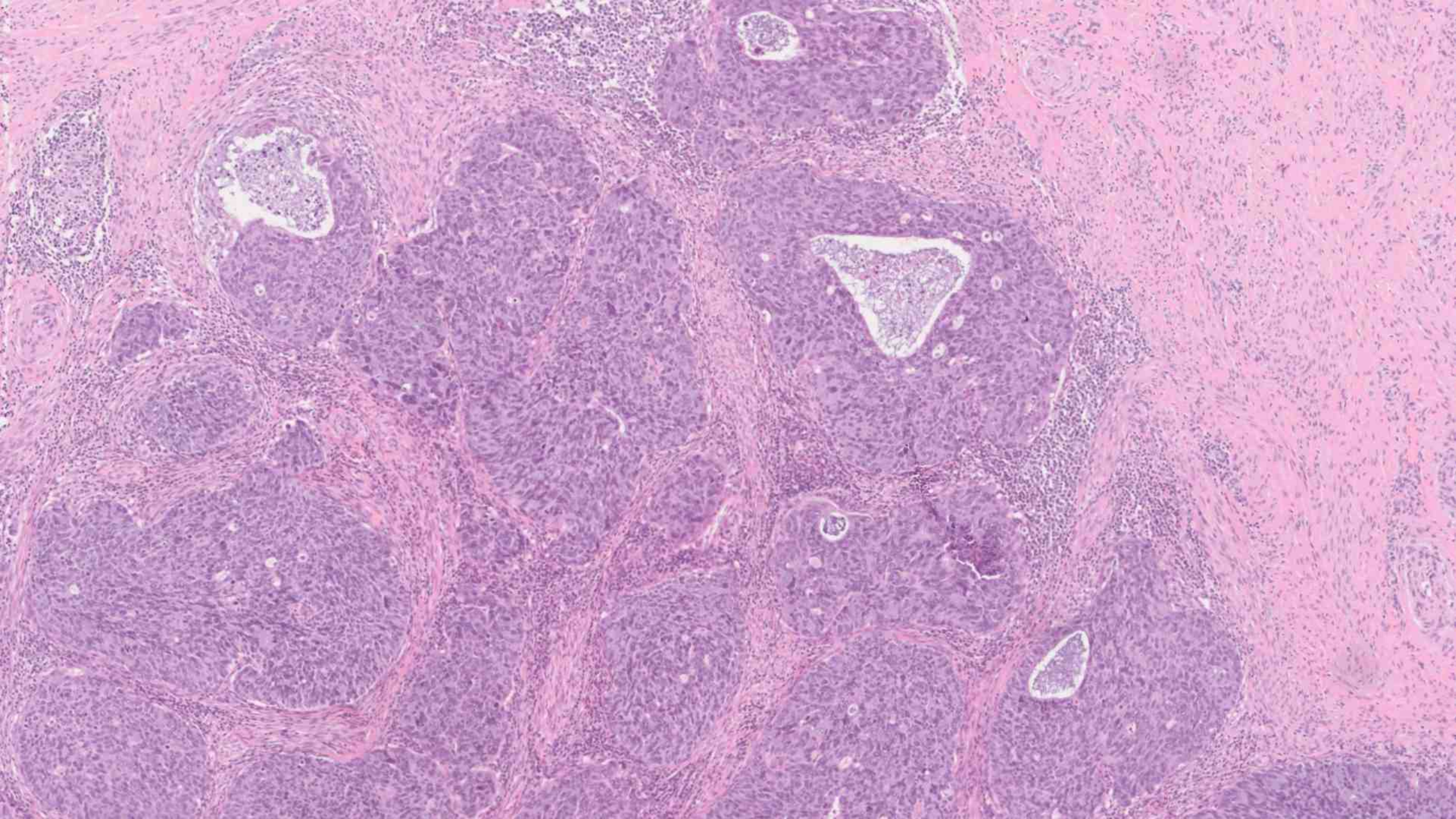

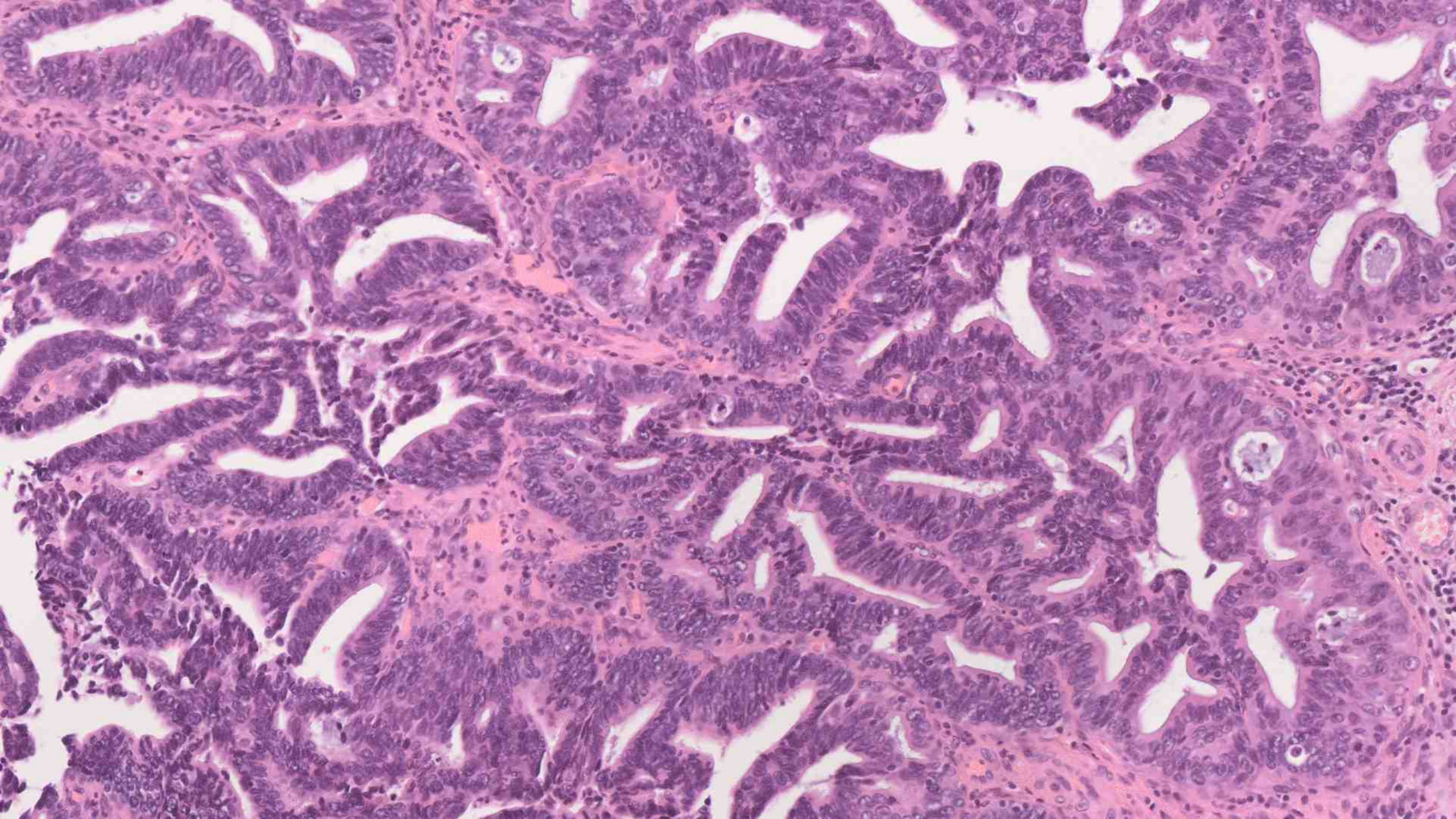

VULVA

Punch biopsy, WLE, partial and total vulvectomies

Anovulvectomy, pelvic exenteration

Partial Vulvectomies

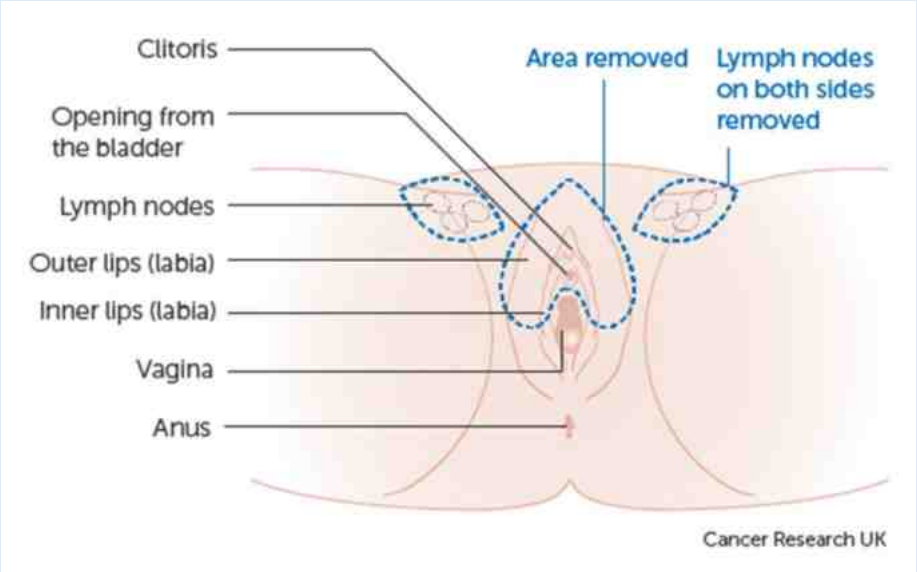

Anterior vulvectomy +- groin/sentinel nodes

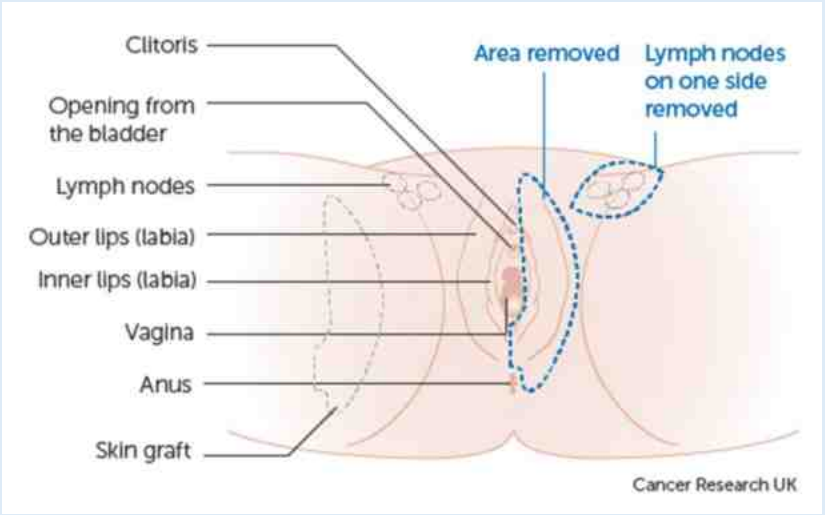

Left hemi-vulvectomy with left groin nodes/sentinel nodes

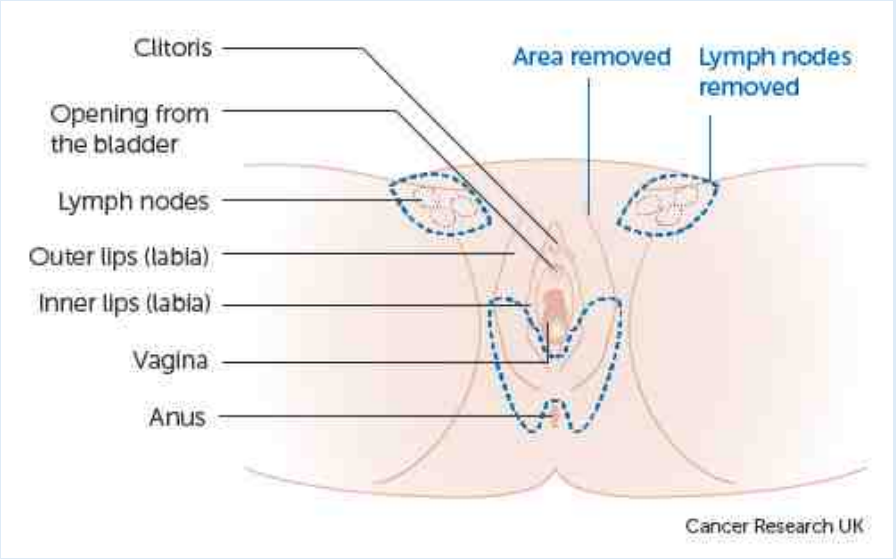

Posterior vulvectomy +-groin/sentinel nodes

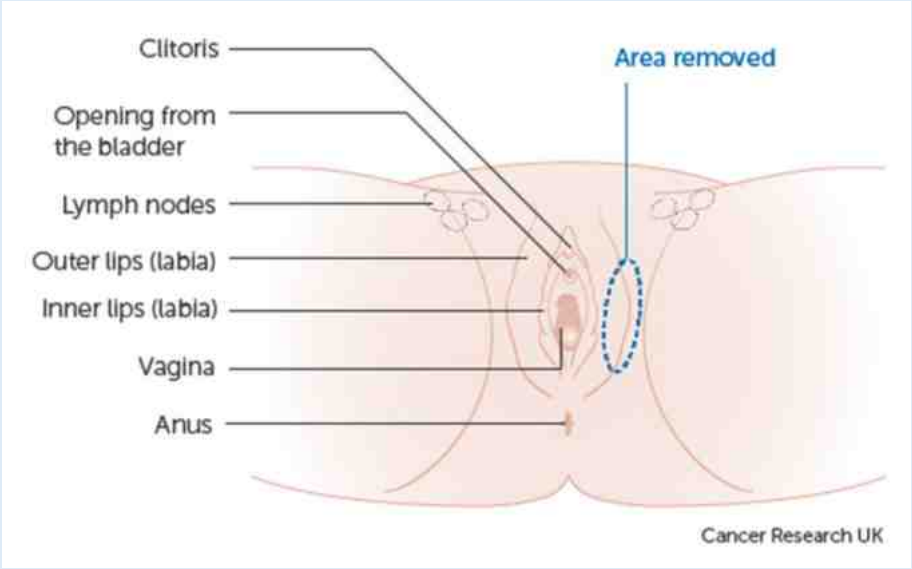

Wide Local Excision, left vulva

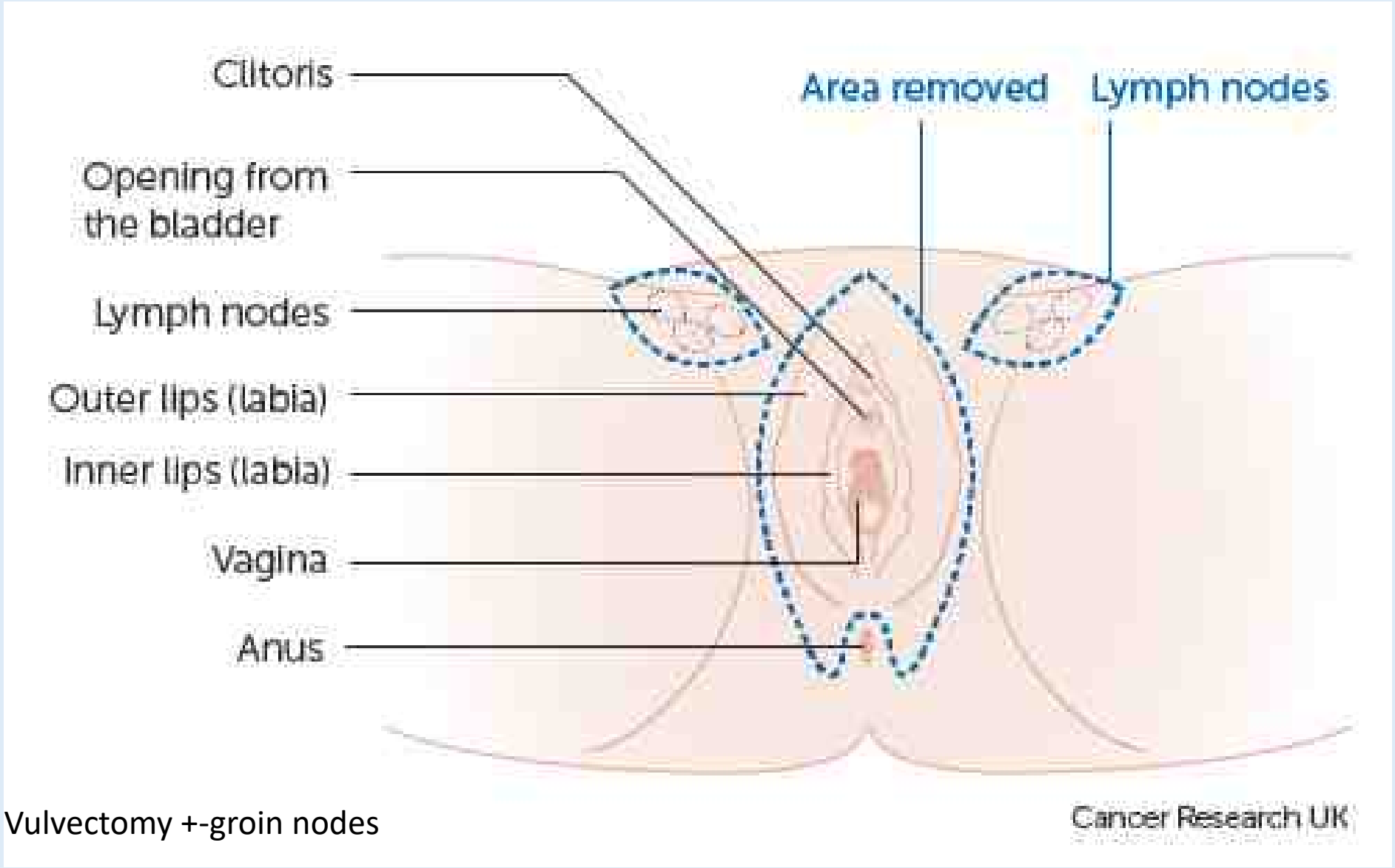

Radical Vulvectomy +-groin nodes



Steps

- Orientate
- Identify anatomic structures
  - Clitoris, urethra, vagina
- Photograph
- Ink margins different colours
- Measure specimen in 3D and describe any visible lesion
  - Appearance
  - Size
  - Location
- Margins (I prefer margins measured on glass slide)





- Ink margins different colours
- Measure specimen in 3D and describe any visible lesion
  - Appearance
  - Size
  - Location
- Margins (I prefer margins measured on glass slide)
- Bread slice specimen
- Embed sequential sections
- Cruciates to 6 and 12 o’ clock



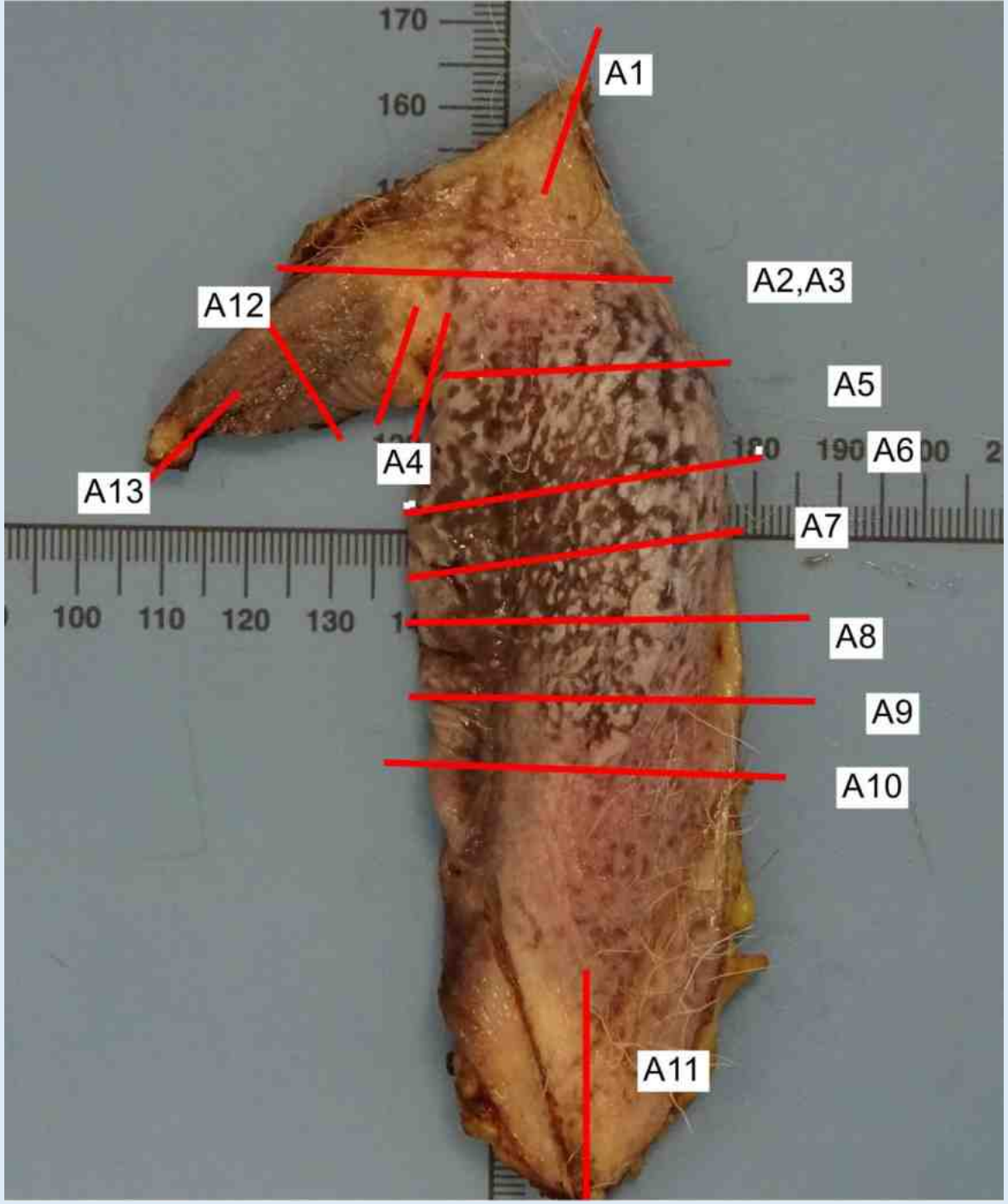
A1
A2,A3
A12
A5
A4
A6
A13
A7
A8
A9
A10
A11


mm
20 mm
210
200
130
170
180
190
230
240
250
260
270
280
290
0
20
30
40
50
60
70
80
90
100
110
120
90
70
60
50
40
30
20
10
0

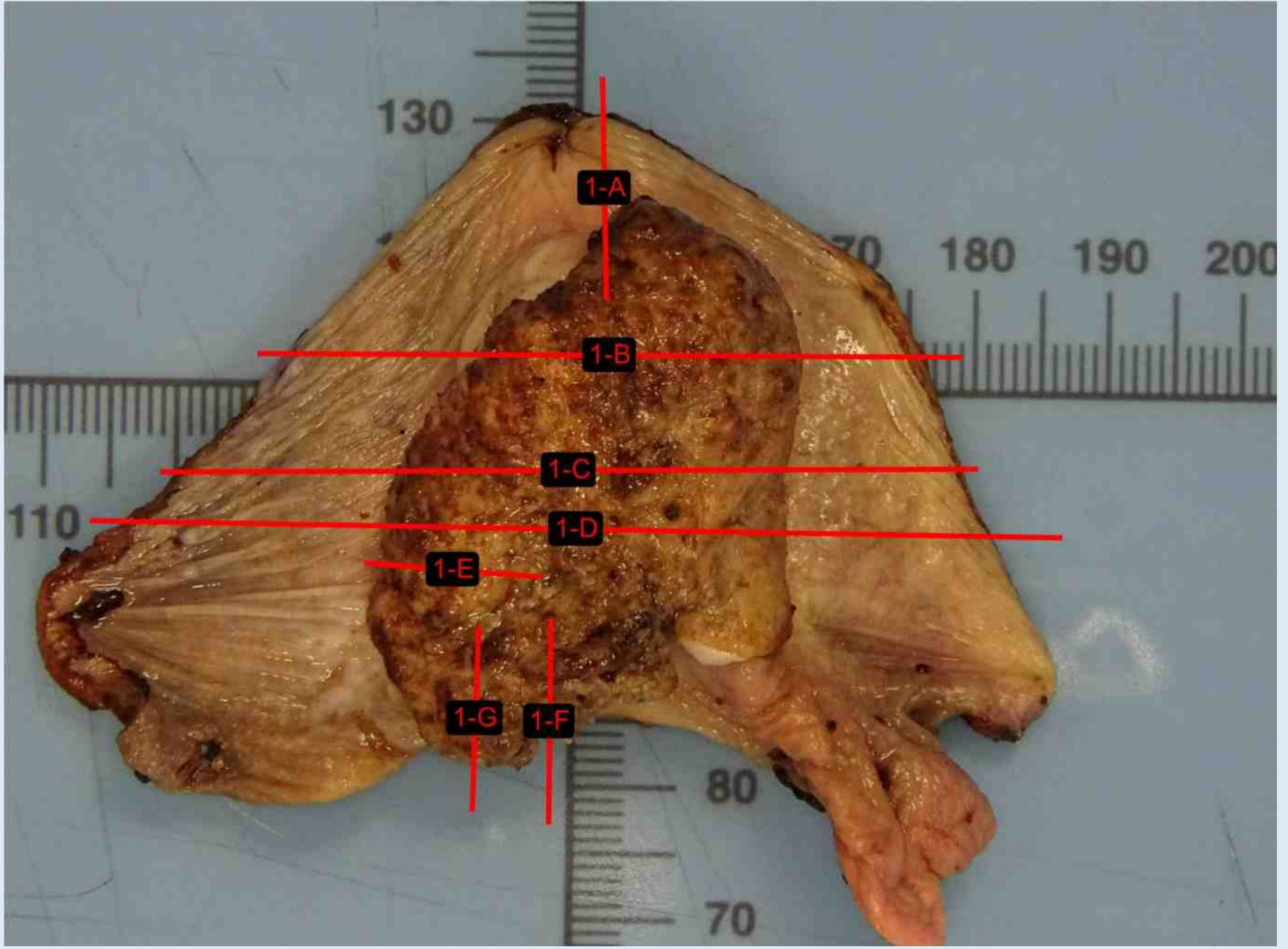
130
180
190
200
110
80
70
1-A
1-B
1-C
1-D
1-E
1-G
1-F


200
190
180
170
160
150
130
70
10
0
20 30 40 50 60 70 80 90 100 110 120 130
170 180 190 200 210 220 230 240 250 260 270 280


200
90
80
70

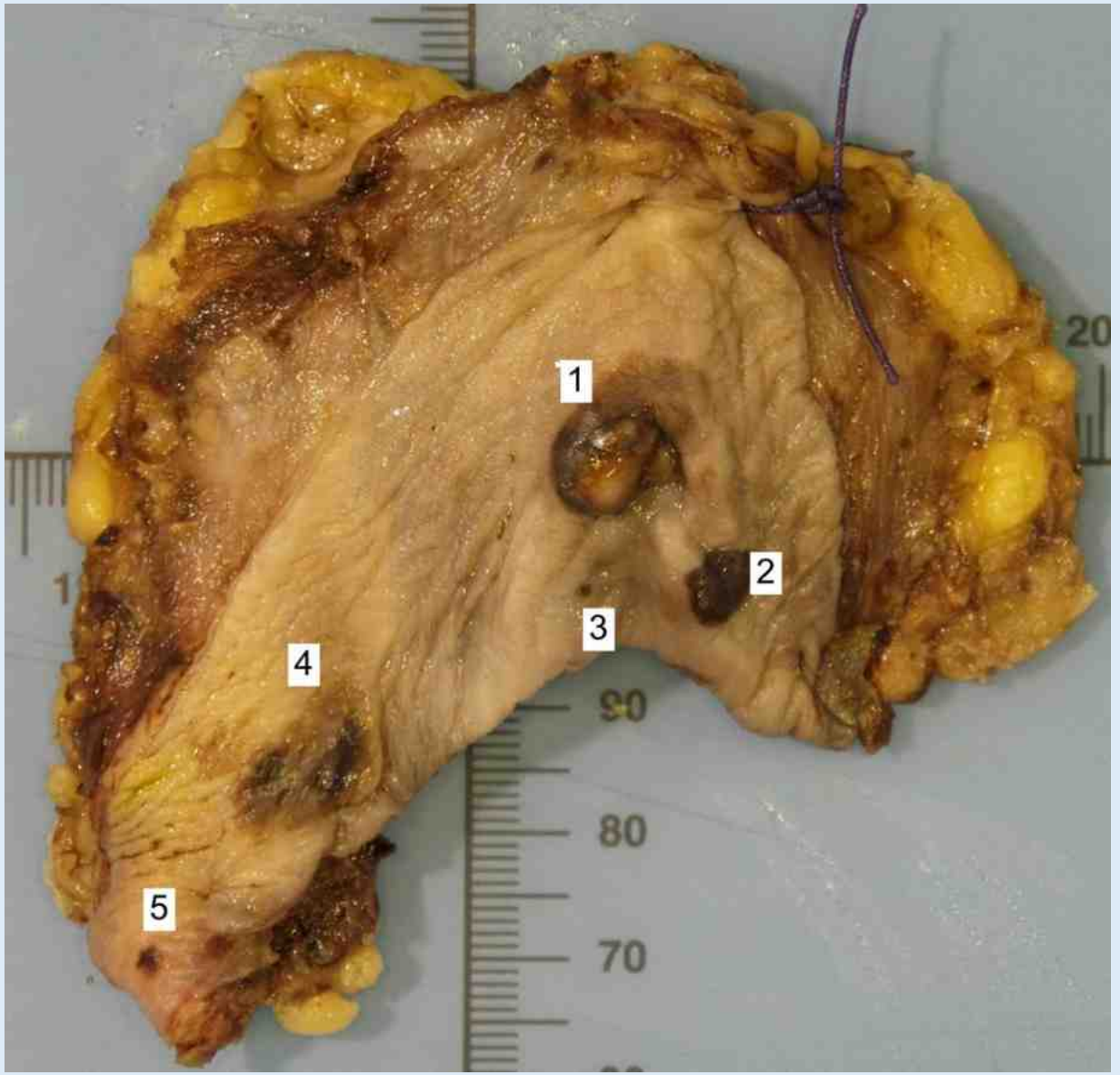
1
2
3
4
5
90
80
70

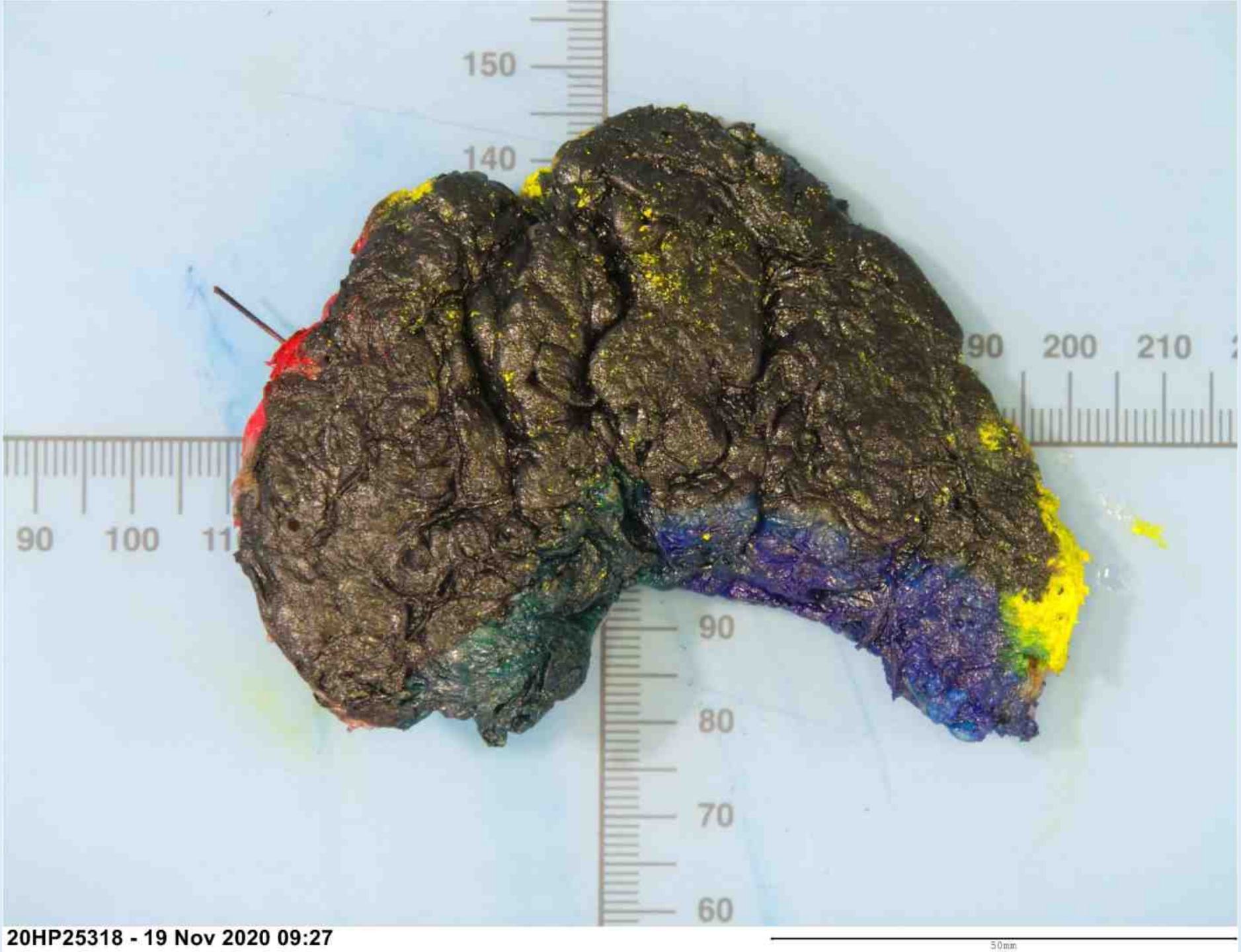
150
140
90
200
210
90
100
90
80
70
60
20HP25318 - 19 Nov 2020 09:27
50mm

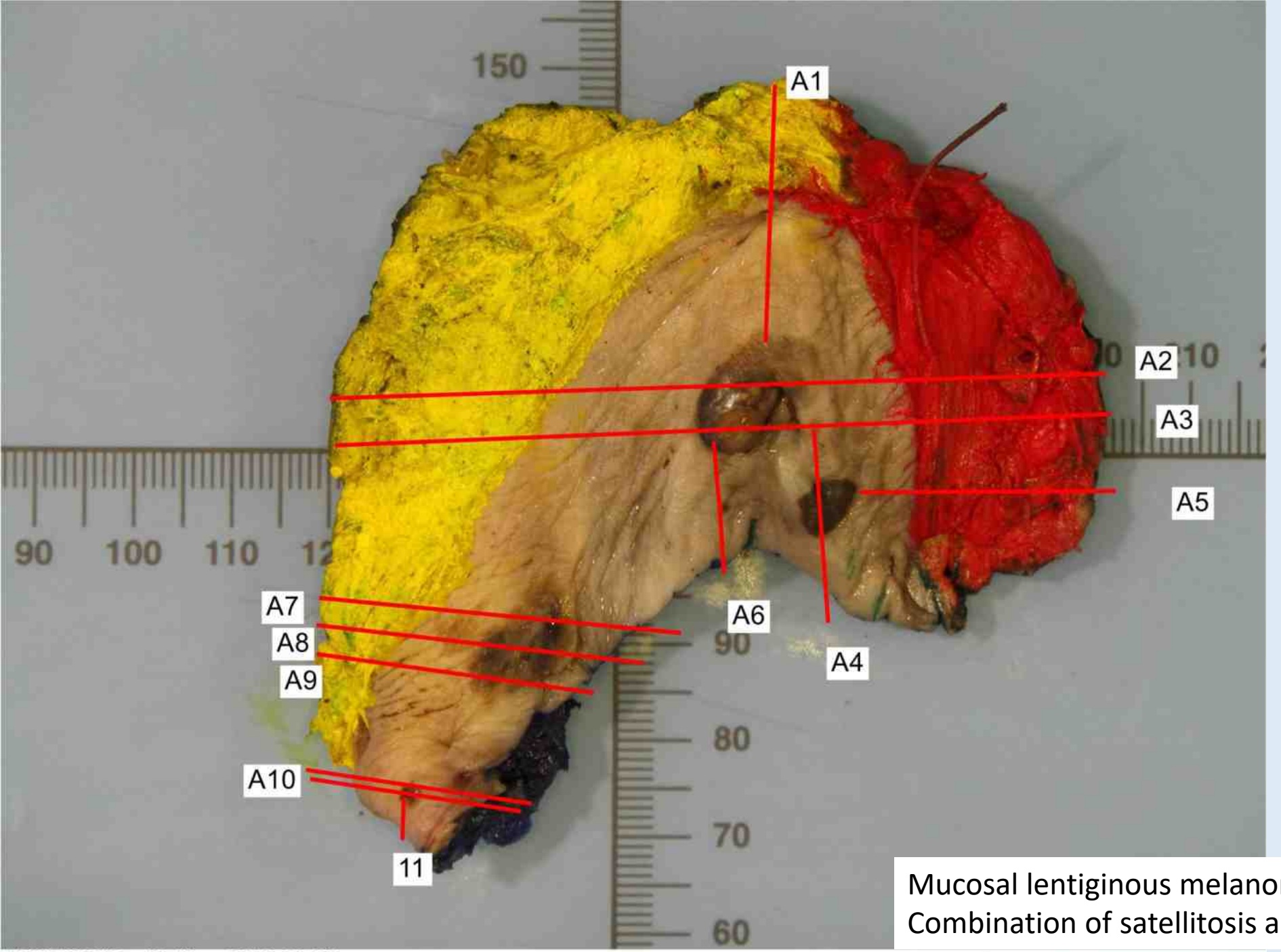

Mucosal lentiginous melanoma in vertical growth phase
Combination of satellitosis and direct spread

VAGINA
R
L
ANUS

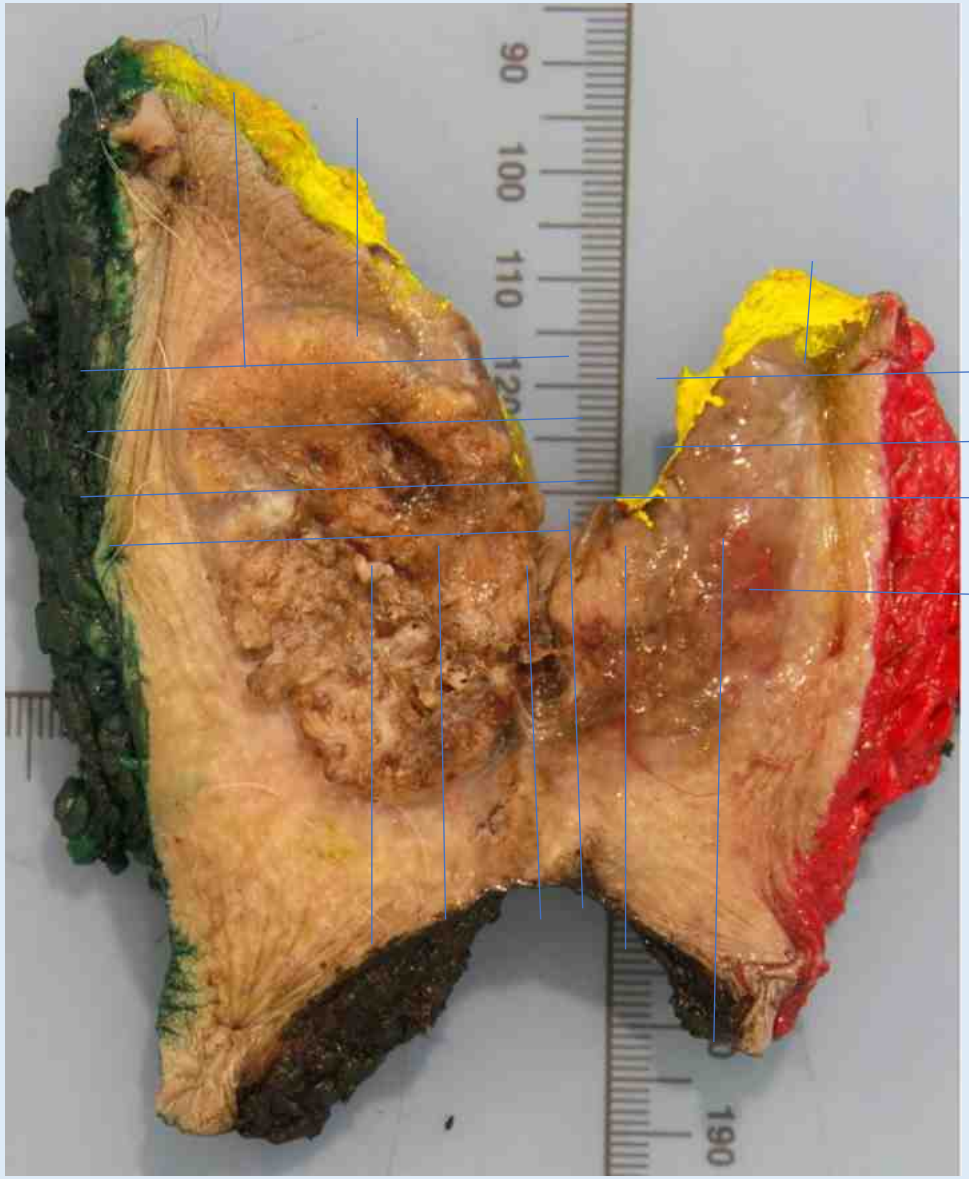
90
100
110
190


60
70
240

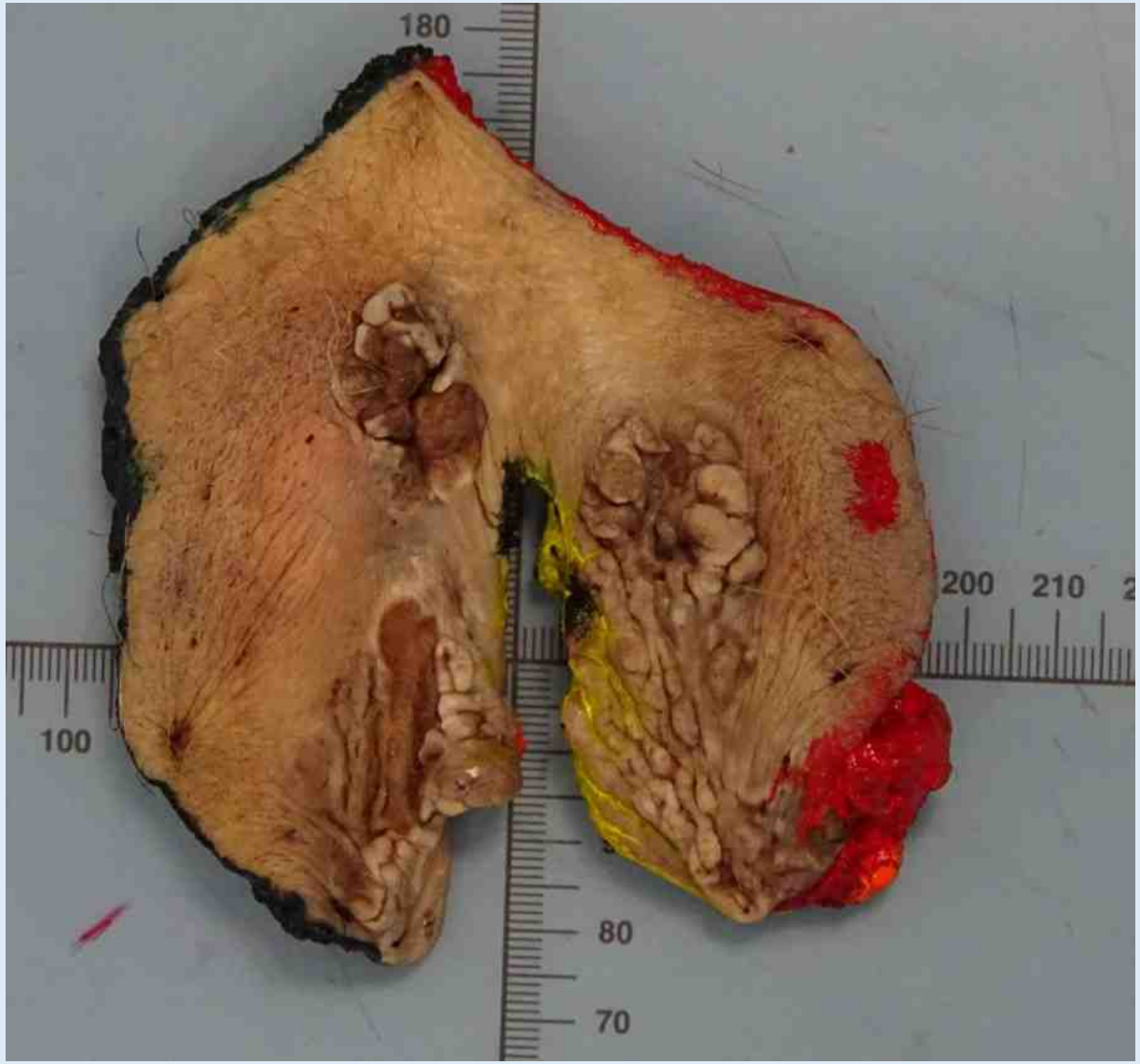
180
200
210
100
80
70

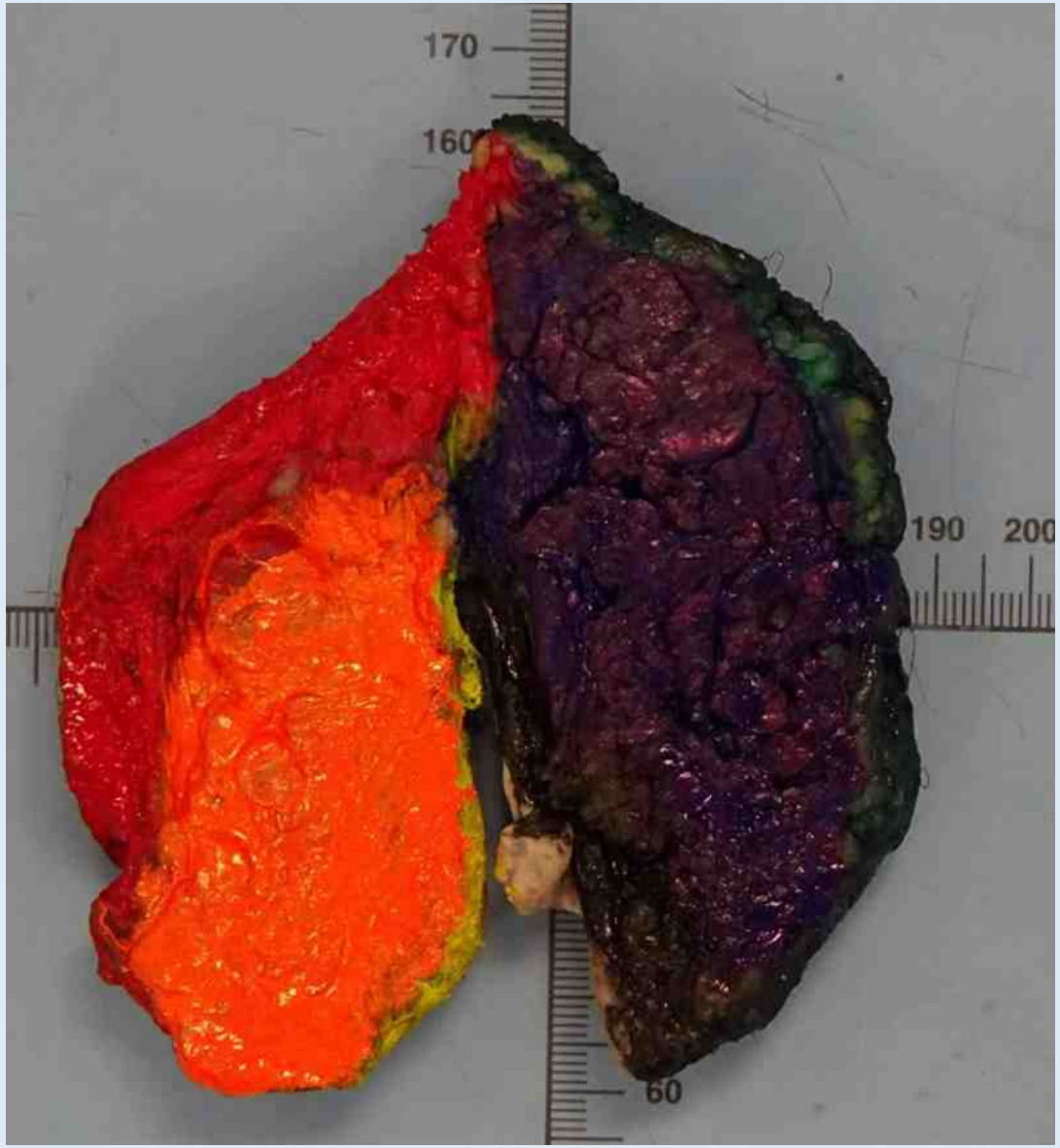
170
160
190
200
60

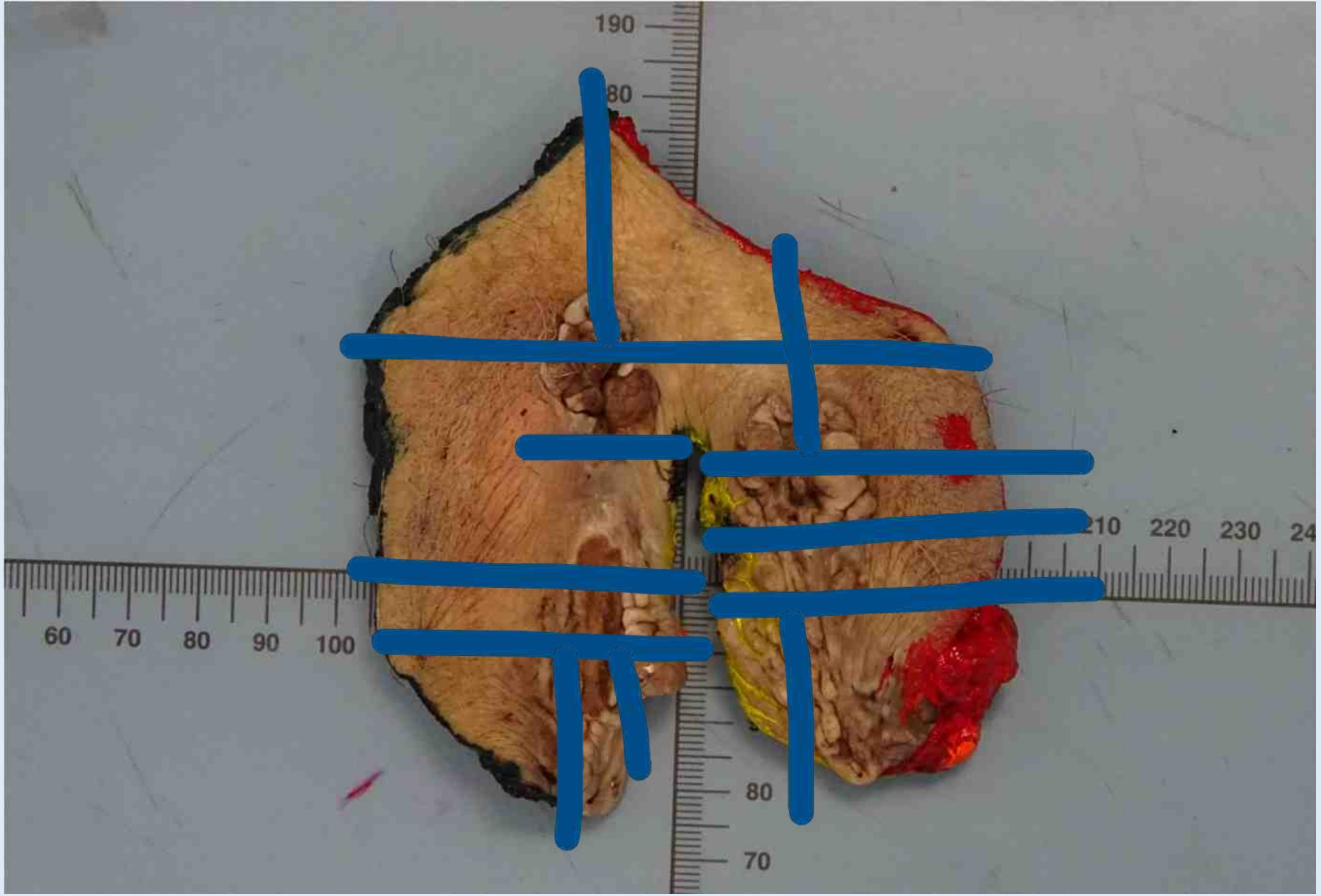
190
80
60
70
80
90
100
210
220
230
80
70


www.milestonemed.com
10 mm
20 mm
R
L
10 20 30 40 50
260 270 280 290 300
mm

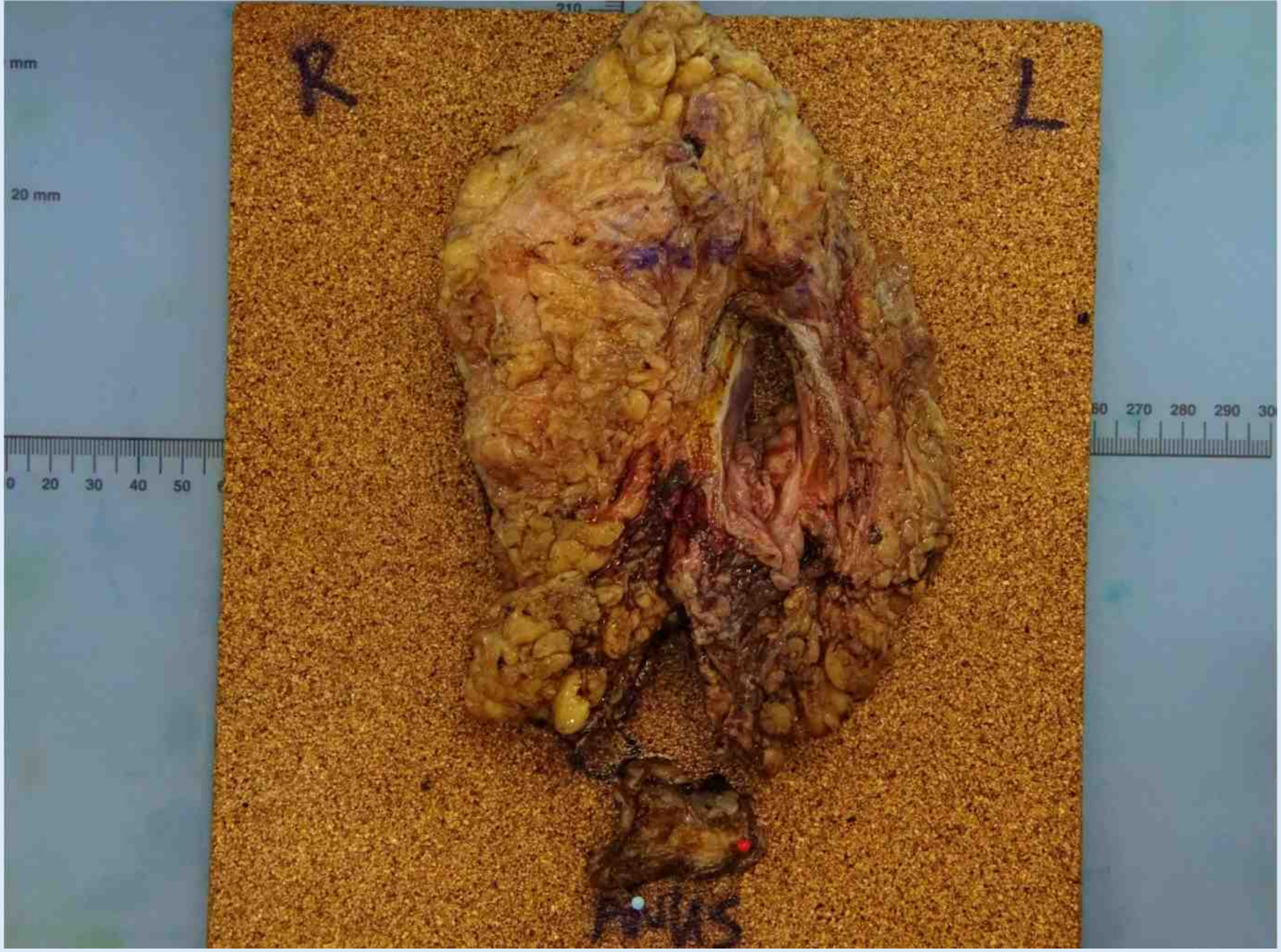
R
L
mm
20 mm
0 20 30 40 50
270 280 290

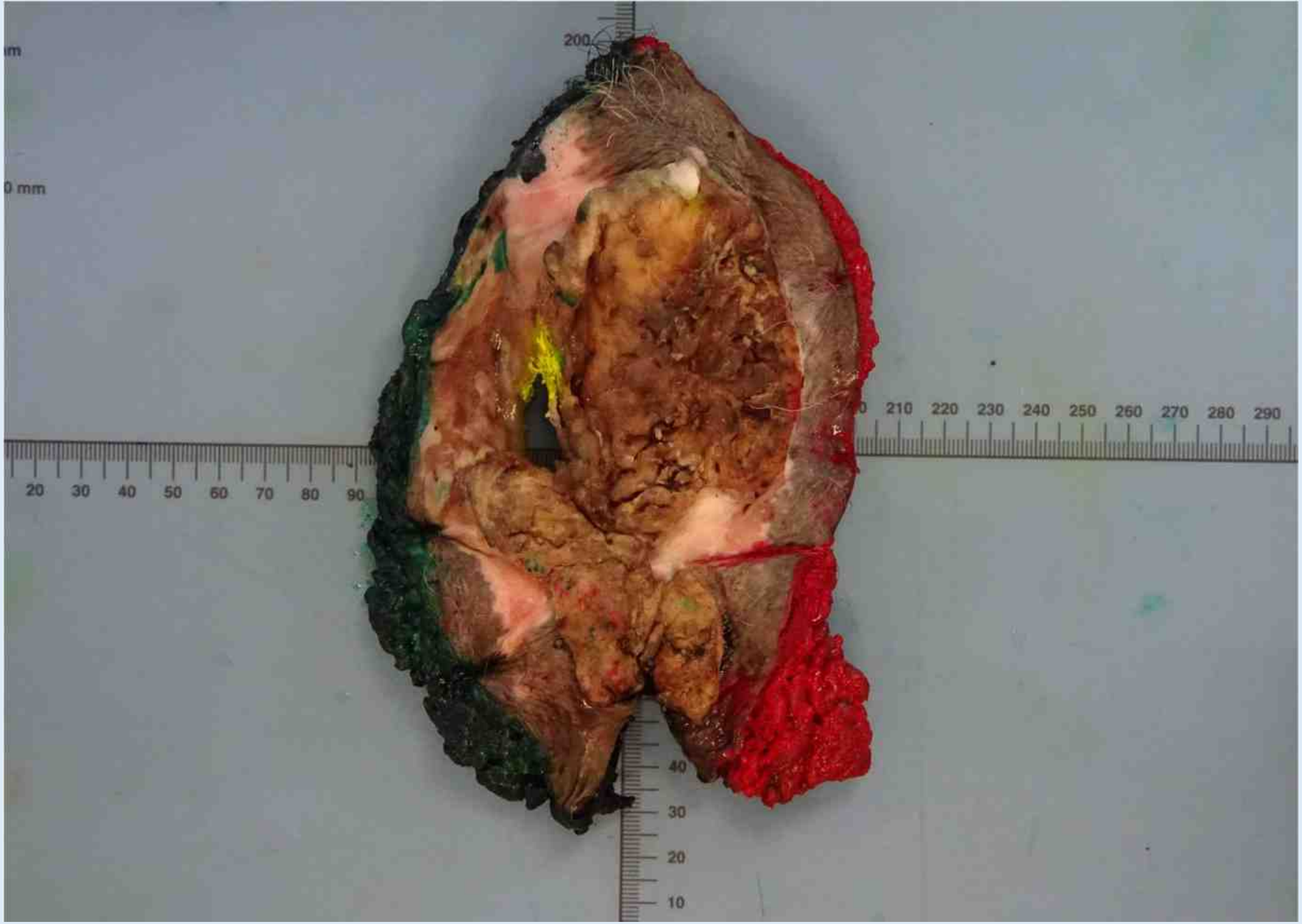
200
0 mm
210 220 230 240 250 260 270 280 290
20 30 40 50 60 70 80 90
40
30
20
10



YUSUF-PORTER, BARBARA - 30 Jul 2021 09:36


180
170
160
150
220
230
290
30
40
120
60
50
40
30
20
10
0
mm







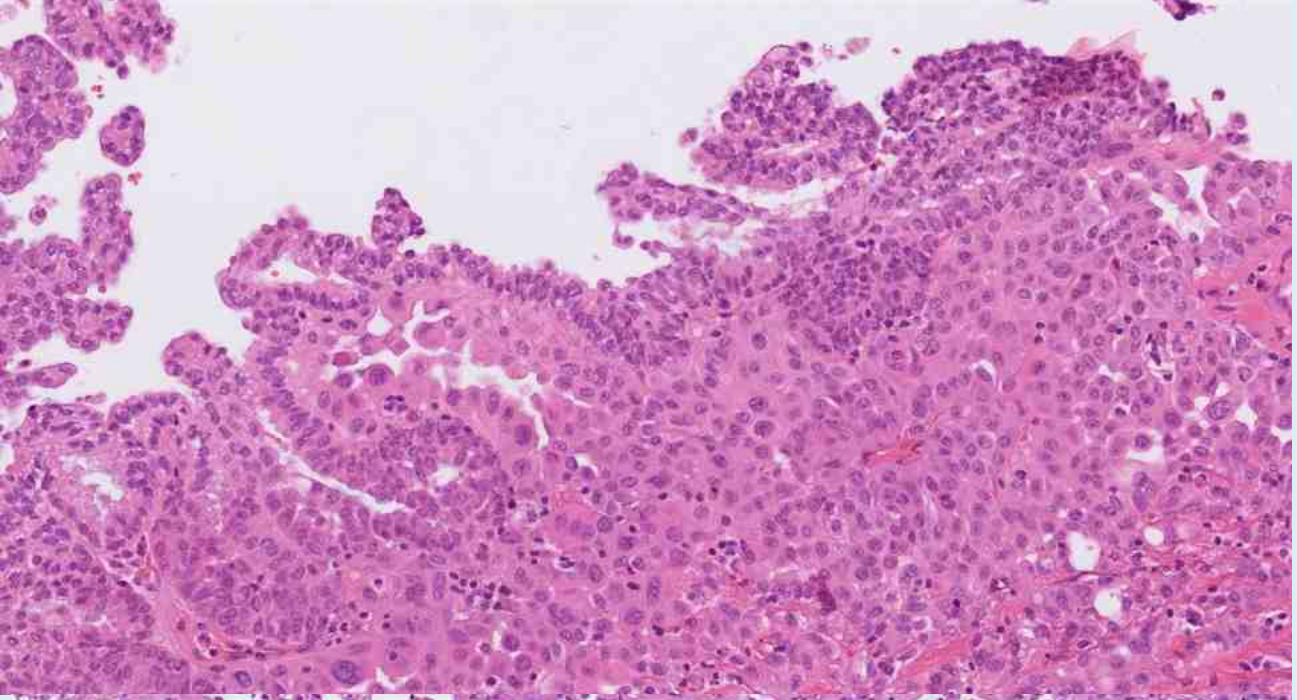

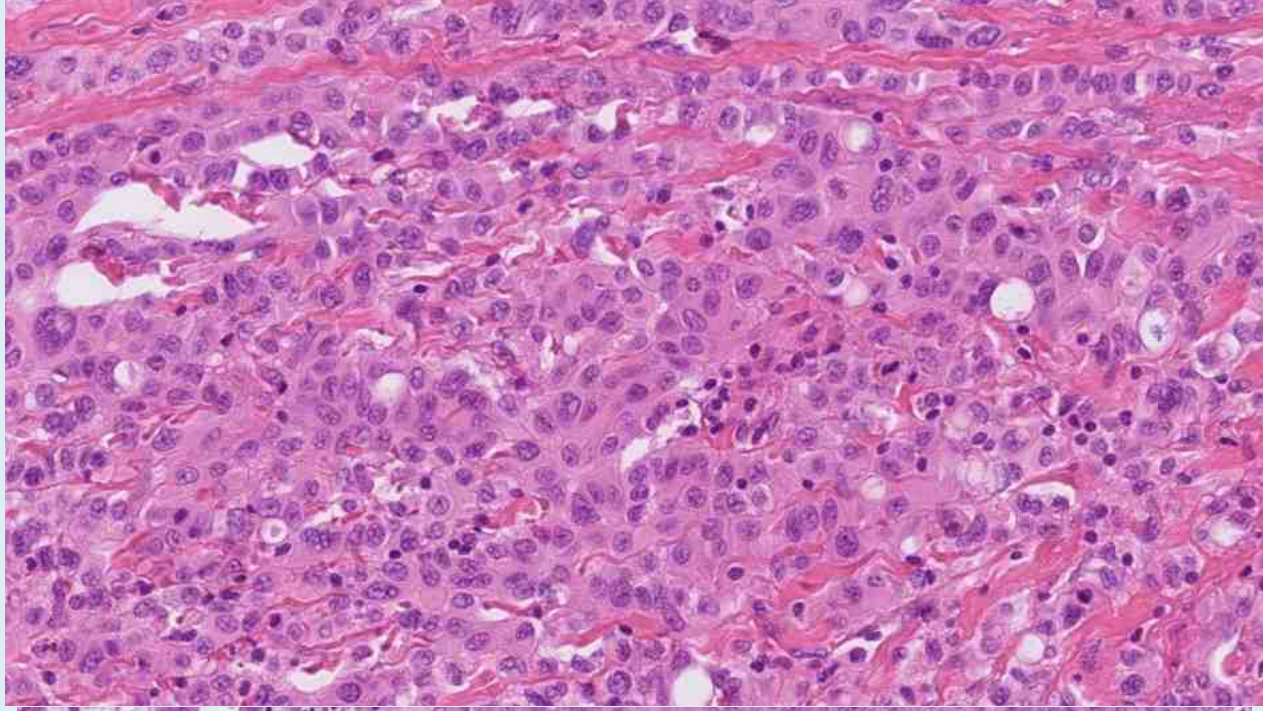

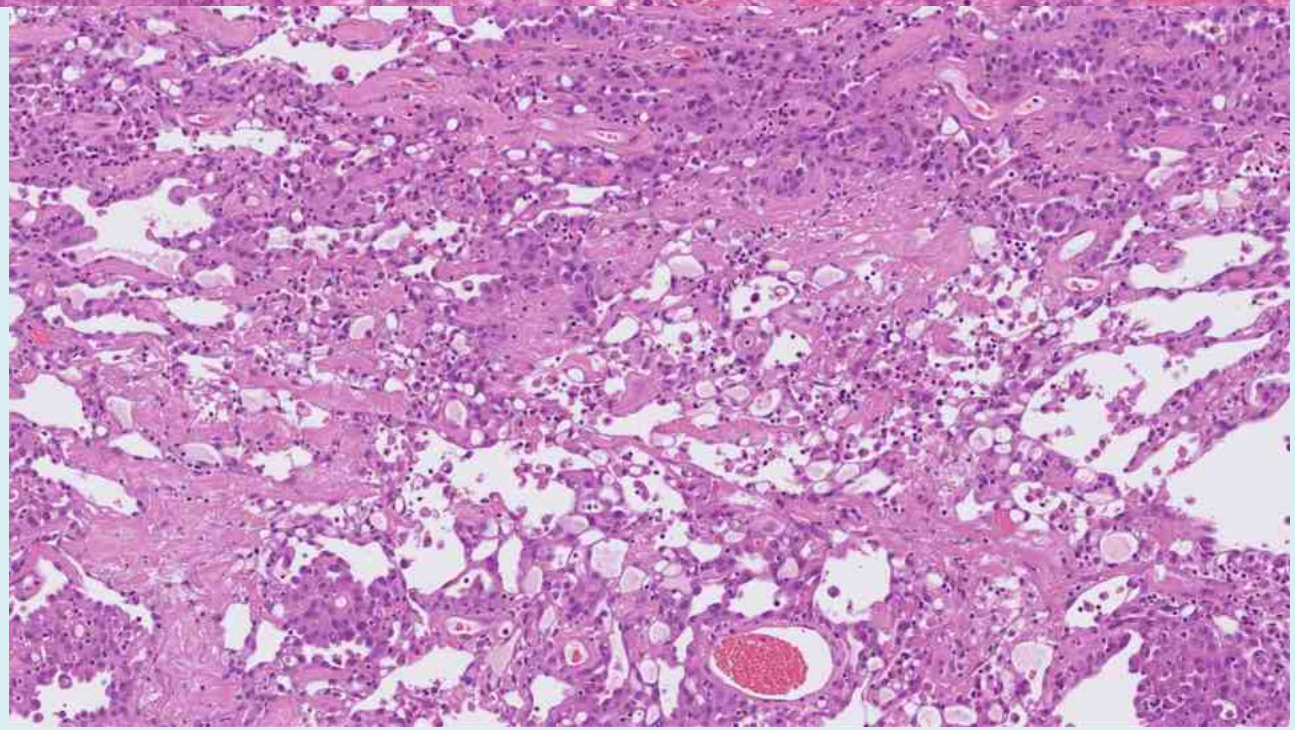

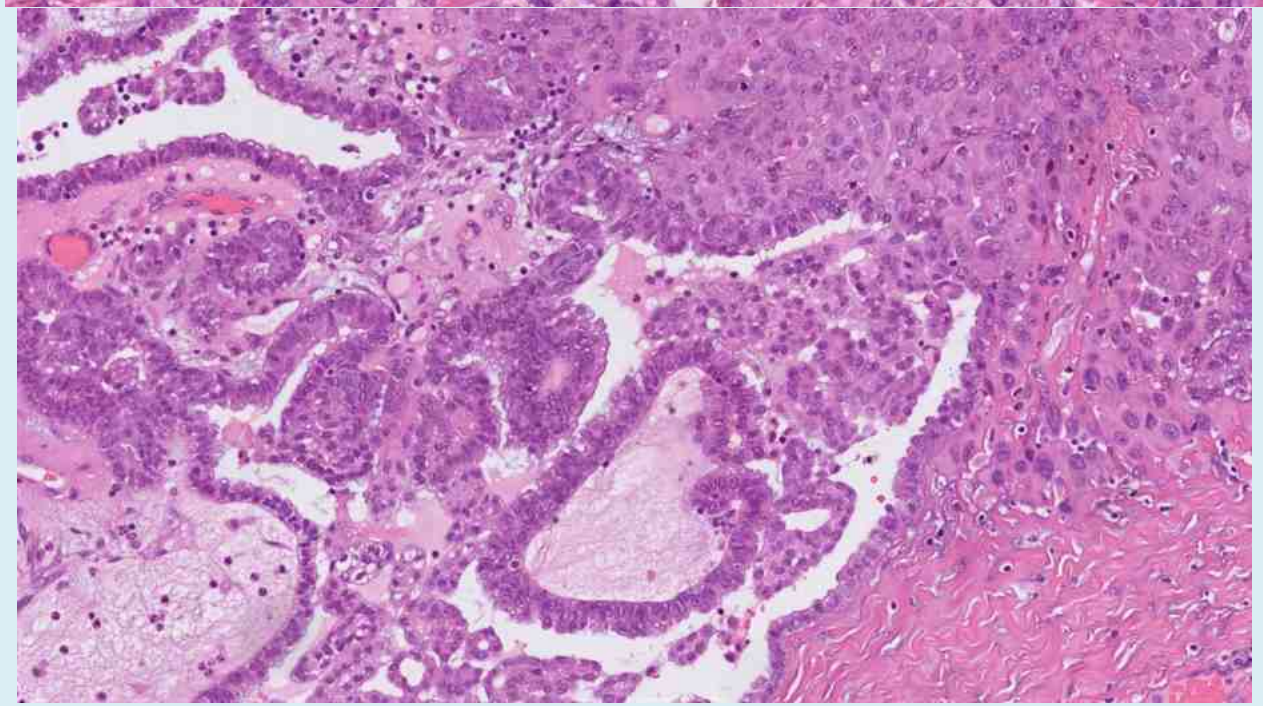

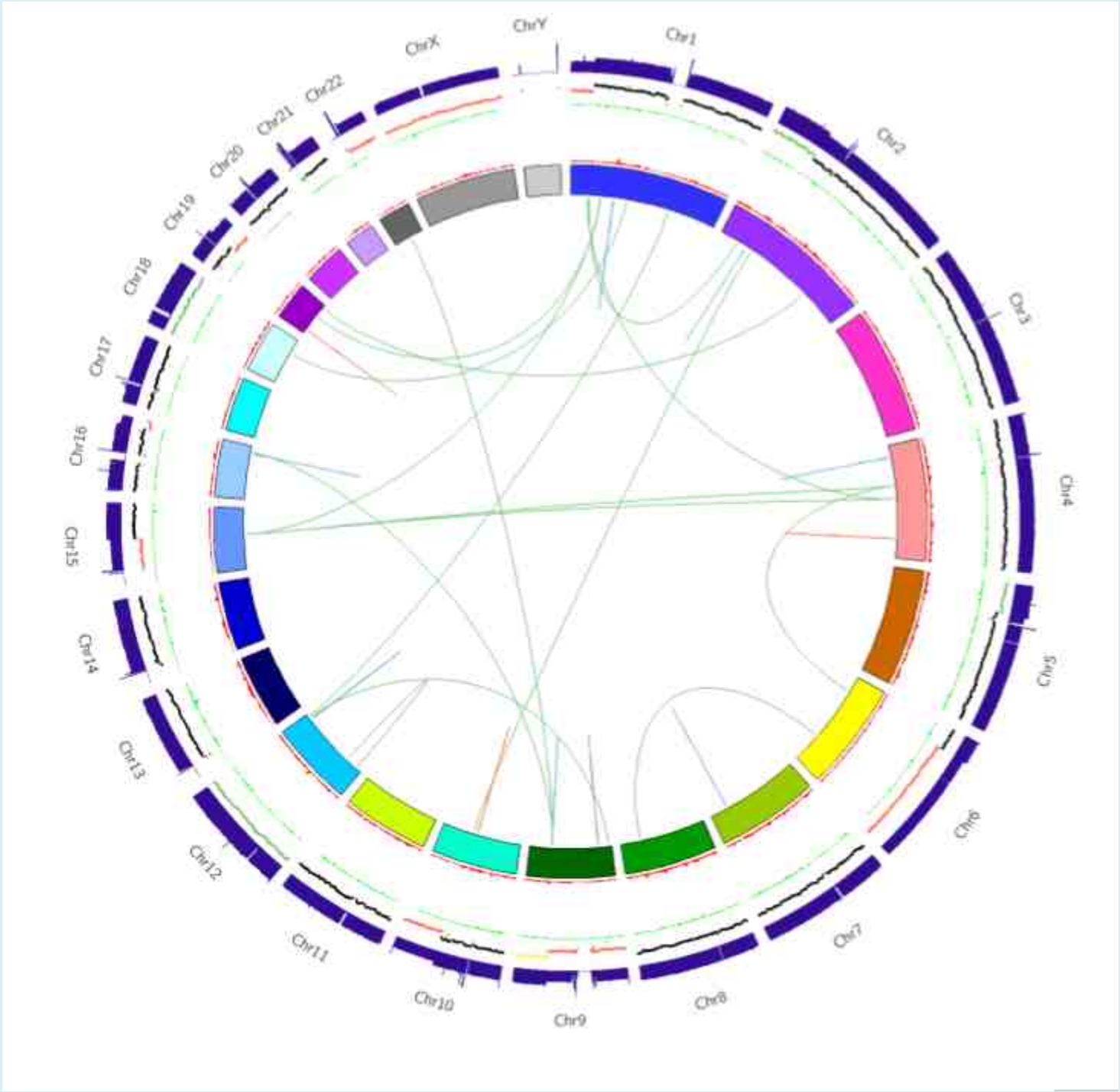
ChrY
Chr1
Chr2
Chr3
Chr4
Chr5
Chr6
Chr7
Chr8
Chr9
Chr10
Chr11
Chr12
Chr13
Chr14
Chr15
Chr16
Chr17
Chr18
Chr19
Chr20
Chr21
Chr22
ChrX

WGS Results Summary *(insert one row per variant)*							
	Domain	**Gene**	**HGVS**	**VAF**	**Classification**	**AMP/GTAB feedback**	**Confirmation?**
Small somatic variants	1	*SMARCB1* (NM_003073)	c.364G>T p.(Glu122Ter)	38%	Driver	II	
	2	*NF2* (NM_181832.2)	c.556G>T p.(Glu186Ter)	34%	Driver	II	
		PPP2R1A (NM_014225.6)	c.548G>A p.(Arg183Gln)	25%	Driver	II	
		RNF213 (NM_001256071.1)	c.1979G>T p.(Arg660Leu)	20%	VUS	III	
Germline findings	No tier 1 SSV or CNV germline findings No tier 3 SSV or CNV germline findings in *BRCA1, BRCA2, MLH1, MSH2, MSH6, PALB2, RET* ✓						
	Domain	**Variant Description**			**Classification**	**AMP/GTAB feedback**	**Confirmation?**
Structural variants	1/2	**LOSS:** 1p36.33p35.3 (*ARID1A*), 6p22.16q27, 9p24.3q22.33 (*CDKN2A/B*), 9p21.3p21.3 (*CDKN2A/B*), 10q23.1q26.3 (*PTEN*), 15q11.2q21.3, 16q23.2q24.3, 18, 19q13.11q13.43, 22, X **GAIN:** 2p25.3p16.1, 5p15.33p13.2, 12 **LOH:** 9q22.33q34.3			Reportable	II	
	2	**t(1;15)(p32.3;p32.3)** **Likely loss of *CDKN2C* function - VUS**			Reportable	III	
Overall structural assessment	Diploid genome with whole chromosome and large segmental gains, losses and LOH including copy number loss of tumour suppressor genes *ARID1A, CDKN2A/B* (bi-allelic) and *PTEN*. A complex rearrangement on chromosome 1, involving *CDKN2C* was also detected, which is predicted to cause LOF of the tumour suppressor gene. Please note in addition to the domain 1 LOF variants in *SMARCB1* and domain 2 LOF variant in *NF2* there is also loss of whole chromosome 22 resulting in bi-allelic *SMARCB1* and *NF2* losses.						

References

- Ganesan R et al. Tissue pathways for Gynaecological Pathology. London, UK: The Royal College of Pathologists. February 2023
- Malpica et al. Endometrial carcinoma, grossing and processing issues: recommendations of the International Society of Gynecologic Pathologists. Int J Gynecol Pathol 2019;38:S9–S24
- Wilkinson N, Vroobel K, Glenn W. Dataset for Histopathological Reporting of Carcinomas and Borderline Tumours of the Ovaries, Fallopian Tubes and Peritoneum (4th edition). London, UK: The Royal College of Pathologists, 2019.
- Faruqi A, Rous B. Dataset for Histopathological Reporting of Vulval Carcinomas (4th edition). London, UK: The Royal College of Pathologists, 2018
- Ganesan R, Singh N, Williams AT. Dataset for Histopathological Reporting of Cervical Neoplasia (4th edition). London, UK: The Royal College of Pathologists, 2021
- Ganesan R, Singh N, Williams TA. Dataset for Histological Reporting of Endometrial Cancer (5th edition). London, UK: The Royal College of Pathologists, 2017
- Fisher C. Dataset for Histopathological Reporting of Soft Tissue Sarcomas (5th edition). London, UK: The Royal College of Pathologists, 2017

Acknowledgements- Gynaepath Team

- Mrs Andrea Jewitt –BMS
- Dr Annu Sajeev- Specialty Doctor
- Dr Bronislava Slana
- Dr Cristina Cavallo
- Mr Gary Player-CBMS
- Dr Peter Newton
- Dr Razaan Yousif
- Dr Scarlet Brockmoeller
- Dr Sophia Williamson

Dr Rachna Khera (Liverpool Hospitals)-who helped me reduce my slide count from 300 to 200 ☺!

Thank you