The British Association of Gynaecological Pathologists

Lecturer – Prof. Koen Van de Vijver

koen.vandevijver@uzgent.be



Prof. Koen Van de Vijver is a surgical pathologist with a keen interest in the diagnosis and treatment of cancers of the female genital tract and the breast. Most of his activities involve diagnostic work, teaching, and clinico-pathologic research. His research is mainly focused on the molecular analysis of ovarian neoplastic diseases. He is co-author of more than 150 peer-reviewed A1 publications, including New England Journal of Medicine, Nature Medicine, Lancet Oncology and Journal of Clinical Oncology.

In 2011-2012 he completed a full year fellowship with prof. dr. Esther Oliva in Gynaecological Pathology at Massachusetts General Hospital, Harvard Medical School, Boston (USA). After working as a consultant histopathologist in the Netherlands Cancer Institute in Amsterdam (NL), he became Professor of Gynaecological Pathology at Ghent University (Belgium) in 2018. He serves on several guidelines panels and subspecialized gynaecological and breast pathology working groups. Currently, he is a council member of the BAGP, councillor at the ICCR and President of the Belgian Society of Pathology.

The British Association of Gynaecological Pathologists

Everyday Dilemmas in Gynaecological Pathology

- Title: Grading endometrioid endometrial carcinoma
- Speaker: Koen Van de Vijver
- Affiliation: Ghent University Hospital
- Date: Friday, March 7, 2025

The British Association of Gynaecological Pathologists

Speaker disclosures

I have the following to disclose:

Consulting fees (advisory role) paid to my institution by AbbVie, Owkin, GlaxoSmithKline (GSK), Exact Sciences and AstraZeneca.

No personal benefits.
All of these outside the scope of my presentations.

Grading = standard histology ?



Grading = standard histology

endometrioid subtype: grade 1 - 2 - 3

all other types: high grade / grade 3

(serous, clear cell, undifferentiated/dedifferentiated, gastric-type, mesonephric-like carcinoma, and carcinosarcoma)

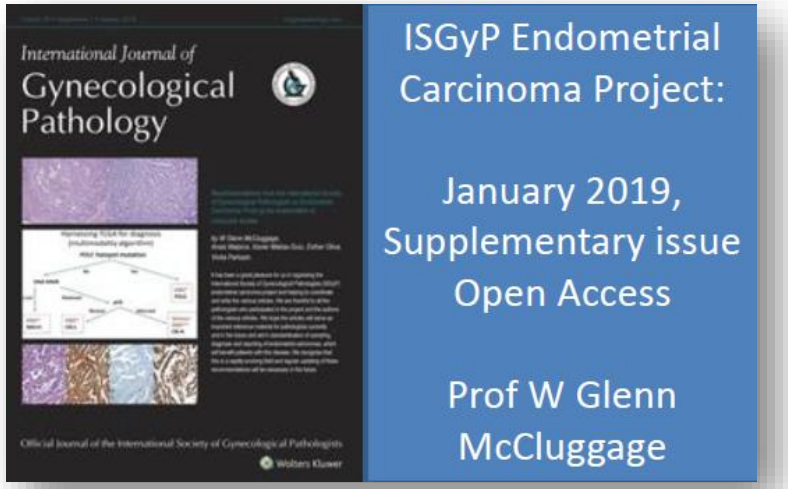

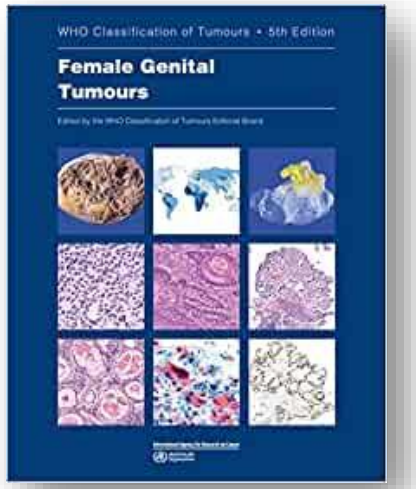



Grading = standard histology

EEC is graded using FIGO grading criteria: grades 1, 2 and 3 tumours exhibit ≤ 5%, 6-50% and >50% solid non-glandular, non-squamous growth. Severe cytological atypia in > 50% of cells increases the grade by one level.

Cave: severe atypia = often serous carcinoma !

Binary grading is recommended, whereby grade 1 and 2 tumours are considered low-grade and grade 3 tumours high-grade.

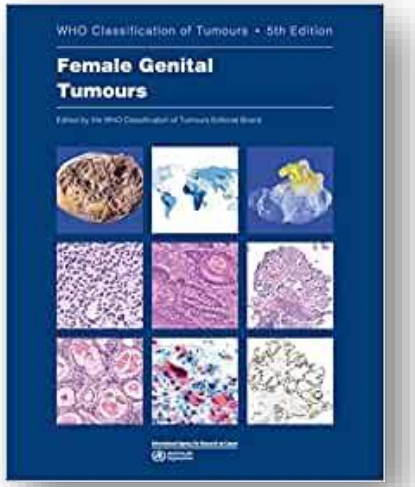


ESGO/ESTRO/ESP guidelines for the management of patients with endometrial carcinoma

Grading = standard histology

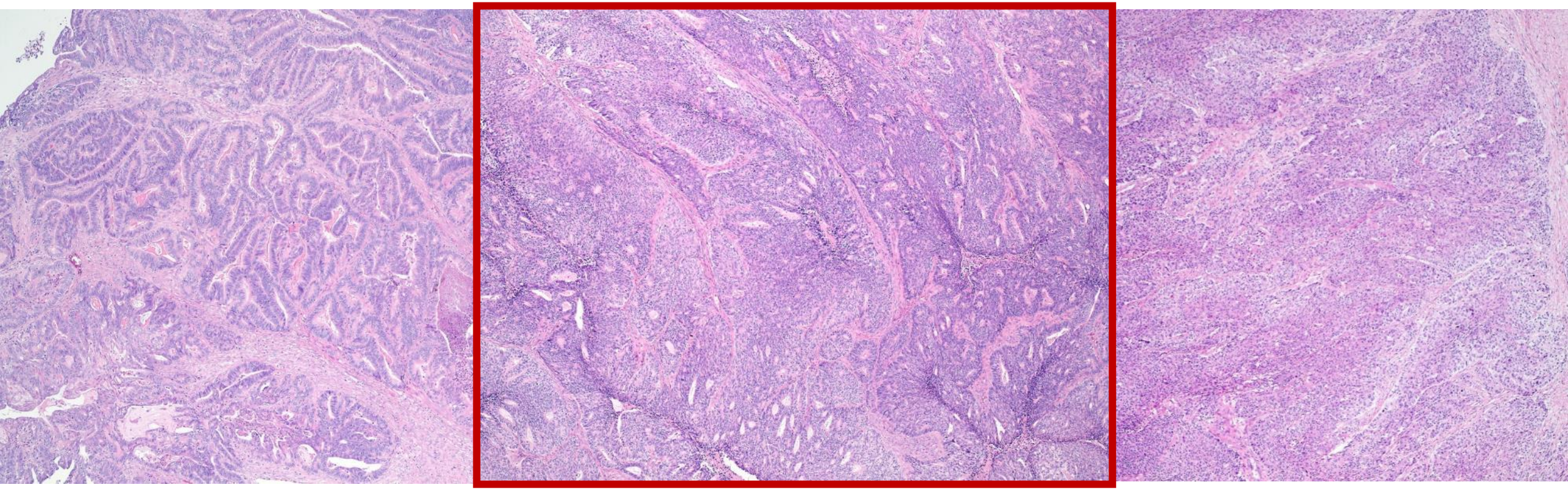

grade 1 | grade 2 | grade 3

low-grade | high-grade

Grading Uterine Endometrioid Carcinoma

A Proposal That Binary Is Best

Niamh Conlon, MB, Mario M. Leitao, Jr, MD,†‡*
Nadeem R. Abu-Rustum, MD,†‡ and Robert A. Soslow, MD‡*

Am J Surg Pathol • Volume 38, Number 12, December 2014

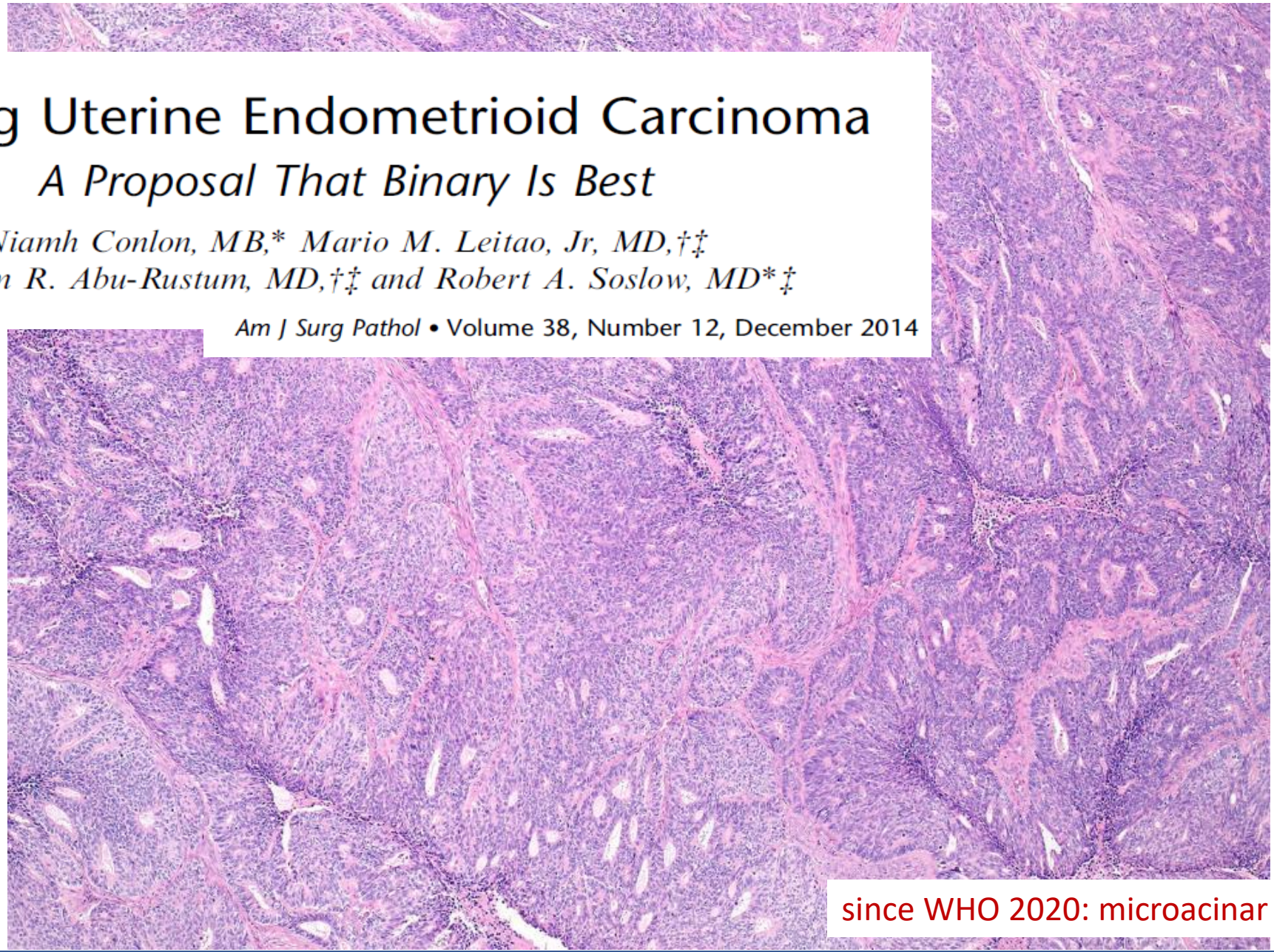

since WHO 2020: microacinar growth = solid

MOLECULAR CLASSIFICATION

The Cancer Genome Atlas Research Network
Kandoth et al, Nature 2013

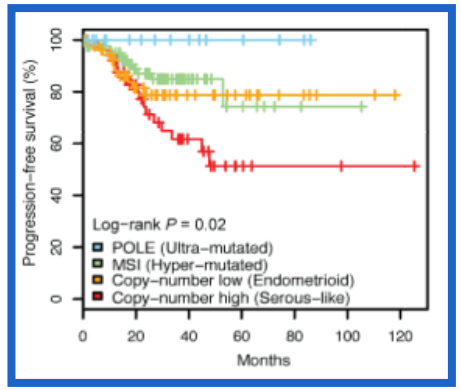

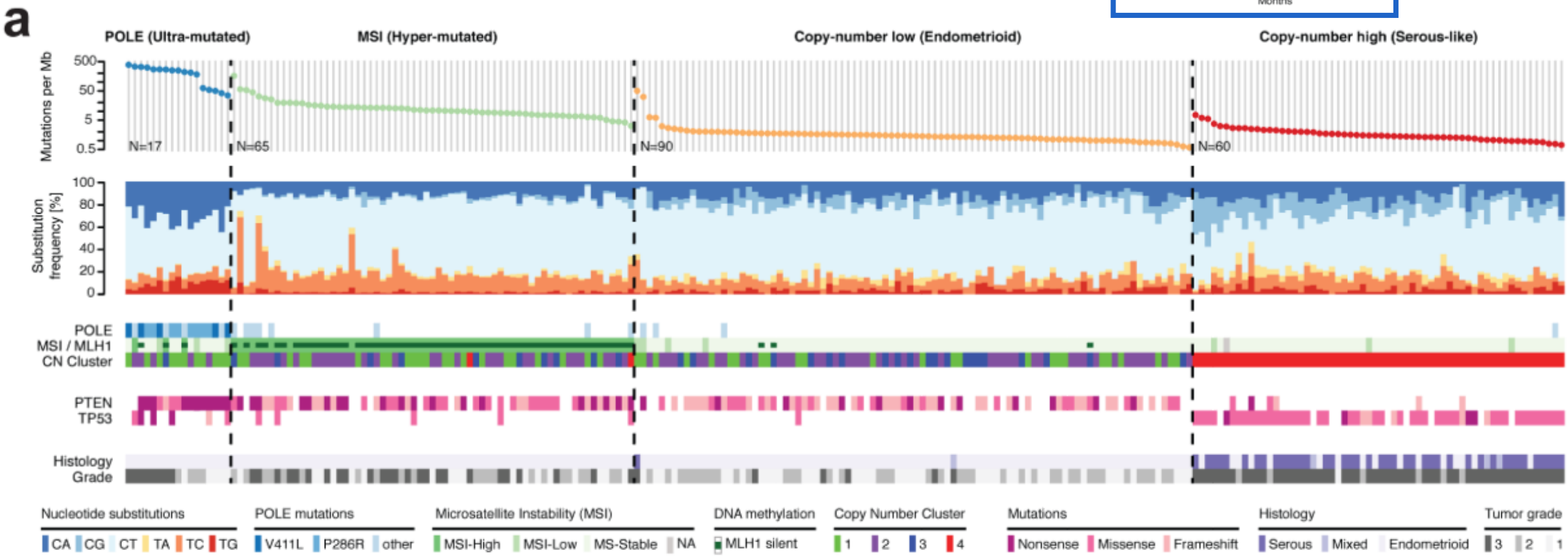

FIGO staging of endometrial cancer: 2023

Jonathan S. Berek[1] | Xavier Matias-Guiu[2] | Carien Creutzberg[3] | Christina Fotopoulou[4] | David Gaffney[5] | Sean Kehoe[6] | Kristina Lindemann[7] | David Mutch[8] | Nicole Concin[9,10] | Endometrial Cancer Staging Subcommittee, FIGO Women's Cancer Committee

Int J Gynecol Obstet. 2023;162:383–394

TABLE 1 2023 FIGO staging of cancer of the endometrium.[a,b]

Stage	Description
Stage I	Confined to the uterine corpus and ovary[c]
IA	Disease limited to the endometrium OR non-aggressive histological type, i.e. low-grade endometroid, with invasion of less than half of myometrium with no or focal lymphovascular space involvement (LVSI) OR good prognosis disease
	IA1 Non-aggressive histological type limited to an endometrial polyp OR confined to the endometrium
	IA2 Non-aggressive histological types involving less than half of the myometrium with no or focal LVSI
	IA3 Low-grade endometrioid carcinomas limited to the uterus and ovary[c]
IB	Non-aggressive histological types with invasion of half or more of the myometrium, and with no or focal LVSI[d]
IC	Aggressive histological types[e] limited to a polyp or confined to the endometrium
Stage II	Invasion of cervical stroma without extrauterine extension OR with substantial LVSI OR aggressive histological types with myometrial invasion
IIA	Invasion of the cervical stroma of non-aggressive histological types
IIB	Substantial LVSI[d] of non-aggressive histological types
IIC	Aggressive histological types[e] with any myometrial involvement

[e] Non-aggressive histological types are composed of low-grade (grade 1 and 2) EECs. Aggressive histological types are composed of high-grade EECs (grade 3), serous, clear cell, undifferentiated, mixed, mesonephric-like, gastrointestinal mucinous type carcinomas, and carcinosarcomas.

Stage designation	Molecular findings in patients with early endometrial cancer (Stages I and II after surgical staging)
Stage IAm$_{POLEmut}$	*POLEmut* endometrial carcinoma, confined to the uterine corpus or with cervical extension, regardless of the degree of LVSI or histological type
Stage IICm$_{p53abn}$	p53abn endometrial carcinoma confined to the uterine corpus with any myometrial invasion, with or without cervical invasion, and regardless of the degree of LVSI or histological type

2025 *in press*

DEFINITION OF RISK GROUPS

ESTRO European Society of Pathology

ESGO European Society of Gynaecological Oncology

The British Association of Gynaecological Pathologists

Low | Intermediate | High-Intermediate | High | Uncertain

2023 FIGO staging[T]			Molecular classification*				
			*POLE*mut	MMRd	NSMP low-grade+ERpos	NSMP high-grade/ERneg**	p53abn
I	**Confined to the uterine corpus**						
IA	IA1	Low-grade endometrioid, limited to polyp/endometrium (no myoinvasion)	IAm *POLE*mut			**	
	IA2	Low-grade endometrioid, myoinvasion <50%, no/focal LVSI	IAm *POLE*mut			**	p53abn
	IA3	Low-grade endometrioid carcinoma of the endometrium & ovary#	IAm *POLE*mut			**	IICm p53abn
IB		Low-grade endometrioid, myoinvasion ≥50%, no/focal LVSI	IAm *POLE*mut			**	IICm p53abn
IC		High-grade histologies^, limited to polyp/endometrium	IAm *POLE*mut		n.a.		
II	**Confined to the uterus**						
IIA		Low-grade endometrioid, invasion of the cervical stroma	IAm *POLE*mut			**	IICm p53abn
IIB		Low-grade endometrioid, substantial LVSI***	IAm *POLE*mut			**	IICm p53abn
IIC		High-grade histologies^, myoinvasion	IAm *POLE*mut	Myoinvasion <50%, no/focal LVSI	n.a.		IICm p53abn
			IAm *POLE*mut	Myoinvasion ≥50%, no/focal LVSI			
			IAm *POLE*mut	Cervical stromal invasion, no/focal LVSI			
			IAm *POLE*mut	Substantial LVSI**			

Grading: dilemmas ?

When are glandular structures not endometrioid (but rather pseudo-endometrioid) ?

When are solid structures not really solid ?

Which non-glandular “differentiation” can be ignored ?

Advances in Anatomic Pathology
Vol. 9, No. 3, pp. 145–184
© 2002 Lippincott Williams & Wilkins, Inc., Philadelphia

2002

Review Article

Endometrioid Carcinoma of the Uterine Corpus: A Review of Its Pathology With Emphasis on Recent Advances and Problematic Aspects

*Philip B. Clement and †Robert H. Young

UZ GENT UNIVERSITEIT GENT

The British Association of Gynaecological Pathologists

SLIDE SEMINAR

Case 1

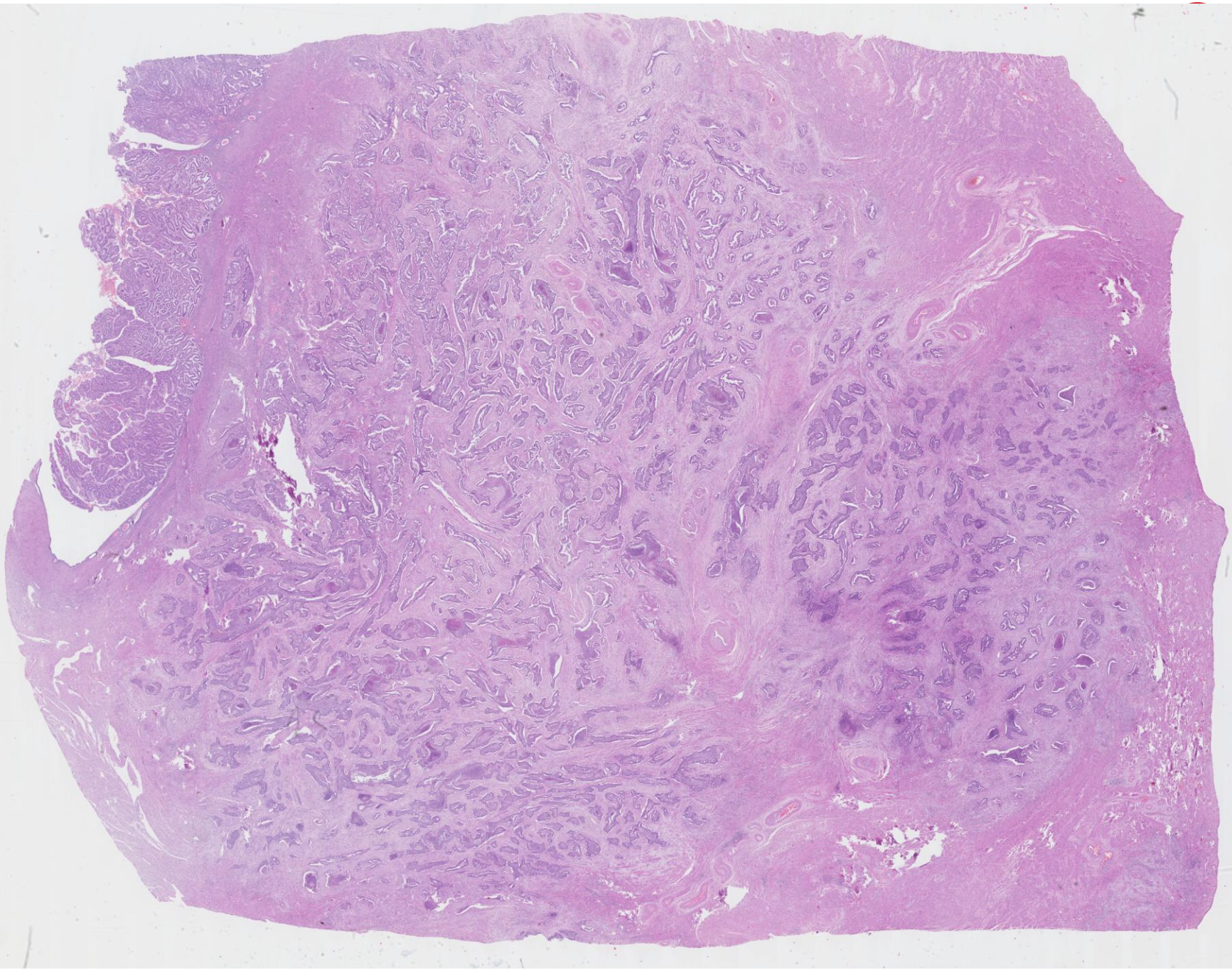

0,84x

2,5 mm

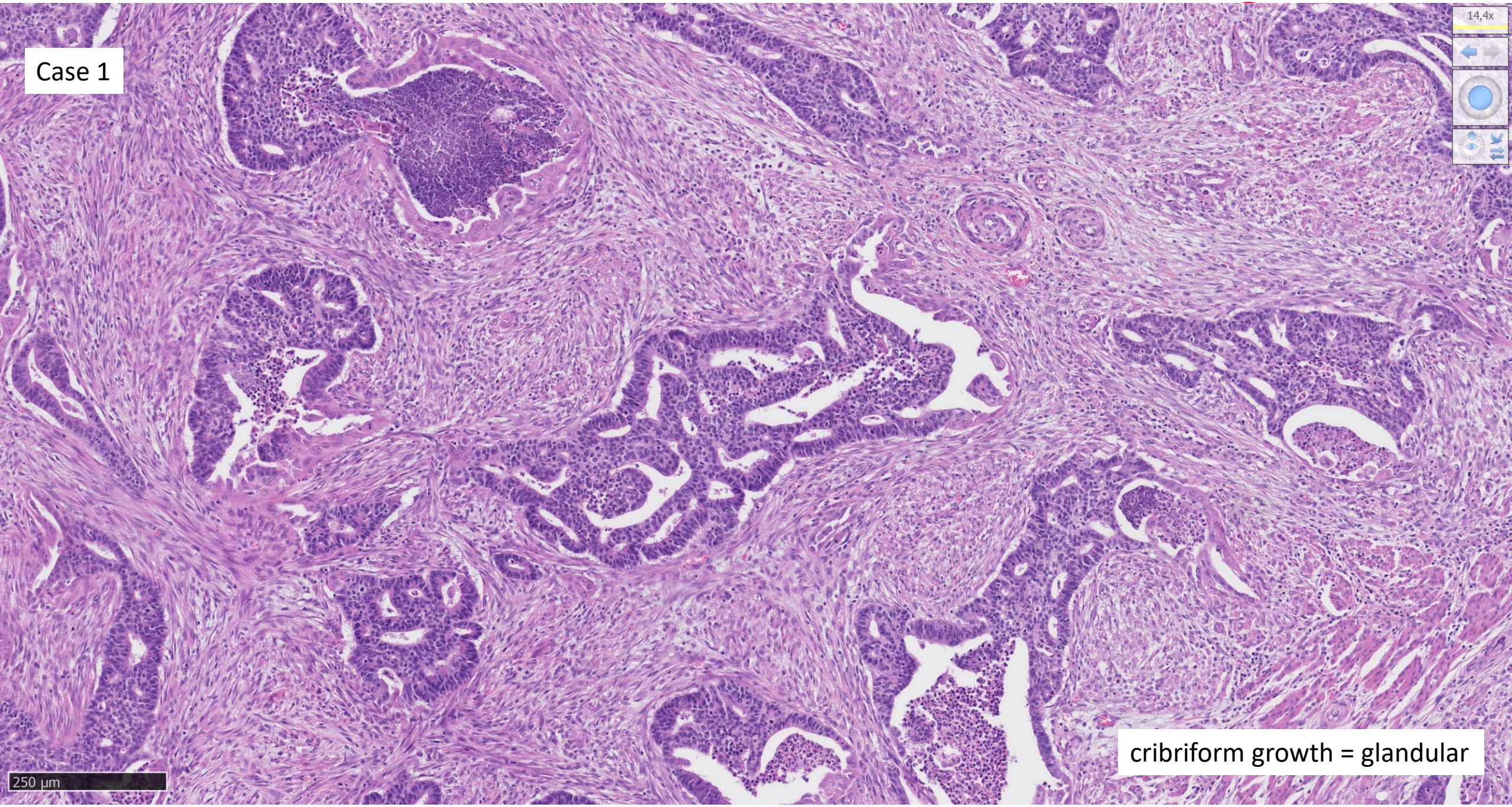
Case 1
14,4x
250 µm
cribriform growth = glandular

Case 2

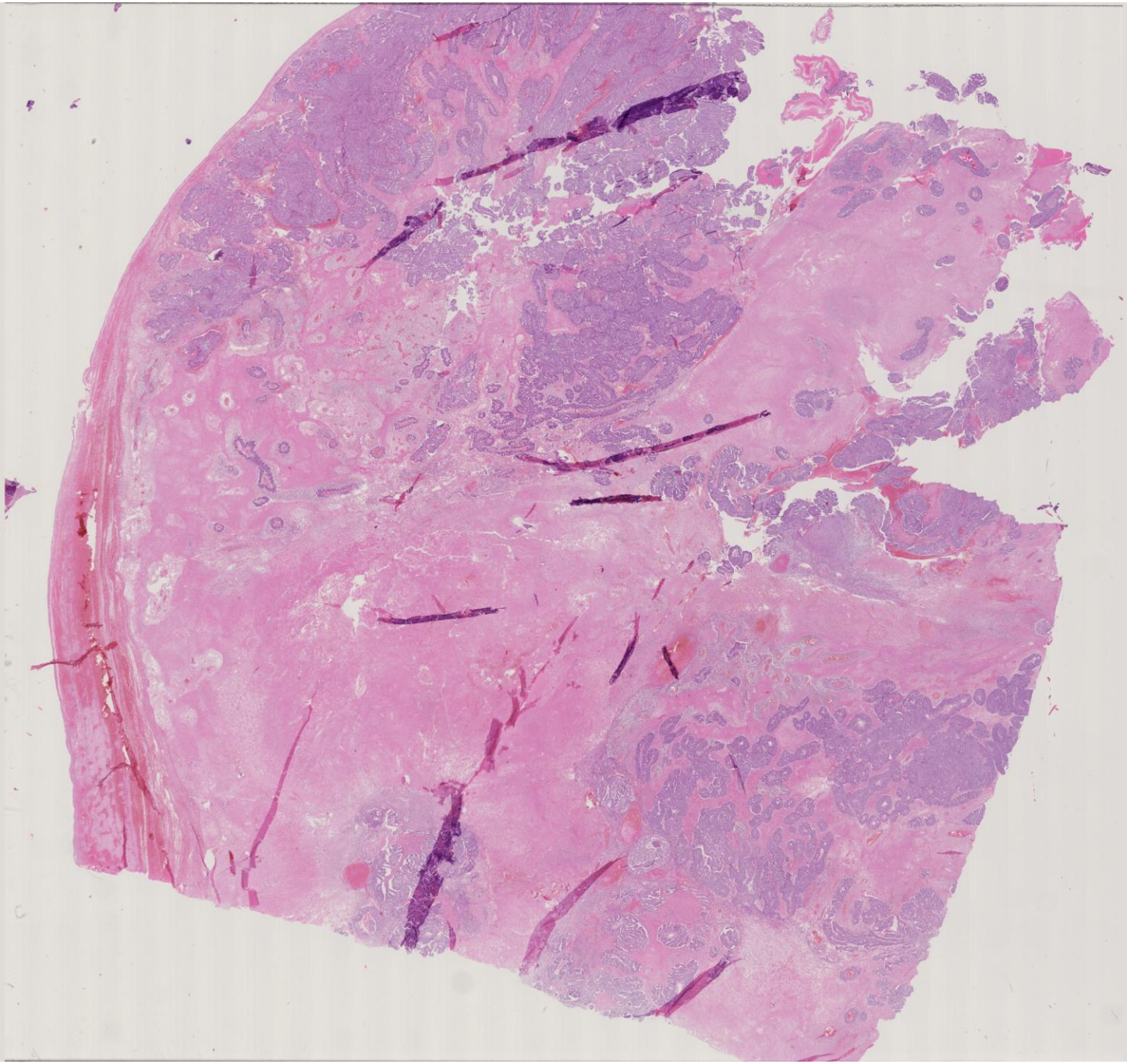

0,77x

2,5 mm

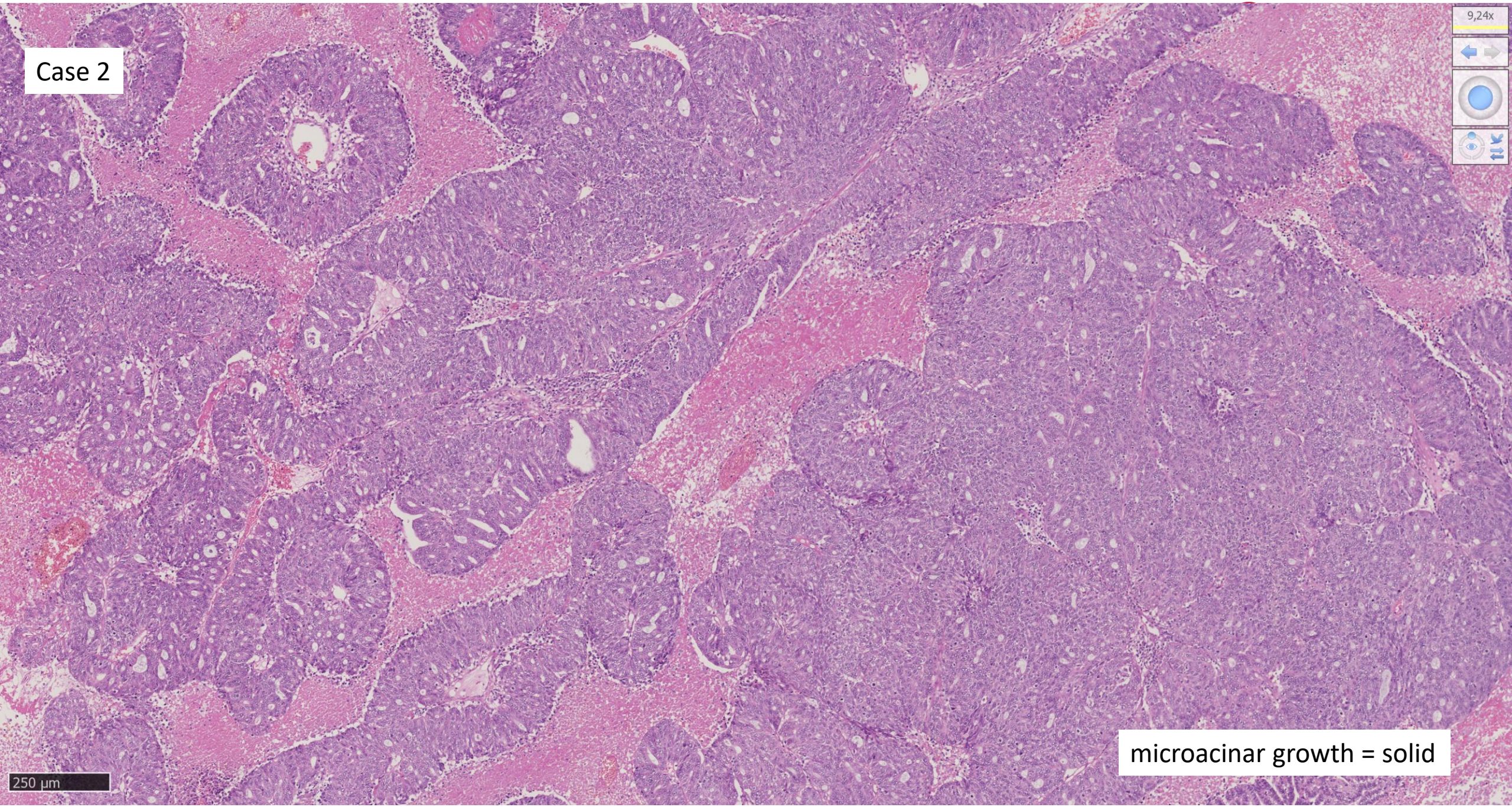
Case 2
9,24x
250 µm
microacinar growth = solid

Case 3

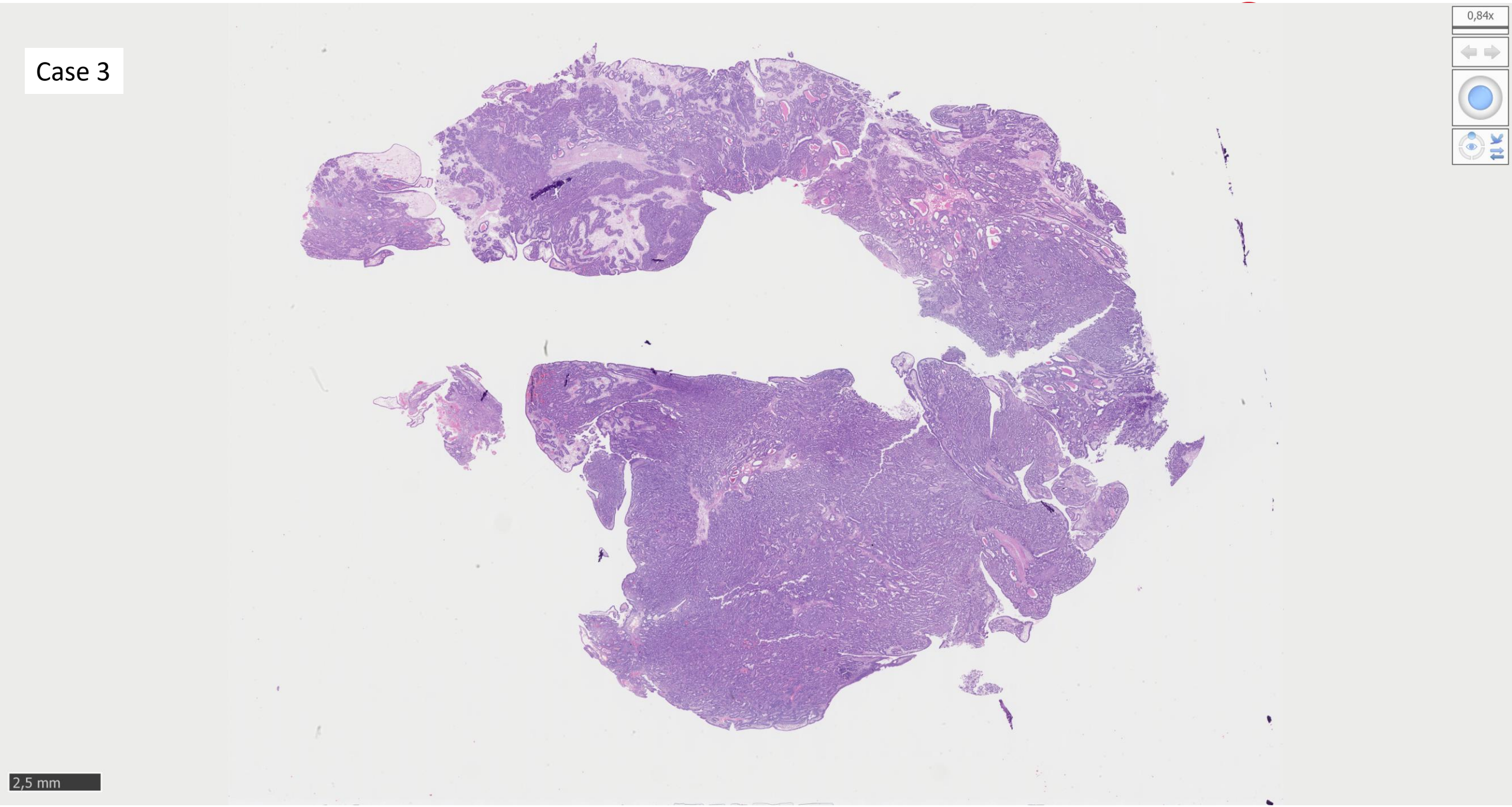

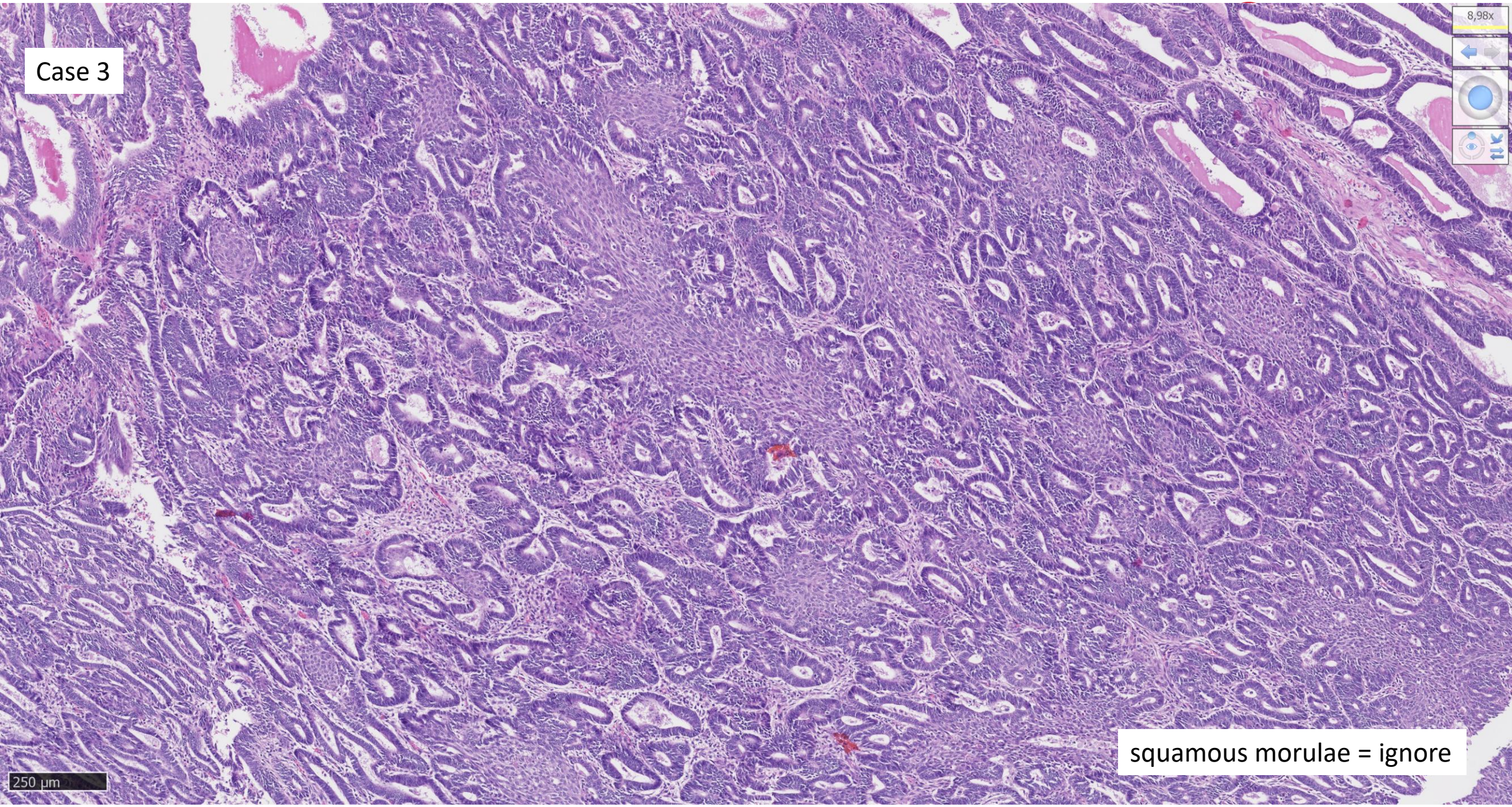
Case 3
8,98x
250 µm
squamous morulae = ignore

Histopathology 2008, **53**, 156–165. DOI: 10.1111/j.1365-2559.2008.03083.x

Morules in endometrioid proliferations of the uterus and ovary consistently express the intestinal transcription factor CDX2

O Houghton, L E Connolly & W G McCluggage
Department of Pathology, Royal Group of Hospitals Trust, Belfast, Northern Ireland, UK

Date of submission 25 January 2008
Accepted for publication 28 January 2008

International Journal of Gynecological Pathology
00:1–7, Lippincott Williams & Wilkins, Baltimore
Copyright © 2018 by the International Society of Gynecological Pathologists

Original Article

SATB2 is Consistently Expressed in Squamous Morules Associated With Endometrioid Proliferative Lesions and in the Stroma of Atypical Polypoid Adenomyoma

W. Glenn McCluggage, F.R.C.Path and Koen Van de Vijver, Ph.D.

› Am J Clin Pathol. 2024 Aug 1;162(2):141-150. doi: 10.1093/ajcp/aqae023.

Morules and β-catenin predict POLE mutation status in endometrial cancer: A pathway to more cost-effective diagnostic procedures

Rujia Fan [1], Wanrun Lin [2], Ruijiao Zhao [3], Li Li [4], Rui Xin [5], Yunfeng Zhang [6 7], Yuxin Liu [8], Ying Ma [9], Yiying Wang [1], Yue Wang [1], Wenxin Zheng [10 11 12]

Case 4

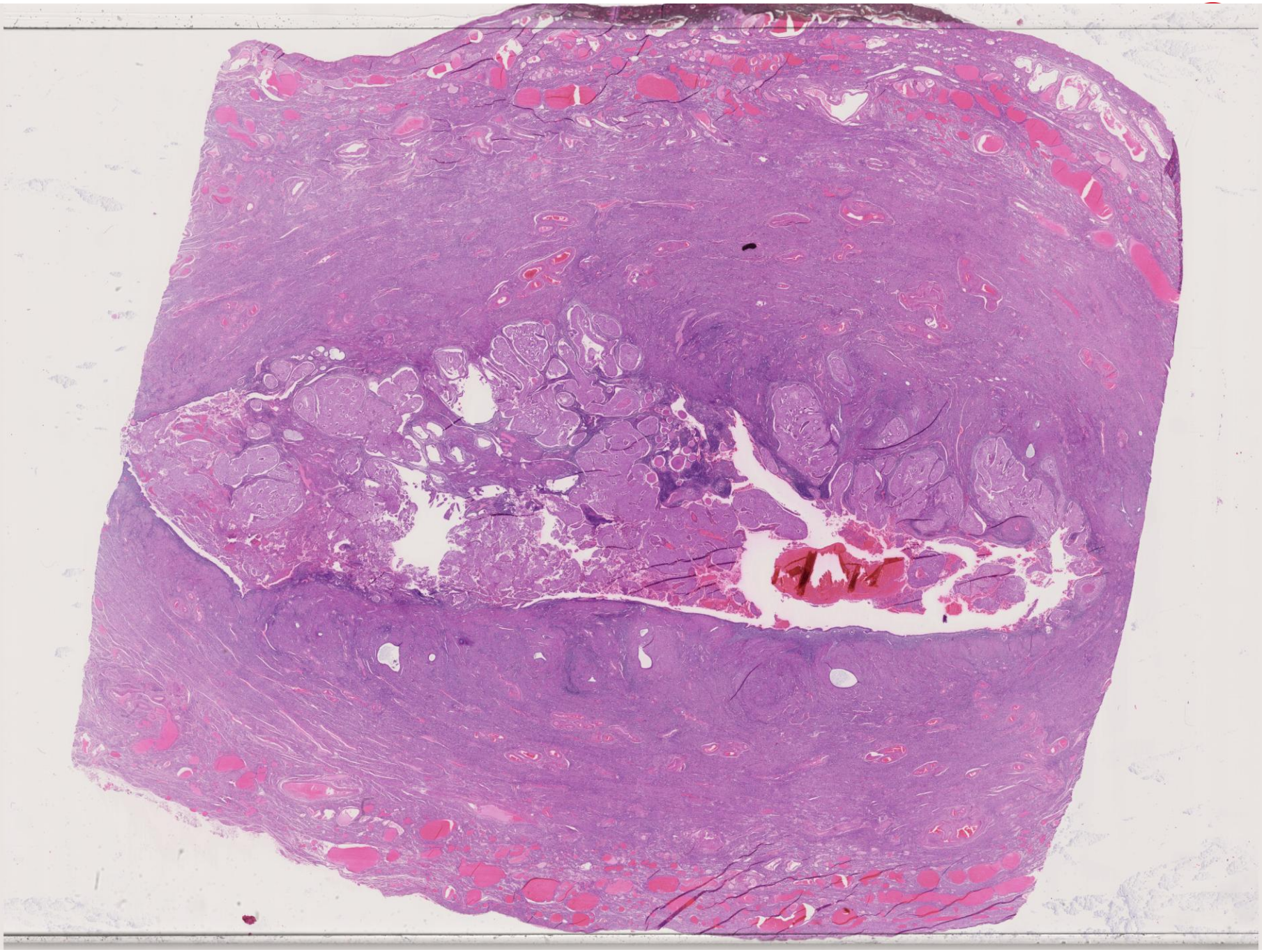

0,74x

2,5 mm

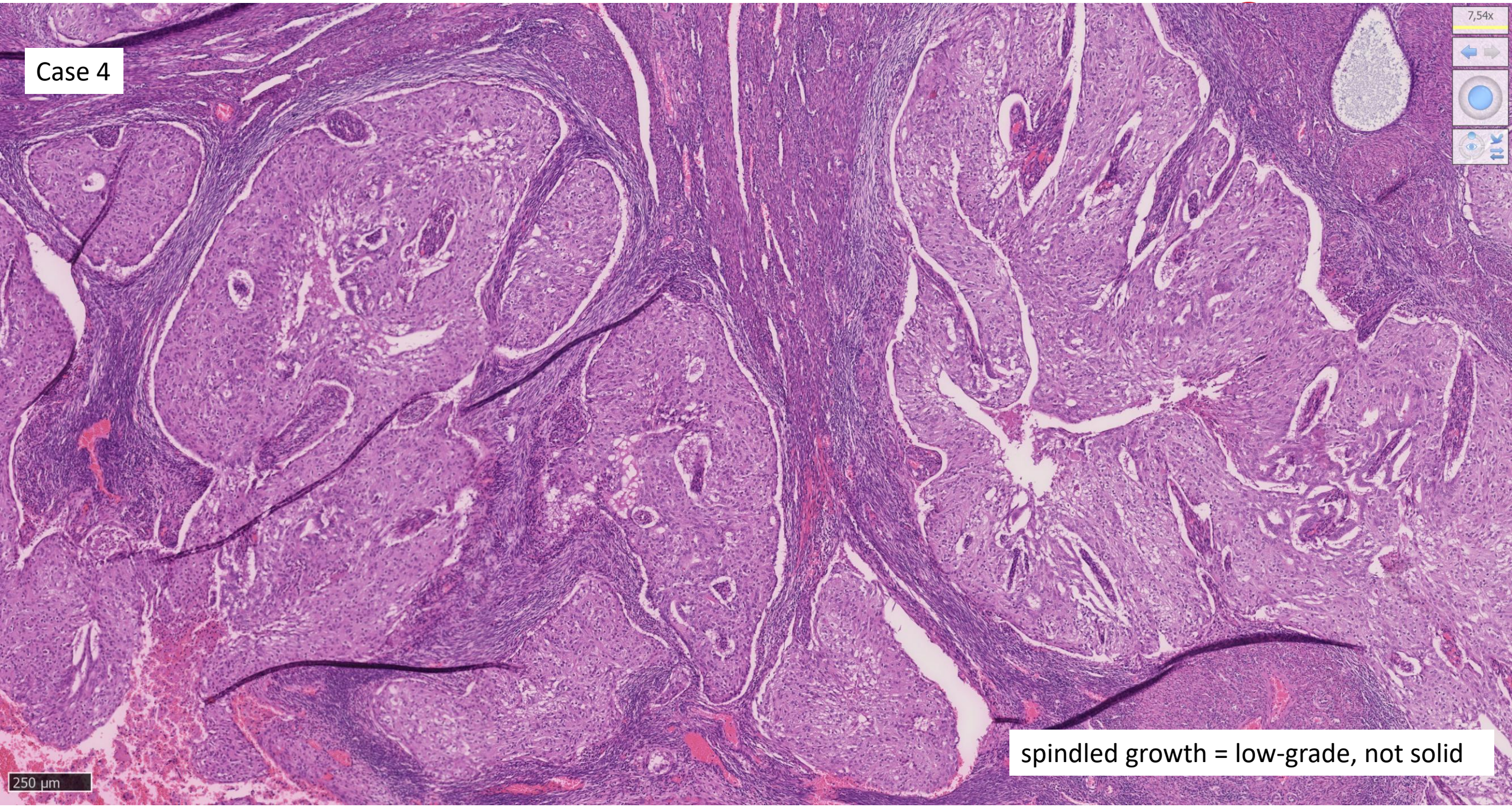
Case 4
7,54x
250 µm
spindled growth = low-grade, not solid

Case 5

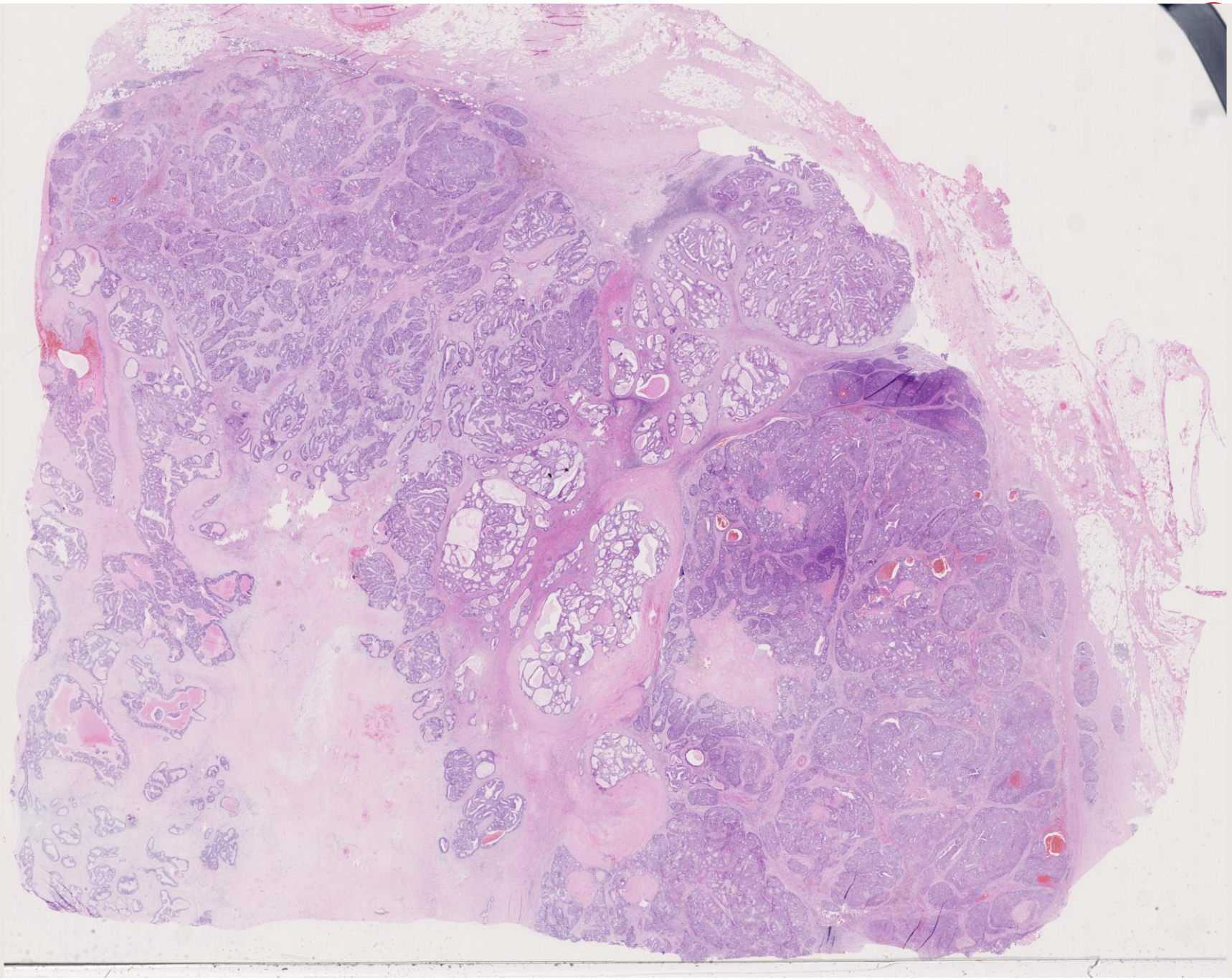

2,5 mm

0,78x

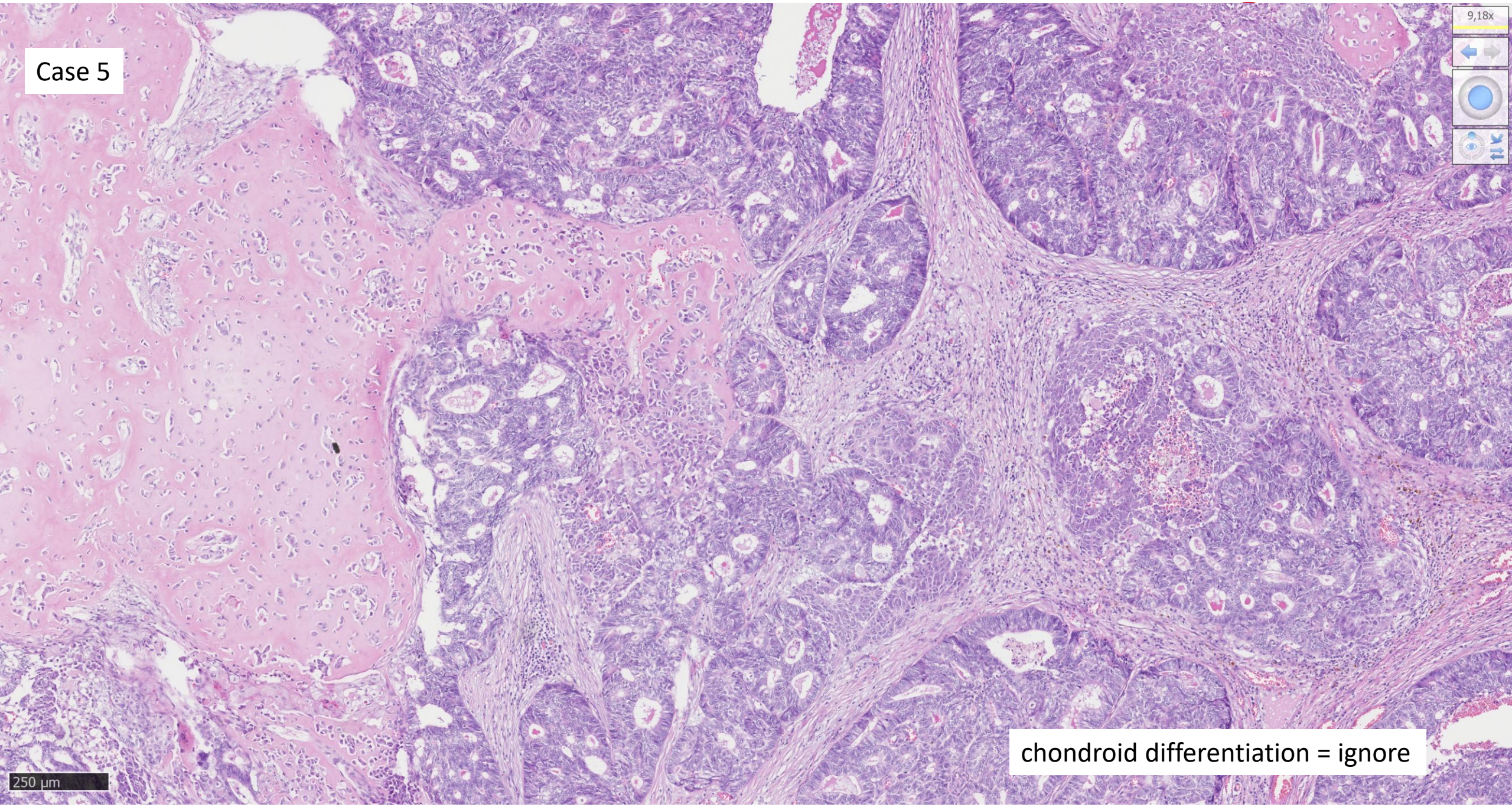
Case 5
9,18x
250 µm
chondroid differentiation = ignore

ORIGINAL ARTICLE

AJSP 2005

Endometrioid Carcinomas of the Uterine Corpus With Sex Cord-like Formations, Hyalinization, and Other Unusual Morphologic Features

A Report of 31 Cases of a Neoplasm That May Be Confused With Carcinosarcoma and Other Uterine Neoplasms

Shawn K. Murray, MD, Philip B. Clement, MD,† and Robert H. Young, MD‡*

ORIGINAL ARTICLE

AJSP 2023

The Evolving Spectrum of Endometrial Glandular Proliferations With Corded and Hyalinized Features

Jennifer Pors, MD,† Julianna J. Weiel, MD,*‡ Emily Ryan, MD,* and Teri A. Longacre, MD**

International Journal of Gynecological Pathology
00:1–13, Lippincott Williams & Wilkins, Baltimore
Copyright © 2020 by the International Society of Gynecological Pathologists

Original Article

Corded and Hyalinized Endometrioid Adenocarcinoma (CHEC) of the Uterine Corpus are Characterized by *CTNNB1* Mutations and Can Show Adverse Clinical Outcomes

Nicholas R. Ladwig, M.D., Sarah E. Umetsu, M.D., Ph.D., Charles Zaloudek, M.D., Joseph Rabban, M.D., M.P.H., and Karuna Garg, M.D.

Seminars in Diagnostic Pathology 39 (2022) 159–175

Contents lists available at ScienceDirect

Seminars in Diagnostic Pathology

journal homepage: www.elsevier.com/locate/semdp

Review article

Low grade endometrial endometrioid adenocarcinoma: A review and update with emphasis on morphologic variants, mimics, immunohistochemical and molecular features

Elena Lucas, M.D., Kelley S. Carrick, M.D. *

1) ECa with mucinous differentiation of conventional (Müllerian) type;
2) ECa with squamous differentiation;
3) ECa with morular metaplasia;
4) ECa with patterns resembling cervical transformation zone tissue and/or microglandular hyperplasia;
5) ECa with cytoplasmic clearing;
6) ECa with papillation, including villoglandular variant of ECa, ECa with small nonvillous papillae, and ECa with a “low-grade serous”-like component or surface changes mimicking ovarian serous borderline tumor;
7) corded and hyalinized variant of ECa;
8) ECa with spindled epithelial cells;
9) ECa with sex cord-like pattern;
10) ECa with other unusual cytologic and associated features

Case 6

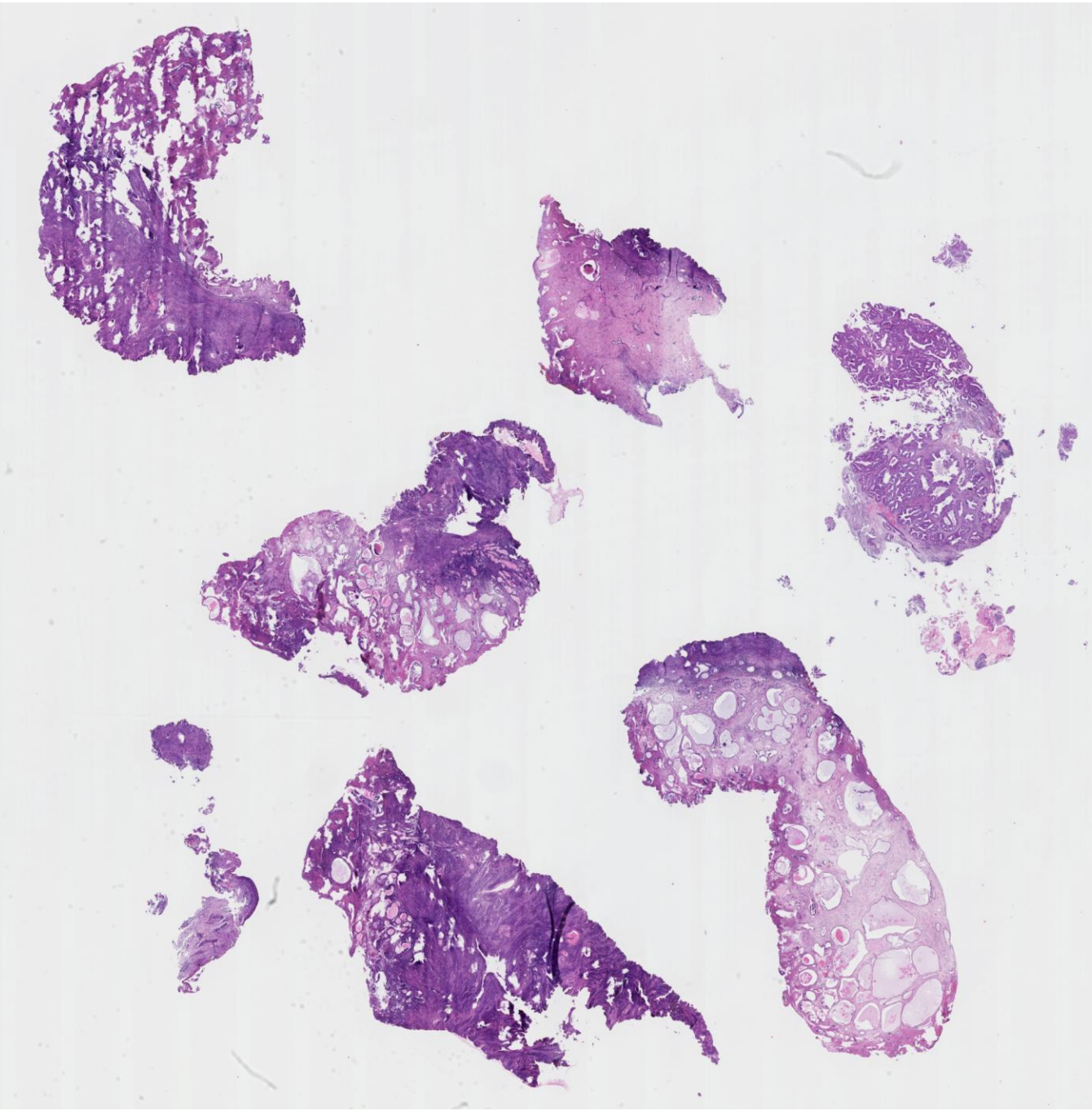

1,08x

2,5 mm

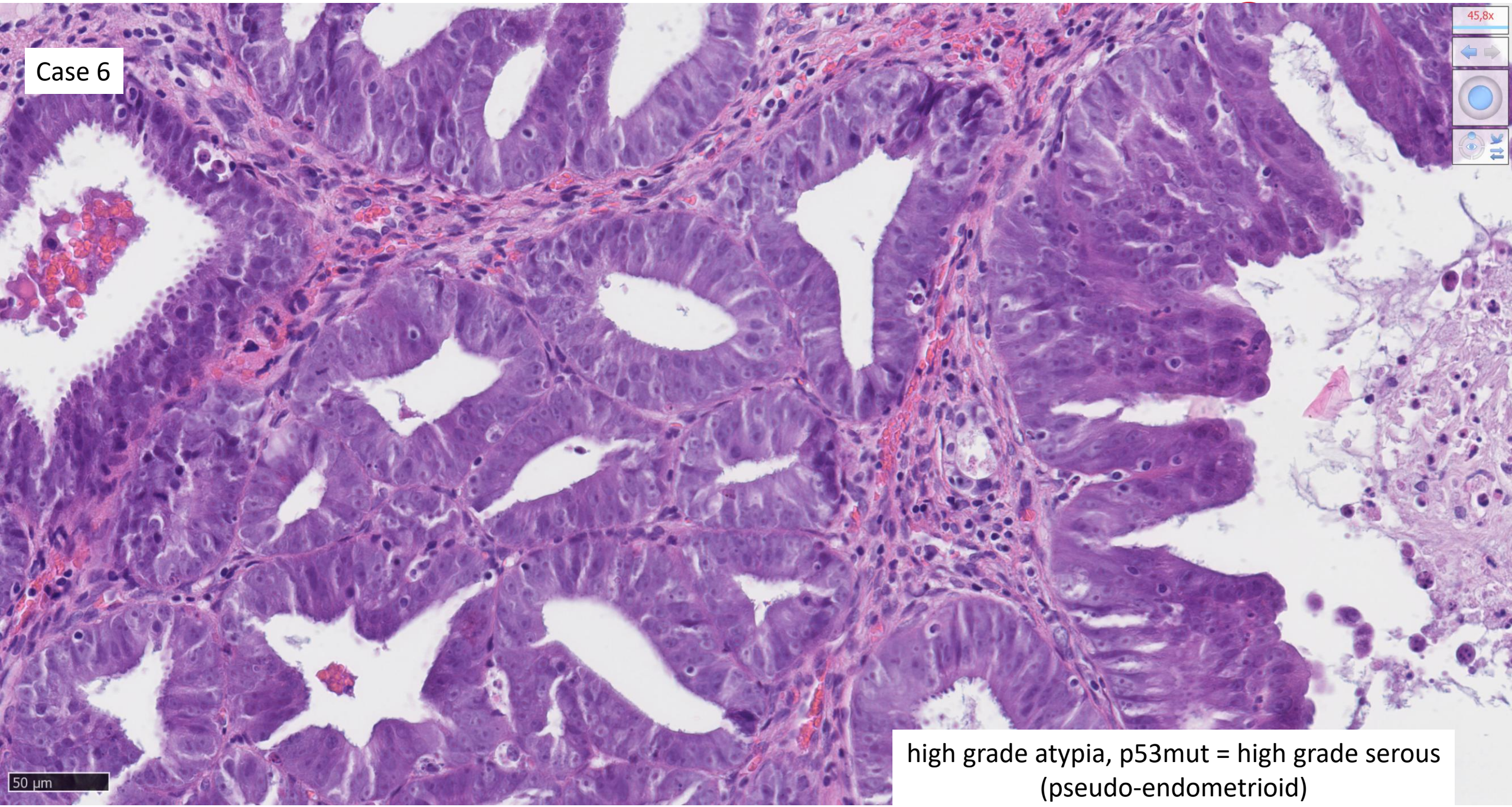

high grade atypia, p53mut = high grade serous (pseudo-endometrioid)

Case 7

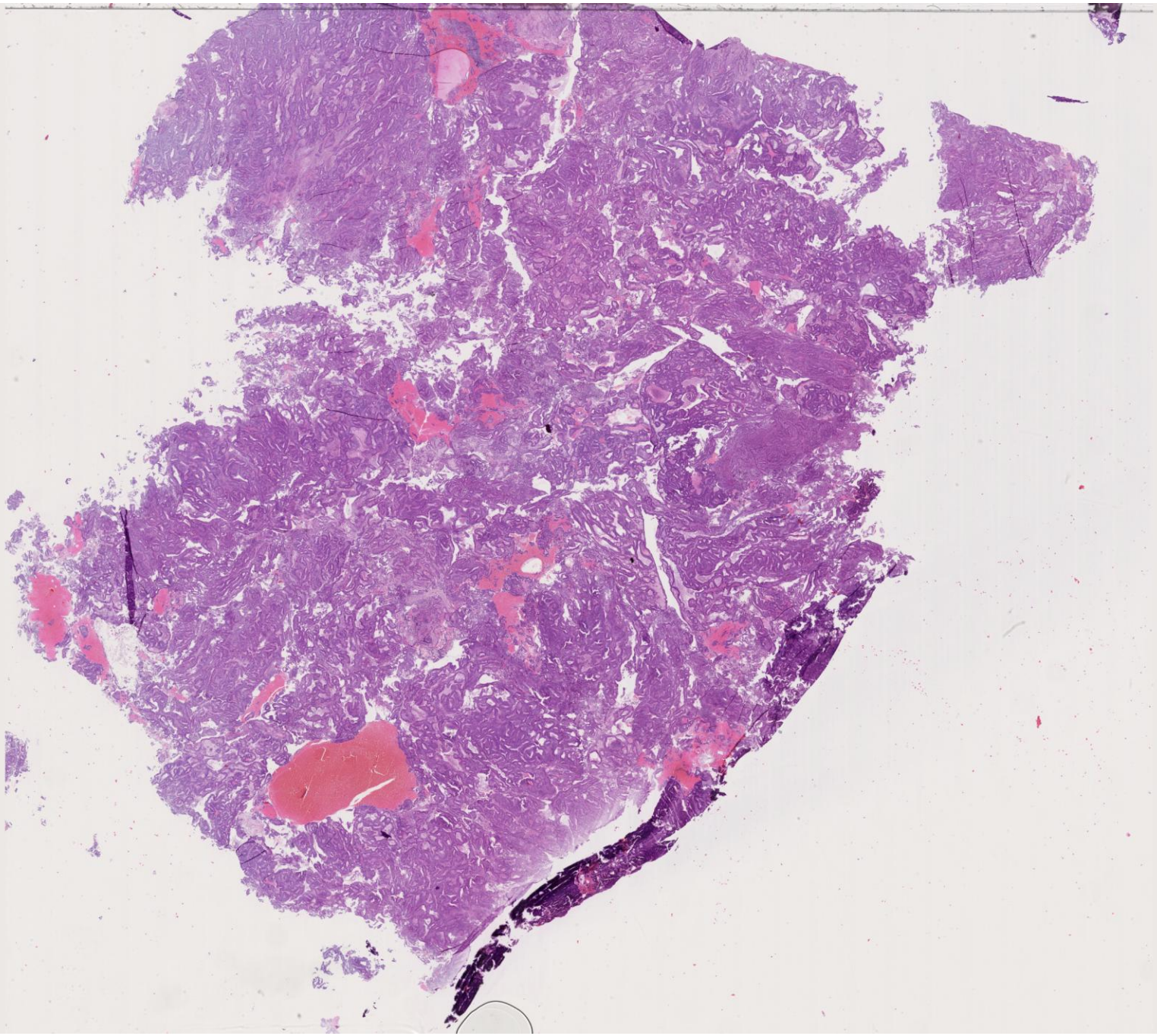

0,79x

2,5 mm

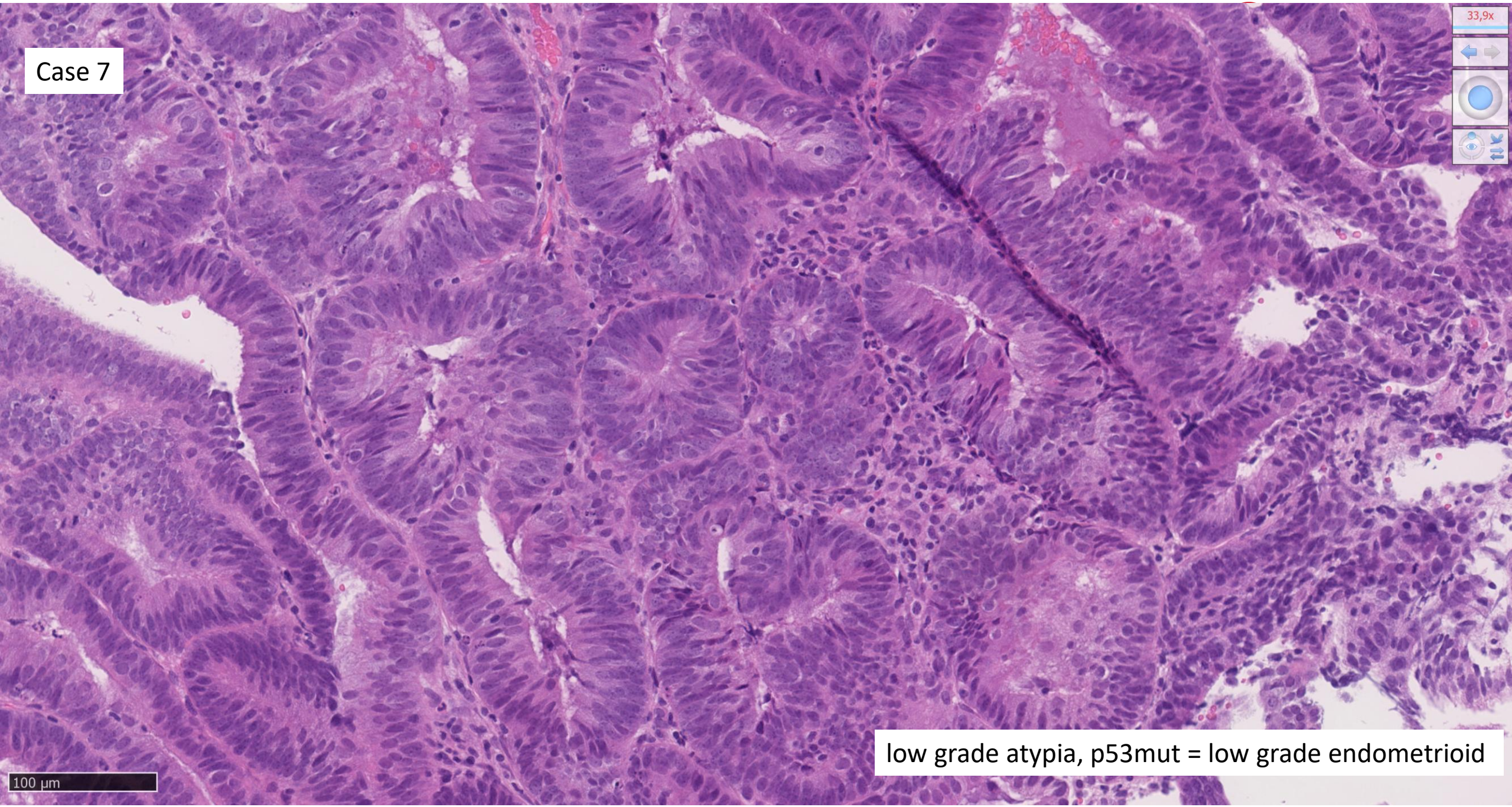
Case 7
33,9x
100 µm
low grade atypia, p53mut = low grade endometrioid

CLINICAL CANCER RESEARCH | TRANSLATIONAL CANCER MECHANISMS AND THERAPY

Clinical Behavior and Molecular Landscape of Stage I p53-Abnormal Low-Grade Endometrioid Endometrial Carcinomas

Amy Jamieson[1], Lisa Vermij[2], Claire J.H. Kramer[2], Jan J. Jobsen[3], Ina Jürgemlienk-Schulz[4], Ludy Lutgens[5], Jan Willem Mens[6], Marie A.D. Haverkort[7], Annerie Slot[8], Remi A. Nout[9], Jan Oosting[2], Joseph Carlson[10], Brooke E. Howitt[11], Philip P.C. Ip[12], Sigurd F. Lax[13], W. Glenn McCluggage[14], Naveena Singh[15], Jessica N. McAlpine[1], Carien L. Creutzberg[9], Nanda Horeweg[9], C. Blake Gilks[15], and Tjalling Bosse[2]

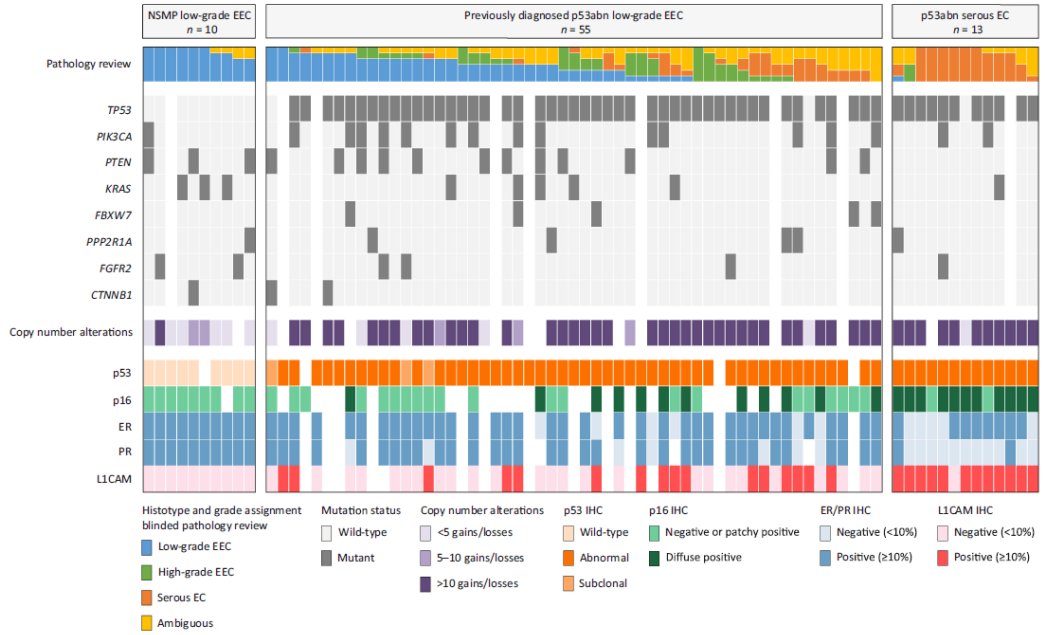

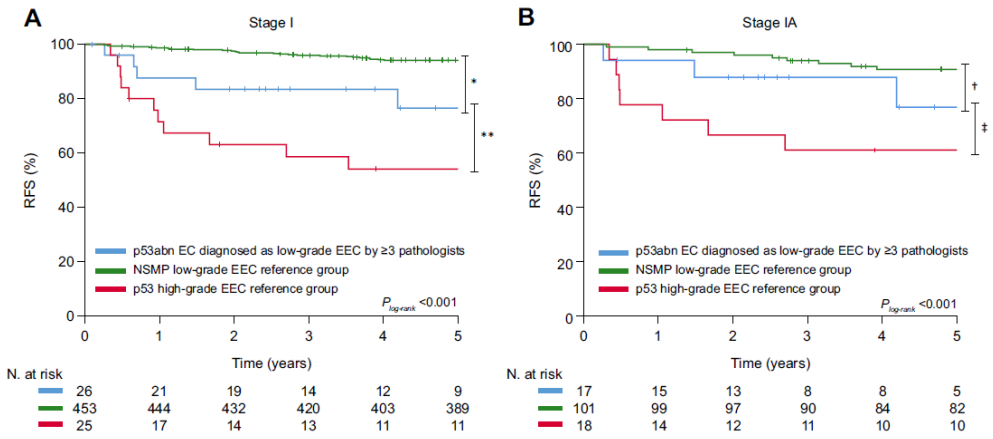

Case 8

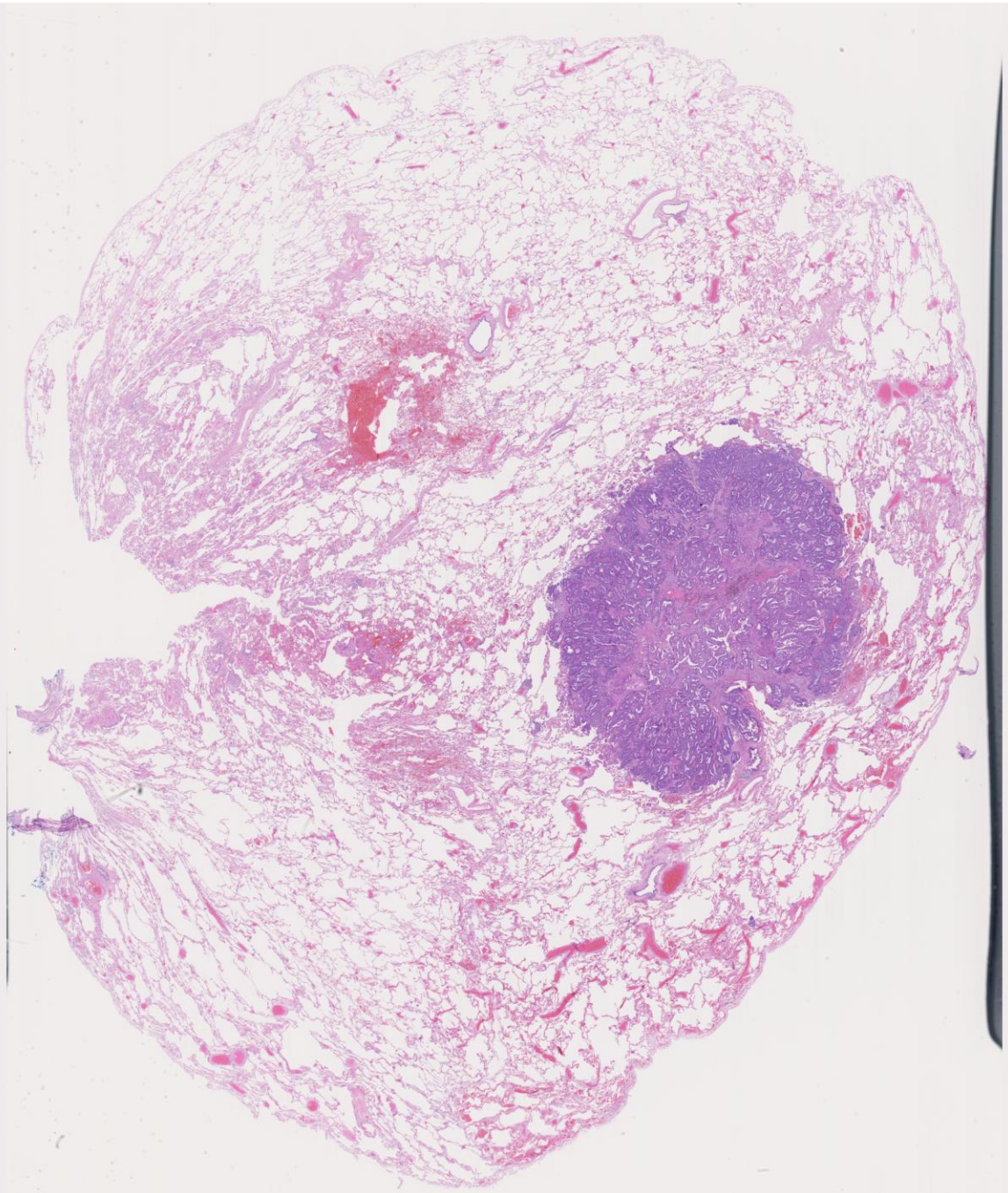

0,81x

2,5 mm

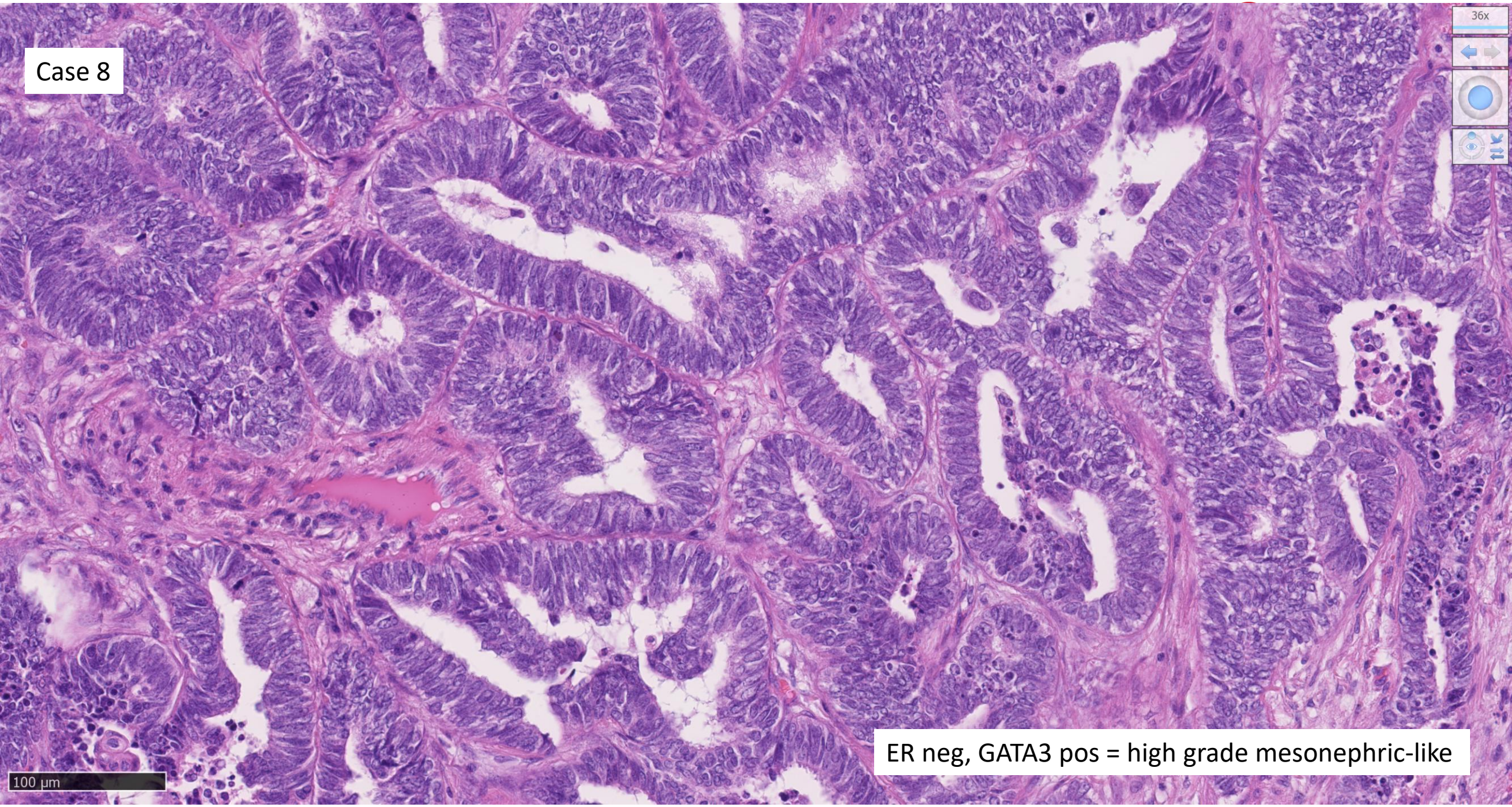
Case 8
36x
100 µm
ER neg, GATA3 pos = high grade mesonephric-like

ORIGINAL ARTICLE

AJSP2020

Clinicopathologic Characteristics of Mesonephric Adenocarcinomas and Mesonephric-like Adenocarcinomas in the Gynecologic Tract

A Multi-institutional Study

Jennifer Pors, MD, Sheila Segura, MD,† Derek S. Chiu, MSc,‡ Noorah Almadani, MD,* Hezhen Ren, MD,* Daniel J. Fix, MD,† Brooke E. Howitt, MD,§ David Kolin, MD,‖ W. Glenn McCluggage, FRCPath,¶ Jelena Mirkovic, MD,# Blake Gilks, MD,*** Kay J. Park, MD,† and Lynn Hoang, MD****

ORIGINAL ARTICLE

AJSP2022

Mesonephric-like Endometrial Carcinoma

Results From Immunohistochemical Screening of 300 Endometrial Carcinomas and Carcinosarcomas for This Often Overlooked and Potentially Aggressive Entity

Anne M. Mills, MD, Taylor M. Jenkins, MD,* Brooke L. Howitt, MD,† Jinbo Fan, PhD, MD,* Kari L. Ring, MD,‡ and Ian Cook, MD‡*

Review

Mesonephric-Like Adenocarcinoma of the Endometrium: Diagnostic Advances to Spot This Wolf in Sheep's Clothing. A Review of the Literature

Ellen Deolet [1], Jo Van Dorpe [1,2] and Koen Van de Vijver [1,2,*]

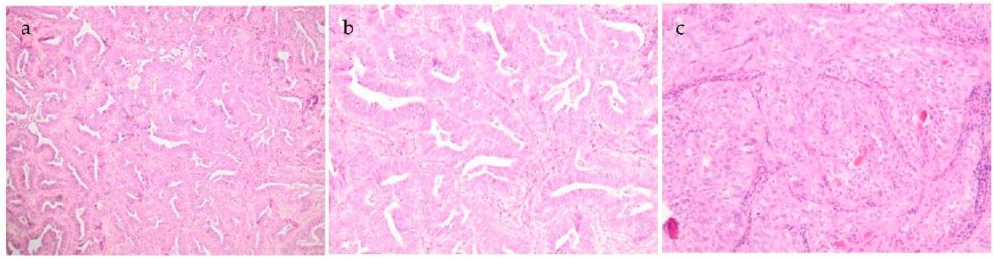

Figure 1. (**a**–**c**). Metastasis to the lung with glandular and ductular to focal solid growth pattern. Several eosinophilic intraluminal secretions are present (**c**). No high-grade atypia and low mitotic figures. (magnification: 40×, 100×, 100×-HE staining).

Case 9

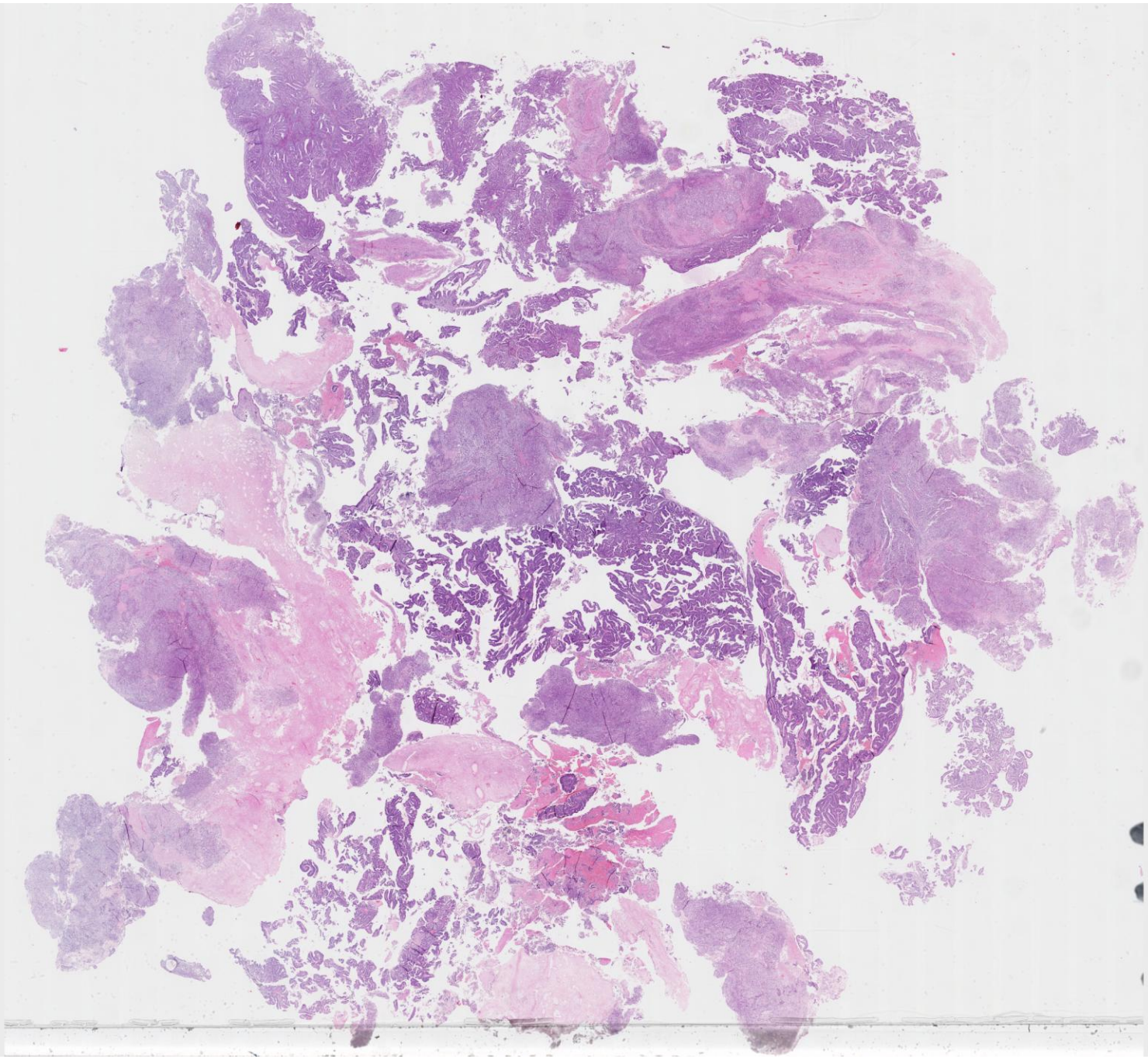

0,76x

2,5 mm

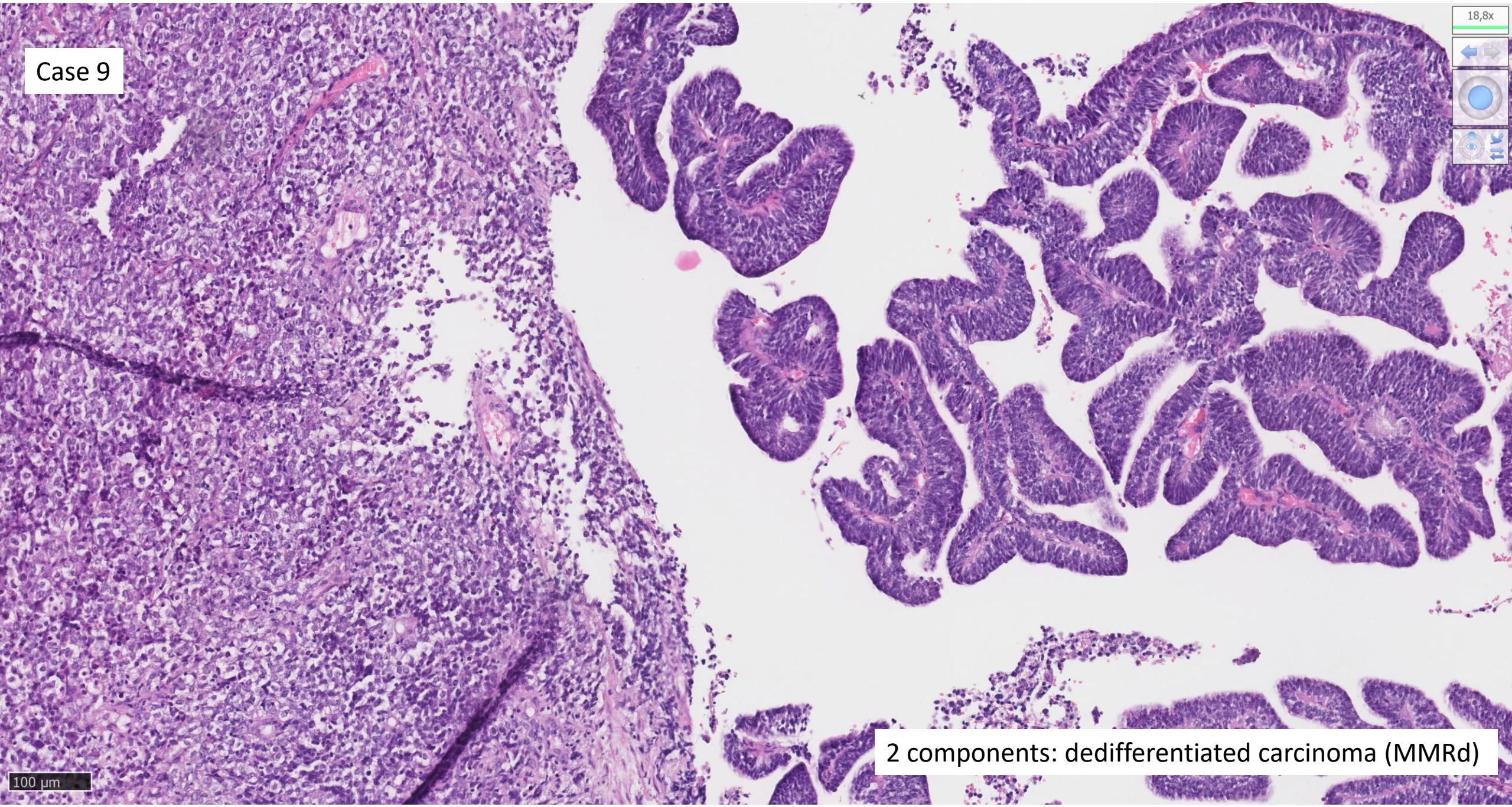
Case 9
18,8x
100 µm
2 components: dedifferentiated carcinoma (MMRd)

Case 10

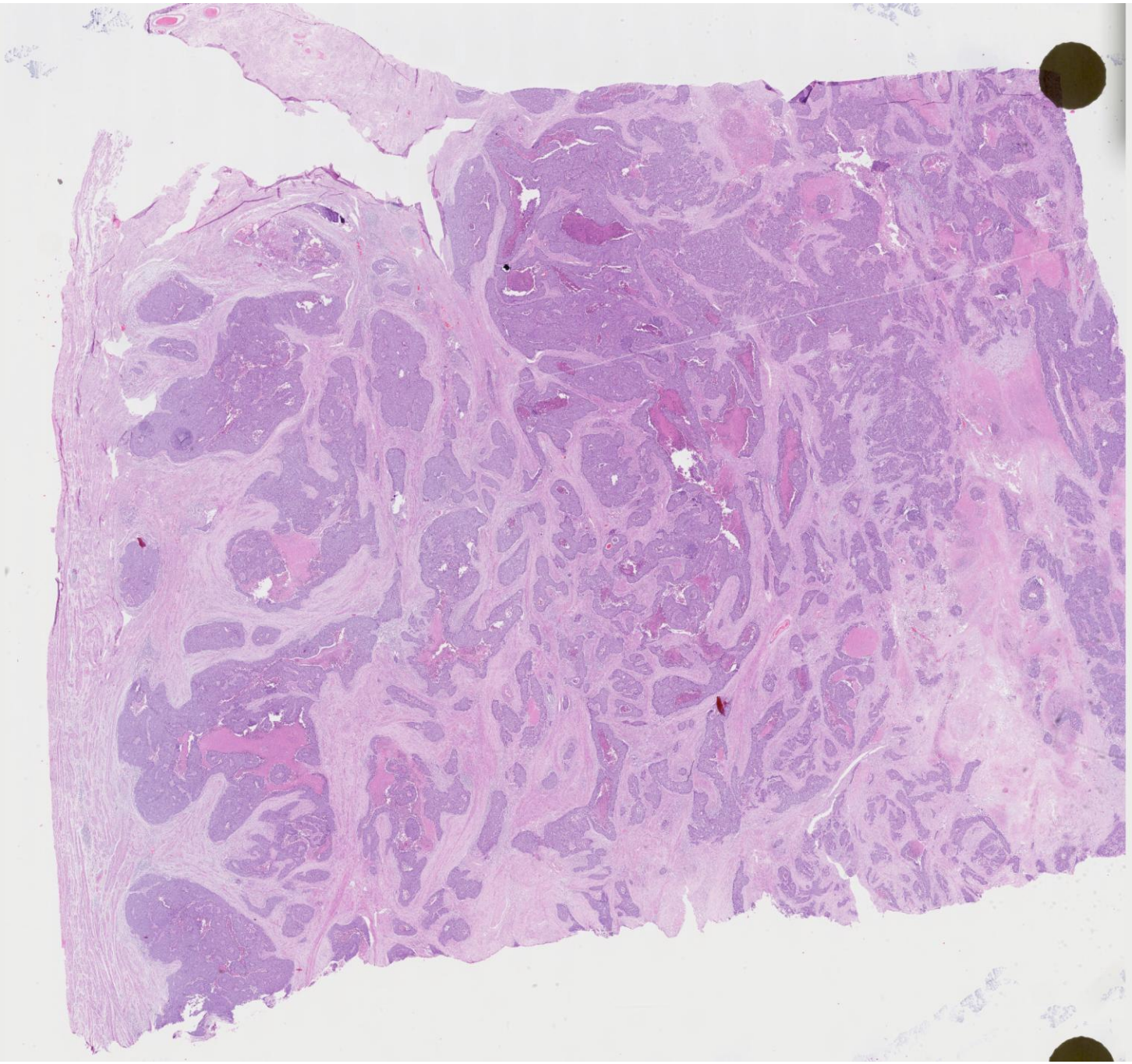

0,9x

2,5 mm

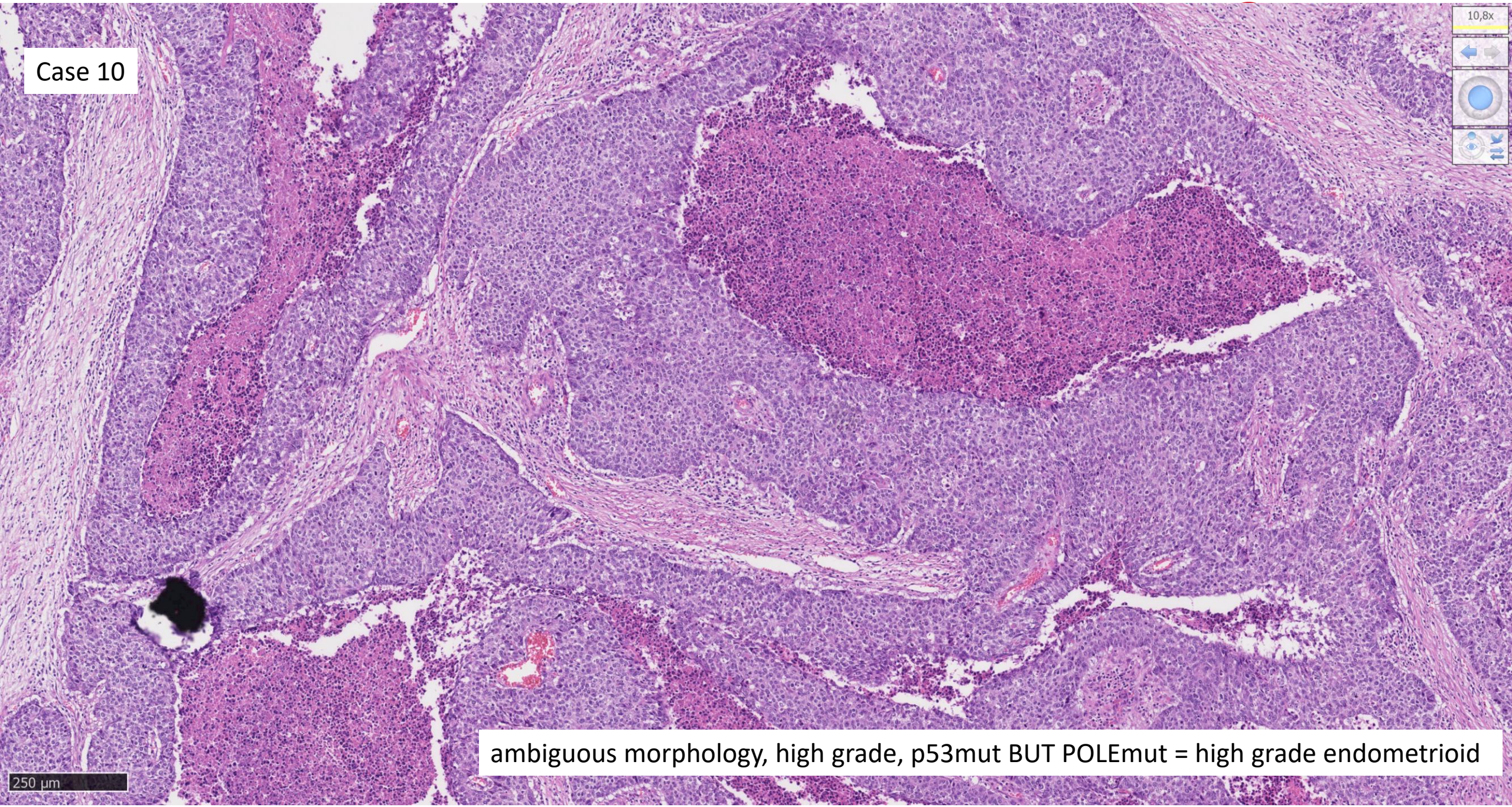
Case 10
10,8x
250 µm
ambiguous morphology, high grade, p53mut BUT POLEmut = high grade endometrioid

Molecular Classification Outperforms Histologic Classification in Prognostication of High-grade Endometrial Carcinomas With Undifferentiated and Sarcomatous Components

Phoebe M. Hammer, MD, Aihui Wang, ScM,* Lisa Vermij, PhD,† Sabrina Zdravkovic, BS,* Lucas Heilbroner, BA,* Emily Ryan, MD,* Rachel L.P. Geisick, MLS (ASCP),* Vivek Charu, MD, PhD,* Teri A. Longacre, MD,* Carlos J. Suarez, MD,* Chandler Ho, MLS (ASCP), MB,* Taylor M. Jenkins, MD,‡ Anne M. Mills, MD,§ Tjalling Bosse, MD, PhD,† and Brooke E. Howitt, MD**

(*Am J Surg Pathol* 2024;48:953–964)

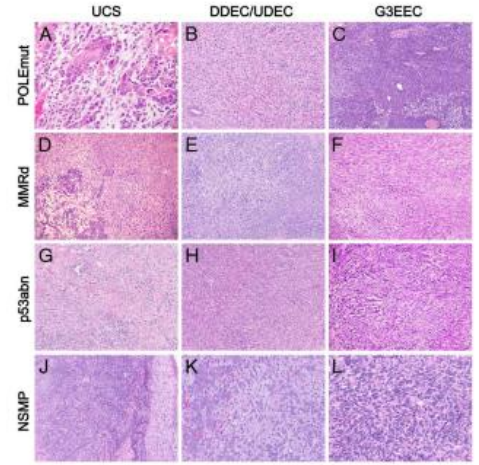

FIGURE 2. Uterine carcinosarcoma (UCS), dedifferentiated/undifferentiated carcinoma (DDEC/UDEC), and grade 3 endometrioid endometrial carcinoma (GR3spEEC) may all show spindled morphology and morphologic overlap. In our cohort, all molecular subtypes were represented in each histotype: (A–C) *POLE*-mutated (*POLE*mut), (D–F) mismatch repair deficient (MMRd), (G–I) p53 abnormal (p53abn), (J–L) and no specific molecular profile (NSMP).

