UPDATE ON CERVICAL PATHOLOGY: INCORPORATING WHO 2020

W Glenn McCluggage
Belfast
United Kingdom

TO DISCUSS

- Changes to WHO 2020 5TH EDITION
- Comments on WHO 2014
- Classification of cervical squamous carcinomas and premalignant and malignant glandular lesions in detail

CHANGES TO WHO 2020

- Cervical squamous cell carcinomas and adenocarcinomas- **HPV-associated, HPV-independent**
- Precursors of cervical adenocarcinomas- **HPV-associated, HPV-independent adenocarcinoma in situ (AIS)**
- Category of adenofibroma dropped (also from uterine corpus)
- Neuroendocrine neoplasms now included in stand-alone chapter

CERVICAL SQUAMOUS CELL CARCINOMAS- WHO 2014 and 2020

- WHO 2014- keratinising, non-keratinising, basaloid, warty, papillary, verrucous, squamotransitional, lymphoepithelioma-like TYPES- meaningless, not true tumour types, poorly reproducible, lack of prognostic significance, most pathologists did not use
- WHO 2020- HPV-associated, HPV-independent, HPV-NOS; morphological patterns above, not types, mentioned in text
- ICCR cervical cancer update will recommend to NOT grade cervical squamous cell carcinoma

Comparison of 2014 and 2020 WHO Classifications of Squamous Cell Carcinoma of the Cervix

2014 WHO Classification: Histologic types	2020 WHO Classification: Histologic types
Squamous cell carcinoma usual type Keratinizing type Non-keratinizing type Papillary type Basaloid type Warty type Verrrucous type Squamotransitional type Lymphoepithelioma-like	• Squamous cell carcinoma, HPV-associated • Squamous cell carcinoma, HPV-independent • Squamous cell carcinoma, NOS

HPV STATUS OF CERVICAL SQUAMOUS CELL CARCINOMAS

- WHO 2020- HPV-associated, HPV-independent, HPV, NOS
- No HPV-independent precursor lesion recognised
- Almost all cervical SCC are HPV-associated
- Same classification as other organs (vulva, vagina, head and necl)
- Unlike other organs, no established prognostic significance
- Can’t reliably morphologically distinguish between HPV-associated and HPV-independent

VULVA- HPV-INDEPENDENT SCC

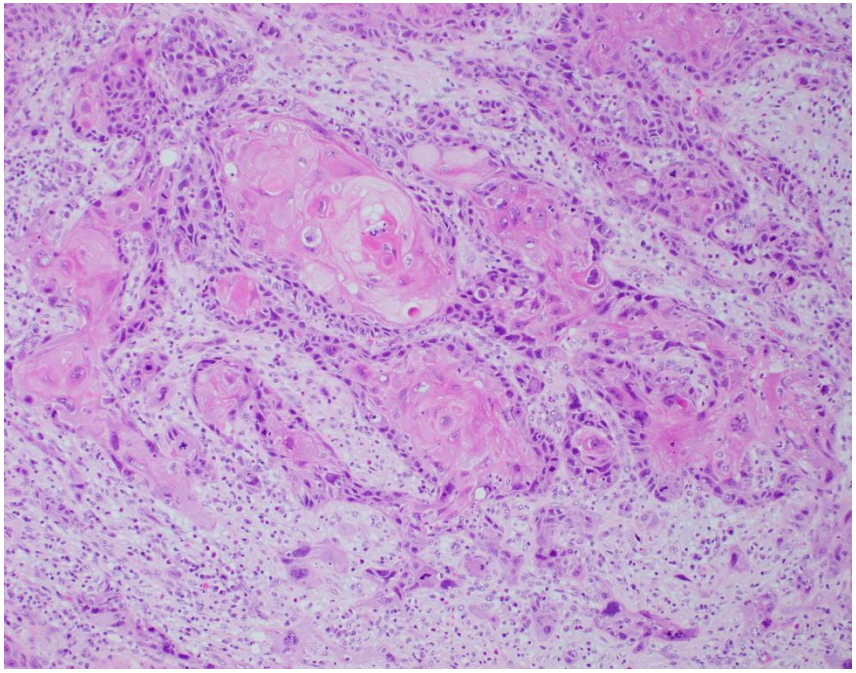

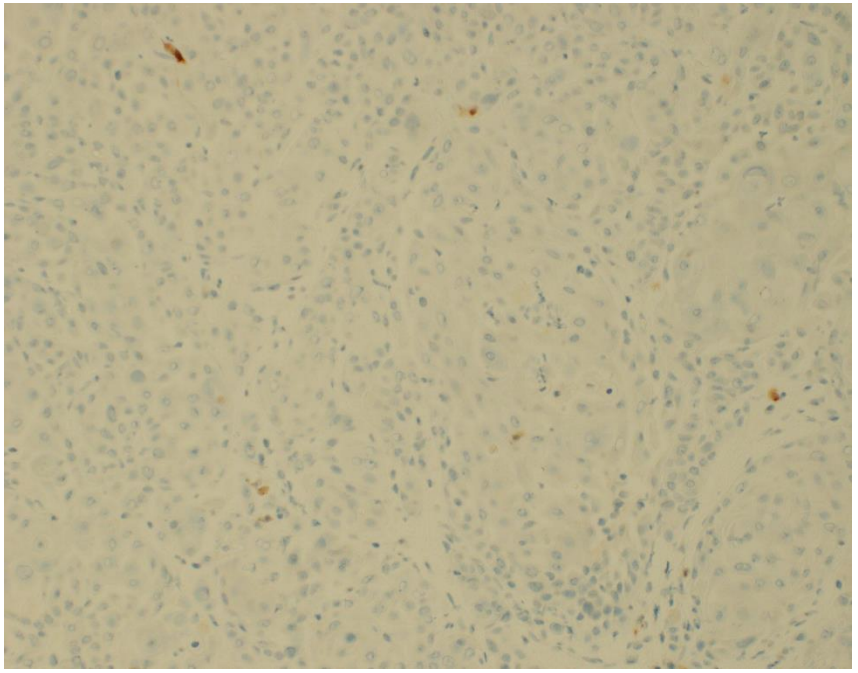

p16

VULVA- HPV-ASSOCIATED SCC

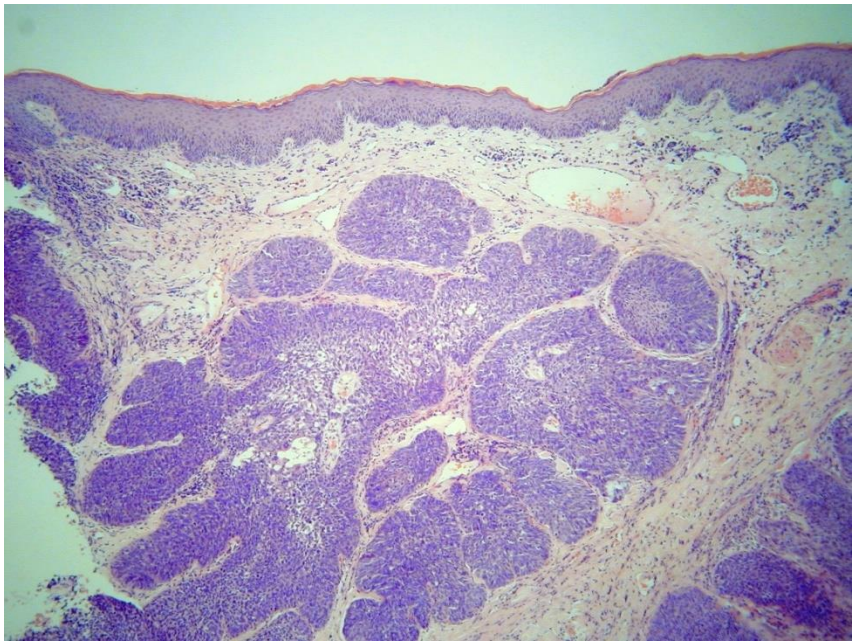

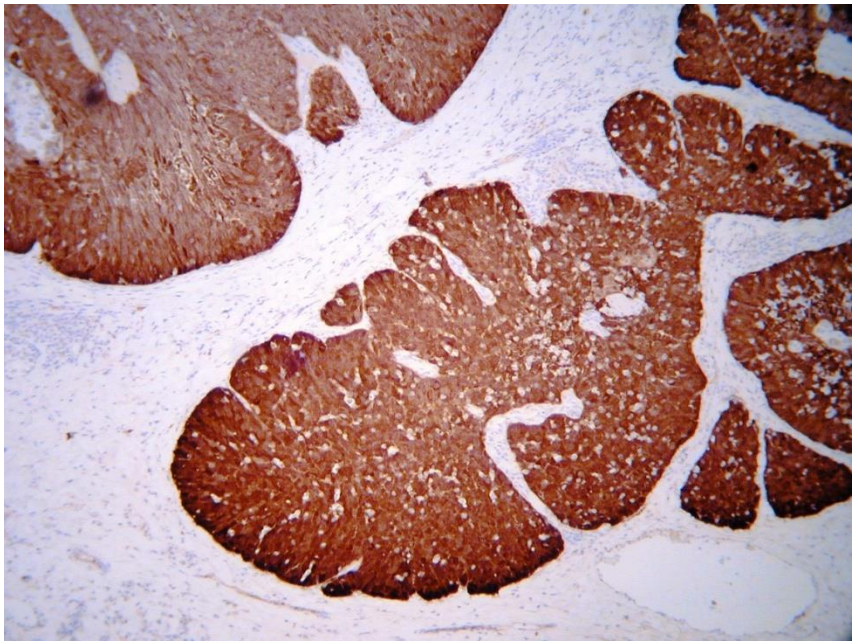

p16

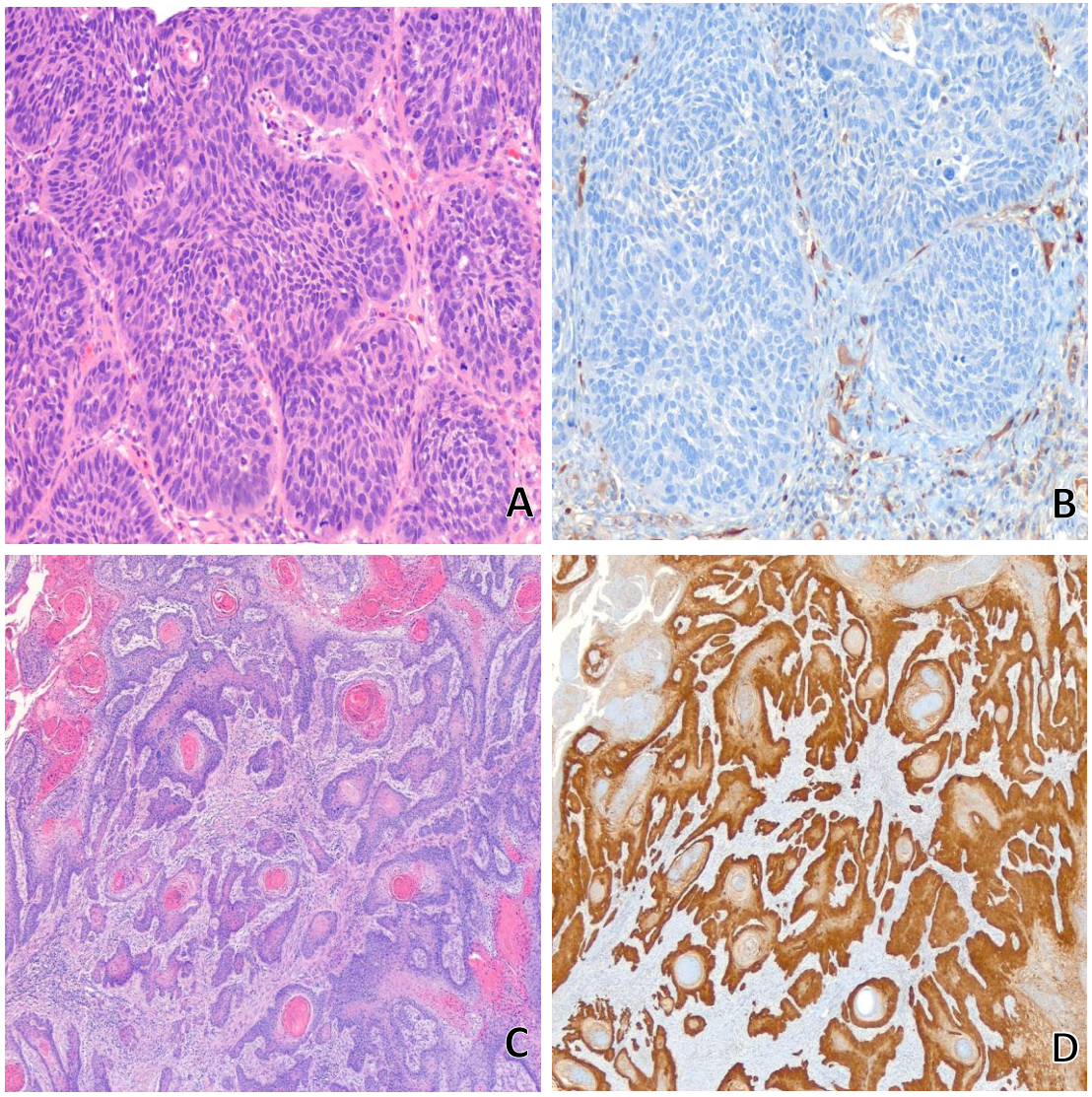

VULVAL SCC- CASES WHERE MORPHOLOGY AND p16 YIELD DISCREPANT RESULTS.

Modern Pathology
https://doi.org/10.1038/s41379-019-0249-1

ARTICLE

HPV-negative tumors of the uterine cervix

Inmaculada Nicolás[1,2] · Lorena Marimon[2,3] · Esther Barnadas[2,3] · Adela Saco[3] · Leonardo Rodríguez-Carunchio[3] · Pere Fusté[1] · Cristina Martí[1] · Adriano Rodriguez-Trujillo[1] · Aureli Torne[1] · Marta del Pino[1] · Jaume Ordi[2,3]

Received: 19 September 2018 / Revised: 21 December 2018 / Accepted: 22 December 2018
© United States & Canadian Academy of Pathology 2019

PMID 30911077

- 214 cervical carcinomas (p16 and sensitive HPV PCR testing (SPF10))
- 21 of 214 (10%) HPV-negative
- 12 of 168 (7%) squamous cell carcinomas HPV-negative; 10 of 12 were non-keratinising (no differences in morphology between HPV-associated and HPV-independent SCC)
- HPV-negative SCC more frequently diagnosed with clinical symptoms and advanced stage and had worse disease-free and overall survival on univariate (but not multivariate) analysis
- Point made that older studies not reliable- problems with older blocks (p16 staining and molecular testing), misclassification and techniques not sensitive enough

International Journal of Gynecological Pathology
34:208–212, Lippincott Williams & Wilkins, Baltimore
© 2015 International Society of Gynecological Pathologists

Case Report

A Rare Case of HPV-Negative Cervical Squamous Cell Carcinoma

Shauna Casey, F.R.C.Path., Ian Harley, F.R.C.O.G., Jackie Jamison, F.I.B.M.S., Anco Molijn, M.Sc., Henk van den Munckhof, B.Sc., and W. Glenn McCluggage, F.R.C.Path.

HPV-INDEPENDENT CERVICAL SCC

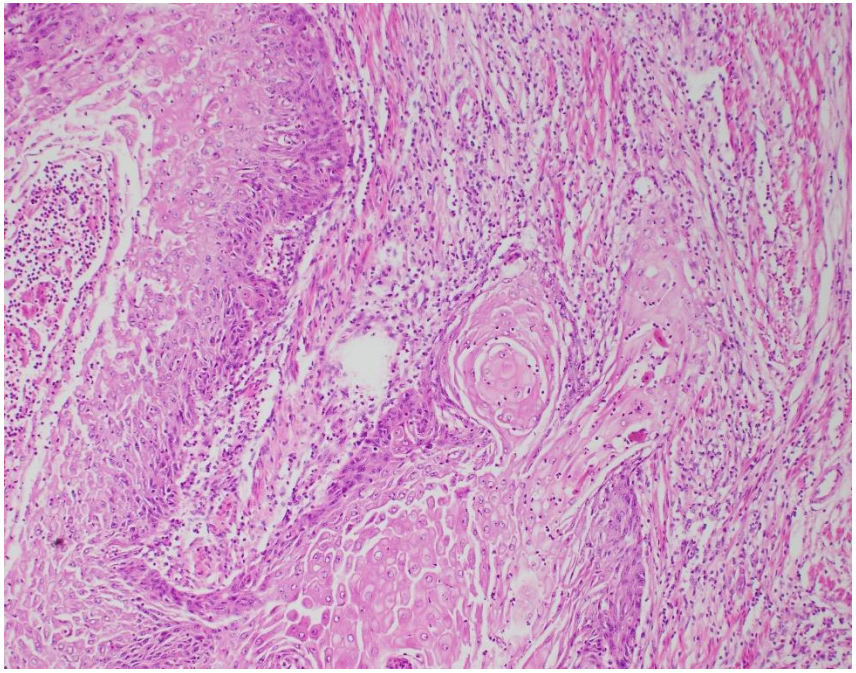

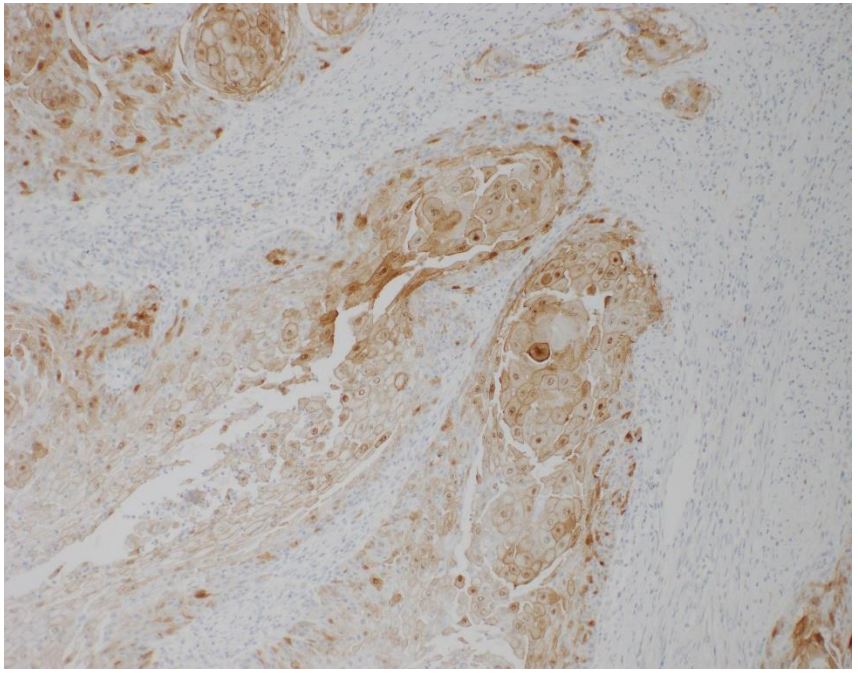

p16

HPV STATUS OF CERVICAL SQUAMOUS CELL CARCINOMAS

- Controversial as to whether need to do p16 and/ or HPV testing in all cervical squamous carcinomas since almost all are HPV-associated
- Options:- **do p16 in all and HPV-testing if p16 is non block-type**; just call all HPV-associated; just call all HPV, NOS; only undertake p16 and/ or HPV testing if morphology suggests an HPV-independent neoplasm
- ? Is adjacent CIN III, enough evidence to call HPV-associated
- WHO 2020- NOS when p16 or HPV molecular studies not possible (poorly resourced areas)

METHODS FOR DETECTING HPV

- Neither p16 nor molecular methods 100% reliable (but p16 is a good surrogate marker in the correct context)
- Can get loss of p16 in HPV-associated neoplasms secondary to methylation
- Currently best recommended molecular method for HPV is HPV RNA in situ hybridisation (HPV RISH)

p16 IN CERVICAL SCC

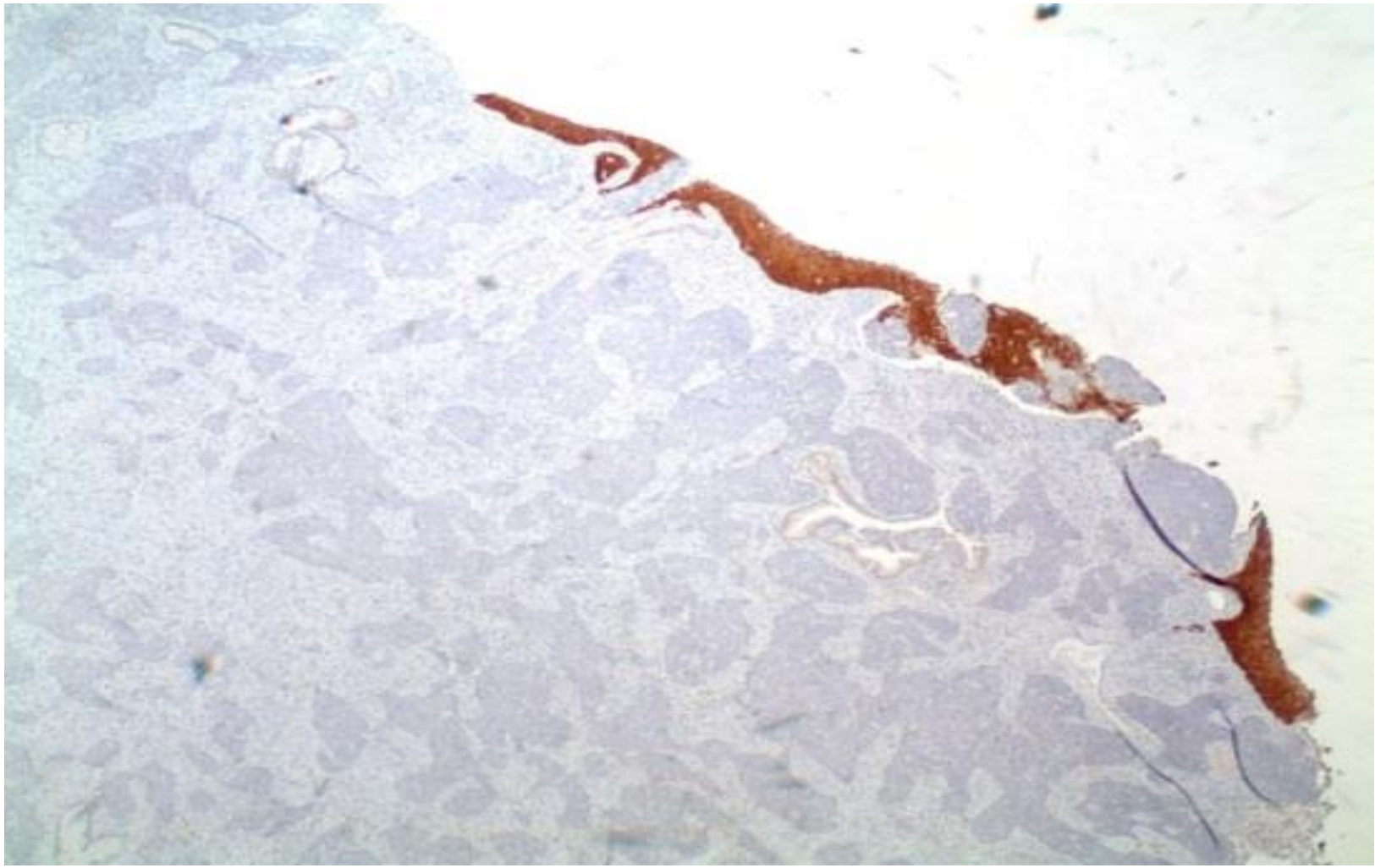

p16 IN CASE OF HPV-ASSOCIATED AIS

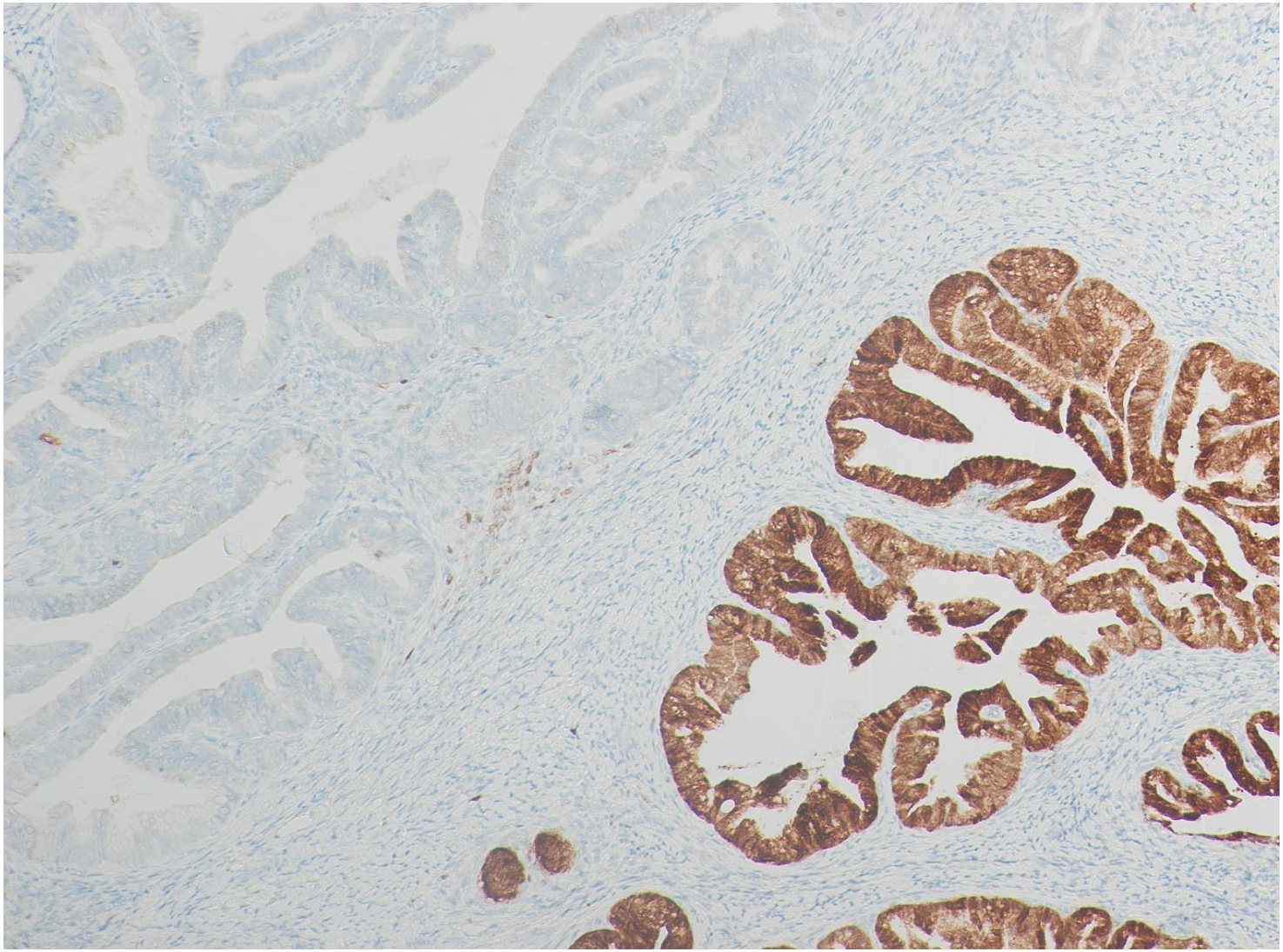

2020 WHO: New Classification of Glandular Precursor Lesions

HPV-associated AIS	**HPV-independent AIS**
AIS (usual type) SMILE (morphological variant) Acceptable: *"High-grade cervical glandular intraepithelial neoplasia" / HCGIN*	Gastric-type AIS Atypical LEGH

ADVANCES IN ANATOMIC PATHOLOGY
2020;27;278-293; PMID 32482967

REVIEW ARTICLE

The Evolving Spectrum of Precursor Lesions of Cervical Adenocarcinomas

Simona Stolnicu, MD, Karen L. Talia, FRCPA,† and W. Glenn McCluggage, FRCPath‡*

HPV-ASSOCIATED AIS

- Much more common than HPV-independent AIS
- Characterised by apical mitoses and basal apoptotic bodies
- Should do p16

HPV-INDEPENDENT AIS

- Gastric type AIS and atypical lobular endocervical glandular hyperplasia; precursors of gastric-type adenocarcinoma
- No known premalignant precursor lesions of clear cell and mesonephric adenocarcinomas

HPV-ASSOCIATED AIS

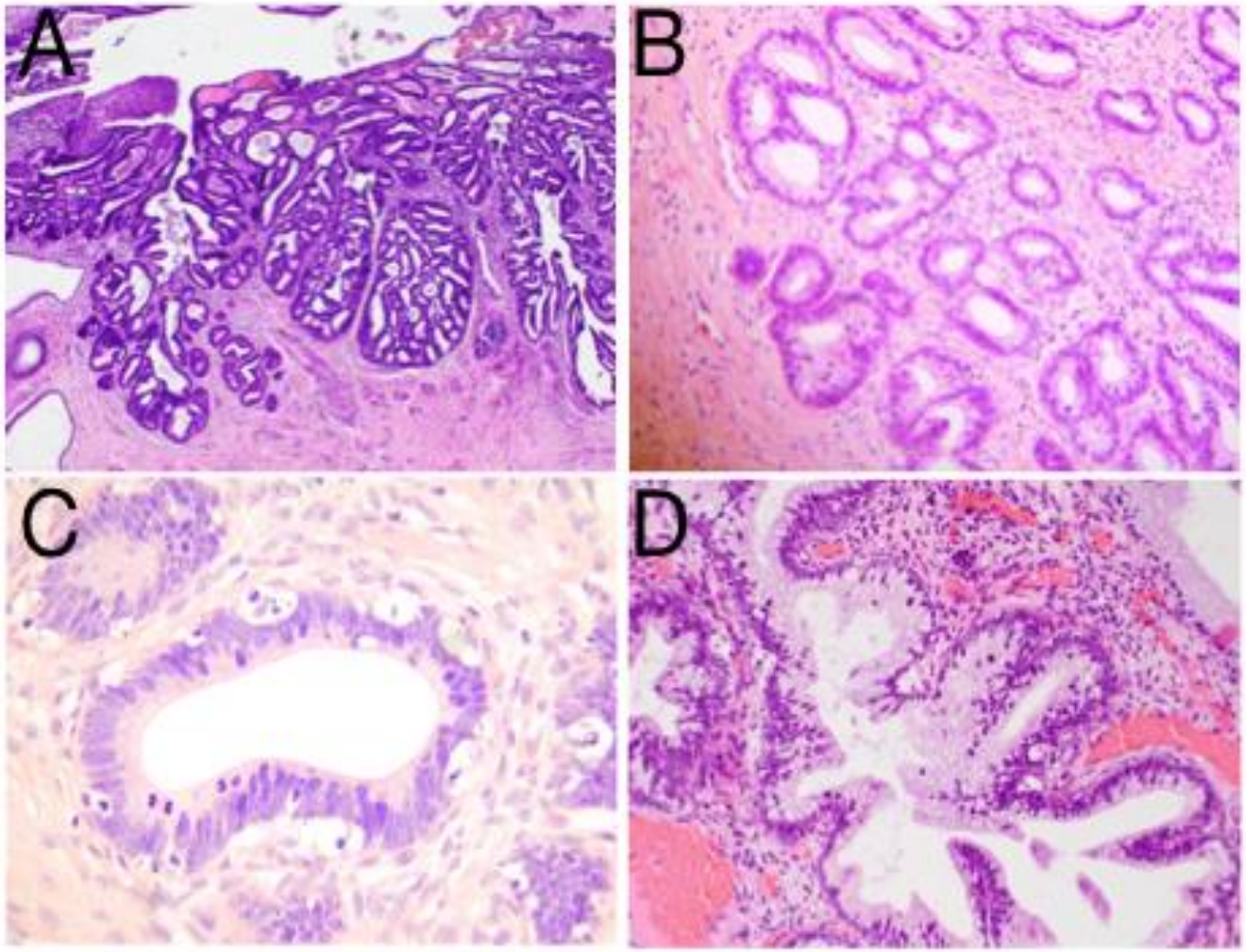

HPV-ASSOCIATED AIS WITH INTESTINAL DIFFERENTIATION

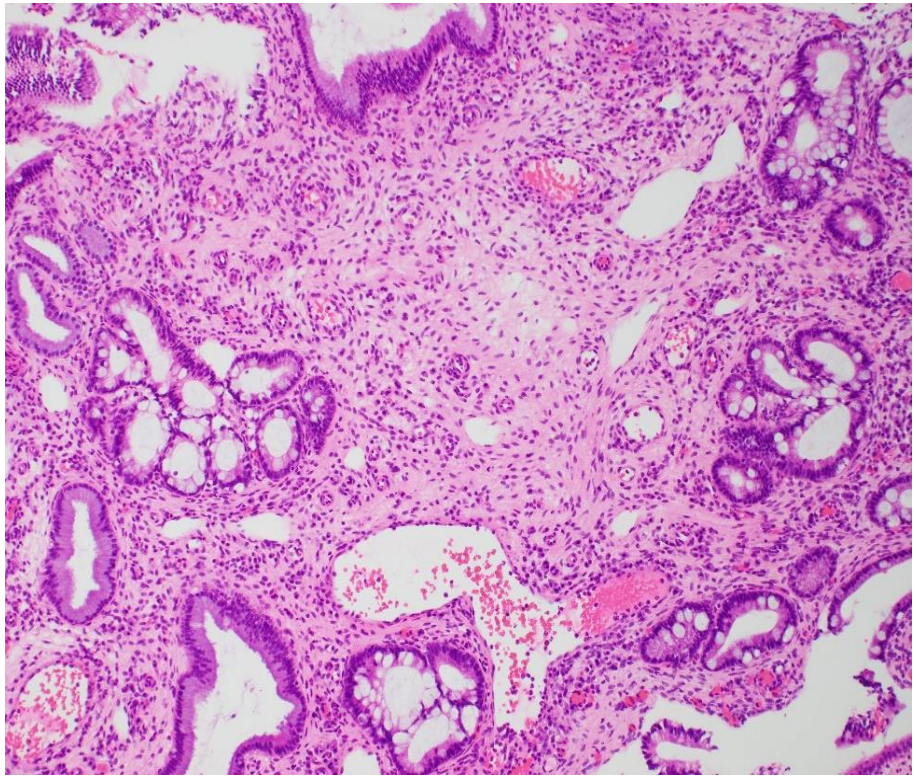

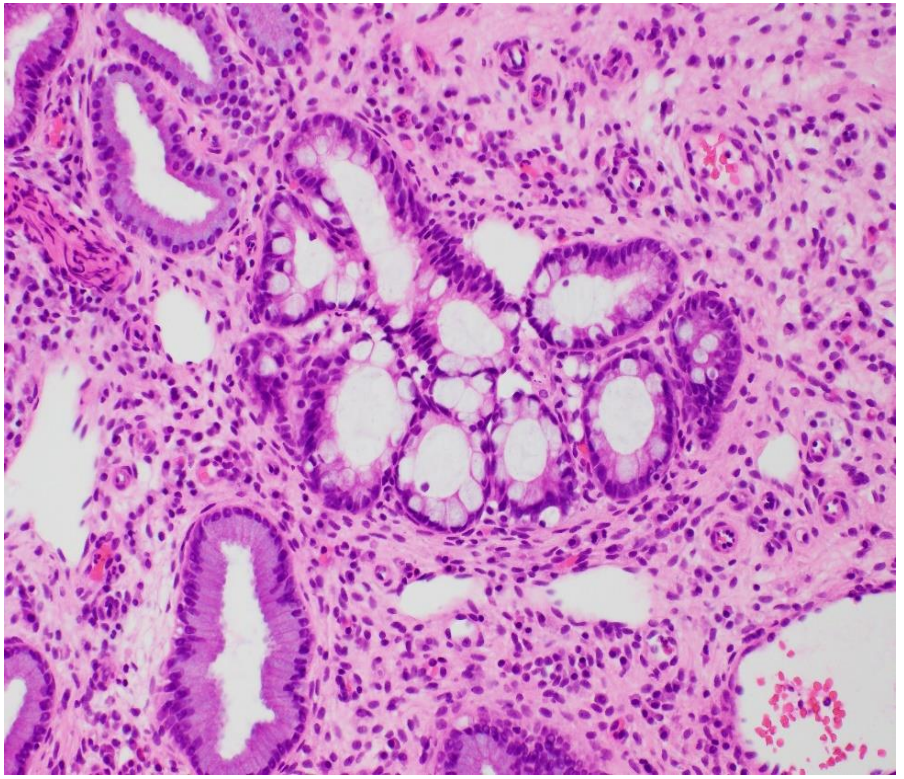

HPV-ASSOCIATED AIS- p16

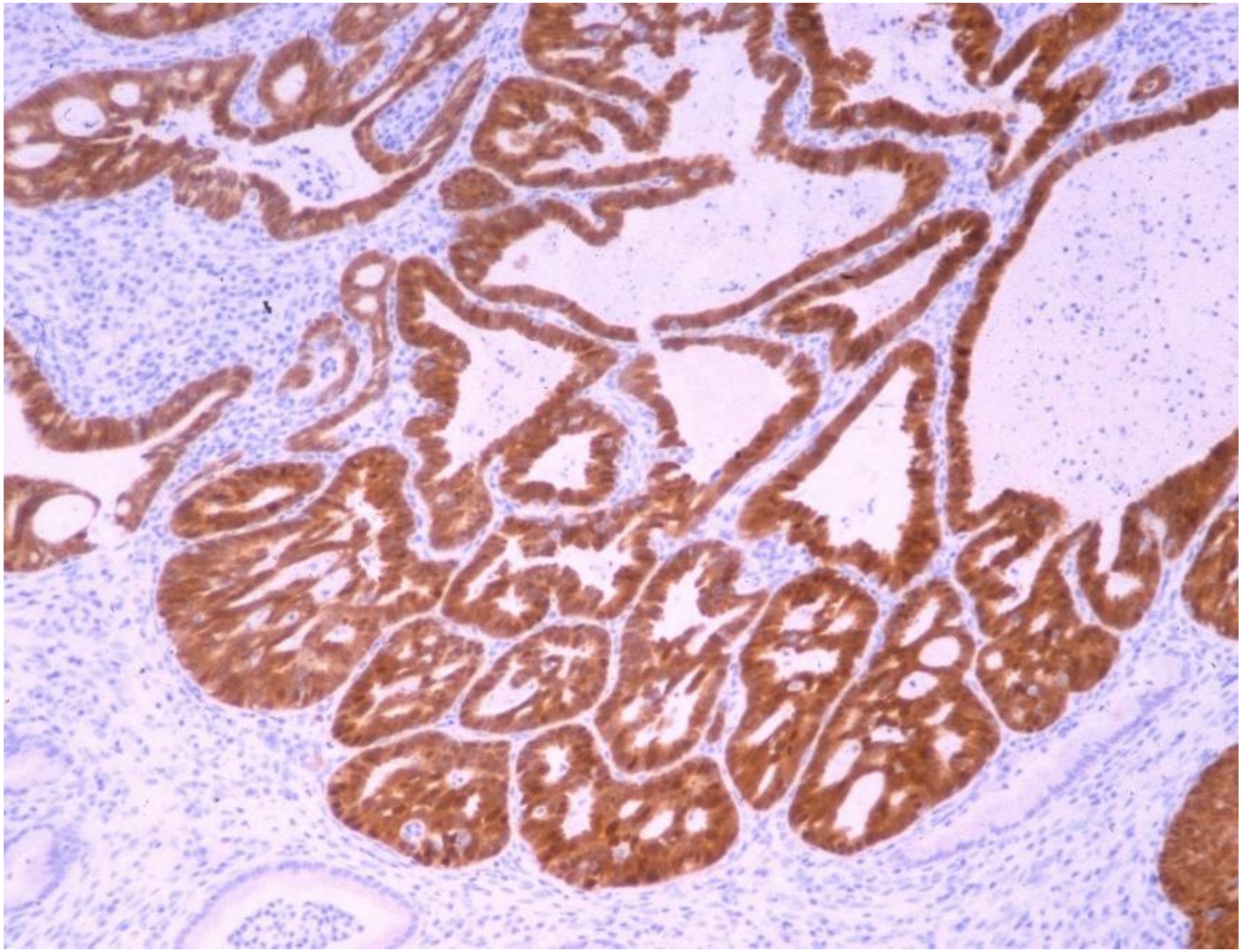

WHO 2003- PRIOR ENDOCERVICAL GLANDULAR DYSPLASIA/ LCGIN- NOW AIS (VALUE OF p16)

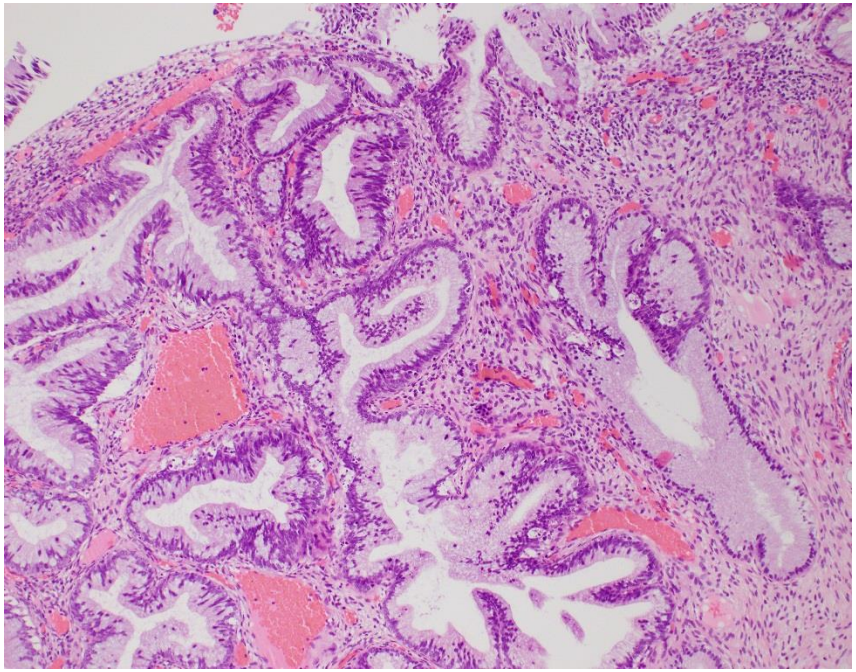

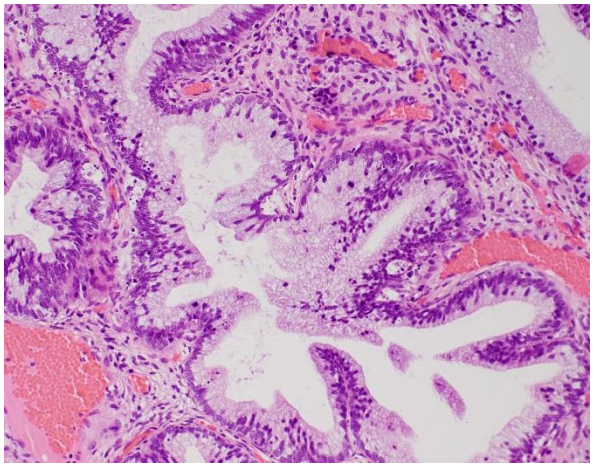

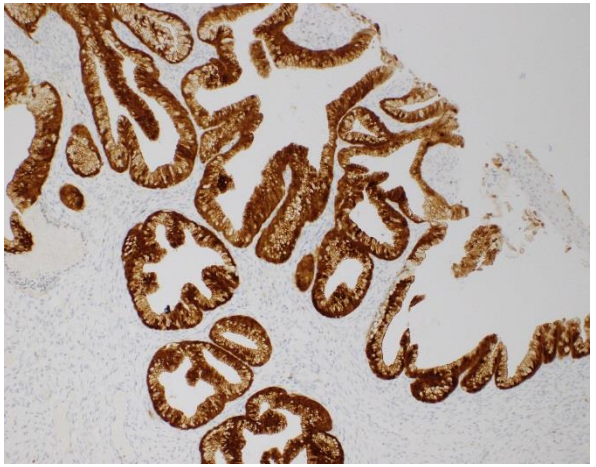

STRATIFIED MUCIN PRODUCING INTRAEPITHELIAL LESION (SMILE)

- rare; risk of overdiagnosis
- WHO 2020 considers as morphological variant of AIS
- I consider form of high grade reserve cell dysplasia with morphological features of both CIN and AIS
- often associated with CIN and AIS but may occasionally occur in pure form
- may involve surface or glands
- can be a difficult diagnosis

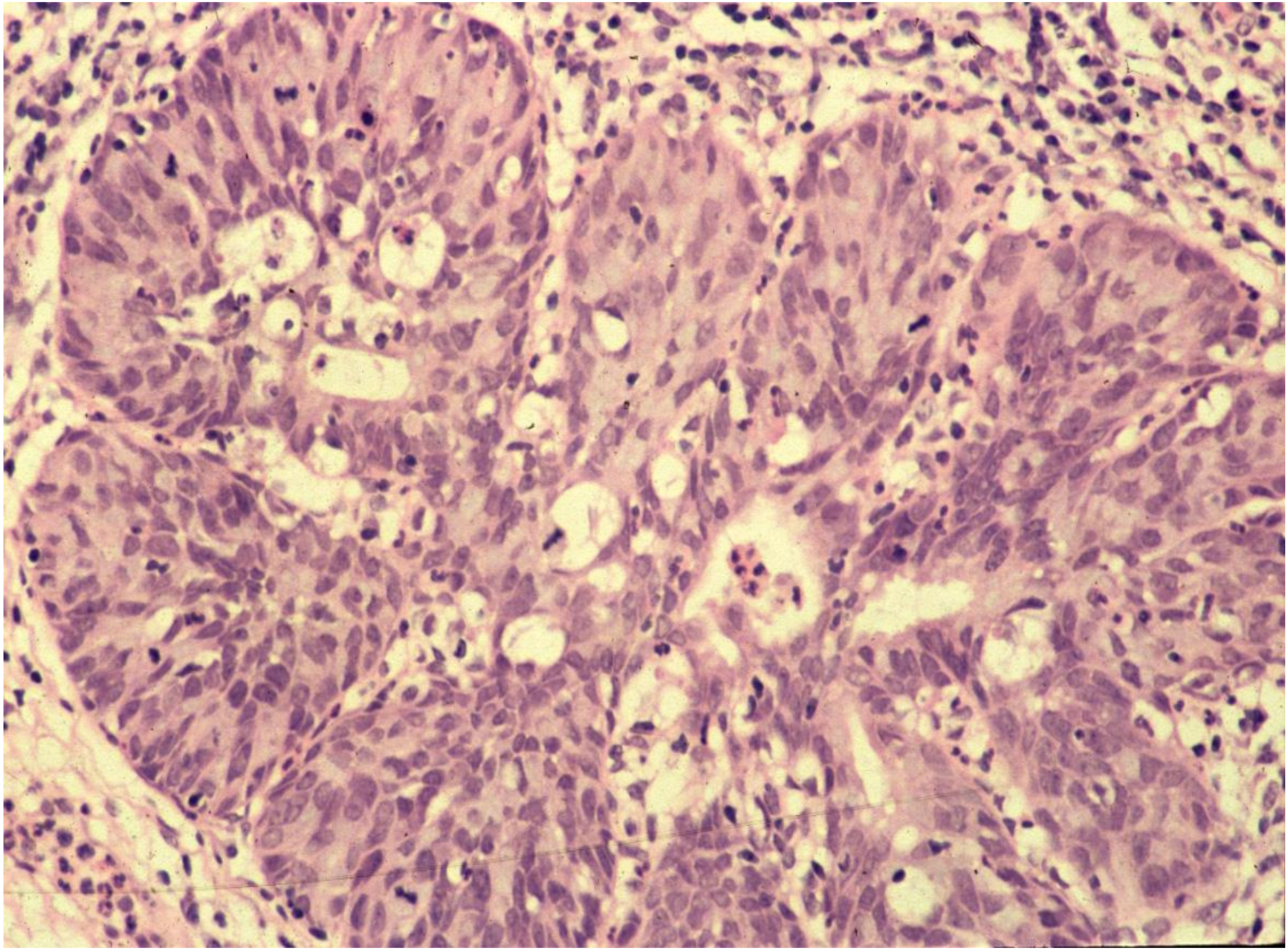

SMILE

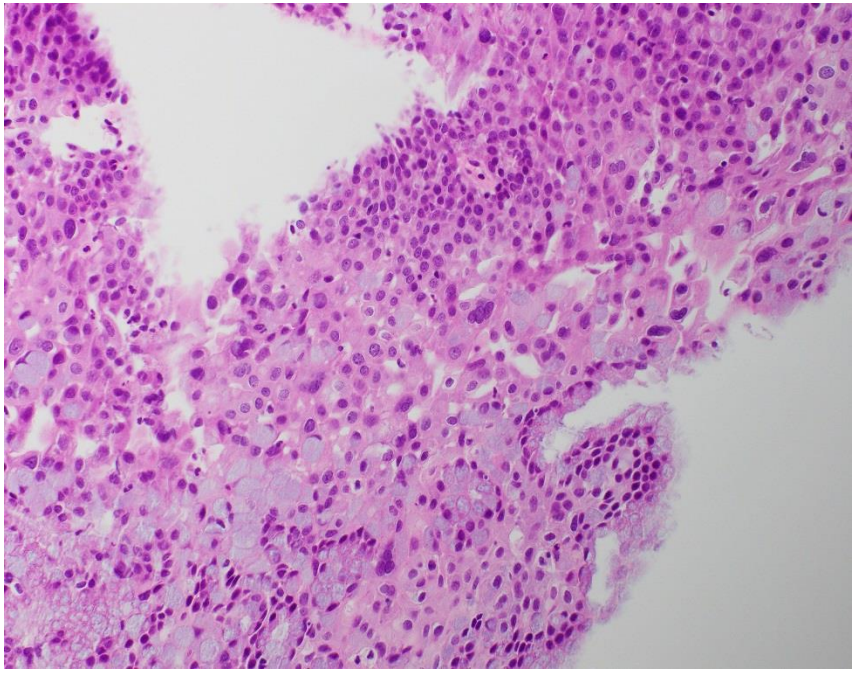

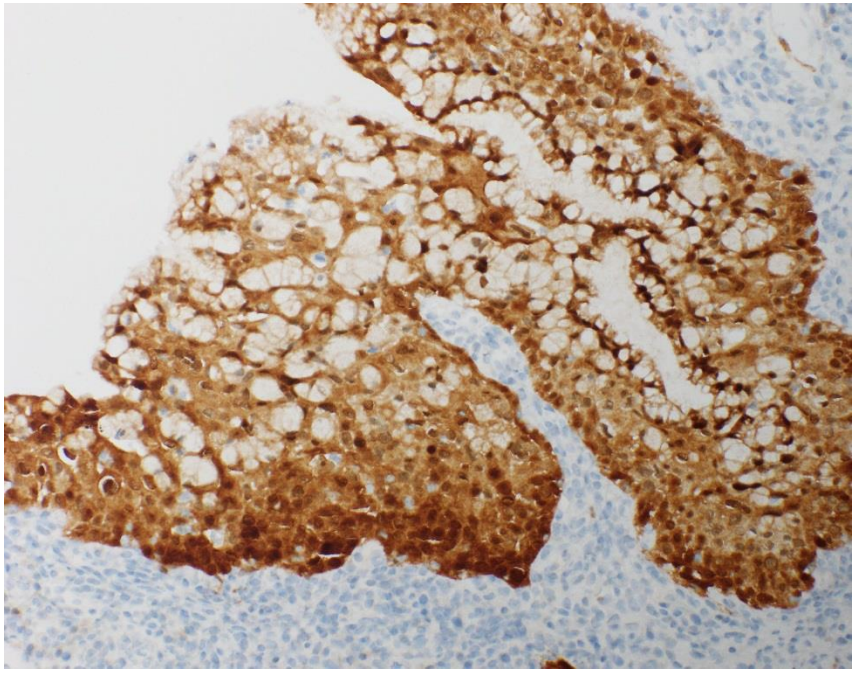

p16

RISK OF OVERDIAGNOSIS OF SMILE

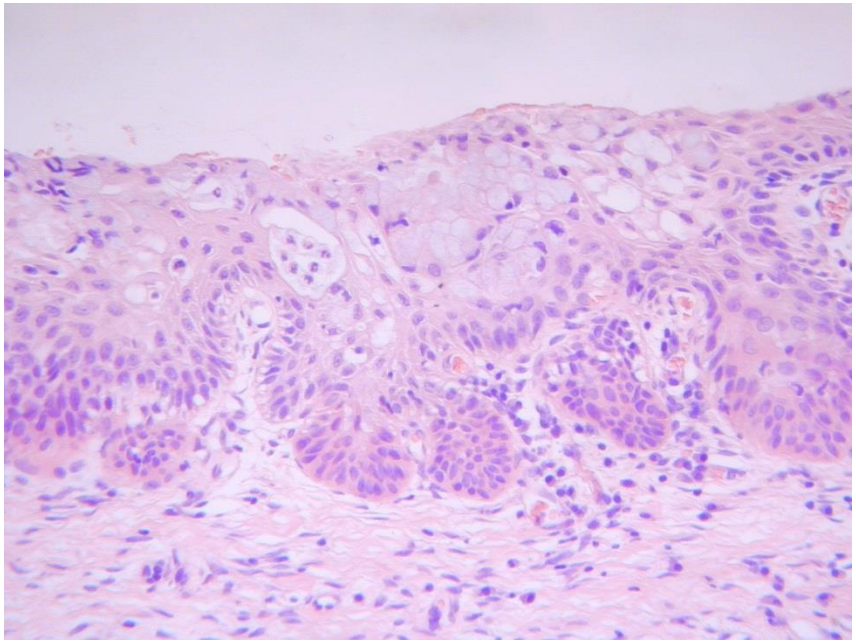

Immature squamous metaplasia

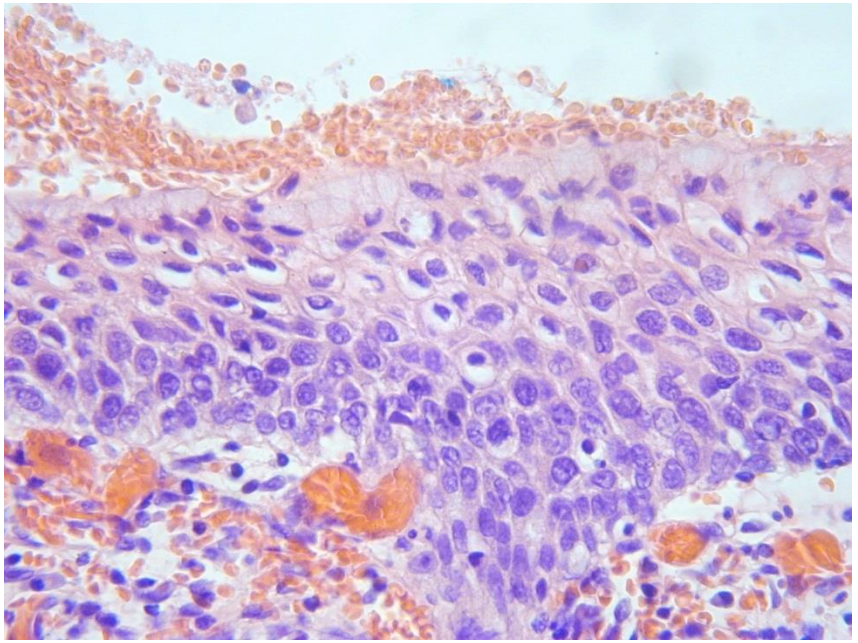

CIN involving immature metaplastic squamous epithelium

SMILE

- PMID 25039487. HISTOPATHOLOGY 2015;66;658-663
- 69 cases over 6 year period (0.6% of all cervical specimens)
- Coexisted with high grade CIN in 93%; AIS in 42%; invasive carcinoma in 10%
- Best regarded as form of high grade reserve cell dysplasia
- Management as for AIS (state on pathology report) (ensure clear margins)

CERVICAL ADENOCARCINOMA

- increasing in incidence
- now accounts for 20-25% of cervical carcinomas in Western Countries
- HPV-associated accounts for 80-85%; most commonly HPV 16 and 18
- most of unusual types are HPV-independent

Cervical Epithelial Lesions (WHO 2014)

Squamous cell tumours and precursors

- Squamous intraepithelial lesions
  - Low-grade squamous intraepithelial lesion (HPV only, CIN I)
  - High grade squamous intraepithelial lesion (CIN II, CIN III)
- Squamous cell carcinoma

Glandular tumours and precursors

- Adenocarcinoma in situ

Adenocarcinoma

- Endocervical adenocarcinoma, usual type
- Mucinous carcinoma, NOS
  - Gastric type (including adenoma malignum / minimal deviation adenocarcinoma)
  - Intestinal type
  - Signet-ring cell type
- Villoglandular adenocarcinoma
- Endometrioid adenocarcinoma

- Clear cell adenocarcinoma
- Serous adenocarcinoma
- Mesonephric adenocarcinoma
- Adenocarcinoma admixed with neuroendocrine carcinoma

COMMENTS ON WHO 2014 CLASSIFICATION OF CERVICAL ADENOCARCINOMAS

- Much room for improvement; poorly reproducible, no criteria for diagnosis; not pathogenesis based
- Some of types probably don’t exist or are extremely rare- endometrioid, serous, villoglandular; most are variants of usual HPV-associated

WHO 2020

- Cervical adenocarcinomas divided on basis of HPV-association
- HPV-associated (usual and mucinous types (50% mucin) with variants)- these subtypes are only listed in a table and not mentioned in the text
- Various **TYPES** of HPV-independent (gastric-type, clear cell, mesonephric)
- Others (endometrioid)
- Initially based on International Endocervical Adenocarcinoma Criteria and Classification (IECC)
- Silva pattern based classification of invasion discussed for HPV-associated adenocarcinomas

HPV-ASSOCIATED

- Conspicuous mitoses and apoptotic bodies stressed (based on IECC); over-emphasised in my opinion
- **Usual-type** (incorporates villoglandular and micropapillary as morphological variants)
- **Mucinous-type** (mucinous, NOS; signet-ring; intestinal; invasive SMILE)
- STILL OVERCOMPLICATED IN MY OPINION

USUAL-TYPE HPV-ASSOCIATED

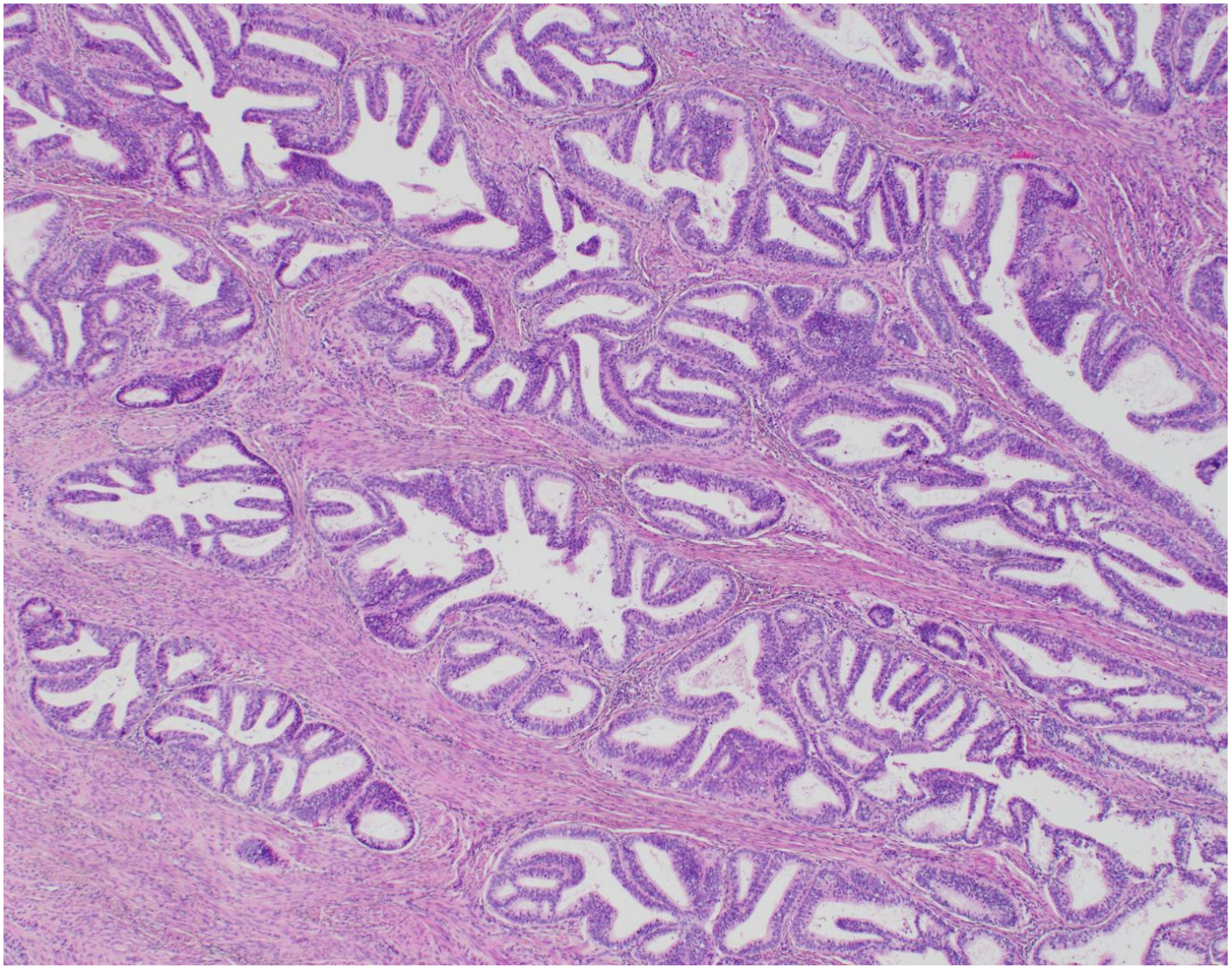

USUAL-TYPE HPV-ASSOCIATED- CONSPICUOUS MITOSES AND APOPTOSES- YES

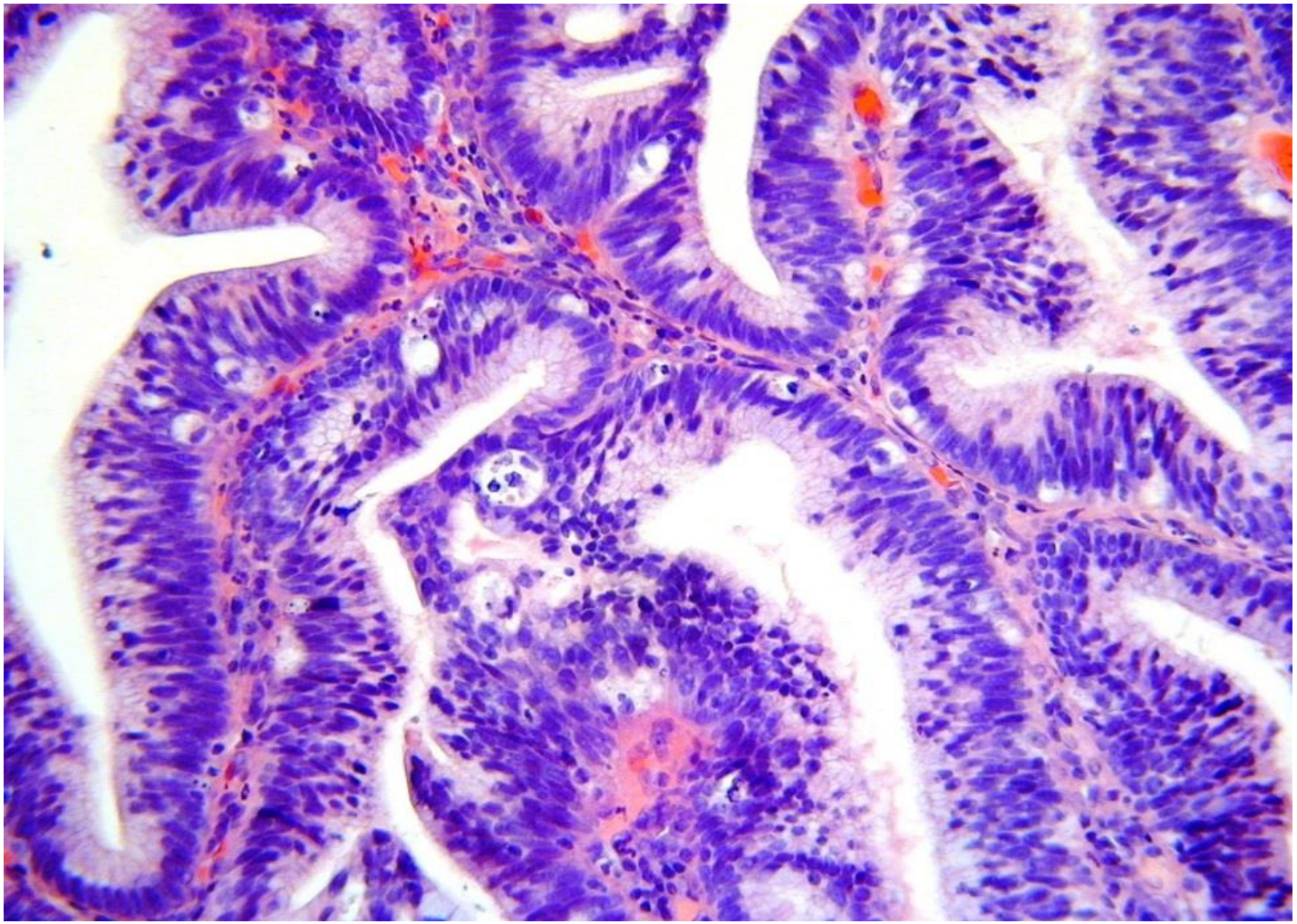

USUAL-TYPE HPV-ASSOCIATED- CONSPICUOUS MITOSES AND APOPTOSES- NO

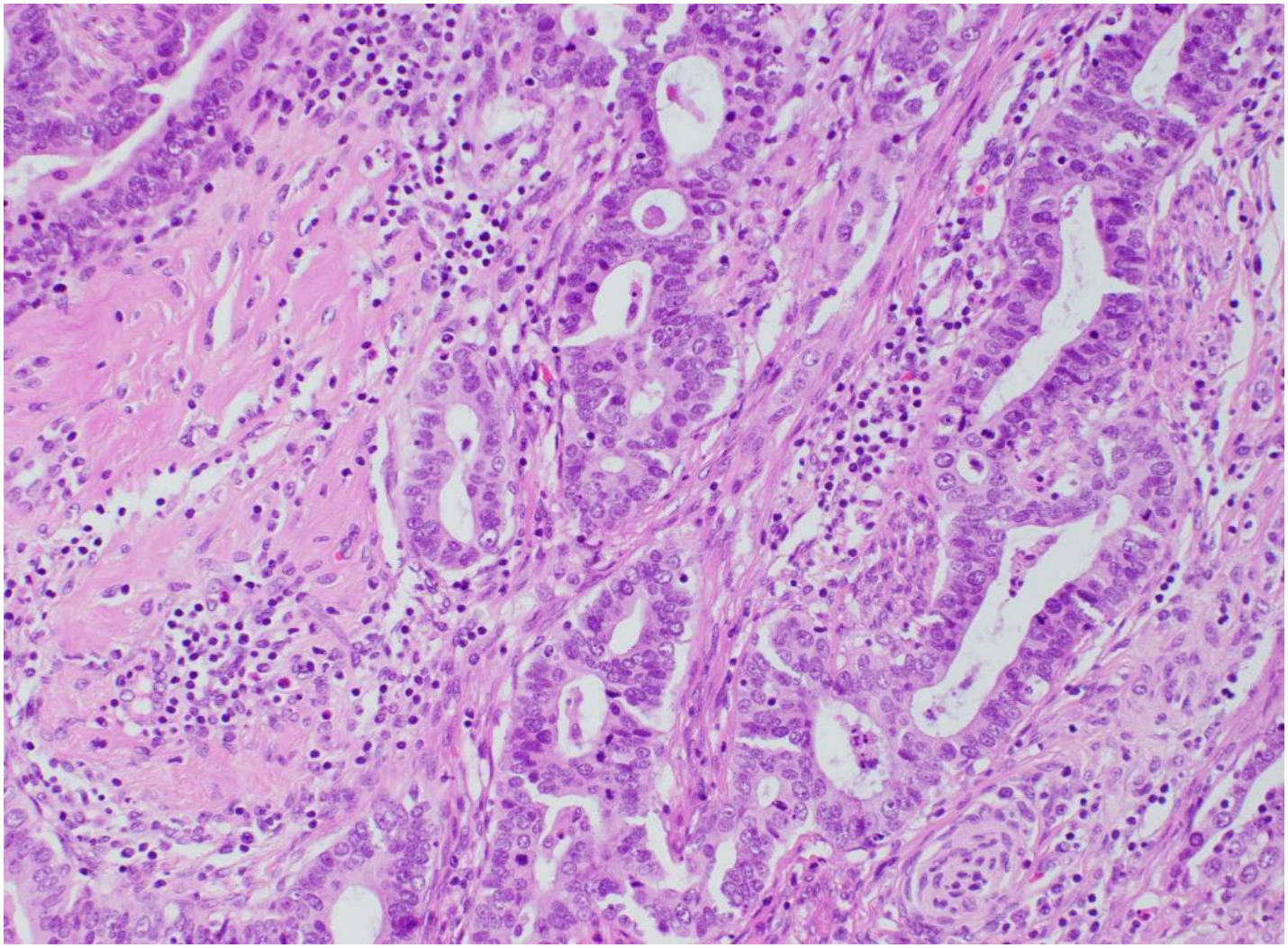

PAPILLARY ARCHITECTURE IN USUAL-TYPE HPV-ASSOCIATED CERVICAL ADENOCARCINOMA

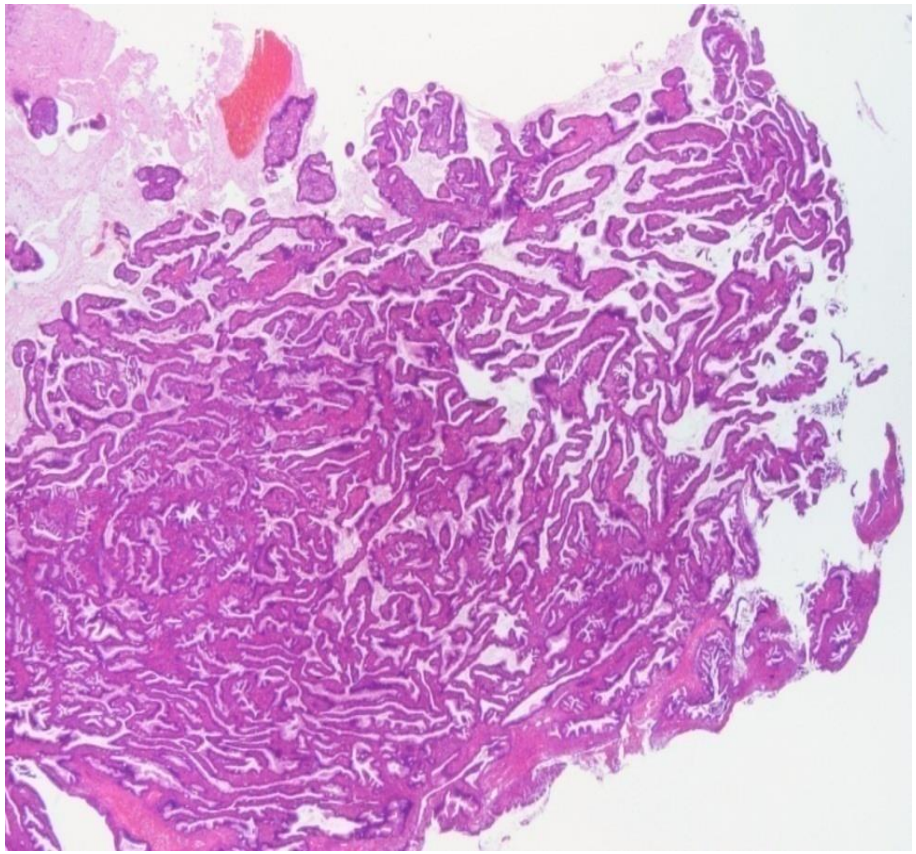

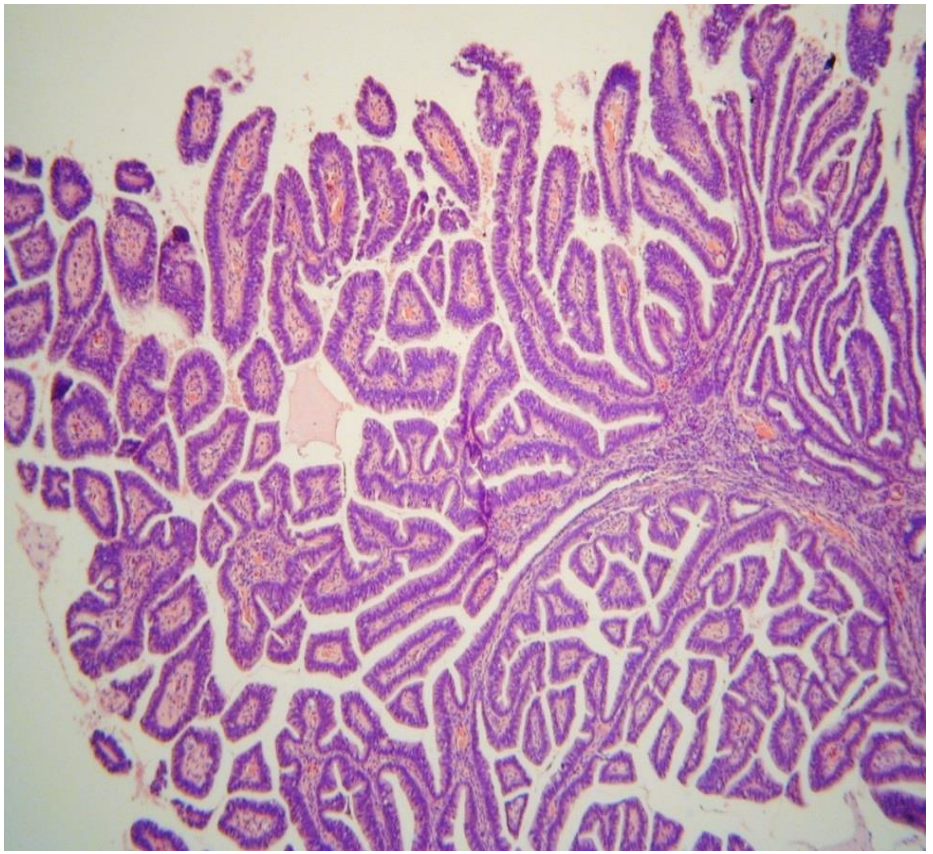

CRIBRIFORM ARCHITECTURE IN USUAL-TYPE HPV-ASSOCIATED CERVICAL ADENOCARCINOMA

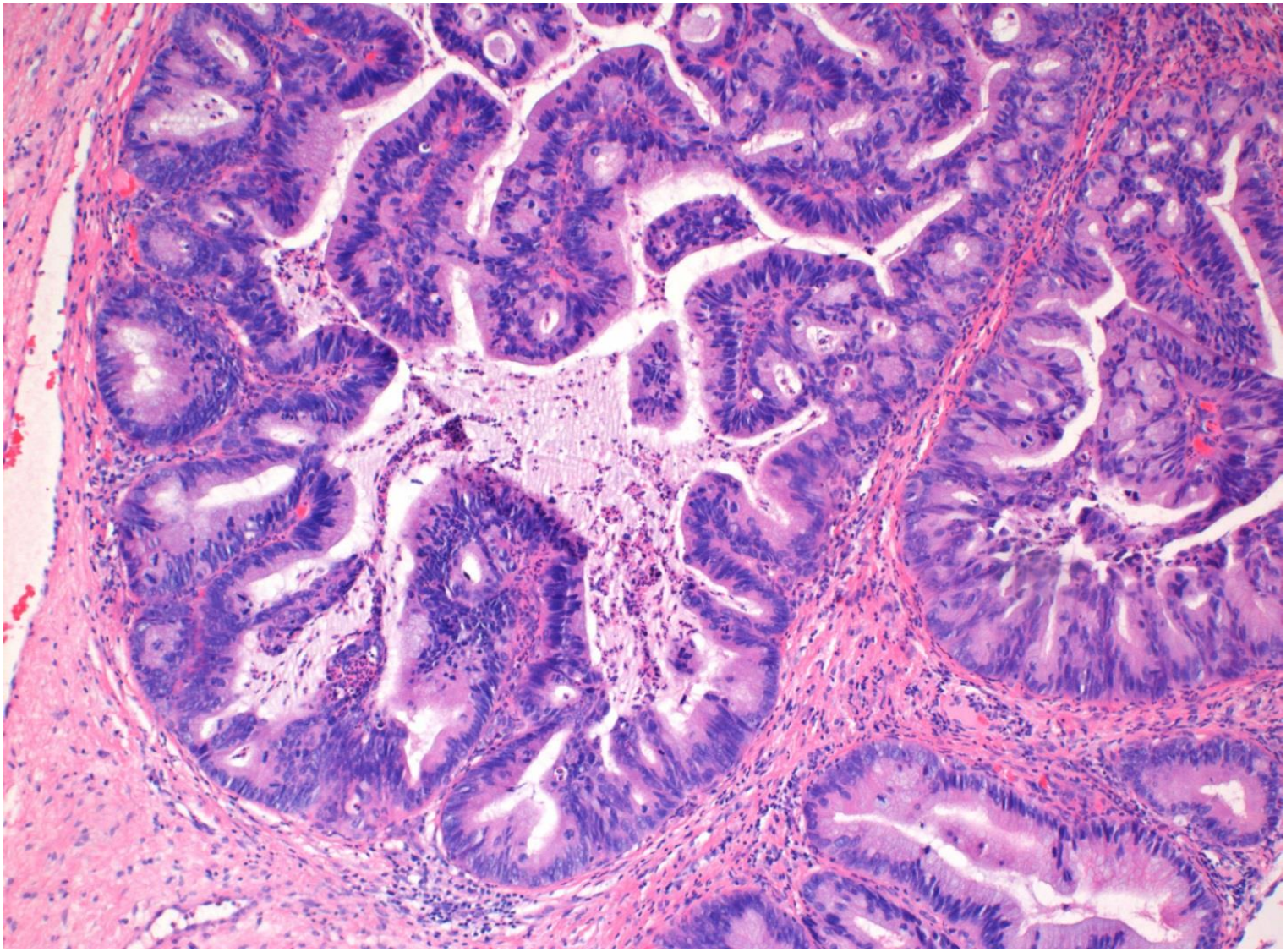

USUAL-TYPE HPV-ASSOCIATED- NOT ENDOMETRIOID

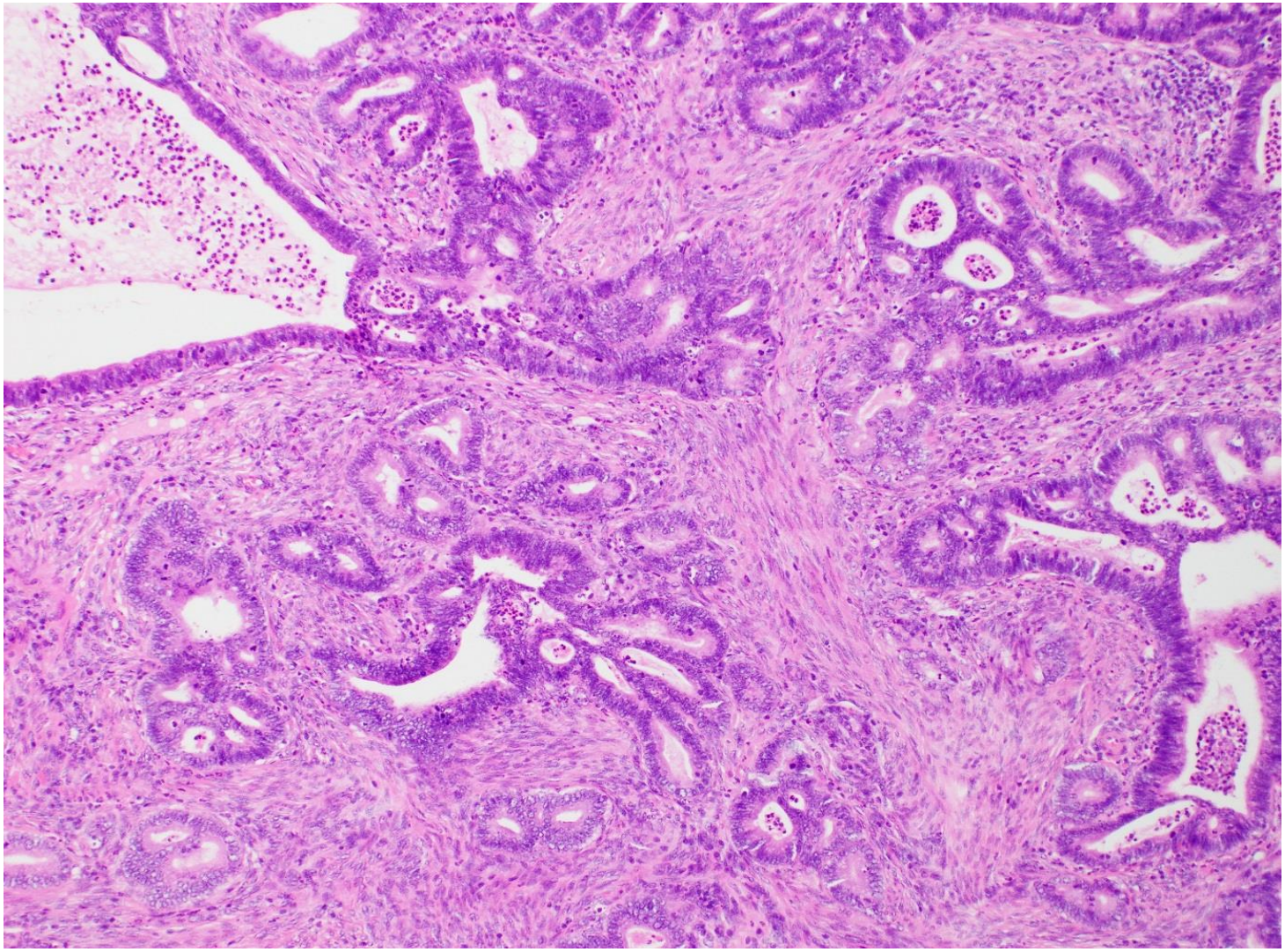

INTESTINAL DIFFERENTIATION IN USUAL-TYPE HPV-ASSOCIATED ADENOCARCINOMA

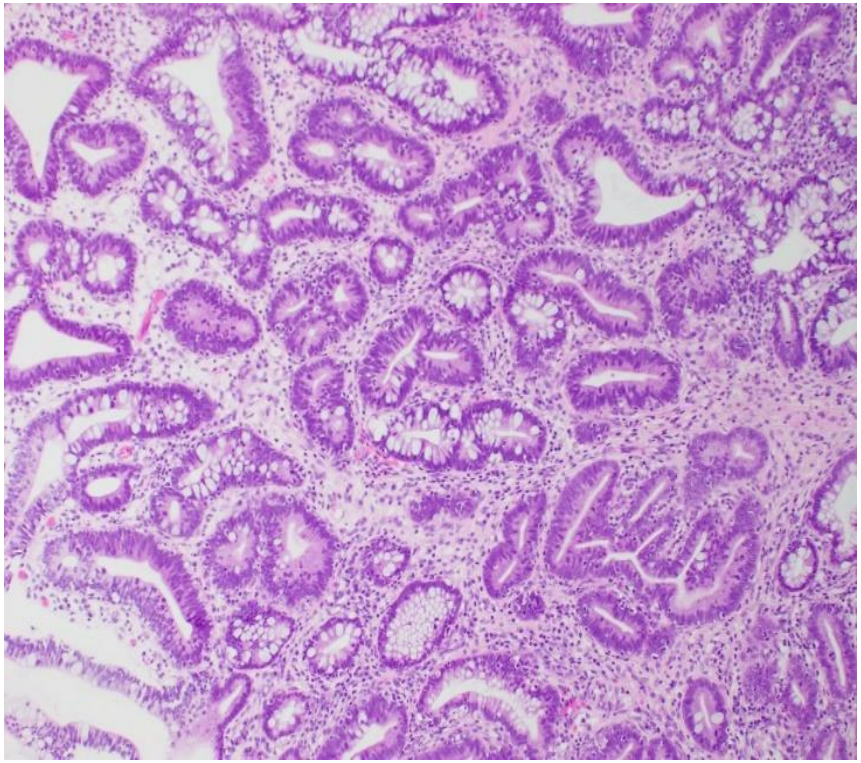

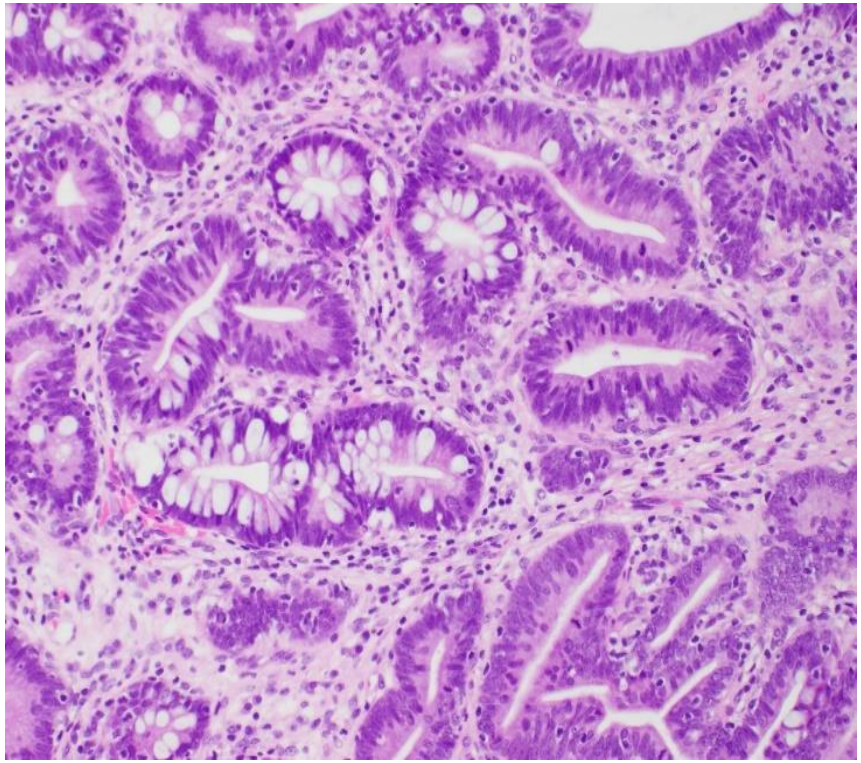

USUAL-TYPE HPV-ASSOCIATED CERVICAL ADENOCARCINOMA – “NAKED” INVASION

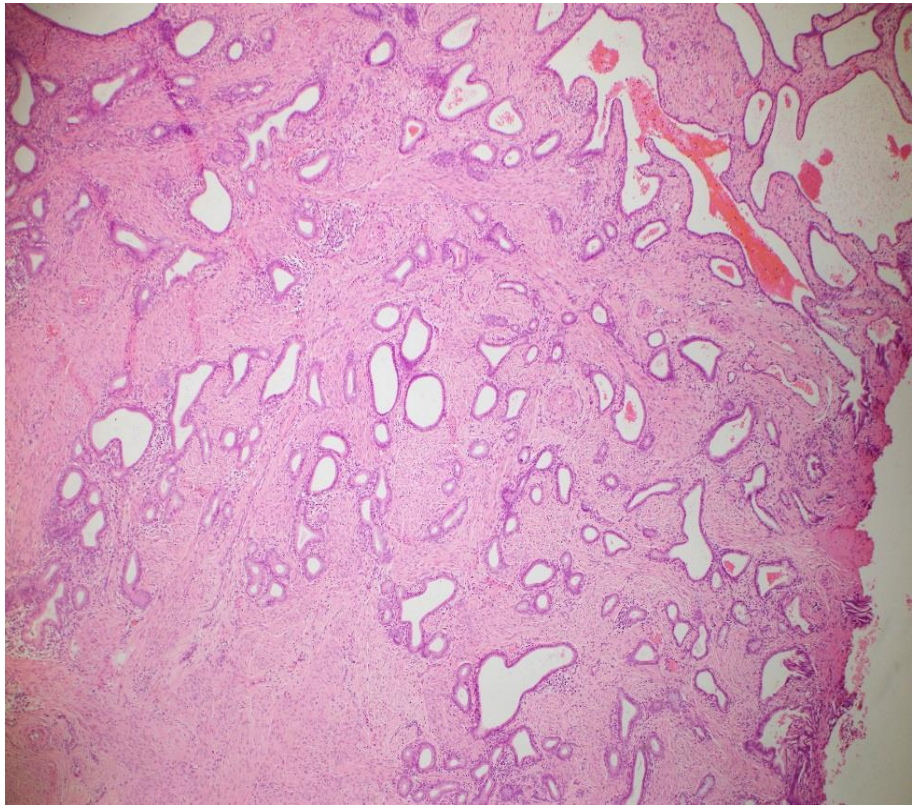

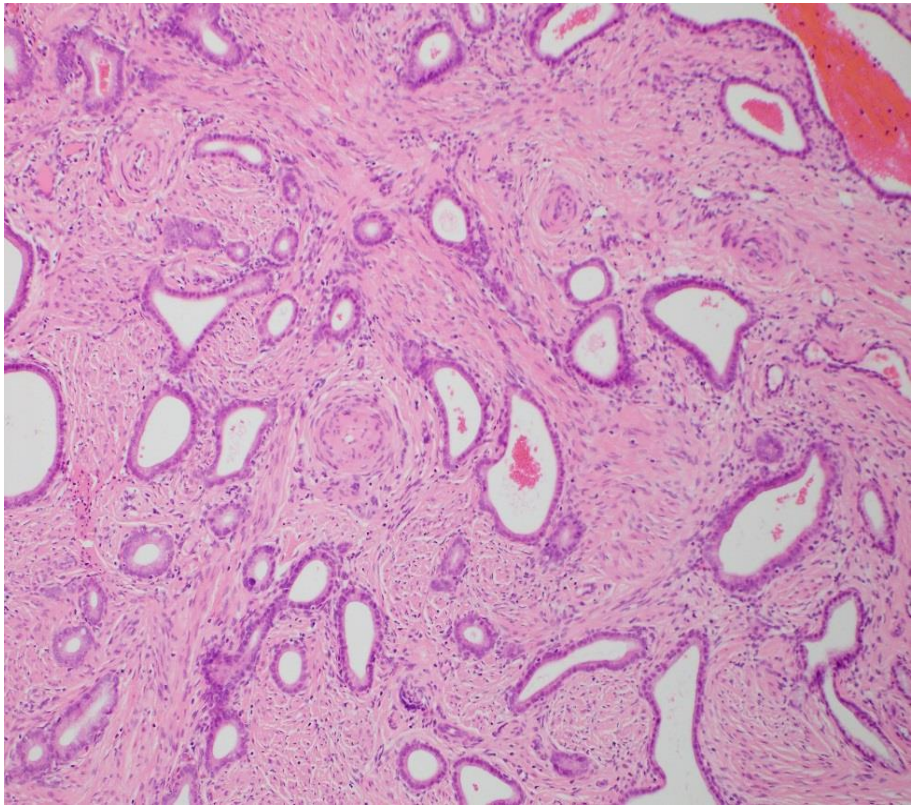

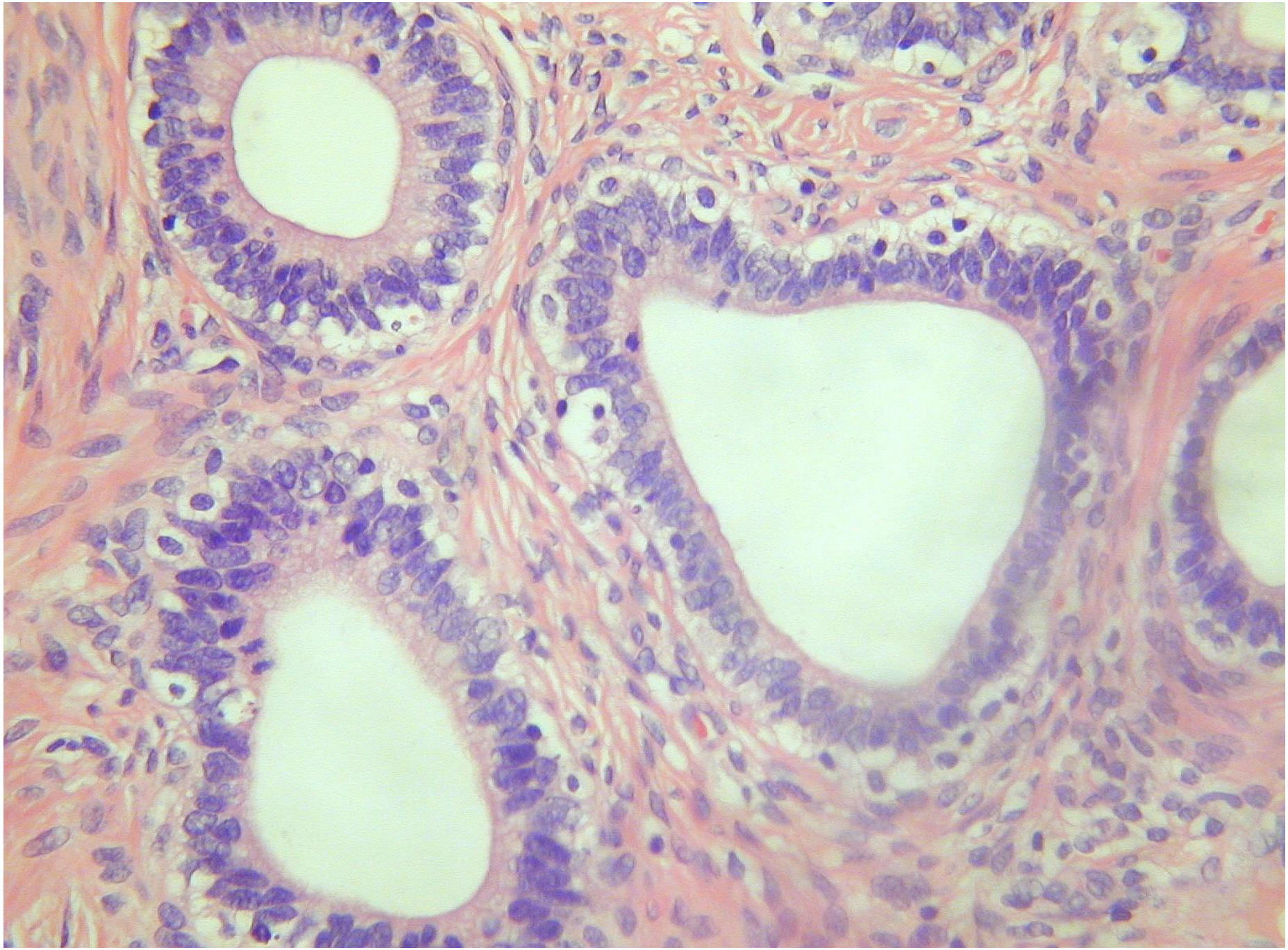

USUAL-TYPE HPV-ASSOCIATED CERVICAL ADENOCARCINOMA WITH MICROCYSTIC ARCHITECTURE

- rare
- microcystic appearance
- may be mistaken for a variety of benign endocervical glandular lesions (tunnel clusters etc)
- diffuse or focal phenomenon in otherwise usual-type HPV-associated

USUAL-TYPE HPV-ASSOCIATED CERVICAL ADENOCARCINOMA WITH MICROCYSTIC ARCHITECTURE

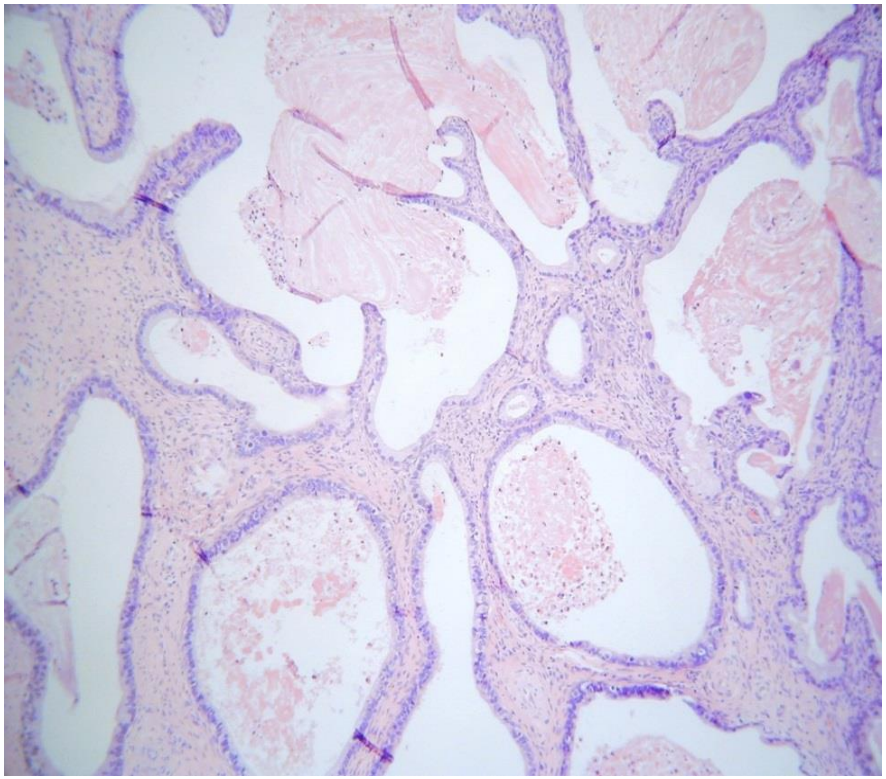

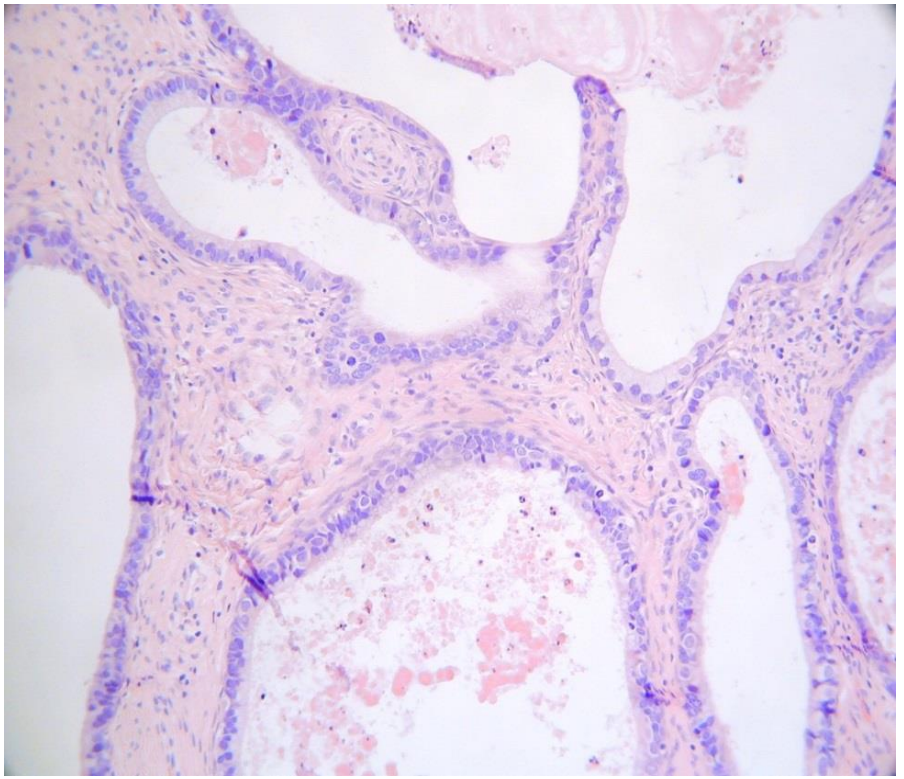

IMMUNOHISTOCHEMISTRY HPV-ASSOCIATED

p16

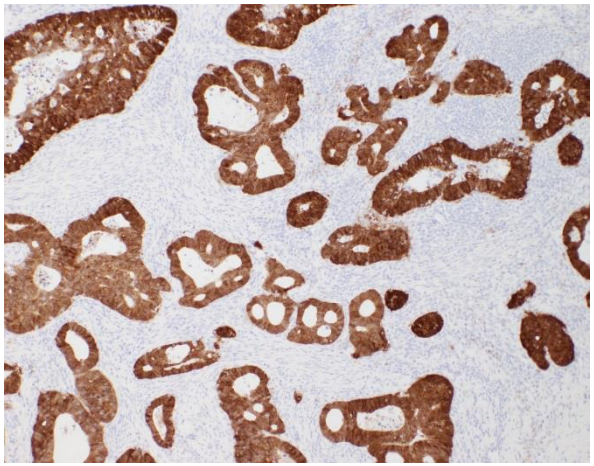

CEA

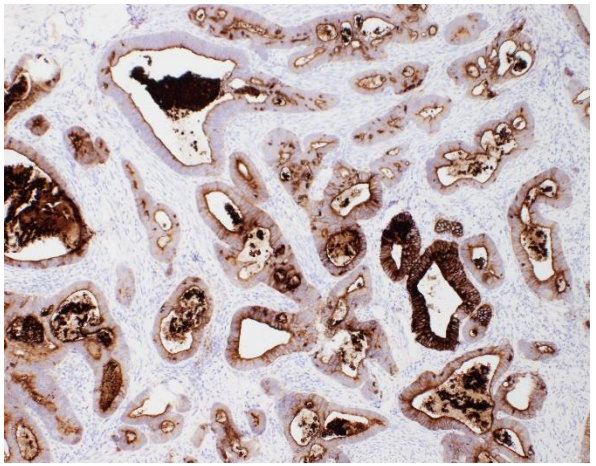

ER

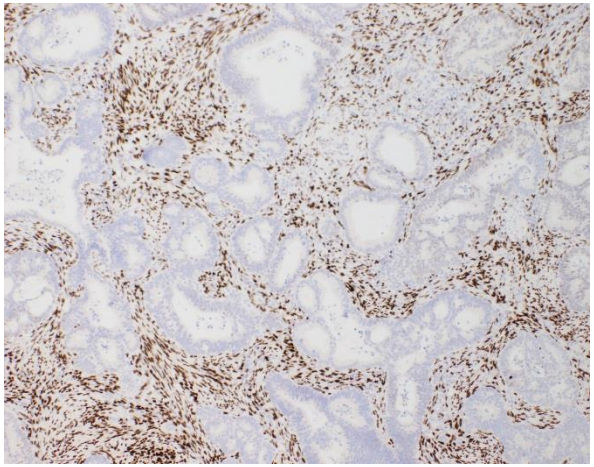

vimentin

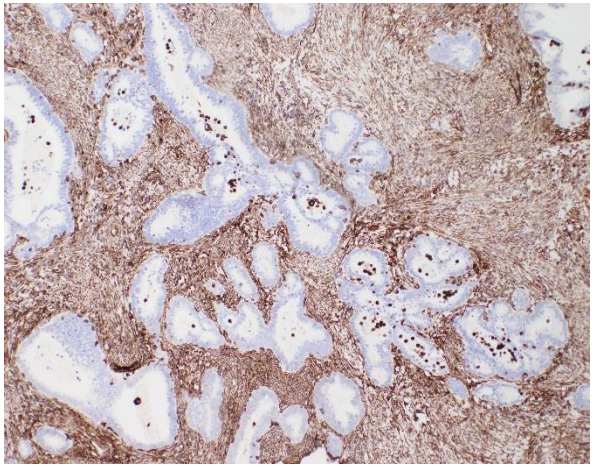

ER NOT ALWAYS NEGATIVE

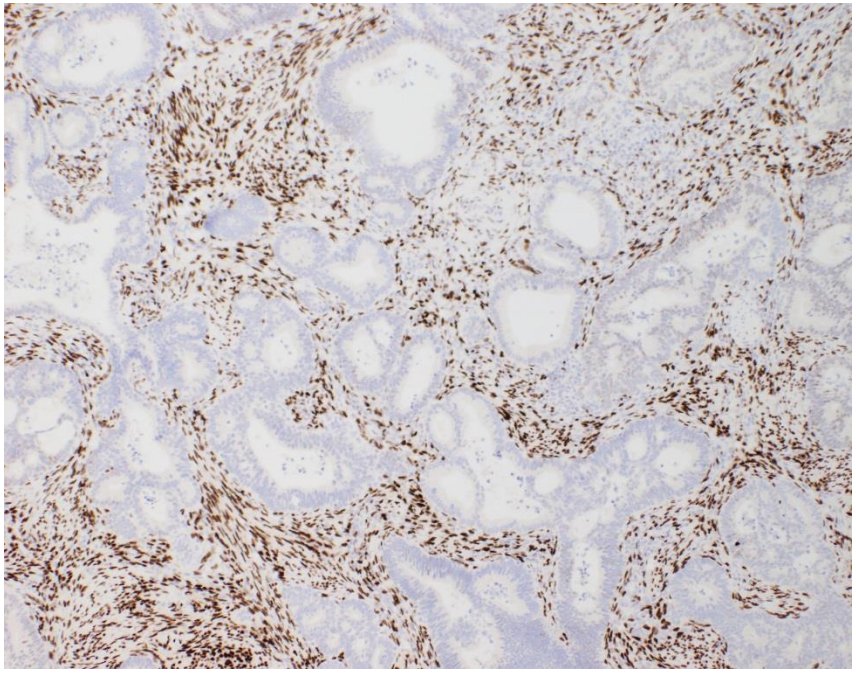

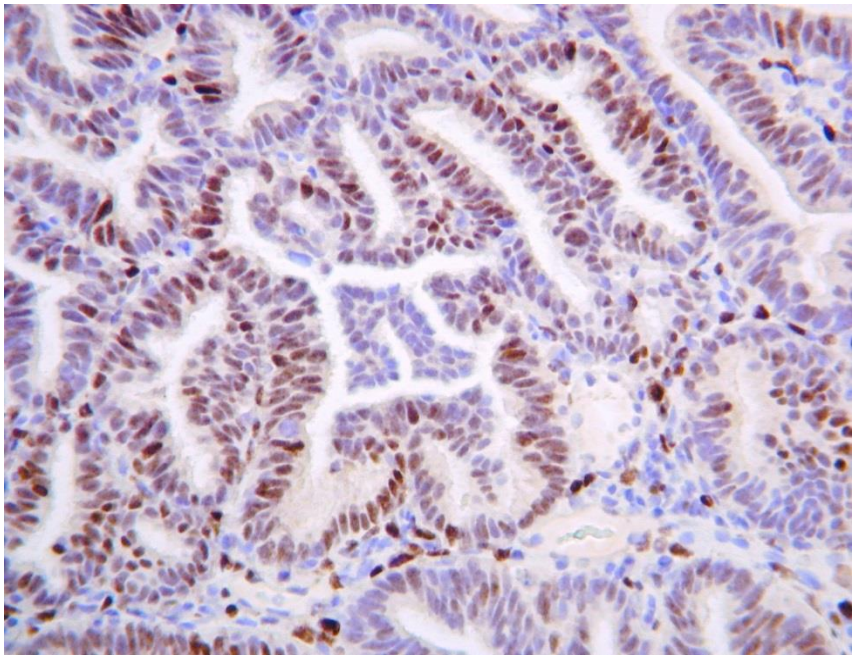

IMMUNOHISTOCHEMISTRY- HPV-ASSOCIATED

PAX8

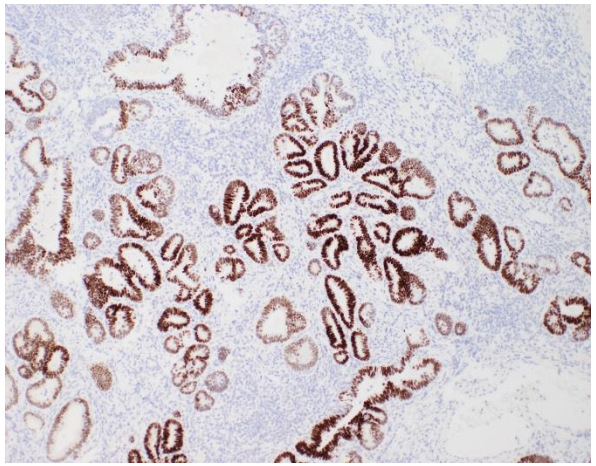

CDX2

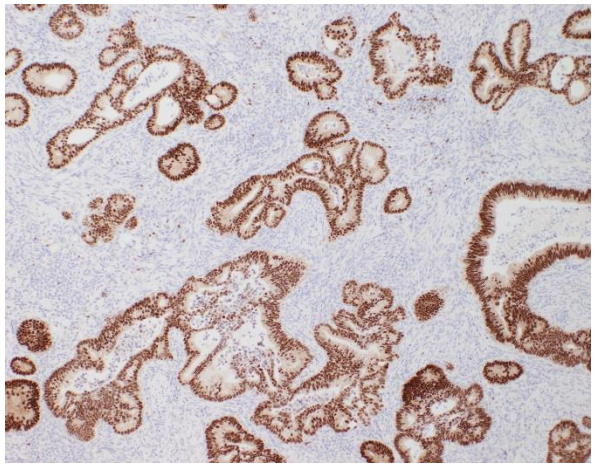

p53-almost always wild-type

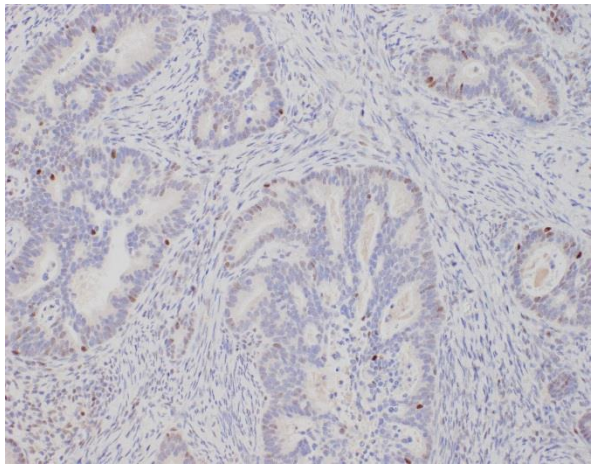

CK7

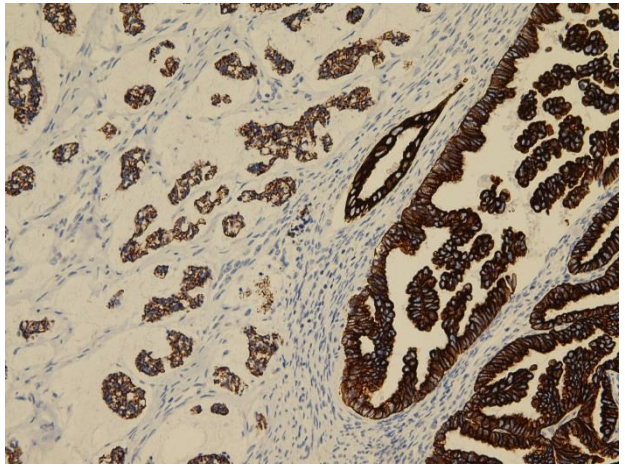

VILLOGLANDULAR ADENOCARCINOMA

- NOT A SEPARATE TUMOUR TYPE BUT VARIANT OF USUAL-TYPE HPV-ASSOCIATED ADENOCARCINOMA
- grossly polypoid lesion
- papillary/ villous-like growth pattern with fibrovascular cores (often inflamed) and low-grade cytology
- may be confined to surface or be only superficially invasive, although some may be deeply invasive
- “invasive” component often looks like usual-type
- may be better prognosis (BUT BECAUSE WELL-DIFFERENTIATED AND CONFINED TO SURFACE)
- included in text as variant of HPV-associated usual type in WHO 2020

VILLOGLANDULAR PATTERN

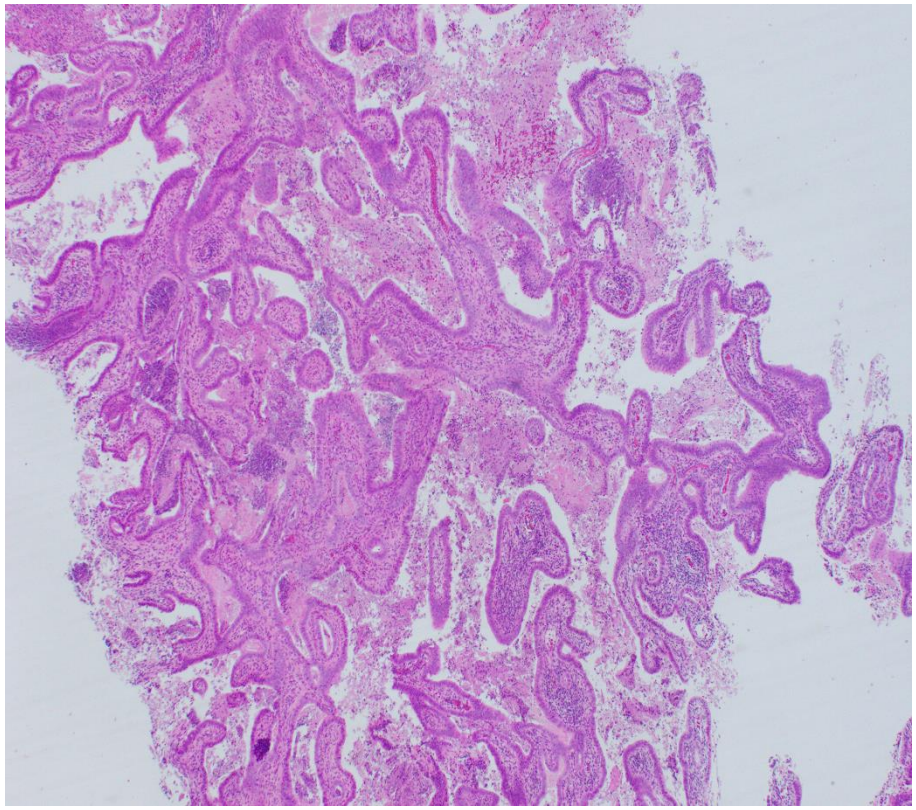

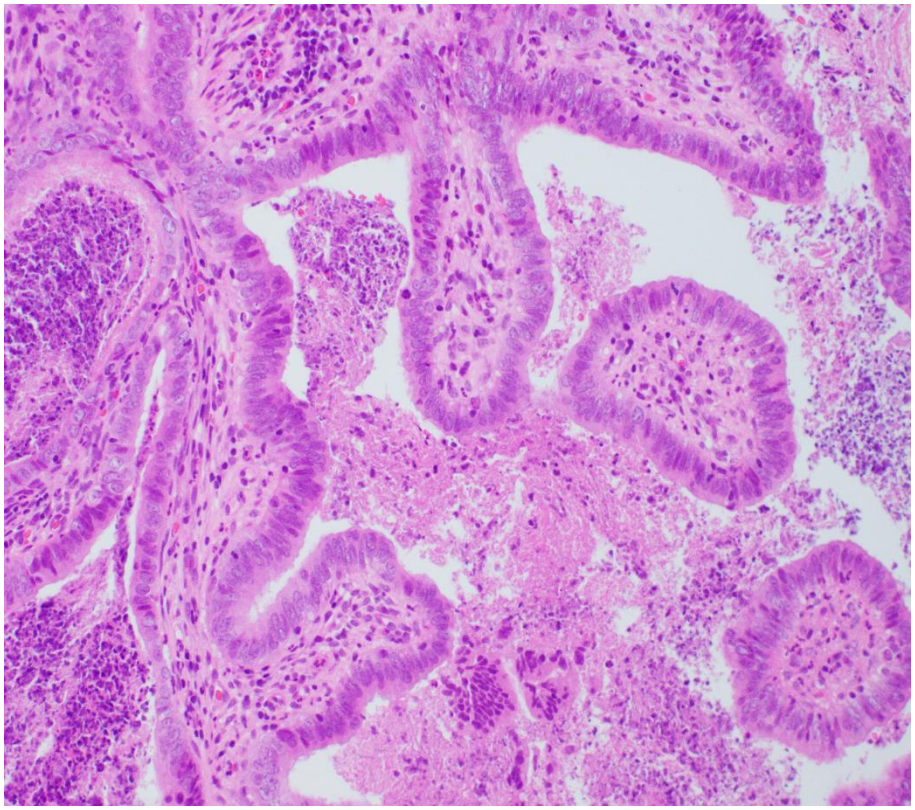

VILLOGLANDULAR PATTERN

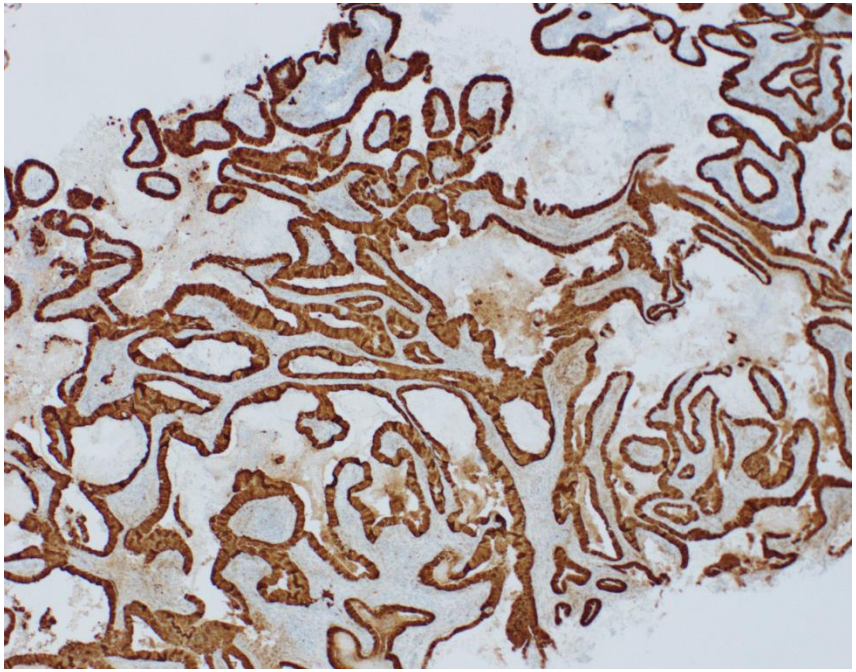

p16

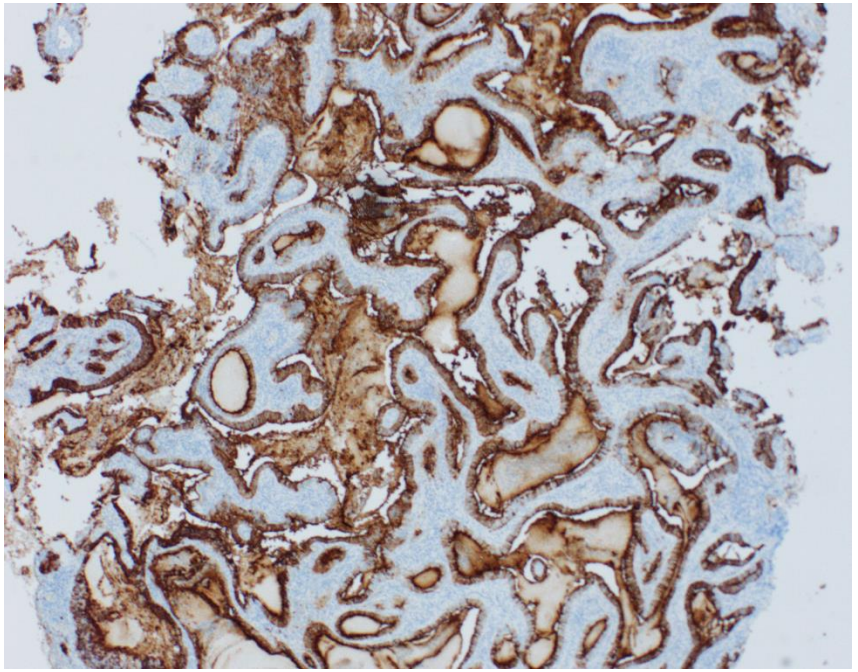

CEA

SEROUS ADENOCARCINOMA CERVIX

- now accepted that true serous carcinoma does not exist in cervix
- not included in WHO 2020
- cases diagnosed as primary cervical serous carcinoma represent spread from undetected endometrial (or tubo-ovarian) primary or usual-type HPV-associated mimicking serous carcinoma (these will be p53 wild-type)
- TIP- high-risk HPV related lesions almost never exhibit mutation-type p53 staining; exception is a few cervical neuroendocrine carcinomas
- if tumour exhibits block-type p16 and mutation-type p53 staining, almost certainly HPV-independent neoplasm (for example uterine serous or tubo-ovarian HGSC)

HPV-ASSOCIATED MIMICKING SEROUS CARCINOMA

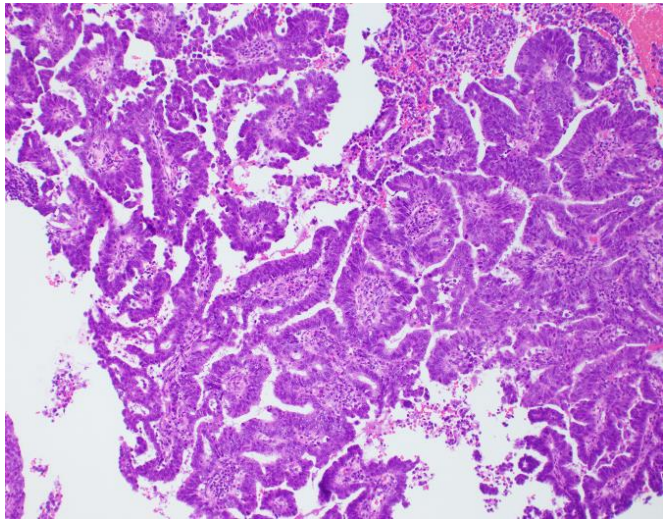

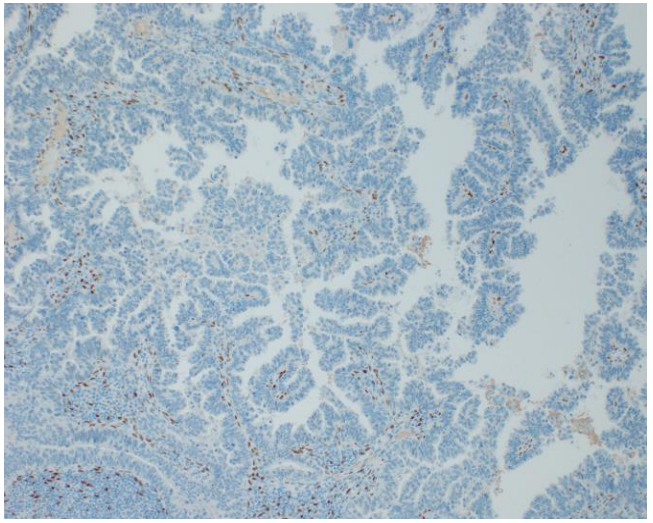

ER

p16

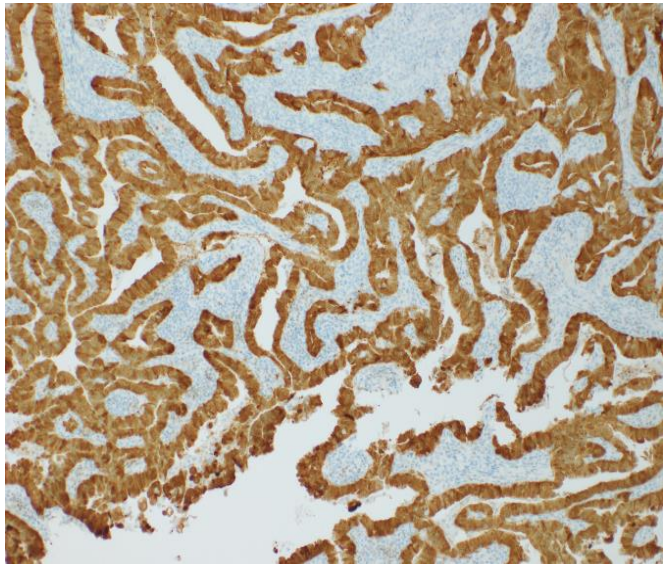

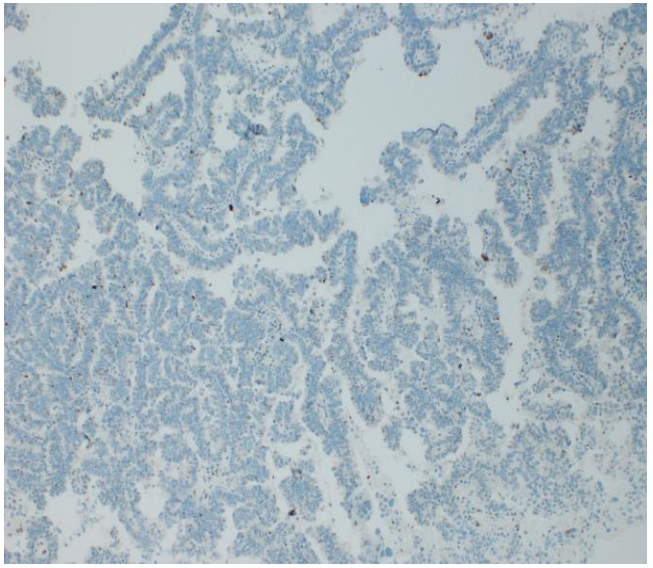

p53

MICROPAPILLARY VARIANT OF USUAL-TYPE HPV-ASSOCIATED CERVICAL ADENOCARCINOMA

- AJSP 2019; 43; 802-809
- Histopathology 2018; 72;623-633
- Focal or diffuse finding usually in usual HPV-associated cervical adenocarcinoma (diffuse p16 positive)
- HPV 16 or 18 most commonly
- Almost invariably exhibit prominent LVSI and often nodal involvement
- Aggressive behaviour
- Metastasis is often purely / predominantly micropapillary component
- Can be misdiagnosed as serous carcinoma (cervix, uterine or tubo-ovarian)- p53 usually wild-type in micropapillary cervical adenocarcinoma
- Rarely get micropapillary architecture in HPV-independent cervical adenocarcinomas (gastric, mesonephric)- don’t use term micropapillary adenocarcinoma for these

MICROPAPILLARY VARIANT OF USUAL-TYPE HPV-ASSOCIATED CERVICAL ADENOCARCINOMA

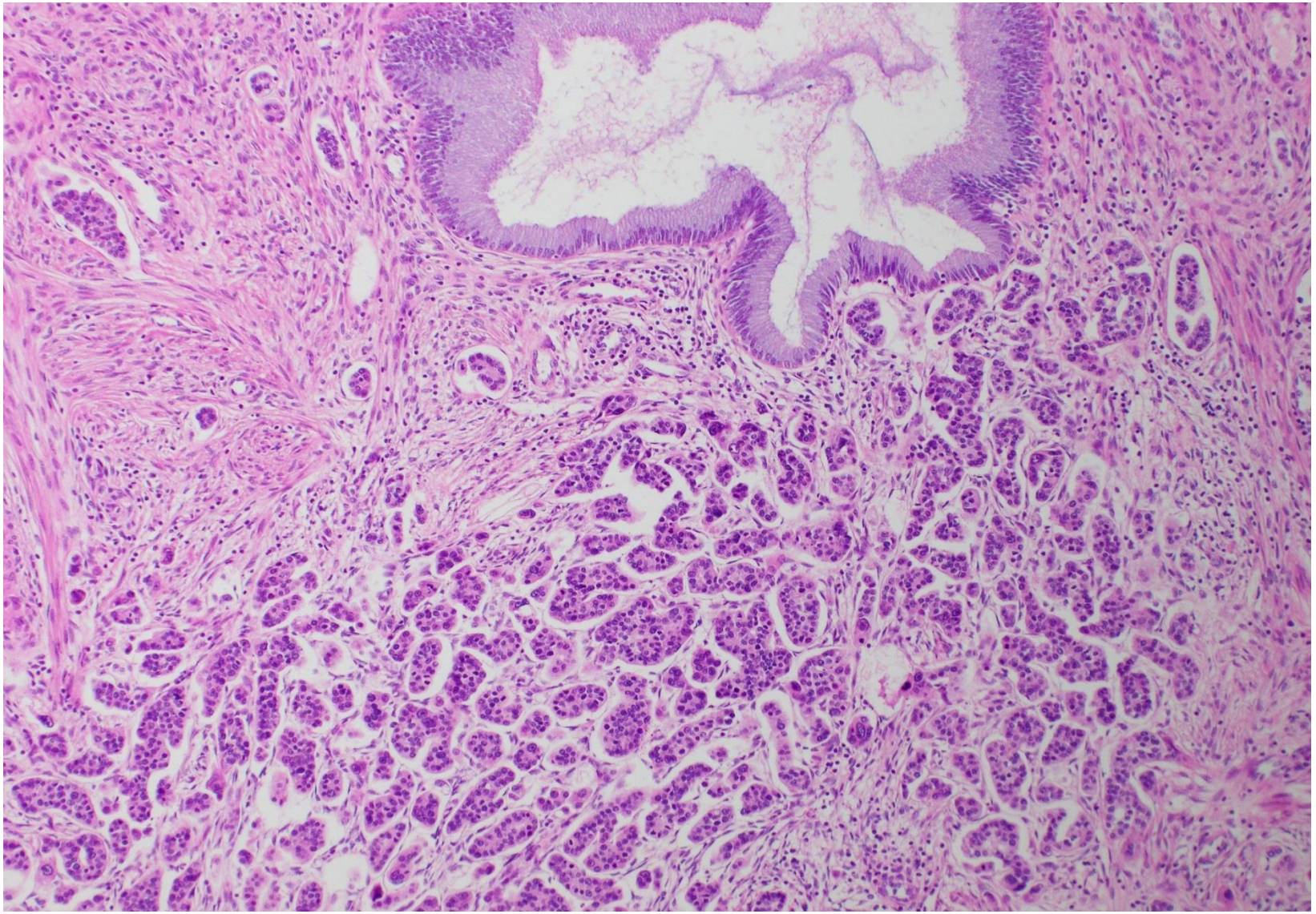

MICROPAPILLARY VARIANT OF USUAL-TYPE HPV-ASSOCIATED CERVICAL ADENOCARCINOMA

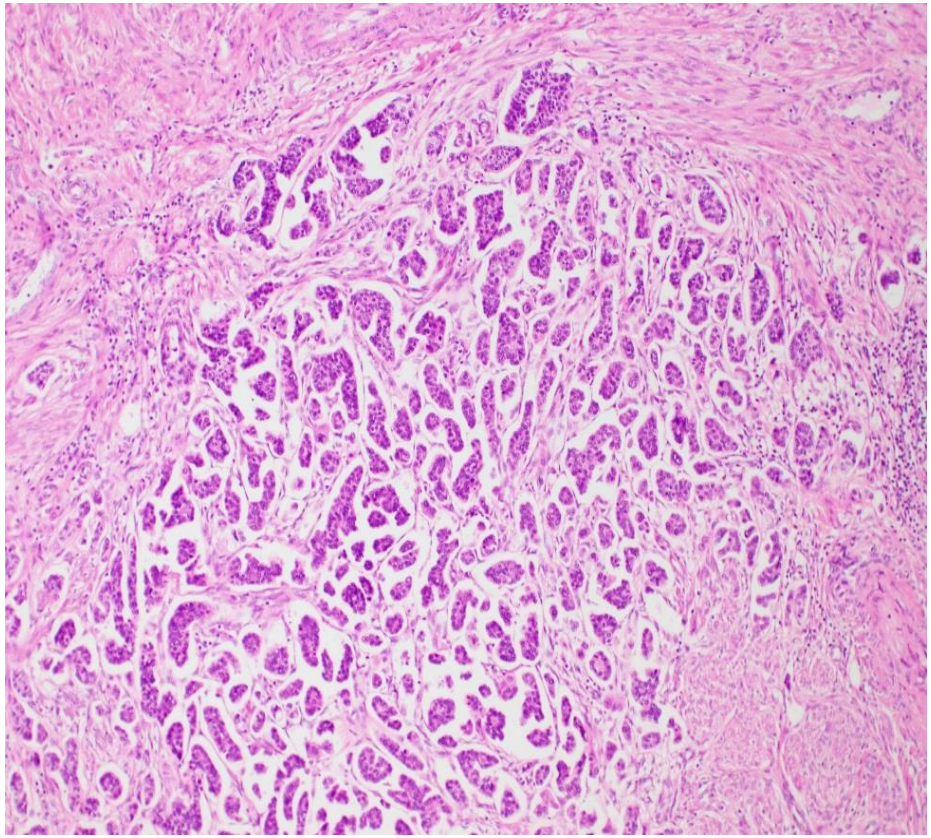

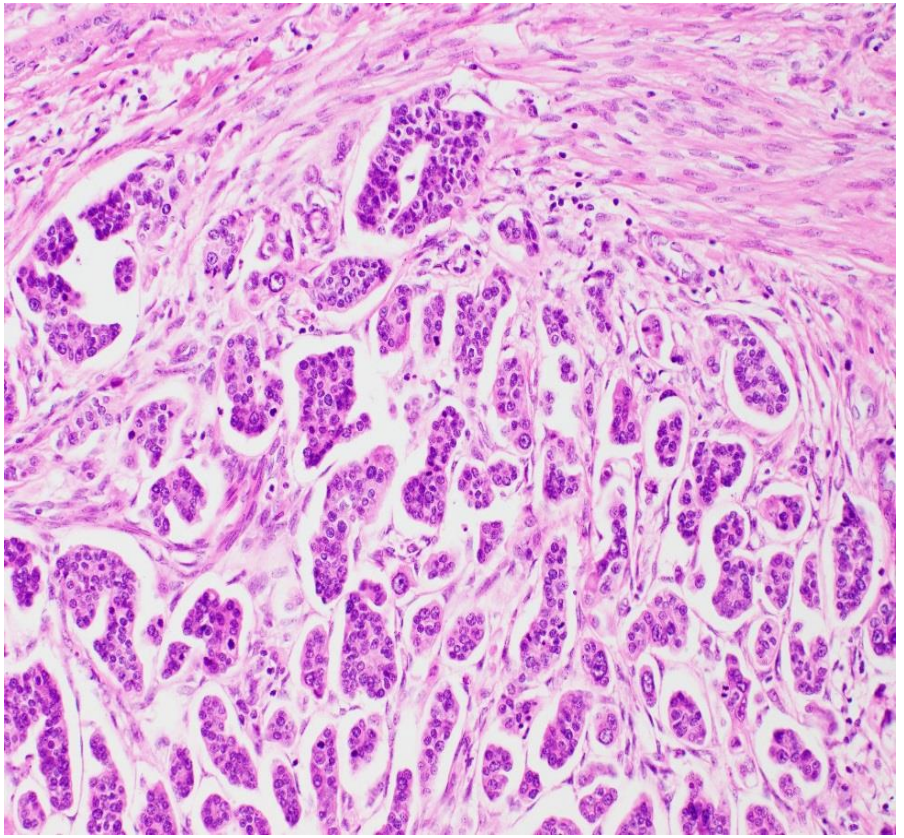

MICROPAPILLARY VARIANT OF USUAL-TYPE HPV-ASSOCIATED CERVICAL ADENOCARCINOMA

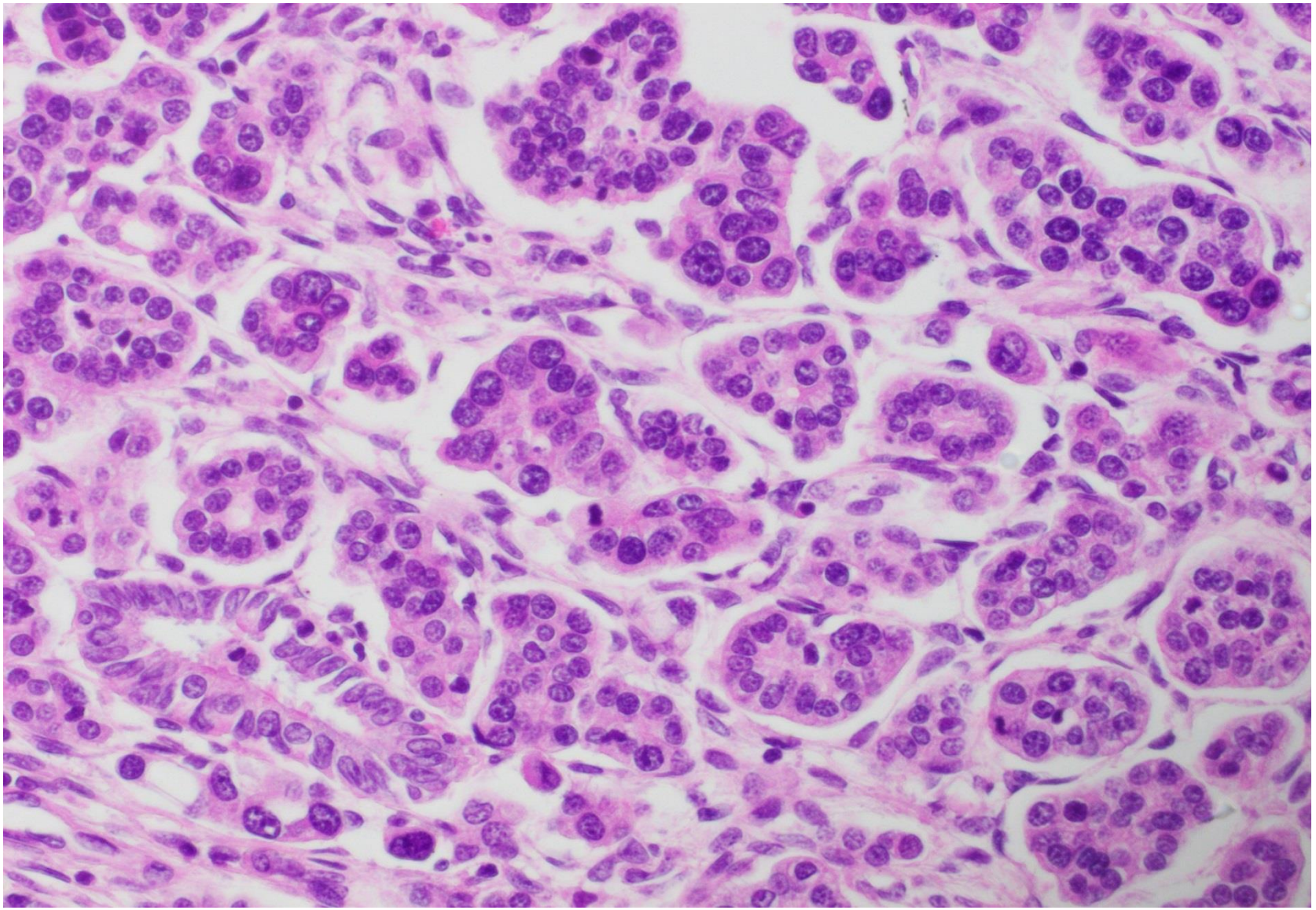

MICROPAPILLARY VARIANT OF USUAL-TYPE HPV-ASSOCIATED CERVICAL ADENOCARCINOMA

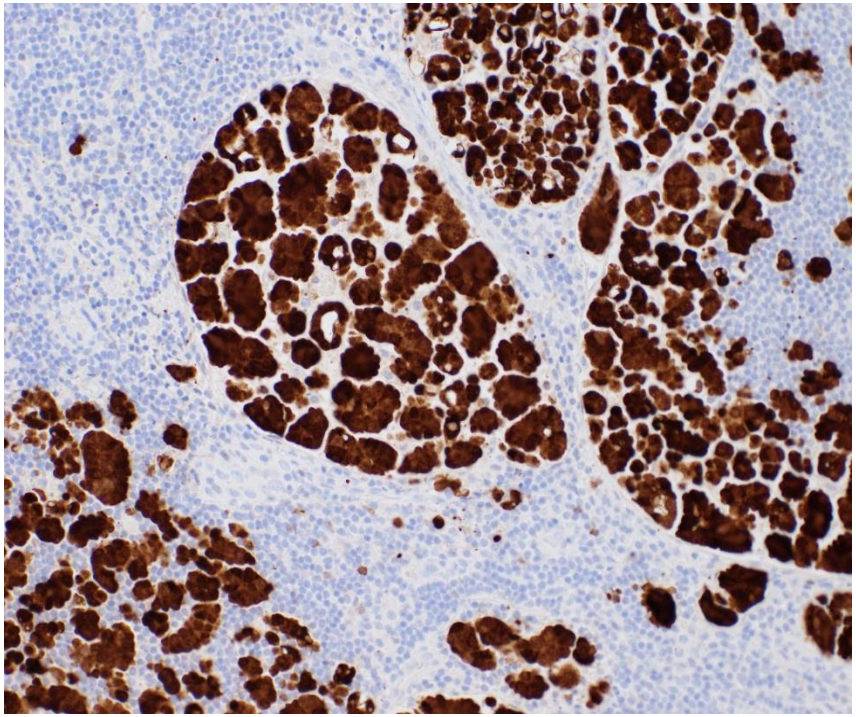

p16

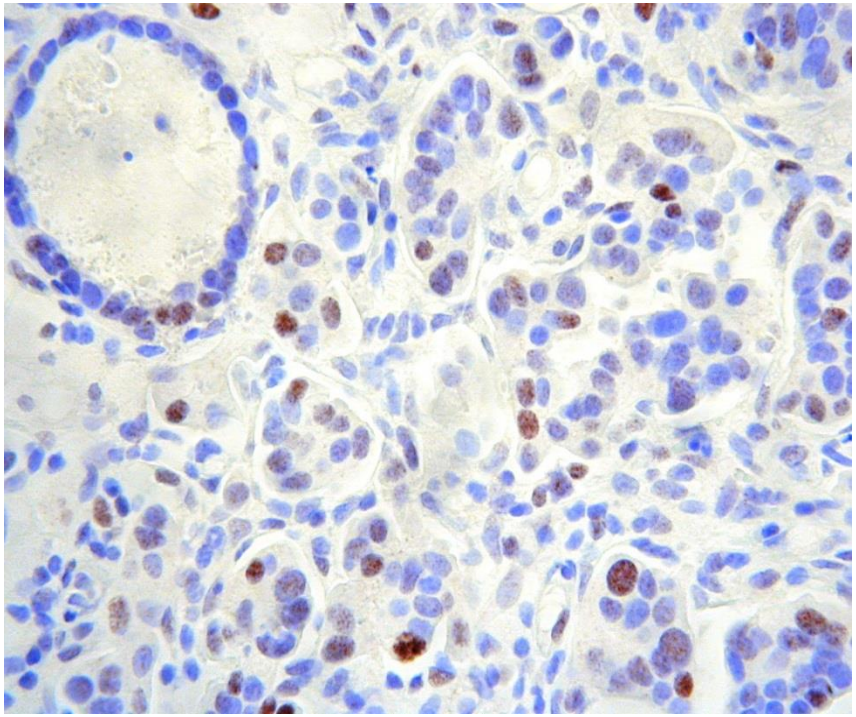

p53

EMA- “INSIDE-OUT” PATTERN

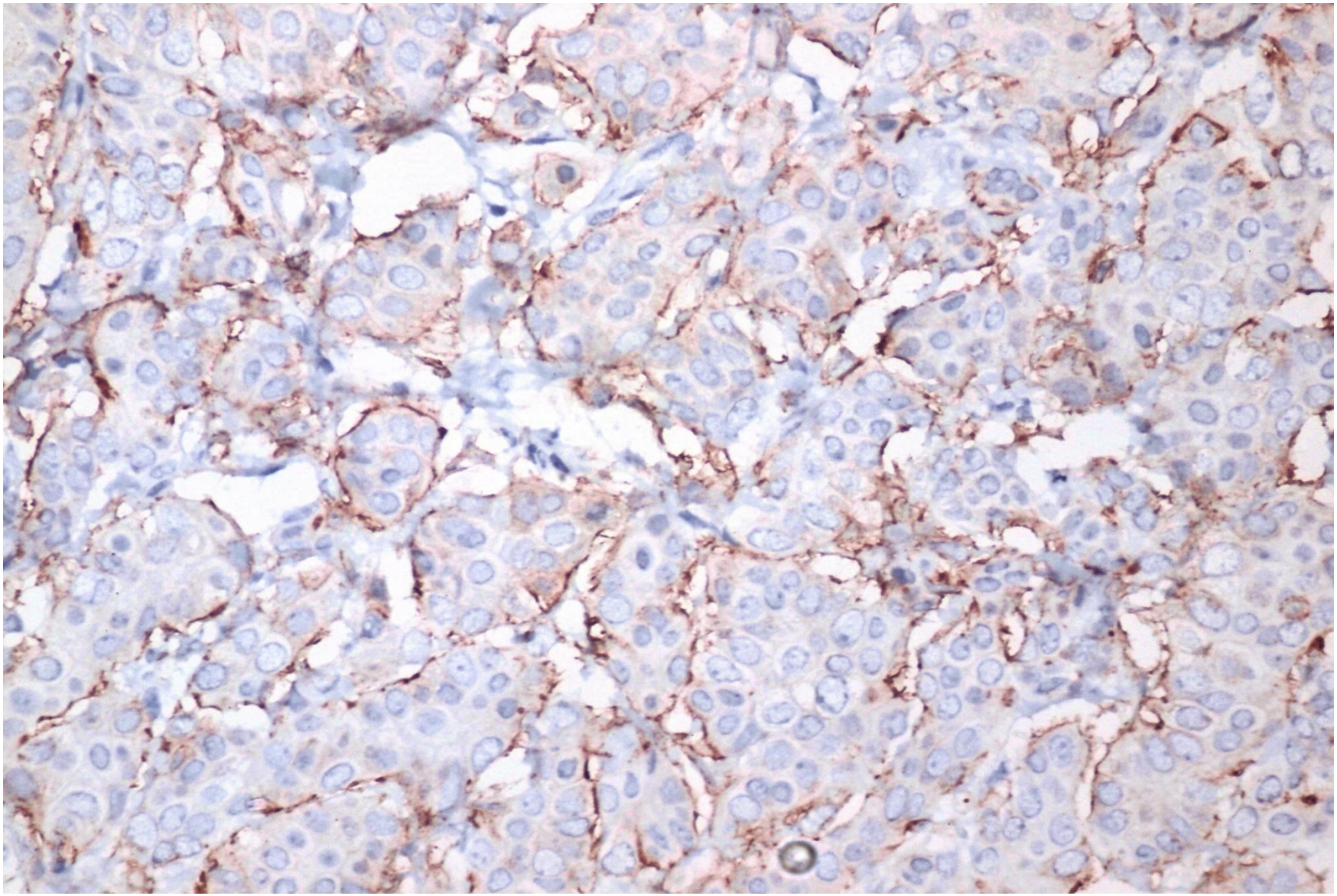

MICROPAPILLARY ADENOCARCINOMAS

- Reported in many organs- breast, urinary tract, lung, colon etc
- Small cohesive micropapillary arrangements of cells, no fibrovascular cores, often in clear spaces resembling vessels
- Usually aggressive behaviour (poor prognosis)
- Often extensive lymphovascular involvement

HPV-ASSOCIATED MUCINOUS- WHO 2020

- Mucinous, NOS (>50% intracytoplasmic mucin) – thought to have worse prognosis than usual-type (NOT PROVEN- NEED MORE STUDIES)
- Intestinal-type (>50% goblet cells)
- Signet ring-cell type
- Invasive SMILE

MUCINOUS, NOS

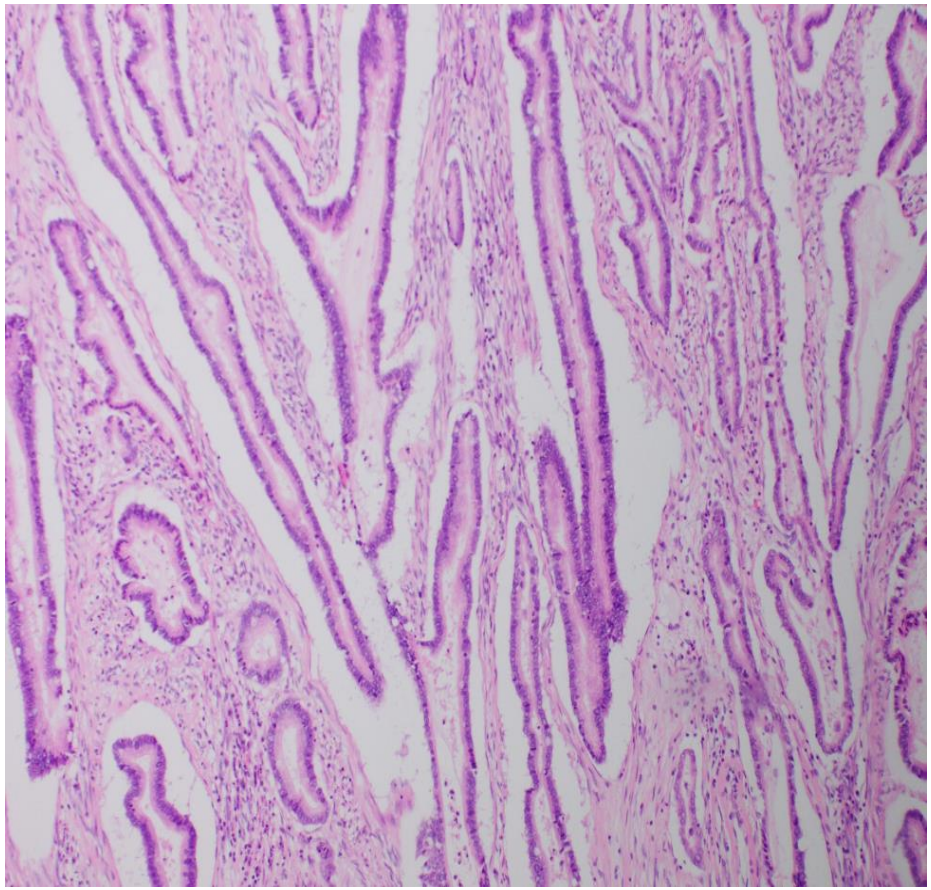

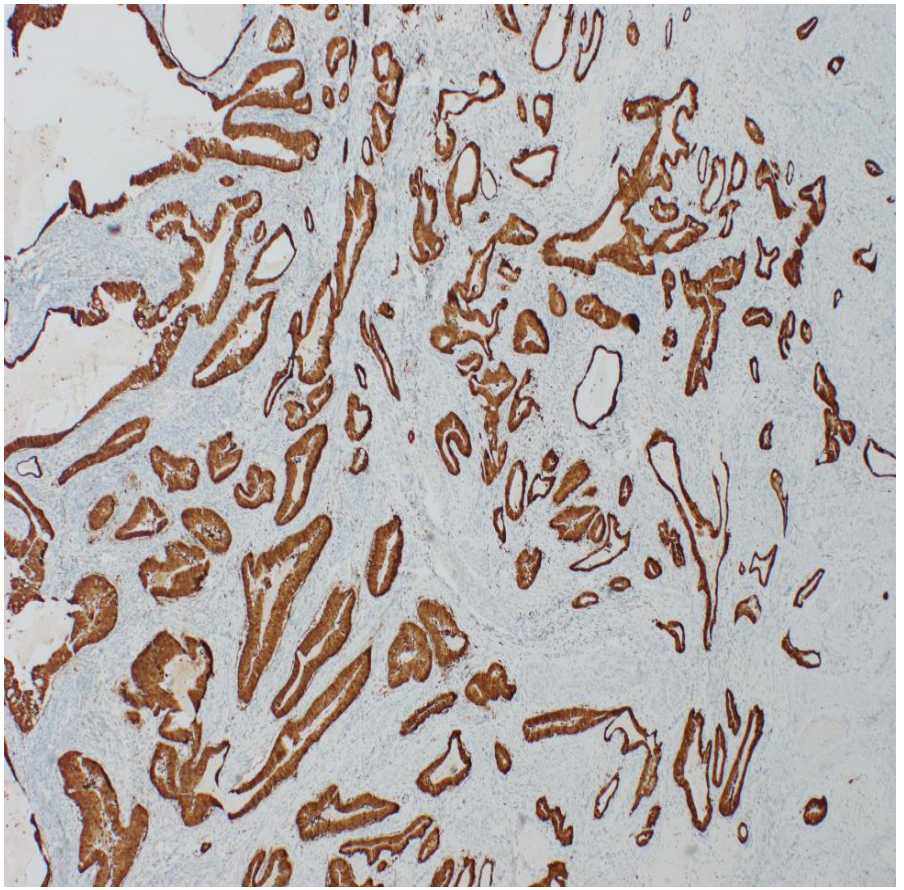

p16

SIGNET RING-CELL ADENOCARCINOMA

- rare
- usually associated with component of usual-type HPV-associated adenocarcinoma
- if pure, think of spread from stomach, breast, elsewhere
- subtype of HPV-associated mucinous adenocarcinoma and p16 block-type (occasionally see signet ring cells in HPV-independent cervical adenocarcinomas)

SIGNET RING-CELL

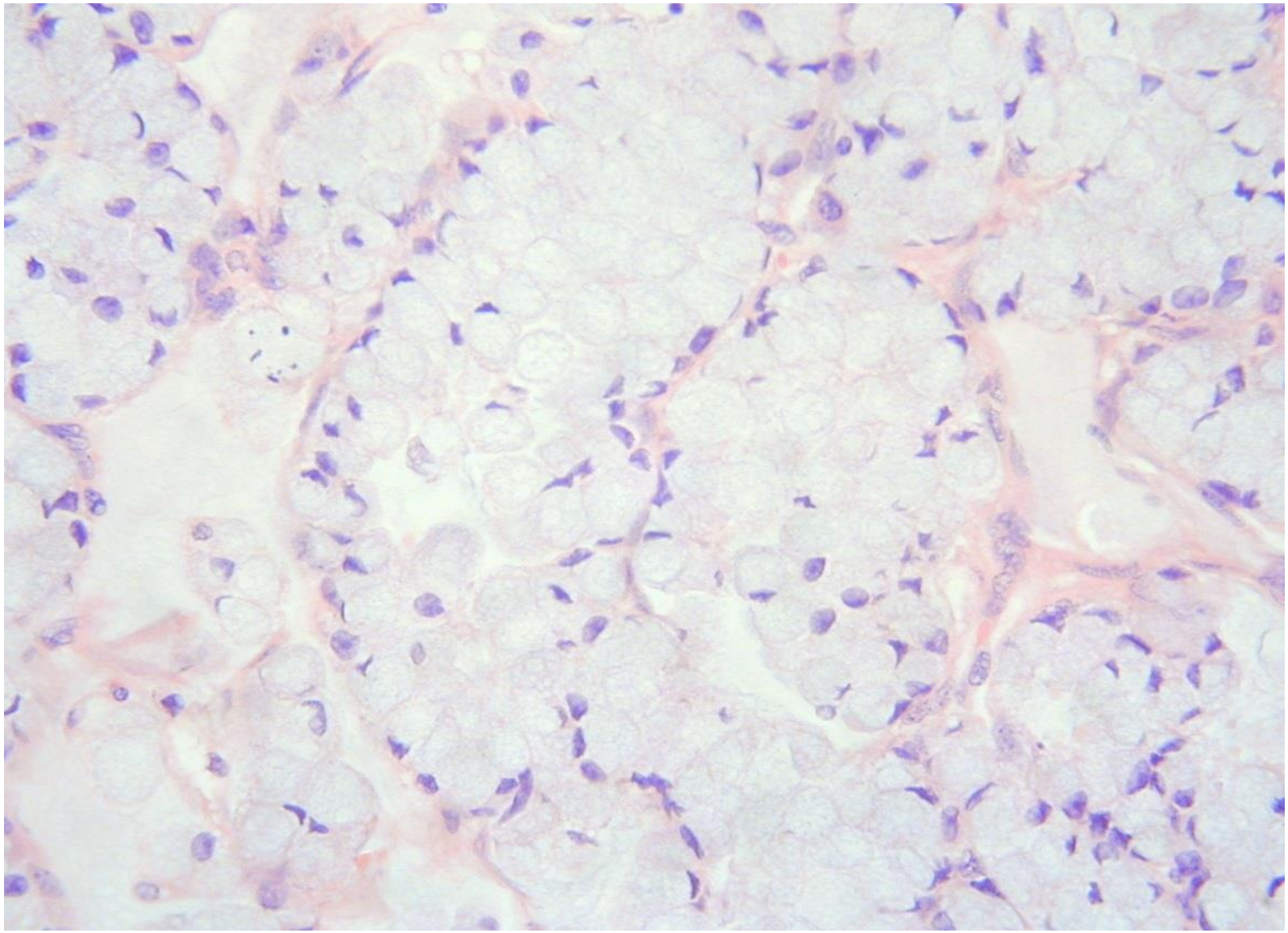

INVASIVE STRATIFIED MUCIN PRODUCING CARCINOMA (INVASIVE SMILE) (AJSP 2016; 40; 262-269; PMID 26523540)

- SMILE (stratified mucin producing intraepithelial lesion); variant of reserve cell dysplasia with features of both CIN and AIS
- Can get invasive counterpart
- Poor prognosis
- Included as variant of mucinous HPV-associated in WHO 2020

INVASIVE SMILE

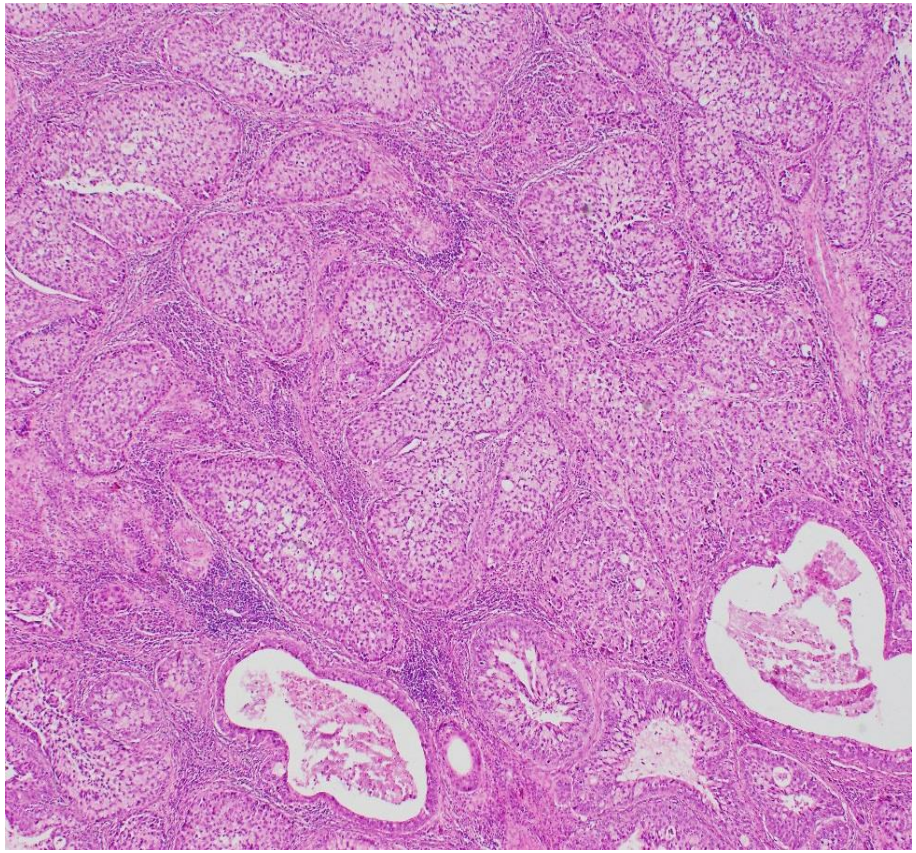

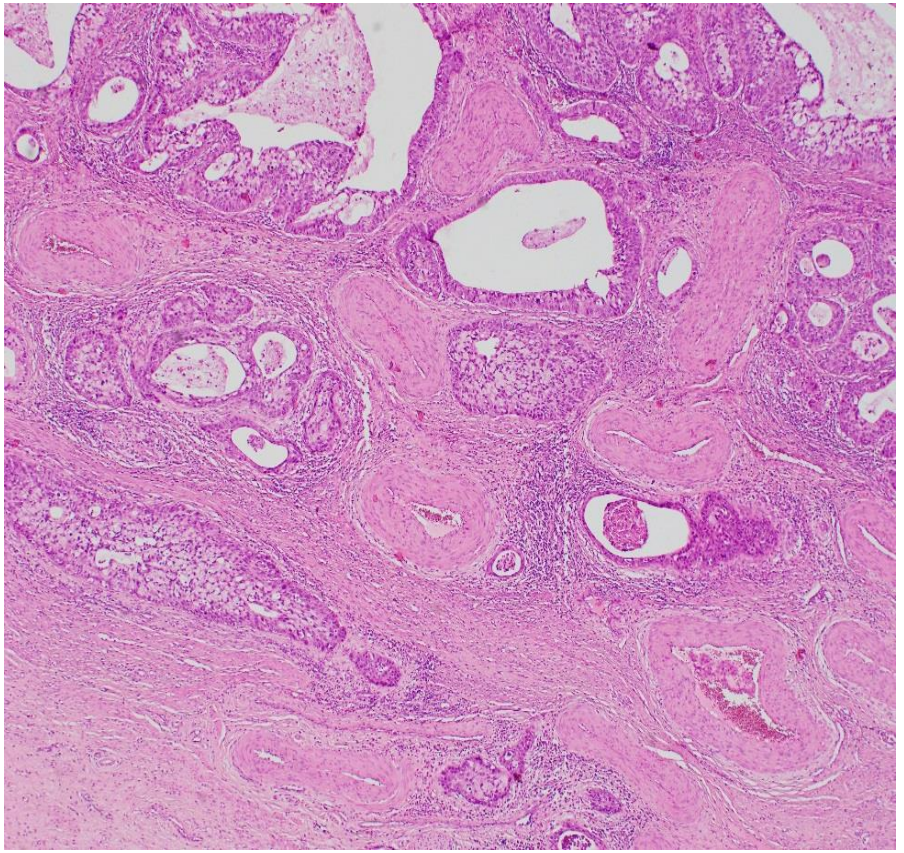

INVASIVE SMILE

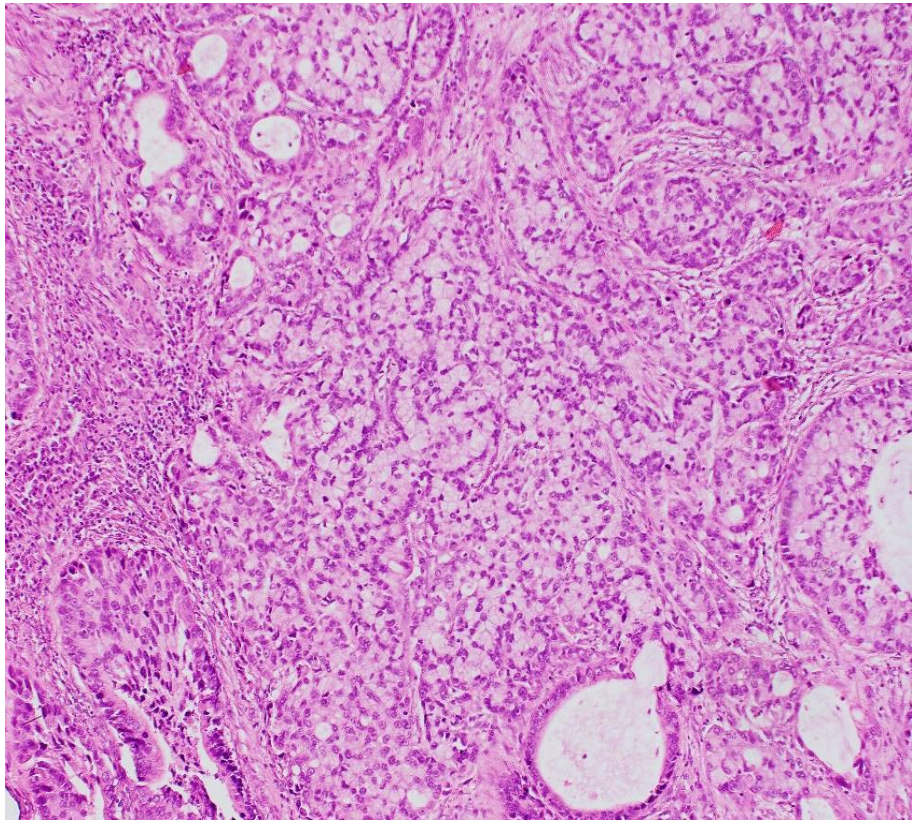

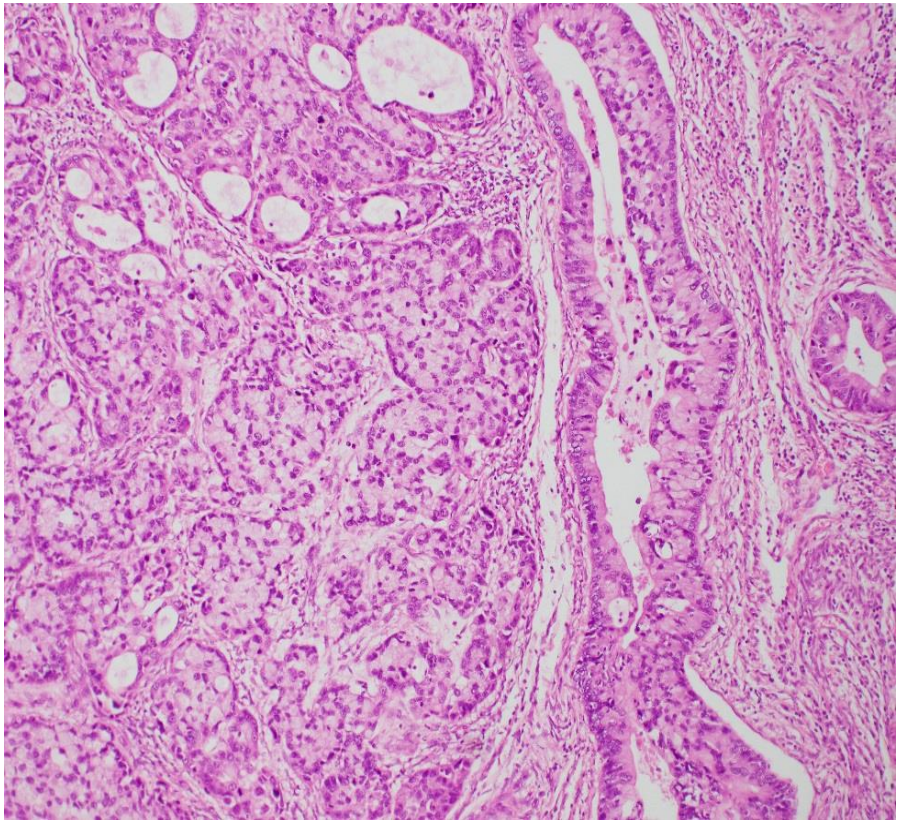

INVASIVE SMILE

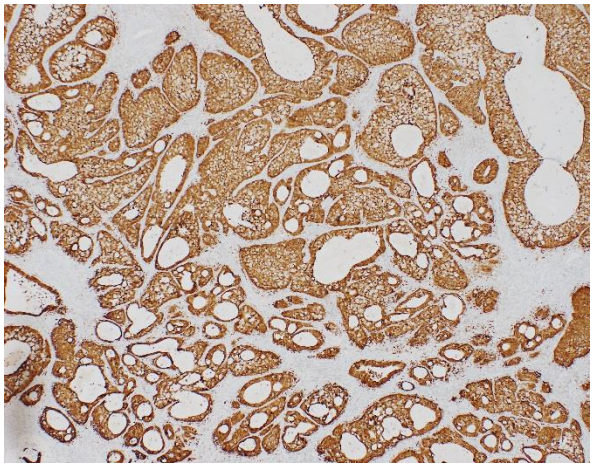

p16

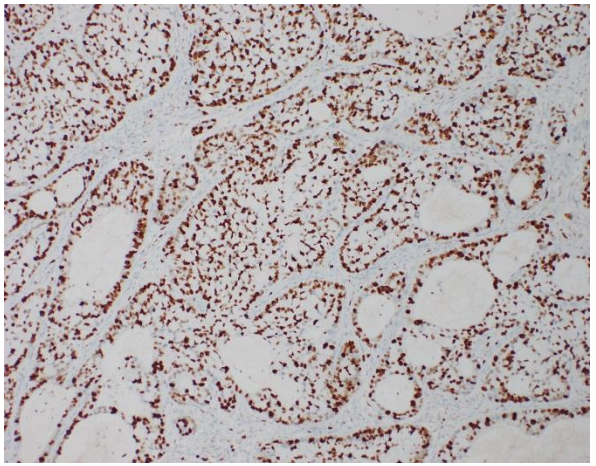

MIB1

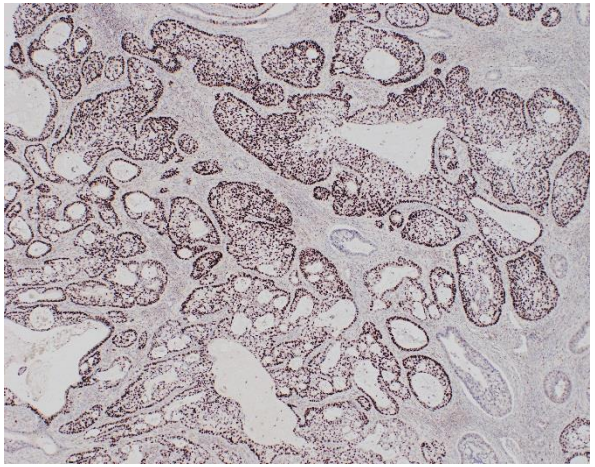

p63

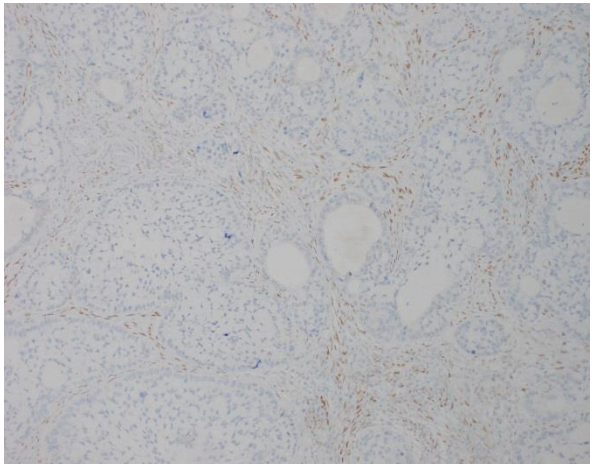

ER

GRADING OF CERVICAL ADENOCARCINOMAS

- No validated grading system
- ICCR recommends to grade HPV-associated adenocarcinomas using FIGO grading system for uterine endometrioid adenocarcinomas (NON-CORE ELEMENT)
- **ISGyP cervical adenocarcinoma project- recommend to grade some HPV-associated adenocarcinomas using modified FIGO grading (10% rather than 5% cut-off)**

ISGyP RECOMMENDATION

- HPVA cervical adenocarcinomas (with some exceptions) should be graded using a combination of architecture and cytology. Do not grade micropapillary, signet ring, invasive SMILE regardless of percentage of component (regarded as high-grade)
- HPVA cervical adenocarcinomas with ≤10% solid growth are Grade 1, 11-50% solid growth Grade 2 and >50% solid growth Grade 3. Tumours can be upgraded in the presence of marked nuclear atypia involving >50% of the tumour.
- HPVI adenocarcinomas should not be graded; in particular, gastric-type adenocarcinomas should not be graded but considered high-grade regardless of morphology.
- Cervical adenocarcinoma admixed with neuroendocrine carcinoma should not be graded but considered high-grade regardless of morphology.

HPV-INDEPENDENT CERVICAL ADENOCARCINOMAS

- emerging category of primary cervical adenocarcinomas (about 10-15% of all adenocarcinomas; 2-4 % of all cervical carcinomas)
- tend to be older than HPV-associated adenocarcinomas
- **gastric type (including adenoma malignum) is most common**
- clear cell carcinoma
- mesonephric adenocarcinoma
- endometrioid adenocarcinoma (very rare)- included in other adenocarcinomas in WHO 2020
- HPV screening programmes will not detect
- HPV vaccination will not prevent
- precursor lesions not well defined

HPV-independent adenocarcinoma

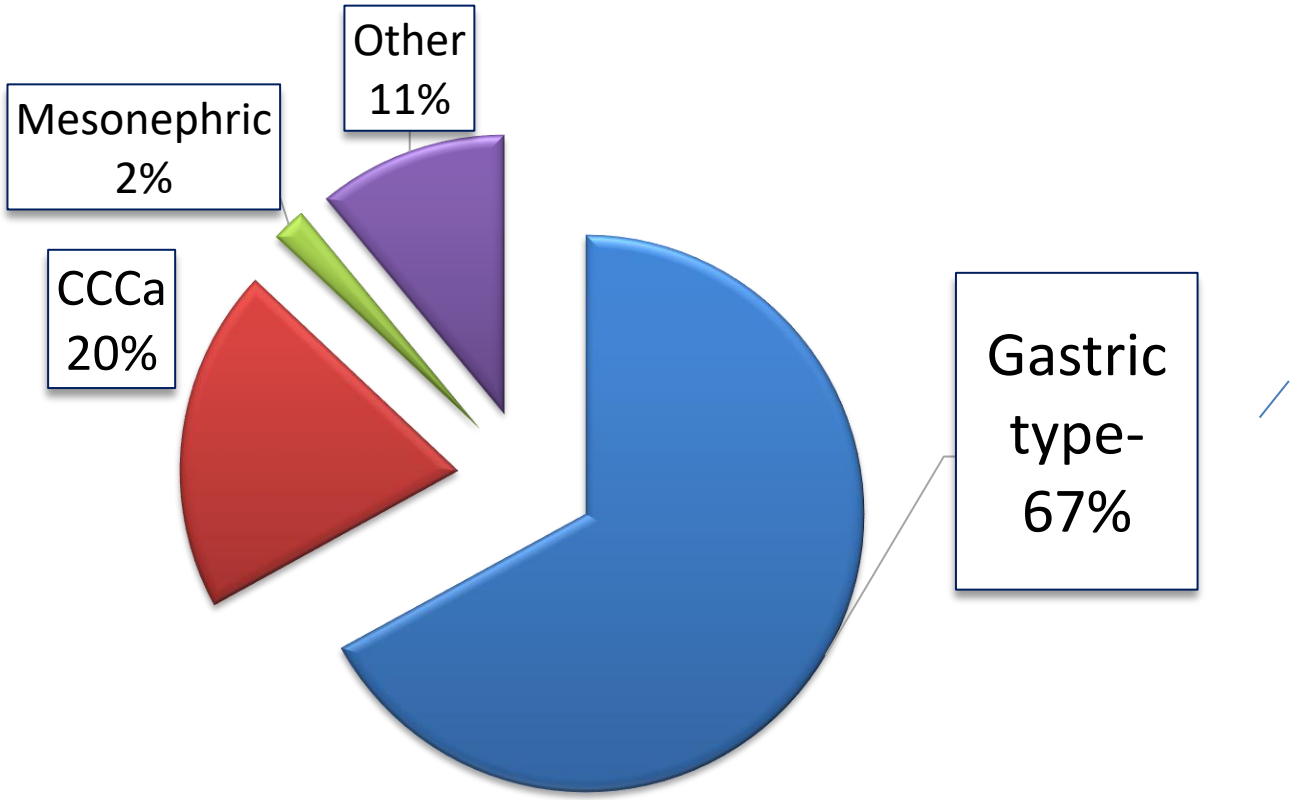

ADENOMA MALIGNUM

- mucinous variant of minimal deviation adenocarcinoma (MDA)
- uncommon variant of cervical adenocarcinoma
- **HPV-independent neoplasm**
- association with Peutz-Jeghers syndrome
- highly differentiated but in resection specimen almost always find areas of significant atypia
- known to exhibit gastric/pyloric differentiation (HIK 1083/MUC6 positive)

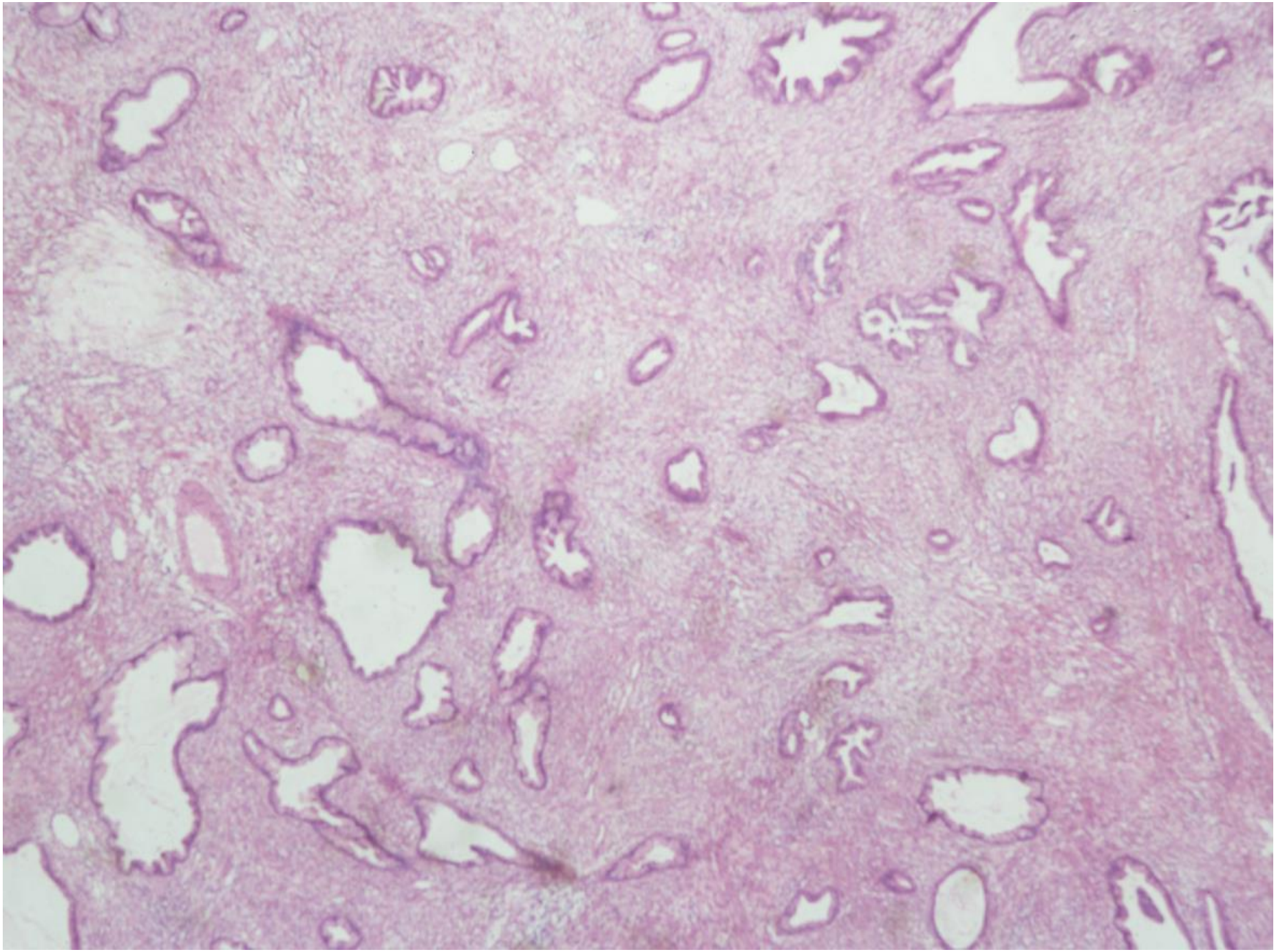



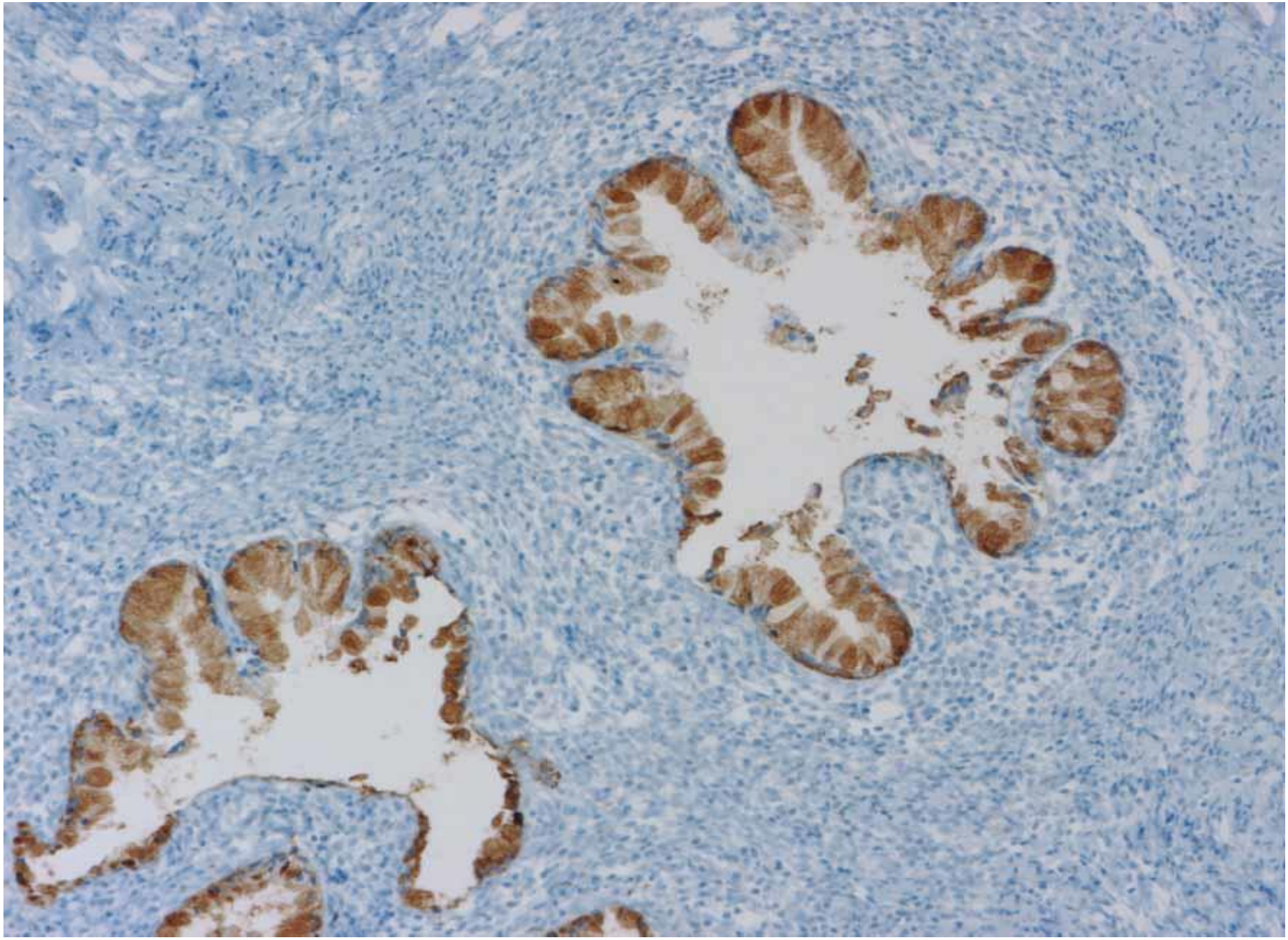

HIK1083

GASTRIC-TYPE CERVICAL ADENOCARCINOMA

- HPV-independent cervical adenocarcinoma
- cells with abundant clear or eosinophilic cytoplasm; sometimes prominent cell membranes; often lot of inflammatory cells
- often low mitotic and apoptotic activity
- variable morphology, including goblet cells, signet ring cells, papillary elements, squamous elements (form of adenosquamous carcinoma), neuroendocrine cells
- often positive with “gastric” markers (but don’t need to diagnose)
- second commonest form of cervical adenocarcinoma
- part of spectrum with adenoma malignum and often get admixtures (just call gastric-type adenocarcinoma)
- 10-15% have Peutz-Jeghers syndrome (worth mentioning on report)

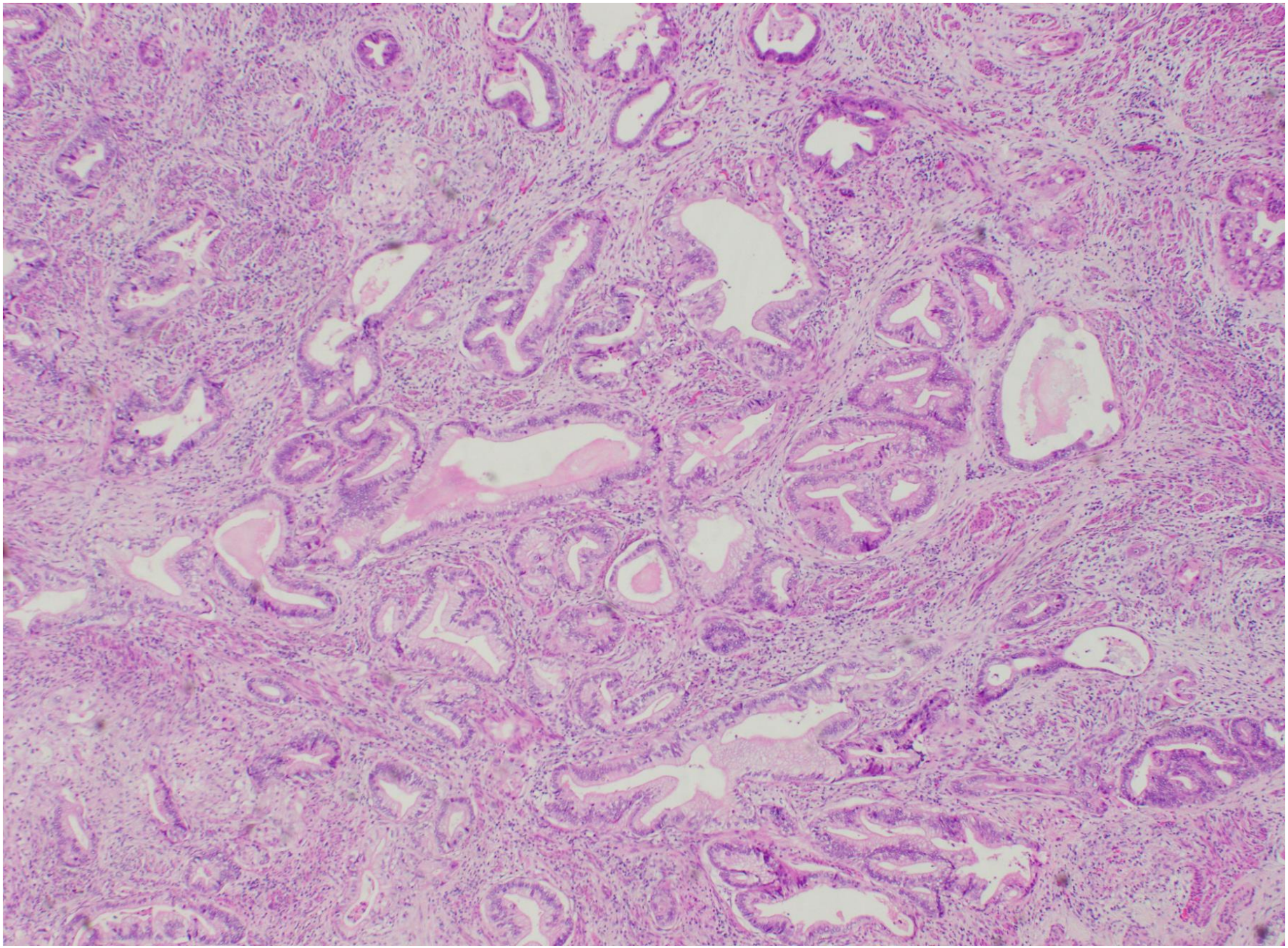

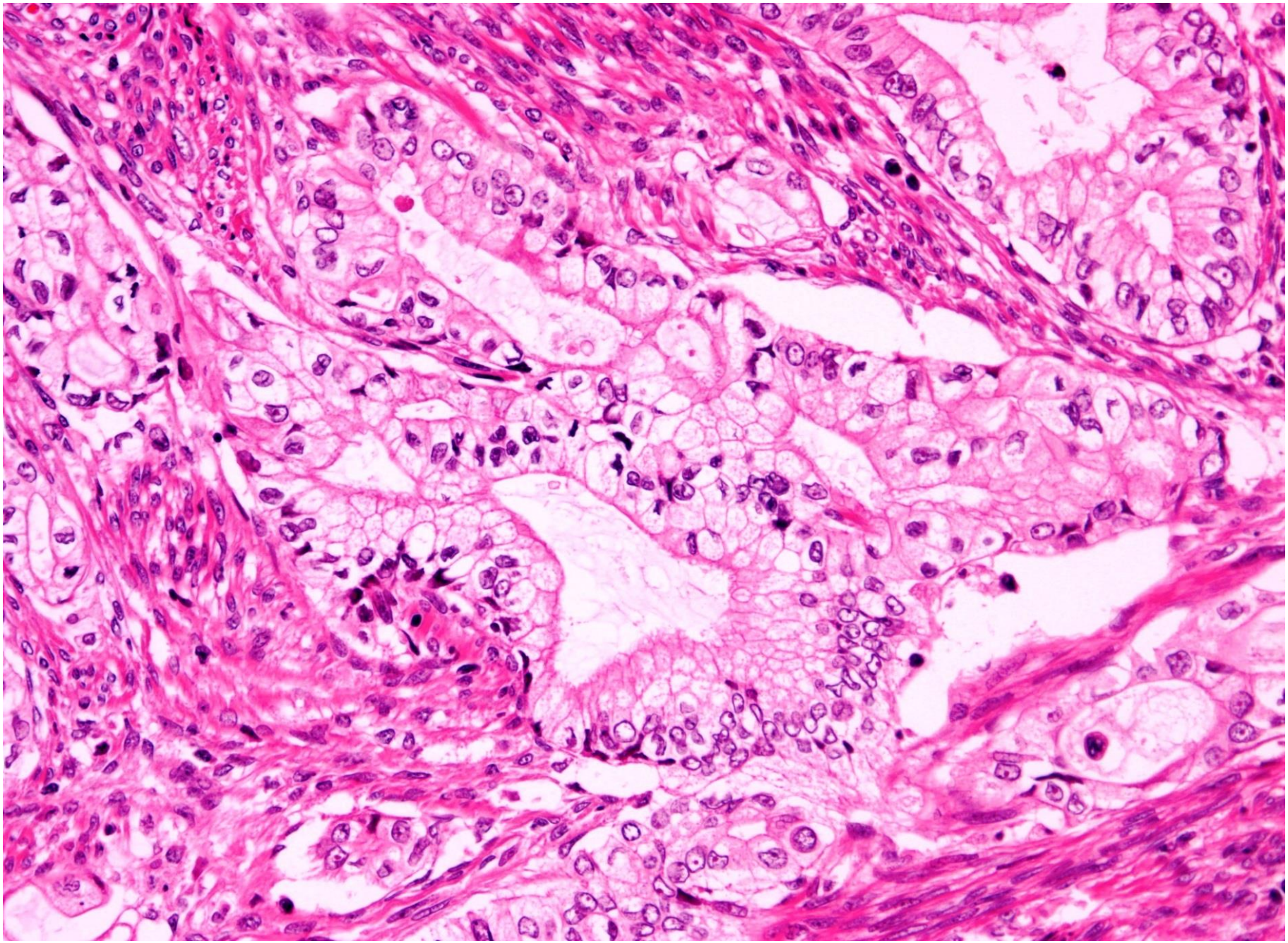

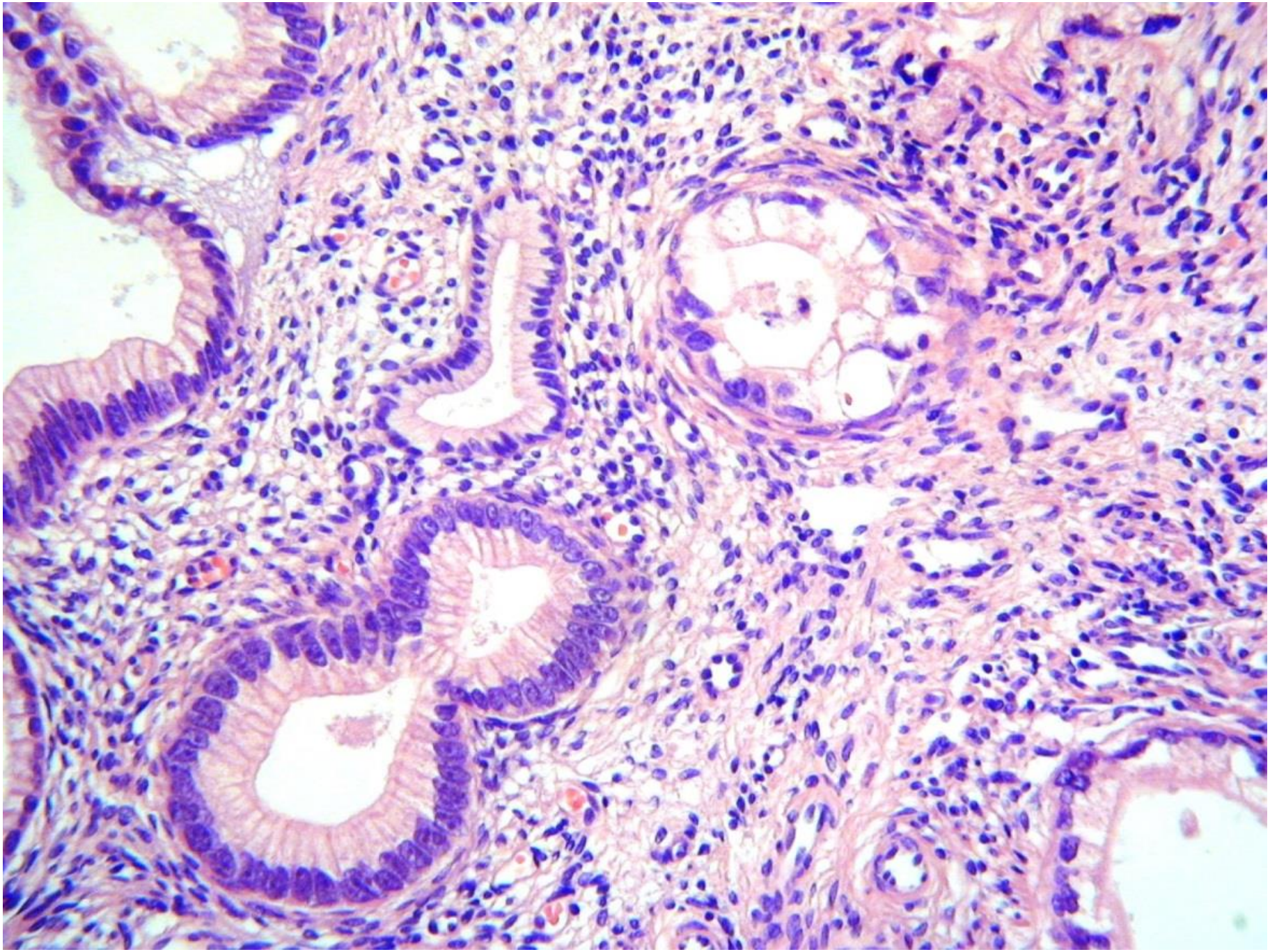

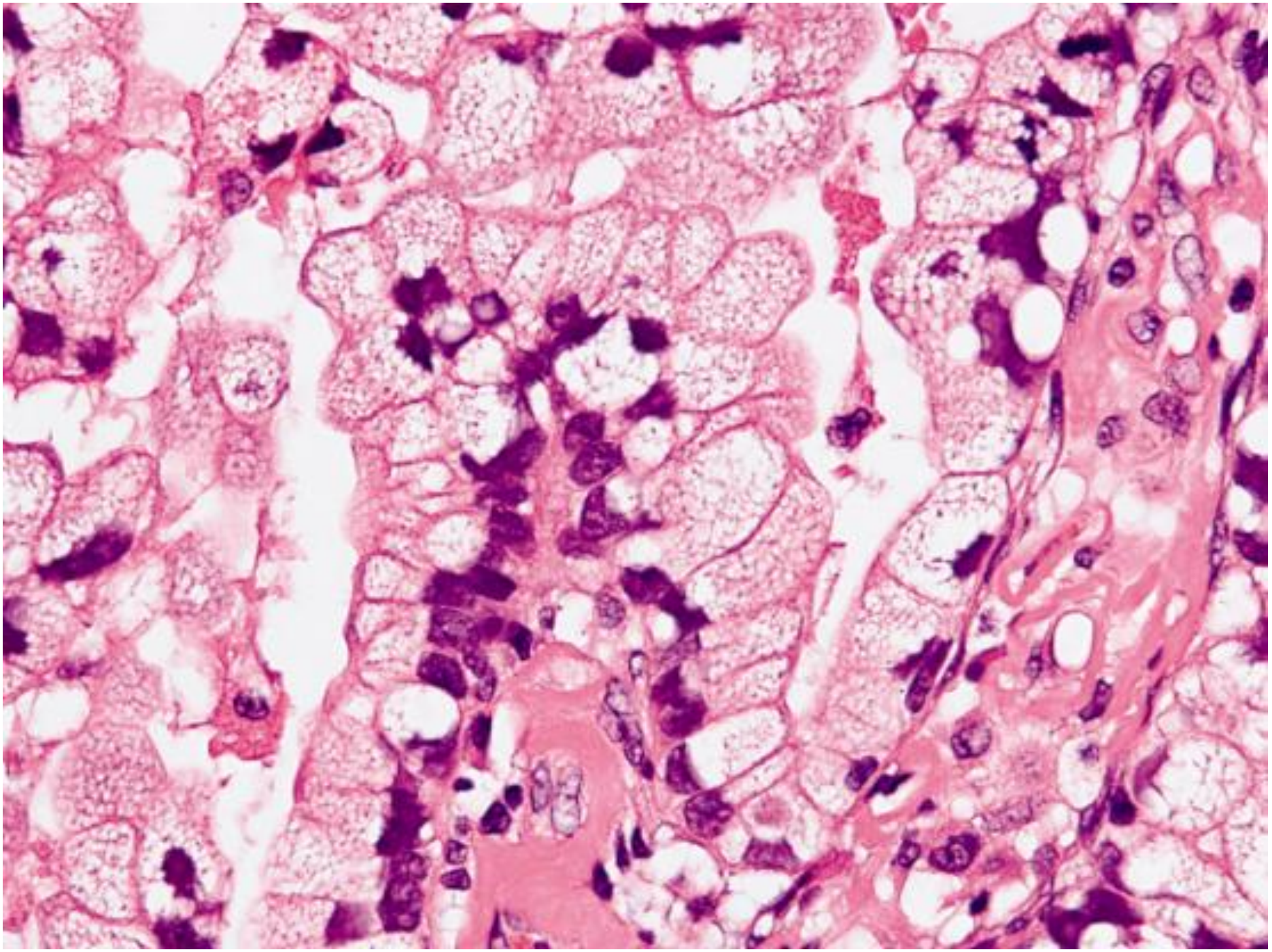

NEUROENDOCRINE CELLS

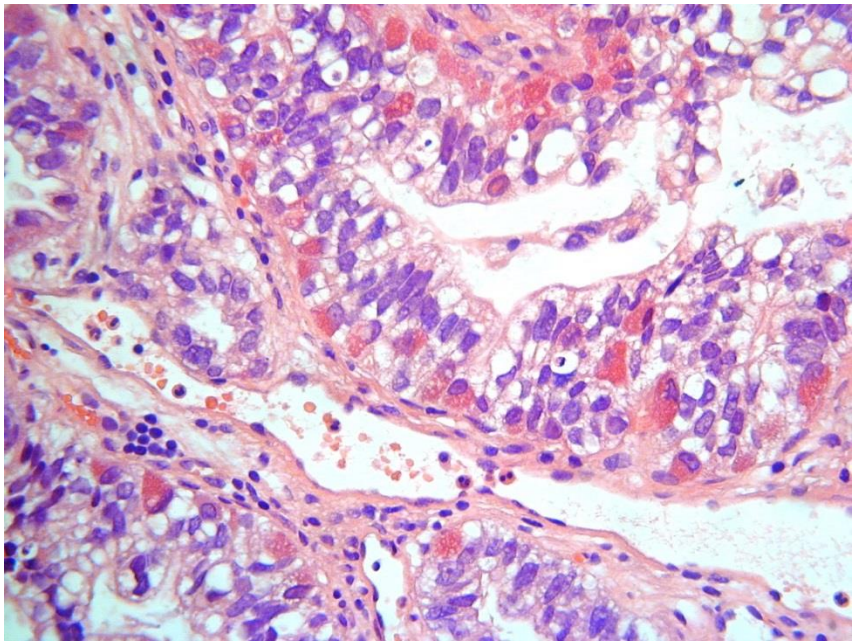

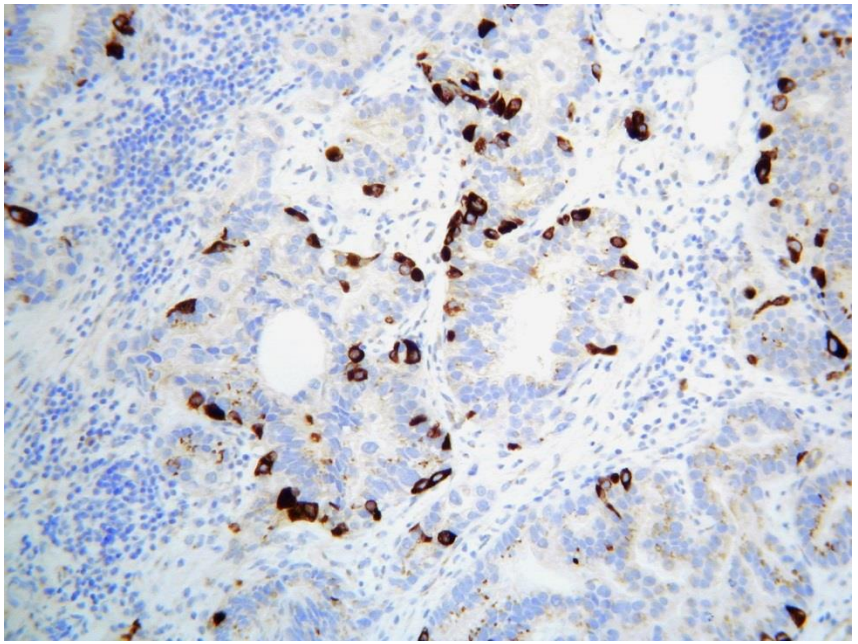

synaptophysin

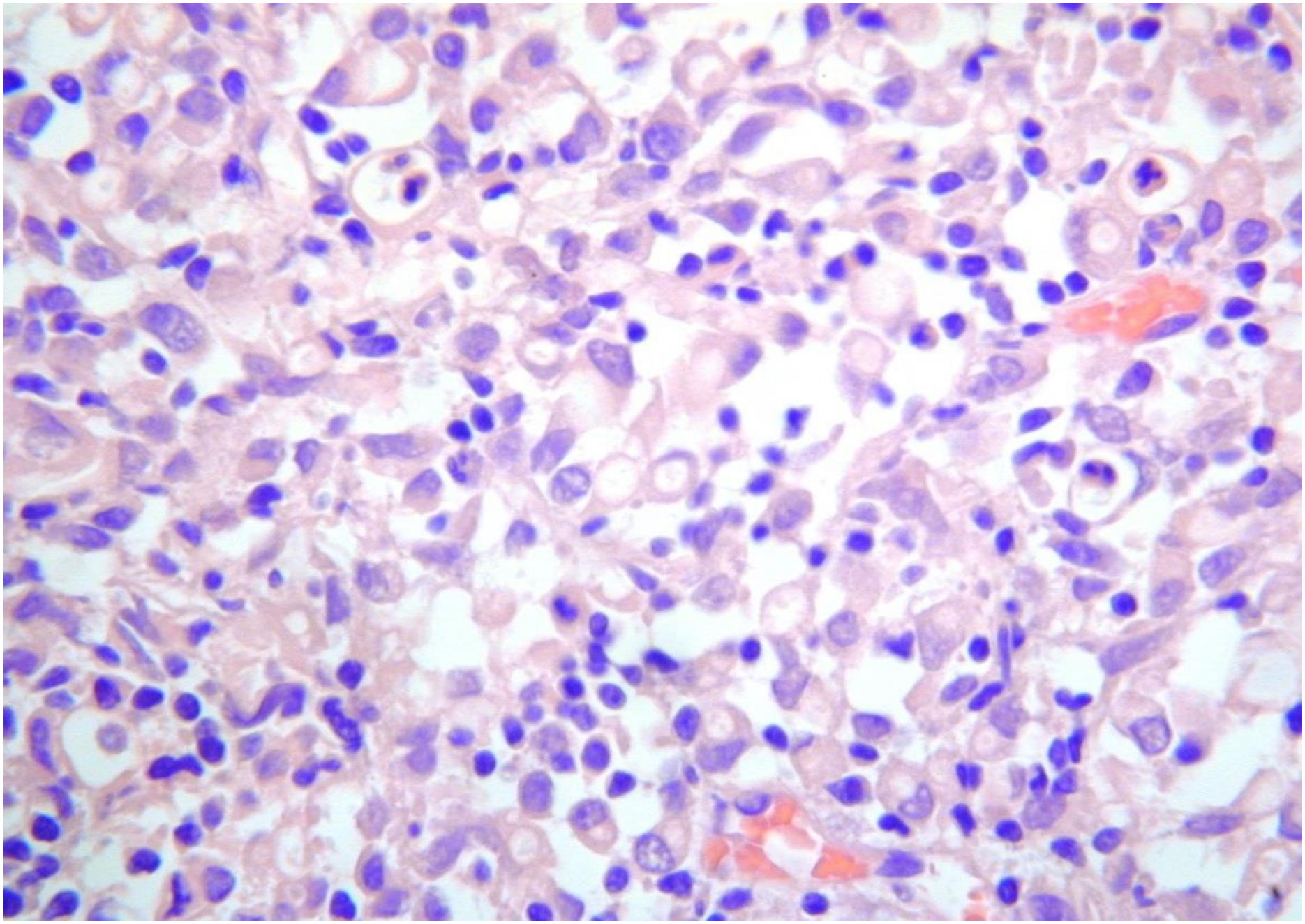

Signet ring cells

PROGNOSIS OF GASTRIC-TYPE

- poor prognosis with tendency to abdominal/adnexal and lung dissemination and metastasis to other unusual sites (5 year survival 30 versus 77% for usual type) (AJSP 2007;31;664-672)
- AJSP (2015;39;1449-1457): 59% stage II-IV at presentation; 50% lymph node metastasis; 35% ovarian involvement; 20% abdominal involvement; disease specific survival at 5 years 42% versus 91% for usual type adenocarcinoma
- no survival differences between well differentiated (adenoma malignum) and more poorly differentiated (non-adenoma malignum) (don’t need to grade- consider all as one tumour type)

MOLECULAR OF GASTRIC-TYPE

- not much on molecular but some similar events to pancreaticobiliary adenocarcinomas
- MODERN PATHOLOGY in press (68 cases)- PMID 33318584
- *KRAS (18%), CDKN2A (18%), STK11 (10%), TP53 (41%), ERB2 (8%), ERB3 (10%), BRAF (4%)* mutations
- Some potentially targetable- ERB2/3

Modern Pathology
https://doi.org/10.1038/s41379-020-00726-1

ARTICLE

Massively parallel sequencing analysis of 68 gastric-type cervical adenocarcinomas reveals mutations in cell cycle-related genes and potentially targetable mutations

Pier Selenica[1,2] · Barbara Alemar[1] · Cathleen Matrai[3] · Karen L. Talia[4] · Emanuela Veras[5] · Yaser Hussein[6] · Esther Oliva[7] · Regina G. H. Beets-Tan[2] · Yoshiki Mikami[8] · W. Glenn McCluggage[9] · Takako Kiyokawa[10] · Britta Weigelt[1] · Kay J. Park[1] · Rajmohan Murali[1]

Received: 10 October 2020 / Revised: 28 October 2020 / Accepted: 29 October 2020
© The Author(s), under exclusive licence to United States & Canadian Academy of Pathology 2020

HER2

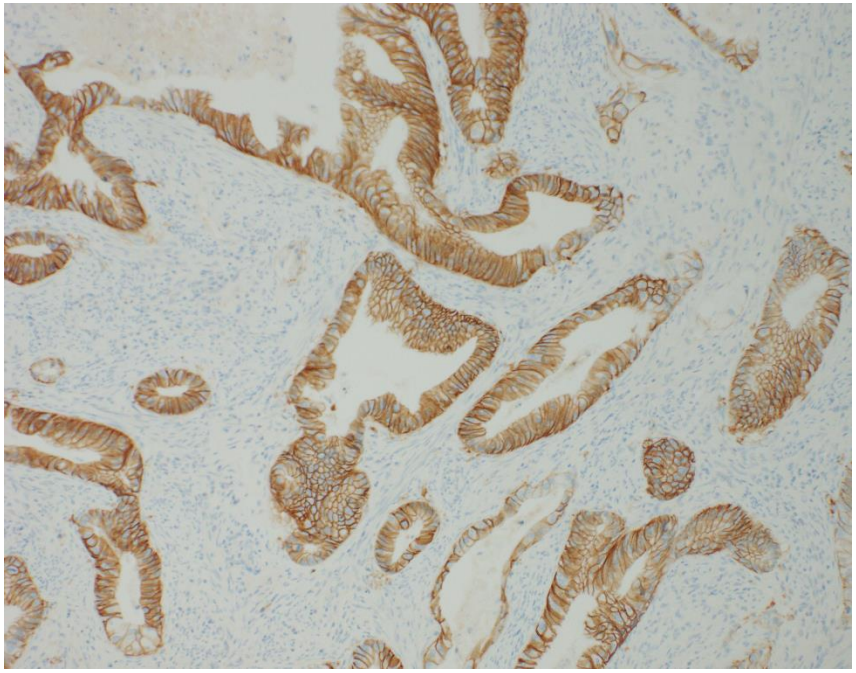

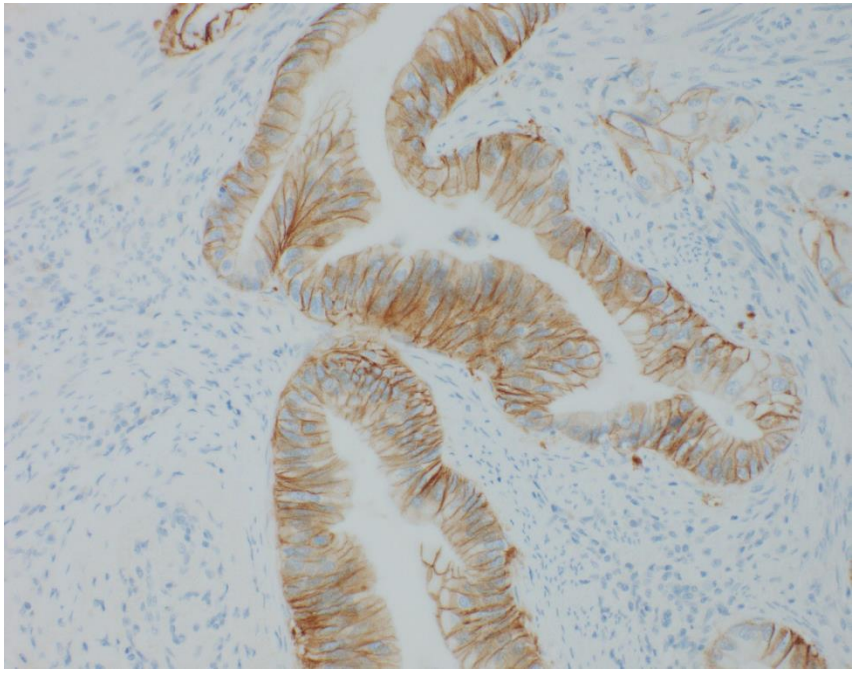

MANAGEMENT OF CERVICAL GASTRIC-TYPE ADENOCARCINOMAS

- Tumour type (variant of adenocarcinoma) not usually factored into treatment decisions
- ? More intense radiological assessment (adnexa and omentum) preoperatively
- Probably should remove ovaries routinely (tend to be older)
- Probably not suitable for trachelectomy **(ESGO GUIDELINES)**
- ? Poor response to chemotherapy, ? Choice of chemotherapy (may need different chemotherapeutic agents)

IMMUNOHISTOCHEMICAL RESULTS- GASTRIC TYPE ADENOCARCINOMA- AJSP 2016; 40; 636-633; PMID 26685087- 47 cases

- Lot of immunophenotypic overlap with pancreas/ biliary adenocarcinomas (CK7, CK20, CEA, CDX2, CA125, CA19.9 often positive)
- PAX8 may be useful (usually, but not always, diffusely positive)
- HNF1 beta- usually positive (differential with clear cell carcinoma)
- ER/PR- almost always “flat” negative (NOT ALWAYS)
- p53- about half “mutation-type” staining
- p16 usually negative/ non-block
- MUC6 usually (not always) positive
- 1 case in patient with Lynch syndrome (loss of MSH2 and MSH6)

CYTOKERATINS

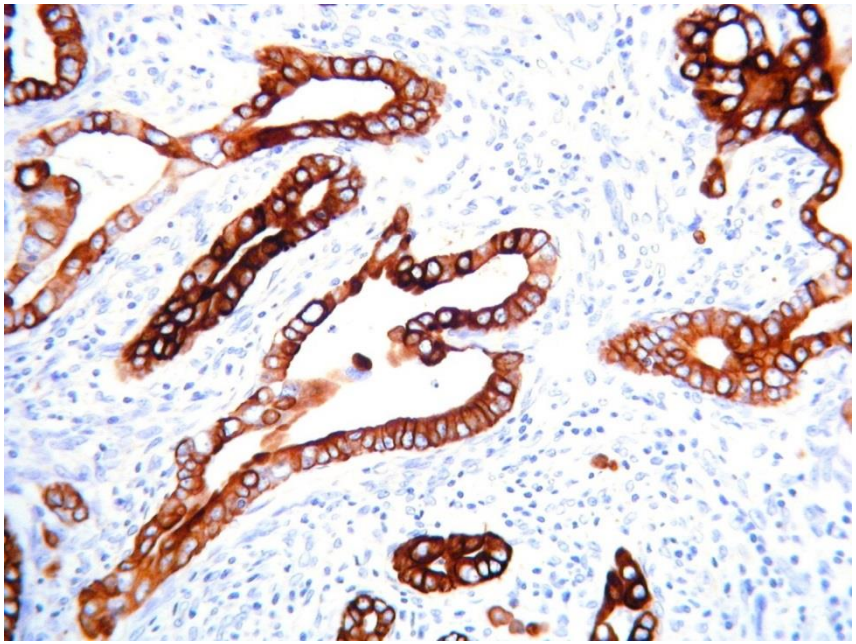

CK7

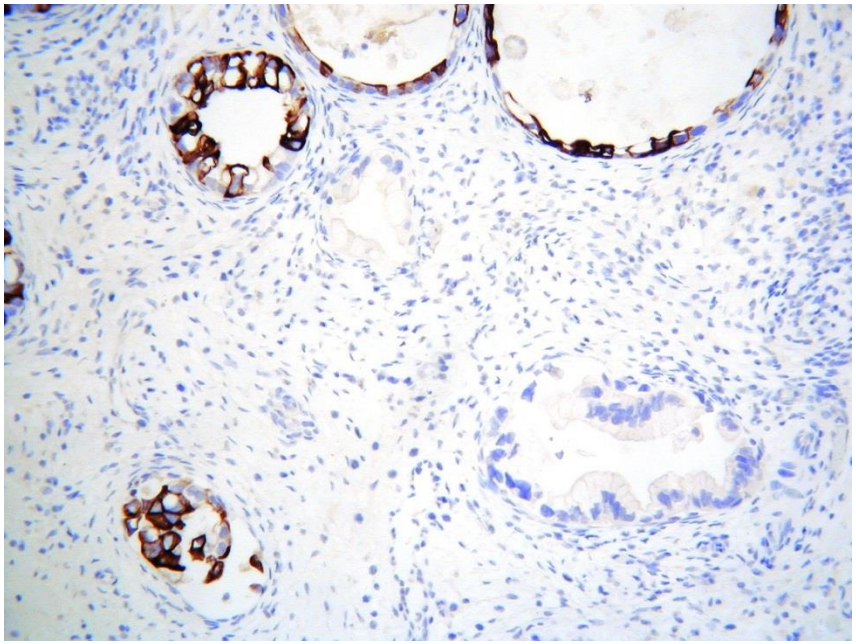

CK20

IMMUNOHISTOCHEMISTRY

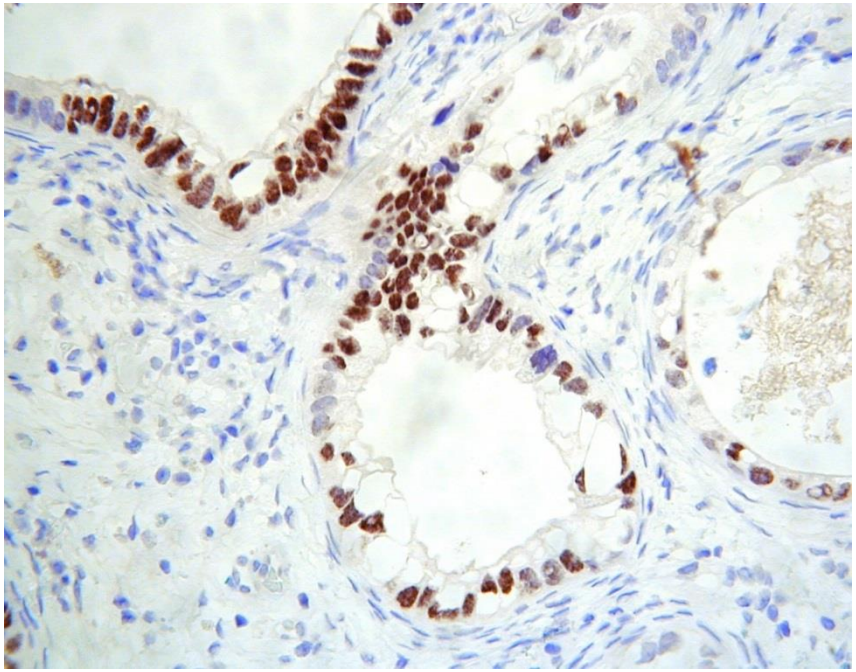

CDX2

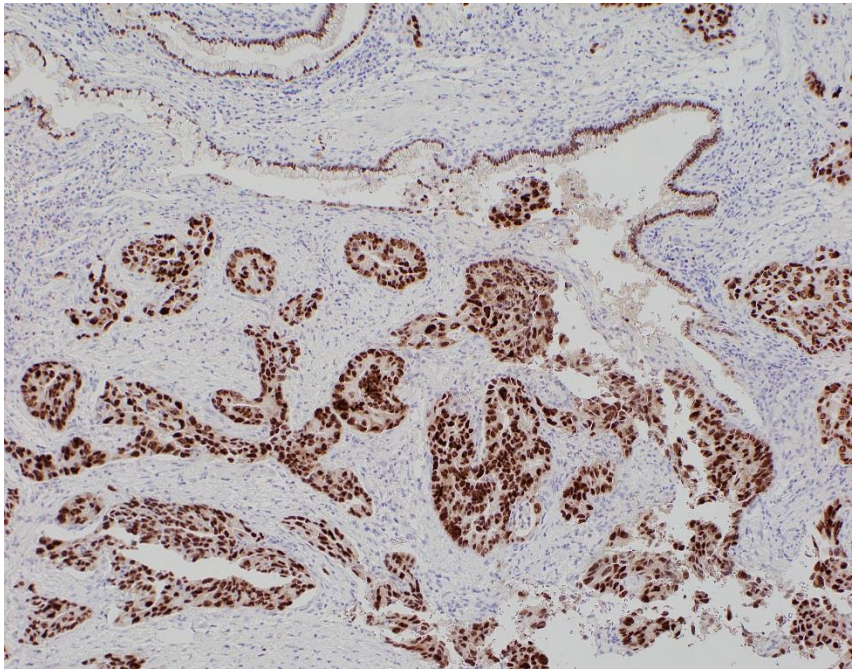

PAX8

IMMUNOHISTOCHEMISTRY

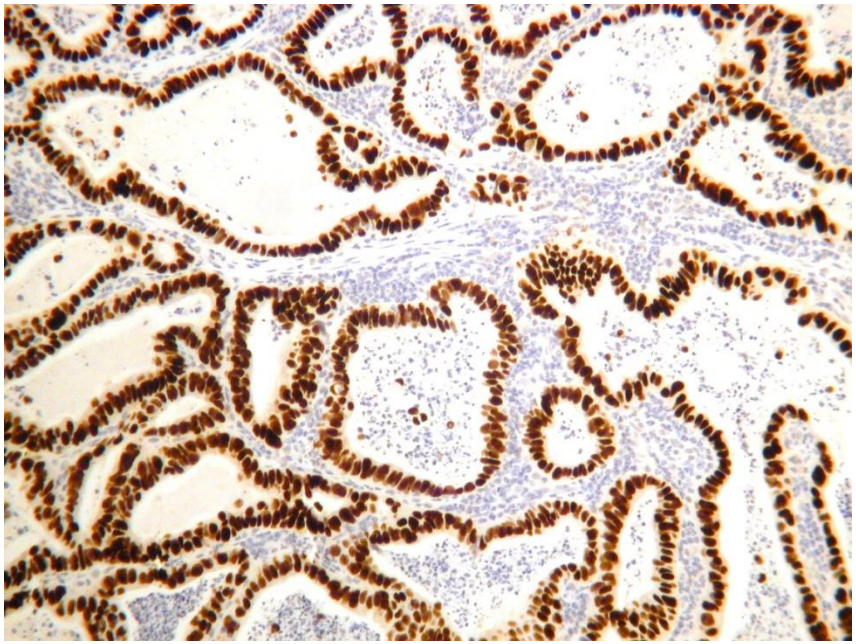

HNF1 beta

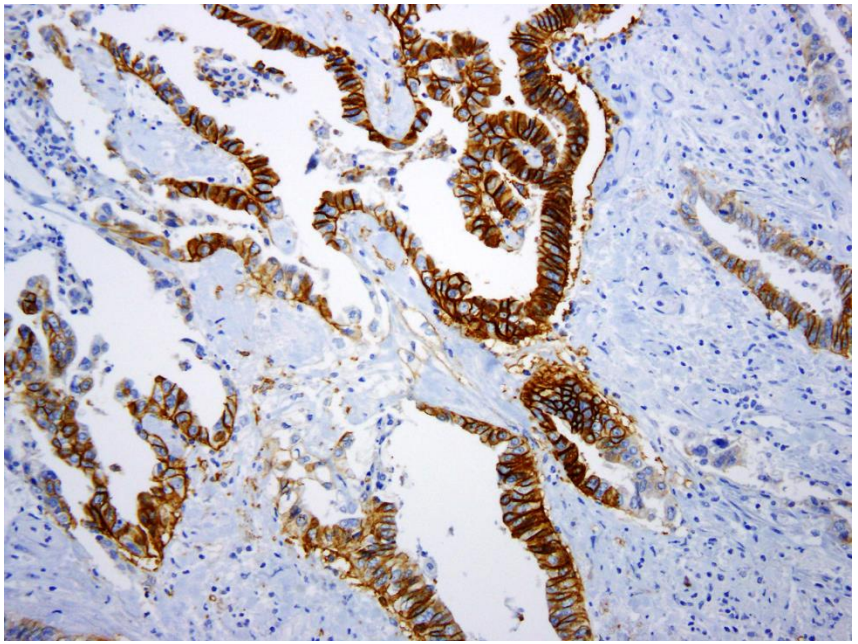

MUC6

p16

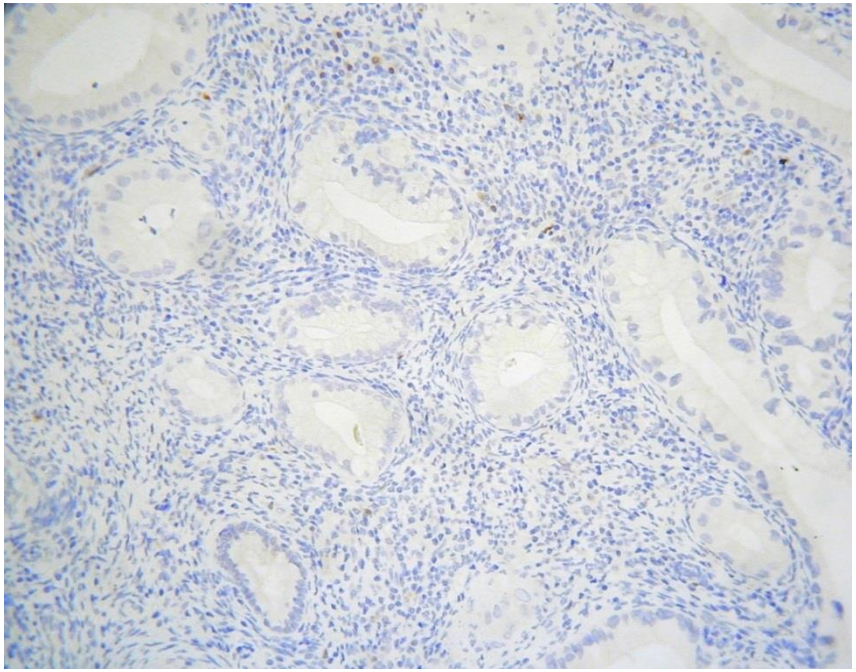

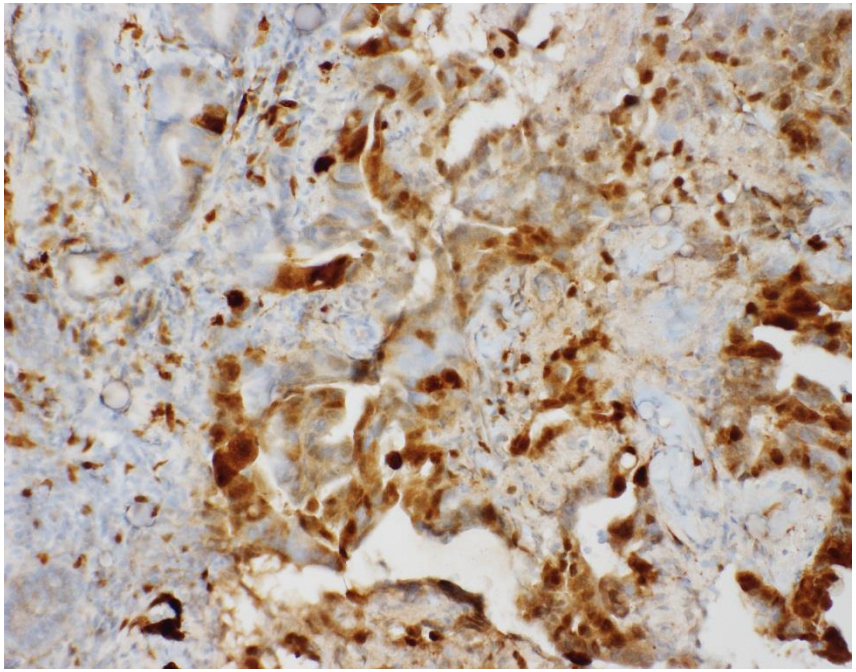

ER USUALLY NEGATIVE; RARELY FOCALLY POSITIVE

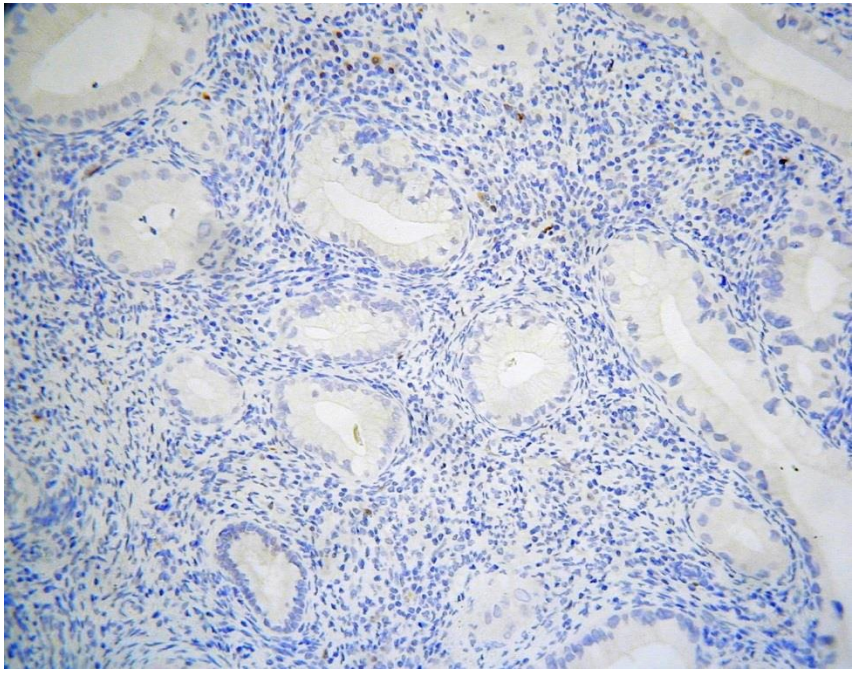

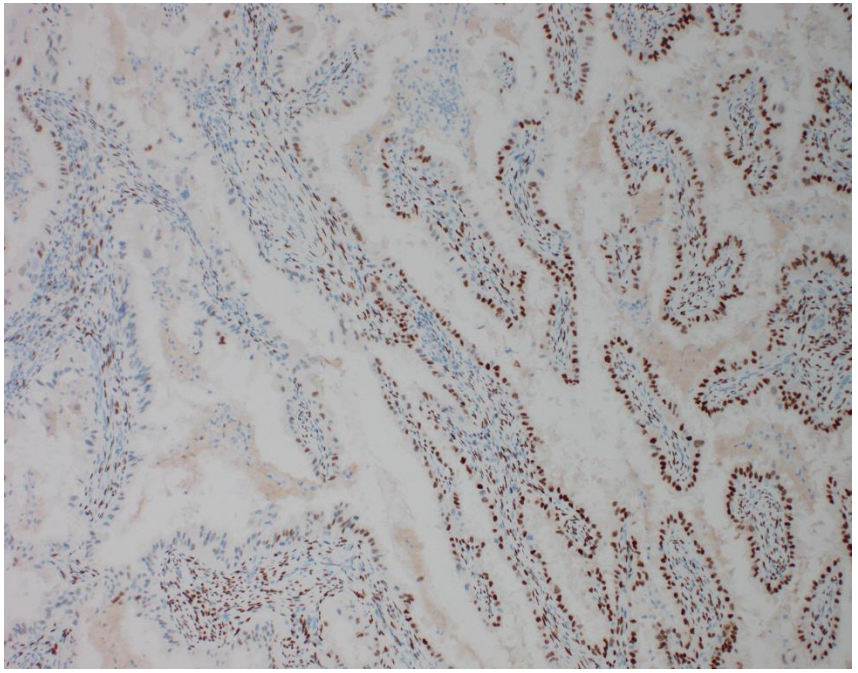

GASTRIC MARKERS

- Two most commonly used are MUC6 and HIK1083
- HIK1083- not widely available
- HIK1083- less sensitive but much more specific
- MUC6- quite sensitive but sometimes only focally positive
- MUC6- very non-specific (normal endocervical glands may be positive; HPV-associated adenocarcinomas may be positive; endometrial adenocarcinomas often positive; PMID 31021421)
- Other “gastric” markers (trefoil factor 2/ TFF2)

GASTRIC TYPE CERVICAL LESIONS- Advances in Anatomic Pathology 2013;20;227-237

BENIGN

lobular endocervical glandular hyperplasia (complex pyloric/gastric metaplasia)

simple gastric/pyloric metaplasia

type A tunnel cluster

PREMALIGNANT

atypical lobular endocervical glandular hyperplasia

adenocarcinoma in situ (AIS) of gastric type

MALIGNANT

gastric type adenocarcinoma

minimal deviation adenocarcinoma

SPECIFIC CONDITIONS

synchronous mucinous metaplasia and neoplasia of the female genital tract

Peutz-Jeghers syndrome

PMID 23752085

REVIEW ARTICLE

Endocervical Glandular Lesions Exhibiting Gastric Differentiation: An Emerging Spectrum of Benign, Premalignant, and Malignant Lesions

Yoshiki Mikami, MD and W. Glenn McCluggage, FRCPath†*

LOBULAR ENDOCERVICAL GLANDULAR HYPERPLASIA (LEGH)

- very rare
- sometimes associated with Peutz-Jeghers
- complex gastric (pyloric) metaplasia
- often high in endocervical canal
- positive with gastric markers
- may be difficult to distinguish from adenoma malignum
- MOST (NOT ALL) GASTRIC LESIONS ARE FLAT NEGATIVE WITH HORMONE RECEPTORS (ER, PR) (useful in distinction of LEGH from other benign glandular lesions)

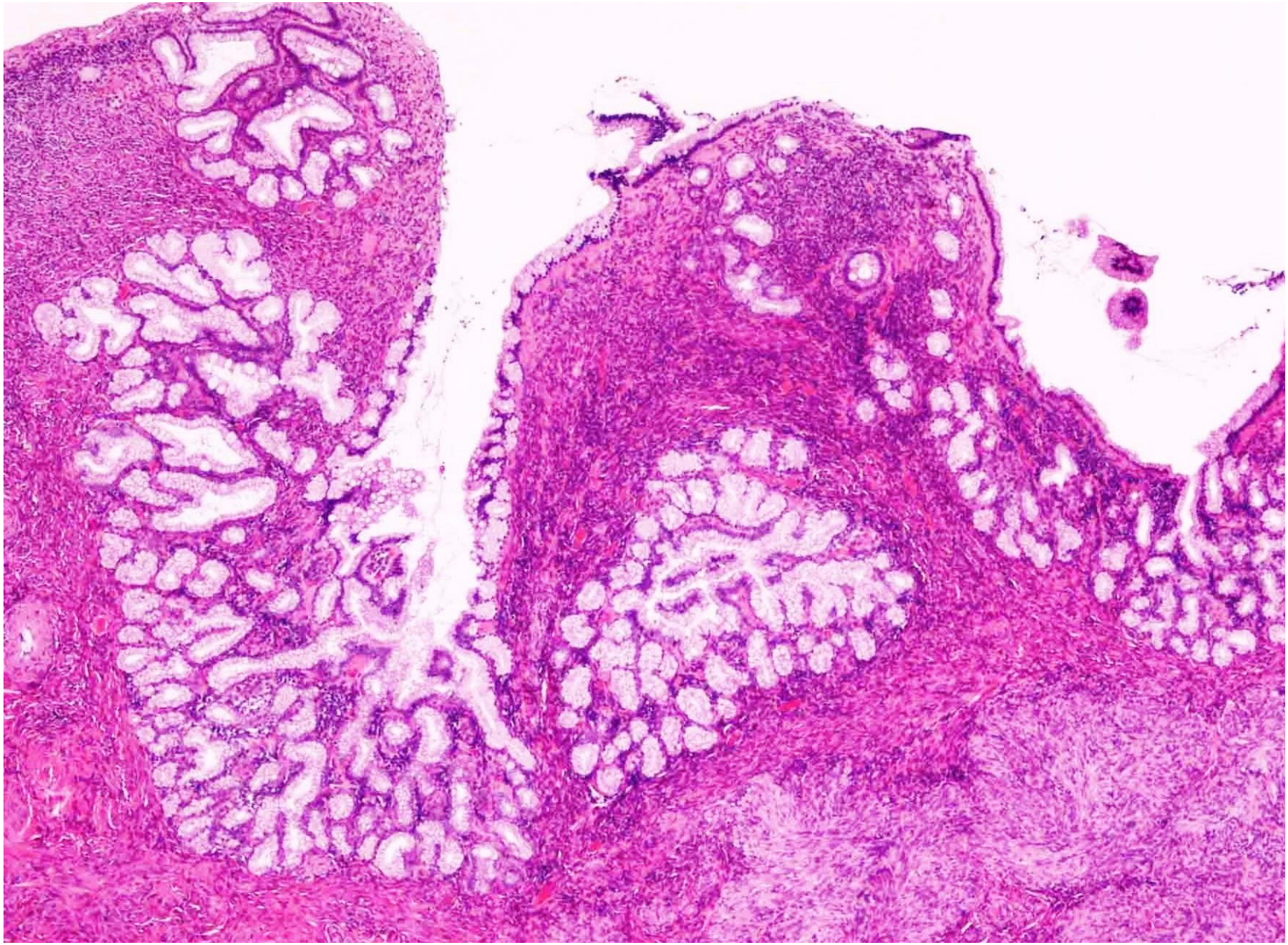

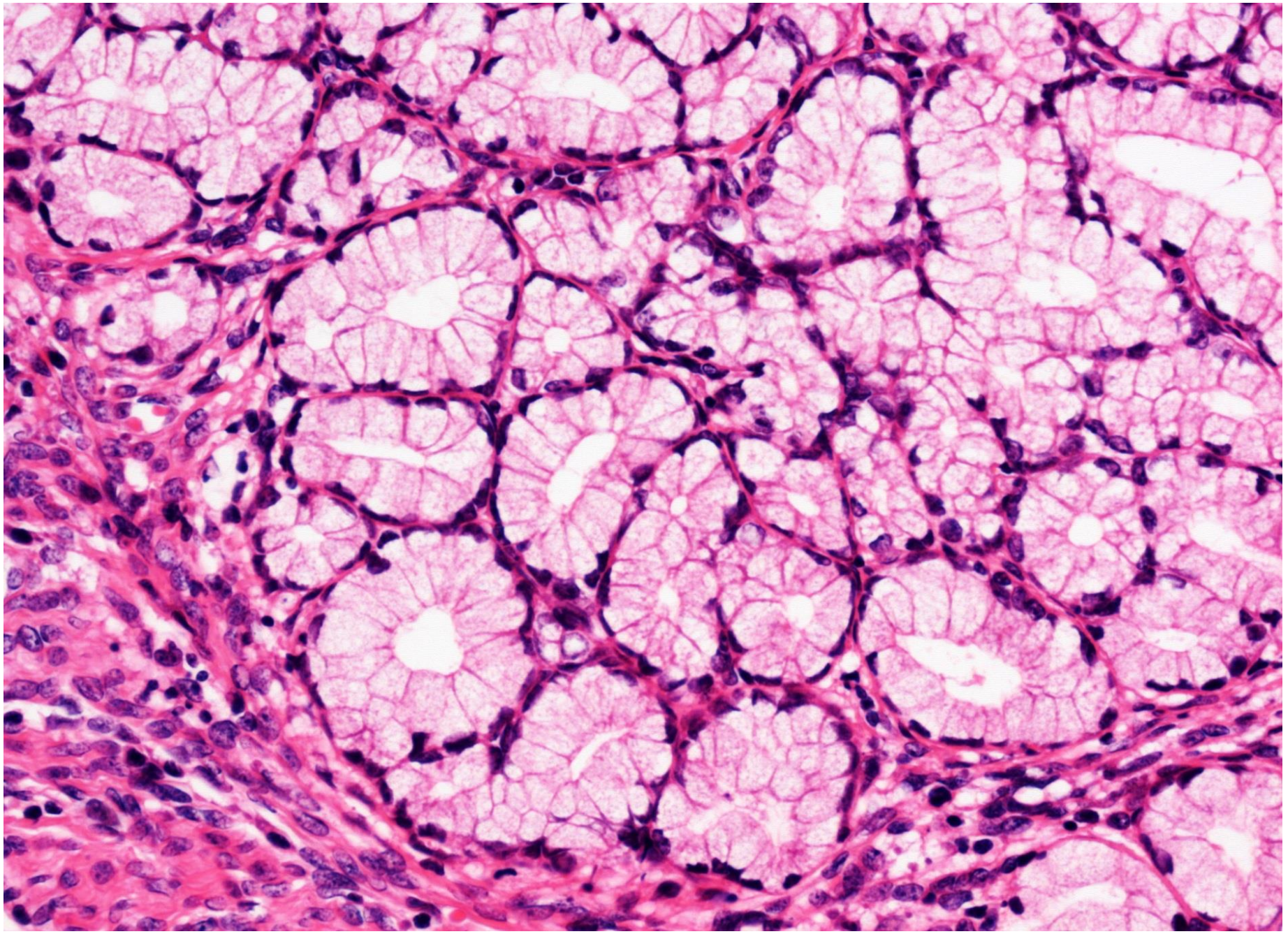

intestinal metaplasia/ goblet cells



NEUROENDOCRINE CELLS IN LEGH

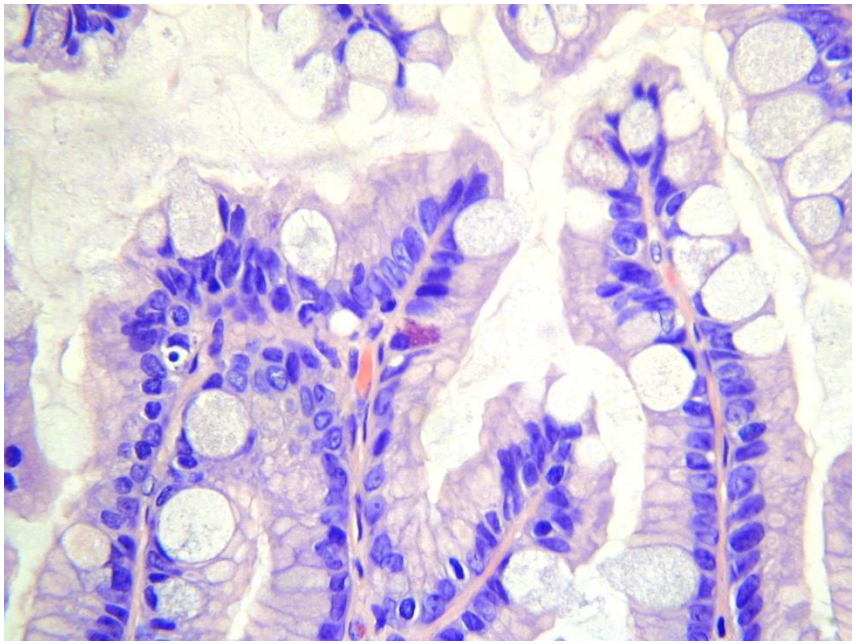

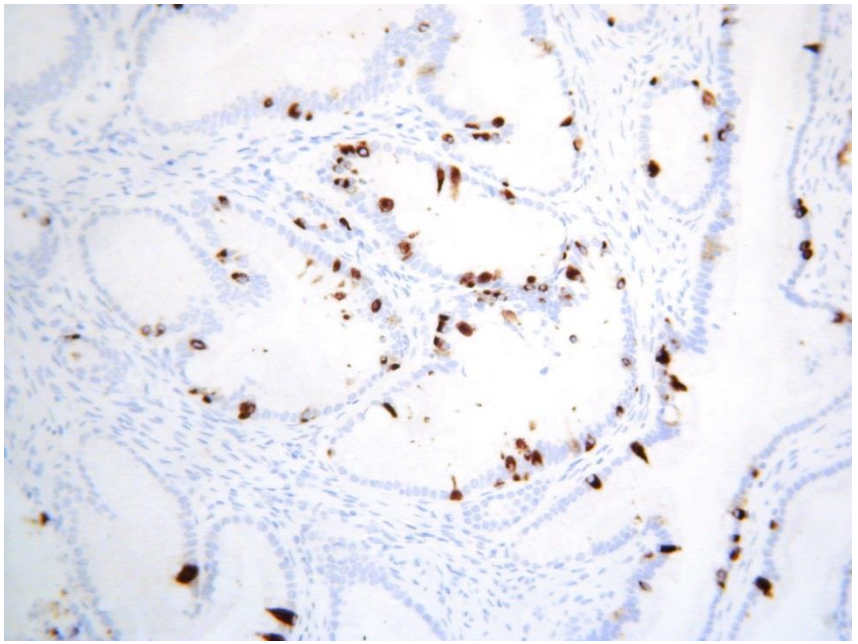

chromogranin

LEGH- MORE CLASSICAL CASE

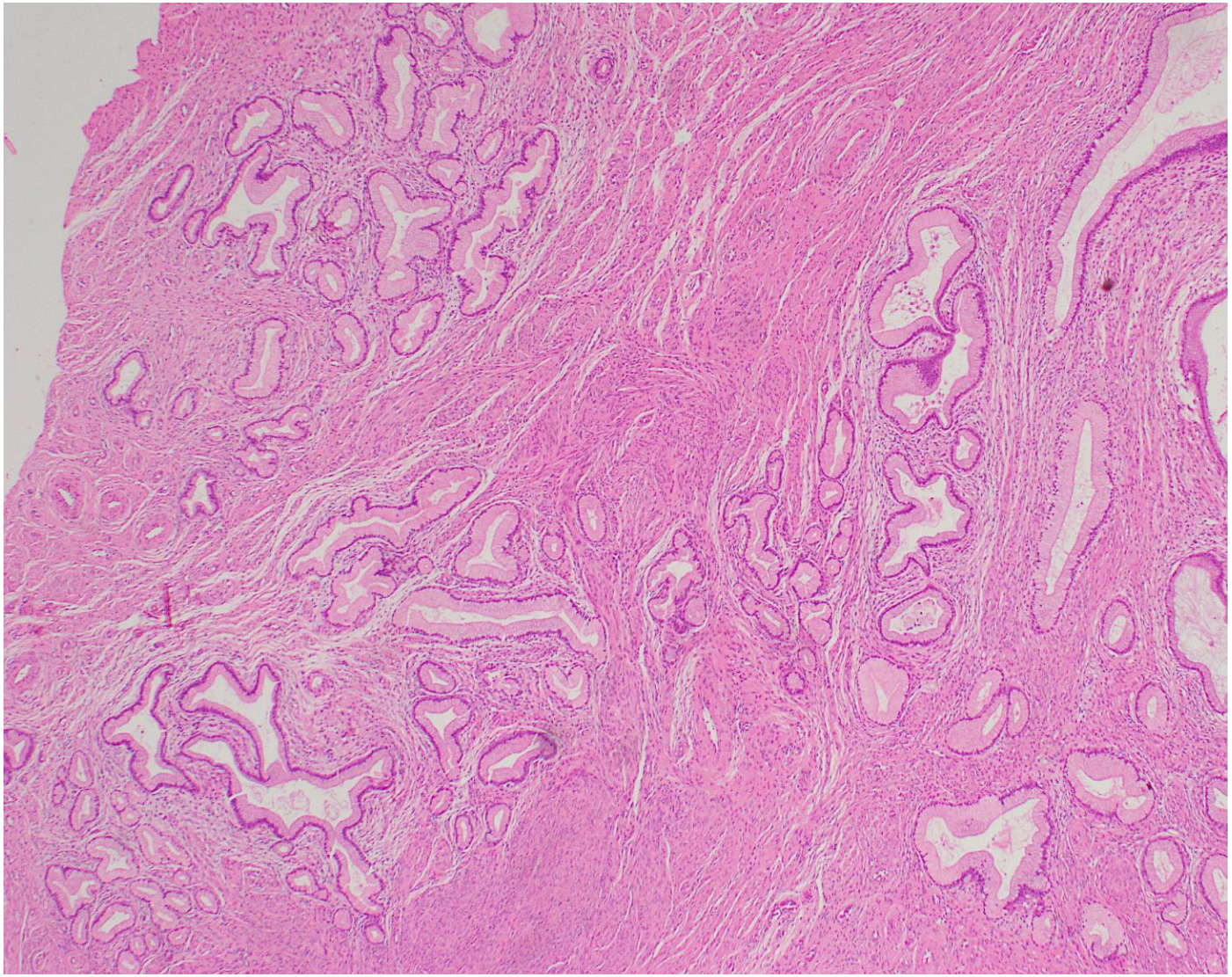

LEGH- SUBTLE CYTOLOGIC DIFFERENCES FROM NORMAL ENDOCERVICAL GLANDS

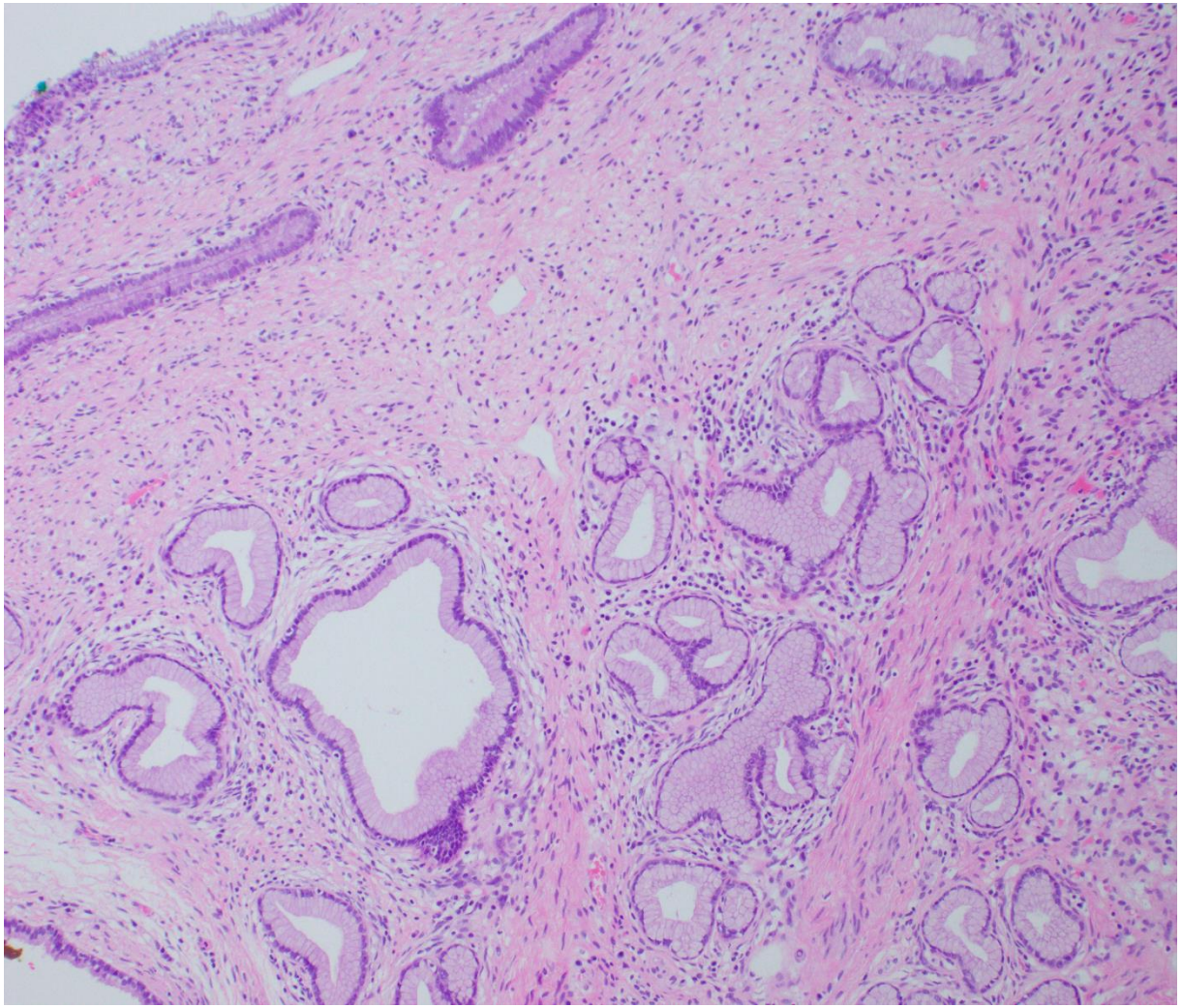

ATYPICAL LOBULAR ENDOCERVICAL GLANDULAR HYPERPLASIA (LEGH)

- very rare
- cytologic and/ or architectural abnormalities
- atypical LEGH probably spectrum from mild reactive changes to precursor of adenoma malignum/ gastric-type adenocarcinoma
- some (not all) gastric-type adenocarcinomas may arise from atypical LEGH
- can be regarded as type of gastric-type AIS

atypical LEGH

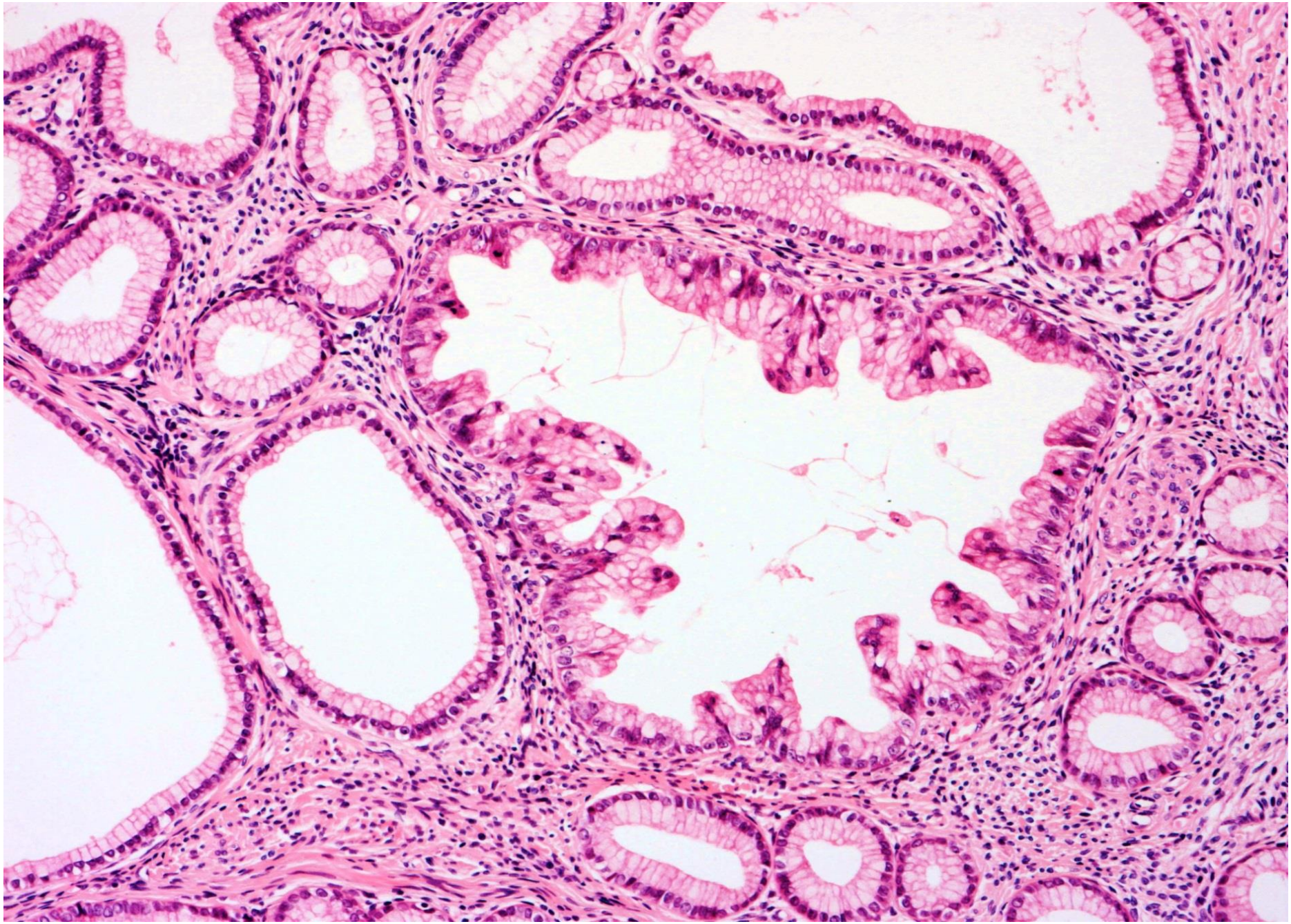

atypical LEGH

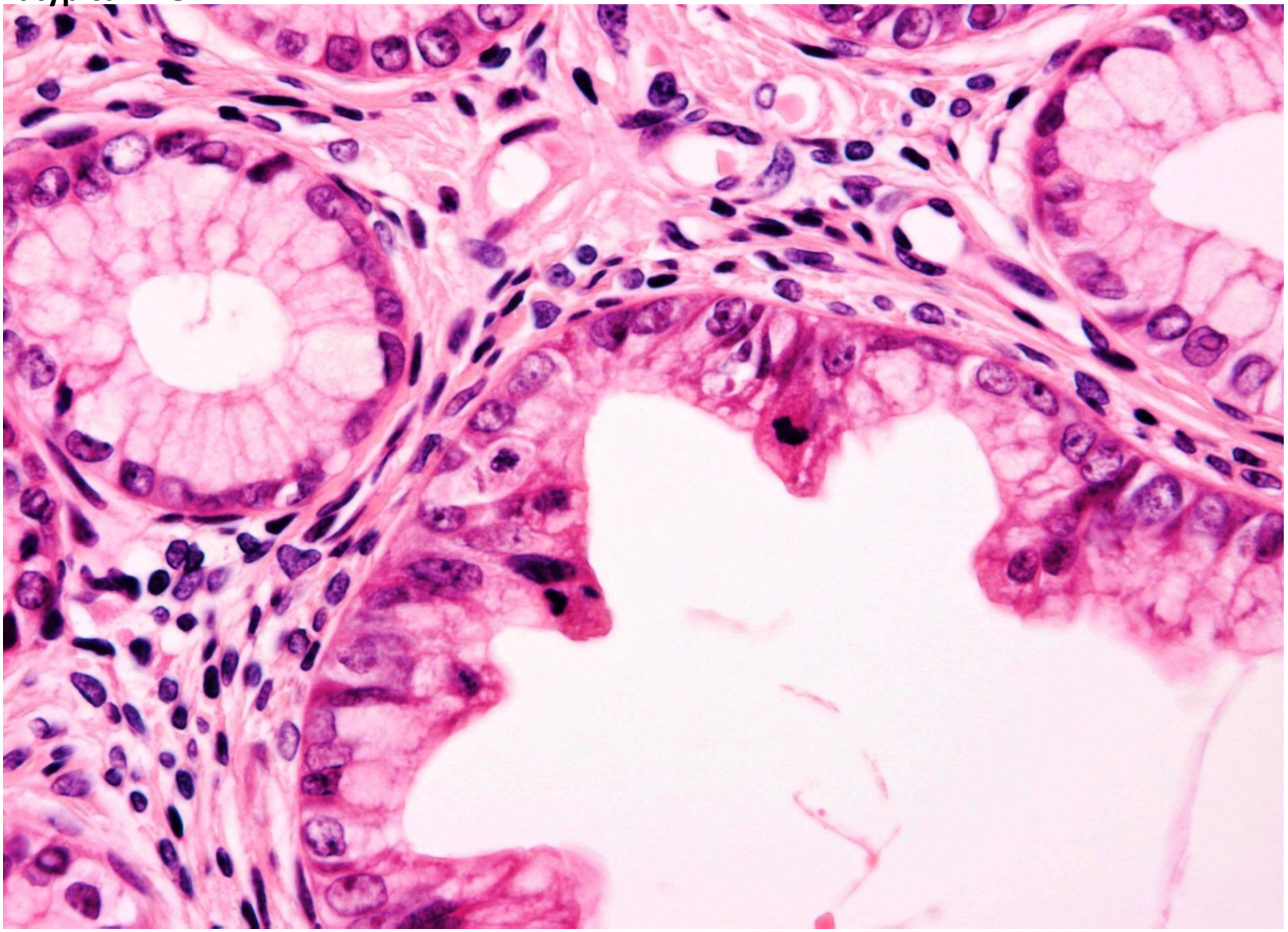

AIS OF GASTRIC-TYPE

- AJSP 2017; 41; 1023-1033 (PMID 28394803)
- 9 cases of AIS exhibiting gastric differentiation age 25- 73 (mean 51)
- HPV negative
- all at transformation zone but extension to LUS in 3 cases (2 also involved uterine corpus)
- 4 purely gastric; 5 mixed gastric and intestinal (more accurate terminology would be “gastrointestinal” type AIS)
- generally low grade nuclear atypia; subtle lesion
- less frequent mitoses and apoptosis than in HPV associated AIS
- some contain neuroendocrine cells
- **probable precursor to gastric-type adenocarcinoma**

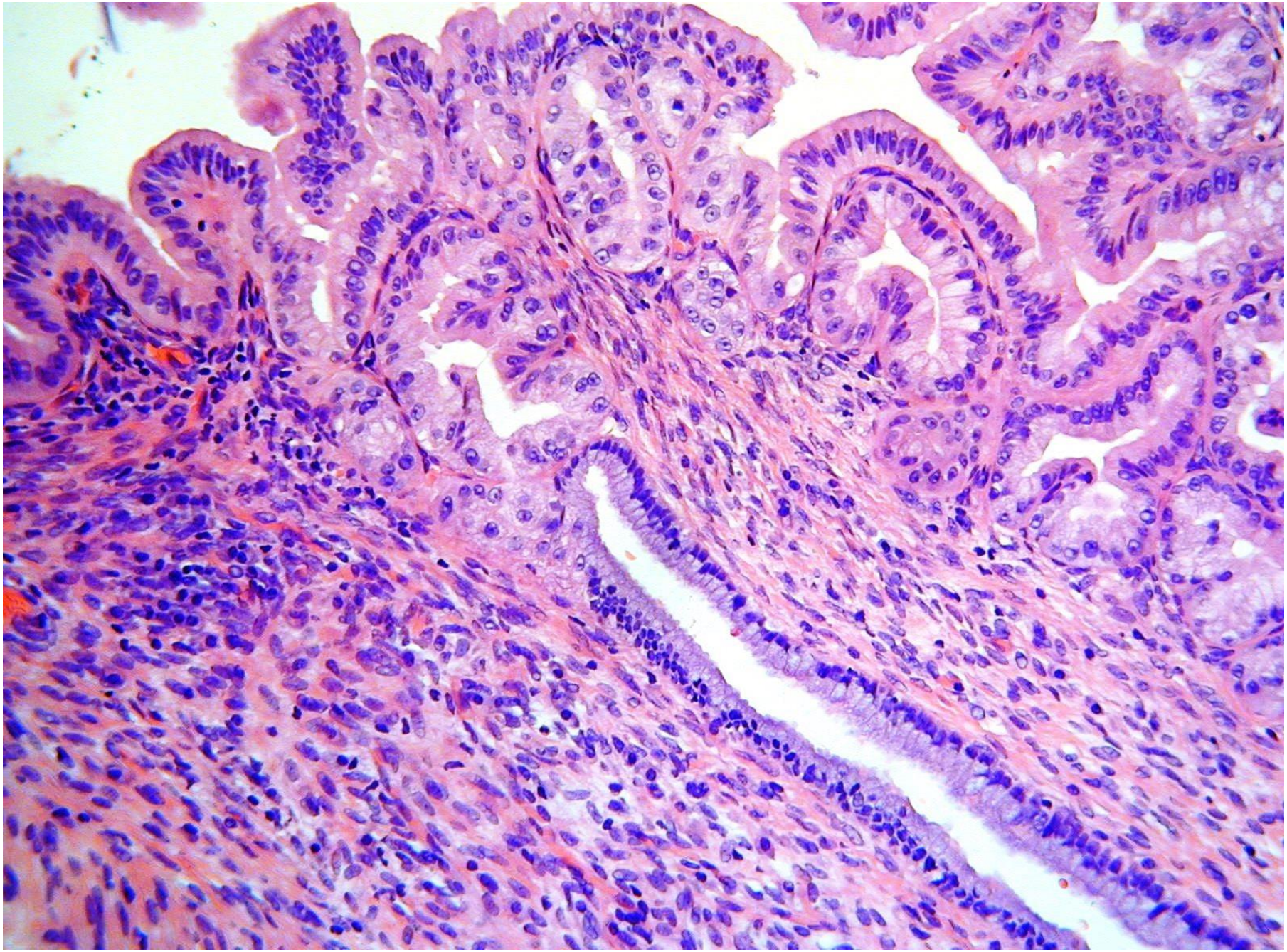

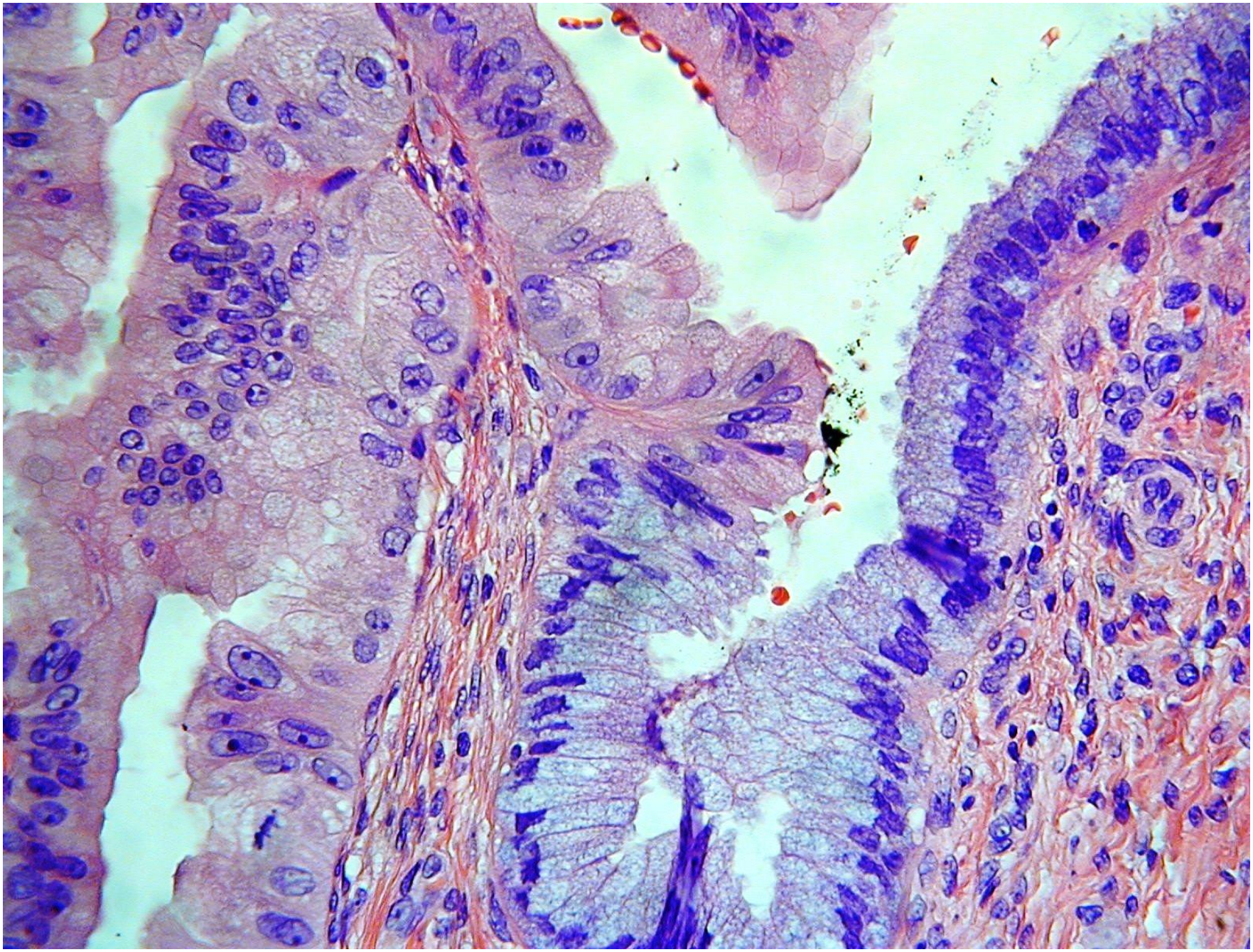

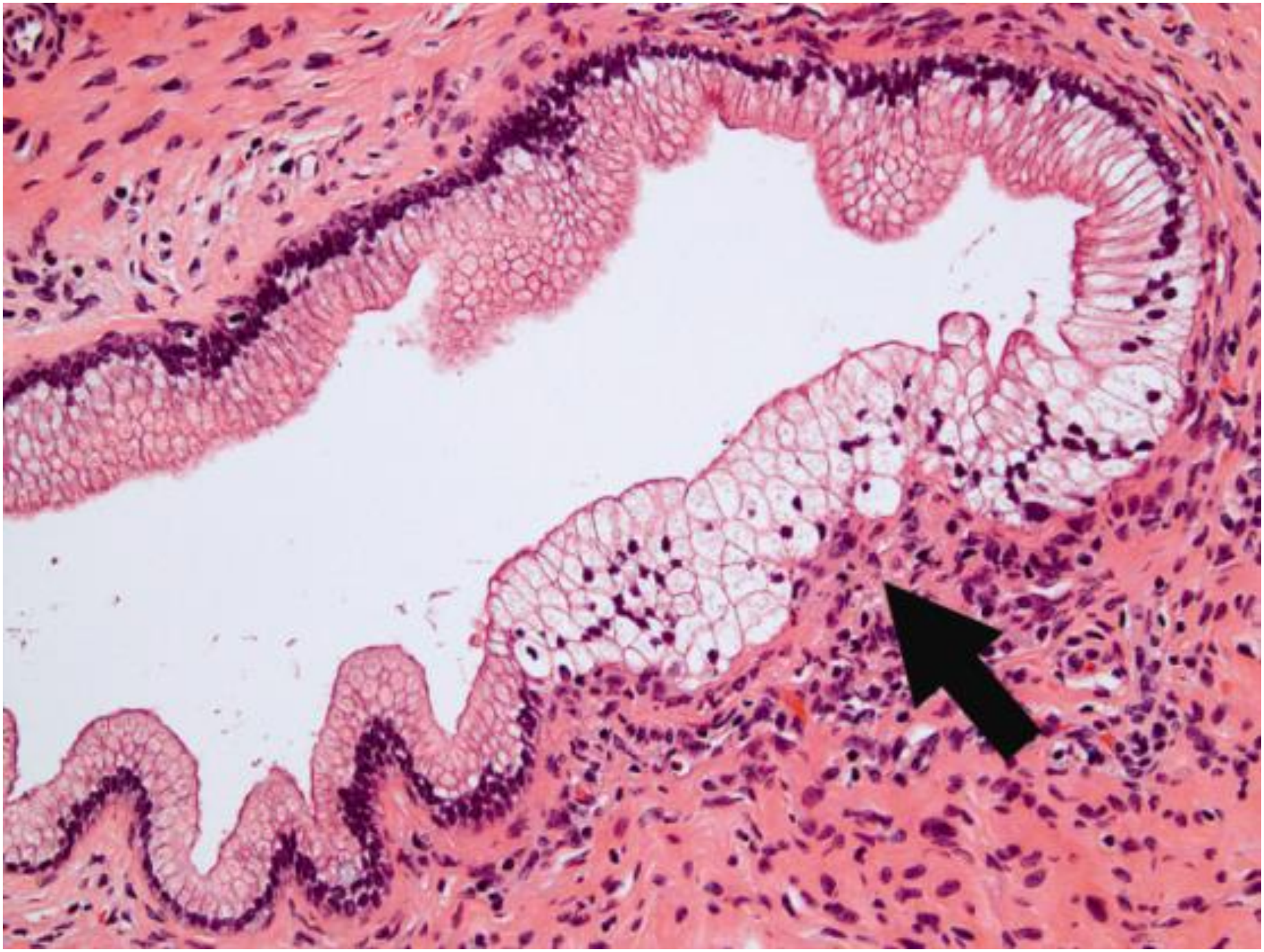

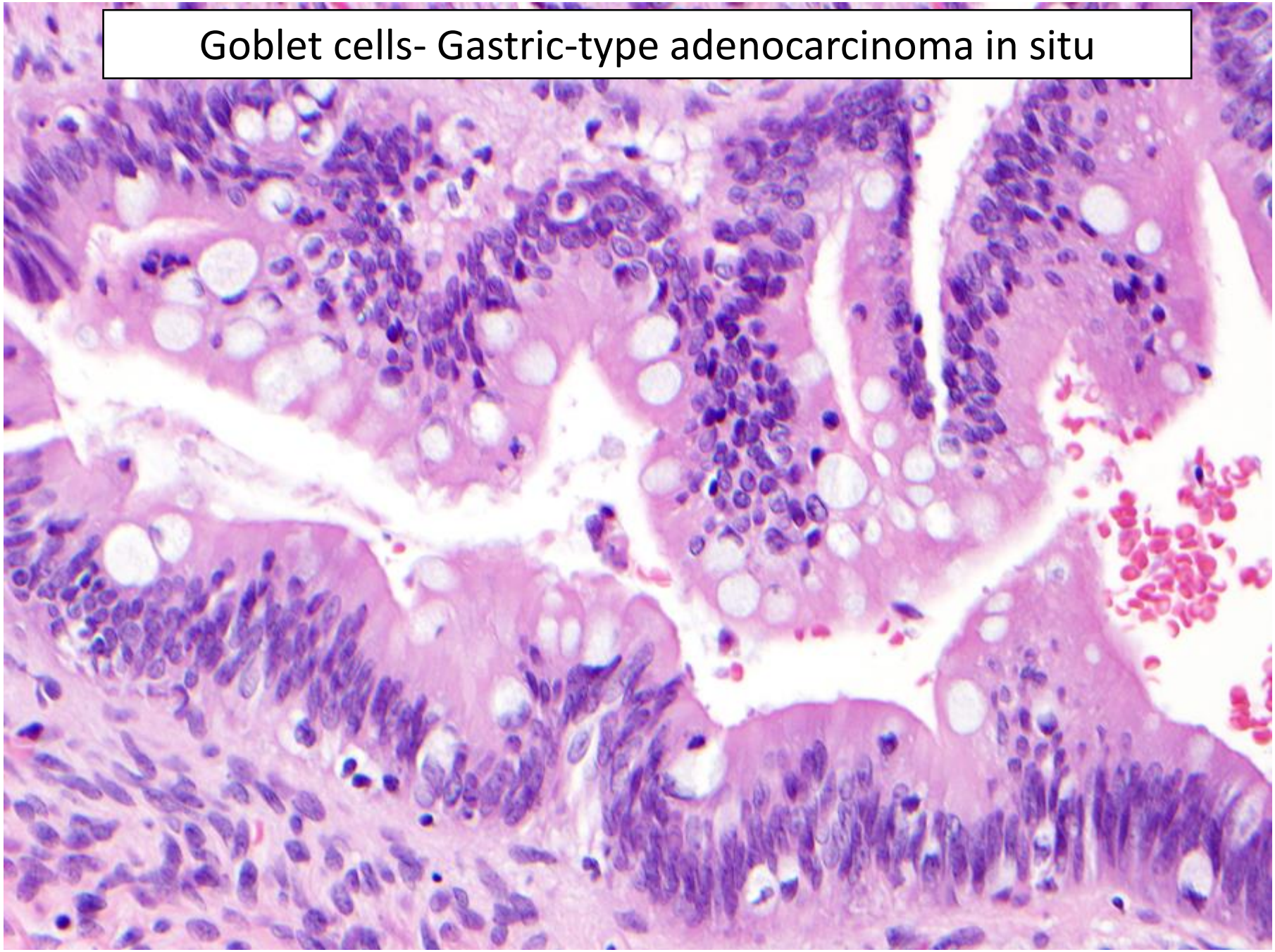
Goblet cells- Gastric-type adenocarcinoma in situ

AIS OF GASTRIC TYPE

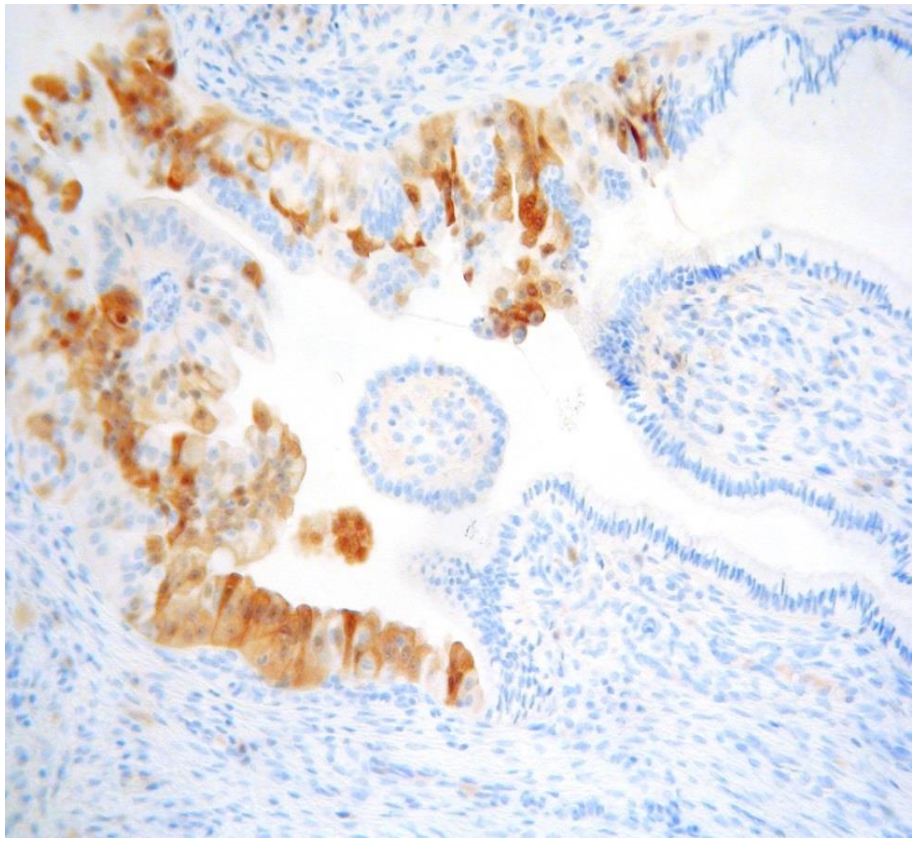

p16

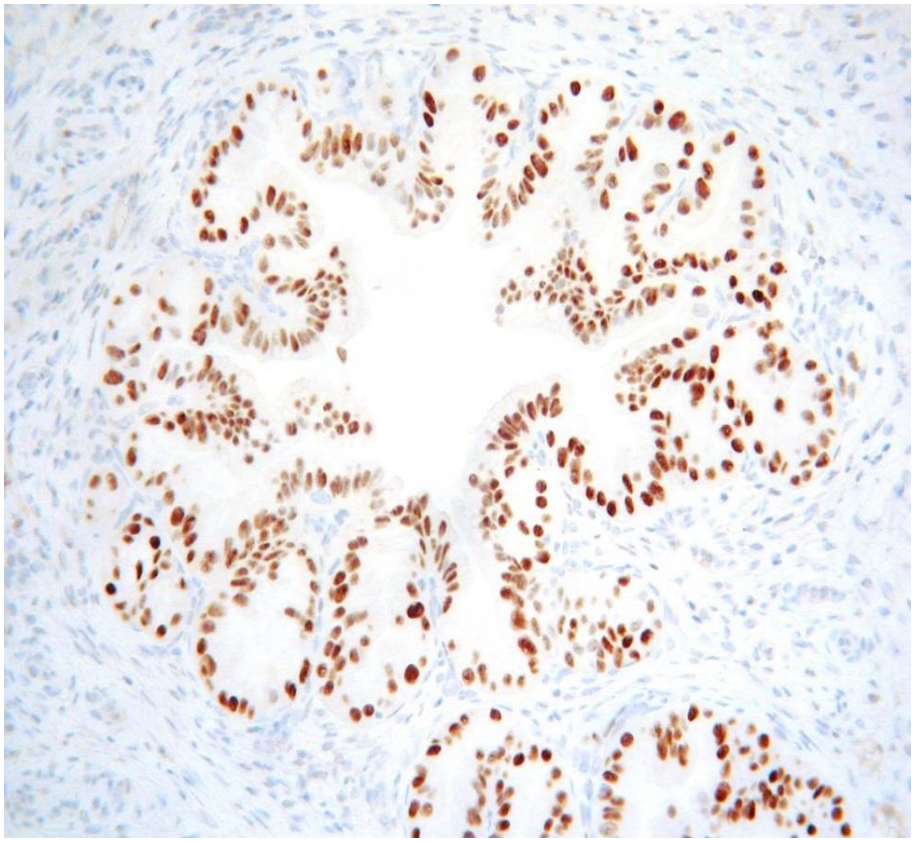

p53

AIS OF GASTRIC TYPE

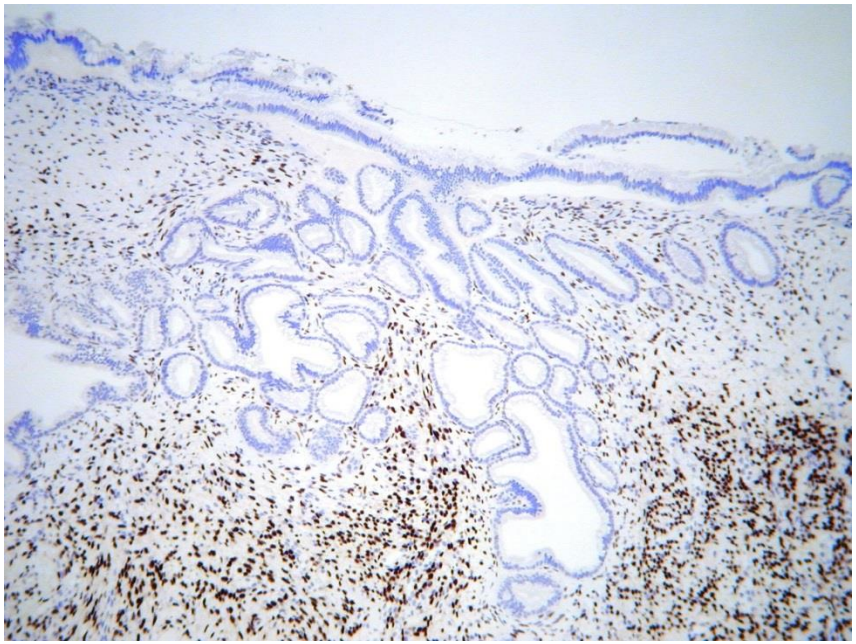

ER

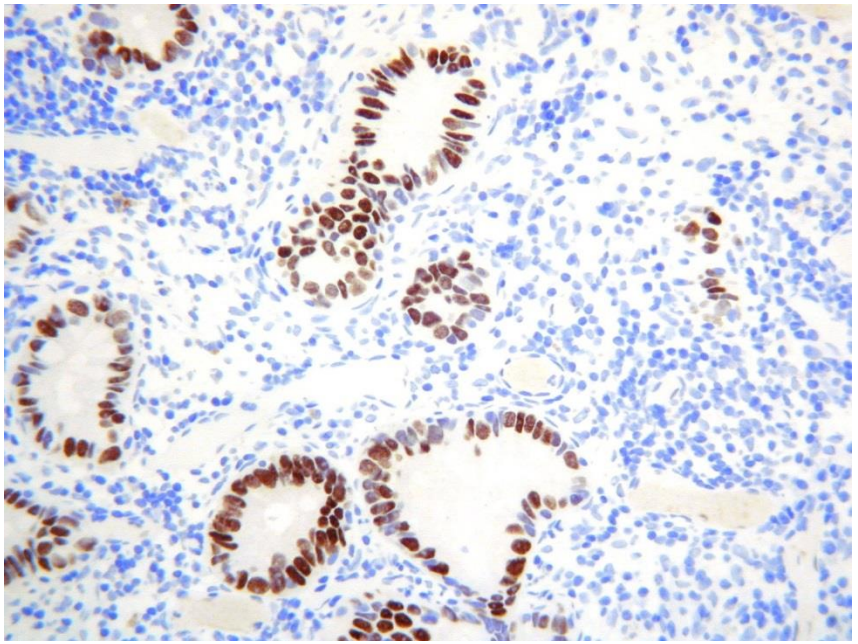

CDX2

INTESTINAL-TYPE AIS

- Do not use this terminology since goblet cells may be seen in HPV-associated and HPV-independent AIS
- Former- HPV-associated AIS with intestinal differentiation
- Latter- gastric-type AIS

OTHER HPV-INDEPENDENT CERVICAL ADENOCINOMAS

- Clear cell carcinoma
- Meseonephric carcinoma
- Endometrioid carcinoma (included with others in WHO 2020)

CERVICAL CLEAR CELL CARCINOMA

- uncommon
- HPV-independent
- association with in-utero exposure to DES (usually not nowadays)
- bimodal age peaks (20s and 60/70s)
- morphologically similar to uterine corpus/ovarian counterparts; tend to have “subtle” tubulocystic pattern in cervix
- in older women especially, exclude spread from uterine corpus/ovary
- useful markers Napsin A, racemase, HNF1 beta
- occasional cases associated with MMR defects and Lynch syndrome
- rarely arise from cervical endometriosis
- can be misdiagnosed as gastric-type or mesonephric-type

CLEAR CELL CARCINOMA

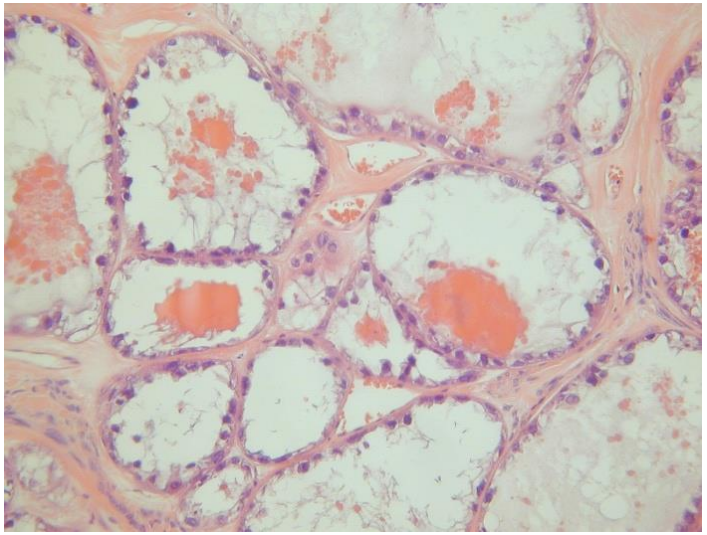

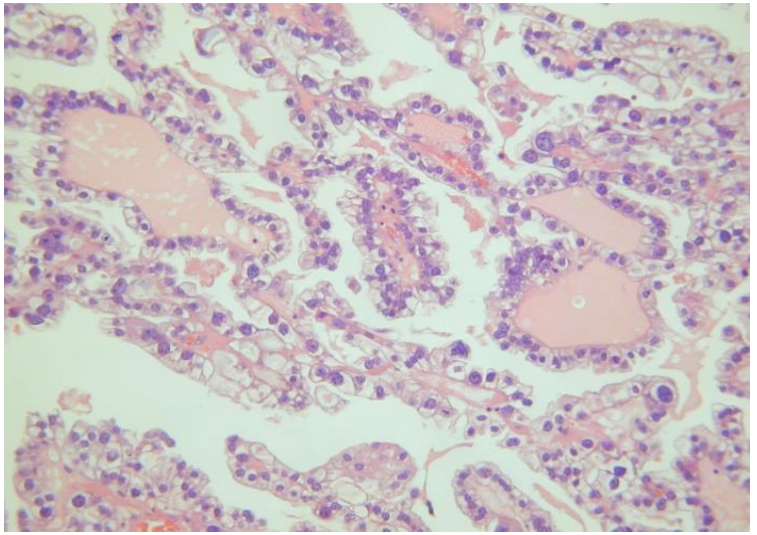

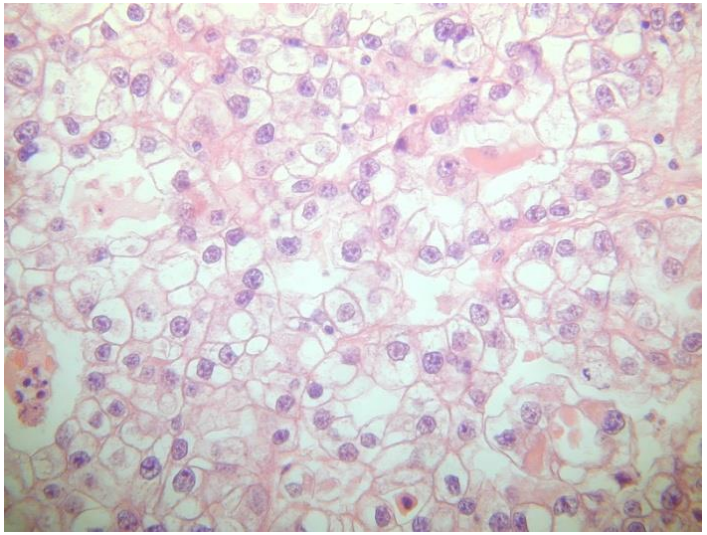

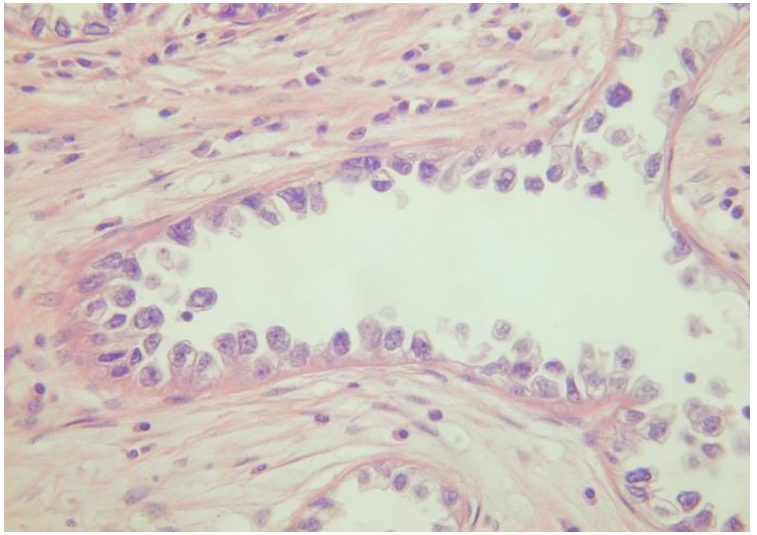

CLEAR CELL CARCINOMA

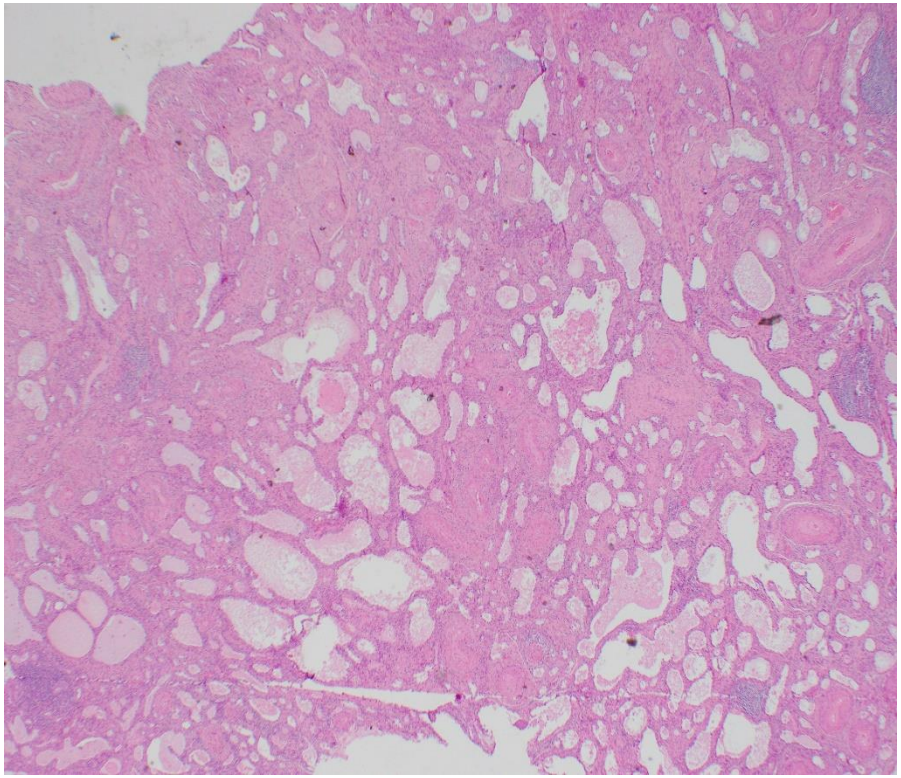

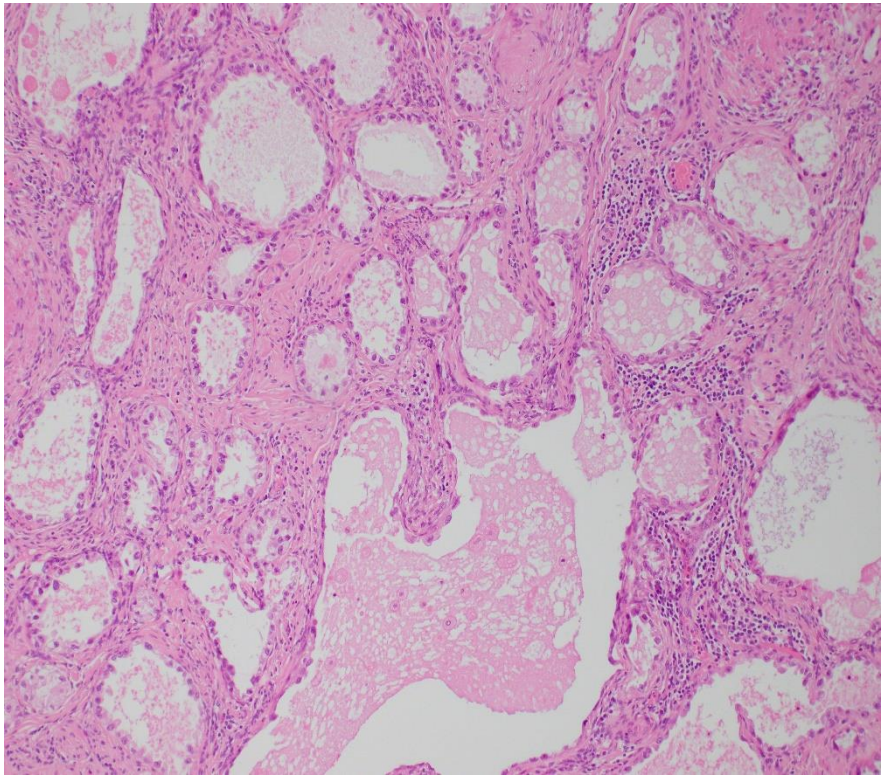

IMMUNOHISTOCHEMISTRY

- International Journal of Gynecological Pathology 2019;38;276-282; PMID 29901522
- 24 cases of cervical/ vaginal gastric-type adenocarcinoma; 14 cervical clear cell carcinomas stained with Napsin A and HNF1 beta
- HNF1 beta positive in 91.3% of gastric-type and 71.4% of clear cell
- Napsin A positive in 16.7% of gastric-type and 78.6% of clear cell

IMMUNOHISTOCHEMISTRY- CLEAR CELL CARCINOMA

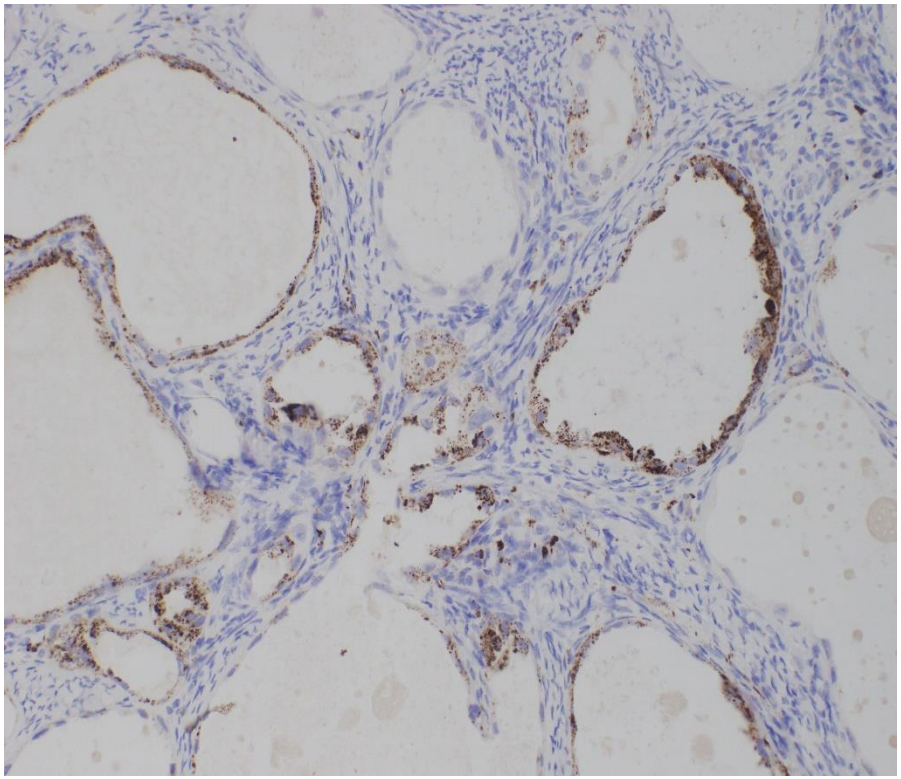

Napsin A

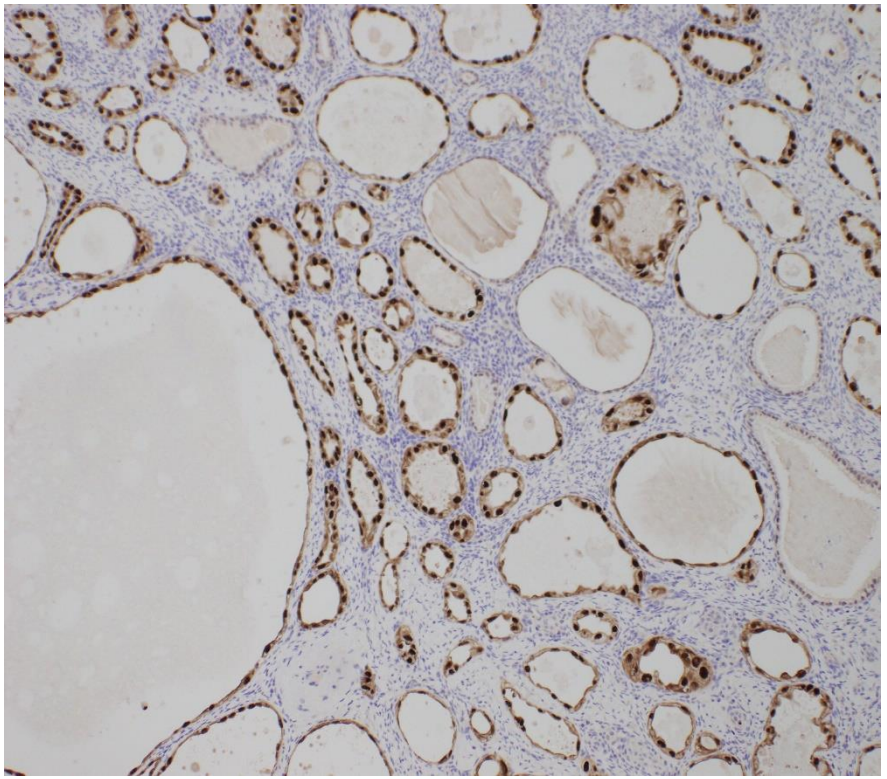

HNF1 beta

CERVICAL MESONEPHRIC ADENOCARCINOMA

- Uncommon
- HPV-independent
- admixture of morphological patterns is characteristic but my result in diagnostic problems
- may get spindle cell component but usually morphologically bland (do not call carcinosarcoma unless heterologous elements)
- may be associated with and arise from hyperplastic mesonephric remnants
- immunohistochemistry of some value (lots of markers suggested to be of value) but diagnosis predominantly morphological

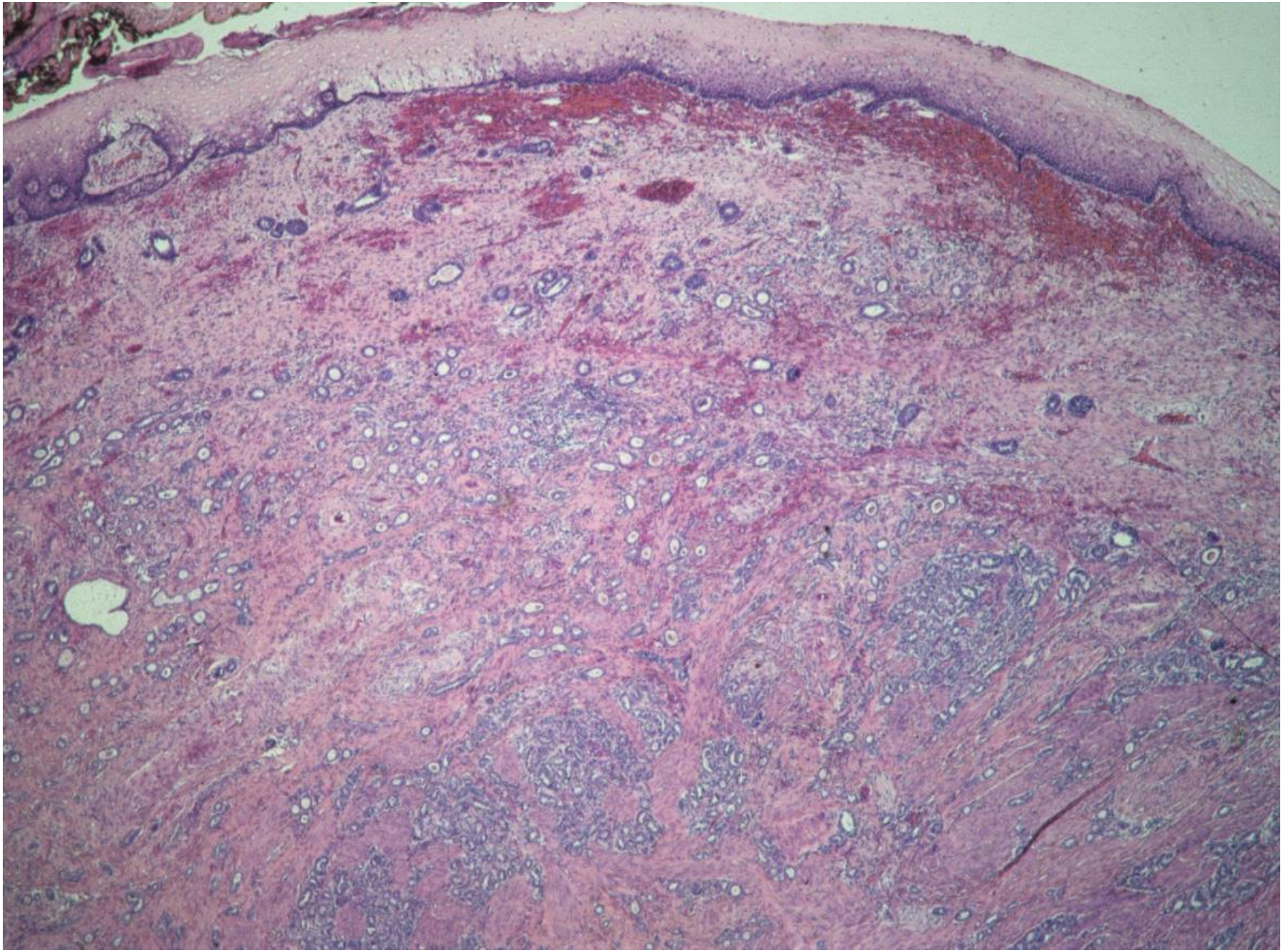

DIFFERENT PATTERNS- TUBULES

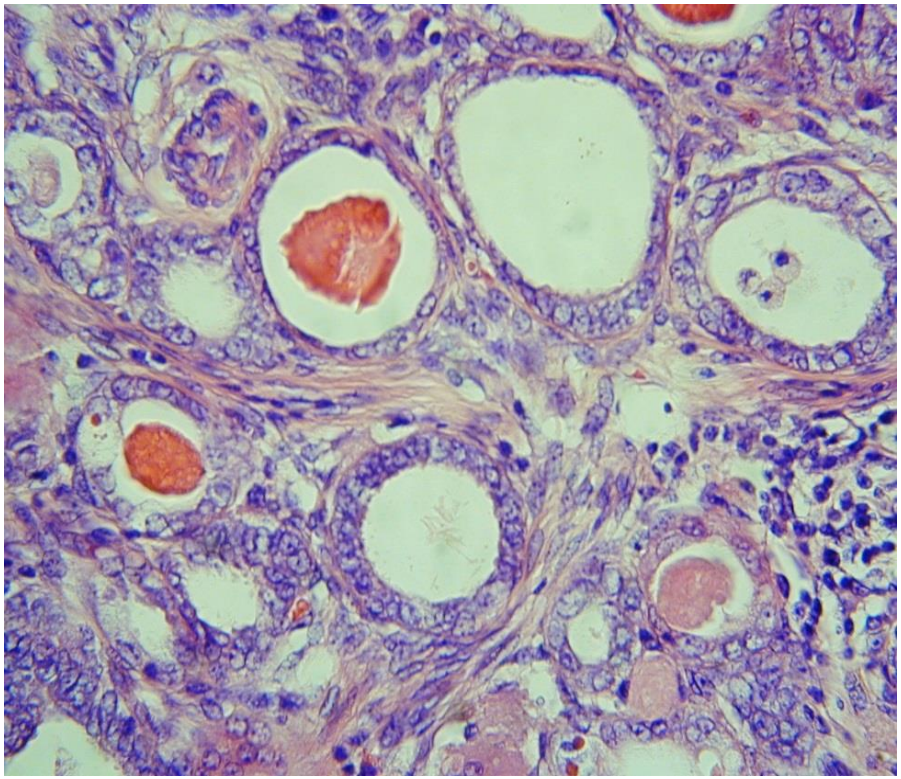

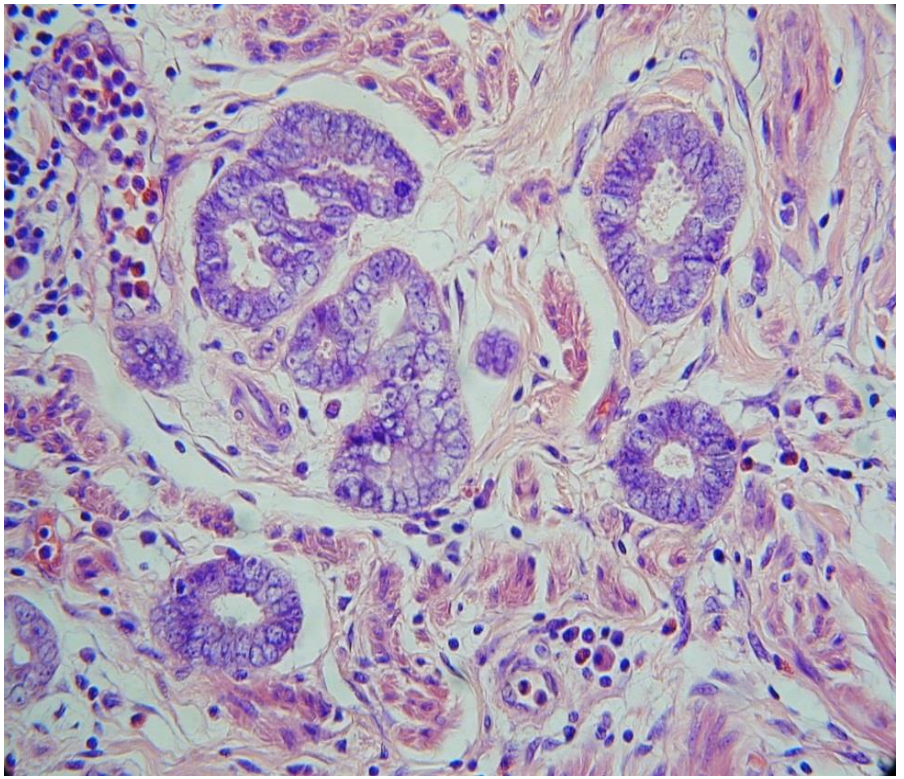

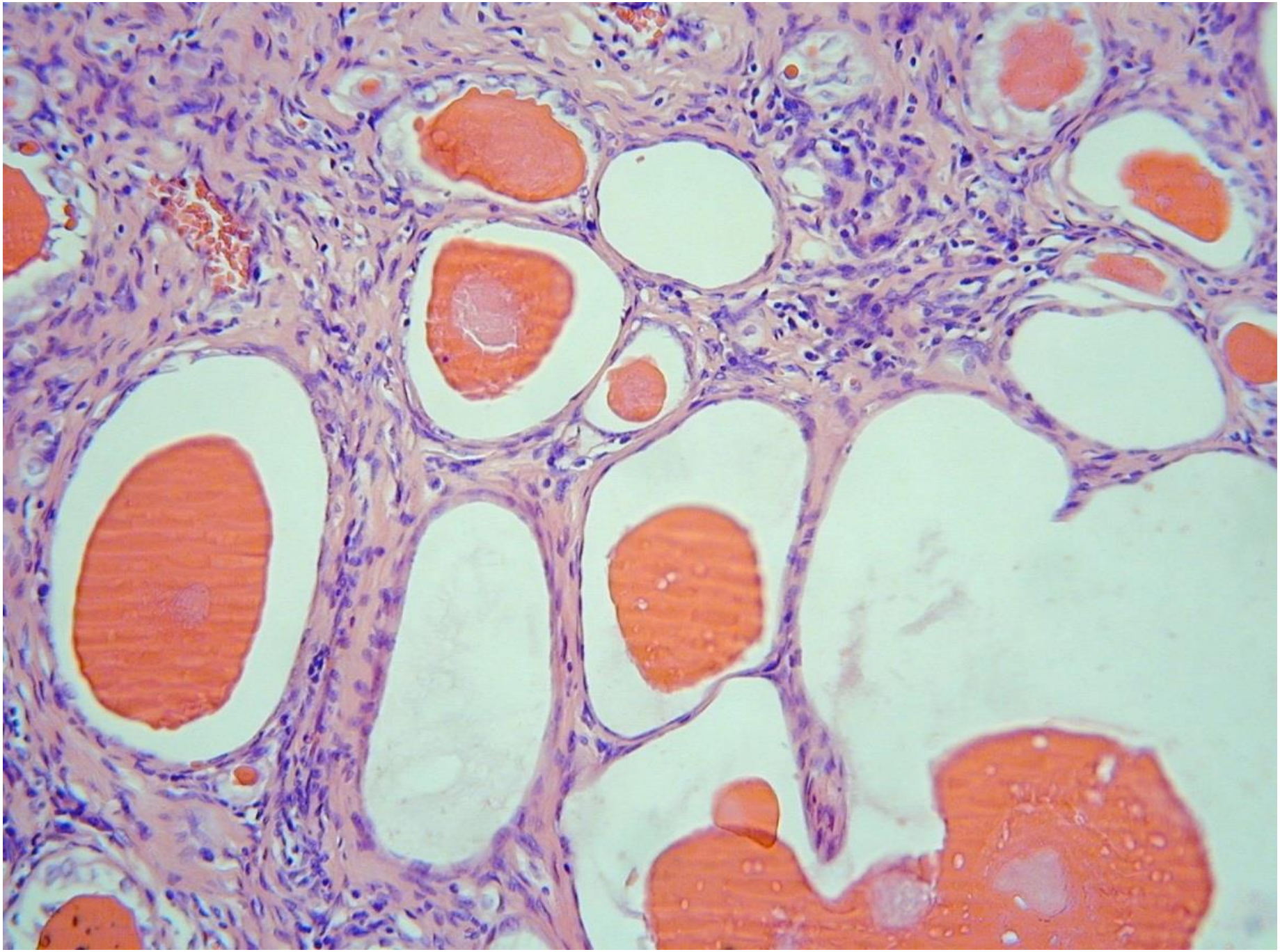

DIFFERENT PATTERNS

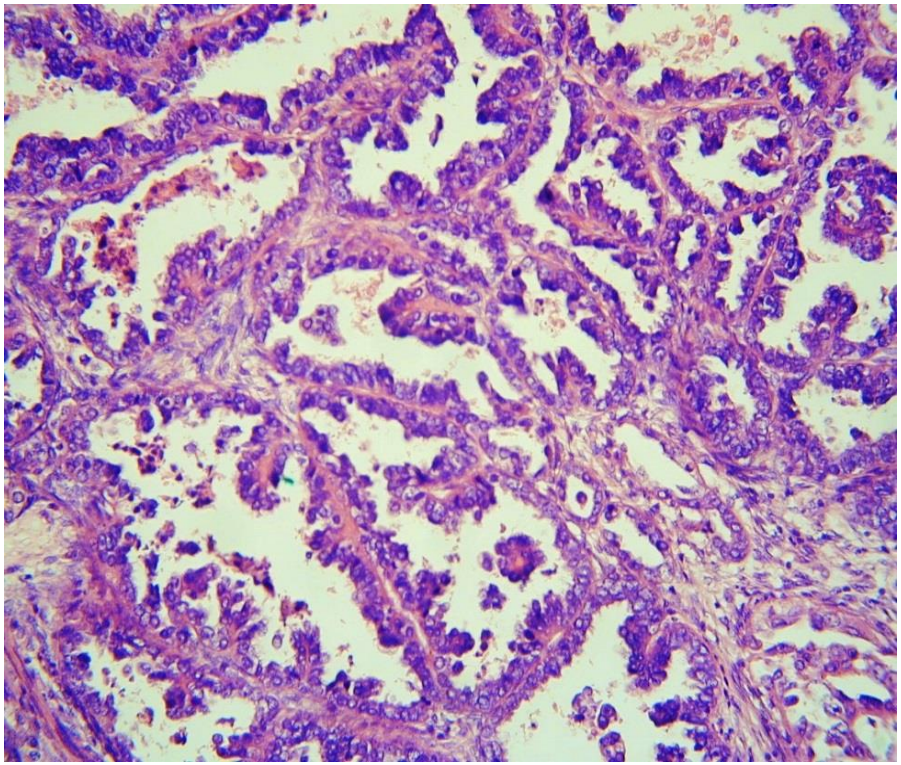

Serous-like

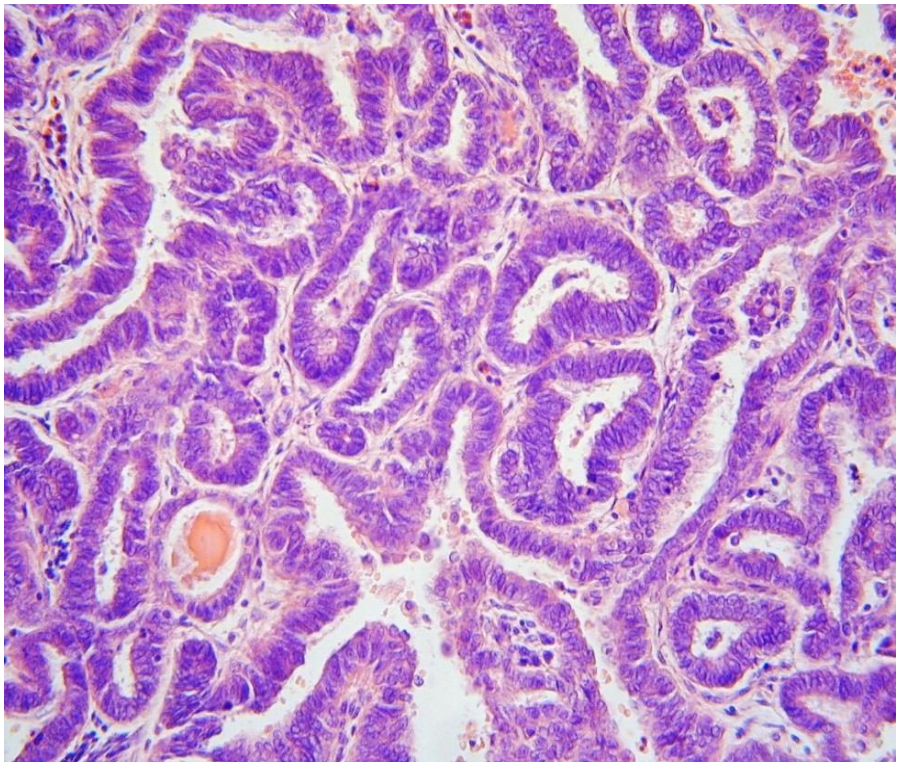

Ductal-like

DIFFERENT PATTERNS

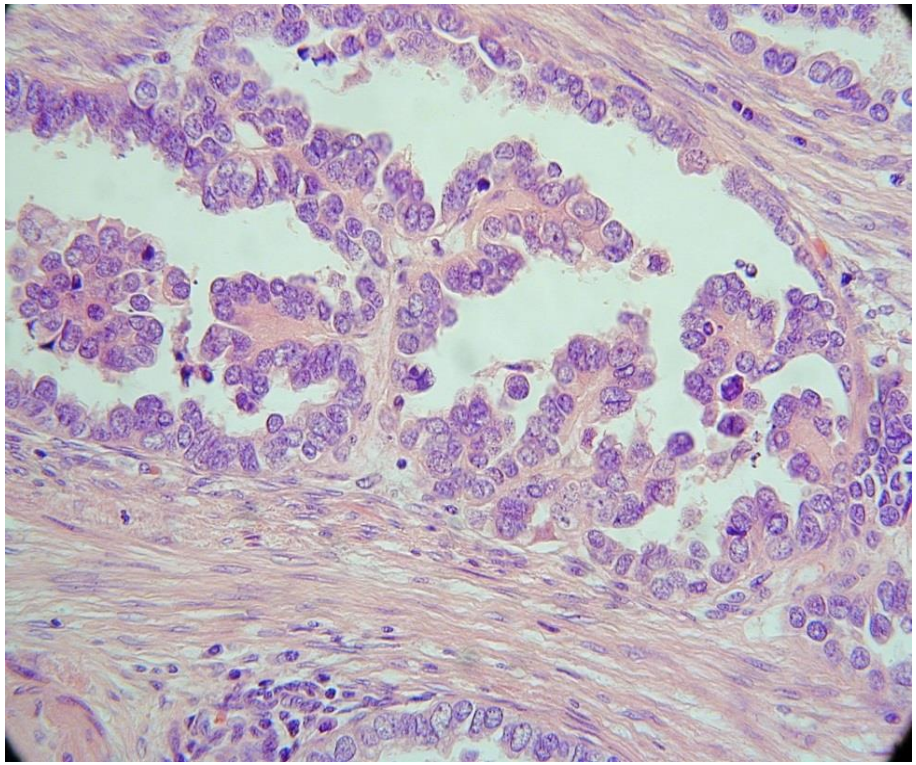

Clear cell-like

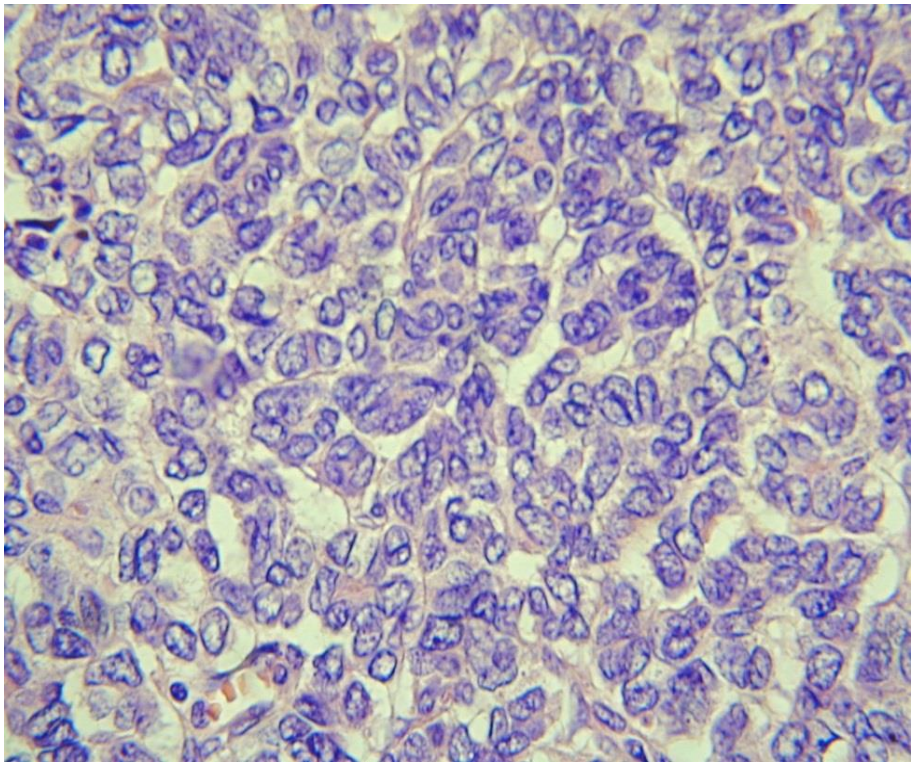

Solid

IMMUNOHISTOCHEMISTRY OF MESONEPHRIC ADENOCARCINOMA- AJSP PMID 22456609

- diagnosis largely based on morphology (no pathognomonic markers)
- CD10, inhibin, calretinin, vimentin may be positive (but variable and not reliable)
- PAX8 positive
- GATA 3, TTF1 may be positive (often “inverse” correlation)
- ER, PR characteristically totally/ flat negative
- p16- negative/ focal
- p53- wild-type

IMMUNOHISTOCHEMISTRY

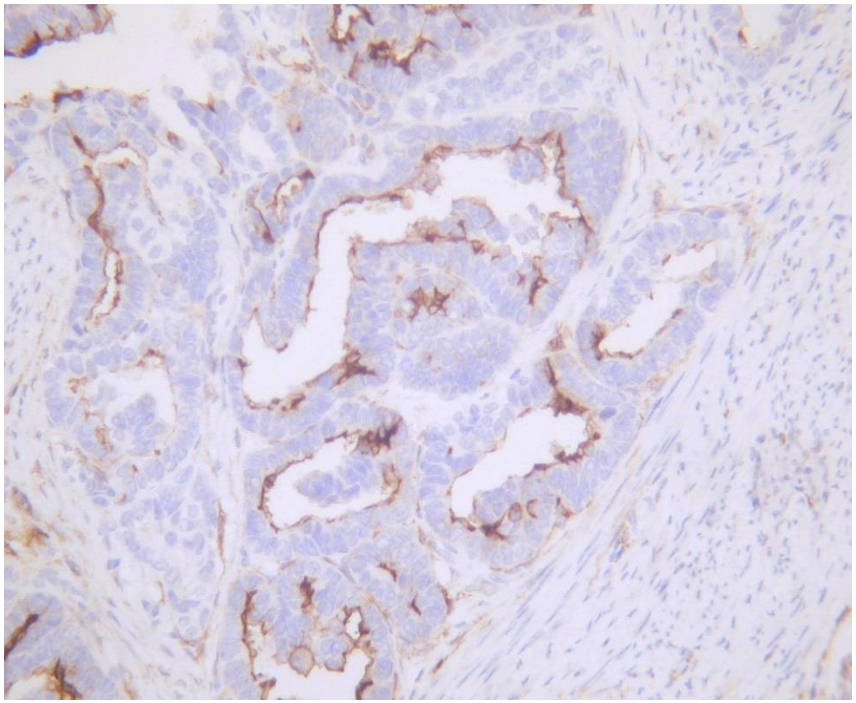

CD10

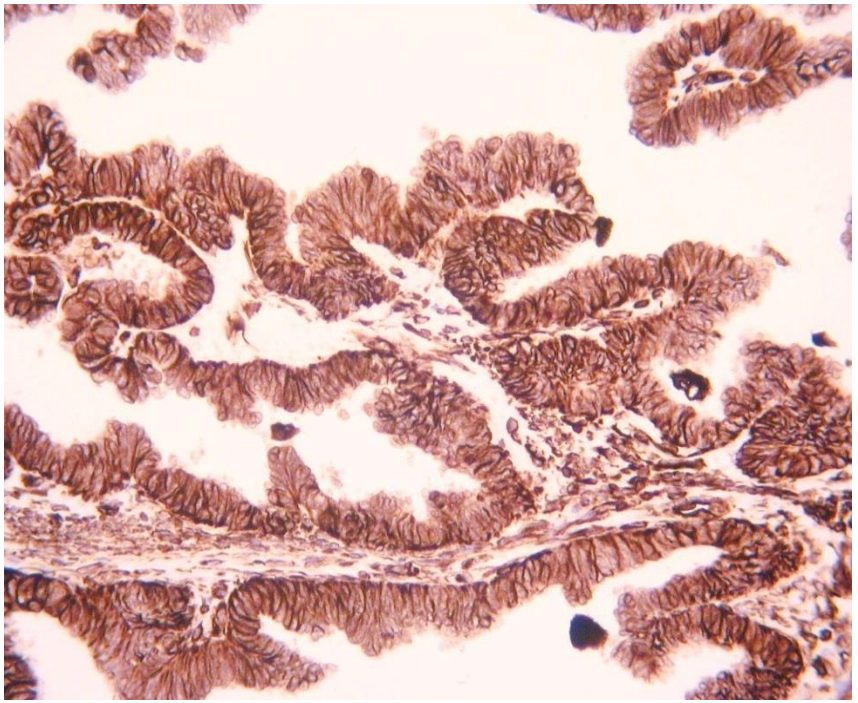

vimentin

IMMUNOHISTOCHEMISTRY

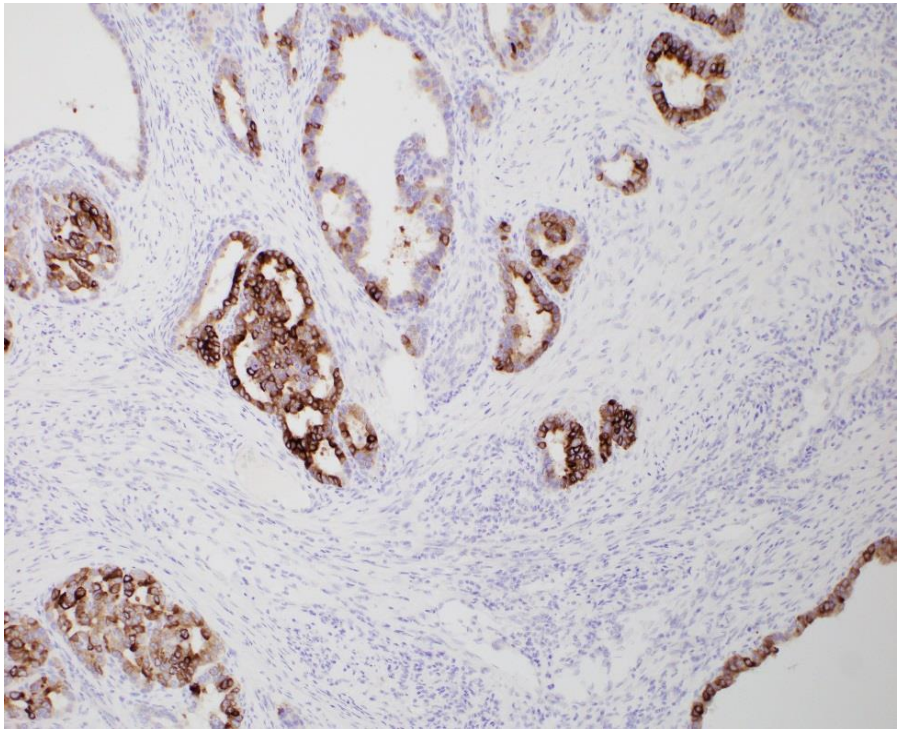

inhibin

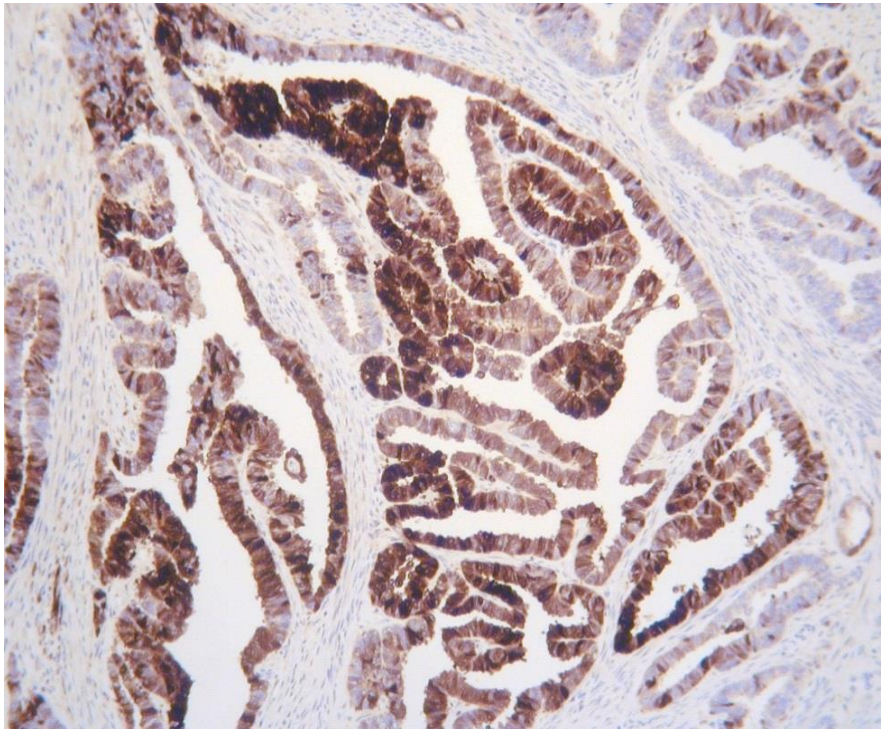

calretinin

IMMUNOHISTOCHEMISTRY

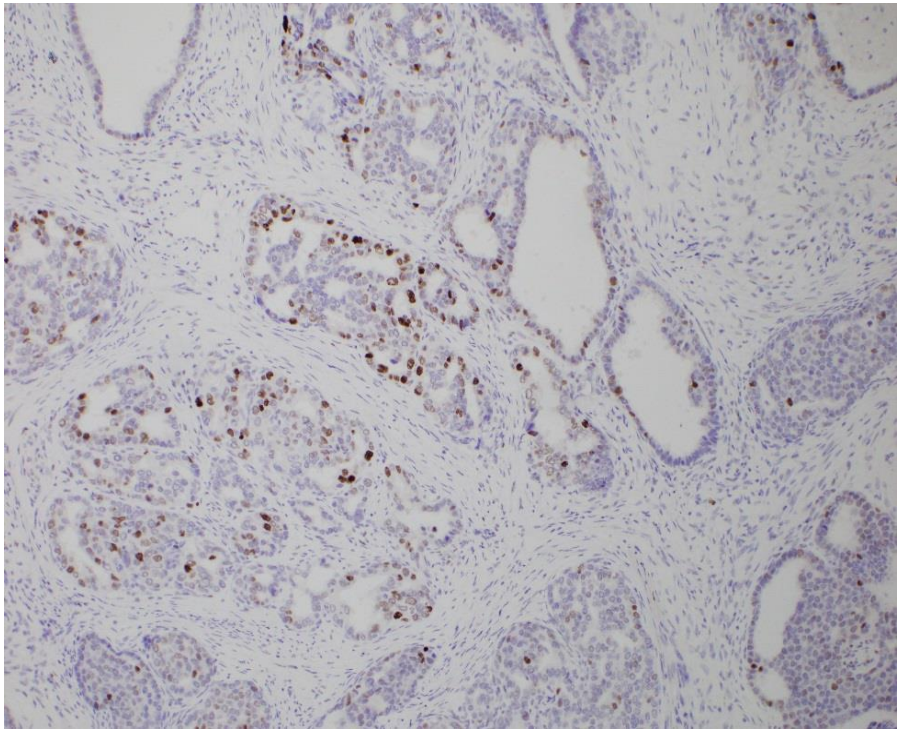

p53

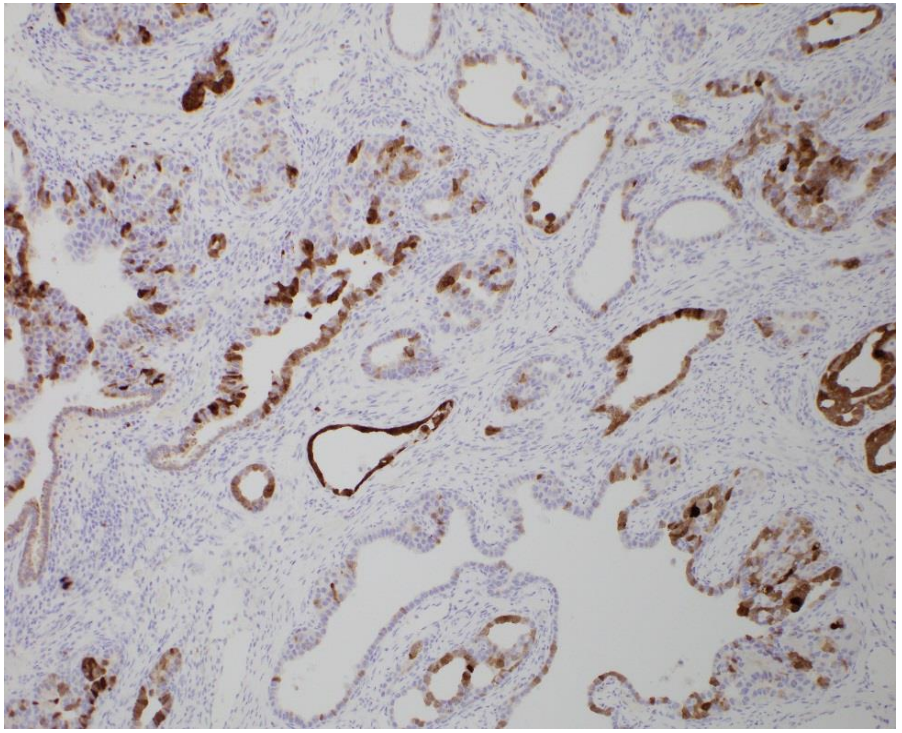

p16

IMMUNOHISTOCHEMISTRY

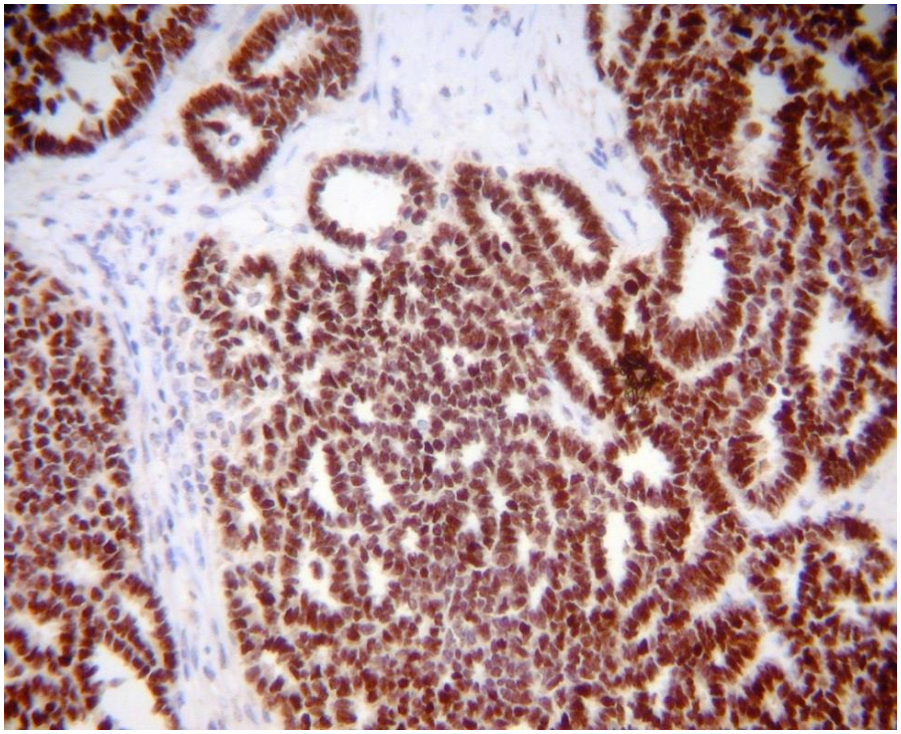

TTF1

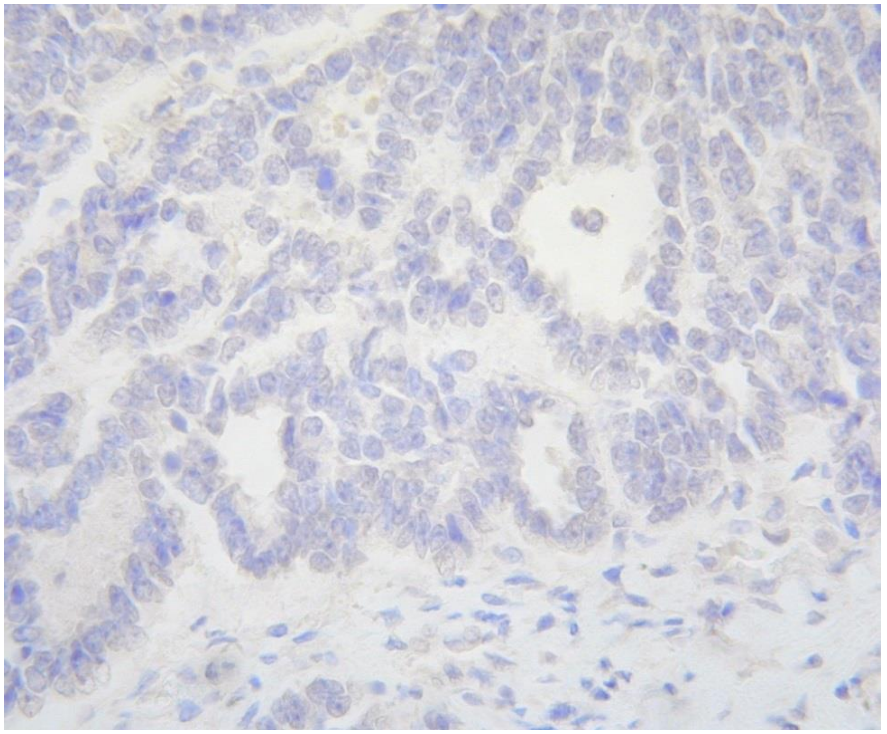

ER

IMMUNOHISTOCHEMISTRY- GATA3

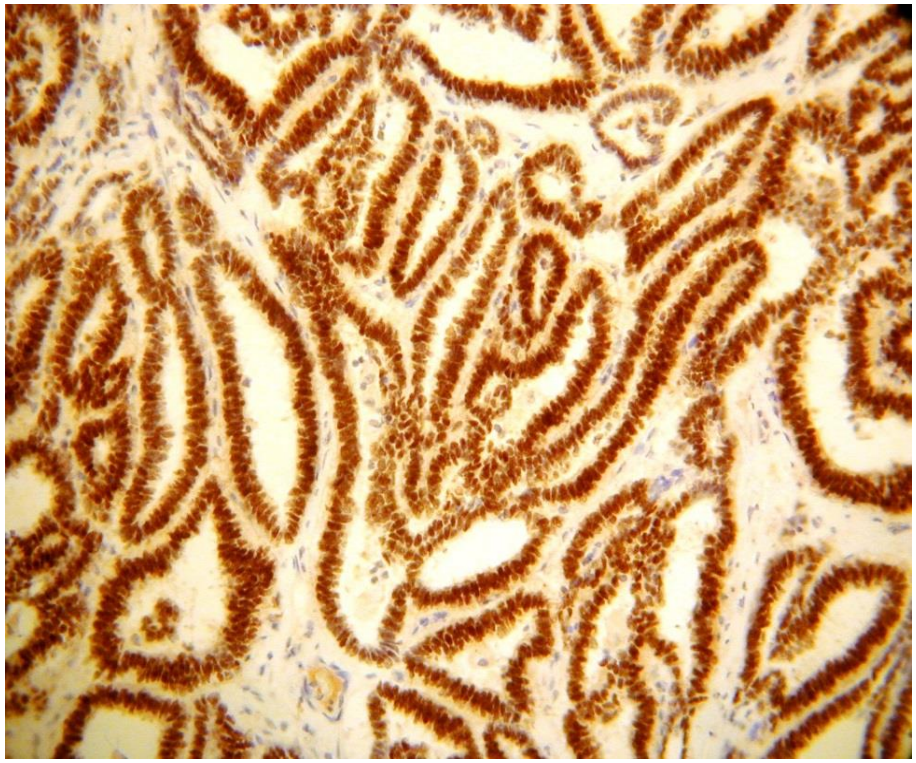

Mesonephric carcinoma

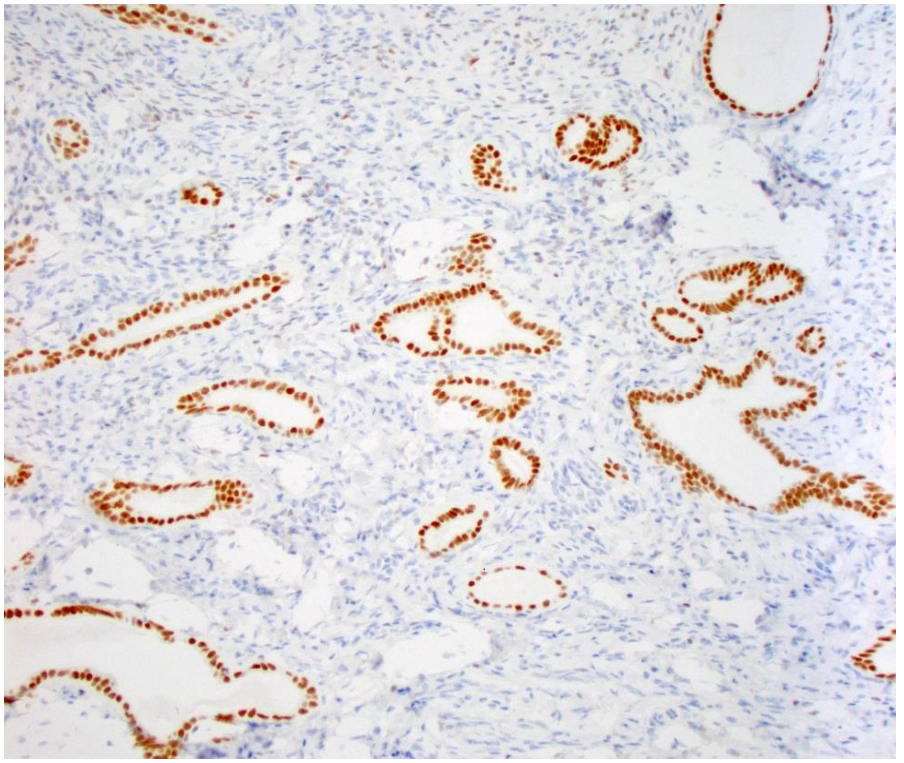

Mesonephric remnants

MOLECULAR EVENTS IN CERVICAL MESONEPHRIC ADENOCARCINOMAS

- Modern Pathology 2015; 28; 1504-1514
- 13 of 16 (81%) had *KRAS* or *NRAS* mutation
- 62% had mutations in chromatin remodelling genes (*ARID1A, ARID1B, SMARCA4*)
- Different molecular events than in other cervical adenocarcinomas and endometrial adenocarcinomas

MESONEPHRIC CARCINOMA- DIFFERENTIAL WITH CLEAR CELL CARCINOMA

- Can be very difficult, especially on small biopsy
- Both may be composed of small tubules and dilated glands with little stromal response
- Usually more hobnail cells and cytoplasmic clearing in clear cell carcinoma
- Immunohistochemistry of value (but HNF1 beta may be positive in mesonephric carcinoma; 3 of 8 cases in PMID 22456609)

CLEAR CELL CARCINOMA OF CERVIX MIMICKING MESONEPHRIC

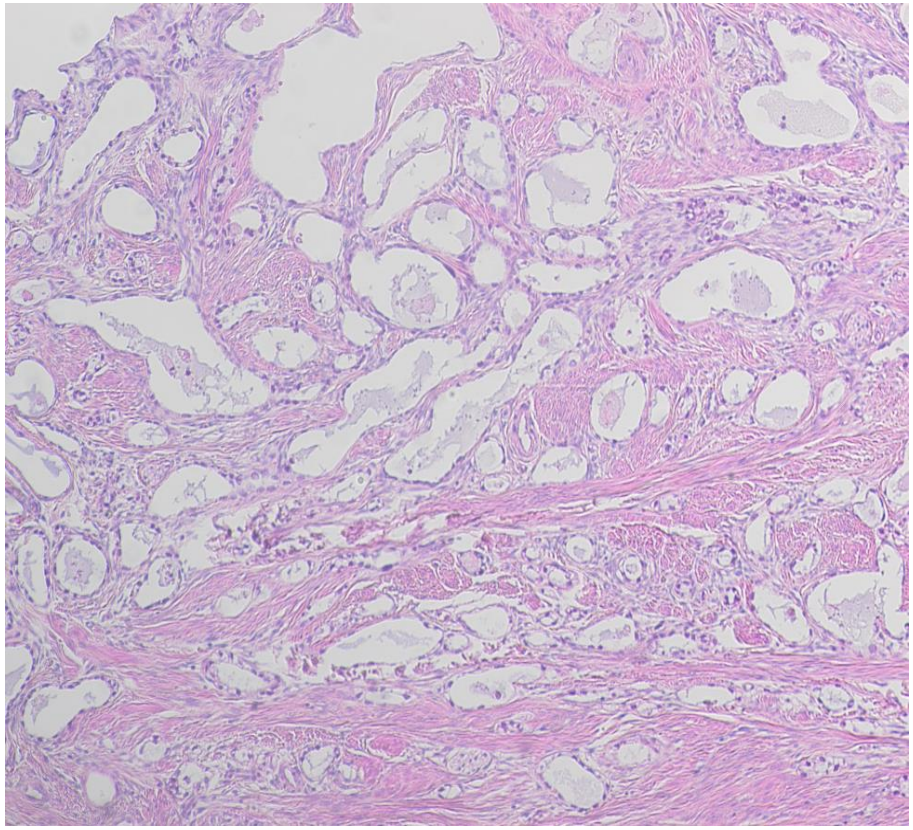

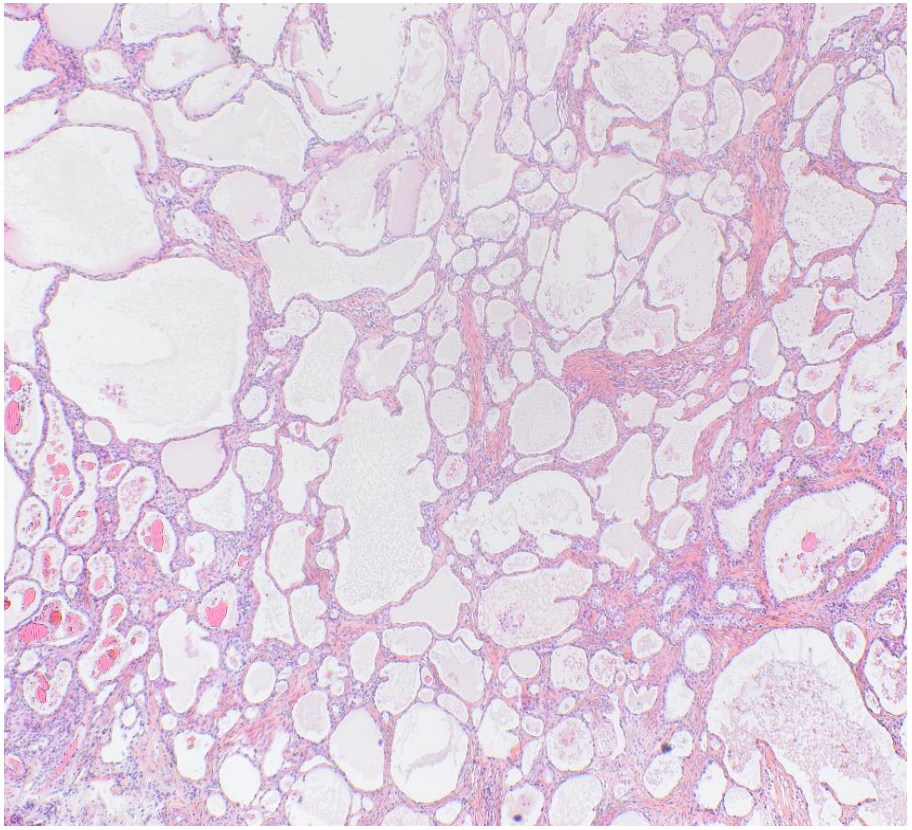

CLEAR CELL CARCINOMA OF CERVIX MIMICKING MESONEPHRIC

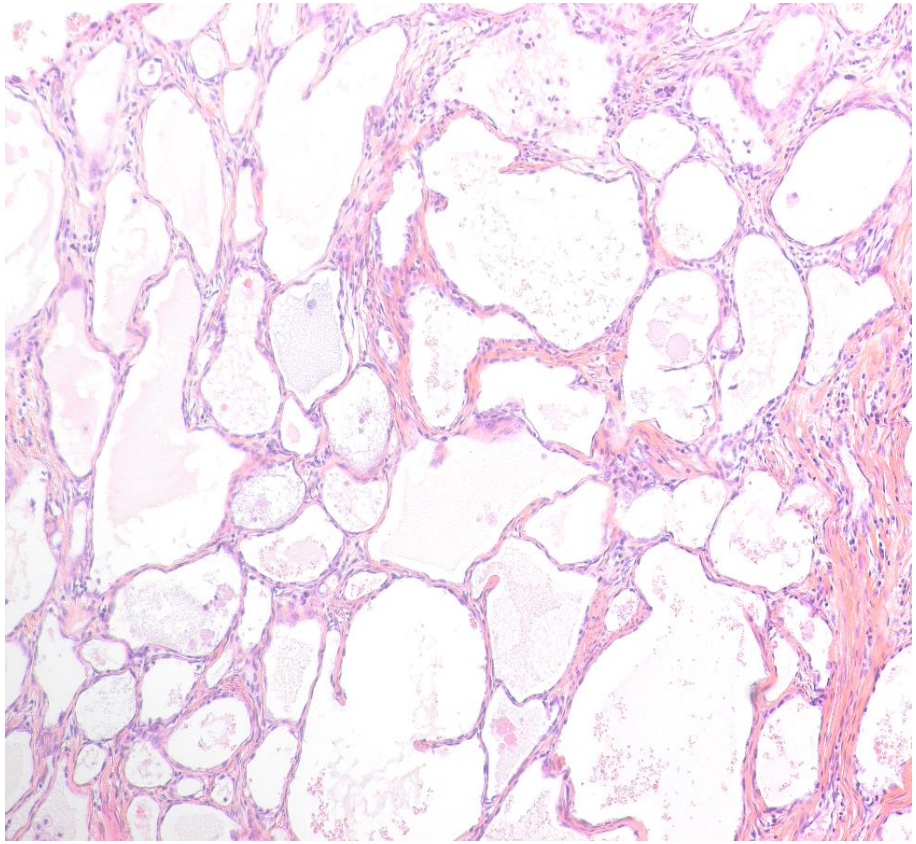

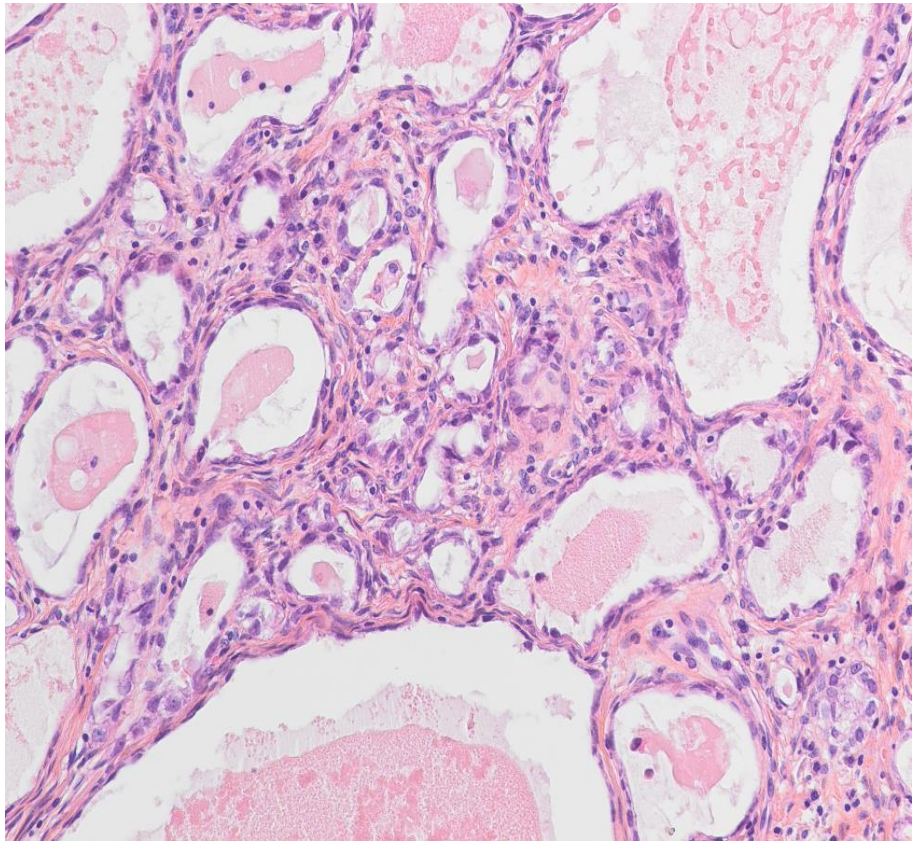

CLEAR CELL CARCINOMA OF CERVIX MIMICKING MESONEPHRIC

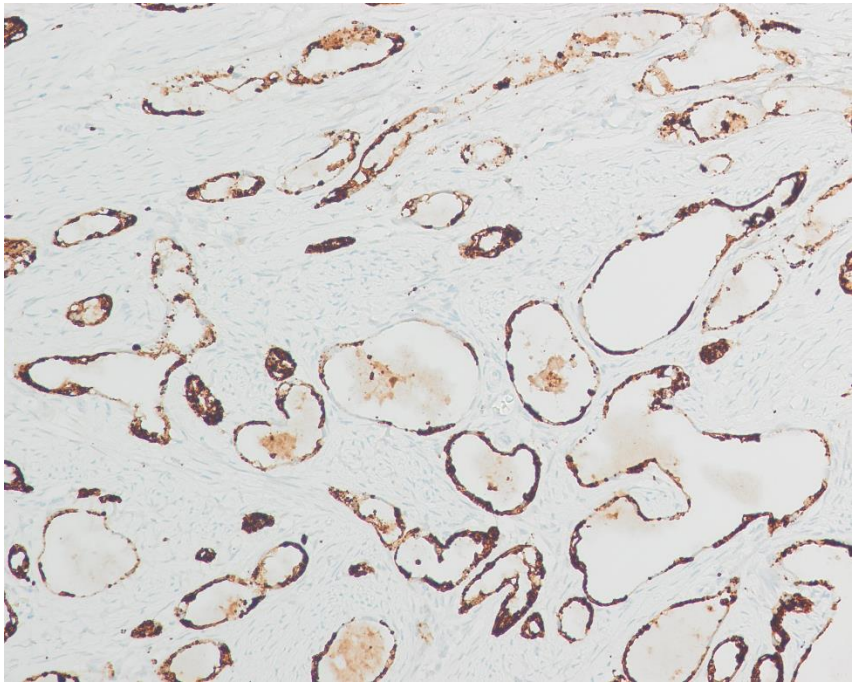

Napsin A

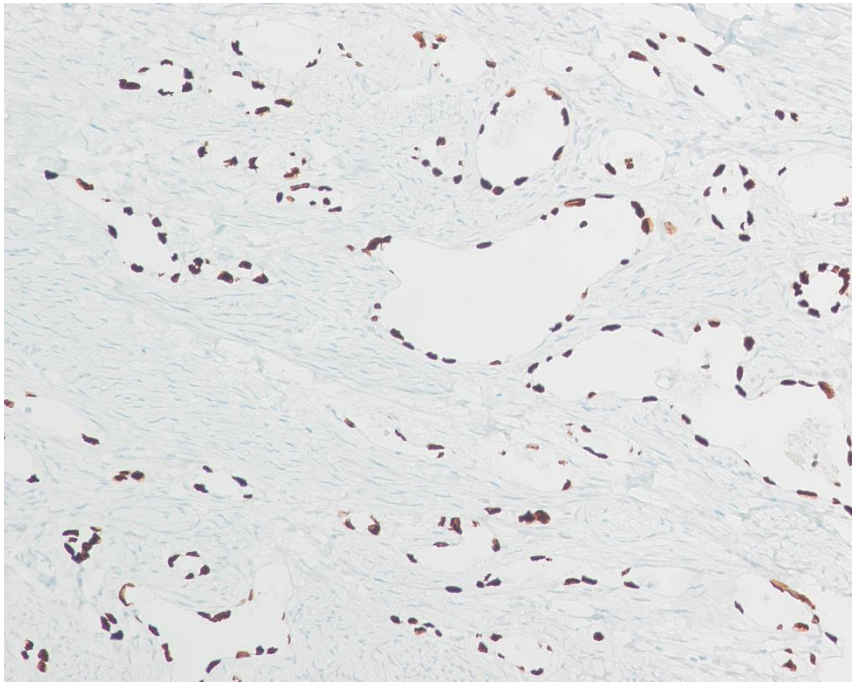

HNF1 beta

CERVICAL ENDOMETRIOID ADENOCARCINOMAS

- Very uncommon
- Previously overdiagnosed (mucin-depleted usual-type HPV-associated adenocarcinomas)
- Very rarely get true endometrioid adenocarcinoma arising from cervical endometriosis (HPV-independent)