The British Association of Gynaecological Pathologists

21st Annual Meeting in Collaboration with ISGyP

5th and 6th June 2025

- Title. Gestational Trophoblastic Neoplasia
- Speaker. Pei Hui, MD
- Affiliation. Yale University School of Medicine
- Date. 6th June 2025

The British Association of Gynaecological Pathologists

Speaker disclosures

I have no relevant financial conflicts of interest to disclose

- Pathological Classification
- Precision Diagnosis
- Therapeutic and Prognostic Implications



Diagnosis of Post-molar GTN

- Clinical Diagnosis – plateauing or rising serum hCG during post-molar surveillance
- Histologic confirmation – typically not needed

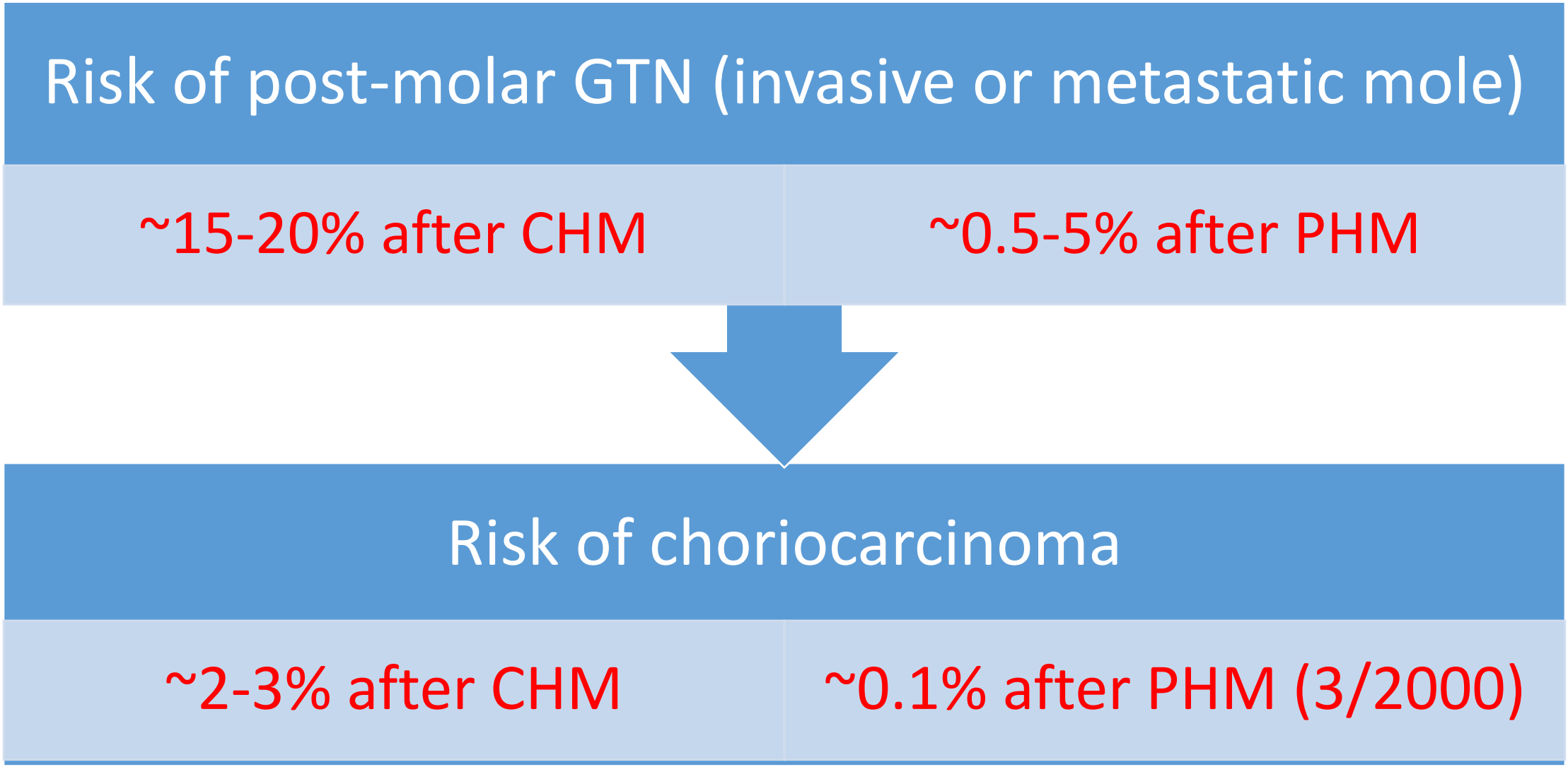
Risk of post-molar GTN (invasive or metastatic mole)
~15-20% after CHM
~0.5-5% after PHM
Risk of choriocarcinoma
~2-3% after CHM
~0.1% after PHM (3/2000)

Gestational Trophoblastic Neoplasia (GTN)

- Invasive mole (complete or partial)
- Gestational choriocarcinoma
- Placental site trophoblastic tumor (PSTT)
- Epithelioid trophoblastic tumor (ETT)

Invasive Hydatidiform Mole



Invasive Complete Mole

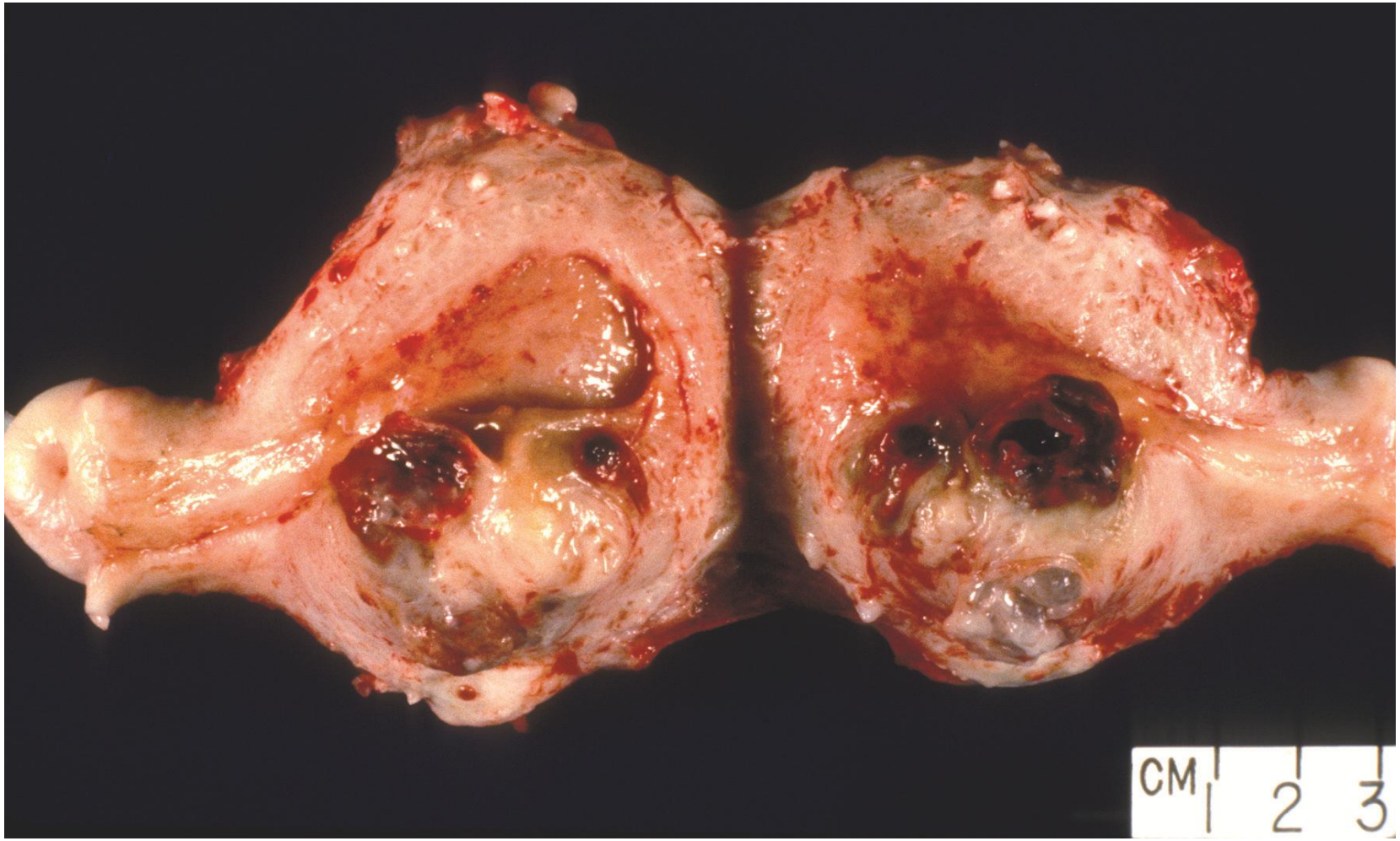

Invasive Complete Mole

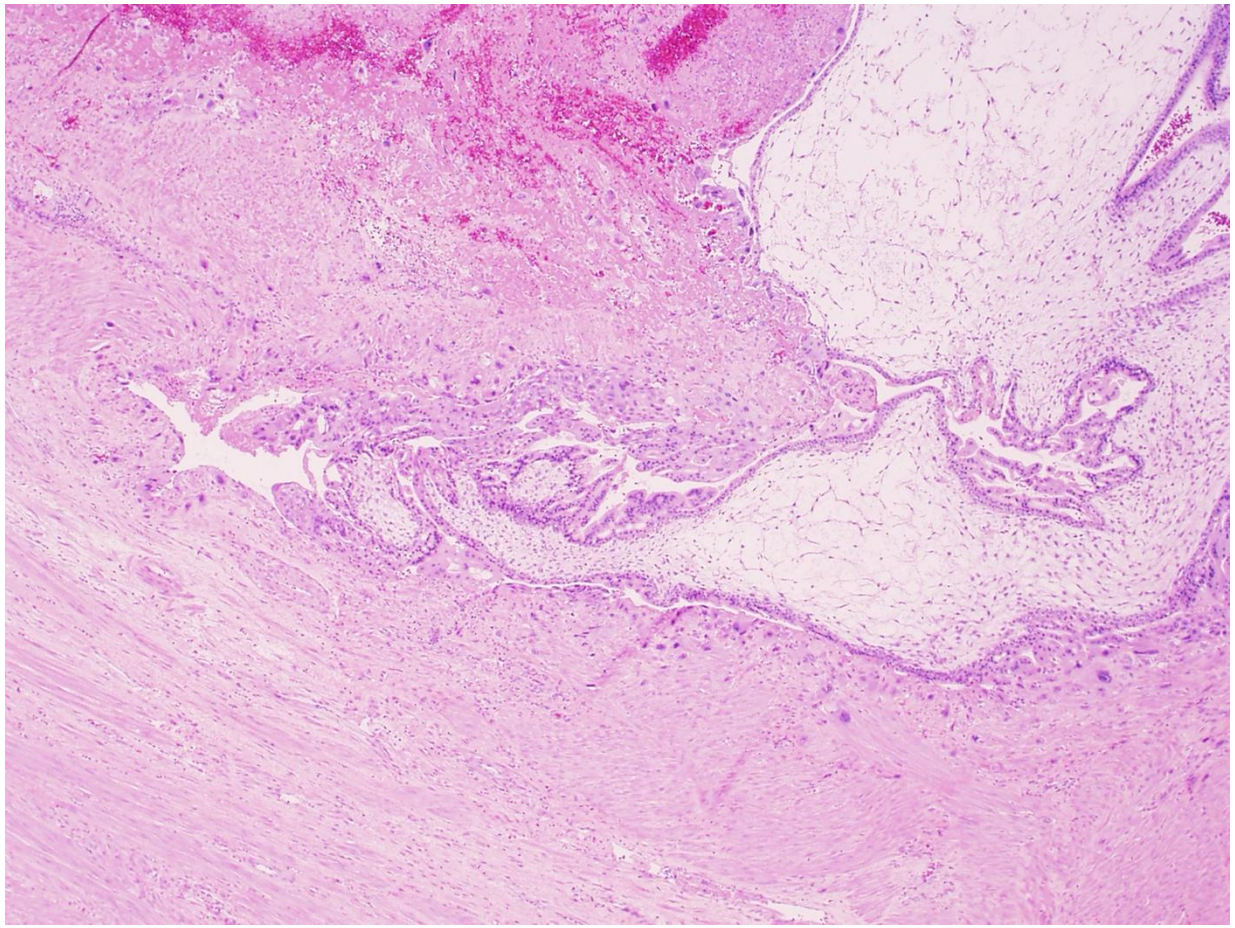

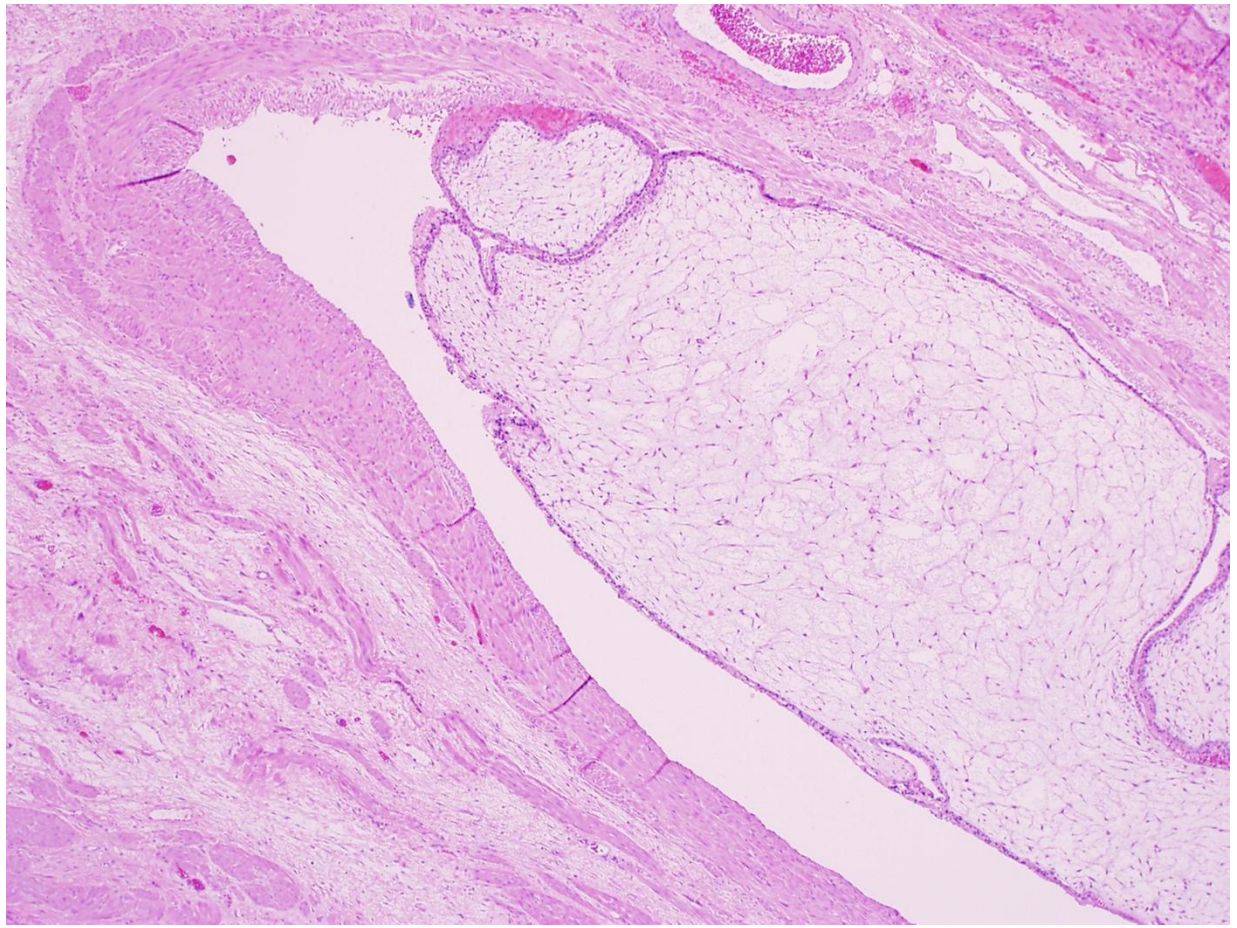

Invasive Partial Mole

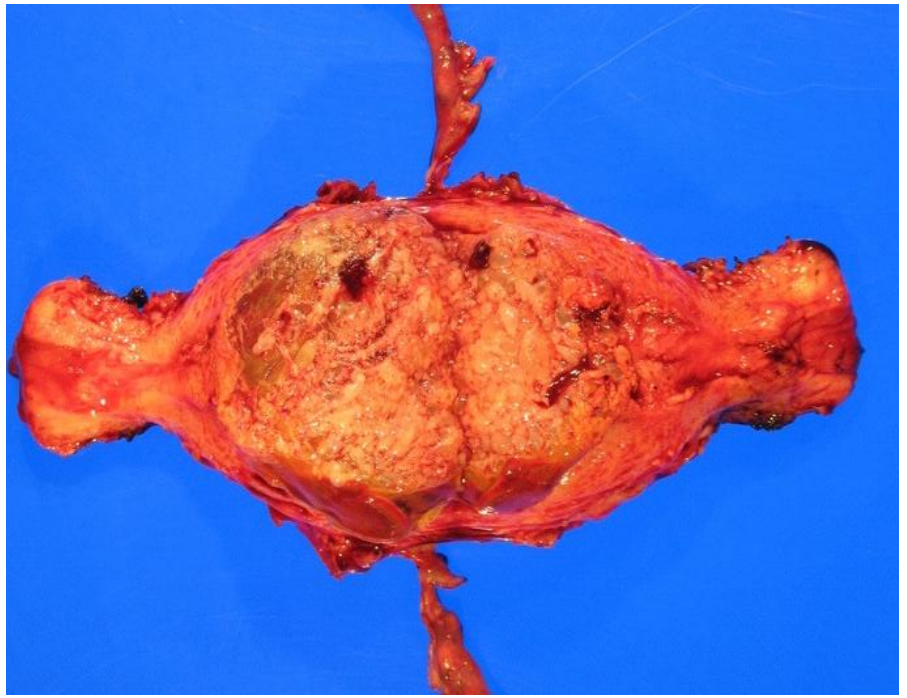

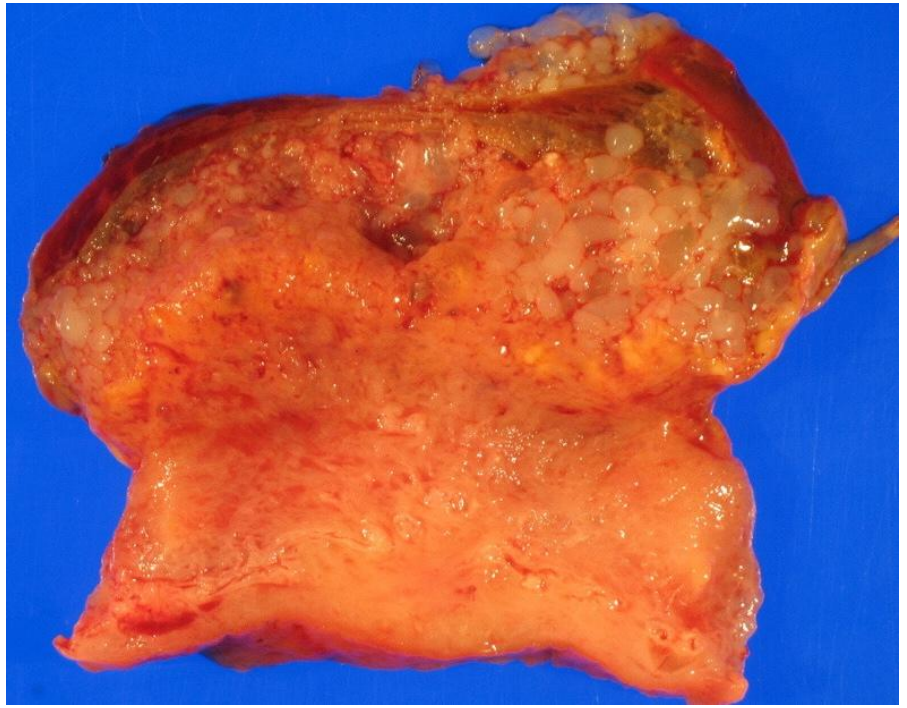

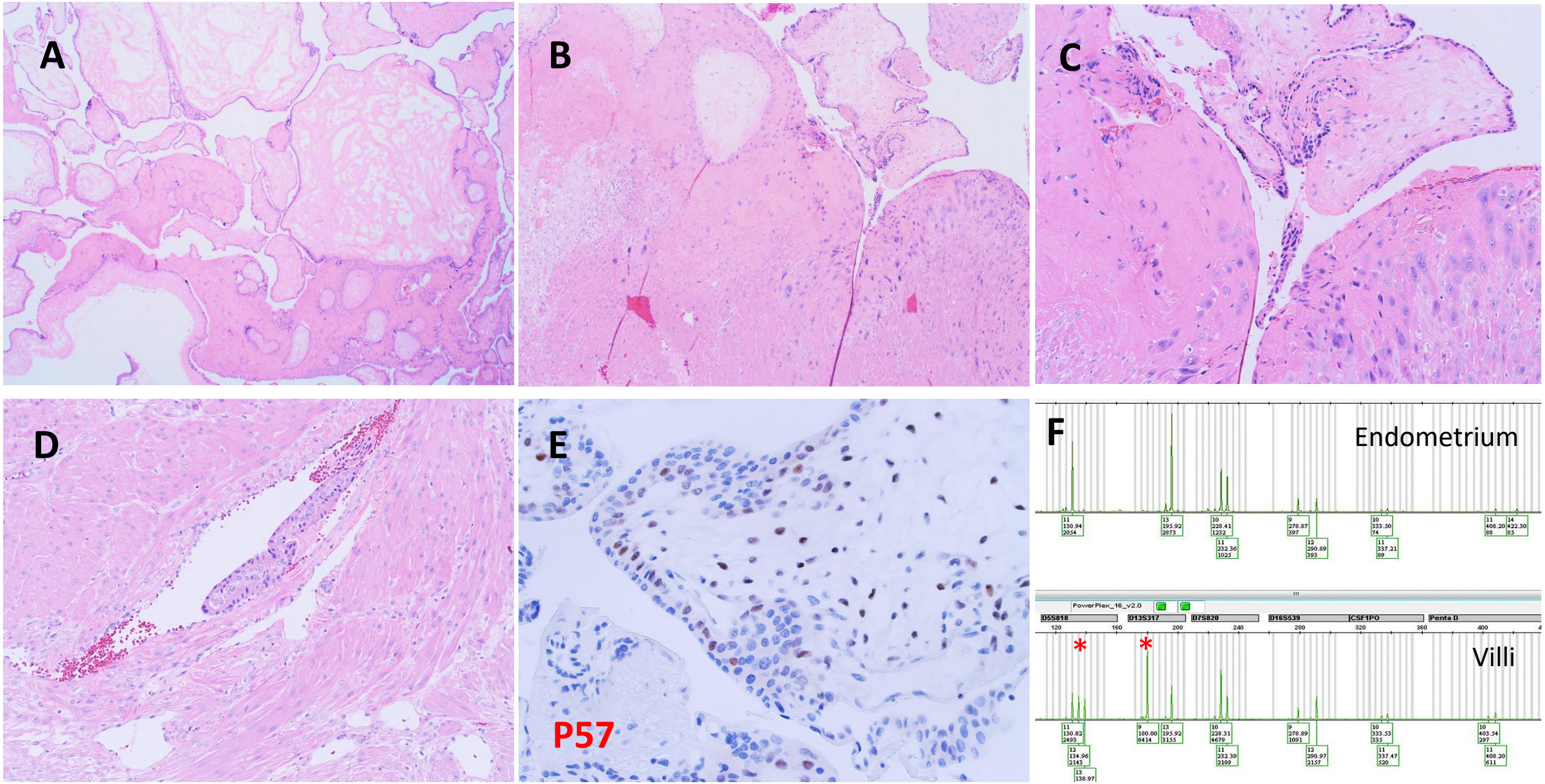
A
B
C
D
E
P57
F
Endometrium
PowerPlex_16_v2.0
D5S818
D13S317
D7S820
D16S539
CSF1PO
Penta D
Villi

Gestational Choriocarcinoma



Gestational Choriocarcinoma

- The most common gestational trophoblastic tumor
- Vaginal bleeding or extrauterine hemorrhage
- Serum hCG over 10,000 mIU/ml
- Bulky uterine masses with extensive hemorrhage and necrosis

Gestational Choriocarcinoma



Curtesy of Dr. Xianrong Zhou, 2021

Gestational Choriocarcinoma

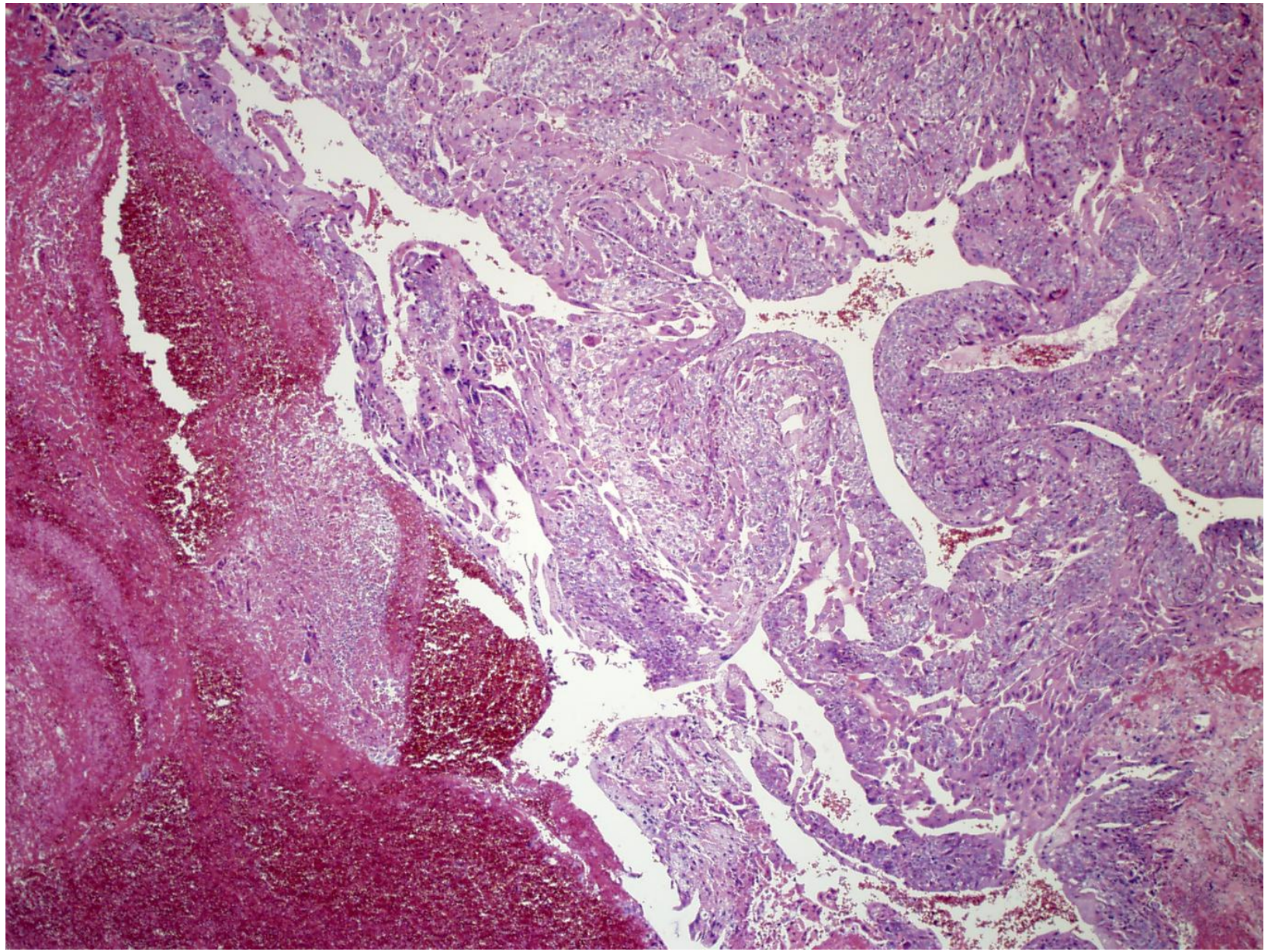

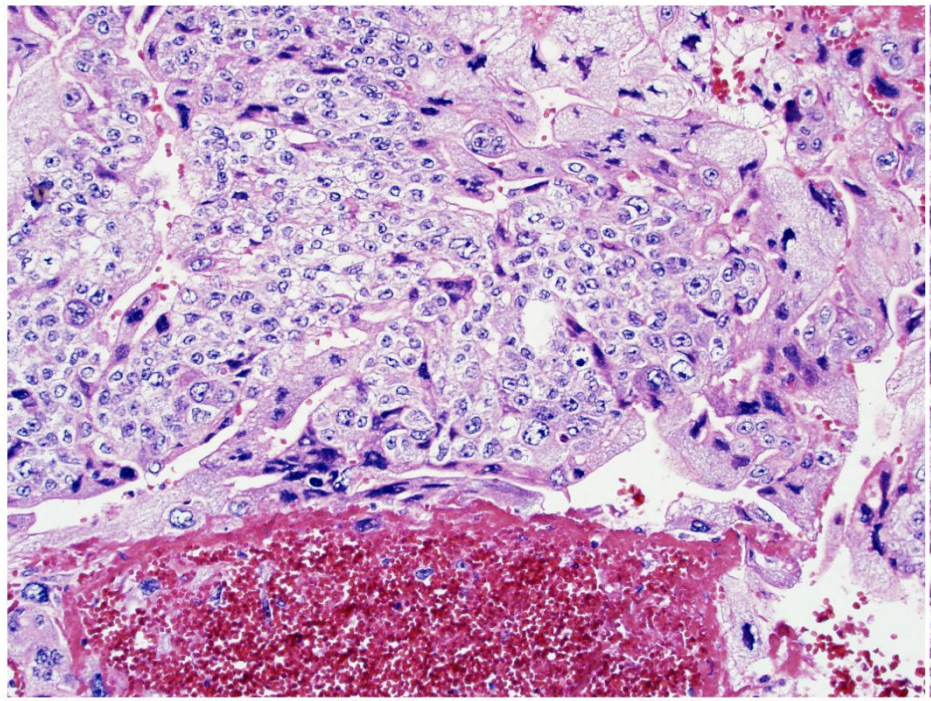
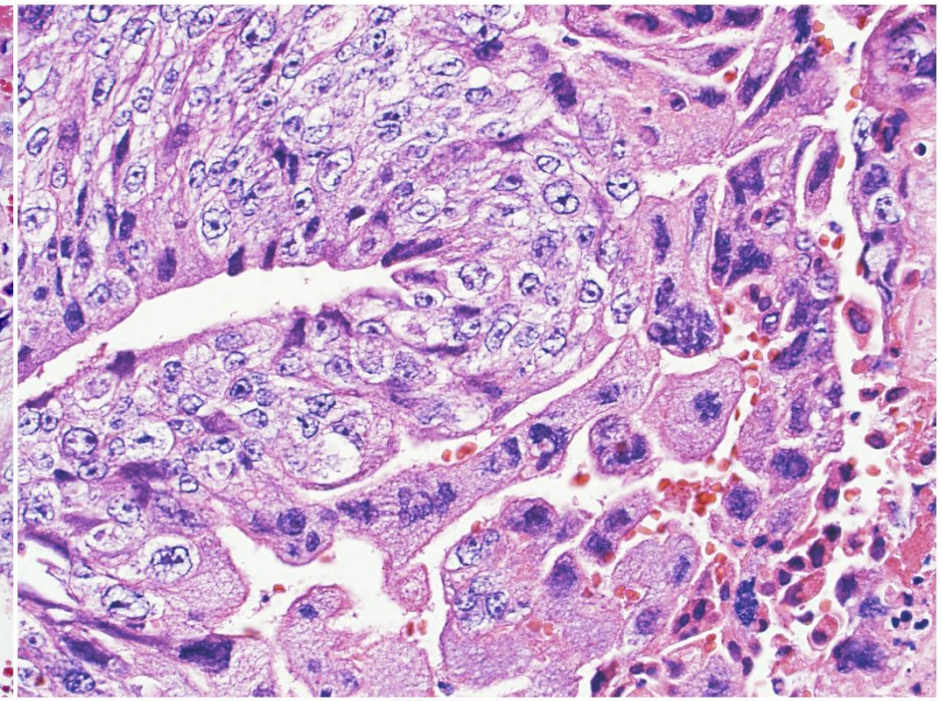
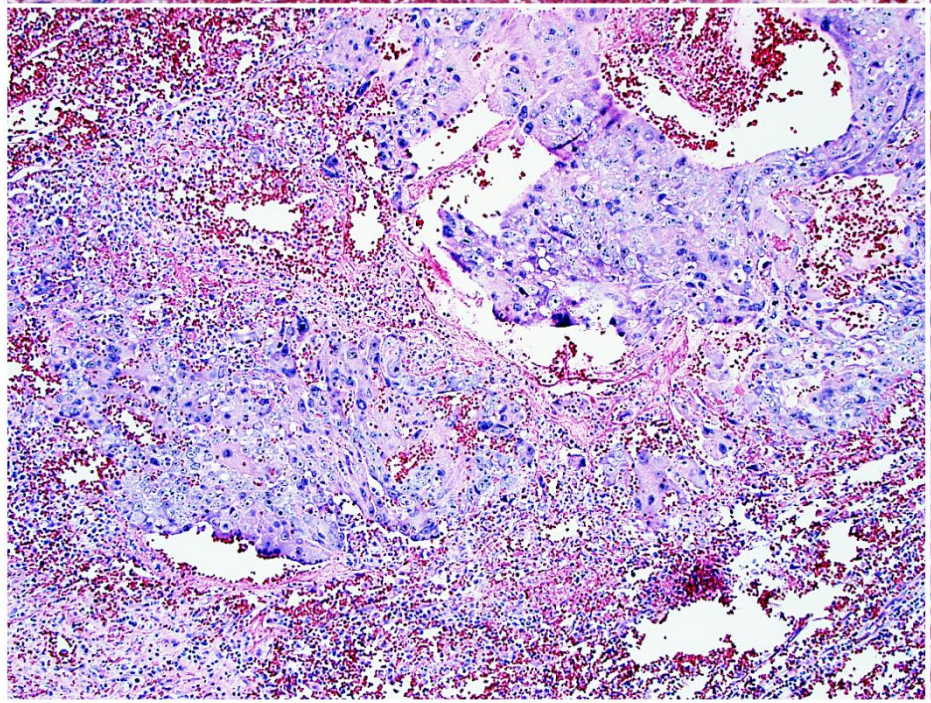
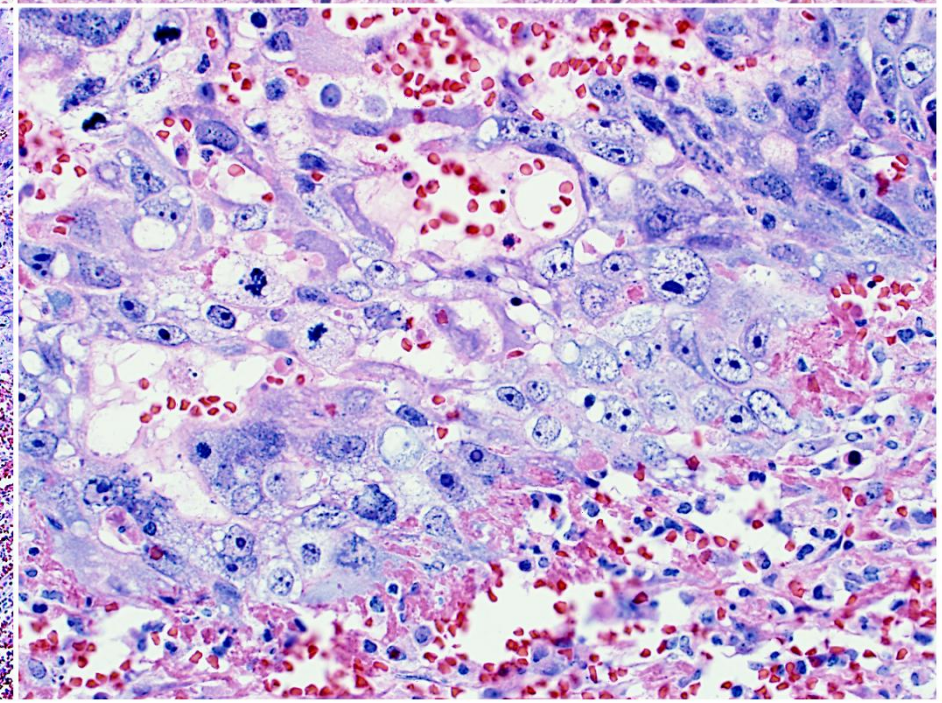

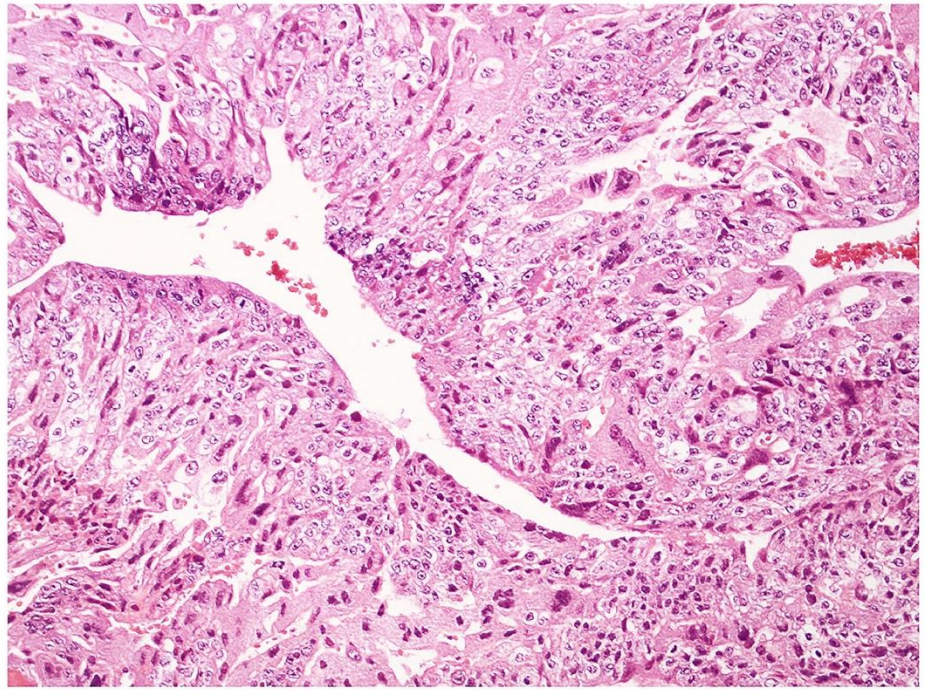

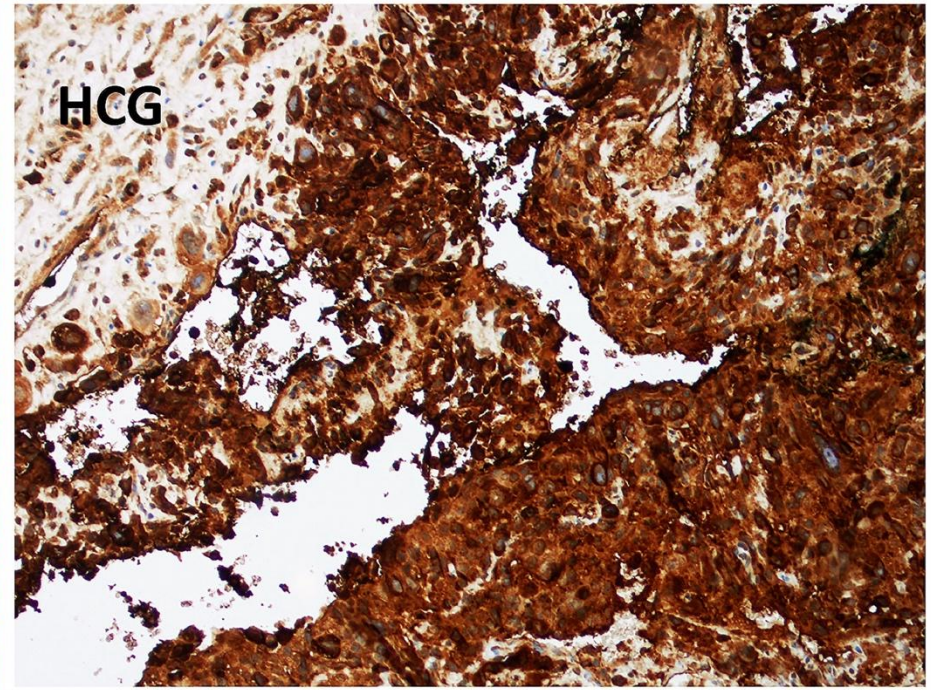
HCG

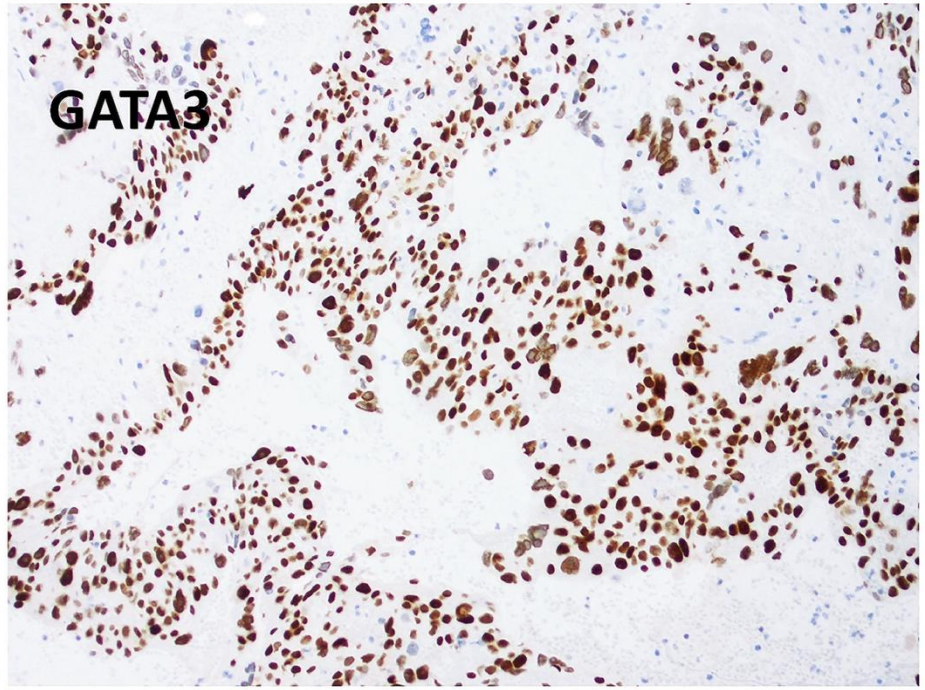
GATA3

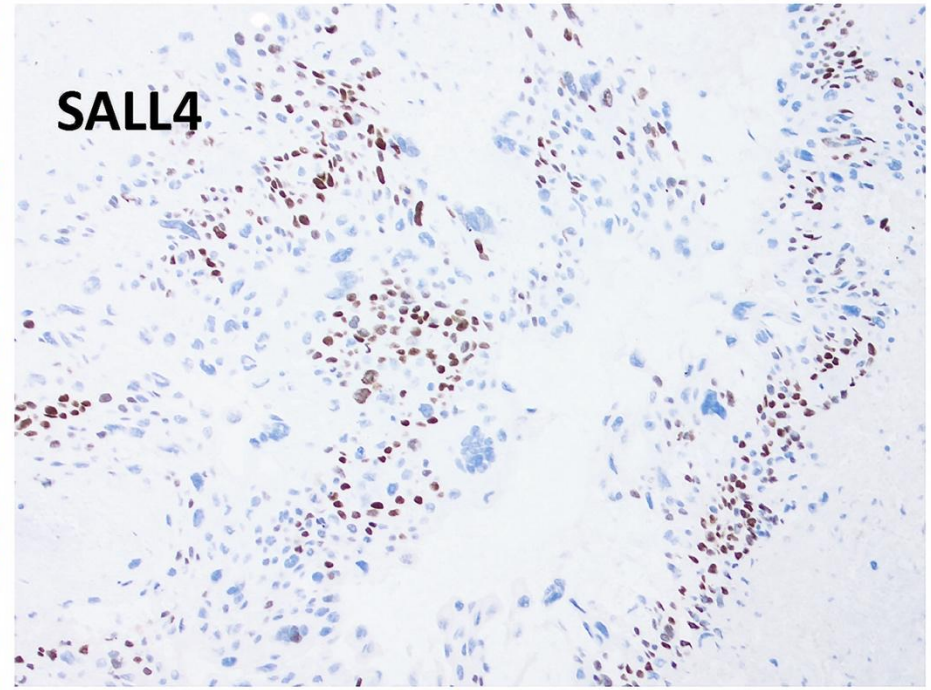
SALL4

WHO Tumor Classification (2020)

Intraplacental choriocarcinoma: intraplacental lesion of markedly atypical trophoblasts resembling choriocarcinoma.

Intramolar choriocarcinoma: abundant proliferation of markedly atypical trophoblasts resembling choriocarcinoma associated with rare molar villi.

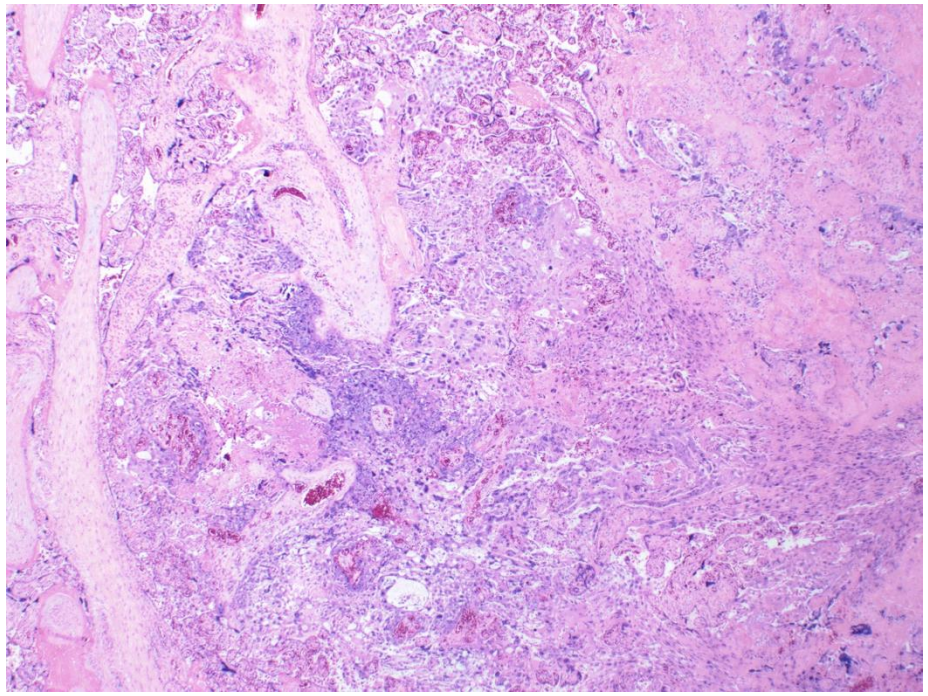
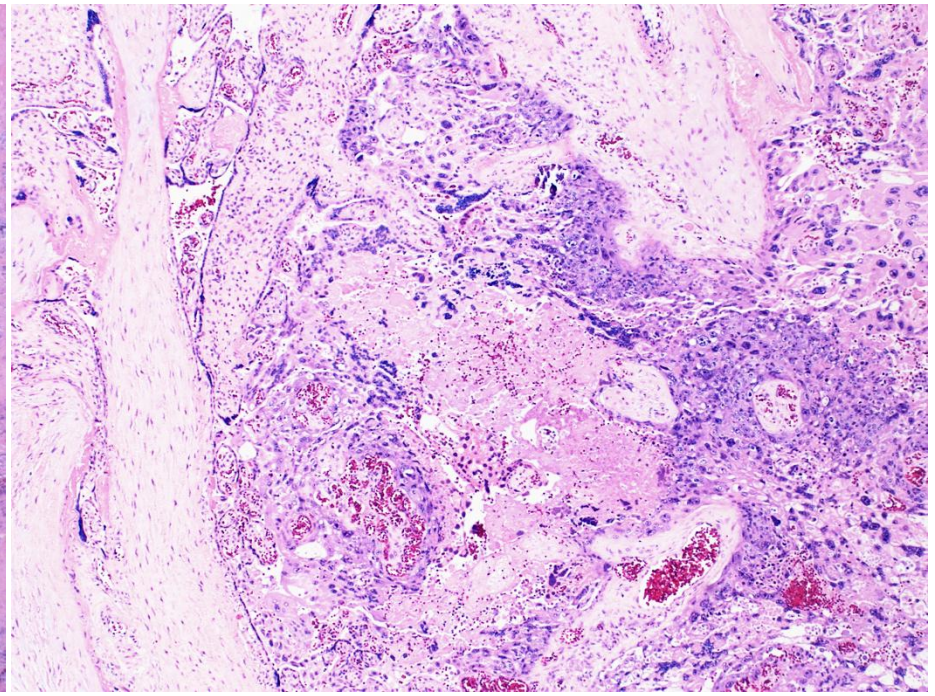
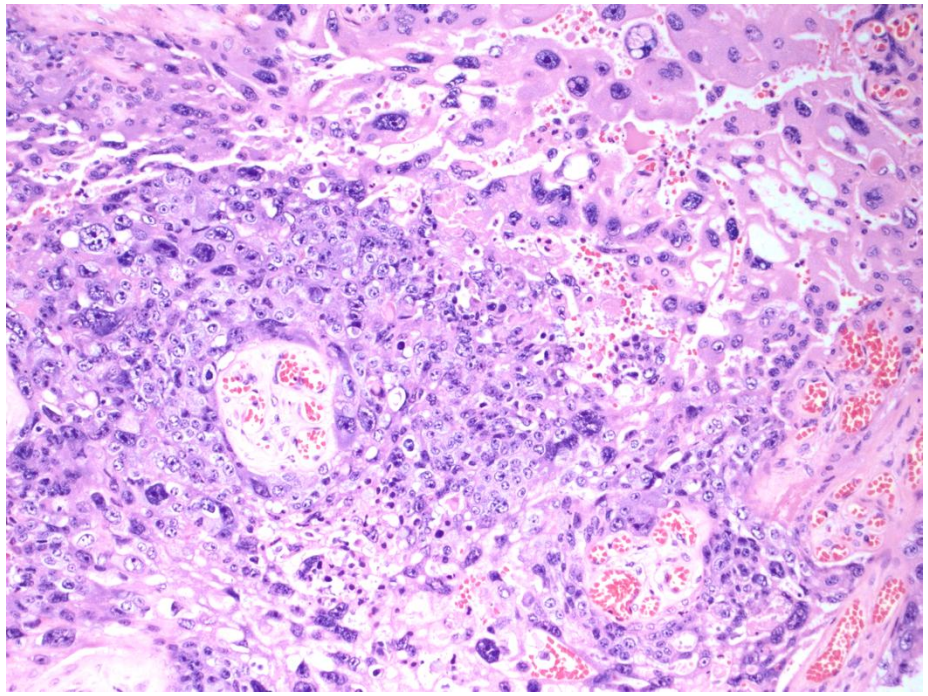
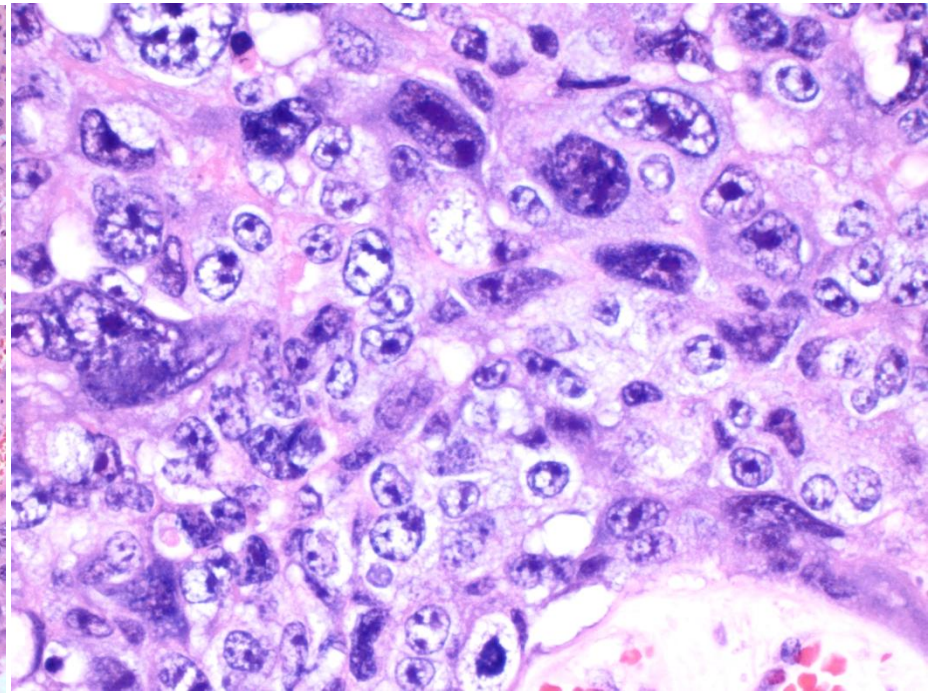

Intraplacental choriocarcinoma

Intraplacental Choriocarcinoma (curettage specimen)

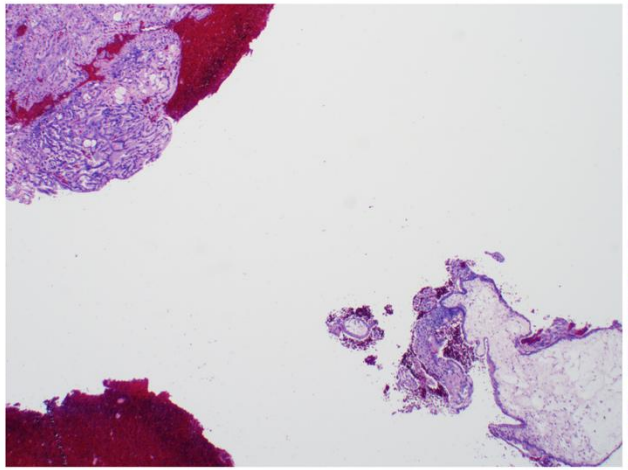

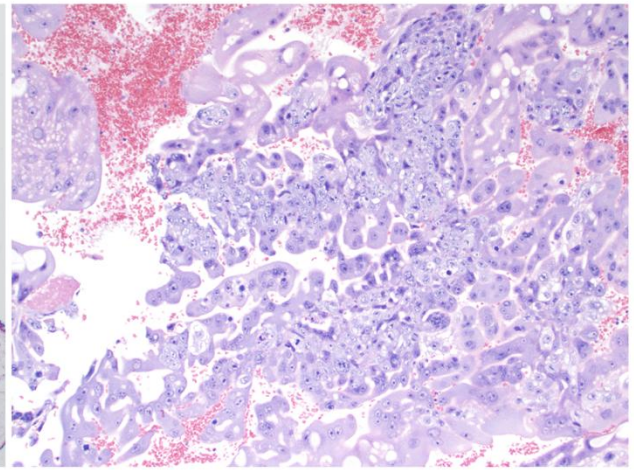

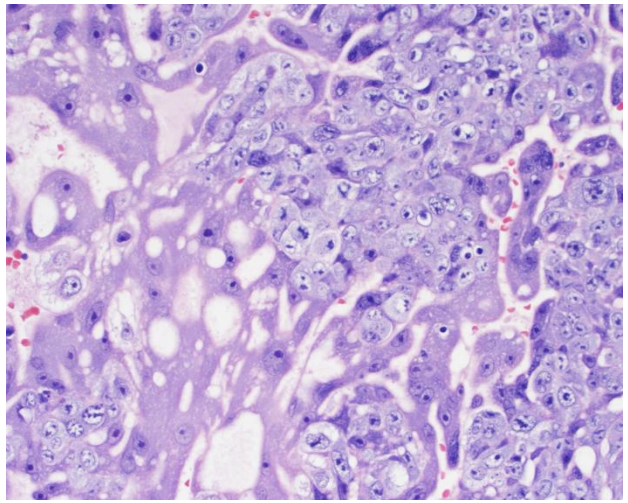

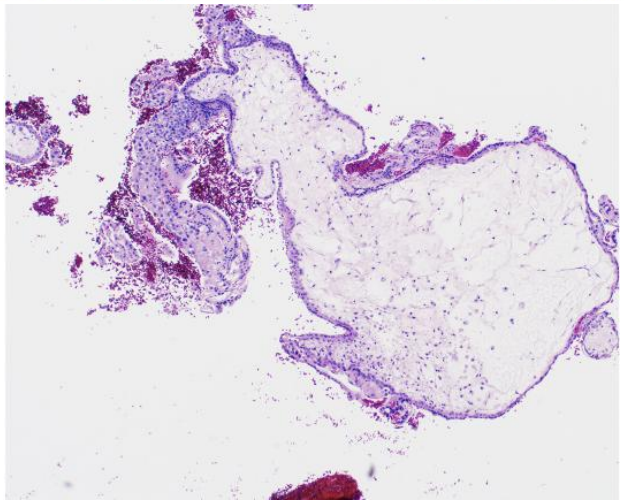

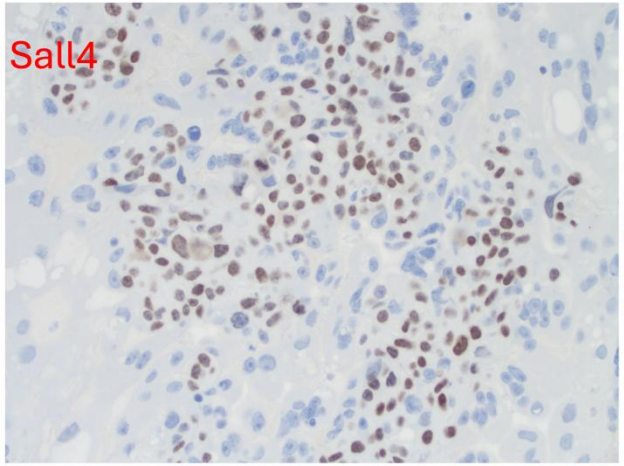

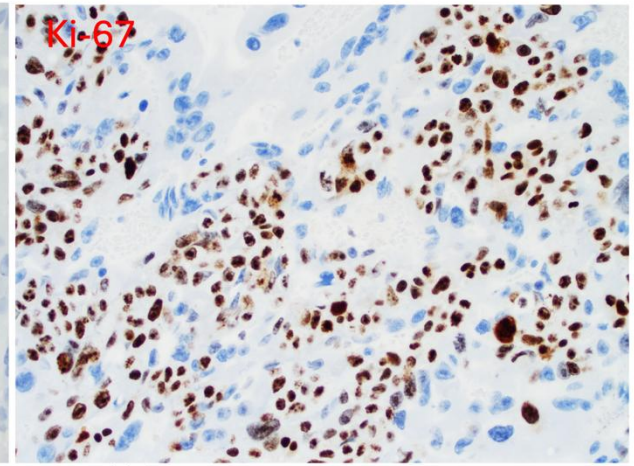

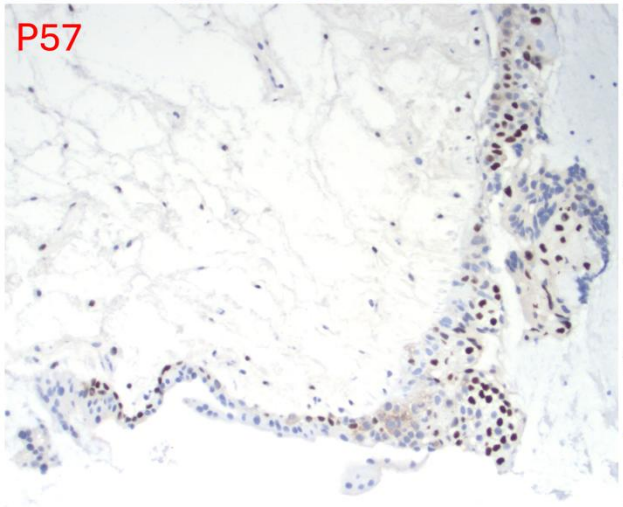



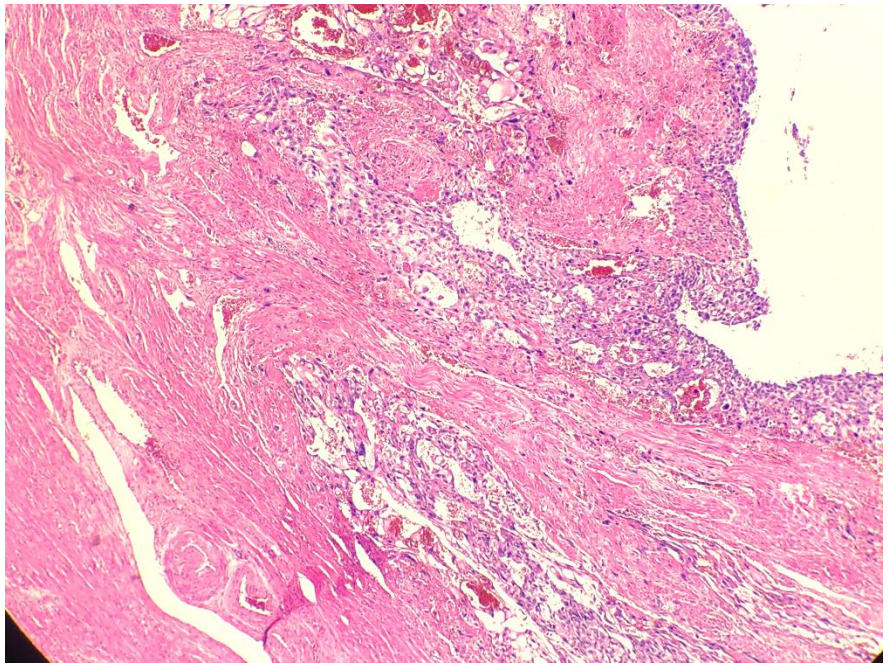

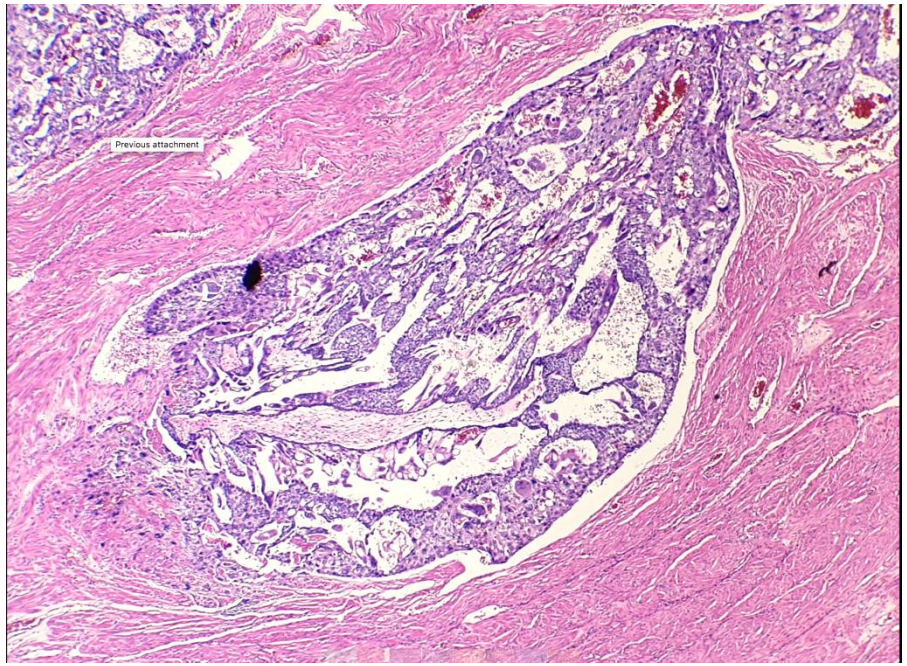

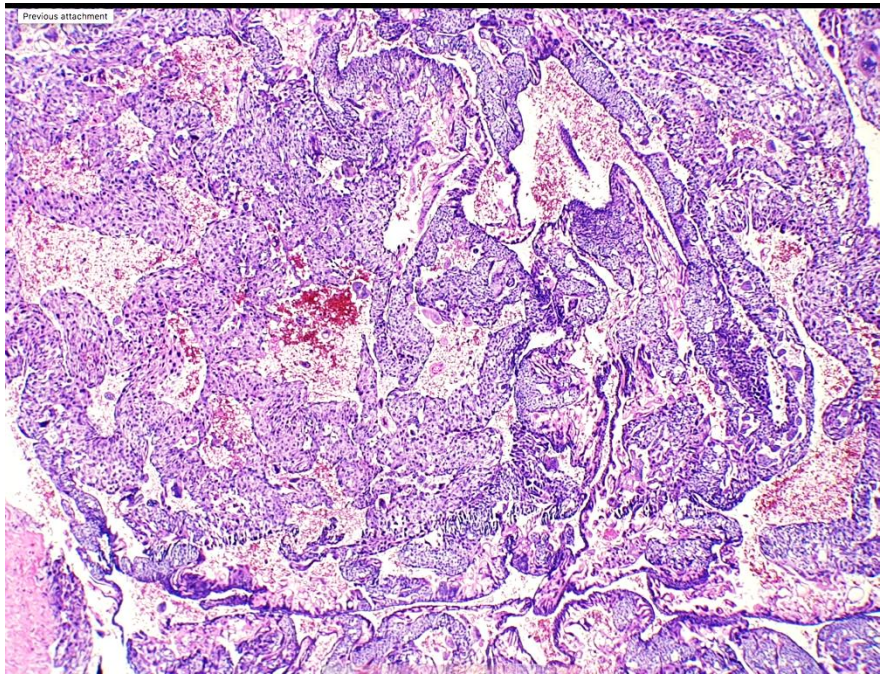

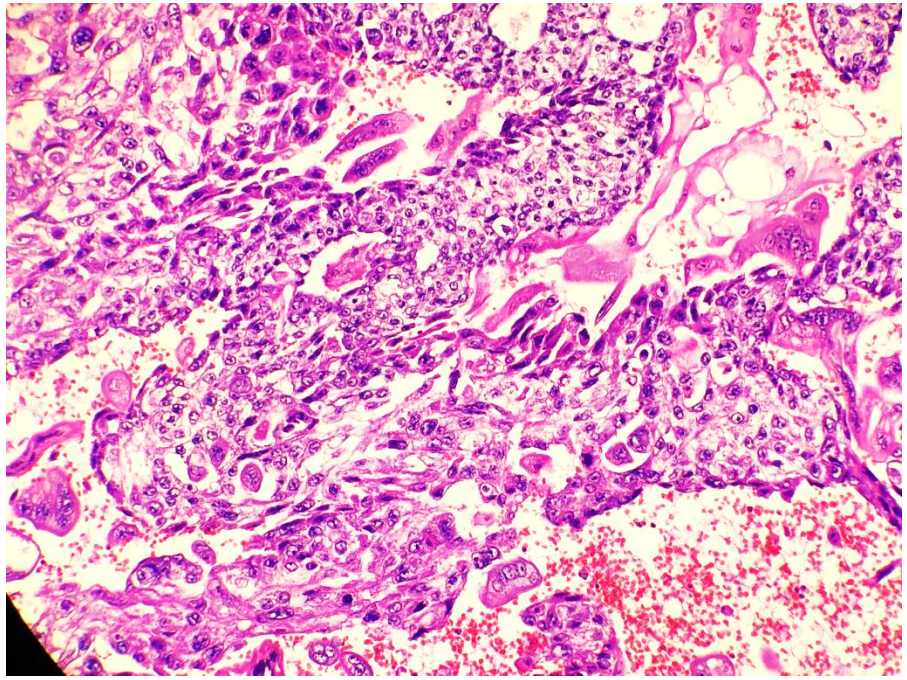

Intra-molar Choriocarcinoma in Invasive CHM

Curtesy of Dr. Rubina Razack, 2020

Intra-molar Choriocarcinoma in Complete Mole

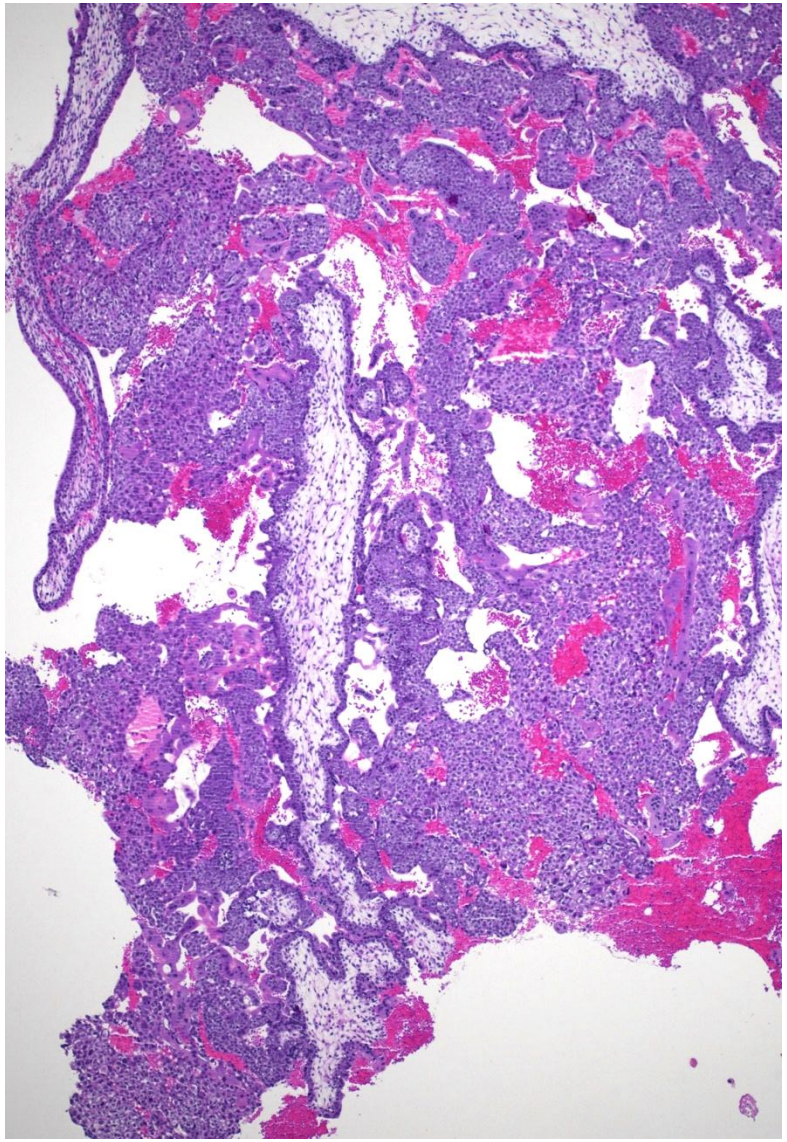

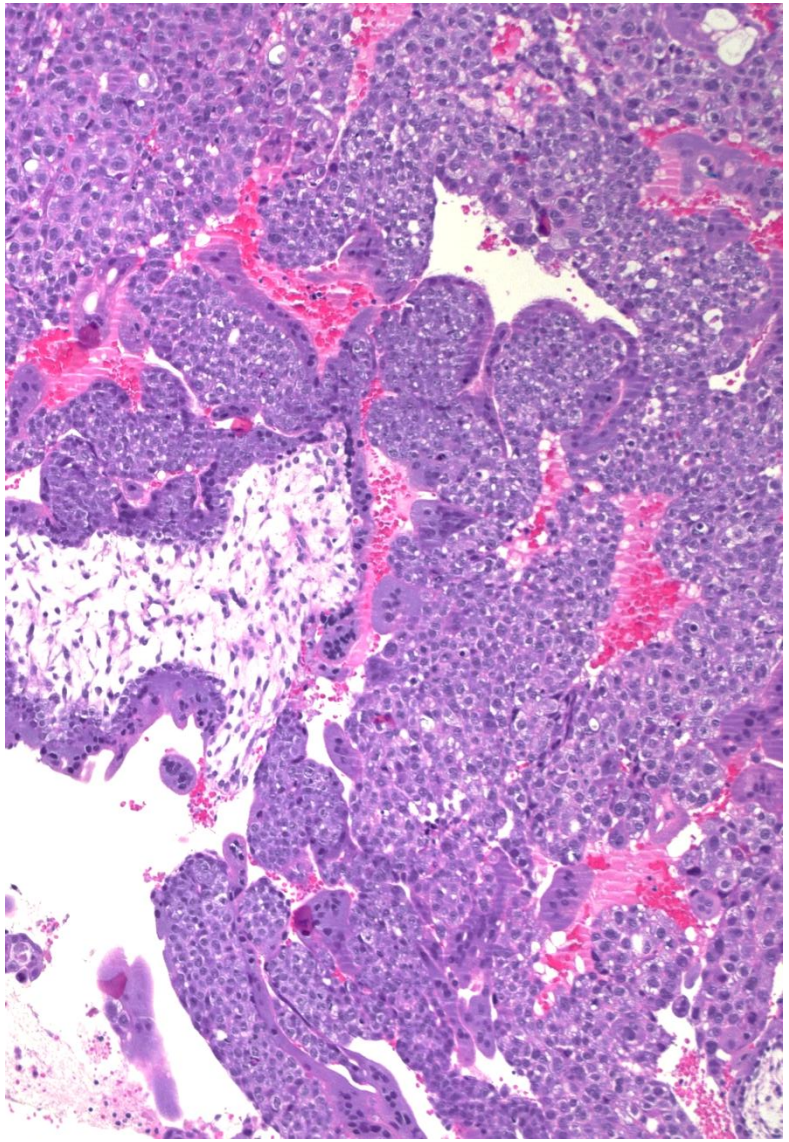

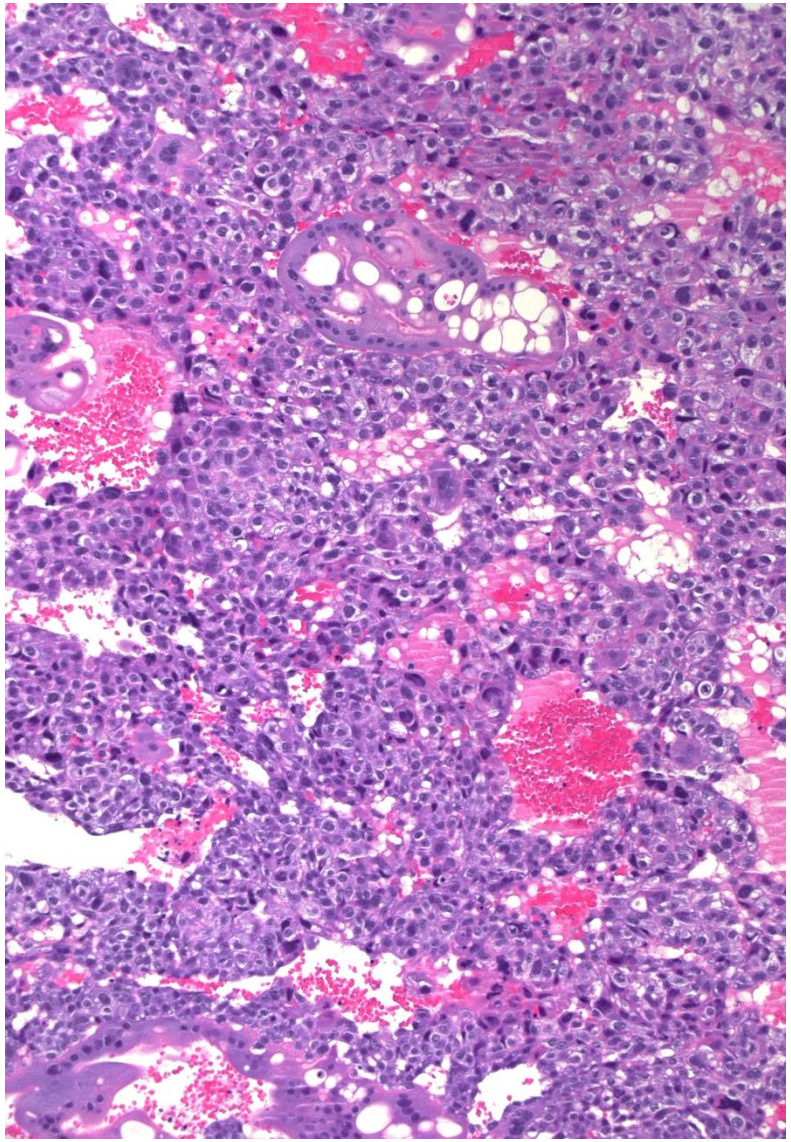

Curtesy of Dr. Maria Orsaria, 2021

Intra-molar Choriocarcinoma Arising from Tubal CHM

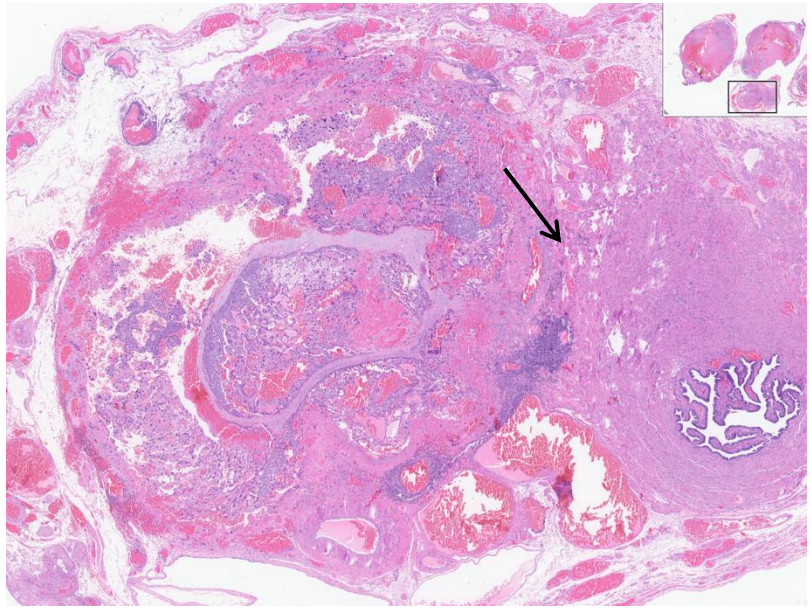

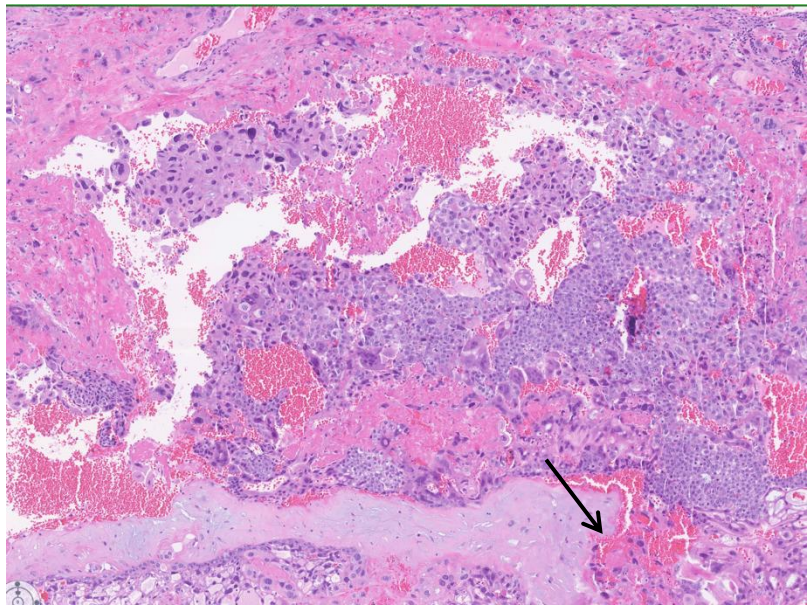

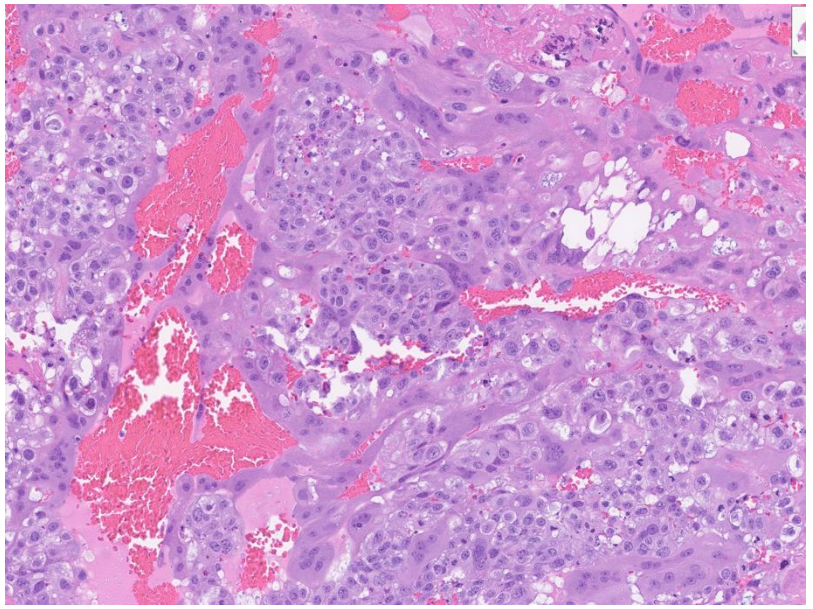

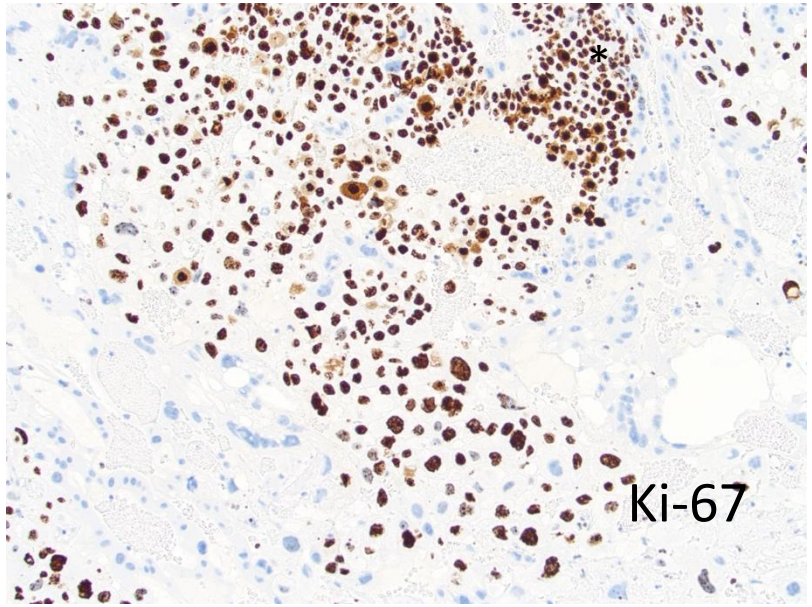

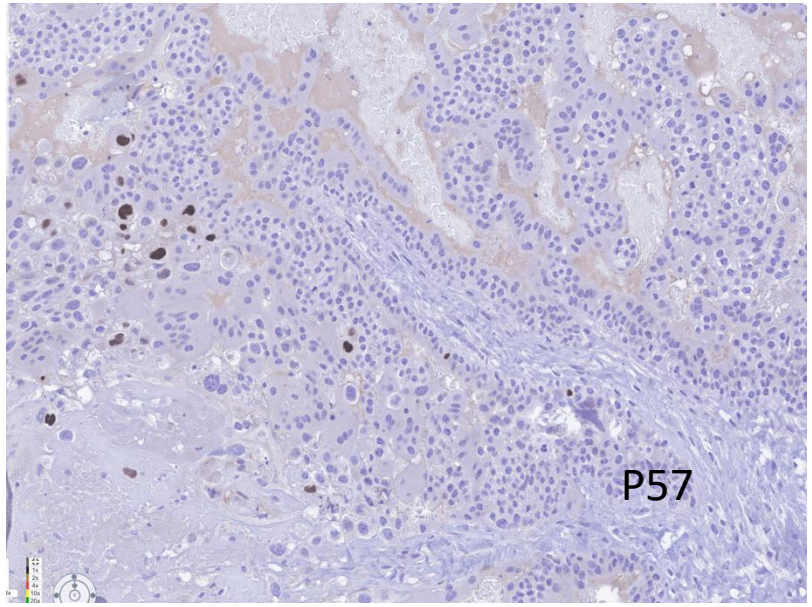

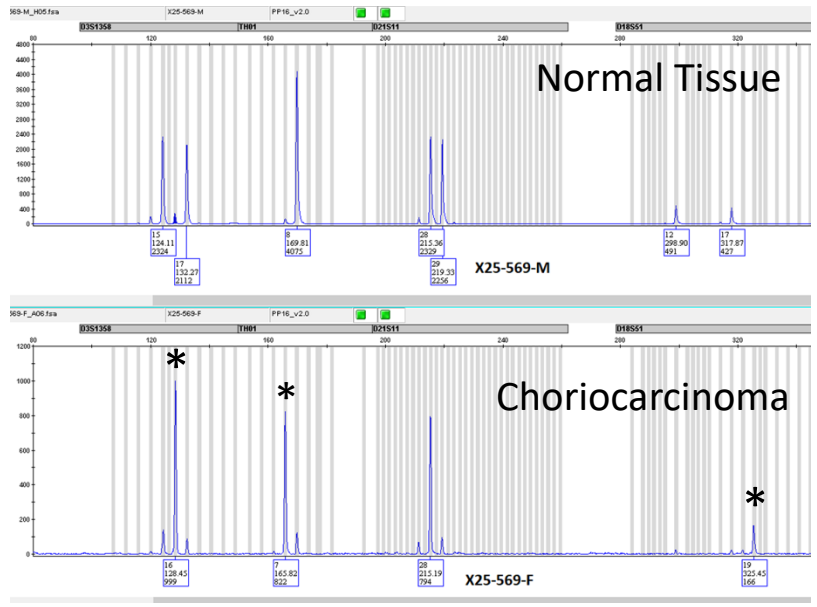

Diagnostic criterion – Yet to be defined

- Abundant biphasic trophoblastic proliferation
- Rare molar villi
- Markedly atypical trophoblasts
- Presence of necrosis
- Ki-67 of >70% in mononuclear trophoblasts

CASE PRESENTATION

29-year-old underwent D/C for demised fetus at estimated 13.5 weeks of gestation with serum hCG of 163,308 mIU/ml. Villous karyotyping showed 69,XXY and PHM was diagnosed. Postmolar hCG decreased to 31 mIU/ml in 2.5 months and then bounced back. She underwent second D/C for presumed retained partial mole 3.5 months after the initial evacuation.

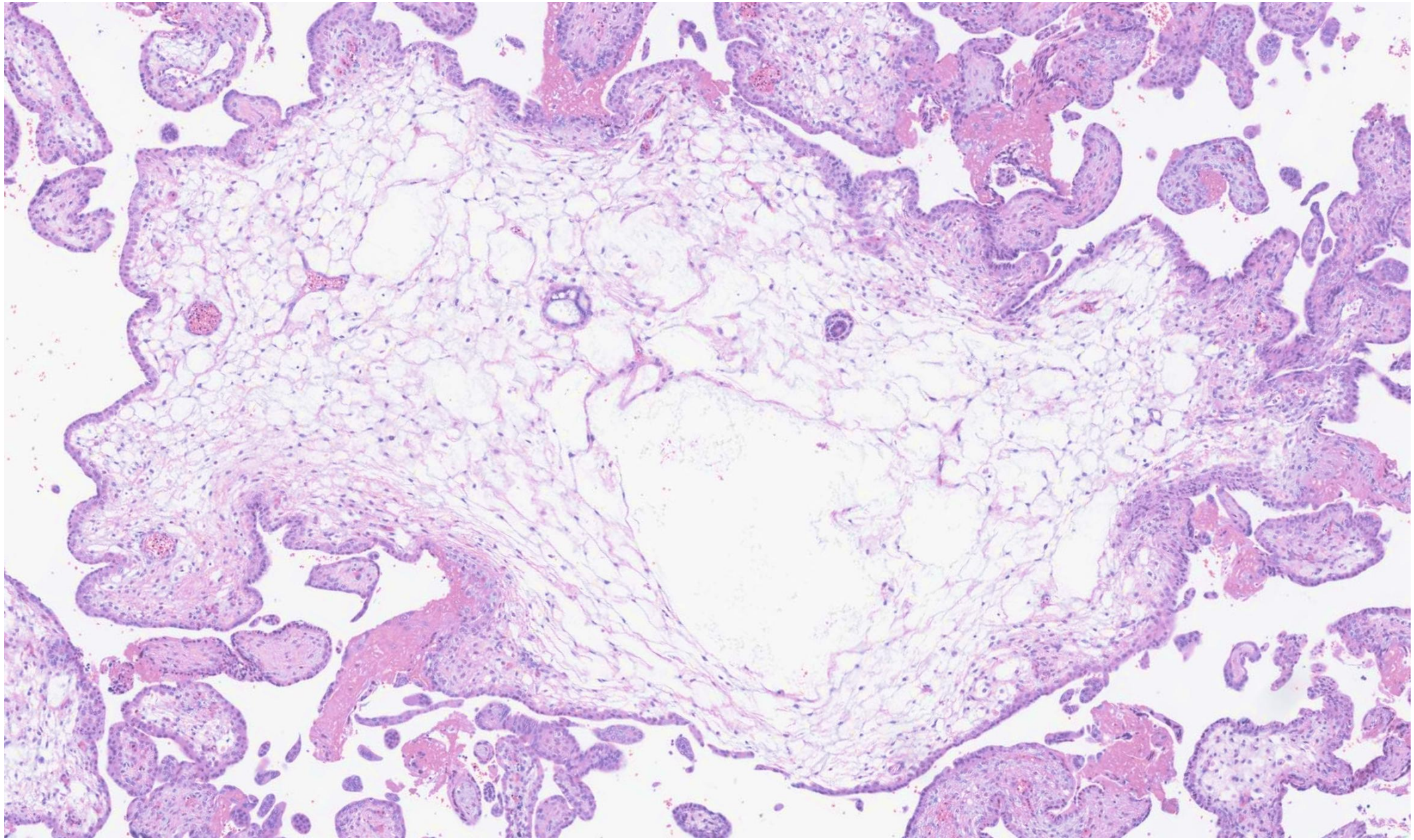

Initial D/C of PHM

Diandric Partial Hydatidiform Mole

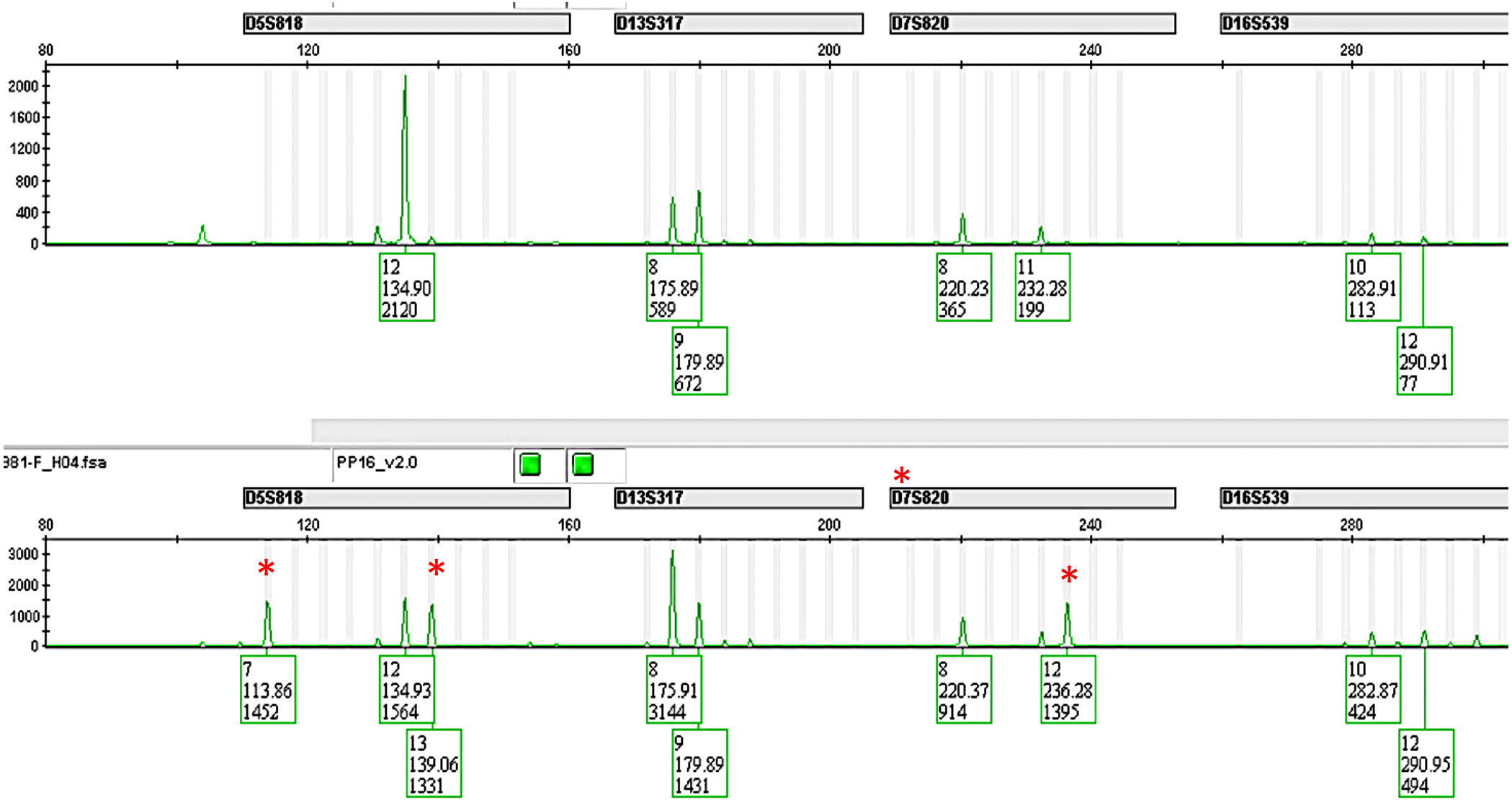

29-year-old underwent initial D/C for fetal demise with serum hCG of 163,308 mIU/ml leading to a diagnosis of partial mole with fetal demise. Postmolar hCG decreased to 31 mIU/ml in 2.5 months and bounced back. She underwent the second D/C for presumed retained partial mole 3.5 months later.

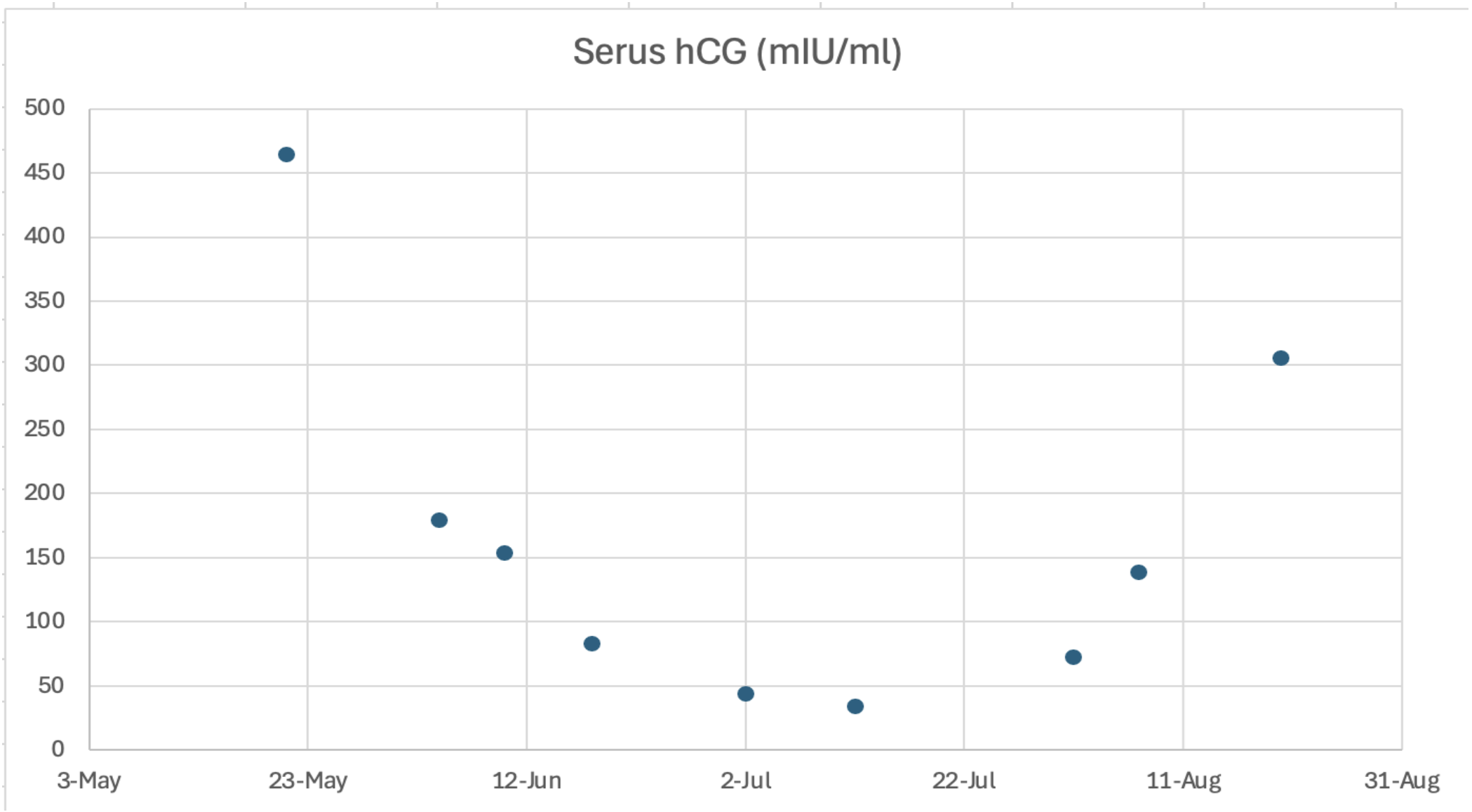

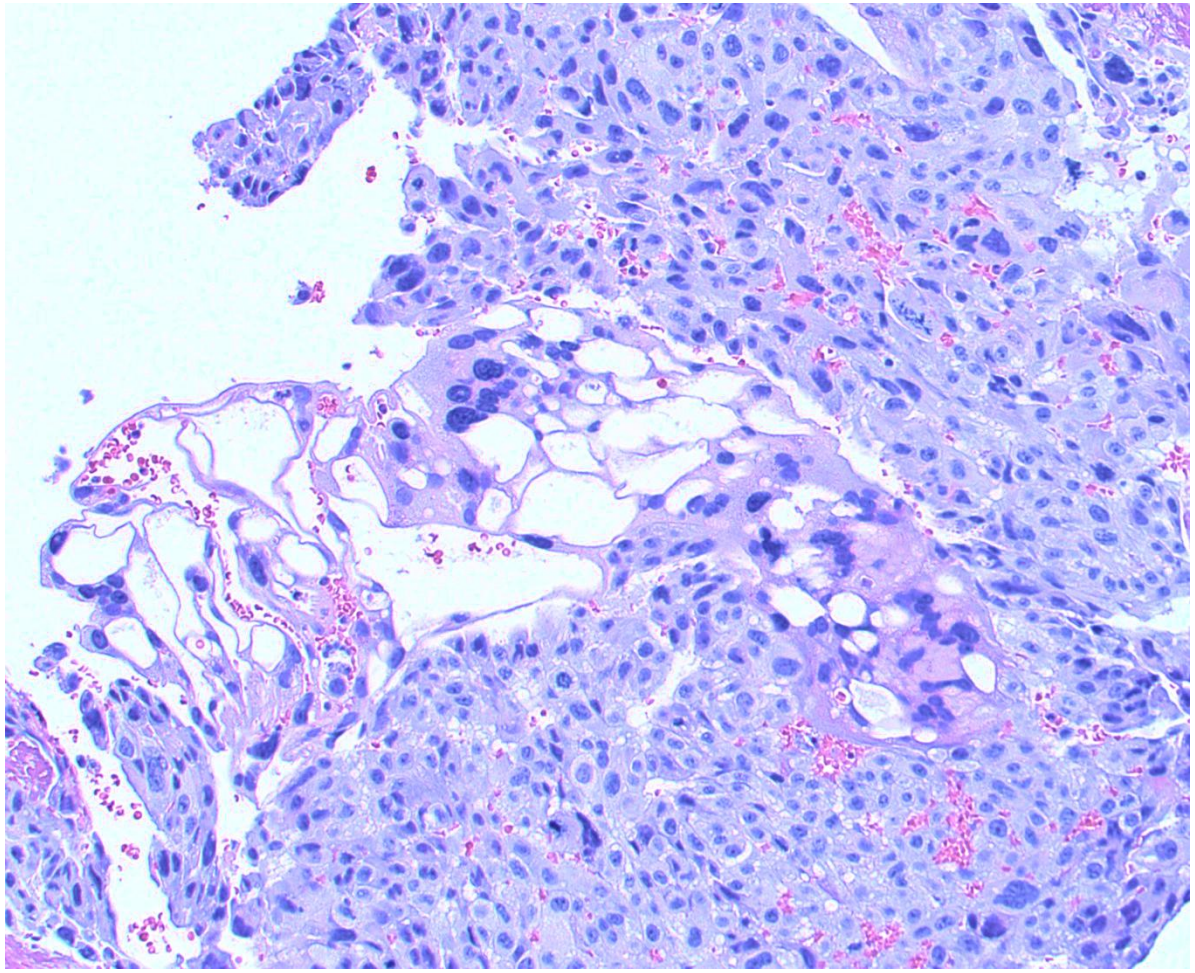

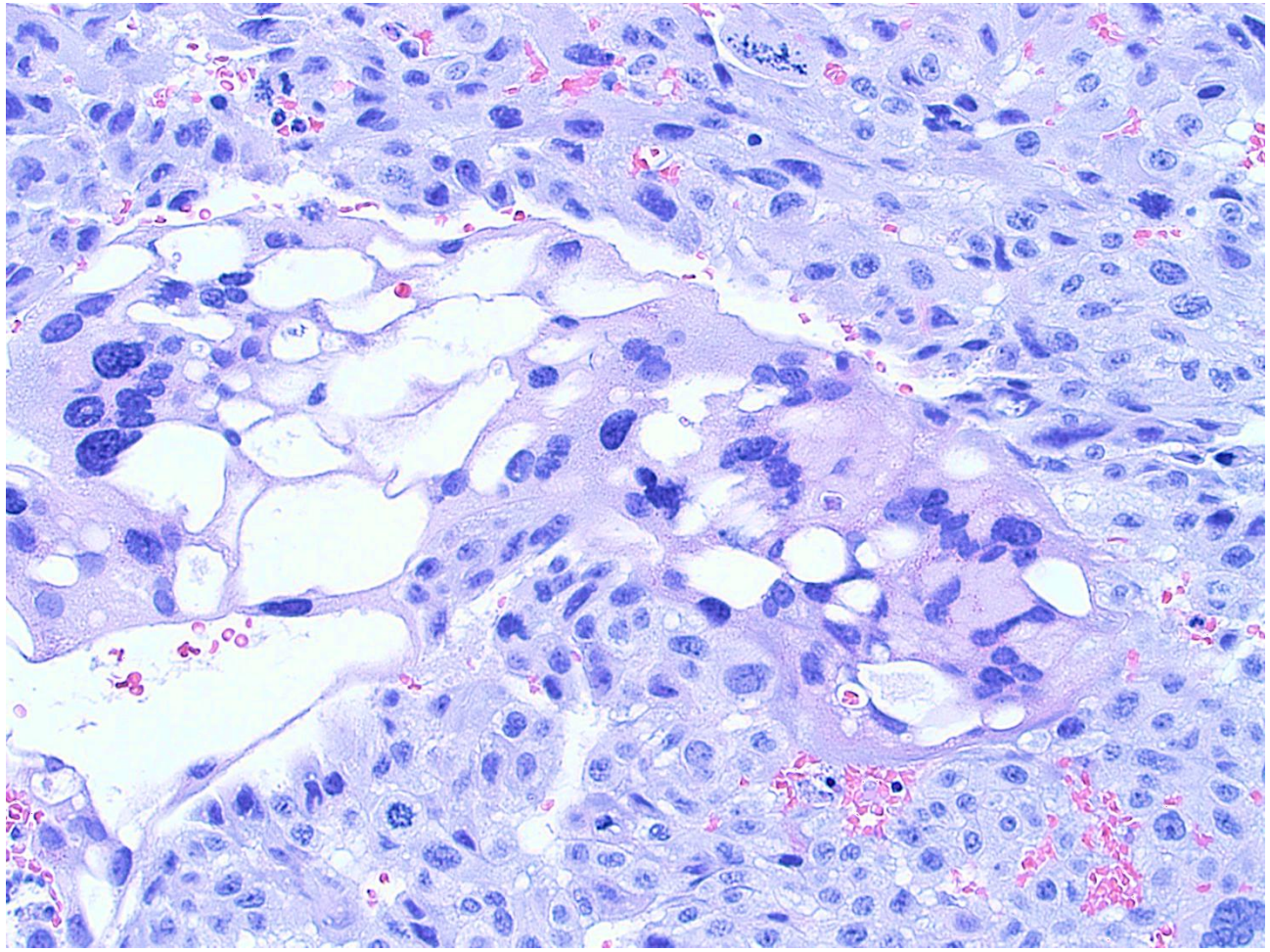

D/C 3.5 months after PHM. No molar villi found

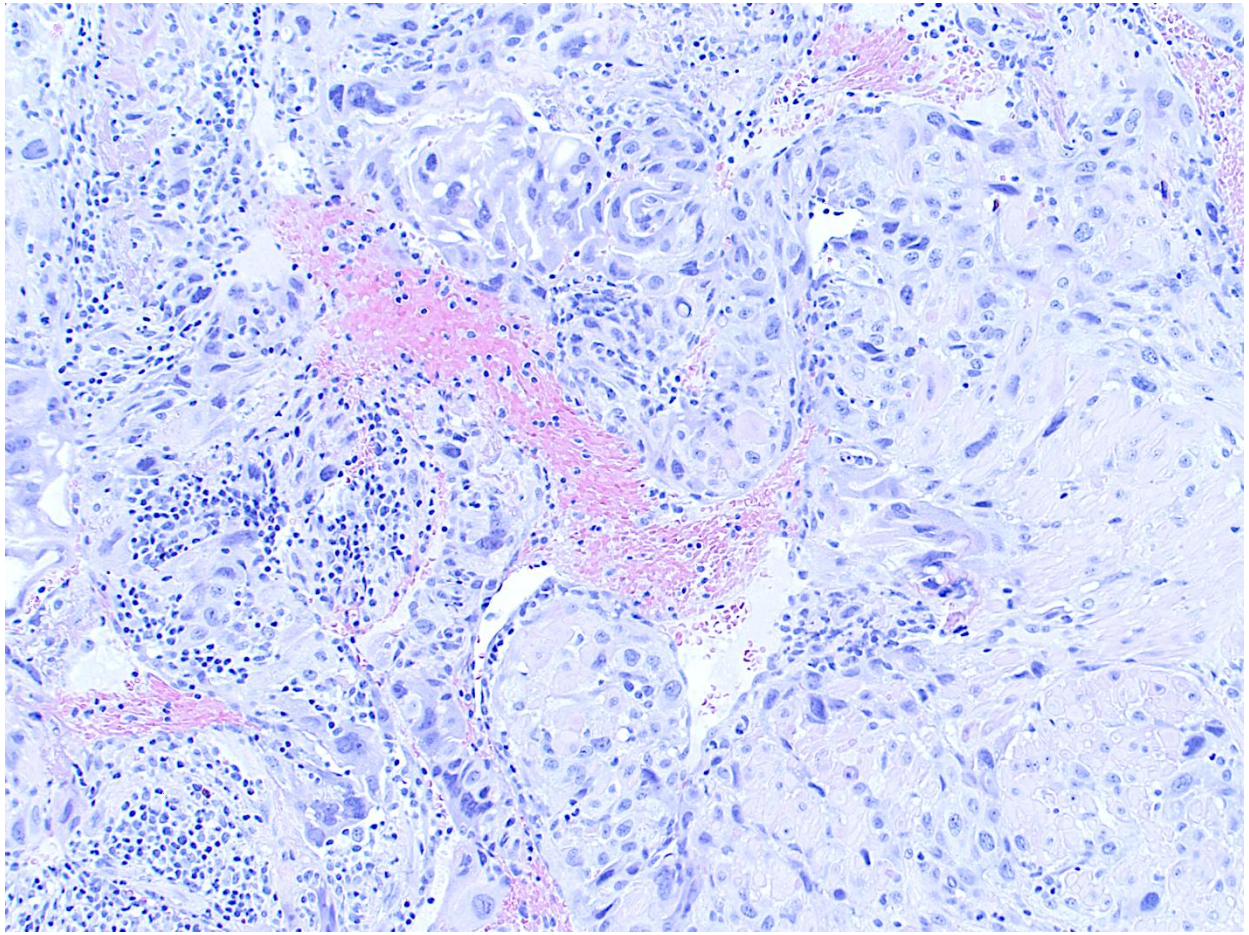

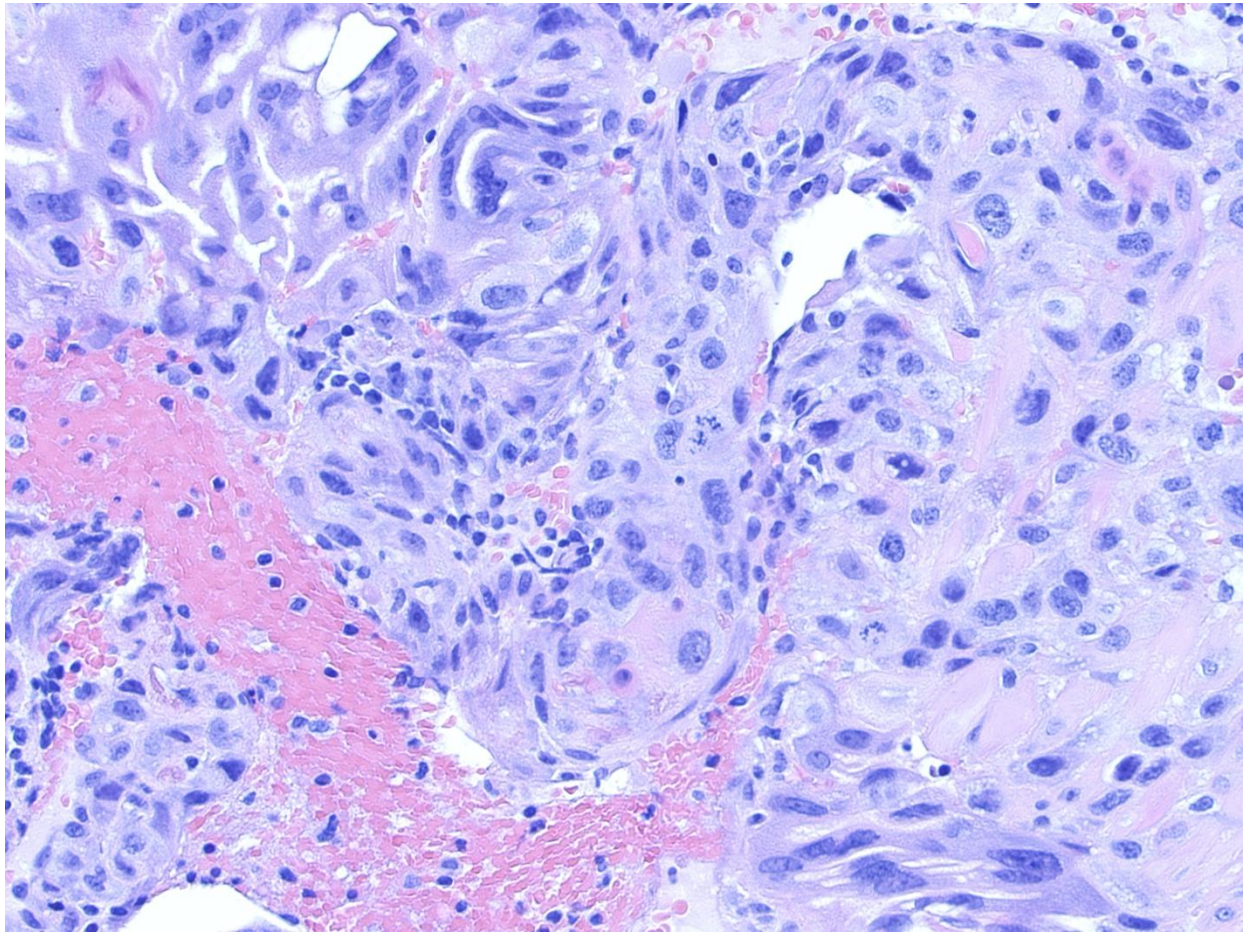

Early Choriocarcinoma

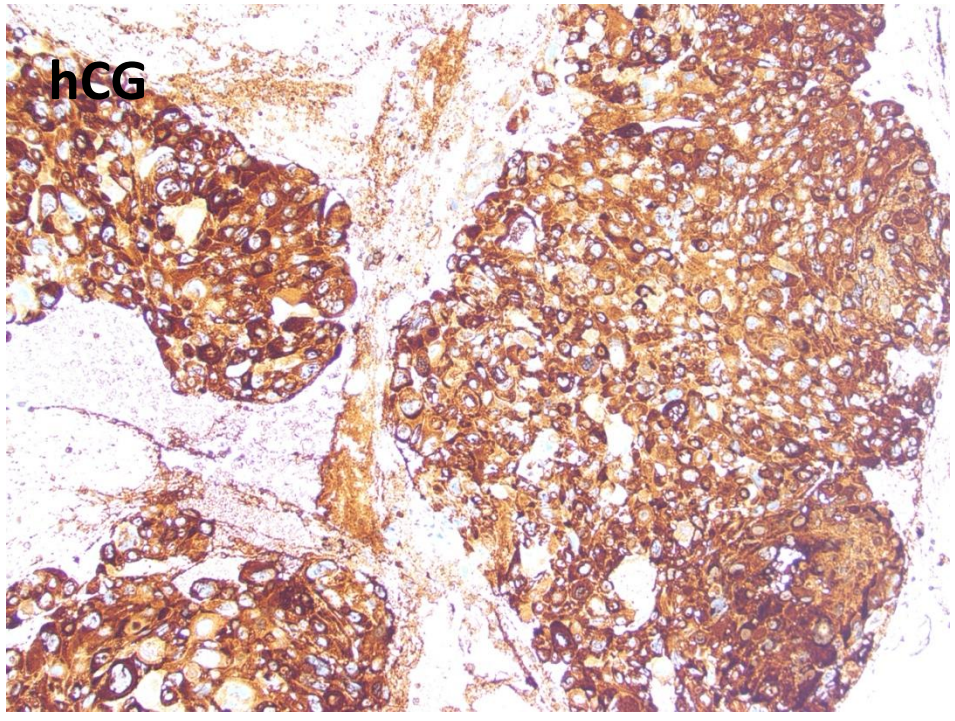
hCG

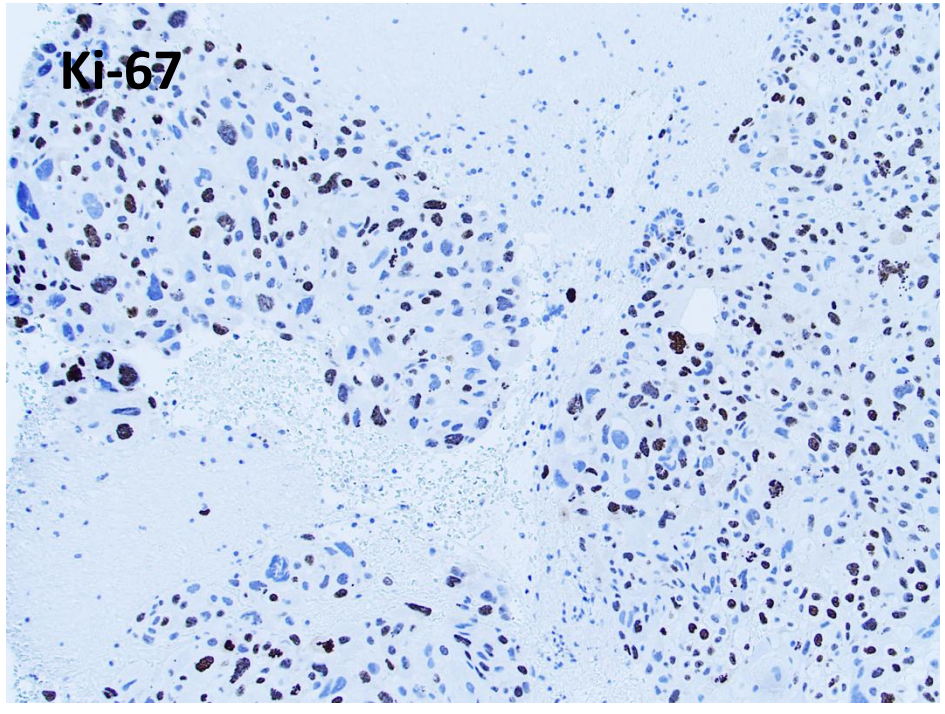
Ki-67

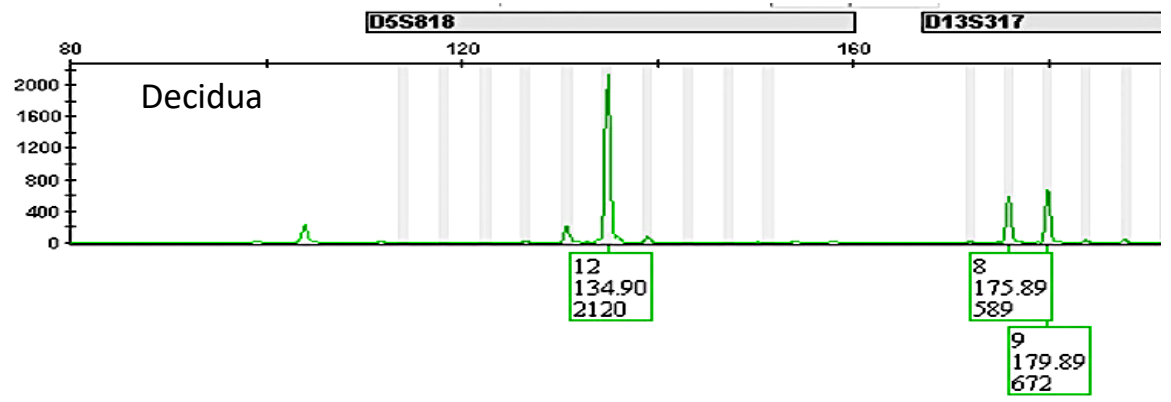
Decidua
D5S818
D13S317
80
120
160
2000
1600
1200
800
400
0
12
134.90
2120
8
175.89
589
9
179.89
672

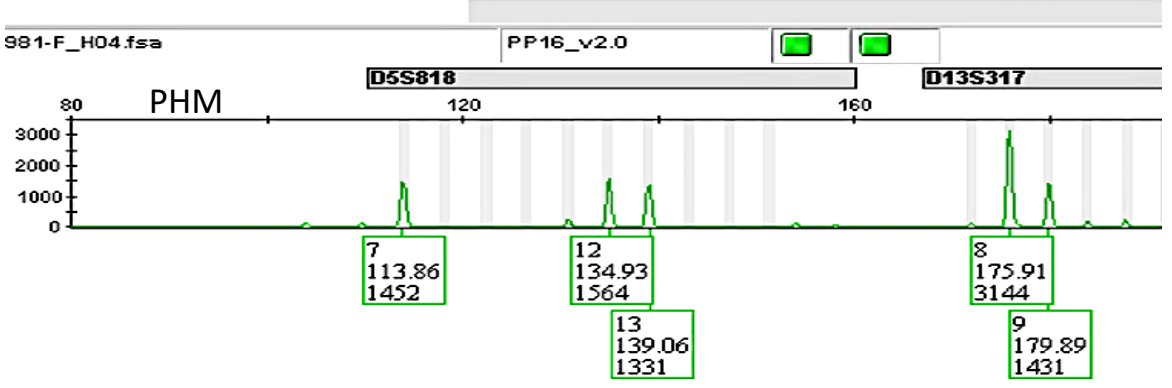
981-F_H04.fsa
PP16_v2.0
PHM
D5S818
D13S317
80
120
160
3000
2000
1000
0
7
113.86
1452
12
134.93
1564
13
139.06
1331
8
175.91
3144
9
179.89
1431

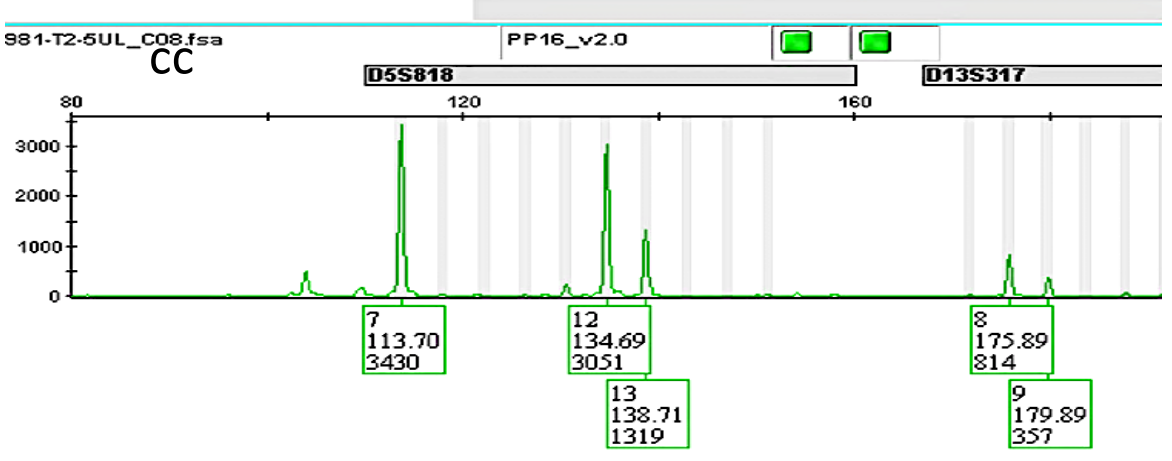
981-T2-5UL_C08.fsa
PP16_v2.0
CC
D5S818
D13S317
80
120
160
3000
2000
1000
0
7
113.70
3430
12
134.69
3051
13
138.71
1319
8
175.89
814
9
179.89
357

Early choriocarcinoma arising from PHM 3.5 months after molar evacuation.

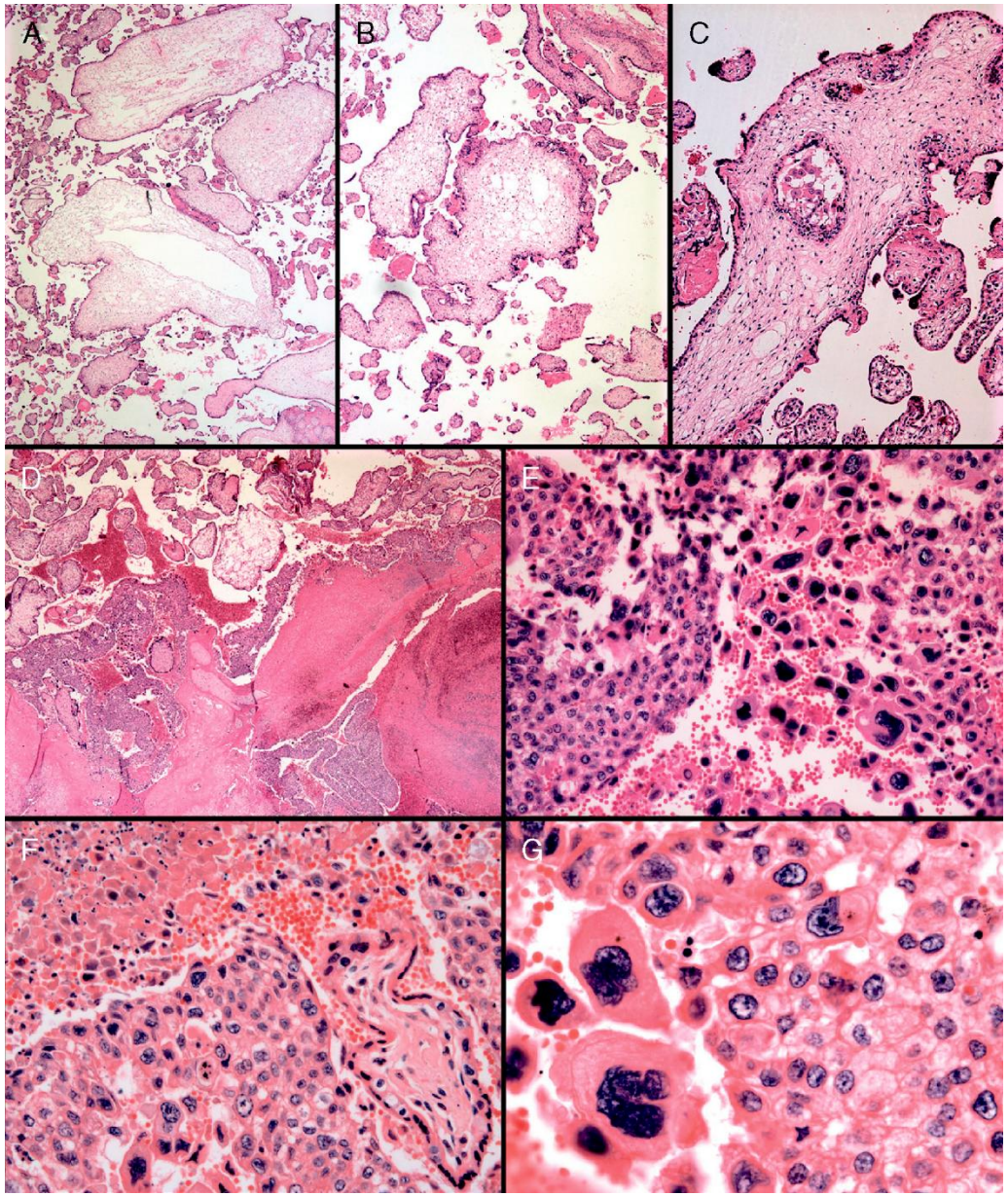

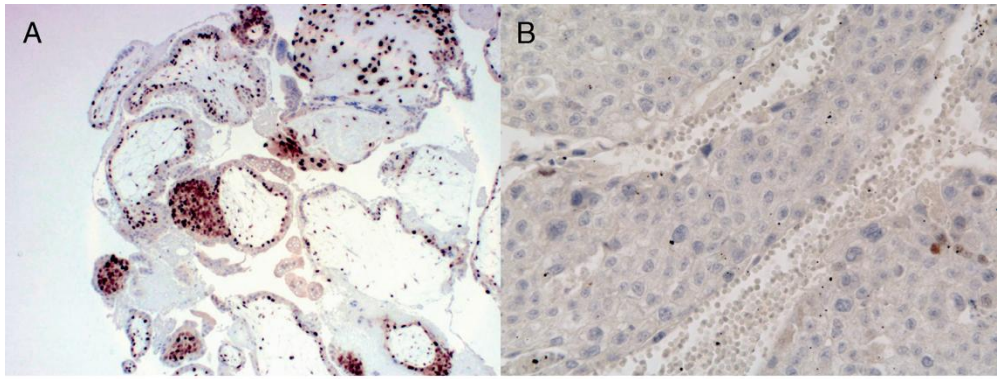

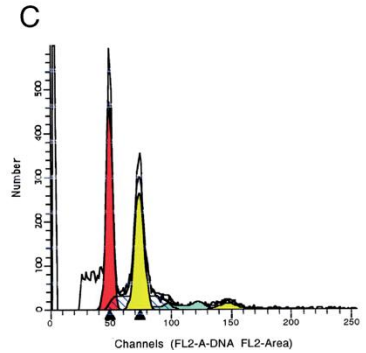

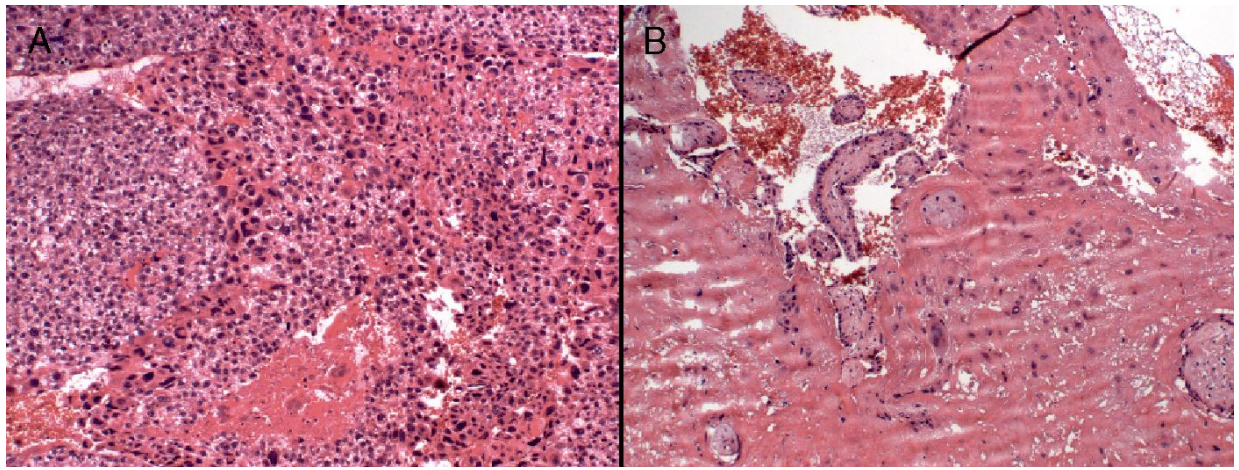

Medeiros, F. *et al.* Intraplacental choriocarcinoma arising in a second trimester placenta with partial hydatidiform mole. *Int J Gynecol Pathol* 2008, **27**, 247-251.

Vejerslev LO, Larsen G, Jacobsen M. Partial hydatidiform mole with subsequent trophoblastic tumor; a case report. Eur J Obstet Gynecol Reprod Biol. 1991;40(1):73-7. Epub 1991/06/05. PubMed PMID: 1649776.

Baert T, Vermeesch J, Timmerman D, Vergote I, Moerman P. Choriocarcinoma in Situ in a Partial Hydatidiform Mole A: Case Report. J Reprod Med. 2016;61(7-8):398-402. Epub 2016/08/01. PubMed PMID: 30408390.

0.1% PHM progress to choriocarcinoma

Three gestational choriocarcinomas directly arising from their corresponding partial moles (STR genotyping and flow cytometry) among 3,000 PHM

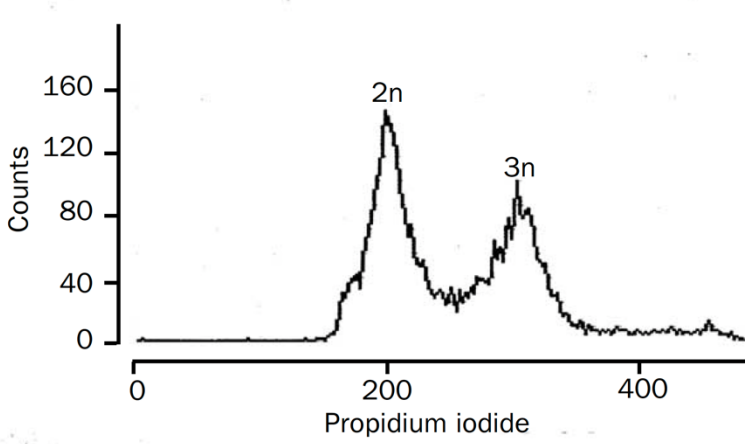

Figure 2: **Flow cytometry analysis (patient 1)**

Patient number	Microsatellite	Patient	PM	Tumour	Partner
1	VWA	a–b	b-c–d	b-c–d	c-d
1	D16S516	a–b	b-c–d	b-c–d	c-d
1	D20S186	a–b	b-c–d	b-c–d	c-d
2	D10S179	a–b	a–b-c	a–b-c	NA
2	D18S535	a	a–b-c	a–b-c	NA
3	D2S1391	a–b	a-c–d	a-c–d	c-d
3	D20S481	a–b	b-c–d	b-c–d	c-d

The letters a, b, c, and d are used to differentiate between different alleles and do not represent specific polymorphisms. NA=not available.

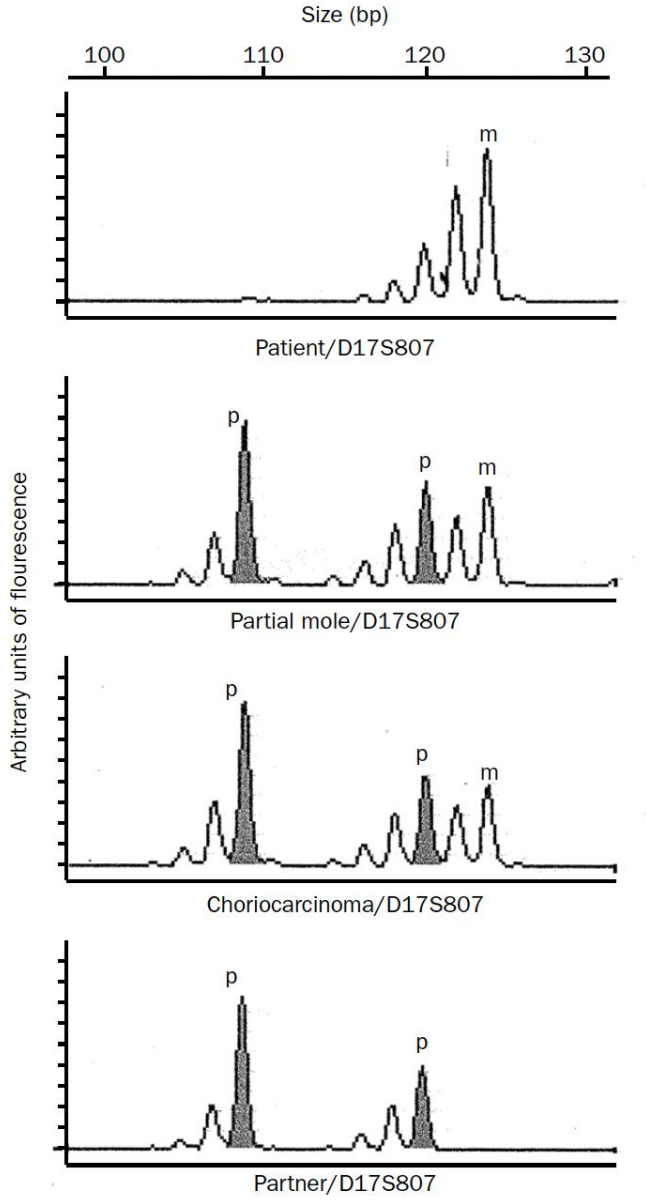

Figure 4: **Genetic analysis**
Fluorescently labelled microsatelites are displayed as characteristic electropherogram peaks after capillary gel electrophoresis. M=maternally derived alleles. P=paternally derived alleles.

Seckl MJ, et al: Choriocarcinoma and Partial Hydatidiform Moles. Lancet. 2000;356:36-39.

No Primary Tissue Diagnosis of GTN

Uncertain type of the index gestation (when multiple pregnancies)

Immediate prior pregnancy may not be the index/causative gestation

Gestational choriocarcinomas are more often encountered as extrauterine tumors by pathologists

Choriocarcinoma at Extrauterine Sites

Gestational choriocarcinoma: Trophoblast

- From term placenta (50%)
- From complete and partial mole (25%)
- From missed abortion (25%)

Germ cell choriocarcinoma: Germ cell origin

- Pure germ cell choriocarcinoma
- Mixed germ cell tumor component

Somatic choriocarcinoma: Epithelial origin

- Carcinoma with trophoblastic differentiation

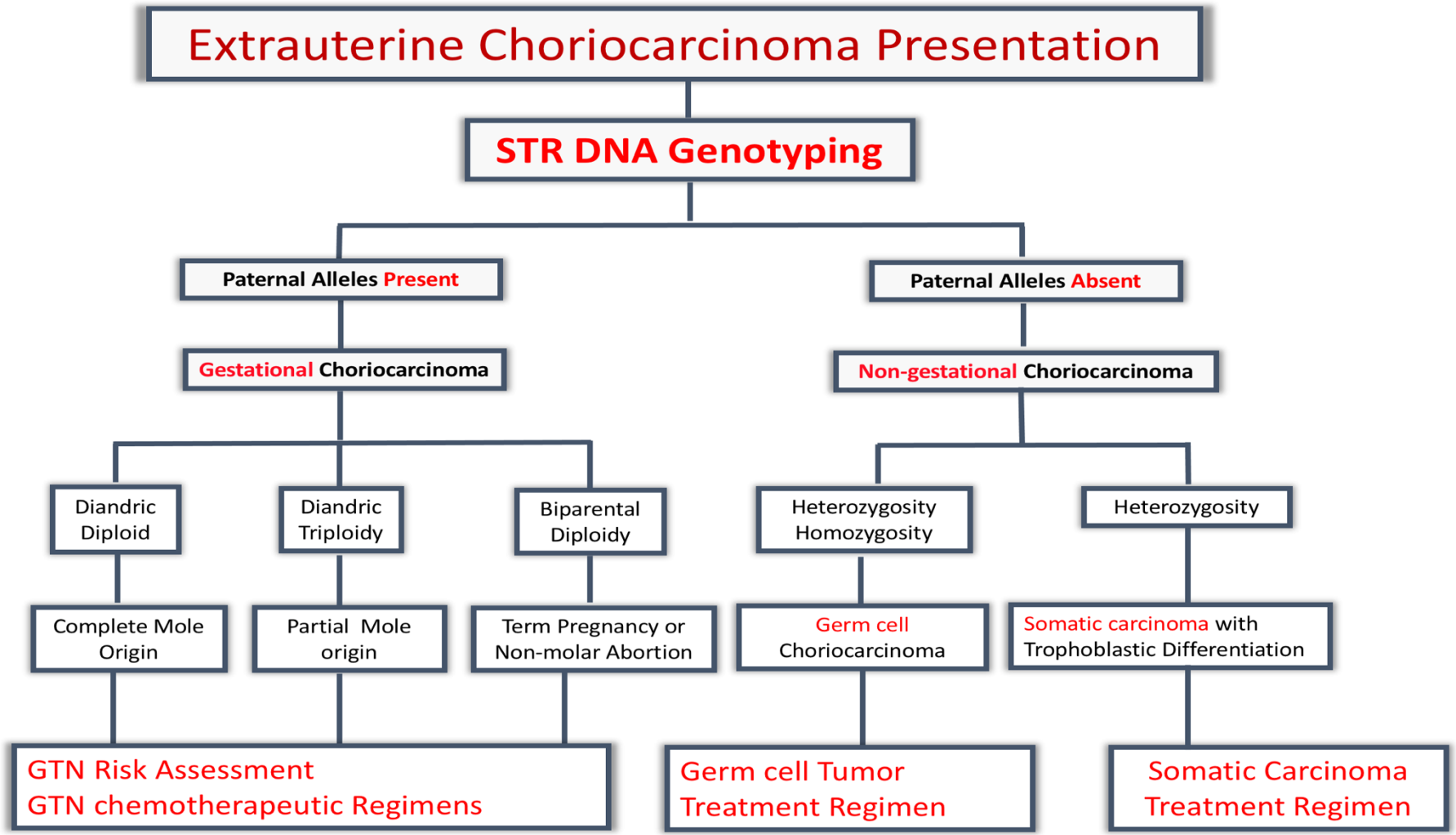
Extrauterine Choriocarcinoma Presentation
STR DNA Genotyping
Paternal Alleles Present
Paternal Alleles Absent
Gestational Choriocarcinoma
Non-gestational Choriocarcinoma
Diandric Diploid
Diandric Triploidy
Biparental Diploidy
Heterozygosity Homozygosity
Heterozygosity
Complete Mole Origin
Partial Mole origin
Term Pregnancy or Non-molar Abortion
Germ cell Choriocarcinoma
Somatic carcinoma with Trophoblastic Differentiation
GTN Risk Assessment
GTN chemotherapeutic Regimens
Germ cell Tumor Treatment Regimen
Somatic Carcinoma Treatment Regimen

Metastatic Gestational choriocarcinoma

48-year-old G3P2: chest pain at emergency room

CT: right hemothorax and lung tumor

Term delivery 6 years ago with retained placenta.

Beta-hCG measurement was NOT considered preoperatively.

Lung wedge resection: 7 cm cystic hemorrhagic mass

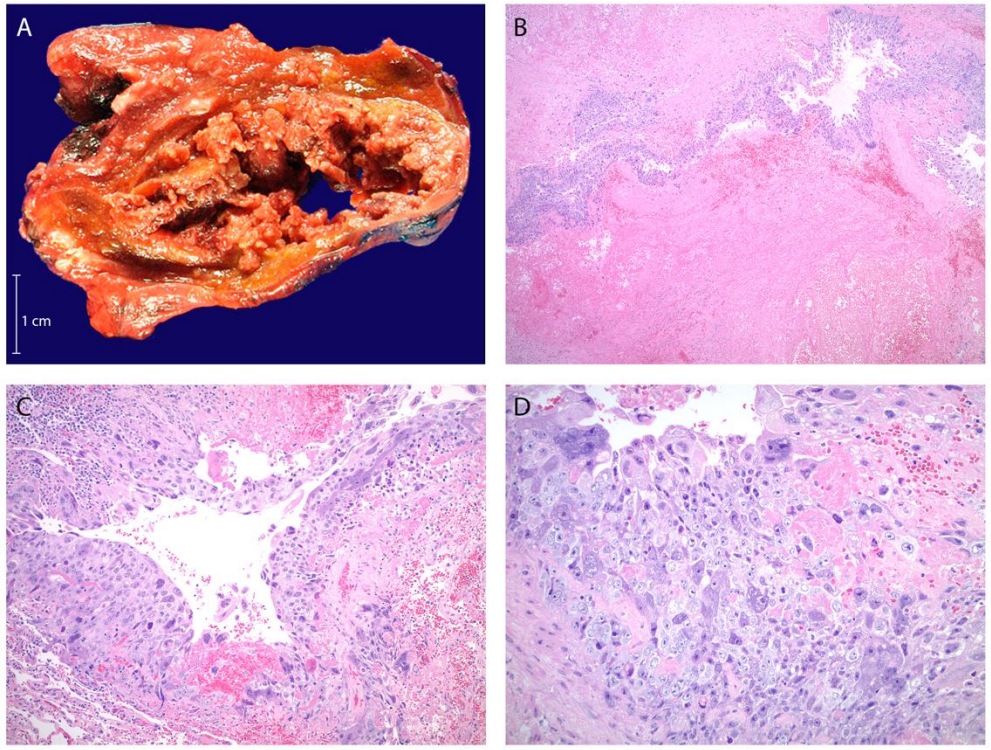

Initial pathology diagnosis: large cell carcinoma of lung (Positive for CK7, GATA3, and PAX8 but negative for p40, TTF-1, Napsin A, CK5-6, OCT4, ER and CDX2)

- Targeted next generation sequencing: no mutations
- ALK and ROS1 FISH: negative

GYN pathology consultation: rule out choriocarcinoma

Beta-hCG of 315 mIU/mL



AJCC: pT1 M1a, Stage III and FIGO risk score of 8

EMA-CO chemotherapy

Serum beta-hCG normalized after 2 cycles

Well without evidence of disease 4 months after

Buza, Bain, Hui: Mod Pathol. 2019;32:1271-1280.

Large cell carcinoma of lung with trophoblastic differentiation

41-year-old G5P2: Heavy smoker with vaginal bleeding for 4 months

Positive urine pregnancy test but negative D/C

Last pregnancy: 6 years ago

Clinical impression: ectopic pregnancy

Treated with MTX but continued rising hCG

U/S: no adnexal mass or uterine lesion

CT scan: 9.7 cm lung mass

Rule out metastatic gestation choriocarcinoma

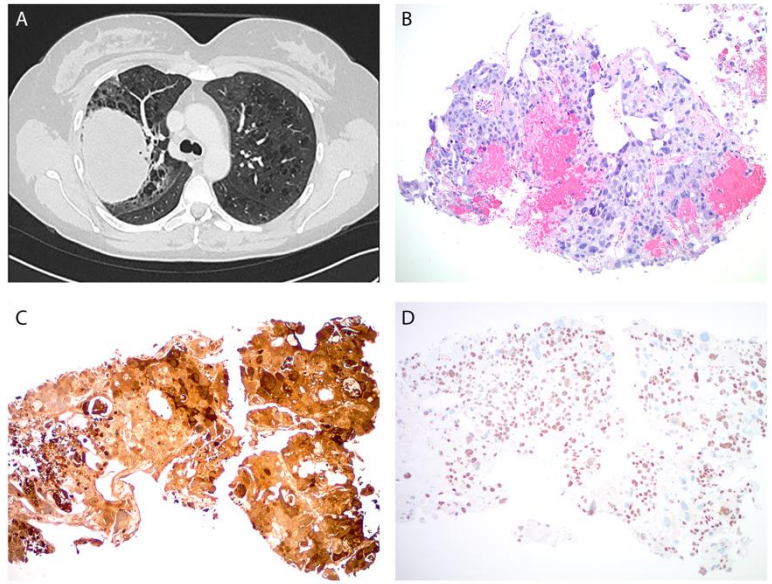

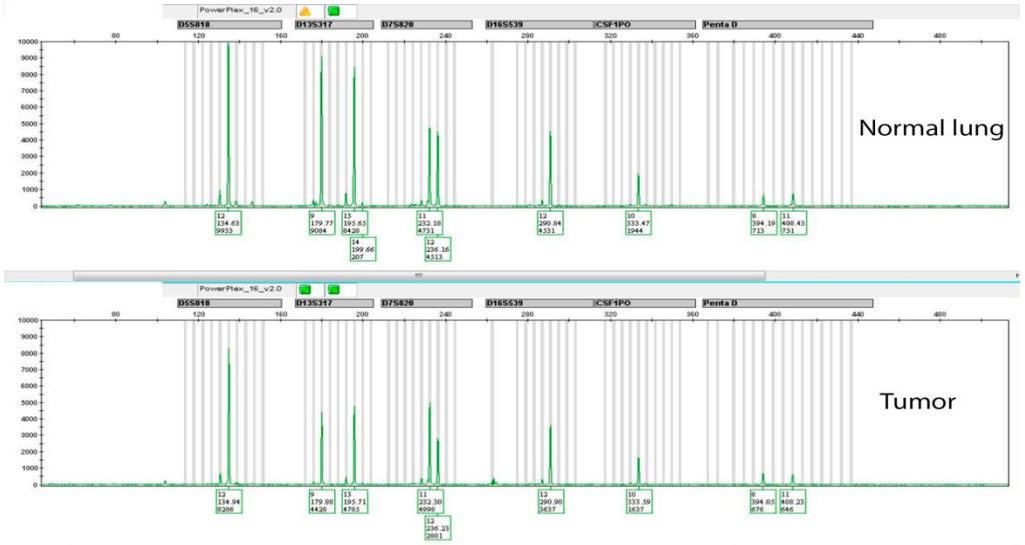

6 cycles of carboplatin, paclitaxel, followed by pembrolizumab

Patient died of the disease 15 months later

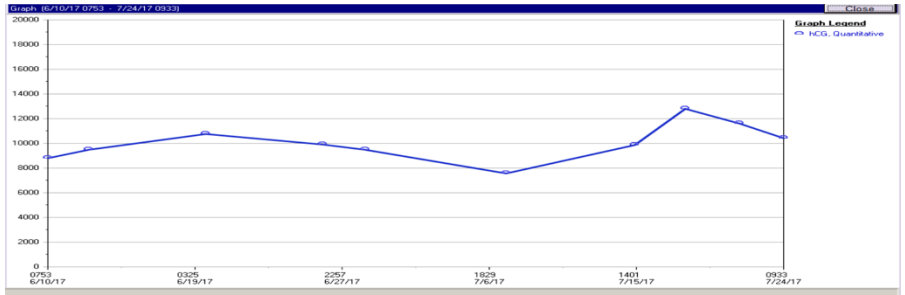

Buza, Bain, Huil: Mod Pathol. 2019;32:1271-1280.

Ovarian Germ Cell Choriocarcinoma

22-year-old G1P1: "right adnexal mass" at emergency room.

Term pregnancy with C-section one year ago

Last menstrual period (LMP) was 10 weeks prior

Serum β-hCG > 200,000 mIU/mL and normal AFP

Pelvic examination: no intrauterine gestation

CT: 9.3 cm mass involving right ovary and broad ligament

Clinical diagnosis: "ruptured ectopic pregnancy"

Right salpingectomy with excision of the right broad ligament.

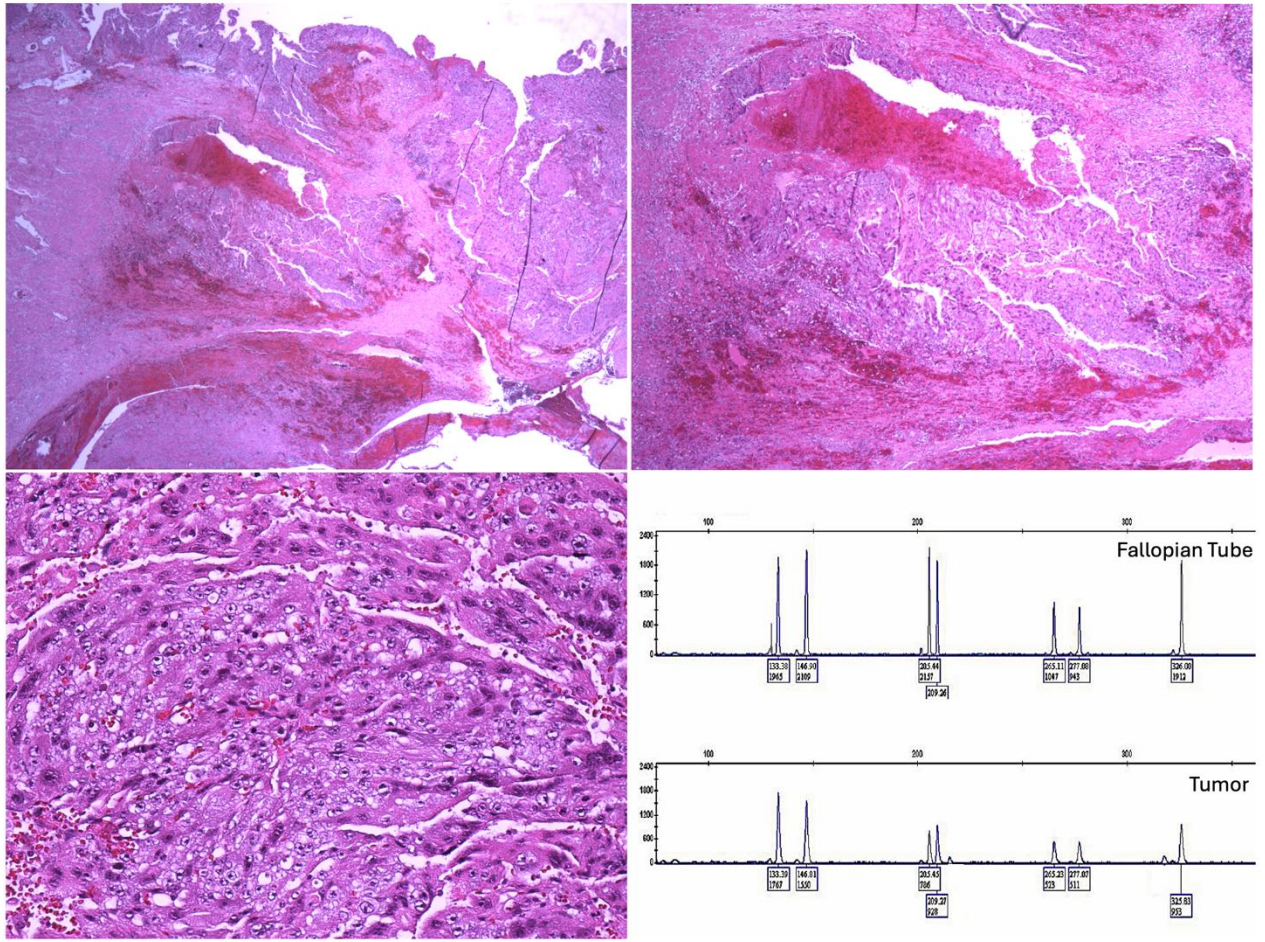

Buza, Hui: Int J Gyn Path 2014;33:507-10

Case number	Informative Microsatellite	Patient	Choriocarcinoma	Partner	Genetic origin of choriocarcinoma	Antecedent pregnancy	First location
1	D8S1110	272, 276	260	260	Gestational choriocarcinoma,	Induced abortion	Uterus
	D10S89	140	142	142	Secondary from androgenesis		
	D20S481	231	239	239			
2	D8S136	68, 75	68, 75		Non-gestational choriocarcinoma	/	Ovary
	D11S875	102, 117	102, 117				
	D14S306	193, 201	193, 201				
	D17S807	126, 138	126, 138				
	D22S685	184	184				
3	D8S136	75, 84	80	68, 80	Gestational choriocarcinoma,	Term delivery	Ovary
	D8S1110	280, 288	284	276, 284	Secondary from androgenesis		
	D10S89	150, 151	142, 154	142, 154			
	D11S875	110, 114	106	106, 118			
	D20S481	236, 244	231	231, 239			
4	D11S875	101, 105	103, 111		Gestational choriocarcinoma,	Term delivery	Ovary
	D17S807	116, 126	132, 134		Secondary from androgenesis		
	D20S481	243	235, 239				
5	D8S136	68, 80	68, 80	75, 82	Non-gestational choriocarcinoma	Ectopic pregnancy	Ovary
6	D8S1110	260, 276	260, 276	284	Non-gestational choriocarcinoma	Ectopic pregnancy	Ovary
	D10S189	182, 186	182, 186	188			
	D14S306	197, 209	197, 209	201, 205			
	D22S685	188	188	184, 196			
7	D22S685	192, 196	184	184, 192	Gestational choriocarcinoma,	Term delivery	Uterus
					Secondary from androgenesis		
8	D8S136	68, 80	68, 80		Non-gestational choriocarcinoma	/	Genitical gland
	D8S1110	272, 280	272, 280				
	D10S89	142	142				
	D11S875	110	110				
	D14S306	193, 197	193, 197				
	D17S807	114	114				
	D20S481	235, 239	235, 239				
	D22S685	180	180				
9	D9S43	95	76, 95	76, 91	Gestational choriocarcinoma,	Molar pregnancy	Uterus
	D20S481	239	239, 243	243	Secondary from normal fertilisation		
10	D8S136	68, 72	68, 80	80	Gestational choriocarcinoma,	Induced abortion	Uterus
	D10S89	142	142, 152	152	Secondary from normal fertilisation		
11	D3S1262	114, 120	112	112	Gestational choriocarcinoma,	Induced abortion	Uterus
					Secondary from androgenesis		
12	D2S165	96, 100	88	88, 96	Gestational choriocarcinoma,	Term delivery	Ovary
	D3S1262	119	111	111, 119	Secondary from androgenesis		
	D8S1110	260, 276	284	276, 284			
	D10S189	181	182	182			
	D20S481	232, 248	240	236, 240			

NOTE: Case 2 is a sixteen-years-old unmarried girl. The social sex of case 8 is female, but her karyotype is 46, XY. These two ladies haven't partner. "First location" = the first location of the choriocarcinoma observed. "Antecedent pregnancy" = last pregnancy clinical observed before the choriocarcinoma occurrence.

Placenta 30 (2009) 816–820

Contents lists available at ScienceDirect

Placenta

journal homepage: www.elsevier.com/locate/placenta

Molecular Genetic Analyses of Choriocarcinoma

J. Zhao [a], Y. Xiang [a,*], X.R. Wan [a], F.Z. Feng [a], Q.C. Cui [b], X.Y. Yang [a]

[a] Department of Obstetrics and Gynecology, Peking Union Medical College Hospital, Peking Union Medical College, Chinese Academy of Medical Science, Beijing 100730, PR China
[b] Department of Pathology, Peking Union Medical College Hospital, Peking Union Medical College, Chinese Academy of Medical Science, Beijing 100730, PR China

TABLE 2. Genotyping Data

Case	Specimen	Diagnosis	Genotyping	Zygosity
1	Placenta	Intraplacental choriocarcinoma	Gestational, biparental (tumor matches villous tissue)	XX
2	Left fallopian tube	Choriocarcinoma (tubal ectopic)	Gestational, androgenetic	XX, homozygous
3	Uterine curetting	Choriocarcinoma with associated CHM	Gestational, androgenetic (tumor matches hydatidiform mole)	XX, homozygous
4	Right ovary	Choriocarcinoma	Nongestational (tumor matches maternal tissue and has allelic imbalances)	XX
5	Placenta	Intraplacental choriocarcinoma	Gestational, biparental (tumor matches villous tissue)	XX
6	Uterus	Choriocarcinoma in cornu; separate 21 wk placenta (dispermic "twin" gestation)	Tumor: gestational, androgenetic; villous tissue: biparental	Tumor: XX, homozygous; villous tissue XY (different sperm in tumor and villi
7	Uterine curetting	Choriocarcinoma (no villi in entirely submitted specimen)	Gestational, androgenetic	XX, homozygous
8	Uterine curetting	Choriocarcinoma with associated CHM	Gestational, androgenetic (tumor matches hydatidiform mole)	XX, homozygous
9	Placenta	Intraplacental choriocarcinoma (incidental, 1 slide)	Gestational, biparental (tumor matches villous tissue)	XY
10	Rectal mesenteric mass	Choriocarcinoma (negative endometrial specimen)	Nongestational (tumor matches maternal tissue and has allelic imbalances)	XX
11	Uterine curetting	Choriocarcinoma (no villi in entirely submitted specimen)	Gestational, biparental (no villous tissue or prior placenta available for comparative analysis)	XX
12	Right uterine cornu	Choriocarcinoma (no villi in entirely submitted specimen)	Gestational, androgenetic	XX, homozygous
13	Left fallopian tube	Choriocarcinoma (tubal ectopic; no villi in entirely submitted specimen)	Gestational, androgenetic	XX, homozygous
14	Left ovary	Choriocarcinoma (ovarian ectopic); concurrent intrauterine term placenta (dispermic "twin" gestation)	Tumor: gestational, androgenetic; villous tissue: biparental	Tumor: XX, homozygous; villous tissue: XX (different X sperm in tumor and villi)
15	Uterus	Choriocarcinoma	Gestational, biparental with allelic imbalances (no villous tissue or prior placenta available for comparative analysis)	XYY
16	Uterine curetting	Choriocarcinoma (no villi in entirely submitted uterine specimen; negative fallopian tube)	Gestational, androgenetic	XX, homozygous
17	Left uterine cornu	Choriocarcinoma (no villi in entirely submitted specimen)	Gestational, androgenetic	XX, homozygous
18	Uterine curetting, vaginal mass	Choriocarcinoma with associated CHM	Gestational, androgenetic (tumor matches hydatidiform mole)	XX, homozygous
19	Uterine curetting	Choriocarcinoma with associated CHM	Gestational, androgenetic (tumor matches hydatidiform mole)	XX, homozygous
20	Uterine curetting	Choriocarcinoma with associated very early CHM	Gestational, androgenetic (tumor matches hydatidiform mole)	XX, homozygous
21	Right ovary	Choriocarcinoma	Nongestational (tumor matches maternal tissue and has allelic imbalances)	XX
22	Right uterine cornu	Choriocarcinoma	Gestational, androgenetic (tumor matches prior hydatidiform mole)	XX, homozygous

Choriocarcinoma in Women: Analysis of a Case Series With Genotyping

Savage, Johanna MD*; Adams, Emily BS*; Veras, Emanuela MD*; Murphy, Kathleen M. PhD†; Ronnett, Brigitte M. MD*‡

The American Journal of Surgical Pathology: December 2017 - Volume 41 - Issue 12 - p 1593–1606

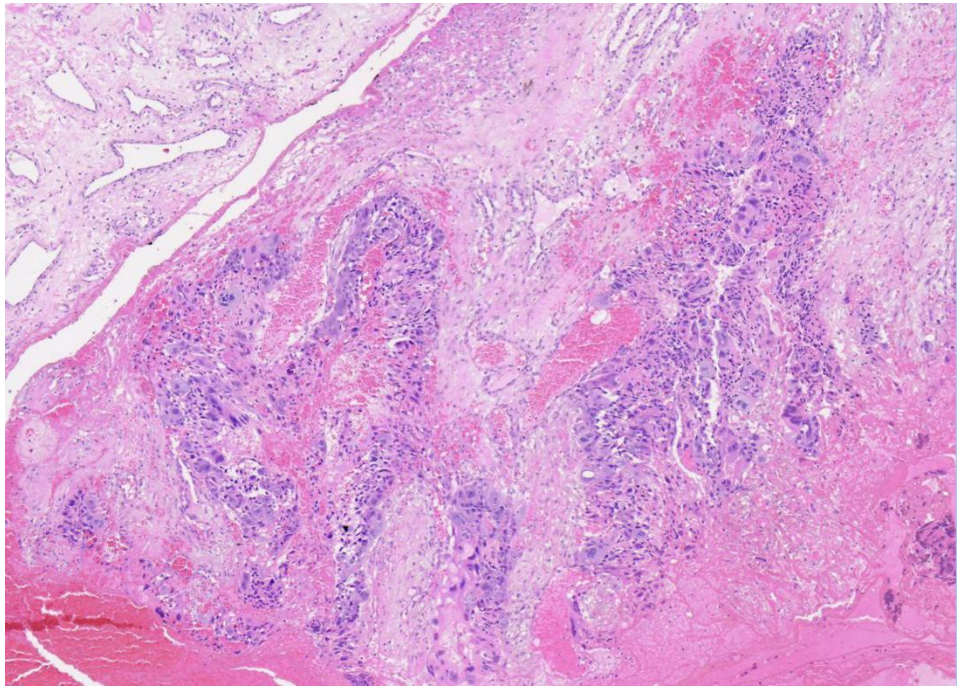

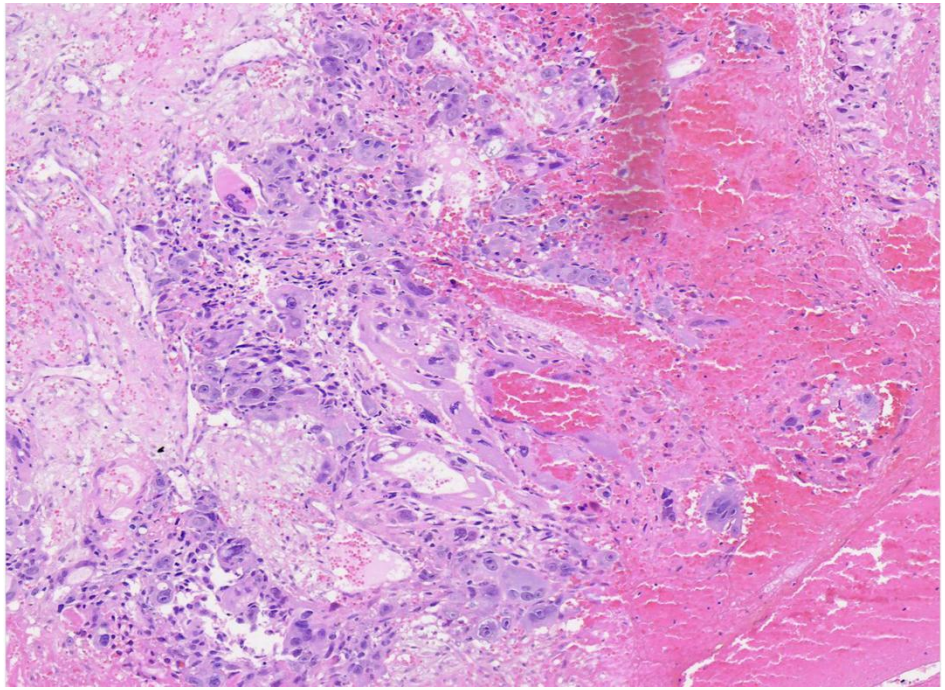

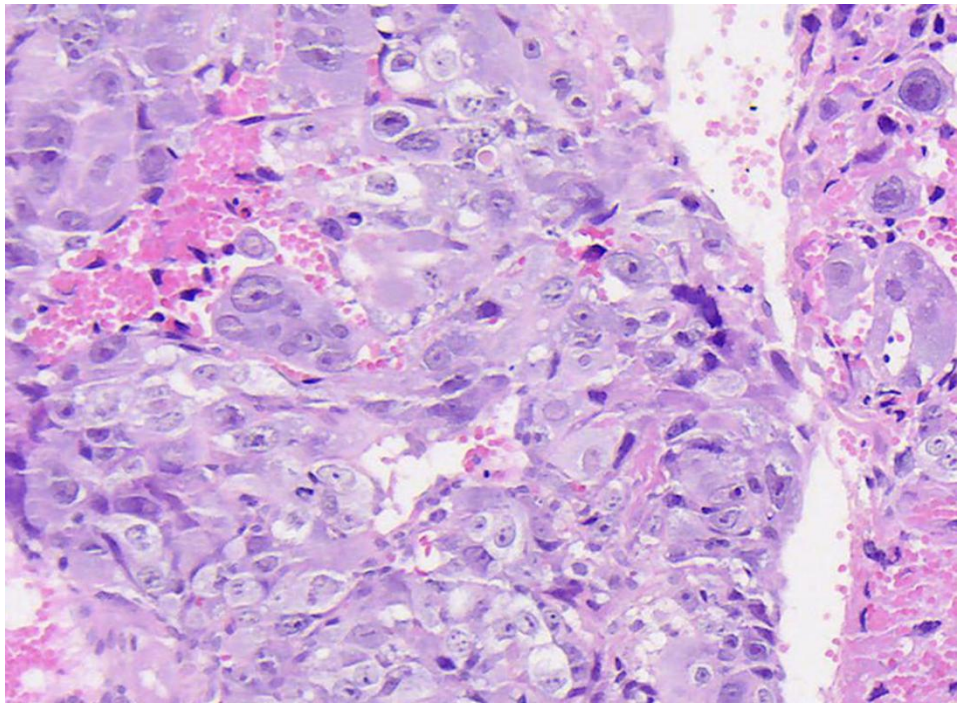

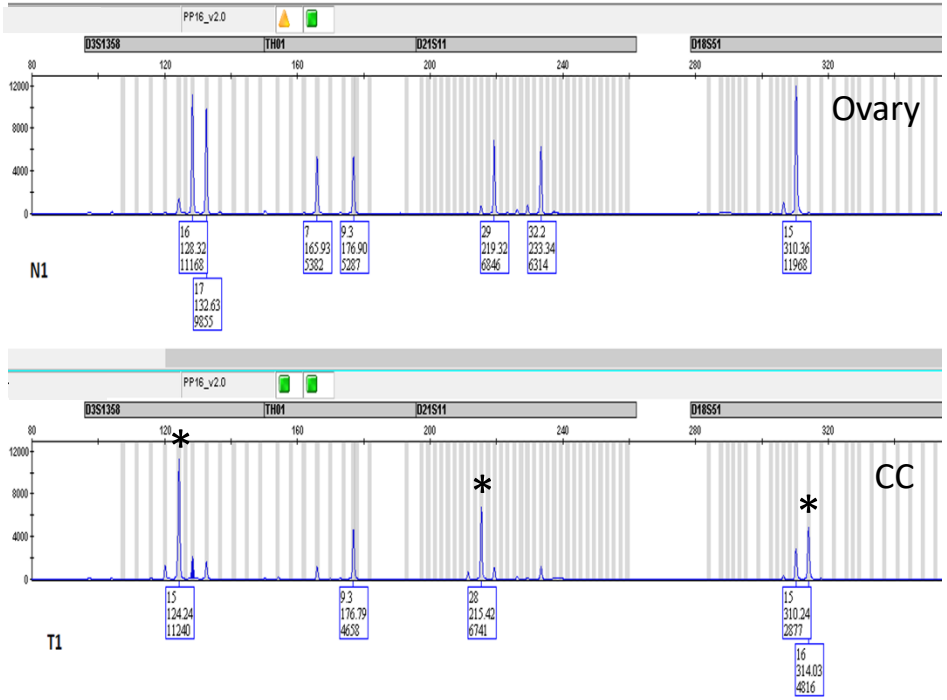

Gestational choriocarcinoma from ectopic CHM (broad ligament)

Non-gestational choriocarcinoma: staging surgery followed by cisplatin based multi-agent chemotherapy.

Gestational choriocarcinoma: FIGO/WHO prognostic scoring into low, high and ultrahigh risk groups for single to multi-agent GTN chemotherapy.

FIGO/WHO Risk Factor	0	1	2	4
Age	< 40	> 40	-	-
Index pregnancy	**Mole**	**Abortion**	**Term**	
Interval from index pregnancy, months	**< 4**	**4-6**	**7-12**	**> 12**
Pretreatment hCG mIU/mL	$< 10^3$	$> 10^3$-10^4	$> 10^4$-10^5	$> 10^5$
Largest tumor size including uterus, cm	-	3-4	≥ 5	-
Site of metastases including uterus	Lung	Spleen, kidney	Gastrointestinal tract	Brain, liver
Number of metastases identified	-	1-4	5-8	> 8
Previous failed chemotherapy	-	-	Single drug	Two or more drugs

Clinical Significance

Gestational Choriocarcinoma

- Requires prompt diagnosis
- Rigorous risk/prognostic scoring
- Single or combined chemotherapy
- Surgery only for uncontrollable bleeding and/or chemotherapy-resistant disease
- ~100% survival at GTD centers

While most are treated successfully by chemotherapy, rare patients may die of high stage/high risk scores choriocarcinokma, primarily due to delayed diagnosis/unnoticed preceding hydatidiform mole!

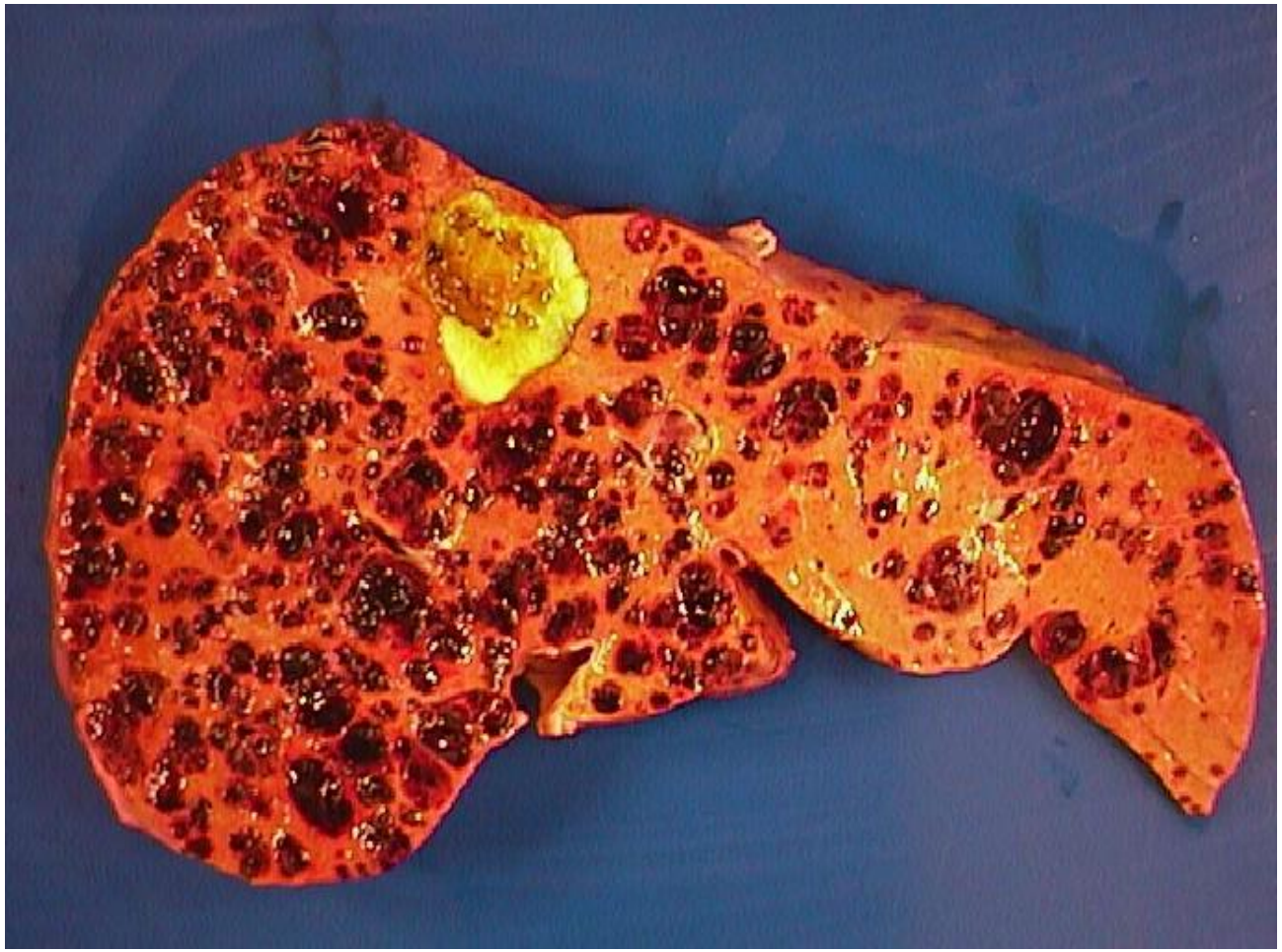

Seckl MJ, et al: Choriocarcinoma and Partial Hydatidiform Moles. Lancet. 2000;356:36-39.

Epithelioid Trophoblastic Tumor (ETT)



Epithelioid Trophoblastic Tumor (ETT)

- Reproductive age with vaginal bleeding
- ~6 years after pregnancy
- 50% arising from cervix
- 2/3 after normal pregnancy, 15% after mole, 15% after abortion
- Serum hCG <3000 mIU/ml
- Recurrence rate: 25-30%

Epithelioid Trophoblastic Tumor (ETT)





Epithelioid Trophoblastic Tumor

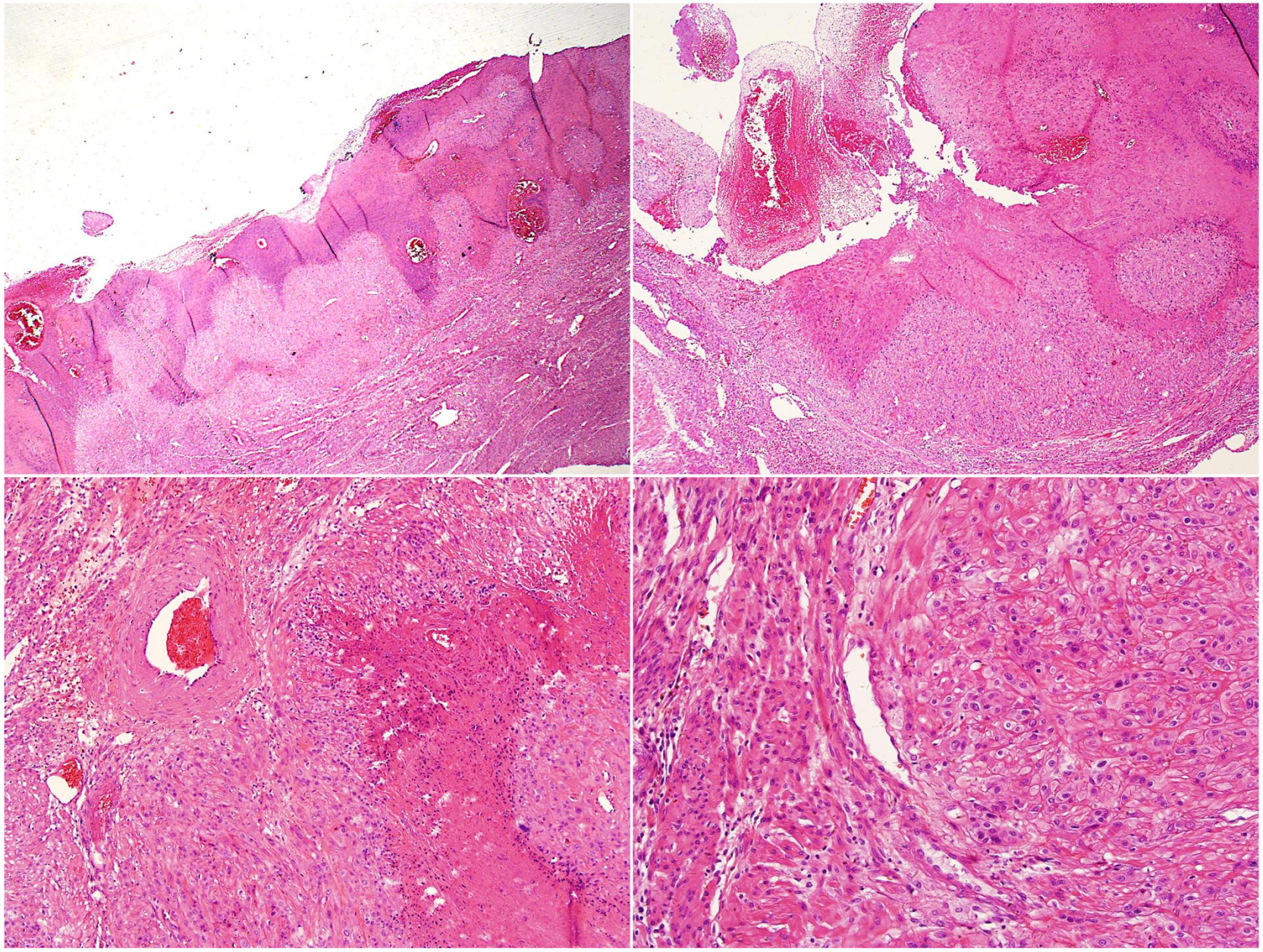

The Most Important Differential Diagnosis:
Squamous Cell Carcinoma of the Cervix

- 50% ETT arise in the cervix/lower uterine segment

Epithelioid Trophoblastic Tumor

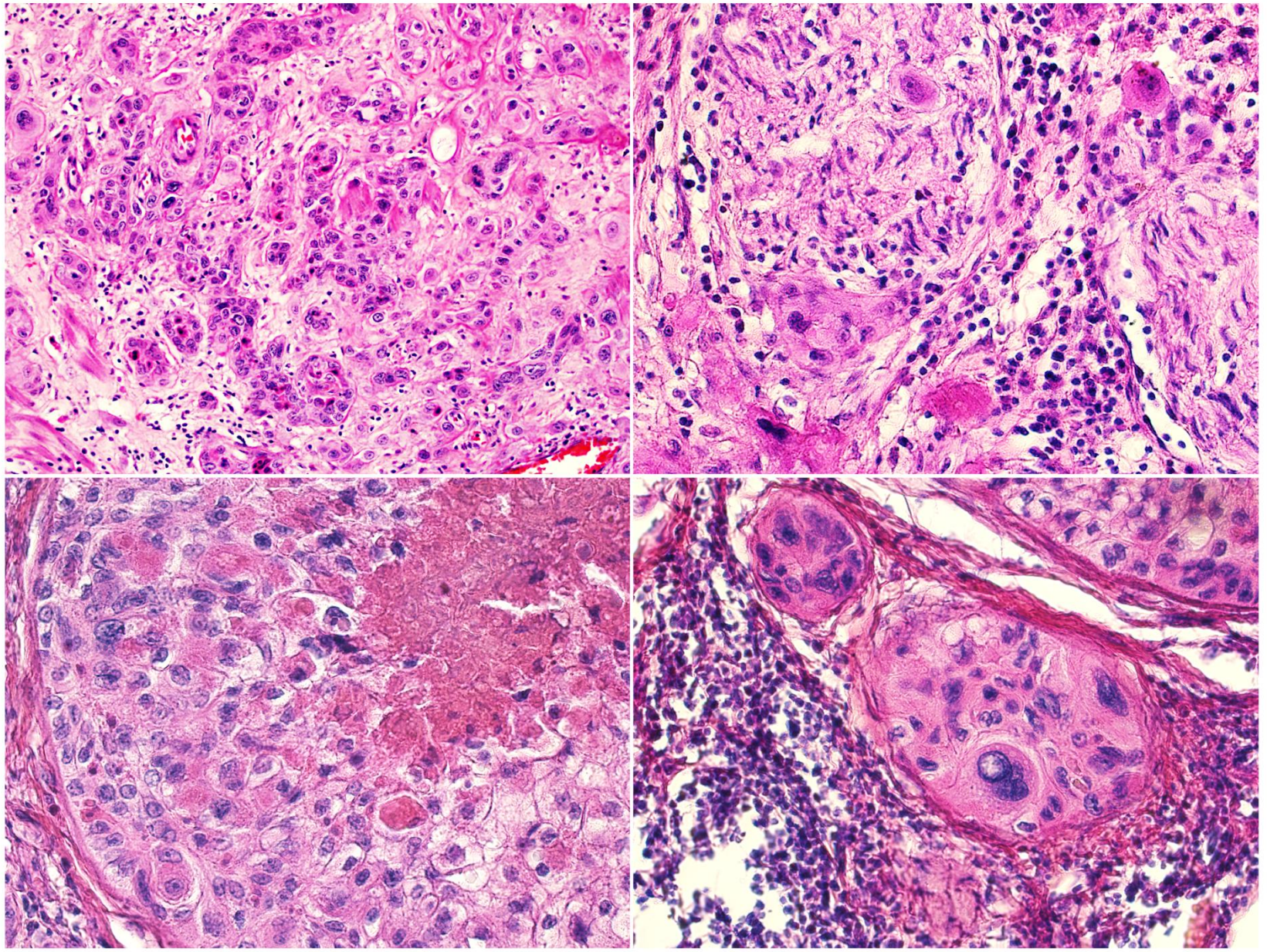

Epithelioid Trophoblastic Tumor

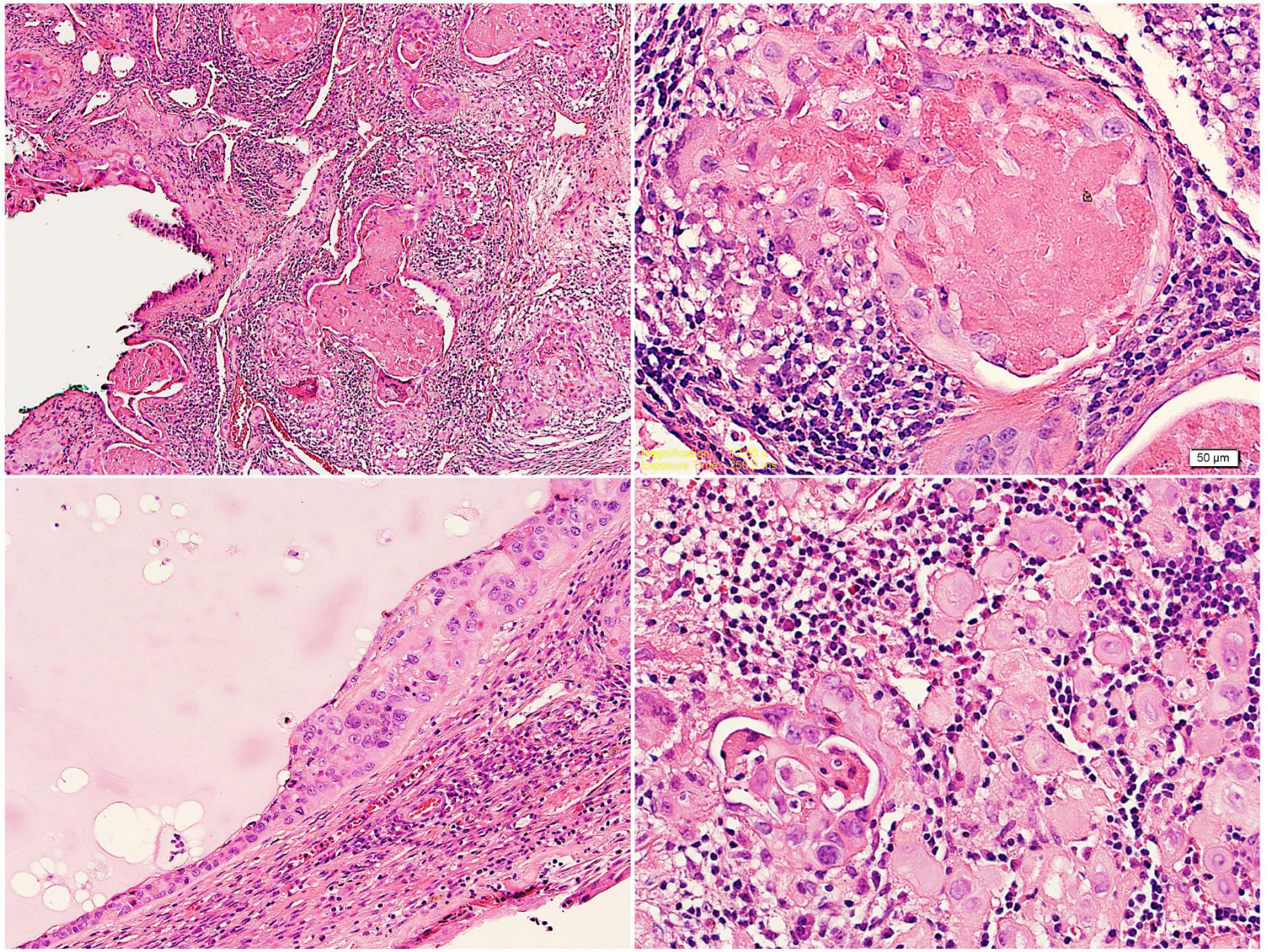

ETT - Lung Met

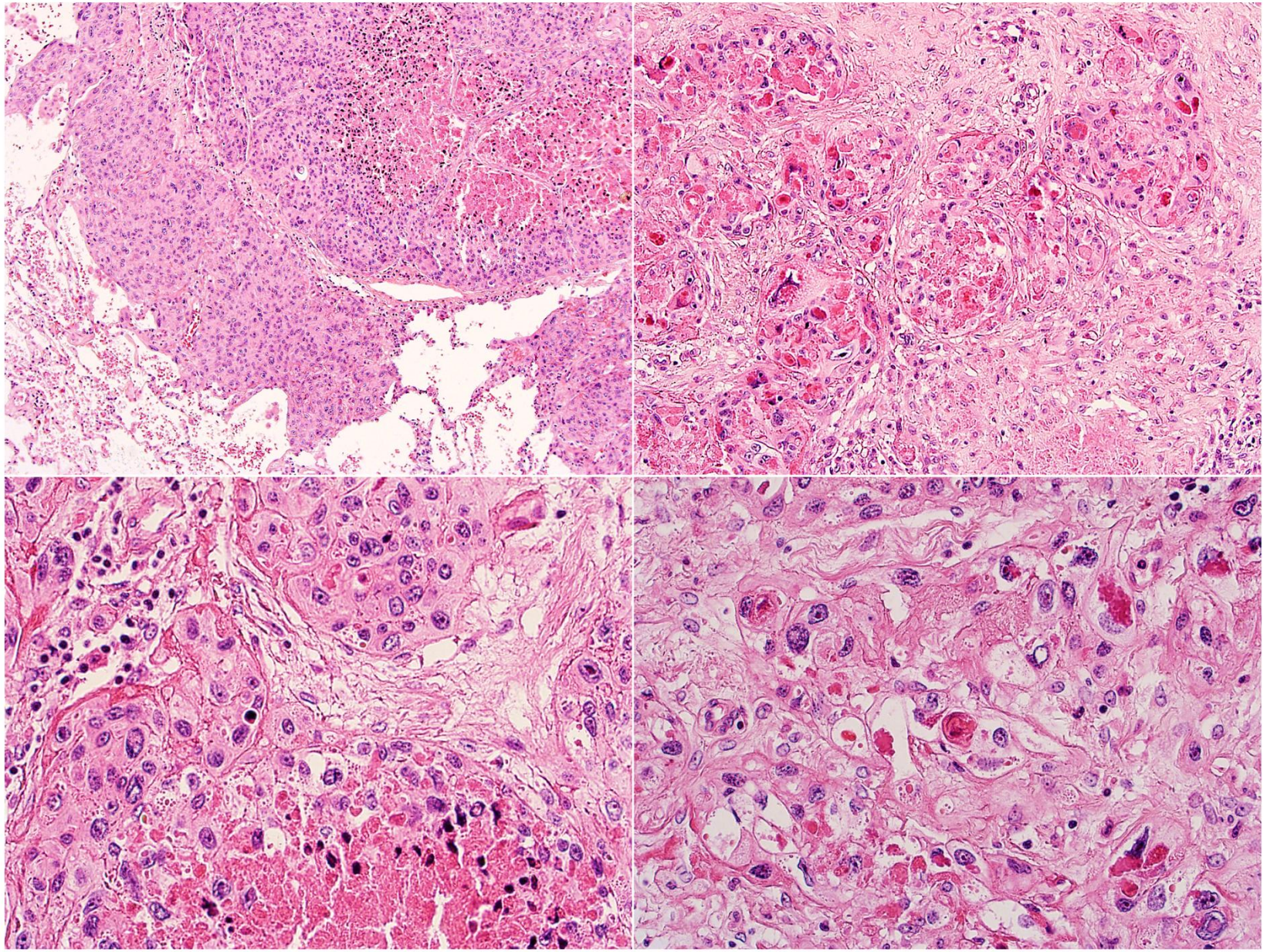

61-year-old G1P1 with pain and bleeding; EMB – poorly differentiated carcinoma; CT – large uterine mass, fistula and pleural effusion; TAH-BSO: frozen pelvis; Omental biopsy

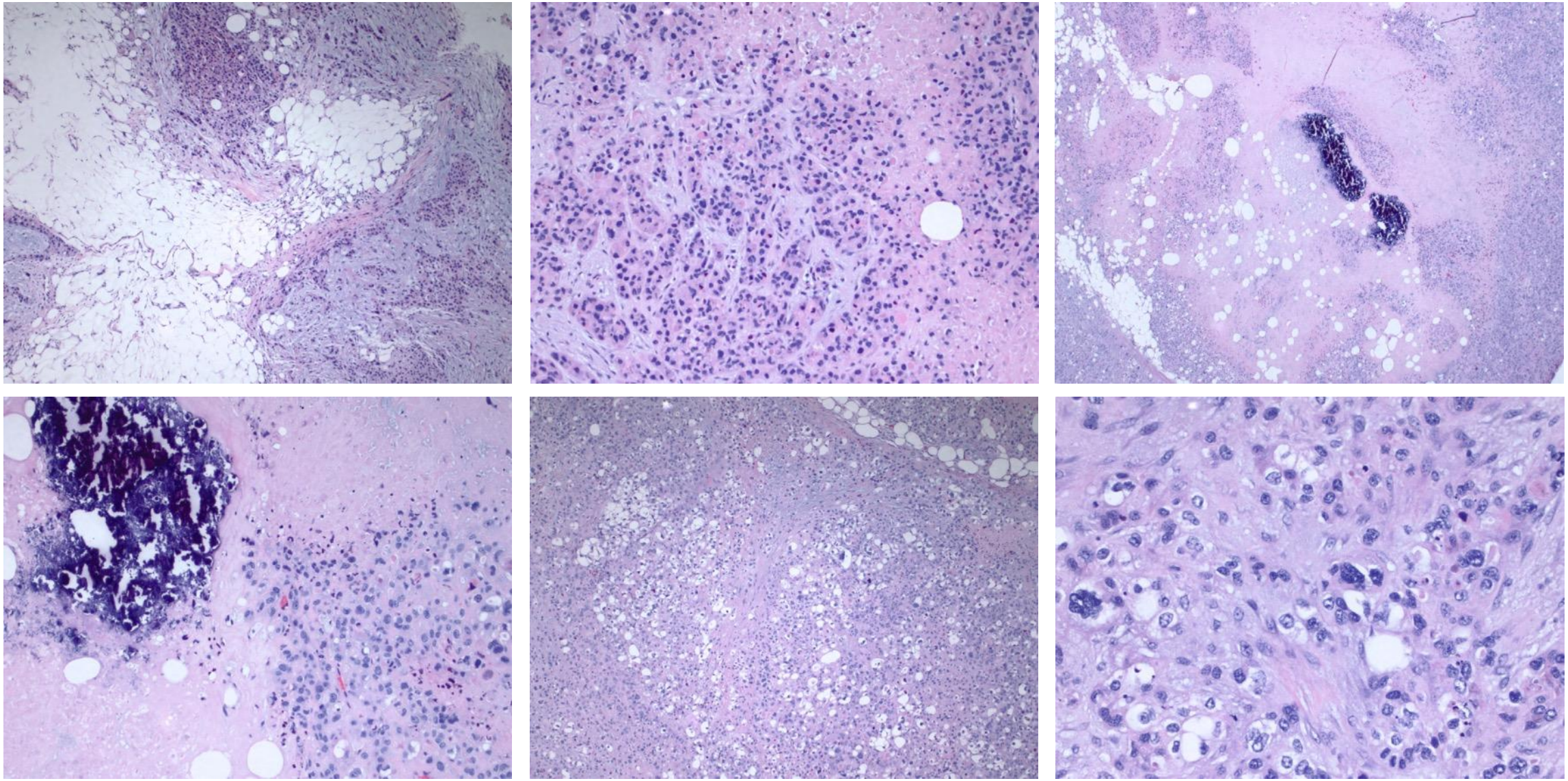

Initial Dx: Poorly Differentiated Carcinoma with Squamous Features

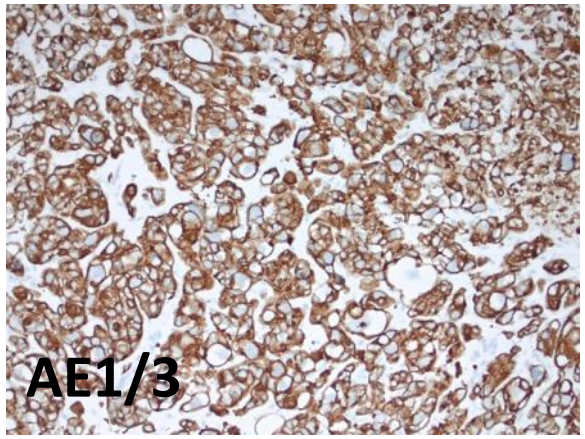

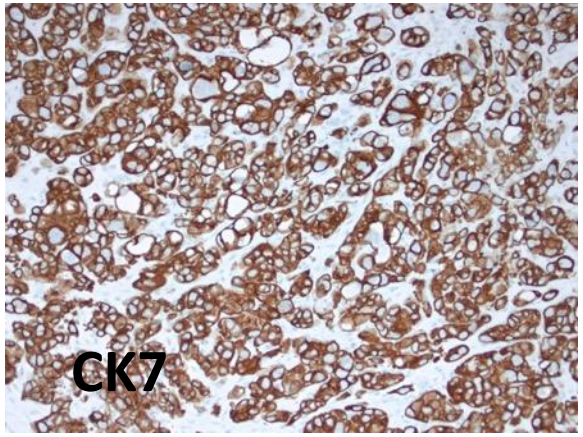

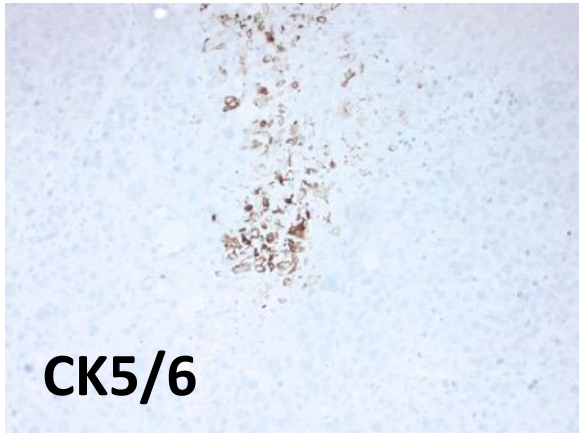

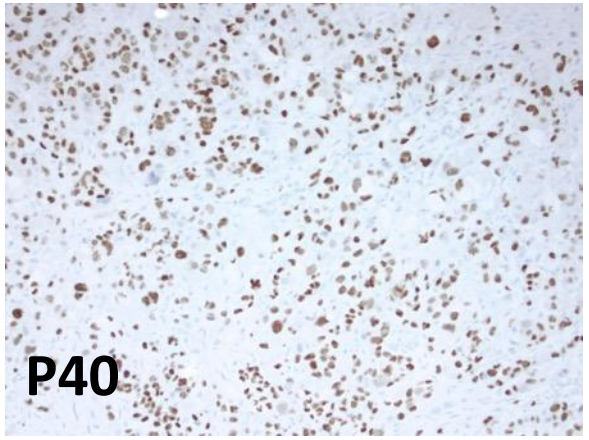

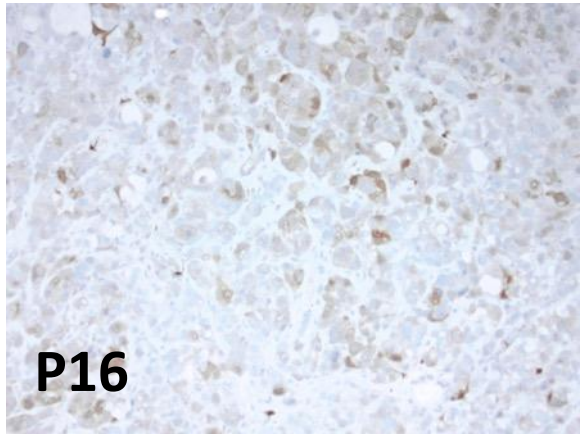

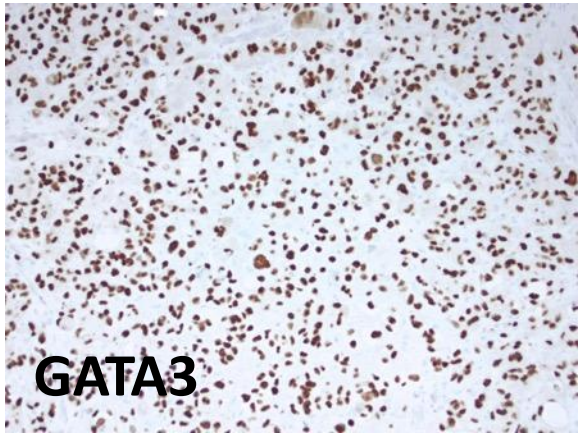

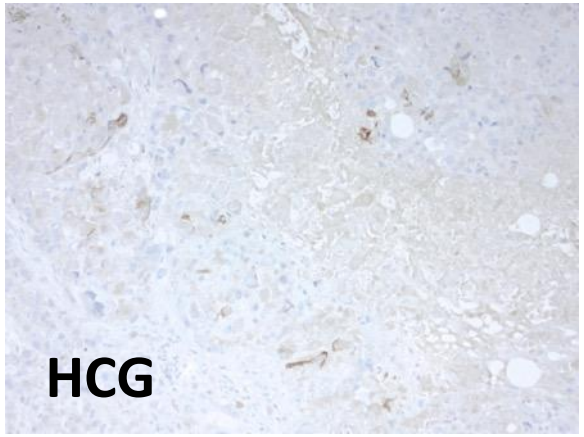

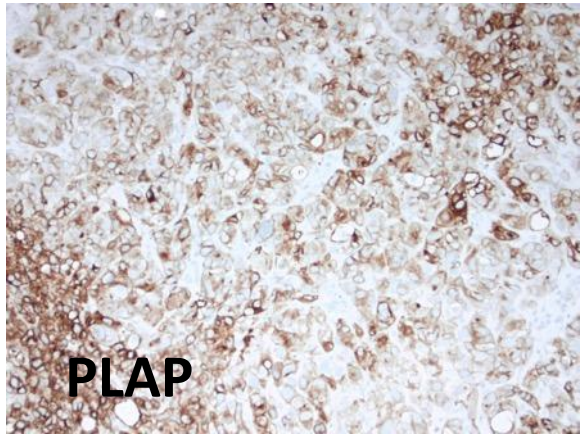

Metastatic Epithelioid Trophoblastic Tumor

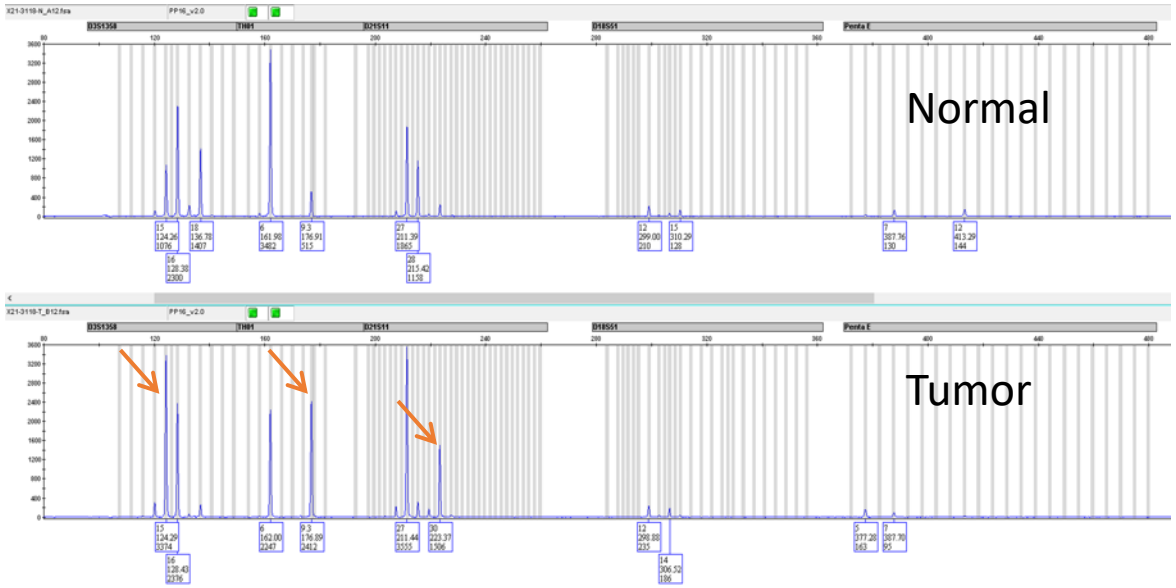

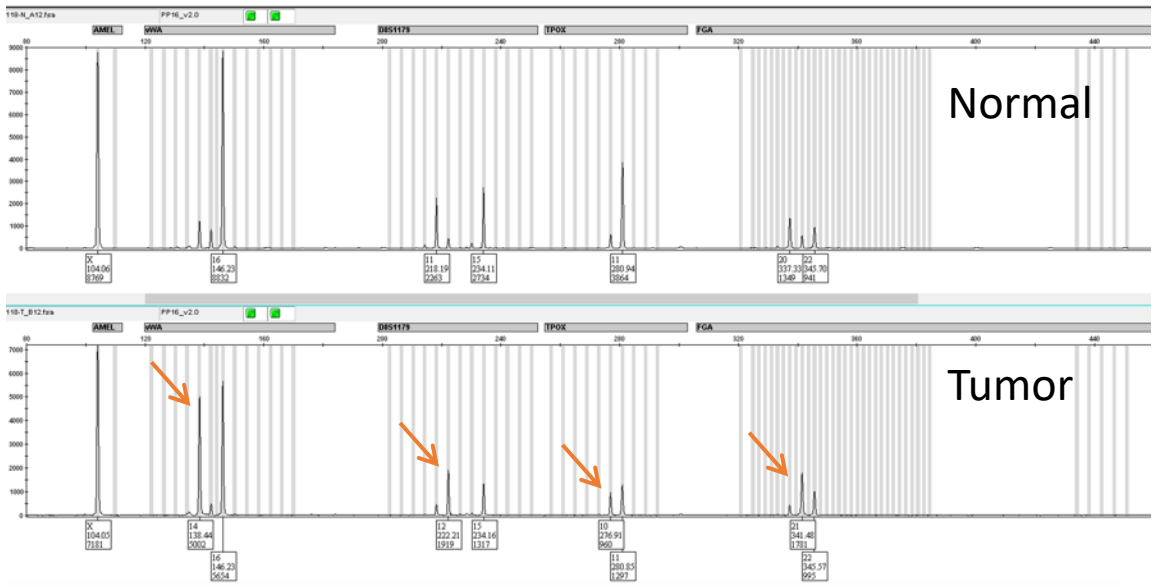

STR Genotyping - Distinct Paternal Alleles In the Tumor (arrows)

Niu N, Ordulu Z, Burak Z, Buza N, Hui P. Histopathology. 2024 Jan;84:325-335.

Table 2. Summary of the clinicopathological information and STR genotyping results

	Case 1	Case 2	Case 3	Case 4
Patient age (years)	61	26	65	57
Prior gestations	G1P0	G3P0A1	NA	G7P3
Presenting symptoms	Vaginal bleeding, abdominal pain weight loss	Home pregnancy test positive	Supraclavicular lymphadenopathy and liver nodules	Dyspnoea
Reported PMH	Endometrial cancer, poorly differentiated	Abortion	Triple-negative breast cancer, stage IV	NA
Lesion site	Anterior abdominal wall, omentum, intestine	Multiple lung nodules	Multiple nodules in the liver	Multiple bilateral lung nodules, neck and mediastinal lymphadenopathy
Initial diagnosis at outside institution	Poorly differentiated carcinoma with squamoid features and extensive necrosis	Malignant neoplasm with trophoblastic features involving lung	ETT	ETT
Treatment/ procedure	Exploratory laparotomy, omentectomy	Lung wedge resection	First-round chemotherapy for trophoblastic tumour without response	Right lung core biopsy
Molecular genotyping	Distinct paternal alleles (not present in normal tissues)	Distinct paternal alleles (not present in normal tissues and recent full-term pregnancy)	Matching alleles with the patient's normal tissues	Matching alleles with the patient's normal tissues
Final diagnosis	Metastatic ETT	Metastatic ETT	Somatic carcinoma with trophoblastic differentiation	Somatic carcinoma with trophoblastic differentiation

ETT, Epithelioid trophoblast tumour; NA, Not available; PMH, Past medical history.

Somatic Carcinomas mimicking ETT

Niu N, et al Histopathology. 2024 Jan;84:325-335.

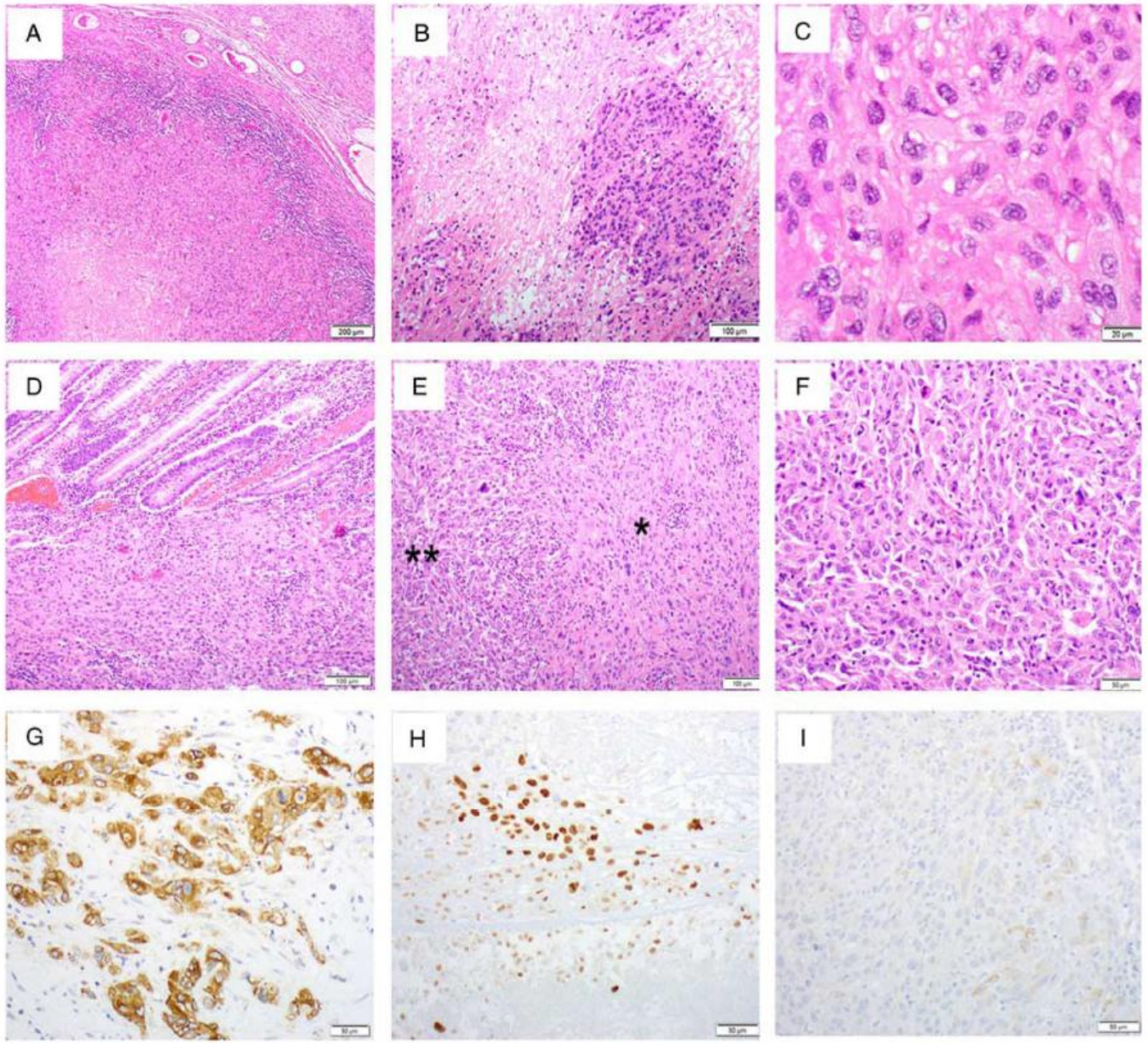

ETT of germ cell origin

Xing, D et al., Am J Surg Pathol 2020

Placental Site Trophoblastic Tumor (PSTT)



Placental Site Trophoblastic Tumor (PSTT)

- Reproductive age
- Vaginal bleeding or amenorrhea
- 12-18 months after pregnancy (mostly term)
- HCG <1000 mIU/ml
- Recurrence rate: 25-30%

Placental Site Trophoblastic Tumor (PSTT)

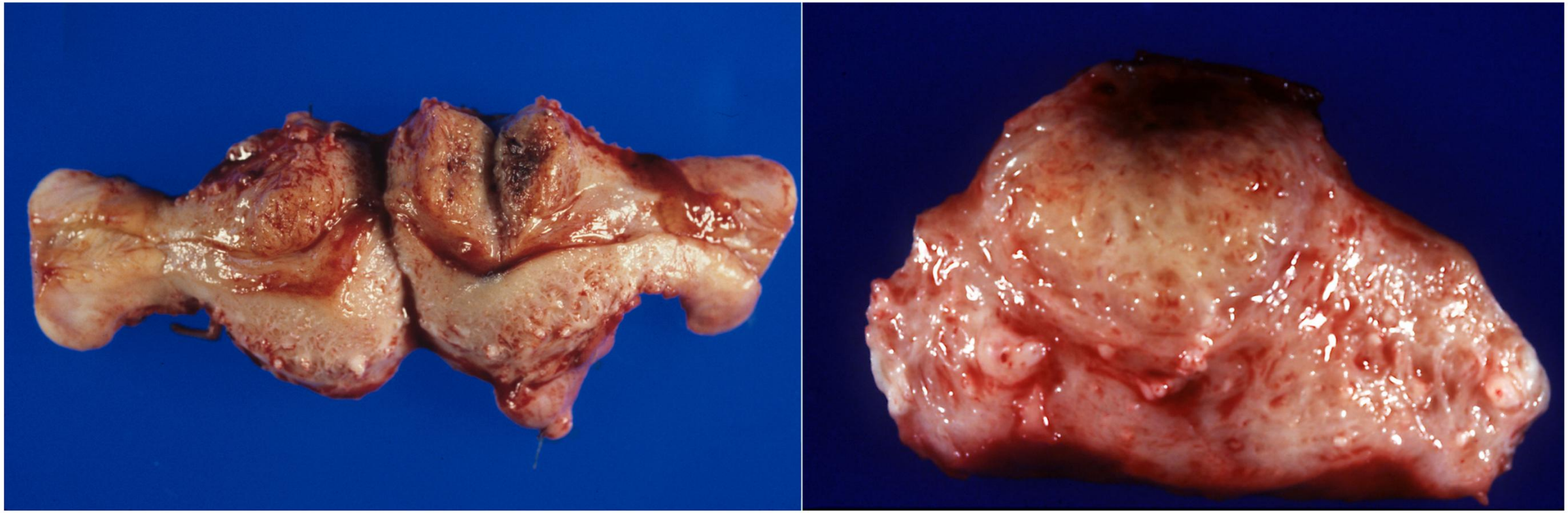

Placental Site Trophoblastic Tumor

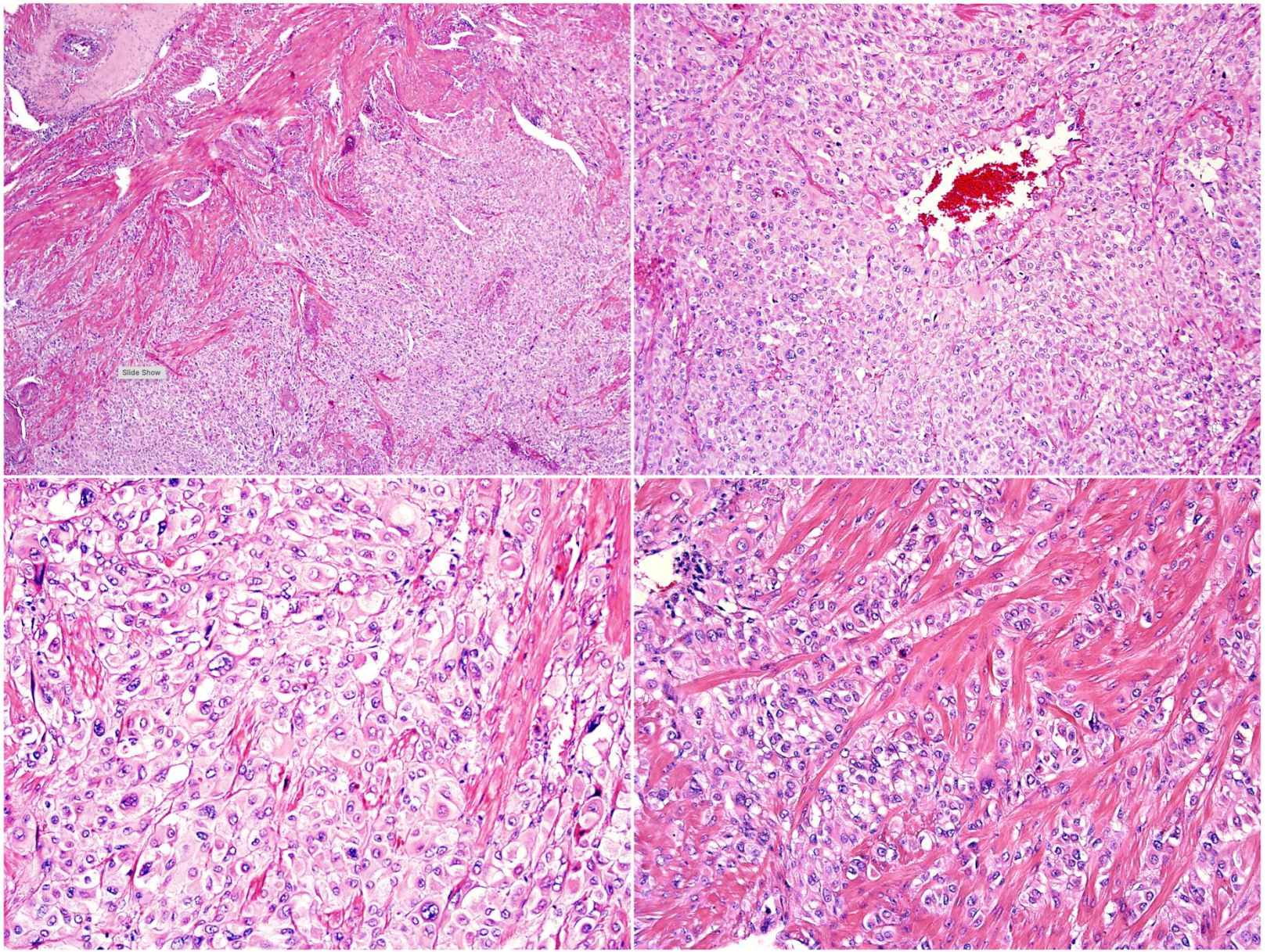

Placental Site Trophoblastic Tumor

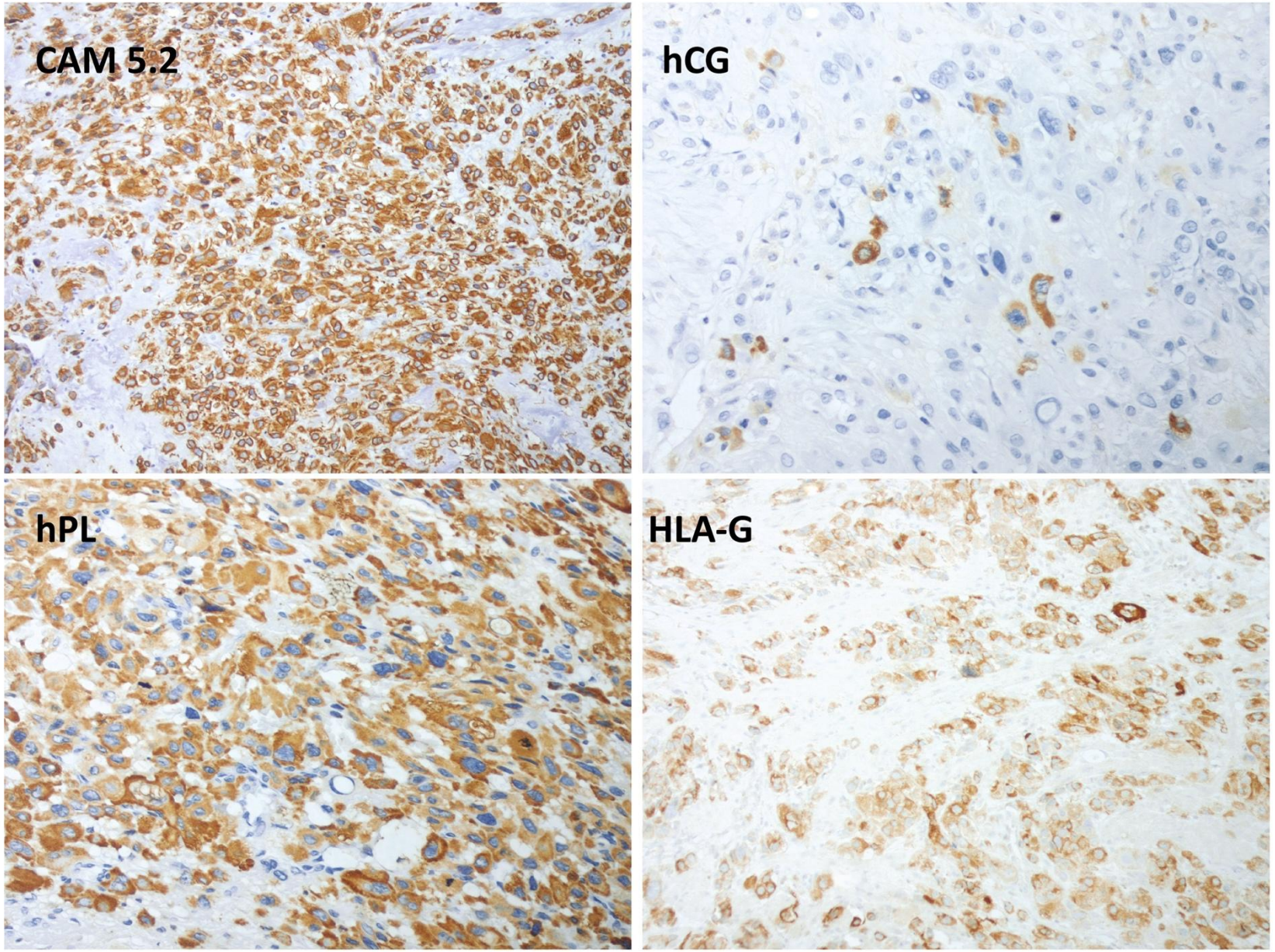

Non-gestational PSTT of germ cell origin

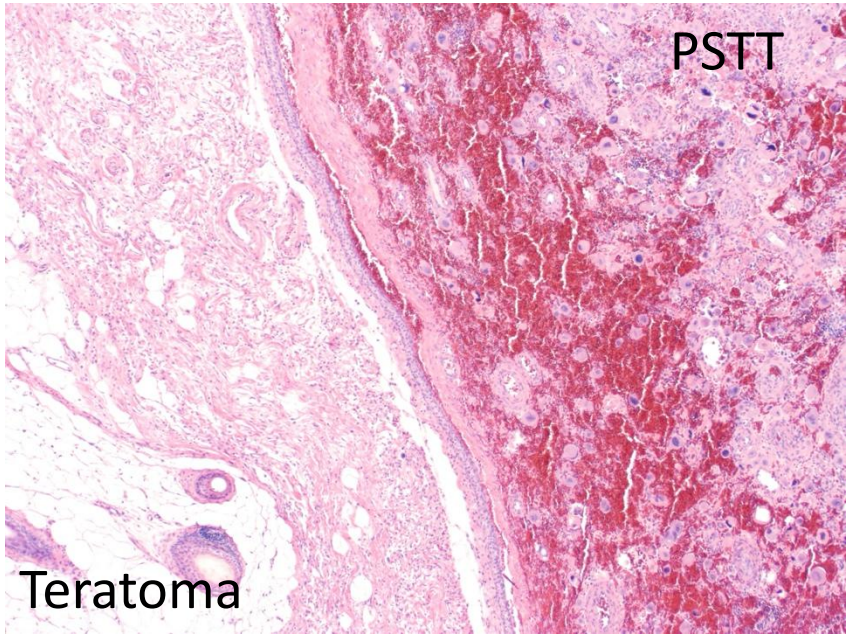

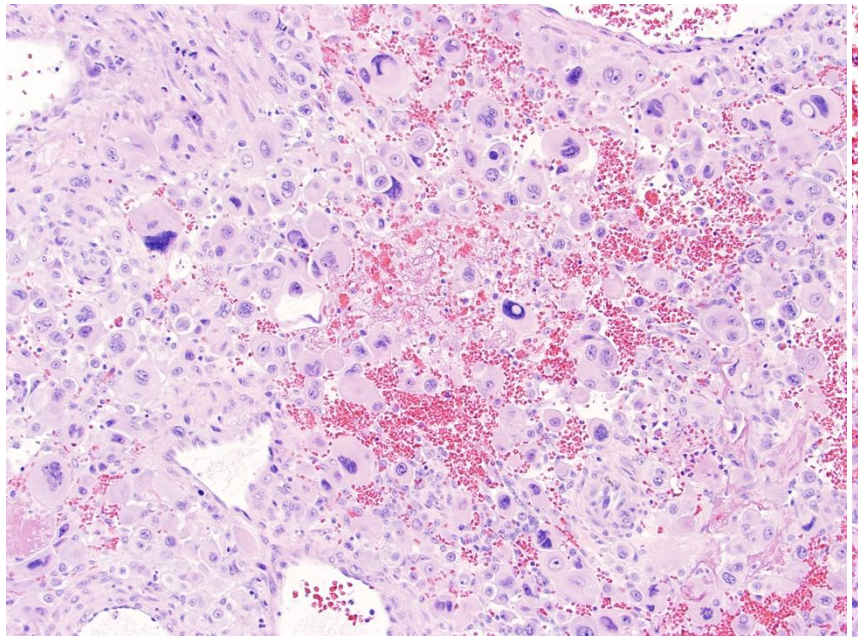

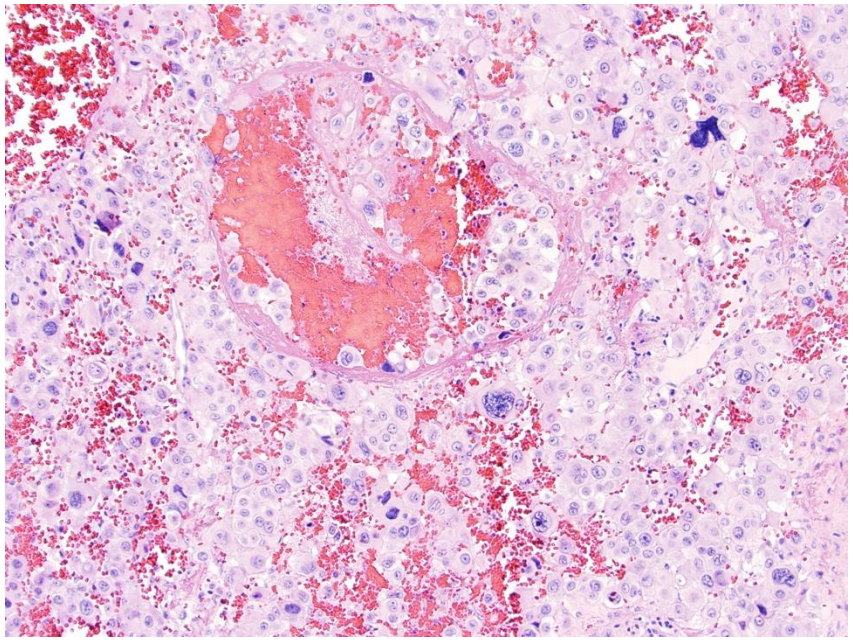

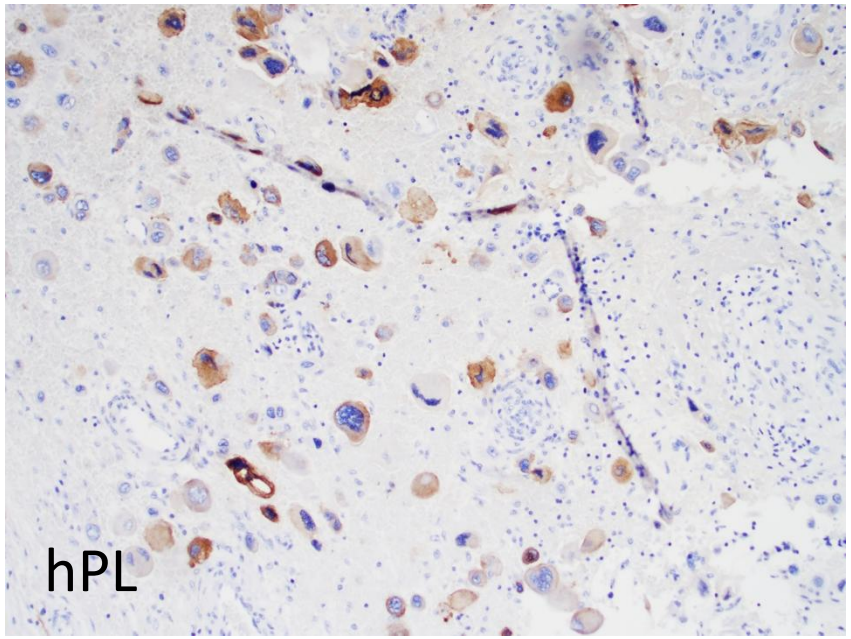

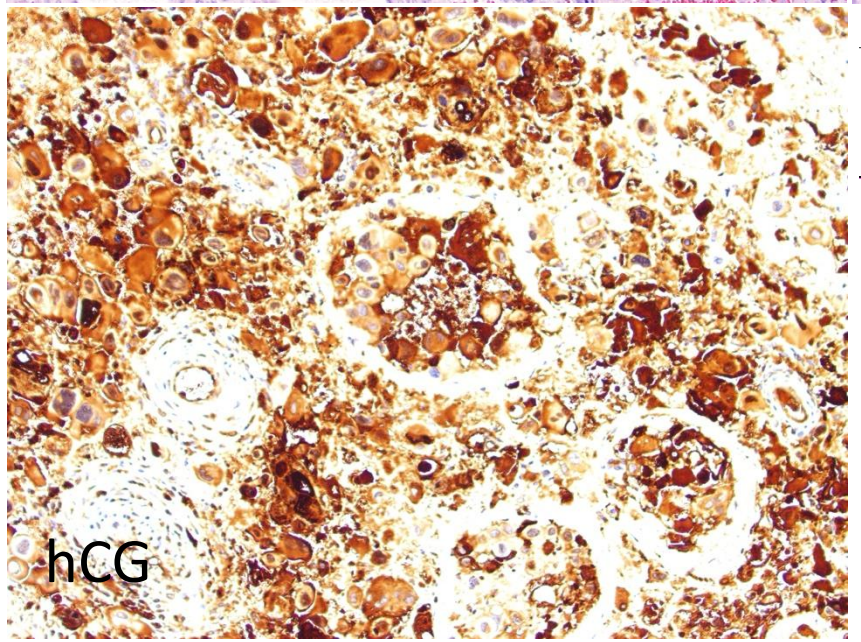

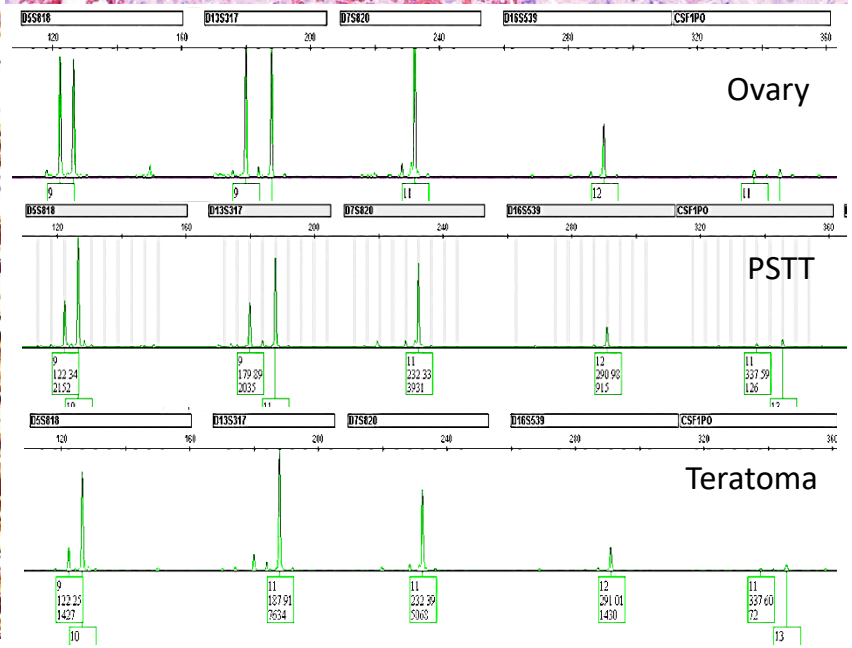

TABLE 1. Clinicopathologic Features

Case No.	Age (y)	Clinical Presentation	β-hCG at Presentation (mIU/mL)	Specimen	Tumor Site and Size (cm)	Diagnosis	Origin
1	43	Abdominal/pelvic mass	Not tested	Bilateral ovaries and fallopian tubes	Right ovary: 6.0; left ovary: 11.0	Right ovary: PSTT; mature cystic teratoma; left ovary: mature cystic teratoma	Nongestational
2	30	Right ovarian mass with increased β-hCG level	1083	Bilateral ovaries and fallopian tubes	Right ovary: 3.0	PSTT; mature cystic teratoma; 1 para-aortic lymph node with metastasis	Nongestational
3	2.5 (30 mo)	Isosexual precocious puberty of 1 mo duration; right ovarian mass	37.5	Right ovary and fallopian tube	Right ovary: 3.6	PSTT; epidermoid cyst	Nongestational
4	39	Left ovarian mass with a second mass in the rectosigmoid colon	Not tested	Left ovary and rectosigmoid colon	Left ovary: 2.2; rectosigmoid colon: 6.5	ETT	Nongestational
5	36	Right ovarian mass	Not tested	Right ovary	Right ovary: 9.0	ETT	Gestational
6	55	Right ovarian mass	29,166	Uterus, cervix, bilateral ovaries, and fallopian tubes	Right ovary: 11.6	ETT with choriocarcinomatous differentiation	Gestational

Prognostic Indicators for ETT and PSTT

- **TNM/FIGO stage**
- **Interval time of ≥ 4 years from causative gestation**
- Larger tumor size
- Deep myometrial invasion
- High mitotic count (≥ 5/ 10 HPF)
- Necrosis
- Clear cytoplasm (PSTT)

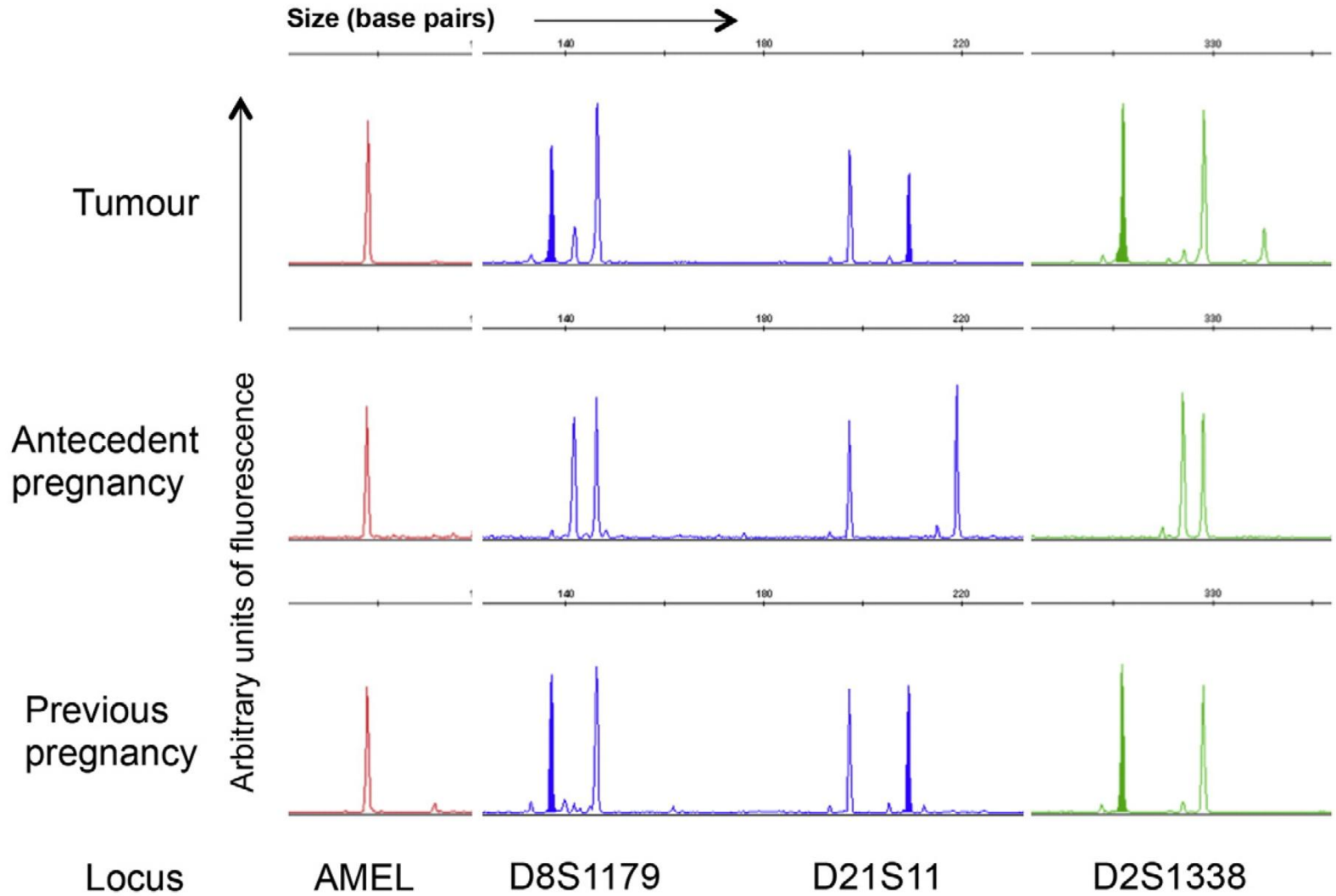

Fig. 4. Partial genotypes of tumour tissue in a case of PSTT/ETT following a female term birth. Both the tumour and antecedent pregnancy are female. However, genotyping of the tumour for STR loci D8S1179, D21S11 and D2S1338 (and others not shown) identified alleles in the tumour that were not present in DNA from the child of the antecedent pregnancy (solid peaks). Genotyping of the child from the previous pregnancy identified a genotype consistent with that in the tumour.

Zhao, et al. Gynecologic Oncology. 2016: 142:501-507

41-year-old woman with a 3.0 cm ETT confined to uterus for determination of the interval time

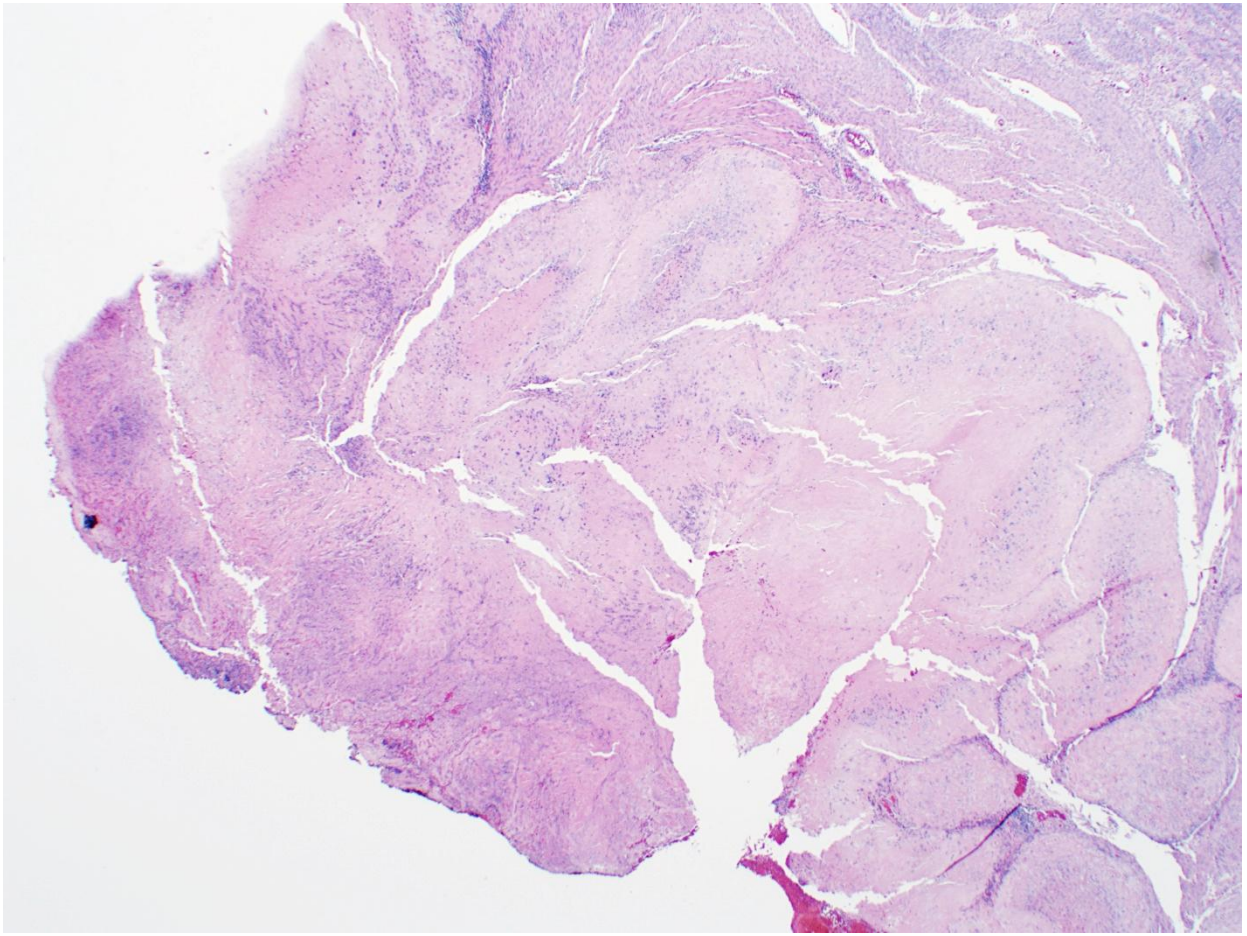

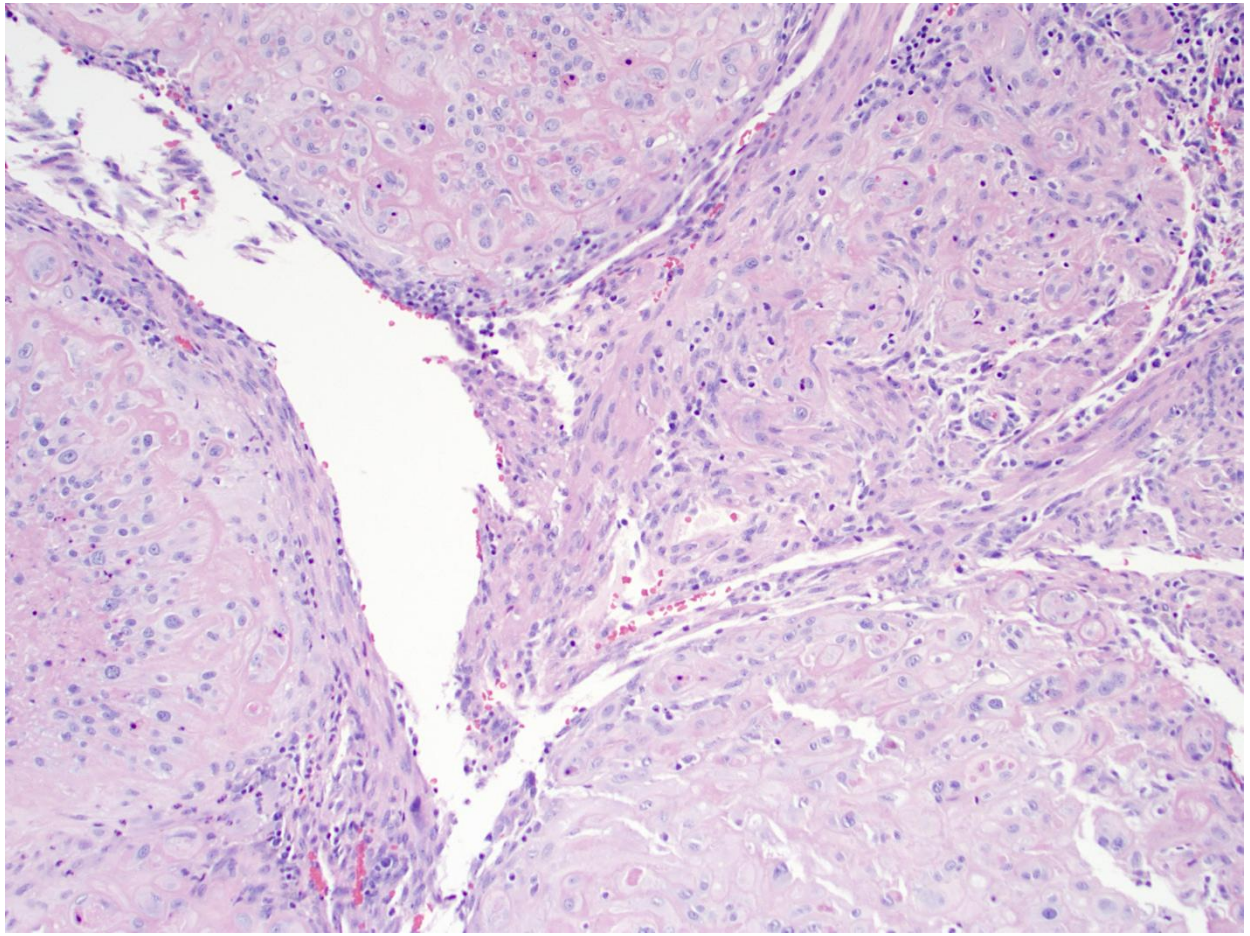

41-year-old woman with 3.0 cm ETT confined to uterus for determination of the interval time

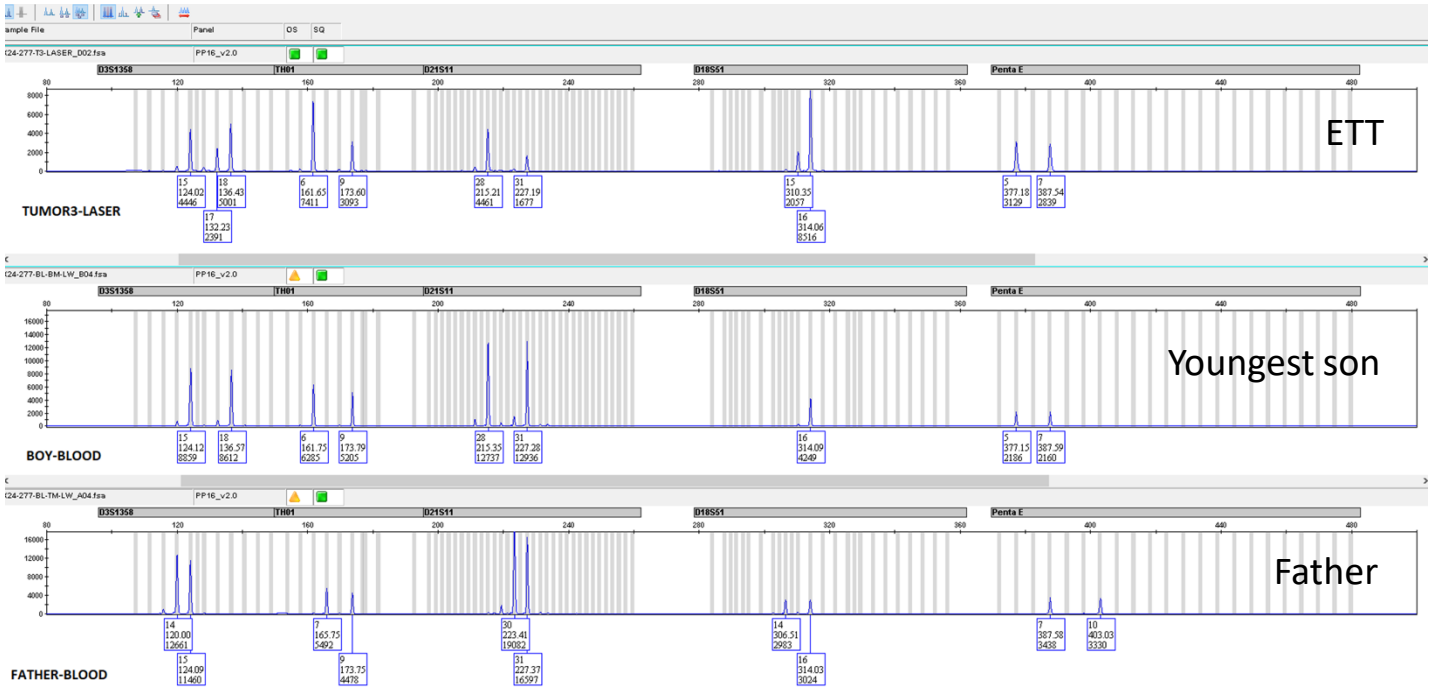

- ETT genetic profile matches with that of the youngest son among the three children with age of 1, 7, 9 years
- Interval time of < 4 years – low risk factor

Case#: X24-277			Patient name: Mudd, Cambridge M				
STR Loci	Tumor #1	Tumor #2	Mother (CM, DOB:1-23-82)	Father (TM, DOB:5-10-77)	Child#1 (AM, DOB:6-12-15)	Child#2 (VM, DOB:1-6-17)	Child#3 (BM, DOB:2-2-23)
D3S1358	15,17,18	15,17,18	17,18	14,15	15,18	15,17	15,18
TH01	6,9	6,9	6	7,9	6,7	6,9	6,9
D21S11	28,31	28,31	28	30,31	28,30	28,30	28,31
D18S51	15,16	15,16	15,16	14,16	14,16	16	16
Penta E	5,7	5,7	5,7	7,10	5,10	7,10	5,7
D5S818	10,11,13	10,11,13	10,11	11,13	10,13	10,11	10,13
D13S317	8,11	8,11	8,11	11,14	8,11	8,11	8,11
D7S820	10,12,13	10,12,13	10,12	11,13	10,13	10,11	10,13
D16S539	9,11,13	9,11,13	9,11	13	11,13	9,13	11,13
CSF1PO	11,12,13	11, 12,13	12,13	8,11	8,13	8,13	11,13
PENTA D	9,13	9,13	9	11,13	11	11	9,13
AMEL (XY)	XY	XY	X	XY	X	X	XY
vWA	14,17,18	14,17,18	14,17	17,18	14,18	14,18	14,18
D8S1179	12,13	12,13	12,13	12	12	12	12
TPOX	8,11	8,11	8,11	8,11	8,11	8,11	8,11
FGA	19,21,24	19,21,24	19,21	22,24	21,24	19,22	21,24

Gestational Trophoblastic Neoplasia (GTN)

- Rare tumors
- Unique genetic compositions
- Distinct histopathology
- Challenging differential diagnoses
- Powerful STR genotyping applications
- Profound clinical implications

THANK YOU

