The British Association of Gynaecological Pathologists

Lecturer – Laura Casey



Laura Casey is a Consultant Histopathologist at the Royal London Hospital, specialising in gynaecological pathology. She has presented internationally, published in a number of peer reviewed journals, contributed book chapters, and currently sits on the BAGP council.

The British Association of Gynaecological Pathologists

Everyday Dilemmas in Gynaecological Pathology

- Gastric type cervical adenocarcinoma: a case based discussion
- Laura Casey
- Consultant Pathologist, Royal London Hospital
- 7th March 2025

The British Association of Gynaecological Pathologists

Speaker disclosures

Choose one

- ❑ I have no financial conflicts of interest to disclose

HISTORY

44 year old woman, para 2, presented to GP complaining of vaginal discharge / fluid leak. Watery yellow, sometimes brown. Smear history up to date (negative).

GP queried urine leak from vesicovaginal fistula. Patient referred for MRI pelvis.

Findings: ***'…. There is a prominent cluster of cysts replacing most of the cervix. Although these are most likely to be florid Nabothian cysts, an adenoma malignum can have similar appearances on MRI… No VVF is seen and the bladder and anterior vaginal walls are normal.'***

Diagnostic LLETZ performed.

NOTE: 'Adenoma malignum' is an outdated term, the use of which is discouraged. Along with the term 'minimal deviation adenocarcinoma' (use of which is also not recommended), it described a somewhat cystic, cytologically bland, mucinous adenocarcinoma of the cervix which was could be difficult to distinguish from benign endocervical glandular proliferations. The preferred terminology is 'adenocarcinoma, HPV-independent, gastric type, of the uterine cervix' [WHO 2020]

LLETZ 1



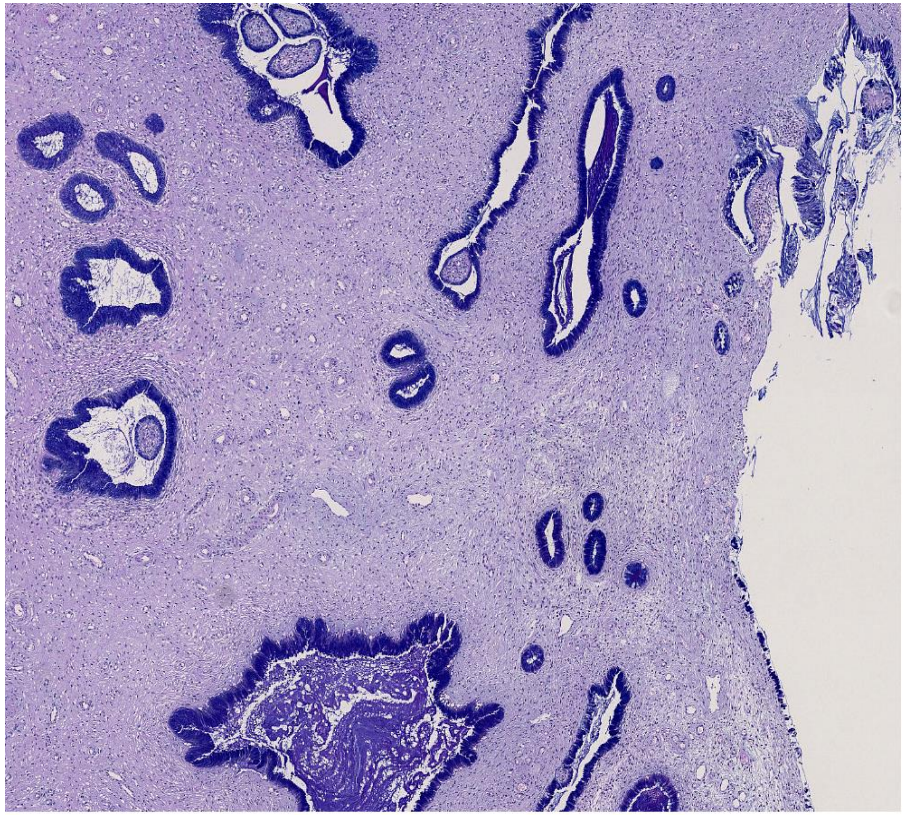

Acidic endocervical glandular mucin stains blue with ABPAS

LLETZ 1: Lobular endocervical glandular hyperplasia

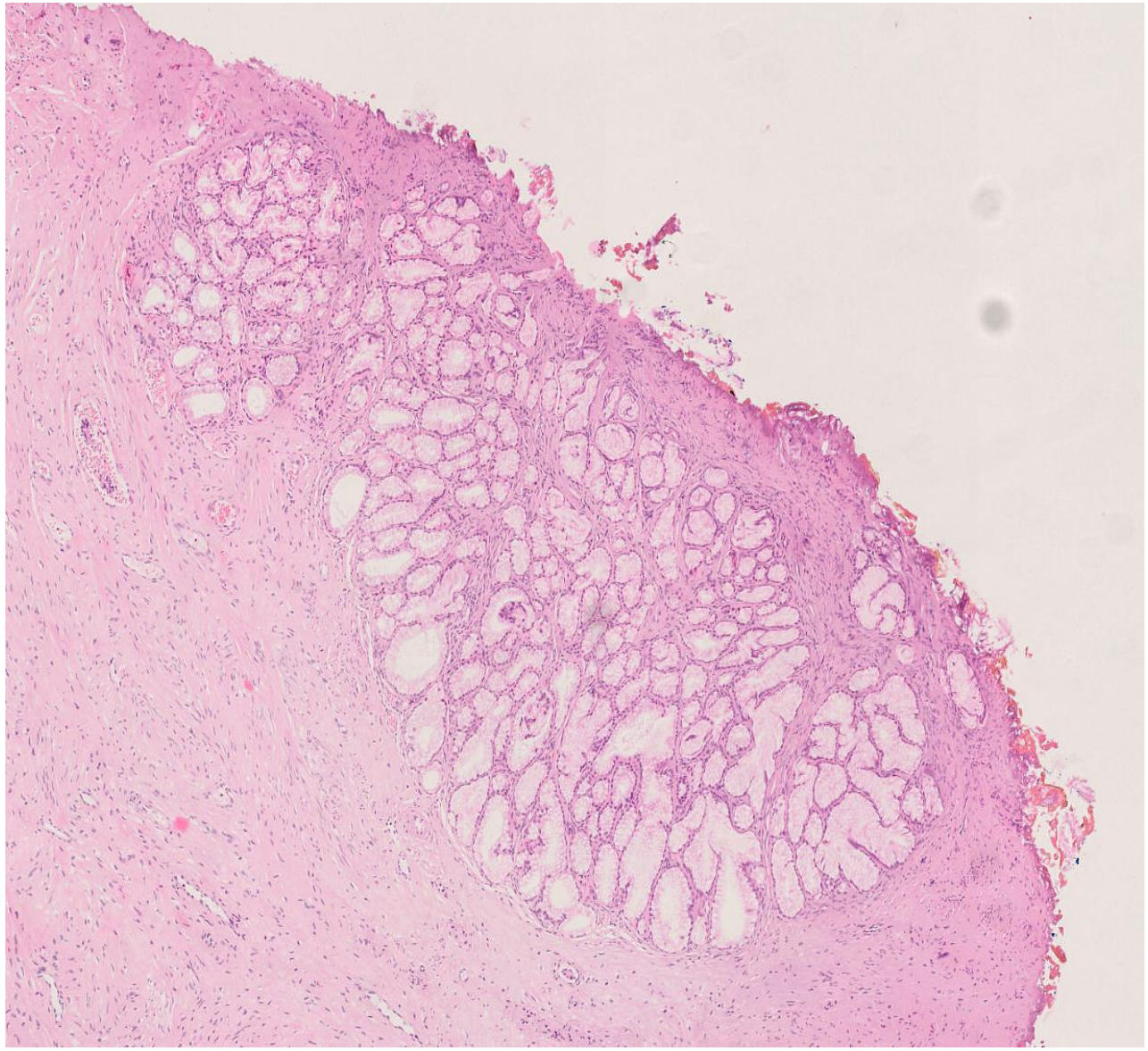

A lobular proliferation of small to medium-sized endocervical glands, often with pyloric gland differentiation.

The glands are composed of tall columnar mucinous epithelium (sometimes with granular eosinophilic cytoplasm) and bland, basally-located nuclei.

LEGH presents over a wide age range though typically during the reproductive years.

Patients may present with mucoid or watery discharge.

LEGH can occur in patients with Peutz-Jeghers syndrome (germline STK11 mutation).

Sporadic LEGH can show mutations in GNAS (42%), KRAS (5%), and STK11 (10%).

LLETZ 1



Unlike the background endocervical glands, the mucin in lobular endocervical glandular hyperplasia is neutral and, therefore, stains magenta on ABPAS.

LLETZ 1

Conclusion:

- Negative for carcinoma
- A 3mm focus of LEGH (lobular endocervical glandular hyperplasia) is identified, present at diathermied radial margin
-No evidence of HPV-associated change, CIN, CGIN or invasive malignancy

Comment: Pure LEGH without atypical features (as in this case) is regarded as benign, and in itself therefore requires no additional treatment. The radiologic impression is noted, however; please correlate as to whether the imaging abnormality is likely to have been included in this LLETZ specimen.

The patient proceeded to have a second LLETZ…

LLETZ 2

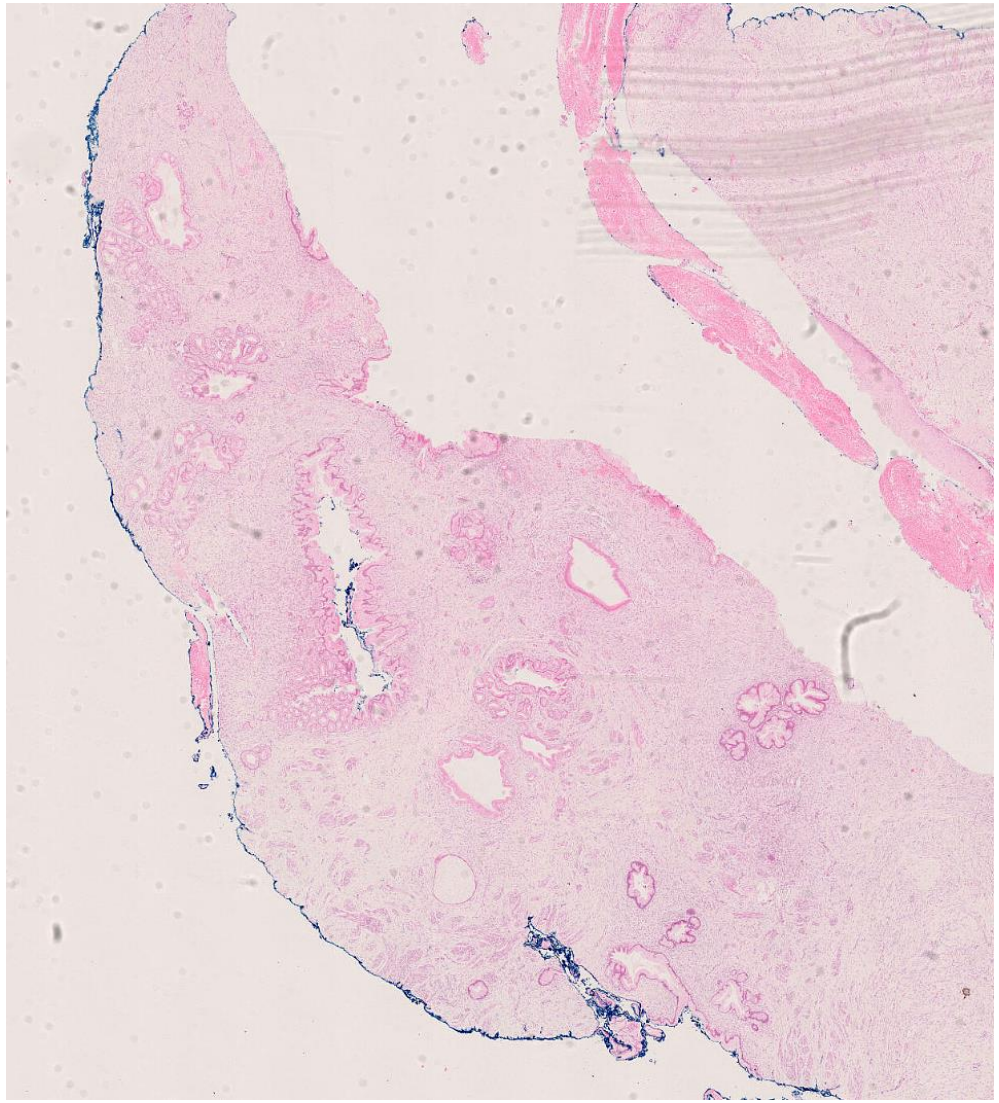

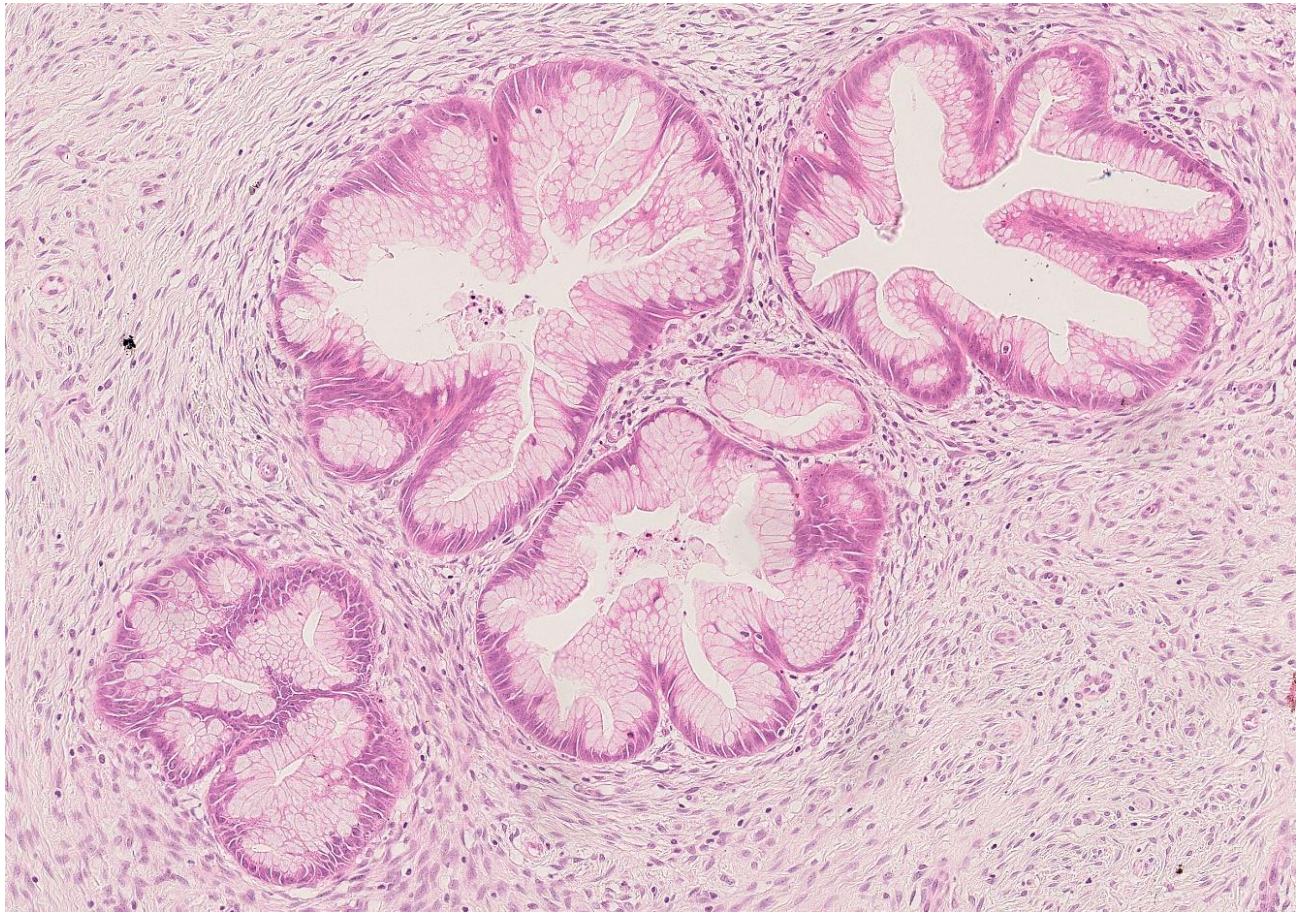

Nuclear hyperchromasia. Occasional mitoses. Architectural complexity (compared to small, uniform, rounded glands of LEGH).

LLETZ 2

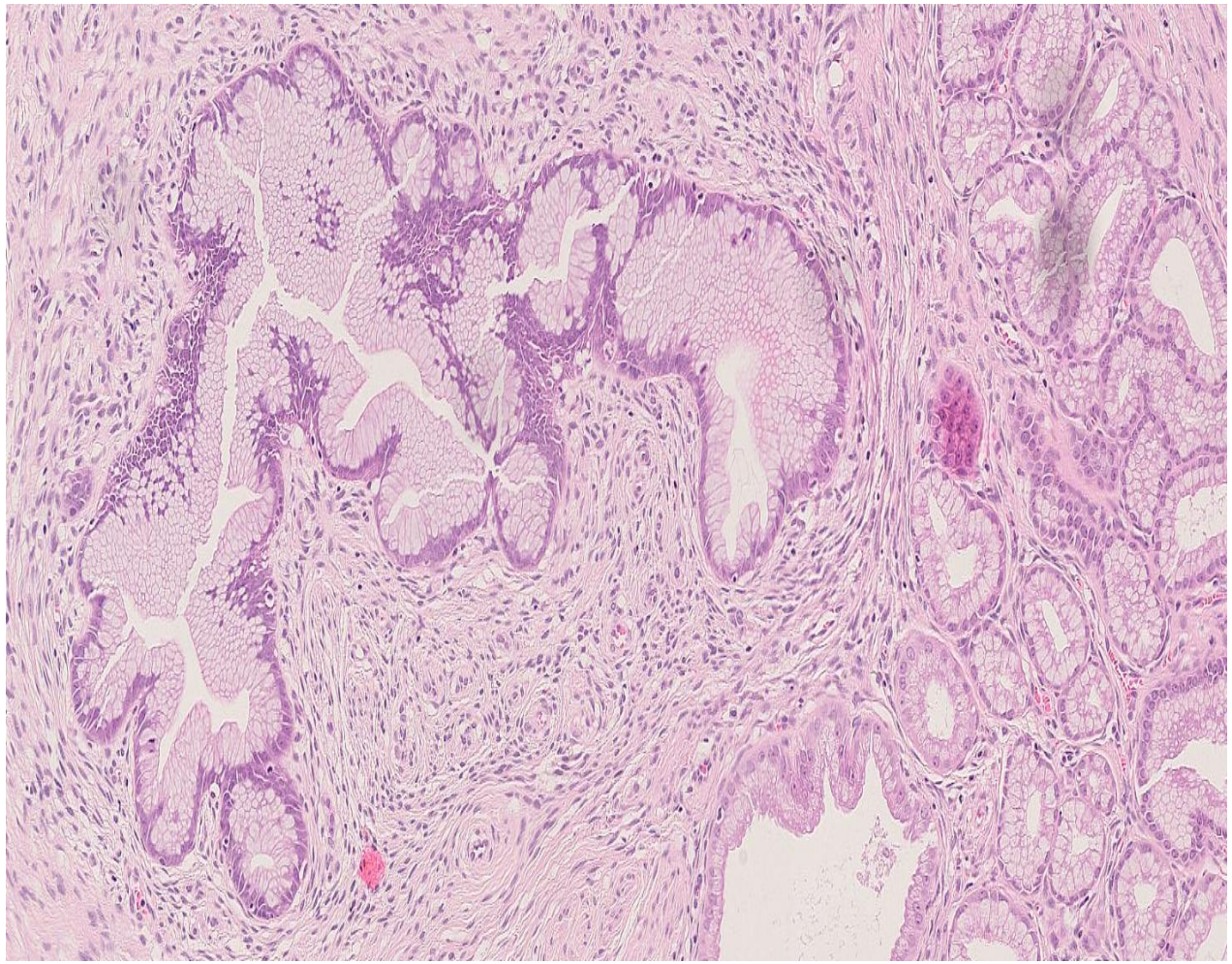

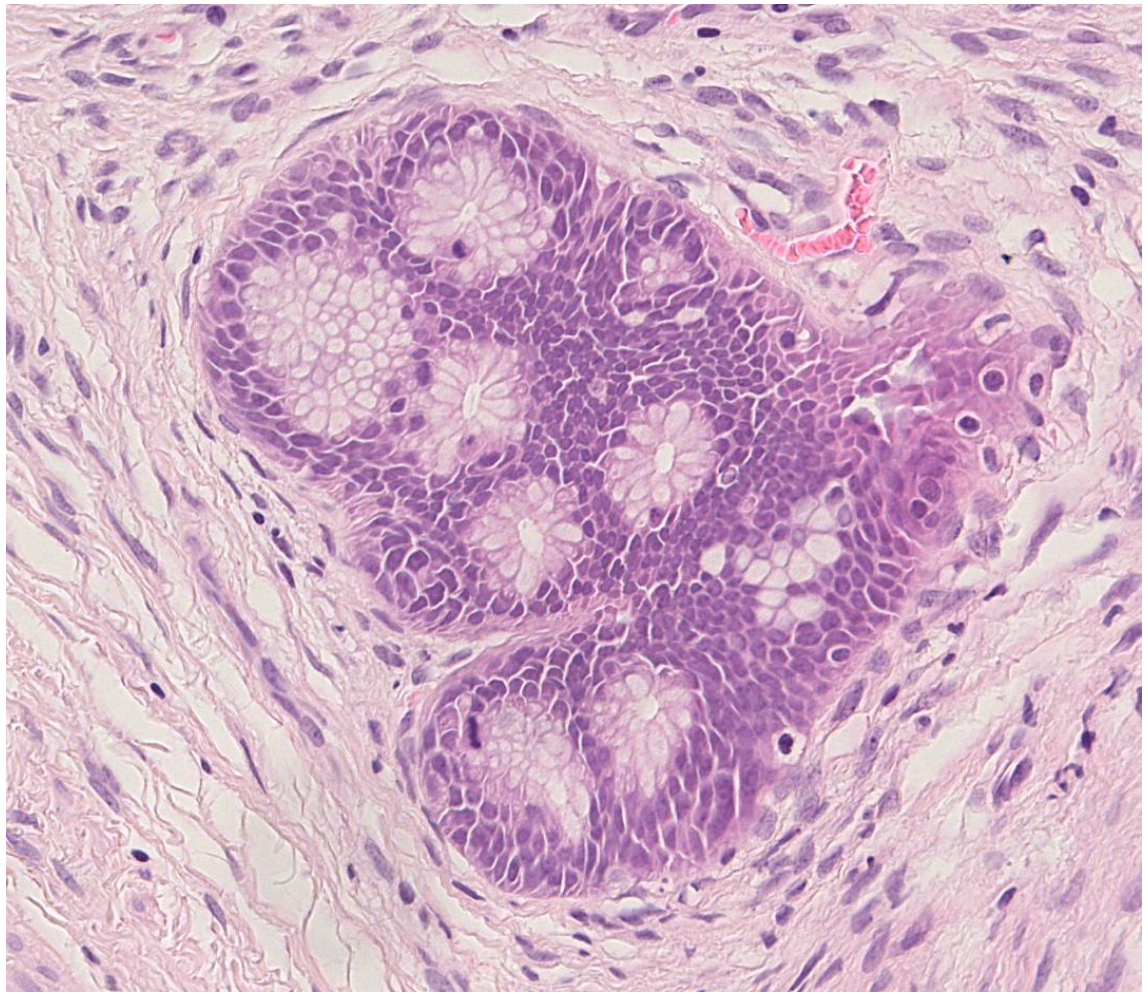

LLETZ 2

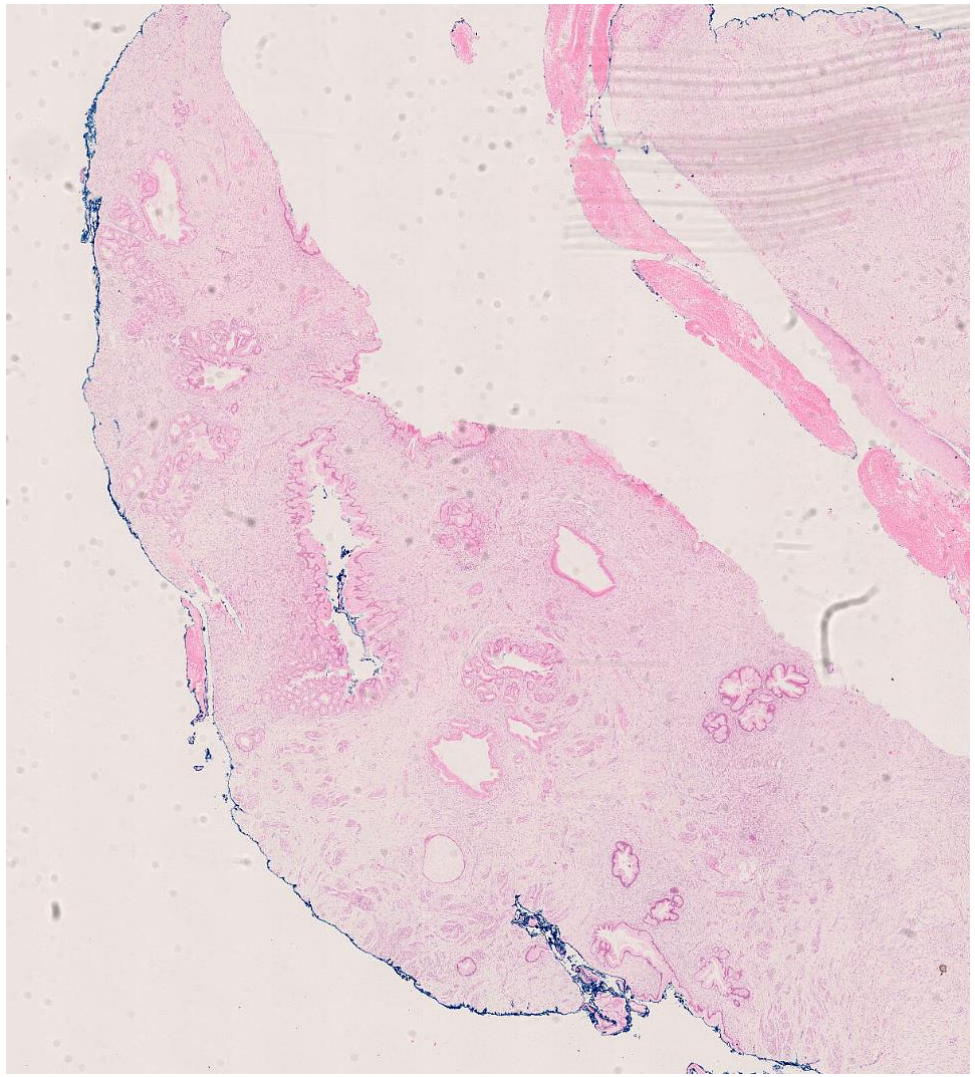

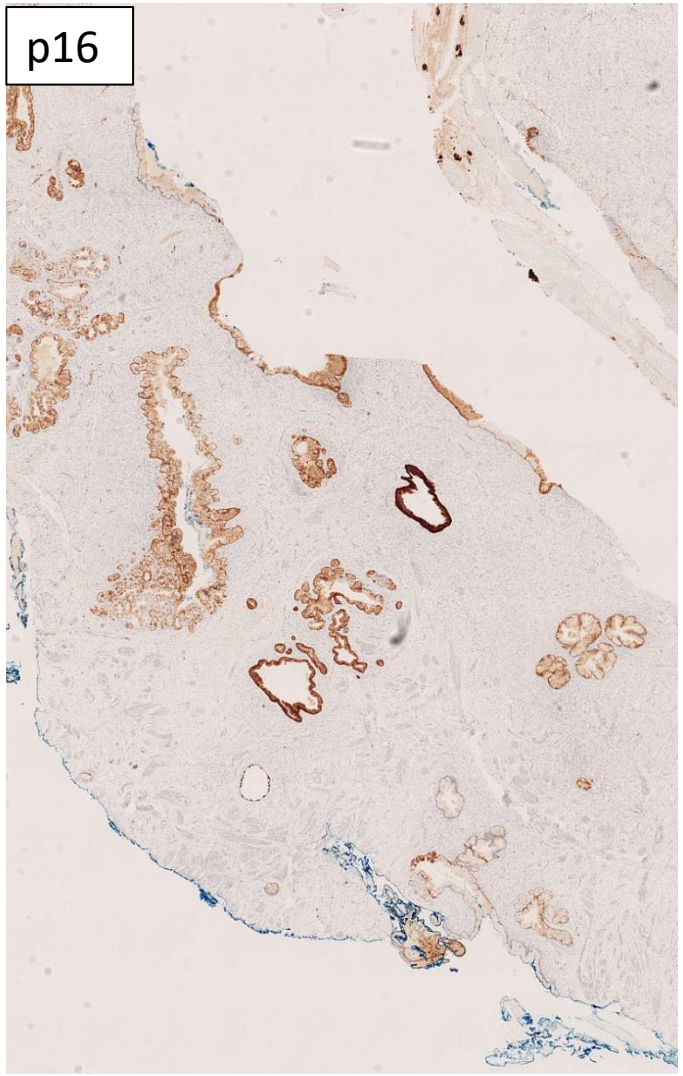

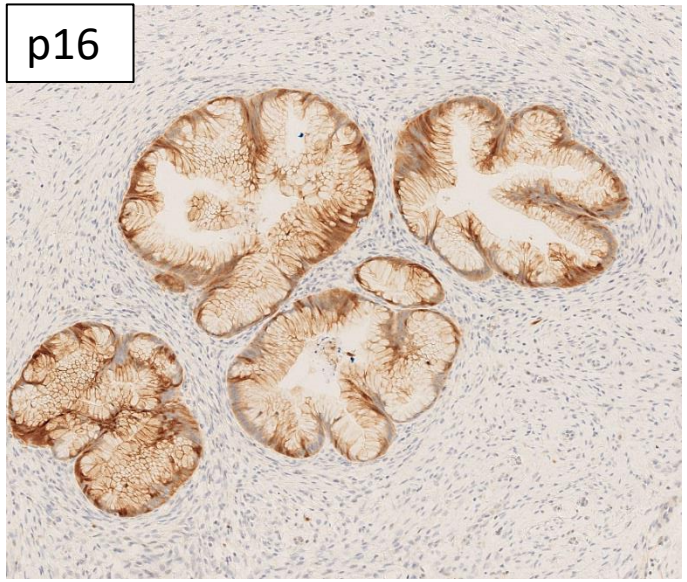

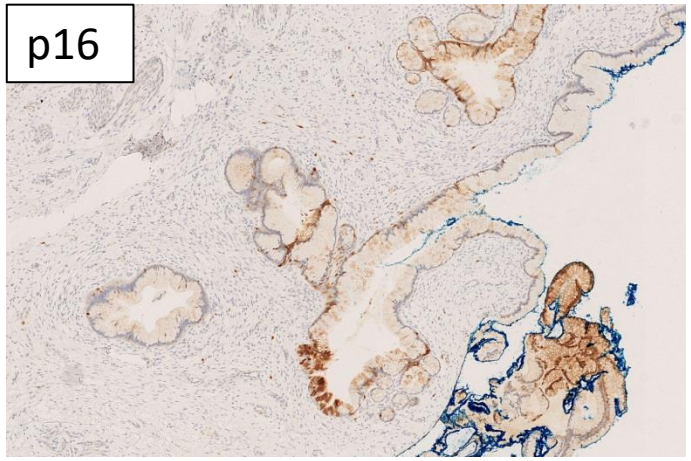

LLETZ 2: Atypical Lobular Endocervical Glandular Hyperplasia

Described in WHO 2020 as being ‘characterized by epithelial in-foldings, tufts or papillae, as well as nuclear hyperchromasia, enlargement, distinct nucleoli, apoptotic bodies, and occasional apical mitoses.’

Unlike CGIN, it is not associated with HPV infection and does not demonstrate abnormal expression of p16.

LLETZ 2

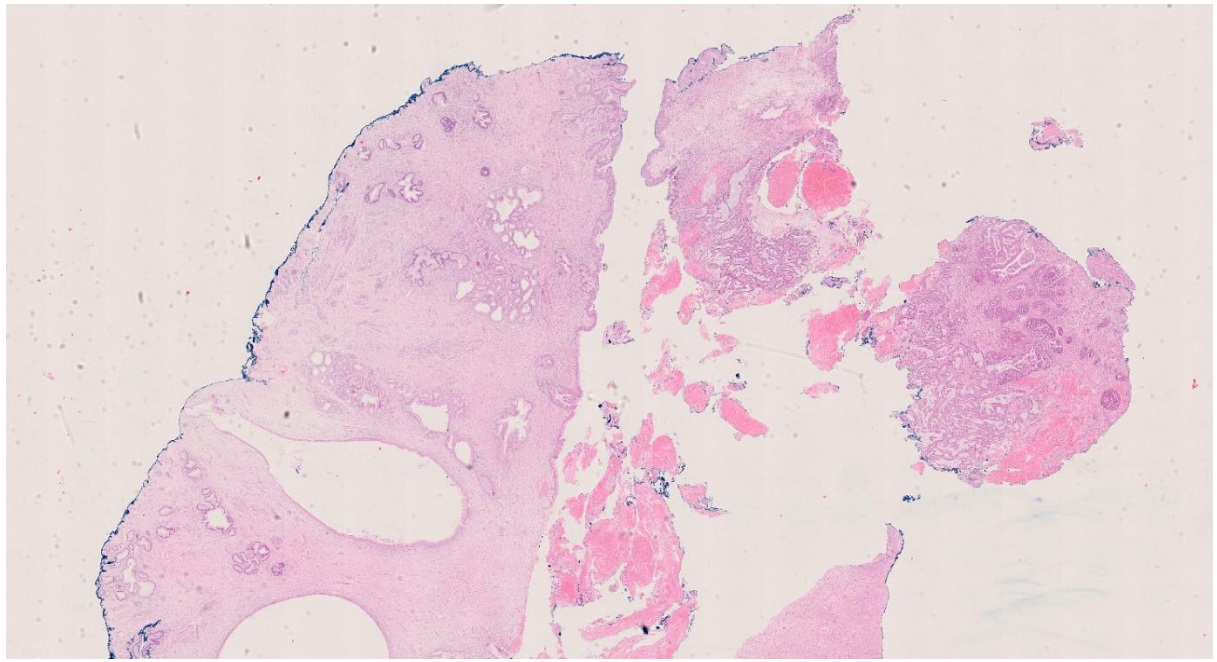

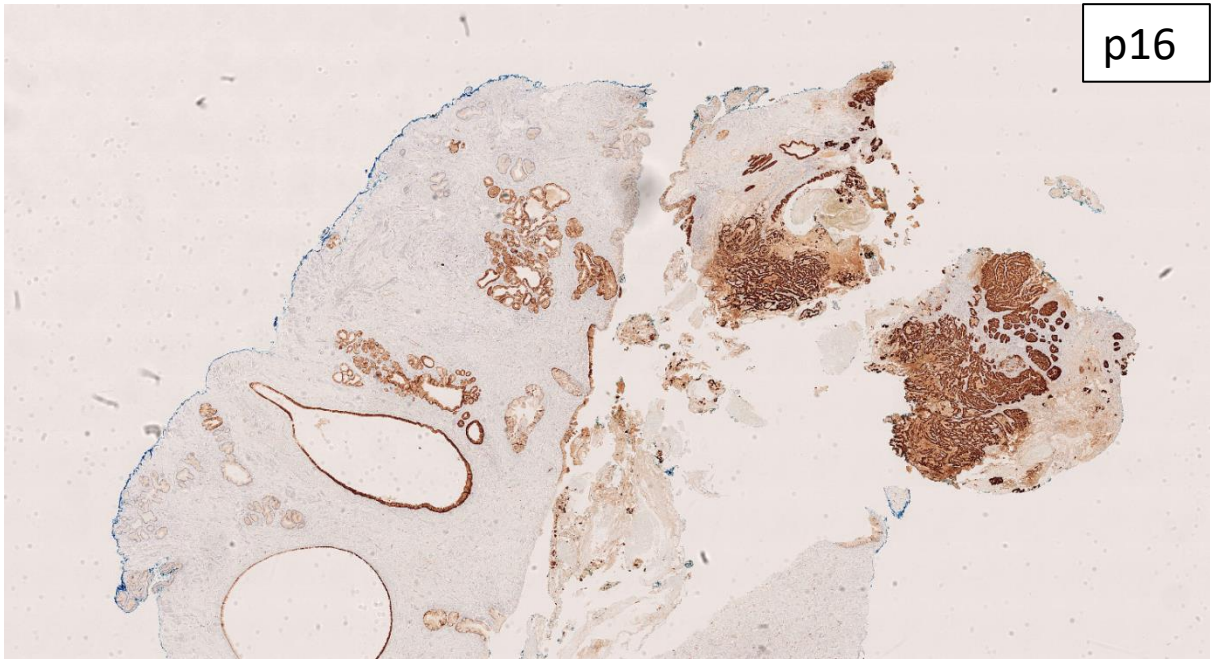

LLETZ 2

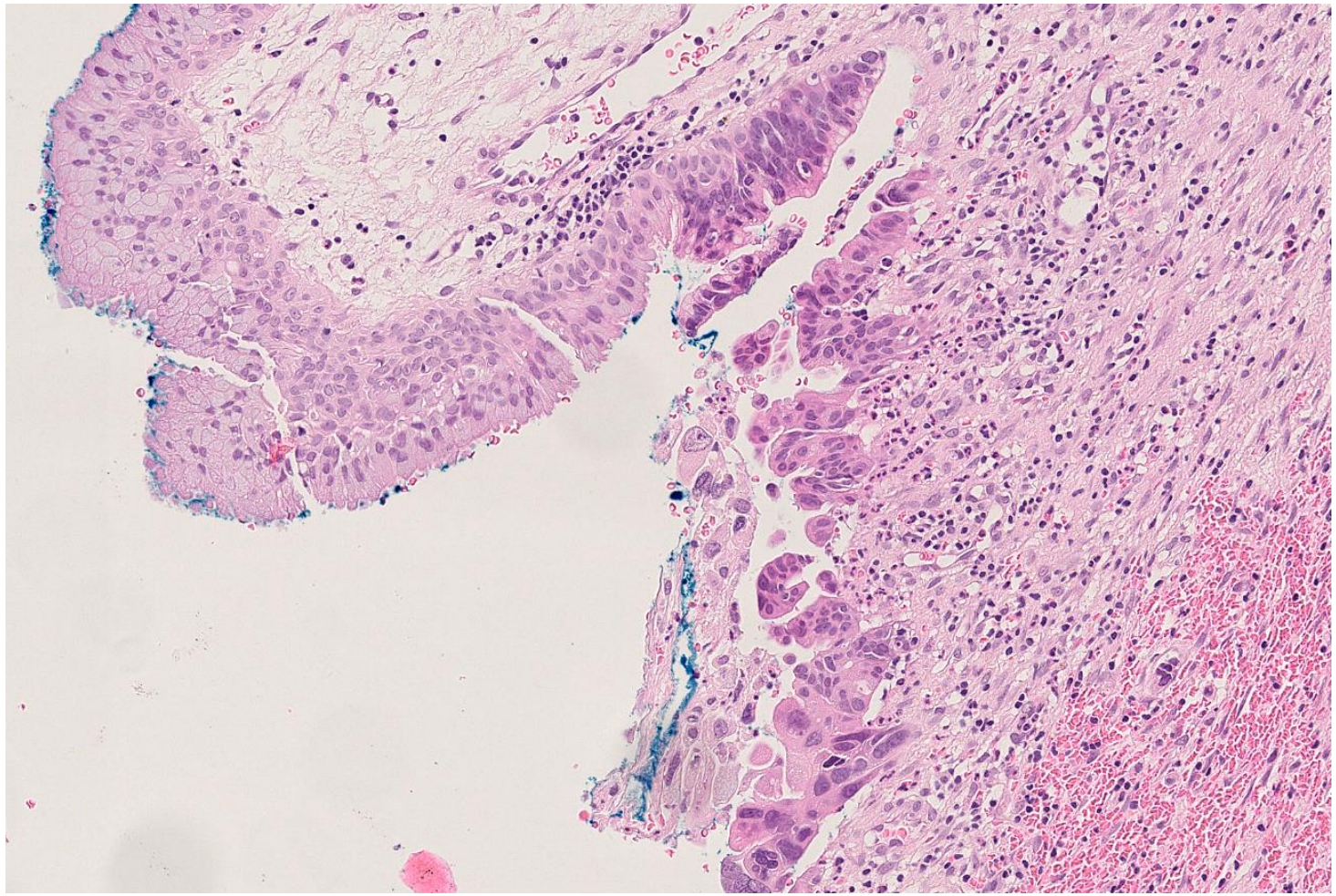

LLETZ 2

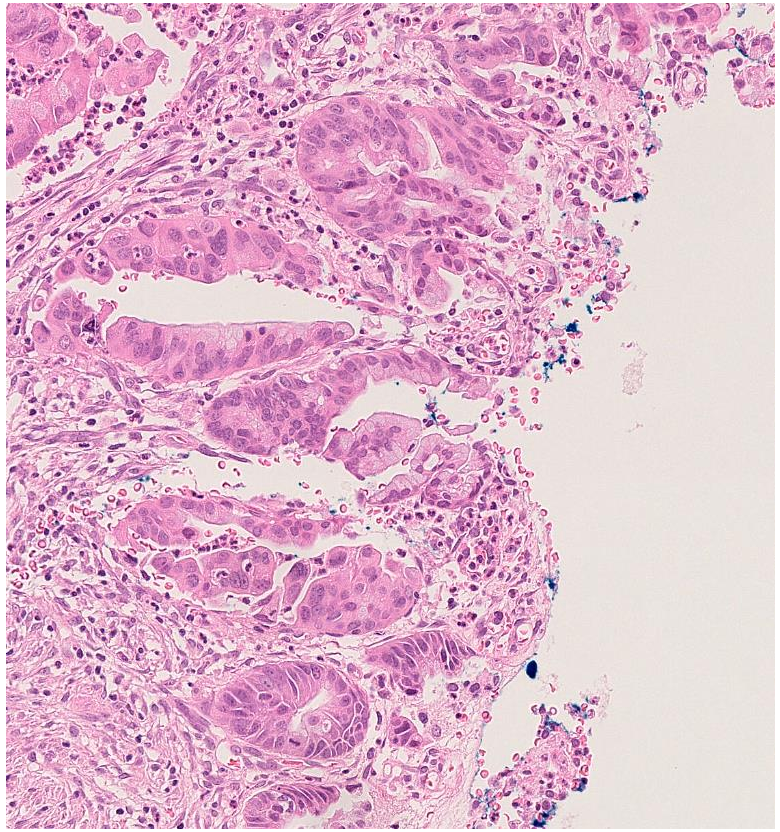

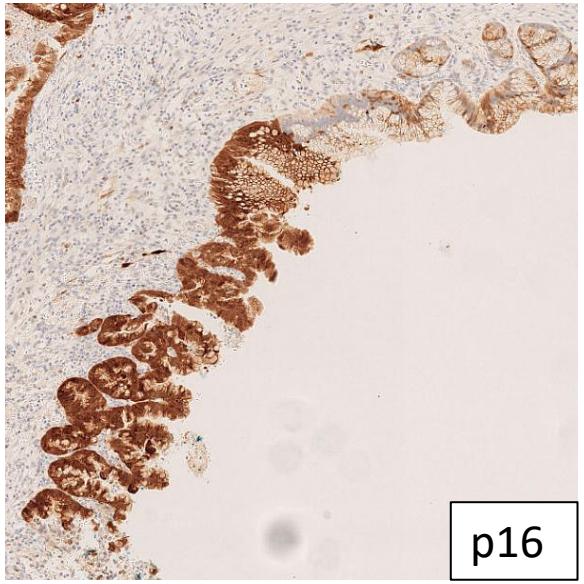

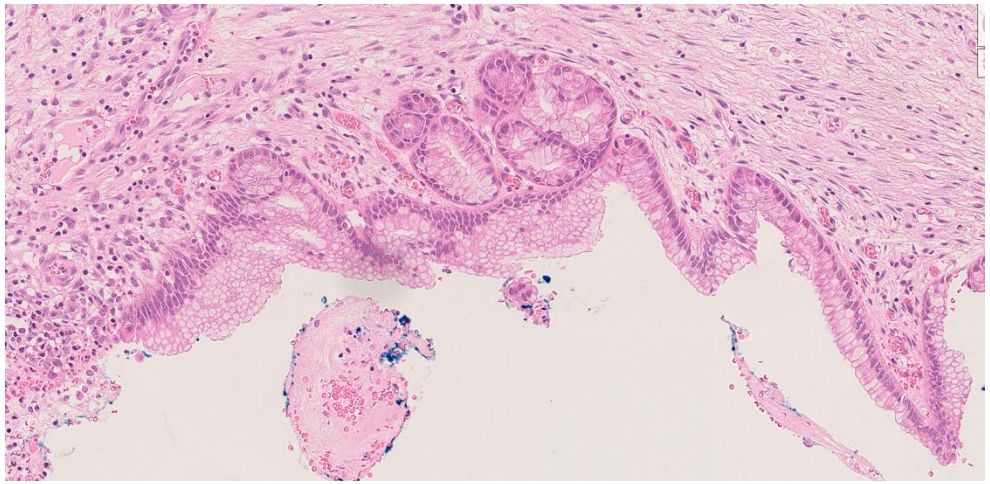

LLETZ 2: HPV-independent adenocarcinoma in situ of the uterine cervix aka Gastric-type adenocarcinoma in situ (gAIS)

This is a non-invasive glandular neoplasm unrelated to HPV.

Gastric-type differentiation is characteristic.

The proliferation involves pre-existing endocervical glands so it does not form a visible mass lesion and it lacks haphazard glandular crowding or confluence (though intraglandular complexity – cribriform or papillary growth – can occur.)

gAIS is characterised by cuboidal / columnar cells with distinct cell borders, eosinophilic to pale and/or foamy vacuolated cytoplasm, and nuclear atypia that ranges from mild to severe. Mitoses and apotoses are present. Goblet cells are usually identifiable (though may not be prominent).

The WHO describes this lesion as being distinct from atypical LEGH in that the latter occurs within the confines of a lobulated proliferation consistent with lobular endocervical glandular hyperplasia.

It probably exists on a spectrum with atypical LEGH.

The interesting thing about this case is that areas of gAIS typified by pronounced nuclear atypia and conspicuous mitotic activity demonstrate abnormal expression of p16 (see difficulty in distinguishing from CGIN), whereas those with more subtle atypia, nuclear hyperchromasia and less obvious mitotic activity show mosaic p16 staining.

LLETZ 2

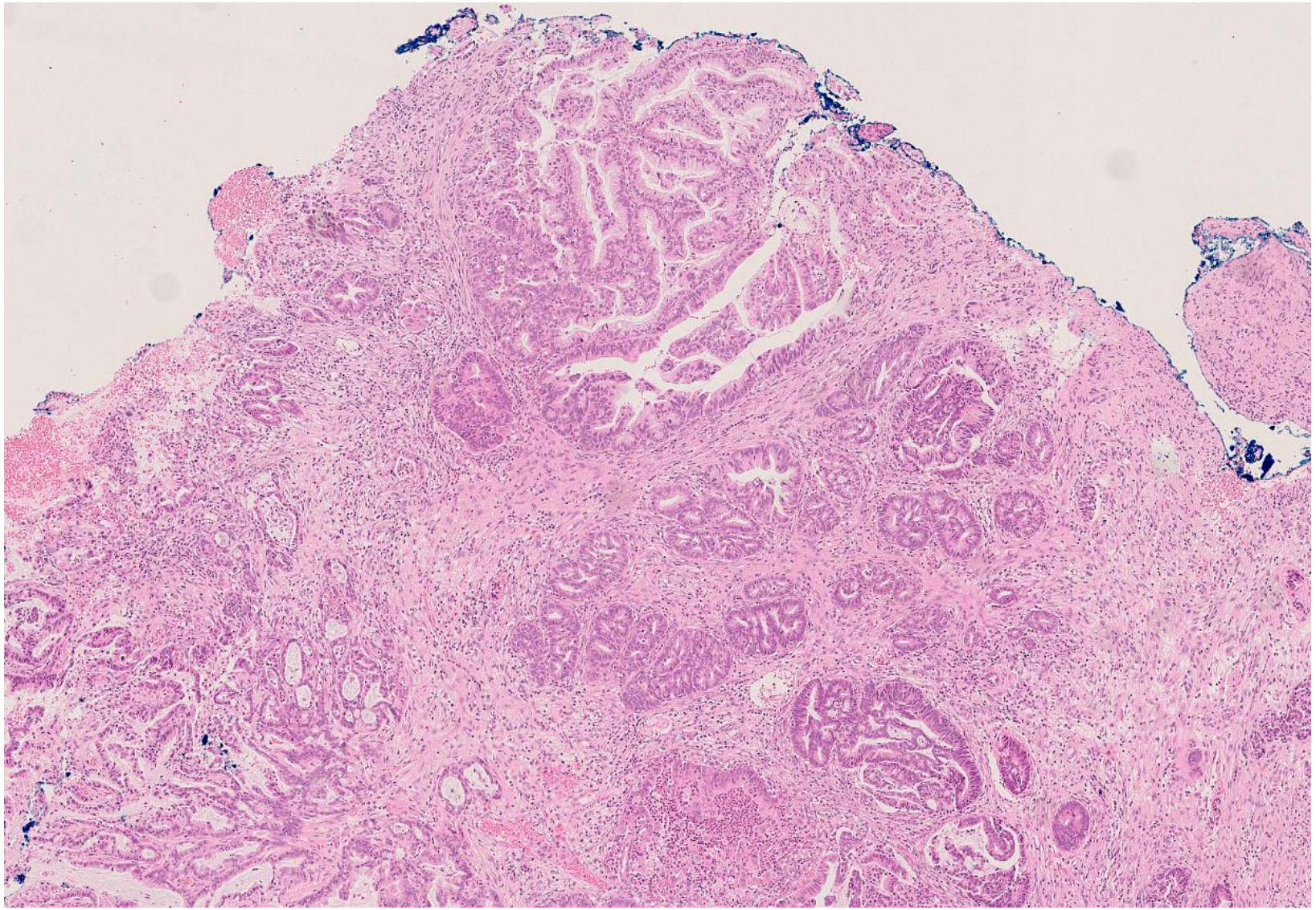

LLETZ 2

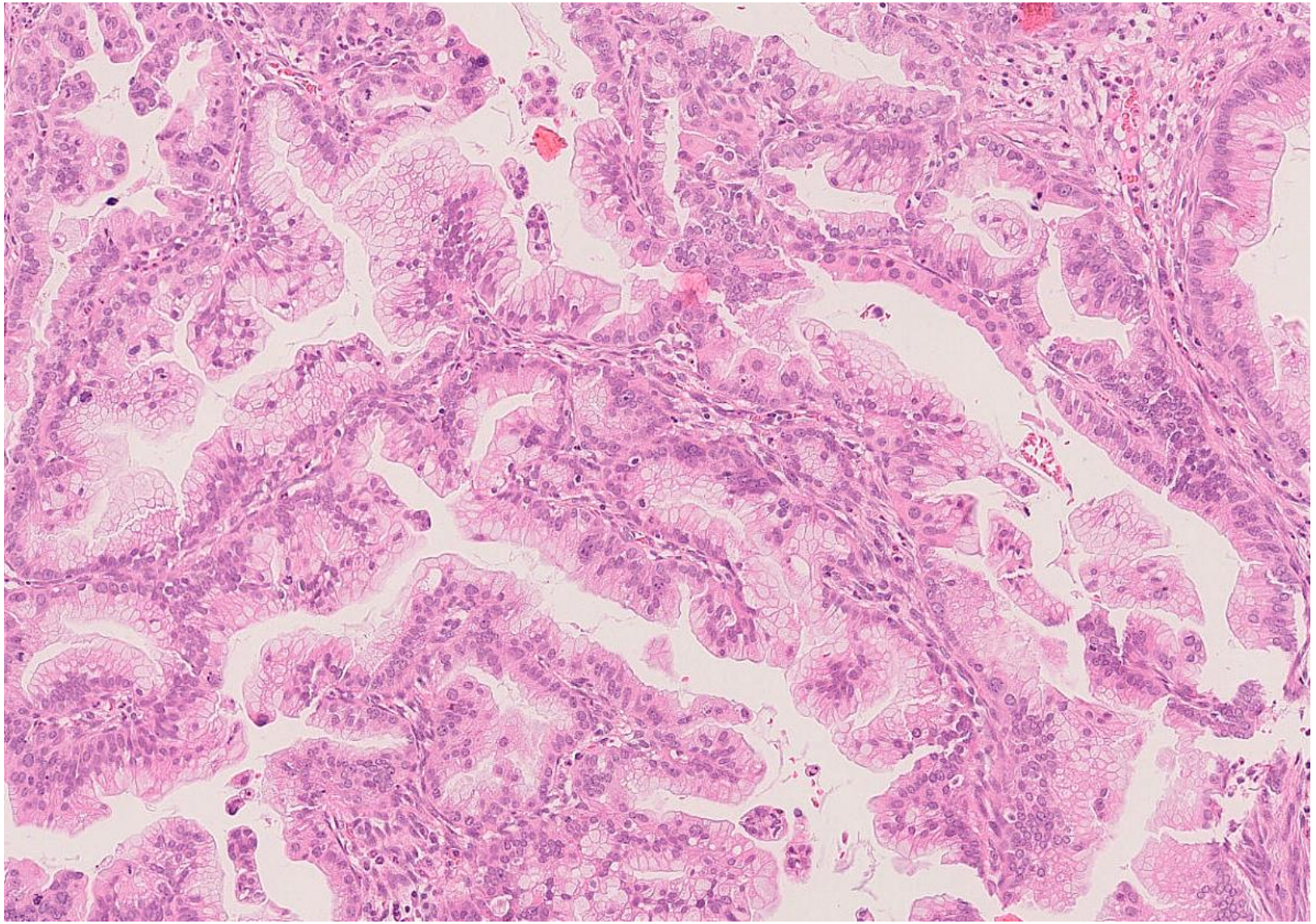

LLETZ 2

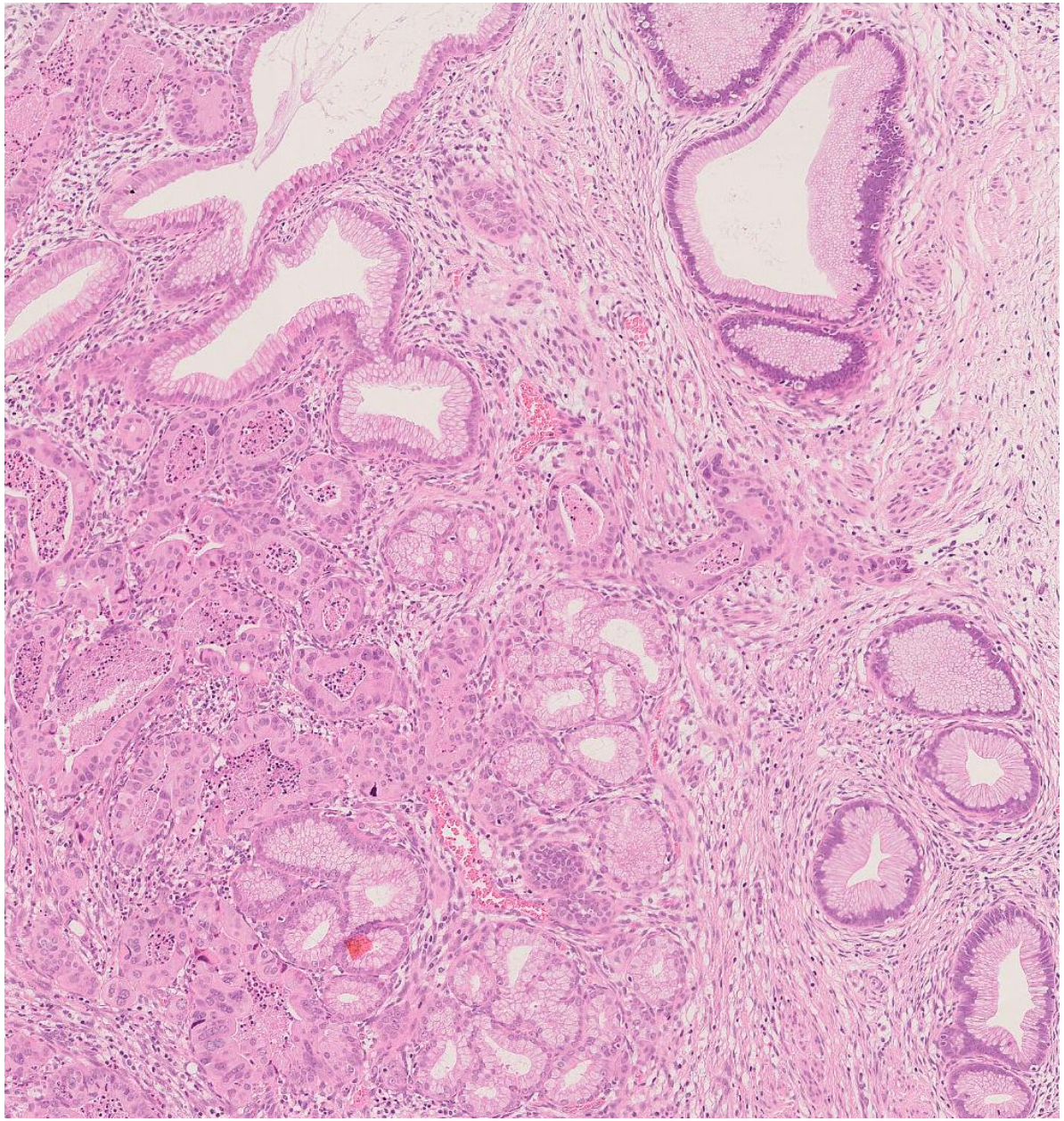

LLETZ 2

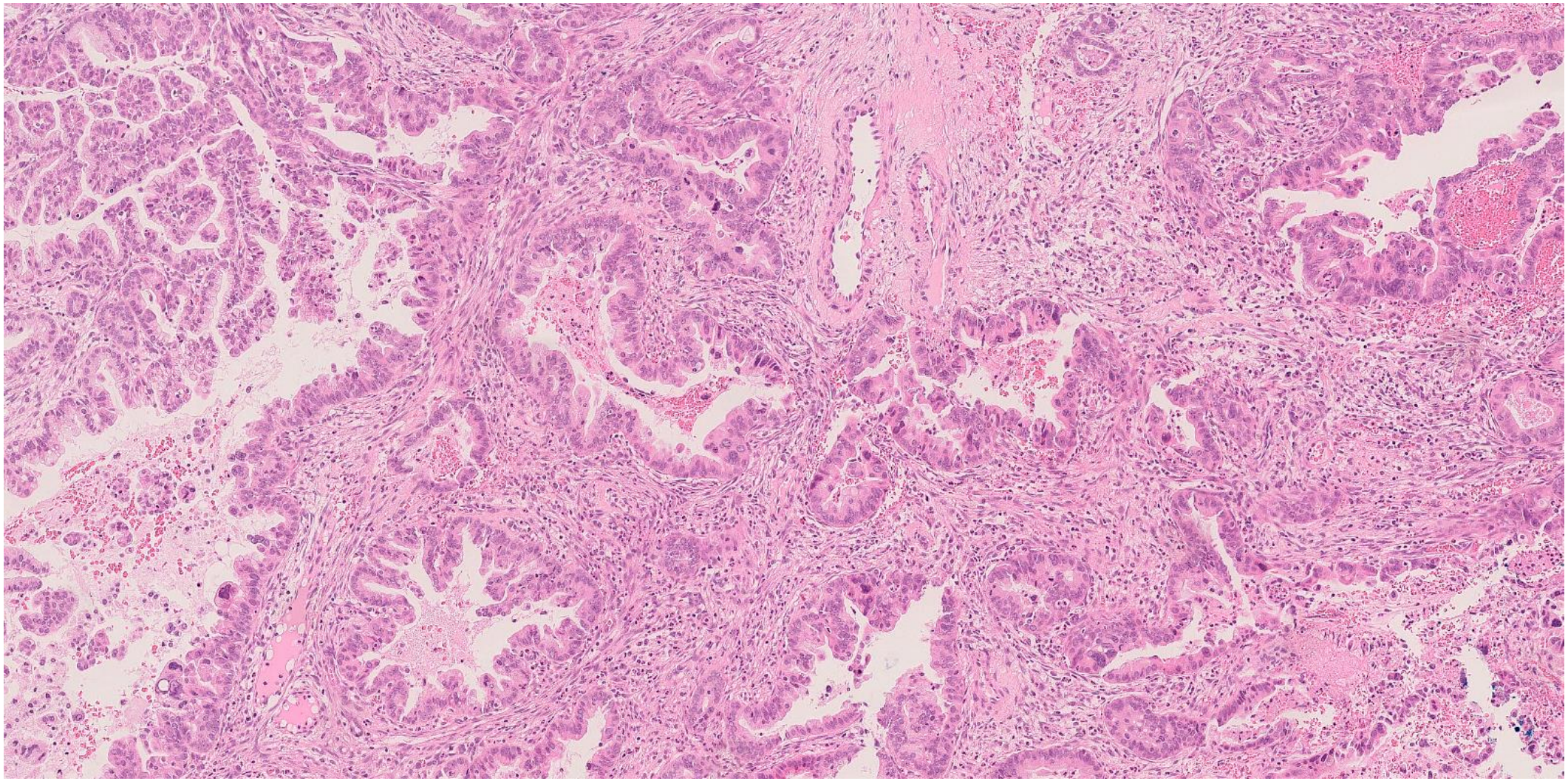

LLETZ 2

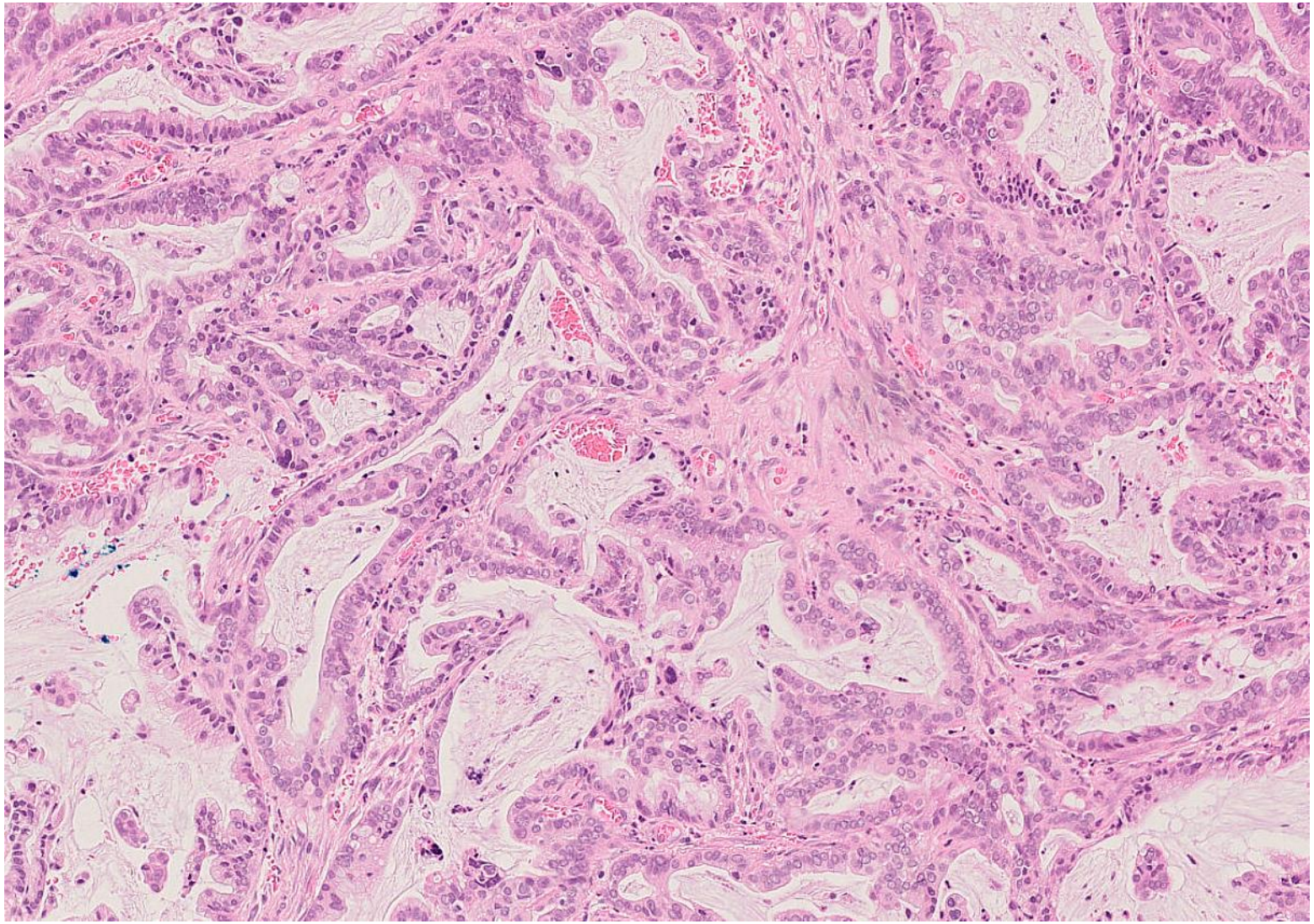

LLETZ 2: Adenocarcinoma, HPV-independent, gastric type, of the uterine cervix

An invasive adenocarcinoma showing gastric (pyloric) differentiation.

It is unrelated to HPV infection.

Patients present with bleeding and watery vaginal discharge.

It accounts for 10-15% of all cervical adenocarcinomas worldwide.

The mean patient age is 50 – 55 years (range 37 – 84 years) – significantly older than for HPV-associated adenocarcinoma (mean patient age 40 – 42 years).

As with their precursor lesions (atypical lobular endocervical glandular hyperplasia and gastric-type adenocarcinoma in situ), they can be associated with germline mutations in STK11 (Peutz-Jeghers syndrome).

The key morphological feature is glandular cells with abundant clear or pale eosinophilic cytoplasm.

LLETZ 2

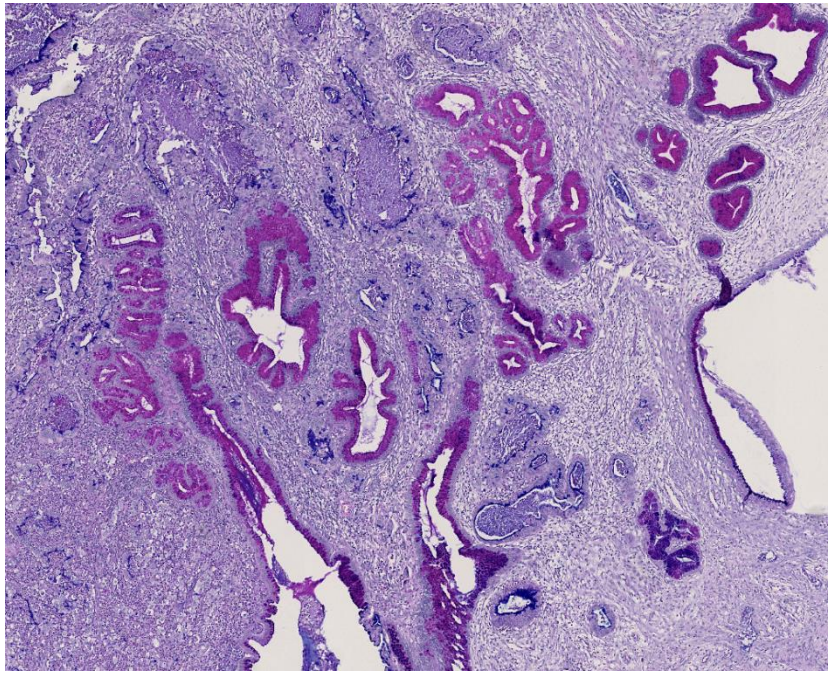

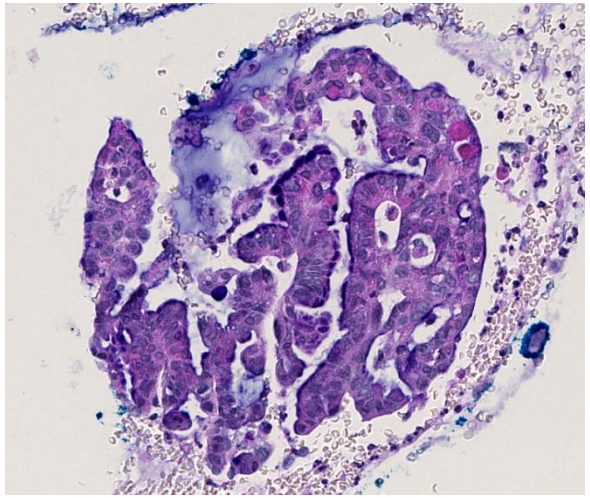

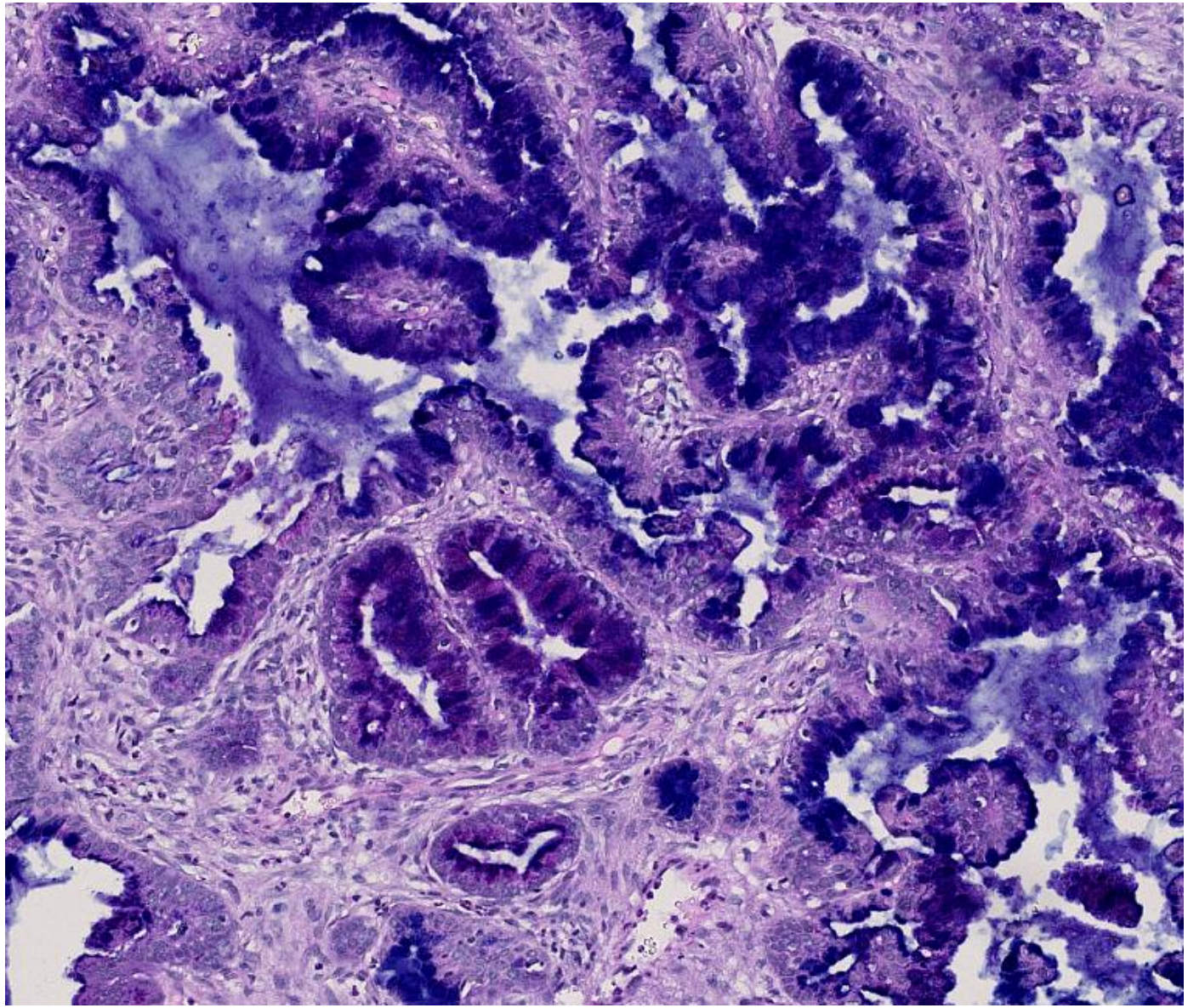

LLETZ 2: Adenocarcinoma, HPV-independent, gastric type, of the uterine cervix

Morphology ranges from extremely well-differentiated adenocarcinoma (‘adenoma malignum’ or ‘minimal deviation adenocarcinoma’ – don’t use these terms!) with deep, haphazard claw-like gland distribution and limited desmoplasia, to poorly-differentiated with irregular glands, small cell clusters, and single cells. Poorly-differentiated glands are lined by cells with variable nuclear changes that include large vesicular nuclei with visible nucleoli, foamy cytoplasm, cuboidal cells with depleted cytoplasm, and goblet cells.

Lymphovascular permeation is common (48% of cases).

LLETZ 2

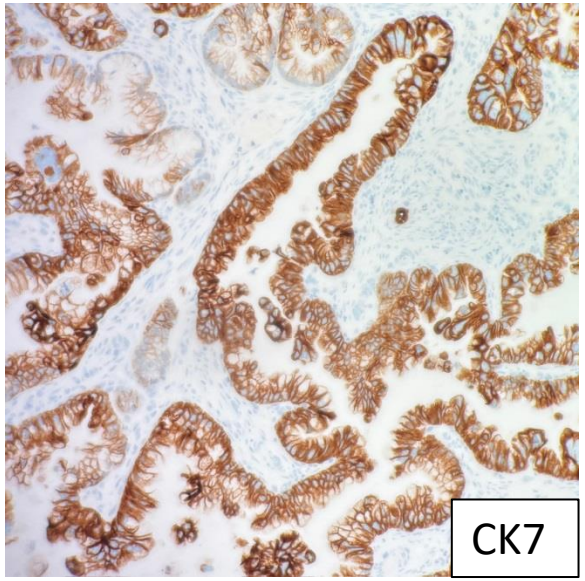

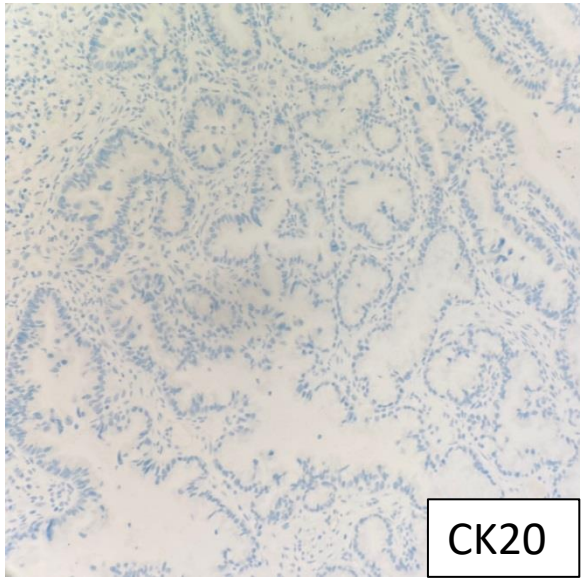

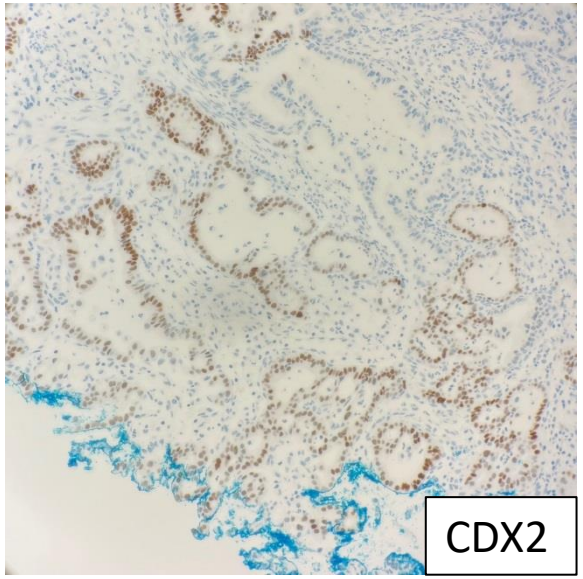

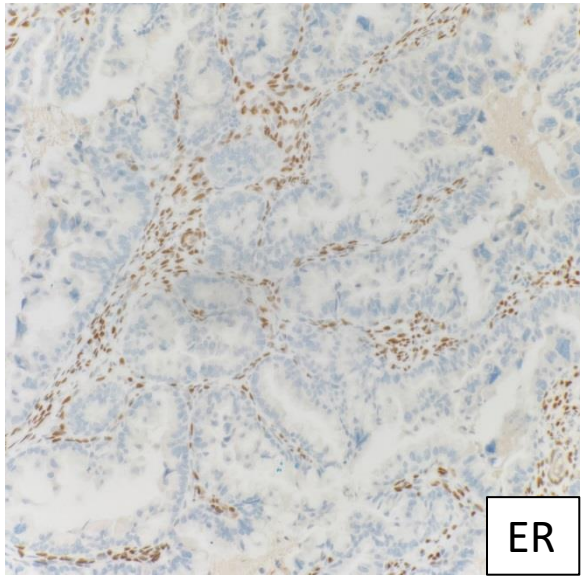

Immunohistochemistry:
Tend to be positive for gastric (pyloric) markers HIK1083 and MUC6. Expression can be focal versus LEGH where staining should be diffuse.

PAX8, CEA, CK7 usually positive.

CK20 and CDX2 can be focally positive.

Loss of PAX2 expression.

ER and PR usually negative.

p16 is either entirely negative or mosaic in most cases *but abnormal, diffuse positive staining can be seen .*

p53 mutant pattern staining (overexpression or null) is seen in ~50% of cases.

LLETZ 2

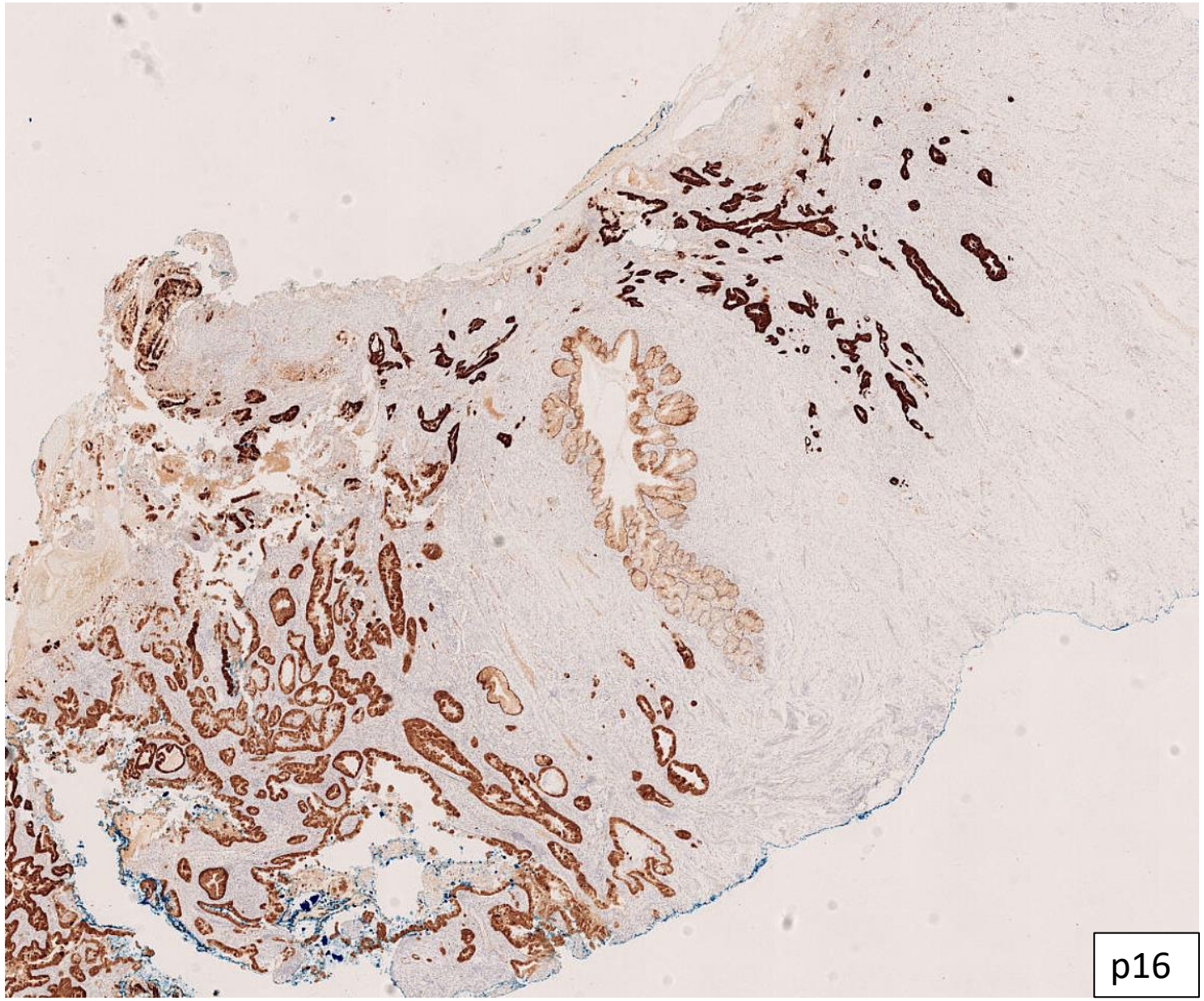

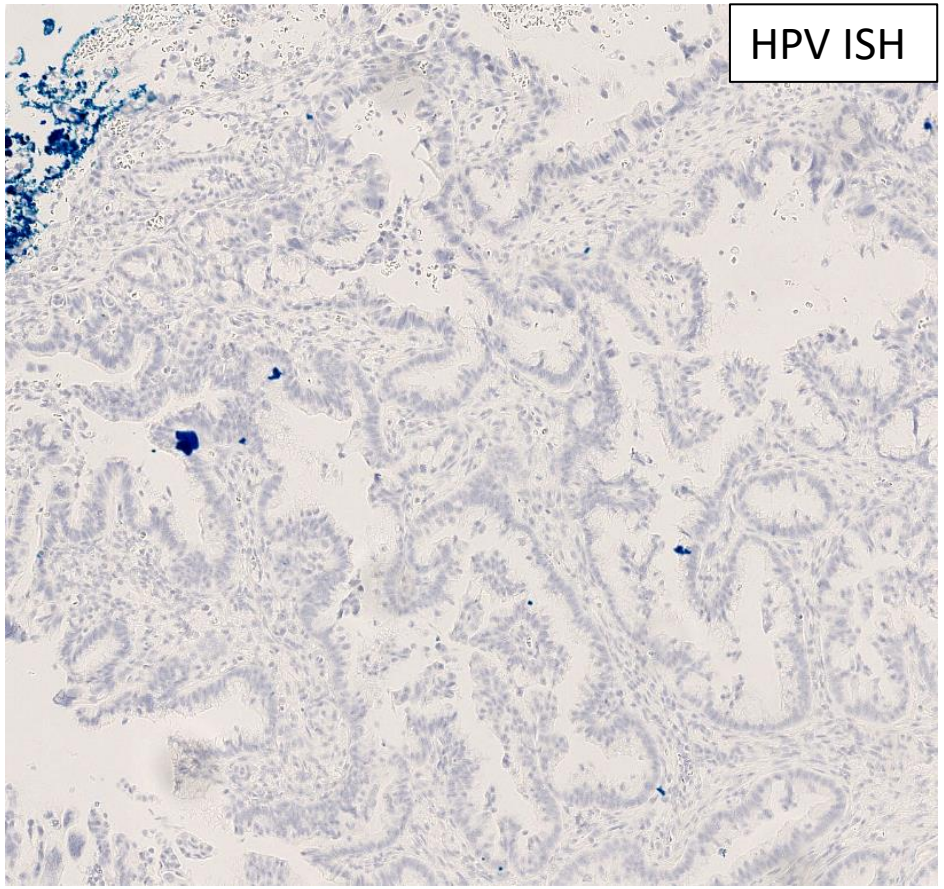

LLETZ 2

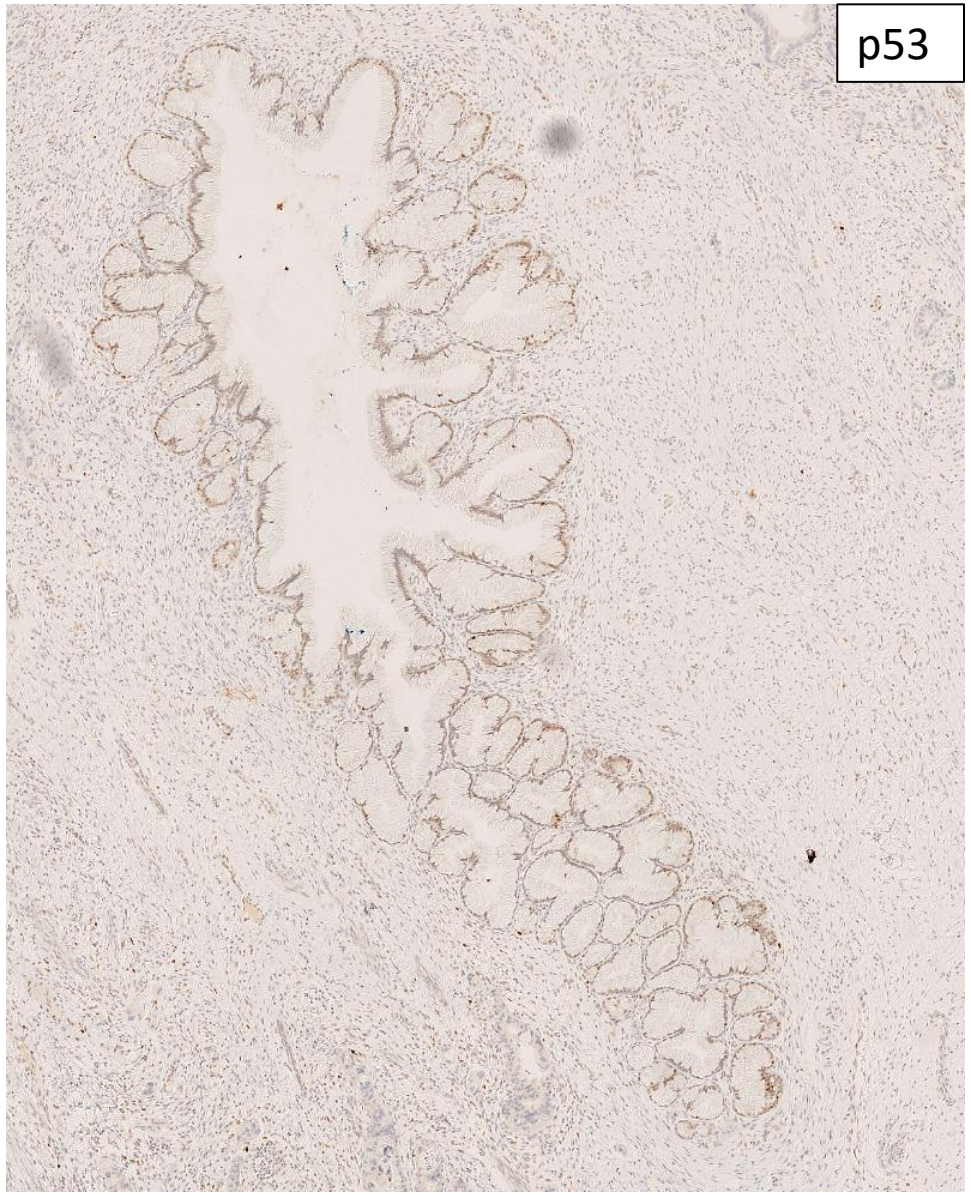

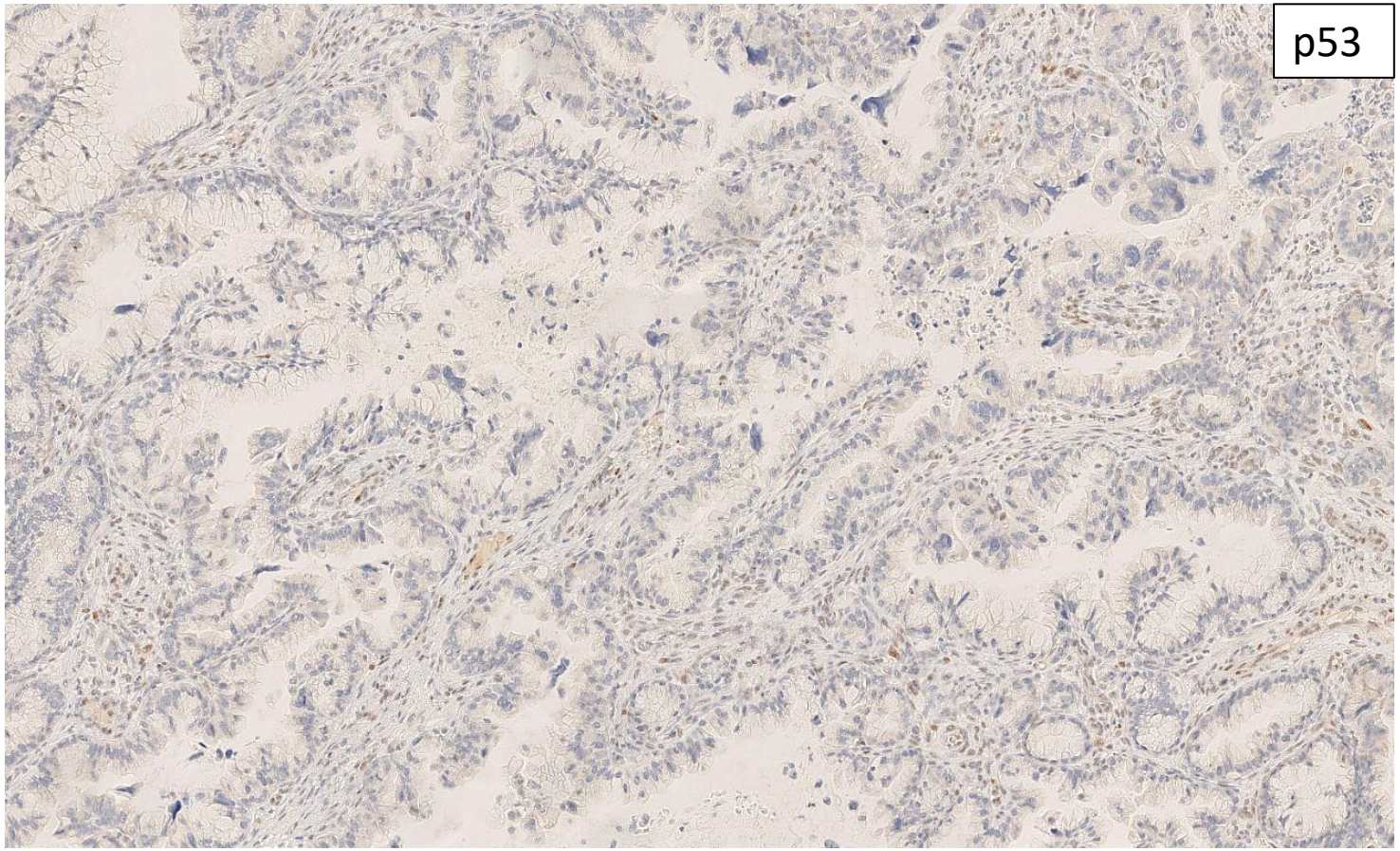

Summary:

This 44 year old woman presented to her GP with watery vaginal discharge. She was found to have an abnormal cervix on MRI and underwent a LLETZ procedure.

In that first LLETZ she was found to have lobular endocervical glandular hyperplasia. The incidence of LEGH with coexistent atypical LEGH is considered to be low (<10%) and the usual recommendation would be that no further intervention is required. However, in this case it was felt that the histological appearances did not match the MRI findings and a further LLETZ procedure was advised.

In the second LLETZ there was an **HPV-independent, gastric-type adenocarcinoma** alongside the full spectrum of precursor lesions to this entity: **Lobular endocervical glandular hyperplasia → Atypical lobular endocervical glandular hyperplasia → HPV-independent adenocarcinoma in situ of the uterine cervix** aka **Gastric-type adenocarcinoma in situ**.

These tumours and their precursors can occur in the context of germline STK11 mutations (Peutz-Jegher syndrome).

Remember, abnormal diffuse expression of p16 doesn't automatically mean HPV-associated. There are other things in the cervix that express p16 (tuboendometrioid metaplasia, a subset of HPV-independent (gastric-type) adenocarcinomas, endometrial carcinomas extending down from the uterine corpus…). Look closely at the morphology and use ancillary techniques – mucin stains, a panel of immunohistochemistry, and HPV in-situ hybridisation.

The British Association of
Gynaecological Pathologists

Questions

